

https://dspace.org/

The effect of implanting various substances into artificially created circumscribed defects in rat femurs

Melcher, A. H.; Irving, J. T.

1963

http://hdl.handle.net/10539/20732

Melcher, A.H, Irving, J.T. 1963. The effect of implanting various substances into artificially created circumscribed defects in rat femurs. Bone & joint journal;45(1):162-75.

Downloaded from a DSpace repository. https://dspace.org/

THE EFFECT OF IMPLANTING VARIOUS SUBSTANCES INTO ARTIFICIALLY CREATED CIRCUMSCRIBED DEFECTS IN RAT FEMURS*

A. H. MELCHER, LONDON, ENGLAND, and J. T. IRVING, BOSTON, UNITED STATES OF AMERICA

From the Joint Council for Scientific and Industrial Research and the Dental Research Unit of the University of the Witwatersrand, South Africa

The literature contains numerous reports on the various implant materials which have been used in attempts to assist the healing of bone (Orell 1937, Urist and McLean 1952, Chase and Herndon 1955, Losee and Hurley 1956*a* and 1956*b*, and Ray and Holloway 1957). This investigation compares the fate and the effect of heterogenous anorganic bone (Losee and Hurley 1956*a* and 1956*b*; Ray and Holloway 1957; Mitchell and Shankwalker 1958; and Hurley, Stinchfield and Zeier 1959), homogenous organic bone (Ray and Holloway 1957), autogenous cancellous bone (Ghormley and Stuck 1934, Bertelsen and Hasner 1950, and Ham 1953) and autogenous compact bone (Abbott, Schottstaedt, Saunders and Bost 1947) on the healing of artificially created circumscribed defects in rat femurs. The natural healing process in this type of defect has been described by Melcher and Irving (1962).

MATERIALS AND METHODS

Heterogenous anorganic bone—This material was obtained by courtesy of Armour and Company Research Division. The chips used were of 20/40 mesh size and had been prepared from the shaft of the bovine femur by extraction with ethylenediamine as described by Losee and Hurley (1956*a*, 1956*b*).

Homogenous organic bone—Femora, tibiae and fibulae were obtained from rats of the same strain as the experimental animals and were immersed in 0·5 M versene (ethylenediamine tetra-acetic acid, pH7·4) at room temperature for two weeks. The versene was changed every two days. When the bones were demineralised they were washed in tap water for twenty-four hours and stored in water at 4 degrees Centigrade.

Autogenous iliac crest—Chips of compact bone were obtained from the crest of the ilium.

Autogenous bone callus—Since Siffert (1955) found that autogenous bone callus and autogenous cancellous bone have a similar effect when used as implant materials, and since there was difficulty in obtaining enough autogenous cancellous bone, it was decided to use autogenous bone callus for implantation. The material was obtained by allowing a bone defect in the left femur to heal for two weeks; the formed callus was then removed and immediately implanted into a defect in the right femur.

TABLE I

Nature of bone implanted	Number of rats
Heterogenous anorganic bone	25
Homogenous organic bone .	20
Autogenous iliac crest . .	20
Autogenous callus . .	12

Method—Seventy-seven albino rats of the Wistar strain, varying in weight from 150 to 400 grammes, were used. Circumscribed defects communicating with the medullary cavity were created in the right and left femora of each animal. Details of the technique have been

* This study forms part of a Dissertation submitted by A. H. M. and approved for the degree of Master of Dental Surgery in the University of the Witwatersrand, Johannesburg.

described previously (Melcher and Irving 1962). Implants of heterogenous anorganic bone, homogenous organic bone, autogenous iliac cortical bone, or autogenous callus, were placed in the defects of the right femora. No implants were placed in the defects of the left femora, which were allowed to heal as ungrafted controls. The animals were killed at periods varying from three days to two months. The rate of healing in the defect of the right femur was compared with that in the control defect of the left femur of the same animal. The number of rats implanted with each material is shown in Table I.

OBSERVATIONS

Because it was found that rats of the same age and weight often show different rates of healing, progress in the grafted defects is described at fixed time periods and conclusions are drawn on the basis of comparison with the controls. Only defects in which there were significant changes are recorded.

HETEROGENOUS ANORGANIC BONE IMPLANTS

Four days after operation—The haematoma in the defect was organised by vascular granulation tissue which had attached itself to the anorganic bone chips and invaded a few of the macrocanals. The chips were pink when stained with haematoxylin and eosin. The stain was not taken up uniformly by the implanted chips but varied in density from chip to chip and in different areas of the individual chips. In some instances parts of the chips were completely unstained.

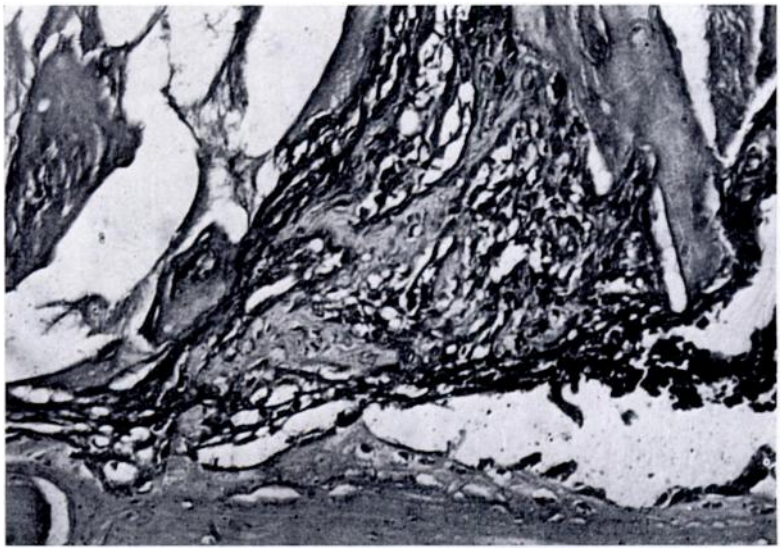

FIG. 1

Four days after operation. Endosteal bone trabeculae are in the process of becoming attached to a chip of heterogenous anorganic bone. The femoral cortex lies in the lower part of the section and the anorganic bone in the upper right quadrant. (Haematoxylin and eosin, × 210.)

The canals of the macrocanalicular system of the anorganic bone remained unstained and were therefore readily recognisable. Bone callus was laid down by cells of the endosteum and some of these trabeculae were becoming attached to an adjacent anorganic bone chip (Fig. 1).

The control defect contained granulation tissue which was more vascular than that in the grafted defect. The endosteal proliferation was not so well advanced as that in the grafted defect but there was evidence of early new bone formation.

Seven days after operation—The development of the endosteal trabeculae varied in different parts of the defect and this unevenness in growth was directly related to the number of anorganic bone chips present. Bone formation appeared to be mechanically obstructed by the chips (Figs. 2 and 3). The proliferating endosteal callus readily gained attachment to adjacent anorganic bone chips and was apparently surrounding them.



FIG. 2
Seven days after operation. The defect, which lies to the right of the section, has been implanted with heterogenous anorganic bone. The proliferation of endosteal callus is being impeded by the implanted chips. (Haematoxylin and eosin, × 40.)

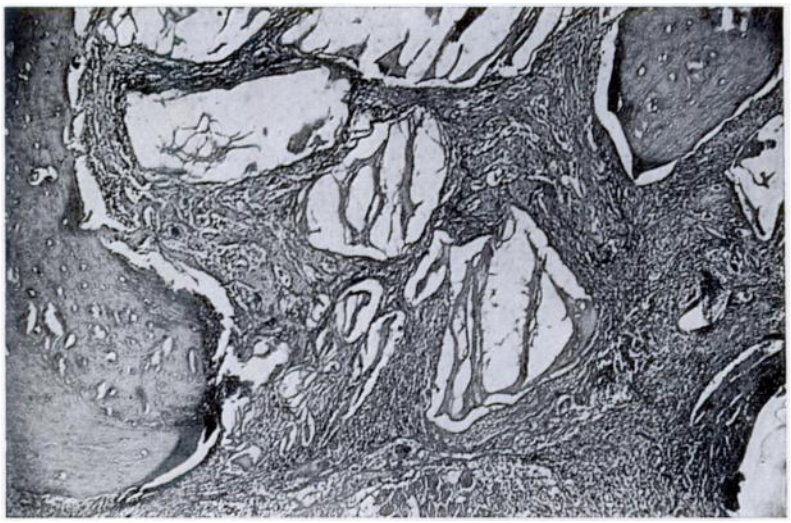

FIG. 3
Seven days after operation. A serial section taken from the same defect as that illustrated in Figure 2. There are fewer implanted chips in the defect than there are in Figure 2, and there is a greater proliferation of endosteal callus. (Haematoxylin and eosin, × 40.)

In the control defect healing was in advance of that seen in the grafted defect. In nearly all the sections the endosteal trabeculae from the opposing margins had fused in the centre and in some areas the callus was proliferating towards the periosteum. Connective tissue fibres in the periosteal aspect of the defect were orientated more regularly than those in the grafted defect.

Eleven days after operation—Many large multinucleated giant cells were seen in relation to the anorganic bone chips lying both in the defect and in the surrounding tissues (Fig. 4). The development of the endosteal callus was inversely related to the number of anorganic bone chips present and varied in different parts of the defect. This observation resembled that in the seven-day sections. In some areas of the defect the implanted chips prevented the endosteal

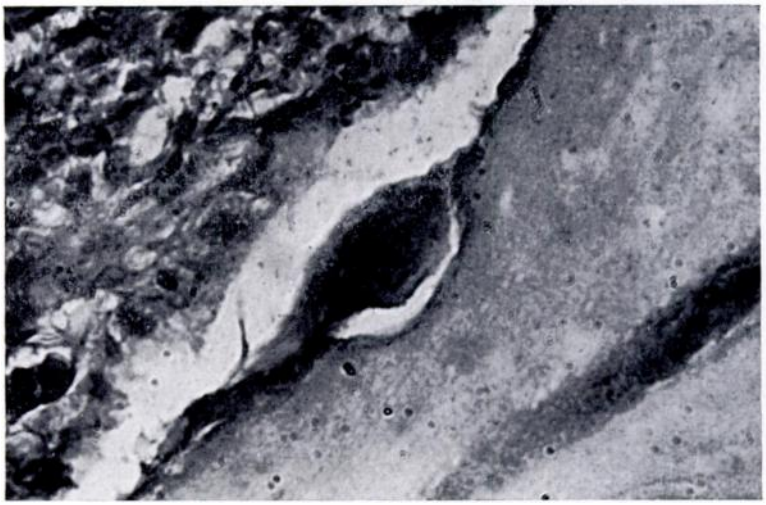

FIG. 4
The right half of this illustration is occupied by anorganic bone. A multinucleated giant cell lies in a lacuna in the implant and it is apparently resorbing the anorganic bone. (Haematoxylin and eosin, ×650.)



FIG. 5
Eleven days after operation. To the left of the defect an anorganic bone chip has prevented the outward proliferation of the endosteal callus. The margin of the defect is covered by callus which is continuous with the subperiosteal callus. (Haematoxylin and eosin, ×40.)

callus from proliferating outwards and parts of the margin of the defect were covered by subperiosteal callus which was developing towards the endosteal trabeculae (Fig. 5).

In the control defect the endosteal callus was more prolific and more mature than that in the grafted defect. There was progress towards the re-establishment of a periosteum over the bone in the defect.

Sixteen days after operation—Throughout the defect it was evident that attempts were being made to vascularise the anorganic bone chips, but revascularisation was not well advanced and many macrocanals did not show any evidence of fibro-endothelial invasion. No example of intracanalicular new bone formation was recognised. There was evidence of removal of anorganic bone by multinucleated giant cells, but not so obviously as in the eleven-day defect.

The development of endosteal callus was inversely related to the number of anorganic bone chips present. Figure 6 illustrates the best developed area of the defect. The callus on the external aspect of the defect was well formed but resorption of the endosteal callus was tardy.

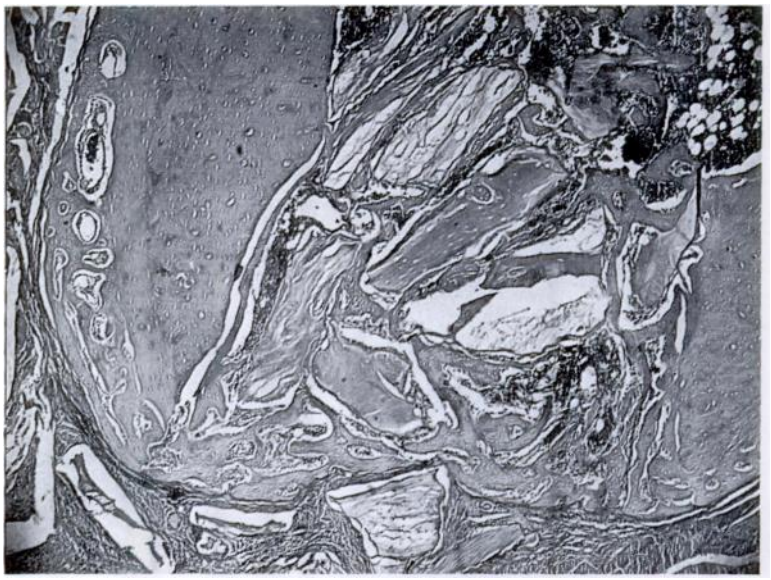

FIG. 6

Sixteen days after operation. The subperiosteal aspect of this defect has been bridged by callus, the development of which has not been impeded by implanted anorganic bone chips. (Haematoxylin and eosin, ×40.)

In the control defect the healing process was far more advanced than in the grafted defect. The periosteal aspect of the defect was completely restored by trabeculae which were continuous with the subperiosteal callus and covered by a well developed periosteum. Removal of endosteal callus was further advanced than in the grafted defect.

HOMOGENOUS ORGANIC BONE IMPLANTS

Six days after operation—The endosteal trabeculae had gained attachment to the organic bone grafts which were eosinophilic (Fig. 7). Vascularisation of the implants was taking place rapidly, and although the organic bone was apparently being removed no multinucleated giant cells could be seen. The organic bone chips seemed to hinder proliferation of the endosteal trabeculae, and callus was best developed in the areas where there were not many implanted chips.

Control defect—Nine-tenths of this defect was filled with endosteal callus. Healing was far in advance of that in the grafted defect.

Nine days after operation—Endosteal callus was being developed rapidly and had attached itself to some of the implanted chips. It was clear however that the organic bone was a hindrance to the development of the bone trabeculae. They were unable to circumnavigate the grafted chips and had not fused in the centre-line. The margin of the defect was covered by proliferating subperiosteal callus (Fig. 8).

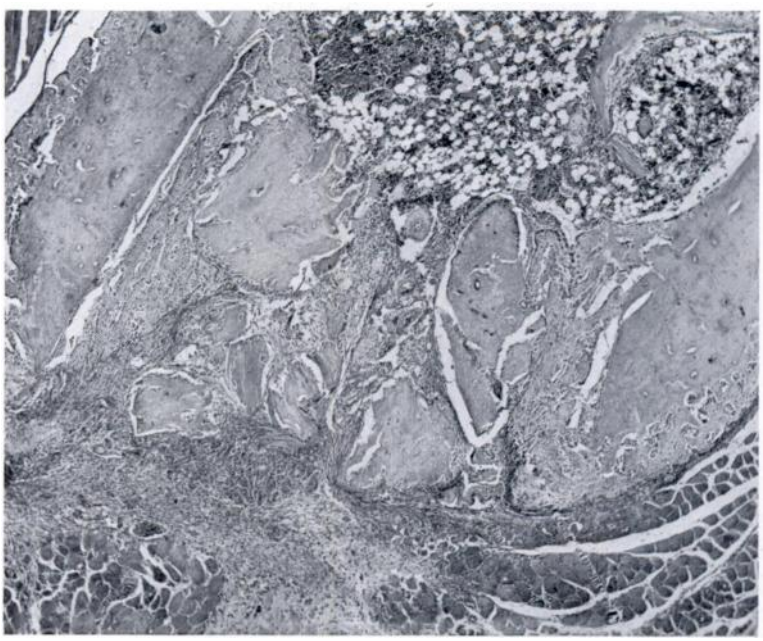

FIG. 7

Six days after operation. Homogenous organic bone has been implanted into the defect. The proliferating endosteal trabeculae are gaining attachment to the organic bone. (Haematoxylin and eosin, × 40.)

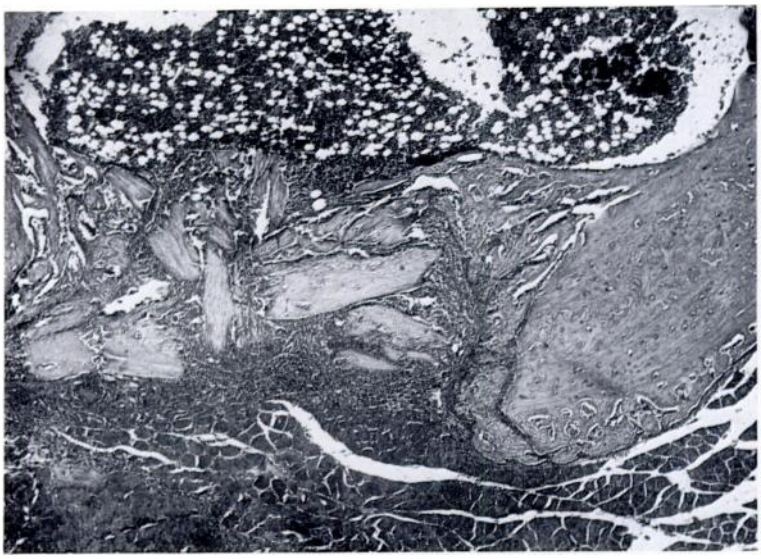

FIG. 8

Nine days after operation. The endosteal callus has not bridged the medullary aspect of the defect and this has apparently resulted from the presence of organic bone chips. The wall of the defect to the right of the photomicrograph is covered by callus which appears to be continuous with the subperiosteal callus. (Haematoxylin and eosin, × 40.)

The most striking feature of these sections was the presence of large numbers of eosinophilic multinucleated giant cells which were applied to the surface of the organic bone chips and were clearly concerned with their removal. Some of these cells were enormous, with from fifteen to twenty nuclei (Fig. 9). Removal of the organic bone chips and their colonisation by vascular connective tissue was well advanced.

In the control defect the healing process was far in advance of that in the grafted defect and removal of the endosteal callus had been started.

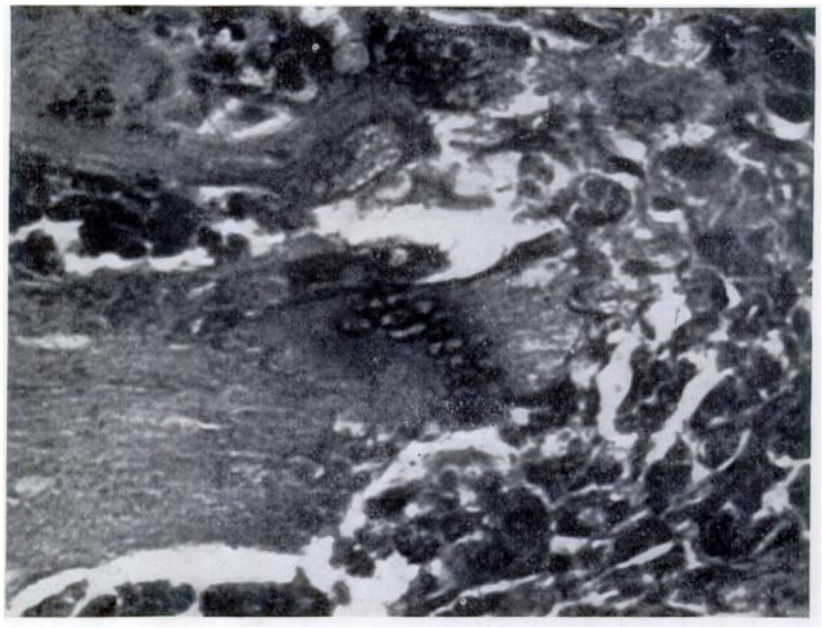

FIG. 9

Nine days after operation. In the centre of the field is a large multinucleated giant cell which is lying in intimate association with an implanted organic bone chip to the left of it. (Haematoxylin and eosin, ×650.)

Twelve days after operation—The organic bone had hindered attempts of the endosteal trabeculae to fill the defect. The endosteal aspect of the defect had been bridged and many endosteal trabeculae, originating from the region of the defect, were proliferating into the medullary cavity so that the callus had no clear-cut endosteal border. There was evidence however of early resorption of this deep callus. In no part of the section was the periosteal aspect of the defect closed. The organic bone was well vascularised and was being removed rapidly. Multinucleated giant cells were found in relation to the chips. The bone trabeculae had fused with the implants in many places and were proliferating slowly along their surfaces (Fig. 10). All the host callus appeared to be continuous with the endosteal and periosteal proliferation. The organic bone did not appear to have induced new bone formation. In some places the surfaces of the implanted chips were covered with osteoblasts, but these were continuous with osteoblasts covering adjacent trabeculae.

The control defect was filled with callus. The periosteal aspect was clearly sealed and well defined. The periosteum over the defect was being reconstructed and was continuous with the pre-existing periosteum. The process of resorption of endosteal callus was more advanced in some areas than in others.

Twenty-one days after operation—Marked resorption of the medullary callus had occurred. There had been little resorption of the organic bone, and the implants had seriously interfered with callus formation (Fig. 11).

In the control defect removal of the endosteal callus was well advanced. The callus on the periosteal aspect of the defect was being remodelled and was more mature than in the grafted defect.

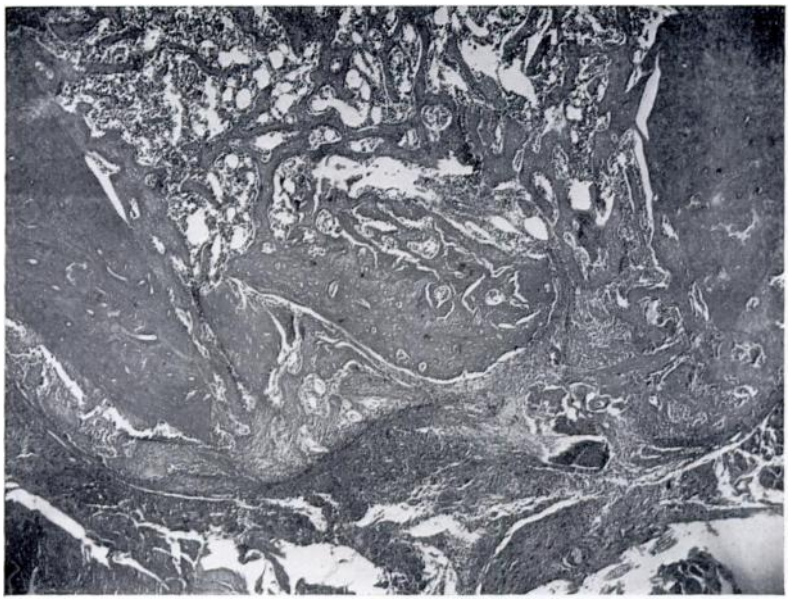

FIG. 10

Twelve days after operation. The endosteal callus, which is proliferating into the medullary cavity, is well attached to the implanted organic bone chips. Resorption of the medullary aspect of the callus has been initiated. (Haematoxylin and eosin, ×40.)



FIG. 11

Twenty-one days after operation. The development of the healing callus is very poor and appears to have been hindered by the implanted organic bone chips. (Haematoxylin and eosin, ×40.)

IMPLANTS OF COMPACT BONE FROM THE ILIAC CREST

Nine days after operation—The implanted bone chips were stained pink and were necrotic as shown by empty lacunae. Vascularisation of the chips was evident, and they were being removed by multinucleated giant cells. Osteoblasts were seen to cover the borders of many

of the chips but they appeared to be continuous with, and to have originated from, the osteoblasts which covered the endosteal trabeculae.

The endosteal trabeculae had fused with the implanted chips and in many sections fusion between the endosteal and periosteal proliferations had taken place. The extent to which the

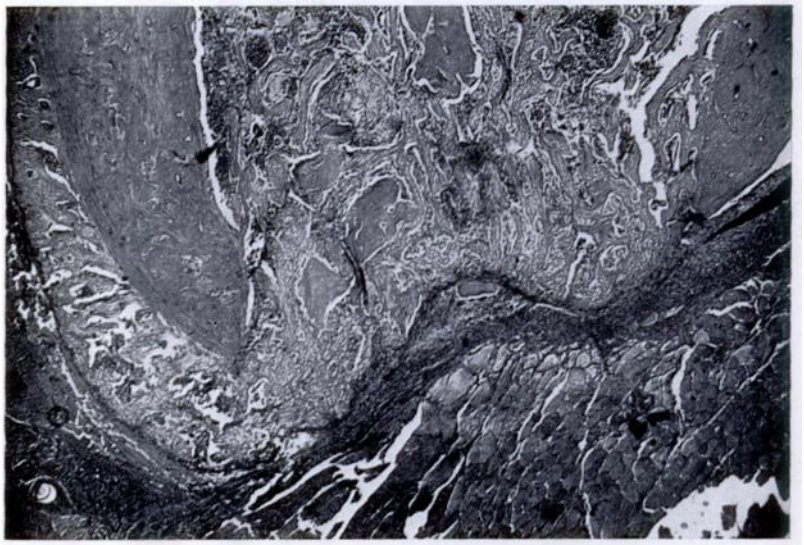

FIG. 12

Nine days after operation. There are few implanted chips of autogenous compact bone in this part of the defect, and the bony callus is well developed. (Haematoxylin and eosin, ×40.)

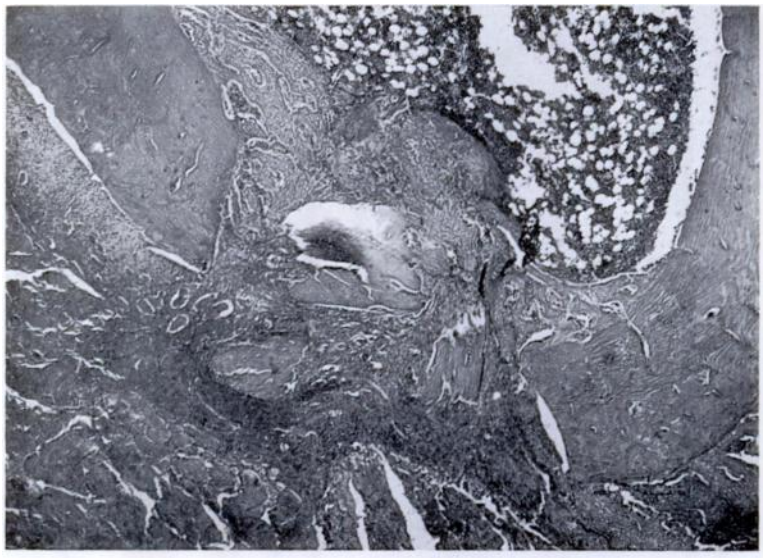

FIG. 13

Nine days after operation. A section taken from a part of the defect different from that illustrated in Figure 12. The autogenous compact bone chips are larger than those in Figure 12 and the development of the bony callus is poorer. (Haematoxylin and eosin, ×40.)

defect had been repaired by new bone appeared to be dependent upon the number and size of the implanted chips. In Figure 12 there were few chips and the defect was almost completely filled with endosteal callus while in a different part of the lesion (Fig. 13) the implanted chips were bulky and more numerous, and the callus formation was not nearly so well advanced.

It seems likely that the development of the callus was hindered by the bone grafts. The formation of a periosteum over the healing callus was not observed in any of the sections.

The control defect was filled with callus which appeared to be far more mature than that in any of the sections taken from the grafted defect. There was evidence that the connective tissue overlying the healing defect was condensing to form a periosteum.

Twelve days after operation—In this defect the periosteum was being developed over the healing callus in areas where the implanted chips had not interfered with the formation of the bone trabeculae. Many of the implanted chips appeared to have given rise to the formation of new bone on their surfaces, but serial sections disclosed that all new bone formation in the defect originated from the host callus (Fig. 14).

In the control defect the rate of healing was similar to that which occurred in the grafted defect.



FIG. 14

Twelve days after operation. There is no implanted compact bone in the peripheral aspect of the defect which is filled with well developed bony callus. (Haematoxylin and eosin, × 40.)

Three weeks after operation—The periosteal aspect of the defect was sealed with callus and the new overlying periosteum was well defined. The implanted chips were surrounded by callus and could be recognised as solid blocks of bone devoid of osteocytes lying in the body of the host trabeculae. In some places perivascular resorption of both callus and graft was taking place and these areas were being replaced by host bone. No multinucleated giant cells were recognised in these sites. Resorption of the medullary aspect of the callus appeared to have almost ceased. The implant, however, appeared to be more resistant to the resorptive process than did the healing callus.

Control defect—The periosteal aspect of the defect was sealed by callus and the newly formed overlying periosteum was well differentiated. The callus was more mature than that seen in the grafted defect.

IMPLANTS OF AUTOGENOUS CALLUS

Six days after operation—The defect was filled with immature coarse fibrillar trabeculae. The implanted chips stained a little more brightly than did the host trabeculae. Most of them were devoid of osteocytes, but an occasional viable osteocyte could be recognised. All the chips had gained attachment to the host callus and had become surrounded by it. The development of the host callus did not appear to have been hindered in any way by the implanted chips (Fig. 15). Examination of the serial sections from the defect revealed that the covering cells of the grafted chips had unquestionably been responsible for the production of new bone (Fig. 16).

Control defect—The progress of the healing in the control defect was similar to that seen in the grafted defect.

Eighteen days after operation—The periosteal aspect of the defect had been sealed by host callus and the overlying connective tissue was condensing to form a periosteum.

The trabeculae were of mature appearance and were covered by osteoblasts which seemed to be very active. In the periosteal aspect of the defect the implanted chips of callus could

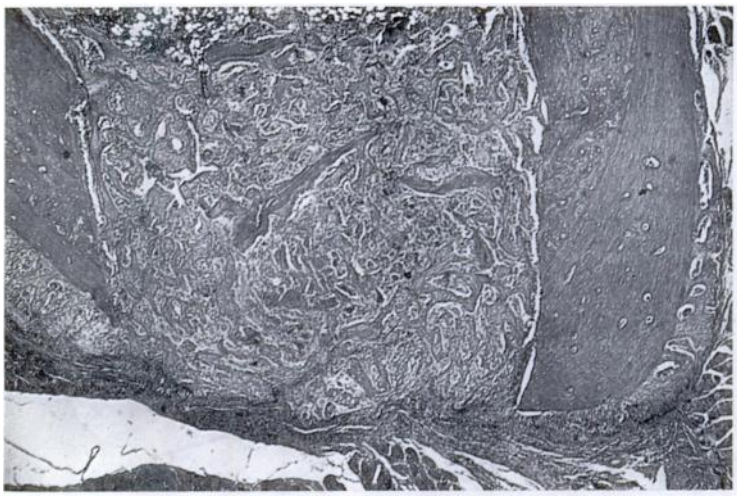

FIG. 15
Six days after operation. Autogenous bone callus chips have been implanted into the defect and these appear darker than the proliferating bone trabeculae which fill the defect. The implanted chip in the centre of the defect is illustrated in Figure 16. (Haematoxylin and eosin, ×40.)

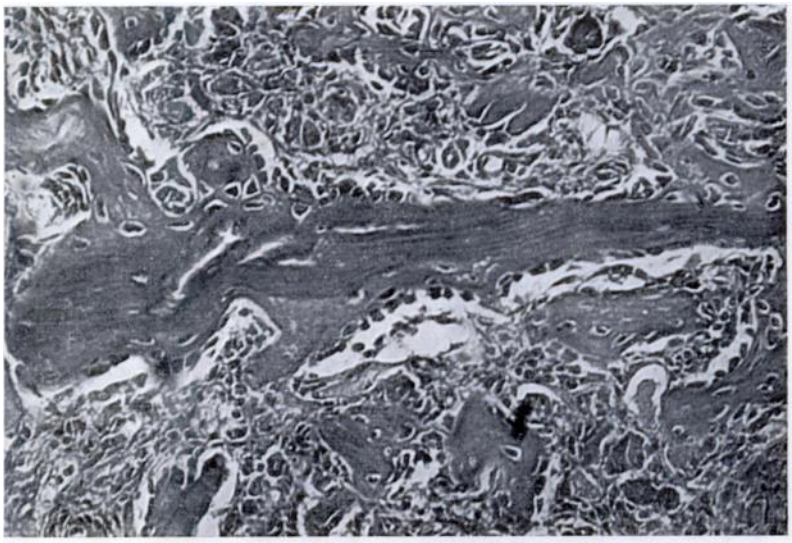

FIG. 16
Six days after operation. A higher magnification of the implanted autogenous callus chip lying in the centre of the defect in Figure 15. The new bone being developed on the lower aspect of the implant has arisen from osteogenic cells of the implant. (Haematoxylin and eosin, ×210.)

be recognised as areas of bone devoid of osteocytes, embedded in the host trabeculae. Progressive vascularisation of the implant was evident. Resorption of the medullary aspect of the host callus was well advanced but the implanted callus chips appeared to be comparatively resistant and they, together with some of the host callus covering them, projected into the medullary cavity from the callus in the periosteal aspect of the defect (Fig. 17).

Control defect—The progress of healing in the control defect was very like that in the grafted defect, but the bone trabeculae of the callus in the control defect were of more mature appearance.

DISCUSSION

The fact that heterogenous anorganic bone can take up histological stain after the block of tissue has been decalcified, and that it does not appear as a void in the histological section, has been explained by Lyon (1958) on the grounds that the implanted chips are permeated by " tissue juices " which gel, and that after decalcification these form a " mask " of the chips and take up the stain. We believe that anorganic bone always contains a small quantity of organic material and that it is this which is stained. This interpretation is supported by the fact that areas of the chips often remain unstained and appear as voids. These areas are

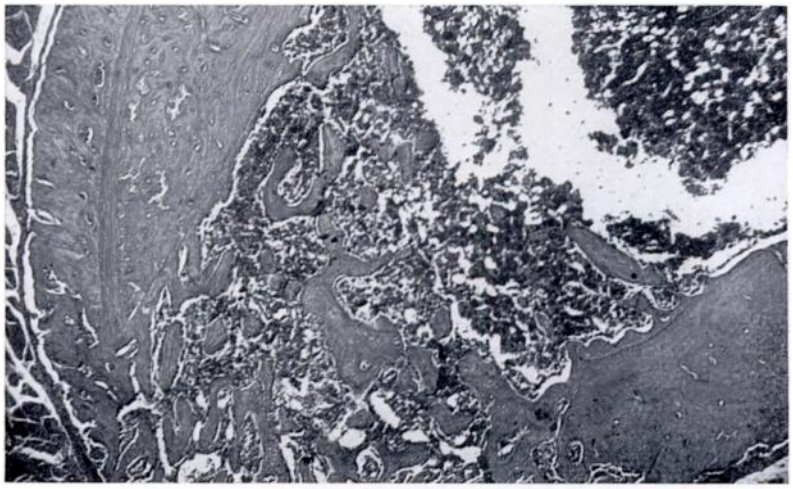

FIG. 17
Eighteen days after operation. The healing of the defect is well advanced. Two unresorbed implanted autogenous callus chips are lying in the medullary cavity; one a little beneath the centre of the field and the other to the right of the field. (Haematoxylin and eosin, × 40.)

seldom situated centrally; they are generally continuous with a margin, suggesting that they are small regions from which all organic material has been removed during the preparation of the anorganic bone.

Losee and Hurley (1956*a*, 1956*b*) claimed that anorganic bone is rapidly invaded by host connective tissue. This has not been substantiated by the present investigation, nor by that carried out by Ray and Holloway (1957). On the other hand organic bone, autogenous compact bone and autogenous cancellous bone are readily colonised by host fibro-endothelial elements.

It is apparent from this investigation that all the implant materials act as a physical obstacle to the normal proliferation of bone trabeculae. Although the implants are readily accepted by the host and soon become attached to and incorporated in the developing callus, this interference with normal development slows healing when compared with that of ungrafted control defects. Some of these findings confirm the views of Ray and Holloway (1957) and Mitchell and Shankwalker (1958) on the effect of implanting anorganic bone into a healing bone defect. It is noteworthy that where anorganic bone and organic bone implants obstructed the endosteal proliferation to such an extent that it was unable to develop into the outer part of the defect, the subperiosteal callus proliferated across the defect wall towards the endosteal callus. The subperiosteal callus never behaved in this manner in ungrafted defects (Melcher and Irving 1962).

The osteocytes of the implanted compact bone do not appear to survive the operation but a few of the superficial osteocytes of the callus grafts do apparently remain viable.

Autogenous callus is the only one of the materials investigated which appears to be able to function as a centre of osteogenesis. New bone is developed by the covering cells of the implant. It is not possible to determine from these experiments whether the implant induced any of the cells of the fibrous callus to modulate to osteoblasts and to lay down new bone. But when the healing rate in the grafted defects is compared with that in the control defects it is apparent that the new bone developed by the graft has not resulted in any shortening of the healing time. It is thought that these additional centres of osteogenesis do no more than compensate for the delay in healing caused by the obstruction of the implant material to the normal development of the trabeculae. It is perhaps also true that the greatest benefit that is bestowed by a graft on the healing process in a circumscribed defect is derived from its osteogenic cells and the new bone which they lay down, but that the substance of the graft is in itself a hindrance. The view of Hutchison (1952) that the empty lacunae of viable autografts are repopulated by the emigration of osteoblasts modulated from proliferating endosteal cells was not confirmed. On the basis of these results, fresh autogenous callus or cancellous bone is superior to fresh autogenous cortical bone.

It is not always possible to use fresh autogenous cancellous bone for grafting purposes and a good preserved substitute might, at times, be desirable. Heterogenous anorganic bone has been advocated for this purpose, and many claims have been made in its favour. This investigation indicates that, while it is readily accepted by host tissues, it is very slowly absorbed and replaced by host bone and it acts as a formidable barrier to new bone development. On the other hand, whereas homogenous organic bone does hinder new bone formation, it is removed comparatively rapidly and replaced by host trabeculae. On the basis of this investigation, homogenous organic bone is superior to heterogenous anorganic bone as a material for grafting into defects when strength is not required. This conclusion supports the views of Ray and Holloway (1957). Mitchell and Shankwalker (1958) found that untreated defects heal better than those grafted with various non-viable materials. Their contention is supported by the results of this investigation.

Two significant findings arise out of this investigation. In a circumscribed defect the implantation of viable osteogenic cells is of the greatest value in assisting healing. On the other hand, the grafting of the intercellular substance of bone, whether it is fresh or processed, hinders rather than assists bone repair. This conclusion cannot be applied to the healing of bone wounds where there has been a loss of continuity and where it is necessary to provide a scaffolding along which the proliferating host trabeculae can be guided from one fragment to the other.

Removal of implanted materials—This investigation has shown that multinucleated giant cells, possibly osteoclasts, are associated with the removal of autogenous callus, autogenous compact bone, heterogenous anorganic bone and homogenous organic bone.

Multinucleated giant cells are associated with the removal of organic bone but they do not remove osteoid. It is thought that when bone is calcified a change takes place in the matrix and that this determines whether or not giant cells will attack the tissue. Thus osteoid, which has never been calcified, will not be attacked, whereas organic bone, the matrix of which has been previously calcified, will be removed. Anorganic bone does contain some organic matrix and the material is consequently attacked by giant cells, but the small quantity of organic matrix that is present may be responsible for its tardy removal. The finding that the removal of anorganic bone is associated with the presence of multinucleated giant cells is in direct conflict with the views of Losee and Hurley (1956*a*) who maintained that these cells do not play any part in this process.

SUMMARY AND CONCLUSIONS

1. The effect of implanting heterogenous anorganic bone, homogenous organic bone, autogenous compact bone from the iliac crest, and autogenous bony callus into circumscribed defects in the femur of albino rats of the Wistar strain is described.

2. Neither heterogenous anorganic bone nor homogenous organic bone appeared to induce new bone formation in a healing defect.
3. Some of the osteogenic cells of autogenous callus implants survived transplantation to a bone defect and gave rise to new bone formation. This did not occur when compact bone from autogenous iliac crest was implanted.
4. Implants of autogenous callus, autogenous compact bone, homogenous organic bone and heterogenous anorganic bone all impeded the normal development of host bone trabeculae in a healing bone defect, seemingly because they acted as physical barriers to the proliferating host callus. None of the implant materials appeared to suppress the healing reaction of the host.
5. Implanted homogenous organic bone was removed and replaced by host bone more quickly than was implanted heterogenous anorganic bone, and it appears to be the better material for grafting into bone defects.
6. Autogenous callus or autogenous cancellous bone is a superior implant material to autogenous compact bone and is the bone graft material of choice.
7. The absorption of all the implant materials used in this investigation was associated with the presence of multinucleated giant cells.
8. The activity of multinucleated giant cells may be influenced by the organic matrix of the material which is to be absorbed.
9. Except when fresh autogenous callus was implanted into the defects, the rate of healing in the grafted defects was slower than that in the control defects. In the defects grafted with fresh autogenous callus the healing rates of the control and grafted defects were the same.

REFERENCES

ABBOTT, L. C., SCHOTTSTAEDT, E. R., SAUNDERS, J. D. De C. M., and BOST, F. C. (1947): Evaluation of Cortical and Cancellous Bone as Grafting Material. A Clinical and Experimental Study. *Journal of Bone and Joint Surgery*, **29**, 381.

BERTELSEN, A., and HASNER, E. (1950): On Transplantation of Cancellous Bone from the Iliac Crest. *Acta Orthopaedica Scandinavica*, **19**, 481.

CHASE, S. W., and HERNDON, C. H. (1955): The Fate of Autogenous and Homogenous Bone Grafts. A Historical Review. *Journal of Bone and Joint Surgery*, **37-A**, 809.

GHORMLEY, R. K., and STUCK, W. G. (1934): Experimental Bone Transplantation with Special Reference to Effect of " Decalcification." *Archives of Surgery*, **28**, 742.

HAM, A. W. (1953): *Histology*. Second edition. London: Pitman Medical Publishing Co. Ltd.

HURLEY, L. A., STINCHFIELD, F. E., and ZEIER, F. G. (1959): Presented at National Meeting of the American Academy of Orthopaedic Surgeons. Chicago. January 25th.

HUTCHISON, J. (1952): The Fate of Experimental Bone Autografts and Homografts. *British Journal of Surgery*, **39**, 552.

LOSEE, F. L., and HURLEY, L. A. (1956*a*): *U.S. Naval Medical Research Institute Progress Report*. NM. 004.006.0901.

LOSEE, F. L., and HURLEY, L. A. (1956*b*): Bone Treated with Ethylenediamine as a Successful Foundation Material in Cross-Species Bone Grafts. *Nature*, **177**, 1,032.

LYON, H. W. (1958): *Personal communication.*

MELCHER, A. H., and IRVING, J. T. (1962): The Healing Mechanism in Artificially Created Circumscribed Femoral Defects in the Albino Rat. *Journal of Bone and Joint Surgery*, **44-B**, 928.

MITCHELL, D. F., and SHANKWALKER, G. B. (1958): Osteogenic Potential of Calcium Hydroxide and Other Materials in Soft Tissue and Bone Wounds. *Journal of Dental Research*, **37**, 1,157.

ORELL, S. (1937): Surgical Bone Grafting with " Os Purum," " Os Novum " and " Boiled Bone." *Journal of Bone and Joint Surgery*, **19**, 873.

RAY, R. D., and HOLLOWAY, J. A. (1957): Bone Implants. Preliminary Report on an Experimental Study. *Journal of Bone and Joint Surgery*, **39-A**, 1,119.

SIFFERT, R. S. (1955): Experimental Bone Transplants. *Journal of Bone and Joint Surgery*, **37-A**, 742.

URIST, M. R., and MCLEAN, F. C. (1952): Osteogenetic Potency and New-Bone Formation by Induction in Transplants to the Anterior Chamber of the Eye. *Journal of Bone and Joint Surgery*, **34-A**, 443.