

https://dspace.org/

Extremity fasciotomy in the developing world setting a South African experience

A Bok; V Kong; J Ko; J Wang; Damian Clarke ...

https://hdl.handle.net/10539/46615
WOS

Downloaded from a DSpace repository. https://dspace.org/

S Afr J Surg. 2025;63:8-11. Online first
https://doi.org/10.36303/SAJS.00434

Open Access article distributed under the terms of the Creative Commons Attribution-Non-Commercial Works 4.0 South Africa License (CC BY NC)
http://creativecommons.org/licenses/by-nc-nd/4.0

S Afr J Surg
ISSN 038-2361
© 2025 The Author(s)
TRAUMA SURGERY

Extremity fasciotomy in the developing world setting – a South African experience

A Bok,[1] VY Kong,[2,3] J Ko,[4] J Wang,[4] JL Bruce,[3] GL Laing,[3] DL Clarke[3,5]

[1] *Department of Orthopaedic Surgery, Northshore Hospital, New Zealand*
[2] *Department of Surgery, University of Auckland, New Zealand*
[3] *Department of Surgery, University of KwaZulu-Natal, South Africa*
[4] *Department of Surgery, Auckland City Hospital, New Zealand*
[5] *Department of Surgery, University of the Witwatersrand, South Africa*

Corresponding author, email: *victorywkong@yahoo.com*

Background: This study aims to determine the cause, spectrum and outcomes of acute fasciotomy for compartment syndrome in a developing world setting. This study serves as an overview of the Pietermaritzburg Metropolitan Trauma Service (PMTS) experience of acute fasciotomy.
Methods: All patients who underwent a fasciotomy between December 2012 and September 2020 were identified from the Hybrid Electronic Medical Registry (HEMR).
Results: During the eight-year period under review, a total of 97 patients required fasciotomy. The mean age was 27.96 years. Of these patients, 88% (85/97) were male and 12% (12/97) were female. There were 57 penetrating injuries, 23 snakebite-related injuries and 17 blunt trauma-related injuries resulting in compartment syndrome requiring fasciotomy. Of these, 52% of injuries involved the lower limb and 47% involved the upper limb, with 1% involving an injury to both upper and lower limbs. The average hospital stay was 12 days, and the mortality rate was 3%.
Conclusion: A broad range of injuries may precipitate acute compartment syndrome (ACS) of the extremity and mandate fasciotomy. Clinicians must actively exclude ACS when managing these conditions. Once identified, ACS requires fasciotomy. In an environment with long prehospital times there seems to be little role for expectant treatment of ACS.
Keywords: compartment syndrome, acute compartment syndrome, fasciotomy

Introduction

Acute compartment syndrome (ACS) of the extremity is a limb-threatening condition, resulting from increased pressure within a non-expansile tissue space and, if untreated, results in limb loss. Several diverse traumatic conditions can precipitate ACS of an extremity. The diagnosis of ACS is mainly clinical, but patients who develop ACS often have multiple competing injuries which distract clinicians from identifying an at-risk limb.[1,2,3] ACS mandates urgent treatment as delayed therapy results in significant morbidity.[4] Fasciotomy is definitive and ensures immediate reduction of intra-compartment pressure by releasing the skin and fascia, so allowing oedematous and swollen muscle to expand.[3,5] Fasciotomy is a morbid procedure which creates a major soft tissue wound.[6] Fasciotomy must not be omitted if the clinical scenario demands, but due consideration must be given to the associated morbidity. This study reviews a single centre's experience with extremity fasciotomy for ACS over a decade. It aims to review and clarify the indications for and the outcomes of the procedure and the approach to closing the subsequent wound. It is hoped that this information will provide good quality evidence to support local therapeutic algorithms.

Methods

The Pietermaritzburg Metropolitan Trauma Service (PMTS) has maintained a Hybrid Electronic Medical Registry (HEMR) since 2012. All patients admitted to our trauma centre are entered onto this system. All patients who underwent acute fasciotomy at Greys Hospital between December 2012 and September 2020 were identified from the database for review. Patients transferred from another centre who had already undergone fasciotomy were excluded. Pertinent details regarding patient demographics, mechanism of injury, imaging usage, operative management and wound management were extracted from the database. All relevant data were entered into an Excel spreadsheet for review. Ethical approval for the HEMR is obtained from the Biomedical Research Ethics Committee of the University of KwaZulu-Natal. This class approval is renewed on an annual basis. The ethics number is (BCA221/13).

Results

Demographics

During the study period, 102 patients were identified from the HEMR as having required an extremity fasciotomy. Five patients were excluded, as fasciotomy had been performed at another centre, leaving 97 patients. The mean age was 27.96 years (SD 15.14) and the majority, 87% ($n = 85$), were male. The average delay from injury to presentation was 27 hours (SD = 32.14). This ranged from 0.5 to 158 hours. The incidence of upper and lower limb fasciotomy is similar, at

47% (n = 46) and 52% (n = 50) respectively, with a single patient requiring both an upper and lower limb fasciotomy.

The average injury severity score (ISS) was 9, the average extremity abbreviated injury scale (AIS) was 3.

Table I: Demographics

Characteristics	Overall (n = 97)
Mean age (years)	27.59
Range of age (years)	0.3–71
Male	85 (87.63%)
Female	12 (12.37%)
Injury to assessment time (hours)	26.98
Range of injury to assessment time (hours)	0.51–158.48

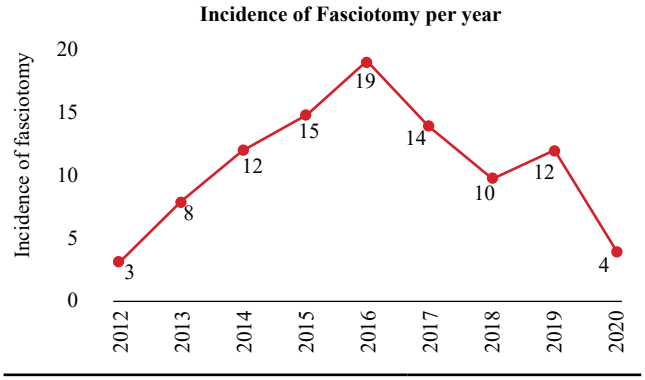

Imaging

The diagnosis of ACS is clinical. In this study, 62% (n = 60) of patients had no imaging prior to fasciotomy. However, various modalities were used as part of the workup for fasciotomy in the context of acute trauma.

Table II: Imaging

	n = 97	Percentage total
XR	9	9.28%
CT	22	22.68%
XR AND CT	5	5.15%
MRI	1	1.03%
None	60	61.86%

Extremity injury

There was a near equal distribution of upper and lower extremity fasciotomies, with upper limb fasciotomies occurring in 47% (n = 46), lower limb fasciotomies in 52% (n = 50) and one patient required both upper and lower limb fasciotomy (1%, n = 1). In both upper and lower limbs penetrating trauma was the most common mechanism (58%) necessitating fasciotomy. In the upper limb, bite injury was more common than blunt trauma whereas the opposite pertained in the lower limb.

Mechanism of injury

Injuries requiring fasciotomy were grouped into three mechanisms – penetrating trauma 59% (n = 57), snakebites 24% (n = 23), and blunt trauma 18% (n = 17). Of the penetrating mechanisms 54% (n = 31) of fasciotomies were secondary to a gunshot wound (GSW) and 40% (n = 23) were secondary to a stab wound (SW) and in 5% (n = 3) there was a miscellaneous penetrating mechanism. Blunt trauma included falls 29% (n = 5), motor vehicle collisions 24% (n = 4), assaults 18% (n = 3), industry related blunt trauma 24% (n = 4), and a single animal-related injury 6% (n = 1).

Table III: Trauma mechanisms

Type	Total (n = 97)	Mechanism	n	Percentage of total
Penetrating	57	Gun shot	31	32.0%
		Stab wound	23	23.7%
		Other	3	3.1%
Blunt	17	MVA	4	4.1%
		Fall from height	5	5.2%
		Assault	3	3.1%
		Industrial	4	4.1%
		Animal injury	1	1.0%
Bite	23	Snakebite	23	23.7%

Indication for fasciotomy

The most common indication for fasciotomy was isolated arterial injury in 36% (n = *35*). This was followed by snakebite in 24% (n = 23), combined arterial and venous injury in 13% (n = 13), and combined fracture and vascular injury in 8% (n = 8). Of the combined fracture and vascular injuries, 50% (n = 4) were secondary to a knee dislocation. Crush injury accounted for 4% (n = 4) and non-specified vascular was 4% (n = 4). In two patients (2%) an isolated venous injury and in three patients (3%) an isolated fracture necessitated a fasciotomy. In five (5%) patients the indication for fasciotomy was undocumented.

Outcomes

The average length of hospital stay was 12 days. Of the 97 patients, 97% (n = 94) survived to discharge, and 3% (n = 3) died during admission. ICU admission was required in 34% (n = 33). Patients admitted to ICU stayed an average of four days. In total 11% (n = 11) of patients required amputation, 7% (n = 7) during index surgery and 4% (n = 4) as a delayed procedure. Due to lack of patient consent at index surgery, 2% (n = 2) deemed to require amputation at the index fasciotomy underwent a delayed ablation procedure. The following complications were recorded – wound infections in 7% (n = 7), acute kidney injury in 3% (n = 3), sepsis in 3% (n = 3), and iatrogenic tendon injury from fasciotomy in 1% (n = 1).

Prophylactic fasciotomy

From analysis of operative notes, it appeared that at least 39% (n = 38) of patients underwent a prophylactic fasciotomy. In this group, the most common mechanism was penetrating trauma 74% (n = 28), followed by blunt trauma 16% (n = 6) and snakebite injury in 11% (n = 4). Arterial injury was the most common indication for prophylactic fasciotomy in 37% (n = 14), followed by combined vascular (venous and arterial) injuries 24% (n = 9) and combined fracture and vascular injuries in 16% (n = 6). Prophylactic fasciotomy secondary to an undefined vascular injury accounted for

8% (n = 3) whilst venous injury and isolated fracture were documented in 3% (n = 1 for each).

Wound management

Of the 97 fasciotomies 38% (n = 37) were closed prior to transfer or discharge. Closure was achieved with the use of negative pressure wound therapy in 12% (n = 12), split thickness skin grafts in 30% (n = 29), delayed primary closure in 8% (n = 8) and acute primary closure in 1% (n = 1). The remainder were transferred to another centre for delayed primary closure 15% (n = 15) or split thickness skin grafts 20% (n = 19). One patient died before closure of the fasciotomy. The remaining patients required amputation.

Discussion

ACS of the extremities was described approximately 130 years ago.[7] Increased pressure in a confined anatomical compartment leads to occlusion of venous outflow and ultimately occlusion of arterial inflow and critical ischemia of the affected limb. The syndrome presents as a spectrum of clinical features which evolve rapidly. These include the classical five "Ps" of pain, pallor, absent pulse, paraesthesia and paralysis.[8,9] Fasciotomy opens the fascial compartments so reducing the intra-compartmental pressure.

South Africa's unique economic, social and political history means that the demographics of the patients requiring fasciotomy differ from the international literature. The unusually high rate of interpersonal violence in the country means that penetrating trauma is the predominant mechanism, followed by snakebite and blunt trauma. There is an equal division between GSW and SW as the precipitating penetrating mechanism. In terms of the cause of the ACS, isolated arterial injury predominates as would be expected with such a high incidence of penetrating mechanisms. The next most common cause is snakebite followed by combined arterial injury and bone fracture. The most infrequent cause is a fracture without an associated arterial injury.

The incidence of upper and lower limb fasciotomy is similar, at 47% and 52% respectively, with a single patient requiring both an upper and lower limb fasciotomy. Penetrating trauma was the leading cause for fasciotomy in both upper and lower limbs. Other studies have documented similar findings.[10,11] Snakebite was associated with a higher incidence of upper limb than lower limb fasciotomy.

Delay in performing fasciotomy is associated with increased limb loss,[4] and traditionally this has justified liberal application of prophylactic fasciotomy. This has been challenged recently by a large prospective, observational multicentre study, which showed that liberal use of fasciotomy did not result in better outcomes than a more restricted approach.[12] These authors defined prophylactic fasciotomy as that performed before any suspicion of compartment syndrome could be identified. In this series 39% (n = 38) of the cohort underwent a prophylactic fasciotomy, especially in the setting of an arterial injury. This high rate must be interpreted in light of the long delays between injury and presentation. These prolonged prehospital times reduce the scope for expectant management in our environment. The high amputation rate of 11% in this series is almost certainly related to these delays. Both delayed management of a vascular injury and delayed fasciotomy are associated with increased risk for amputation. Arterial injury was the leading cause of ACS in this study. This is in keeping with the literature. Vascular injury is associated with the development of compartment syndrome and is predictive of need for fasciotomy, limb loss and mortality.[10]

If delayed primary closure cannot be achieved, split thickness skin graft is required to close the fasciotomy wound. This was the case in 49% (n = 48) of patients. The use of negative pressure wound therapy (NPWT) as an adjunct to fasciotomy wound management has become widespread. NPWT reduces tissue oedema and hematoma formation and may reduce infection.[13] There has been increased use of NPWT over the last decade in keeping with this trend.

Snakebite related fasciotomy and ACS differs from the other mechanisms. Of those who underwent fasciotomy for snakebite, the majority had bites to the upper extremity (n = 13 upper limb, n = 10 lower limb). Of the upper limb cases, three patients sustained snakebite to the hand.[14,15] The hand is especially at risk for ACS due to having 10 compartments and four interosseous compartments.[16] Although cytotoxic envenomation precipitates muscle swelling, the diagnosis of snakebite-related ACS is challenging, as envenomation may produce a pseudo compartment syndrome, secondary to swelling of subcutaneous fat and skin, rather than a true ACS of the muscular compartments.[17,18] It can be difficult to differentiate this clinically. Several techniques have been advocated to measure the intra-compartmental pressure. These include attempts to directly measure this pressure and more recently ultrasound assessment of the compartments.[19] Although some authors argue that compartment syndrome post-snakebite is uncommon, the subspecies of snake and delays in receiving appropriate therapy mean that in our series ACS post-snakebite remains a clinical concern.[20,21]

There are several limitations to this study. These plague most retrospective reviews of clinical data and include lack of prehospital data as well as data pertaining to the management in referral hospitals. This makes it difficult to clarify and understand the reasons for the long delays seen in this cohort. Unnecessary delay in transfer needs to be addressed if we hope to intervene earlier in this group of patients.

Conclusion

A broad range of injuries may precipitate ACS of the extremity and mandate fasciotomy. Clinicians must actively exclude ACS when managing these conditions. Once identified, ACS requires fasciotomy. In an environment with long prehospital times, there seems to be little role for expectant treatment of ACS.

Conflict of interest

The authors declare no conflict of interest.

Funding source

No funding was required.

Ethical approval

Prior to commencement of the study, ethical approval was obtained from the University of KwaZulu-Natal Biomedical Research Ethics Committee (BREC BCA221/13).

ORCID

A Bok https://orcid.org/0009-0008-3368-2083
VY Kong https://orcid.org/0000-0003-2291-2572

J Ko https://orcid.org/0000-0001-8139-5208
J Wang https://orcid.org/0000-0002-8227-7796
JL Bruce https://orcid.org/0000-0001-8666-4104
GL Laing https://orcid.org/0000-0001-8075-0386
DL Clarke https://orcid.org/0000-0002-8467-1455

REFERENCES

1. Lee C, O'Toole RV. Compartment syndrome in polytrauma patients. In: Mauffrey C, Hak DJ, Martin III MP, editors. Compartment syndrome - a guide to diagnosis and management. Cham (CH): Springer; 2019 Sep. https://doi.org/10.1007/978-3-030-22331-1_14
2. Donaldson J, Haddad B, Khan WS. The pathophysiology, diagnosis and current management of acute compartment syndrome. Open Orthop J. 2014;8:185-93. https://doi.org/10.2174/1874325001408010185.
3. Elliott KG, Johnstone AJ. Diagnosing acute compartment syndrome. J Bone Joint Surg Br. 2003;85(5):625-32. https://doi.org/10.1302/0301-620X.85B5.14352.
4. Farber A, Tan TW, Hamburg NM, et al. Early fasciotomy in patients with extremity vascular injury is associated with decreased risk of adverse limb outcomes: A review of the National Trauma Data Bank. Injury. 2012;43:1486-91. https://doi.org/10.1016/j.injury.2011.06.006.
5. McQueen MM, Christie J, Court-Brown CM. Acute compartment syndrome in tibial diaphyseal fractures. J Bone Joint Surg Br. 1996;78(1):95-8. https://doi.org/10.1302/0301-620X.78B1.0780095.
6. Lim KBL, Laine T, Chooi JY, et al. Early morbidity associated with fasciotomies for acute compartment syndrome in children. J Child Orthop. 2018;12(5):480-7. https://doi.org/10.1302/1863-2548.12.180049.
7. Von Volkmann R. Ischaemic muscle paralyses and contractures. Clin Orthop Relat Res. 2007;456:20-1. https://doi.org/10.1097/BLO.0b013e318032561f
8. Torlincasi AM, Lopez RA, Waseem M. Acute compartment syndrome. [Updated 2022 Aug 7]. In: StatPearls [Internet]. Treasure Island (FL): StatPearls Publishing; 2022 Jan. Available from: https://www.ncbi.nlm.nih.gov/books/NBK448124/.
9. Bowyer MW. Lower extremity fasciotomy: Indications and technique. Curr Trauma Rep. 2015;1:35-44. https://doi.org/10.1007/s40719-014-0002-7.
10. Branco BC, Inaba K, Barmparas G, et al. Incidence and predictors for the need for fasciotomy after extremity trauma: A 10-year review in a mature level I trauma centre. Injury. 2011;42(10):1157-63. https://doi.org/10.1016/j.injury.2010.07.243.
11. Gonzalez RP, Scott W, Wright A, et al. Anatomic location of penetrating lower extremity trauma predicts compartment syndrome development. Am J Surg. 2009;197:371-5. https://doi.org/10.1016/j.amjsurg.2008.11.013.
12. Keating JJ, Klingensmith N, Moren AM, et al. Fasciotomy Group Investigators. Dispelling dogma. American Association for Surgery of Trauma prospective, multicentre trial of index vs delayed fasciotomy after extremity trauma. J Am Coll Surg. 2023;236(5):1037-44. https://doi.org/10.1097/XCS.0000000000000612.
13. Igoumenou VG, Kokkalis ZT, Mavrogenis AF. Fasciotomy wound management. In: Mauffrey C, Hak DJ, Martin III MP, editors. Compartment syndrome - a guide to diagnosis and management. Cham (CH): Springer; 2019 Sep. https://doi.org/10.1007/978-3-030-22331-1_9.
14. Jyala A, Shah N, Ali N. An unusual case of compartment syndrome of the upper extremity caused by an iPad. Cureus. 2021;13(4): e14457. https://doi.org/10.7759/cureus.14457.
15. Oak NR, Abrams RA. Compartment syndrome of the hand. Orthop Clin North Am. 2016;47(3):609-16. https://doi.org/10.1016/j.ocl.2016.03.006.
16. Chandraprakasam T, Kumar RA. Acute compartment syndrome of forearm and hand. Indian J Plast Surg. 2011;44(2):212-8. https://doi.org/10.4103/0970-0358.85342.
17. Pattinson JP, Kong VY, Bruce JL, et al. Defining the need for surgical intervention following a snakebite still relies heavily on clinical assessment: the experience in Pietermaritzburg, South Africa. S Afr Med J. 2017;107(12):1082-5. https://doi.org/10.7196/SAMJ.2017.v107i12.12628.
18. Wood D, Sartorius B, Hift R. Ultrasound findings in 42 patients with cytotoxic tissue damage following bites by South African snakes. Emerg Med J. 2016;33(7):477-81. https://doi.org/10.1136/emermed-2015-205279
19. Dhar D. Compartment syndrome following snake bite. Oman Med J. 2015;30(2):e082. https://doi.org/10.5001/omj.2015.32.
20. Garfin SR, Mubarak SJ, Davidson TM. Rattlesnake bites: Current concepts. Clin Orthop Relat Res. 1979;140:50-7. https://doi.org/10.1097/00003086-197905000-00012.
21. Lu HY, Mao YC, Liu PY, et al. Clinical predictors of early surgical intervention in patients with venomous snakebites. Eur J Med Res. 2023;28(1):131. https://doi.org/10.1186/s40001-023-01101-x.