

https://dspace.org/

Disease indicators and pathological bone conditions in South African Plio-Pleistocene Hominins

Odes, Edward John

2017
https://hdl.handle.net/10539/26977

Downloaded from a DSpace repository. https://dspace.org/

Disease Indicators and Pathological Bone Conditions in South African Plio-Pleistocene Hominins

By

Edward John Odes

A dissertation submitted to the Faculty of Health Sciences, University of the Witwatersrand, Johannesburg, in fulfilment of the requirements for the degree of Doctor of Philosophy in Anatomical Sciences.

Johannesburg, 2017.

DECLARATION

I declare that this thesis is my own work, and that I contributed adequately towards the research findings published herein. It is being submitted for the Degree of Doctor of Philosophy at the University of the Witwatersrand, Johannesburg. It has not been submitted before for any degree or examination in any other University.

Signature: 

Date: December 14th, 2017

Dedicated to my late parents, Wolf and Joyce Odes,

My daughter Kelly and my wife Monica

ABSTRACT

South African Plio-Pleistocene hominin remains have not been studied extensively for signs of disease. In this study, hominin fossilized remains from eight South African Plio-Pleistocene assemblages were assessed for evidence of pathology. Studies of palaeopathology have historically relied heavily on external bone features to make diagnoses and classify disease. In addition to using conventional gross morphological and microscopic methods to identify disease, here technologically advanced three-dimensional (3D), non-invasive microtomographic virtual imaging techniques were used to assess internal and external characteristics of both fossilized skeletal material and comparative modern human bone homologues. These imaging techniques produced qualitatively higher resolutions than what are currently achievable with conventional clinical scanning methods and conventional clinical radiography. The results of this study included the reporting of rare fossil neoplasms including the earliest malignant and benign neoplastic disease in the hominin record. These discoveries not only illustrate the antiquity of cancer and osteogenic neoplasia in ancient South African hominins, but push back evidence for these diseases in hominins to approximately between 1.7 Mya and 2 Mya respectively. This study also reported on the first palaeopathological analysis of an osteogenic lesion in the extinct species, Homo naledi from Dinaledi Cave (Rising Star), and the first application of microtomographic imaging techniques of the lumbar region of a partial Australopithecus africanus skeleton (StW 431), identifying ante-mortem pathology and reporting postmortem alteration by an unknown insect. This study provided a glimpse into some of the possible physical restrictions that hominins may have experienced because of the disease conditions that affected them, and suggests how these conditions may have impacted their functional behaviour and survival. It provides medical science and palaeopathology with a clearer understanding of the strong evolutionary and remarkably similar appearance between hominin and contemporary human disease and also sheds light on the antiquity of neoplastic diseases. The advanced technology of non-invasive, three-dimensional imaging techniques, such as micro-computed X-ray tomography and phase-contrast synchrotron tomography, combined with the appropriate use of clinical analogues made a significant contribution to this study, by enabling reliable and accurate diagnoses of hominin fossil disease.

TABLE OF CONTENTS

DECLARATION……...2

DEDICATION……...3

ABSTRACT……...4

ACKNOWLEDGEMENTS …….9

CHAPTER 1: INTRODUCTION……...14

1.1 Background to the study……14

1.2 Aims and Objectives…….…19

CHAPTER 2: LITERATURE REVIEW …….20

2.1 Contributions of palaeopathology to the understanding of past disease…...20

2.1.1 A short history of palaeopathology…….20

2.1.2 Scientific rigour in palaeopathology……....25

2.1.3 How bone reacts to disease……...29

2.1.4 Palaeoepidemiology- is it truly epidemiology? ……...30

2.1.5 Shortcomings and limitations in palaeopathological samples, of palaeopathology as a discipline, and 'the Osteological Paradox'…….….33

2.2 Pathology in the palaeontological record…….38

2.3 Early hominid pathology……...39

2.4 The use of imaging techniques in palaeopathology…….43

2.4.1 Conventional radiographic imaging……44

2.4.2 Medical computed tomography (CT)…….….47

2.4.3 Micro-Computed tomography (µCT).……50

2.4.4 Propagation phase contrast X-ray synchrotron microtomography protocol (SRµCT).…….54

CHAPTER 3: MATERIALS AND METHODS…….....57

3.1 Materials……57

3.1.1 Facilities and equipment…….57

3.2 Methods…….58

3.2.1 Observation of modern comparative human skeletons……...60

3.2.2 Investigation of hominin fossil assemblages…….60

3.2.3 Scoring Methods…….61

3.2.4 Macroscopic method……...62

3.3 Imaging techniques…….64

3.3.1 Microscopic imaging……...……64

3.3.2 Micro-focus X-ray computed tomography (µCT) protocol……65

3.3.3 Propagation phase contrast X-ray synchrotron microtomography protocol (SRµCT) ……...68

CHAPTER 4: Earliest Hominin Cancer: 1.7-Million-Year -Old Osteosarcoma from Swartkrans Cave, South Africa……72

CHAPTER 5: A Case of Benign Osteogenic Tumour: In *Homo naledi*: Evidence for Peripheral Osteoma in the U.W. 101-1142 Mandible……...…….79

CHAPTER 6: Osteopathology and Insect Traces in the *Australopithecus africanus* Skeleton StW 431……88

CHAPTER 7: A Case of Benign Osteogenic Tumour: In *Homo naledi*: Evidence for Peripheral Osteoma in the U.W. 101-1142 Mandible…….97

CHAPTER 8: DISCUSSION……107

CHAPTER 9: REFERENCES…….....141

CHAPTER 10: LETTERS OF SUPPORT.…….175

1. **Letter of support for Chapter 2: Earliest Hominin Cancer: 1.7-**

Million-Year-Old Osteosarcoma from Swartkrans Cave, South Africa…….176

2. Letter of support for Chapter 3: Osteogenic Tumour in *Australopithecus sediba*: Earliest Hominin Evidence for Neoplastic Disease……177

3. Letter of support for Chapter 4: Osteopathology and Insect Traces in the *Australopithecus africanus* Skeleton StW 431…….178

4. Letter of support for Chapter 5: A Case of Benign Osteogenic Tumour: In *Homo naledi*: Evidence for Peripheral Osteoma in the U.W. 101-1142 Mandible……179

LIST OF FIGURES…….180

LIST OF TABLES……...185

APPENDIX A: SA HOMININ PALAEOPATHOLOGY……...186

APPENDIX B: SUPPLEMENTAL MATERIAL TO CHAPTER 4- Earliest Hominin Cancer: 1.7-Million-Year-Old Osteosarcoma from Swartkrans Cave, South Africa……..189

APPENDIX C: SUPPLEMENTAL MATERIAL TO CHAPTER 5- Osteogenic Tumour in *Australopithecus sediba*: Earliest Hominin Evidence for Neoplastic Disease…….201

APPENDIX D: SUPPLEMENTAL MATERIAL TO CHAPTER 6- Osteopathology and Insect Traces in the *Australopithecus africanus* Skeleton StW 431…….213

APPENDIX E: DECLARATION BY STUDENT AND CO-AUTHORS' AGREEMENT FOR WRITE-UP WITH PUBLISHED ARTICLES……219

APPENDIX F: ETHICS WAIVER……238

ACKNOWLEDGEMENTS

There are many people that I would like to express my deepest gratitude to, and without whose support this study would have been impossible.

Thank you to Professor Lee Berger for the opportunity of becoming your student for a second time. When I met you for the first time to discuss a project for my Masters, I knew that this was to be a long association and that you would have a transformative effect on the science of early humans and the way we view them. As fate would have it, it came to pass. Providence struck some eighteen months later, when I again had the good fortune of meeting up with you again. This time to discuss a PhD project. One thing I shall never forget, you said to me: "Be sure to be where the lightning strikes". The rest is history. Words are sometimes inadequate to express my sincere gratitude for believing in me, and for taking me on as your PhD student. For your constant support and positive guidance, I am deeply grateful to you.

My deepest and sincere gratitude goes to my supervisor, Professor Maryna Steyn. Your wise counsel, strong guiding hand, and critical review of my final draft thesis, and the associated and daunting correction process that accompanies a study of this magnitude is humbly appreciated. I am deeply grateful for your strong commitment to my PhD. I am also grateful to you for taking time in the earlier part of the study, to carefully evaluate my bone and fossil scans, and give me much needed feedback on differential diagnoses of various types of bone lesions. I am honoured and thankful for your contribution as a co-author, which clearly went beyond the ordinary, and am privileged to have been privy to your ideas and valuable inputs on modern skeletal disease, internal bone morphology and malignant disease identification.

I would like to thank Dr Patrick Randolph-Quinney, my co-supervisor for co-conceptualising my PhD project with Lee. I am extremely grateful for your guidance, support and encouragement, and for the many hours of editing, discussing differential diagnoses and teaching me to use three-dimensional imaging of fossil and modern bone remains. Thank you for the many discussions on how to prepare for publications, palaeopathology and anatomy in general, over a few beers in Melville. Thank you for assisting with developing my writing skills and with getting my papers published. I

could not have done without you. For these things and for the positive impact that you made on my academic life, thank you.
Thank you to Dr Jackie Smilg, for sharing your knowledge of radiographical pathology with me and for our discussions on cancer and tumour diagnosis. This area of study and knowledge has, and will always be helpful to my future studies. I am privileged and grateful to you for your contribution and co-authorship on three of my papers.

My sincere thanks go to my colleague and fellow PhD candidate Alex Parkinson for his invaluable contribution as a co-author to one of my papers, and his help with imaging, and knowledge on insect taphonomy.

I would like to thank Dr Tanya Augustine, one of my co-authors for her assistance and support with her input on oncogenetics, and editing, and cell biology, and for her encouragement and support always.

To Professor Zach Throckmorton, thank you for your friendship, support and input on human foot bone pathology and your co-authorship of one of my papers. Thank you for also taking the time to travel with me to the Ditsong Museum and assess the possible pathologies of fossil bone specimens. I am grateful for your constant encouragement and support.

I would like to thank Dr Bernhard Zipfel, for always being so obliging, and making the fossil collections available to me, with not too much notice given on occasions, and for the invaluable, constructive discussion and input on two of the papers included in this thesis, especially foot bone and vertebral pathologies. I am very grateful for your co-authorship on these papers.

My sincerest thanks go to Jacobus Hoffman of NECSA, for your help and support with the scanning of fossil and modern bone material. Thank you for accommodating me whenever necessary to complete my scanning requirements for my study. Thank you also for your valuable knowledge of micro-CT scanning and your contribution as a co-author on one of the papers in this thesis.

I would like to thank Frikkie De Beer of NECSA for your guidance, and making the micro-CT facility available to us whenever it was necessary, and for your years of experience when it came to input as a co-author.

My sincerest gratitude goes to Kudakwashe Jakata for assisting with scanning of the Sterkfontein hominin specimens, and for your input on micro-CT scanning, and as a co-author of two of the papers in this thesis.

Thank you to Dr Ryan Franklin, who's PhD in palaeopathology guided me throughout my PhD study, and without which, may well have had a different outcome. Your work helped bring definition to my study, and I am thankful to you for the contribution you made to my studies on hominin tumours and palaeopathology in general.

I would like to thank my co-authors, Dr Scott Williams, Dr Marc Meyer, Dr Steve Churchill, and Dr Paul Tafforeau for their co-authorship, major contributions to my studies and valuable input in the 'Osteogenic tumour in *Australopithecus sediba* paper. I am very honoured and grateful to you all for having been a co-author of this paper too.

My sincere thanks go to Dr Heather Bonney, for her valuable input, support, critical discussion and co-authorship of the osteopathology and insect trace paper of *Australopithecus africanus*.

I would like to thank Dr Ashley Kruger for his friendship, help and support work with imaging of fossil specimens, and for all the time spent on teaching me the intricacies of various software imaging packages.

I would like to express my sincere thanks to Dr Lucinda Backwell for her continued support of my work, valuable guidance with microscopic imaging, and her unwavering belief in my goal of obtaining my PhD.

My deepest gratitude goes to Dr Merrill Van der Walt for assisting with editing my thesis, for listening to my thoughts, for your friendship and mentorship and unfailing belief and support in me. This is something I shall never forget.
My sincere thanks go to Dr Bonita de Klerk for her guidance with software support, editing my early draft thesis, advice on the layout of my thesis and for her constant encouragement during my academic journey.

My sincere gratitude goes to Wilma Lawrence, for always being available to help me to liaise with Lee, always offering support with tricky administrative detail, and giving me good advice when it counted most.

Thank you to Brendon Billings for your unstinting support and valuable anatomical and pathological input when it came to the human skeletal material at Wits Medical School. I will always remember the morning coffees and chats on anatomy and pathology and life in general. Thank for allowing me the opportunity to work on the cadaveral material in the dissection halls. This is something that will always stand me in good stead for the future.

My sincere thanks to Stephany Potze, Lazarus Kgasi, and Dr Heidi Fourie of the Ditsong Natural History Museum for allowing me the opportunity of working on their hominin specimens and for assisting me to transport them to the scanning facility at NECSA.

My sincere thanks go to the University of the Witwatersrand, the Centre of Excellence in Palaeopathology and the NRF for funding my PhD, without which this project would not have happened.

To Kelly, my beautiful daughter, thank you for your belief, love and confidence in me. You are a constant light in my life even though you are thousands of earth kilometres away, you are with me all the time.
Your excellent academic accomplishments continue to motivate me on my own path of discovery and knowledge.

To Monica, my beautiful wife, thank you for your total commitment to my life, for your love, and for your support and steadfast belief in me, for which I will always be eternally grateful. Your successful corporate and life achievements are a constant inspiration to me. *Te adoro mi amor divina.*

This thesis is dedicated to the memory of my late parents, Wolf and Joyce Odes, who believed in and loved me unconditionally, and always encouraged me to dare and persevere until I found what it was that I was searching for.

"Come to the edge," he said.
"We can't, we're afraid!" they responded.
"Come to the edge," he said.
"We can't, we will fall!" they responded.
"Come to the edge," he said.
And so, they came.
And he pushed them.
And they flew."

Guillaume Apollinaire
(1880-1918)

Chapter 1

INTRODUCTION

1.1 Background to the study

Palaeopathology is the study of ancient and prehistoric diseases (Roberts 2012) in fossil and archaeological remains of hominins, humans and other non-human fauna. Palaeopathologists provide an inimitable prospect to observe the evolutionary spectrum of diseases over time (Rühli et al., 2016). Sources of information include mummified and skeletal remains as well as ancient documents and other archaeological materials (Ortner 2003, Buikstra 2010). This study will focus on signs of disease in the hominin fossil record in the South African Late Pliocene to Early Pleistocene Period (approximately 2.5 - 1.6mya). In particular, it will include remains from several sites in the Cradle of Humankind including Sterkfontein, Swartkrans, Malapa, Makapansgat, Dinaledi (Rising Star) and Cooper's cave.

Palaeopathology includes recording disease history and their origins, and the description of bone lesions with the aid of specific and non-specific anatomical characteristics and biomarkers. The ultimate aim would be to identify specific diseases, with differential diagnoses, although this is often not possible as many signs of disease are non-specific. The study of diseases in antiquity can contribute to the understanding of the evolution of specific diseases, and this knowledge can also be used to help understand the influences of various diseases on human evolution (Lovell *et al*., 2000; Roberts 2012). Within this context, it is important to acknowledge that not all diseases leave signs on bone, and a condition needs to be chronic in nature to leave evidence on the skeleton.

Whether the focus is on the skeletal material of early hominins, *Homo*, or modern humans, bone anatomy will fundamentally show a complex inter-relationship between the environment, genetics and bio-evolutionary history. Hominin and early human skeletal remains can provide useful biological information on the life-ways of individuals; their health status and diet, and diseases that affected them. Palaeopathological studies thus examine the development and manifestation of the processes of ancient disease over time, aiding in the reconstruction of the live experiences of early hominins (Virchow 1895; Brothwell 1969; Steinbock 1976; White, 1978; Ripamonti, 1988, 1989; Grine *et al*., 1990; Fisk and Macho, 1992; Ripamonti, *et al*., 1997; Guatelli-Steinberg, 2003; Ortner 2003; Capasso 2005; D'Anastasio *et al*., 2009; Curnoe and Brink 2010; Randolph-Quinney 2013).

Various diseases affect the skeleton including congenital pathology, trauma, circulatory abnormalities, infectious diseases, metabolic diseases, endocrine diseases, haematological disorders, neoplasms, diseases of the joints and dental disease (Steinbock 1976; White 1978; Resnick 1994, 1995; Resnick and Greenway 1996; Aufderheide and Rodríguez-Martín, 1998; Ortner 2003). As mentioned before, not every disease will result in a bone lesion, and the manifestations of disease on bone can be affected by several factors, such as the individual's particular stage of life, the type of condition, and how long the individual has suffered from the pathological condition. Consequently, bone lesions will normally be likely to be the result of chronic disease and also may be seen more frequently in adults or adolescents, and rarely in younger individuals (Randolph-Quinney, Mallet and Black 2009).

Steinbock (1976), for example, detailed the rarity of prehistoric expressions of thalassemia, which is a familiar condition affecting modern children in a hospital

setting. He illustrated that the disease became protracted after medical treatment in modern medical cases, because prehistoric individuals would have died before the disease would have had a chance to manifest skeletally. This illustrates one of the principles of the 'osteological paradox' formalised by Wood *et al*. (1992). The osteological paradox proposes that some individuals may look healthy at the time their remains are examined by palaeopathologists, without any clear signs of pathology. However, these individuals may well have died before the disease had progressed to their bones and may thus be the weaker members of the society; conversely stronger individuals who were able to live longer with their chronic conditions often would look more diseased from their skeletal remains. It is extremely difficult to account for this heterogeneous frailty in palaeopathological assessments.

Other than just assessing the presence / absence of disease, various authors (e.g. Angel 1984; Pearson and Buikstra 2006) also attempted to interpret human behaviour using skeletal remains. This specifically includes skeletal change as a reaction to various forms of physical stress and the reconstruction of lifestyles through musculoskeletal stress markers, such as osteoarthritis, trauma and enthesopathy.

There is a longstanding association between studies of modern medicine, bio-evolutionary sciences and the evolution of disease, having its roots in the 1700s (Desmond 1992; Nesse and Stearns 2008, Gluckman 2011). One of the first studies to assess palaeopathology in the South African Plio-Pleistocene was a doctoral thesis by Franklin (2011). This work primarily examined and described pathological lesions and their frequencies in postcranial macro-mammalian fauna and included some

observations of hominin pathology in two sites, Coopers Cave and Swartkrans (Members 1-3). Bone remains were categorised into taxon and skeletal type to identify trends and patterns by anatomical location. These results indicated that joint disease, trauma and enthesopathies were the most common pathological lesions at the two sites studied.

A possible case of neoplasm was also described from the Swartkrans hominin site remains (Franklin 2011). Franklin further noted, that pathology occurred at higher frequencies in felids and hominins as opposed to bovids. Lesions also occurred most frequently on the same osseous elements in all families, namely on the vertebrae and distal limb.

It should be noted that palaeopathological assessments were also done on fossil material of other species. For example, Rothschild's early work in fossil palaeopathology diagnosed a case of infectious spondylitis from vertebrae in a mosasaur, *Plateocarpus* (Martin and Rothschild 1989). Rothschild *et al*. (1999) also reported spondyloarthropathy in Pleistocene Rhinocerotidae, and metastatic cancer in a fragmentary dinosaur bone from the Upper Jurassic Morrison Formation in Colorado, North America.

The current research aims to develop a more comprehensive picture of the diseases found in South African hominins. This would contribute to our knowledge of ancient disease, its evolution, and the possibility to compare diseases found in antiquity to modern disease expressions. The question why so few studies done in the field of hominin palaeopathology of South Africa needs to be stated. It should be acknowledged that there are relatively few obvious examples of hominin palaeopathology, and the assemblages are not large. It also spans a very long-time

period, making it difficult to draw overall conclusions on the health status of hominins in the distant past. Laird *et al*. (2016) briefly mention that there is a possibility of an osteoma in a *H. naledi* mandible, but doesn't pursue it further. Only a few reported cases of disease in hominins exist in the published literature (White, 1978; Ripamonti, 1988, 1989; Grine *et al*., 1990; Fisk and Macho, 1992; Ripamonti, *et al*., 1997; Guatelli-Steinberg, 2003; D'Anastasio *et al*., 2009; Curnoe and Brink 2010; Franklin 2011; Laird *et al.*, 2016). The majority of these publications focus on hominin dental palaeopathology (enamel hypoplasia, caries, periodontal disease). Fisk and Macho (1992) discussed a healed compression fracture in a Plio-Pleistocene hominin talus, and D'Anastasio *et al*. (2009) assessed the possibility of brucellosis in a case with vertebral pathology. Franklin's (2011) thesis mostly focused on faunal macro-mammalian postcranial pathology and included some hominin pathology. A disadvantage in Franklin's study was the poor resolution in some of the clinically scanned images, which with current state-of the art three-dimensional imaging (microtomographic imaging) can be vastly improved.

An area where a significant contribution can be made is in the types of imaging methods used for fossil disease comparison, description, classification and interpretation. Clinical imaging methods may not be the most suitable way to identify pathological conditions in fossilized remains. Although radiographic imaging has been historically valuable in identifying surface and sub-surface bone lesions, conventional clinical scanning has not proved to be very successful in delivering a comparatively superior resolution. Microtomographic scanning and sub-micron microscopy are now accepted as the gold standard when studying palaeopathological specimens (McCall 2005; Tafforeau et al., 2006, 2009). These methods assess internal bone structures in hominin fossil bone and modern human bone comparatives, at

qualitatively higher resolutions than are currently achievable with clinical scanning modalities (Straight et al., 2009; Particelli et al., 2012; Sutton, Rahman & Garwood, 2014).

1.2 Aims and Objectives

The aim of this study is to assess all hominin fossils from the Cradle of Humankind (South Africa) for signs of disease. These include specimens dated to 2.6 mya to 1.6 mya. A comprehensive list of all observed signs of disease will be provided and, from this, specific notable cases will be assessed in detail.

The specific objectives are to:

1. Observe and document all cases with signs of pathology in South African Plio-Pleistocene hominins. These include specimens from the sites of Sterkfontein, Makapansgat, Swartkrans, Malapa, Cooper's Cave and Kromdraai.

2. Select specific unusual, interesting or notable cases from these sites for detailed description, analysis and differential diagnosis.

3. Assess published and unreported specimens for the presence of pseudo-pathologies. These include characteristics / lesions that may have originally been described as being the result of disease, but which may (with more recent knowledge of disease and the use of modern imaging techniques) possibly be ascribed to other factors such as taphonomy or post-depositional factors.

4. Use advanced, modern imaging techniques to investigate specific cases in detail, in order to assess the usability and contributions of these techniques to the study of palaeopathology.

Chapter 2
LITERATURE REVIEW

2.1 Contributions of palaeopathology to the understanding of past disease

Palaeopathology, the study of ancient disease processes, includes the assessment of normal and abnormal variation in human and fossil remains. It focuses primarily on describing and interpreting historical evidence of pathology and diseases (Roberts *et al*., 2012) and how diseases influence human development and evolution.

2.1.1 A short history of palaeopathology

Several authors have reviewed the historical development of palaeopathology (Moodie 1923; Williams 1929; Wells 1964; Jarcho 1966; Brothwell and Sandison 1967; Armelagos 1969, 1997; Janssens 1970; Angel 1971, 1981; Buikstra and Cook 1980; Ubelaker 1982, Aufderheide *et al*., 1998); Buikstra and Beck 2006, Grauer 2008; Buikstra 2010; Ortner 2003; Cook and Powell 2006, Roberts and Manchester 2007, Buikstra and Roberts 2012). The many interpretations of these researchers indicate clearly the complexities inherent in palaeopathology as a discipline (Grauer 2008).

Prior to the mid-19th century the early studies in palaeopathology were focused on the diseases in fossilised faunal material. The origins of palaeopathology are found in the 19th century when physicians and anatomists such as Virchow, Wood Jones and Smith focused on the identification of disease in ancient bone and applied a clinical approach to their work, producing descriptions and diagnosing bone lesions (Lovell 2000; Armelagos 2003; Grauer 2008). During the 19th century, the focus shifted away from faunal palaeopathology, to human archaeological palaeopathology (Aufderheide *et al*., 1998). Virchow published various papers on lesions in ancient human remains from the Palaeolithic and Neolithic periods (Virchow 1895). By the end of the 19th century, the origins of syphilis were studied in

depth by Jones (1876) and Virchow (1896). These studies marked some of the first endeavours to interpret human archaeological remains to answer medically related questions (Ortner 2003).

The concept of disease occurrence was evidenced in Welcker's study in 1888 of cribra orbitalia. Studies in disease/lesion frequency are also noted in the works of Grafton Elliot Smith and Wood Jones during the early 1900s. Wood-Jones and Elliot Smith's studies concentrated on Nubian bone material (Ortner 2003).

By the late 1960s, transition toward a more ecological and anthropological synthesis in health studies became apparent (Roberts and Manchester 2005), with pioneering work from Brothwell and Sandison (1967), Jarcho (1966), Angel (1967), Kerley and Bass (1967), and Armelagos (1969). Standardising methods for the collecting and synthesising of data was becoming necessary in the science (Roberts and Manchester 2005), with attempts at integration of large data sets of pathological skeletal material (Roberts and Cox 2003; Steckel and Rose 2002).

The publications of the 1960s show a significant contrast between studies focusing on diagnosis and historical data and an interpretation of disease from a cultural and ecological perspective on the other side (Goodman and Leatherman 1998).

In the early 1960s, Cockburn (1963) proposed that epidemiological methods be used in palaeopathology to investigate the antiquity of pathogens in human hosts in cultural environments. During the mid-1980s, 1990s, and early 2000s, a number of studies focused on infectious disease evolution in humans (Manchester and Roberts 1989; Wakely, Manchester and Roberts 1991; Lewis *et al*. 1995; Roberts *et al*. 1998; Roberts 2000; Roberts *et al*. 2002), the reconstruction of past health patterns, and the aetiology of various diseases. Ragsdale (1992), argued for standardising methods to record data and an efficient system of disease classification in palaeopathology. Their

recommendations involved using seven category types to diagnose disease (Miller *et al*. 1996). Rothschild and Rothschild (1995) re-evaluated the ability to recognise metastatic cancer. Buikstra and Ubelaker (1994) and Brickley and Mckinley (2004) proposed the development of a rigorous method of reporting osteological data.

Literature produced during the late 19th and early 20th centuries provided some evidence of diseases in the past, with studies mainly focused on singular pathological descriptions and contained little medical precision (Roberts and Manchester 2005; Grauer 2008; Pinhasi and Turner 2008). Bone specimens exhibiting pathological lesions at this time were seen more as oddities and not beneficial to the medical sciences or to history (Lovell 2000; Roberts and Manchester 2005). Cultural frameworks and discussions on mechanisms of disease in prehistoric human populations were absent from the early development period of palaeopathology (Buikstra and Cook, 1980; Armelagos and Van Gerven, 2003). Palaeopathology endured as a predominantly descriptive science with little theoretical basis (Armelagos 2003). During this period medical researchers and academics such as Rudolf Virchow (1821-1902), Sir Marc Ruffer (1859-1917) and Wood Jones (1879-1954) applied their medical education to identify pathology in human remains and strictly applied a clinical approach to their work, producing descriptions and diagnosing bone lesions (Lovell 2000; Armelagos 2003; Grauer 2008).

Soon after the discovery of X-rays in the late 19th century, archaeologists began applying X-rays to examine dry archaeological bones, in order to visualise pathological changes (Eaton 1916; Means 1925; Williams, 1929), and rigorous methods beyond pure descriptions were introduced to improve differential diagnosis (Buikstra and Cook 1980; Roberts and Manchester 2005).

Hooton's (1930) early studies in epidemiology made a significant contribution to palaeopathology by introducing a novel population based method to the science, utilising an ecological and cultural approach to understand the causes

of disease in the population of Pecos Pueblo, USA (Aufderheide *et al*. 1998; Ortner 2003; Grauer 2008). Lovejoy and Heiple's (1981) studies on the recording of fractures combined with comparative clinical studies of Wood-Jones (1910) made it possible for later researchers to confidently assess patterns of injury and treatments to contemporary groups (Judd and Redfern 2012).

Also during 1930, Aleš Hrdlĭcka, founder of the Physical Anthropology Department at the Smithsonian Institution, had acquired the valuable Huntington skeletal collection for palaeopathological study at a population level (Roberts and Manchester 2005). This collection included major skeletal collections from anatomical, dissecting-room cadavers, which had among them pathological specimens. Hrdlĭcka's studies also included the health status of living Native American groups (Hrdlĭcka 1909). Palaeopathological and anthropological studies began to concentrate on the linkages between disease processes, human behavioural patterns, ecology, and culture (Grauer 2008).

Møller-Christensen's (1953) study on skeletal remains of a medieval leper cemetery in Denmark is unique in the history of palaeopathology. The historical knowledge of a leper cemetery ultimately led to excavation of the remains. His interpretational analysis of this pathological material has added important data on ancient leprosy. It has also expanded the knowledge base of the implications of this disease on skeletal tissue (Ortner 2003).

Audy and Dunn's study (1974) of the definition of health and disease and Selye's (1973) 'general adaptation syndrome', were to become the precursors that drove palaeopathologists to move their focus from lesions associated with singular pathogens to concentrate on a wide range of abnormal bone conditions. Studies on non-specific periosteal reaction and growth interruption began emerging. Research work on stress indicators became an important focus for some researchers (Armelagos 1997; Goodman *et al*. 1984).

Palaeopathological studies of Neandertal remains have demonstrated a high incidence of developmental and degenerative defects (e.g. dental enamel hypoplasia), indicating stress during early development, and evidence of scarring from traumatic bone lesions (Trinkaus, 1983, 1985; Duday and Arensburg, 1991; Berger and Trinkaus, 1995; Smith *et al*. 2006)

The assemblages from both the Sima de los Huesos, and Sima de Elefante sites in Sierra de Atapuerca, Spain have provided rich palaeopathological data and an insight into ancient human Middle Pleistocene populations (approximately 1.3 Mya). Fossilized remains include the earliest hominin remains from Western Europe (Pérez *et al*. 1996; Martinón-Torres 2011).

The early human Dmanisi colony in the Georgian Caucasus in the Republic of Georgia. represents the earliest evidence of hominins outside of Africa with an age of approximately 1.8 Ma. Pathology in this early human Pleistocene occupation includes dental wear, root exposure and dental migration, enamel fractures and periapical abscesses, tooth rotation and temporomandibular arthropathy (Ferring *et al*. 2011; Martín-Francés *et al*. 2014).

Substantial interest in epidemiological research during the late 1980s was evident with Steckel and Rose establishing groups of historians, anthropologists and other scientists, who set out to record and investigate the history of health in the Western Hemisphere using data from archeological skeletons (Steckel and Rose 2002b). Out of this large collaboration came the Global History of Health Project, which collected a dataset from over 17,000 skeletons from different temporal periods and contexts in continental Europe detailing the history of health. This culminated in Steckel and Rose's (2002) publication of 'The Backbone of History'.

Other significant contemporary studies include Bennike's (1985) examination of disease in Danish human skeletal remains, Roberts and Cox's (2003) study of prehistoric and post-medieval British health, Cohen and Crane-Kramer's

(2007) publication on global health status, and the Cohen and Armelagos (1984) study on the status of health present at the time of origin of agriculture.

2.1.2 Scientific rigour in palaeopathology

Identifying and diagnosing pathological disease processes accurately from fossil and archaeological skeletal remains, is one of the most problematic issues facing palaeopathology researchers (Schultz, 2001; Byers and Roberts, 2003; Mays 2012). In order to conserve scientific rigour in palaeopathology through differential diagnosis, collaborations are encouraged between researchers encompassing various aspects of medico-clinical science, palaeoanthropology, geology, bioarchaeology and socio-cultural sciences, as no individual researcher has the capacity to perform all the skills required in today's modern multi-disciplinary environment (Buikstra *et al*. 2017).

The chances of an erroneous diagnosis in palaeopathology are ever present and therefore it is essential that palaeopathologists develop standardised conventions to interpret pathology on skeletal remains which are capable of offering a consistent and dependable differential diagnosis. As with most research the qualitative level of palaeopathological data is reliant upon the employment of several lines of evidence and the use of as many reliable and tested methods as possible (Miller *et al*. 1996; Ortner 2003; Mays 2012). The quality of data and the rigour in the application of the methods used to collect it, are critical to both the diagnostic accuracy and the strength of future interpretations made on the prevalence of disease and the health status of various populations based on the skeletal assemblage examined (Ortner 2007). Even though the eventual goal of a well-researched description is the correct identification of the disease process, the definitive cause of an abnormality on skeletal material is not always arrived at using the most meticulous analysis of the palaeopathological sample. However, even when the specific disease is not identifiable, the pathology may provide important descriptive case frequency data (Ortner and Putschar 1985).

The need for continuous scientific rigour in palaeopathological studies has long been an issue that has guided debates by many palaeopathologists. Jarcho (1966) identified a general failure to apply diagnostic methods of the day to the study of ancient bone (Buikstra and Cook 1980; Grauer 2008). He called for a synthesis of research on ancient disease, and pressed for the adoption of rigorous and standardised methods of diagnostics. This was done to facilitate and make the dissemination of osteological information available to as many researchers as possible.

Efforts at better diagnostic rigour was evidenced through the studies of Møller-Christensen in the early as the 1950s and 1960s through well-defined diagnostic criteria on the presence of ancient leprosy in past human populations (Møller-Christensen, 1965) and systematically described disease lesions (Møller-Christensen, 1967, 1978). He further presented differential diagnoses, and employed known pathological characteristics and measurement data of the disease to assist in the diagnoses of archaeological skeletal remains (Møller-Christensen, 1974). Despite these early advances there were concerns that diagnostic rigour was generally not being adequately implemented by scholars in palaeopathology (Jarcho, 1966; Brothwell and Sandison, 1967).

Following this wide call to scholars of palaeopathology the discipline responded in a positive way to address the broad needs of methodology. Brothwell and Sandison's work offered the discipline a large corpus of skeletally recognisable pathologies and diseases. This substantial work offered insights into the geographical scope of skeletal lesions, and provided radiographic, photographic and histologic data to the discipline. Steinbock (1976) integrated clinical data with archaeological specimens, and supplied data on the development of diseases and different conditions, radiographic data, gross morphology, differential diagnosis and photography of archaeological material to provide a contextual foundation for researchers interested in diagnostics and analysis of skeletal lesions (Grauer 2008).

More recently endeavours to improve diagnostics and interpretational analysis of skeletal lesions by Ortner and Putschar (1985), Manchester (1983), Aufderheide *et al*. (1998) and and Ortner (2003), coupled with an imaging database from Ortner's skeletal pathology collection (http://global.sbs.ohio-state.edu/cd-contents/Ortner-slides), have supplied researchers with a strong visual basis upon which to examine pathological skeletal lesions. This signified a positive change for macroscopic evaluation, in that a broad collection of medical, archaeological data and skeletal imaging was becoming available for researchers to work with (Grauer 2008).

Palaeopathologists also began turning their attention from single case reports to a broader approach to disease in populations. Multiple and non-specific indicators of stress (Huss-Ashmore *et al*. 1982; Armelagos, 1997; Goodman and Martin, 2002) were assessed and included conditions such as non-specific periosteal bone reaction and growth disturbance.

New methods began to emerge from the adoption of new theoretical approaches within palaeopathology. The necessity to integrate previously excluded variables including age at death, sex of the individual, nutrition, genetic and social factors into skeletal analyses, arose (Armelagos *et al*. 1982; Armelagos and van Gerven, 2003). Emphasis on population analysis rather than on individuals was becoming the norm, with archaeological and cultural background analyses becoming a prerequisite to the research effort. Constant improvement in recording protocols and diagnosis through rigorous comparative analysis with clinical data was being required.

The implications for data collection were substantial. More standardised recording of skeletal variables to meet the needs of for population-based approaches and cross-cultural comparative research were becoming essential. In the early 1990s, in response to a need to improve terminology and classification of skeletal lesions, Ragsdale (1992) produced a list of terms in an attempt to standardise terminology. Thillaud (1992) followed with a similar undertaking with suggestions to standardise macroscopic terminology. A

similar response by Lovell (2000) incorporating her earlier research followed. Much work was done to improve the standardization of data recording to enable data sharing and population-based studies. Several contributions to scientific rigour in palaeopathology followed. The publication of 'Standards for Data Collection from Human Skeletal Remains' (Buikstra and Ubelaker, 1994), provided recommendations for terminology during data collection, and the formation of a coding system of variables, to facilitate easier data comparability between researchers (Grauer 2008).

With the acknowledgement that large amounts of data would be generated and improve researchers' ability to access this data, an independent database commonly referred to as the Standardized Osteological Database (SOD) was established at no cost to users (http://www.cast.uark.edu/cast/sod). Researchers at the Smithsonian Institution Repatriation Osteology Laboratory have also created a database capable of integrating researchers' capacity to link datafiles together and prevent the unnecessary duplication of records. This system further facilitates comparison of many records concurrently deploying large quantities of data (Hefner and Ousley 2006).

Endeavours to confront problems intrinsic to the collection of data were identified and introduced in the United Kingdom. The British Association of Biological Anthropology and Osteoarchaeology (BABAO) also made recommendations for data collection that focused on improved functionality (Brickley and McKinley, 2004). This concluded in the establishment of 'Guidelines to the Standards for Recording Human Remains' (Brickley and McKinley, 2004), giving researchers a solid foundation for appropriate recording measures to be made available to a broad range of palaeopathologists (Grauer 2008).

Many studies have showed the importance of rigorous differential diagnosis, and that careful comparison should be made with specimens with identified diseases or injuries in pathology museums and archaeological bone collections (Bennike, 2003). There is no single method, however, by which

macroscopic diagnoses and data collection are accomplished. However, guidelines developed by Buikstra and Ubelaker (1994), Ortner (1991, 1992, 1994, 2003), and Brickley and McKinley (2004) indicate that a standard of rigour can be created and adopted.

2.1.3 How bone reacts to disease

Bone is a dynamic tissue that consistently alters its shape in response to the stresses that are imposed upon it. It will respond to disease processes and physiological changes. Bones will become necrotic if blood and sufficient nutrients are not supplied to them. They also heal after traumatic insult and atrophy if not utilised sufficiently (Bloom and Fawcett 1994; Schwamm and Millward 1998). The application of pressure will result in resorption, and tension can cause new bone formation (Goodman & Armelagos, 1989; Gartner & Hiatt, 2007). These activities are achieved through a process of bone remodelling where osteoclasts remove bone and osteoblasts add bone. Diseases that affect bone disturb the remodelling balance and the result is that excess bone is formed or lost or both. Bone diseases have a tendency therefore to be either mostly proliferative or erosive in nature. These mechanisms account for the majority of the changes seen in pathological bone (Beachley *et al*. 1977). The primary step in differential diagnosis in palaeopathological study is to differentiate a normal response from an abnormal one (Ortner 2012).

There are only a limited number of ways that bone reacts to disease processes (production or destruction or both), but with variation in the types of laid down bone (e.g. lamellar or woven). These dissimilarities are not always evident macroscopically and may be identifiable histologically or by other high resolution three-dimensional methods such as microtomography (µCT). Addition of a description of the bone surface process, for example the type of bone laid down and region (periosteal, cortical or endosteal), can improve a differential diagnosis markedly (Klepinger 1983).

It is through the identification of pathological changes from the 'normal' state of bone that disease can potentially be revealed. A fundamental knowledge of bone biology and histology is thus necessary to interpret bone responsiveness, and in addition, how to differentiate between normal and abnormal bone responses to disease (Buikstra and Cook 1980). Changes to the cortex would include features such as destruction, erosion and thickening (Beachley *et al*. 1977). Loss of bone to destruction can occur by resorption or direct destruction of trabeculae by metastatic tumour cells (Jaffe 1958). Early bone destruction may be recognised radiologically as a faint alteration of bone texture or minor decrease in bone density. A destructive focus is more easily visible in cortical bone than medullary bone and more easily apparent in normal than in osteoporotic bone.

2.1.4 Palaeoepidemiology- is it truly epidemiology?

The aetiology of disease in palaeontological, archaeological and modern contexts has been of great interest and the subject of much scientific endeavour throughout human history. This interest prompted many questions including who acquired diseases? What did they suffer from? When and where were diseases found? (Waldron 2007). These attempts at trying to provide answers in archaeological, palaeopathological and modern clinical contexts led to the rise of modern epidemiological and palaeoepidemiological studies.

Epidemiology is the study of the aetiologies, effects and patterns of disease in living human populations attempting to identify causal relationships between disease and demographic, social, and cultural risk factors (Pinhasi and Turner 2008). These studies involve the collection of data on the exposure features associated with the production of a specific disease/s (Lilienfeld and Stolley 1994), and include factors such as sex, age, hereditary characteristics, and environmentally associated factors, such as vectors related to the particular disease, climates, pollution factors, and individual and group living conditions (Waldron 2007; Pinhasi and Turner 2008). Case-control study strategies are

frequently used when evaluating different diseases and their associated risk factors. Modern epidemiology considers the identification and understanding of the potential causes of disease in living populations, with no interest in human, ancient or prehistoric remains (Waldron 2007).

In epidemiology, the main focus involves the study of disease and characteristics of populations, such as age data, height distributions, temporal trends or perhaps studies relating to preceding conclusions (Waldron 2007). They also attempt to discern the risk factors associated with disease in populations under study. In epidemiology, the subject being observed is frequently known as an 'outcome variable'. Studies of outcome variables are constrained by the available skeletal material in palaeopathology. Disease, death and other health associated outcomes are then determined and compared to other population groups.

Palaeoepidemiology can generally be defined as an interdisciplinary area of research which combines aspects of palaeopathology with epidemiology by applying particular epidemiological methods to the study of pathology and disease aetiologies in hominin and archaeological human remains from past populations (de Souza *et al*. 2003; Pinhasi and Turner, 2008). Palaeopathology's task is to make information and statistics available on the range of pathological conditions observed in bones and dentition of past populations. Palaeoepidemiology similarly to modern epidemiology also assimilates information on various geographies, environmental changes, societal and cultural risk factors of disease, and data extracted from contemporary clinical diagnoses, in order to assesses potential causes of disease. Factors such as sex, age, and genetic links would also need resolution, however in palaeoepidemiology, these can only be estimated (Waldron 2007; Pinhasi and Turner 2008).

The term palaeoepidemiology first found its way into the published literature inferring primarily epidemiology as it applied to past populations, or secondarily the epidemiology of past diseases (Angel 1966). This term and

several others with the prefix *palaeo-*, such as palaeopathology, and palaeodemography are considered somewhat controversial (de Souza *et al*. 2003). Is it truly correct to speak of a palaeoepidemiology? And is the proposition of epidemiological investigation in palaeopathology valid, considering the obtainable information in archaeological and palaeoanthropological sites? The majority of epidemiologists most probably would not agree with the notion of epidemiological interpretations based on the small numbers of dispersed skeletal material, spanning long time periods, available for study. Most contemporary epidemiological investigation methods are not considered suitable for the study of archaeological and palaeopathological assemblages although it is becoming a growing phenomenon that more papers in recent times are starting to include epidemiological analyses with their research (Tyson 1997).

In contrast to epidemiology, palaeoepidemiologists are primarily interested in ancient skeletal populations and lack the ability to collect data from living populations using the case control approach. These investigations do not start with and are not characterised by an identified outcome (Waldron 2007, 2009). Palaeoepidemiological study investigations are instead characterised as 'cross-sectional', and begin with various forms of bio- archaeological or palaeoanthropological data, including evidence of skeletal disease, which is utilised to reconstruct likely biological disease risk factors or exposure factor scenarios. The reconstruction of contexts and exposure variables in past populations is combined with skeletal data and modern clinical data on known diseases and a probable outcome is recommended (Buikstra and Cook 1980). This probable suggested outcome will be either a specific or non-specific disease identified by the process of differential diagnosis (Waldron 2009). Epidemiological methods have not always played a noteworthy role in palaeopathology studies due to the specific nature of archaeological and palaeoanthropological skeletal assemblages and their limited sample sizes. Consequently, many contemporary researchers exclude these types of methods from their research analyses due to these limitations. However, with the knowledge of the limitations characterising skeletal samples, population

level analyses may be helpful in the suggestion of significant inferences about the evolution of disease, its spread, and the history of disease in past human and hominin populations (Pinhasi and Turner 2008).

Waldron (2007) importantly points out that an assemblage is both not a population or a sample, because it is not a living or a random choice of those who once lived, and must at best be thought of as 'non-random'. The reason according to him that epidemiological studies on assemblages of human remains are problematic is that we have no control over the selection of these assemblages because of extrinsic and intrinsic factors.

There are four extrinsic (independent of any biological features of the assemblage) factors that act on the death assemblage. They also reduce the study base, so that the number of individuals for study is reduced and most likely makes it smaller than it was originally: 1) the proportion of all those who died whose remains lie buried at the site under study, 2) the proportion of those buried whose remains survive until discovery, 3) the proportion discovered, and 4) the total number recovered. Waldron (2007) further states that the intrinsic factor that needs consideration in this context is one of a death assemblage not a living population. This should be an obvious observation, but is often disregarded and an assemblage is examined as though it is a living population.

In palaeopathology therefore we are dealing with a study of remains that have suffered and died of diseases that are largely 'non-random' – a social or cultural construct not a biological one, suffering a number of destructions between death and discovery (Waldron 2007).

2.1.5 Shortcomings and limitations in palaeopathological samples, of palaeopathology as a discipline and 'the Osteological Paradox',

It is fundamental for a palaeopathologist to acquire an understanding of the characteristics and health status of past populations under study, by

establishing how representative a skeletal assemblage is for a population based analysis (Pinhasi and Bourbou 2008). Put another way, how accurately does a skeletal assemblage represent the population that once lived? (Waldron 2007). Ideally the sample would represent the precise number of deaths in the population during a particular temporal period (Alesan *et al*. 1999; Pinhasi and Bourbou 2008). The reality is different, however, as several taphonomic, demographic and cultural factors will certainly affect the skeletal sample thereby affecting the larger population sample (Waldron 1994, 2007; Hoppa 2002; Pinhasi and Turner 2008).

Critical to disease diagnosis and to the ultimate assessment of disease prevalence, is the level of preservation of bone remains (Pinhasi and Bourbou 2008; Turner-Walker 2008). The extent of remains lost can depend on the type of *in-situ* or surface environment where these samples are found, the level of exposure and weathering over hundreds, thousands or in the cases of fossils, millions of years, and their capacity to remain intact during excavations and other necessary processes post excavation until the final analysis of the samples. As different elements of the skeleton are characterised by differing structural strengths, preservation will be variable and brittle skeletal elements can be potentially underrepresented (Buikstra and Cook 1980; Lambert *et al*. 1982; Pinhasi and Bourbou 2008). Decreased mineralisation and the brittleness of some types of bone remains, for instance, juvenile and adolescent remains may also contribute to poor preservation and therefore may contribute to the lower representation of young individuals in some skeletal assemblages (Gordon and Buikstra 1981; Nicholson 2001).

The survival of archaeological and fossil bones with pathological lesions will also be variable and dependent on the severity and type of disease condition, and its effect on the physical integrity of the bone specimen. This is illustrated in leprosy cases where disruption to the peripheral innervation of the hands and feet causes a loss of sensation, and can invariably lead to skin ulcerations and infections to hand and foot bones (Steinbock 1976; Aufderheide et al. 1998). As a result, hand and foot phalanges are more rendered more

vulnerable to post-mortem damage and are often absent from affected individuals in skeletal assemblages (Pinhasi and Bourbou 2008). In numerous archaeological and palaeoanthropological cases skeletal elements can be damaged or absent, resulting in the poor preservation or total loss of pathognomonic characteristics and non-specific indicators of skeletal disease (Buikstra and Cook 1980; Pinhasi and Bourbou 2008).

Thus, palaeopathologists need to cautiously evaluate the state of preservation and completeness of bone or fossil specimens, including the potential presence of other diagnostic determinants to conclude whether the variability of preservation may prejudice diagnoses and analysis of disease prevalence (Pinhasi and Turner 2008).

The pathway from skeletal lesion frequencies to the prevalence of particular pathological conditions in past populations is complex and challenging. Wood *et al.* (1992) raised several contextual problems including what is commonly referred to as "the osteological paradox". Vigorous debates of these contextual issues and their implications on the interpretation of skeletal data have ensued since its publication (Goodman 1993; Cohen 1994, 1997; Wood and Milner 1994; Goodman and Martin 2002; Steckel and Rose 2002b; Wright and Yoder 2003; Milner *et al*. 2008).

The Osteological Paradox (Wood *et al*. 1992) is regarded as a significant paper in palaeoepidemiology, palaeopathology and archaeology. It emphasises some important difficulties relating to the interpretation of ancient health information from skeletal assemblages (Wood *et al*. 1992; Pinhasi and Bourbou 2008). Three important conceptual difficulties relating to assessment of population health status using archaeological remains are discussed in this publication: (1) 'demographic nonstationarity', (2) 'selective mortality', and (3) hidden 'heterogeneity in risks'. Wood *et al*. (1992) implied that if these issues are not dealt with, interpretations based on different demographic and epidemiological procedures could potentially carry limited value.

The first conceptual problem, demographic nonstationarity, discusses the parting of a population from a stationary condition. Stationary populations are characterised as non-migratory, with a zero-growth rate, an unchanging age-explicit fertility and mortality rate, and an age distribution that is regular and stable (Wood *et al*. 1992; Wright and Yoder 2003). Providing that a population is stationary, and most are not, estimated age-at-death distributions of the skeletal sample and data points such as life expectancy and mean age at death will suggest indications of fertility rather than those of mortality. Minor changes in fertility will have large influences on age-at-death distributions, while large changes in mortality have almost no effects (Wood *et al*. 1992).

The selective mortality problem confirms a truism that all remains of the individuals in the series are not part of a living population (Wood *et al*. 1992; Cohen *et al*. 1994). An archaeological and fossil hominin skeletal sample characterises only the individuals who died, and never represents all individuals of a population who were at risk of dying or contracting a disease. This means that each age group will be highly selected for pathological lesions that raise the risk of death in that age group. Therefore, the estimation of prevalence computed for the archaeological skeletal sample will have the same selectivity bias as the resultant group of preferences extracted from clinical data points, because both types of data do not constitute a representative sample of the total population at risk. Thus, the incidence of diseases in these two situations may overestimate the exact prevalence in the broader population (Wood *et al*. 1992).

The third issue, hidden heterogeneity in risks, implies that the population from which the skeletal sample is drawn consists of a random and unidentified mix of individuals who will vary in their vulnerability to disease and death, depending on many environmental, biological and cultural influences (Wood *et al*. 1992; Roberts and Manchester, 2005). Disease expression can fluctuate in their severity, infectious manifestation and distribution, and as a result of variances in the level of immunity and proneness of each individual in a selected population (Ridley and Jopling, 1966). Different individuals may

show variable expressions of disease. On the one end of the spectrum, the skeletal material of an infected individual may demonstrate pathognomonic characteristics of a disease. On the other end, another individual having the identical condition may exhibit hardly any abnormality. Factors that contribute to this variance in susceptibility, are mostly not identifiable and may confuse the interpretation of prevalence of a condition in skeletal series (Wood *et al*. 1992; Roberts and Manchester 2005; Pinhasi and Bourbou 2008). Wood *et al*. (1992) alert palaeopathologists against applying the method of identifying presence or absence of skeletal lesions in a sample as an unequivocal marker of disease or level of health status in a population as this can influence interpretations of disease prevalence in a past population that had previously lived (Wood *et al*. 1992; Roberts and Manchester, 2005).

Researchers in palaeopathology are at a distinct advantage in that they can study fossil or archaeological remains directly. One limitation however, is that studies are limited mostly to diseases affecting the skeleton. Most diseases involve soft tissues and skeletal diseases are generally not common. Therefore, palaeopathologists find it particularly complex to determine the exact cause of death of the fossil or archaeological materials being examined (Waldron 2007). This is a major drawback as the causes of death may well have changed over time, and this information would have added considerably to our understanding of the evolutionary history of disease. Another limitation in palaeopathology is that there is no standard system for diagnosing skeletal disease that all palaeopathologists can ascribe to.

Knowing the status of an individual's health when its remains became part of an assemblage, equally remains a fundamental problem. The reason is because the factors that determine their state of health not only depends on the diseases that affected their organs but also their diet, environmental and social conditions, their mental health, all of which cannot be determined from skeletal remains.

2.2 Pathology in the palaeontological record

Most of the early palaeopathological studies from the Renaissance period through to the middle of the 19th century focused on fossil faunal material. Johann Esper diagnosed an osteosarcoma in 1774 (Brothwell 1969; Aufderheide *et al*. 1998) in a Pleistocene bear femur, marking the beginnings of the field of palaeopathology (Ubelaker 1982). His diagnosis was later proved incorrect and was re-diagnosed as a healed fracture with callus (Brothwell 1969). The earliest known definitive case of neoplastic disease, an osteoma in a carboniferous fossil fish, *Phanerosteon mirabile* dated to approximately 300 Mya (Ackernecht 1955), is one of the earliest examples of neoplastic disease (Capasso 2005).

Instances of arthritis, cancer, and benign neoplasia in dinosaurs and fossil fauna illustrate that these conditions did not only occur in human populations (Lovell 2000; Capasso 2005). Moodie (1923) published a major work on prehistoric disease that included fossilised human, non-human and plant material. Only a few cases of neoplastic disease have been recognised in non-human animals including sea lions, gibbons, ferrets, seals, tigers, kangaroos, camels, deer, and killer whales (Capasso 2005). Other assessments of neoplastic disease in extant wild non-human primates (Lovell 1990), however, have indicated that neoplasia in monkeys and great apes may be more prevalent than have been proposed. The majority of cases however, consist of benign soft tissue tumours. A single case of benign osteochondroma was noted in a Gombe chimpanzee (Jurmain 1989).
Early research in dinosaur palaeopathology was characterised by a plethora of diagnostic hypotheses, most of which were never rigorously substantiated. There is a quantum difference between a hypothesised diagnosis of how a disease may affect a skeleton and observing the actual impact of known disease on the skeleton (Tanke and Rothschild 2002). Rothschild and colleagues developed an alternative approach (Rothschild and Tanke 1992; Rothschild and Martin 1993), using clinical cases and population samples

where diagnosis is known, in order to establish a standard for disease recognition (Tanke and Rothschild 2002).

Rothschild's studies in dinosaur palaeopathology demonstrated the potential of understanding some of their behavioural and lifestyle traits, and broaden insight into the diseases that affected them (Rothschild and Tanke 1992). Although haemangioma has been discussed by Moodie (1923), Rothschild's reporting of the Mesozoic haemangioma from the Upper Jurassic, USA is the first published case (Rothschild *et al*. 1998). While investigating the fossils at the University of Kansas Museum of Natural History, Rothschild and his colleague Martin, observed co-ossified vertebrae of a Mesozoic mosasaur *Platecarpus*, diagnosing it as a potential case of infectious spondylitis (Martin and Rothschild 1989). Erosive arthritis is the most frequent form of arthritis recognized in fossil specimens. Erosive arthritis spondyloarthropathy has now been reported in Perissodactyla extending back to the Eocene (Rothschild *et al*. 2001). Different types of bony overgrowth are known in dinosaurs. Rothschild and colleagues (2014) investigated pathological lesions in a camarasaurid sauropod. His results included the description and analysis of phalangeal lateral osteophyte formation, and enthesophytes in pedal fossil bones. The study indicated that the lateral osteophytes were symptomatic of osteoarthritis.

The recognition of cancer/neoplastic disease in deep prehistory is limited to osteomas in mosasaurs and haemangiomas in dinosaurs of questionable origin. A case of potential metastatic cancer was identified from a section of dinosaur bone (CM 72656) from an unknown location from the Morrison Formation in Colorado (Rothschild et al. 1999).

2.3 Early hominid pathology

Although the Plio-Pleistocene offers several examples of pathological conditions in fossil hominins, in general, the early hominin fossil record excluding the Upper Pleistocene has not been extensively studied and not many pathological lesions were described.

Early modern humans and their hominin ancestors were affected by several diseases including infectious diseases, degenerative conditions (Armelagos, Barnes and Lin, 1996) neoplasia among others (Capasso 2005; Aufderheide *et al*. 1998). Early hominin populations were probably too small and relatively widely dispersed to attract many of the acute transmissible pathogens common in densely populated sedentary communities (Burnet, 1962). However, Cockburn (1971) has suggested that Plio-Pleistocene hominins may have conceivably become ill, from diseases passed on from an evolutionary ancestral non-human primate.

Previously described lesions include an exostosis - myositis ossificans (Day and Molleson 1973) - in a *Pithecanthropus erectus* femur (Dubois 1937). Neanderthal specimens show evidence of traumatic insult, arthritis and infection (Ackerknecht 1955, Ackerknecht and Haushofer, 2016). Johanson *et al*. (1982a) reported that *Australopithecus afarensis* (A.L. 288-1 ['Lucy']), demonstrates a specific spinal pathology with severe thoracic kyphosis, new vertebral bone formation, compressed intervertebral disc space and minor osteophyte formation indicating probable Scheuermann's disease and abnormal bone formation (Cook *et al*., 1983). D2600, the holotype of *Homo georgicus* (Dmanisi) displays marked dental wear, periapical abscesses, enamel fracturing, tooth migration, dental rotation and arthropathic conditions (Martín-Francés *et al*. 2014). Olduvai hominin (OH8) (Leakey *et al*. 1964) displays osteophytosis and lipping (Weiss 2012). Porotic hyperostosis is a suggested diagnosis for the parietal fragments of Olduvai Hominid (OH 81) (Domínguez-Rodrigo *et al*. 2012). Specimens from Sima de los Huesos site, in Atapuerca, Spain, display bilateral temporomandibular arthropathic conditions, ear hyperostosis, osteomata, trauma, erosions on cranial vaults, extensive maxillary osteitis, apical root abscesses and lambdoid craniosynostosis (Pérez *et al*. 1997; Gracia *et al*. 2009). The Mauer mandible exhibits osteophyte formation, erosion, abnormal bone growth, osteochondrosis dissecans and periodontal disease (Schoetensak 1908; Czarnetski Jakob and Pusch 2003). Hulu 1 displays ectocranial pathology, new bone formation and resorption (Shang and Trinkaus 2008). The Büyük Menderes specimen (Kappelman *et al*. 2008) displays endocranial lesions.

The Salé specimen displays an abnormal nuchal plane (Hublin 1985), probably arising from congenital torticollis. It also suggests possible nuchal muscle atrophy (Hublin 2001).

Aubesier 11, a partial mandible, displays severe labial alveolar resorption and incisal apical root wear, buccal bone damage, periodontal and endodontic pathology, expanded root apices, lingual bone erosion, and alveolar bone loss (Lebel and Trinkaus 2002). La Chapelle-aux-Saints 1 displays osteoarthritis, osteophytic formation, eburnation of facet joints and Schmorl's nodes (Dawson and Trinkaus 1997). La Ferrassie 1 displays periodontal pathology, a fractured great trochanter, a small degree of vertebral osteoarthritis, and bilateral femoral, tibial and fibular periostitis and periosteal bone formation (Fennel and Trinkaus 1997). The Garba IV child displays abnormal enamel formation and amelogenesis imperfecta (Zilberman *et al*. 2004). KNM-ER 1808 displays coarse woven periosteal bone in its long bones (Walker *et al*. 1982; Fennell and Trinkaus 1997).

Closer to home, the 'Broken Hill' (Kabwe) cranium displays carious lesions, apical abscesses and periodontal disease (Carter 1928; Brothwell 1959). Price and Molleson (1974) described a temporal lesion, where the differential diagnosis suggested an intra-diploic dermoid tumour or an eosinophilic granuloma (Montgomery *et al*. 1994).

Shanidar 1 exhibits trauma related conditions, osteomyelitis (Trinkaus and Zimmerman 1982), degenerative joint disease, osteophytic and enthesophytic growth, and probable diffuse idiopathic skeletal hyperostosis (Crubézy and Trinkaus 1992). The KNM-WT 15000 (Nariokotome Boy) displays multiple congenital pathologies (Latimer and Ohman 2001), limb shortening, abnormally small vertebrae, and other spine pathologies suggesting an abnormally small-boned individual. Trinil I femur presents with a bony exostosis likely to be myositis ossificans (Kennedy 1983a). KNM-ES 11693, the Eliye Springs (Lake Turkana) specimen, presents with severe cranial thickening and porosis. The Singa calvaria exhibits a pathological deformity in the vault with a missing bony labyrinth in one of the temporal bones (Spoor *et al*. 1998).

Reed *et al*. (1993) described a left proximal femur (MLD 46), an Australopithecine (*A. africanus*) from Makapansgat, which displays characteristics of arthritis of the hip (Haeusler et al. 2015) in the form of osteophyte formation. Marginal osteophyte formation in human and hominin femoral heads are largely age related, and indicate the possibility that MLD 46 may have had this condition for a longer than usual period (Reed *et al*. 1993).

Staps's (2002) discussion of *A. africanus* (StW 431), a partial hominin skeleton from the late Pliocene from Sterkfontein (Toussaint *et al*. 2003), reported lesions present on two of the lower lumbar vertebrae. He suggested a diagnosis of spondylosis deformans possibly due to a traumatic insult. D'Anastasio *et al*. (2009) presented the first possible occurrence of brucellosis in the lower vertebrae of the same individual (StW 431).

Enamel hypoplasia, a pathological defect of enamel formation exhibiting pitting and indentation of dental crowns, is known from South African sites (SK 64), East African Plio-Pleistocene hominins, Neanderthals, archaeological, and modern populations (Brothwell 1963), and was reported in a study of early Swartkrans hominins by White (1978), who found that the incidence of enamel hyperplasia in the Swartkrans hominins was greater than that of the Sterkfontein hominins. White (1978) further demonstrated that enamel hypoplasia was found to be present in gracile and robust hominins at Swartkrans (White 1978).

Other dental lesions in the form of caries on a RM1 (SKX 5023) of an adult *Paranthropus robustus* (1.8 Mya from Swartkrans Cave) have been reported (Grine *et al*. (1990). Clement (1956) noted the presence of carious lesions in the mandible of SK 15, an early human specimen, from Swartkrans. Grine's studies (1981) described a case of alveolar resorption on Sts 24a and Sts 24, belonging to a juvenile *A. africanus* specimen, and were subsequently studied by Ripamonti (1988), who concluded that the individual suffered from a type of aggressive periodontitis, also known as pre-pubertal periodontitis.

A 5th metatarsal (SK 7923) bone fragment from an unknown hominin from Swartkrans (1.6-1.8 Mya), was diagnosed as having a benign osteoid osteoma by Franklin (2011), using conventional medical X- ray. There were no other associated remains of this individual found.

The 'Florisbad Skull' exhibits among other pathologies, cortical lesions and thinning, ante-mortem tooth loss, maxillary alveolar bone changes, maxillary resorptive activity, diploë disruption and an abnormally expanded medullary cavity. It also displays an ectocranial neoplasm and orbital roof lesions. Differential diagnoses include a haematological disorder, possible metabolic system disorder, possible traumatic insults, or Paget's bone disease. The orbital lesions may have also had an infectious origin (Curnoe and Brink 2010).

2.4 The use of imaging techniques in palaeopathology

Achieving accurate diagnoses in palaeopathology is potentially possible by using multiple methods to examine ancient skeletal disease. This analysis should include as many methods as possible to confirm diagnostic evidence (Grauer 2012). In order to determine which techniques will be the most viable to obtain diagnostic evidence, several factors have to be taken into account. The level of preservation of the assemblage is a primary factor in determining which method/s will be suitable to assess the material. The level of data required for research will dictate which methods are the most appropriate to be used.

Some diseases and pathological expressions may only be accurately diagnosed by utilising techniques such as internal bone imaging techniques. These methodological approaches may offer crucial internal information which can improve the accuracy of differential diagnoses (Schultz 2001). These additional methods of analysis which often complement macroscopic visual observations include conventional radiography (e.g. Stuart Macadam, 1989), clinical computed tomography (e.g. Harwood-Nash 1979; Lewin *et al*. 1990), microscopy and histology (Schultz, 2001), and more recent technological advances micro-computed tomography (Kuhn *et al*. 2007;

Rühli *et al*. 2007; Tafforeau *et al*. 2006, 2009). Histologic methods should be cautiously applied due to their destructive nature, and radiologic imaging can be expensive (Ortner 2003; Turner-Walker and Mays 2008).

Biochemical (isotopic and trace element recognition) and biomolecular methods (genetics, DNA and antigen identification) have made substantial impacts on palaeopathological science, but are not relevant to this study (for detailed discussions see Grupe and Dörner 1989; Katzenberg and Lovell 1999; Dittman and Grupe 2000; Katzenberg *et al*. 2000; Donoghue 2008; Roberts and Ingham 2008; Murphy *et al*. 2013).

2.4.1 Conventional radiographic imaging

It was not until the 1960s that radiographic methods were readily accepted by palaeopathologists, due mainly to the lack of medical and diagnostic knowledge, using radiography rather than microscopy to analyse skeletal remains (Wells 1963, 1964). Following the use of radiography in mummified remains, this method was gradually embraced for dry bone material to identify abnormal changes in bone, for example fractures, osteoarthritis and also dental conditions (Mays 2008).

The imaging of ancient human skeletal remains using plain film has been performed for over a century to visualize bone lesions, and it soon became evident that the images derived from X-ray were a powerfully efficient tool at the time to visualise bone (Fiori and Nunzi 1995). It was first recognised by Sir William Flinders Petrie (1853-1942), an Egyptologist, and other archaeologists in the late 19th century were quick to adopt this imaging method (Böni *et al*. 2004). It began to fall out of favour to a large extent in palaeopathology until the 1960s however, because of the method's expense (Filer 1995). Subsequently, numerous studies have employed radiographic methods over macroscopic ones to study fractures, osteoarthritic conditions and dental pathology (Metcalfe 2007). Conventional radiographic imaging is still considered a significant auxiliary to gross visual assessments of bone, in descriptive analysis and differential diagnosis of disease processes in

palaeopathology today (Lovell 2000; Lynnerup 2008; Mays 2008, Beckett and Conlogue 2010; Wanek *et al*. 2012).

Archaeological and fossil remains can potentially reveal considerable data when examined by non-intrusive radiographic methods. In the case of archaeological bone, it is not surrounded by soft tissue, and can be directly examined. Radiographic imaging provides important diagnostic information regarding internal structural changes and characteristics of a lesion not able to be seen through a macroscopic visual examination (Ortner, 2003; Roberts & Manchester, 2005; Rühli *et al*. 2007; Mays 2008; O'Brien *et al*. 2009).

When examining fossil bone and archaeological remains, radiographic imaging has historically been valuable in identifying sub-surface bone lesions, which are most often concealed from gross evaluation. With the use of radiography, prehistorical bone lesions can be compared with modern human lesion morphology, establishing a strong association between the pathological changes in prehistorical bone and those of modern patients with known disease (Mays 2008).

Since the advent of Roentgen's invention of the original X-ray photo plate in the late 19th century, the original design has undergone numerous changes, with the basic parts of imaging system and the principles of X-ray production remaining unchanged. The X -ray imaging system consists of 3 main constituents: a high voltage electrical supply capable of producing kilovoltage (kV) sufficient for imaging, an X-ray tube, and an image detector (Carlton and Adler 2001; Saab *et al*. 2008; Beckett and Conlogue 2010).

For several decades, conventional radiography has been extensively applied in numerous anthropological applications in palaeopathological research. Radiography is of significant value to palaeopathological research because it allows for a non-destructive approach to analyse internal bone changes caused by disease processes, but it also provides a direct link between the appearance of lesions seen in archaeological specimens and lesions in living individuals with known pathology (Resnick and Pettersson 1992; Rühli *et al*. 2007; Wade *et al*. 2009; Beckett and Conlogue 2010). Comparative

diagnostic measures from clinical X-ray and archaeological X-ray offer a meticulous, consistent and repeatable method for diagnostic evaluation (Stuart-Macadam 1987).

It is not therefore not uncommon to see medical/clinical and archaeological radiographic data points integrated in many major palaeopathological published works. This principally presents a basis for differential diagnosis of disease processes from radiographic imaging (Brothwell and Sandison 1967; Steinbock 1976; Ortner and Putschar 1981; Aufderheide *et al*. 1998; Ortner 2003).

Although radiography has an important part to play in determining pathological diagnoses in living individuals, and most certainly influences differential diagnosis processes in palaeopathological studies, its position when it comes to analysis of dry bone specimens has clear drawbacks (Beckett and Conlogue 2010). Consequently, even although a number of archaeologists have become exceedingly well versed in the interpretation of radiographic imaging, some of these researchers are lacking in experience or training may not be able to recognise pathology on radiographic imaging. This can result in major diagnostic data being overlooked by wrong imaging exposures, but also inadequate training can result in damage to equipment through erroneous settings and usage; time and financial loss (Chhem and Brothwell 2008; Beckett and Conlogue 2010).

Another limitation with radiographic imaging is that it is basically a two-dimensional image, and anatomy is a three-dimensional science. Certain tissues and bone structures therefore, end up being overlaid on the image. Changes to bone structures, and essential for purposes of differential diagnosis, may become concealed or overlooked altogether by unrelated structures (Rühli *et al*. 2007; Saab *et al*. 2008; Wu and Hochman 2009; Wade *et al*. 2009). In cases where morphological differences in skeletal structure may be slight, two-dimensional radiographic imaging may not be dependable enough to make a firm diagnosis, and three-dimensional structural data become necessary for accurate differential diagnosis (Wanek *et al*. 2012).

With three-dimensional visualization, skeletal structures can be assessed morphologically, as well as measured quantitatively for the detection of subtle differences caused by pathological changes, resulting in more reliable differential diagnoses and a better understanding of the pathogenesis of non-specific skeletal lesions (Wu and Schepartz 2009). Subsequently, a growing use of new radiological techniques in the field of medical sciences, for example computed tomography (CT), led to the availability of new choices which offered more complete and well-organised three-dimensional visualization of internal skeletal architecture in palaeopathology studies (Spoor *et al*. 2000; Rühli *et al*. 2002a, b; van Kaick and Delorme 2005; Lynnerup 2008; Wade *et al*. 2009).

2.4.2 Medical computed tomography (CT)

Since the 19th century and the subsequent innovation of radiographic imaging, several related techniques have been employed in the medical sciences. One of the most significant advances in radiographic imaging has been computed tomography (CT). Work began on the first CT scanners by Hounsfield, an English engineer in the mid-1960s. During the mid-1970s, Hounsfield and Cormack, a physicist, designed a new imaging technology to avoid the superimposition problem of structures, which characterised conventional radiography (Hounsfield 1973; Chhem 2006; Goldman 2007; Lynnerup 2008; Saab *et al*. 2008; Conlogue *et al*. 2010). Since the introduction of the first scanners in the early 1970s, there have been numerous advances, resulting in higher resolutions and faster acquisition times (Hsieh, 2002). CT scanning equipment is currently used in hospitals but with software designed for clinical purposes and specifically for imaging of tissues and organ systems of living individuals. Hounsfield and Cormack received a joint Nobel Prize in Physiology and Medicine for developing computed tomography (Lynnerup 2008). This new technology helped advance both the ability to image and clinically diagnose bone disease. Computed tomography and its processing functionality since its inception has been widely accepted as a valuable non-destructive method in

anthropology and palaeopathology studies (Recheis *et al*. 1999; Spoor *et al*. 2000; Rühli *et al*. 2002b; Minozzi *et al*. 2010).

Computed tomographic scanning generates an image in the format of a slice of the object being scanned. The object is then moved through the CT scanner, generating multiple two-dimensional slices, which may be viewed as serial, two-dimensional images. More technically advanced multi-slice versions became operational in the late 1990s. These systems delivered more comprehensive data than conventional X-ray imaging, and allowed for better perception into pathological changes in the body (Goldman 2000). Increasing computing power gradually increased the quality of imaging resolution and rapid three-dimensional visualizations, enabling palaeopathologists to visualize and record the condition of bone material at substantially higher resolution than was ever possible before (Marx and D'Auria, 1988; Pickering *et al*., 1990; Cesarani *et al*. 2003; Tafforeau *et al*. 2006, 2009).

In contrast to conventional X-ray, CT had the potential to identify small contrast variations, which made this technique exceedingly more valuable from a diagnostic perspective (Wanek *et al*. 2012). CT has also influenced the investigation of infectious diseases such as leprosy and tuberculosis in skeletal remains. Haas (2000) demonstrated the pathological signs of "facies leprosa" of the skull using CT imaging by recognizing extended osteolysis in the mandible and reactive new bone formation.

Because computed tomography is primarily based on X-ray type technology, the visualisation of skeletal material can easily be performed. This allows for bone structures to be viewed, measured, and assessed morphologically (Lynnerup 2008). Computed tomography (CT) has subsequently also created interest in diagnostic imaging of ancient hominin remains. Conroy and Vannier (1987) assessed the dentition and paranasal sinuses of the Taung 'Child', a young *Australopithecus africanus* specimen, using computed tomography, and a recent study in hominin brain evolution using high resolution computed tomography was performed on the same specimen (Holloway *et al*. 2014). A study using CT by Tobias (2001) involved the creation of virtual endocasts in hominin skulls. Computed tomographic

methods have also been used to separate skeletal material from soil matrix (Chhem *et al*. 2004).

There are limitations to access CT technology including the lack of availability of the equipment and systems for non-clinical research and significant operating costs that may restrain the use of CT scanning techniques in palaeopathology (Lynnerup 2008; Ortner 2008; Conlogue *et al*. 2010; Wanek *et al*. 2012). CT scanners have also been developed for diagnosing disease and traumatic injury in living individuals, and this takes priority over imaging ancient diseased individuals. Accessing scanners often means discussions with clinical imaging facilities to schedule scanning times when medical patients are not programmed (Conlogue *et al*. 2010).

There are a number of non-clinical research facilities equipped with CT scanning systems which has improved the accessibility challenges for anthropological study, but these are the exception (Conlogue *et al*. 2010). In light of the gradually improving accessibility and affordability of CT scanners systems, computed tomographic methods should under certain circumstances be considered for palaeopathological research: firstly, when additional three-dimensional diagnostic information on internal bone structures is necessary, and there are preservation issues such as with archaeological remains. It can secondly be considered, when internal abnormal skeletal changes, not obtainable from both macroscopic or radiographic methods, may potentially provide a more solid differential diagnosis (Wanek *et al*. 2012).

The erroneous use of CT scanner system settings by personnel with insufficient training and unaccustomed to the procedures required for ideal diagnostic imaging from dry skeletal material can be a serious drawback. CT scanners are designed with protocols for scanning living individuals, and it can be time consuming and expensive to adapt protocols for dry bone remains. Large amounts of time are invariably needed to assess the

appropriate settings for high quality CT imaging of dry skeletal material (Conlogue *et al*. 2010).

Examination of bone micro-morphology necessary to accomplish an accurate differential diagnosis in palaeopathological studies is constrained by the resolution delivered by most clinical CT scanning systems (Stauber and Müller 2008). Most modern clinical CT scanners can reach a spatial resolution suitable for the diagnostic assessment of soft tissue structures and bone morphology, but does not achieve the resolution level necessary to demonstrate internal bone structures of trabeculae (Stauber and Müller 2008; Wu and Schepartz 2009).

The spatial resolution and slice thickness constraints of clinical CT scanners may cause volume effects when assessing smaller structures, and volume artifacts will most probably affect the quality of CT images for structures such as trabeculae, making their examination difficult or impossible (Zollikofer and Ponce de León 2005; Lynnerup 2008).

Cross-sectional clinical imaging technology such as computed tomography (CT) has afforded palaeopathologists, archaeologists, and clinicians the ability to examine skeletal and soft tissue remains non-destructively (O'Brien 2009), and provided an efficient method to evaluate palaeopathological and archaeological remains. The importance of using non-invasive methods has clear long-term benefits for museum and palaeopathological collections and is gaining momentum in replacing histological thin-sectioning of palaeopathological, and palaeoanthropological specimens.

In summary, the value of non-destructive computed tomographic (CT) imaging to researchers in palaeopathology is considerable and the role it plays in differential diagnosis continues to be important (Lynnerup 2008).

2.4.3 Micro-Computed tomography

Micro-focus X-ray computed tomography (μCT) is a relatively recent imaging technique, which emerged in the early to mid-1970s (Hounsfield 1973). In the mid-1980s, a number of micro-CT (μCT) scanners were developed with small, bench type X-ray systems, making the technology more easily available to researchers

Although another innovative imaging technique, synchrotron radiation, emerged at the time (Bowen *et al*. 1986), which could easily achieve sub-micron (μm) resolutions, growth in the application of this technology was pedestrian as a result of its limited availability (Bart and Wallace 2013).

During the late 1980s, Feldkamp together with colleagues developed the first micro-computed tomographic (micro-CT) system for high-resolution, three-dimensional (3D) imaging of the skeletal micro-architecture in small animal models, to clinically investigate osteoarthritis and osteoporosis (Feldkamp *et al*. 1989; Kinney *et al*. 1995; Balto *et al*. 2000; Holdsworth and Thornton 2002). Since then, this particular technique has gradually gained in stature to become the 'gold standard' for examining three-dimensional (3D) architecture of trabecular bone tissue (Tafforeau *et al*. 2006; 2009; Britz *et al*. 2010), and is considered an effective non-intrusive imaging method suitable to investigate highly mineralised fossil specimens (Ryan and Van Rietbergen 2005; Mazurier 2006). According to Pinhasi and Mays (2008), it was potentially the most important modality to emerge out of radiographic imaging methods. Over the last 40 years, and with the continued development of clinical computed tomography, imaging techniques have improved considerably.

The majority of current research in the area of micro-CT development focuses on resolution improvement for imaging of small animals in-vivo and experimental studies of ex-vivo tissues related to the study of disease, organ structure, and drug treatments (Bart and Wallace 2013). Micro-CT has been performed to assess ancient bone and teeth (McErlain *et al*. 2004) to further our understanding of pathogenesis and evolutionary skeletal pathology.

It is a non-invasive radiation based research technique to study very intricate and fine samples in a non-destructive way. This technique is an adaptation of computed axial tomography, and in relation to medical CT, delivers images with a much higher resolution and substantially narrower slice thicknesses (Mees *et al*. 2003). This non-invasive imaging technique can produce three-dimensional images and two-dimensional maps with voxel sizes that approach sub1μm, giving it a considerably better-quality resolution than ultrasound and magnetic resonance imaging (MRI) (Müller 2009). Reconstruction of a 3D image is achieved by rotating the sample (desktop system) to produce a series of 2D projections. These will subsequently be converted into a 3D format, using a digital protocol known as back-projection (Guldberg *et al*., 2003; Müller 2009).

It can be used to assess internal bone structures using three-dimensional imaging, to identify and diagnose pathology and disease expression in hominin fossil bone and modern human bone comparatives, at qualitatively higher resolutions than are currently achievable with clinical scanning modalities (Straight *et al*., 2009; Particelli *et al*. 2012; Sutton, Rahman & Garwood, 2014).

While micro-CT, as with histological thin-sectioning, can expose intricate patterning of specific disease processes (Schultz 2001), it appears that with micro-CT methods, diagnostic features inferable to specific conditions, are still difficult to identify for the majority of non-specific bone lesions (Morgan 2014). Three-dimensional (3D) micro-CT methods nevertheless are proficient enough to provide precise visual diagnostic data on specific diseases, a critical non-intrusive tool required for differential diagnoses in pathological specimens.

Micro-CT imaging systems offer several advantages over conventional CT imaging for the evaluation and analysis of archaeological human bone. Unlike conventional CT scanners, not only does micro-CT offer higher resolution images in the micron range, the modified equipment set-up developed by Feldkamp *et al*. (1989) also allows micro-CT images to be reconstructed in three-dimensional form (3D), rather than as a series of two-

dimensional slices (Feldkamp *et al*. 1989; Kuhn *et al*. 1990; Rühli *et al*. 2007).

One of the main advantages of micro-CT over destructive methods is the ability to non-destructively qualify and quantify bone micro-structure in 3D. Evaluations of the morphological features and characteristics of cortical and trabecular bone based on 2D histologic sections are not representative of the complete 3D structure of the sample.

Although the three-dimensional structure of cortical bone is relatively simple to characterize, trabecular bone structures are extremely complex and variable. Singular 2D sections cannot present a comprehensive representation of the variability in trabecular micro-architecture while micro-CT imaging allows an accurate depiction of the 3D trabecular network of skeletal samples (Feldkamp *et al*. 1989; Guldberg *et al*. 2003; Rühli *et al*. 2007). Image processing algorithms, quantitative analysis features, and tools to determine variations in skeletal micro-architecture and spacial volumes have been developed to assist in the interpretation of micro-CT images (Feldkamp *et al*. 1989; Barbier *et al*. 1999; Holdsworth and Thornton 2002).

Morphometric measurements historically assembled from two dimensional histologic thin-sections is currently capable of being accumulated in 3D for non-invasive research studies (Barbier *et al*. 1999). Micro-CT post-processing computer programs (such as VG Studio) using 3D tools are able to assemble data using identical morphometric bases extracted from thin sections, including bone and surface densities, and trabecular features such as thicknesses, number, spacing, and degrees of anisotropies (Barbier *et al*. 1999; Ulrich *et al*. 1999; Stauber and Müller 2008).

Assembling, reconstruction, and morphometric study of micro-CT images are capable of being completed in a few hours or less, depending on the size of the sample, choice of resolution, and capability of software capability. A large assemblage of skeletal specimens can be scanned and studied without performing invasive processes which can cause irreparable harm to valuable archaeological and fossil remains (Guldberg *et al*. 2003; Rühli *et al*. 2007).

Although only a small number of palaeopathological studies have applied micro-CT techniques to the examination of historical and archaeological bone pathologies (e.g. McErlain *et al*. 2004; Tafforeau *et al*. 2006; 2009; Kuhn *et al*. 2007; Rühli *et al*. 2007; Wade *et al*. 2009; Swain and Xue 2009; Minozzi *et al*. 2010), the number is gradually increasing. Micro-CT scanners and its associated reconstruction and visualisation software, which is needed to construct micro-CT images are expensive and the equipment is not yet readily available to the broader scientific community. This may explain in part the low level of adoption of this method by palaeopathological researchers (Müller *et al*. 1998; Rühli *et al*. 2007). In recent years, however, various types of micro-CT scanning technology have become more widely available and accessible to researchers in an increasing number of scientific disciplines (Rühli *et al*. 2007).

2.4.4 Propagation phase contrast X-ray synchrotron microtomography protocol (SRμCT)

Tafforeau *et al*. (2006) demonstrated that propagation phase contrast synchrotron imaging (Snigirev *et al*. 1995; Cloetens *et al*. 1996a) is an effective way to reveal and precisely locate inclusions in fossil material prior to microtomographic investigations. Phase contrast imaging was originally developed using synchrotron sources, but the effect can also be observed in some cases using micro-focus X-ray tubes (Wilkins *et al*.1996), and was used recently to image small inclusions in amber using micro- CT (Dierick *et al*. 2007).

Despite the superior quality data that can be extracted from several clinical scanners, the examination of many fossils remains problematic. The utilisation of a third-generation synchrotron source optimised for hard X-rays, instead of conventional sources, creates a new alternative technique to investigate fossilised material. Indeed, X-ray beams used for X-ray synchrotron microtomography (SR-μCT) at the ESRF present three main properties that significantly improve data quality and imaging options: the monochromaticity, high beam intensity and the partial coherence.

This technique is now widely accepted as the gold standard for high quality, non-destructive, virtual 3D- reconstructed imaging of fossils. It has a superlative record of imaging internal structures of fossilized material with high degrees of quality (Tafforeau *et al*. 2006; 2009), and includes larger specimens (Carlson *et al*. 2011; Sanchez *et al*. 2013). The use of propagation phase contrast X-ray microtomography can reveal structures that are completely invisible using X-ray absorption only (Lak *et al*. 2008; Fernandez *et al*. 2015).

Observations of the external morphology of fossilised material are not always enough to identify all the data needed for a paleontological study. This imaging technique allows imaging the internal structures of a large variety of fossils with a resolution and precision not obtainable with other non-destructive methods (Tafforeau *et al*. 2006.

Today, observations of internal structures are becoming increasingly important to study. It is clear nowadays that these observations should be non-intrusive, primarily to preserve highly relevant and significant samples. The finest quality microtomographic images are acquired with third-generation synchrotrons producing hard X-rays. This technique vastly improves the image contrast, and therefore is ideal for studying fossils that cannot be examined by conventional micro-CT, as a result of high levels of mineralisation or low absorption contrast (*ibid*. 195). A series of scans is usually carried out using specific beamlines. When acquisition of the data is complete, reconstruction is performed using a filter back projection protocol adapted to suit local tomography purposes, taking into account ring artefact correction protocols (Lykegaard *et al*. 2011). Scans are then segmented in 3D, using region growing protocols with software from VGStudioMax 2.1 (Volume Graphics, Heidelberg, Germany).
Propagation phase contrast X-ray synchrotron microtomographic imaging has been demonstrated to potentially be an ideal technique to investigate palaeontological specimens (Tafforeau *et al*. 2006). This system is currently located at the European Synchrotron Radiation Facility, in Grenoble, France,

but due to its high cost and size, large synchrotron technology systems are generally inaccessible to small or medium size research institutions and laboratories (Eggl *et al*. 2015).

Chapter 3
MATERIALS AND METHODS

3.1 Materials

For purposes of this study, a total of 3050 hominin fossil bone and tooth fragments were examined. These originated from eight South African Plio-Pleistocene hominin assemblages namely Sterkfontein, Swartkrans, Makapansgat, Kromdraai, Taung, Cooper's Cave, and selected fossils from Malapa, and Dinaledi Chamber (Rising Star) caves. The fossil assemblages of Swartkrans and Kromdraai are housed at the Ditsong Museum of Natural History (formerly the Transvaal Museum). The fossil assemblages of Sterkfontein, Makapansgat, Taung, Malapa and Dinaledi Caves (Rising Star), are housed at the Phillip V. Tobias Hominin Collection, in the Evolutionary Studies Institute, at the University of Witwatersrand. Permission to study the fossil material was obtained from the curators of the Phillip V Tobias hominin collection, and the Ditsong Museum of Natural History.

In order to better understand normal and pathological morphology of fossils found in the eight fossil assemblages in this study, a survey of a normal and pathological modern human bone needed to be conducted to for morphological and pathological comparison. The comparative collections housed at the Raymond A. Dart Collection of Human Skeletons (Dart Collection), in the School of Anatomy, at the Faculty of Health Sciences, of University of the Witwatersrand were used for this purpose.

3.1.1 Facilities and equipment

The equipment used for this study included a micro-focus X-ray computed tomography system (micro-CT), an Olympus SZX 16 multi-focus microscope with digital camera capability, with Analysis 5.0 software both housed in the Evolutionary Studies Institute, at the University of the Witwatersrand; and a phase contrast X-ray synchrotron microtomography system (micro-CT) housed in the European Synchrotron Radiation Facility (ESRF), located in Grenoble, France. The Nikon XTH 225 ST micro-focus X-ray tomography system is fitted with a large X-ray cabinet, an external control module, and chiller, X-ray tube, sample manipulator and flat panel detector with a 16bit dynamic range. The size of the detector (Perkin Elmer) is 400 mm x 400 mm with a pixel size of 200micron x 200micron. The Nikon XTH 225

system is fitted with pre-installed image acquisition and sample manipulation software, and an automatic function for tomography. X-ray features of the XTH 225 ST μXCT system include a voltage range 30-225 (kV); Current: 0-1 (mA); Spot size (+/-1-3 μm); beam angle (25 degrees). Further characteristics include several different axis directions; capacity to move the sample in a horizontal plane (20mm); in a vertical plane (300 mm); and the capacity to move the sample in the direction of the beam bearing (610mm). It also provides for a revolution accuracy of 1/1000th of a degree. The system is also installed with reconstruction software (CT-Pro) to transform 2D projections into a 3D volume later visualization (VG Studio and analysis (Hoffman and De Beer 2012). The final product from a reconstruction in CT-Pro is a 'RAW' 3D volume file was imported into VGStudioMax visualization software to enable differentiation between different materials following segmentation. Secondary reconstruction processing was performed using Avizo Amira 5.4 computer software.

The propagation phase contrast X-ray synchrotron system (European Synchrotron Radiation Facility, Grenoble, France) (ESRF) is a cyclic particle accelerator, in a fixed closed-loop system, and includes various functional parts including an electron gun, a linear accelerator, a circular accelerator, an imaging beamline, an optical which contains diaphragms, filters, a control shutter to control bandwidth, photon flux and beam dimensions of the X-rays. A satellite laboratory houses the monochromators and the experimental receptacle. The system also includes a storage ring, undulator, wiggler and bending magnet, sample rotator, lens and cooling system. Collectively this makes up the assembly of the of the synchrotron facility at the ESRF (see fig. 1 a, b; Betz *et al*. 2007). The synchrotron assembly and functionality are more fully described later (see section 3.3.3).

3.2 Methods

In the pursuit of the most accurate differential diagnosis, the analysis of bone lesions should embrace as many methods as possible in palaeopathological studies (Grauer 2008). It is important to consider a number factors in the determination of which methods would be the most appropriate in the circumstances to ultimately obtain the most accurate and reliable differential diagnosis. The degree of preservation of

archaeological and fossil specimens will be critical in the determination of which particular methodological approach should be selected. Methods will be shaped by the extent of analysis needed to answer particular questions and the types of information required. Gross visual examination is the primary method used to examine archaeological bone for pathological lesions (Pinhasi and Mays, 2008; Ortner 2012). According to Schultz (2001) some diseases are only accurately diagnosable using radiologic and microscopic techniques, which can offer the necessary osteological data needed to enhance the quality of diagnosis (Schultz 2001). When further techniques are able to offer substantial additional auxiliary data to a study, and can potentially influence the diagnostic outcome positively, these should be considered. Some methods for example, biochemical and radiologic imaging, are costly, and others such as histology are clearly invasive. All these methods therefore need to be approached with caution (Ortner 2003; Turner-Walker and Mays 2008).

Over the last five decades there has been a considerable movement by palaeopathological researchers to improve the diagnostic criteria of diseases (Grauer 2012) and strengthen the rigour in the discipline. The meaning of scientific rigour in palaeopathology fundamentally refers to "*the need to carefully follow protocols and to exercise objectivity in drawing conclusions…not attempting to render a diagnosis beyond the available data… considering all possible alternatives when constructing a differential diagnosis…the researcher must be…objective in searching out all possible relevant evidence rather than selectively choosing a facile example that supports a favored explanation"* (Buikstra *et al*. 2017, *article in press*).

For the purposes of this study, all remains were assessed for specific as well as non-specific signs of disease. This was carried out using a hand lens coupled with a light lamp, a 10x magnification lens, and the naked eye. Following an initial evaluation, observations of surface bone were performed using a multi-focus microscope with image enlargement capability.

Observations of non-specific and specific indicators of disease included various forms of lytic and erosive lesions, new bone formation, presence of callus, abnormal bone formation, periosteal pitting, exostotic and other bony outgrowths, neoplasms,

fracturing, generalised bone remodelling, pitting, osteophytes, enthesophytes, tooth caries, periodontal disease, and fusions.

Researchers started improving recording and diagnostics of disease using comparative clinical data combined with cutting-edge technologies (Pinhasi and Mays 2008). Several important literary works emerged in this regard, such as Ragsdale's descriptors for bone lesions (1992), Thillaud and Charon's (1994) study on standardising macroscopic terminology, and Lovell's palaeopathological study (2000). A significant contribution to methodology emerged from the Paleopathology Association Skeletal Database Committee Recommendations, which produced a set of guidelines for the types of data and methods to employ (Rose, 1991) in palaeopathological studies. These sources including others (e.g., Jurmain and Kilgore 1995; Martin and Osterholtz 2015; and Waldron 2009 for osteoarthritis) were the basis of choice of scoring methods used in this study.

3.2.1 Observation of modern comparative human skeletons

This study began with a preliminary survey of modern human cadaveric skeletal material to more fully understand and identify variations between normal and pathological human bone morphology, and pathological and normal morphological features of various extinct hominin species from the eight hominin fossil sites in this project. The comparative modern human skeletal collection housed in the School of Anatomical Sciences (Raymond A. Dart Human Collection of Human Skeletons), in the Faculty of Health Sciences, at the University of the Witwatersrand was used for this purpose. These modern specimens were studied to assist in identifying the spectrum of abnormal bone changes and their association with various disease conditions as far as possible.

3.2.2 Investigation of hominin fossil assemblages

Full skeletal inventories of all available abnormal cranial and postcranial fossil material from the eight sites included in this study was entered into a dedicated and purpose designed data file, including photographs of observable pathological lesions and expressions of disease. The data fields included cave site locations, institutionally allocated specimen numbers, genus and species groups, anatomical and dental

element identifications, presence or absence of pathological lesions, type of lesions and published reference data.

For some diseases exhibited in dry bone specimens, accurate identification is possible, such as fractures and some infections, and some characteristic bone lesions are easily comparable with modern skeletal homologues. However, some conditions present with ambiguous evidence, as bone can only react to a limited number of ways to disease. The lack of sufficient, clinically diagnosed and appropriately recorded specimens and the difficulty in finding abnormalities in bone that are unique to individual diseases are considerations that remain significant to palaeopathologists when determining appropriate diagnostic methods for dry bone specimens (Miller *et al*. 1996). According to these authors, there may be no modern diseases or evidence that produces variations in bone that are identical to those in prehistory. Some diseases may have become extinct due to natural selection and have no modern homologue (Miller *et al*. 1996).

3.2.3 Scoring Methods

To analyse and diagnose diseases and specific lesions in fossil, archaeological or modern bone remains, many methods can be followed. Diagnostic accuracy, however, depends on a number of factors and there is considerable morphological overlap with various diseases (Miller *et al*.1996). There is no single methodology to carry out macroscopic diagnoses and data collection. Guidelines introduced by several researchers in the field of palaeopathology have been helpful in consolidating several useful gross techniques. Systems of scoring have been developed for various disease and pathological conditions, including for enamel hypoplasia (Hargreaves *et al*. 1989; Fédération Dentaire International, 1992; Ensor and Irish, 1995; Blakey and Armelagos, 1997; Ogden 2008), and periodontal disease (Ramfjord 1967). Assessment of degenerative and osteoarthritic lesions usually follow Jurman and Kilgore (1995), and Rogers and Waldron (1989). Researchers are generally in agreement with the scoring methods developed by Jurmain, (1991), Kilgore *et al*. (1997) and Smith (1996) for healed long bone fractures. For purposes of this study, disease conditions and pathological morphologies were noted as present or absent.

In all cases where attempts are made at a specific diagnosis, a differential diagnosis should be included. A comprehensive list of potential aetiologies should be considered, and would also include taphonomic processes that potentially can mimic antemortem abnormal bone changes (pseudopathology). Important factors including palaeoanthropological, archaeological, demographic (age and sex), environmental, and contextual data, where applicable, should be taken into account in the analysis of the material. Microscopic, radiographic and biochemical investigations can assist (Pinhasi and Mays 2008). Following this, data need to be synthesised to arrive at a possible identification of the disease (Aufderheide et al. 1998; Ortner 2003; Schultz 2001). Whilst these methods are there to arrive at a diagnosis through the eventual elimination of the majority of potential disease options, often the researcher is faced with several diagnostic options (Pinhasi and Mays 2008).

3.2.4 Macroscopic method

All specimens were initially examined using gross visual methods, which included the aid of a 10x hand lens and a magnifying lamp, for the presence or absence of surface disease processes and pathological morphology. Fossilised bones demonstrating pathological expression and assessed as having transpired during the life of the individual was included in the study. This process included the taking of selected photographic and microtomographic images of skeletal elements with noticeable abnormal lesions.

In the investigation of palaeopathology, the first step involved identifying whether the skeletal element exhibited abnormal characteristics. Identification criteria involved in the identification process followed Buikstra and Ubelaker (1994), Aufderheide *et al*. (1998), Ortner 2003, Roberts and Manchester (2005). The next step in the process was to observe the locus of abnormality. Lesions were identified, using the following categories after Ortner (2003: 49):

1. single pathological focus;
2. multifocal and bilateral pathology is identifiable in two or more sites within the skeleton;
3. random multifocal abnormalities;
4. a general decrease in bone mass evident; and

5. localised or general size and shape disruptions

The next step was to determine the type of abnormal morphology, which is classified according to Ortner (2003) in 4 categories, abnormal bone size, loss, shape, and formation. Abnormal bone formation includes examples such as compact bone formation, which includes smooth compact bone formation; porous, striated or spiculated compact bone, and plaque (smooth thin and flat compact bone exhibited on a flat normal bone surface). Abnormal destruction includes no clear margin; a clear margin with no evidence of repair (absence of sclerosis); clear margin and evidence of repair (sclerotic); centralised destruction with evidence of margin formation; porotic focal damage. Other types of destruction include remodeling damage, generalised porotic destruction; osteoporosis and osteopenia, and fracture damage.

Abnormal formation of bone is typically a pathological process occurring antemortem. Fossil and archaeological bone material sometimes exhibit abnormal bone protrusions which result from a post-mortem process, such as concretions from chemical elements present in soil material in the burial environment, and become attached to bone surfaces. This may mimic pathological processes (pseudopathology) (Wells 1967; Ortner 2003). Bone destruction is frequently associated with disease processes and is also known to be caused by post-mortem processes affecting bone. The determination whether the irregularity in bone is from an ante-mortem or post-mortem process is often difficult. It is necessary to use some form of magnification (Ortner 2003).

The evidence of ante-mortem disease processes in bone is typically identified by the presence of rounded or smooth edges which indicates attempts at healing. Sharp irregular edges are rarely found in association with pathological processes, which are common in cases of postmortem destructive activity. Ante-mortem destructive lesions usually exhibit osteoblastic activity in the form of rounded edges or proliferative bone formation often at the margins of the lesion. Any type of remodeling or the presence of repair of bone indicates that the lesion is ante-mortem.

After collecting the above data, published literature reference material and modern comparative collections were then used to potentially categorize pathological

conditions observed. As a result of the considerable complexity in concluding reliable differential diagnoses, broad categories of disease rather than specific diagnoses were used (Waldron, 1994; Miller *et al*. 1996). This study focused primarily on the identification of hominin diseases. In so doing, several potential causes of the pathological skeletal conditions were proposed including the differential diagnosis methodology to potentially diagnose abnormal fossil bone expression in the project sample.

3.3 Imaging techniques

The methods used to identify different lesions are primarily based on visual assessment of specimens to establish the presence or not of abnormal development or any markers that could potentially indicate pathology on the external and internal surfaces of fossil bone. Primary visual macroscopic assessment was undertaken using the naked eye and a 10x magnification magnifier lamp with oblique lighting, to emphasise surface morphological differences, such as woven bone formation, lytic lesions, or non-weathered artefacts. Following this initial investigation, several additional methods of data acquisition and visualisation were employed:

- An Olympus SZX 16 multi-focus microscope with digital camera capability, with Analysis 5.0 software.
- Micro-focus X-ray computed tomography (micro-CT).
- Phase contrast X-ray synchrotron microtomography.
- Clinical X-ray (comparative analysis from source literature).

3.3.1 Microscopic imaging

Microscopic imaging was the first imaging method applied to specific fossils to investigate for probable pathology. It was achieved using an Olympus SZX 16 multi-focus microscope installed with digital camera competency fitted with Analysis 5.0 software. This software is equipped with a functionality (Z-stacking function) that allows for a ‘smoothing’ effect which can be applied to images and permits multiple images to be combined into a single high-resolution image. A record was prepared of

the presence of pathology in the study sample and arranged by species and genus, pathology type, anatomical element and site (see Appendix A).

3.3.2 Micro-focus X-ray computed tomography (µCT) protocol

Micro-CT provides improvements over and above normal CT. Although computed tomography (CT) is a commonly used imaging method and diagnostic tool for examining and interpreting internal bone structures in radiology and is useful at imaging skeletal tissue (Ortner 2003), conventional CT imaging has some disadvantages. They include limited contrast resolution, and resolution depending on the field of view (FOV). Blurring of images and contrast reduction are frequent drawbacks, and limited soft tissue discrimination of compacted tissue layers can be a problem. Some clinicians have also been critical of the quality of CT imaging and diagnostic certainty with ancient remains in comparison to modern samples (Wanek *et al*. 2012).

Micro-focus X-ray computed tomography (µCT) was the second imaging method used. It was also applied to assess internal bone structures using three-dimensional imaging, identify and diagnose pathology and disease expression in hominin fossil bone and modern human bone comparatives. This could be done at qualitatively higher resolutions than are currently achievable with clinical scanning modalities (Straight *et al*. 2009; Particelli *et al*. 2012; Sutton *et al*. 2014).

This non-invasive imaging technique permitted scanning and mapping of external and internal bone structures of fossil and modern comparative human bone material. High-resolution imaging quality was a critical factor (especially sub-micron resolution capability) needed for evaluation and interpretation of pathological lesions, and a careful evaluation of qualitative resolution capability was taken into consideration when selecting this method. Other important factors included establishing the uppermost limits of the detector apparatus, focal point magnitude, and magnification capacity (Stauber and Müller 2008).

Several specimens were micro-CT scanned at the South African Nuclear Centre for Radiography and Tomography, situated at NECSA (the South African Nuclear Energy Corporation), using a Nikon XTH225ST µXCT system. The remainder of the specimens was micro-CT scanned with a Nikon Metrology XTH 225/320 LC dual

source industrial CT system at the Evolutionary Studies Institute of the University of the Witwatersrand (ESI). The primary responsibilities undertaken using these two systems were to accomplish three-dimensional virtual imaging reconstruction, visualisation, and analysis of fossilised and modern comparative skeletal specimens selected for this study. The imaging was aimed to include scanning both external and internal bone matrices, porosities and fracture quantification. Both systems have similar features, and the resultant images of both are almost indistinguishable in quality and visualisation.

Before any scanning acquisition took place, samples were firmly secured onto a receptacle and enclosed with Styrofoam to safeguard and protect them against any movement and possible damage during the acquisition process. The reason for the selection of Styrofoam is that it is radiolucent, generally invulnerable to X-rays, and does not affect the final imaging results, whereas other resources such as cardboard and other solid materials are radiopaque and will become detectible in the scanned images, making them unsuitable for analysis (Stauber and Müller 2008; Conlogue *et al*. 2010).

Samples are placed whenever possible, with the longest axis situated in line with the rotating axis of the scanning apparatus, to lessen the extent of material that the X-rays have to pass through (Saab *et al*. 2008), and the impact of beam hardening. Following the fixing and placement of the samples in the sample container, density parameters and maximum resolution limits were determined and entered into the system. Optimal spatial resolution of micro-CT images is contingent upon a number of factors that need to be considered and include the resolution limits of the X-ray detector, spot size, geometric magnification, and steadiness of the rotating device, and size of the scanning sample (Holdsworth and Thornton 2002; Stauber and Müller 2008).

Current micro-CT techniques had to be modified to allow for as high a resolution as possible in order to arrive at results that were sufficiently good enough, if not better than the resolution of destructive-type methods (i.e. histology), which is capable of achieving sub-micron (µm) resolution. As a visually suitable resolution for analysing trabecular bone microstructure has been previously determined to be between 50 and 100µm (Stauber and Müller 2008), a scanning protocol needed to be adapted to achieve a higher resolution to allow for microanalysis within and on the surface of

bone as close to sub-20 µm, or as close to this parameter as possible. The highest nominal resolution was achieved by fine-tuning the system's field of view (FOV) capability, until the amplification level and position of the sample occupied around 85-95% of the field of view. The sample was then revolved 360º to confirm that it would be totally in view throughout the entire scanning process (after Morgan 2014).

While micro-CT can accomplish a higher nominal resolution for a particular bone locus, the outcome is invariably a lower image quality. Subsequently if a section of the specimen is excluded horizontally from the image, the data regarding that particular section of the specimen's revolving angles will not be available. As a result, artifacts will most probably appear in the reconstructed image volume. Therefore, a decision had to be made to either accept a high image quality with a lower resolution in some cases, rather than an inferior image with a higher resolution. In the case of smaller size specimens, the problem was somewhat alleviated, as the field of view was able to accommodate the relatively smaller fossilized bone material (after Stauber and Müller 2008; Morgan 2014).

Specific scanning protocols for the various specimens to be scanned were then established. As a direct result of the different sizes, contours and thicknesses of the fossil and modern bone material, the kVp levels had to be perfected accordingly to allow for precise pervasion. Following these steps, the system is started and radiographic scanning (X-rays) of the rotating specimens sends signals from a particular mark to a detector panel.

When the level of nominal resolution was decided, a scan protocol for each of the samples was defined. Integration time and average frame is fixed, while energy and current and some projections are not. Because of the many irregularities inherent in shapes, thicknesses and sizes of fossil bone material, energy levels (kVp) had to be attuned for each specimen to allow for sufficient diffusion. Thus, the ideal energy levels (kVp) were chosen when most of the anatomical characteristics were discernible, and internal bone structures were at least detectable. All specimens were then scanned using a potential difference of between 60 kV and a current of 75 µA, and at resolutions of between 8µ-33 µm.

After the completion of scanning, the images were saved as a series of unbroken TIFF files. Using CT-Pro reconstruction software, the resultant micro-CT volume was generated. During reconstruction, automatic rotation capability assists in finding the sharpest images achievable given the input limits of the system. A beam hardening corrective function is used during the reconstruction stage. This process allows the choice of image with the least minimal beam hardening effects to be chosen. When selection of reconstruction type is confirmed, the volume files (with the reconstructed volumes) are made and saved (. VOL file format). All reconstructed data files were them named and allotted to the scanned specimens in the study. Conversion to 16-bit VGI files then takes place to decrease file size (after Hofmann and De Beer 2012; Morgan 2014). This software is also equipped with functionality to obtain morphometric data for two-dimensional and three-dimensional analyses, 3-D surface rendering, and sample segmentation which was used in secondary reconstruction of some of the project images.

Following the initial procurement and reconstruction phases, the micro-CT volume was further evaluated, and secondary reconstruction commenced using Avizo Amira 5.4 software. This software is provided with functions which allow manoeuvring and segmenting of 3-D data and yield both two-dimensional orthoslices and three-dimensional surface rendered projections, which were used to develop the final selection of specimen images in this project.

3.3.3 Propagation phase contrast X-ray synchrotron microtomography protocol (SRμCT)

The third method used to identify internal skeletal hominin pathology was by synchrotron generated X-rays. This particular method is commonly referred to as Propagation phase contrast X-ray synchrotron microtomography (SRμCT).

Micro-CT slices are reconstructed from projections obtained over 180°. When phase contrast microradiographs are employed and not the absorption type, it results in phase contrast SR-μCT (Cloetens *et al*. 1997, Buffière *et al*. 1999), and produces high quality images on fossil material exhibiting low levels of contrast. This method demonstrates characteristic features that frequently can only be examined with the use of microscopic slides (Tafforeau *et al*. 2006).

Electrons are produced and emitted by an electron gun, and accelerated in a linear accelerator (Linac) followed by a circular accelerator (booster ring) to attain an energy level of 6 GeV at the ESRF. The electrons are then inserted into a storage ring. Magnets then manipulate the electron path and send them into the next process consisting of a straight shaped mechanism. The next step is that in order to create X-rays by circulating electrons, they have to be accelerated or slowed down. This next process involves the bending of magnets in the curved portions of the loop, and for third generation storage rings, this process takes place in the straight portions by insertion mechanisms. These mechanisms are groups of magnets that are placed in the path of the electrons and initiate wave movements, and move through the system being divided into 'wigglers and undulators'. Radiation is produced in a planned direction, peripheral to the electron storage ring and specific beamlines for imaging experiments. The imaging beamline ID19 of the ESRF, was used for the scanning in this study. Its setup was boosted for the use of a homogeneous, X-ray beam with dimensions of 45 by 15 mm at the sample position, and a photon energy ranging from 6 to 120 keV (Betz *et al*. 2007).

Phase-contrast imaging permits the recording of refractive changes. Different materials have different densities and often indicate refractive discontinuities. This can lead to fringe effects in the images (Cloetens *et al*. 1997). Phase-contrast imaging is equipped with technology to alleviate edge effects. This improves the visualisation of small internal skeletal structures, making it possible to image samples with miniscule differences in density and contrast features (Betz *et al*. 2007). For purposes of this study the facility at the European Synchrotron Radiation Facility (ESRF) in Grenoble, France was used.

Microtomographic scans were performed using a high-energy polychromatic beam on the beamline ID19 of 55*10mm. An average energy level of 72 keV was achieved. The detector was a FreLoN 2K (Fast Readout Low Noise) CCD (charged couple device) camera (Labiche *et al*. 2007), and provided a voxel size of 30.93µm. This detector was coupled with a 750-µm-thick LuAG: Ce (Lutetium Aluminium Garnet doped with Cerium) scintillator. The average detected energy was 76 keV. These parameters allow about 30% of minimum transmission through the specimens, with a reasonably small bandwidth. The result is data that are almost free of beam-hardening

effects, but with a faster acquisition speed than using a monochromatic beam. A propagation distance of 900 mm was used to obtain some phase-contrast effect, and to improve visibility of the smallest structures as well as to increase the signal-to-noise ratio.

Scanning was executed at 4000 projections over 360°, in an uninterrupted rotation mode and imaged twice using the centre and margin of the beam, to guarantee a constant level of movement for the imaging of the entire sample. Each scan lasted 21 min, and 24 scans were performed to image the full plate. The non-stop rotational function offers a better-quality image.

After the scans are attained, the volume data are reconstructed using a filtered back-projection algorithm (PyHST software), expressly established for tomography, at the ESRF. The reconstructions used both filtered back-projection algorithms with a single distance phase retrieval technique (after Paganin *et al*. 2002). The reconstruction protocol described by Sanchez et al. (2012), used a 3D filter on the reconstructions after the phase retrieval process, to allow for blurring introduced by the algorithm and further provided a higher phase retrieval sensitivity level. This resulted in no loss of resolution from the edge detection effects. A correction technique for ring effects was applied on reconstructed slices to allow for the highest quality level of the final volume. The 3-D renderings and segmentation were performed using the software VGStudioMax 2·2 (Volume Graphics, Heidelberg, Germany). The rendering for solid views was performed with Phong's algorithm in volume rendering, with false colours attributed to different grey levels of tomographic data, and a shadow effect was implemented. The segmentation protocol reconstructed a mirror image of the fragment of absent vertebral bone, and then segmentation of the empty void was created using 3D region growing. The concluding element of the segmentation procedure consisted of manual application of a segmentation mask for the matrix filled area. Volume, surface rendering and shadowing was applied using a variety of different colours for various levels of tomographic data. A semi-transparent model of the vertebra with the lesion was prepared by selecting a 10- voxel layer on the whole surface of the vertebra, set as transparent with Phong algorithm at 10% (See Supplementary Figure S1).

Secondary reconstruction and volume rendering of image volumes with Aviso Amira 5.4.5 was performed to attain further detailed internal structure slices and 3D images, by manoeuvring of axes using the multiplanar tool.

A difficulty with this technique is that the specific tools used to analyse structures are designed for absorption based micro-CT datasets, and cannot be modified to those of the phase contrast technique. Phase-contrast techniques have been validated (Nugent *et al*. 1996; Cloetens *et al*. 1999), however the recovery procedure with regard to densities is cumbersome and further supplementary datasets are invariably necessary (Betz *et al*. 2007).

CHAPTER 4: Earliest Hominin Cancer: 1.7-Million-Year-Old Osteosarcoma from Swartkrans Cave, South Africa*

*Published: South African Journal of Science

Citation: **Odes, E.J.**, Randolph-Quinney, P.S., Steyn, M., Throckmorton, Z., Smilg, J.S., Zipfel, B., Augustine, T.N., De Beer, F., Hoffman, J.W., Franklin, R.D. and Berger, L.R., 2016. Earliest hominin cancer: 1.7-million-year-old osteosarcoma from Swartkrans Cave, South Africa. South African Journal of Science, 112(7-8), pp.1-5.

AUTHORS:
Edward J. Odes[1,2]
Patrick S. Randolph-Quinney[1,2*]
Maryna Steyn[1]
Zach Throckmorton[2,3]
Jacqueline S. Smilg[2,4,5]
Bernhard Zipfel[2,6]
Tanya N. Augustine[1]
Frikkie de Beer[7]
Jakobus W. Hoffman[7]
Ryan D. Franklin[8]
Lee R. Berger[2,6]

AFFILIATIONS:
[1]School of Anatomical Sciences, University of the Witwatersrand, Johannesburg, South Africa
[2]Evolutionary Studies Institute, School of Geosciences, University of the Witwatersrand, Johannesburg, South Africa
[3]De Busk College of Osteopathic Medicine, Lincoln Memorial University, Harrogate, Tennessee, USA
[4]School of Radiation Sciences, University of the Witwatersrand, Johannesburg, South Africa
[5]Department of Radiology, Charlotte Maxeke Academic Hospital, Johannesburg, South Africa
[6]DST/NRF South African Centre of Excellence in Palaeosciences, University of the Witwatersrand, Johannesburg, South Africa
[7]Radiography/Tomography Section, South African Nuclear Energy Corporation (NECSA), Pelindaba, South Africa
[8]Archaeological and Historical Conservancy, Davie, Florida, USA
*Current address: School of Forensic and Applied Sciences, University of Central Lancashire, Preston, Lancashire, United Kingdom

CORRESPONDENCE TO:
Patrick Randolph-Quinney

EMAIL:
prandolph-Quinney@uclan.ac.uk

POSTAL ADDRESS:
School of Forensic and Applied Sciences, University of Central Lancashire, Preston, Lancashire, PR1 2HE, UK

DATES:
Received: 11 Dec. 2015
Revised: 16 Mar. 2016
Accepted: 17 Mar. 2016

KEYWORDS:
palaeopathology; oncology; malignant neoplasia; metatarsal; micro-computed tomography

HOW TO CITE:
Odes EJ, Randolph-Quinney PS, Steyn M, Throckmorton Z, Smilg JS, Zipfel B, et al. Earliest hominin cancer: 1.7-million-year-old osteosarcoma from Swartkrans Cave, South Africa. S Afr J Sci. 2016;112(7/8), Art. #2015-0471, 5 pages. http://dx.doi.org/10.17159/sajs.2016/20150471

© 2016. The Author(s).
Published under a Creative Commons Attribution Licence.

Earliest hominin cancer: 1.7-million-year-old osteosarcoma from Swartkrans Cave, South Africa

The reported incidence of neoplasia in the extinct human lineage is rare, with only a few confirmed cases of Middle or Later Pleistocene dates reported. It has generally been assumed that pre-modern incidence of neoplastic disease of any kind is rare and limited to benign conditions, but new fossil evidence suggests otherwise. We here present the earliest identifiable case of malignant neoplastic disease from an early human ancestor dated to 1.8–1.6 million years old. The diagnosis has been made possible only by advances in 3D imaging methods as diagnostic aids. We present a case report based on re-analysis of a hominin metatarsal specimen (SK 7923) from the cave site of Swartkrans in the Cradle of Humankind, South Africa. The expression of malignant osteosarcoma in the Swartkrans specimen indicates that whilst the upsurge in malignancy incidence is correlated with modern lifestyles, there is no reason to suspect that primary bone tumours would have been any less frequent in ancient specimens. Such tumours are not related to lifestyle and often occur in younger individuals. As such, malignancy has a considerable antiquity in the fossil record, as evidenced by this specimen.

Introduction

The reported incidence of neoplastic disease in the extinct human lineage is rare. Only a few confirmed cases of Middle or Later Pleistocene dates (780 000 to 120 000 years old) have been reported.[1,2] It is generally assumed that pre-modern incidence of neoplastic disease of any kind is rare and limited to benign conditions, but new fossil evidence suggests this is not so. We here present the earliest identifiable case of malignant neoplastic disease from an early human ancestor dated to 1.8–1.6 million years old (Ma). The diagnosis is possible only because of advances in 3D imaging methods as an aid in diagnosis.

A neoplasm ('new-growth' or tumour) is defined as a mass of localised tissue growth in which cellular proliferation is no longer subject to the effects of normal growth-regulating mechanisms.[1,2] A tumour may be benign or malignant in nature; malignant tumours are often colloquially referred to as a cancer.[3] Malignancy is the primary cause of death in industrialised countries and the second foremost cause of death in developing countries.[4,5] Since 1999, malignancy has surpassed cardiac disease as the leading cause of death for humans younger than 85 years in the USA[6], and is often perceived to be a disease of modernity[7-9]. At present, true neoplastic diseases seem to be restricted to complex vertebrate animals. Only one observation of true malignancy has been described in one of the simpler living vertebrates, specifically hepatomas in the cartilaginous skeleton of the jawless hagfish.[2] This is a very important case for the comparative pathology of malignancy, because lampreys are among the simplest living vertebrates.

The fact that malignancy has great antiquity is demonstrated from the fossil record. The earliest definitive evidence for neoplastic disease comes from pre-Cenozoic contexts, with purported cases of neoplasm found in fossil fish from the Upper Devonian. The earliest unequivocal case dates from 300 Ma, with evidence of benign osteoma with focal hyperostosis affecting a partial skeleton of the fish *Phanerosteon mirabile* from the North American Lower Carboniferous.[2] Later cases include diagnoses of benign haemangioma and eosinophilic granuloma in Jurassic dinosaurs; benign osteoma in mosasaurs; and haemangioma, metastatic disease, desmoplastic fibroma, and osteoblastoma in Cretaceous hadrosaurs.[10,11] Benign osteoid osteoma and osteoblastoma have been identified in European mammoths dating from 24 to 23 thousand years ago (ka).[12] Evidence for neoplastic disease is not unknown in the human fossil, archaeological and historical records,[1,3,13] but is generally considered rare. Historically, the earliest fossil evidence for neoplastic disease in the human lineage was suggested to be from a mandible of archaic *Homo* from Kanam in Kenya. This lesion has variously been attributed to osteosarcoma, bone keloid, Burkitt's lymphoma, or traumatic osteomyelitis.[2,14-17] The first substantive evidence for hominin neoplastic disease is derived from a juvenile skeleton of *Australopithecus sediba,* dated to 1.98 Ma, from the site of Malapa in South Africa. An invasive spinal lesion has been attributed by Randolph-Quinney and colleagues to benign osteoid osteoma, a non-malignant tumour.[18] Later significant evidence for near-human neoplastic disease is suggested by Monge and colleagues'[19], who present a case of fibrous dysplasia from a Neanderthal rib dated to 120 000 ka from the site of Krapina.

Here we present the earliest fossil evidence for malignant neoplastic disease in the hominin record, with a detailed description and differential diagnosis of malignant osteosarcoma. Our report is based on re-analysis of a hominin metatarsal specimen (SK 7923) (*gen. et spec. indet.*) from the cave site of Swartkrans in the Cradle of Humankind, South Africa. SK 7923 is a metatarsal recovered from the Member 1 Hanging Remnant, which has yielded fossils of both *Homo ergaster* and *Paranthropus robustus*.[20] Several faunal estimates have indicated the age of the Hanging Remnant at between 1.5 Ma and 1.8 Ma.[21-23] Recent electron spin resonance dating has estimated the age of the Hanging Remnant of Swartkrans at 1.6 Ma.[24] The oldest southern African specimens of early *Homo* and *Paranthropus* present around 2.1–1.9 Ma in Member 1, and are recorded until around 1.0–0.6 Ma in Member 3 of the Swartkrans cave.[25]

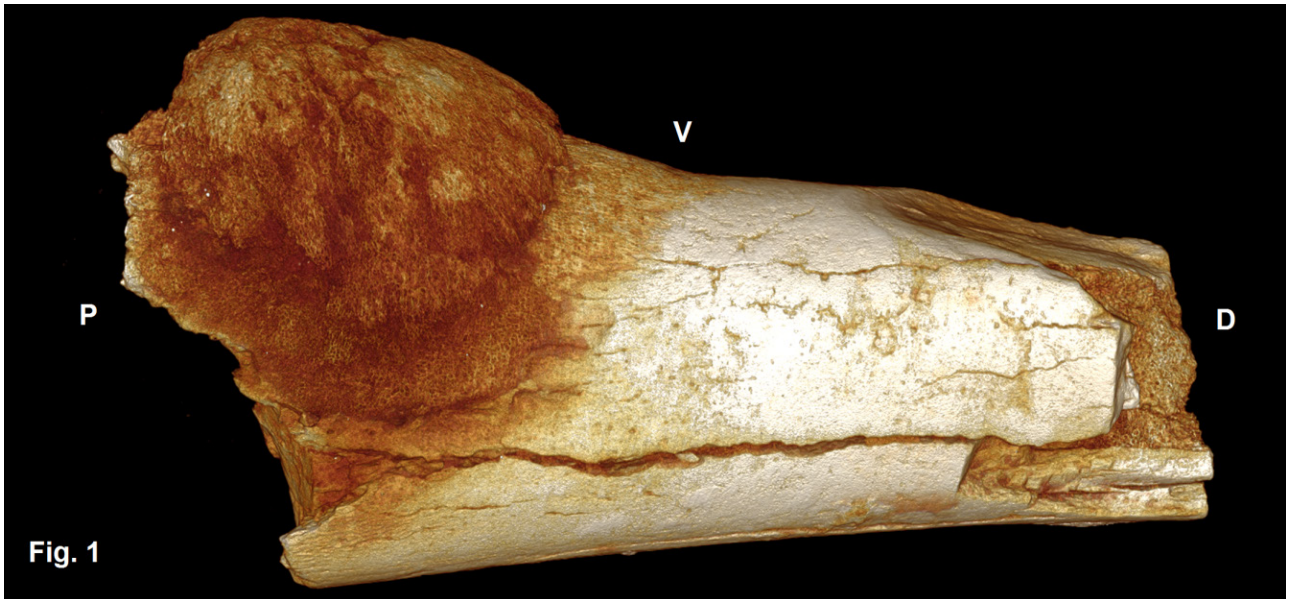

Figure 1: SK 7923 , a hominin 5th metatarsal, exhibits a hemi-spherical bony mass located on the proximo-ventral aspect of the shaft, abutting the cortical bone surface. P – proximal, D – distal, V – ventral.

Swartkrans hominin site

Swartkrans was discovered in 1948. The site is situated approximately 40 km northwest of Johannesburg, on the bank of the Blaauwbank River in the province of Gauteng, South Africa. It is arguably one of the most important palaeocave sites in southern Africa, if not globally, and is best known for its rich heritage of *Paranthropus robustus* fossils, and purported evidence for early hominin use of controlled pyrotechnology. During much of their early research, Broom and his assistant Robinson excavated a considerable sample of hominin remains attributable to *Paranthropus robustus* and *Homo* from the site.[26,27] Swartkrans was the first site where these two genera of hominins were considered to be contemporary.

After an approximately 12-year hiatus of non-activity, Brain's subsequent excavations at Swartkrans from the mid-1960s to the mid-1980s produced a significant addition to the faunal[20], fossil and archaeological collection. From the total number of specimens obtained at the Swartkrans site, 415 accessioned specimens are identified as hominin.[20] Brain's work demonstrated that the stratigraphy of the site was much more complex than originally posited. Brain subsequently demonstrated five members at Swartkrans.[22] Member 1 consists of two distinct masses, the Hanging Remnant and Lower Bank[22], each of them yielding *Homo ergaster* and *Paranthropus robustus*[28]. *Homo* and *Paranthropus* have been discovered from Member 2.[28]

SK 7923 case study

SK 7923 is a left 5th metatarsal, preserving the proximal diaphysis and much of the distal portion, but lacking the articular end. The specimen is hominin, but cannot be allocated to a specific taxon. Pathologically, SK 7923 presents a growth on the proximo-ventral aspect of the shaft. Here, an irregular hemi-spherical mass abuts the cortex (Figure 1), measuring 5.2 mm x 4.7 mm. The specimen was originally studied as part of an unpublished doctoral thesis, where the morphology led one of us (R.F.) to diagnose osteoid osteoma. However, recent internal imaging has led to a re-evaluation of the pathology.

The bone was examined using micro-focus X-ray computed tomography (μXCT) at the South African Nuclear Centre for Radiography and Tomography (located at the South African Nuclear Energy Corporation, NECSA). The bone was scanned by F.d.B. and J.W.H. using a Nikon XTH225ST μXCT system, at an energy potential of 100 kV and resolution of 17 microns. Reconstruction was performed by E.J.O. and P.R.Q. using Avizo Amira 5.4 to generate both 2D orthoslice and 3D surface rendered views. The cross-section shows that the hemispherical mass is not fully fused to or integrated with the cortex, but adheres to the bone surface, displaying an irregular spongy woven bone texture with a cauliflower-like external appearance (Figure 2a). The cortical bone directly underlying the mass is covered with a thin layer of new woven bone, with a Codman triangle displayed at the margins. The texture is granular and exhibits ellipsoid lytic lesions in transverse view. There is localised sub-periosteal invasion by the mass into the cortex (Figure 2a). Surprisingly, μXCT showed much of the medullary cavity to be infilled with bone, with clear internal remodelling and *de-novo* bone formation (Figure 2b). Inside the cortex are several irregular and large circular voids, caused by bony encapsulation of normal vascular channelling found within the endosteal surface of the medullary cavity. The remaining medullary space is obliterated by new bone growth.

A number of bone-forming conditions should be considered in the differential diagnosis: chondrosarcoma, Ewing's sarcoma, metastatic carcinoma, osteochondroma, osteoblastoma and osteosarcoma (see Supplementary Appendix for a more detailed breakdown).[3,29-46] Osteosarcoma usually starts in the medulla and characteristically arises within the metaphysis of long bones, growing circumferentially through the cortex into soft tissue and raising the periosteum. This seems to have occurred in SK 7923, with a Codman triangle visible. Osteosarcoma (osteogenic sarcoma) prefers fast-growing regions and usually occurs around the knee. It presents in metatarsals in less than 1% of clinical cases. According to Vigorita[47], the periosteal reaction may have a 'sunburst' appearance, which is to some extent visible in Figure 2a. Given the internal and external morphology of this specimen, it seems most likely that this pathology is attributable to osteosarcoma, with a strong possibility of the parosteal variant of this condition. Diagnosis was supported by μXCT imaging of a modern clinically diagnosed case of osteosarcoma of the distal femur. Comparison of Figures 2b and 2c shows clear similarities between the appearance of the fossil and modern medullary infills.

Osteosarcoma is a primary malignant tumour that typically exhibits cortical and medullary disruption and some degree of mineralisation. It also typically shows aggressive periosteal new bone reaction, which can include either lamination, Codman triangle, or spiculated sunburst reaction. The most common form is central osteogenic sarcoma, which could be osteoblastic or osteolytic in nature, or both. This typically occurs in the metaphyseal and diaphyseal area of the major long bones. Parosteal osteosarcoma is the most common type of juxtacortical or surface osteosarcoma. This often presents as a lobulated 'cauliflower' mass with central ossification adjacent to the bone, and may infiltrate the bone marrow. Bone destruction is rare, but when present is regional.

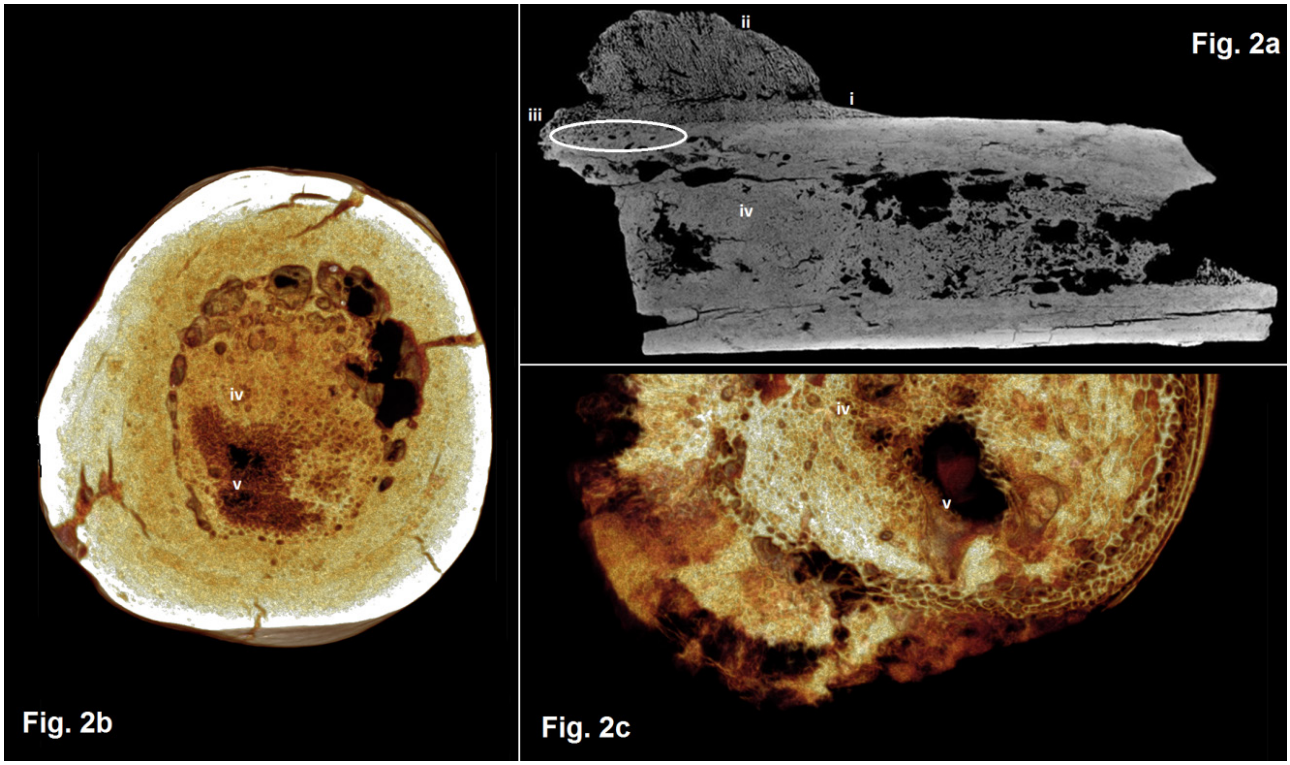

Figure 2: (a) Axial micro-CT orthoslice indicating (i) reactive new bone formation subperiosteally forming a Codman triangle, (ii) ossified exophytic (cauliflower-like) and/or spiculated mass adjacent to the bone, (iii) localised sub-periosteal invasion by the mass into the cortex, (iv) remodelled bone infill; (b) transverse rendered view of SK 7923; (c) transverse rendered view of modern clinical case of osteoblastic osteosarcoma with aggressive local medullary infilling (Courtesy: Department of Anatomy, University of Pretoria). Note (v) the homologous combination of spongy and solid bone between the fossil and clinical specimens.

Most parosteal osteosarcomas are found in the metaphyseal region of long tubular bones. The most common site is the distal femur, followed by the upper shaft of the tibia, and then the proximal humerus.

Functionally, this malignancy may have presented secondary consequences in our case study. The belly of *abductor digitii minimi* may have been displaced laterally, and with *fibularis brevis* and *f. tertius* inserting just proximal and distal to the growth, some influence on gait was likely. The presence of sub-periosteal bone formation in the form of a Codman triangle, cortical invasion, spiculated mass abutting the exosteum, and aggressive medullary infilling (including the combination of trabeculated and avascular bone) indicates that what was originally diagnosed as a benign exosteal growth is now shown to represent a malignant bone malignancy. This change in diagnosis is entirely the result of advances in high-resolution 3D imaging, together with the judicious use of comparative clinical pathology. It is thus possible that cases of malignancy might remain unknown in fossil assemblages awaiting imaging and discovery.

Discussion

This case highlights a significant issue with regard to modern clinical incidence and expression of neoplastic disease, and malignancy in particular. That is, how can we understand ancient disease evolution when sample sizes are extremely small? As noted above[7-9], malignancy is perceived as a disease of modernity. However, it is worth noting that primary skeletal malignant tumours are not commonly encountered in the modern clinical environment, and although rare they do feature in the archaeological and fossil record[3,18]. Historically, factors of preservation have limited the study of human neoplasia to the skeleton, from which the confident diagnosis of tumours has been problematical.[48] Recent work on artificially mummified Egyptian remains has suggested to some scholars[9,49] that malignancy was almost absent in pre-modern human populations. For example, Gray[49] reported no radiological confirmation of malignant neoplasia among 193 examined Egyptian mummies. However, we view this assertion as tautological, because the samples on which the claim is based are not representative of the bulk of the human species living in antiquity; they represent only a small fraction of all humans living at that time[50]. From the global historical sample available to us for study, malignancy does exist, albeit rarely – and a subset of those cases include osteosarcoma. Probable pre-modern cases are reported from Hawaii[51], the Czech Republic[52], and the Peruvian Andes[1].

The precise range of causes underlying malignancies is still largely unknown. Where causes have been established, these are generally understood to fall into three categories: physical, chemical, and viral.[1] Physical causes include being exposed to ultraviolet light (which increases the risk of basal cell carcinoma and malignant melanoma) and levels of background radiation.[1] Causative examples in the historical modern environment include the effects of radiation from the dropping of atomic bombs on Japan during World War II, which has been linked to an escalation in myelogenous leukaemia and thyroidal malignancy.[1] Chemical carcinogens in humans have historically been known to target skin and lungs, urinary bladder, and nasal sinuses and pleura. Potts demonstrated a relationship between scrotal malignancy in chimney sweepers and exposure to soot as early as 1775.[53] Many chemicals are widely accepted to be carcinogenic. Radon from granite, for example, is a radioactive gas causing lung malignancy.[1] Several viruses can cause malignancy in animals, and the association of some viruses with human malignancy is considerable. Examples include human papilloma virus (cervix malignancy), hepatitis B or C virus (liver malignancy), Epstein-Barr virus (non-Hodgkin lymphomas and nasopharyngeal malignancy), and human immunodeficiency virus (linked to non-Hodgkin lymphoma and Kaposi sarcoma).[1]

Whilst most modern human malignancies are thought to be caused by environmental agents of a chemical nature, the evidence for this is not entirely conclusive.[1,p.373] The internal environment, namely

diet and lifestyle, is thought to play a significant role in malignancy disposition. Some malignancies are certainly triggered by modern lifestyle factors, such as smoking, drinking (which can lead to liver and oesophageal malignancy), sunbathing, and obesity (which can lead to gastrointestinal gut malignancy).[1] Pesticides and industrial chemicals can cause malignancy, but their contribution is thought to be relatively minor. Of perhaps greatest impact is colorectal malignancy, which kills approximately 700 000 people every year worldwide[8], and is most prevalent in developed countries such as USA and Europe. The lowest incidence occurs in underdeveloped countries in Africa, which have vastly different dietary regimes available to the population. Brody[8] has named colorectal cancer a disease of modernity and development. In other words, economic growth is associated with a rise in the incidence of colorectal malignancy, with corresponding lifestyle changes possibly playing a strong role in the prevalence of this disease. An example is China, where a marked increase in the prevalence of colorectal malignancy is occurring.[8]

In addition, whilst the modern lifestyles of humans may enhance the frequency of cancer, longer life expectancies mean malignancy would logically occur at a higher rate among modern people than in our prehistory. We are unable to assess the age at death of the Swartkrans SK 7923 hominin (other than skeletally adult), but it was likely to have been substantially less than modern life expectancy, based on demographic studies of early hominin taxa[54].

The expression of malignant osteosarcoma in the Swartkrans SK 7923 specimen indicates that whilst the explosion of malignancy incidence is clearly correlated with the hazards of the modern world and increased life expectancy, primary bone tumours evidently occurred throughout history. Then, as now, such tumours would have occurred predominantly in younger individuals. Neoplastic disease has considerable antiquity, as evidenced by this specimen and further supported by numerous published case studies of benign neoplasms with deep antiquity in the fossil record, as noted above.[1-3,10-12,18,55,56] The theory that the almost total lack of malignancies in Egyptian mummies indicates that the disease occurs only in industrialised societies[9] is thus questionable.

The lack of substantial evidence of malignancy in the fossil and bio-archaeological records might arguably be an artefact of preservation, or of sampling bias and tiny sample sizes, or of analytical techniques or the application of inefficient imaging modalities[57]. For example, the results would differ if plain radiography or clinical magnetic resonance imaging are used rather than micro-computed tomography. The absolutely small sample sizes arise from short life expectancy among pre-modern societies. Hence, the rare incidence of cancer cases found in the record can be seen as most likely non-representative, and should not be construed as indicating the true prevalence of disease. It is important to note that because of the worldwide demographic transition and average increased age at death for humans, non-primary bone malignancy can be expected to occur at a higher rate today than in pre-transition populations.[50]

As highlighted in the introduction, malignancy occurs in almost all metazoans, suggesting that the mechanisms of malignancy have an extremely old evolutionary history. For example, neoplasms have been recorded in dinosaurs and other fossil forebears.[2,11,56] A number of oncogenes are particularly archaic, with their antecedents exhibited in some form in primitive common ancestor metazoans of chordates and arthropods.[55,58] Thus, the *capacity* for malignancy is ancient, and the higher incidence of malignancy in today's developed and developing world may be related to the unique interaction between environmental factors – which have no parallel in prehistory[59]. It is also important to note that modern non-invasive imaging techniques (such as micro-computed tomography or phase-contrast synchrotron tomography), together with the appropriate use of clinical homologues, play a considerable role in enabling accurate diagnoses. These new techniques hold considerable potential for re-investigating previously reported palaeopathological lesions.

Acknowledgements

We would like to thank Stephany Potze and Lazarus Kgasi of the Ditsong National Museum of Natural History for providing access to the Swartkrans fossil specimen. E.J.O. would like to acknowledge the National Research Foundation of South Africa, the DST/NRF South African Centre of Excellence in Palaeosciences, and the University of the Witwatersrand for funding this research. We would like to thank the Department of Anatomy, University of Pretoria for permission to image and analyse the comparative clinical specimen used in this study. M.S. is supported by the National Research Foundation of South Africa.

Authors' contributions

E.J.O. and P.S.R.Q. wrote the original draft of the manuscript, incorporating additional information and data on SK 7923 obtained from M.S., J.S., Z.T., B.Z., T.N.A. and L.R.B. P.S.R.Q. and L.R.B. supervised the research. Critical input on the pathology of malignant neoplasms was provided by M.S. and J.S., and Z.T. and B.Z. gave input on functional aspects of pedal pathology. E.J.O. provided the differential diagnoses and historical pathological and palaeoanthropological data. J.W.H. and F.d.B. undertook the micro-computed tomographic scanning of the hominin specimen and the primary reconstruction. E.J.O. and P.S.R.Q. undertook secondary reconstruction from orthoslice and 3D volume data. All authors contributed equally to analysis and editing.

References

1. Aufderheide AC, Rodríguez-Martin C. The Cambridge Encylopedia of human paleopathology. Cambridge: Cambridge University Press; 1998.
2. Capasso LL. Antiquity of cancer. Int J Cancer. 2005;113:2–13. http://dx.doi.org/10.1002/ijc.20610
3. Ortner DJ. Tumors and tumor-like lesions of bone. In: Ortner DJ, editor. Identification of pathological conditions in human skeletal remains. Amsterdam: Academic press; 2003. p. 503–544. http://dx.doi.org/10.1016/b978-012528628-2/50057-0
4. Jemal A, Bray F, Center M, Ferlay J, Ward E, Forman D. Global cancer statistics. CA-Cancer J Clin. 2011;61:69–90. http://dx.doi.org/10.3322/caac.20107
5. World Health Organization. The global burden of disease: 2004 update. Geneva: WHO Press; 2008. 153 pages.
6. Jemal A, Siegal R, Xu J, Ward E. Cancer statistics, 2010. CA-Cancer J Clin. 2010;60:277–300. http://dx.doi.org/10.3322/caac.20073
7. Binder M, Roberts C, Antoine D, Cartwright C. On the antiquity of cancer: Evidence for metastatic carcinoma in a young man from Ancient Nubia (c. 1200BC). PloS ONE [Internet]. 2014;9, Art. #e90924 11 pages. http://dx.doi.org/10.1371/journal.pone.0090924
8. Brody H. Colorectal cancer. Nature. 2015;521, Art. #a7551. http://www.nature.com/nature/journal/v521/n7551_supp/full/521S1a.html
9. David RA, Zimmerman MR. Cancer: An old disease, a new disease or something in between? Nat Rev Cancer. 2010;10:728–32. http://dx.doi.org/10.1038/nrc2914
10. Rothschild BM, Tanke DH, Hebling M, Martin LD. Epidemiologic study of tumors in dinosaurs. Naturwissenschaften. 2003;90:495–500. http://dx.doi.org/10.1007/s00114-003-0473-9
11. Rothschild BM, Martin LD. Paleopathology: Disease in the fossil record. Boca Raton, FL: CRC Press; 1993.
12. Leshchinsky SV. Paleoecological investigation of mammoth remains from the Kraków Spadzista Street (B) site. Quatern Int. 2012;(276–277):155–169. http://dx.doi.org/10.1016/j.quaint.2012.05.025
13. Retief FP, Cilliers L. Breast cancer in antiquity. S Afr Med J. 2011;101(8):513–515.
14. Phelan J, Weiner MJ, Ricci JL, Plummer T, Gauld S, Potts R, et al. Diagnosis of the pathology of the Kanam mandible. Oral Surg Oral Med O. 2007;103(4), Art. #e20. http://dx.doi.org/10.1016/j.tripleo.2006.12.041
15. Stathopoulos G. Kanam mandible's tumour. Lancet. 1975;305(7899). p. 165. http://dx.doi.org/10.1016/S0140-6736(75)91462-2

16. Tobias PV. The Kanam jaw. Nature. 1960;185:946-947. http://dx.doi.org/10.1038/185946a0

17. Tobias PV. A re-examination of the Kanam mandible. In: Mortelmans G, Nenquin J, editors. Actes du IVe Congrès Panafricain de Préhistoire et de l'Étude du Quaternaire, Sections I and II. Tervuren, Belgique: Annales Ser. Qu-8o, Sciences Humaines 40; 1962. p. 341–350. [French].

18. Randolph-Quinney PS, Williams SA, Steyn M, Meyer MR, Smilg JS, Churchill SE, et al. Osteogenic tumour in *Australopithecus sediba*: Earliest hominin evidence for neoplastic disease. S Afr J Sci. 2016;112(7/8), Art. #2015-0470, 7 pages. http://dx.doi.org/10.17159/sajs.2016/20150470

19. Monge J, Kricun M, Radovčić J, Radovčić D, Mann A, Frayer DW. Fibrous dysplasia in a 120,000+ year old Neandertal from Krapina, Croatia. PLoS ONE. 2013;8(6), Art. #e64539. http://dx.doi.org/10.1371/journal.pone.0064539

20. de Ruiter DJ. Revised faunal lists for Members 1–3 of Swartkrans, South Africa. Ann Trans Mus. 2003;40:29–41.

21. Berger L, Lacruz R, De Ruiter D. Revised age estimates of *Australopithecus*-bearing deposits at Sterkfontein, South Africa. Am J Phys Anthropol. 2002;119:192–197. http://dx.doi.org/10.1002/ajpa.10156

22. Brain C. Structure and stratigraphy of the Swartkrans cave in light of the new excavations. In: Brain C, editor. Swartkrans: A cave's chronicle of early man. Pretoria: Transvaal Museum; 1993. p. 23–34.

23. Vrba E. Early hominids in southern Africa: Updated observations on chronological and ecological background. In: Tobias P, editor. Hominid evolution: Past, present and future. New York: Alan R. Liss; 1985. p. 195–200.

24. Curnoe D, Grun R, Taylor L, Thackeray J. Direct ESR dating of a Pliocene hominin from Swartkrans. J Hum Evol. 2001;40:379–391. http://dx.doi.org/10.1006/jhev.2000.0459

25. Herries A, Curnoe D, Adams J. A multi-disciplinary seriation of early Homo and Paranthropus bearing palaeocaves in southern Africa. Quatern Int. 2009;202(1):14–28. http://dx.doi.org/10.1016/j.quaint.2008.05.017

26. Brain C. New finds at the Swartkrans australopithecine site. Nature. 1970;225:1112–1119. http://dx.doi.org/10.1038/2251112a0

27. Broom R, Robinson J. A new type of fossil man. Nature. 1949;164:322. http://www.nature.com/nature/journal/v164/n4164/pdf/164322a0.pdf

28. Brain C. A taphonomic overview of the Swartkrans fossil assemblages. In: Brain C, editor. Swartkrans: A cave's chronicle of early man. Pretoria: Transvaal Museum; 1993. p. 257–264.

29. Burchill S. Ewing's sarcoma: Diagnostic, prognostic, and therapeutic implications of molecular abnormalities. J Clin Pathol. 2003;56(2):96–102. http://dx.doi.org/10.1136/jcp.56.2.96

30. Eisenberg R. Bubbly lesions of bone. Am J Roentgenol. 2009;193(2):W79–94. http://dx.doi.org/10.2214/AJR.09.2964

31. Geirnaerdt M, Hogendoorn P, Bloem J, Taminiau A, van der Woude H. Cartilaginous tumors: Fast contrast-enhanced MR Imaging 1. Radiology. 2000;214(2):539–546. http://dx.doi.org/10.1148/radiology.214.2.r00fe12539

32. Huvos A. Ewing's sarcoma. In: Huvos A, editor. Bone tumors: Diagnosis, treatment and prognosis. 2nd ed. Philadelphia PA: Sanders; 1991. p. 523–552.

33. Llauger J, Palmer J, Amores S, Bague S, Camins A. Primary tumors of the sacrum: Diagnostic imaging. Am J Roentgenol. 2000;174(2):417–424. http://dx.doi.org/10.2214/ajr.174.2.1740417

34. Lucas D, Unni K, McLeod R, O'Connor M, Sim F. Osteoblastoma: Clinicopathologic study of 306 cases. Hum Pathol. 1994;25(2):117–134. http://dx.doi.org/10.1016/0046-8177(94)90267-4

35. McLeod R, Dahlin D, Beabout J. The spectrum of osteoblastoma. Am J Roentgenol. 1976;126:321–325. http://dx.doi.org/10.2214/ajr.126.2.321

36. Murphey M, Walker E, Wilson A, Kransdorf M, Temple H, Gannon F. From the archives of the AFIP: Imaging of primary chondrosarcoma: Radiologic–pathologic correlation. Radiographics. 2003;23(5):1245–1278. http://dx.doi.org/10.1148/rg.235035134

37. Osborne R. The differential radiologic diagnosis of bone tumors. CA-Cancer J Clin 1974;24(4):194–211. http://dx.doi.org/10.3322/canjclin.24.4.194

38. Trübenbach J, Nägele T, Bauer T, Ernemann U. Preoperative embolization of cervical spine osteoblastomas: Report of three cases. Am J Neuroradiol. 2006;27(9):1910–1912.

39. Unni K, Dahlin D. Osteosarcoma: Pathology and classification. Semin Roentgenol. 1989;24(3):143–152. http://dx.doi.org/10.1016/0037-198X(89)90010-2

40. Berry M, Mankin H, Gebhardt M, Rosenberg A, Hornicek F. Osteoblastoma: A 30-year study of 99 cases. J Surg Oncol. 2008;98:179–183. http://dx.doi.org/10.1002/jso.21105

41. Binning M, Klimo Jr P, Gluf W, Goumnerova L. Spinal tumors in children. Neurosurg Clin N Am. 2007;18(4):631–658. http://dx.doi.org/10.1016/j.nec.2007.07.001

42. de Souza Dias L, Frost HM. Osteoid Osteoma – Osteoblastoma. Cancer. 1974;33:1075–1081. http://dx.doi.org/10.1002/1097-0142(197404)33:4<1075::AID-CNCR2820330427>3.0.CO;2-4

43. Giannico G, Holt G, Holmar K, Johnsson J, Pinnt J, Bridge J. Osteoblastoma characterized by a three-way translocation: Report of a case and review of the literature. Cancer Genet Cytogen. 2009;195:168–171. http://dx.doi.org/10.1016/j.cancergencyto.2009.06.024

44. Lucas DR. Osteoblastoma. Arch Pathol Lab Med. 2010;134:1460–1466.

45. Osborn AG. Tumors, cysts, and tumorlike lesions of the spine and spinal cord. In: Osborn AG, editor. Diagnostic neuroradiology. St. Louis: Mosby; 1994. p. 876–918.

46. Saccomanni B. Osteoid osteoma and osteoblastoma of the spine: A review of the literature. Curr Rev Musculoskel Med. 2009;2:65–67. http://dx.doi.org/10.1007/s12178-009-9047-6

47. Vigorita VJ. Orthopaedic pathology. 2nd ed. Philadelphia: Lippincott Williams & Wilkins; 2008.

48. Rothschild BM, Rothschild C. Comparison of radiologic and gross examination for detection of cancer in defleshed skeletons. Am J Phys Anth. 1995;96(4):357–363. http://dx.doi.org/10.1002/ajpa.1330960404

49. Gray PHK. The radiography of mummies of ancient Egyptians. J Hum Evol. 1973;2:51–53. http://dx.doi.org/10.1016/0047-2484(73)90098-5

50. Chamberlain AT. Demography in archaeology. Cambridge: Cambridge University Press; 2006. http://dx.doi.org/10.1017/CBO9780511607165

51. Suzuki T. Paleopathological study on a case of osteosarcoma. Am J Phys Anth. 1987;74:309–318. http://dx.doi.org/10.1002/ajpa.1330740305

52. Strouhal E, Vyhnanek L, Horackova L, Benesova L, Nemeckova A. A case of osteosarcoma in a late medieval–early modern skull from Kyjov (Czech Republic). Int J Osteoarchaeol. 1997;7:82–90. http://dx.doi.org/10.1002/(SICI)1099-1212(199701)7:1<82::AID-OA320>3.0.CO;2-J

53. Clayson D. Chemical carcinogenesis. Boston: Little, Brown & Co; 1962.

54. Mann A. Paleodemographic aspects of the South African australopithecines. Philadelphia: University of Pennsylvania; 1975.

55. Davies PCW, Lineweaver CH. Cancer tumors as Metazoa 1.0: Tapping genes of ancestors. Phys Biol. 2011;8, Art. #a015001. http://dx.doi.org/10.1088/1478-3975/8/1/015001

56. Rothschild BM, Witzke BJ, Hershkovitz I. Metastatic cancer in the Jurassic. Lancet. 1999;354. p. 398. http://dx.doi.org/10.1016/S0140-6736(99)01019-3

57. Beckett RG, Conlogue GJ. Paleoimaging: Field applications for cultural remains and artefacts. Boca Raton, FL: CRC Press; 2010.

58. Weinberg R. Oncogenes and the molecular biology of cancer. J Cell Biol. 1983;97:1661–1662. http://dx.doi.org/10.1083/jcb.97.6.1661

59. Klepinger L. The evolution of human disease: New findings and problems. J Biosoc Sci. 1980;12(4):481–486. http://dx.doi.org/10.1017/s0021932000013067

Note: This article is accompanied by supplementary material.



Copyright of South African Journal of Science is the property of Academy of Science of South Africa and its content may not be copied or emailed to multiple sites or posted to a listserv without the copyright holder's express written permission. However, users may print, download, or email articles for individual use.

CHAPTER 5: Osteogenic Tumour in *Australopithecus sediba*: Earliest Hominin Evidence for Neoplastic Disease*

*Published: South African Journal of Science

Randolph-Quinney, P.S., Williams, S.A., Steyn, M., Meyer, M.R., Smilg, J.S., Churchill, S.E., **Odes, E.J.**, Augustine, T., Tafforeau, P. and Berger, L.R., 2016. Osteogenic tumour in Australopithecus sediba: Earliest hominin evidence for neoplastic disease. South African Journal of Science, 112(7-8), pp.1-7.

AUTHORS:
Patrick S. Randolph-Quinney[1,2*]
Scott A. Williams[2,3]
Maryna Steyn[1]
Marc R. Meyer[4]
Jacqueline S. Smilg[2,5,6]
Steven E. Churchill[2,7]
Edward J. Odes[1,2]
Tanya Augustine[1]
Paul Tafforeau[8]
Lee R. Berger[2,9]

AFFILIATIONS:
[1]School of Anatomical Sciences, University of the Witwatersrand, Johannesburg, South Africa
[2]Evolutionary Studies Institute, School of Geosciences, University of the Witwatersrand, Johannesburg, South Africa
[3]Center for the Study of Human Origins, Department of Anthropology, New York University, New York, New York, USA
[4]Department of Anthropology, School of Social & Behavioral Sciences, Chaffey College, Rancho Cucamonga, California, USA
[5]School of Radiation Sciences, University of the Witwatersrand, Johannesburg, South Africa
[6]Department of Radiology, Charlotte Maxeke Academic Hospital, Johannesburg, South Africa
[7]Department of Evolutionary Anthropology, Duke University, Durham, North Carolina, USA
[8]European Synchrotron Radiation Facility, Grenoble, France
[9]DST/NRF South African Centre of Excellence in Palaeosciences, University of the Witwatersrand, Johannesburg, South Africa
*Current address: School of Forensic and Applied Sciences, University of Central Lancashire, Preston, Lancashire, United Kingdom

CORRESPONDENCE TO:
Patrick Randolph-Quinney

EMAIL:
prandolph-quinney@uclan.ac.uk

POSTAL ADDRESS:
School of Forensic and Applied Sciences, University of Central Lancashire, Preston, Lancashire, PR1 2HE, UK

DATES:
Received: 11 Dec. 2015
Revised: 16 Mar. 2016
Accepted: 17 Mar. 2016

KEYWORDS:
Malapa; palaeopathology; neoplasia; taphonomy; osteoma; malignant

HOW TO CITE:
Randolph-Quinney PS, Williams SA, Steyn M, Meyer MR, Smilg JS, Churchill SE, et al. Osteogenic tumour in *Australopithecus sediba*: Earliest hominin evidence for neoplastic disease. S Afr J Sci. 2016;112(7/8), Art. #2015-0470, 7 pages. http://dx.doi.org/10.17159/sajs.2016/20150470

© 2016. The Author(s). Published under a Creative Commons Attribution Licence.

Osteogenic tumour in *Australopithecus sediba*: Earliest hominin evidence for neoplastic disease

We describe the earliest evidence for neoplastic disease in the hominin lineage. This is reported from the type specimen of the extinct hominin *Australopithecus sediba* from Malapa, South Africa, dated to 1.98 million years ago. The affected individual was male and developmentally equivalent to a human child of 12 to 13 years of age. A penetrating lytic lesion affected the sixth thoracic vertebra. The lesion was macroscopically evaluated and internally imaged through phase-contrast X-ray synchrotron microtomography. A comprehensive differential diagnosis was undertaken based on gross- and micro-morphology of the lesion, leading to a probable diagnosis of osteoid osteoma. These neoplasms are solitary, benign, osteoid and bone-forming tumours, formed from well-vascularised connective tissue within which there is active production of osteoid and woven bone. Tumours of any kind are rare in archaeological populations, and are all but unknown in the hominin record, highlighting the importance of this discovery. The presence of this disease at Malapa predates the earliest evidence of malignant neoplasia in the hominin fossil record by perhaps 200 000 years.

Introduction

A neoplasm ('new-growth' or tumour) is defined as a mass of localised tissue growth, the cellular proliferation of which is no longer subject to the effects of normal growth-regulating mechanisms.[1-3] A neoplasm may be benign or malignant. Malignant tumours are often referred to colloquially as cancer, although the term 'malignant neoplasia' is more clinically appropriate.[1] In the developed world, death from malignancy is second only to cardiovascular disease and is often perceived as a disease of modernity.[4] Neoplastic disease would have been prevalent in the past (e.g. Odes et al.[5]), but most likely occurred at much lower levels of incidence than today, given the shorter life expectancy for victims[1,6,7] and the differing environmental context. Both these factors strongly influence the incidence and prognosis of any cancer.[3,8] The preserved signatures of neoplasms of any kind are rare in archaeological populations, and are all but unknown in the hominin record. Here we present the earliest fossil evidence for neoplastic disease in the human lineage, with a detailed description and diagnosis of a tumorous lesion affecting the spine of a juvenile male *Australopithecus sediba,* Malapa Hominin 1 (MH1).[9,10] This species has been postulated as a possible ancestor of the genus *Homo*.[9] The clinical and evolutionary implications of the diagnosed condition are discussed.

The Malapa hominin site

The Malapa site is one of several hominin-bearing Plio-Pleistocene cave deposits located within the Cradle of Humankind World Heritage Site to the northwest of Johannesburg, South Africa. The region includes sites such as Sterkfontein[11], Swartkrans[12], Kromdraai[13], Gladysvale[14] and Rising Star[15]. The fossil deposits in these caves were formed in roughly similar fashion as debris cone accumulations deposited beneath vertical cave openings, which formed phreatically within the dolomites of the Malmani Subgroup.[15,16] At Malapa, the main hominin-bearing deposits have been dated using uranium-lead dating of flowstones, combined with palaeomagnetic and stratigraphic analyses of flowstones and underlying sediments, to 1.977 ± 0.002 million years ago (Ma).[17] The cave deposits comprise five sedimentary facies, termed A to E, from stratigraphically lowest to highest.

Facies A and B occur below a central flowstone sheet, and are overlain by an erosion remnant (facies C), which in turn is overlain by the main hominin-bearing breccia, facies D. This has yielded well-preserved macro- and micro-mammal fossils (such as carnivores, equids and bovids[18]), including the fossilised remains of at least six hominins. Two of these, MH1 and MH2, have been reported in the literature as representatives of a new hominin species, *Australopithecus sediba*[9]. Taphonomically the site has been interpreted as a complex cave system with open deep vertical shafts that operated as death traps for animals on the surface of the landscape. This death-trap scenario might have been the process by which the Malapa hominins entered the cave system[17,18], as evidenced by peri-mortem damage on the skeletons of MH1 and MH2, consistent with a fatal fall[19]. Furthermore, both skeletons present partial anatomical articulation consistent with rapid incorporation into the cave sediments early in the decomposition process.[18]

Case study: Vertebra U.W. 88-37

A pathological lesion affects the spine of Malapa Hominin 1 (MH1), the type specimen of *Australopithecus sediba*. This individual (Figure 1) was male, and at death he was at a developmental stage equivalent to that of a human child aged 12 to 13 years[9]. The pathological specimen (U.W. 88-37) is a complete vertebra originally assigned to T5-T7[10], now considered to represent the sixth thoracic vertebra[10]. The dorsal surface of the right-side lamina exhibits a rounded penetrating defect (Figure 2), measuring approximately 6.7 mm supero-inferiorly and 5.9 mm medio-laterally.

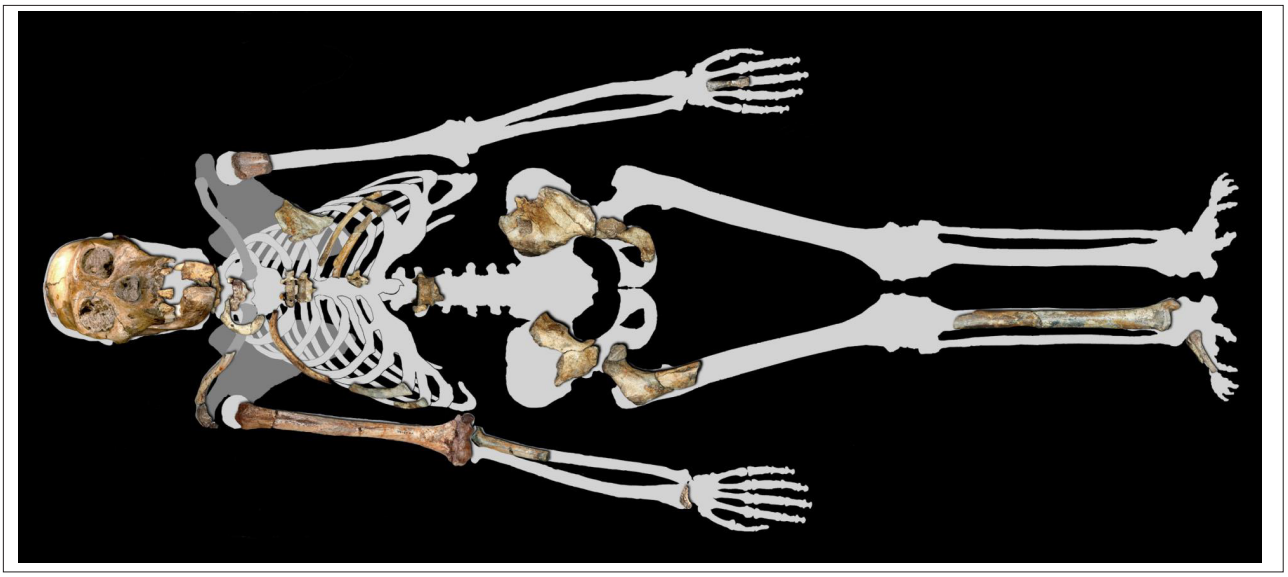

Figure 1: Surviving skeletal elements attributed to Malapa Hominin 1 (at time of writing).



Figure 2: Vertebra U.W. 88-37. Photographs of surface morphology of U.W. 88-3 showing position of lesion on right side of vertebral lamina: (a) right lateral aspect, (b) left lateral aspect, (c) inferior aspect, (d) superior aspect, (e) posterior aspect, (f) anterior aspect. Note that apertures seen on lateral aspects of the vertebral body in images (a), (b) and (f) represent normal vascular foramina infilled with residual breccia matrix. Images produced by Peter Schmidt.

The defect presents as a lytic lesion that extends ventrally into the lamina for much of its length, the most anterior portion of which remains infilled with breccia matrix (Figure 3). On the surface, the lesion has well-rounded edges with a somewhat sclerotic appearance. There is no evidence of periosteal or reactive bone formation on the cortex of the specimen. Viewing the right lamina from above, it appears thicker than the left lamina and bulges laterally over the lesion, indicating a reactive remodelling response to the presence of the defect.



Figure 3: Vertebra U.W. 88-37. Multi-focus (composite image stack) micrograph of surface morphology of U.W. 88-37 showing sub-angular penetrating defect on the right vertebral lamina. The lesion has well-rounded edges with lateral bulging of the cortex over the lesion, indicating a reactive remodelling response to the presence of the defect. Note that anterior portion of defect remains infilled with breccia matrix. Micrograph taken with Olympus SZX Multi-focus microscope, magnification 7x. Scale bar = 10 mm. Image courtesy of Alexander Parkinson.

The lesion initially widens directly under the oval opening, but then narrows as it progresses anteriorly. The base of the lesion appears smooth and sclerotic under microscopic evaluation insofar as the presence of residual breccia allows. The spinous process deviates slightly to the right, but appears in keeping with slight asymmetry noted elsewhere in the surviving thoracic vertebrae. This deviation falls within normal variation; we do not consider it significant enough to cause scoliosis or other vertebral misalignment, and it is unlikely that this asymmetry was related to the pathology.

Because of the presence of breccia within the lesion, the internal morphology of the specimen was assessed using phase-contrast X-ray synchrotron microtomography (performed at the European Synchrotron Radiation Facility, ESRF) and a specific acquisition protocol applied for high-quality imaging of large fossils (see Supplementary Appendix materials and methods). From the microtomographic volume, the maximum long axis of the lesion in the transverse plane measures 11.8 mm x 4.9 mm along the minor axis, with a cross-sectional area of 45.6 mm, and in the sagittal plane the lesion measures 14.7 mm x 7.9 mm, with a cross-sectional area of 68.6 mm. The internal linear dimensions are consistently less than 20 mm in diameter, which has important implications for final diagnosis.

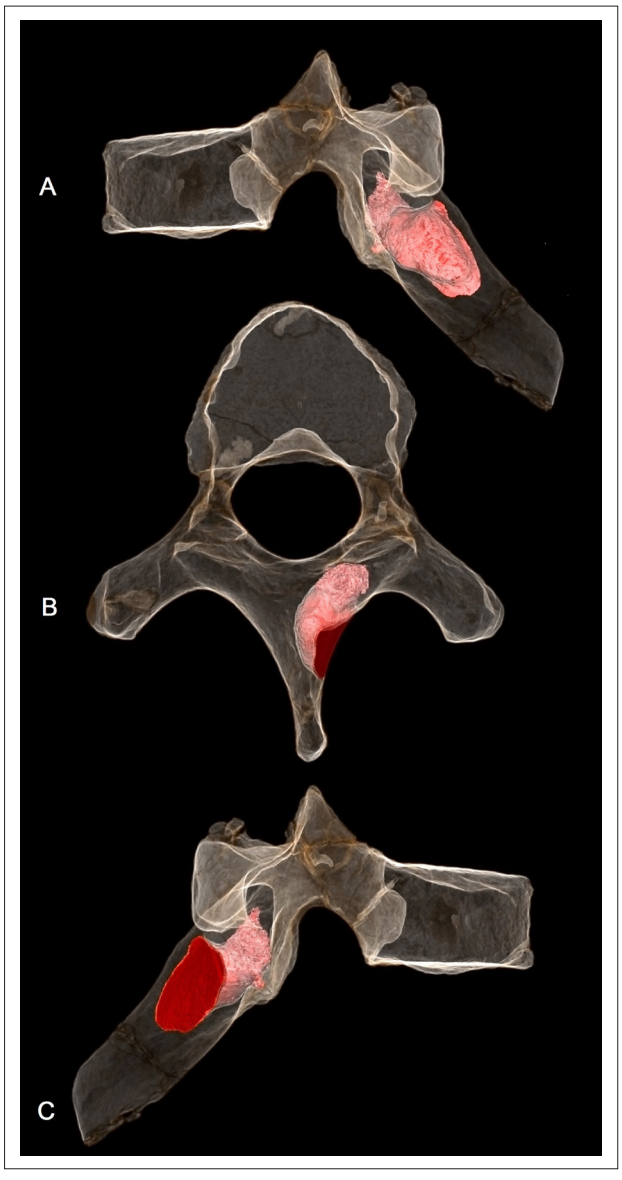

Figure 4: Vertebra U.W. 88-37. Sixth thoracic vertebra of juvenile *Australopithecus sediba* (Malapa Hominin 1). Partially transparent image volume with the segmented boundaries of the lesion rendered solid pink. Volume data derived from phase-contrast X-ray synchrotron microtomography. (a) left lateral view, (b) superior view, (c) right lateral view. Images produced by P.T.

Figure 4 shows the microtomographic imaging, with a semi-transparent volume-rendered image row. The imaging indicates that the lesion is highly penetrative and extends ventrally within the right-side of the spinous process, penetrating the lamina before terminating at the approximate level of the superior articular facet. The internal morphology shows no involvement of the transverse process or pedicle, and the lesion does not penetrate the vertebral canal. No mineralised focal point or nidus was discerned. The edges of the first two-thirds of the lesion (moving dorsal to ventral) display sclerotic characteristics, with circumscribed margins of well-integrated cortical bone, abutted and intersected by trabecular striae (Figure 5 and Supplementary Appendix). This pattern is indicative of a slow-forming bony process, with remodelling and reorganisation of posterior aspects of the lesion. The shape of a lesion is indicative of its growth rate, with lesions that are long and oriented with the long axis of a bone indicating a nonaggressive benign process. The ventral third of the lesion, however, displays a geographic pattern of bone destruction, showing a sharp non-sclerotic margin and evidence of active osteolytic processes, with sharply-defined transection of individual trabeculae, and active osteolytic penetration into the anterior portion of the lamina. A volume-rendered negative surface model of the lesion (Figure 6) demonstrates the clear distinction between the dorsal sclerotic zone and the ventral lytic zone within the body of the active lesion.

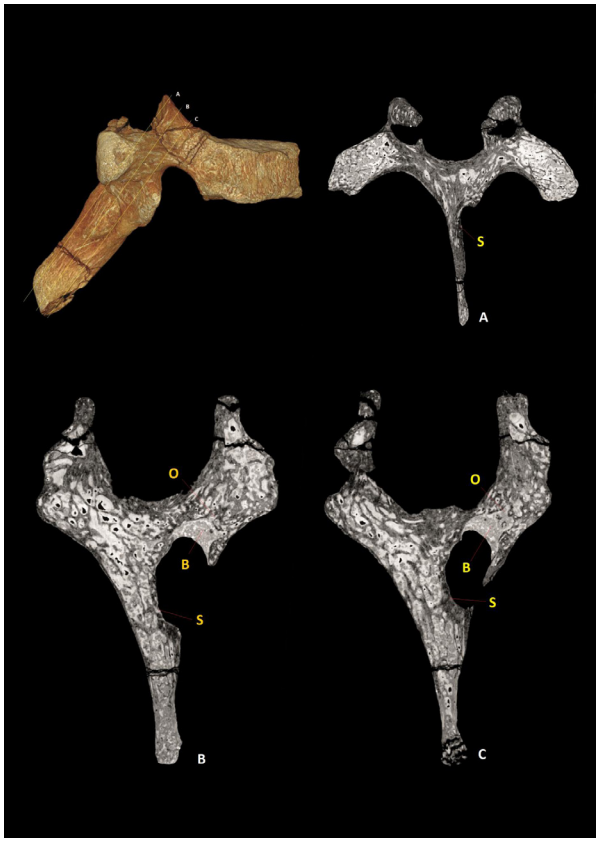

Key: S – quiescent sclerotic zone, O – active osteolytic zone, B – remaining breccia matrix infill.

Figure 5: Transverse slices through vertebra U.W. 88-37 derived from phase-contrast X-ray synchrotron microtomography. Relative position and anatomical orientation of orthoslices (a), (b) and (c) shown on the volume-rendered model. The posterior portion of the lesion is sclerotic with circumscribed margins of well-integrated cortical bone, abutted and intersected by trabecular striae, with remodelling and reorganisation of the cortex. The anterior portion of the lesion displays a geographic pattern of bone destruction, showing a sharp non-sclerotic margin and evidence of active osteolytic processes, with sharply defined transection of individual trabeculae and active osteolytic penetration into the anterior portion of the lamina. Image produced by P.S.R.Q.

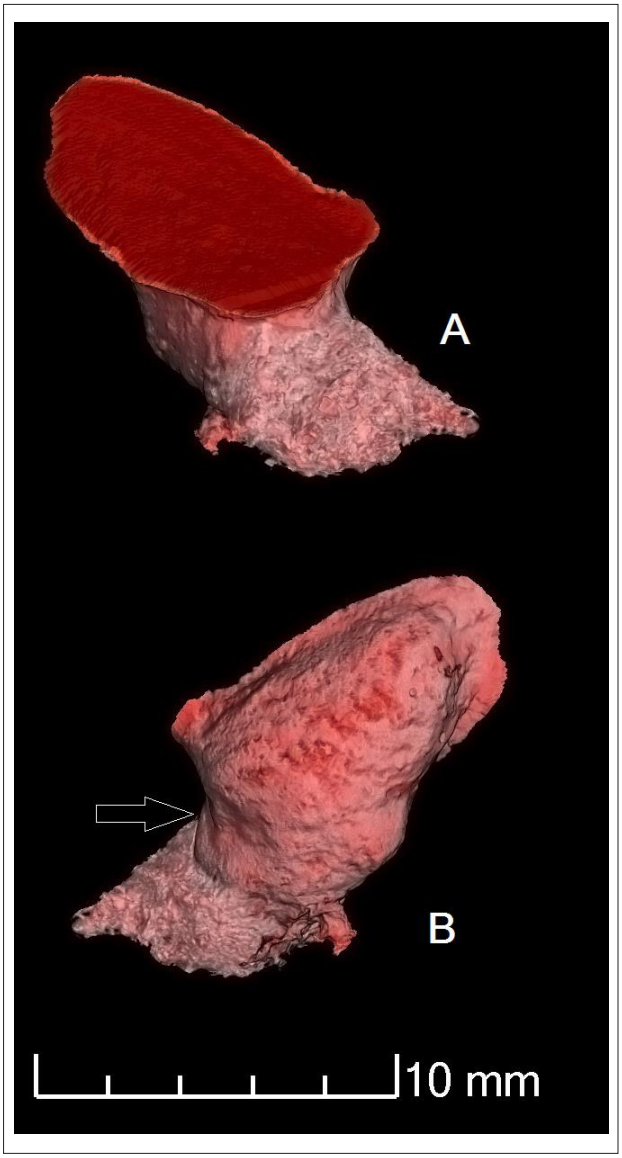

Figure 6: Surface rendered image volume of the U.W. 88-37 lesion derived from phase-contrast X-ray synchrotron microtomography. Images show isosurface derived from segmented boundaries of the lesion (remaining breccia infill removed). The arrow denotes the interface between the smoother dorsal sclerotic zone and the disorganised ventral lytic zone within the body of the lesion. (a) right lateral view, (b) medial view. Images produced by P.T.

Differential diagnosis

Diagnosis was undertaken using palaeopathological and clinical diagnostic criteria[1,2,20-34]. The accumulated evidence for osteolytic and osteosclerotic processes indicates that the disease process was both chronic and active at the time of death of MH1 (as mentioned, at a developmentally equivalent stage to a modern human child of 12 to 13 years of age). The lesion was less than 15 mm at the largest diameter, extending deep into the right side of the spinous process and involving only the vertebral lamina. The presence of reorganised sclerotic bone indicates a reactive ante-mortem process, and the lesion can therefore not be attributed to taphonomic, diagenetic or pathology-mimicking effects or processes[1].

The morphology of the lesion externally and internally is inconsistent with vertebral osteomyelitis. The absence of a proliferative cortical inflammatory response (such as periosteal and/or endosteal bone hypertrophy) or secondary lytic lesions across both the U.W. 88-37 vertebra and the surviving cranial and post-cranial elements of MH1 excludes a diagnosis of specific or non-specific systemic infection, such as brucellosis, non-specific osteitis, haematogenous osteomyelitis or treponemal osteitis. There is no evidence of deformation or callus formation associated with skeletal trauma such as a healed fracture, and the lesion does not present morphology consistent with post-traumatic processes such as cortical hypertrophy or the development of a cloaca. It is therefore most likely that this condition represents a primary osteogenic or osseous tumour of the spine. These are rare lesions with a much lower incidence than metastases, multiple myeloma or lymphoma.[1,2,20,21,23,27,32] Based on age at death, sex, anatomical location of the lesion, and specific patterns of expression and skeletal involvement, conditions such as osteosarcoma, chondrosarcoma or Ewing's sarcoma can be excluded; these neoplasms are often more aggressive, with destruction of the cortex[1,21,23].

Included in the differential diagnosis as the most likely cause of the observed lesion are osteoid osteoma, osteoblastoma, giant cell tumour and aneurysmal bone cyst. A number of secondary diagnoses are possible, specifically enostosis (compact bone island), fibrous cortical defect (fibroxanthoma), plasmacytoma, eosinophilic granuloma, and hydatid cyst infection. The range of possible differential diagnoses and primary diagnostic criteria are detailed in Table S1 (Supplementary Appendix).

Based on the observed pathological, morphological, and life-history criteria, the two most likely diagnoses are osteoid osteoma and osteoblastoma. Taking the demographic data for these two tumour types into account, both options seem possible: both are primary bone-forming tumours, osteoblastic in nature; benign; have a predilection for males; and show the highest prevalence in juveniles and adolescents. Osteoid osteoma resembles the observed lesion in terms of size, as these tumours are usually less than 20 mm in diameter, with well-circumscribed margins and being round or oval in form[23].

McCall[22] notes that computed tomography is the most valuable method to investigate this type of lesion. Under CT imaging of osteoid osteoma a small lucency is often recorded, which may have a central high attenuation as a result of mineralisation, and surrounding sclerotic bone is noted with some thickening of the lamina or pedicle. These are features seen in MH1 (Figure 4). On plain radiographs, most osteoid osteomas are osteosclerotic, with or without a visible nidus. By contrast, Kan and Schmidt[35] suggest that osteoblastomas are predominantly lucent or lytic in roughly 50% of cases, sclerotic in 30% of cases, and mixed in the remaining 20% of cases. On plain radiographs, osteoblastomas are typically expansile with a scalloped or lobulated appearance, and their margins are well-defined, with a sclerotic rim evident in approximately 30% of patients. A sclerotic rim is therefore much more common in osteoid osteomas than in osteoblastomas. The smooth, sclerotic, well-defined posterior margins of the lesion we studied are fully consistent with a resolving osteoid osteoma. However, the skeletal distribution of osteoid osteoma might argue against this being the most likely diagnosis, as osteoid osteomas are most commonly found in the lower extremities; occurrence in the spine is less likely than that exhibited in osteoblastoma[22].

To quantifiably assess the differential diagnosis, we applied Bayes Theorem of conditional probability to the diagnosis of osteoid osteoma and osteoblastoma. Using absolute clinical incidence data of osteoid osteoma[36-38] and osteoblastoma[25,37-42] to calculate prior and conditional probabilities of the disease expression in the vertebral column (as opposed to elsewhere in the skeleton), a conditional probability of 0.214 was derived for the likelihood of osteoid osteoma, and 0.068 for osteoblastoma. These results indicate a 3.75-fold higher likelihood that osteoid osteoma was represented in this case than osteoblastoma (see supplementary online material Table S2 for discussion of Bayes parameters and probability functions used). Given the morphological and pathological similarities between the two tumour types, and the age and nature of the specimen under analysis, the results suggest osteoid osteoma firstly and osteoblastoma secondly as the most likely diagnoses of what was clearly a benign entity of abnormal nature.

Discussion

MH1 suffered from a primary osteogenic tumour, which affected the right lamina of the sixth thoracic vertebra. The neoplastic lesion was chronic and was still active at the time of his death. From modern clinical studies[36-38] it is likely that osteoid osteoma may have taken months, rather than years, to develop. This neoplastic condition may involve neurological deficits, although this is unlikely as the lesion did not penetrate the neural canal, and no scoliosis was noted. However, the position of the lesion may have affected normal musculoskeletal function and movement of both the shoulder-blade and the upper right quadrant of the back. The tumour may have invoked a number of physiological responses including acute or chronic pain, muscular disturbance and pain-provoked muscular spasm, as discussed in clinical case studies.[21,36-38,40] A close association exists between the affected region and overlaying or closely inserting muscles such as trapezius, erector spinae, and rhomboid major, and this might have led to limitations on normal movement, given the likely arboreal component in the locomotor repertoire of *A. sediba.*[9,43]

The presence of a primary bone-forming tumour of the spine presents a number of considerations with regard to both the life-history of *Australopithecus sediba,* and evidence for neoplasia elsewhere in the deep past. Evidence for neoplastic disease is not unknown in the fossil, archaeological and historical records[1,8,44]. However, preservational factors limit the study of neoplasms to the skeleton (with the rare exception of naturally and artificially mummified bodies that may preserve pathological soft tissues) from which the confident diagnosis of tumours has been problematical[45]. The earliest skeletal evidence for neoplastic disease comes from pre-Cenozoic contexts, with purported cases of neoplasm found in fossil fish from the Upper Devonian. The earliest unequivocal case dates from 300 Ma, with evidence of benign osteoma with focal hyperostosis affecting the skeleton of *Phanerosteon mirabile* from the North American Lower Carboniferous[3]. Later terrestrial cases include diagnoses of benign haemangioma and eosinophilic granuloma in Jurassic dinosaurs; benign osteoma in mosasaurs; and haemangioma, metastatic cancer, desmoplastic fibroma and osteoblastoma in Cretaceous hadrosaurs.[46,47] In the more recent past, benign osteoid osteoma and osteoblastoma have been identified in European mammoths dating from 24 000 to 23 000 years ago (ka).[48]

The presence of neoplastic disease in the hominin fossil record is highly contentious. Until recently, the earliest purported evidence was suggested to be from a mandible of archaic *Homo* from Kanam, Kenya. This fossil is generally thought to derive from the Lower or Middle Pleistocene, and expresses pathological growth in the symphysial region. The lesion has been attributed to osteosarcoma, bone keloid, or Burkitt's lymphoma, although some researchers have diagnosed it as osteomyelitis resulting from a facial fracture[49-52]. The first substantive evidence for malignant neoplasia in hominins is derived from the SK7923 metatarsal fragment, dated to 1.8 to 1.6 Ma, from the site of Swartkrans, South Africa; a bony cortical exostosis together with osseous infilling of the medullary cavity of the shaft of the bone has been attributed by Odes and colleagues to osteosarcoma[5].

The next significant evidence for near-human neoplastic disease is suggested by Monge and colleagues, who present a case of fibrous dysplasia in a rib of *Homo neanderthalensis* dated to 120 ka from the European site of Krapina.[53] The Middle Pleistocene site of Atapuerca (Sima de los Huesos) evidenced small benign osteoid osteomata affecting the orbital roof of crania AT-777 and the endocranial surface of Cranium 4.[54] Other evidence comes from the Vogelherd (Stetten) II parietal bone, initially thought to represent a 35-ka-old Neanderthal, but now known to be Neolithic in origin[55]; in this specimen new bone formation has been linked to a possible meningioma although the final diagnosis remains equivocal[56]. The most significant evidence for neoplastic disease in antiquity derives from the bio-archaeological record of the recent Holocene (and the last four millennia in particular) and is detailed in a number of historical reviews and texts[1-3,46] to which the reader is directed.

As noted above, neoplastic disease in various forms, including osteoid osteoma and osteoblastoma, is an ancient phenomenon. It first appeared during the Palaeozoic and Mesozoic in extinct fish and members of the Dinosauria respectively.[3,46,47] However, the fact that reports of cancers or neoplasms remain exceedingly rare in the fossil record of almost any geological epoch[1,3,8,46,47,53] may be due to a number of factors, exacerbated by the relative disjunction between osseous tumours and all other forms of neoplasms. Primary bone tumours are rare compared with other neoplasms and account for around 7% of all soft and hard tissue cancers.[22] Neoplasms are historically reported to be rare in wild living mammals, with only 1.8% of deaths in chimpanzee communities reportedly resulting from cancer.[3] A mere handful of neoplastic cases have been recorded based on observational studies of camels, deer, gibbons, tigers, kangaroos, pacaranas, fur seals, ferrets, killer whales, harbour seals, sea lions and harp seals.[3] However, recent reviews of neoplasms in wild non-human primates[57] have shown that neoplastic disease might be far more widespread than previous studies suggest, in both monkeys and great apes; however, the vast majority of such cases involve benign soft tissue rather than malignant tumours. When bone tumours have been noted, they have tended to present as small benign growths such as button osteomata, which have been observed in both gorilla subspecies but have not been seen in either chimpanzees or orangutans[57]. An isolated case of benign osteochondroma was observed in the Gombe chimpanzee 'Old Female'.[58] Whilst these rare cases of neoplasia in non-human primates share morphological homology with human disease expression, it is unclear whether they share a common genetic basis or evolutionary history.

With regard to osteoid osteoma in humans, cytogenetic chromosomal studies indicate some degree of a genetic basis. This includes the involvement of chromosome 22, 22q monosomy and trisomy aberrations[59]; aberrant expression of transcription factors *Runx2* and *Osterix*, both of which are master regulators of osteoblastic lineage differentiation[60]; and duplications and deletions at 22q13.1[59], the locus of which reflects genes that play a role directly in osteogenesis (PDGF-B and ATF-4). The involvement of the latter suite of genes may suggest a degree of evolutionary conservatism, which warrants further investigation across primate taxa. As noted by Odes et al.[5], whilst the expression of neoplasia is rare in prehistory, the *capacity* for neoplastic disease (as evidenced by both fossil evidence and oncogenes) was present in deep-time.

It is no surprise that metastatic bone tumours are rare or absent in the archaeological and fossil records, because of the limited life expectancies of our ancestors[6,7] and the low incidence generally of skeletally forming or affecting neoplasms[1,3,20,23,46]. It is well known that primary bone tumours mostly occur in younger individuals[1,20,21,27,37,40], and it can therefore be expected that such tumours would have been present and have a similar prevalence to what is observed among modern individuals. It seems likely that neoplastic disease was as prevalent in ancient hominin populations as that expressed today in wild primate groups, but for various reasons it left little fossil trace. One reason might be the sheer paucity of individuals recovered from the hominin record, which would represent an issue of epidemiological sampling[6].

With regard to the earliest evidence for neoplastic disease in the hominin fossil record reported here, the fact that primary bone neoplasms are so rare makes this an important discovery. Whilst we consider it unlikely that neoplastic disease would have played a major role in the evolutionary forces operating on the Homininae, this case provides a unique glimpse into the individual life experience of a single extinct hominin. MH1 provides a window onto the expression and evolution of neoplastic disease in the human lineage, and highlights the utility of multidisciplinary clinical studies applied to the understanding of the evolution and development of disease in the human lineage.

Acknowledgements

We would like to acknowledge the assistance and help of the following people in the production of this research: Bonita de Klerk, Wilma Lawrence and Jennifer Randolph-Quinney. S.A.W. would like to acknowledge the help of Morgan Hill and Eric Mazelis from the

Microscopy and Imaging Facility, and Neil Duncan and Eileen Westwig of the Department of Mammalogy at the American Museum of Natural History. Further support in scanning time was given by the European Synchrotron Radiation Facility and by the Department of Radiology at Charlotte Maxeke Academic Hospital in Johannesburg. The research was funded by grants to L.R.B. from the National Geographic Society, the National Research Foundation of South Africa and the DST/NRF South African Centre of Excellence in Palaeosciences. Additional direct support for E.J.O. was received from the National Research Foundation of South Africa and the DST/NRF South African Centre of Excellence in Palaeosciences. M.S. was supported by the National Research Foundation of South Africa.

Authors' contributions

P.S.R.Q. coordinated the research and wrote the original draft of the manuscript, incorporating additional case notes and observational data on U.W. 88-37 as provided by S.A.W., M.S., M.R.M., J.S.S., S.E.C. and L.R.B. Detailed discussion of oncogenetics was provided by T.A, and E.J.O. provided detailed discussion of the historical data on early hominin palaeopathology. P.T. undertook the synchrotron scanning of the specimen, and primary reconstruction, segmentation and imaging. All authors contributed equally to data acquisition and analysis, and to editing.

References

1. Ortner DJ. Tumors and tumor-like lesions of bone. In: Ortner DJ, editor. Identification of Pathological Conditions in Human Skeletal Remains. Amsterdam: Academic Press; 2003. p. 503–544. http://dx.doi.org/10.1016/B978-012528628-2/50057-0
2. Aufderheide AC, Rodríguez-Martin C. The Cambridge encylopedia of human paleopathology. Cambridge: Cambridge University Press; 1998.
3. Capasso LL. Antiquity of cancer. Int J Cancer. 2005;113(1):2–13. http://dx.doi.org/10.1002/ijc.20610
4. Jemal A, Bray F, Center M, Ferlay J, Ward E, Forman D. Global cancer statistics. CA Cancer J Clin. 2011;61(2):69–90. http://dx.doi.org/10.3322/caac.20107
5. Odes EJ, Randolph-Quinney PS, Steyn M, Throckmorton Z, Smilg JS, Zipfel B, et al. Earliest hominin cancer: 1.7-milllion-year-old osteosarcoma from Swartkrans Cave, South Africa. S Afr J Sci. 2016;112(7/8), Art. #2015-0471, 5 pages. http://dx.doi.org/10.17159/sajs.2016/20150471
6. Chamberlain AT. Demography in archaeology. Cambridge: Cambridge University Press; 2006. http://dx.doi.org/10.1017/CBO9780511607165
7. Mann A. Paleodemographic aspects of the South African australopithecines. Philadelphia: University of Pennsylvania; 1975.
8. Retief FP, Cilliers L. Breast cancer in antiquity. S Afr Med J. 2011;101(8):513–515.
9. Berger LR, de Ruiter DJ, Churchill SE, Schmid P, Carlson KJ, Dirks PHGM, et al. *Australopithecus* sediba: A new species of *Homo*-like australopith from South Africa. Science. 2010;328(5975):195–204. http://dx.doi.org/10.1126/science.1184944
10. Williams SA, Ostrofsky KR, Frater N, Churchill SE, Schmid P, Berger LR. The vertebral column of *Australopithecus sediba*. Science. 2013;340(6129). http://dx.doi.org/10.1126/science.1232996
11. Berger L, Lacruz R, De Ruiter D. Revised age estimates of *Australopithecus*-bearing deposits at Sterkfontein, South Africa. Am J Phys Anthropol. 2002;119:192–197. http://dx.doi.org/10.1002/ajpa.10156
12. Brain CK. Structure and stratigraphy of the Swartkrans Cave in the light of the new excavations. In: Brain CK, editor. Swartkrans. Pretoria: Transvaal Museum Monograph 8; 1993. p. 23–34.
13. Berger LR, Menter CG, Thackeray JF. The renewal of excavation activities at Kromdraai, South Africa. S Afr J Sci. 1994;90:209–210.
14. Lacruz RS, Brink JS, Hancox J, Skinner AS, Herries A, Schmidt P, et al. Paleontology, geological context and paleoenvironmental implications of a Middle Pleistocene faunal assemblage from the Gladysvale Cave, South Africa. Paleontologia Africana. 2002;38:99–114.
15. Dirks PHGM, Berger LR, Roberts EM, Kramers JD, Hawks J, Randolph-Quinney PS, et al. Geological and taphonomic context for the new hominin species *Homo naledi* from the Dinaledi Chamber, South Africa. eLife. 2015;4, Art. #e09561. http://dx.doi.org/10.7554/eLife.09561
16. Dirks P, Berger L. Hominin-bearing caves and landscape dynamics in the Cradle of Humankind, South Africa. J Afr Earth Sci. 2012;78:109–131. http://dx.doi.org/10.1016/j.jafrearsci.2012.09.012
17. Dirks PHGM, Kibii JM, Kuhn BF, Steininger C, Churchill SE, Kramers JD, et al. Geological setting and age of *Australopithecus sediba* from Southern Africa. Science. 2010;328(5975):205–208. http://dx.doi.org/10.1126/science.1184950
18. Val A, Dirks PHGM, Backwell LR, d'Errico F, Berger LR. Taphonomic analysis of the faunal assemblage associated with the hominins (*Australopithecus sediba*) from the Early Pleistocene cave deposits of Malapa, South Africa. PLoS ONE. 2015;10(6), Art. #e0126904. http://dx.doi.org/10.1371/journal.pone.0126904
19. L'Abbé EN, Symes SA, Pokines JT, Cabo LL, Stull KE, Kuo S, et al. Evidence of fatal skeletal injuries on Malapa Hominins 1 and 2. Sci Rep. 2015;5, Art. #15120. http://dx.doi.org/10.1038/srep15120
20. Bahk Y-W. Combined scintigraphic and radiographic diagnosis of bone and joint diseases. New York: Springer; 2007. http://dx.doi.org/10.1007/978-3-540-68732-0_4
21. Khurana JS. The surgical pathology of bone tumors and tumor-like lesions. In: Khurana JS, editor. Bone pathology. London: Humana Press; 2009. p. 285–345. http://dx.doi.org/10.1007/978-1-59745-347-9_19
22. McCall IW. Radiology and pathological correlations of bone tumours of the spine. In: Gourtsoyiannis NC, Ros PR, editors. Radiologic-pathologic correlations from head to toe: Understanding the manifestations of disease. Berlin: Springer; 2005. p. 721–742. http://dx.doi.org/10.1007/3-540-26664-X_32
23. Vigorita VJ. Orthopaedic pathology. 2nd ed. Philadelphia: Lippincott Williams & Wilkins; 2008.
24. Baba H, Maezawa Y, Furusawa N, Wada M, Kokubo Y, Imura S, et al. Solitary plasmacytomas of the spine associated with neurological complications. Spinal Cord. 1998;36(7):470–475. http://dx.doi.org/10.1038/sj.sc.3100572
25. Berry M, Mankin H, Gebhardt M, Rosenberg A, Hornicek F. Osteoblastoma: a 30-year study of 99 cases. J Surg Oncol. 2008;98:179–183. http://dx.doi.org/10.1002/jso.21105
26. Betsy M, Kupersmith LM, Springfield DS. Metaphyseal fibrous defects. J Am Acad Orthop Surg. 2004;12(2):89–95. http://dx.doi.org/10.5435/00124635-200403000-00004
27. Binning M, Klimo Jr P, Gluf W, Goumnerova L. Spinal tumors in children. Neurosurg Clin N Am. 2007;18(4):631–658. http://dx.doi.org/10.1016/j.nec.2007.07.001
28. McLain RF, Weinstein JN. Solitary plasmacytomas of the spine: A review of 84 cases. J Spinal Disord. 1989;2(2):69–74. http://dx.doi.org/10.1097/00002517-198906000-00001
29. Mendenhall WM, Zlotecki RA, Scarborough MT, Gibbs CP, Mendenhall NP. Giant cell tumor of bone. Am J Clin Oncol. 2006;29(1):96–99. http://dx.doi.org/10.1097/01.coc.0000195089.11620.b7
30. Celik C, Münevver FS, Ucan H. Spinal hydatid cyst: Review. Türkiye Klinikleri J Med Sci. 2010;30(3):1073–1077. http://dx.doi.org/10.5336/medsci.2009-13722
31. Kransdorf MJ, Sweet DE. Aneurysmal bone cyst: Concept, controversy, clinical presentation, and imaging. Am J Roentgenol. 1995;164(3):573–580. http://dx.doi.org/10.2214/ajr.164.3.7863874
32. Osborn AG. Tumors, cysts, and tumorlike lesions of the spine and spinal cord. In: Osborn AG, editor. Diagnostic neuroradiology. St. Louis: Mosby; 1994. p. 876–918.
33. Kuruvath S, O'Donovan DG, Aspoas AR, David KM. Benign fibrous histiocytoma of the thoracic spine: Case report and review of the literature. J Neurosurg Spine. 2006;4(3):260–264. http://dx.doi.org/10.3171/spi.2006.4.3.260
34. Kaye JJ, Freiberger RH. Eosinophilic granuloma of the spine without vertebra plana: A report of two unusual cases. Radiology. 1969;92(6):1188–1191. http://dx.doi.org/10.1148/92.6.1188

35. Kan P, Schmidt MH. Osteoid osteoma and osteoblastoma of the spine. Neurosurg Clin North Am. 2008;19(1):65–70. http://dx.doi.org/10.1016/j.nec.2007.09.003

36. de Souza Dias L, Frost HM. Osteoid Osteoma–Osteoblastoma. Cancer. 1974;33(4):1075–1081. http://dx.doi.org/10.1002/1097-0142(197404)33:4<1075::AID-CNCR2820330427>3.0.CO;2-4

37. Azouz EM, Kozlowski K, Marton D, Sprague P, Zerhouni A, Asselah F. Osteoid osteoma and osteoblastoma of the spine in children: Report of 22 cases with brief literature review. Pediatr Radiol. 1986;16(1):25–31. http://dx.doi.org/10.1007/BF02387501

38. Saccomanni B. Osteoid osteoma and osteoblastoma of the spine: A review of the literature. Curr Rev Musculoskelet Med. 2009;2(1):65–67. http://dx.doi.org/10.1007/s12178-009-9047-6

39. Lucas DR. Osteoblastoma. Arch Pathol Lab Med. 2010;134:1460–1466.

40. Amacher AL, Eltomey A. Spinal osteoblastoma in children and adolescents. Child Nerv Syst. 1985;1(1):29–32. http://dx.doi.org/10.1007/BF00706727

41. Aszódi K. Benign osteoblastoma: Quantitative histological distinction from osteoid osteoma. Arch Orthop Unfallchir. 1977;88(3):359–368. http://dx.doi.org/10.1007/BF00416625

42. Boriani S, Capanna R, Donati D, Levine A, Picci P, Savini R. Osteoblastoma of the spine. Clin Orthop Relat Res. 1992;278:37–45. http://dx.doi.org/10.1097/00003086-199205000-00006

43. Churchill SE, Holliday TW, Carlson KJ, Jashashvili T, Macias ME, Mathews S, et al. The upper limb of *Australopithecus sediba*. Science. 2013;340(6129), Art. #1233477. http://dx.doi.org/10.1126/science.1233477

44. Eshed V, Latimer B, Greenwald CM, Jellema LM, Rothschild BM, Wish-Baratz S, et al. Button osteoma: Its etiology and pathophysiology. Am J Phys Anthropol. 2002;118(3):217–230. http://dx.doi.org/10.1002/ajpa.10087

45. Rothschild BM, Rothschild C. Comparison of radiologic and gross examination for detection of cancer in defleshed skeletons. Am J Phys Anthropol. 1995;96(4):357–363. http://dx.doi.org/10.1002/ajpa.1330960404

46. Rothschild BM, Martin LD. Paleopathology: Disease in the fossil record. Boca Raton, FL: CRC Press; 1993.

47. Rothschild BM, Tanke DH, Hebling M, Martin LD. Epidemiologic study of tumors in dinosaurs. Naturwissenschaften. 2003;90(11):495–500. http://dx.doi.org/10.1007/s00114-003-0473-9

48. Leshchinsky SV. Paleoecological investigation of mammoth remains from the Kraków Spadzista Street (B) site. Quartern Int. 2012;276–277:155–169. http://dx.doi.org/10.1016/j.quaint.2012.05.025

49. Phelan J, Weiner MJ, Ricci JL, Plummer T, Gauld S, Potts R, et al. Diagnosis of the pathology of the Kanam Mandible. Oral Surg Oral Med Oral Pathol Oral Radiol Endod. 2007;103(4), Art. #e20. http://dx.doi.org/10.1016/j.tripleo.2006.12.041

50. Tobias PV. The Kanam jaw. Nature. 1960;185:946–947. http://dx.doi.org/10.1038/185946a0

51. Tobias PV. A re-examination of the Kanam mandible. In: Mortelmans G, Nenquin J, editors. Actes du IVe Congrès Panafricain de Préhistoire et de l'Étude du Quaternaire, Sections I and II. Tervuren, Belgique: Annales Ser. Qu-8o, Sciences Humaines 40; 1962. p. 341–350.

52. Stathopoulos G. Kanam mandible's tumour. Lancet. 1975;305(7899). p. 165. http://dx.doi.org/10.1016/S0140-6736(75)91462-2

53. Monge J, Kricun M, Radovčić J, Radovčić D, Mann A, Frayer DW. Fibrous dysplasia in a 120,000+ year old Neandertal from Krapina, Croatia. PLoS ONE. 2013;8(6), Art. #e64539. http://dx.doi.org/10.1371/journal.pone.0064539

54. Pérez P, Gracia A, Martínez I, Arsuaga J. Paleopathological evidence of the cranial remains from the Sima de los Huesos Middle Pleistocene site (Sierra de Atapuerca, Spain). Description and preliminary inferences. J Hum Evol. 1997;33(2):409–421. http://dx.doi.org/10.1006/jhev.1997.0139

55. Conard NJ, Grootes PM, Smith FH. Unexpectedly recent dates for human remains from Vogelherd. Nature. 2004;430:198–201. http://dx.doi.org/10.1038/nature02690

56. Czarnetzki A. Pathological changes in the morphology of the Young Paleolithic skeletal remains from Stetten (South-west Germany). J Hum Evol. 1980;9(1):15–17. http://dx.doi.org/10.1016/0047-2484(80)90037-8

57. Lovell NC. Patterns of injury and illness in Great Apes. Washington, DC: Smithsonian Press; 1990.

58. Jurmain R. Trauma, degenerative disease and other pathologies among the Gombe chimpanzees. Am J Phys Anthropol. 1989;80(2):229–237. http://dx.doi.org/10.1002/ajpa.1330800211

59. López-Terrada D, Hicks JM. Genetics and molecular biology of bone and soft tissue tumors. In: Khurana JS, editor. Bone pathology. Dordrecht: Humana Press; 2009. p. 91–124. http://dx.doi.org/10.1007/978-1-59745-347-9_6

60. Dancer J, Henry S, Bondaruk J, Lee S, Ayala A, de Crombrugghe B, et al. Expression of master regulatory genes controlling skeletal development in benign cartilage and bone forming tumors. Hum Pathol. 2010;41(12):1788–1793. http://dx.doi.org/10.1016/j.humpath.2010.06.008

Note: This article is accompanied by supplementary material.



Copyright of South African Journal of Science is the property of Academy of Science of South Africa and its content may not be copied or emailed to multiple sites or posted to a listserv without the copyright holder's express written permission. However, users may print, download, or email articles for individual use.

CHAPTER 6: Osteopathology and Insect Traces in the *Australopithecus africanus* Skeleton StW 431 *

**Published: South African Journal of Science*

Odes, E.J., Parkinson, A.H., Randolph-Quinney, P.S., Zipfel, B., Jakata, K., Bonney, H. and Berger, L.R., 2017. Osteopathology and insect traces in the *Australopithecus africanus* skeleton StW 431. South African Journal of Science, 113(1-2), pp.1-7.

AUTHORS:
Edward J. Odes[1]
Alexander H. Parkinson[2]
Patrick S. Randolph-Quinney[1,2,3]
Bernhard Zipfel[2,4]
Kudakwashe Jakata[2]
Heather Bonney[5]
Lee R. Berger[2]

AFFILIATIONS:
[1]School of Anatomical Sciences, University of the Witwatersrand, Johannesburg, South Africa
[2]Evolutionary Studies Institute, University of the Witwatersrand, Johannesburg, South Africa
[3]School of Forensic and Applied Sciences, University of Central Lancashire, Preston, Lancashire, United Kingdom
[4]School of Geosciences, University of the Witwatersrand, Johannesburg, South Africa
[5]Department of Earth Sciences, Natural History Museum, London, United Kingdom

CORRESPONDENCE TO:
Edward J. Odes

EMAIL:
eddieodes@gmail.com

DATES:
Received: 17 May 2016
Revised: 07 Sep. 2016
Accepted: 08 Sep. 2016

KEYWORDS:
Sterkfontein; micro computed tomography; spinal degenerative joint disease; palaeopathology; taphonomy

HOW TO CITE:
Odes EJ, Parkinson AH, Randolph-Quinney PS, Zipfel B, Jakata K, Bonney H, et al. Osteopathology and insect traces in the *Australopithecus africanus* skeleton StW 431. S Afr J Sci. 2017;113(1/2), Art. #2016-0143, 7 pages. http://dx.doi.org/10.17159/sajs.2017/20160143

ARTICLE INCLUDES:
✓ Supplementary material
× Data set

FUNDING:
DST/NRF Centre of Excellence in Palaeosciences; National Research Foundation (South Africa); University of the Witwatersrand

© 2017. The Author(s). Published under a Creative Commons Attribution Licence.

Osteopathology and insect traces in the *Australopithecus africanus* skeleton StW 431

We present the first application of high-resolution micro computed tomography in an analysis of both the internal and external morphology of the lumbar region of StW 431 – a hominin skeleton recovered from Member 4 infill of the Sterkfontein Caves (South Africa) in 1987. The lumbar vertebrae of the individual present a number of proliferative and erosive bony processes, which were investigated in this study. Investigations suggest a complex history of taphonomic alteration to pre-existing spinal degenerative joint disease (SDJD) as well as post-mortem modification by an unknown insect. This study is in agreement with previous pathological diagnoses of SDJD which affected StW 431 and is the first time insect traces on this hominin are described. The results of this analysis attest to the complex series of post-mortem processes affecting the Sterkfontein site and its fossil assemblages.

Significance:

- First application of high-resolution micro computed tomography of the lumbar region of StW 431, a partial skeleton of *Australopithecus africanus,* attests to pre-existing degenerative joint disease and identifies post-mortem modification by an unknown insect.
- The co-occurrence of degenerative pathology and insect modification may not be unique to StW 431. A combination of traditional morphoscopic analysis and non-invasive high-resolution tomography is recommended.

Introduction

The StW 431 hominin skeleton was discovered by excavation teams from the University of the Witwatersrand during February and March 1987,[1] at the karstic cave site of Sterkfontein, Cradle of Humankind, South Africa. This site has yielded the largest sample of the taxon *Australopithecus africanus,* fossil members of the genus *Homo* and archaeological evidence of Oldowan and more recent lithic technologies.[2-7]

The StW 431 specimen comprises a partial skeleton of *Australopithecus africanus,* consisting of 48 fragments reconstructed into 18 partial elements.[1] The skeletal remains (Figure 1) consist of portions of the right scapula and clavicle, right humerus, radius and ulna, a right rib, five thoracic vertebrae, five lumbar vertebrae, the first three sacral segments and os coxae, and part of the right acetabulum. The individual is skeletally adult (based on sacral vertebral fusion) and has been previously assigned as male on the basis of a number of morphological characteristics. These characteristics include overall robusticity and muscular markers, the proportions between the body of the first sacral segment and the sacral base, and a relatively large estimated body mass (41.1–42.5 kg) based on reduced major axis regression consistent with the male range of body size for *A. africanus.*[1] The postcranial remains were associated to a single individual, based partly on position, refit, similar colour and physical condition, state of preservation and morphology.[1]

Stratigraphic understanding of the site at the time of excavation attributed the remains to Bed B of Member 4 within the Sterkfontein Formation.[1] While the exact chronological age of this stratigraphic bed is unknown, age estimates range between 1.5 Ma and 2.8 Ma for the member as a whole.[2-7] It is widely acknowledged that accurate dating of South African cave sites has been historically problematical.[8] Age ranges of between 2.4 mya and 2.8 mya of Sterkfontein Member 4 have been established by faunal analysis and archaeology[9-12], where absolute dating methods have proved problematic[13]. Electron spin resonance methods have also been used to date South African Plio-Pleistocene sites, and dates between 1.6 mya and 2.87 mya for Member 4 Sterkfontein have been suggested, with an average electron spin resonance estimated age of 2.1 ± 0.5 Ma.[14] Using U-Pb dating methods, a new absolute age range of between 2.65 ± 0.30 Ma and 2.01 ± 0.05 Ma has been assigned to fossiliferous deposits of Sterkfontein Member 4.[15] Electron spin resonance, isotopic and palaeomagnetic studies carried out on speleothem and siltstone material from Member 4 Sterkfontein Cave suggests the date of the deposits and *A. africanus* fossils at between 2.58 Ma and 2.16 Ma. Thus largely based on arguments of parsimony, provenance and morphology, most researchers studying the skeleton have accepted a taxonomic assignment to *A. africanus.*[16,17]

StW 431 is additionally important as the skeleton has been cited with regard to ongoing debate concerning the presence of skeletal pathology in the specimen; researchers have previously identified two conditions – brucellosis and spondylosis deformans – affecting this specimen.[18,19] Staps[18] diagnosed spondylosis deformans with osteophytic formation, and osteoarthritis of the facet joints from L4 to S1. In contradistinction, D'Anastasio and colleagues[19] diagnosed a case of possible brucellosis. In this paper, we attempt to resolve this debate and clarify the nature of ante- versus post-mortem processes affecting the specimen.



Scale = 50 mm

Figure 1: StW 431 – a partial skeleton of *Australopithecus africanus* discovered at Sterkfontein Caves in 1987. Stw 431 represented only the third partial skeleton attributed at the time to *A. africanus*, and represents the only probable male skeleton attributed to this taxon to date.

Materials and methods

The fourth and fifth lumbar vertebrae of StW 431 were studied macro- and microscopically to record surface morphology. Internal bone structure was imaged using micro computed tomography (micro-CT). Comparative skeletal material – including healthy modern human and pathological vertebrae from the Bone Teaching Collection and Raymond A. Dart Collection of Human Skeletons housed in the School of Anatomical Sciences at the University of the Witwatersrand – was also imaged. Comparative material with known and purported brucellar pathology from radiographical and palaeopathological literature was also studied (see Supplementary table 1 for a list of all comparative materials used in this study).

Gross surface morphology of the vertebral specimens was studied microscopically at magnifications of 7–25 times under reflected light using an Olympus SZX 16 multifocus microscope fitted with a digital camera. Micrographic imaging of the anterior and lateral bodies, antero-superior margins and endplates of the two lumbar vertebrae was carried out by applying Analysis 5.0, which includes a Z-stacking function. This function operates as an automated smoothing process whereby multiple sub-images are transformed into a single high-quality, high-resolution image with greater depth of field than a single micrograph.

In order to investigate internal (as well as external) morphology, imaging of the StW 431 vertebral specimens was carried out using micro-CT undertaken with a Nikon Metrology XTH 225/320 LC dual source industrial CT system housed in the Evolutionary Studies Institute of the University of the Witwatersrand. Both specimens were scanned using a potential difference of 85 kV and a current of 75 μA at a resolution of 33 μm; a TIFF format image stack was generated in VG Studio Max following volume reconstruction. Further reconstruction was undertaken using Avizo Amira 5.4 to generate both two-dimensional orthoslice and three-dimensional surface rendered views based on the volume data; multiplanar mode was used to allow the recovery of homologous orthoslices (superior, inferior, coronal and sagittal) through both specimens for comparative purposes.

Results

Macroscopic analysis

The fourth lumbar vertebra (L4) is largely complete (Figure 2) and presents as the bulk of the vertebral centrum, the right pedicle, with right superior articular and transverse processes. Some degree of post-mortem damage has occurred, resulting in the loss of the left pedicle, lamina and superior, inferior and transverse processes. The remaining superior and transverse processes display some degree of post-mortem damage, with apices of both processes truncated, leading to exposure of internal trabeculae. The vertebral body further displays a fracture which runs slightly antero-laterally from the margin of the vertebral foramen to the anterior border of the body, just to the right of the midline. This fracture has led to the loss of a wedge of cortical bone at the antero-inferior margin of the centrum, with loss of cortex and exposure of underlying trabecular bone either side of the plane of the fracture. This erosion is contiguous with a zone of cortical erosion affecting the anterior surface of the body, with greatest removal of cortex on the left side of the body. Additionally, there is a small area of post-mortem erosion at the antero-superior rim of the centrum, on either side of the fracture, which has shaved off part of the labrum of the body over approximately 5–7 mm of the margin.

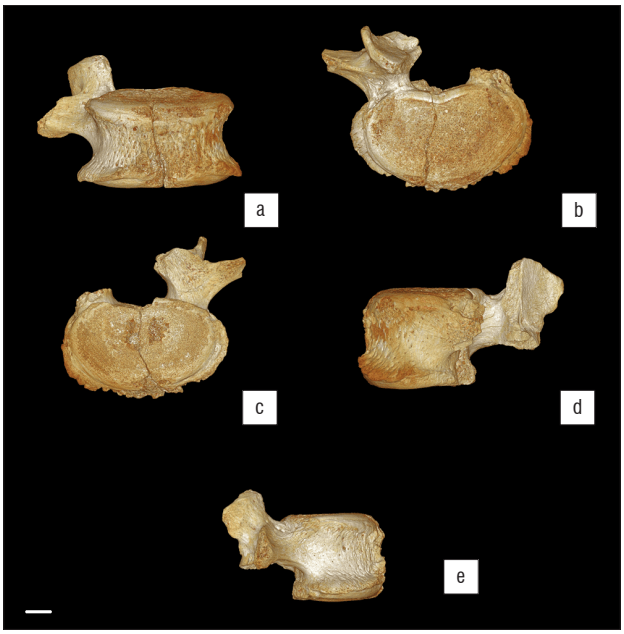

Scale = 10 mm

Figure 2: Three-dimensional volume rendered micro-CT views of the L4 vertebra of StW 431: (a) anterior, (b) superior, (c) inferior, (d) left lateral and (e) right lateral.

Slight osteophytic lipping occurs around the antero-superior region of L4, which creates a rolled appearance to the margin of the labrum, which is further disturbed by the erosion of this surface (Figure 2a). Extensive osteophytosis is expressed around the circumference of the inferior border of the vertebral body, present as a crenulated skirt of bone running from the anterior roots of the pedicles (the pedicle on the left, remaining as a short stump of the original process) around the margin of the body (Figure 2b,c). This skirt projects anteriorly a maximum of 5 mm beyond the inferior margin, and is most pronounced at the lateral

borders of the body. The superior endplate exhibits a generalised pattern of mild porosity. The surface of the inferior endplate exhibits more extensive erosion, with two major areas of cortical loss on either side of the midline of the vertebra – these are approximately 4 mm by 5 mm in diameter, the left of which is transected by the fracture which runs through the body.

The fifth lumbar vertebra (Figure 3) is less complete than L4 (Figure 2), displaying extensive post-mortem fracturing and damage. L5 presents as the left half of the vertebral body, with the pedicle, superior and inferior articular processes, and transverse process largely intact. The left lamina is present, together with a small portion of right lamina still attached, thus preserving a significant portion of the spinous process. In keeping with L4, L5 exhibits extensive osteophytic deposition, but both superior and inferior endplate margins, and the anterior surface of the body in the midline, which forms a series of cranio-caudally orientated buttresses, are more pronounced on the lateral side of the body. The osteophytic lipping extends from the left pedicle antero-laterally and continues anteriorly until it reaches the most anterior point of the vertebral body before it is interrupted by the fracture, which slices through the approximate midpoint of the vertebral body. The anterior projection of the superior osteophytic formation is interrupted by a large zone of removal of osseous tissue, which presents as a scooped, hollowed-out region that has removed both the osteophytic rim and a portion of the anterior body (Figure 3): this zone of removal has previously been described elsewhere as a region of osteolysis, possibly related to the presence of infectious disease.[19]

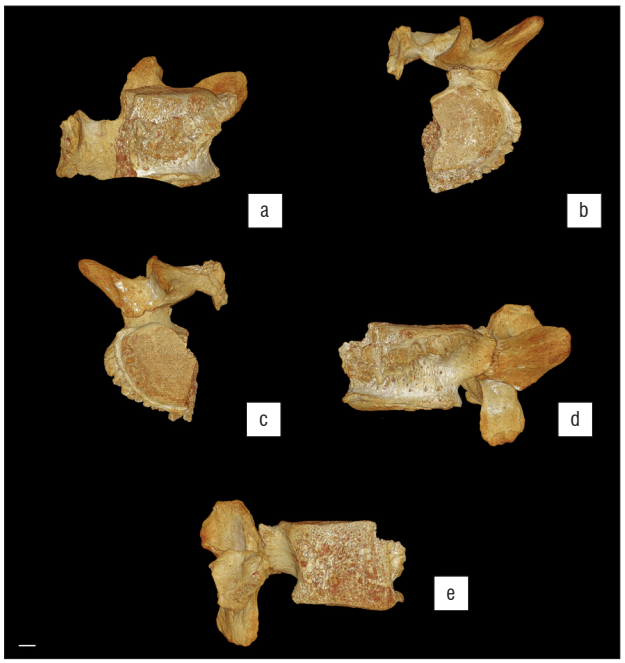

Scale = 10 mm

Figure 3: Three-dimensional volume rendered micro-CT views of the L5 vertebra of StW 431: (a) anterior, (b) superior, (c) inferior, (d) left lateral and (e) right lateral. Note the osteophytic formation on the superior and inferior endplate margins, as well as the anterior surface of the body in midline.

Microscopic analysis

Micro-tomographic imaging of the internal morphology of L4 indicates areas of both bone deposition and removal. The superior body displays very slight osteophytic lipping around the antero-superior margin, which overall presents a slightly rolled appearance in cross section. This is clearly seen in Figure 4a,b, with a slight degree of remodelling and an increase in trabecular thickness and concomitant reduction in trabecular spacing in the antero-superior margin of the centrum. The greatest expression of osteophytosis occurs in the inferior body, where the original cortical bone making up the surface of the body can be seen (Figure 4c). Secondly extensive areas of new bone formation of varying densities (from open woven to sclerotic) can be seen in transverse and coronal sections (Figure 4c,d). In addition to the marginal osteophytes, the two zones of endplate erosion are clearly evidenced. These appear as punched out cavities within the inferior body, where struts of individual trabeculae are truncated (and subsequently infilled with breccia in areas) with no evidence of sclerosis or reactive bone formation around the cavity margins (Figure 4c).

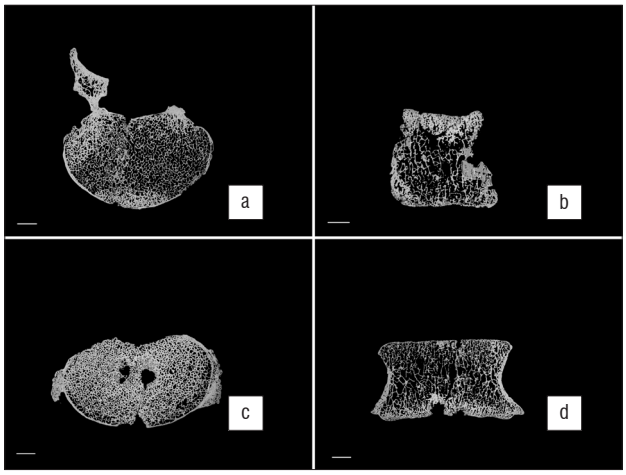

Scale = 10 mm

Figure 4: Micro-CT orthoslice views of the L4 vertebra of StW 431: (a) transverse superior, (b) sagittal midline, (c) transverse inferior and (d) anterior. Note the bilateral osteophytic formation and two zones of erosion evident on the inferior endplate surface of the L4 in (c). There is no evidence of sclerosis or new bone formation around the margins of the cavities (c). Also note areas of new bone formation ranging from open woven (c) to sclerotic (d).

In keeping with gross morphological assessment, micro-tomographic imaging of the internal morphology of L5 indicates extensive areas of both bone deposition and removal, with pronounced osteophytosis affecting the superior, anterior and inferior margins of the vertebral body. Figure 5a shows a transverse cross section through the superior region of the endplate (just inferior to the labrum), which demonstrates the extensive projection of osteophytes at the antero-superior margin. Unlike those affecting L4, these osteophytes express as direct remodelling of the cortical bone, appearing as both a thickened sclerotic margin and as crenulated buttresses of porous bone devoid of internal trabeculae; such a pattern is further reflected in the mid-transverse region of the body (Figure 5b). The inferior endplate, on the other hand, only presents osteophytosis as a thin ordered sclerotic rim extending around the inferior circumference, without buttressing (Figure 5c).

The pattern of erosion affecting L4 was identified by us (AHP) as being of potential post-mortem origin, and specifically surface modification caused by insects. In order to clarify this modification, potential insect damage was further imaged at magnifications between 7x and 115x using an Olympus SZX 16 multifocus microscope fitted with a digital camera. Terminologies used to describe the morphology of traces observed is based on a recent summary of general morphologies of bioerosional traces in bone.[20] Length and width measurements were taken using Stream Essentials© image processing software linked to the Olympus SZX multifocus microscope. Depth measurements were obtained using digital callipers. Two comparative collections of insect damage to bone were utilised in this study: these experimental collections comprise bones exposed to the following agents under control conditions; a southern African termite (*Trinervitermes trinervoides*)[21] and a dermestid beetle (*Dermestes maculatus*)[22]. Furthermore, insect damage was compared to available data gleaned from the literature.[21-24]

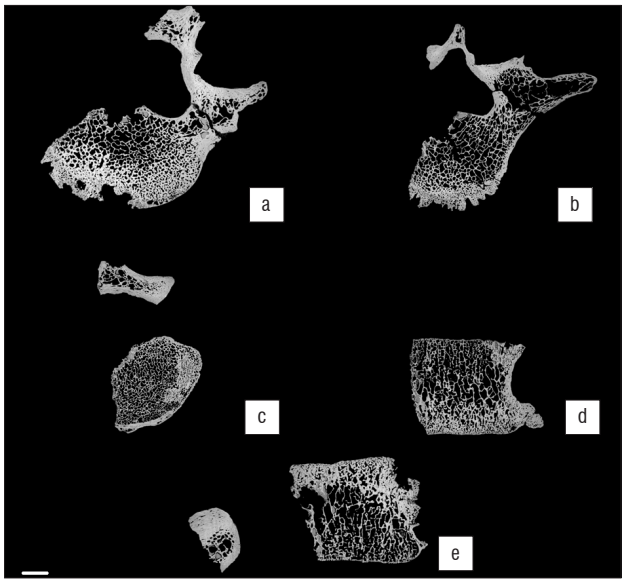

Scale = 10 mm

Figure 5: Micro-CT orthoslice views of the L5 vertebra of StW 431: (a,b) transverse to the midline (close to surface), (c) transverse to inferior, (d) coronal midline, (e) sagittal superior to bottom. Note new bone formation on the anterior wall (e) and major osteophytic formation at the antero-superior margin indicating remodelling of the cortex, revealing a sclerotic margin, and as crenulated buttresses of porous bone devoid of internal trabeculae (a,b). There is no evidence of sclerosis or reactive bone formation around the cavity margins (a). The inferior endplate (c) exhibits an osteophytic formation as a thin ordered sclerotic rim around inferior circumference with no presence of buttressing. Notice the channel interpreted as invertebrate damage in (e).

Insect traces

A channel-like structure is present on the antero-superior margin of the L5 vertebral body (Figure 6a,b). The channel comprises a series of conjoined excavations and cavities and extends from approximately the midpoint of the antero-superior rim of the body (where the vertebra has been fractured post-mortem) until the mid-lateral antero-superior margin of the upper endplate. Externally, there is no evidence of sclerosis or reactive bone formation around the cavity margins. The channel narrows from 8 mm to 3 mm in diameter and penetrates to a maximum depth of 4 mm. Embedded in this channel are distinctive circular holes which are 3–4 mm in diameter and 3–4 mm deep (Figure 5e demonstrates this pattern in cross section). No discernible mandible marks were found in association with the insect traces. The micro-CT images demonstrate an absence of bone remodelling related to either the channel or holes.

Discussion

Pathology

Gross observation of surface morphology and micro-tomographic imaging of the internal cortical and trabecular morphology of the StW 431 hominin vertebrae have indicated the presence of osseous proliferation (osteophytosis) consistent with degenerative spinal joint disease. Degenerative joint disease (DJD) is one of the most common pathological ailments observed in archaeo-skeletal assemblages, and is seen in many cases as a natural internal response of the body to 'wear and tear'.[25-29] Skeletal involvement in DJD usually consists of the covarying processes of bone formation and bone destruction, including: (1) degeneration of articular cartilage with exposure of the bone surface, leading to progressive erosive porosity in the subchondral bone; (2) bone remodelling which produces stabilising focal nodules (osteophytes) of new bone formation at joint margins or ligament/tendon insertions (entheses); (3) subchondral cysts or lytic cavities in cartilage-depleted areas; and (4) eburnation produced by direct bone-on-bone abrasion, often leaving polished wear facets on the affected areas.[30-32]

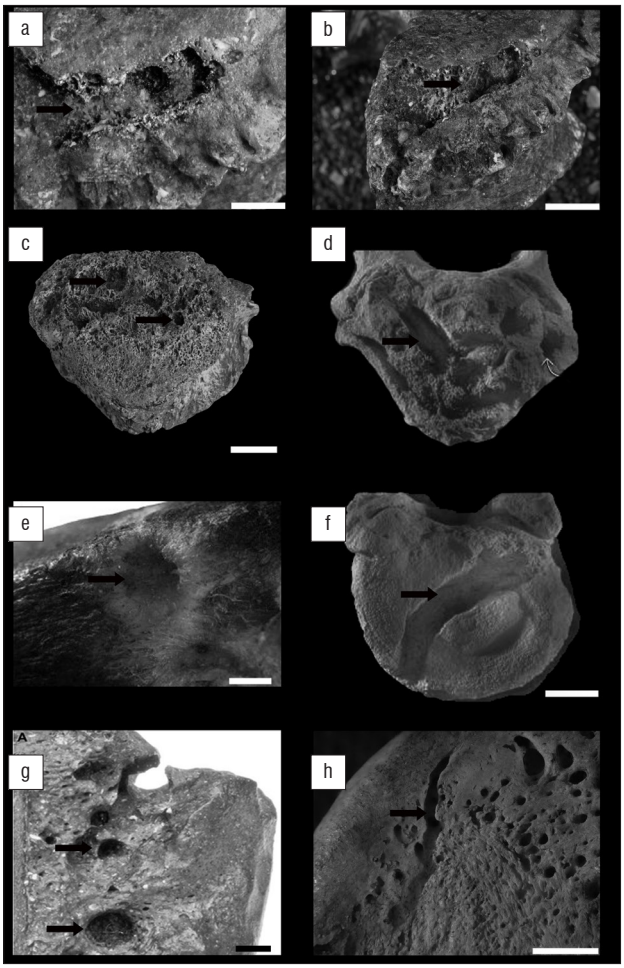

Scale = 10 mm

Figure 6: Insect traces excavated into the L5 vertebrae on StW 431 are indicated by arrows (a and b); (c) circular boring on a cercopithecus vertebra from Cooper's D; (d, f) furrows attributed to *Dermestes maculatus* from the Jurassic period[34]; (e) hole produced by the termite *Trinervitermes trinervoides*[21]; (g) holes produced by dermestids under experimental conditions[39]; and (h) furrow produced by the termite *T. trinervoides*[21].

DJD is a chronic disease process affecting joints, particularly large weight-bearing joints and is common in older individuals, but can occur in younger individuals either through a genetic mechanism or, more commonly, because of previous joint trauma.[30-32] Affected individuals may express reduced mobility, reduced flexibility and chronic pain. In modern clinical practice, DJD is equally prevalent in men and women in their mid-forties to mid-fifties, although the disease has been shown to affect much younger age groups in forensic, historical and archaeological populations in individuals with physically stressful lifestyles or occupations.[33]

The presence of osteophytosis and other associated degenerative traits elsewhere in the lumbar and sacral region of StW 431 has been proposed by Staps[18] as symptomatic of spondylosis deformans in this specimen, and our results are broadly consistent with this diagnosis, although the degenerative changes observed could also be attributed to normal age-related degenerative joint changes. However, the causal mechanism behind the destructive erosion seen on L4 and L5 has yet to be unequivocally addressed from a pathological perspective and here we attribute it to post-mortem alteration by insects.

Pirrone et al.[20] proposed that traces in bone produced by insects can be classified into one of eight general morphological categories. Subsequently, Parkinson[23] synonymised grooves and striae, as well as furrows and channels, thus reducing the number of general morphological categories to only six. These categories now are: pits, holes, chambers, tubes, furrows and grooves. The insect traces identified during the course

of this study can be classified into two of these morphological categories, namely furrows and holes. Holes (Figure 6c,e,g) are considered vertical excavations in bone which display a circular morphology in plan view and a bowl-shaped morphology in cross section. Holes are primarily found embedded in the outer cortical surface or as shallow excavations which penetrate the cortical surface and terminate in the trabecular bone.[20,23] Furrows (Figure 6d,f,h) are horizontal excavations which present as a meandering trail across the surface of a bone. Furrows are distinguishable from chambers as they lack the characteristic ellipsoidal morphology in plan view. Furrows are constructed to variable depths, and thus either record the presence or absence of vertical walls, and in cross section either display a bowl-shaped or shallow, rounded profile (see Parkinson[23(Fig.2)] and Pirrone et al.[20(Fig.3)] for a summary of plan and cross-sectional views of these common morphologies). Thus, the primary basis for identifying the insect traces on StW 431 is morphological similarity with traces widely attributed to insects in the literature (Figure 6).

The holes identified on StW 431 have a diameter range of 3–4 mm which are within the range of holes recently reported from Cooper's D (1–8.6 mm)[23] (Figure 6c) and those produced by the southern African termite *T. trinervoides* under experimental conditions (1.54–3.63 mm)[21] (Figure 6e). However, it is necessary to compare size data to data across all morphological categories because of the transitional nature of these traces. In that the morphological categories proposed by Pirrone et al.[20] and Parkinson[23] are by no means independent of one another – it is widely accepted that they represent transitional morphotypes which relate to the orientation of the excavation relative to the bone surface.[34-37] For example, if an insect excavates perpendicular to the bone surface and thus penetrates vertically in the bone, the trace would transition through a number of morphologies: initially it would be a pit, transition into a hole, and culminate in a tube. Alternatively, if the excavation is orientated parallel to the bone surface, the initial excavations would potentially take the form of a chamber and culminate in a meandering furrow. The transitional nature of these morphologies is an important consideration when one compares measurement data available in the literature. Thus the holes identified on StW 431 also fall within the range of tubes reported from Swartkrans (2–5 mm)[38], as well as those produced by *T. trinervoides* (3.41–4.2 mm)[21]. The holes on StW 431 fall outside of the range of tubes produced by *D. maculatus* (0.21–0.68 mm) and that of pits (1.5–2.5 mm) produced by dermestids[39] under experimental conditions (Figure 6g). Actualistic experimental results of bones exposed to *D. maculatus* suggests that dermestids rarely produce tubes or holes in bones, even after extended periods of exposure.[22] Lastly, the StW 431 holes also fall outside of the range of holes or tubes reported from Makapansgat which were attributed to dermestids by Kitching[40].

Morphological and metrological variables are key in the identification of insect traces on bone but they have little application in identifying a specific causal agent responsible for their creation.[23,35-37] Traces produced by insects are morphologically consistent despite geographical and/or temporal distribution; for example, furrows as described in this study from the Plio-Pleistocene are consistent with traces recently reported from the Jurassic of China.[36] Shallow circular holes have been reported throughout the Mesozoic and well into the Late Cenozoic; the most commonly inferred causal agent of traces during the Mesozoic are dermestids[34,41-44], but this shifts during the Cenozoic to termites being the most commonly inferred agent[21,24,45-47]. This temporal and geographical consistency of trace gross morphology relates to the similarity in the associated behaviour of insects whilst producing traces in bone. This unfortunate reality suggests that gross morphological categories should not be attributed to a specific agent, or should be attributed only with a high degree of caution. The trace that best illustrates this is a star-shaped pit mark.[24,45] Star-shaped pit marks have been widely reported from the Cenozoic of Africa and have been attributed to termites. Backwell and colleagues[21] sought to test this hypothesis and found that *T. trinervoides* do in fact produce star-shaped pit marks comparable to those reported in the literature.[21] Subsequent to this research, Parkinson[22] experimentally tested the impact of *D. maculatus* on bone under controlled conditions. The results of this later study suggest that dermestids also produce traces comparable to star-shaped pit marks attributed to termites. Thus inferring termites as a causal agent of star-shaped pit marks has lost a degree of credibility because various agents can produce similar morphological traces as a result of commonality in the behaviour attributed to the trace production; this then becomes an issue of equifinality which cannot be addressed directly in the palaeorecord.[22,48,49]

Despite the limitations of comparing gross morphological variables across both geologically and temporally disparate traces, one solution may be to describe traces more comprehensively within an ichnotaxonomic framework.[20,23,35] Such a description would require establishing to what degree the traces identified on bones are distinguishable from other trace taxa described in the literature, and whether the trace is substantially different to motivate the establishment of a new ichnotaxa. For example, on a gross morphological level many traces are described as chambers, but various authors have gone one step further and formally diagnosed ichnotaxa belonging to the ichnogenus *Cubiculum*. *Cubiculum ornatus* was described by Robert and colleagues[44] to include traces in bone which display a chamber-like morphology but which are characterised by the additional presence of gnawing marks/grooves. Subsequently, *Cubiculum levis* was described from Argentina as a chamber which is characterised by a bowl-shaped morphology in cross section.[35] However, in the past 18 months *Cubiculum* has expanded to include a further two taxa: *C. inornatus,* which is similar in morphology and size to *C. ornatus* but lacks the characteristic gnawing marks/grooves[36], and, most recently, *C. cooperi*, which has been described from Cooper's D in the Cradle of Humankind[23]. *C. cooperi* is distinguishable from all other *Cubiculum* taxa because of the absence of gnawing marks/grooves, as well as a uniquely consistent length to width ratio of 2:1.

This brief history of *Cubiculum* illustrates that at a gross morphological level, traces are broadly similar, but in fact the minor morphological variables between traces can be used as a basis for comparison and differentiation. The establishment of ichnotaxa in bone produced by insects also links morphological characteristics to the behavioural tendency of the trace makers. For example, *Cubiculum* ichnospecies are believed to represent the behaviour of producing pupation chambers in bone.[23,35-37,44] Interestingly, the majority of these authors who have described ichnotaxa in bone have avoided attributing a specific causal agent to the traces for various reasons.[23,35-37] These authors recognise that the trace is a reflection of behaviour, and that behaviour could easily be mimicked by numerous agents belonging to a diversity of insect groups. Simply put, more experimental research is required to begin to better understand and document the minor morphological variables between traces in bone produced by a substantially wider diversity of potential agents. Expanding research to address concerns of equifinality would be a fundamental step towards establishing practical criteria to enable causal agent determination/differentiation in the palaeorecord. In the case of the traces identified on StW 431, it is clear that these traces can be attributed to an insect based on gross morphological similarity to traces reported in the literature. High-resolution micro-CT provided clear evidence that the traces were produced post-mortem because there was no bone remodelling. However, because of the limited sample size and morphological and metrological similarity with traces produced by both termites and dermestids, we avoid attributing a specific agent. Lastly, the limited number of traces and lack of distinctive morphology do not warrant the diagnosis of an independent ichnotaxa, nor do the traces on StW 431 bear similarity to the existing ichnotaxa diagnosed in the region during the Plio-Pleistocene, namely *Munitusichnus pascens* and *C. cooperi.*[23] Lastly, drawing behavioural conclusions from a limited sample of traces which are not particularly well preserved would be futile in our opinion.

Conclusion

Our results have demonstrated that – with the exception of the presence of osteopathological lesions in the form of osteophytic lipping, demonstrating minor degenerative joint disease – the pre-mortem bone remodelling described by previous researchers[14] as evidence for infectious disease is shown here to have been caused by post-mortem processes. Our results suggest that the areas described to be as a result of infection are in fact post-mortem modifications made by insects or regions exhibiting degenerative joint disease. We draw these conclusions

based upon new imaging modalities applied to the fossil specimens. This is contrast to the methods used by D'Anastasio and colleagues[19] which comprised observation of surface morphology using light and scanning electron microscopy. In relation to the present study, in addition to macroscopic and microscopic methods, micro-CT was used in order to achieve a much higher resolution than in previous studies with full three-dimensional capacities to model and render previously identified lesions. No previous studies have used micro-CT to evaluate the surface bone of StW 431. Until now, insect traces have not been reported on StW 431.

Macroscopic and microscopic examinations are important prerequisites to determine the difference between post-mortem taphonomic and pre-mortem pathological processes as these two processes can look extremely similar, and are difficult to distinguish. This distinction can mean the difference between an interpretation of ante-mortem pathology or post-mortem pseudopathology. The modifications observed on StW 431 cannot be considered unique, as a similar pattern of bone modification is recorded on a fossil cercopithecoid vertebra from nearby Cooper's D (Figure 6c). Skeletal material at both sites (Cooper's D and Sterkfontein) experienced similar taphonomic sequences of events. Quadrupedal and bipedal primates apparently suffered from similar joint disease conditions[50], and after they died their bones appear to have been modified by an unknown insect.

This study is in agreement with previous pathological diagnoses of spinal DJD which affected StW 431, whilst shedding additional light on the complex series of post-mortem processes affecting the Sterkfontein site and its fossil assemblages. The co-occurrence of degenerative pathological processes *and* subsequent insect modifications of the same regions – the former being an ante-mortem in-vivo response and the latter a post-mortem or post-fossilisation modification – presents an interesting taphonomic case that may not be specific to StW 431, with a cercopithecoid vertebra from Cooper's D showing a similar taphonomic sequence of events. We suggest that it is only with a combination of traditional morphoscopic analyses of external gross morphology, coupled with non-invasive high-resolution tomographic methods (i.e. micro-CT, nano-CT or synchrotron tomography), that diagnoses can be rationalised. This comparative approach has been successfully demonstrated elsewhere in the South African fossil record, with the identification of the earliest evidence for neoplastic disease in the hominin record,[51,52] which would have been impossible using conventional diagnostic methods. Such caution is further supported by Mays[53] who suggests that, in future, secure diagnosis of infective disease processes in bone should primarily be undertaken using biomolecular means. Ancient bacterial DNA may, of course, not survive in such deep time scales, lending greater emphasis to the use of comparative non-invasive methods.[51,52]

Acknowledgements

We acknowledge the assistance and help of the following people in the production of this research: Bonita de Klerk, Wilma Lawrence and Jennifer Randolph-Quinney, and the Department of Geology (Wits). We thank the Evolutionary Studies Institute Fossil Access Advisory Panel for permission to study the StW 431 skeleton and comparative fossil specimens. The research was funded by grants to L.R.B. by the National Geographic Society, the National Research Foundation of South Africa, the South African Centre of Excellence in Palaeosciences, and the Lyda Hill Foundation. Additional direct support for E.J.O. was received from the National Research Foundation of South Africa and the South African Centre of Excellence in Palaeosciences. Direct research support for P.S.R-Q. was provided by the School of Forensic and Applied Sciences, University of Central Lancashire, UK.

Authors' contributions

E.J.O., L.R.B. and P.S.R-Q. wrote the original draft of the manuscript, incorporating additional information and data on Stw 431 from A.H.P., B.Z. and L.R.B., with additional palaeopathological commentary from H.B. K.J. undertook the micro-CT scanning of the hominin specimen and primary reconstruction. E.J.O. and P.S.R-Q. undertook secondary reconstruction from orthoslice and three-dimensional volume data; all authors contributed equally to analysis and editing.

References

1. Toussaint M, Macho GA, Tobias PV, Partridge TC, Hughes AR. The third partial skeleton of a late Pliocene hominin (Stw 431) from Sterkfontein, South Africa. S Afr J Sci. 2003;99:215–223.
2. Clarke RJ. Early Acheulean with *Homo habilis* at Sterkfontein. In: Tobias PV, editor. Hominid evolution: Past, present, and future. New York: Alan R. Liss Inc; 1985. p. 287–298.
3. Clarke RJ. On some new interpretations of Sterkfontein stratigraphy. S Afr J Sci. 1994;90:211–214.
4. Clarke RJ. The hominid species of Sterkfontein through time. Am J Phys Anthropol. 2002;suppl 34:54.
5. Wilkinson MJ. Lower-lying and possibly older fossiliferous deposits at Sterkfontein. In: Tobias PV, editor. Hominid evolution: Past, present, and future. New York: Alan R. Liss Inc; 1985. p. 165–170.
6. Brain CK. Cultural and taphonomic comparisons of hominids from Swartkrans and Sterkfontein. In: Delson E, editor. Ancestors: The hard evidence. New York: Alan R. Liss Inc; 1985. p. 72–75.
7. Stratford D, Grab S, Pickering TR. The stratigraphy and formation history of fossil- and artefact-bearing sediments in the Milner Hall, Sterkfontein Cave, South Africa: New interpretations and implications for palaeoanthropology and archaeology. J Afr Earth Sci. 2014;96:155–167. http://dx.doi.org/10.1016/j.jafrearsci.2014.04.002
8. Granger DE, Gibbon RJ, Kuman K, Clarke RJ, Bruxelles L, Caffee MW. New cosmogenic burial ages for Sterkfontein Member 2 *Australopithecus* and Member 5 Oldowan. Nature. 2015;522(7554):85–88. http://dx.doi.org/10.1038/nature14268
9. Clarke R. On the unrealistic 'revised age estimates' for Sterkfontein. S Afr J Sci. 2002;98(9–10):415–419.
10. Vrba ES. Early hominids in southern Africa: Updated observations on chronological and ecological background. In: Tobias PV, editor. Hominid evolution: Past, present, and future. New York: Alan R. Liss Inc; 1985. p. 195–200.
11. Delson E. Chronology of South African australopith site units. In: Grine FE, editor. Evolutionary history of the robust australopithecines. New York: Aldine de Gruyter; 1988. p. 317–325.
12. McKee JK, Thackeray JF, Berger LR. Faunal assemblage seriation of southern African Pliocene and Pleistocene fossil deposits. Am J Phys Anthropol. 1995;96(3):235–250. http://dx.doi.org/10.1002/ajpa.1330960303
13. Partridge T. Dating of the Sterkfontein hominids: Progress and possibilities. Trans Roy Soc S Afr. 2005;60(2):107–109. http://dx.doi.org/10.1080/00359190509520486
14. Schwarcz HP, Grün R, Tobias PV. ESR dating studies of the australopithecine site of Sterkfontein, South Africa. J Hum Evol. 1994;26(3):175–181. http://dx.doi.org/10.1006/jhev.1994.1010
15. Pickering R, Kramers JD. Re-appraisal of the stratigraphy and determination of new U-Pb dates for the Sterkfontein hominin site, South Africa. J Hum Evol. 2010;59(1):70–86. http://dx.doi.org/10.1016/j.jhevol.2010.03.014
16. McHenry HM, Berger LR. Body proportions in *Australopithecus afarensis* and *A. africanus* and the origin of the genus *Homo*. J Hum Evol. 1998;35:1–22. http://dx.doi.org/10.1006/jhev.1997.0197
17. Tobias PV. 21st Annual report of PARU and its precursors. Johannesburg: Department of Anatomy, University of the Witwatersrand; 1987.
18. Staps D. The first documented occurrence of spondylosis deformans in an early hominin. Am J Phys Anthropol. 2002;suppl 34:146.
19. D'Anastasio M, Zipfel B, Moggi-Cecchi J, Stanyon R, Capasso L. Possible brucellosis in an early hominin skeleton from Sterkfontein, South Africa. PLoS One. 2009;4(7), Art. e6439, 5 pages. http://dx.doi.org/10.1371/journal.pone.0006439
20. Pirrone CA, Buatois LA, Bromley RG. Ichnotaxobases for bioerosion trace fossils in bones. J Paleontol. 2014;88(1):195–203. http://dx.doi.org/10.1666/11-058
21. Backwell LR, Parkinson AH, Roberts EM, d'Errico F, Huchet JB. Criteria for identifying bone modification by termites in the fossil record. Palaeogeogr Palaeoclimatol Palaeoecol. 2012;337–338:72–87. http://dx.doi.org/10.1016/j.palaeo.2012.03.032

22. Parkinson AH. *Dermestes maculatus* and *Periplaneta americana*: Bone modification criteria and establishing their potential as climatic indicators [MSc dissertation]. Johannesburg: University of the Witwatersrand; 2013.

23. Parkinson AH. Traces of insect activity at Cooper's D fossil site (Cradle of Humankind, South Africa). Ichnos. 2016;23(3–4):322–339. http://dx.doi.org/10.1080/10420940.2016.1202685

24. Kaiser TM. Proposed fossil insect modification to fossil mammalian bone from Plio-Pleistocene hominid-bearing deposits of Laetoli (Northern Tanzania). Ann Entomol Soc Am. 2000;93(4):693–700. http://dx.doi.org/10.1603/0013-8746(2000)093[0693:PFIMTF]2.0.CO;2

25. Agarwall SC, Grynpas MD. Measuring and interpreting age-related loss of vertebral bone mineral density in a medieval population. Am J Phys Anthropol. 2009;139(2):244–252. http://dx.doi.org/10.1002/ajpa.20977

26. Roberts C, Cox M. Health and disease in Britain from prehistory to the present day. Stroud: Sutton Publishing; 2003.

27. Roberts CA, Manchester K. The archaeology of disease. 2nd ed. Bradford: Bradford University Press; 1996.

28. Aufderheide AC, Rodríguez-Martin C. The Cambridge encylopedia of human paleopathology. Cambridge: Cambridge University Press; 1998.

29. Ortner DJ, Putschar WGJ. Identification of pathological conditions in human skeletal remains. Smithsonian contributions to anthropology 28. Washington DC: Smithsonian Institution Press; 1981.

30. Resnick D. Orthopedics: Diagnosis of bone and joint disorders: Volume 4. 3rd ed. Philadelphia, PA: W.B. Saunders; 1994.

31. Resnick D. Diagnosis of bone and joint disorders. 3rd ed. Philadelphia, PA: W.B. Saunders Company; 1995.

32. Resnick D, Niwayama G. Diagnosis of bone and joint disorders. 1st ed. Philadelphia, PA: Saunders; 1988.

33. Rogers J. The palaeopathology of joint disease. In: Cox M, Mays S, editors. Human osteology in archaeology and forensic science. Cambridge: Cambridge University Press; 2000. p. 163–182.

34. Britt BB, Scheetz RD, Dangerfield A. A suite of dermestid beetle traces on dinosaur bone from the Upper Jurassic Morrison Formation, Wyoming, USA. Ichnos. 2008;15(2):59–71. http://dx.doi.org/10.1080/10420940701193284

35. Pirrone CA, Buatois LA, González Riga B. A new ichnospecies of *Cubiculum* from Upper Cretaceous dinosaur bones in Western Argentina. Ichnos. 2014;21(4):251–260. http://dx.doi.org/10.1080/10420940.2014.958225

36. Xing L, Parkinson AH, Ran H, Pirrone CA, Roberts EM, Zhang J, et al. The earliest fossil evidence of bone boring by terrestrial invertebrates, examples from China and South Africa. Hist Biol. 2015:1–10. http://dx.doi.org/10.1080/08912963.2015.1111884

37. Neto VDP, Parkinson AH, Pretto FA, Soares MB, Schwanke C, Schultz CL, et al. Oldest evidence of osteophagic behavior by insects from the Triassic of Brazil. Palaeogeogr Palaeoclimatol Palaeoecol. 2016;453:30–41. http://dx.doi.org/10.1016/j.palaeo.2016.03.026

38. Newman R. The incidence of damage marks on Swartkrans fossil bones from the 1979–1986 excavations. Swartkrans: A cave's chronicle of early man: Transvaal Museum Monograph. Pretoria: Transvaal Museum; 1993. p. 217–228.

39. Holden AR, Harris JM, Timm RM. Paleoecological and taphonomic implications of insect-damaged pleistocene vertebrate remains from Rancho La Brea, southern California. PLoS One. 2013;8(7):e67119. http://dx.doi.org/10.1371/journal.pone.0067119

40. Kitching J. On some fossil arthropoda from the limeworks Makapansgat, Potgietersrus. Palaeontol Afr. 1980;23(6):63–68.

41. Bader KS, Hasiotis ST, Martin LD. Application of forensic science techniques to trace fossils on dinosaur bones from a quarry in the Upper Jurassic Morrison Formation, Northeastern Wyoming. PALAIOS. 2009;24(3):140–158. http://dx.doi.org/10.2110/palo.2008.p08-058r

42. Dangerfield A, Britt B, Scheetz R, Pickard M. Jurassic dinosaurs and insects: The paleoecological role of termites as carrion feeders. Paper presented at: Salt Lake City Annual Meeting; 2005 October 16–19; Salt Lake City, UT, USA.

43. Paik IS. Bone chip-filled burrows associated with bored dinosaur bone in floodplain paleosols of the Cretaceous Hasandong Formation, Korea. Palaeogeogr Palaeoclimatol Palaeoecol. 2000;157(3):213–225. http://dx.doi.org/10.1016/S0031-0182(99)00166-2

44. Roberts EM, Rogers RR, Foreman BZ. Continental insect borings in dinosaur bone: Examples from the late Cretaceous of Madagascar and Utah. J Paleo. 2007;81(1):201–208. http://dx.doi.org/10.1666/0022-3360(2007)81[201:CIBIDB]2.0.CO;2

45. Fejfar O, Kaiser TM. Insect bone-modifications and palaeoecology of Oligocene mammal-bearing sites in the Doupov Mountains, Northwestern Bohemia. Palaeontol Electron. 2005;8(1), 11 pages. Available from: http://palaeo-electronica.org/2005_1/fejfar8/fejfar8.pdf

46. Hill A, Leakey M, Harris J. Damage to some fossil bones from Laetoli. Laetoli: A Pliocene site in Northern Tanzania. Oxford: Clarendon Press; 1987. p. 543–545.

47. Pomi LH, Tonni EP. Termite traces on bones from the Late Pleistocene of Argentina. Ichnos. 2011;18(3):166–171. http://dx.doi.org/10.1080/10420940.2011.601374

48. Lyman RL. The concept of equifinality in taphonomy. J Taphonomy. 2004;2(1):15–26.

49. Bristow J, Simms Z, Randolph-Quinney PS. Taphonomy. In: Ferguson E, editor. Forensic anthropology 2000–2010. Boca Raton, FL: CRC Press; 2011. p. 279–318. http://dx.doi.org/10.1201/b10727-10

50. Jurmain R. Degenerative joint disease in African great apes: An evolutionary perspective. J Hum Evol. 2000;39(2):185–203. http://dx.doi.org/10.1006/jhev.2000.0413

51. Odes EJ, Randolph-Quinney PS, Steyn M, Throckmorton Z, Smilg JS, Zipfel B, et al. Earliest hominin cancer: 1.7-million-year-old osteosarcoma from Swartkrans Cave, South Africa. S Afr J Sci. 2016;112(7–8), Art. #2015-0471, 5 pages. http://dx.doi.org/10.17159/sajs.2016/20150471

52. Randolph-Quinney PS, Williams SA, Steyn M, Meyer MR, Smilg JS, Churchill SE, et al. Osteogenic tumour in *Australopithecus sediba*: Earliest hominin evidence for neoplastic disease. S Afr J Sci. 2016;112(7–8), Art. #2015-0470, 7 pages. http://dx.doi.org/10.17159/sajs.2016/20150470

53. Mays SA. Lysis at the anterior vertebral body margin: Evidence for brucellar spondylitis? Int J Osteoarchaeol. 2007;17:107–118. http://dx.doi.org/10.1002/oa.903

Copyright of South African Journal of Science is the property of Academy of Science of South Africa and its content may not be copied or emailed to multiple sites or posted to a listserv without the copyright holder's express written permission. However, users may print, download, or email articles for individual use.

CHAPTER 7: A Case of Benign Osteogenic Tumour: In *Homo naledi*: Evidence for Peripheral Osteoma in the U.W. 101-1142 Mandible*

**Published: International Journal of Paleopathology*

Odes, E.J., Delezene, L.K., Randolph-Quinney, P.S., Smilg, J.S., Augustine, T.N., Jakata, K. and Berger, L.R., 2017. A case of benign osteogenic tumour in *Homo naledi*: Evidence for peripheral osteoma in the U.W. 101-1142 mandible **(***Article in press*).

International Journal of Paleopathology xxx (xxxx) xxx–xxx

Contents lists available at ScienceDirect

International Journal of Paleopathology

journal homepage: www.elsevier.com/locate/ijpp

A case of benign osteogenic tumour in *Homo naledi*: Evidence for peripheral osteoma in the U.W. 101-1142 mandible

Edward J. Odes[a,b,*], Lucas K. Delezene[b,c], Patrick S. Randolph-Quinney[a,b,d,*], Jacqueline S. Smilg[e,f], Tanya N. Augustine[a], Kudakwashe Jakata[b], Lee R. Berger[b]

[a] School of Anatomical Sciences, Faculty of Health Sciences, University of the Witwatersrand Medical School, Parktown, Johannesburg, 2193, South Africa
[b] Evolutionary Studies Institute, University of the Witwatersrand, Johannesburg, South Africa
[c] Department of Anthropology, University of Arkansas, Fayetteville, United States
[d] School of Forensic and Applied Sciences, University of Central Lancashire, Preston, PR1 2HE, UK
[e] School of Radiation Sciences, University of the Witwatersrand, Johannesburg, South Africa
[f] Department of Radiology, Charlotte Maxeke Academic Hospital, Johannesburg, South Africa

ARTICLE INFO

Keywords:
Rising star
Dinaledi chamber
Hominin
Palaeopathology
Neoplasia micro-computed tomography

ABSTRACT

The reported incidence of neoplasia in the extinct hominin record is rare. We describe here the first palaeopathological analysis of an osteogenic lesion in the extinct hominin *Homo naledi* from Dinaledi Cave (Rising Star), South Africa. The lesion presented as an irregular bony growth, found on the right lingual surface of the body of the adult mandible U.W. 101-1142. The growth was macroscopically evaluated and internally imaged using micro-focus x-ray computed tomography (μCT). A detailed description and differential diagnosis were undertaken using gross and micromorphology, and we conclude that the most probable diagnosis is peripheral osteoma – a benign osteogenic neoplasia. These tumours are cryptic in clinical expression, though they may present localised discomfort and swelling. It has been suggested that muscle traction may play a role in the development and expression of these tumours. The impact of this lesion on the individual affected is unknown. This study adds to the growing corpus of palaeopathological data from the South African fossil record, which suggests that the incidence of neoplastic disease in deep prehistory was more prevalent than traditionally accepted. The study also highlights the utility of micro-computed tomography in assisting accurate diagnoses of ancient pathologies.

1. Introduction

We present a detailed case study and palaeopathological analysis of a mandibular exostosis present on the lingual aspect of the U.W. 101-1142 fossil specimen, initially identified by Laird and colleagues (2016) as a mandibular osteoma. This was recovered from the Dinaledi Chamber, Rising Star Cave, Cradle of Humankind, South Africa. Rising Star Cave is located within the dolomitic karst landscape of the Cradle of Humankind World Heritage Site, some 50 km outside of Johannesburg, South Africa (Fig. 1). Excavations at the site have, to date, yielded more than 1550 identifiable fossil elements (Berger et al., 2015; Randolph-Quinney, 2015). The fossils were derived from at least 15 individuals, a total likely to represent a small fraction of the fossils remaining in the chamber and awaiting excavation (Fig. 2). This discovery is the largest single fossil hominin assemblage found on the African continent to date (Berger et al., 2015; Randolph-Quinney, 2015). The context of the Naledi deposition in the cave has been described by Dirks and colleagues (Dirks et al., 2015, 2016), and the formation of the assemblage is interpreted as being due to deliberate body disposal by conspecifics (Dirks et al., 2015, 2016), a process known as funerary caching (after after Pettitt, 2011; Berger et al., 2017; Randolph-Quinney, 2015). Fossils from the Dinaledi Chamber have been attributed to the taxon *Homo naledi* (Berger et al., 2015; Laird et al., 2016). While highly primitive in terms of cranial capacity and body size, this taxon presents a mixture of primitive and derived characters that convincingly argue for inclusion in the *Homo* genus (Berger et al., 2015; Dembo et al., 2016; Laird et al., 2016; Schroeder et al., 2015).

The Dinaledi Chamber fossils have been shown to be late Middle Pleistocene in age. Based on optically stimulated luminescence (OSL) dating of the cave sediments, U-Th and palaeomagnetic dating of flowstones, and U-series and electron spin resonance (ESR) dating of

* Corresponding authors at: School of Anatomical Sciences, Faculty of Health Sciences, University of the Witwatersrand Medical School, Parktown 2193, Johannesburg, South Africa (E.J. Odes); School of Forensic and Applied Sciences, University of Central Lancashire, Preston, PR1 2HE, UK (P.S. Randolph-Quinney).
E-mail addresses: eddieodes@gmail.com (E.J. Odes), prandolph-quinney@uclan.ac.uk (P.S. Randolph-Quinney).

http://dx.doi.org/10.1016/j.ijpp.2017.05.003
Received 28 December 2016; Received in revised form 8 May 2017; Accepted 8 May 2017
1879-9817/ © 2017 Elsevier Inc. All rights reserved.

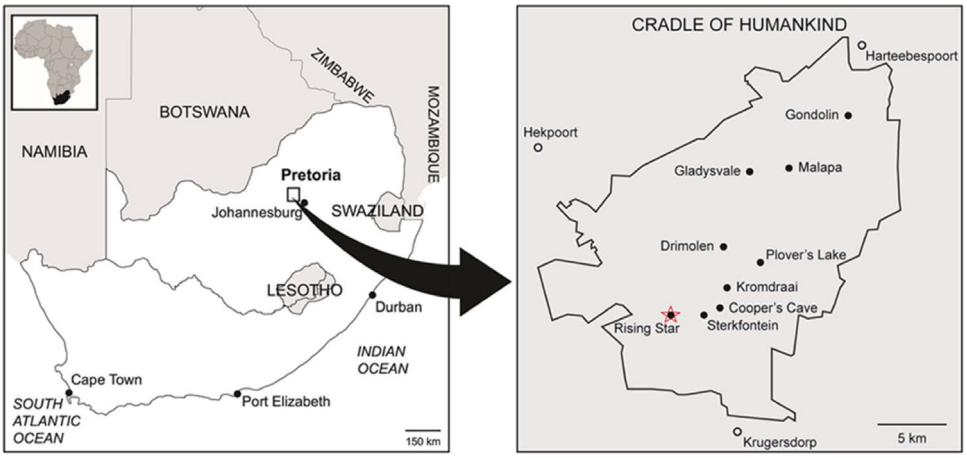

Fig. 1. Location of the Rising Star Cave system within the Cradle of Humankind, South Africa.



Fig. 2. Layout photograph of some of the Dinaledi Chamber fossils. The figure includes all of the material incorporated into the diagnosis of *Homo naledi*, and includes the holotype specimen, paratypes and referred material list in Berger and colleagues (2015). The fossil shown make up 737 partial or complete anatomical elements, many of which consist of several refitted specimens. Specimens not identified to element, such as non-diagnostic long bone or cranial fragments, are not shown. The 'skeleton' layout in the centre of the photo is a composite of elements that represent multiple individuals. The view is foreshortened and the table on which the bones are arranged is 120-cm wide for scale. Image, courtesy of John Hawks and taken with permission from Berger et al., 2015.

teeth, the skeletal remains from the Dinaledi Chamber were deposited between 236 ka and 335 ka (Dirks et al., 2017). This Middle Pleistocene date should not be viewed as representing first or last appearance of *Homo naledi*, whilst some researchers have suggested that the species may be of Lower Pleistocene origin or older, based on analyses of cranial morphology (Dembo et al., 2016; Thackeray, 2015). A second chamber within the Rising Star cave system has recently yielded further remains of *Homo naledi* (Hawks et al., 2017). This has been named the Lesedi Chamber, and has yielded the remains of at least three individuals which fall within the range of morphological variation exhibited by the Dinaledi Chamber fossils; for the moment the Lesedi Chamber fossils remain undated.

2. Materials

Specimen U.W. 101-1142 is an adult right mandibular fragment comprising the midpoint and proximal aspect of the body extending to the mandibular angle, including the RM_2 and RM_3, and a portion of the distal (inferior) ramus, excluding the coronoid, condyle processes and anterior mandibular body. This partial mandible has been attributed to *Homo naledi*; a detailed description of the morphology and metrics of the specimen can be found in Laird and colleagues (Laird et al., 2016). The specimen was recovered in a partially fragmented state, and reconstructed by Peter Schmidt. The largest fragment of U.W. 101-1142 preserves a damaged right corpus, RM_2, RM_3, and a portion of the right ramus. To this fragment, a piece of the gonial region and a small portion of the ramus have been refit (Fig. 3a and c). An isolated RM_1, U.W. 101-1304, fits into the preserved portion of the M_1 alveolus (Fig. 3f). Supporting their allocation to a single biological individual, the interproximal contact facets of U.W. 101-1304 and the U.W. 101–1142 M_2, match in size and shape. Other isolated teeth from the U.W. 101 assemblage may represent this individual as well, but their associations are less certain.

As judged by dental eruption and attrition, U.W. 101-1142/1304 is an adult. Further, though lacking dentine exposure, the M_3 cusp tips are blunted by wear, which corresponds to Smith's (1984) wear stage 2. The M_2 has tiny pits of dentine exposed over each of its buccal cusps; though, much of the occlusal fissure pattern remains (stage 3). The U.W. 101–1304 M_1 is worn and uncoalesced pits of dentin are exposed over each of the five cusps (stage 4) (Fig. 3c). Antemortem enamel chipping is also evident on all three molars. The allocation of U.W. 101-1142/1304 to *H. naledi* is supported by its dental morphology. For example, the molars have an $M_1 < M_2 < M_3$ size gradient, the hypoconulid on all molars is relatively large, all molars lack supernumerary cusps (Fig. 3f), the protostylid is present on M_2 and M_3 as a faint crest restricted to the mesiolingual corner of the crown, and a three-dimensional geometric morphometric analysis of the enamel-dentine junction shows that the U.W. 101–1142 M_2 falls into a unique region of phenotype space with the rest of the U.W. 101 molar teeth.

3. Methods

The specimen was evaluated macroscopically, and the morphology was compared to all other mandibular specimens of *Homo naledi* recovered to date. Initial external macro-photographic images were taken using a Canon 70D 20MP DSLR, with a 60 mm Canon EF f2.8 macro lens and ring-flash. Following macro-photography, images of the internal structure of the specimen were obtained using micro-focus X-ray computed tomography (μCt) at the Evolutionary Studies Institute of the University of the Witwatersrand. Scanning of the bone fragment

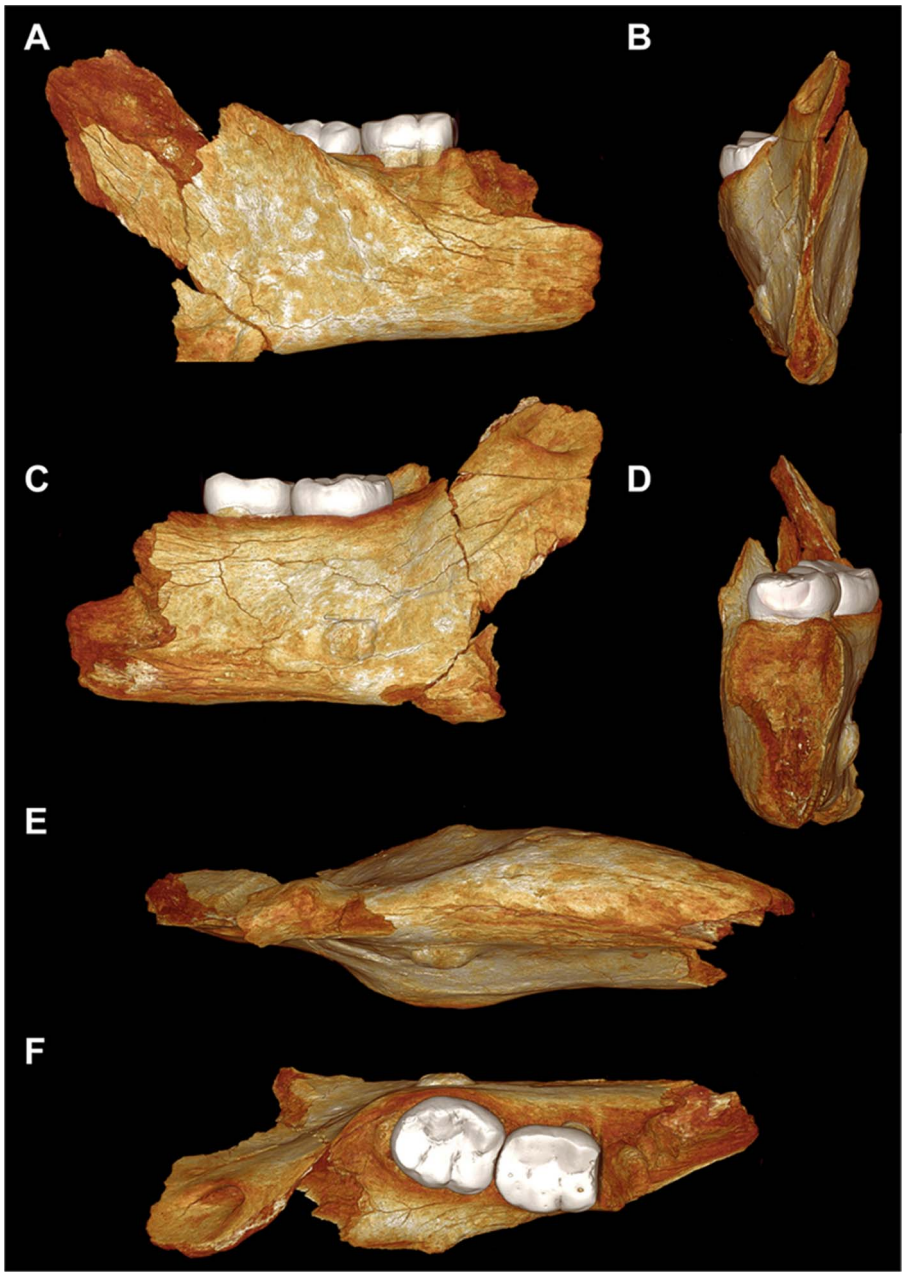

Fig. 3. External morphology of the U.W. 102-1142 mandible. (A) buccal (B) posterior (C) lingual (D) anterior (E) inferior and (F) occlusal views. All image derived from 3D surface rendering of micro-tomographic volume data.

was carried out by K.J. and L.K.D. using a Nikon XTH 225/320 LC µCT system. This was done using a confocal beam of X-rays produced using a potential difference of 60 kV. The source to specimen to detector distances were chosen to keep the fossil in the field of view and resulted in a resolution of 16 µm. Volume reconstruction was undertaken by K.J. using CT-Pro 3D, with the image volume output as a tiff stack. Subsequent imaging, with 2D orthoslice generation and 3D volume rendering was carried out by P.S.R-Q, L.K.D. and E.J.O. using Avizo Amira 5.4.5 (see Fig. 3 panel). Analysis of internal structure and external morphology was undertaken by E.J.O., P.S.R-Q., L.K.D. and J.S.S.

4. Results

The lingual surface of the body of the U.W. 101-1142 corpus displays an irregular bony growth on the corpus, noted in the formal description of the specimen by Laird and colleagues (Laird et al., 2016). This is externally visible as an irregularly-shaped bony mass attached directly to the right lingual cortex, directly below RM_3. The exostosis measures approximately 10 mm in diameter and is located 20 mm below the mylohyoid line, and 20 mm cranially from the inferior margin of the corpus. Macroscopically, the external surface of the exostosis appears relatively smooth and sub-rectangular to ovoid in shape, with rounded edges in the inferolateral quadrant and with a somewhat planar (flattened) surface along its superior edge. To the antero-superior aspect of the lesion can be seen a short vascular canal (Fig. 3c), which travels mesially, penetrating parallel to, and then diving obliquely into the cortex of the corpus (Fig. 4a), before connecting with the medulla (Fig. 4b).

Cross-sections (2D orthoslices) derived from micro-tomographic imaging (Fig. 6a–h – see Fig. 5 for guide to slice placement) indicate an irregularly shaped hemispherical, bi-lobular mass sessile dome-shaped, 1 cm diameter, sub rectangular to oval application to cortex with smooth convex surface, indicating slow if any enlargement in



Fig. 4. Detailed image of vascular canal observed superior to the bony mass. This canal does not occur within the range of normal variation of *Homo naledi* and may be co-responsive with the formation of the lesion. The canal travels disto-mesially, penetrating parallel to, and then diving obliquely into the cortex of the corpus (surface rendered view 4a), before connecting with the medulla (orthoslice 4b).



Fig. 5. Anatomical location of orthoslices A to H displayed in Fig. 6.

premortem time, which is integrated almost completely into the lingual cortex. The mass is dominated by a large primary lobe, with a smaller lobule occurring in the disto-inferior quadrant. The lesion is complete, with no post-mortem loss, except for a slight discontinuity caused by post-mortem cracking of the cortex in the inferolateral portion; this cracking can be seen penetrating the junction between the mass and the cortex in Figs. 6a–d.

The internal morphology of the mass is highly informative (Fig. 6a–h). The central region of the lesion exhibits a stratified convex lamella (radio-opaque laminations) in cross section (Fig. 6c and e) as in the common button osteoma which is most pronounced in the anterior half of the exostosis. Overall, the cortical bone and the margin of the lesion are contiguous to the extent that it is difficult to distinguish the cortex from the lesion, other than the slightly sclerotic and irregular internal morphology of the bone at the margin. There is no evidence of invasion by the mass sub-cortically into the medulla of the corpus, and instead the mass presents a lingual expansion of the cortex as seen in Fig. 6e–g. As noted above, a well-defined vascular canal is also present on the external cortex of the corpus, just antero-superiorly to the lesion (Fig. 6a and b). Whilst this does not penetrate the lesion directly, the walls of the canal share a similar pattern of radiopacity as seen in the outer edge of the lesion, and the presence of the canal may well be predicated on the presence and growth of the lesion. Such a vascular feature is not noted or identified in any other comparable mandibular specimen of *Homo naledi* (Laird *personal communication,* November 2016) and was not observed in non-pathological modern human mandibles in the Raymond A. Dart Collection (University of the Witwatersrand, sampled by E.J.O) and skeletal collections housed at the University of Central Lancashire (sampled by P.S.R-Q.).

4.1. Differential diagnosis

Diagnosis was undertaken using both palaeopathological and clinical diagnostic criteria (Ortner, 2003; Resnick, 1995; Roberts and Cox, 2003; Rothschild and Martin, 1993; Vigorita, 2008). The presence of reorganized sclerotic bone indicates an ante-mortem process, and the lesion cannot therefore be attributed to taphonomic, diagenetic, or pathology-mimicking effects or processes (Bloem and Kroon, 1993). The accumulated evidence for both osteogenic and osteosclerotic processes indicates that the pathological process was chronic, with no evidence of aggressive bone remodelling, cortical resorption, osteolysis, and sub-periosteal reactive processes (Aufderheide and Rodríguez-Martin, 1998; Bloem and Kroon, 1993). With specific regard to the specimen, the lesion offers no evidence of a healed bone fracture or any bone deformity, as a consequence of traumatic insult. Traumatic avulsion at a remote muscle insertion site with subsequent remodelling is possible (given the proximity of the lesion to the medial pterygoid muscle) though we consider this unlikely given the lobulated morphology of the lesion, and the lack of sub-periosteal reactive processes or osseous reaction within the surviving region of the medial pterygoid enthosite. There is no evidence of perilesional or endosteal inflammation of the mandibular bone cortex or associated osteolytic lesions on the jaw, ruling out any form of systemic infection or inflammatory diseases such as condensing osteitis, periodontal, periapical, or endodontal lesions, including mandibular osteomyelitis and Garre's sclerosing osteomyelitis (Nakano et al., 2008). Osteosarcoma is not comprised

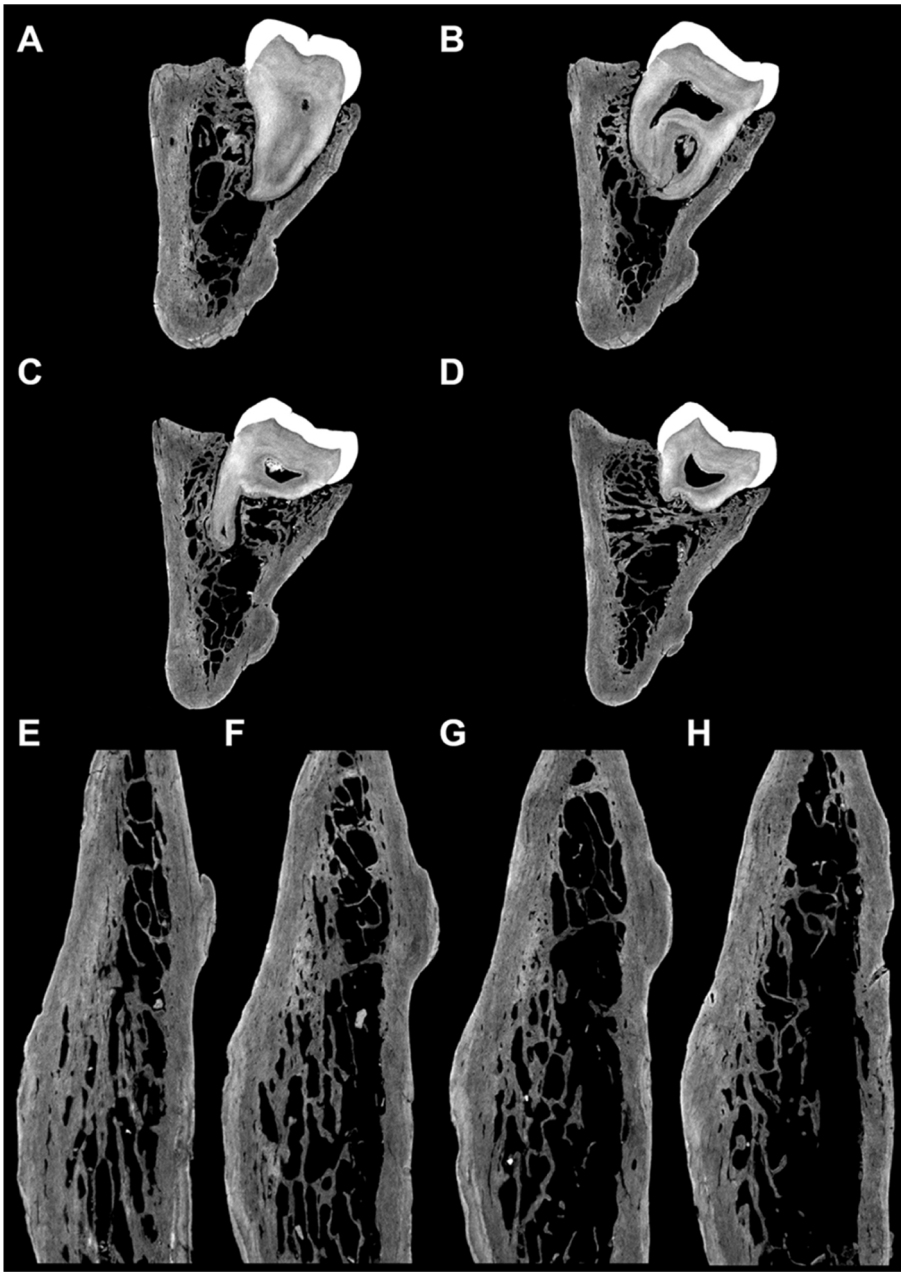

Fig. 6. Coronal (A to D) and transverse (E to H) micro-tomographic orthoslices through the U.W. 101-1142 mandible. See Fig. 5 for anatomical location of each slice.

of lamellar bone and the small size of the lesion is unrealistic and thus rules out osteosarcoma as a possible diagnosis (Mensforth et al., 2000; Strouhal et al., 1997; Suzuki, 1987; Unni and Dahlin, 1989).

The morphology and location of the lesion suggests that several bone-forming pathologies should be included in a differential diagnosis for this condition and include: osteochondroma, osteoid osteoma, mandibular osteoma, and mandibular torus (exostosis). Table 1 lists and details the diagnostic criteria

As there is no visible evidence of delineation with the bone cortex which shows total integration (Ragsdale, 1993), a generally smooth texture of the lesion under study indicates a strong possibility of mandibular osteoma (Baykul et al., 2003; Capasso, 1997; Durão et al., 2012; Fallahi Motlagh et al., 2015; Federspiel, 1924; Georgalas et al., 2011; Green and Boweran, 1974; Johann et al., 2005; MacLennan and Brown, 1974; Premužić et al., 2013; Roy, 2008; Sayan et al., 2002; Souza et al., 2015; Steinberg and George, 1989; Yadav et al., 2015) with secondary diagnosis of mandibular exostosis. Based on the observed gross pathological, micro-morphological, and location criteria, the two most likely diagnoses are mandibular osteoma (Baykul et al., 2003; Capasso, 1997; de Souza et al., 2015; Durão et al., 2012; Fallahi Motlagh et al., 2015; Federspiel, 1924; Georgalas et al., 2011; Green and Boweran, 1974; Johann et al., 2005; MacLennan and Brown, 1974; Premužić et al., 2013; Roy, 2008; Sayan et al., 2002; Steinberg and George, 1989; Yadav et al., 2015) or congenital mandibular torus (exostosis). Exostoses are hyperplastic bone protuberances occurring in mandibular and maxillary bone (Allan and Reid, 1967; Katz et al., 1993; Revington, 1984; Sanders and McKelvy, 1977; Smitha and Smitha, 2015). They can be trabecular or cortical in nature and mostly comprise mature bone. Generally, they are bilateral lesions, and we are unable to ascertain whether this is bilateral expression due to the absence of the left mandibular antimere. However, internal morphology, the location of the lesion (occurring below the mylohyoid line), and its relationship to the alveolus is inconsistent with such an exostosis. We consider it most likely that this specimen presents peripheral mandibular osteoma, and thus a condition of benign osteogenic neoplasia.

Table 1
Differential diagnostic options for the U.W. 101-1142 mandible.

Osteochondroma (mandibular)	A common benign bone tumour, also known as osteocartilaginous exostosis. It can be interpreted as a developmental irregularity; commonly asymptomatic, and if singular has a low malignancy potential. They are usually slow growing, and presents as a radiopaque mass with well-defined margins. Radiographic images have indicated exophytic growths measuring 3–4 cm. Osteocartilaginous exostosis (osteochondromas) are generated from a cartilage cap by enchondral ossification and present with a bony stalk-type protrusion; a smooth cortical plate develops with mature bone. The cartilage cap will stop its growth and is completely absorbed by the enchondral process. It is rare in the in the maxillofacial region due to intra-membranous growth of these bones, and tends to occur wherever bones grow through endochondral ossification; when seen in the mandible it most commonly affects the condylar and coronoid processes (Sanders and McKelvy 1977; Andrade et al., 2014).
Osteoid osteoma	A benign slow-growing bone-forming tumour. It usually originates in spongy bone but can also involve the cortex. Usually less than 2 cm in diameter. Presents characteristically with a lucent nidus framed with a thin fibrovascular rim surrounded by sclerotic tissues of host bone. The nidus may exhibit a central mineralised region. Radiologically seen as round or oval lesions less than 2 cm in diameter, with a 1–2 mm peripheral radiolucent zone in radiographs. They are usually cortical lesions, and can manifest anywhere in the bone. Up to 80% of cases are found in the long bones of the lower extremities. Other sites include the hands, feet, pelvis, vertebrae, and phalanges. Less than 1% of cases occur in the jaws (Infante-Cossio et al., 2016; Singh and Solomon, 2012; Greene et al., 1968; de Souza Dias and Frost 1974; Zulian et al., 1987; Radcliffe et al., 1998; Tochihara et al., 2001; Liu et al., 2002; Jones et al., 2006; An et al., 2013; Adouly et al., 2015; Da Costa et al., 2015).
Osteoma (of the jaw)	Types of mandibular osteoma include periosteal (peripheral), endosteal (central) or extra-skeletal (coming from soft tissue). Several different causes such as neoplastic, developmental and reactive have been inferred as possible etiologic factors for mandibular osteoma. These peripheral osteomas have been argued are not neoplastic because they are slow growing. Other researchers have reported them as a reactive condition caused by trauma, because peripheral osteomas typically present on the inferior border of the buccal aspect of the mandible which is an area susceptible to traumatic insult. Peripheral osteomas are usually located in close proximity to muscle attachments, suggesting muscle traction may be involved in their development (Roy 2008). Although common in crania, they are less common in the jaws, though they occur more frequently in the mandible than the maxilla. The lingual region of the mandibular body is one of the most frequent sites for this osteoma (Richards et al., 1986; Sayan et al., 2002). Radiographically they can present as a single, well defined, pedunculated (or not), oval or round mushroom-shaped radiopaque mass displaying a density resembling bone (Kaplan et al., 1994). A histologic similarity of "button osteomas" of calvarium and osteomas of mandible has been established. The frequency of button osteoma is similar in modern (37.6%) and archaeological (41.1%) populations, in blacks, whites, males, and females, and correlates with age. It is rare in nonhuman primates. The frequency of large osteomas (0.5-1.0 cm) was similar in young and old age groups. The demographic characteristics of button osteoma, mainly its high frequency among ancient and modern populations, its independence of sex and race, its scarcity in other primates, and the fact that its macro- and microstructure are indicative of an hamartoma, and not a neoplastic osteoma or post-traumatic exostosis. This suggests an evolutionary history to this condition (Eshed et al., 2002). Alternative locations for the presentation of osteomas include external auditory canal, orbits, temporal bone and pterygoid process (Soni and Bhargava 2014; Federspiel 1924; Green and Boweran 1974; MacLennan and Brown 1974; Steinberg and George 1989; Capasso 1997; Sayan et al., 2002; Baykul et al., 2003; Johann et al., 2005; Roy 2008; Georgalas et al., 2011; Durão et al., 2012; Premužić et al., 2013; de Souza et al., 2015; Fallahi Motlagh et al., 2015; Yadav et al., 2015). The World Health Organization (WHO) in its recent classification of diseases reports osteoma as a benign Aussies neoplasm, and specifically distinct from exostoses and tori, which are hamartoma, has been followed by several investigators (Agrawal et al., 2015). The published literature is contradictory on frequency of the condition. The lingual region of the mandible is considered one of the most common loci for mandibular osteoma (Richards et al., 1986; Sayan et al., 2002). According to Khandelwal et al. (2016), involvement of the mandibular lingual cortex is rare.
Tori or mandibular exostoses	Tori are amongst the most frequent benign jaw lesions (Platzek et al., 2014). Tori are outgrowths of bone projecting from the surface of the mandible or maxilla (Choi et al., 2012; Cortes et al., 2014; Igarashi 2016). They consist mostly of compact bone, and are homogenously mineralised. Mandibular tori typically form from the inner surface of the mandible, and are found near the premolars and distal to the molars. They are commonly found below the alveolus and above the mylohyoid muscle attachment (Sneck et al., 2009; Hassan et al., 2012). Some researchers however, disagree and note that torus mandibularis is also known from the lingual surface of the mandible and often located medial to molar roots (Ihunwo and Phukubye 2006). They are not commonly exhibited before 10 years old (Shah et al., 1992). They are known to occur bilaterally, with solitary tori more commonly observed than multiple occurrences and are known to present earlier in life (Axelsson and Hedegard, 1981). They are not commonly exhibited before 10 years old (Shah et al., 1992). Several studies have reported incidences of tori and exostoses, increase with age, with higher prevalence observed in the over 18 year old age group (Auškalnis et al., 2015). Tori are more commonly known to occur during mid-life (García-García et al., 2010). In both male and female, incidence of the two types of tori was the highest in the 35–65 year old group (Haugen, 1992). Some consist of marrow space and display trabeculations. In a clinical case study, patients presenting with torus mandibularis showed a much greater prevalence with characteristics such as a square-shaped jaw, sharp angular morphology ($P = .001$) and a normal mandibular cortex ($P = .03$). The subjects displaying an absence of torus mandibularis were more highly likely to have rounded mandibles with less sharp angular morphology and mandibular cortical erosion. The study concluded that parafunctional activity may be a possible cause of torus mandibularis by applying stress in the locus where the tori typically develop. This may infer that squarely-shaped mandibles, which are more prone to stress concentration, may be associated with a greater incidence of torus mandibularis (Cortes et al., 2014). This may have an interesting implication for this pathology in hominin mandibles in future studies.

5. Discussion

The hominin individual associated with U.W. 101-1142, most likely was affected by a peripheral osteoma, a benign osteogenic neoplasm. A neoplasm ('new-growth' or tumour) is defined as a mass of localised tissue growth, the cellular proliferation of which is no longer subject to the effects of normal growth-regulating mechanisms (Binder et al., 2014; Capasso, 2005; Retief and Cilliers, 2011; Weinberg, 1983). A neoplasm may be benign or malignant; in the case of malignancy they are often referred to as cancer (Aufderheide and Rodríguez-Martin, 1998; Ortner, 2003). The preserved signatures of neoplasms of any kind are rare in archaeological populations, and are extremely rare in the fossil record (Capasso, 2005), though there is building evidence for such conditions in the fossil record as recent publications attest. The earliest confirmed evidence of neoplastic disease, an osteoid osteoma, comes from a 300-million-year-old fossil fish (*Phanerosteon mirabile*) from the Devonian Period (Capasso, 2005; Ortner, 2003; Rothschild et al., 1999; Rothschild et al., 2003; Rothschild and Martin, 1993). The condition is also the first observed neoplasia in the hominin fossil record, with a case of vertebral osteoid osteoma from the MH1 skeleton of *Australopithecus sediba* from Malapa, South Africa, dated to 1.98 Ma (Randolph-Quinney et al., 2016). Osteoid osteoma also has been recognised in 24,000-year-old European mammoths (Leshchinskiy, 2012). The earliest evidence for malignancy (cancer) in the hominin record comes from Swartkrans, South Africa, with a case of parosteal osteosarcoma dated to c. 1.7 mya (Odes et al., 2016). Other reported cases of neoplasia (both benign and malignant) are rare in the fossil record, with the majority of cases in the human lineage dating from the Holocene (Capasso, 2005; Ortner, 2003; Rothschild and Martin, 1993).

Osteoma of the cranium, particularly of the vault, is widely reported from the palaeopathological record of the Holocene, with (less-frequent) mandibular cases noted (Capasso, 2005; Ortner, 2003; Rothschild and Martin, 1993). In non-human primates it is worth noting that benign osteomas have been observed in both gorilla

subspecies but have not been seen in either chimpanzees or orangutans (Lovell, 1990). Because the pathogenesis of osteoma is not fully resolved, some researchers regard it as a neoplasm whilst others deem it to be the consequence of a traumatic insult (Bloem and Kroon, 1993; Capasso, 1997; MacLennan and Brown, 1974; Roy, 2008). Both hamartomatous and neoplastic factors have been advocated, but no definite conclusion has been reported. Developmental, neoplastic and reactive causes have been attributed as possible etiologic factors (Capasso, 1997), though it is unlikely that peripheral osteomas are a developmental anomaly, as most cases occur in adults (MacLennan and Brown, 1974; Roy, 2008). The oncogenetic basis of this condition is for the present unresolved. Other benign osteogenic tumours display a clear genetic basis to expression. In osteoid osteoma for instance, cytogenetic chromosomal studies indicate that there is some degree of genetic basis to the condition. This includes duplications and deletions at 22q13.159, the locus of which reflects genes that play a role directly in osteogenesis (PDGF-B and ATF-4), and aberrant expression of transcription factors Runx2 and Osterix, both of which are master regulators of osteoblastic lineage differentiation (Baruffi et al., 2001; Selvarajah et al., 2010; Weinberg, 1983).

With regards to the U.W. 101-1142 specimen, clinical manifestations and effects on the individual may have been slight. Large tori have been known to present with small amounts of localised discomfort (Gil Tutor, 1999). From modern clinical studies it is known that osteoma is a slow growing lesion, which is often cryptic, though it may have caused other symptoms such as pain and localised swelling. The proximity of the lesion to the insertion of the medial pterygoid muscle, and the associated vascular involvement and sequestration of the cortex suggests the potential impact on normal function of the medial pterygoid, which may have had consequences for elevation of the jaw on the right side, as well as consequential discomfort of the right temporo-mandibular joint. This is in keeping with the classification of the condition. Many peripheral osteomas are in close proximity to muscle attachments (i.e. masseter, medial pterygoid, temporalis), and researchers have considered it possible that muscle traction may play a role in the development and expression of these tumours (Al-Yahya et al., 2015; Arzul et al., 2012; Baykul et al., 2003; Kaplan et al., 2008; MacLennan and Brown, 1974; Ogbureke et al., 2007; Roy, 2008).

This study illuminates the importance of the challenge of understanding ancient hominin neoplastic disease and other diseases, constrained by limited sample sizes versus the more abundant samples of modern clinical disease restricted studies of tumours in human specimens of skeletal remains, making definitive diagnoses difficult (Aufderheide and Rodríguez-Martin,1998; Capasso, 2005; Ortner, 2003). However, neoplastic disease has been observed by a number of past studies of benign and malignant bone tumours arising from the fossil record that extend into deep ancient time (Capasso, 1997, 2005; David and Zimmerman, 2010; Davies and Lineweaver, 2011; Odes et al., 2016; Randolph-Quinney et al., 2016; Retief and Cilliers, 2011; Roberts and Cox, 2003; Rothschild et al., 1999; Rothschild et al., 2003; Rothschild and Martin, 1993). The paucity of definitive neoplastic evidence in the archaeological and fossil record may well be put down to a number of factors such as preservational or sample size bias, poor imaging methods, or deficient analyses. Computed tomography, and micro-computed tomography in particular, has been widely suggested as the imaging method of choice when diagnosing bone neoplasms, where radiolucency and sclerosis are most often evidenced, and is especially useful when experiencing difficulty with dense bone material (Odes et al., 2016). Modern imaging techniques (such as micro-computed tomography or phase-contrast synchrotron tomography), and the use of carefully selected clinical skeletal comparatives have become exceedingly important tools in assisting with obtaining accurate diagnoses of ancient pathologies.

Authors' contributions

P.S.R.Q. and L.R.B. coordinated the research and incorporated case notes and observational data on U.W. 101-1142 that were provided by E.J.O, L.K.D. and J.S.S. J.K. and L.K.D. undertook the micro-tomographic scanning of the specimen, and primary reconstruction. Post-reconstruction rendering and slicing was carried out by P.S.R-Q, L.K.D. and E.J.O. Analysis of micro-tomographic results was undertaken by E.J.O., P.S.R-Q., L.K.D. and J.S.S., T.N.A. provided discussion of oncogenetics. All authors contributed equally to data acquisition and analysis and to editing.

Acknowledgements

We would like to acknowledge the assistance and help of the following people in the production of this research: Bonita de Klerk, Wilma Lawrence, and Jennifer Randolph-Quinney. We gratefully acknowledge the help of Ashley Kruger in the production of the final images used in this paper, and Myra Laird for constructive comments on normal mandibular morphology and variation in *Homo naledi*. We would like to thank John Hawks for permission to use Fig. 2. Finally we are extremely grateful to the anonymous reviewers for their insightful comments on the initial submission, and whose input has greatly improved this paper. The research was funded by grants to L.R.B. by the National Geographic Society, the National Research Foundation of South Africa and the South African Centre for Excellence in PalaeoSciences, and the Lyda Hill Foundation. Additional direct support for E.J.O. was received from the National Research Foundation of South Africa and the South African Centre for Excellence in PalaeoSciences. Direct research support for P.S.R-Q., was provided by the School of Forensic and Applied Sciences, University of Central Lancashire. Support for L.K.D. was also provided by Connor Family Faculty Fellowship and from the Office of Research and Development at the University of Arkansas.

References

Adouly, T., Oubahmane, T., Adnane, C., Rouadi, S., Abada, R., Roubal, M., Mahtar, M., 2015. Bilateral osteoid osteoma of the mandible: an unusual case report. Int. J. Pediatr. Otorhinol. 10 (3), 56–58.

Agrawal, R., Agrawal, S., Bhargava, S., Motlani, M., Agrawal, R., 2015. An uncommon case of solitary peripheral osteoma in the mandible. Case Rep. Dent. 15 (Article ID 319738, 4 pages http://dx.doi.org/10.1155/2015/319738).

Al-Yahya, S.N.S.H., Wan Hamizan, A.K., Zainuddin, N., Arshad, A.I., Ismail, F., 2015. Mastoid osteoma: report of a rare case. EJENTAS 16 (2), 189–191.

Allan, I.M.B., Reid, W.H., 1967. Unilateral exostosis of the coronoid process of the mandible: a report of two cases. Br. J. Oral Surg. 5 (1), 20–24.

An, S.-Y., Shin, H.-I., Choi, K.-S., Park, J.-W., Kim, Y.-G., Benavides, E., Kim, J.-W., An, C.-H., 2013. Unusual osteoid osteoma of the mandible: report of case and review of the literature. Oral Surg. Oral Med. Oral Pathol. Oral Radiol. Endod. 116 (2), e134–e140.

Andrade, N.N., Gandhewar, T.M., Kapoor, P., Thomas, R., 2014. Osteochondroma of the mandibular condyle—report of an atypical case and the importance of computed tomography. J. Oral. Biol. Craniofac. Res. 4 (3), 208–213.

Arzul, L., Vincent, C., Mercier, J.M., 2012. Ostéome mandibulaire post-traumatique. Rev. Stomatol. Chir. Maxillofac. 113 (3), 169–172.

Auškalnis, A., Bernhardt, O., Putnienė, E., Šidlauskas, A., Andriuškevičiūtė, I., Basevičienė, N., 2015. Oral bony outgrowths: prevalence and genetic factor influence. Study of twins. Medicina (Mex) 51 (4), 228–232.

Aufderheide, A.C., Rodríguez-Martin, C., 1998. The Cambridge Encylopedia of Human Paleopathology. Cambridge University Press, Cambridge.

Axelsson, G., Hedegard, B., 1981. Torus mandibularis among Icelanders. Am. J. Phys. Anthropol. 54 (3), 383–389.

Baruffi, M., Volpon, J., Neto, J., Casartelli, C., 2001. Osteoid osteomas with chromosome alterations involving 22q. Cancer Genet. Cytogenet. 124, 127–131.

Baykul, T., Heybeli, N., Oyar, O., Doğru, H., 2003. Multiple huge osteomas of the mandible causing disfigurement related with Gardner's syndrome: case report. Auris Nasus Larynx 30 (4), 447–451.

Berger, L.R., Hawks, J., de Ruiter, D.J., Churchill, S.E., Schmid, P., Delezene, L.K., Kivell, T.L., Garvin, H.M., Williams, S.A., DeSilva, J.M., Skinner, M.M., Musiba, C.M., Cameron, N., Holliday, T.W., Harcourt-Smith, W., Ackermann, R.R., Bastir, M., Bogin, B., Bolter, D., Brophy, J.K., Cofran, Z.D., Congdon, K.A., Deane, A.S., Dembo, M., Drapeau, M., Elliott, M.C., Feuerriegel, E.M., Garcia-Martinez, D., Green, D.J., Gurtov, A., Irish, J.D., Kruger, A., Laird, M.F., Marchi, D., Meyer, M.R., Nalla, S., Negash, E.W., Orr, C.M., Radovcic, D., Schroeder, L., Scott, J.E., Throckmorton, Z.J.,

Tocheri, M.W., VanSickle, C., Walker, C.S., Wei, P., Zipfel, B., 2015. Homo Naledi, A New Species of the Genus Homo from the Dinaledi Chamber. eLife, South Africa, pp. e09560.
Berger, L.R., Hawks, J., Dirks, P.H.G.M., Elliott, M., Roberts, E.M., 2017. Homo naledi and Pleistocene hominin evolution in subequatorial Africa. eLife 6, e24234.
Binder, M., Roberts, C., Antoine, D., Cartwright, C., 2014. On the antiquity of cancer: evidence for metastatic carcinoma in a young man from ancient nubia (c. 1200BC). PLoS One 9, e90924.
Bloem, J.L., Kroon, H.M., 1993. Osseous lesions. Radiol. Clin. N. Am. 31 (2), 261–278.
Capasso, L., 1997. Osteoma: palaeopathology and phylogeny. Int. J. Osteoarchaeol. 7 (6), 615–620.
Capasso, L.L., 2005. Antiquity of cancer. Int. J. Cancer 113, 2–13.
Choi, Y., Park, H., Lee, J.-S., Park, J.-C., Kim, C.-S., Choi, S.-H., Cho, K.-S., Chai, J.-K., Jung, U.-W., 2012. Prevalence and anatomic topography of mandibular tori: computed tomographic analysis. J. Oral Maxillofac. Surg. 70 (6), 1286–1291.
Cortes, A.R.G., Jin, Z., Morrison, M.D., Arita, E.S., Song, J., Tamimi, F., 2014. Mandibular tori are associated with mechanical stress and mandibular shape. J. Oral Maxillofac. Surg. 72 (11), 2115–2125.
Da Costa, D.N.B., Almeida Júnior, P., De Melo, M.D.E.F.B., Da Fonte, J.B.M., Valois, R.B.V., De Albuquerque Júnior, R.L.C., 2015. Small osteoblastoma or osteoid osteoma of the mandible? Report of an atypical case. Oral Surg. Oral Med. Oral Pathol. Oral Radiol. Endod. 120 (2), e76.
David, R.A., Zimmerman, M.R., 2010. Cancer: an old disease, a new disease or something in between? Nat. Rev. 10, 728–733.
Davies, P.C.W., Lineweaver, C.H., 2011. Cancer tumors as Metazoa 1.0: tapping genes of ancestors. Phys. Biol. 8, a015001.
de Souza Dias, L., Frost, H.M., 1974. Osteoid osteoma – osteoblastoma. Cancer 33, 1075–1081.
de Souza, P.D., Leonhardt, F.D., Ahumada, N.G., Abrahão, M., Cervantes, O., 2015. Giant osteoma of the mandible. Braz. J. Otorhinolaryngol. 81 (1), 107–108.
Dembo, M., Radovčić, D., Garvin, H.M., Laird, M.F., Schroeder, L., Scott, J.E., Brophy, J., Ackermann, R.R., Musiba, C.M., de Ruiter, D.J., Mooers, A., Collard, M., 2016. The evolutionary relationships and age of Homo naledi: an assessment using dated Bayesian phylogenetic methods. J. Hum. Evol. 97, 17–26.
Dirks, P.H.G.M., Berger, L.R., Roberts, E.M., Kramers, J.D., Hawks, J., Randolph-Quinney, P.S., Elliott, M., Musiba, C.M., Churchill, S.E., de Ruiter, D.J., Schmid, P., Backwell, L.R., Belyanin, G.A., Boshoff, P., Hunter, K.L., Feuerriegel, E.M., Gurtov, A., Harrison, J.D., Hunter, R., Kruger, A., Morris, H., Makhubela, T.V., Peixotto, B., Tucker, S., 2015. Geological and taphonomic context for the new hominin species Homo naledi from the Dinaledi Chamber, South Africa. eLife 4, e09561.
Dirks, P.H.G.M., Berger, L.R., Hawks, J., Randolph-Quinney, P.S., Backwell, L.R., Roberts, E.M., 2016. Comment on deliberate body disposal by hominins in the dinaledi chamber, cradle of humankind, South Africa? J. Hum. Evol. 96, 149–153.
Dirks, P.H.G.M., Roberts, E.M., Hilbert-Wolf, H., Kramers, J.D., Hawks, J., Dosseto, A., Duval, M., Elliott, M., Evans, M., Grün, R., Hellstrom, J., Herries, A.I.R., Joannes-Boyau, R., Makhubela, T.V., Placzek, C.J., Robbins, J., Spandler, C., Wiersma, J., Woodhead, J., Berger, L.R., 2017. The age of Homo naledi and associated sediments in the Rising Star Cave, South Africa. eLife 6, e24231.
Durão, A.R., Chilvarquer, I., Hayek, J.E., Provenzano, M., Kendall, M.R., 2012. Osteoma of the zygomatic arch and mandible: report of two cases. Rev. Port. Estomatol. Cir. Maxilofac. 53 (2), 103–107.
Eshed, V., Latimer, B., Greenwald, C.M., Jellema, L.M., Rothschild, B.M., Wish-Baratz, S., Hershkovitz, I., 2002. Button osteoma: its etiology and pathophysiology. Am. J. Phys. Anthropol. 118 (3), 217–230.
Fallahi Motlagh, M., Janbaz, Y., Abaszade, A., 2015. Huge peripheral osteoma of the mandibular condyle: a case report. J. Oral. Maxillofac. Surg. Med. Pathol. 27 (6), 808–811.
Federspiel, M.N., 1924. A clinical report reganding a case of osteoma involving the maxilla. Int. J. Orthod. Oral. Surg. Radiogr. 10 (10), 654–655.
García-García, A.S., Martínez-González, J.M., Gómez-Font, R., Soto-Rivadeneira, Á., Oviedo-Roldán, L., 2010. Current status of the torus palatinus and torus mandibularis. Med. Oral Patol. Oral Cir. Bucal 15 (2), e353–e360.
Georgalas, C., Goudakos, J., Fokkens, W.J., 2011. Osteoma of the skull base and sinuses. Otolaryngol. Clin. N. Am. 44 (4), 875–890.
Gil Tutor, E., 1999. Torus mandibularis. Apropos a case. An. Otorrinolaringol. Ibero. Am. 26 (5), 457–460 (Spanish. PubMed PMID: 10568301).
Green, A.E., Boweran, J.E., 1974. An osteoma of the mandible. Br. J. Oral Maxillofac. Surg. 12 (2), 225–228.
Greene Jr., G.W., Natiella, J.R., Spring Jr., P.N., 1968. Osteoid osteoma of the jaws: report of a case. Oral Surg. Oral Med. Oral Pathol. Oral Radiol. Endod. 26 (3), 342–351.
Hassan, K.S., Alagl, A.S., Abdel-Hady, A., 2012. Torus mandibularis bone chips combined with platelet rich plasma gel for treatment of intrabony osseous defects: clinical and radiographic evaluation. Int. J. Oral Maxillofac. Surg. 41 (12), 1519–1526.
Haugen, L.K., 1992. Palatine and mandibular tori: a morphologic study in the current Norwegian population. Acta Odontol. Scand. 50 (2), 65–77.
Hawks, J., Elliott, M., Schmid, P., Churchill, S.E., d. Ruiter, D.J., Roberts, E.M., Hilbert-Wolf, H., Garvin, H.M., Williams, S.A., Delezene, L.K., Feuerriegel, E.M., Randolph-Quinney, P., Kivell, T.L., Laird, M.F., Tawane, G., DeSilva, J.M., Bailey, S.E., Brophy, J.K., Meyer, M.R., Skinner, M.M., Tocheri, M.W., VanSickle, C., Walker, C.S., Campbell, T.L., Kuhn, B., Kruger, A., Tucker, S., Gurtov, A., Hlophe, N., Hunter, R., Morris, H., Peixotto, B., Ramalepa, M., v. Rooyen, D., Tsikoane, M., Boshoff, P., Dirks, P.H.G.M., Berger, L.R., 2017. New fossil remains of Homo naledi from the Lesedi Chamber, South Africa. eLife 6, e24232.
Igarashi, Y., 2016. Frequency of mandibular tori in prehistoric and historic Japanese island populations. Quatern Int. 405, 87–100 (Part B).
Ihunwo, A.O., Phukubye, P., 2006. The frequency and anatomical features of torus mandibularis in a Black South African population. HOMO 57 (4), 253–262.
Infante-Cossio, P., Restoy-Lozano, A., Espin-Galvez, F., Gonzalez-Perez, L.-M., 2016. Mandibular osteoid osteoma. J. Emerg. Med pii: S0736-4679(16)30878-2. 10.1016/j.jemermed.2016.10.003.
Johann, A.C.B.R., Freitas, J.B.D., Aguiar, M.C.F.D., Araújo, N.S.D., Mesquita, R.A., 2005. Peripheral osteoma of the mandible: case report and review of the literature. J. Craniomaxillofac. Surg. 33 (4), 276–281.
Jones, A.C., Prihoda, T.J., Kacher, J.E., Odingo, N.A., Freedman, P.D., 2006. Osteoblastoma of the maxilla and mandible: a report of 24 cases, review of the literature, and discussion of its relationship to osteoid osteoma of the jaws. Oral Surg. Oral Med. Oral Pathol. Oral Radiol. Endod. 102 (5), 639–650.
Kaplan, I., Calderon, S., Buchner, A., 1994. Peripheral osteoma of the mandible: a study of 10 new cases and analysis of the literature. J. Oral Maxillofac. Surg. 52 (5), 467–470.
Kaplan, I., Nicolaou, Z., Hatuel, D., Calderon, S., 2008. Solitary central osteoma of the jaws: a diagnostic dilemma. Oral Surg. Oral Med. Oral Pathol. Oral Radiol. Endod. 106 (3), e22–e29.
Katz, J.O., Theisen, F.C., Mosby, E.L., 1993. Bony exostosis of the mandibular condyle. Oral Surg. Oral Med. Oral Pathol. Oral Radiol. Endod. 75 (6), 783–785.
Khandelwal, P., Dhupar, V., Akkara, F., 2016. Unusually large peripheral osteoma of the mandible–a rare case report. J. Clin. Diagn. Res. 10 (11), ZD11–ZD12. http://dx.doi.org/10.7860/JCDR/2016/21399.8807.
Laird, M.F., Schroeder, L., Garvin, H.M., Scott, J.E., Dembo, M., Radovčić, D., Musiba, C.M., Ackermann, R.R., Schmid, P., Hawks, J., Berger, L.R., de Ruiter, D.J., 2016. The skull of Homo naledi. J. Hum. Evol pii: S0047-2484(16)30136-1. 10.1016/j.jhevol.2016.09.014.
Leshchinskiy, S.V., 2012. Paleoecological investigation of mammoth remains from the Kraków Spadzista Street (B) site. Quatern Int. 276, 155–169.
Liu, C.J., Chang, K.W., Chang, K.M., Cheng, C.Y., 2002. A variant of osteoid osteoma of the mandible: report of a case. J. Oral Maxillofac. Surg. 60 (2), 219–221.
Lovell, N.C., 1990. Patterns of Injury and Illness in Great Apes. SIP, Washington, DC.
MacLennan, W.D., Brown, R.D., 1974. Osteoma of the mandible. Br. J. Oral Maxillofac. Surg. 12 (2), 219–224.
Mensforth, R.P., Way-Mosakowski, J., Zeman, K.E., 2000. A rare case of periosteal osteosarcoma of the mandible from the late archaic ward site (McL-11), McLean County, Kentucky. Am. J. Phys. Anthropol 22–227.
Nakano, H., Miki, T., Aota, K., Sumi, T., Matsumoto, K., Yura, Y., 2008. Garré's osteomyelitis of the mandible caused by an infected wisdom tooth. Oral Sci. Int. 5 (2), 150–154.
Odes, E.J., Randolph-Quinney, P.S., Steyn, M., Throckmorton, Z., Smilg, J.S., Zipfel, B., Augustine, T.N., de Beer, F., Hoffman, J.W., Franklin, R.D., Berger, L.R., 2016. Earliest cancer in the hominin record: 1. 7 milllion year old osteosarcoma from Swartkrans Cave, South Africa. S. Afr. J. Sci. 112 (7/8) (Art. #2015-0471.).
Ogbureke, K.U.E., Nashed, M.N., Ayoub, A.F., 2007. Huge peripheral osteoma of the mandible: a case report and review of the literature. Pathol. Res. Pract. 203 (3), 185–188.
Ortner, D.J., 2003. Tumors and tumor-like lesions of bone. Identification of Pathological Conditions in Human Skeletal Remains. D. J. Ortner, Amsterdam, AP, pp. 503–544.
Pettitt, P., 2011. The Palaeolithic Origins of Human Burial. Routledge, London.
Platzek, I., Schubert, M., Sieron, D., Laniado, M., 2014. Mandibular tori as an incidental finding in MRI. Acta Radiol. Open 3 (2) (2047981614522790).
Premužić, Z., Rajić Šikanjić, P., Mašić, B., 2013. Frontal sinus osteoma in a 16th century skeleton from Zagreb, Croatia. IJPP 3 (1), 54–58.
Radcliffe, S.N., Walsh, H.J., Carty, H., 1998. Osteoid osteoma: the difficult diagnosis. Eur. J. Radiol. 28 (1), 67–79.
Ragsdale, B.D., 1993. Morphologic analysis of skeletal lesions: correlation of imaging studies and pathologic findings. RAPL 6, 445–490.
Randolph-Quinney, P.S., Williams, S.A., Steyn, M., Meyer, M.R., Smilg, J.S., Churchill, S.E., Odes, E.J., Augustine, T., Taffreau, P., Berger, L.R., 2016. Osteogenic spinal tumor in Australopithecus sediba: earliest evidence for neoplasia in the human lineage. S. Afr. J. Sci. 112 (7/8) (Art. #2015-0470).
Randolph-Quinney, P.S., 2015. The mournful ape: conflating expression and meaning in the mortuary behaviour of Homo naledi. S. Afr. J. Sci. 111 (11/12) (Art. #a0131).
Resnick, D., 1995. Diagnosis of Bone and Joint Disorders. W.B. Saunders Company, Philadelphia, PA.
Retief, F.P., Cilliers, L., 2011. Breast cancer in antiquity. S. Afr. Med. J. 101 (8), 513–515.
Revington, P.J., 1984. 'Turret exostosis' of the coronoid process. Br. J. Oral Maxillofac. Surg. 22 (1), 37–41.
Richards, H.E., Strider, J.W., Short, S.G., Theisen, F.C., Larson, W.J., 1986. Large peripheral osteoma arising from the genial tubercle area. Oral Surg. Oral Med. Oral Pathol. Oral Radiol. Endod. 61 (3), 268–271.
Roberts, C., Cox, M., 2003. Health and Disease in Britain From Prehistory to the Present Day. Sutton Publishing, Stroud.
Rothschild, B.M., Martin, L.D., 1993. Paleopathology: Disease in the Fossil Record. CRC Press, Boca Raton, FL.
Rothschild, B.M., Witzke, B.J., Hershkovitz, I., 1999. Metastatic cancer in the Jurassic. Lancet 354, 398.
Rothschild, B.M., Tanke, D.H., Hebling, M., Martin, L.D., 2003. Epidemiologic study of tumors in dinosaurs. Sci. Nat. 90, 495–500.
Roy, I.D., 2008. Peripheral osteoma of mandible. Med. J. Armed Forces India 64 (4), 385–386.
Sanders, B., McKelvy, B., 1977. Osteochondromatous exostosis of the condyle. J. Am. Dent. Assoc. 95 (6), 1151–1153.
Sayan, N.B., Üçok, C., Karasu, H.A., Günhan, Ö., 2002. Peripheral osteoma of the oral and maxillofacial region: a study of 35 new cases. J. Oral Maxillofac. Surg. 60 (11), 1299–1301.
Schroeder, L., Scott, J.E., Garvin, H.M., Laird, M.F., Dembo, M., Radovčić, D., Berger,

ARTICLE IN PRESS

L.R., 2015. Skull diversity in the Homo lineage and the relative position of Homo naledi. J. Hum. Evol pii: S0047-2484(16)30136-1. 10.1016/j.jhevol.2016.09.014.
Selvarajah, S., Zielenska, M., Squire, J., Park, P., 2010. Genetic Aspects of Bone Tumors. Bone Cancer. D. Heymann, Elsevier, London, pp. 161–170.
Shah, D.S., Sanghavi, S.J., Chawda, J.D., Shah, R.M., 1992. Prevalence of torus palatinus and torus mandibularis in 1000 patients. Indian J. Dent. Res. 3 (4), 107–110.
A. Singh, M.C. Solomon. (2012). Osteoid osteoma of the mandible: a case report with review of the literature. JDS (in press) http://dx.doi.org/10.1016/j.jds.2012.10.002.
Smith, B.H., 1984. Patterns of molar wear in hunter–gatherers and agriculturalists. Am. J. Phys. Anthropol. 63 (1), 39–56 ().
Smitha, K., Smitha, G.P., 2015. Alveolar exostosis–revisited: a narrative review of the literature. Saudi J. Oral. Dent. Res. 6 (1), 67–72.
Sneck, M., Scott, G.R., Leeper, K.L., 2009. Mandibular torus in the Greenlandic Norse. Am. J. Phys. Anthropol 243–243.
Soni, S., Bhargava, A., 2014. Revisiting peripheral osteoma of the mandible with case series and review of literature. Indian J. Otolaryngol. Head Neck Surg. 66 (2), 212–218.
Steinberg, H., George, C., 1989. Fracture-associated osteogenic sarcoma and a mandibular osteoma in two goats. J. Comp. Pathol. 100 (4), 453–457.
Strouhal, E., Vyhnanek, L., Horackova, L., Benesova, L., Nemeckova, A., 1997. A case of osteosarcoma in a late medieval-early modern skull from Kyjov (Czech Republic). Int. J. Osteoarchaeol. 7, 82–90.
Suzuki, T., 1987. Paleopathological study on a case of osteosarcoma. Am. J. Phys. Anthropol. 74, 309–318.
Thackeray, J.F., 2015. Estimating the age and affinities of Homo naledi. S. Afr. J. Sci. 11 (11/12) (#a0124).
Tochihara, S., Sato, T., Yamamoto, H., Asada, K., Ishibashi, K., 2001. Osteoid osteoma in mandibular condyle. Int. J. Oral Maxillofac. Surg. 30 (5), 455–457.
Unni, K., Dahlin, D., 1989. Osteosarcoma: pathology and classification. Semin. Roentgenol. 24 (3), 143–152.
Vigorita, V.J., 2008. Orthopaedic Pathology. Lippincott Williams & Wilkins, Philadelphia.
Weinberg, R., 1983. Oncogenes and the molecular biology of cancer. J. Cell Biol. 97, 1661–1662.
Yadav, S., Malik, S., Mittal, H.C., Puri, P., Duhan, A., 2015. Gigantic osteoma of the mandible—an unusual sequelae to dental caries. J. Oral. Maxillofac. Surg. Med. Pathol. 27 (4), 592–594.
Zulian, M.A., Kirk Vincent, S., Robert Hiatt, W., 1987. Osteoid osteoma of the mandibular ramus. J. Oral Maxillofac. Surg. 45 (8), 712–714.

Chapter 8

Discussion

8.1 Summary of findings from this study

5.1.1 Survey of pathology occurring in the fossil hominins

A comprehensive survey of pathology occurring in the fossil hominin remains of seven South African Plio-Pleistocene fossil assemblages was performed during this study (see Appendix A). The site assemblages included Sterkfontein, Swartkrans, Kromdraai, Taung, Makapansgat, Coopers and Malapa, as well as selected material from Dinaledi (Rising Star). In Appendix (A), the results of the survey are tabulated into six different categories: fossil site; specimen number; pathology/disease type; anatomical element; genus and species; and references. The findings from the survey of pathology of each site assemblage answer three important questions:

a) How many specimens have pathology?
b) What was the most common pathology?
c) Which sites have the most specimens with pathology?

Sterkfontein

Following a complete examination of the Sterkfontein Cave hominin fossil assemblage, 17 specimens were considered to have signs of pathology out of a sample of 784 available specimens (2.16%). The pathology observed can be divided into two broad categories: dental (15 specimens) and post-cranial (2 specimens). Examples of dental pathology include periodontal disease , dental crowding, buccal displacement (molar impaction with buccoversion - mesioangular orientation as a result of impaction/molar displacement; see Calcagno and Gibson 1993); transverse (banded) and pitted enamel hypoplasia. Only 12% of the observed pathological lesions were observed in the post-cranium. Examples of postcranial pathology include osteophyte formation found in a pair of lumbar vertebrae, degenerative joint disease / osteoarthritis, lytic lesions diagnosed as spondylosis deformans, and a possible case of brucellosis. One case of

healed trauma in the form of a compressed talus fracture was also observed. All pathology in this assemblage was found in *A. africanus*. The most common pathology in this assemblage was identified as enamel hypoplasia.

Swartkrans

After systematic observation of the Swartkrans Cave assemblage, 21 hominin fossils with pathology were identified out of a total of 351 available specimens. Of the 21 specimens considered to be pathological, 16 were attributed to dental pathology, with the balance (5) being postcranial in nature. Examples of dental pathology observed in the Swartkrans specimens included dental crowding (*P. robustus*), pitting enamel hypoplasia (*P. robustus*), carious lesions (*H. erectus[ergaster] and P. robustus*), periodontal disease, dental abscesses (*H. erectus*) and alveolar bone loss. Examples of post-cranial pathology included a neoplasm (5th metatarsal) (*Hominidae indet.*), abnormal bone formation left metaphysis (left metatarsal (I) (hallucial)/ exostotic outgrowth (*P. robustus*), vertebral osteophyte formation, and enthesopathy (2nd phalanx; *H. indet.*). The most common pathology observed in the Swartkrans fossil hominin assemblage is enamel hypoplasia, followed closely by caries. The overall prevalence of pathology in the Swartkrans fossil hominin assemblage is considered to be approximately 5.9%, with dental pathology accounting for most of it (76.1%).

Makapansgat

Following a systematic survey of the hominin fossils from the Makapansgat assemblage, 7 out of a total of 48 specimens were demonstrated to be pathological. All affected specimens are classified as *Australopithecus africanus*. The prevalence of pathology in the Makapansgat hominins is thus approximately 14.5%. Of the 7 pathological specimens, 6 exhibited dental pathology (87.5%), and one specimen revealed postcranial pathology. These included pitting enamel hypoplasia, linear hypoplastic defects, dental crowding, and a single case

of osteonecrosis / joint arthritis in a proximal femur. The most common pathology in this hominin assemblage is various forms of enamel hypoplasia.

Malapa

After a systematic survey of the Malapa Cave hominin assemblage, 2 post-cranial specimens belonging to *Australopithecus sediba* (MH1), out of an available total of 225 hominin fossils, revealed pathological characteristics. These included a neoplasm and osteophyte formation. The prevalence of specimens with signs of pathology is thus approximately 0.89%.

A cursory evaluation of the dentition of this assemblage identified a few potential samples of enamel hypoplasia. The dental material however, was not available for study in this project. Under the circumstances, it was therefore not possible to comment on the most common pathology prevalent in this assemblage until a more in-depth study has been undertaken.

Taung

The Taung Site comprises of only one hominin specimen, the holotype of the Plio-Pleistocene hominin species *Australopithecus africanus* - the 'Taung Child'. After an analysis of this specimen was performed, the dentition revealed linear enamel hypoplasia of its first permanent molars (RM^1 and RM_1).

Kromdraai

After a complete survey of all available specimens from Kromdraai was performed, one specimen out of a total of 28 hominin fossils (3.6%) revealed pathological characteristics. This specimen (*Australopithecus robustus*) had an enamel hypoplastic lesion.

Dinaledi Chamber (Rising Star)

Following the undertaking of a comprehensive survey of the Dinaledi hominin assemblage, 5 specimens were identified as pathological out of a total of approximately 1550 specimens (0.32%). Examples of pathology included a peripheral osteoma (mandibular), osteophytic lipping, and healed traumatic fractures. The most common pathological lesion in this assemblage are split evenly between healed traumatic fractures in two proximal pedal phalanges) which occurred in two individuals (U.W. 101-1013; 1395) (Throckmorton *et al*. 2017), and two examples of mild osteophytic lipping on opposite dorsal margins of two associated cuneiforms (left medial and intermediate).

Coopers Cave

Subsequent to a survey of the available fossil hominins of the Coopers Cave assemblage, 4 specimens out of a total of 29 (13.8%) were found to exhibit pathological features. All pathological specimens exhibited enamel hypoplasia (*P. robustus*).

Site with highest number of pathological specimens

The site with the highest prevalence of pathology is Makapansgat (14.5%), followed by Cooper's Cave (13.8%), Swartkrans (5.9%), Sterkfontein (2%), Dinaledi (0.32%), and Malapa (postcranial pathology) (0.88%). The Taung site only has one hominin specimen, which also showed signs of pathology. In general, the occurrence of pathological lesions is fairly low. As the number of available specimens is quite limited and spans long periods of time, it is not possible to make deductions regarding overall health. The short life span of hominins (i.e., young ages at death) probably limits the number of lesions that developed.

8.1.2 Summary of published case studies

8.1.2.1 Earliest Hominin Cancer: 1.7-Million-Year-Old Osteosarcoma from Swartkrans Cave, South Africa

Odes, E.J., Randolph-Quinney, P.S., Steyn, M., Throckmorton, Z., Smilg, J.S., Zipfel, B., Augustine, T.N., De Beer, F., Hoffman, J.W., Franklin, R.D. and Berger, L.R., 2016. Earliest hominin cancer: 1.7-million-year-old osteosarcoma from Swartkrans Cave, South Africa. South African Journal of Science, 112(7-8), pp.1-5.

Prehistoric cases of neoplastic disease are generally assumed to be rare and benign (Aufderheide *et al.* 1998; Capasso, 2005), but this new fossil evidence proves the contrary with the earliest recognizable case of a possible malignant neoplasia (osteosarcoma) in a hominin ancestor from the Swartkrans Cave dated to approximately 1.7 mya. This lesion was visualized using three dimensional (3D) microtomographic imaging methods. The evidence of malignancy in the South African fossil record attests to the antiquity of this disease.

The Swartkrans Cave hominin site is located northwest of Johannesburg in the Cradle of Humankind, South Africa, a World Heritage Site, and widely known for its *Paranthropus robustus* and *Homo ergaster* fossils (Broom and Robinson 1949; Brain 1970; De Ruiter 2003). SK 7923 (*gen. et spec. indet.*) is a 5th metatarsal hominin fragment recovered from Member 1, Hanging Remnant. This bone fragment was originally diagnosed with osteoid osteoma (Franklin 2011). Using advanced three-dimensional (3D) micro-imaging methods to study the internal morphology of this specimen, a reassessment of the previous diagnosis was done.

The bone fragment in this study was examined using micro-focus X ray computed tomographic methods (McCall 2005) with acquisition and reconstruction protocols. The computed microtomographic methods (Hoffman and De Beer 2012) used are similar to those described in Randolph-Quinney *et al*. (2016), Tafforeau *et al*. (2009) and Tafforeau *et al*. (2006). Using this method, differential diagnosis (using palaeopathological and clinical diagnostic standards, and published

sources) (See Table 2) was performed to shed light on the interpretation of expressions of pathology and lesion patterns.

Table 2. Detailed differential diagnosis of the hominin SK 7923 5th Metatarsal

Disease or condition	Pathological expression	Elements affected	Prevalence
Chondrosarcoma	Chondrosarcoma are cancerous cartilaginous neoplasms is a slow growing tumour commonly found in tubular bone. Can develop as a primary lesion and also develop on pre-existing benign cartilaginous neoplasms (secondary). May be located in the central region of a bone; can also be on the bone periphery; producing a 'saucer'-type defect in the cortical bone (Osborn 1974). Chondrosarcomas are large masses and can measure between 4-10 cm. in size. They can exhibit a lytic pattern radiographically or the production of a ring and arc feature (Osborn 1974; *Murphey et al*. 2003), and may include intra-lesional calcifications. It can exhibit regional bone destruction and an expanded cortical shell and trabeculation. A chondrosarcoma can be an extremely large tumour and lies on the surface of a flat or a long bone. Central osteochondromas pressure the cortex and lead to sclerotic margins or endosteal bone 'buttressing' in long bones (Osborn 1974). A spiculated or periosteal reactivity may be evidenced; soft tissue masses can sometimes also be visible (Osborn 1974).	Frequently found in long bones (45%); femur (20-35%); tibia (5%); upper limb (mostly proximal humerus) (10-20%); pelvis (25%); ribs (8%); spine (7%) with thoracic most frequent: scapula (5%); sternum (2%); head and neck (inclusive of cervical spine) (7%); craniofacial (2%). Hands and feet are rare and observed with caution (Osborn 1974). Location comprises 30%-50% of long bone shafts. A second form of chondrosarcoma affects the ribs, scapulae and pelvis.	This type of neoplasm represents 20-27% of all primary malignant tumours (Murphey et al. 2003). Presents typically in individuals in their forties and fifties. There is a male predominance of 1.5-2:1.
Ewing's sarcoma	Radiographical expressions typically exhibit poorly defined osteolytic lesions and a laminated periosteal reaction (57%) (Maygarden *et al*. 1993). It consistently exhibits on a radiograph either as a neoplastic entity or an inflammation[4]. Radiographic tumours are usually radiolucent, infiltrative, exhibit a moth-eaten and/or a permeative pattern of destruction (Maygarden *et al*. 1993). Lesion can be mottled, with a laminated periosteal reaction (57%). Occasionally presents with a spiculated hair-on-end response, Codman's triangles, or thick periosteal reaction. Its proliferative response often mimics osteomyelitis; also known to be sclerotic (40%) (Maygarden *et al*. 1993).	Usually affects femoral bone and it is mostly found in central meta-diaphyseal or diaphyseal regions; most common sites affected by this tumour are lower limb (45%), innominate (20%), upper limb (13%), ribs and axial skeleton (13%) and facial bones (2%) (Grier 1997).	A highly malignant primary tumour of childhood and young adulthood. ES accounts for 10–15% of all primary bone tumours (Huvos 1991). It typically begins in the medullary cavity and invades the Haversian system. Incidence has been approximated at around 0.6 per million on a yearly basis; It usually occurs between 10-20 years of age (Burchill 2003). Approximately 13 per million are affected in the age bracket 0- 24 years old in the UK (Cotterill 2003). Not commonly encountered in individuals over 25 years old (Osborn 1974). Male predilection (1.5:1) (Burchill 2003, Maygarden et al. 1993).

Table 2. Continued

Disease or condition	Pathological expression	Elements affected	Prevalence
Osteochondroma	The lesion comprises cortical and medullary bone, protruding from and continuous with underlying bone; lesions can be sessile or pedunculated; arcs and (rings)/flocculent calcification may be exhibited; in some cases, some mineralisation of the cartilage cap and irregular subchondral bone can be evidenced; aggressive structures may be seen including bony destruction, large soft tissue and metastases indicating possible malignancy.	Lower extremity long bones are most often affected (50%); occur mostly above the knee(40%); femur most affected bone (30%), distal regions being the most frequently involved; tibia (15-20%); small bones of the hand and foot (10%); scapula (4%);pelvis (5%); spine (2%). Long bone lesions mostly affect the metaphyseal regions commonly projecting away from epiphysis; diaphyseal involvement is rare	Constitute 10-15% of all bone tumours, and 20%-50% of benign tumours; Symptomatic lesions occur mostly in young patients;75-80% present before 20 years old; male predilection approximately 1.6-3.4:1
Metastatic carcinoma	Metastatic cancer often simulates benign disease or primary malignancies. Generally, metastases lead to skeletal loss and bone formation. Loss can arise out of either osteoclastic activity or enzymatic damage, and bone formation can arise within the neoplastic substrate or the adjacent bone reaction to the neoplasm, equivalent to callus development [10]. Metastases can follow three different processes. They can be either lytic, sclerotic or a combination of sclerotic and lytic. Morphologically metastases can be diffuse, focal or expansive. Bone metastases can be difficult to identify radiographically as between 30 and 50% bone loss is needed before density loss is observable [9]. Other examples are visible by cortical damage and evidence of sclerotic repair. Metastatic neoplasms generally exhibit little or no periosteal reaction[10].	Metastases usually found in pelvis, vertebrae, proximal femur, proximal humerus and cranium. Uncommonly found on knee and elbow.	Bone metastases make up 70% of malignant bone, with breast cancer, renal cell carcinoma, lung and prostate cancer accounting for about 80% of all bone metastases[9].

Table 2. Continued

Disease or condition	Pathological expression	Elements affected	Prevalence
Osteoblastoma	Osteoblastoma lesions are benign, mostly lytic; focally obliterative and may be expansive; they appear as radiolucent defects and may present with internal ossification; may have a sclerotic border or periostitis (50%), cortical expansion and some destruction is common; a soft tissue mass may be present; microscopic findings include irregular spicules of mineralised bone, eosinophilic osteoid and woven bone rimmed by osteoblasts [11-15]. The neoplasm forms osteoid and bone. Vascularity is high. Lesions are typically above 2cm in size [18-19].	Commonly found in the metaphysis and distal diaphysis of long bones; spine (up to 46%) [16], and commonly involves the posterior cervical spine (up to 40%) [16], and the sacrum (17%) [17].	Osteoblastoma is a rare primary bone neoplasm and represents approximately 1-3% of all primary bone tumours[16, 17]. It affects mainly adolescents and young adults in the 2nd and 3rd decades of life; wide age range (6-75); representing 1% of primary bone tumours; predilection of male to female (2.5:1)
Osteosarcoma	This type of primary malignant tumour typically including a moth-eaten or permeated bone destruction pattern, can exhibit cortical and medullary obliteration, and some degree of tumour matrix mineralisation; exhibits wide zones of transition; presence of aggressive periosteal new bone reaction seen which either can include a lamellated reaction, Codman's triangle and/or a spiculated sunburst-type of reaction; sometimes soft tissue masses are present. Most common form is central osteogenetic sarcoma which could either be an osteoblastic or osteolytic lesion or a mix of both. Osteosarcoma has several categories depending on the focus within the bone, and histology and variation: intramedullary (80%); surface or juxta-cortical (10-15%) and extra-skeletal (5%) [21].	Typically occurs in the metadiaphyseal area of long bones, commonly the distal femur (40%); proximal tibia (16%); humerus (15%). Also occurs less frequently in the mandible, maxilla, clavicle and ribs, os coxae, and vertebrae. Primary tumours exhibit in the metaphyseal areas of long bones, preferring the knee; secondary neoplasms have a preference for flat bones	Accounting for approximately 20% of all primary bone neoplasms[20]. They can be primary or secondary. Primary osteosarcoma- typically occurring in the 10-20 age group with occurrence < 20 years (75%); Secondary osteosarcoma is prevalent in elderly individuals. Minor male predilection.
Low-grade osteogenic sarcomas	This group of low grade tumours first described by Dahlin and Unni (1977) includes low grade intramedullary and surface forms of osteogenic sarcoma (juxta-cortical osteosarcomas). Their incidence does not more than 5% of all osteogenic sarcomas. Diagnosis is difficult due to its rarity but also because of the complexity of the fibrous surface lesions.	Most frequently affects long tubular bones; femur and tibia	Predilection is equal between sexes.
Low grade intramedullary (Central) Osteogenic Sarcoma	Represents less than 2% of all osteosarcomas. Usually exhibits large medullary sclerotic tumours at the end of long bones. Mixed sclerotic and lytic lesions can be detected. Periosteal new bone formation is rare, as is soft tissue extension. Macroscopically it appears as a slowly growing lesion; clearly distinct mass with erosion of the endosteum. In older lesions cortical invasion can be seen.		

Micro-computed tomography offers the potential for reassessing previously reported palaeopathological phenomena, and has proven to be a valuable technique to analyse fossil morphology, and comparative clinical bone analogues, and capably aid with reliable diagnoses.

SK 7923 exhibits an abnormal mass abutting the cortex on the proximo-ventral aspect of the shaft (See Appendix B; Figure 1). Osteosarcoma typically originates in the medullary cavity and presents within the metaphysis of tubular-type bone elements, proliferating through cortical bone into soft tissue disrupting the periosteum and exhibiting a Codman triangle. The periosteal reaction may present with a 'sunburst' pattern (Vigorita 2008). This appears to be the case in this 5th hominin metatarsal (SK 7923). Thus, considering the morphology of internal and external bone structure, it appears most probable that the pathology affecting the SK 7923 metatarsal is osteosarcoma (osteogenic sarcoma), with a likelihood of the parosteal variant of this disorder. Diagnosis was further reinforced by μXCT virtual imaging of a known modern clinical case of osteosarcoma of a distal human femur.

A significant query raised by this case study about the expression and incidence of malignant neoplastic disease, is understanding the evolution of ancient cancers given such small sample sizes. Malignancy is further alleged to be a modern disease by some researchers (David and Zimmerman 2010; Binder *et al*. 2014; Brody 2015). However, primary osteogenic malignant and non-malignant tumours are not frequently evidenced in the contemporary clinical environment (Dahlin *et al*., 1970; Burkitt 1971; Huvos 1986; Greenspan 1993; Harris *et al*. 1999; Kleihues and Cavenee, 2000; Fletcher 2002; Fletcher Unni and Mertens, 2002; World Health Organization, 2004; Barnes et al. 2005; Vardiman 2009; Solooki *et al*. 2011), and although infrequent, are also not unknown in the archaeological and fossil record (David and Zimmerman 2010; Binder *et al*. 2014). Preservational factors have traditionally constrained the study

of human neoplastic disease to skeletal remains making diagnosis complex (Rothschild and Rothschild 1995).

The presence of a possible malignant osteosarcoma in the Swartkrans specimen (SK 7923) indicates that even though currently observed increases in malignancies are usually correlated to hazards of the modern world and greater life expectancies, primary bone tumours did occur throughout history. These tumours in the ancient and modern world would have occurred mostly in young and adolescent individuals.

Thus, malignant neoplastic disease has significant antiquity as evidenced by SK 7923, the hominin foot bone fragment. This is reinforced by other reports of benign neoplasms in the fossil record (Rothschild and Martin, 1993; Aufderheide *et al*. 1998; Rothschild, Witzke, and Hershkovitz, 1999; Ortner, 2003; Rothschild *et al*, 2003; Capasso, 2005; Davies and Lineweaver, 2011; Leshchinskiy, 2012). The hypothesis that the near complete absence of cancers in Egyptian mummified material shows that the disease only occurs in industrialised societies (David and Zimmerman, 2010), is therefore dubious.

The lack of substantial evidence of malignant disease in the fossil and archaeological record might arguably be attributed to many causes, including artefacts of preservation, sampling bias, miniscule sampling sizes, analytical methodologies, or inefficient imaging techniques (Beckett and Conlogue 2010). Thus, the rarity of cancer in the fossil record can most probably be understood as being due to the non-representative nature of the sample. It is to be expected that with the modern global demographic transition and higher mean age at death for the human species, non-primary bone cancers will occur more often today than in population groups before the transition took place (Chamberlain 2006).
As malignancy also occurs in several metazoans and other fossils, it indicates that the mechanisms of malignancy have a considerable ancient evolutionary history (Capasso 2005; Rothschild and Martin 1993;

Rothschild *et al*. 1999). Some oncogenes appear to have an extremely ancient evolutionary history, that some forms are present in ancient chordates and arthropod metazoans (Davies and Lineweaver 2011; Rothschild *et al*. 1999). Thus, the capacity for malignancy is archaic, and the greater frequency of the disease in the modern world today may be due to the convergence of environmental factors, having no counterpart in the prehistoric environment (Klepinger, 1980).

8.1.2.2 Osteogenic Tumour in *Australopithecus sediba*: Earliest Hominin Evidence for Neoplastic Disease

Randolph-Quinney, P.S., Williams, S.A., Steyn, M., Meyer, M.R., Smilg, J.S., Churchill, S.E., **Odes, E.J.,** Augustine, T., Tafforeau, P. and Berger, L.R. 2016. Osteogenic tumour in *Australopithecus sediba*: Earliest hominin evidence for neoplastic disease. South African Journal of Science, 112 (7-8), pp.1-7.

Preserved neoplastic signatures are rare in archaeological groups, and are all but unknown in the hominin record (Capasso 1997; Aufderheide *et al*. 1998; Ortner 2003). Neoplastic disease would have been prevalent in the past, but most likely occurred at lower incidences than today, given the shorter life expectancy of our ancestors (Ortner 2003; Chamberlain 1986; Mann 1975) and the different environmental context. This paper reports the earliest fossil evidence for neoplastic disease in the human lineage, with a detailed description of a lesion affecting the spine of a juvenile male hominin, *Australopithecus sediba*, Malapa Hominin 1 (Berger *et al*. 2010; Williams *et al*. 2013), and discusses clinical and evolutionary inferences of the diagnosis.

Malapa is a Plio-Pleistocene cave site containing hominin-bearing deposits. It is situated in the Cradle of Humankind World Heritage Site, northwest of Johannesburg, South Africa. The principal hominin-bearing deposits were dated using uranium-lead dating of flowstones, and

palaeomagnetic and stratigraphic methods of flowstones and sediments to 1.977± 0.002 Ma (Dirks *et al*. 2010). This cave site has yielded numerous fossils including at least six fossilized hominin individuals. Of these fossilized remains, MH1 and MH2 have been reported in the literature as individuals belonging to a new species, *Australopithecus sediba* (Berger *et al*. 2010). One of these specimens, *Australopithecus sediba* (MH1), an adolescent male hominin, is affected by a pathological spinal lesion in the 6th thoracic vertebra (U.W. 88-37), which exhibits as a round penetrating lytic defect in the dorsal surface of the right lamina.

The internal morphology of this fossil specimen was assessed using phase-contrast X-ray synchrotron microtomography with a scanning protocol set for high resolution three-dimensional (3D) imaging. Using differential diagnostic methods, evidence showed that the disease process was active and chronic at the time of this individual's (MH1) death. This indicated an ante-mortem process, ruling out taphonomic, pseudopathological, or diagenetic processes (Ortner 2003). This condition may have caused several physiological reactions including chronic or acute discomfort, abnormal function of the muscles, and spasmodic pain as noted in several clinical case studies. Bayes Theorem of conditional probability was applied to two different most likely diagnoses for the *A. sediba* specimen: osteoid osteoma and osteoblastoma. Given the similarities that exist between the two benign neoplasm types, and the age and characteristics of the specimen, the results suggest that the most likely diagnosis is an osteoid osteoma followed by an osteoblastoma.

This primary spinal bone tumour in *A. sediba* offers important information on the life-history of *A. sediba* and also for other individuals presenting evidence of prehistoric neoplastic disease. Preservational factors are known to constrain the study of neoplasms to mostly skeletal material making specific diagnosis of tumours difficult (Rothschild and Rothschild 1995), and although neoplastic disease is recognized in the hominin archaeological and historical record (Eshed *et al*. 2002; Ortner 2003;

Retief and Cilliers 2011) it is understood to be controversial. Such is the case of an archaic *Homo* mandible, the Kanam jaw from Kenya, with several researchers offering varying diagnoses, but none with a definitive resolution to the pathology of this fossil jaw (Tobias 1960, 1962; Stathopoulos 1975; Phelan *et al*. 2007).

Neoplastic disease and more particularly osteoid osteoma and osteoblastoma are considered an ancient phenomenon with its first appearance in the Palaeozoic and Mesozoic in extinct fish and Dinosauria (Capasso 2005; Rothschild and Martin 1993; Rothschild *et al*. 2003). Cytogenetic chromosomal research indicates a genetic basis for osteoid osteoma in humans, suggesting that although the expression of neoplasia is uncommon in the fossil record, the capacity for neoplasia existed in deep time. It is widely acknowledged that primary osteogenic tumours occur most often in young individuals (Amacher and Eltomey 1985; Ortner 2003; Azouz *et al*. 1986; Bahk 2007; Binning *et al*. 2007; Khurana 2008), and thus would have been expected to occur in prehistory and have a similar prevalence in modern individuals. It appears likely that primary bone tumours were as prevalent in ancient populations as those seen in wild primate populations but has left few meaningful evidential traces. A reason for this could be the lack of hominin individuals recovered from the record which points to an epidemiological sampling phenomenon (Chamberlain 2006).

The rarity of neoplastic disease and the earliest evidence thereof in the hominin record makes this a significant discovery. This case offers key insights into the individual life experience of an individual hominin (MH1), and affords a glimpse into the expression and evolution of neoplasia in the human lineage. It further illustrates the value of a multidisciplinary approach and its application to the understanding of the development of disease in humans and its ancestors.

8.1.2.3 A Case of Benign Osteogenic Tumour in *Homo naledi*: Evidence for Peripheral Osteoma in the U.W. 101-1142 Mandible.

Odes, E.J., Delezene, L.K., Randolph-Quinney, P.S., Smilg, J.S., Augustine, T.N., Jakata, K. and Berger, L.R., 2017. A case of benign osteogenic tumour in *Homo naledi*: Evidence for peripheral osteoma in the U.W. 101-1142 mandible. International Journal of Paleopathology. *In Press, corrected proof.*

This case study presents a palaeopathological analysis of a mandibular exostosis on the lingual aspect of U.W.101-1142, first identified by Laird *et al*. (2016) as a mandibular osteoma. This fossil is an adult right partial mandibular fragment attributed to *Homo naledi* (Berger *et al*. 2015; Laird *et al*. 2016). It was recovered from the Dinaledi Chamber, Rising Star Cave, Cradle of Humankind, South Africa, and formed part of an excavation which yielded over 1550 fossil bone fragments (Berger *et al*. 2015; Randolph-Quinney 2015). This discovery is the largest single fossil hominin assemblage uncovered on the continent of Africa to date (Berger *et al*. 2015; Randolph-Quinney 2015). The context of the Naledi deposition in the cave has been described by Dirks *et al*. (2015, 2016), and the assemblage organisation is thought to have resulted from deliberate body disposal practices (Dirks *et al*. 2015, 2016), or funerary caching (see Pettitt 2011; Randolph-Quinney 2015; Berger *et al*. 2017).

The specimen was evaluated and photographed macroscopically. Mandibular morphology of the specimen was compared to all other *H. naledi* mandibular specimens excavated to date. External macro-photographic imaging was performed using a Canon 70D 20MP DSLR, with a 60 mm Canon EF f2.8 macro lens and ring-flash. The internal structure was then imaged using micro-focus X-ray-computed tomography (μCT). Volume reconstruction, orthoslice production, and three-dimensional volume rendering were performed following scanning. The last step of the method involved analysis of the internal structure and external morphology.

The external lingual surface of the body of U.W. 101-1142 exhibits an abnormal bony mass on the corpus attached to the right lingual cortex below RM3. The lesion is almost complete, except for minor discontinuity due to cortical cracking, indicating no post-mortem loss. The internal structure indicates that the cortical bone and margin of the lesion are largely contiguous with no evidence of invasion by the mass. The mass shows as a cortical expansion (Fig 6e-g).

Differential diagnosis was performed using palaeopathological and clinical diagnostic standards (Rothschild and Martin, 1993; Resnick, 1995; Ortner, 2003; Roberts and Cox, 2003; Vigorita, 2008). The presence of remodeled sclerotic bone indicates an ante-mortem process, ruling out taphonomic, pseudopathological or diagenetic processes associated with the lesion (Bloem and Kroon, 1993). The evidence for both osteogenic and osteosclerotic processes indicates that the pathological mechanism was chronic, with no aggressive remodeling of bone, resorption of the cortex, or expressions of osteolytic or sub-periosteal reactive processes (Bloem and Kroon, 1993; Aufderheide *et al*. 1998). Differential diagnosis includes several possible bone-forming conditions including osteochondroma, osteoid osteoma, mandibular osteoma, and mandibular torus (exostosis).
Based on the gross pathological appearance, micro-morphology, and locus, the two most likely diagnoses are mandibular osteoma or congenital mandibular torus (exostosis) It is proposed that this specimen presents a peripheral mandibular osteoma, a benign osteogenic neoplasia.

In U.W. 101-1142, clinical manifestations and effects on the individual would probably have been minor. Although it is widely known from modern clinical studies that osteoma is a slow growing condition, and often cryptic, it may cause symptoms such as pain and swelling in and around the lesion. There may have been potential impact on the function of the pterygoid muscle due to the proximity of the lesion to the insertion of the medial pterygoid muscle. Many peripheral osteomas are found near

muscle attachments and researchers have considered it possible that muscle traction may be involved in the development of these tumours.

This study demonstrates the difficulty in understanding hominin neoplasias and other diseases, which are restricted by small sample sizes as opposed to the more profuse samples of contemporary clinical tumours in human skeletal material. This makes definitive diagnosis problematic (Aufderheide *et al*. 1998; Ortner 2003; Capasso 2005). It is important to note that neoplastic disease has been observed by several previous studies of benign and malignant bone tumours from the fossil and deep time record (Rothschild and Martin, 1993; Capasso, 1997, 2005; Rothschild *et al*. 1999; Roberts and Cox, 2003; Rothschild *et al*. 2003; David and Zimmerman, 2010; Davies and Lineweaver, 2011; Retief and Cilliers, 2011; Odes *et al*. 2016; Randolph-Quinney *et al*. 2016). The lack of definitive neoplastic evidence in the archaeological and fossil record may well be the result of preservational or sample size bias, poor methods or a lack of effective analysis. Computed tomographic methods, particularly micro-computed tomography, has been suggested as the most valuable method to investigate this type of lesion (i.e. neoplasm) (McCall 2005; Randolph-Quinney *et al*. 2016), and has been thought of as the 'gold standard' for imaging bone micro-architecture (Tafforeau *et al*. 2006; 2009). This method is useful where radiolucency and sclerosis are most frequently encountered, and is especially valuable when experiencing difficulties with dense bone material (Odes *et al*. 2016).

8.1.2.4 Osteopathology and Insect Traces in the *Australopithecus africanus* Skeleton StW 431.

Odes, E.J., Parkinson, A.H., Randolph-Quinney, P.S., Zipfel, B., Jakata, K., Bonney, H. and Berger, L.R. 2017. Osteopathology and insect traces in the *Australopithecus africanus* skeleton StW 431. South African Journal of Science, 113 (1-2), pp.1-7.

StW 431 consists of a partial hominin skeleton of *Australopithecus africanus* discovered in 1987 from Member 4, Sterkfontein Caves, Cradle of Humankind, South Africa (Toussaint *et al*. 2003). This specimen has been the subject of continuing debate regarding the presence of pathology (Staps 2002; D'Anastasio *et al*. 2009). This study attempted to resolve this debate and shed light on the character of ante versus post-mortem processes affecting this specimen.

Two lumbar vertebrae (4th and 5th) of StW 431 were examined macroscopically and microscopically to record morphological surface characteristics. The internal morphology was imaged using micro-computed tomography (μCT). Comparative skeletal material including normal modern and pathological human vertebrae were also imaged. Comparative skeletal specimens with known and purported brucellar pathology from radiographical and palaeopathological literature were also studied, as D'Anastasio *et al*. 2009 suggested a possible diagnosis of Brucellosis as the cause of the lesions on the two fossil lumbar vertebrae, using scanning electron microscopic techniques.

The macroscopic analysis of the fourth lumbar vertebra (L4) indicates some postmortem damage resulting in the loss of some vertebral elements, and fracture damage. Areas of slight and extensive osteophytosis on the anterior superior and anterior-inferior rims were noted. A mild porotic pattern is present on the superior endplate.

The fifth lumbar vertebra (L5) demonstrates severe post - mortem damage and fracturing and erosion with two areas of severe cortical loss. This vertebra presents as the left half of the vertebral body with some elements intact and others only partially present. L5 exhibits extensive osteophyte formation with superior and endplate margins and the midline anterior surface of the body more severely affected than the lateral side of the body. The anterior projection of the superior osteophyte formation is disrupted by a large area of detached osseous tissue. This zone has been described

previously as osteolysis, and possibly related to infectious disease (D'Anastasio *et al*. 2009).

Micro-tomographic imaging of the internal morphology of L4 indicates areas of both bone deposition and removal. Osteophytic lipping is present on the antero-superior margin, as is a slight degree of remodeling, an increase in trabecular thickness and reduction in trabecular spacing on the margin of the anterior superior body. Micro-tomographic imaging of L5 indicates marked areas of bone deposition and removal with severe osteophytosis of the vertebral body.

Potential post-mortem erosion patterning and specifically surface modification by insects was identified. Further imaging using a multifocal microscope equipped with image processing software was undertaken to clarify these observations. Comparative collections of insect damage to bone were used in this study. Insect damage was also compared to existing data published in several literature sources (e.g., Backwell *et al*. 2012; Parkinson 2013, 2016; Kaiser 2000). A channel-like structure is present on the L5 vertebral body. No evidence was found of sclerosis or reactive bone formation around cavity margins. Micro-CT imaging shows an absence of bone remodeling with respect to the channel or the holes.

Macroscopic observations of the surface morphology and microtomographic imaging of the internal cortical and trabecular morphology of StW 431 hominin vertebrae have indicated the presence of osseous proliferation (osteophytosis) consistent with degenerative spinal disease, including various processes of bone formation and bone destruction (Resnick 1994, 1995; Resnick and Niwayama 1988, 1995). The presence of osteophytosis and other associated degenerative characteristics elsewhere in the lumbar and sacral regions have been proposed by Staps as spondylosis deformans (Staps 2002). Our results are broadly consistent with this diagnosis, however the degenerative changes seen could be attributed to normal age-related degenerative joint changes.

The causal process accounting for the destructive erosion of L4 and L5 has yet to be addressed definitively from a pathological point of view. Here we attribute it to post-mortem alteration by insects.

Voids identified in StW 431 are within the range recently reported from Cooper's D specimens (Parkinson 2016) and those produced by South African termite species, *T. trinervoides* under experimental conditions (Backwell *et al*. 2012). The holes identified in StW 431 also fall into the range of defects reported from Swartkrans (Newman 1993), but fall outside the range of voids or tubes reported from Makapansgat which were attributed to dermestids (Kitching 1980).

The traces identified on StW 431 have been attributed to insects based on morphological similarity with traces reported in the literature. High resolution micro-CT imaging provided visual evidence that the traces were produced post-mortem as there was no bone remodeling. Because of the limited sample size, morphological and metric similarity with traces produced by termites and dermestids, attributing these to a specific agent was avoided. Attempting to establish behavioural conclusions from a limited sample of traces which are not well preserved would have been pointless in our opinion.

This study demonstrates that except for osteopathological lesions in the form of osteophytic lipping demonstrating minor degenerative joint disease, the observed changes were caused by post-mortem processes. These changes were described by previous researchers as evidence for infectious bone disease (D'Anastasio *et al*. 2009), Our results thus suggest that the areas previously described to be the result of infection are post-mortem modifications made by insects.

These conclusions have been drawn based on new microtomographic imaging methods applied to the fossil specimens. This is different from the methods used by D'Anastasio *et al*. (2009) which consisted of

observations of surface morphology using light and scanning electron microscopy. In the present study, in addition to macroscopic and microscopic methods, micro-CT was used to achieve a far higher resolution than in previous studies with three-dimensional capabilities to model and render previously identified lesions. No previous studies have used micro-CT to evaluate the surface bone of StW 431 and no insect traces have been reported on this specimen until now.

This study agrees with the diagnoses of spinal DJD which affected StW 431, while shedding light on the various post-mortem processes affecting Sterkfontein site and its assemblages. Macroscopic and microscopic examinations are necessary prerequisites to distinguish the difference between post-mortem taphonomic and pre-mortem pathological processes as they can both look very similar, and can be difficult to distinguish. It can distinguish between ante-mortem pathology or post-mortem pseudo-pathology. The co-occurrence of degenerative pathological processes and subsequent insect alterations of the same zones, presents an interesting taphonomic case that may not be specific to StW431, with a cercopithecoid vertebra from Cooper's D showing similar taphonomic changes. This demonstrates that the alterations on StW 431 cannot be considered unique. This study found that the method of combining traditional morphoscopic analyses of external gross morphology, together with non-invasive high-resolution tomographic methods (micro-CT, nano-CT, or synchrotron tomography), offers a valuable means with which to improve diagnoses. This comparative method has been used elsewhere successfully in the South African fossil record with the identification of the earliest hominin cancer and neoplastic disease which would have been impossible utilising conventional diagnostic techniques (Odes *et al*. 2016; Randolph-Quinney *et al*. 2016). It has been suggested by Mays (2008), that secure diagnosis of infectious disease processes in bone should be undertaken using biomolecular means. Fossil bacterial DNA however, may not survive in such deep time scales, placing a much greater emphasis on the use of non-invasive, comparative methods.

8.2 Neoplasms in the fossil record

The leading model of the 20th century for the explanation of cancer is premised upon the theory that the accumulation of mutations impairs the control of cellular growth and invasive mechanisms (Nordling 1953; Armitage and Doll 1954). This theory gained wide acceptance when particular mutated genes were demonstrated to have enhanced cellular proliferation in cancerous cells. Subsequently this understanding promoted further studies on the aetiology of mutation, including the roles that radiation and carcinogenic chemicals play in the proliferation of various cancers (Tomasetti *et al*. 2017). Furthermore, persuasive rationalizations for different causes of environmentally-linked cancers, for example smoking of tobacco products and its link to lung cancer, ultraviolet radiation (UVR) in respect of skin cancer, and heritable weaknesses, as in the mutagenic features associated with BRCA genes for breast cancer (Pfeifer *et al*. 2002; Narayanan *et al*. 2010; Pomerantz and Freedman, 2011), have been argued.

The rarity of cancer in ancient human skeletal remains may have been as a consequence of the lack of exposure to cancer causing compounds (David and Zimmerman, 2010; McAloose and Newton, 2009). This opinion includes notions of contemporary exposure to factors that can cause genetic mutation (chemicals), as in the smoking of tobacco products and abnormal levels of radioactive substances (Del Bino and Bernerd, 2013).

The scarcity of cancer in ancient human remains has been construed to infer that cancer was rare in ancient populations (David and Zimmerman, 2010; Binder *et al*. 2014). This notion must be challenged for two reasons, firstly even although the disease is largely absent from archaeological remains does not necessarily mean it may not have been relatively commonplace. Secondly, the accumulative mutation theory of cancer may

not be adequate on its own as a basis to explain the mechanisms and genesis of malignancy (Ewald 2017).

A specific difficulty with concluding cancer from skeletal evidence is the uncertainty that comes with differential diagnosis (Brothwell, 2016; Phelan *et al*. 2007). A significant difference between malignant and benign neoplasm, is metastasis. Metastatic skeletal changes however, are generally not well-defined, and can be challenging to differentiate from inflammatory features and postmortem modification (Brothwell, 2016).
Individuals with cancer in prehistoric times almost certainly were vulnerable to the activities of predators. Predatory activity may well have affected the time period that cancer could influence bone, concealed expressions of cancer on skeletal remains, or substantially damaged the bones *in toto*. Outcomes of prehistoric predation can similarly be equated to the "osteological paradox" (Wood *et al*. 1992), with "selective mortality" affecting bias in the fossil record by decreasing the occurrence of skeletal remains with definitive expressions of cancer. Prevalence of cancer in the fossil record can also be affected by the postmortem location of the remains (Assis *et al*. 2015), where factors such as predation, burial, and erosion may have had an influence on the bone, and may have resulted in a lower assumed prevalence than actual prevalence (Ewald 2017).

It appears plausible to suggest that bone cancers were most probably less frequent in ancient populations than other forms of cancer, taking contemporary occurrences into account (Ewald 2017). In the modern day, primary bone cancers are also considered relatively rare (Guise and Mundy 1998; Longhi *et al*. 2006), and general bone cancers develop mostly as a result of metastasis from primary cancers in the prostate, breast and lung (Guise, 2000; Mundy 2002). In prehistory these kinds of cancer were probably rare. Lung cancer which is considered chiefly a modern disease is linked to the smoking of tobacco products (Hecht 1999). Prostate cancer mostly affects older aged individuals (Li *et al*. 2012), which may have been less common than today due to a lower life expectancy in ancient and

prehistoric periods (Gurven and Kaplan, 2007). Breast cancer is also inclined to occur mainly in older age groups (Youlden *et al*. 2014; Verdial *et al*. 2017), and as a result may have also been uncommon in prehistoric populations (Eaton *et al*. 1994).

These considerations therefore appear to suggest that cancers affecting bone are likely to be less frequent in ancient skeletal material, and more especially in fossilized material, relative to benign tumours and modern incidences of skeletal cancer. Benign neoplasms have been found in prehistoric hominins suggesting the likelihood for the presence of non-malignant bone tumours (Randolph-Quinney *et al*. 2016). According to Brothwell (2016), none of the bone lesions found in hominin fossils could be unquestionably attributed to cancer. Subsequent to his assessment however, an osteosarcoma in an early *Homo* metatarsal fossil bone dated to approximately 1.7 million years ago has been reported (Odes *et al*. 2016). The scarcity of fossilized bone remains, the minimal ratio of cancers leaving definitive evidence on fossilized bones, and the shorter life expectancies of prehistoric groups together may contribute to the dearth of evidence recording prehistoric hominin cancer (Randolph-Quinney *et al*. 2016).

Ewald's (2017) paper considers three different approaches relating to infection-induced cancers as a means of improving understanding of cancer in ancient populations. The first approach involves molecular mechanisms through which parasites generate cancer. The second approach considers comparative analysis of different types of cancer prevalence between various ancient populations and extant human population groups. Thirdly, he reflects on cancer in ancient settings and wildlife contexts, focusing on the necessity to observe wildlife's interface with contemporary manufactured carcinogens and cancer cancer-causing organisms.

Although oncogenesis has been traditionally explained by way of mutation theory, there is a growing acknowledgment that parasites can initiate cancer, and play some part in causing approximately 20% of all human cancers (zur Hausen and de Villiers, 2014). Historically, the causality of parasitic organisms of human cancer was broadly explained through the effects of mutations of cellular growth and infective reaction. The understanding of how the mechanistic pathways used by parasites contribute to human cancer is gaining wider acceptance, and in so doing has led to an alternative conclusion; one which limits expression of the mutagenic accumulation theory (Ewald 2017).

It is plausible that oncogenic viruses that infect modern humans had a similar capacity in deep antiquity and before the development of agriculture. Oncogenic human papillomaviruses (HPVs), for example, are widely acknowledged causes of a number of cancers including cervical and oropharyngeal types (see Saraiya *et al*. 2015). Comparative analysis of humans and HPVs indicates that an HPV cancer-causing variant (type 16) occurs in *Homo sapiens*, and has done in its ancestral lineage for approximately 500 000 years (Pimenoff *et al*. 2017). It is widely accepted as a cause of Burkitt's and Hodgkin's lymphomas, gastric, and nasopharyngeal cancer, and also linked to other kinds of cancers. Phylogenetic studies reveal that Epstein Barr virus (EBV) (an acknowledged cause of various cancers including Burkitt's and Hodgkin lymphomas) (Hsu and Glaser, 2000), diverged from faunal viruses before the emergence of *Homo sapiens* (McGeoch, 2001; Gerner *et al*. 2004), and a lengthy association with humans has been demonstrated phylogenetically, in the early evolutionary history of *Homo sapiens* (McGeoch and Gatherer, 2007).

Whether cancers caused by infections in ancient populations were more or less prevalent than in modern populations is still an open question. Mutations play a contributive role, however, in infection driven oncogenesis (zur Hausen and de Villiers 2014). Because of today's higher

rates of exposure to environmental mutagens this may suggest that a higher prevalence of cancer currently exists than may have occurred in ancient periods. According to a recent study by Tomasetti *et al*. (2017), it is suggested that the majority of mutations playing a contributive role with oncogenesis may be as a result of errors during replication rather than from mutative processes. If studies confirm this, modern environmental mutagens manufactured by humans may not be as significant for infection driven oncogenesis as is commonly thought (Ewald 2017).

In summary, palaeopathological studies of ancient human skeletal remains have indicated that cancer and benign neoplasms have existed in human populations for several thousands of years. Cancer causing pathogens may also point to the existence of cancer in human antiquity and prehistory. Phylogenetic studies of a number of oncogenic viruses indicate that they were oncogenic in humans substantially prior to the commencement of agriculture and some all the way through to the development of modern *Homo sapiens* (McGeoch and Gatherer, 2007).

Arguably, the incidence of cancer in modern day hunter-gatherers could provide a greater insight into its prevalence in archaeological and prehistoric human populations. Differences in the incidence of cancers in these present-day hunter-gatherer groups suggest inconsistency in the occurrence of oncogenic agents (Gurven *et al*. 2007). Evidence of oncogenic pathogens that existed in the human species prior to the origins of agriculture suggests that cancers may have been present in ancient human population groups. It appears that ancient and prehistoric humans have interfaced with the environment in a very similar manner as wildlife species do today, and this parallel points to the likelihood that cancer in various wildlife species may offer an understanding into its presence in early *Homo* and its ancestral lineage (Ewald 2017).

8.3 Contributions from micro-computed tomographic (micro-CT) imaging techniques

Although various clinical imaging modalities of choice such as plain radiography, MRI, CT, and MR are often used for the diagnosis of different conditions, they do have their advantages and disadvantages (for a full discussion, see Carrera *et al*. 1980; Raskin 1981; Modic *et al*. 1984; Smith *et al*. 1989; Assoun *et al*. 1994; Leone *et al*. 1994; Resnick and Niwayama 1995; Spouge and Thain *et al*. 2000; Nelemans *et al*. 2001). The adoption of high resolution three-dimensional imaging methods in palaeopathology for the study of comparative skeletal hominin disease description, classification, interpretation, and differential diagnosis, however, may well prove very useful in narrowing the historical data 'gap' that contemporary researchers face in their observations, diagnoses and analyses of palaeopathology in hominin skeletal material. While palaeopathology has historically used only radiography and some forms of clinical scanning to assess fossil bone for palaeopathology (Brothwell 1969; Ortner and Putschar 1985; Aufderheide *et al*. 1998; Ortner 2003; Rothschild *et al*. 2003; Capasso 2005), it is fast becoming the norm to use high resolution three-dimensional non-invasive scanning methods such as microtomographic scanning and sub-micron microscopy. These technologies cannot be used clinically.

The imaging techniques used in this study (such as micro-computed X-ray tomography and phased contrast X-ray synchrotron tomography) presented an unparalleled visual imaging technique to investigate the internal and surface morphological structures of hominin fossil bone lesions. It was critical in establishing accurate lesion descriptions and a reliable differential diagnosis, with support of comparative use of appropriate clinical homologues.

Micro-focus X-ray computed tomography (μXCT), and phase contrast synchrotron microtomographic methods are being seen as superior, when it comes to visualising antemortem and postmortem changes in bone, respectively (Rühli *et al*. 2002b; Tafforeau *et al*. 2006, 2009). Palaeopathological research is now gradually adopting these high three-

dimensional resolution imaging methods in contemporary publications (Tafforeau *et al*. 2006; Pinhasi and Mays 2008; Waldron 2008; Grauer 2012; Binder *et al*. 2014).

Through the use of virtual visualization, contrast, multiplanar functions, axis mobility protocols and segmentation functions embedded in the specific software, microtomographic, non-destructive techniques were able to provide clarification of various pathological conditions, additional diagnostic data and the potential pathogenesis and causes of disease processes, as well as distinguishing pseudopathological markers in fossilized hominin bone. These included 3D virtual images of neoplastic disease, osteophyte formation and degenerative bone features, trabecular remodeling and reductions in trabecular spacing. In addition, the techniques delivered near perfect virtual visualization of other imaging features such as erosional effects in fossil and comparative modern bone, insect modification, internal cortical and trabecular morphology, osseous proliferation (osteophytosis), and medullary bone infills.

The techniques were extremely valuable, achieving a resolution of <10 microns (µm), in one of the reported cases in this study (such as in osteosarcoma), a level of resolution approaching that of thin section histology, but without the destruction of specimens. Under normal circumstances this internal bone analysis would not be available for study, as the only option to study the internal structures of fossils would have been to use invasive techniques, such as thin section histology, resulting in the destruction of iconic and other hominin specimens currently protected under South African heritage legislation.

The use of microtomographic imaging techniques in this study has helped to expose a number of new diseases in fossilized hominin bone that were not previously known. These include demonstrating that ante-mortem bone remodeling reported by previous researchers (e.g., D'Anastasio *et al*. 2009), as evidence for possible infectious disease, has been caused by postmortem

processes. Through microtomographic techniques, our results suggest that the areas described as pathological expressions of infection, are in fact post-mortem modifications made by insects or areas exhibiting degenerative joint disease. In contrast to the techniques used by D'Anastasio *et al*. (2009) which included examination of surface morphology using two types of electron microscopy, micro-CT techniques were applied to accomplish substantially higher resolutions than those achieved in prior studies with three-dimensional functionality, to model previously identified lesions. No prior studies have applied micro-CT to analyse the surface bone of StW 431, and up to now, no insect traces have been reported on StW 431.

In summary, the value of microtomographic imaging techniques used in this study included several benefits for this research project and for the science of palaeopathology in general. It was primarily non-destructive, allowing for the easy storage of data files. It was convenient to re-apply and share imaging files with other researchers and palaeopathologists. Secondly, it was a superior and an efficient technique to investigate and map internal fossil bone structures non-invasively, and allowed for rapid data acquisition at substantially high resolutions and improved image contrast capability.

5.4 Limitations of the study

The study of palaeopathology has several limitations including the complexities of differing risks amongst different individuals and populations with regard to diseases and mortality, and the natural behavioural patterns of populations to be constantly on the move (Wood *et al*., 1992). There are also several biases and limitations that affect fossil remains, excavation methods, and survivability of fossil specimens (Pinhasi and Mays 2008).

The study of diseases in prehistory can be approached in a number of ways and has evolved over time from observing surface pathologies of bone, to invasive histological methods. The next level up in the scale of methods

included the use of conventional medical radiology to investigate the internal structure of fossil bone. This ultimately led to a substantial improvement in technology, culminating in non-invasive three-dimensional imaging methods to examine the internal biology of abnormal bone, with each methodology having its own characteristics and skill sets, but also having limitations.

Fossil and other skeletal material are subject to various kinds of damage risk, including the inadvertent kind occasioned by researchers during research, and scanning damage, representing probable limitations to the study of fossil bone. A direct example in this study for example that caused a limitation was curational damage to a skeletal vertebral specimen, rendering it unusable for a research case study due to damage of the margins. Microtomographic imaging of the margins in this particular instance would be critical for diagnosis, and as the margins were broken, any possibility of an accurate diagnosis was lost.

Palaeontologists have a distinct advantage though of being able to examine original fossil bone material of the human ancestral lineage. However, the key drawback to this study, as is of other palaeopathological investigations, is that they are largely focused on diseases and pathological conditions affecting dry bone and fossil remains. Bone diseases are inherently rare, because the majority of diseases affect soft tissue (Waldron 2008), and we are therefore usually unable to determine the cause of death of an individual. The limitations of using fragmentary fossil bone remains to identify disease markers and palaeopathological expression in hominin populations of the South African Plio-Pleistocene is associated with a well-known complication in palaeopathology - the lack of a true Plio-Pleistocene hominin population as sample sizes are small and the time span huge. As a result, no epidemiological studies can be performed, and no hypotheses as to the status of health of these hominins can be developed.

As internal pathological changes in skeletal remains are not always readily observable from the surface of bone specimens, this could have

implications for accurately estimating the prevalence of pathological conditions in palaeopathological assemblages. This can easily result in overlooking potential pathology from 'healthy' looking bone or fossil specimens because it is not readily observable from the surface. Palaeopathological researchers tend to only scan / image clearly abnormal looking specimens. and may overlook those seemingly healthy specimens that may have internal pathology.

Added to observer error, there are other inherent problems in palaeopathology. Biased reporting could result in rare conditions being over stated. An unusual diagnosis tends to be published more than ordinary diseases and could affect the true prevalence rate. Moreover, pathological expressions may have changed as a direct result of modifications in the characteristics of the host of the pathogen, and pathogenic virulence may have also changed in different time periods (Pinhasi and Mays 2008).

Intrinsic to palaeopathological studies is the presupposition that gross skeletal expression of modern diseases is similar if not identical to those in prehistory (Grauer 2008), but the large body of work within clinical medicine, parasitological, immunological and other studies suggest that pathogens and their host-pathogen linkages have evolved considerably over time (Klepinger 2003; Grauer 2008). The pattern of human disease is therefore not unalterable nor static (Klepinger 2003). Human diseases are subject to extreme evolutionary pressure, with evolution towards stability controlled by random mutations, seeming to occur with every new infection. Therefore, some diseases have the capacity to change their expression, others to die out, and new ones to emerge (Read and Keeling 2003).

Although the latest microtomographic methods are improving the quality of differential diagnosis with the benefit of high resolution imaging, one of the significant limitations in this study was the poor quality of the comparative human radiographic and fossil clinical CT images in the published literature, where internal bone structures were unclear and

blurred. However, it is also clear that without the conservation of internal biological elements, such as vascular channels, sclerosis, and bone morphology trabeculae, even the best imaging techniques would not be able to resolve this limitation.

8.5 Future directions

Despite the limitations that many researchers face in palaeopathological studies, which revolve mainly around the accurate description, diagnosis, and interpretation of pathological lesions in hominin bone, this and other studies have exposed many new and interesting osteopathological phenomena. It is important to continue to find new techniques to strengthen macroscopic, microscopic, and microtomographic methods. This would include being supportive of novel imaging ideas that may arise in the future, to assist in the investigation and analyses of pathology in hominin skeletal material. It is also necessary to apply multiple pathways of evidence, mobilize multiple collaborative research teams, and continue to look for higher resolution imaging capability to examine skeletal material, until the resolution achieves sub-micron (µm) level, putting it on a par with histological thin sectioning (Pinhasi and Mays 2008). Synthesizing multiple types of data including cultural, biomolecular and palaeopathological data are the types of objectives to work towards when investigating fossil hominin assemblages for prehistoric disease markers.
An example of hominin pathology identified in this project was hip joint osteoarthritis in a proximal femur from an australopithecine specimen from Makapansgat (MLD 46). It has been diagnosed and reported in a podium abstract by Haesler *et al*. (2015) at the 84th Annual Meeting of the American Association of Physical Anthropologists in 2015. As a result, this specimen was excluded as a possible case study from this project, but can be explored further in future and may shed light on life style of South African Plio-Pleistocene hominins.

Looking into the future, studies of ancient DNA in palaeopathology have the potential to answer important questions pertaining to both human

disease and host-parasite evolution. It is widely acknowledged that this research field is fraught with difficulty such as high fragmentation, and modern contamination. Despite major advances in biomolecular studies however, the broader debates over published ancient DNA results, have not always been very favourably received (Rühli *et al*. 2016). The potential of these methods is of course limited in fully fossilized remains.

Work in ancient biomes may offer some promise for the future. Warinner *et al*. (2014) demonstrated through the use of dental calculus that the mouth cavity can be a rich reservoir for bacteria associated in both local and systemic disease, and could further be used to answer questions in taxonomy and protein characterization of the ancient oral microbiome. Dental calculus is an emerging archaeological source of host-associated biomolecules. Although there is a low proportion of mitochondrial DNA within dental calculus, its considerably higher total DNA content means dental calculus contains more DNA than dentine per milligram. The application to test this research in fossil hominin studies may well be an area worth looking at in the future.

Conclusion

In this study microtomographic methods were used to identify, describe, analyse and interpret disease conditions in eight South African Plio-Pleistocene hominin assemblages from the Cradle of Humankind, South Africa. The study further illustrated how these advanced three-dimensional microtomographic imaging techniques can assist in delivering reliable diagnostic methods to analyse skeletal hominin disease and contribute to the field of palaeopathology. It was confirmed that the hominins of the Plio-Pleistocene of South Africa were affected by several pathological conditions including neoplasms, dental disease, spinal and degenerative joint disease and traumatic injury. This study also reported a number of conditions not described in hominins before - these included a possible example of the earliest hominin cancer as well as a benign neoplasm. It further reported on insect modification in an *Australopithecus*

africanus specimen from Sterkfontein Cave (StW 431), and the first descriptive analysis on a mandibular growth in *Homo naledi*.

Palaeopathological assessment in this study provided some insight and a unique glimpse into the life experiences of hominins in the Plio-Pleistocene period. It contributed to our understanding of the evolving patterns of disease, giving us a rare opportunity to peer into the prehistoric lives of hominins and observe some of the diseases that befell them. Some of these conditions would have affected their daily lives with others ultimately causing their death.

CHAPTER 9

REFERENCES

Ackerknecht, E.H. and Haushofer, L., 2016. A short history of medicine. JHU Press.

Ackerknecht, E.H., A short history of medicine, New York, 1955. Ackerknecht135A Short History of Medicine1955, p.135.

Amacher, A.L. and Eltomey, A., 1985. Spinal osteoblastoma in children and adolescents. Child's Nervous System, 1(1), pp.29-32.

Angel, J.L., 1984. Health as a crucial factor in the changes from hunting to developed farming in the eastern Mediterranean. Paleopathology at the Origins of Agriculture, pp.51-74.

Angel JL. 1981. History and development of paleopathology. American Journal of Physical Anthropology, 56(4), pp.509-15.

Angel JL. 1971. Early Neolithic skeletons from Çatal Hüyük: demography and pathology. Anatolian Studies, 1, pp.77-98.

Angel, JL. 1967. Porotic hyperostosis or osteoporosis symmetrica. Diseases in antiquity, pp.378-389.

Angel JL 1966. Porotic hyperostosis anemia, malaria and marshes in the prehistoric Eastern Mediteranean. Science 153, pp.760-763.

Armelagos GJ. 1997. Paleopathology. History of Physical Anthropology. New York: Garland, pp.790-6.

Armelagos, G.J., Barnes, K.C. and Lin, J., 1996. Disease in human evolution: the re-emergence of infectious disease in the third epidemiological transition. National Museum of Natural History Bulletin for Teachers, 18(3), pp.1-6.

Armelagos GJ, Carlson DS, van Gerven DP. 1982. The theoretical foundation and development of skeletal biology. In A History of American Physical Anthropology, 1930–1980, Spencer F (ed.). Academic Press: New York; 305–328.

Armelagos, G.J., 2003. Bioarchaeology as Anthropology. Archaeological Papers of the American Anthropological Association, 13(1), pp.27-40.

Armelagos, G.J. and Gerven, D.P.V., 2003. A century of skeletal biology and paleopathology: contrasts, contradictions, and conflicts. American Anthropologist, 105(1), pp.53-64.

Armitage, P. and Doll, R., 1954. The age distribution of cancer and a multi-stage theory of carcinogenesis. British journal of cancer, 8(1), p.1.

Assis, S., Keenleyside, A., Santos, A.L., Cardoso, F.A., 2015. Bone diagenesis and its implication for disease diagnosis: the relevance of bone microstructure analysis for the study of past human remains microscopy and microanalysis: the official Journal of Microscopy Society of America, Microbeam Analysis Society. Microsc. Soc. Can. 21 (4), 805–825.

Assoun, J., Richardi, G., Railhac, J.J., Baunin, C., Fajadet, P., Giron, J., Maquin, P., Haddad, J. and Bonnevialle, P., 1994. Osteoid osteoma: MR imaging versus CT. Radiology, 191(1), pp.217-223.

Audy, J.R. and Dunn, F.L., 1974. Health and disease. Human ecology, pp.325-43.

Aufderheide, A.C., Rodríguez-Martín, C. and Langsjoen, O., 1998. The Cambridge encyclopedia of human paleopathology. Cambridge University Press.

Azouz, E.M., Kozlowski, K., Marton, D., Sprague, P., Zerhouni, A. and Asselah, F., 1986. Osteoid osteoma and osteoblastoma of the spine in children. Pediatric radiology, 16(1), pp.25-31.

Backwell, L.R., Parkinson, A.H., Roberts, E.M., d'Errico, F. and Huchet, J.B., 2012. Criteria for identifying bone modification by termites in the fossil record. Palaeogeography, Palaeoclimatology, Palaeoecology, 337, pp.72-87.

Bahk Y-W. 2007. Combined scintigraphic and radiographic diagnosis of bone and joint diseases. New York: Springer.

Balto, K., Müller, R., Carrington, D. C., Dobeck, J., Stashenko, P. 2000. Quantification of periapical bone destruction in mice by micro-computed tomography. Journal of Dental Research, 79(1), pp.35-40.

Barbier, A., Martel, C., De Vernejoul, M.C., Tirode, F., Nys, M., Mocaer, G., Morieux, C., Murakami, H. and Lacheretz, F., 1999. The visualization and evaluation of bone architecture in the rat using three-dimensional X-ray microcomputed tomography. Journal of bone and mineral metabolism, 17(1), pp.37-44.

Barnes, L. ed., 2005. Pathology and genetics of head and neck tumours. IARC.

Bart, Z.R. and Wallace, J.M., 2013. Microcomputed tomography applications in bone and mineral research.

Beckett, R.G. and Conlogue, G.J. 2010. Paleoimaging: Field Applications for Cultural Remains and Artifacts. Boca Raton: Taylor and Francis Group.

Beachley M.C.1977. Vascular Tumors of Bone. In: Ranniger K. (eds) Bone Tumors. Handbuch der Medizinischen Radiologie / Encyclopedia of Medical Radiology, vol 5 / 6. Springer, Berlin, Heidelberg.

Bennike P. 2003. Ancient trepanations and differential diagnosis: a re-evaluation of skeletal remains from Denmark. In Trepanation: History, Discovery, Theory, Arnott R, Finger S, Smith CUM (eds). Swets & Zeitlinger: Lisse; 95–116.

Bennike P. 1985. Paleopathology of Danish skeletons. Copenhagen, Denmark: Akademisk Forlag.

Berger, L.R., Hawks, J., Dirks, P.H.G.M., Elliott, M., Roberts, E.M., 2017. *Homo naledi* and Pleistocene hominin evolution in subequatorial Africa. eLife 6, e24234.

Berger, L.R., Hawks, J., de Ruiter, D.J., Churchill, S.E., Schmid, P., Delezene, L.K., Kivell, T.L., Garvin, H.M., Williams, S.A., DeSilva, J.M. and Skinner, M.M., 2015. *Homo naledi*, a new species of the genus *Homo* from the Dinaledi Chamber, South Africa. Elife, 4, p.e09560.

Berger, L.R., De Ruiter, D.J., Churchill, S.E., Schmid, P., Carlson, K.J., Dirks, P.H. and Kibii, J.M., 2010. *Australopithecus sediba*: a new species of *Homo*-like australopith from South Africa. Science, 328(5975), pp.195-204.

Berger TD, Trinkaus E. 1995. Patterns of trauma among the Neandertals. J Archaeol Sci 22, pp.841–852.

Betz, O., Wegst, U., Weide, D., Heethoff, M., Helfen, L., LEE, W.K. and Cloetens, P., 2007. Imaging applications of synchrotron X-ray phase-contrast microtomography in biological morphology and biomaterials science. I. General aspects of the technique and its advantages in the analysis of millimetre-sized arthropod structure. Journal of Microscopy, 227(1), pp.51-71.

Binder, M., Roberts, C., Spencer, N., Antoine, D. and Cartwright, C., 2014. On the antiquity of cancer: Evidence for metastatic carcinoma in a young man from Ancient Nubia (c. 1200BC). PloS one, 9(3), p.e90924.

Binning M, Klimo Jr P, Gluf W, Goumnerova L. 2007. Spinal tumors in children. Neurosurg Clin N Am., 18(4), pp.631–658.

Blakey ML, Armelagos GJ. 1997. Comment on ‘‘Hypoplastic area method for analyzing enamel hypoplasia’’ B.E. Ensor and J.D. Irish, American Journal of Physical Anthropology (1995) 98, pp.507–517. Am J Phys Anthropol 102:295–299.

Böni, T., Rühli, F.J. and Chhem, R.K., 2004. History of paleoradiology: early published literature, 1896-1921. Canadian Association of Radiologists Journal, 55(4), p.203.

Boriani, S., Capanna, R., Donati, D., Levine, A., Picci, P. and Savini, R., 1992. Osteoblastoma of the Spine. Clinical orthopaedics and related research, 278, pp.37-45.

Bloem, J.L. and H.M. Kroon. 1993.*Osseous lesions.* Radiol Clin North Am, 31(2), p. 261-78.

Bloom, D.W. and Fawcett, A. 1994. A Textbook of Histology (12th edition). New York: Chapman and Hall.

Bombin, M., 1990. Transverse enamel hypoplasia on teeth of South African Plio-Pleistocene hominids. Naturwissenschaften, 77(3), pp.128-129.

Braga, J. and Thackeray, J.F., 2003. Early *Homo* at Kromdraai B: probabilistic and morphological analysis of the lower dentition. Comptes Rendus Palevol, 2(4), pp.269-279.

Brain, C.K., 1970. New finds at the Swartkrans australopithecine site. Nature, 225(5238), pp.1112-1119.

Brickley, M. and McKinley, J.I., 2004. Guidelines to the standards for recording human remains. IFA paper, 7.

Britz, H.M., Jokihaara, J., Leppänen, O.V., Järvinen, T. and Cooper, D.M.L., 2010. 3D visualization and quantification of rat cortical bone porosity using a desktop micro-CT system: a case study in the tibia. Journal of microscopy, 240(1), pp.32-37.

Brody H. Colorectal cancer. Nature. 2015, p.521.

Bowen, D.K., Elliott, J.S., Stock, S.R. and Dover, S.D., 1986, August. X-ray microtomography with synchrotron radiation. In X-ray imaging II (Vol. 691, pp. 94-99). International Society for Optics and Photonics.

Broom, R. and Robinson, J.T., 1949. A new type of fossil man. Nature, 164(4164), pp.322-322.

Brothwell, D., 2016. Tumors: problems of differential diagnosis in paleopathology. Chapter 23. In: Grauer, A.L. (Ed.), A Companion to Paleopathology. Wiley, Chichester, UK, pp. 420–433.

Brothwell, D. 1969. The palaeopathology of Pleistocene and more recent mammals. Brothwell, D. and Higgs, E. Science in Archaeology: a survey of progress and research. Thames and Hudson, London, pp.31-314.

Brothwell, D.R., 1963. Macroscopie Dental Pathology of Some Earlier Human Populations. In:" Symposia of the Society for the Study of Human Biology, Dr. Brothwell (Editor).

Brothwell, D. and Sandison, A.T., 1967. Diseases in antiquity. A survey of the diseases, injuries and surgery of early populations. Diseases in antiquity. A survey of the diseases, injuries and surgery of early populations.

Brothwell, D.R., 1959. Teeth in earlier human populations. Proceedings of the Nutrition Society, 18(01), pp.59-65.

Buffière, J.Y., Maire, E., Cloetens, P., Lormand, G., Fougères, R. 1999. Acta Mater. 47, 1613.

Buikstra, J.E., and Beck., L.A. eds., 2006. Bioarchaeology: The Contextual Analysis of Human Remains. New York: Academic Press.

Buikstra, J.E., Cook, D.C. and Bolhofner, K.L., 2017. Introduction: Scientific rigor in paleopathology. International Journal of Paleopathology.

Buikstra, J.E. and Roberts, C. eds., 2012. The global history of paleopathology: pioneers and prospects. Oxford University Press on Demand.

Buikstra, J.E., 2010. Paleopathology: A Contemporary. A Companion to Biological Anthropology, 20, p.395.

Buikstra, J.E. and Cook, D.C., 1980. Palaeopathology: an American account. Annual Review of Anthropology, 9(1), pp.433-470.

Buikstra, J.E. and Ubelaker, D.H., 1994. Standards for data collection from human skeletal remains: proceedings of a seminar at the Field Museum of Natural History.

Burchill S. Ewing's sarcoma: diagnostic, prognostic, and therapeutic implications of molecular abnormalities. 2003. Journal of Clinical Pathology, 56(2), pp.96-102.

Burkitt, D.P., 1971. Epidemiology of cancer of the colon and rectum.

Burnet FM. 1962. Natural History of Infectious Disease. Cambridge, UK: Cambridge Univ. Press.

Byers, S.N. and Roberts, C.A., 2003. Bayes' theorem in paleopathological diagnosis. American journal of physical anthropology, 121(1), pp.1-9.

Capasso, L.L., 2005. Antiquity of cancer. International journal of cancer, 113(1), pp.2-13.

Capasso, L. 1997. *Osteoma: palaeopathology and phylogeny.* International Journal of Osteoarchaeology, 7(6), pp. 615-620.

Carlson, K.J., Stout, D., Jashashvili, T., De Ruiter, D.J., Tafforeau, P., Carlson, K. and Berger, L.R., 2011. The endocast of MH1, Australopithecus sediba. Science, 333(6048), pp.1402-1407.

Carrera, G.F., Haughton, V.M., Syvertsen, A. and Williams, A.L., 1980. Computed tomography of the lumbar facet joints. Radiology, 134(1), pp.145-148.

Carlton, R.R, and Adler, A.M. 2001. Principles of Radiographic Imaging: an art and a science. Amerika Serikat: Delman

Carter, J.T., 1928. The teeth of Rhodesian man. Rhodesian Man and Associated Remains, 64.

Cesarani, F., Martina, M.C., Ferraris, A., Grilletto, R., Boano, R., Marochetti, E.F., Donadoni, A.M. and Gandini, G., 2003. Whole-body three-dimensional multidetector CT of 13 Egyptian human mummies. American Journal of Roentgenology, 180(3), pp.597-606.

Chamberlain, A., 2009. Archaeological demography. Human Biology, 81(2-3), pp.275-286.

Chamberlain AT. 2006. Demography in archaeology. Cambridge: Cambridge University Press.

Chhem, R.K., 2006. Paleoradiology: imaging disease in mummies and ancient skeletons. Skeletal radiology, 35(11), pp.803-804.

Chhem, R.K. and Brothwell, D.R., 2008. Paleoradiology. Imaging mummies and fossils. Berlin: Springer.

Chhem RK, Venkatesh SK, Wang SC, et al. 2004. Multislice computed tomography of two 2000-year-old skeletons in a soil matrix from Angkor, Cambodia. Can Assoc Radiol J, 55(4), pp.235–241.

Clement, A.J., 1956. Caries in the South African apeman: some examples of undoubted pathological authenticity believed to be 800,000 years old. Brit. Dent. J., 101, pp.4-7.

Cloetens, P., Ludwig, W., Baruchel, J., Van Dyck, D., Van Landyut, J., Guigay, J.P. & Schlenker, M. 1999. Holotomography: quantitative phase tomography with micrometer resolution using hard synchrotron radiation x-rays. Appl. Phys. Lett. 75, pp.2912–2914.

Cloetens, P., Pateyron-Salomé, M., Buffière, J.Y., Peix, G., Baruchel, J., Peyrin, F., Schlenker, M. 1997. J. Appl. Phys. 81, 5878.

Cloetens, P., Barrett, R., Baruchel, J., Guigay, J.-P. & Schlenker, M. 1996a. Phase objects in synchrotron radiation hard X-ray imaging. J Phys D Appl Phys 29, pp.133–146.

Cockburn, T.A., 1971. Infectious diseases in ancient populations. Current Anthropology, 12(1), pp.45-62.

Cockburn, T.A., 1963. The evolution and eradication of infectious diseases. Perspectives in biology and medicine, 7(4), pp.498-499.

Cohen, M. N., 1994 The Osteological Paradox Reconsidered. Current Anthropology 35, pp.629–631.

Cohen, M. N., 1997. Does Paleopathology Measure Community Health? A Rebuttal of “The Osteological Paradox” and Its Implication for World History. In Integrating Archaeological Demography: Multidisciplinary Approaches to Prehistoric Population. R. R. Paine, ed. pp. 242–260. Occasional Paper 24. Carbondale: Center for Archaeological Investigations, Southern Illinois University.

Cohen, M.N. and Armelagos, G.J., 1984. Paleopathology at the origins of agriculture: Editor's summation.

Cohen MN, Crane-Kramer GMM. (eds) 2007. Ancient Health: Skeletal Indicators of Agricultural and Economic Intensification. Gainesville, Florida: Florida University Press.

Cohen, M.N., Wood, J.W. and Milner, G.R., 1994. The osteological paradox reconsidered.

Conlogue, G., Beckett, R. and Posh, J., 2010. Computer based imaging. Beckett, RG–Conlogue, GJ: Paleoimaging. Field applications for cultural remains and artifacts. Boca Raton: Taylor & Francis Group, pp.123-184.

Conroy, G.C. and Vannier, M.W., 1987. Dental development of the Taung skull from computerized tomography. Nature, 329(6140), pp.625-627.

Cook DC, Powell ML. 2006. The evolution of American paleopathology. Bioarchaeology: the contextual analysis of human remains. Amsterdam: Academic Press. pp.281-323.

Cook, D.C., Buikstra, J.E., DeRousseau, C.J. and Johanson, D.C., 1983. Vertebral pathology in the Afar australopithecines. American Journal of Physical Anthropology, 60(1), pp.83-101.

Cotterill, J., 2003. Language and power in court: A linguistic analysis of the OJ Simpson trial. Springer.

Crubézy, E. and Trinkaus, E., 1992. Shanidar 1: a case of hyperostotic disease (DISH) in the middle Paleolithic. American Journal of Physical Anthropology, 89(4), pp.411-420.

Curnoe, D. and Brink, J., 2010. Evidence of pathological conditions in the Florisbad cranium. Journal of human evolution, 59(5), pp.504-513.

Czarnetzki, A., Jakob, T. and Pusch, C.M., 2003. Palaeopathological and variant conditions of the *Homo heidelbergensis* type specimen (Mauer, Germany). Journal of human evolution, 44(4), pp.479-495.

D'Anastasio, R., Zipfel, B., Moggi-Cecchi, J., Stanyon, R. and Capasso, L., 2009. Possible brucellosis in an early hominin skeleton from Sterkfontein, South Africa. PLoS One, 4(7), p.e6439.

Dahlin, D.C., Cupps, R.E. and Johnson, E.W., 1970. Giant-cell tumor: A study of 195 cases. Cancer, 25(5), pp.1061-1070.

Dart, R.A., 1954. The adult female lower jaw from Makapansgat. American Anthropologist, 56(5), pp.884-888.

David, A.R. and Zimmerman, M.R., 2010. Cancer: an old disease, a new disease or something in between? Nature Reviews Cancer, 10(10), pp.728-733.

Dawson, J.E. and Trinkaus, E., 1997. Vertebral osteoarthritis of the La Chapelle-aux-Saints 1 Neanderthal. Journal of Archaeological Science, 24(11), pp.1015-1021.

Davies, P.C. and Lineweaver, C.H., 2011. Cancer tumors as Metazoa 1.0: tapping genes of ancient ancestors. Physical biology, 8(1), p.015001.

Day, M.H. and Molleson, T.I., 1973. The Trinil femora. In Symposia of the Society for the Study of Human Biology (Vol. 2, pp. 127-154).

Del Bino, S., Bernerd, F., 2013. Variations in skin colour and the biological consequences of ultraviolet radiation exposure. Br. J. Dermatol. 169 (Suppl 3), 33–40.

Desmond, A., 1992. The politics of evolution: Morphology, medicine, and reform in radical London. University of Chicago Press.

De Ruiter, D.J., 2003. Revised faunal lists for Members 1-3 of Swartkrans, South Africa. Annals of the Transvaal Museum, 40(1), pp.29-41.

De Souza, S.M., Carvalho, D. M.D., and Lessa, A. (2003). Paleoepidemiology: is there a case to answer? Memórias do Instituto Oswaldo Cruz, 98, 21-27.

Dierick, M., Cnudde, V., Masschaele, B., Vlassenbroeck, J., Van Hoorebeke, L. & Jacobs, P. 2007. Micro-CT of fossils preserved in amber. Nucl Instrum Methods A 580, pp.641–643.

Dirks, P.H., Berger, L.R., Roberts, E.M., Kramers, J.D., Hawks, J., Randolph-Quinney, P.S., Elliott, M., Musiba, C.M., Churchill, S.E., de Ruiter, D.J. and Schmid, P., 2015. Geological and taphonomic context for the new hominin species *Homo naledi* from the Dinaledi Chamber, South Africa. Elife, 4, p.e09561.

Dirks PHGM, Kibii JM, Kuhn BF, Steininger C, Churchill SE, Kramers JD, et al. Geological setting and age *of Australopithecus sediba* from Southern Africa. Science. 2010, 328(5975), pp.205–208.

Dirks, P.H.G.M., Berger, L.R., Hawks, J., Randolph-Quinney, P.S., Backwell, L.R. and Roberts, E.M., 2016. Deliberate body disposal by hominins in the Dinaledi Chamber, Cradle of Humankind, South Africa? Journal of human evolution, 30, p.1e5.

Dittmann, K. and Grupe, G., 2000. Biochemical and palaeopathological investigations on weaning and infant mortality in the early Middle Ages. Anthropologischer Anzeiger, pp.345-355.

Domínguez-Rodrigo, M., Pickering, T.R., Diez-Martín, F., Mabulla, A., Musiba, C., Trancho, G., Baquedano, E., Bunn, H.T., Barboni, D., Santonja, M. and Uribelarrea, D., 2012. Earliest porotic hyperostosis on a 1.5-million-year-old hominin, Olduvai Gorge, Tanzania. PloS one, 7(10), p.e46414.

Donoghue, H.D. 2008. Molecular paleopathology of human infectious disease. In S. Mays and R. Pinhasi (Eds.), Advances in Human Palaeopathology (pp. 147-176). West Sussex: John Wiley and Sons Ltd.

Dubois, E., 1937. 1. On the Fossil Human Skulls Recently Discovered in Java and *Pithecanthropus Erectus*. Man, pp.1-7.

Duday H, Arensburg B. 1991. La pathologie. In: Bar-Yosef O, Vandermeersch B, editors. Le Squelette Mouste´rien de Ke´bara 2. Paris: C.N.R.S. p 179–193.

Eaton, S.B., Pike, M.C., Short, R.V., Lee, N.C., Trussell, J., Hatcher, R.A., Wood, J.W., Worthman, C.M., Jones, N.G., Konner, M.J., et al., 1994. Women's reproductive cancers in evolutionary context. Q. Rev. Biol. 69 (3), pp.353–367.

Eaton, G.F., 1916. The collection of osteological material from Machu Picchu (Vol. 5). Tuttle, Morehouse & Taylor Company.

Eggl, E., Schleede, S., Bech, M., Achterhold, K., Loewen, R., Ruth, R.D. and Pfeiffer, F., 2015. X-ray phase-contrast tomography with a compact laser-driven synchrotron source. Proceedings of the National Academy of Sciences, 112(18), pp.5567-5572.

Eisenberg, R.L., 2009. Bubbly lesions of bone. American Journal of Roentgenology, 193(2), pp.W79-W94.

Ensor BE, Irish JD. 1995. Hypoplastic area method for analysing dental enamel hypoplasia. Am J Phys Anthropol 98, pp.507–517.

Eshed V, Latimer B, Greenwald CM, Jellema LM, Rothschild BM, Wish-Baratz S, et al. 2002. Button osteoma: Its etiology and pathophysiology. Am J Phys Anthropol., 118(3), pp. 217–230.

Ewald, P.W., International Journal of Paleopathology. 2017. *Article in press.*

Fédération Dentaire International. 1992. A review of the developmental defects of enamel index (DDE Index). Commission on oral health, research & epidemiology: report of an FDI working group. Int Dent J 42, pp.411–426.

Feldkamp, L.A., Goldstein, S.A., Parfitt, A.M. et al. 1989. The direct examination of bone architecture in vitro by computed tomography. Bone, 4, pp.3-11.

Fennell, K.J. and Trinkaus, E., 1997. Bilateral femoral and tibial periostitis in the La Ferrassie 1 Neanderthal. Journal of Archaeological Science, 24(11), pp.985-995.

Ferring, R., Oms, O., Agustí, J., Berna, F., Nioradze, M., Shelia, T., Tappen, M., Vekua, A., Zhvania, D. and Lordkipanidze, D., 2011. Earliest human occupations at Dmanisi (Georgian Caucasus) dated to 1.85–1.78 Ma. Proceedings of the National Academy of Sciences, 108(26), pp.10432-10436.

Fernandez, V., Buffetaut, E., Suteethorn, V., Rage, J.C., Tafforeau, P. and Kundrát, M., 2015. Evidence of egg diversity in squamate evolution from Cretaceous anguimorph embryos. PloS one, 10(7), p.e0128610.

Filer J. Disease. 1995. London: British Museum Press.

Fiori, M.G. and Nunzi, M.G., 1995. The earliest documented applications of X-rays to examination of mummified remains and archaeological materials. Journal of the Royal Society of Medicine, 88(2), p.67.

Fisk, G.R. and Macho, G.A., 1992. Evidence of a healed compression fracture in a Plio-Pleistocene hominid talus from Sterkfontein, South Africa. International Journal of Osteoarchaeology, 2(4), pp.325-332.

Fletcher, C.D., Berman, J.J., Corless, C., Gorstein, F., Lasota, J., Longley, B.J., Miettinen, M., O'leary, T.J., Remotti, H., Rubin, B.P. and Shmookler, B., 2002. Diagnosis of gastrointestinal stromal tumors: a consensus approach. Human pathology, 33(5), pp.459-465.

Fletcher, C.D., Unni, K.K. and Mertens, F. eds., 2002. Pathology and genetics of tumours of soft tissue and bone (Vol. 4). Iarc.

Franklin, R.D., 2011. The recognition, frequency, and taxonomic association of skeletal pathology from selected Plio-Pleistocene-aged sites from the Cradle of Humankind, Witwatersrand, South Africa (unpublished doctoral dissertation, University of the Witwatersrand).

Gartner, L.P. and Hiatt, J.L. (2007). Color Textbook of Histology. Philadelphia: Saunders Elsevier.

Gedgaudas-McClees, R. K., and Torres, W. E. 1990. Essentials of Body Computed Tomography. Philadelphia: WB Saunders.

Gerner, C.S., Dolan, A., and McGeoch, D.J., 2004. Phylogenetic relationships in the Lymphocryptovirus genus of the Gammaherpesvirinae. Virus Res. 99 (2), pp.187–192.

Gibson, K.R. and Calcagno, J.M., 1993. Brief communication: possible third molar impactions in the hominid fossil record. American journal of physical anthropology, 91(4), pp.517-521.

Gluckman, P.D., Low, F.M., Buklijas, T., Hanson, M.A. and Beedle, A.S., 2011. How evolutionary principles improve the understanding of human health and disease. Evolutionary Applications, 4(2), pp.249-263.

Goldman, L.W., 2007. Principles of CT and CT technology. Journal of nuclear medicine technology, 35(3), pp.115-128.

Goldman, L., 2000. Principles of CT and Evolution of CT Technology: CT and US Cross-Sectional Imaging. In Categorical Course in Diagnostic Radiology Physics. L. Goldman, W., and Fowlkes, J.B. eds. pp. 33–52. Oak Brook, IL: Radiological Society of North America.

Goodman, A. H., 1993. On the Interpretation of Health from Skeletal Remains. Current Anthropology 34,2 pp.81–288.

Goodman, A.H. and Armelagos, G.J. 1989. Infant and childhood morbidity and mortality risks in archaeological populations. World Archaeology, 21(2), 225-243.

Goodman, A.H. and Leatherman, T.L., 1998. Building a new biocultural synthesis: political-economic perspectives on human biology. University of Michigan Press.

Goodman, A.H., Martin, D.L., Armelagos, G.J. and Clark, G., 1984. Indications of Stress from Bone and Teeth. In: Paleopathology at the Origins of Agriculture.

Goodman, A. H., and Martin, D. L., 2002 Reconstructing Health Profiles from Skeletal Remains. In: The Backbone of History: Health and Nutrition in the Western Hemisphere. R. H. Steckel, and J. C. Rose, eds. pp. 11–60. Cambridge: Cambridge University Press.

Gordon, C. C., and Buikstra, J. E. 1981. Soil pH, bone preservation, and sampling bias at mortuary sites. American Antiquity, 566-571.

Gracia, A., Arsuaga, J.L., Martínez, I., Lorenzo, C., Carretero, J.M., de Castro, J.M.B. and Carbonell, E., 2009. Craniosynostosis in the Middle Pleistocene human

cranium 14 from the Sima de los Huesos, Atapuerca, Spain. Proceedings of the National Academy of Sciences, 106(16), pp.6573-6578.

Grauer, A.L., 2012. A companion to paleopathology. John Wiley & Sons.

Grauer, A.L., 2008. Macroscopic analysis and data collection in palaeopathology. In: Advances in Human Palaeopthology. Chapter 4. Eds. R. Pinhasi & S. Mays. John Wiley & Sons, Ltd, pp.57-76.

Greenspan, A., 1993. Benign bone-forming lesions: osteoma, osteoid osteoma, and osteoblastoma. Skeletal radiology, 22(7), pp.485-500.

Grenfell, B.T., Pybus, O.G., Gog, J.R., Wood, J.L., Daly, J.M., Mumford, J.A. and Holmes, E.C., 2004. Unifying the epidemiological and evolutionary dynamics of pathogens. science, 303(5656), pp.327-332.

Grine, F.E., 1993. Description and preliminary analysis of new hominid craniodental fossils from the Swartkrans Formation. Swartkrans: A Cave's Chronicle of Early Man. Transvaal Museum, Pretoria, pp.75-116.

Grine, F.E., Gwinnett, A.J. and Oaks, J.H., 1990. Early hominid dental pathology: interproximal caries in 1.5 million-year-old *Paranthropus robustus* from Swartkrans. Archives of Oral Biology, 35(5), pp.381-386.

Grine, F.E., 1989. New hominid fossils from the Swartkrans Formation (1979–1986 excavations): craniodental specimens. American Journal of Physical Anthropology, 79(4), pp.409-449.

Grine, F.E., 1982. A new juvenile hominid (Mammalia: Primates) from Member 3, Kromdraai Formation, Transvaal, South Africa. Annals of the Transvaal Museum, 33(11), pp.165-239.

Grine, F.E., 1981. A new composite juvenile specimen of *Australopithecus africanus* (Mammalia, Primates) from Member 4 Sterkfontein formation, Transvaal. Annals of the South African Museum. 84, pp.169- 201.

Grier, H.E., 1997. The Ewing family of tumors: Ewing's sarcoma and primitive neuroectodermal tumors. Pediatric Clinics of North America, 44(4), pp.991-1004.

Greenspan, A., Jundt, G. and Remagen, W., 2007. Differential diagnosis in orthopaedic oncology. Lippincott Williams & Wilkins.

Grupe, G. and Dörner, K., 1989. Trace elements in excavated human hair. Zeitschrift für Morphologie und Anthropologie, pp.297-308.

Guatelli-Steinberg, D., 2003. Macroscopic and microscopic analyses of linear enamel hypoplasia in Plio-Pleistocene South African hominins with respect to

aspects of enamel development and morphology. American Journal of Physical Anthropology, 120(4), pp.309-322.

Guise, T.A. and Mundy, G.R., 1998. Cancer and bone. Endocrine Reviews, 19(1), pp.18-54.

Guise, T.A., 2000. Molecular mechanisms of osteolytic bone metastases. Cancer, 88(S12), pp.2892-2898.

Guldberg, R.E., Ballock, R.T., Boyan, B.D., Duvall, C.L., Lin, A.S., Nagaraja, S., Oest, M., Phillips, J., Porter, B.D., Robertson, G. and Taylor, W.R., 2003. Analyzing bone, blood vessels, and biomaterials with microcomputed tomography. IEEE engineering in medicine and biology magazine, 22(5), pp.77-83.

Gurven, M., Kaplan, H., 2007. Longevity among hunter-gatherers: a cross-cultural examination. Popul. Dev. Rev. 33 (2), 321–365.

Gurven, M., Kaplan, H., Supa, A.Z., 2007. Mortality experience of Tsimane Amerindians of Bolivia: regional variation and temporal trends. Am. J. Hum. Biol. The Off. J. Hum. Biol. Counc. 19 (3), pp.376–398.

Haeusler, M., Landis, S. and Zipfel, B., 2015, March. Hip joint osteoarthritis in the MLD 46 (*Australopithecus africanus*) proximal femur. In American Journal of Physical Anthropology (Vol. 156, pp. 156-156). Wiley-Blackwell.

Hargreaves JA, Cleaton-Jones PE, Williams SD. 1989. Hypocalcification and hypoplasia in permanent teeth of children from different ethnic groups in South Africa assessed with a new index. Adv Dent Res 3, pp.126–131.

Harris, N.L., Jaffe, E.S., Diebold, J., Flandrin, G., Muller-Hermelink, H.K., Vardiman, J., Lister, T.A. and Bloomfield, C.D., 1999. World Health Organization classification of neoplastic diseases of the hematopoietic and lymphoid tissues: report of the Clinical Advisory Committee meeting—Airlie House, Virginia, November 1997. Journal of clinical oncology, 17(12), pp.3835-3849.

Harwood-Nash, D.C., 1979. Computed tomography of ancient Egyptian mummies. Journal of Computer Assisted Tomography, 3(6), pp.768.

Haas, C.J., Zink, A., Pálfi, G., Szeimies, U. and Nerlich, A.G., 2000. Detection of leprosy in ancient human skeletal remains by molecular identification of Mycobacterium leprae. American Journal of Clinical Pathology, 114(3), pp.428-436.

Hecht, S.S., 1999. Tobacco smoke carcinogens and lung cancer. J. Natl. Cancer Inst. 91(14), pp.1194–1210.

Hefner, J.T. and Ousley, S.D., 2006, February. Morphoscopic traits and the statistical determination of ancestry II. In Proceedings of the 58th Annual Meeting of the American Academy of Forensic Sciences (pp. 20-25).

Hoffman, J.W. and De Beer, F.C., 2012, April. Characteristics of the micro-focus x-ray tomography facility (MIXRAD) at Necsa in South Africa. In 18th World Conference on Nondestructive Testing (pp. 16-20).

Holdsworth, D.W. and Thornton, M.W. 2002. Micro-CT in small animal and specimen imaging. Trends in Biotechnology, 20, s1-s6.

Hoppa, R.D. 2002. Paleodemography: Looking back and thinking ahead. In Hoppa, R.D. and Vaupel, J.W. (Eds.), Paleodemography: Age Distributions from Skeletal Samples. (pp. 9-23) Cambridge: Cambridge University Press.

Hounsfield, G.N. 1973. Computerized transverse axial scanning (tomography): Part 1. Description of System, British Journal of Radiology, Vol. 46, No. 552, 1973, pp. 1016-1022.

Hrdlika A. 1909. Tuberculosis among certain Indian tribes of the United States. In Smithsonian Institution, Bureau of the American Ethnology, Bulletin 42. Washington, D.C.: Government Printing Office, pp.1-48. Bulletin.

Hsieh J. 2002. Computed Tomography. Principles, Design, Artifacts, and Recent Advances. SPIE: Bellingham, WA.

Hsu, J. L., Glaser, S. L., 2000. Epstein-barr virus-associated malignancies: epidemiologic patterns and etiologic implications. Crit. Rev. Oncol. Hematol. 34 (1), pp.27–53.

Hublin, J.J., 2001. Northwestern African Middle Pleistocene hominids and their bearing on the emergence of Homo sapiens. Human Roots, pp.99-121.

Hublin, J.J., 1985. Human fossils from the North African Middle Pleistocene and the origin of Homo sapiens. Ancestors: The hard evidence, pp.283-288.

Huss-Ashmore, R., Goodman, A.H. and Armelagos, G.J., 1982. Nutritional inference from paleopathology. Advances in archaeological method and theory, 5, pp.395-474.

Huvos A. Ewing's sarcoma. 1991. In: Huvos A, editor. Bone tumors: diagnosis, treatment and prognosis. 2nd ed. Philadelphia PA: Sanders; pp.523-552.

Huvos, A.G., 1986. Osteogenic sarcoma of bones and soft tissues in older persons. A clinicopathologic analysis of 117 patients older than 60 years. Cancer, 57(7), pp.1442-1449.

Jaffe, H. L.1958. Tumors and Tumorous Conditions of the Bones and Joints. Philadelphia: Lea and Febiger.

Janssens, P.A., 1970. Palaeopathology: diseases and injuries of prehistoric man. J. Baker.

Jarcho, S., 1966. Human paleopathology.

Johanson, D.C., Taieb, M. and Coppens, Y., 1982a. Pliocene hominids from the Hadar Formation, Ethiopia (1973–1977): stratigraphic, chronologic, and paleoenvironmental contexts, with notes on hominid morphology and systematics. American Journal of Physical Anthropology, 57(4), pp.373-402.

Jones J. 1876. Explorations of the aboriginal remains of Tennessee. Smithsonian Contributions to Knowledge, 259, pp.1-171.

Judd, M., Redfern, R. and Trauma, A.G., 2012. A Companion to Paleopathology.

Jurmain, R.D. and Kilgore, L., 1995. Skeletal evidence of osteoarthritis: a palaeopathological perspective. Annals of the rheumatic diseases, 54(6), p.443.

Jurmain, R.D., 1991. Paleopathology of trauma in a prehistoric central California population. Human Paleopathology: Current Synthesis and Future Options.

Jurmain, R., 1989. Trauma, degenerative disease, and other pathologies among the Gombe chimpanzees. American Journal of Physical Anthropology, 80(2), pp.229-237.

Kaiser, T.M., 2000. Proposed fossil insect modification to fossil mammalian bone from Plio-Pleistocene hominid-bearing deposits of Laetoli (Northern Tanzania). Annals of the Entomological Society of America, 93(4), pp.693-700.

Kappelman, J., Alçiçek, M.C., Kazancı, N., Schultz, M., Özkul, M. and Şen, Ş., 2008. First Homo erectus from Turkey and implications for migrations into temperate Eurasia. American Journal of Physical Anthropology, 135(1), pp.110-116.

Katzenberg, M.A. 2000. Stable isotope analysis: A tool for studying past diet, demography, and life history. In M.A. Katzenberg and S.R. Saunders (Eds.), Biological Anthropology of the Human Skeleton pp.305-327. New York: Wiley-Liss.

Katzenberg, M.A. and Lovell, N.C., 1999. Stable isotope variation in pathological bone. International Journal of Osteoarchaeology, 9(5), pp.316-324.

Kennedy, G.E., 1983a. Some aspects of femoral morphology in *Homo erectus*. Journal of Human Evolution, 12(7), pp.587-616.

Kerley, E.R. and Bass, W.M., 1967. Paleopathology: meeting ground for many disciplines. Science, 157(3789), pp.638-644.

Khurana JS. 2009. The surgical pathology of bone tumors and tumor-like lesions. In: Khurana JS, editor. Bone pathology. London: Humana Press, pp.285–345.

Kilgore, L., Jurmain, R. and Van Gerven, D., 1997. Palaeoepidemiological patterns of trauma in a medieval Nubian skeletal population. International Journal of osteoarchaeology, 7(2), pp.103-114.

Kinney, J.H., Lane, N.E., Haupt, D.L. 1995. In vivo, three-dimensional microscopy of trabecular bone. Journal of Bone and Mineral Research, 10(2), pp.264-270.

Kitching J. 980. On some fossil arthropoda from the limeworks Makapansgat, Potgietersrus. Palaeontol Afr. 1, 23(6), pp.63–68.

Kleihues, P. and Cavenee, W., 2000. World Health Organization classification of tumours. Pathology and genetics of tumours of the nervous system. IARC, Lyon.

Klepinger, L.L., 1983. Differential diagnosis in paleopathology and the concept of disease evolution. Medical anthropology, 7(1), pp.73-77.

Klepinger, L.L., 1980. The evolution of human disease: New findings and problems. Journal of biosocial science, 12(04), pp.481-486.

Kuhn, G., Schultz, M., Müller, R. and Rühli, F.J., 2007. Diagnostic value of micro-CT in comparison with histology in the qualitative assessment of historical human postcranial bone pathologies. HOMO-Journal of Comparative Human Biology, 58(2), pp.97-115.

Kuhn, J.L., Goldstein, S.A., Feldkamp, L.A., Goulet, R.W. and Jesion, G., 1990. Evaluation of a microcomputed tomography system to study trabecular bone structure. Journal of Orthopaedic Research, 8(6), pp.833-842.

Labiche, J.C., Mathon, O., Pascarelli, S., Newton, M.A., Ferre, G.G., Curfs, C., Vaughan, G., Homs, A. and Carreiras, D.F., 2007. Invited article: The fast readout low noise camera as a versatile x-ray detector for time resolved dispersive extended x-ray absorption fine structure and diffraction studies of dynamic problems in materials science, chemistry, and catalysis. Review of scientific instruments, 78(9), p.091301.

La Cruz, R.S., Rozzi, F.R. and Bromage, T.G., 2006. Variation in enamel development of South African fossil hominids. Journal of Human Evolution, 51(6), pp.580-590.

Laird, M.F., Schroeder, L., Garvin, H.M., Scott, J.E., Dembo, M., Radovčić, D., Musiba, C.M., Ackermann, R.R., Schmid, P., Hawks, J. and Berger, L.R., 2016. The skull of *Homo naledi*. Journal of human evolution.

Lak, M., Néraudeau, D., Nel, A., Cloetens, P., Perrichot, V. and Tafforeau, P., 2008. Phase contrast X-ray synchrotron imaging: opening access to fossil inclusions in opaque amber. Microscopy and microanalysis, 14(3), pp.251-259.

Lambert, J.B., Vlasak, S.M., Thometz, A.C., and Buikstra, J.E. 1982. A comparativestudy of the chemical analysis of ribs and femurs in Woodland populations. American Journal of Physical Anthropology, 59(3), 289-294.

Latimer, B. and Ohman, J.C., 2001, March. Axial dysplasia in *Homo erectus*. In Journal of Human Evolution (Vol. 40, No. 3, pp. A12-A12). 24-28 Oval Rd, London Nw1 7dx, England: Academic Press Ltd.

Leakey, L.S., Tobias, P.V. and Napier, J.R., 1964. A new species of the genus *Homo* from Olduvai Gorge. na.

Lebel, S. and Trinkaus, E., 2002. Middle Pleistocene human remains from the Bau de l'Aubesier. Journal of Human Evolution, 43(5), pp.659-685.

Leone, A., Aulisa, L., Tamburrelli, F., Lupparelli, S. and Tartaglione, T., 1994. Ruolo della tomografia computerizzata e della risonanza magnetica nella valutazione della artropatia degenerativa delle facette articolari lombari. Radiol Med, 88, pp.547-552.

Leshchinskiy, S.V., 2012. Paleoecological investigation of mammoth remains from the Kraków Spadzista Street (B) site. Quaternary International, 276, pp.155-169.

Lewin, P.K., Trogadis, J.E. and Stevens, J.K., 1990. Three-dimensional reconstructions from serial X-ray tomography of an Egyptian mummified head. Clinical Anatomy, 3(3), pp.215-218.

Lewis, M.E., Roberts, C.A. and Manchester, K., 1995. Comparative study of the prevalence of maxillary sinusitis in later medieval urban and rural populations in northern England. American Journal of Physical Anthropology, 98(4), pp.497-506.

Li, J., Djenaba, J.A., Soman, A., Rim, S.H., Master, V.A., 2012. Recent trends in prostate cancer incidence by age, cancer stage, and grade, the United States, 2001–2007. Prostate Cancer 2012, 691380.

Lilienfeld, D.E. and Stolley, P.D. 1994. Foundations of Epidemiology, third edition. Oxford University Press: New York.

Llauger, J., Palmer, J., Amores, S., Bague, S. and Camins, A., 2000. Primary tumors of the sacrum: diagnostic imaging. American Journal of Roentgenology, 174(2), pp.417-424.

Longhi, A., Errani, C., De Paolis, M., Mercuri, M. and Bacci, G., 2006. Primary bone osteosarcoma in the pediatric age: state of the art. Cancer treatment reviews, 32(6), pp.423-436.

Lovejoy, C. O., and Heiple, K. G., 1981. The Analysis of Fractures in Skeletal Populations with an Example from the Libben Site, Ottowa, Ohio. American Journal of Physical Anthropology 55:529–541.

Lovell, N.C., Jurmain, R. and Kilgore, L., 2000. Skeletal evidence of probable treponemal infection in free-ranging African apes. Primates, 41(3), pp.275-290.

Lovell, N.C., 1990. Patterns of injury and illness in great apes: a skeletal analysis. Smithsonian Institution Press.

Lucas D, Unni K, McLeod R, O'Connor M, Sim F. 1994. Osteoblastoma: clinicopathologic study of306 cases. Human Pathology, 25(2), pp.117-134.

Lyckgaard, A., Johnson, G., and Tafforeau, P. 2011. Correction of ring artifacts in X-ray tomographic images. International Journal of Tomography & Statistics, 18(F11), pp.1-9.

Lynnerup, N. 2008. Computed tomography scanning and three-dimesional visualization of mummies and bog bodies. In S. Mays and R. Pinhasi (Eds.), Advances in Human Palaeopathology (pp. 101-120). West Sussex: John Wiley and Sons Ltd.

McAloose, D., Newton, A.L., 2009. Wildlife cancer: a conservation perspective. Nat. Rev. Cancer 9 (7), pp.517–526.

Manchester, K., 1983. The archaeology of disease. University of Bradford.

Manchester, K. and Roberts, C., 1989. The palaeopathology of leprosy in Britain: a review. World Archaeology, 21(2), pp.265-272.

Mann A. 1975. Paleodemographic aspects of the South African australopithecines. Philadelphia: University of Pennsylvania.

Martin, L.D. and Rothschild, B.M., 1989. Paleopathology and diving mosasaurs. American Scientist, 77, pp.460-467.

Martín-Francés, L., Martinón-Torres, M., Lacasa-Marquina, E., Fernández-Colón, P., Gracia-Téllez, A. and de Castro, J.M.B., 2014. Palaeopathology of the Pleistocene specimen D2600 from Dmanisi (Republic of Georgia). Comptes Rendus Palevol, 13(3), pp.189-203.

Marx, M. and D'Auria, S.H., 1988. Three-dimensional CT reconstructions of an ancient human Egyptian mummy. American journal of roentgenology, 150(1), pp.147-149.

Mays, S., 2012. The relationship between paleopathology and the clinical sciences. A Companion to Paleopathology, pp.285-309.

McAloose, D., Newton, A.L., 2009. Wildlife cancer: a conservation perspective. Nat. Rev. Cancer 9 (7), 517–526.

McCall, I.W., 2005. Radiology and pathological correlations of bone tumours of the spine. In Radiologic-Pathologic Correlations from Head to Toe (pp. 721-741). Springer Berlin Heidelberg.

McLeod, R.A., Dahlin, D.C. and Beabout, J.W., 1976. The spectrum of osteoblastoma. American Journal of Roentgenology, 126(2), pp.321-325.

McErlain D.D, Chhem R.K, Bohay R.N, et al. 2004. Micro-computed tomography of a 500-year-old tooth: technical note. JCAR, 55(4), pp.242–245.

McGeoch, D.J., 2001. Molecular evolution of the gamma-Herpesvirinae Philosophical transactions of the Royal Society of London Series B. Biol. Sci. 356 (1408), pp.421–435.

McGeoch, D.J., Gatherer, D., 2007. Lineage structures in the genome sequences of three Epstein-Barr virus strains. Virology 359 (1), pp.1–5.

Martín-Francés, L., Martinón-Torres, M., Lacasa-Marquina, E., Fernández-Colón, P., Gracia-Téllez, A. and de Castro, J.M.B., 2014. Palaeopathology of the Pleistocene specimen D2600 from Dmanisi (Republic of Georgia). Comptes Rendus Palevol, 13(3), pp.189-203.

Martin, D.L. and Osterholtz, A.J., 2015. Bodies and Lives in Ancient America: Health Before Columbus. Routledge.

Martinón-Torres, M., Martín-Francés, L., Gracia, A., Olejniczak, A., Prado-Simón, L., Gómez-Robles, A., Lapresa, M., Carbonell, E., Arsuaga, J.L. and de Castro, J.M.B. 2011. Early Pleistocene human mandible from Sima del Elefante (TE) cave site in Sierra de Atapuerca (Spain): a palaeopathological study. Journal of Human Evolution, 61(1), pp.1-11.

Mays, S. 2008. Radiography and allied techniques in the palaeopathology of skeletal remains. In S. Mays and R. Pinhasi (Eds.), Advances in Human Palaeopathology pp. 77-100. West Sussex, England: John Wiley and Sons Ltd.

Maygarden, S.J., Askin, F.B., Siegal, G.P., Gilula, L.A., Schoppe, J., Foulkes, M., Kissane, J.M. and Nesbit, M., 1993. Ewing sarcoma of bone in infants and toddlers. A clnicopathologic report from the intergroup Ewing's study. Cancer, 71(6), pp.2109-2118.

Mazurier, A., Volpato, V. & Macchiarelli, R. 2006. Improved noninvasive microstructural analysis of fossil tissues by means of SR-microtomography. Appl. Phys. A, 83, pp.229–233

Means, H.J., 1925. A roentgenological study of the skeletal remains of the prehistoric mound builder Indians of Ohio. Paul B. Hoeber.

Mees, F., Swennen, R., Van Geet, M. and Jacobs, P., 2003. Applications of X-ray computed tomography in the geosciences. Geological Society, London, Special Publications, 215(1), pp.1-6.

Metcalfe, N.H., 2007. In what ways can human skeletal remains be used to understand health and disease from the past? Postgraduate medical journal, 83(978), pp.281-284.

Miller, E., Ragsdale, B.D., and Ortner, D.J., 1996. Accuracy in dry bone diagnosis: a comment on palaeopathological methods. International Journal of Osteoarchaeology, 6(3), pp.221-229.

Milner, G. R., Wood, J. W., and Boldsen, J. L., 2008 Advances in Paleodemography. In: Biological Anthropology of the Human Skeleton, 2nd edition. M. A. Katzenberg, and S. R. Saunders, eds. pp. 561–600. New York: Wiley-Liss.

Minozzi, S., Giuffra, V., Bagnoli, J., Paribeni, E., Giustini, D., Caramella, D. and Fornaciari, G., 2010. An investigation of Etruscan cremations by Computed Tomography (CT). Antiquity, 84(323), pp.195-201.

Modic MT, Pavlicek W, Weinstein MA, Boumphrey F, Ngo F, Hardy R, *et al*. 1984. Magnetic resonance imaging of intervertebral disc disease. Radiology, 152, pp.103-11.

Moggi-Cecchi, J., Grine, F.E. and Tobias, P.V., 2006. Early hominid dental remains from Members 4 and 5 of the Sterkfontein Formation (1966–1996 excavations): catalogue, individual associations, morphological descriptions and initial metrical analysis. Journal of Human Evolution, 50(3), pp.239-328.

Moodie, R.L., 1923. Paleopathology. An Introduction to the Study of Ancient Evidences of Disease. University of Illinois Press, Urbana.

Møller-Christensen, V., 1978. Leprosy changes of the skull. Odense university press.

Møller-Christensen, V., 1974. Changes in the anterior nasal spine and the alveolar process of the macillae in leprosy a clinical examination. International journal of leprosy and other mycobacterial diseases: official organ of the International Leprosy Association, 42(4), pp.431-435.

Møller-Christensen, V., 1967. Evidence of leprosy in earlier peoples. Charles C. Thomas, Publisher.

Møller-Christensen V. 1953. Ten Lepers from Naestved in Denmark. A Study of Skeletons from a Medieval Danish Leper Hospital. Copenhagen: Danish Science Press.

Montgomery, P.Q., Williams, H.O.L., Reading, N. and Stringer, C.B., 1994. An assessment of the temporal bone lesions of the Broken Hill cranium. Journal of archaeological science, 21(3), pp.331-337.

Morgan, J.A., 2014. The methodological and diagnostic applications of micro-CT to palaeopathology: a quantitative study of porotic hyperostosis (Doctoral dissertation, The University of Western Ontario).

Müller R. 2009. Hierarchical microimaging of bone structure and function. Nat Rev Rheumatol, 5, pp.373–81.

Müller, R., Van Campenhout, H., Van Damme, B., Van der Perre, G., Dequeker, J., Hildebrand, T., Rüegsegger, P. 1998. Morphometric analysis of human bone biopsies: a quantitative structural comparison of histological sections and micro-computed tomography. Bone, 23(1), 59-66.

Mundy, G.R., 2002. Metastasis: Metastasis to bone: causes, consequences and therapeutic opportunities. Nature Reviews Cancer, 2(8), pp.584-593.

Murphy, E.M., Schulting, R., Beer, N., Chistov, Y., Kasparov, A. and Pshenitsyna, M., 2013. Iron Age pastoral nomadism and agriculture in the eastern Eurasian steppe: implications from dental palaeopathology and stable carbon and nitrogen isotopes. Journal of Archaeological Science, 40(5), pp.2547-2560.

Murphey, M.D., Walker, E.A., Wilson, A.J., Kransdorf, M.J., Temple, H.T. and Gannon, F.H., 2003. From the Archives of the AFIP: Imaging of Primary Chondrosarcoma: Radiologic-Pathologic Correlation 1. Radiographics, 23(5), pp.1245-1278.

Narayanan, D.L., Saladi, R.N. and Fox, J.L., 2010. Review: Ultraviolet radiation and skin cancer. International journal of dermatology, 49(9), pp.978-986.

Nelemans, P.J. and Sturmans, F., 2001. Injection therapy for subacute and chronic benign low back pain. Spine, 26(5), pp.501-515.

Nemoto, R., Hattori, K., Uchida, K., Shimazui, T., Nishijima, Y., Koiso, K. and Harada, M., 1990. S-phase fraction of human prostate adenocarcinoma studied with in vivo bromodeoxyuridine labeling. Cancer, 66(3), pp.509-514.

Nesse, R.M. and Stearns, S.C., 2008. The great opportunity: evolutionary applications to medicine and public health. Evolutionary Applications, 1(1), pp.28-48.

Newman R. 1993. The incidence of damage marks on Swartkrans fossil bones from the 1979–1986 excavations. Swartkrans: A cave's chronicle of early man: Transvaal Museum Monograph. Pretoria: Transvaal Museum, pp.217–228.

Nicholson, R.A. 2001. Taphonomic investigations. In Pollard, M.A. and Brothwell, D. (Eds.), Handbook of Archaeological Science (pp. 179-190). Chichester: Wiley.

Nordling, C.O., 1953. A new theory on cancer-inducing mechanism. Br. J. Cancer 7 (1), 68–72.

Nugent, K.A., Gureyev, T.E., Cookson, D.F.,Paganin,D. & Barnea, Z. 1996. Quantitative phase imaging using hard X-rays. Phys. Rev. Lett. 77, pp.2961–2964.

O'Brien, J.J., Battista, J.J., Romagnoli, C. and Chhem, R.K., 2009. CT imaging of human mummies: a critical review of the literature (1979–2005). International Journal of Osteoarchaeology, 19(1), pp.90-98.

Odes, E.J., Randolph-Quinney, P.S., Steyn, M., Throckmorton, Z., Smilg, J.S., Zipfel, B., Augustine, T.N., De Beer, F., Hoffman, J.W., Franklin, R.D. and Berger, L.R., 2016. Earliest hominin cancer: 1.7-million-year-old osteosarcoma from Swartkrans Cave, South Africa. South African Journal of Science, 112(7-8), pp.1-5.

Ogden, A. 2008. Chapter 13. Advances in the Palaeopathology of Teeth and Jaws. In Advances in human palaeopathology., eds. R. Pinhasi and S. Mays. John Wiley & Sons, Ltd.

Oppenheimer, A., 1964. Tool use and crowded teeth in Australopithecinae. Current Anthropology, 5(5), pp.419-421.

Ortner, D. J. 2007. Differential Diagnosis of Skeletal Lesions in Infectious Disease, in Advances in Human Palaeopathology (eds R. Pinhasi and S. Mays), John Wiley & Sons, Ltd, Chichester, UK.

Ortner, D. J. 2012. Differential diagnosis and issues in disease classification. In. Grauer A.L. (Ed.), A Companion to Paleopathology (pp. 250-267). West Sussex: Blackwell Publishing Ltd.

Ortner, D.J., 2008. Differential diagnosis of skeletal lesions in infectious disease. Advances in human palaeopathology, pp.189-214.

Ortner, D.J., 2003. Identification of pathological conditions in human skeletal remains. Academic Press.

Ortner, D.J., 1994. Descriptive methodology in paleopathology. In D.W. Owsley and R.J. Jantz (Eds.), Skeletal Biology in the Great Plains. Washington: Smithsonian Institution, pp. 73-80

Ortner, D.J., 1992. Skeletal paleopathology: probabilities, possibilities and impossibilities. In J.W. Verano and D.H. Ubelaker (Eds.), Disease and Demography in the Americas. Washington: Smithsonian Insititution, pp. 5-15

Ortner, D.J., 1991. Theoretical and methodological issues in paleopathology. In D.J. Ortner and A.C. Aufderheide (Eds.), Human Paleopathology: Current Syntheses and Future Options. Washington: Smithsonian Insitution, pp. 5-12.

Ortner, D., and Putschar, W., 1985. Identification of Pathological Conditions in Human Skeletal Remains (Smithsonian Contributions to Anthropology 28; Washington, DC.

Ortner DJ., and Putschar WJC., 1981. Identification of pathological conditions in human skeletal remains. Smithsonian contributions to anthropology, no 28. Bulletins et Mémoires de la Société d'anthropologie de Paris, 9(3), pp.233-233.

Osborne R. The differential radiologic diagnosis of bone tumors. CA: a cancer journal for clinicians. 1974;24(4): pp.194-211.

Paganin D, Mayo S, Gureyev T, Miller P, Wilkins S. 2002. Simultaneous phase and amplitude extraction from a single defocused image of a homogeneous object. J Microsc Oxford, 206, pp.33–40.

Parkinson, A.H., 2016. Traces of Insect Activity at Cooper's D Fossil Site (Cradle of Humankind, South Africa). Ichnos, 23(3-4), pp.322-339.

Parkinson, A.H., 2013. Dermestes maculatus and Periplaneta americana: bone modification criteria and establishing their potential as climatic indicators (Masters dissertation).

Particelli, F., Mecozzi, L., Beraudi, A., Montesi, M., Baruffaldi, F. and Viceconti, M., 2012. A comparison between micro-CT and histology for the evaluation of cortical bone: effect of polymethylmethacrylate embedding on structural parameters. Journal of microscopy, 245(3), pp.302-310.

Pearson, O.M. and Buikstra, J.E., 2006. Behavior and the bones. Bioarchaeology: the contextual analysis of human remains, pp.207-225.

Pérez, P.J., Gracia, A., Martínez, I. and Arsuaga, J.L., 1997. Paleopathological evidence of the cranial remains from the Sima de los Huesos Middle Pleistocene site (Sierra de Atapuerca, Spain). Description and preliminary inferences. Journal of human evolution, 33(2-3), pp.409-421.

Pettitt, P., 2011. The Palaeolithic Origins of Human Burial. Routledge, London.

Pfeifer, G.P., Denissenko, M.F., Olivier, M., Tretyakova, N., Hecht, S.S., Hainaut, P., 2002. Tobacco smoke carcinogens, DNA damage and p53 mutations in smoking-associated cancers. Oncogene 21 (48), pp.7435–7451.

Phelan, J., Weiner, M.J., Ricci, J.L., Plummer, T., Gauld, S., Potts, R. and Bromage, T.G., 2007. Diagnosis of the pathology of the Kanam mandible. Oral Surgery, Oral Medicine, Oral Pathology, Oral Radiology, and Endodontology, 103(4), p.e20.

Pickering, T.R., Heaton, J.L., Sutton, M.B., Clarke, R.J., Kuman, K., Senjem, J.H. and Brain, C.K., 2016. New early Pleistocene hominin teeth from the Swartkrans Formation, South Africa. Journal of Human Evolution, 100, pp.1-15.

Pickering, T.R., Heaton, J.L., Clarke, R.J., Sutton, M.B., Brain, C.K. and Kuman, K., 2012. New hominid fossils from Member 1 of the Swartkrans formation, South Africa. Journal of human evolution, 62(5), pp.618-628.

Pickering RB, Conces DJ, Braunstein EM, Yurco F. 1990. Three-dimensional computed tomography of the mummy Wenhotep. American Journal of Physical Anthropology 83, pp.49–55.

Pimenoff, V.N., de Oliveira, C.M., Bravo, I.G., 2017. Transmission between archaic and modern human ancestors during the evolution of the oncogenic human papillomavirus 16. Mol. Biol. Evol. 34 (1), pp.4–19.

Pinhasi, R. and Mays, S. eds., 2008. Advances in human palaeopathology. John Wiley & Sons.

Pinhasi, R. and Turner, K. 2008. Epidemiological approaches in paleopathology. In S. Mays and R. Pinhasi (Eds.), Advances in Human Palaeopathology (pp. 45-56). WestSussex: John Wiley and Sons Ltd.

Pinhasi, R., and Bourbou, C. 2008. How representative are human skeletal assemblages for population analysis? In S. Mays and R. Pinhasi (Eds.), Advances in Human Palaeopathology (pp. 30-44).

Pomerantz, M.M., Freedman, M.L., 2011. The genetics of cancer risk. Cancer J. 17 (6), pp.416–422.

Price, J.L. and Molleson, T.I., 1974. A radiographic examination of the left temporal bone of Kabwe Man, Broken Hill Mine, Zambia. Journal of Archaeological Science, 1(3), pp.285-289.

Ragsdale, B., 1992. Task force on terminology: provisional word list. Paleopathology Newsletter, 78, pp.7-8.

Ramfjord, S.P., 1967. The periodontal disease index (PDI). Journal of Periodontology, 38(6 Part II), pp.602-610.

Randolph-Quinney, P.S., Williams, S.A., Steyn, M., Meyer, M.R., Smilg, J.S., Churchill, S.E., Odes, E.J., Augustine, T., Tafforeau, P. and Berger, L.R., 2016. Osteogenic tumour in *Australopithecus sediba*: Earliest hominin evidence for neoplastic disease. South African Journal of Science, 112(7-8), pp.1-7.

Randolph-Quinney, P.S., 2015. The mournful ape: Conflating expression and meaning in the mortuary behaviour of *Homo naledi*. South African Journal of Science, 111(11-12), pp.1-5.

Randolph-Quinney, P.S. From the cradle to the grave: the bioarchaeology of Clonfad and Ballykilmore 6. 2013. In: N. Brady, P. Stevens and J. Channing (eds.) Settlement and Community in the Fir Tulach Kingdom. Dublin: National Roads Authority Press, pp.376-399

Randolph-Quinney, P., Mallett, X. and Black, S.M., 2009. Forensic anthropology. Wiley encylopedia of forensic science. London: John Wiley and Son, pp.152-178.

Raskin S. P. 1981. Computed tomography findings in lumbar disk disease. Orthopedics 5:419–531

Recheis, W., Weber, G.W., Schafer, K., Knapp, R., Seidler, H., zur Nedden, D. 1999. Virtual reality and anthropology. European Journal of Radiology, 31, pp.88–96.

Read, J.M. and Keeling, M.J., 2003. Disease evolution on networks: the role of contact structure. Proceedings of the Royal Society of London B: Biological Sciences, 270(1516), pp.699-708.

Reed, K.E., Kitching, J.W., Grine, F.E., Jungers, W.L. and Sokoloff, L., 1993. Proximal femur of *Australopithecus africanus* from member 4, Makapansgat, South Africa. American journal of physical anthropology, 92(1), pp.1-15.

Resnick D., 1995. Diagnosis of bone and joint disorders. 3rd ed. Philadelphia, PA: W.B. Saunders Company.

Resnick D., 1994. Orthopedics: Diagnosis of bone and joint disorders: Volume 4. 3rd ed. Philadelphia, PA: W.B. Saunders.

Resnick D, Greenway GD. 1996. Tumors and tumor-like lesions of bone: imaging and pathology of specific lesions. In: Resnick D, ed. Bone and Joint Imaging. Philadelphia, PA: Saunders, pp.991-1063.

Resnick, D. and Niwayama, G., 1995. Degenerative disease of the spine. Diagnosis of Bone and Joint Disorders. ed, 3, pp.1372-1462.

Resnick, D. and Niwayama, G., 1988. Diagnosis of bone and joint disorders. Volumes 1-6.

Resnick, D. and Kransdorf, M.J., 2005. Polyarteritis nodosa and other vasculitides. Bone and joint imaging, 3rd edn. Elsevier Saunders, Philadelphia.

Resnick, D., and Pettersson, H. 1992. Skeletal Radiology. London: Merit Communications.

Retief, F.P. and Cilliers, L., 2011. Breast cancer in antiquity. SAMJ: South African Medical Journal, 101(8), pp.513-515.

Richardson, R.R., 2005, October. Variants of exostosis of the bone in children. In Seminars in roentgenology (Vol. 40, No. 4, pp. 380-390). WB Saunders.

Ridley DS, Jopling WH. 1966. Int J Lepr 34, 255.

Ripamonti, U., 1988. Paleopathology in *Australopithecus africanus*: A suggested case of a 3-million-year-old prepubertal periodontitis. American Journal of Physical Anthropology, 76(2), pp.197-210.

Ripamonti, U., 1989. The Hard Evidence of Alveolar Bone Loss in Early Hominids of Southern Africa* A Short Communication. Journal of periodontology, 60(2), pp.118-120.

Ripamonti, U., Kirkbride, A.N., Yates, S.C. and Thackeray, J.F., 1997. Further evidence of periodontal bone pathology in a juvenile specimen of *Australopithecus africanus* from Sterkfontein, South Africa.

Roberts, C., 2012. The global history of paleopathology: pioneers and prospects. Oxford University Press on Demand.

Roberts, C.A. (2002). Palaeopathology and archaeology: the current state of play. In: The archaeology of medicine. Oxford: Archaeopress, pp. 1-20. BAR international series.

Roberts, C., 2000. Infectious disease in biocultural perspective: past, present and future work in Britain. Human osteology in archaeology and forensic science. London: Greenwich Medical Media p. 2000, pp.145-162.

Roberts, C. and Ingham, S., 2008. Using ancient DNA analysis in palaeopathology: a critical analysis of published papers, with recommendations for future work. International Journal of Osteoarchaeology, 18(6), pp.600-613.

Roberts, C.A. and Manchester, K., 2007. The archaeology of disease. Cornell University Press.

Roberts C.A. Manchester K., 2005. The archaeology of disease. 3rd ed. Cornell University Press. Ithaca, New York.

Roberts, C.A. and Cox, M., 2003. Health and disease in Britain: from prehistory to the present day. Sutton publishing.

Roberts, C.A., Boylston, A., Buckley, L., Chamberlain, A.C. and Murphy, E.M., 1998. Rib lesions and tuberculosis: the palaeopathological evidence. Tubercle and Lung Disease, 79(1), pp.55-60.

Robinson, J.T., 1956. The dentition of the Australopithecinae: Maxillary molars. Transvaal Museum Memoirs, 9 (1), pp.81-100.

Robinson, J.T., 1952. Some hominid features of the ape-man dentition.

Rodriguez, D.P. and Poussaint, T.Y., 2010. Imaging of back pain in children. American Journal of Neuroradiology, 31(5), pp.787-802.

Rogers, J. and Waldron, T., 1989. Infections in palaeopathology: the basis of classification according to most probable cause. Journal of Archaeological Science, 16(6), pp.611-625.

Rose, J.C., 1991. Paleopathology Association, Skeletal Database Committee and Skeletal database committee recommendations. Paleopathology Association.

Rothschild, B.M., Tanke, D.H., Helbling, M. and Martin, L.D., 2003. Epidemiologic study of tumors in dinosaurs. Naturwissenschaften, 90(11), pp.495-500.

Rothschild, B.M., Arriaza, B., Woods, R.J. and Dutour, O., 1999. Spondyloarthropathy identified as the etiology of Nubian erosive arthritis. American Journal of Physical Anthropology, 109(2), pp.259-267.

Rothschild, B.M. and Rothschild, C., 1995. Comparison of radiologic and gross examination for detection of cancer in defleshed skeletons. American Journal of Physical Anthropology, 96(4), pp.357-363.

Rothschild, B.M. and Martin, L.D., 1993. Paleopathology: disease in the fossil record. CRC Press I Llc.

Rothschild, B.M., Witzke, B.J. and Hershkovitz, I., 1999. Metastatic cancer in the Jurassic. The Lancet, 354(9176), p.398.

Rothschild, B.M., Tanke, D., Hershkovitz, I. and Schultz, M., 1998. Mesozoic neoplasia: origins of haemangioma in the Jurassic age. The Lancet, 351(9119), p.1862.

Rothschild, B.M. and Tanke, D., 1992. Paleoscene 13. Paleopathology of vertebrates: insights to lifestyle and health in the geological record. Geoscience Canada, 19(2), pp. 73-82.

Rothschild, B.M., Prothero, D.R. and Rothschild, C., 2001. Origins of spondyloarthropathy in Perissodactyla. Clinical and experimental rheumatology, 19(6), pp.628-632.

Rühli, F.J., Galassi, F.M. and Haeusler, M., 2016. Palaeopathology: current challenges and medical impact. Clinical Anatomy, 29(7), pp.816-822.

Rühli, F.J., Kuhn, G., Evison, R., Müller, R., and Schultz, M. 2007. Diagnostic value of micro-CT in comparison with histology in the qualitative assessment of historical human skull bone pathologies. American Journal of Physical Anthropology, 133, pp.1099-1111.

Rühli, F.J., Hodler, J., Böni, T. 2002a. CT-guided biopsy: a new diagnostic method for paleopathological research: technical note. American Journal of Physical Anthropology,117, pp.272-275.

Rühli, F.J., Lanz, C., Ulrich-Bochsler, S. and Alt, K.W., 2002b. State-of–the–art imaging in palaeopathology: the value of multislice computed tomography in visualizing doubtful cranial lesions. International Journal of Osteoarchaeology, 12(5), pp.372-379.

Ryan, T.M. and van Rietbergen, B., 2005. Mechanical significance of femoral head trabecular bone structure in Loris and Galago evaluated using micromechanical finite element models. American Journal of Physical Anthropology, 126(1), pp.82-96.

Saab, G., Chhem, R. and Bohay, R.N., 2008. Paleoradiologic techniques. In Paleoradiology (pp. 15-54). Springer Berlin Heidelberg.

Sanchez, S., Fernandez, V., Pierce, S.E. and Tafforeau, P., 2013. Homogenization of sample absorption for the imaging of large and dense fossils with synchrotron microtomography. Nature protocols, 8(9), pp.1708-1717.

Saraiya, M., Unger, E.R., Thompson, T.D., Lynch, C.F., Hernandez, B.Y., Lyu, C.W., Steinau, M., Watson, M., Wilkinson, E.J., Hopenhayn, C., et al., 2015. US assessment of HPV types in cancers: implications for current and 9-valent HPV vaccines. J. Natl. Cancer Inst. 107 (6) (djv086).

Shang, H. and Trinkaus, E., 2008. An ectocranial lesion on the Middle Pleistocene human cranium from Hulu Cave, Nanjing, China. American journal of physical anthropology, 135(4), pp.431-437.

Schoetensack, O., 1908. Der Unterkiefer des Homo heidelbergensis aus den Sanden von Mauer bei Heidelberg. Ein Beitrag zur Paläontologie des Menschen. Molecular and General Genetics MGG, 1(1), pp.408-410.

Schultz, M., 2001. Paleohistopathology of bone: a new approach to the study of ancient diseases. American Journal of Physical Anthropology, 116(S33), pp.106-147.

Schwamm, H.A. and Millward, C.L. 1995. Histological Differential Diagnosis of Skeletal Lesions. New York: Igaku-Shoin.

Selye, H., 1973. The Evolution of the Stress Concept: The originator of the concept traces its development from the discovery in 1936 of the alarm reaction to modern therapeutic applications of syntoxic and catatoxic hormones. American scientist, 61(6), pp.692-699.

Smith FH, Smith MO, Schmitz, RW. 2006. Human skeletal remains from the 1997 and 2000 excavations of cave deposits derived from Kleine Feldhofer Grotte in the Neandertal Valley, Germany. In: Schmitz RW, editor. Neanderthal 1856 – 2006. Mainz am Rhein: Verlag Philipp von Zabern, pp.187–246.

Smith, A.S., Weinstein, M.A., Mizushima, A., Coughlin, B., Hayden, S.P., Lakin, M.M. and Lanzieri, C.F., 1989. MR imaging characteristics of tuberculous spondylitis vs vertebral osteomyelitis. American Journal of Roentgenology, 153(2), pp.399-405.

Smith, M. O. 1996. Parry fractures and female-directed interpersonal violence: implications from the Late Archaic Period of West Tennessee. International Journal of Osteoarchaeology 6, pp.84–91.

Snigirev, A., Snigireva, I., Kohn, V., Kuznetsov, S. & Schelokov, I. 1995. On the possibilities of X-ray phase contrast microimaging by coherent high-energy synchrotron radiation. Rev Sci Instrum 66, 5486–5492.

Solooki, S., Vosoughi, A.R. and Masoomi, V., 2011. Epidemiology of musculoskeletal tumors in Shiraz, south of Iran. Indian journal of medical and paediatric oncology: official journal of Indian Society of Medical & Paediatric Oncology, 32(4), p.187.

Spoor, F., Jeffery, N. and Zonneveld, F., 2000. Using diagnostic radiology in human evolutionary studies. Journal of anatomy, 197(1), pp.61-76.

Spoor, F., Stringer, C. and Zonneveld, F., 1998. Rare temporal bone pathology of the Singa calvaria from Sudan. American Journal of Physical Anthropology, 107(1), pp.41-50.

Spouge, A.R. and Thain, L.M., 2000. Osteoid osteoma: MR imaging revisited. Clinical imaging, 24(1), pp.19-27.

Staps, D., 2002, January. The first documented occurrence of spondylosis deformans in an early hominin. In American Journal of Physical Anthropology (Pp. 146-146). Div John Wiley & Sons Inc, 605 Third Ave, New York, Ny 10158-0012 Usa: Wiley-Liss.

Stathopoulos, G., 1975. Kanam mandible's tumour. The Lancet, 305(7899), p.165.

Stauber, M and Müller, R. 2008. Micro-computed tomography: A method for the non-destructive evaluation of the three dimensional structure of biological specimens. In J.J. Westendorf (Ed.), Methods in Molecular Biology, Vol. 455, Osteoporosis: Methods and Protocols (pp. 273-285). Totowa, N.J: Humana Press.

Steckel, R.H. and Rose, J.C., 2002. The backbone of history: health and nutrition in the Western Hemisphere (Vol. 2). Cambridge University Press.

Steckel, R. H., and Rose, J. C., 2002b Patterns of Health in the Western Hemisphere. In: The Backbone of History: Health and Nutrition in the Western Hemisphere. R. M. Steckel and J. C. Rose, eds. pp. 563–579. Cambridge: Cambridge University Press.

Steinbock, R.T., 1976. Paleopathological diagnosis and interpretation: bone diseases in ancient human populations. Charles C Thomas Pub Limited.

Straight, W.H., Davis, G.L., Skinner, H.C.W., Haims, A., McClennan, B.L. and Tanke, D.H., 2009. Bone lesions in hadrosaurs: Computed Tomographic Imaging as a guide for paleohistologic and stable-isotopic analysis. Journal of Vertebrate Paleontology, 29(2), pp.315-325.

Stuart-Macadam, P.L., 1989. Nutritional deficiency diseases: a survey of scurvy, rickets, and iron-deficiency anemia. Reconstruction of Life from the Skeleton, 201, p.222.

Stuart-Macadam, P. 1987. A radiographic study of porotic hyperostosis. American Journal of Physical Anthropology, 74, pp.511-520.

Sutton, M., Rahman, I. and Garwood, R., 2014. Techniques for virtual palaeontology. John Wiley & Sons.

Tafforeau, P., Hublin, J.J. and Smith, T.M., 2009. Hominin Dental Structure and Development Revealed Non-Destructively by Multi-Scale Synchrotron Imaging, pp. 252-252

Tafforeau, P., Boistel, R., Boller, E., Bravin, A., Brunet, M., Chaimanee, Y., Cloetens, P., Feist, M., Hoszowska, J., Jaeger, J.J. and Kay, R.F., 2006. Applications of X-ray synchrotron microtomography for non-destructive 3D studies of paleontological specimens. Applied Physics A, 83(2), pp.195-202.

Tanke, D.H. and Rothschild, B.M., 2002. Dinosores: An Annotated Bibliography of Dinosaur Paleopathology and Related Topics—1838-2001: Bulletin 20 (Vol. 20). New Mexico Museum of Natural History and Science.

Thillaud, P.L. and Charon, P., 1994. Lesions osteo-archeologiques: recueil et identification. Kronos BY Editions.

Thillaud, P.L., 1992. Retrospective diagnosis in paleopathology. Palaeopathol Newslett 80 (suppl): 1, 4.

Throckmorton, Z., Zipfel, B., Randolph-Quinney, P., Odes, E., Congdon, K., DeSilva, J., Harcourt-Smith, W. and Berger, L., 2017, *Homo naledi*'s pedal pathologies. 86th AAPA meeting, poster.

Tobias PV. Re-creating ancient hominid virtual endocasts by CT-scanning. 2001. Clin Anat;14(2), pp.134–141.

Tobias, P.V., 1962. A re-examination of the Kanam mandible. In G. Mortelmans and J. Nenquin eds., Actes du IVe Congres Panafricain de Préhistoire et de l'Étude du Quaternaire, Sections I and II. Tervuren, Belgique: Annales Ser. Qu-8o, Sciences Humaines (Vol. 40, pp. 341-350).

Tobias, P.V., 1960. The Kanam jaw. Nature, 185(4717), pp.946-947.

Tomasetti, C., Li, L., Vogelstein, B., 2017. Stem cell divisions, somatic mutations, cancer etiology, and cancer prevention. Science 355 (6331), pp.1330–1334.

Toussaint, M., Macho, G.A., Tobias, P.V., Partridge, T.C. and Hughes, A.R., 2003. The third partial skeleton of a late Pliocene hominin (Stw 431) from Sterkfontein, South Africa: research articles. South African Journal of Science, 99(5-6), pp.215-223.

Trinkaus E. 1983. The Shanidar Neandertals. New York: Academic Press.

Trinkaus E. 1985. Pathology and the posture of the La Chapelle-aux-Saints Neandertal. Am J Phys Anthropol 67, pp.19–41.

Trinkaus, E. and Zimmerman, M.R., 1982. Trauma among the Shanidar Neandertals. American Journal of Physical Anthropology, 57(1), pp.61-76.

Trübenbach, J., Nägele, T., Bauer, T. and Ernemann, U., 2006. Preoperative embolization of cervical spine osteoblastomas: report of three cases. American journal of neuroradiology, 27(9), pp.1910-1912.

Tschopp, E., Wings, O., Frauenfelder, T. and Rothschild, B.M., 2014. Pathological phalanges in a camarasaurid sauropod dinosaur and implications on behaviour. Acta Palaeontologica Polonica, 61(1), pp.125-134.

Turner-Walker, G. and Mays, S., 2008. Histological studies on ancient bone. Advances in human palaeopathology, pp.121-146.

Turner-Walker, G. 2008. The chemical and microbial degradation of bones and teeth. In R. Pinhasi and S. Mays (Eds.), Advances in Human Paleopathology (pp. 3-30). West Sussex: John Wiley and Sons Ltd.

Tyson R 1997. Human Paleopathology and Related Subjects: An International Bibliography, San Diego Museum of Man, San Diego, 716 pp.

Ubelaker, D.H., 1982. Development of American Paleopathology.

Ulrich, D., Van Rietbergen, B., Laib, A. and Ruegsegger, P., 1999. The ability of three-dimensional structural indices to reflect mechanical aspects of trabecular bone. Bone, 25(1), pp.55-60.

van Kaick, G. and Delorme, S. 2005. Computed tomography in various fields outsidemedicine. European Radiology Supplements, 15(4), d74-d81.

Vardiman, J.W., Thiele, J., Arber, D.A., Brunning, R.D., Borowitz, M.J., Porwit, A., Harris, N.L., Le Beau, M.M., Hellström-Lindberg, E., Tefferi, A. and Bloomfield, C.D., 2009. The 2008 revision of the World Health Organization (WHO) classification of myeloid neoplasms and acute leukemia: rationale and important changes. Blood, 114(5), pp.937-951.and Mineral Research, 17(3), pp.465-471.

Verdial, F.C., Etzioni, R., Duggan, C., Anderson, B.O., 2017. Demographic changes in breast cancer incidence, stage at diagnosis and age associated with population-based mammographic screening. J. Surg. Oncol. 115 (5), pp.517–522.

Vigorita, V.J., 2008. Orthopaedic pathology. Lippincott Williams & Wilkins.

Virchow R. I. 1896. Beitrag zur Geschichte der Lues. Dermatology. (Discussion of the history of Syphilis). 1, 3(1), pp.1-9.

Virchow, R., 1895. *Pithecanthropus erectus* Dubois. Verh. Berl. Ges. Anthrop.

Wade, A.D., Holdsworth, D.W., and Garvin, G.J. 2009. CT and micro-CT analysis of a case of Paget's disease (osteitis deformans) in the Grant skeletal collection. International Journal of Osteoarchaeology, 21(2), pp.127-135.

Wakely, J., Manchester, K. and Roberts, C., 1991. Scanning electron microscopy of rib lesions. International Journal of Osteoarchaeology, 1(3-4), pp.185-189.

Waldron, T. 2009. Palaeopathology. Cambridge: Cambridge University Press.

Waldron, T., 2008. Palaeopathology. Cambridge University Press.

Waldron, T., 2007. Palaeoepidemiology: The measure of disease in the human past. Left Coast Press.

Waldron, T. 1994. Counting the Dead: The Epidemiology of Skeletal Populations. New York: John Wiley and Sons.

Walker, A., Zimmerman, M.R. and Leakey, R.E., 1982. A possible case of hypervitaminosis A in *Homo erectus*. Nature, 296, pp.248-250.

Wanek, J., Papageorgopoulou, C., Rühli, F. 2012. Fundamentals of paleoimaging techniques: Bridging the gap between physicists and paleopathologists. In. Grauer A.L. (Ed.), A Companion to Paleopathology (pp. 324-338). West Sussex: Blackwell Publishing Ltd.

Warinner, C., Rodrigues, J.F.M., Vyas, R., Trachsel, C., Shved, N., Grossmann, J., Radini, A., Hancock, Y., Tito, R.Y., Fiddyment, S. and Speller, C., 2014. Pathogens

and host immunity in the ancient human oral cavity. Nature genetics, 46(4), pp.336-344.

Weiss, E., 2012. Olduvai Hominin 8 foot pathology: A comparative study attempting a differential diagnosis. HOMO-Journal of Comparative Human Biology, 63(1), pp.1-11.

Wells, C. 1967. Pseudopathology. D. Brothwell, AT. Sandison (Eds.), Diseases in Antiquity, Thomas, Springfield, Illinois (1967), pp. 5–19

Wells, C., 1964. Bones, Bodies, and Diseases. Thames and Hudson.

Wells, C., 1963. The radiological examination of human remains. Science in archaeology. London, Thames & Hudson, pp.401-412.

White TD. Early hominid enamel hypoplasia. American Journal of Physical Anthropology. 1978. Jul 1;49(1), pp.79-83.

Wood, J. W., and Milner, G. R., 1994 Reply. Current Anthropology 35, pp.631–637.

Wood, J.M., Milner, G.R., Harpending, H.C., Weiss, K.M. 1992. The osteological paradox: Problems of inferring prehistoric health from skeletal samples. Current Anthropology, 33, 343-370.

Wood-Jones F., 1910. General pathology (including diseases of the teeth), In: G. Elliot-Smith and F. Wood-Jones (eds.), The archaeological survey of Nubia report for 1907-1908, vol. 2: report on the human remains, London

Williams, S.A., Ostrofsky, K.R., Frater, N., Churchill, S.E., Schmid, P. and Berger, L.R., 2013. The vertebral column of Australopithecus sediba. Science, 340(6129), p.1232996.

Williams, H.W., 1929. Human paleopathology: With some original observations on symmetrical osteoporosis of the skull. American medical association.

White TD. Early hominid enamel hypoplasia. American journal of physical anthropology. 1978 Jul 1;49(1), pp.79-83.

Wilkins, S.W., Gureyev, T.E., Gao, D., Pogany, A. & Stevenson, A.W. 1996. Phase-contrast imaging using polychromatic hard X-rays. Nature, 384, pp.335–338.

World Health Organization, 2004. International statistical classification of diseases and related health problems (Vol. 1). World Health Organization.

Wright, L. E., and Yoder, C. J., 2003 Recent Progress in Bioarchaeology: Approaches to the Osteological Paradox. Journal of Archaeological Research 11, pp.43–70.

Wu, J.S. and Hochman, M.G., 2009. Soft-tissue tumors and tumorlike lesions: a systematic imaging approach. Radiology, 253(2), pp.297-316.

Wu, X., and Schepartz, L.A. 2009. Application of computed tomography inpaleoanthropological research. Progress in Natural Science, 19(8), 913-921.

Youlden, D.R., Cramb, S.M., Yip, C.H., Baade, P.D., 2014. Incidence and mortality of female breast cancer in the Asia-Pacific region. Cancer Biol. Med. 11 (2), pp.101–115.

Zilberman, U., Smith, P., Piperno, M. and Condemi, S., 2004. Evidence of amelogenesis imperfecta in an early African Homo erectus. Journal of human evolution, 46(6), pp.647-653.

Zollikofer, C.P. and de León, M.S.P., 2005. Virtual reconstruction: a primer in computer-assisted paleontology and biomedicine. Wiley-Interscience.

zur Hausen, H., de Villiers, E.M., 2014. Cancer causation by infections? individual contributions and synergistic networks. Semin. Oncol. 42 (2), pp.207–222.

CHAPTER 10: LETTERS OF SUPPORT

1. **Letter of support for Chapter 2: Earliest Hominin Cancer: 1.7-Million-Year-Old Osteosarcoma from Swartkrans Cave, South Africa**

2. **Letter of support for Chapter 3: Osteogenic Tumour in *Australopithecus sediba*: Earliest Hominin Evidence for Neoplastic Disease**

3. **Letter of support for Chapter 4: Osteopathology and Insect Traces in the *Australopithecus africanus* Skeleton StW 431**

4. **Letter of support for Chapter 5: A Case of Benign Osteogenic Tumour: In *Homo naledi*: Evidence for Peripheral Osteoma in the U.W. 101-1142 Mandible**

INVESTOR IN PEOPLE

University of Central Lancashire
School of Forensic and Applied Sciences
University of Central Lancashire
Preston PR1 2HE
Tel: (Office) 01772 894386
www.uclan.ac.uk

16th August 2017

RE: Support of stated contributions of PhD candidate Edward John Odes

To whom it may concern:

As corresponding author I am writing in support of the contributions made by Edward Odes to the paper published in the *South African Journal of Science*: "Earliest hominin cancer: 1.7-million-year-old osteosarcoma from Swartkrans Cave, South Africa".

Edward co-conceptualised and co-designed the study, undertook the primary research and analysis and co-wrote the original draft of the manuscript and subsequent manuscripts, incorporating information from co-authors. Edward undertook differential diagnosis, and provided historical, pathological and palaeoanthropological data for the project. He also undertook secondary reconstruction from volume data, analysis and editing and data acquisition, together with his primary supervisor. My part involved supervising the student, contributing to the writing of the original and subsequent drafts, and jointly performing secondary reconstruction from orthoslice and 3D volume data.

Edward's contributions are significant as per his position as first author, and in keeping with inclusion of this research paper in the corpus of his PhD.

Yours sincerely,

Dr Patrick S. Randolph-Quinney

Dr Patrick Randolph-Quinney BSc PhD
Senior Lecturer in Biological and Forensic Anthropology
T +44 (0)1772 895683
Email prandolph-quinney@uclan.ac.uk

INVESTOR IN PEOPLE

University of Central Lancashire

School of Forensic and Applied Sciences
University of Central Lancashire
Preston PR1 2HE
Tel: (Office) 01772 894386
www.uclan.ac.uk

16th August 2017

RE: Support of stated contributions of PhD candidate Edward John Odes

To whom it may concern:

As lead author and principle investigator of the tumour in *Australopithecus sediba* research, I am writing in support of the contributions made by Edward Odes to the paper published in the *South African Journal of Science*: "Osteogenic tumour in *Australopithecus sediba*: Earliest hominin evidence for neoplastic disease."

Edwards' contributions to this work include the collection of detailed historical data on early hominin paleopathology, and assistance in differential diagnosis of pathology, both fundamental to this study. His contributions also included data acquisition, analysis and editing.

Edward's contributions are classed as significant, and in keeping with inclusion of this research paper in the corpus of his PhD.

Yours sincerely,

Dr Patrick S. Randolph-Quinney

Dr Patrick Randolph-Quinney BSc PhD
Senior Lecturer in Biological and Forensic Anthropology
T +44 (0)1772 895683
Email prandolph-quinney@uclan.ac.uk

INVESTOR IN PEOPLE

University of Central Lancashire

School of Forensic and Applied Sciences
University of Central Lancashire
Preston PR1 2HE
Tel: (Office) 01772 894386
www.uclan.ac.uk

16th August 2017

RE: Support of stated contributions of PhD candidate Edward John Odes

To whom it may concern:

As co-author I am writing to confirm the contributions made by PhD candidate Edward Odes to the research paper entitled "Osteopathology and insect traces in the *Australopithecus africanus* skeleton StW 431", published in the *South African Journal of Science* (Odes et al., 2017).

Edward co-conceptualised and co-designed the study, undertook the primary research and analysis and co-wrote the original draft of the manuscript and subsequent manuscripts, incorporating information from co-authors. Edward undertook differential diagnosis, and provided historical, pathological and palaeoanthropological data for the project. He also undertook secondary reconstruction from volume data, analysis and editing and data acquisition, together with his primary supervisor. My part involved supervising the student, contributing to the writing of the original and subsequent drafts, and jointly performing secondary reconstruction from orthoslice and 3D volume data.

Edward's contributions are significant as per his position as first author, and in keeping with inclusion of this research paper in the corpus of his PhD.

Yours sincerely,

Dr Patrick S. Randolph-Quinney

Dr Patrick Randolph-Quinney BSc PhD
Senior Lecturer in Biological and Forensic Anthropology
T +44 (0)1772 895683
Email prandolph-quinney@uclan.ac.uk

INVESTOR IN PEOPLE

University of Central Lancashire

School of Forensic and Applied Sciences
University of Central Lancashire
Preston PR1 2HE
Tel: (Office) 01772 894386
www.uclan.ac.uk

16th August 2017

RE: Support of stated contributions of PhD candidate Edward John Odes

To whom it may concern:

As corresponding author I am writing to confirm the contributions made by PhD candidate Edward Odes to the research paper entitled "A case of benign osteogenic tumour in *Homo naledi*: evidence for peripheral osteoma in the U.W. 101-1142 mandible", published in the *International journal of Paleopathology* (Odes et al., 2017).

Edward co-conceptualised and co-designed the study, undertook the primary research and analysis and co-wrote the original draft of the manuscript and subsequent manuscripts, incorporating information from co-authors. Edward undertook differential diagnosis, and provided historical, pathological and palaeoanthropological data for the project. He also undertook secondary reconstruction from volume data, analysis and editing and data acquisition, together with his primary supervisor. My part involved supervising the student, contributing to the writing of the original and subsequent drafts, and jointly performing secondary reconstruction from orthoslice and 3D volume data.

Edward's contributions are significant as per his position as first author, and in keeping with inclusion of this research paper in the corpus of his PhD.

Yours sincerely,

Dr Patrick S. Randolph-Quinney

Dr Patrick Randolph-Quinney BSc PhD
Senior Lecturer in Biological and Forensic Anthropology
T +44 (0)1772 895683
Email prandolph-quinney@uclan.ac.uk

LIST OF FIGURES

CHAPTER 4: EARLIEST HOMININ CANCER: 1.7-MILLION-YEAR-OLD OSTEOSARCOMA FROM SWARTKRANS CAVE, SOUTH AFRICA

Figure 1. SK 7923, a hominin 5th metatarsal, exhibits a hemi-spherical bony mass located on the proximo-ventral aspect of the shaft, abutting the cortical bone surface…….39

Figure 2. (a) Axial micro-CT orthoslice indicating (i) reactive new bone formation subperiosteally forming a Codman triangle, (ii) ossified exophytic (cauliflower-like) and/or spiculated mass adjacent to the bone, (iii) localised sub-periosteal invasion by the mass into the cortex, (iv) remodeled bone infill; (b) transverse rendered view of SK 7923; (c) transverse rendered view of modern clinical case of osteoblastic osteosarcoma with aggressive local medullary infilling (Courtesy: Department of Anatomy, University of Pretoria). Note (v) the homologous combination of spongy and solid bone between the fossil and clinical specimens…….....40

CHAPTER 5: OSTEOGENIC TUMOUR IN *AUSTRALOPITHECUS SEDIBA*: EARLIEST HOMININ EVIDENCE FOR NEOPLASTIC DISEASE

Figure 1. Surviving skeletal elements attributed to Malapa Hominin 1 (at time of writing) …….45

Figure 2: Vertebra U.W. 88-37. Photographs of surface morphology of U.W. 88-3 showing position of lesion on right side of vertebral lamina: (a) right lateral aspect, (b) left lateral aspect, (c) inferior aspect, (d) superior aspect, (e) posterior aspect, (f) anterior aspect. Note that apertures seen on lateral aspects of the vertebral body in images (a), (b) and (f) represent normal vascular foramina infilled with residual breccia matrix…….45

Figure 3: Vertebra U.W. 88-37. Multi-focus (composite image stack) micrograph of surface morphology of U.W. 88-37 showing sub-angular penetrating defect on the right vertebral lamina. The lesion has well-rounded edges with lateral bulging of the cortex over the lesion, indicating a reactive remodeling response to the presence of the defect. Note that anterior portion of defect remains infilled with breccia matrix. Micrograph taken with Olympus SZX Multi-focus microscope, magnification 7x. Scale bar = 10 mm……...45

Figure 4: Vertebra U.W. 88-37. Sixth thoracic vertebra of juvenile *Australopithecus sediba* (Malapa Hominin 1). Partially transparent image volume with the segmented boundaries of the lesion rendered solid pink. Volume data derived from phase-contrast X-ray synchrotron microtomography. (a) left lateral view, (b) superior view, (c) right lateral view…….46

Figure 5: Transverse slices through vertebra U.W. 88-37 derived from phase-contrast X-ray synchrotron microtomography. Relative position and anatomical orientation of orthoslices (a), (b) and (c) shown on the volume-rendered model. The posterior portion of the lesion is sclerotic with circumscribed margins of well-integrated cortical bone, abutted and intersectedby trabecular striae, with remodelling and reorganization of the cortex. The anterior portion of the lesion displays a geographic pattern of bone destruction, showing a sharp nonsclerotic margin and evidence of active osteolytic processes, with sharply defined transection of individual trabeculae and active osteolytic penetration into the anterior portion of the lamina…….46

Figure 6: Surface rendered image volume of the U.W. 88-37 lesion derived from phase-contrast X-ray synchrotron microtomography. Images show isosurface derived from segmented boundaries of the lesion (remaining breccia infill removed). The arrow denotes the interface between the

smoother dorsal sclerotic zone and the disorganised ventral lytic zone within the body of the lesion. (a) right lateral view, (b) medial view…….47

CHAPTER 6: OSTEOPATHOLOGY AND INSECT TRACES IN THE *AUSTRALOPITHECUS africanus* SKELETON STW 431

Figure 1: StW 431 – a partial skeleton of Australopithecus africanus discovered at Sterkfontein Caves in 1987. StW 431 represented only the third partial skeleton attributed at the time to A. africanus, and represents the only probable male skeleton attributed to this taxon to date……53

Figure 2: Three-dimensional volume rendered micro-CT views of the L4 vertebra of StW 431: (a) anterior, (b) superior, (c) inferior, (d) left lateral and (e) right lateral…….53

Figure 3: Three-dimensional volume rendered micro-CT views of the L5 vertebra of StW 431: (a) anterior, (b) superior, (c) inferior, (d) left lateral and (e) right lateral. Note the osteophytic formation on the superior and inferior endplate margins, as well as the anterior surface of the body in midline……54

Figure 4: Micro-CT orthoslice views of the L4 vertebra of StW 431: (a) transverse superior, (b) sagittal midline, (c) transverse inferior and (d) anterior. Note the bilateral osteophytic formation and two zones of erosion evident on the inferior endplate surface of the L4 in (c). There is no evidence of sclerosis or new bone formation around the margins of the cavities (c). Also note areas of new bone formation ranging from open woven (c) to sclerotic (d)…….54

Figure 5: Micro-CT orthoslice views of the L5 vertebra of StW 431: (a, b) transverse to the midline (close to surface), (c) transverse to inferior, (d) coronal midline, (e) sagittal superior to bottom. Note new bone formation on the anterior wall (e) and major osteophytic formation at the antero-superior margin indicating remodelling of the cortex, revealing a sclerotic margin,

and as crenulated buttresses of porous bone devoid of internal trabeculae (a, b). There is no evidence of sclerosis or reactive bone formation around the cavity margins (a). The inferior endplate (c) exhibits an osteophytic formation as a thin ordered sclerotic rim around inferior circumference with no presence of buttressing. Notice the channel interpreted as invertebrate damage in (e)……55

Figure 6: Insect traces excavated into the L5 vertebrae on StW 431 are indicated by arrows (a and b); (c) circular boring on a cercopithecus vertebra from Cooper's D; (d, f) furrows attributed to *Dermestes maculatus* from the Jurassic period34; (e) hole produced by the termite *Trinervitermes trinervoides*[21]; (g) holes produced by dermestids under experimental conditions[39]; and (h) furrow produced by the termite *T. trinervoides*[21]……55

CHAPTER FIVE: A CASE OF BENIGN OSTEOGENIC TUMOUR: IN *HOMO naledi*: EVIDENCE FOR PERIPHERAL OSTEOMA IN THE U.W. 101-1142 MANDIBLE

Figure 1: Location of the Rising Star Cave system within the Cradle of Humankind, South Africa…….61

Figure 2: Layout photograph of some of the Dinaledi Chamber fossils. The figure includes all of the material incorporated into the diagnosis of *Homo naledi*, and includes the holotype specimen, paratypes and referred material list in Berger and colleagues (2015). The fossil shown make up 737 partial or complete anatomical elements, many of which consist of several refitted specimens. Specimens not identified to element, such as non-diagnostic long bone or cranial fragments, are not shown. The 'skeleton' layout in the centre of the photo is a composite of elements that represent multiple individuals. The view is foreshortened and the table on which the bones are arranged is 120-cm wide for scale. Image, courtesy of John Hawks and taken with permission from Berger et al., 2015……...61

Figure 3: External morphology of the U.W. 102-1142 mandible.
(A) buccal (B) posterior (C) lingual (D) anterior (E) inferior and
(F) occlusal views. All image derived from 3D surface rendering
of micro-tomographic volume data…….62

Figure 4: Detailed image of vascular canal observed superior to the bony mass. This canal does not occur within the range of normal variation of Homo naledi and may be co-responsive with the formation of the lesion. The canal travels disto-mesially, penetrating parallel to, and then diving obliquely into the cortex of the corpus (surface rendered view 4a), before connecting with the medulla (orthoslice 4b) ……63

Figure 5: Anatomical location of orthoslices A to H displayed in Fig. 6……63

Figure 6: Coronal (A to D) and transverse (E to H) micro-tomographic orthoslices through the U.W. 101-1142 mandible. See Fig. 5 for anatomical location of each slice…….64

LIST OF TABLES

CHAPTER FIVE: A CASE OF BENIGN OSTEOGENIC TUMOUR: IN *HOMO naledi*: EVIDENCE FOR PERIPHERAL OSTEOMA IN THE U.W. 101-1142 MANDIBLE

Table 1: Differential diagnostic options for the U.W. 101-1142 mandible ……

Table 2: Detailed differential diagnosis of the hominin SK 7923 5th metatarsal…

APPENDIX A– SOUTH AFRICAN HOMININ PALAEOPATHOLOGY

Table 1. Specimens[++] of purported pathology and disease observed in South African Plio-Pleistocene hominin material from several sites in the Cradle of Humankind, South Africa

Fossil Site	specimen no	pathology/ disease type	anatomical element**	genus & species	references
STERKFONTEIN					
	Sts 24a	periodontal disease, abnormal periodontal alveolar processes, indicating likely periodontitis	incomplete mandible with R lower DC, lower DM 1-2 & lower M1, L lower D incisor 1-2, D C, DM1, also crown of lower incisor 1-2, R & L lower P3, also R lower D incisor 2,part of crown of L lower incisor 1	*A. africanus*	Grine (1982); Ripamonti et al. (1997)
	Sts 52a;b	dental crowding of anterior dentition and buccal displacement of RM3 (mandibular third molar), as in buccoversion; LM3 indicates impaction	mandible with full dentition but without L ramus	*A. africanus*	Gibson & Calcagno (1993)
	Stw 431: L4; L5	osteophyte formation (degenerative joint disease/osteoarthritis); lytic lesions have been previously diagnosed as spondylosis deformans) and possible infectious disease (brucellosis)	lumbar vertebrae L4 & L5	*A. africanus*	Staps (2002); D'Anastasio *et al*., 2009
	TM 1512	transverse and pitted hypoplasia	R maxilla with I^2, C, P^3 & M^1	*A. africanus*	Moggi-Cecchi Grine & Tobias (2006)
	Stw 75	hypoplastic groove I^2, and on LP^3	LI^1, LI^2, L^C, LP^3	*A. africanus (Homo)*[+]	Moggi-Cecchi, Grine & Tobias (2006)
	Stw 80	hypoplastic horizontal banding above cervical region.	crushed mandible with L and RI_1-I_2, L_C-M_3,	*A. africanus*	Moggi-Cecchi, Grine & Tobias (2006)
	Stw 188	horizontal hypoplastic groove on buccal side.	RM^2	*A. africanus*	Moggi-Cecchi, Grine & Tobias (2006)
	Stw 212	enamel hypoplasia on buccal face of P_3	LP_3, LC; RP_4, LM_1, LC, RM_2-M_3; isolated mandibular teeth.	*A. africanus*	Moggi-Cecchi, Grine & Tobias (2006)
	Stw 213	hypoplastic pitting on left canine crown and marked hypoplastic; marked transverse hypoplasial banding on the right canine	RI_2, Lc; R_C-M_2	*A. africanus*	Moggi-Cecchi, Grine & Tobias (2006)
	Stw 252	Hypoplastic pitting on the labial face of canine (Stw 252a)	complete permanent set of maxillary teeth; RI^1-M^3	*A. africanus*	Moggi-Cecchi, Grine & Tobias (2006)
	Stw 279	diffusely distributed hypoplastic pitting	L^c	*A. africanus*	Moggi-Cecchi, Grine & Tobias (2006)
	Stw 365	transverse hypoplastic grooves on labial surface	L_C	*A. africanus*	Moggi-Cecchi, Grine & Tobias (2006)
	Stw 404	hypoplastic pitting on right crown of,	R_C-M_3	*A. africanus*	Moggi-Cecchi, Grine & Tobias (2006)

		and protoconid and partial occlusal area of hypoconid of M_3			
	Stw 488	hypoplastic pitting on buccal and lingual surfaces	Rdm^2	*A. africanus*	Moggi-Cecchi, Grine & Tobias (2006)
	Stw 498	hyperplastic banding on labial surface of I^1, in the cervical region of the labial aspect	RI^1, LI^2, R^C-M^3; RI_1-M_3		Moggi-Cecchi, Grine & Tobias (2006)
	Stw 230	Transverse enamel Hypoplasia	R upper canine	*A. africanus*	Bombin 1990
	Stw 363	trauma/ healed compression fracture	left talus	*A. africanus*[10]	Fisk and Macho (1992)
MAKAPANSGAT					
	MLD 46	osteonecrosis/ joint osteoarthritis	proximal femur	*A. africanus*	Pers. Comm. B. Zipfel; Reed *et al*. (1993)
	MLD 18	dental crowding	mandible	*A. africanus*	Robinson (1956); Oppenheimer 1964; Dart, 1948
MALAPA					
	UW 88-37	osteoid osteoma	6th thoracic (T6) vertebra	*A. sediba*	Randolph-Quinney *et a*l. (2016)
TAUNG					
	'Taung Child'	dental hypoplasia	RM^1; RM_1	*A. africanus*	La Cruz, Rozzi & Bromage (2005)
KROMDRAAI					
	KB 5223	enamel hypoplasia	incomplete and associated crowns of deciduous and permanent mandibular teeth: Ldc, Ldm_I, Ldm_2 and Rdm_2, LI_I and RI_I, LI_2 and RI_2, L^C, and the LM_I and RM_I	*P. robustus*/ Early *Homo***	Grine** (1982, 1993); Braga and Thackeray 1992
DINALEDI CHAMBER (RISING STAR)					
	U.W. 101-1142	peripheral osteoma	mandible with RM2-RM3	*H. naledi*	Odes *et al*., 2017
COOPERS 'D' CAVE					
	U.W. 27-5774	pitted hypoplasia	M2	*P. robustus*	Pers. Comm. B.Zipfel; Christine Steiniger
	U.W. 27-22619	pitted hypoplasia	dm (1) L	*P. robustus*	Pers. Comm. B.Zipfel; Christine Steiniger
	U.W. 27-1638	pitted hypoplasia	dm (1) L	*P. robustus*	Pers. Comm. B.Zipfel; Christine Steiniger
	U.W. 27-1634	pitted hypoplasia	dm (2) L	*P. robustus*	Pers. Comm. B.Zipfel; Christine Steiniger

* late *Australopithecus* (Clarke 1995); *H. habilis* (Hughes and Tobias 1977)

**Grine suggested KB 5223 represented a robust australopithecine species different from Swartkrans from that which was represented at Swartkrans. Braga and Thackeray[22] have shown that KB 5223 is probably attributable to early *Homo*

+ attributed to *Homo habilis* by Clarke

++ This pathological sample of hominin fossil remains was observed and the data data table prepared by EJO.

SWARTKRANS					
	SK 838b	dental crowding	LM1 lower frag	*P. robustus*	Gibson and Calcagno (1993)
	SK 64	pitted hypoplasia	mandible Rdm2 Rdm3	*P. robustus*	White (1978)
	SWT/TC-8	hypoplasia	M^1	*P. robustus*	Pickering *et al*., (2016)
	SKX 32832	root caries	Rdm2 upper	*P. robustus*	Grine (1989)
	SK 55	carious lesions[3] on palate; enamel hypoplasia	LM1; palate maxilla LM2 LM1 P4 P3; RM3 RM2 RM1	*P. robustus*	Grine Gwinnett and Oaks (1990); Robinson (1952)
	SKX 5023	interproximal carious lesion on mesial surface	RM1 lower (isolated molar)	*P. robustus*	Grine Gwinnett and Oaks (1990)
	SKX 26625	pitted hypoplasia	LP4 upper	*P. robustus*	Grine (1989)
	SKX 28724	pitted hypoplasia	RC upper	*P. robustus*	Grine (1989)
	SK 7923	malignant neoplasm	5th metatarsal (side indet)	Hominidae indet.	Odes *et al*. (2016)
	SK 23	periodontal disease; dental crowding	mandible complete tooth set	*P. robustus*	Robinson (1956); Gibson and Calcagno (1993)
	SK 847	dental abscesses	face partial left orbit maxilla	*H. erectus*	Pers. Comm. Dr Heidi Fourie; Dr U Ripamonti
	SK 15	carious interproximal lesion, mesial surfaces of RM2 (lower) and LM1 (lower)	mandible L&R M2, L&R M2, RM1	*H. erectus*	Robinson (1956)
	SK 13/14	occlusal and mesiobuccal caries; pitted hypoplasia	reconstructed adolescent maxilla with teeth; L&R M1-3; L&R P3-4; palate	*P. robustus*	Grine Gwinnett and Oaks (1990)
	SKX 5017	abnormal bone formation on distal metaphysis; exostotic outgrowth - possible osteochondrosis or trauma	Left Metatarsal (I) (hallucial)	*P. robustus*	Richardson (2005)
	SKX 3342	Abnormal bone formation/ osteophytic formation on margins of vertebral body	thoracic vertebra fragment (T6-T9?)	*H. indet.*	Franklin (2011)
	SK 48	dental crowding		*P. robustus*	Gibson and Calcagno (1993)
	SK 1590b	dental crowding		*P. robustus*	Gibson and Calcagno (1993)
	SKX 35439	abnormal bone formation/enthesopathy	2nd phalanx; insertion of *m. flexor digitorum superficialis*	*H. indet*	Franklin (2011)
	SK 12	alveolar bone loss/ periodontal disease, root caries	maxilla and mandible: Palate, P1 P2, M1, LI1-2, ri1-2, Lc, Rc,	*P. robustus*	Ripamonti (1989)
	SKX 38653	osteophytic formation; abnormal bone formation	2nd phalanx; interphalangeal joint margin	*H. indet*	Franklin 2011
	SWT1/LB-13	enamel hypoplasia Its enamel displays pitting labially and lingually	left permanent I^1	*P. robustus*[23]	Pickering *et al*., 2012

APPENDIX B

SUPPLEMENTAL MATERIAL TO CHAPTER 4: Earliest Hominin Cancer: 1.7-Million-Year-Old Osteosarcoma from Swartkrans Cave, South Africa

Figure 1. (a) and (b) surface rendered models (proximo-dorsal aspects), showing medullary bone infill and clear focalised cortical destruction near the periosteal margin in (b)……85

Figure 2. 5th Metatarsal SK 7923 (a) and (b) surface rendered models (dorso-distal aspects), showing medullary spongy bone infill and clear focalised cortical destruction near the periosteal margin; also evident on external cortical margin directly abutting malignant neoplasm is the characteristic hair on end bone reaction in (b)……...86

Figure 3. (a) and (b). Transverse micro-ct orthoslices through 5th metatarsal SK 7923. (a) The transverse ortholice shows sclerotic cortical margin abutting the neoplasm. The sub-periosteal cortical invasion is clearly evident ventrally, with the medullary cavity mostly infilled with bone. In (b) the cortical bone abutting the neoplasm shows a sclerotic arc for the majority of the area under the neoplasm, and spicular hair on end reaction is evident proximally……...87

Figure 4. (a) and (b). Axial micro-ct orthoslices through SK 7923. Orthoslices taken at lateral aspect of the neoplasm. The posterior and ventral aspect shows sclerosis especially in the cortical regions abutting the neoplasm. The central medullary cavity exhibits clear osteoblastic remodeled bone infill processes. In (b), the distal end of the lesion displays localised sub-periosteal invasion by the mass into the cortex. The cross-section shows that the ossified cauliflower-like mass is not completely fused or integrated with the cortex, but adheres to the cortical surface displaying an irregular spongy woven bone texture. Note the Codman triangle is clearly visible at the distal end of the cortical erosion which appears sclerotic. Image produced by

EJO and PSRQ. The arrow in (a) denotes a Codman triangle; the oblique line denotes a clear example of invasion of cortical bone. The arrow in (b) illustrates invasion of the cortex…….88

Table 1. Detailed differential diagnoses of Swartkrans hominin SK7923 metatarsal.……89

SUPPLEMENTARY APPENDIX

This appendix has been provided by the authors to give readers additional information about their work.

Supplement to: Earliest cancer in the hominin record: 1.7 milllion year old osteosarcoma from Swartkrans Cave, South Africa

Edward J. Odes, Patrick S. Randolph-Quinney, Maryna Steyn, Zach Throckmorton, Jacqueline Smilg, Bernhard Zipfel, Tanya N. Augustine, Frikkie de Beer, Jakobus W. Hoffman, Ryan D. Franklin and Lee R. Berger.

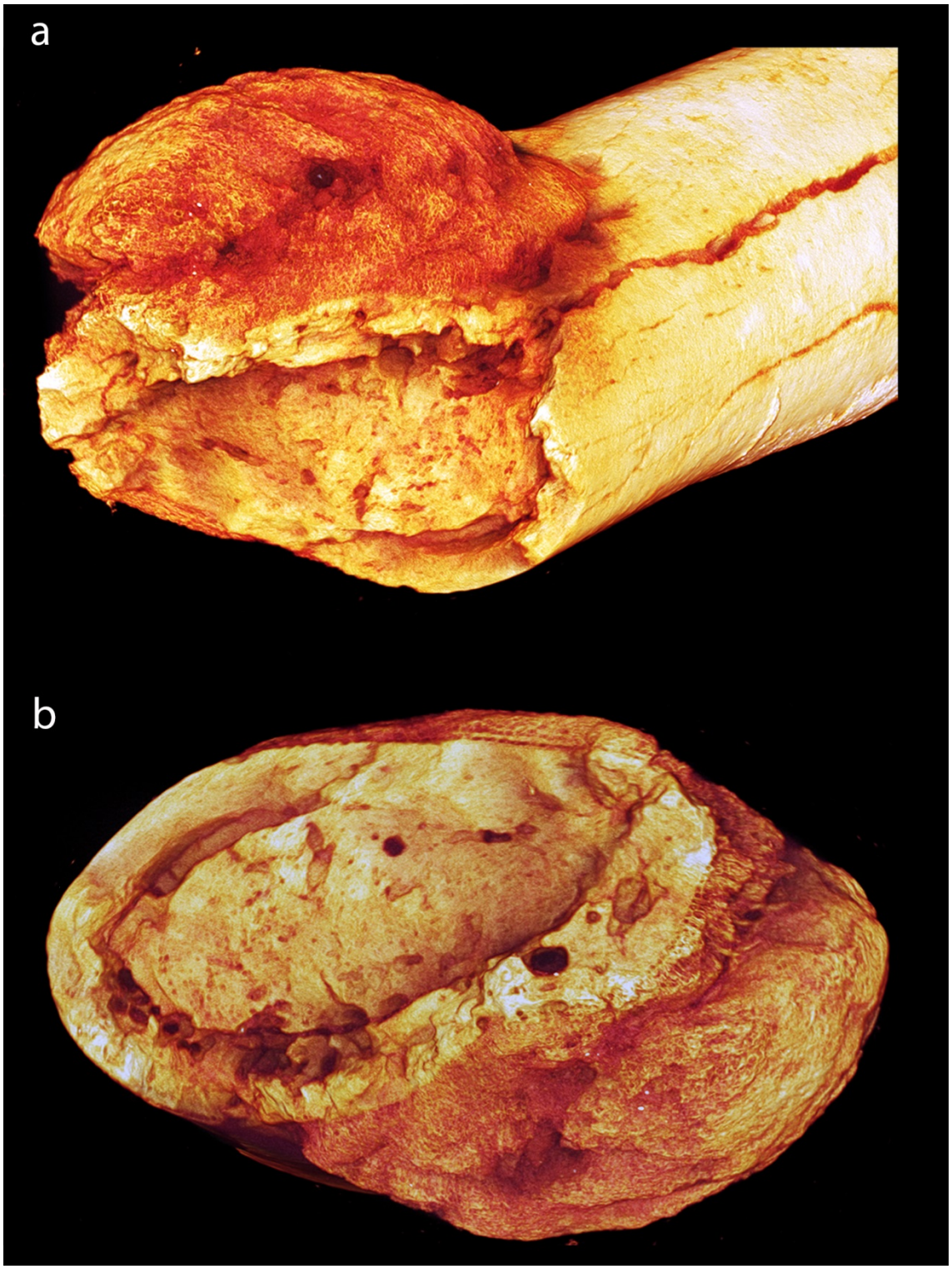

Figure 1. (a) and (b) surface rendered models (proximo-dorsal aspects), showing medullary bone infill and clear focalised cortical destruction near the periosteal margin in (b).

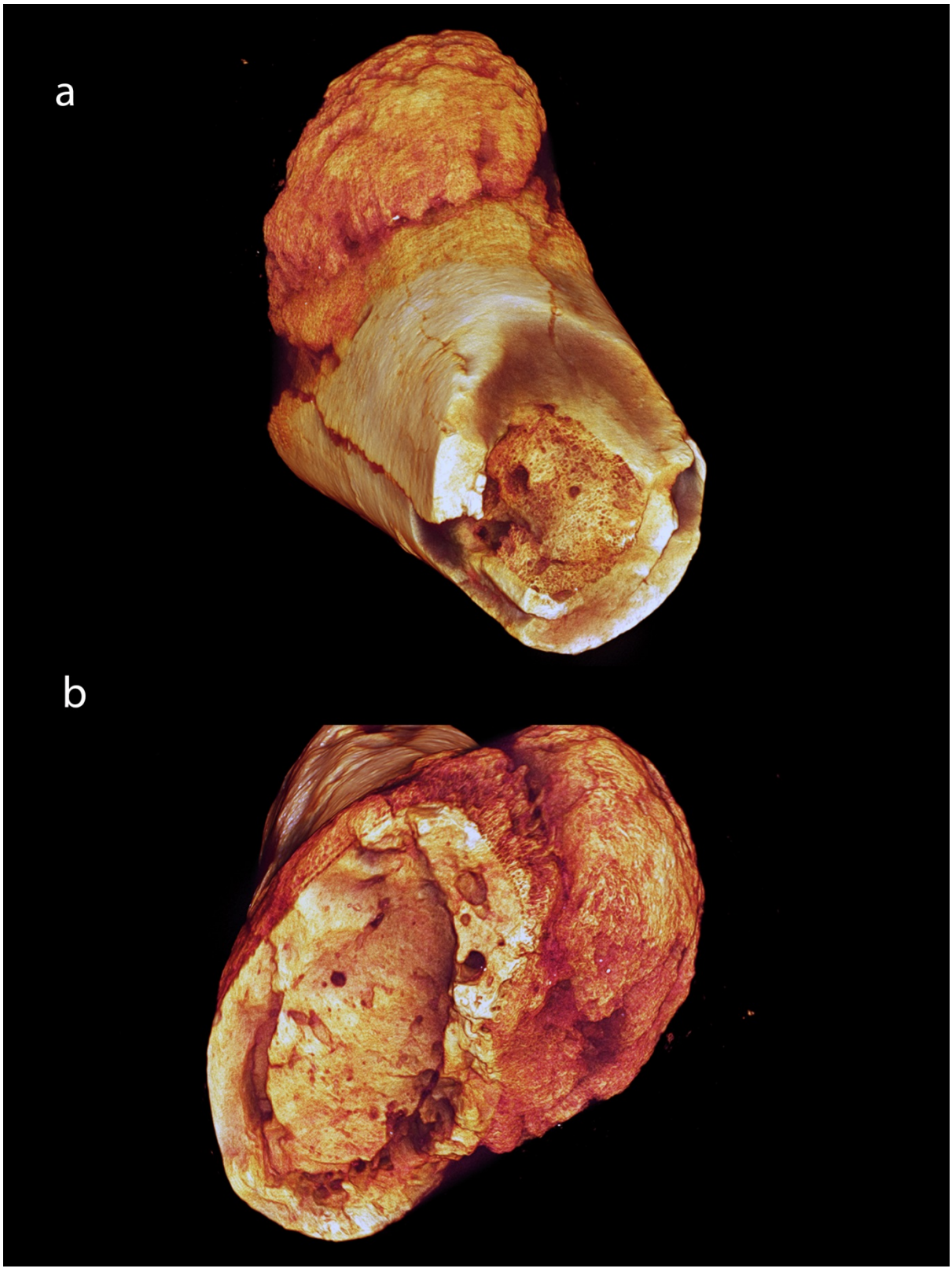

Figure 2. 5th Metatarsal SK 7923 (a) and (b) surface rendered models (dorso-distal aspects), showing medullary spongy bone infill and clear focalised cortical destruction near the periosteal margin; also evident on external cortical margin directly abutting malignant neoplasm is the characteristic hair on end bone reaction in (b).

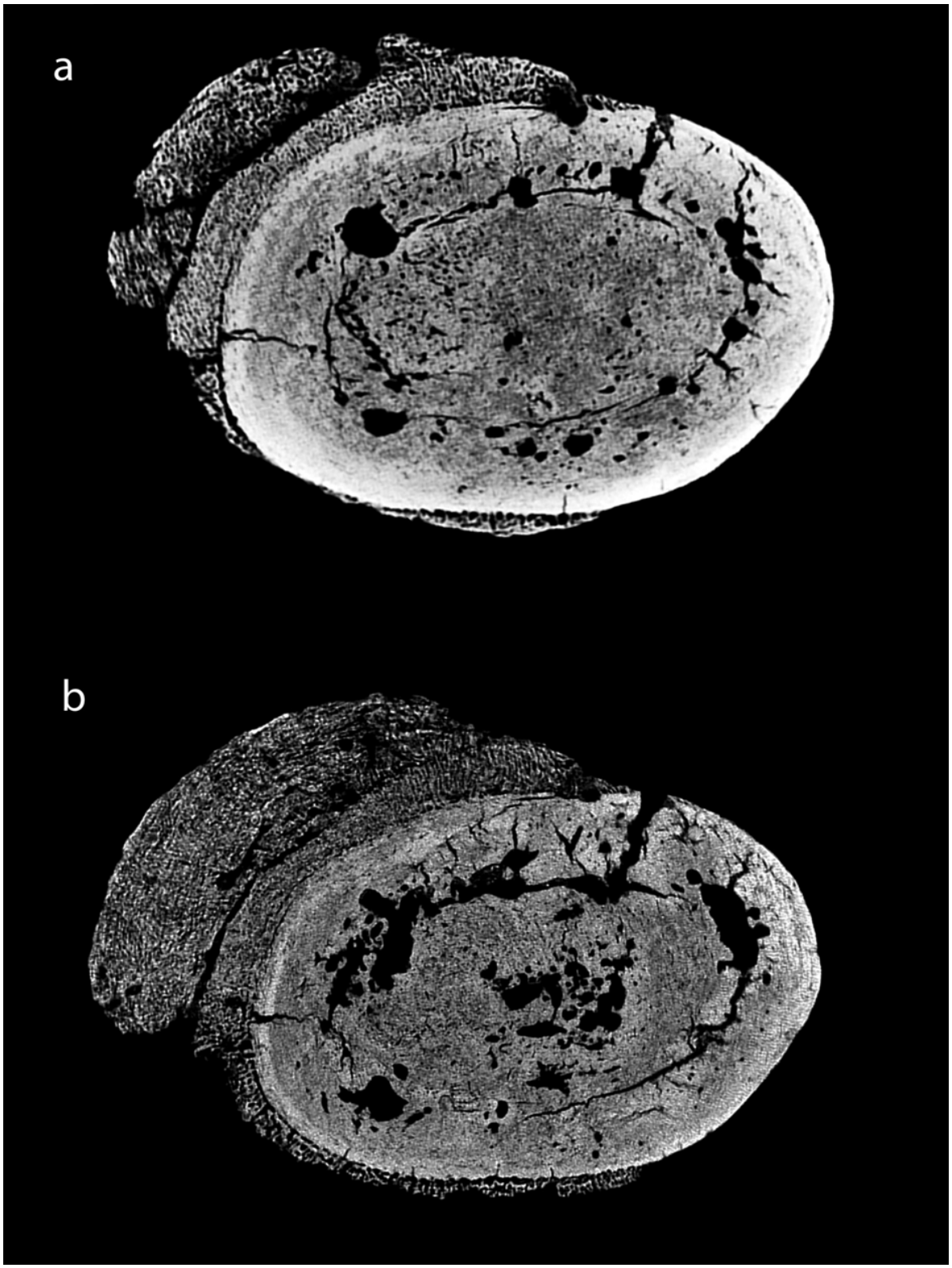

Figure 3. (a) and (b). Transverse micro-ct orthoslices through 5th metatarsal SK 7923. (a) The transverse ortholice shows sclerotic cortical margin abutting the neoplasm. The sub-periosteal cortical invasion is clearly evident ventrally, with the medullary cavity mostly infilled with bone. In (b) the cortical bone abutting the neoplasm shows a sclerotic arc for the majority of the area under the neoplasm, and spicular hair on end reaction is evident proximally.



Figure 4. (a) and (b). Axial micro-ct orthoslices through SK 7923. Orthoslices taken at lateral aspect of the neoplasm. The posterior and ventral aspect shows sclerosis especially in the cortical regions abutting the neoplasm. The central medullary cavity exhibits clear osteoblastic remodelled bone infill processes. In (b), the distal end of the lesion displays localised sub-periosteal invasion by the mass into the cortex. The cross-section shows that the ossified cauliflower-like mass is not completely fused or integrated with the cortex, but adheres to the cortical surface displaying an irregular spongy woven bone texture. Note the Codman triangle is clearly visible at the distal end of the cortical erosion which appears sclerotic. Image produced by ESO and PSRQ. The arrow in (a) denotes a Codman triangle; the oblique line denotes a clear example of invasion of cortical bone. The arrow in (b) illustrates invasion of the cortex.

Table 1. Detailed differential diagnoses of Swartkrans hominin SK7923 metatarsal. Data derived from[1-20].

Disease or condition	Pathological expression	Elements affected	Prevalence
Chondrosarcoma	Chondrosarcoma are malignant cartilaginous neoplasms; slow growing tumour commonly found in tubular bone. Can occur de novo (primary) and also develop on pre-existing benign cartilaginous neoplasms (secondary). May be located in the central region of a bone; can also be on the bone periphery; producing a 'saucer'-type defect in the cortical bone . Chondrosarcomas are large masses and can measure between 4-10 cm. in size. They can exhibit a lytic pattern radiographically or the production of a ring and arc feature , and may include intra-lesional calcifications. It can exhibit regional bone destruction and an expanded cortical shell and trabeculation. A chondrosarcoma can be an extremely large tumour and lies on the surface of a flat or a long bone. Central osteochondromas pressure the cortex and lead to sclerotic margins or endosteal bone 'buttressing' in long bones. A spiculated or periosteal reactivity may be evidenced; soft tissue masses can sometimes also be visible.	Frequently found in long bones (45%); femur (20-35%); tibia (5%); upper limb (mostly proximal humerus) (10-20%); pelvis (25%); ribs (8%); spine (7%) with thoracic most frequent: scapula (5%); sternum (2%); head and neck (inclusive of cervical spine) (7%); craniofacial (2%). Hands and feet are rare and observed with caution. Location comprises 30%-50% of long bone shafts. A second form of chondrosarcoma affects the ribs, scapulae and pelvis.	This type of neoplasm represents 20-27% of all primary malignant tumours. Presents typically in individuals in their forties and fifties. There is a male predominance of 1.5-2:1.
Ewing's sarcoma	Radiographical expressions typically exhibit poorly defined osteolytic lesions and a laminated periosteal reaction (57%). It consistently exhibits on a radiograph either as a neoplastic entity or an inflammation. Radiographic tumours are usually radiolucent, infiltrative, exhibit a moth-eaten and/or a permeative[6] pattern of destruction. Lesion can be mottled, with a laminated periosteal reaction (57%). Occasionally presents with a spiculated hair-on-end response, Codman's triangles, or thick periosteal reaction. Its proliferative response often mimics osteomyelitis; also known to be sclerotic (40%).	Usually affects femoral bone and it is mostly found in central meta-diaphyseal or diaphyseal regions; most common sites affected by this tumour are lower limb (45%), innominate (20%), upper limb (13%), ribs and axial skeleton (13%) and facial bones (2%).	A highly malignant primary tumour of childhood and young adulthood. ES accounts for 10–15% of all primary bone tumours. Typically begins in the medullary cavity and invades the Haversian system. Incidence has been approximated at around 0.6 per million on a yearly basis; It usually occurs between 10-20 years of age. Approx-imately 13 per million are affected in the age bracket 0- 24 years old in the UK. Not commonly encountered in individuals over 25 years old. Male predilection (1.5:1) .

Disease or condition	Pathological expression	Elements affected	Prevalence
Osteochondroma	The lesion comprises cortical and medullary bone, protruding from and continuous with underlying bone; lesions can be sessile or pedunculated; arcs and (rings)/flocculent calcification may be exhibited; in some cases some mineralisation of the cartilage cap and irregular subchondral bone can be evidenced; aggressive structures may be seen including bony destruction, large soft tissue and metastases indicating possible malignancy.	Lower extremity long bones are most often affected (50%); occur mostly above the knee(40%); femur most affected bone (30%), distal regions being the most frequently involved; tibia (15-20%); small bones of the hand and foot (10%); scapula (4%); pelvis (5%); spine (2%). Long bone lesions mostly affect the metaphyseal regions commonly projecting away from epiphysis; diaphyseal involvement is rare	Constitute 10-15% of all bone tumours, and 20%-50% of benign tumours; Symptomatic lesions occur mostly in young patients;75-80% present before 20 years old; male predilection approximately 1.6-3.4:1
Metastatic carcinoma	Metastatic malignancy often simulates benign disease or primary malignancies. Generally metastases lead to skeletal loss and bone formation. Loss can arise out of either osteoclastic activity or enzymatic damage, and bone formation can arise within the neoplastic substrate or the adjacent bone reaction to the neoplasm, equivalent to callus development. Metastases can follow three different processes. They can be either lytic, sclerotic or a combination of sclerotic and lytic. Morphologically metastases can be diffuse, focal or expansive. Bone metastases can be difficult to identify radiographically as between 30 and 50% bone loss is needed before density loss is observable [9]. Other examples are visible by cortical damage and evidence of sclerotic repair. Metastatic neoplasms generally exhibit little or no periosteal reaction.	Metastases usually found in pelvis, vertebrae, proximal femur, proximal humerus and cranium. Uncommonly found on knee and elbow.	Bone metastases make up 70% of malignant bone, with breast malignancy, renal cell carcinoma, lung and prostate malignancy accounting for about 80% of all bone metastases.
Osteoblastoma	Osteoblastoma lesions are benign, mostly lytic; focally obliterative and may be expansive; they appear as radiolucent defects and may present with internal ossification; may have a sclerotic border or periostitis (50%), cortical expansion and some destruction is common; a soft tissue mass may be present; microscopic findings include irregular spicules of mineralised bone, eosinophilic osteoid and woven bone	Commonly found in the metaphysis and distal diaphysis of long bones; spine (up to 46%) , and commonly involves the posterior cervical spine (up to 40%) , and the sacrum (17%) .	Osteoblastoma is a rare primary bone neoplasm and represents approximately 1-3% of all primary bone tumours[16, 17]. It affects mainly adolescents and young adults in the 2nd and 3rd decades of life; wide age range (6-75);

Disease or condition	Pathological expression	Elements affected	Prevalence
	rimmed by osteoblasts . The neoplasm forms osteoid and bone. Vascularity is high. Lesions are typically above 2cm in size.		representing 1% of primary bone tumours; predilection of male to female (2.5:1)
Osteosarcoma	This type of primary malignant tumour typically including a moth-eaten or permeated bone destruction pattern, can exhibit cortical and medullary obliteration, and some degree of tumour matrix mineralisation; exhibits wide zones of transition; presence of aggressive periosteal new bone reaction seen which either can include a lamellated reaction, Codman's triangle and/or a spiculated sunburst-type of reaction; sometimes soft tissue masses are present. Most common form is central osteogenetic sarcoma which could either be an osteoblastic or osteolytic lesion or a mix of both. Osteosarcoma has several categories depending on the focus within the bone, and histology and variation: intramedullary (80%); surface or juxta-cortical (10-15%) and extra-skeletal (5%).	Typically occurs in the metadiaphyseal area of long bones, commonly the distal femur (40%); proximal tibia (16%); humerus (15%). Also occurs less frequently in the mandible, maxilla, clavicle and ribs, os coxae, and vertebrae. Primary tumours exhibit in the metaphyseal areas of long bones, preferring the knee; secondary neoplasms have a preference for flat bones.	Accounting for approximately 20% of all primary bone neoplasms[20]. They can be primary or secondary. Primary osteosarcoma- typically occurring in the 10-20 age group with occurrence < 20 years (75%); Secondary osteosarcoma is prevalent in elderly individuals. Minor male predilection.
Low-grade osteogenic sarcomas	This group of low grade tumours first described by Dahlin and Unni (1977) includes low grade intramedullary and surface forms of osteogenic sarcoma (juxta-cortical osteosarcomas). Their incidence does not more than 5% of all osteogenic sarcomas. Diagnosis is difficult due to its rarity but also because of the complexity of the fibrous surface lesions.		
Low grade intramedullary (Central) Osteogenic Sarcoma	Represents less than 2% of all osteosarcomas. Usually exhibits large medullary sclerotic tumours at the end of long bones. Mixed sclerotic and lytic lesions can be detected. Periosteal new bone formation is rare, as is soft tissue extension. Macroscopically it appears as a slowly growing lesion; clearly distinct mass with erosion of the endosteum. In older lesions cortical invasion can be seen.		

References

1. Ortner DJ. Tumors and tumor-like lesions of bone. In: Ortner DJ, editor. Identification of Pathological Conditions in Human Skeletal Remains. Amsterdam: Academic Press; 2003. p. 503-544.

2. Burchill S. Ewing's sarcoma: diagnostic, prognostic, and therapeutic implications of molecular abnormalities. Journal of Clinical Pathology. 2003;56(2):96-102.

3. Eisenberg R. Bubbly lesions of bone. AJR American Journal of Roentgenology. 2009;193(2):W79-94.

4. Geirnaerdt M, Hogendoorn P, Bloem J, Taminiau A, van der Woude H. Cartilaginous Tumors: Fast Contrast-enhanced MR Imaging 1. Radiology. 2000;214(2):539-546.

5. Huvos A. Ewing's sarcoma. In: Huvos A, editor. Bone tumors: diagnosis, treatment and prognosis. 2nd ed. Philadelphia PA: Sanders; 1991. p. 523-552.

6. Llauger J, Palmer J, Amores S, Bague S, Camins A. Primary tumors of the sacrum: diagnostic imaging. American Journal of Roentgenology. 2000;174(2):417-424.

7. Lucas D, Unni K, McLeod R, O'Connor M, Sim F. Osteoblastoma: clinicopathologic study of 306 cases. Human Pathology. 1994;25(2):117-134.

8. McLeod R, Dahlin D, Beabout J. The spectrum of osteoblastoma. American Journal of Roentgenology. 1976;126:321-325.

9. Murphey M, Walker E, Wilson A, Kransdorf M, Temple H, Gannon F. From the archives of the AFIP: imaging of primary chondrosarcoma: radiologic-pathologic correlation. Radiographics. 2003;23(5):1245-1278.

10. Osborne R. The differential radiologic diagnosis of bone tumors. CA: a cancer journal for clinicians. 1974;24(4):194-211.

11. Trübenbach J, Nägele T, Bauer T, Ernemann U. Preoperative embolization of cervical spine osteoblastomas: report of three cases. American Journal of Neuroradiology. 2006;27(9):1910-1912.

12. Unni K, Dahlin D. Osteosarcoma: pathology and classification. Seminars in Roentgenology. 1989;24(3):143-152.

13. Berry M, Mankin H, Gebhardt M, Rosenberg A, Hornicek F. Osteoblastoma: A 30-Year Study of 99 Cases. J Surg Oncol. 2008;98:179-183.

14. Binning M, Klimo Jr P, Gluf W, Goumnerova L. Spinal Tumors in Children. Neurosurgery Clinics of North America. 2007;18(4):631-658.

15. de Souza Dias L, Frost HM. Osteoid Osteoma - Osteoblastoma. Cancer. 1974;33:1075-1081.

16. Giannico G, Holt G, Holmar K, Johnsson J, Pinnt J, Bridge J. Osteoblastoma characterized by a three-way translocation: report of a case and review of the literature. Cancer Genetics and Cytogenetics. 2009;195:168-171.

17. Lucas DR. Osteoblastoma. Archives of Pathology & Laboratory Medicine. 2010;134:1460-1466.

18. Osborn AG. Tumors, cysts, and tumorlike lesions of the spine and spinal cord. In: Osborn AG, editor. Diagnostic Neuroradiology. St. Louis: Mosby; 1994. p. 876-918.

19. Saccomanni B. Osteoid osteoma and osteoblastoma of the spine: a review of the literature. Current Reviews in Musculoskeletal Medicine. 2009;2:65-67.

20. Vigorita VJ. Orthopaedic Pathology. 2nd Edition ed. Philadelphia: Lippincott Williams & Wilkins.; 2008.

APPENDIX C

SUPPLEMENTAL MATERIAL TO CHAPTER 5: Osteogenic Tumour in *Australopithecus sediba*: Earliest Hominin Evidence for Neoplastic Disease

Table 1. Clinical and epidemiological characteristics: Primary and secondary differential diagnoses for U.W. 88-37 vertebral lesion……96

Table 2. Bayes Theorem parameters for calculating relative probability estimates for primary and secondary differential diagnoses for U.W. 88-37 vertebral lesion…….99

Figure S1: (a) vertebra U.W. 88-37…….103

Figure S2: Sagittal slices through vertebra U.W. 88-37 derived from phase-contrast X-ray synchrotron microtomography. Relative position and anatomical orientation of orthoslices A, B and C are shown on the volume-rendered model. The posterior portion is sclerotic, with circumscribed margins of well-integrated cortical bone, abutted and intersected by trabecular striae, with remodelling and reorganisation of the cortex. The anterior portion of the lesion displays a geographic pattern of bone destruction, showing a sharp non-sclerotic margin and evidence of active osteolytic processes, with sharply defined transection of individual trabeculae, and active osteolytic penetration into the anterior portion of the lamina……104

Supplementary material to: Randolph-Quinney PS, Williams SA, Steyn M, Meyer MR, Smilg JS, Churchill SE, et al. Osteogenic tumour in *Australopithecus sediba*: Earliest hominin evidence for neoplastic disease. S Afr J Sci. 2016;112(7/8), Art. #2015-0470, 7 pages. http://dx.doi.org/10.17159/sajs.2016/20150470

Differential diagnosis of U.W. 88-37

Table 1. Clinical and epidemiological characteristics: Primary and secondary differential diagnoses for U.W. 88-37 vertebral lesion

Disease	Pathological expression	Elements and regions affected	Prevalence (where known)
Osteoid osteoma (OO)	Benign painful tumour. Usually less than 20 mm diameter. Presents clinically as a nidus framed with a thin fibrovascular rim surrounded by sclerotic tissues of host bone. Radiologically seen as round or oval lesions less than 2 cm in diameter, with a 1–2 mm peripheral radiolucent zone in radiographs.	80% of cases found in the long bones. 5–10% of cases found in spine; of these 59% affect lumbar region, 27% cervical, 12% thoracic, and 2% sacrum.	Common. Accounts for over 12% of bone-forming tumours. Mainly affects individuals younger than 30 years. Male to female ratio 2.2:1.
Osteoblastoma (OB)	Also called giant osteoid osteoma. Benign bone-forming tumour; but can present with more aggressive characteristics than OO. Undergoes continuous remodelling and presents as sharply marginated structure with peripheral rind of sclerotic bone; in active cases trabeculae connect with the bony edge of the tumour. May present a nidus surrounded by radiolucent halo similar to OO; 25% of cases mimic a malignant growth.	30–36% of cases occur in the vertebral column; affects dorsal elements (lamina, pedicle, tranverse or spinous process).	Very rare; accounts for less than 1% of all bone-forming tumours. 80–90% of cases are seen in patients younger than 30 years. Male to female ratio 1.9:1
Giant cell tumour (GCT)	Benign tumour. Typically presents as large, diffuse and ill-defined osteolytic areas; lesions tend to be aggressive with multiple compartments. The characteristic radiological features include localised osteolysis with trabeculation in the long bone epiphysis, with metaphyseal extension after physeal fusion and ballooning in flat and irregular bones.	Most common at the end of long bones. The spine is involved in only 7% of cases. When GCT does affect spine, sacrum is usually involved, affecting 90% of cases.	Rare; accounts for 5% of all bone tumours. Most cases are found in adults between 30 and 40 years of age. Condition is slightly more common in women than men.
Aneurysmal bone cyst (ABC)	This is a spongy, multilocular, cystic lesion containing freely flowing blood or fluid. Arises as a consequence of primary bone tumours or trauma. Some aneurysmal cysts present with extensive periosteal new bone formation, whereas others are filled with new bone. Radiologically, ABC appears as a lytic, fluid-filled mass with well-defined smooth margins, often with cortical expansion, although the periosteum usually stays intact.	Can affect virtually any bone, but around 54% of cases are found in the long bones and 16% of cases affect spine. In vertebrae, it commonly affects the posterior elements and has a predilection for the thoracic region.	Rare; occurs in around 3% of biopsied bone tumours. 80% of cases occur under 20 years of age. Male to female ratio 2.5:1.
Enostosis	Not specifically a neoplasm. The lesion is composed of compact lamellar bone and expresses as ovoid, round or oblong in shape, measuring between 2 mm and 20 mm in diameter. When an enostosis occurs in a vertebra, it may have an osteoma-like appearance and is termed an endosteoma. Enostoses in the vertebrae are usually ivory-dense, and border but do not invade the endplate.	Can affect any bone. Specific regional incidence is unknown, but primarily affects the long bones, followed by pelvis and spine.	General incidence is unknown. Males and females are nearly equally affected.

Disease	Pathological expression	Elements and regions affected	Prevalence (where known)
Fibrous cortical defect (FCD)	Also known as fibroxanthoma or benign fibrous histiocytoma. Benign bony lesion is histologically identical to larger non-ossifying fibroma (NOF). Appear as small (< 20–30 mm) lucent defects within the cortex that become sclerotic as they heal. Radiographically, FCD presents as a longitudinally stretched lucent defect surrounded by a thin sclerotic rim in the metaphyses of the long bones.	Typically located in distal femur, proximal or distal tibia, and less frequently in upper limb. Very rare in vertebrae, with only 11 such cases having been reported worldwide by 2010.	Typically occur in children. One of the most common benign bony lesions; when combined with NOF, are seen in up to 30–40% of subadults. Male to female ratio 2:1.
Plasmacytoma (PM)	Plasmacytoma is a systemic malignant cancer. Typically presents as ill-defined osteolytic areas. Commonly leads to complete destruction of vertebra, including intrusion into contents of neural canal.	Has a predilection for the thoracic spine and can involve the posterior vertebral components.	PM is the most frequent primary tumour affecting the skeleton.
Eosinophilic granuloma (EO)	Also known as Langerhans-cell histiocytosis. Benign. Resembles an inflammatory process rather than neoplasm. Presents as single autoimmune tumour because of the overproduction of histiocytes. Solitary lesions typically have a broad zone of transition, with ill-defined borders, indicating aggressive growth.	Usually manifests in the thoracic spine; affects the centrum, leading to a collapse and flattening. May also occasionally appear on posterior vertebral components.	General incidence is unknown. Most frequently observed in children aged 5–15 years. Male to female ratio 2:1.
Hydatid cyst infection (HCI)	A parasitic infestation. One of the oldest worldwide human diseases known; caused by larval *Echinococcus granulosus* tapeworm. Spreads by drinking water or eating plants contaminated with faeces of carnivores. In vertebrae, it is characterised by multivesicular diffuse infiltration of cancellous bone, including corpus, pedicles and laminae. Common in thoracic region, but does not remain localised.	Frequency of skeletal involvement is rare, leading to bony changes in only 2% of cases. Of these, vertebral column is the most common site of expression – occurring in around 42% of skeletal cases.	The present and archaeological distribution of the disease is closely tied to the use of dogs for herding cattle and sheep. No age or sex bias is reported in clinical cases.

Source: *Data derived from listed references*[1-25]

Differential diagnosis of U.W. 88-37: Bayesian statistical parameters

To quantifiably assess the likelihood of the differential diagnosis between osteoid osteoma and osteoblastoma, we applied Bayes Theorem of conditional probability to differentiate between the two pathological conditions. The Bayesian approach assesses the likelihood of the incidence of a particular event. It enables the combination of objective probabilities, such as clinical data, and subjective probabilities (e.g. knowledge and experience of clinicians) to calculate these probability estimates.[26]

The statistical basis of Bayes Theorem is an understanding of the probability (P) of the occurrence of an event, or of a hypothesis (H) being true, given a particular set of evidence (E). In addition, the theorem uses influential background knowledge or information (*b*) that is available when the likelihood of H is considered.[27-31] We thus focus on the relationship between independent and non-independent events which influence the final outcome probability.[27-31] The P of H is referred to as *conditional probability*, which acknowledges that H is conditional or dependent on available evidence E. This calculation is usually denoted as $P(H \mid E)$, which can be read as 'the probability of event H, given evidence E'. The vertical bar separates the event on the left (whose probability is of interest) from events on the right (whose outcomes are known and may affect the probability of the event of interest). The vertical bar therefore means 'conditional on'. Furthermore, $P(H \mid E.b)$ represents the probability of H given E, taking into account relevant background information *b*. This is calculated as follows:

$$P(H \mid E.b) = \frac{P(H \mid b)P(E \mid H.b)}{P(H \mid b)P(E \mid H.b) + P(\neg H \mid b)P(E \mid \neg H.b)}$$

Where P(H) is the prior probability that H is true, and $P(\neg H)$ the prior probability that H is false. $P(E \mid H)$ and $P(E \mid \neg H)$ represent conditional or consequent probabilities given available evidence and background information. Based on clinical incidence data, we estimate the prior and consequent probabilities for the two pathological conditions of interest, as shown in Table S2.

Table S2. Bayes Theorem parameters for calculating relative probability estimates for primary and secondary differential diagnoses for U.W. 88-37 vertebral lesion

Probability function	**Osteoblastoma: clinical incidence**	**Osteoid osteoma: clinical incidence**
$P(H \mid b)$	0·01	0·12
$P(\neg H \mid b)$	0·99	0·88
$P(E \mid H.b)$	0·36	0·10
$P(E \mid \neg H.b)$	0·05	0·05
Relative Probability	*0·068*	*0·214*

The basis of our analysis starts from acceptance that the pathological condition H is caused by primary neoplastic disease of bone. Based on published epidemiological incidence data for osteoid osteoma[19-21] and osteoblastoma[19-25], we accept the prior probability that P(H | b) represents osteoblastoma (OB) as 1% (P = 0·01) and osteoid osteoma (OO) as 12% (P=0·12). Hence OB accounts for less than 1% of bone-forming tumours, whereas OO expresses in around 12% of clinical cases. P(¬H | b) represents the probability that P(H | b) is false. We next assume conditional probabilities [P(E | H.b)] based on the specific anatomical region where each condition manifests in the skeleton. In this case, we assume P=0.36 for osteoblastoma (up to 36% of cases of OB occur in the vertebral column) and P=0·1 for osteoid osteoma (up to 10% of OO cases occur in the region). A false likelihood probability of 5% (P=0·05) is accepted for each condition. On the basis of these prior and conditional probabilities of expression in the vertebral column (as opposed to elsewhere in the skeleton), we derive a conditional probability of 0·214 for the likelihood of osteoid osteoma, and 0·068 for osteoblastoma. This result indicates a 3·75-fold likelihood that osteoid osteoma rather than osteoblastoma is represented in the case under study.

Methods of image data acquisition and visualisation

The U.W. 88-37 vertebral specimen was imaged using propagation phase-contrast X-ray synchrotron microtomography, performed at the European Synchrotron Radiation Facility (ESRF) in Grenoble, France, on the beamline ID19. The imaging was done immediately after the complete imaging of the skull of MH1 performed on ID17.[32] This technique is today widely accepted as the gold standard for high quality 3D non-destructive imaging fossils.[33,34] The specimen was imaged in conjunction with a number of other anatomical elements from MH1 of similar size; the specimen was later cropped out from the combined plate to obtain an isolated volume.

Regarding the size and mineralisation level of the specimens, we used a high-energy polychromatic beam on the beamline ID19 of 55*10mm. To reach suitable effective energy, the white beam produced by the ID19 W150 wiggler with a gap closed at 60 mm was filtered with 3 mm of aluminium and 1 mm of copper, resulting in an average energy of 72 keV. The detector was a FreLoN 2K (Fast Readout Low Noise) CCD (charged couple device) camera[35], mounted on an optical system providing a final voxel size of 30.93 µm. This indirect detector was coupled with a 750-µm-thick LuAG:Ce (Lutetium Aluminium Garnet doped with Cerium) scintillator. When combining the polychromatic spectrum with the detector properties, the average detected energy was 76 keV (see source and detected spectrums). These parameters allow about 30% of minimum transmission through the specimens, with a reasonably small bandwidth (see Figure S3). The result is data that are nearly free of beam-hardening artefacts, but with a far faster acquisition speed than when using monochromatic beam and at a higher dynamical level. A propagation distance of

900 mm was used to obtain some phase-contrast effect, to enhance the visibility of the smallest structures and to increase the signal-to-noise ratio.

The plate with the different samples mounted was imaged using half-acquisition geometry (centre of rotation on one side of the field of view, coupled with 360° rotation) to increase the lateral field of view 1·8-fold relative to the normal view. Scans were performed using 4000 projections of 0·2 s each, over 360°, in continuous rotation mode. We used the frame transfer mode of the camera, which allows one to work without a physical shutter as long as the exposure time is greater than 0·1 s. Each scan lasted 21 min, and 24 scans were performed to image the full plate. The specimen was moved by half of the vertical field of view for each new scan, to ensure that each part of the fossils was imaged twice, using both the centre and border of the beam. This double-scanning approach, with suitable vertical concatenation, avoids the vertical power and spectral gradients from the wiggler source, ensuring constant dynamical level for the imaging of the whole specimen.

The radiographic data were then reconstructed using PyHST software (developed at ESRF). The reconstructions were based on filtered back-projection algorithms combined with a single distance phase retrieval process, adapted from Paganin and colleagues[36]. We applied the reconstruction protocol described by Sanchez and colleagues[37], by adding a 3D unsharp filter on the reconstructions after the phase retrieval process. This compensates for blurring introduced by the algorithm and allows retention of the higher sensitivity of phase retrieval process, without loss of the resolution from the edge detection effect. This approach can provide data similar to absorption contrast, as the specimens are relatively homogeneous regarding their chemical composition, but with a signal-to-noise ratio about 50 times better than real absorption scans, and a higher visibility of small details.[37] Finally, a light correction of ring artefacts was applied on reconstructed slices to ensure the highest possible quality of the final volume.

The 3D renderings and segmentation were performed using the software VGStudioMax 2·2 (Volume Graphics, Heidelberg, Germany). The rendering for solid views was performed with Phong's algorithm in volume rendering, with false colours attributed to different grey levels of tomographic data (dark brown for bone to light brown for matrix), and a projected shadow effect. Segmentation of the lesion was made in three steps. First, missing bone surface was recreated by a mirror image of the other side of the vertebra, to delineate the volume of lesion enclosed in the original bone shape. Then the empty cavity was segmented by simple region growing. Finally, a manual segmentation mask was performed for the area still filled with matrix, by careful delineation on one slice in every four. This first mask was then used to constrain a new region growing to segment only the matrix part, after which the bone was removed from the original segment. The final result was segmentation as close as possible to the real lesion surface, up to the detail levels. The 3D rendering of the lesion was then performed using false colours attributed to the grey levels (from red applied on air and matrix to light pink for voxels in direct contact with bones). Finally, a semi-transparent model of the complete vertebra with the lesion was prepared by selecting a 10-

voxel-thickness layer on the whole surface of the vertebra, set as transparent with Phong algorithm at 10%. (See Supplementary Figure S1.) All this imaging, data processing, segmentation and 3D rendering were performed by P.T.

Additional imaging of user-defined and oriented orthoslices was undertaken by P.S.R.Q. using Avizo Amira 5·4·5. Orthoslices were produced through secondary reconstruction of the image volume, with manipulation of orthogonal axes using the multi-planar viewer facility (see Supplementary Figure S2).

Additional medical imaging data



Figure S1: (a) vertebra U.W. 88-37.

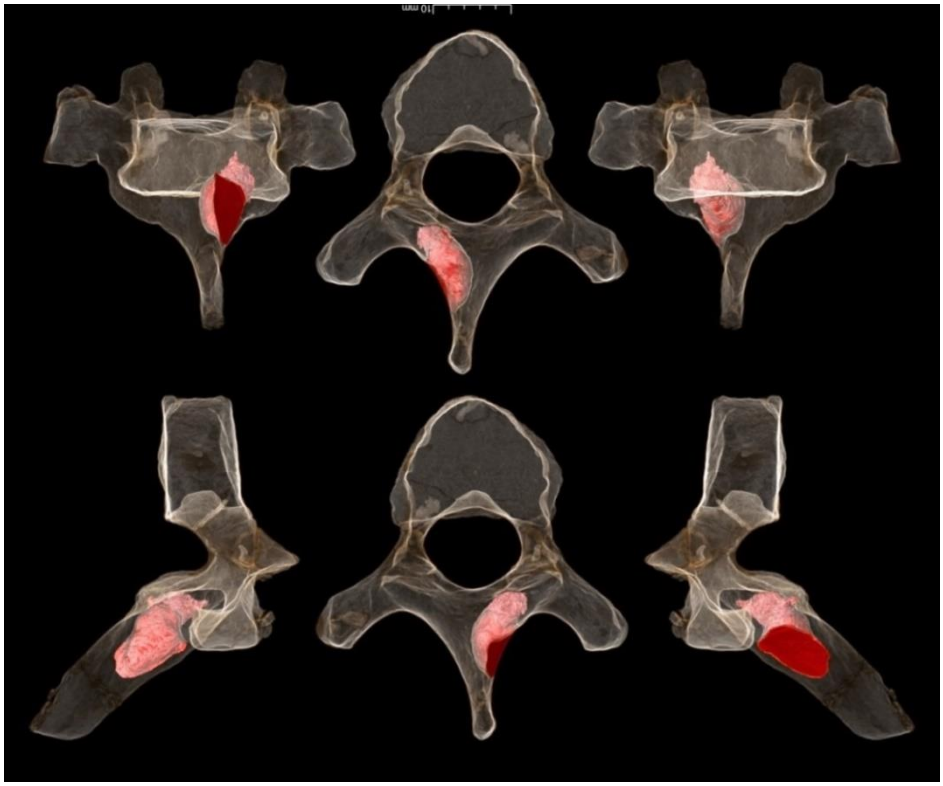

Figure S1: (b) additional images of surface-rendered image volume.

Images produced by P.T.

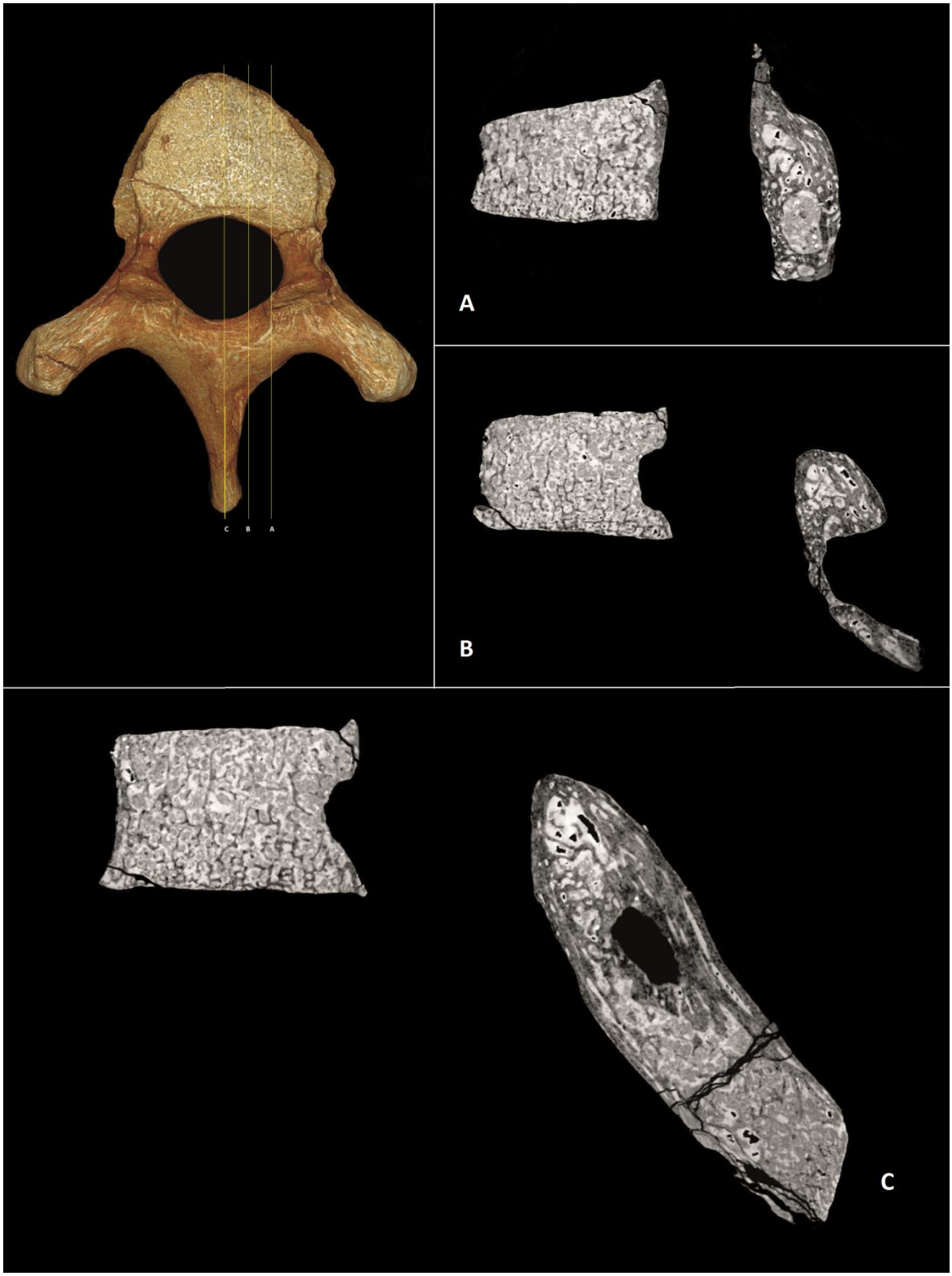

Figure S2: Sagittal slices through vertebra U.W. 88-37 derived from phase-contrast X-ray synchrotron microtomography. Relative position and anatomical orientation of orthoslices A, B and C are shown on the volume-rendered model. The posterior portion is sclerotic, with circumscribed margins of well-integrated cortical bone, abutted and intersected by trabecular striae, with remodelling and reorganisation of the cortex. The anterior portion of the lesion displays a geographic pattern of bone destruction, showing a sharp non-sclerotic margin and evidence of active osteolytic processes, with sharply defined transection of individual trabeculae, and active osteolytic penetration into the anterior portion of the lamina. Images produced by P.S.R.Q.

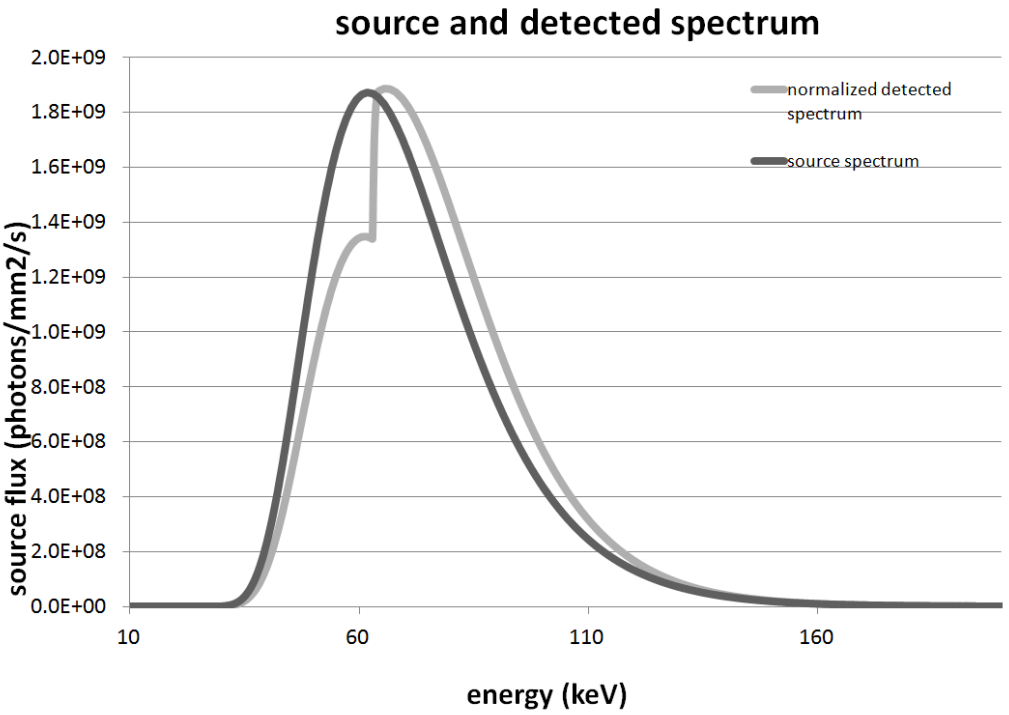

Figure S3: Source and detected spectrum for imaging of U.W. 88-37 conducted on beamline ID19

References

1. Ortner DJ. Tumors and tumor-like lesions of bone. In: Ortner DJ, editor. Identification of pathological conditions in human skeletal remains. Amsterdam: Academic Press; 2003. p. 503–544. http://dx.doi.org/10.1016/B978-012528628-2/50057-0
2. Bahk Y-W. Combined scintigraphic and radiographic diagnosis of bone and joint diseases. New York: Springer; 2007. http://dx.doi.org/10.1007/978-3-540-68732-0_4
3. Khurana JS. The surgical pathology of bone tumors and tumor-like lesions. In: Khurana JS, editor. Bone pathology. London: Humana Press; 2009. p. 285–345. http://dx.doi.org/10.1007/978-1-59745-347-9_19
4. McCall IW. Radiology and pathological correlations of bone tumours of the spine. In: Gourtsoyiannis NC, Ros PR, editors. Radiologic-pathologic correlations from head to toe: Understanding the manifestations of disease. Berlin: Springer; 2005. p. 721–742. http://dx.doi.org/10.1007/3-540-26664-X_32
5. Vigorita VJ. Orthopaedic pathology. 2nd ed. Philadelphia: Lippincott Williams & Wilkins; 2008.
6. Baba H, Maezawa Y, Furusawa N, Wada M, Kokubo Y, Imura S, et al. Solitary plasmacytomas of the spine associated with neurological complications. Spinal Cord. 1998;36(7):470–475. http://dx.doi.org/10.1038/sj.sc.3100572
7. Berry M, Mankin H, Gebhardt M, Rosenberg A, Hornicek F. Osteoblastoma: A 30-year study of 99 Cases. J Surg Oncol. 2008;98:179–183. http://dx.doi.org/10.1002/jso.21105
8. Betsy M, Kupersmith LM, Springfield DS. Metaphyseal fibrous defects. J Am Acad Orthop Surg. 2004;12(2):89–95. http://dx.doi.org/10.5435/00124635-200403000-00004
9. Binning M, Klimo Jr P, Gluf W, Goumnerova L. Spinal tumors in children. Neurosurg Clin N Am. 2007;18(4):631–658. http://dx.doi.org/10.1016/j.nec.2007.07.001

10. McLain RF, Weinstein JN. Solitary plasmacytomas of the spine: A review of 84 cases. J Spinal Disord. 1989;2(2):69–74. http://dx.doi.org/10.1097/00002517-198906000-00001

11. Mendenhall WM, Zlotecki RA, Scarborough MT, Gibbs CP, Mendenhall NP. Giant cell tumor of bone. Am J Clin Oncol. 2006;29(1):96–99. http://dx.doi.org/10.1097/01.coc.0000195089.11620.b7

12. Celik C, Münevver FS, Ucan H. Spinal hydatid cyst: Review. Türkiye Klinikleri J Med Sci. 2010;30(3):1073–1077. http://dx.doi.org/10.5336/medsci.2009-13722

13. Kransdorf MJ, Sweet DE. Aneurysmal bone cyst: Concept, controversy, clinical presentation, and imaging. Am J Roentgenol. 1995;164(3):573–580. http://dx.doi.org/10.2214/ajr.164.3.7863874

14. Osborn AG. Tumors, cysts, and tumorlike lesions of the spine and spinal cord. In: Osborn AG, editor. Diagnostic neuroradiology. St. Louis: Mosby; 1994. p. 876–918.

15. Kuruvath S, O'Donovan DG, Aspoas AR, David KM. Benign fibrous histiocytoma of the thoracic spine: Case report and review of the literature. J Neurosurg Spine. 2006;4(3):260–264. http://dx.doi.org/10.3171/spi.2006.4.3.260

16. Kaye JJ, Freiberger RH. Eosinophilic granuloma of the spine without vertebra plana: A report of two unusual cases. Radiology. 1969;92(6):1188–1191. http://dx.doi.org/10.1148/92.6.1188

17. Aufderheide AC, Rodríguez-Martin C. The Cambridge encylopedia of human paleopathology. Cambridge: Cambridge University Press; 1998.

18. Kan P, Schmidt MH. Osteoid osteoma and osteoblastoma of the spine. Neurosurg Clin North Am. 2008;19(1):65–70. http://dx.doi.org/10.1016/j.nec.2007.09.003

19. de Souza Dias L, Frost HM. Osteoid Osteoma–Osteoblastoma. Cancer. 1974;33(4):1075–1081. http://dx.doi.org/10.1002/1097-0142(197404)33:4<1075::AID-CNCR2820330427>3.0.CO;2-4

20. Azouz EM, Kozlowski K, Marton D, Sprague P, Zerhouni A, Asselah F. Osteoid osteoma and osteoblastoma of the spine in children: Report of 22 cases with brief literature review. Pediatr Radiol. 1986;16(1):25–31. http://dx.doi.org/10.1007/BF02387501

21. Saccomanni B. Osteoid osteoma and osteoblastoma of the spine: A review of the literature. Curr Rev Musculoskelet Med. 2009;2(1):65–67. http://dx.doi.org/10.1007/s12178-009-9047-6

22. Lucas DR. Osteoblastoma. Arch Pathol Lab Med. 2010;134:1460–1466.

23. Amacher AL, Eltomey A. Spinal osteoblastoma in children and adolescents. Child Nerv Syst. 1985;1(1):29–32. http://dx.doi.org/10.1007/BF00706727

24. Aszódi K. Benign osteoblastoma: Quantitative histological distinction from osteoid osteoma. Arch Orthop Unfallchir. 1977;88(3):359–368. http://dx.doi.org/10.1007/BF00416625

25. Boriani S, Capanna R, Donati D, Levine A, Picci P, Savini R. Osteoblastoma of the spine. Clin Orthop Relat Res. 1992;278:37–45. http://dx.doi.org/10.1097/00003086-199205000-00006

26. Lucy, D. Introduction to statistics for forensic scientists. London: Wiley; 2005.

27. Byers SN, Roberts CA. Bayes' theorem in paleopathological diagnosis. Am. J. Phys. Anthropol. 2003;121:1–9. http://dx.doi.org/10.1002/ajpa.10164

28. Evett IW. Bayesian-inference and forensic-science – Problems and perspectives. Statistician. 1987;36:99–105. http://dx.doi.org/10.2307/2348502

29. Taroni F, Aitken CGG. Probabilistic reasoning in the law – Part 1: Assessment of probabilities and explanation of the value of DNA evidence. Sci. Justice. 1998;38:165–177. http://dx.doi.org/10.1016/S1355-0306(98)72101-X

30. Taroni F, Aitken CGG. Probabilistic reasoning in the law – Part 2: Assessment of probabilities and explanation of the value of trace evidence other than DNA. Sci. Justice. 1998;38:179–188. http://dx.doi.org/10.1016/S1355-0306(98)72102-1

31. Taroni F, Bozza S, Aitken C. Decision analysis in forensic science. J. Forensic Sci. 2005;50:894–905. http://dx.doi.org/10.1520/JFS2004443

32. Carlson KJ, Stout D, Jashashvili T, de Ruiter DJ, Tafforeau P, Carlson K, Berger LR.The endocast of MH1, Australopithecus sediba. Science. 2011;333:1402–1407. http://dx.doi.org/10.1126/science.1203922

33. Tafforeau P, Hublin JJ, Smith TM. Hominin dental structure and development revealed non-destructively by multi-scale synchrotron imaging. Am J Phys Anthropol. 2009:252–252.

34. Tafforeau P, Boistel R, Boller E, Bravin A, Brunet M, Chaimanee Y, et al. Applications of X-ray synchrotron microtomography for non-destructive 3D studies of paleontological specimens. Appl Phys A-Mater. 2006;83:195–202. http://dx.doi.org/10.1007/s00339-006-3507-2

35. Labiche J-C, Mathon O, Pascarelli S, Newton MA, Ferre GG, Curfs C, et al. Invited article: The fast readout low noise camera as a versatile x-ray detector for time resolved dispersive extended x-ray absorption fine structure and diffraction studies of dynamic problems in materials science, chemistry, and catalysis. Rev Sci Instrum. 2007;78, Art. #091301. http://dx.doi.org/10.1063/1.2783112

36. Paganin D, Mayo S, Gureyev T, Miller P, Wilkins S. Simultaneous phase and amplitude extraction from a single defocused image of a homogeneous object. J Microsc Oxford. 2002;206:33–40. http://dx.doi.org/10.1046/j.1365-2818.2002.01010.x

37. Sanchez S, Ahlberg P, Trinajstic K, Mirone A, Tafforeau P. Three-dimensional synchrotron virtual paleohistology: A new insight into the world of fossil bone microstructures. Microsc Microanal. 2012;18:1095–1105. http://dx.doi.org/10.1017/S1431927612001079

APPENDIX D

SUPPLEMENTAL MATERIAL TO CHAPTER 6: Osteopathology and Insect Traces in the *Australopithecus africanus* Skeleton StW 431

Supplementary table 1: List of modern non-pathological and pathological human vertebral specimens; fossils with purported insect damage; and modern proven radiological and clinical examples of brucellosis……110

Supplementary material to: Odes EJ, et al. S Afr J Sci. 2017;113(1/2), Art. #2016-0143, 7 pages.

How to cite: Odes EJ, Parkinson AH, Randolph-Quinney PS, Zipfel B, Jakata K, Bonney H, et al. Osteopathology and insect traces in the *Australopithecus africanus* skeleton StW 431 [supplementary material]. S Afr J Sci. 2017;113(1/2), Art. #2016-0143, 5 pages. http://dx.doi.org/10.17159/sajs.2017/20160143/suppl

Supplementary table 1: List of modern non-pathological and pathological human vertebral specimens; fossils with purported insect damage; and modern proven radiological and clinical examples of brucellosis

Skeletal specimen	Element	Skeletal pathology	Fossils with purported insect traces similar in shape to StW 431	Fossil anatomical element (with purported modification)	Reference collection
Modern human specimens with pathology[a]					
A 2972, A 7790, X0095, AD 6059 A3387, A0204, A2746 A1945 X 0088 X 0421	Lumbar/thoracic vertebrae	Osteophytes/parrot beak feature Schmorl's nodes Superior endplate erosion Compression superior endplate			Raymond A. Dart Human Skeletal and Teaching Collections (Wits)

Table continues…

Modern human specimens with no pathology[b]					
A 2721, X 0490, AD 5810, X 0469, A 2415, X 0167, A 1600, X 0080, X 0285, A 2463, A 1605, A 1611, AD 7262, 6616, X 0293, A 2131, A 1623, A 2184, A 2463, X 0474, A 2737, A 1804, A 152, X 0520, X 0528, X 0468, AD 5971, A 2372, X 0527, X 0528, X 0296, X 0045, A 3405, A 2601, A 271, A 2095, A 2983, A 3284, X 0529, 5090, X 0528, A 3231, X 0525, A 282, X 0165, X 0165, A 2746, A 3053, A 1646, A 3206, A 2170, X 0490, X 0531, A 2655, X 0087, A 2983, X 0531, A 1623, A 2974, A2983, A 2597, A 1623, A 3387, X 0525, X 0530, X 0192, X 0528	Lumbar/thoracic vertebrae	No pathology observed			Raymond A. Dart Human Skeletal and Teaching Collections (Wits)
Modern human proven radiological and clinical examples of brucellar disease[c]					
Brucellar spondylitis[1-5] (focal and diffuse), osteoarticular complications associated with brucellosis (sacroiliitis, monoarthritis, oligoarthritis, peripheral arthritis)[20-23] Brucellar spondylodiscitis[15-16,19]	Lumbar/ thoracic/sacral vertebrae	Erosions of vertebral endplates (including anterior superior erosions); sclerosis of vertebral endplates; spinal osteomyelitis of neighbouring discs; loss of disc space; 'parrot beak' osteophyte formation; degenerative disc disease; paravertebral abscesses [1-18]			

Fossil faunal and non-human primate and experimental specimens[d]					
16697-39			Ovoid pit	Bison metacarpal	West and Hasiotis[24]
16275-39			Large ovoid pit	Bison phalanx I	West and Hasiotis[24]
16585-39			Large ovoid pit	Bison astragalus	West and Hasiotis[24]
CD 13301			Large circular pit	Hyaenid 2nd phalanx	Cooper's Cave collection, Phillip Tobias Hominin Laboratory (PTHL)
CD 5288			Small pits	Primate lumbar vertebra	PTHL
CD 036			Small pits (lateral)	Bovid lumbar vertebra	PTHL
LACMHC 140712			Dermestid damage. (Fig. 1C) [21] small and medium dermestid pits overlapped by tenebrionid quarry	Bison left proximal sesamoid	Holden et al.[25]
Experimental specimen			Dermestid damage, Fig. 2A[21]	Chicken distal right tarsometatarsus	Holden et al.[25]
LACMHC Z1835			Dermestid damage. Fig. 2B[21]	camel proximal sesamoid, showing dermestid pit walls	Holden et al.[25]

[a]pathological; [b]non-pathological; [c]fossil and experimental specimens; [d]radiological/clinical examples of brucellosis

References

1. Al-Shahed MS, Sharif HS, Haddad MC, Aabed MY, Sammak BM, Mutairi MA. Imaging features of musculoskeletal brucellosis. Radiographics. 1994;14(2):333–348. http://dx.doi.org/10.1148/radiographics.14.2.8190957
2. Bouaziz MC, Ladeb MF, Chakroun M, Chaabane S. Spinal brucellosis: A review. Skeletal Radiol. 2008;37(9):785–790. http://dx.doi.org/10.1007/s00256-007-0371-x
3. Madkour MM, Sharif HS, Abed MY, Al-Fayez MA. Osteoarticular brucellosis: Results of bone scintigraphy in 140 patients. Am J Roentgenol. 1988;150(5):1101–1105. http://dx.doi.org/10.2214/ajr.150.5.1101
4. Madkour MM. Madkour's brucellosis. Berlin: Springer; 2001. http://dx.doi.org/10.1007/978-3-642-59533-2
5. Gotuzzo E, Alarcón GS, Bocanegra TS, Carrillo C, Guerra JC, Rolando I, et al. Articular involvement in human brucellosis: A retrospective analysis of 304 cases. Semin Arthritis Rheum. 1982;12(2):245–255. http://dx.doi.org/10.1016/0049-0172(82)90064-6
6. Gotuzzo ED, Seas C, Guerra JG, Carrillo C, Bocanegra TS, Calvo A, et al. Brucellar arthritis: A study of 39 Peruvian families. Ann Rheum Dis. 1987;46(7):506–509. http://dx.doi.org/10.1136/ard.46.7.506
7. Pourbagher A, Pourbagher MA, Savas L, Turunc T, Demiroglu YZ, Erol I, et al. Epidemiologic, clinical, and imaging findings in brucellosis patients with osteoarticular involvement. Am J Roentgenol. 2006;187(4):873–880. http://dx.doi.org/10.2214/AJR.05.1088
8. Sharif HS, Aideyan OA, Clark DC, Madkour MM, Aabed MY, Mattsson TA, et al. Brucellar and tuberculous spondylitis: Comparative imaging features. Radiology. 1989;171(2):419–425. http://dx.doi.org/10.1148/radiology.171.2.2704806
9. Özaksoy D, Yücesoy K, Yücesoy M, Kovanlıkaya I, Yüce A, Naderi S. Brucellar spondylitis: MRI findings. Eur Spine J. 2001;10(6):529–533. http://dx.doi.org/10.1007/s005860100285
10. Karabay O, Gurel K, Sirmatel O, Sirmatel F. Brucellar spondylitis (Pedro-Pons' sign). New Zeal Med J. 2007;120:97–99.
11. Solera J, Lozano E, Martínez-Alfaro E, Espinosa A, Castillejos ML, Abad L. Brucellar spondylitis: Review of 35 cases and literature survey. Clin Infect Dis. 1999;29(6):1440–1449. http://dx.doi.org/10.1086/313524
12. Colmenero JD, Reguera JM, Fernandez-Nebro A, Cabrera-Franquelo F. Osteoarticular complications of brucellosis. Ann Rheum Dis. 1991;50(1):23–26. http://dx.doi.org/10.1136/ard.50.1.23

13. Doganay M, Aygen B. Human brucellosis: An overview. Int J Infect Dis. 2003;7(3):173–182. http://dx.doi.org/10.1016/S1201-9712(03)90049-X
14. Ekici MA, Özbek Z, Kazancı B, Güçlü B. Collapsed L4 vertebral body caused by brucellosis. J Korean Neurosurg Soc. 2014;55(1):48–50. http://dx.doi.org/10.3340/jkns.2014.55.1.48
15. Harman M, Unal Ö, Onbaşi KT, Kıymaz N, Arslan H. Brucellar spondylodiscitis: MRI diagnosis. Clin Imaging. 2001;25(6):421–427. http://dx.doi.org/10.1016/S0899-7071(01)00334-5
16. Turunc T, Demiroglu YZ, Uncu H, Colakoglu S, Arslan H. A comparative analysis of tuberculous, brucellar and pyogenic spontaneous spondylodiscitis patients. J Infect Prev. 2007;55(2):158–163. http://dx.doi.org/10.1016/j.jinf.2007.04.002
17. Yang X, Meng X, Shi W, Du Y, Zhang L, Wang Y. The comparison of the manifestation of the clinical imageology and pathology between the brucellar spondylitis and the spine turberculosis. Surg Sci. 2014;5:60–69. http://dx.doi.org/10.4236/ss.2014.52014
18. Samra Y, Hertz M, Shaked Y, Zwas S, Altman G. Brucellosis of the spine. A report of 3 cases. Bone Joint J. 1982;64(4):429–431.
19. Bozgeyik Z, Ozdemir H, Demirdag K, Ozden M, Sonmezgoz F, Ozgocmen S. Clinical and MRI findings of brucellar spondylodiscitis. Eur J Radiol. 2008;67(1):153–158. http://dx.doi.org/10.1016/j.ejrad.2007.07.002
20. Colmenero JD, Reguera JM, Fernandez-Nebro A, Cabrera-Franquelo F. Osteoarticular complications of brucellosis. Ann Rheum Dis. 1991;50(1):23–26. http://dx.doi.org/10.1136/ard.50.1.23
21. Mousa AR, Muhtaseb SA, Almudallal DS, Khodeir SM, Marafie AA. Osteoarticular complications of brucellosis: A study of 169 cases. Rev Infect Dis. 1987;9(3):531–543. http://dx.doi.org/10.1093/clinids/9.3.531
22. Gonzalez-Gay MA, Garcia-Porrua C, Ibanez D, Garcia-Pais MJ. Osteoarticular complications of brucellosis in an Atlantic area of Spain. J Rheumatol. 1999;26(1):141–145.
23. Hashemi SH, Keramat F, Ranjbar M, Mamani M, Farzam A, Jamal-Omidi S. Osteoarticular complications of brucellosis in Hamedan, an endemic area in the west of Iran. Int J Infect Dis. 2007;11(6):496–500. http://dx.doi.org/10.1016/j.ijid.2007.01.008
24. West DL, Hasiotis ST. Trace fossils in an archaeological context: Examples from bison skeletons, Texas, USA. In: Trace fossils: Concepts, problems, prospects. Amsterdam: Elsevier; 2007. p. 545–561. http://dx.doi.org/10.1016/B978-044452949-7/50160-1
25. Holden AR, Harris JM, Timm RM. Paleoecological and taphonomic implications of insect-damaged Pleistocene vertebrate remains from Rancho La Brea, southern California. PLOS One. 2013;8(7), Art. e67119, 9 pages. http://dx.doi.org/10.1371/journal.pone.0067119

APPENDIX E

DECLARATION BY STUDENT AND CO-AUTHORS' AGREEMENT FOR WRITE-UP WITH PUBLISHED ARTICLES

I, Edward John Odes, student number 565579, declare that this thesis is my own work and that I contributed adequately towards research findings published in the article(s) stated below which are included in my thesis.

Signature of Student



Date 12th March 2017

Name of Primary Supervisor: Dr Randolph-Quinney

Signature of Primary supervisor



Date: 12th March 2014

Agreement by co-authors: By signing this declaration, the co-authors listed below agree to the use of the article by the student as part of his/her Thesis. In cases where the student is not the 1st author of a published article, the primary supervisor must explain (under comments) why the student is entitled to use the paper for his/her degree purposes.

Article 1: Title: Earliest hominin cancer: 1.7-million-yearold osteosarcoma from Swartkrans Cave, South Africa

South African Journal of Science 2016, 112 7/8, 1-5

1st author	Edward J. Odes		
2nd author	Patrick S. Randolph-Quinney		
3rd author	Maryna Steyn		
4th author	Zach Throckmorton		
5th author	Jacqueline S. Smilg		
6th author	Bernhard Zipfel		
7th author	Tanya N. Augustine		
8th author	Frikkie De Beer		
9th author	Jakobus W. Hoffmann		
10th author	Ryan D. Franklin		

11th author	Lee R. Berger		

Comments by primary supervisor

……
……
……

Article 2: Title: Osteogenic tumour in *Australopithecus sediba*: Earliest hominin evidence for neoplastic disease

South African Journal of Science, 2016, 112, (7/8), 1-7

1st author	Patrick S. Randolph-Quinney		
2nd author	Scott A. Williams		
3rd author	Maryna Steyn		
4th author	Marc R. Meyer		
5th author	Jacqueline S. Smilg		
6th author	Steve E. Churchill		
7th author	Edward J. Odes		
8th author	Tanya N. Augustine		
9th author	Paul Tafforeau		
10th author	Lee R. Berger		

Comments by primary supervisor

……
……
……

Article 3: Osteopathology and insect traces in the *Australopithecus africanus* skeleton StW 431

South African Journal of Science, 2017, 113 (1/2), 1-7

1st author	Edward J. Odes		
2nd author	Alexander H. Parkinson		
3rd author	Patrick S. Randolph-Quinney		
4th author	Bernard H. Zipfel		
5th author	Kudakwashe Jakata		
6th author	Heather Bonney		
7th author	Lee R. Berger		

Comments by primary supervisor

……
……
……

Article 4: Title: A case of benign osteogenic tumour in *Homo naledi*: evidence for peripheral osteoma in the U.W. 101-1142 mandible

International Journal of Palaeopathology, (in submission)

1st author	Edward J. Odes		
2nd author	Lucas Delezene		
3rd author	Patrick S. Randolph Quinney		
4th author	Jaqueline S. Smilg		
5th author	Tanya N. Augustine		
6th author	Kudakwashe Jakata		
7th author	Lee R. Berger		

Comments by primary supervisor

……
……
……

Article 1: Title: Earliest hominin cancer: 1.7-million-yearold osteosarcoma from Swartkrans Cave, South Africa

South African Journal of Science 2016, 112 7/8, 1-5

1st author	Edward J. Odes		
2nd author	Patrick S. Randolph-Quinney		
3rd author	Maryna Steyn		
4th author	Zach Throckmorton		17 Feb 2017
5th author	Jacqueline S. Smilg		
6th author	Bernhard Zipfel		
7th author	Tanya N. Augustine		
8th author	Frikkie De Beer		
9th author	Jakobus W. Hoffmann		
10th author	Ryan D. Franklin		
11th author	Lee R. Berger		

Article 3: Osteopathology and insect traces in the *Australopithecus africanus* skeleton StW 431

South African Journal of Science, 2017, 113 (1/2), 1-7

1st author	Edward J. Odes		
2nd author	Alexander H. Parkinson		
3rd author	Patrick S. Randolph-Quinney		
4th author	Bernard H. Zipfel		
5th author	Kudakwashe Jakata		
6th author	Lee R. Berger		

I, Edward John Odes, student number 565579, declare that this thesis is my own work and that I contributed adequately towards research findings published in the article(s) stated below which are included in my thesis.

Signature of Student  Date

Name of Primary Supervisor: Dr Randolph-Quinney

Signature of Primary Supervisor Date

Agreement by co-authors: By signing this declaration, the co-authors listed below agree to the use of the article by the student as part of his/her Thesis. In cases where the student is not the 1st author of a published article, the primary supervisor must explain (under comments) why the student is entitled to use the paper for his/her degree purposes.

Article 1: Title: Earliest hominin cancer: 1.7-million-yearold osteosarcoma from Swartkrans Cave, South Africa

South African Journal of Science 2016, 112 7/8, 1-5

1st author	Edward J. Odes		
2nd author	Patrick S. Randolph-Quinney		
3rd author	Maryna Steyn		
4th author	Zach Throckmorton		
5th author	Jacqueline S. Smilg		
6th author	Bernhard Zipfel		
7th author	Tanya N. Augustine		
8th author	Frikkie De Beer		
9th author	Jakobus W. Hoffmann		
10th author	Ryan D. Franklin		
11th author	Lee R. Berger		

Comments by primary supervisor

……
……
……

Article 2: Title: Osteogenic tumour in Australopithecus sediba: Earliest hominin evidence for neoplastic disease

South African Journal of Science, 2016, 112, (7/8), 1-7

1st author	Patrick S. Randolph-Quinney		
2nd author	Scott A. Williams		
3rd author	Maryna Steyn		
4th author	Marc R. Meyer		
5th author	Jacqueline S. Smilg		
6th author	Steve E. Churchill		
7th author	Edward J. Odes		
8th author	Tanya N. Augustine		
9th author	Paul Tafforeau		
10th author	Lee R. Berger		

Comments by primary supervisor

……
……
……

Article 3: Osteopathology and insect traces in the *Australopithecus africanus* skeleton StW 431

South African Journal of Science, 2017, 113 (1/2), 1-7

1st author	Edward J. Odes		
2nd author	Alexander H. Parkinson		
3rd author	Patrick S. Randolph-Quinney		
4th author	Bernard H. Zipfel		
5th author	Kudakwashe Jakata		
6th author	Lee R. Berger		

Comments by primary supervisor

……
……
……

Article 4: Title: A case of benign osteogenic tumour in Homo naledi: evidence for peripheral osteoma in the U.W. 101-1142 mandible

International Journal of Palaeopathology, (in submission)

1st author	Edward J. Odes		
2nd author	Lucas Delezene		
3rd author	Patrick S. Randolph Quinney		
4th author	Jaqueline S. Smilg		
5th author	Tanya N. Augustine		
6th author	Kudakwashe Jakata		
7th author	Lee R. Berger		

Comments by primary supervisor

……
……
……

Article 2: Title: Osteogenic tumour in Australopithecus sediba: Earliest hominin evidence for neoplastic disease

South African Journal of Science, 2016, 112, (7/8), 1-7

1st author	Patrick S. Randolph-Quinney		
2nd author	Scott A. Williams		
3rd author	Maryna Steyn		
4th author	Marc R. Meyer	Marc	2/21/17
5th author	Jacqueline S. Smilg		
6th author	Steve E. Churchill		
7th author	Edward J. Odes		
8th author	Tanya N. Augustine		
9th author	Paul Tafforeau		
10th author	Lee R. Berger		

Comments by primary supervisor

.....
.....
.....

Article 3: Osteopathology and insect traces in the *Australopithecus africanus* skeleton StW 431

South African Journal of Science, 2017, 113 (1/2), 1-7

1st author	Edward J. Odes		
2nd author	Alexander H. Parkinson		
3rd author	Patrick S. Randolph-Quinney		
4th author	Bernard H. Zipfel		
5th author	Kudakwashe Jakata		
6th author	Lee R. Berger		

Comments by primary supervisor

.....
.....
.....

Article 2: Title: Osteogenic tumour in Australopithecus sediba: Earliest hominin evidence for neoplastic disease

South African Journal of Science, 2016, 112, (7/8), 1-7

1st author	Patrick S. Randolph-Quinney		
2nd author	Scott A. Williams		
3rd author	Maryna Steyn		
4th author	Marc R. Meyer		
5th author	Jacqueline S. Smilg		
6th author	Steve E. Churchill		
7th author	Edward J. Odes		
8th author	Tanya N. Augustine		
9th author	Paul Tafforeau		
10th author	Lee R. Berger		

Comments by primary supervisor

.....
.....
.....

Article 3: Osteopathology and insect traces in the *Australopithecus africanus* skeleton StW 431

South African Journal of Science, 2017, 113 (1/2), 1-7

1st author	Edward J. Odes		
2nd author	Alexander H. Parkinson		
3rd author	Patrick S. Randolph-Quinney		
4th author	Bernard H. Zipfel		
5th author	Kudakwashe Jakata		
6th author	Lee R. Berger		

Comments by primary supervisor

.....
.....
.....

APPENDIX 5: DECLARATION BY STUDENT AND CO-AUTHORS' AGREEMENT FOR WRITE-UP WITH PUBLISHED ARTICLES

I, Edward John Odes, student number 565579, declare that this thesis is my own work and that I contributed adequately towards research findings published in the article(s) stated below which are included in my thesis.

Signature of Student Edward Date

Name of Primary Supervisor: Dr Randolph-Quinney

Signature of Primary Supervisor Date

Agreement by co-authors: By signing this declaration, the co-authors listed below agree to the use of the article by the student as part of his/her Thesis. In cases where the student is not the 1st author of a published article, the primary supervisor must explain (under comments) why the student is entitled to use the paper for his/her degree purposes.

Article 1: Title: Earliest hominin cancer: 1.7-million-yearold osteosarcoma from Swartkrans Cave, South Africa

South African Journal of Science 2016, 112 7/8, 1-5

1st author	Edward J. Odes		
2nd author	Patrick S. Randolph-Quinney		
3rd author	Maryna Steyn		
4th author	Zach Throckmorton		
5th author	Jacqueline S. Smilg		
6th author	Bernhard Zipfel		
7th author	Tanya N. Augustine		
8th author	Frikkie De Beer		
9th author	Jakobus W. Hoffmann		22 Feb 2017
10th author	Ryan D. Franklin		
11th author	Lee R. Berger		

Comments by primary supervisor

.....
.....
.....

I, Edward John Odes, student number 565579, declare that this thesis is my own work and that I contributed adequately towards research findings published in the article(s) stated below which are included in my thesis.

Signature of Student  Date

Name of Primary Supervisor: Dr Randolph-Quinney

Signature of Primary Supervisor Date

Agreement by co-authors: By signing this declaration, the co-authors listed below agree to the use of the article by the student as part of his/her Thesis. In cases where the student is not the 1st author of a published article, the primary supervisor must explain (under comments) why the student is entitled to use the paper for his/her degree purposes.

Article 1: Title: Earliest hominin cancer: 1.7-million-yearold osteosarcoma from Swartkrans Cave, South Africa

South African Journal of Science 2016, 112 7/8, 1-5

1st author	Edward J. Odes		
2nd author	Patrick S. Randolph-Quinney		
3rd author	Maryna Steyn		
4th author	Zach Throckmorton		
5th author	Jacqueline S. Smilg		
6th author	Bernhard Zipfel		
7th author	Tanya N. Augustine		
8th author	Frikkie De Beer		2017/02/26
9th author	Jakobus W. Hoffmann		
10th author	Ryan D. Franklin		
11th author	Lee R. Berger		

Article 2: Title: Osteogenic tumour in Australopithecus sediba: Earliest hominin evidence for neoplastic disease

South African Journal of Science, 2016, 112, (7/8), 1-7

1st author	Patrick S. Randolph-Quinney		
2nd author	Scott A. Williams		21/2/2017
3rd author	Maryna Steyn		
4th author	Marc R. Meyer		
5th author	Jacqueline S. Smilg		
6th author	Steve E. Churchill		
7th author	Edward J. Odes		
8th author	Tanya N. Augustine		
9th author	Paul Tafforeau		
10th author	Lee R. Berger		

Comments by primary supervisor

.....
.....
.....

Article 3: Osteopathology and insect traces in the *Australopithecus africanus* skeleton StW 431

South African Journal of Science, 2017, 113 (1/2), 1-7

1st author	Edward J. Odes		
2nd author	Alexander H. Parkinson		
3rd author	Patrick S. Randolph-Quinney		
4th author	Bernard H. Zipfel		
5th author	Kudakwashe Jakata		
6th author	Lee R. Berger		

Comments by primary supervisor

.....
.....
.....

Article 2: Title: Osteogenic tumour in Australopithecus sediba: Earliest hominin evidence for neoplastic disease

South African Journal of Science, 2016, 112, (7/8), 1-7

1st author	Patrick S. Randolph-Quinney		
2nd author	Scott A. Williams		
3rd author	Maryna Steyn		
4th author	Marc R. Meyer		
5th author	Jacqueline S. Smilg		
6th author	Steve E. Churchill		
7th author	Edward J. Odes		
8th author	Tanya N. Augustine		
9th author	Paul Tafforeau		
10th author	Lee R. Berger		

Comments by primary supervisor

……
……
……

Article 3: Osteopathology and insect traces in the *Australopithecus africanus* skeleton StW 431

South African Journal of Science, 2017, 113 (1/2), 1-7

1st author	Edward J. Odes		
2nd author	Alexander H. Parkinson		
3rd author	Patrick S. Randolph-Quinney		
4th author	Bernard H. Zipfel		
5th author	Kudakwashe Jakata		
6th author	Lee R. Berger		

Comments by primary supervisor

……
……
……

Article 1: Title: Earliest hominin cancer: 1.7-million-yearold osteosarcoma from Swartkrans Cave, South Africa

South African Journal of Science 2016, 112 7/8, 1-5

1st author	Edward J. Odes		
2nd author	Patrick S. Randolph-Quinney		
3rd author	Maryna Steyn		
4th author	Zach Throckmorton		
5th author	Jacqueline S. Smilg		
6th author	Bernhard Zipfel		
7th author	Tanya N. Augustine		
8th author	Frikkie De Beer		
9th author	Jakobus W. Hoffmann		
10th author	Ryan D. Franklin		
11th author	Lee R. Berger		

Article 3: Osteopathology and insect traces in the *Australopithecus africanus* skeleton StW 431

South African Journal of Science, 2017, 113 (1/2), 1-7

1st author	Edward J. Odes		
2nd author	Alexander H. Parkinson		
3rd author	Patrick S. Randolph-Quinney		
4th author	Bernhard H. Zipfel		
5th author	Kudakwashe Jakata		
6th author	Lee R. Berger		

Article 1: Title: Earliest hominin cancer: 1.7-million-yearold osteosarcoma from Swartkrans Cave, South Africa

South African Journal of Science 2016, 112 7/8, 1-5

1st author	Edward J. Odes		
2nd author	Patrick S. Randolph-Quinney		
3rd author	Maryna Steyn		
4th author	Zach Throckmorton		
5th author	Jacqueline S. Smilg		
6th author	Bernhard Zipfel		
7th author	Tanya N. Augustine		
8th author	Frikkie De Beer		
9th author	Jakobus W. Hoffmann		
10th author	Ryan D. Franklin		
11th author	Lee R. Berger		

Comments by primary supervisor

.....

.....

Article 2: Title: Osteogenic tumour in Australopithecus sediba: Earliest hominin evidence for neoplastic disease

South African Journal of Science, 2016, 112, (7/8), 1-7

1st author	Patrick S. Randolph-Quinney		
2nd author	Scott A. Williams		
3rd author	Maryna Steyn		
4th author	Marc R. Meyer		
5th author	Jacqueline S. Smilg		
6th author	Steve E. Churchill		
7th author	Edward J. Odes		
8th author	Tanya N. Augustine		
9th author	Paul Tafforeau		
10th author	Lee R. Berger		

Article 4: Title: A case of benign osteogenic tumour in Homo naledi: evidence for peripheral osteoma in the U.W. 101-1142 mandible

International Journal of Palaeopathology, (in submission)

1st author	Edward J. Odes		
2nd author	Lucas Delezene		2/17/2017
3rd author	Patrick S. Randolph Quinney		
4th author	Jaqueline S. Smilg		
5th author	Tanya N. Augustine		
6th author	Kudakwashe Jakata		
7th author	Lee R. Berger		

Agreement by co-authors: By signing this declaration, the co-authors listed below agree to the use of the article by the student as part of his/her Thesis. In cases where the student is not the 1st author of a published article, the primary supervisor must explain (under comments) why the student is entitled to use the paper for his/her degree purposes.

Article 1: Title: Earliest hominin cancer: 1.7-million-yearold osteosarcoma from Swartkrans Cave, South Africa

South African Journal of Science 2016, 112 7/8, 1-5

1st author	Edward J. Odes		
2nd author	Patrick S. Randolph-Quinney		
3rd author	Maryna Steyn		
4th author	Zach Throckmorton		
5th author	Jacqueline S. Smilg		
6th author	Bernhard Zipfel		
7th author	Tanya N. Augustine		
8th author	Frikkie De Beer		
9th author	Jakobus W. Hoffmann		
10th author	Ryan D. Franklin		
11th author	Lee R. Berger		

Article 2: Title: Osteogenic tumour in Australopithecus sediba: Earliest hominin evidence for neoplastic disease

South African Journal of Science, 2016, 112, (7/8), 1-7

1st author	Patrick S. Randolph-Quinney		
2nd author	Scott A. Williams		
3rd author	Maryna Steyn		
4th author	Marc R. Meyer		
5th author	Jacqueline S. Smilg		
6th author	Steve E. Churchill		
7th author	Edward J. Odes		
8th author	Tanya N. Augustine		
9th author	Paul Tafforeau	17/02/2017	
10th author	Lee R. Berger		

Comments by primary supervisor

.....
.....
.....

Article 3: Osteopathology and insect traces in the *Australopithecus africanus* skeleton StW 431

South African Journal of Science, 2017, 113 (1/2), 1-7

1st author	Edward J. Odes		
2nd author	Alexander H. Parkinson		
3rd author	Patrick S. Randolph-Quinney		
4th author	Bernard H. Zipfel		
5th author	Kudakwashe Jakata		
6th author	Lee R. Berger		

Comments by primary supervisor

.....
.....
.....

Article 3: Osteopathology and insect traces in the *Australopithecus africanus* skeleton StW 431

South African Journal of Science, 2017, 113 (1/2), 1-7

1st author	Edward J. Odes		
2nd author	Alexander H. Parkinson		
3rd author	Patrick S. Randolph-Quinney		
4th author	Bernard H. Zipfel		
5th author	Kudakwashe Jakata		
6th author	Heather Bonney		21.2.17
7th author	Lee R. Berger		

Comments by primary supervisor

.....

.....

APPENDIX 5: DECLARATION BY STUDENT AND CO-AUTHORS' AGREEMENT FOR WRITE-UP WITH PUBLISHED ARTICLES

I, Edward John Odes, student number 565579, declare that this thesis is my own work and that I contributed adequately towards research findings published in the article(s) stated below which are included in my thesis.

Signature of Student Date

Name of Primary Supervisor: Dr Randolph-Quinney

Signature of Primary Supervisor Date

Agreement by co-authors: By signing this declaration, the co-authors listed below agree to the use of the article by the student as part of his/her Thesis. In cases where the student is not the 1st author of a published article, the primary supervisor must explain (under comments) why the student is entitled to use the paper for his/her degree purposes.

Article 1: Title: Earliest hominin cancer: 1.7-million-yearold osteosarcoma from Swartkrans Cave, South Africa

South African Journal of Science 2016, 112 7/8, 1-5

1st author	Edward J. Odes		
2nd author	Patrick S. Randolph-Quinney		
3rd author	Maryna Steyn		
4th author	Zach Throckmorton		
5th author	Jacqueline S. Smilg		
6th author	Bernhard Zipfel		
7th author	Tanya N. Augustine		
8th author	Frikkie De Beer		
9th author	Jakobus W. Hoffmann		
10th author	Ryan D. Franklin		
11th author	Lee R. Berger		

APPENDIX F

ETHICS WAIVER

Human Research Ethics Committee (Medical)

Research Office Secretariat: Senate House Room SH 10005, 10th floor. Tel +27 (0)11-717-1252
Medical School Secretariat: Medical School Room 10M07, 10th Floor. Tel +27 (0)11-717-2700
Private Bag 3, Wits 2050, www.wits.ac.za. Fax +27 (0)11-717-1265

Ref: W-CJ-140604-1 25/01/2016

TO WHOM IT MAY CONCERN:

Waiver: This certifies that the following research does not require clearance from the Human Research Ethics Committee (Medical).

Investigator: School of Anatomical Sciences (Head: Prof M Steyn - Previously Prof T J M Daly, initial approval 04/06/2014 – recertified 27/01/2016).

Project title: Research on Cadaveric Material.

Reason: In terms of Chapter 8, sections 62-64 of the National Health Act No 61 of 2003 donated bodies and their tissues may be used for, among other purposes, health, and research. Use of such Material is subject only to permission from the responsible person in the School of Anatomical Sciences – the Head or person designed by the Head.

Professor Peter Cleaton-Jones

Chair: Human Research Ethics Committee (Medical)

UNIVERSITY OF THE WITWATERSRAND
OFFICE OF THE DEPUTY VICE CHANCELLOR RESEARCH
29 JAN 2016
RESEARCH OFFICE HREC (Medical)
JOHANNESBURG

Copy - HREC (Medical) Secretariat: Rhulani Mkansi, Zanele Ndlovu.