

https://dspace.org/

Pulmonary TB varying radiological presentations in individuals with HIV in Soweto South Africa

Jesne Kistan; Fatima Laher; Kennedy Otwombe; Ravindre Panchia; Nohemie Mawaka ...

https://hdl.handle.net/10539/24299
ISI 2017

Downloaded from a DSpace repository. https://dspace.org/

Trans R Soc Trop Med Hyg 2017; **111**: 132–136
doi:10.1093/trstmh/trx028

ORIGINAL ARTICLE

Pulmonary TB: varying radiological presentations in individuals with HIV in Soweto, South Africa

Jesne Kistan[a,f,*], Fatima Laher[a], Kennedy Otwombe[a], Ravindre Panchia[a], Nohemie Mawaka[b], Limakatso Lebina[a], Andreas Diacon[c], Bavesh Kana[d] and Neil Martinson[a,e]

[a]Perinatal HIV Research Unit and MRC Soweto Matlosana Collaborating Centre for HIV/AIDS and TB (SoMCHAT), Faculty of Health Sciences, University of the Witwatersrand, South Africa; [b]Faculty of Health Sciences, Simon Fraser University, Burnaby, Canada; [c]Division of Physiology, Department of Medical Biochemistry, Faculty of Medicine and Health Sciences, Stellenbosch University, Cape Town, South Africa; [d]DST/NRF Centre of Excellence for Biomedical TB Research, Faculty of Health Sciences, University of the Witwatersrand, National Health Laboratory Service, Johannesburg, South Africa; [e]Johns Hopkins University Center for TB Research, Baltimore, MD, USA; [f]Department of Community Health, School of Public Health, Faculty of Health Sciences, University of the Witwatersrand, South Africa

*Corresponding author: E-mail: jesnek@gmail.com

Received 21 February 2017; revised 11 May 2017; editorial decision 12 May 2017; accepted 23 May 2017

Background: HIV-uninfected individuals with pulmonary TB (PTB) commonly present with radiological features of upper lobe cavitatory disease. In contrast, individuals with HIV and PTB may present differently. This study compared radiological features of individuals with laboratory-confirmed PTB by HIV status from the largest study in South Africa.

Methods: We conducted a cross-sectional analysis of adults recruited between 2012 and 2015 with laboratory-confirmed PTB in Soweto, South Africa. Baseline characteristics and chest radiograph (CXR) findings were compared by χ^2 test stratified by HIV status.

Results: Of the 474 individuals with PTB, 348 (73.4%) had HIV. Individuals with HIV had a higher proportion of infiltrates (58.9% vs 46.8%, p=0.02) and a lower proportion of cavitations (40.8% vs 68.3%; p<0.0001) compared to HIV-uninfected individuals. Additionally, individuals with HIV had a lower proportion of cavitations sized ≥4 cm (16.7% vs 36.5%, p<0.001) and a lower proportion of disease extent involving half or more of the total lung area radiologically (25.9% vs 45.3%, p<0.0001).

Conclusions: Individuals with HIV co-infected with PTB have a higher proportion of infiltrates and a lower proportion of cavitations relative to the HIV-uninfected PTB individuals. The absence of classical upper lobe cavitatory disease on CXR does not exclude PTB in individuals with HIV.

Keywords: HIV, PTB, Pulmonary tuberculosis, Radiology, South Africa

Introduction

South Africa has one of the highest estimated TB rates in the world with approximately 461 000 new cases each year, with 73% of patients with TB also carrying HIV infection.[1] Diagnosis of pulmonary TB (PTB) is based on clinical history, *Mycobacterium tuberculosis* detection in sputum samples by culture, smear, nucleic acid amplification and/or chest radiograph (CXR). In HIV-uninfected individuals, PTB typically presents on CXR as an upper lobe disease with cavitations, formed as a result of a cell-mediated response involving a variety of host immune cells that eventually undergo caseous necrosis and fragmentation.[2] As a result of CD4 T-cell depletion, individuals with HIV may have a compromised response, a defect that most likely underpins the biological mechanism for why HIV-associated PTB may present differently on CXR. Consistent with this, several smaller studies report atypical radiological findings in individuals with HIV.[3–5] A substantial portion of individuals with HIV with sub-clinical disease may go undiagnosed, underscoring the importance of providing unequivocal evidence of differential CXR presentation in this vulnerable population.[6] Conversely, a large study conducted in Kenya found HIV status not to have any associations with CXR findings in PTB-infected individuals.[7] Further analysis of CXRs involving individuals with HIV with PTB in Africa is warranted to close the gap on conflicting findings.

© *The Author 2017. Published by Oxford University Press on behalf of Royal Society of Tropical Medicine and Hygiene. All rights reserved. For permissions, please e-mail: journals.permissions@oup.com.*

Furthermore, there is limited knowledge regarding the effect of highly active antiretroviral therapy (HAART) on radiological features of HIV-associated PTB. HAART decreases HIV viral load, permits CD4/T-cell immune reconstitution, reduces the risk of TB infection/reactivation, and decreases mortality.[4,6] However, individuals with HIV on HAART still have a greater risk of TB compared to HIV-uninfected individuals.[8] Previous studies have shown that higher CD4 counts correlate with typical CXR findings of PTB but only a few mention the influence of HAART in the same setting.[9,10] One small study conducted in West Africa showed that individuals with HIV on HAART showed typical findings of PTB on CXR.[10] However, further research is required to substantiate this finding.

We compared CXRs of adult individuals with HIV and uninfected individuals newly diagnosed with PTB in Soweto, South Africa. Additionally, we compared CXRs of HIV-infected HAART recipients with those who were HAART-naïve. To our knowledge, this is the largest study in a resource poor setting (Soweto in South Africa) comparing radiological features of individuals with laboratory-confirmed PTB by HIV status.

Materials and Methods

Study design

We conducted a cross-sectional analysis of data from two cohorts who were enrolled in clinical studies investigating novel ways of detecting acid fast bacilli in adults with laboratory-confirmed PTB in Soweto, South Africa. Individuals provided voluntary written informed consent and agreed to have their data used for further research.

For our analysis, we included individuals from both cohorts who were 18 years and older with confirmed PTB (either via Auramine smear, MGIT culture or Gene Xpert on sputum sample) and had both HIV testing and CXRs performed.

Study setting

Both studies were conducted in Soweto, a township of 1.3 million people.[11] Individuals were recruited during 2012–2015 from the township through community outreach efforts as well as community clinics located in and around Chris Hani Baragwanath Academic hospital (CHBAH) which is the largest referral hospital in South Africa; CHBAH experiences an endemic rate of 500 cases per 100 000 population.[12]

Study procedures

Data collected from the cohorts included demographic measures such as gender and age as well as clinical measures such as weight and height. Diagnosis of PTB on sputum was done using Auramine smear, liquid MGIT culture over 42 days and Gene Xpert tests. Furthermore, the cohorts performed HIV and CD4 count testing. Information on HAART usage was elicited from individuals with HIV. Additionally, CXRs were performed by the same independent radiologist firm prior to administration of TB medication. The radiologists were aware of the diagnosis of PTB but were unaware of the HIV and HAART status of individuals. Although different radiologists of the same firm were used, CXRs were analysed in a standardized manner categorizing the presence or absence of cavitations, infiltrates, adenopathy or pleural disease involving either the right or left side of the lung. Cavitations were further categorized as being absent or present, with the size being <4 cm or ≥4 cm. Disease extent is classified by the area of lung involved: less than one quarter, between one quarter and less than one half and one half or more of the entire thoracic cavity or lesion(s) as seen on PA or AP view.

Statistical methods

Baseline characteristics were summarized descriptively using medians and IQRs for continuous variables, while frequencies and proportions were determined for categorical variables. Demographic and clinical characteristics were compared by HIV status. Continuous measures were compared non-parametrically using the Kruskal-Wallis test. The association between HIV status and radiological features of lung disease (infiltrate, adenopathy and pleural disease in the left and right lungs, together with total cavitation and disease extent) was tested by χ^2 analysis. The number of individuals with infiltrates, cavities, adenopathy and pleural disease were presented graphically stratified by HIV status. The association between lung disease and HAART status within the individuals with HIV was also tested by χ^2 analysis. The aim of our sub-analysis was to identify potential differences in CXR patterns among HAART recipients and HAART-naïve individuals. All statistical analyses were performed using SAS Enterprise Guide version 6.1 (SAS Institute, Cary, NC, USA).

Results

We included 474 participants (270 males and 204 females) in our analysis (Figure 1). Overall, 348/474 (73.4%) were HIV-infected; 190/348 (54.6%) men and 158/348 (45.4%) women. The median CD4 count of the HIV-infected population was 170 cells/uL (IQR 83–336.5). There were no significant differences in the median age (36 years; IQR 29–44) or BMI (20.1kg/m^2;

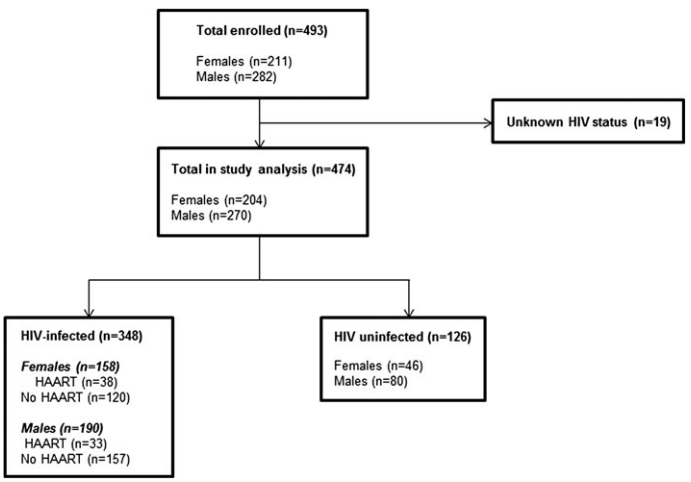

Figure 1. Participant disposition flow chart. HAART: highly active antiretroviral therapy.

Table 1. Demographics and clinical characteristics of individuals with pulmonary TB

Variable	Overall (474)	HIV negative (n=126)	HIV positive (n=348)	p-value
Gender				
Female (%)	204 (43.0)	46 (36.5)	158 (45.4)	0.0838
Male (%)	270 (57.0)	80 (63.5)	190 (54.6)	0.729
Age				
Median age in years (IQR)	36 (29–44)	32 (25.5–45.5)	37 (32–43)	
BMI				
Underweight (%)	130 (27.4)	39 (31.0)	91 (26.1)	
Normal (%)	251 (53.0)	66 (52.4)	185 (53.2)	
Overweight (%)	38 (8.0)	8 (6.3)	30 (8.6)	
Obese (%)	21 (4.4)	5 (4)	16 (4.6)	
Median BMI (IQR)	20.1 (18.1–22.5)	20.3 (18.1–22.5)	20.1 (18.22–22.5)	0.55
CD4 count (cells/uL)				
Median (IQR)	NA	NA	169.5 (83–336.5)	

NA: not applicable.

IQR 18.1–22.5) between HIV-uninfected individuals and patients with HIV (Table 1).

Figure 2 presents a graphical distribution of CXR findings stratified by HIV status. Of the CXRs performed, infiltrates were present in 264/474 individuals; 205/348 (58.9%) HIV-infected and 59/126 (46.8%) HIV-uninfected; p=0.02. Individuals with HIV had a higher proportion of unilateral infiltrates (30.5% [n=106/348] vs 19.0% [n=24/126]; p=0.01) and right-sided infiltrates (47.7% [n=166/348] vs 36.5% [n=46/126]; p=0.03) compared to HIV-uninfected individuals. Left-sided and bilateral infiltrates were similar in individuals with HIV and uninfected individuals (39.7% [n=138/348] vs 38.1% [n=48/126]; p=0.76 and 28.4% [n=99/348] vs 27.8% [n=35/126]; p=0.89, respectively) (Figure 2C).

Figure 2A shows that individuals with HIV had a lower proportion of cavities relative to the HIV-uninfected (40.8% [n=142/348] vs 68.3% [n=86/126]; p<0.0001). Furthermore, there were lower proportions of left (28.4% [n=99/348] vs 56.3% [n=71/126]; p<0.0001), right (31.0% [n=108/348] vs 50.8% [n=64/126]; p<0.0001) and bilateral cavities (18.7% [n=65/348] vs 38.9% [n=49/126]; p<0.0001). The proportion of unilateral cavities were similar between the individuals with HIV and uninfected individuals (22.1% [n=77/348] vs 29.4% [n=37/126]; p=0.10). Similarly there was no difference in adenopathy (any, unilateral or bilateral) and pleural disease (any, unilateral or bilateral) by HIV status (Figure 2B and 2D).

Individuals with HIV had a lower proportion of cavities on CXR (59.2% [n=206/348] vs 33.3% [n=42/126]; p<0.0001) compared to the HIV-uninfected individuals. Furthermore, individuals with HIV had a lower proportion of CXR cavitation ≥4 cm compared to HIV-uninfected individuals (16.7% [n=58/348] vs 36.5% [n=46/126]; p<0.0001).

Individuals with HIV had a higher proportion of disease extent involving more than one quarter thoracic chest cavity compared with HIV-uninfected individuals (45.7% [n=145/317] vs 21.4% [n=25/117]; p<0.0001). Moreover, there was a lower proportion of individuals with HIV with disease extent one half or more of the thoracic cavity (25.9% [n=82/317] vs 45.3% [n=53/117]; p=0.0001).

Of the 348 individuals with HIV with CXRs, 71/348 (20.4%) were HAART-recipients and 277/348 (79.6%) were HAART-naïve individuals. In this subset, HAART-naïve and HAART recipients had similar presentations with regards to presence of infiltrates (60.6 % [n=168/277] vs 52.1% [n=37/71]; p=0.19), cavitations (39.7% [n=110/277] vs 45.1% [n=32/71]; p=0.41) and adenopathy (26.7% [n=74/277] vs 18.3% [n=13/71]; p=0.14). Additionally, the proportion with any (15.9% [n=44/277] vs 25.4% [n=18/71]; p=0.06), unilateral (12.6% [n=35/277] vs 18.3% [n=13/71]; p=0.22) or bilateral pleural disease (3.2% [n=9/277] vs 7.0% [n=5/71]; p=0.15) showed no differences. However, HAART recipients had a higher proportion of left-sided pleural disease (18.3% [n=13/71] vs 9.4% [n=26/277]; p=0.03) and cavities sized ≥4cm (26.8% [n=19/71] vs 14.1% [n=39/277]; p=0.01) compared to HAART-naïve individuals. There were no associations between the extent of disease seen radiologically between HAART-naïve individuals and HAART recipients. Of the 288 individuals with HIV with CD4 counts, 130/288 (45.1%) had CD4>200. These individuals had a higher proportion of infiltrates (66.9% [n=87/130] vs 52.5% [n=83158]; p=0.0135) and cavities (53.1% [n=69/130] vs 32.3% [n=51/158]; p=0.0004) compared to individuals with HIV with CD4≤200, regardless of HAART initiation. Individuals with HIV with CD4>200 also had disease limited to less than one quarter of the thoracic chest cavity compared with individuals with HIV with CD4≤200 (38.2% [n=47/123] vs 54.9% [n=78/142]; p<0.0001.

Discussion

This is the largest study to document radiological manifestations of PTB in individuals with HIV in Soweto, South Africa. Our study, conducted in a resource-limited setting, demonstrates the varying radiological presentation of PTB in individuals with

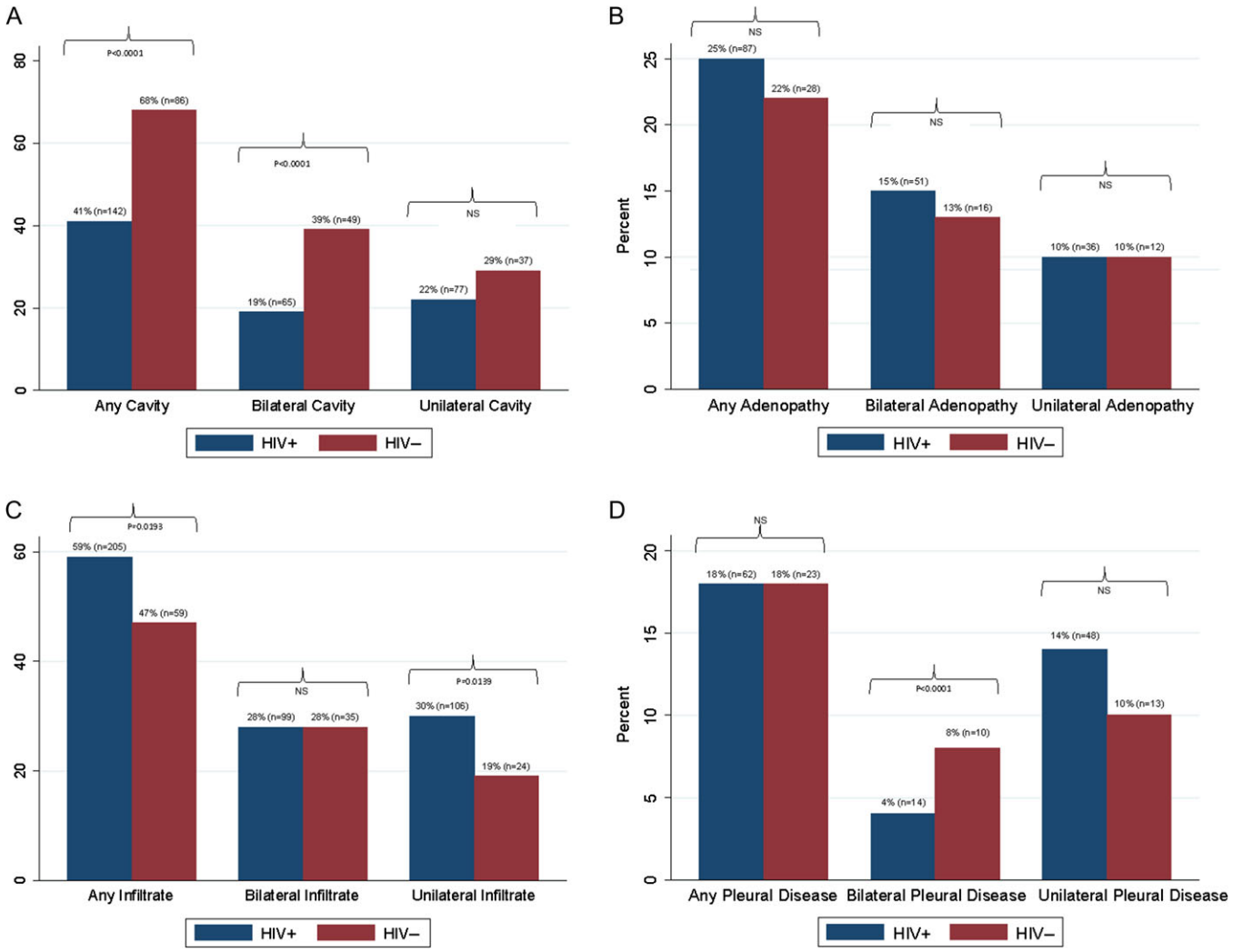

Figure 2. (A) Cavitation chest x-ray findings by HIV status; (B) adenopathy chest x-ray findings by HIV status; (C) infiltrate chest x-ray findings by HIV status; (D) pleural disease chest x-ray findings by HIV status. HAART: highly active antiretroviral therapy; NS: non-significant p-value.

HIV. Compared to HIV-uninfected individuals, those who had HIV had a higher proportion of infiltrates and a lower proportion of cavitations on CXRs. When cavities were present on CXR, they were smaller and more likely to be confined to less than one quarter of the thoracic chest cavity radiologically than in HIV-uninfected individuals.

Our study shows a significant association between infiltrates and HIV status. Individuals with HIV present more with infiltrates compared to HIV-uninfected individuals. It may be that individuals with HIV present with a higher proportion of primary TB compared with post-primary TB.[13,14,15] However, this is in contrast to another study conducted in India which showed a higher proportion of infiltrates in HIV-uninfected individuals.[5]

Our findings are similar to other smaller studies performed in HIV-seropositive individuals co-infected with PTB.[4,5] These studies suggest that individuals with HIV do not present with cavitations when compared to HIV-uninfected individuals.[16,17] This is likely due to individuals with HIV not mounting the robust cell-mediated response required to form granulomas and subsequent cavities.[5,13]

Our subset analysis of individuals with HIV showed an association between cavitation size and HAART. Our study shows the unpredictable presentation of PTB in HAART-recipients and HAART-naïve individuals. It is one of the first studies to show HAART recipients presenting with larger cavitations (≥4 cm) compared to HAART naïve individuals. This is likely due to HAART-mediated restitution of immunity, resulting in larger cavitations being formed. Individuals with HIV with CD4 counts>200 were associated with having a higher proportion of infiltrates and cavities that those with CD4≤200. This is in keeping with a better immune system resulting in cavitations in PTB.

The limitations of the study were that this was a secondary data analysis in which additional important variables such as use of immunosupressants, duration of HAART and co-morbid diseases could not be investigated.

Further analysis of the CXRs such as presence or absence of nodules, fibrosis and miliary TB would have also been unique factors to assess but were unavailable due to the standardized method of reporting.

Conclusions

PTB typically presents as an upper lobe cavitatory disease on CXR. In a resource-limited setting where the burden of HIV-associated PTB remains high, CXR may become moot as individuals with HIV with PTB are unlikely to present with typical CXR findings. However, the absence of typical findings does not exclude the diagnosis of PTB in the individuals with HIV. A high index of suspicion is required when diagnosing PTB as the clinical and radiological features may differ.

Authors' contributions: JK, FL, KO, BK and NM participated in the design of the study and its implementation. JK, FL, KO, RP, NM, LL, AD, BK and NM participated in the analysis and interpretation of data as well as writing the manuscript. All authors read and approved the final manuscript. NM is guarantor of the paper.

Acknowledgements: The authors would like to thank the participants for their time and participation in this study. Our gratitude also goes to the PHRU staff for ensuring the success of this project.

Funding: Funding for this study was obtained from the MRC Soweto Matlosana Collaborating Centre for HIV/AIDS and TB, an International Early Career Scientist Award from the Howard Hughes Medical Institute, the South African National Research Foundation and the South African Medical Research Council.

Competing interests: None declared.

Ethical approval: Ethical approval was provided by the University of the Witwatersrand Human Research Ethics Committee.

References

1 Kanabus A. Information about Tuberculosis. Global Health Education 2016.

2 Hunter R. Pathology of post primary tuberculosis of the lung: an illustrated critical review. Tuberculosis (Edinb) 2011;91:497–509.

3 Patel K, Rami K, Ghanchi F. Radiological manifestations in patients of pulmonary tuberculosis with HIV. Natl J Med Res 2012; 2:420–2.

4 Munthali L, Khan PY, Mwaungulu NJ et al. The effect of HIV and antiretroviral therapy on characteristics of pulmonary tuberculosis in northern Malawi. BMC Infect Dis 2014;14:107.

5 Swaminathan S, Narendran G, Pradeep A et al. Impact of HIV infection on radiological features in patients with pulmonary tuberculosis. Indian J Chest Dis Allied Sci 2007:49: 133–6.

6 Padmapriyadarsini C, Narendran G, Swaminathan S. Diagnosis and treatment of tuberculosis in HIV co-infected patients. Indian J Med Res 2011;134:850–65. doi:10.4103/0971-5916.92630.

7 Van Cleeff MRA, Kivihya-Ndugga LE, Meme H et al. The role and performance of chest X-ray for the diagnosis of tuberculosis: a cost-effectiveness analysis in Nairobi, Kenya. BMC Infect Dis 2005;12:5: 111. Doi:10.1186/1471-2334-5-111.

8 Kisembo NH, Den Boon S, Davis JL et al. Chest radiographic findings in pulmonary tuberculosis in severely immunocompromised with human immunodeficiency virus. The Brit J Radiol 2012;e130 – 9.

9 Tahir NM, Ibinaiye PO, Saad ST et al. Determination of the effect of highly active antiretroviral therapy on radiographic features of pulmonary tuberculosis in HIV infected patients. West Afr J Radiol 2015; 22:1–9.

10 Martinson N, Hoffman C, Chaisson R. Epidemiology of tuberculosis and HIV. Proc Am Thorac Soc 2011; 8:288–93.

11 City of Johannesburg Metropolitan Municipality. Johannesburg, South Africa: The remaking of Soweto End of Term Report 2006 – 2011. City of Johannesburg Metropolitan Municipality; 2006. http://www.joburg.org.za [accessed 7 August 2015].

12 Edginton ME, Wong ML, Phofa R et al. Tuberculosis at Chris Hani Baragwanath Hospital: numbers of patients diagnosed and outcomes of referrals to district clinics. Int J Tuberc Lung Dis 2005;9: 398–402.

13 Greenberg SD, Frager D, Suster B et al. Active pulmonary tuberculosis in patients with AIDS: spectrum of radiographic findings (including normal appearance). Radiology 1994;193:115–9.

14 Badie BM, Mostaan M, Izadi M et al. Comparing radiological features of pulmonary Tuberculosis with and without HIV infection. J AIDS Clin Res 2012; 3:10.

15 Lawn SD, Wood R, De Cock KM et al. Antiretrovirals and isoniazid preventative therapy in the prevention of HIV-associated tuberculosis in settings with limited healthcare resources. Lancet Infect Dis 2010; 10:489–98.

16 Stirling T, Pham P, Chaisson R. HIV infected-related tuberculosis: clinical manifestations and treatment. Clin Infect Dis 2010;50(Suppl 3):S223–30.

17 Hoffman C, Churchyard G. Pulmonary Tuberculosis in Adults. In: Tuberculosis: A Comprehensive Clinical Reference. Schaaf SH, Zulma A, eds. St. Louis: Saunders Elsevier; 2009, p. 332–41.