

https://dspace.org/

Breast Tuberculosis: a retrospective analysis of the disease burden among three tertiary hospitals in Johannesburg

Mathew, Denny

2021
https://hdl.handle.net/10539/32405

Downloaded from a DSpace repository. https://dspace.org/

Breast Tuberculosis: A retrospective analysis of the disease burden in three tertiary hospitals in Johannesburg.

Dr Denny Mathew





A research report submitted to the Faculty of Health Sciences, University of the Witwatersrand, Johannesburg, in partial fulfilment of the requirements for the degree of Master of Medicine in Diagnostic Radiology.

Johannesburg, 2019

Declaration

I, Denny Mathew, declare that this research report is my work. It is being submitted for the degree of MMed (RadD) at the University of the Witwatersrand, Johannesburg. It has not been submitted before for any degree or examination at this or any other University.



Dr Denny Mathew

On this 4th day of August 2019.

This study is dedicated to my loving wife, Hannali. Thank you for your continued support in everything that I do.

Acknowledgements

- My supervisors Dr. Grace Rubin, Professor Nasreen Mahomed, and Professor Sarah Rayne. Thank you for the time and effort you have set aside for me during this period to assist me in completing this study. Your experience in your respective fields, both as specialists and in research, has been invaluable. All the advice, direction, support and motivation have resulted in an end product of which I am very proud.

- Dr. Innocent Maposa for assistance with the statistical analysis.

- Dr. Jacqueline Smilg who initially proposed this study topic to me.

- Department of Diagnostic Radiology, WITS University, for the protected research time to work on this project.

- Mr. Owen Naicker for assisting me with the necessary documentation for the submission of the protocol and final MMed research project.

Publications and presentations

- Electronic poster presentation – "Breast Tuberculosis – A review of 62 cases". *Imaging in Prague, Global Radiology CME, June 2019.* Winner of best electronic poster under the "Body Imaging" category at this congress.
- Oral presentation – "Breast Tuberculosis: A retrospective analysis of the disease burden in three tertiary hospitals in Johannesburg." *RSSA/BISSA breast imaging congress, August 2019.*
- Submitted to the European Journal of Radiology – under review
    - Authors: Denny Mathew, Grace Rubin, Nasreen Mahomed, and Sarah Rayne
    - Year: 2019
    - Title of paper: Imaging and clinical features of breast tuberculosis: A review series of 62 cases

Abstract

INTRODUCTION: Breast Tuberculosis (TB) is a rare condition that has not been commonly reported. The incidence in developed countries has been reported as less than 0.1% of all surgical breast lesions and 3 − 4.5% of breast lesions in countries where TB is endemic.

AIM: To outline the disease burden of breast TB as a quantitative analysis amongst three tertiary hospitals in Johannesburg, South Africa, with correlation to their clinical, demographic and imaging features.

METHOD: A retrospective analysis over 18 months (01/01/2017 – 20/06/2018) of all patients undergoing laboratory investigations for breast disease at the mammography departments of these three tertiary centres.

RESULTS: The prevalence of breast TB was 2.5% (n = 62) of a total of 2516 patients. The median age of presentation was 38.5 years (IQR 33 – 45). HIV status was known in 45 patients, of whom 36 were HIV-infected (80%, 95% CI: [0.65 – 0.90], $p < 0.0001$). Based on the ultrasound and/or mammogram findings, patients were classified under five categories: TB breast abscess (40.3%), inflammatory/disseminated (24.2%), isolated TB lymphadenitis (22.6%), nodular (11.3%) and sclerosing form (1.6%). Histology demonstrated necrotizing granulomatous inflammation in 57 cases (92%). Acid-fast bacilli was positive in 8.1% (n = 5) of the cytology and 16.1% (n = 10) of the histology specimens. Culture for Mycobacterium tuberculosis was positive in 17 cases (27%).

CONCLUSION: Knowledge of the varied clinical and radiological features is necessary to maintain a high degree of suspicion to prevent misdiagnoses, complications and inappropriate management.

Table of Contents

Declaration ii

Acknowledgements iv

Publications and presentations xii

Abstract iv

List of Figures ix

List of Tables x

Nomenclature x

1. Introduction 1

1.1 Tuberculosis 1

1.2 Impact of HIV on TB 2

1.3 Association between HIV infection and EPTB 3

1.4 Breast TB 3

1.4.1 Routes of infection 3

1.4.2 Clinical presentation 4

1.4.3 Imaging characteristics 5

1.4.4 Other findings 6

1.4.5 Differential diagnosis 7

1.4.6 Treatment 7

1.5 Rationale 8

1.6 Research Aim 8

1.7 Study objectives 9

2. Materials and Methods 10

2.1 Study site 10

2.2 Research paradigm and sample 10

2.3 Inclusion criteria 11

2.4 Exclusion criteria 11

2.5 Data collection and safety 11

2.6 Image acquisition 12

2.7 Statistical analysis 12

2.8 Ethical clearance 13

3. Results 13

3.1 Demographic and clinical results 13

3.2 Imaging results 15

3.3 Laboratory results 20

4. Discussion 20

4.1 Diagnosis 31

4.2 Results in context 32

4.3 Current applications 36

4.4 Limitations of the current study 36

4.5 Future applications 37

5. Conclusion 39

6. References 40

Appendix A: Ethics Clearance Certificate 44

List of Figures

		Page number
Figure 2.1	Flow diagram of the research paradigm and process	10
Figure 3.1	Age versus frequency graph	15
Figure 3.2	Clinical presentation of breast mass with radiological correlation	16
Figure 3.3	Ultrasound findings of breast TB	17
Figure 3.4	Mammogram findings of breast TB	18
Figure 4.1	Tuberculous breast abscess	26
Figure 4.2	Inflammatory/disseminated form	27
Figure 4.3	Isolated TB lymphadenitis	28
Figure 4.4	Nodular form	29
Figure 4.5	Sclerosing form	30
Figure 4.6	Proposed algorithm for granulomatous breast disease	38

List of Tables

		Page number
Table 3.1	Demographic and clinical features	14
Table 3.2	Radiological classification of breast TB in this study	19
Table 4.1	Radiological classification of breast TB in this study – imaging features	23
Table 4.2	Comparative analysis of the literature with other case series of breast TB	32 - 35

Nomenclature

AFB	Acid-Fast Bacillus
AIDS	Acquired Immune Deficiency Syndrome
ACE	Angiotensin Converting Enzyme
MPO	Anti-myeloperoxidase
PR3	Anti-proteinase 3
ATT	Anti-tubercular Treatment
ADC	Apparent Diffusion Coefficient
CMJAH	Charlotte Maxeke Johannesburg Academic Hospital

CXR	Chest Radiograph
CHBAH	Chris Hani Baragwanath Academic Hospital
CD4	Cluster of differentiation 4
CI	Confidence Interval
CC	Craniocaudal
c-ANCA	Cytoplasmic Antineutrophil Cytoplasmic Antibodies
DWI	Diffusion Weighted Imaging
DCE-MRI	Dynamic Contrast-enhanced Magnetic Resonance Imaging
EPTB	Extra-pulmonary Tuberculosis
FNA	Fine Needle Aspiration
FNAC	Fine Needle Aspiration and Cytology
HJH	Helen Joseph Hospital
HIV	Human Immunodeficiency Virus
IGM	Idiopathic Granulomatous Mastitis
IQR	Interquartile Range
KZN	Kwazulu-Natal
MRI	Magnetic Resonance Imaging
MLO	Mediolateral Oblique
MHZ	Megahertz
MDR	Multi-drug Resistant
MTB	Mycobacterium Tuberculosis
NHLS	National Health and Laboratory Service
PAS	Para-aminosalicylic acid

PACS	Picture Archive and Communication System
PCR	Polymerase Chain Reaction
PTB	Pulmonary Tuberculosis
SD	Standard Deviation
T2WI	T2 weighted imaging
TB	Tuberculosis
VL	Viral load
WHO	World Health Organization

1. Introduction

1.1 Tuberculosis

Tuberculosis (TB) is a major health problem with over a billion people affected worldwide.[1–4] TB remains an important cause of mortality and morbidity in all age groups.[2] Among individuals affected with human immunodeficiency virus/acquired immunodeficiency syndrome (HIV/AIDS), TB is still the most common opportunistic infection with co-infected persons being at a higher risk of death.[5] TB is a chronic, granulomatous, multi-systemic disease that is predominantly caused by the organism *Mycobacterium tuberculosis*.[1,6] It is categorized as pulmonary TB and extra-pulmonary TB (EPTB).[2] EPTB constitutes approximately 15–20% of all cases of TB in immune-competent individuals and more than 50% in HIV-infected patients.[7,8]

The transmission of TB is via the spread of aerosolized infectious droplet nuclei.[9] The risk of TB transmission is determined by various factors such as the intensity of exposure to an individual with infectious TB; the degree of infectiousness of the index person; intimacy and duration of that interaction; and the environment in which this interaction takes place.[9,10] This risk is increased in those with a compromised immune system due to HIV/AIDS (most commonly) but also with chronic steroid use, chemotherapy, malnutrition, diabetes mellitus, and alcoholism.[9,10]

The incidence of TB is commonly inversely proportional to the development index of the country with developed countries globally demonstrating the lowest incidence rates for TB and parts of Africa and India amongst the highest worldwide.[1,9] It is estimated that at least one in every 100 people in South Africa and Swaziland develops TB each year.[9]

Factors fuelling the TB epidemic and preventing its eradication are related to the increasing prevalence of HIV/AIDS, population dynamics (travel and migration), and the increase in multi-drug resistant strains of TB.[6]

1.2 Impact of HIV on TB

Co-infection with HIV remains the most formidable risk factor for the development of active TB disease.[10]

The World Health Organization (WHO) 2015 report showed that there were 10.4 million incident cases of TB worldwide, of which 10% were co-infected with HIV and about 1.4 million deaths, of which 400 000 deaths were among those co-infected with HIV.[11]

In sub-Saharan Africa, TB/HIV co-infection is estimated to be 32%, which is representative of 74% of those worldwide.[11] The estimated incidence of active TB cases in South Africa by the WHO in 2015 was 454 000, of which about 57% were HIV-infected.[12]

The rise in HIV/TB co-infection is attributed to the increased risk of developing active TB from primary TB infections or reactivation of latent infection – the immune-compromised status facilitates this disease progression.[11]

The pill burden (long-term treatment with various medications) and various drug-drug interactions in those with HIV/TB co-infection results in a higher treatment default rate, ultimately leading to an increase in drug-resistant TB, morbidity and mortality. HIV infection may also be associated with atypical clinical presentations of TB, smear-negative PTB, and a higher frequency of EPTB, thus contributing to a diagnostic, economic and management challenge.[11]

1.3 Association between HIV infection and EPTB

EPTB, defined as TB infection outside of the lungs, is an AIDS-defining condition indicating clinical stage 4 disease in adults.[13] In a study conducted in Soweto, South Africa, the commonest sites of EPTB were the pleura (39.1%) and lymph nodes (31%).[7] In this study of EPTB amongst the Soweto adult population, the incidence was 88.6/100 000, rising to 139.4 and 125.7/100 000 in the 25 – 34-year and 35 - 44-year age groups.[7] Due to the aerobic nature (preference for tissues with high oxygen content) of *Mycobacterium tuberculosis*, the majority of adult TB is largely confined to the lungs.[14,15] As the degree of immunosuppression progresses, EPTB becomes increasingly more common, with patients with a Cluster of Differentiation 4 (CD4) count less than 200 having a higher incidence of EPTB.[16]

EPTB is associated with a poorer prognosis due to a variety of factors: challenging diagnosis with associated diagnostic delay, unrecognized and undiagnosed infection, and longer treatment duration often associated with poor compliance in the completion of therapy.[8]

1.4 Breast TB

Breast TB was first described by Sir Astley Cooper in 1829 as 'scrofulous swelling of the bosom'.[17,18]

1.4.1 Routes of infection

Breast TB is a rare manifestation of EPTB and only represents approximately 0.1% of EPTB.[3] The mammary cells lack the abundance of lymphoid tissue and provide an infertile environment for the organism.[4,19,20] TB was demonstrated in almost all organs except the breast in an autopsy series of 34 patients who died from miliary TB.[6] Breast TB has

traditionally been classified as primary when the only manifestation of TB was within the breast and secondary when a focus of TB is detected elsewhere within the body.[1,21] In addition to lymphatic spread, spread may also occur via direct extension from contiguous structures (e.g. chest wall from tuberculous pleurisy, adjacent infected rib/sternum/costochondral cartilage/shoulder joint, or from the direct inoculation via skin abrasions).[1] Tuberculosis of the faucial tonsils of the suckling infant has also been reported as a potential route for the spread of infection from the infant to the nipple and subsequently to the lactiferous ducts and lactating breast.[1] The breast is considered relatively resistant to the haematogenous spread of tuberculous infection.[1]

1.4.2 Clinical presentation

Within TB and/or HIV endemic regions, breast TB should be suspected and included in the differential diagnosis in any person presenting with an atypical breast mass or persistent abscess with or without a draining sinus.[22] It occurs more frequently in women of reproductive age with risk factors being HIV/TB co-infection, multiparity, and lactation.[3,22,23]

The vast majority of patients (~ 70%) present with axillary lymphadenopathy.[3] Bilateral breast TB is uncommon and is only present in ~3% of cases.[3] Breast TB may present as a painless lump that is hard, irregular and at times fixed to the skin, muscle or chest wall, making it clinically indistinguishable from breast cancer.[1] Nipple or skin retraction may occur, but nipple discharge is uncommon.[24] In persons without systemic TB, constitutional symptoms are rare.[3]

A high index of suspicion for breast TB is needed, particularly in TB endemic areas, as there are no clinical or radiological features that are absolutely diagnostic.[3,25]

1.4.3 Imaging characteristics

Based on the clinical, pathological, and radiological appearances, breast TB is conventionally classified into three types: nodular, diffuse and sclerosing form.[6,26]

1.4.3.1 Nodular form

The nodular form is characterised by a well-circumscribed, slow-growing, painless lesion.[1] An enlargement of this lesion may infiltrate the skin resulting in ulceration and/or discharge from a sinus tract.[27] This course makes the differentiation with breast cancer difficult.[1] If the virulence of the organism is low and the immunity is high, the inflammatory process ends with the formation of a non-caseating granuloma.[6] On mammogram and ultrasound imaging, this may mimic the appearance of a fibroadenoma.[26]

1.4.3.2 Diffuse form

In this form, there are multiple foci of TB within the breast that later caseate and lead to abscess and sinus formation.[6,27] It is seen in those with a poor immune response associated with a virulent infection.[6] On mammography, the radiographic density of the centre of the lesion is less dense compared to the periphery due to its fluid nature, which may be useful in differentiating this form from malignancy.[26] On ultrasound, abscesses are characterized by an irregular margined mass that is hypoechoeic and heterogeneous with the presence of mobile internal echoes.[6]

1.4.3.3 Sclerosing form

The dominant feature in this form is of extensive fibrosis rather than caseation.[27] Mammographic features are dependent on the variable degree of fibrosis.[26] The first being asymmetrical breast density which is localized to the involved sector and

recognized by an increase in the breast density secondary to the fibrosis.[26] The second mammographic feature is a non-uniform pattern of reduction and retraction of the breast volume due to the fibrotic changes to the Coopers ligament (i.e. breast atrophy).[26] On mammogram, reticular scarring and interlobular oedema may obscure an underlying mass.[6] In these instances, ultrasound plays an important role in confirming the presence of a mass and assessing it morphology.[26]

1.4.4 Other findings

Ductal involvement on mammography appears as a retro-areolar serpiginous opacity and on ultrasound as dilated, secretion-filled tubules converging to the nipple.[26]

Calcification may be evident with a healed granulomatous lesion – typically macro calcifications.[26]

Skin thickening may be focal or diffuse which is demonstrable on both mammography and ultrasound.[1,6] The skin bulge and sinus tract sign has been described as the mammographic demonstration of a dense tract connecting an ill-defined breast mass (underlying caseating granuloma) to a localized region of skin thickening and bulge.[26]

Lymphadenopathy (intra-mammary or axillary) may be evident on both mammography and ultrasound; however, ultrasound remains a more sensitive technique in the detection and characterization of lymph nodes.[6,26]

Chest radiograph (CXR) may demonstrate the presence of active or healed previous TB infection in the lungs or calcified lymph nodes.[1]

1.4.5 Differential diagnosis

The differential diagnosis may include breast cancer, pyogenic breast abscess, fungal infections and idiopathic granulomatous mastitis (IGM).[3,28] IGM most commonly presents with a breast mass and this may penetrate the underlying pectoralis muscle or skin.[1]

IGM patients may also present with nipple retraction, sinus formation, and axillary lymphadenopathy – all of which may also be observed in breast TB and breast cancer.[1]

1.4.6 Treatment

Most patients respond well to anti- TB therapy (ATT).[1,3] The current standard treatment regimen for EPTB includes 2 months of isoniazid, rifampicin, pyrazinamide, ethambutol and 7 months of isoniazid and rifampicin.[1, 29]

It has been proposed that patients living in TB endemic areas with a breast mass that demonstrates histological evidence of granulomatous inflammation, should receive ATT even if the TB culture results are inconclusive or negative.[3]

Breast TB with multidrug-resistant tuberculosis (MDR) has been reported.[1] In these instances, therapy would include a combination of first-line and second-line drugs that include kanamycin, ofloxacin, ethionamide, para-aminosalicylic acid (PAS), pyrazinamide, and isoniazid.[1]

Despite the absence of a documented criterion for the radiological response to treatment, drug resistance may be suspected when ultrasound and/or mammography fail to demonstrate a reduction in size or change in the appearance of the breast lesion.[3]

1.5 Rationale

The incidence of TB is sharply rising in developing countries and previously rare extra-pulmonary manifestations such as breast TB can potentially pose diagnostic challenges in clinical practice.[1] Despite the high prevalence of pulmonary TB worldwide and even higher prevalence in South Africa, breast TB is a rare condition and has not been commonly reported.[6] An accurate diagnosis is imperative as this has serious implications in patient management.[3] There is limited literature with regards to breast TB in South Africa with only two studies to date having described this entity. The numbers of cases described are either low and single-centre (Helen Joseph Hospital) [6], or in a population with a different demographic disease profile (Durban, South Africa). [3]

No study to date has evaluated the current disease burden of breast TB amongst the wider Johannesburg population accessing the three tertiary hospitals of south Gauteng – Charlotte Maxeke Johannesburg Academic Hospital (CMJAH), Chris Hani Baragwanath Academic Hospital (CHBAH) and Helen Joseph Hospital (HJH).

1.6 Research Aim

This study aims to outline the disease burden of breast TB as a quantitative analysis amongst those undergoing pathological investigations for breast disease at these three tertiary hospitals in Johannesburg, with correlation to their clinical, demographic and imaging features.

1.7 Study objectives

1.7.1 Primary objective

To determine what proportion of patients are diagnosed with breast TB from those undergoing pathological investigations for breast disease.

This group of patients would include those subjected to core biopsies and/or fine needle aspiration (FNA) of axillary/intra-mammary lymph nodes and/or intra-mammary masses/collections.

1.7.2 Secondary objective

To describe the demographic, clinical and radiological characteristics of those patients diagnosed with breast TB.

- **Any** records confirming the diagnosis of breast TB:
    - histology confirmed breast TB, positive TB culture, smear positivity on Ziehl–Neelsen staining or Polymerase Chain Reaction (PCR) positive for breast TB.

2. Materials and Methods

2.1 Study site

The data was collected from the mammography units of three tertiary hospitals in Johannesburg, South Africa - CMJAH, HJH, and CHBAH. These public sector hospitals are part of the University of the Witwatersrand teaching complex.

2.2 Research paradigm and sample

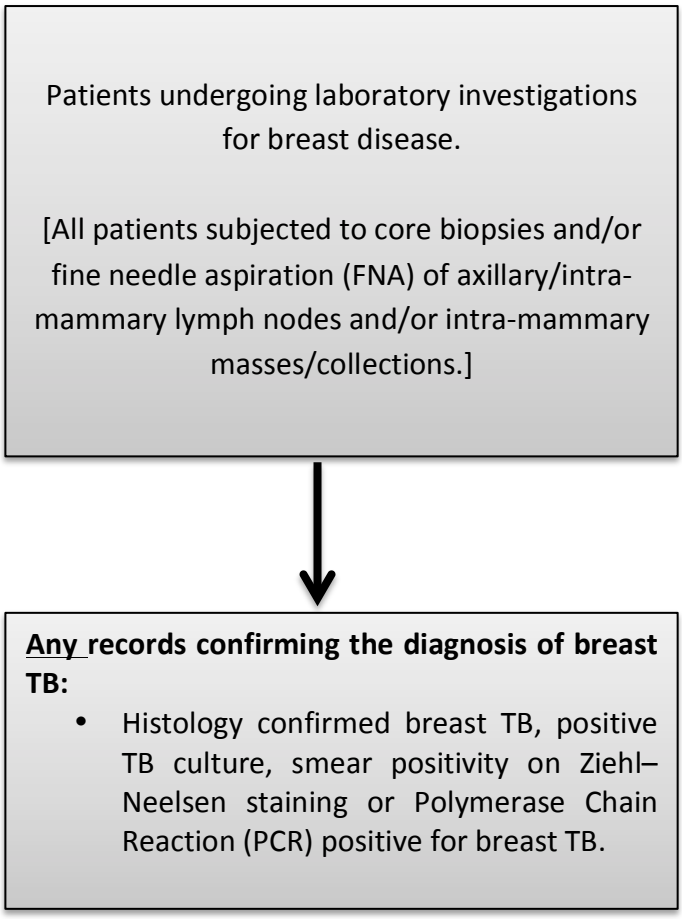

(Records in the procedure book of each mammography unit).

SAMPLE POPULATION

Primary Objective: To determine what proportion of patients are diagnosed with breast TB from those undergoing laboratory investigations for breast disease.

Secondary objective: To describe the demographic, clinical and radiological characteristics of those patients diagnosed with breast TB.

Figure 2.1 Flow diagram of the research paradigm and process

This is a retrospective cross-sectional study for the period of 01/01/17 – 30/06/18.

2.3 Inclusion criteria

- All patients undergoing pathological investigations for breast disease as detailed above.
    - In those with laboratory evidence of breast TB, a correlation was made with the demographic, clinical and imaging findings.

2.4 Exclusion criteria

Patients with laboratory evidence of breast TB with no records of the radiological images or clinical information.

2.5 Data collection and safety

- A procedure book is kept in the mammography units of all three hospitals with the patient's name and surname, hospital number, and a reference barcode of the specimen/s taken.
- The National Health and Laboratory Services (NHLS) lab track viewer was used to trace all the FNA/biopsy results.
- In those with laboratory evidence of breast TB, the demographic and clinical correlation was based on the information on the referral form and/or patient's clinical file.
- Ultrasound and/or mammogram images and reports were extracted from the local Picture Archive and Communication System (PACS) and/or patient files from each hospital.
- The patient's HIV status, if known, was also documented (if mentioned in the history of the imaging reports or serological evidence using the NHLS lab track viewer). If the patient was known to be HIV infected, a correlation with the CD4

count and viral load (VL) was made (if available) using the NHLS lab track viewer. If no HIV result is found, the patient was classified as HIV "unknown". If a negative HIV test was found within 6 months prior to the biopsy date, the patient was classified as HIV-uninfected at time of biopsy.

The data was anonymized and collected using a data collection sheet and entered into a double password protected Excel spreadsheet (password for the computer and password for the spreadsheet). Each patient was allocated a patient code and only this number linked with the patient's details. The key to this code was only available to the primary investigator and supervisors. The patient data was stored on the primary investigator's computer with back up files saved onto an external hard drive. Upon awarding of the MMed degree, the complete data set will be erased and the key deleted.

2.6 Image acquisition

Standard mammography views were obtained for both breasts in mediolateral oblique (MLO) and craniocaudal (CC) views using the standard digital mammographic units within the departments. Ultrasound images of the breast and axilla were obtained using a 14 or 18 megahertz (MHz) linear probe. The ultrasounds were performed and mammograms interpreted by consultant radiologists. Lesions amenable to FNA/biopsy were localized clinically and radiologically and biopsied under ultrasound guidance.

2.7 Statistical analysis

The data were analysed using STATA software, version 13.0. Descriptive statistics using proportions, frequencies and graphs were used to analyse results based on the varied demographic, clinical and radiological (ultrasound and mammography) patterns.

Uni- and multi-variate analysis was used where appropriate to determine factors increasing the likelihood of a positive diagnosis. A p-value of <0.05 was considered significant.

2.8 Ethical clearance

Ethics approval for this study was granted by the University of the Witwatersrand Human Research Ethics Committee. (Certificate No. M180830 – Appendix A)

3. Results

3.1 Demographic and clinical results

A retrospective analysis was done over an 18-month study period dated 01/01/17 – 30/06/18 amongst three tertiary hospitals in Johannesburg.

A total of 2516 patients underwent laboratory investigations for breast disease. This group of patients included those subjected to core biopsies and/or FNA's of axillary/intra-mammary lymph nodes and/or intra-mammary masses/collections.

Sixty-two records of patients with laboratory evidence of breast TB were identified from this subset of patients, thus representing a prevalence of 2.46% for breast TB during this period. A total of 35 cases of breast TB were identified at CMJAH, 15 cases at HJH and 12 cases at CHBAH.

The demographic and clinical features are outlined in Table 3.1 and Figure 3.1. All of the 62 patients diagnosed with breast TB were female and the median age was 38.4 [Interquartile range (IQR 33 – 45)]. One patient presented with bilateral breast disease.

Table 3.1 Demographic and clinical features

Demographic and clinical features (n = 62)		
Characteristics		
	Median	**IQR**
Age at presentation	38.4	33 - 45
Side	**n**	**%**
Right	34	54.8
Left	27	43.5
Bilateral	1	1.6
Axillary nodes	**n**	**%**
Yes	36	58.1
No	26	41.9
HIV status	**n**	**%**
Total known	45	72.6
Infected	36	58.1
Uninfected	9	14.5
Unknown	17	27.4
	Median	**IQR**
CD4 count (cells/mm^3)	278	110 - 481
	Median	**IQR**
Viral Load (IU/mL)	689.5	20 - 42000
Clinical presentation	**n**	**%**
Breast mass	31	50.0
Mastalgia	25	40.3
Breast swelling	18	29.0
Breast erythema	13	20.9
Discharging sinus	6	9.6
Abscess	5	8.1
Nipple discharge	0	0.0

**Patients may have one or more presenting feature*

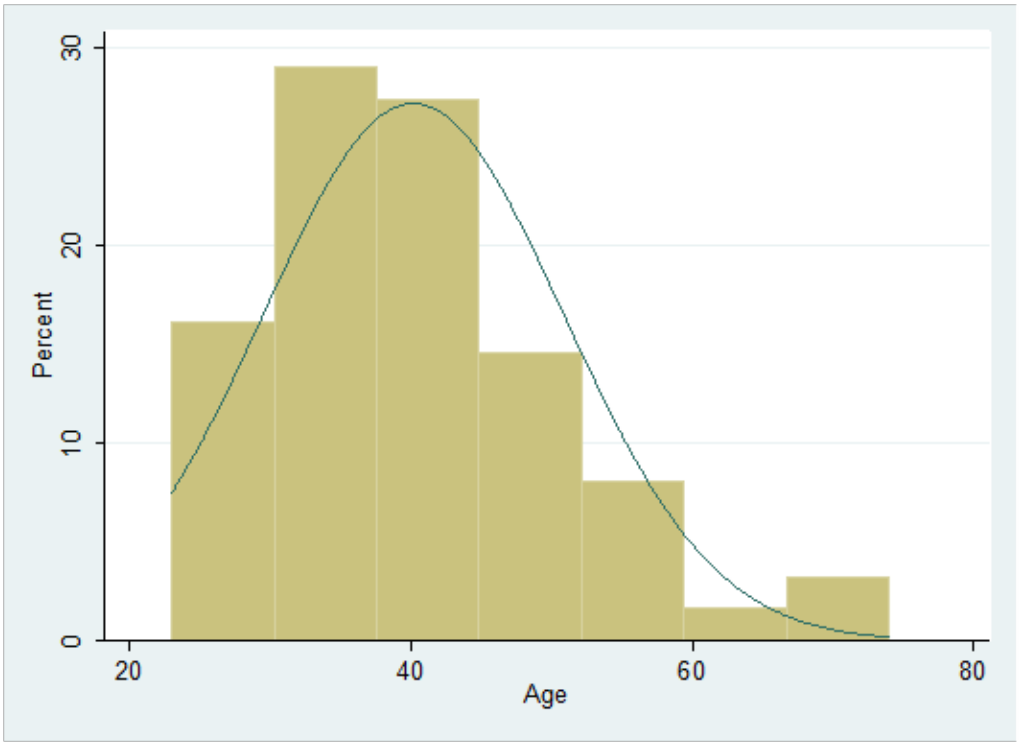

Figure 3.1 Age versus frequency graph

The HIV status was known in 45 patients (72.6%). Breast TB was more common amongst HIV infected patients (n=36) (80%, 95% CI: [0.65 – 0.90], *p*-value < 0.0001).

In those patients known to be HIV-infected, the CD4 count was available in 14 patients (31.1%) and VL in 16 patients (35.6%).

The most common clinical presentation was that of a breast mass, 31 (50%).

3.2 Imaging results

The clinical findings of a breast mass with correlation to the ultrasound and/or mammogram imaging findings are summarized in Figure 3.2.

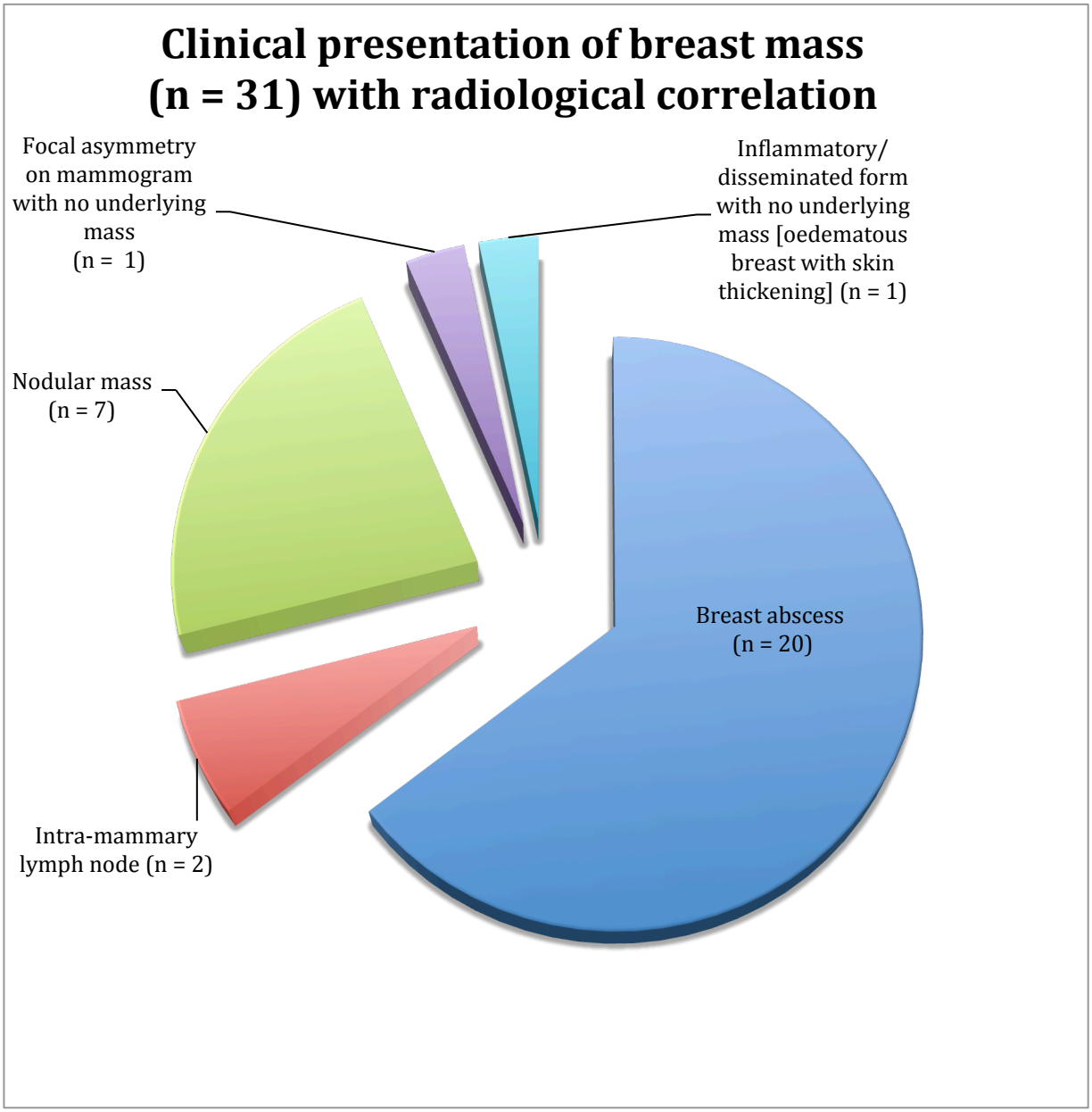

Figure 3.2 Clinical presentation of breast mass with radiological correlation

Radiological features on ultrasound and mammogram are summarized in Figure 3.3 and Figure 3.4.

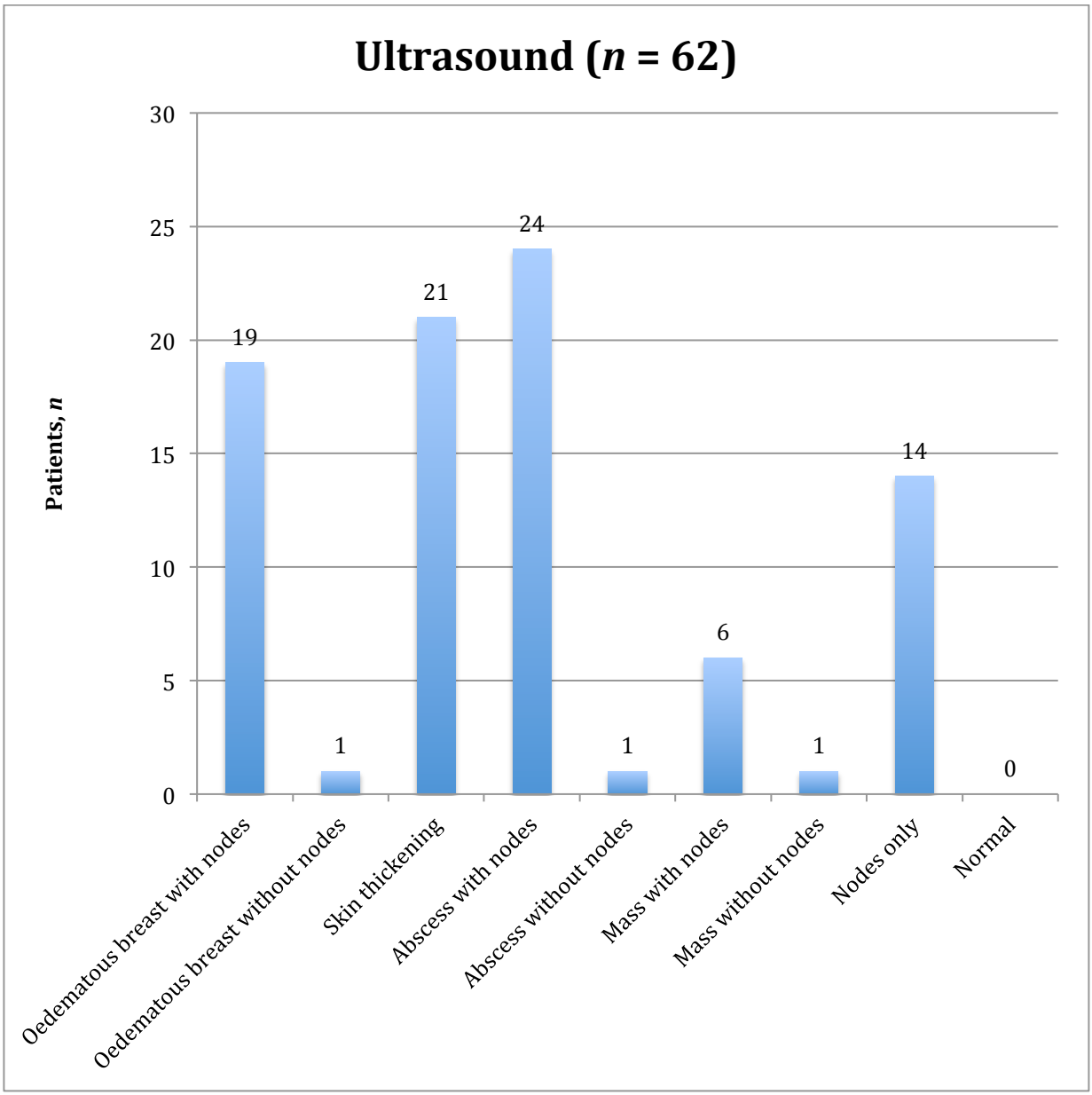

*Patients may have more than 1 ultrasound finding

Figure 3.3 Ultrasound findings of breast TB

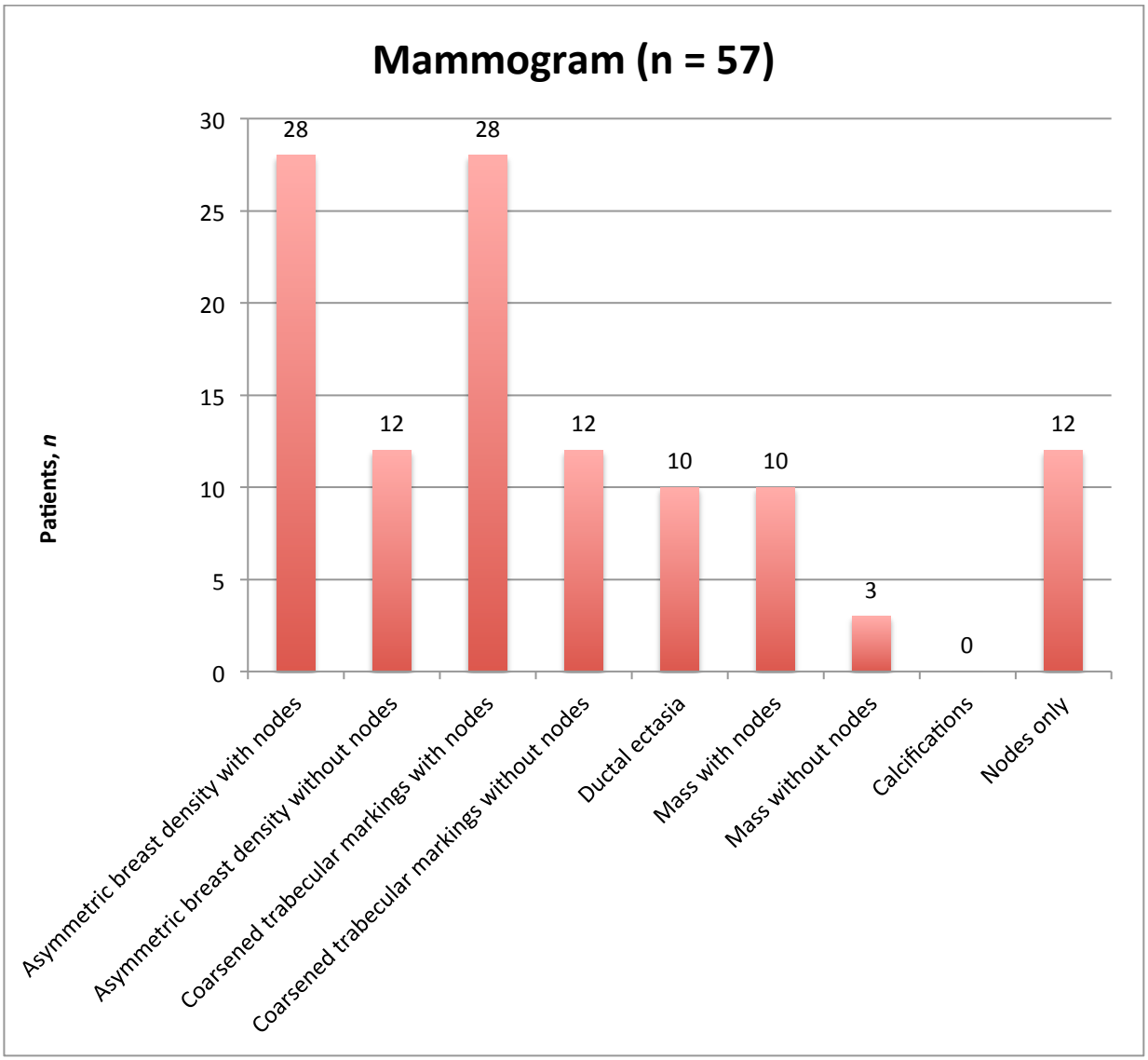

***Patients may have more than 1 mammogram finding*

Figure 3.4 Mammogram findings of breast TB

Ultrasound scans were done in all 62 patients with the most common pattern being that of a breast abscess with nodes (n = 24). A mammogram was done in 57 of the 62 patients – 2 patients (age 14 and 32) did not have mammograms because of their age, 1 patient was pregnant, 1 patient had an open skin wound and 1 patient had a recent mammogram at another hospital with the mammogram images on a disc.

Asymmetric breast density pattern was seen on mammography in 40 cases, of which 25 were segmental and 15 were diffuse. This finding was associated with coarsened

trabecular markings. After supplementary imaging with ultrasound, of the 13 cases identified as a mass on mammography, 9 cases correlated to be an abscess, 2 cases an intra-mammary lymph node and 2 cases a solid mass.

Based on the ultrasound and/or mammogram findings, we classified the patients under 5 categories (Table 3.2).

Table 3.2 Radiological classification of breast TB in this study

Radiological classification		
	n	**%**
1. Tuberculous breast abscess	25	40.3
2. Inflammatory/disseminated form	15	24.2
3. Isolated TB lymphadenitis	14	22.6
4. Nodular form	7	11.3
5. Sclerosing form	1	1.6
Total	**62**	100

Despite the fact only five patients presented clinically with a breast abscess, 40.3% of the patients (n = 25) were classified as Tuberculous breast abscess, of which 19 were single abscesses and 5 multiple breast abscesses. In 3 patients, this was associated with a discharging sinus.

A total of 15 patients (24.2%) were classified as an inflammatory/disseminated type as demonstrated by the diffuse inflammation of the breast parenchyma on ultrasound and/or mammogram.

Isolated TB lymphadenitis was detected in a total of 14 patients (22.6%). In one patient, the axillary nodal mass extended to the skin surface with an associated draining sinus. Two patients were asymptomatic with the incidental findings of pathological intra-mammary and axillary lymph nodes on ultrasound.

Despite 31 patients presenting clinically with a breast mass, only 7 patients (11.3%) were classified as a nodular mass after correlation with ultrasound and/or mammogram images (Figure 3.2). In one patient, this form presented as an infra-clavicular chest wall mass. An inflammatory and ulcerative breast lesion was noted in 1 patient in whom the mammogram was omitted.

3.3 Laboratory results

In the 62 patients diagnosed with breast TB, histology demonstrated necrotizing granulomatous inflammation in 57 cases (92%). Acid-fast bacilli (AFB) were positive in 8.1% (n = 5) of the cytology and 16.1% (n = 10) of the histology specimens. Culture for *Mycobacterium tuberculosis* was positive in 27% (n = 17)), and in 12.9% (n = 8), AFB were detected histologically by PCR testing.

4. Discussion

The incidence of breast TB in developed countries has been reported as less than 0.1% of all surgical breast lesions and 3 – 4.5% of breast lesions in countries where TB is endemic.[3]

The proportion of those diagnosed with breast TB in this study (2.46%) is significantly higher in comparison to most of the other similar international studies (Table 4.2). Sakr *et al.* identified 10 cases of breast TB over 18 months and this constituted 0.2% of all cases referred to their institute. [26] Hiremath *et al.* described 7 cases of breast TB over 3 years with an incidence of 0.15% [25], and Mehta *et al.* analysed 63 cases of breast TB over 17 years with a reported incidence of 1.2%. [4] Tewari *et al.* found 30 cases of breast TB over 20 years with an incidence of 2.5%. [27]

Only two studies to date have looked at a retrospective analysis of breast TB in South Africa.

Ramaema *et al.* (2015) conducted their study at two tertiary hospitals in Durban, South Africa and identified 65 patients with breast TB.[3] They reported a prevalence of breast TB of 0.3%. As part of Kwazulu-Natal (KZN), Durban has a higher rate of HIV incidence and lower treatment success rate compared to Gauteng.[12] 2015 WHO TB incident rate per 100 000 was 685 in KZN compared to 330 in Gauteng and the 2014 WHO TB treatment success rates (%) was 73.8 in KZN compared to 83.4 in Gauteng.[12] KZN has the highest prevalence of TB in South Africa with 1076 notified cases per 100 000 population.[12] KZN has a higher TB and HIV incidence rate compared to Gauteng, therefore, the reported prevalence of breast TB in their study is lower than one would expect. [12]

Meerkotter *et al.* conducted their study at HJH, where 21 cases of breast TB were diagnosed over 7 years (2002 – 2008).[6] We identified 15 cases of breast TB at HJH over a shorter period (18-months). One would have expected a decrease in the number of breast TB cases diagnosed in our study through the advent of more than a decade of universal assess to antiretroviral therapy. Meerkotter *et al.* did not specifically look at HIV co-infection in their cases of diagnosed breast TB.

The patients with breast TB in this study were predominantly young [median age of presentation 38.4 (IQR 33 – 45)]. This is comparable with the 2 previous studies conducted in South Africa and with other international studies (Table 4.2).

The prevalence of HIV co-infection in our study was 58% (n = 36). This number may be potentially higher as the HIV status was unknown in 17 patients. It is well known that HIV

co-infection remains the most formidable risk factor for the development of active TB disease with EPTB becoming increasingly more common with higher degrees of immunosuppression. [10, 14, 16]

Extra-pulmonary manifestations of TB, such as breast TB, should prompt the testing of the HIV status in these patients.

The proportion of those HIV infected in this study compared to the study conducted by Ramaema *et al*. (2015) in the KZN population was nearly identical (p: 0.2320).

Longman *et al.* identified 33 cases of breast TB in London, United Kingdom over the period January 2008 – December 2015, with HIV records only being available for 26 of the patients and only one patient was known to be HIV infected. [22]

A correlation with the CD4 count and VL was not made in the latter 2 above-mentioned studies.

In support of the literature, a large proportion of patients (58%) in our study presented with clinically detectable axillary lymphadenopathy. This is comparable with both local and international studies (Table 4.2) but remains a non-specific finding. Enlarged axillary lymph nodes were detected in 85.5% of out patients. The presence of lymphadenopathy (clinical or radiological) in the presence of risk factors needs to increase the diagnostic suspicion for possible breast TB.

We radiologically classified breast TB based on the imaging features in this study as summarized in Table 4.1.

Table 4.1 Radiological classification of breast TB in this study – imaging features

	Tuberculous breast abscess	Inflammatory/Disseminated	Isolated TB lymphadenitis	Nodular form	Sclerosing form
U/S	Hypoechoeic collection with no associated vascularity or as a complex mass which yields pus on aspiration.	Oedematous breast (diffuse trabecular thickening) with dilated ducts and skin thickening	Pathological axillary and/or intra-mammary lymph nodes: • Increased cortical thickness > 3mm • Loss of fatty hilum • Focal/asymmetrical cortical bulge	Solid lesion which may be hypoechoeic or heterogeneous. Margins varied from well defined to irregular.	Focal region of asymmetric breast density with no underlying mass on U/S
Mammogram	Segmental region of asymmetric breast density with coarsened trabecular markings was the most common pattern of this form; however, it may also present as a focal area of increased density suspicious of an underlying mass that correlates with an underlying collection on ultrasound.	Segmental or diffuse asymmetrical breast density compared to the contralateral side with coarsened trabecular markings and skin thickening.	Pathological axillary and/or intra-mammary lymph nodes: • A well-defined dense lesion with loss of the normal reniform shape (To be correlated with ultrasound to confirm as pathological axillary/intra-mammary lymph nodes)	•Segmental region of asymmetric breast density with an associated focal region of coarse trabecular markings • Focal mass opacity with margins that varied from smooth to irregular.	

Tuberculous breast abscess (Figure 4.1) was the most common pattern on ultrasound and was seen in 40.3% of the patients (n = 25). Meerkotter *et al.* identified 3 patients with unilocular abscesses and 2 patients with multiple, complex, intercommunicating collections in their review series of 21 cases of breast TB (23.8%). [6] Ramaema *et al.* (2015) reported breast abscesses in 39% of their patients (n = 16) and this was the most common pattern on ultrasound. [3] Sakr *et al.* noted 40% (n = 4) to be breast abscesses. In a review series of 7 patients with breast TB, Hiremath *et al.* reported 5 cases of breast abscesses (71.4%). [25] The demonstration of breast abscesses in the above-mentioned studies was confirmed on ultrasound imaging. A pyogenic breast abscess is the major differential diagnosis in this category. [3] The lack of response following antibiotic therapy should prompt the inclusion of breast TB in the differential diagnoses and for the sending of laboratory samples specifically for TB analysis.

The inflammatory/disseminated form (Figure 4.2) constituted those with diffuse inflammation of the breast parenchyma (mastitis) and was the second most common pattern radiologically. Meerkotter *et al.* reported 13 cases (62%) of this form, all of which were all also associated with enlarged axillary lymph nodes, as in our study. This pattern was also the second most common form on ultrasound and mammography in the review series conducted by Ramaema *et al.* (2015) Inflammatory breast cancer is the major differential diagnoses of this form.[3]

Isolated TB lymphadenitis (Figure 4.3) was the third most common pattern radiologically. Lymph nodes may either be axillary, intra-mammary or both. The findings of associated axillary lymph nodes either clinically or radiologically are well supported in the literature in patients with breast TB; however, only some authors have categorized this as a

separate entity with regards to isolated TB lymphadenitis. Rameama *et al.* (2015) reported this form in 2.4% of their ultrasound scans (n = 1) and 12.1% of their mammograms (n = 4). These numbers are markedly lower in comparison to our study and further emphasises the point that despite this being a non-specific finding in isolation, a high index of suspicion is still warranted in these cases, particularly in those with risk factors such as HIV/AIDS. Ramaema *et al.* (2018) described the appearance of tuberculous axillary nodes on post-contrast magnetic resonance imaging (MRI) to show peripheral enhancement with a central low signal. [30]

The nodular form (Figure 4.4) was the fourth most common pattern radiologically. Meerkotter *et al.* classified 24% of their patients in this category (n = 5). [6] Longman *et al.* identified this as the second most common pattern and it was seen in 30% (n = 10) of their patients [22], and Sakr *et al.* reported 50% (n = 5) as a nodular form. [26] The differential diagnosis of this form is broad and ranges from a benign fibroadenoma to that of breast cancer depending on the lesion characteristics on imaging.[3]

In support of the literature, the sclerosing form (Figure 4.5) has not been commonly reported and was only seen in one of our patients. This pattern was not demonstrated in the two previous South African reviews of breast TB previously mentioned.



Figure 4.1 Tuberculous breast abscess

A, B: MLO view mammogram of the right and left breast – heterogeneously dense right and left breast tissue with right breast lesions and enlarged right axillary lymph nodes. Similar appearing smaller lesions are also noted in the left breast (correlated on ultrasound to be breast abscesses – images not shown).

C: Ultrasound demonstrates the complex collection in the right upper quadrant of the right breast.

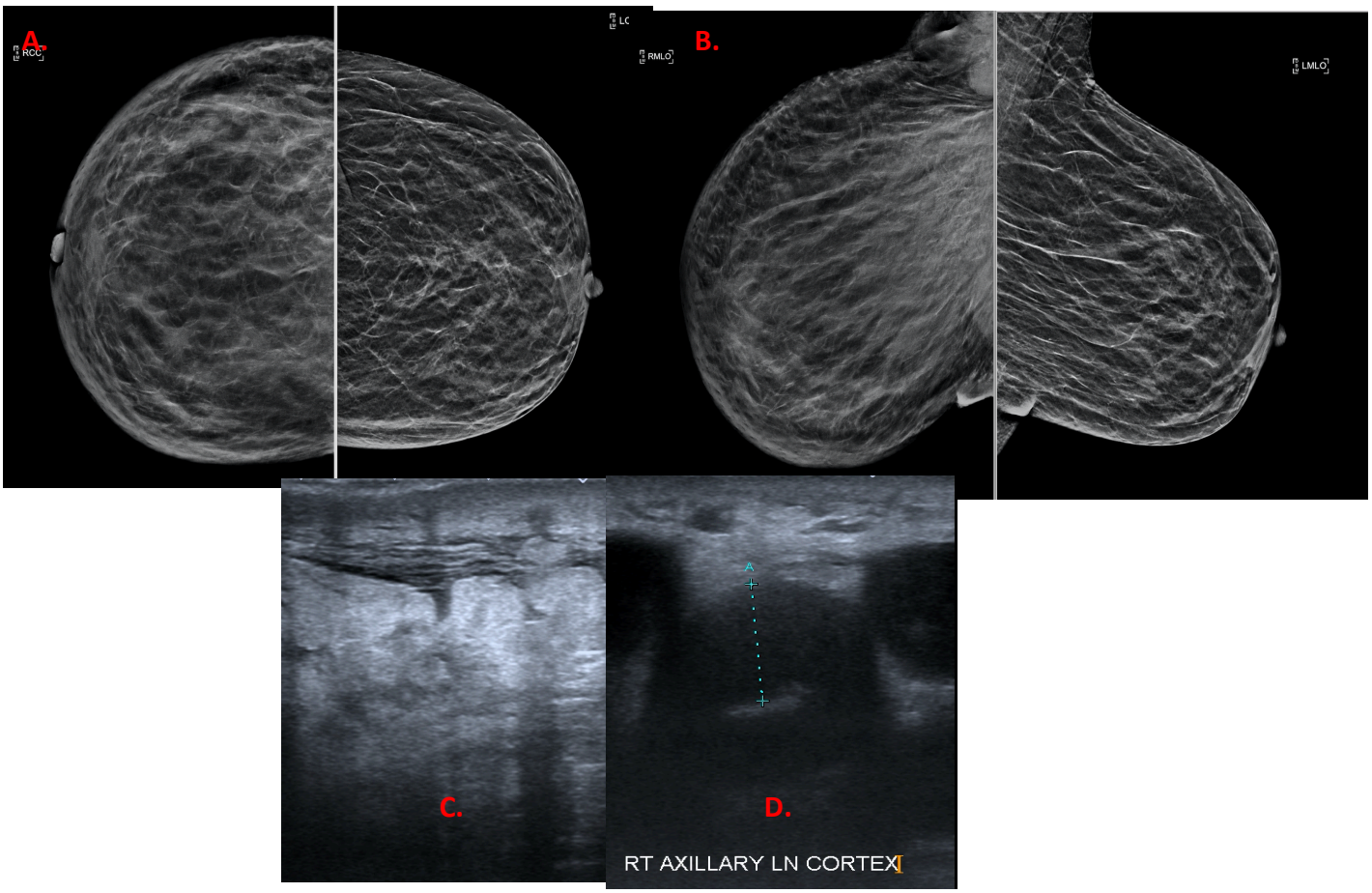

Figure 4.2 Inflammatory/disseminated form

A, B: CC and MLO view mammogram of the right and left breast. Enlarged dense right axillary nodes with a diffuse inflammatory change of the right breast - asymmetrical breast density associated with coarsened trabecular markings and diffuse skin thickening.

C, D: Ultrasound of the right breast and axilla. Oedematous breast and enlarged right axillary nodes with increased cortical thickness.

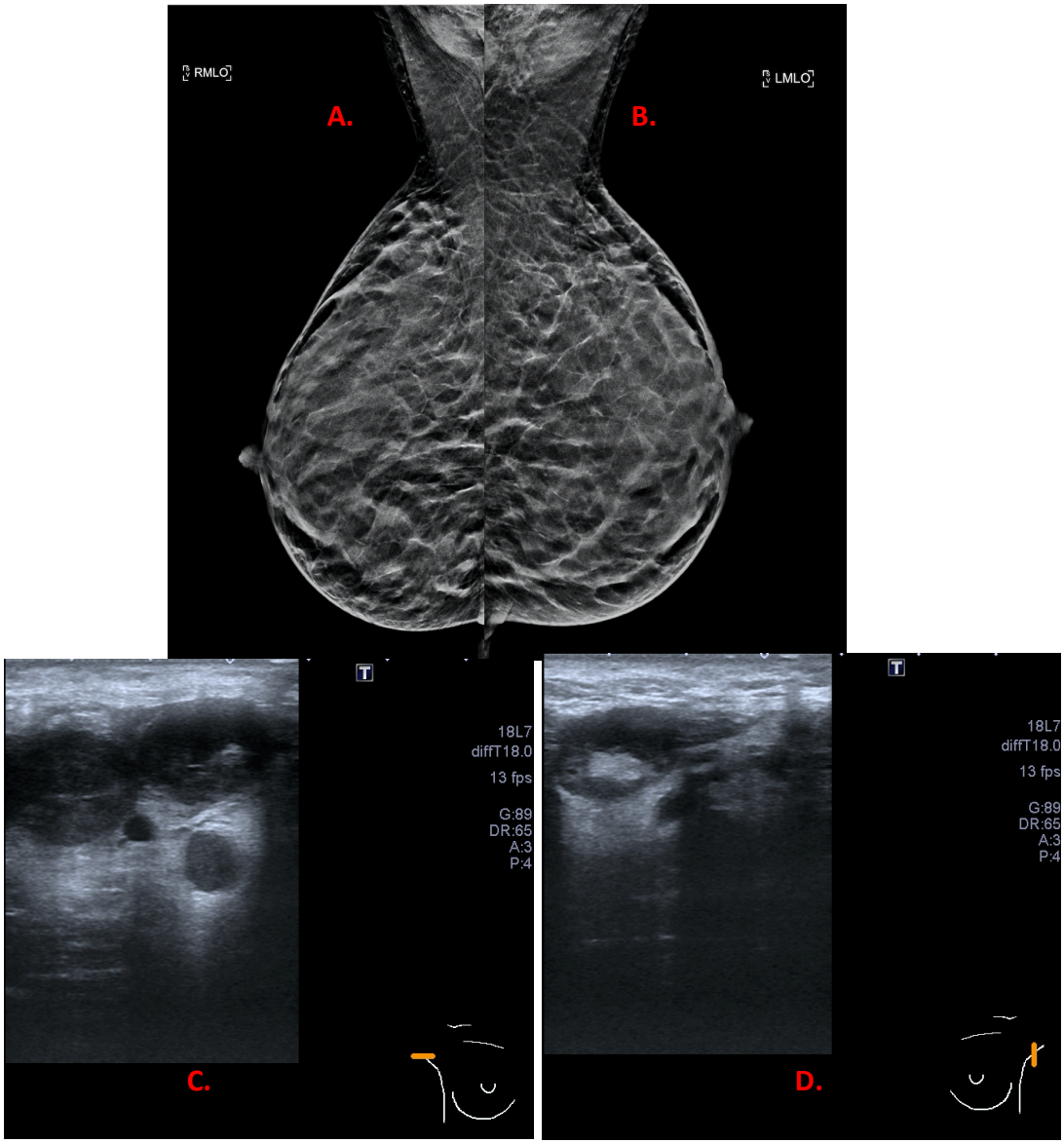

Figure 4.3 Isolated TB lymphadenitis

A, B: MLO view mammogram of the right and left breast. Heterogeneously dense right and left breast tissue with no mammographic suspicious lesions (confirmed on breast tomosynthesis – images not shown).

C, D – Ultrasound of the right and left axilla demonstrates pathological right and left axillary lymph nodes.

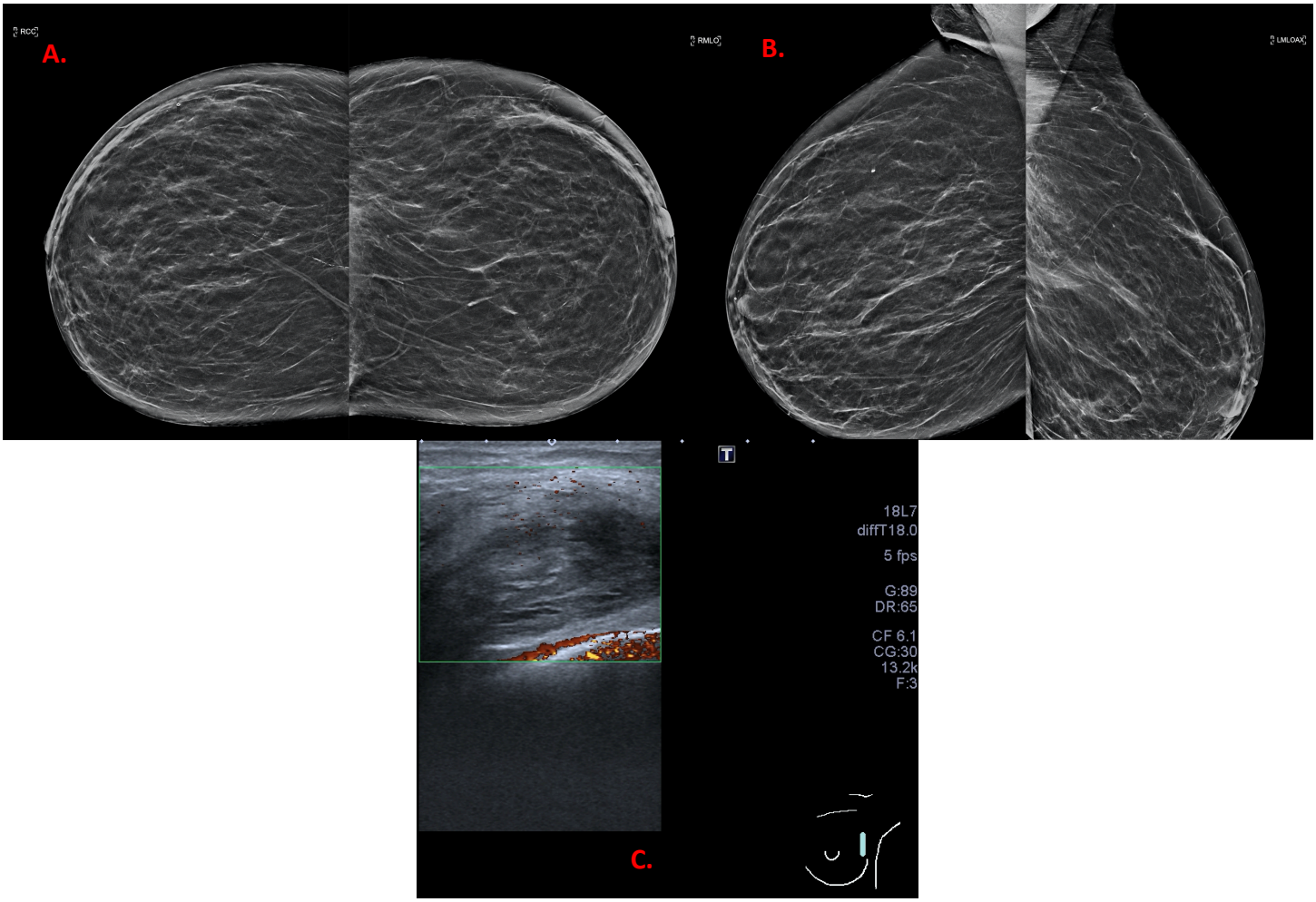

Figure 4.4 Nodular form

A, B: CC and MLO view mammogram of the right and left breast. Scattered fibroglandular tissue within the right and left breasts with a focal region of asymmetric density noted in the upper outer quadrant of the left breast posteriorly.

C – Ultrasound of the left breast confirms an underlying focal mass lesion.

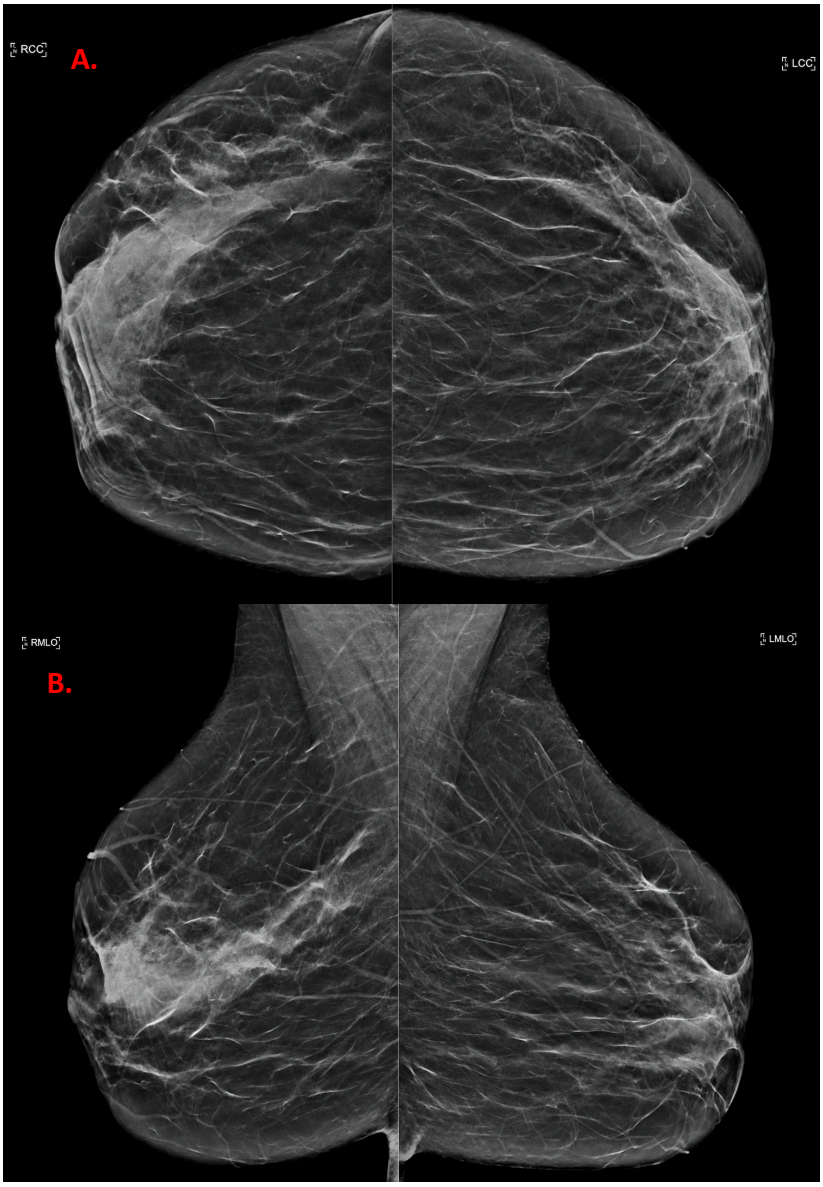

Figure 4.5 Sclerosing form

A, B: CC and MLO view mammogram of the right and left breast. Scattered fibroglandular tissue within the right and left breasts with a segmental area of asymmetric breast density associated with tethering and retraction in the right upper outer quadrant. Correlation with ultrasound failed to demonstrate an underlying mass lesion – images not shown.

4.1 Diagnosis

The sensitivity of histopathology in the diagnosis of breast TB was comparable with the study conducted by Ramaema *et al.* (2015) where the sensitivity of fine needle aspiration and cytology (FNAC) was 28% and histopathology 94%. Histological specimens demonstrated necrotizing granulomatous inflammation.

Breast TB is paucibacillary (containing few bacilli), thus diagnostic tests such as microscopy, culture, and nucleic acid amplification tests do not elicit the same diagnostic utility as it does in PTB.[1] Histology may also be representative of numerous other granulomatous mastitis.[31] This together with the non-specific clinical and radiological features poses challenges in the diagnosis of this disease entity.[1,31] The diagnosis can be made by FNAC to demonstrate AFB using Ziehl–Neelsen staining; demonstration of caseating granulomas on histological specimens; PCR testing or mycobacterial culture.[3,28]

If nipple discharge is present, this should also be screened for TB.[28]

Detection of AFB in a smear requires more than 10,000 organisms/mL; thus nucleic acid amplification tests such as PCR could be very helpful in the diagnosis of TB in smear-negative samples.[1,32]

Culture of *Mycobacterium tuberculosis* remains the gold standard for the diagnosis of breast TB, but the time required and frequent negative results (paucibacillary specimens) are significant limitations.[28] In addition, we experienced a large proportion of cases with laboratory reports stating that the culture specimen was “contaminated”; therefore, no conclusive results were available. In these patients, we were dependant on the histology results to make the diagnosis. Histology was therefore used primarily but not exclusively in making the diagnosis of breast TB as the “gold standard” was less reliable in our setting.

4.2 Results in context

Table 4.2 Comparative analysis of the literature with other case series of breast TB

	Current study	Meerkotter et al. 2011	Ramaema et al. 2015	Sakr et al. 2004	Tewari et al. 2005	Mehta et al. 2010	Hiremath et al. 2015	Beyhan et al. 2016	Longman et al. 2017
Study period	18 - months	7 years	13 years	18 months	20 years	17 years	3 years	8 years	8 years
Number of diagnosed cases of breast TB	62	21	65	10	30	63	7	7	33
Reported proportion diagnosed with breast TB from the total number of patients examined	2.46%	-----	*Accurate clinical attendance was only available for a 5 year period – prevalence for the period of 0.3%	0.2%	2.5%	1.2%	0.15%	-----	-----
Age range	Median 38.4 (IQR 33 – 45)	27 – 34 (Mean 40)	23 – 69 (Mean 38.5)	22 - 63	Most commonly occurring between the ages 20 – 40 (24 patients)	16 – 75 (Mean 32.28)	24 – 67 (average age of 38.6)	24 – 53 (Mean 34)	Mean age of 33

Continued	Current study	Meerkotter et al. 2011	Ramaema et al. 2015	Sakr et al. 2004	Tewari et al. 2005	Mehta et al. 2010	Hiremath et al. 2015	Beyhan et al. 2016	Longman et al. 2017
Most common clinical features	• Axillary nodes in 58% (n = 36)	• Palpable axillary lymph nodes (80%)	• Axillary nodes in 33.9% (n = 21)	• Axillary lymphadenopathy in 40% (n = 4)	• Axillary lymphadenopathy in 60% (n = 18)	• Associated local-regional lymphadenopathy in 42.9% (n = 27)	• Tuberculous breast abscess in 42.9% (n = 3)	Varied between mass, tenderness, pain, swelling, and abscess	• Axillary lump in 9.1% (n = 3)
	• Mastalgia in 40.3% (n = 25)			• Varied between lump, mastalgia, discharge and skin sinus					• Pain/swelling in 6.1% (n = 2)
	• Breast mass in 50% (n = 31)	• Breast mass (38%)	• Mass (nodular form) in 26.2% (n = 17) • Inflammatory mass (disseminated) in 40% (n = 26)		• Lump only in 23.3% (n = 7) • Tubercular ulcer + lump in 36.7% (n = 11) • Breast abscess in 26.7% (n = 8) • Sinus (es) + lump in 13.3% (n = 4)	• Breast lump in 73% (n = 46) • Ulcer/sinus in 20.6% (n = 13) • Nipple discharge in 6.3% (n = 4)	• Painless, mobile breast lump in 14.3% (n = 1) • Recurrent breast abscesses in 28.6% (n = 2)		• Palpable breast mass in 84.8% (n = 28)
	• Breast swelling in 29% (n = 18)	Diffuse breast swelling (52%)	• Adenitis + oedema in 24.6% (n = 16)				Diffusely enlarged, oedematous and tender breast in 14.3% (n = 1)		

Continued	Current study	Meerkotter et al. 2011	Ramaema et al. 2015	Sakr et al. 2004	Tewari et al. 2005	Mehta et al. 2010	Hiremath et al. 2015	Beyhan et al. 2016	Longman et al. 2017
Most common U/S findings	• Abscess in 40.3% (n = 25) • Oedematous breast in 32.3% (n = 20) • Enlarged axillary nodes in 85.5% (n=53) • Isolated axillary lymphadenopathy in 22.6% (n = 14) • Nodular form (breast mass) in 11.3% (n = 7)	• Enlarged axillary lymph nodes (80%) • Oedematous breast (62%) • Unilocular abscess (14%) • Nodular mass – focal (10%) • Multiple, complex, intercommunicating collections (10%)	[Ultrasound done in 41 patients] • Abscess variety in 39% (n = 16) • Oedematous breast in 26.9% (n = 11) • Mass in 26.9% (n = 11)	• Hypoechoeic mass in 60% (n = 6) • Axillary or intra-mammary lymphadenopathy in 50% (n = 5) • Abscess in 40% (n = 4) • Focal or sectorial ductal ectasia in 40% (n = 4)	-----	-----	• Abscess in 71.4 % (n = 5)	-----	• Associated enlarged axillary nodes (n = 23) • Mastitis obliterans (n = 11) [well or poorly defined cystic fluid collections mostly containing debri] • Nodular caseous form (n = 10) • Sclerosing form (n = 5) [textural change mimicking inflammatory cancer and no visible fluid] • Disseminated form (n = 4) [multiple anechoic collections with and without debri]

Continued	Current study	Meerkotter et al. 2011	Ramaema et al. 2015	Sakr et al. 2004	Tewari et al. 2005	Mehta et al. 2010	Hiremath et al. 2015	Beyhan et al. 2016	Longman et al. 2017
Most common mammogram findings	[Mammograms were done in 57 patients] • Density pattern in 64.5% (n = 40) of which 25 cases were segmental and 15 cases diffuse (all of these cases were associated with coarsened trabecular markings) Mass in 22.8% (n = 13) [correlation with ultrasound identified 9 of these cases to be breast abscesses, 2 intra-mammary nodes and only 2 as solid masses] Axillary nodes in 21.1 % (n = 12)	• Enlarged axillary nodes (70%) • Diffuse increase in density (40%) • Focal increase in density (40%) • Coarsened trabecular marking – diffuse (40%), focal (20%) • Diffuse skin thickening (40 %) • Intra-mammary mass (40%)	[Mammogram done in 33 patients] • Asymmetric breast density in 39.4% (n =13) • Inflammation in 21% (n = 7) • Nodular (focal) mass in 18.2% (n = 6) • Isolated lymphadenitis in 12.1% (n = 4)	• Mass (nodular form) in 50% (n = 5) • Axillary or intra-mammary lymphadenopathy in 40% (n = 4) • Asymmetric breast density in 30% (n = 3) • Ductal ectasia in 30% (n = 3) • Ductal ectasia in 30% (n = 3) • Calcification in 20% (n = 2) • Skin thickening in 20% (n = 2)	-----	-----	Breast mass in 42.9% (n = 3)	-----	[Mammogram only performed in 12 patients] • Isolated enlarged axillary nodes (n = 4) • Mass (nodular) (n = 3) • Skin thickening (n = 2) • Asymmetric breast density (n = 1)

4.3 Current applications

A four – limb strategy of clinical assessment, ultrasound, mammogram and core biopsy/FNA is required to make the diagnosis of breast TB.[6] As there are no clinical or radiological features that are absolutely diagnostic for breast TB, a high degree of suspicion and holistic approach is needed to assist in making the diagnosis. Ultrasound is performed in all suspected cases of breast TB and is a complementary modality to mammography in all patients in the evaluation of breast disease, irrespective of the age, and is of even greater benefit in patients with mammographically dense breasts. It assists in detecting and characterizing lymph nodes, differentiating solid from cystic lesions, detecting nodules masked by coarsened trabecular markings on mammogram and is used for percutaneous abscess drainage and biopsy.[6]

4.4 Limitations of the current study

Misclassification bias: as there are no clinical or radiological features absolutely diagnostic of breast TB, there may be potentially positive cases of breast TB with a low clinical/radiological suspicion that was subsequently not subject to FNA/biopsy and subsequently not sent for TB work-up.

This is a government hospital-based population, and the HIV infection rate and incidence of breast TB is likely to be higher; thus the population studied does not reflect the general population of south Gauteng.

Correlation with CXR for evidence of active or previous PTB was not done as the CXR's are still being printed as hard copies in some centres and not kept in the mammography department. Due to limitations in trying to access these films in some of these patients,

the decision was made prior to the development of the protocol for this study to not include this in our data collection and this was not part of our study objectives.

4.5. Future applications

Considering that breast abscess was the most common ultrasound finding in this study, samples need to be obtained specifically for TB analysis in all cases of non-lactational breast abscess, even in the absence of a history of TB elsewhere.[3] Although it is true that not all breast abscesses are secondary to TB infection, the presence of non-resolving breast abscesses to anti-microbial therapy should prompt the inclusion of breast TB in the differential diagnosis with samples sent specifically for TB analysis.

Currently, MRI of the breast is not commonly used in cases of suspected breast TB.[6] Breast TB may mimic the appearance of cancer and ultrasound and mammogram findings alone may not be sufficient to differentiate between these two entities.[30] In a study conducted by Ramaema et al. (2018), they described the use of multi-parametric MRI in differentiating breast TB from cancer.[30] They concluded that the combination of dynamic contrast-enhanced MRI (DCE-MRI) morphological enhancement pattern, T2 signal intensity, quantitative diffusion weighted imaging (DWI) and apparent diffusion coefficient (ADC) values may offer a non-invasive tool in differentiating these two disease processes.[30]

Breast TB needs to be differentiated from other granulomatous conditions.[22] Longman et al. proposed an algorithm for the work-up of granulomatous breast disease (Figure 4.6).



Figure 4.6 Proposed algorithm for granulomatous breast disease

Source: Longman et al.[22]

Legends:

c-ANCA (Cytoplasmic Antineutrophil Cytoplasmic Antibodies)

ACE (Angiotensin Converting Enzyme)

ZN (Ziehl-Neelsen)

MPO (Anti-myeloperoxidase)

PR3 (Anti-proteinase 3)

5. Conclusion

Breast TB is a rare entity and is even uncommon in countries where the incidence of pulmonary and EPTB is high. Breast TB remains a great mimicker and it should be considered in the differential diagnosis of women presenting with breast disease in TB endemic countries, especially if immune-compromised.

Breast TB poses a diagnostic problem as there are often no clinical or radiological features that are specific for the diagnosis and the paucibacillary nature of this disease means that the routine diagnostic tests do not offer the same diagnostic utility as they do in PTB.

Ultrasound-guided core biopsy rather than FNA is advocated as the first-line intervention in diagnosing or excluding this disease, as it yields a better tissue sample and more often a positive diagnosis.

This research aimed to demonstrate the varied clinical and radiological features of breast TB so that clinicians and radiologists may have a high degree of suspicion to prevent misdiagnoses and inappropriate management.

6. References

1. Thimmappa D, Mallikarjuna MN, Vijayakumar A. Breast Tuberculosis. Indian J Surg. 2015;77(3);1378–1384.
2. Bhat GA, Gunasekaran V, Lal P, Khurana N. Tuberculosis breast and its coexistence with carcinoma breast: A retrospective analysis at a tertiary care hospital in India. Breast J. 2017;00:1–2.
3. Ramaema DP, Buccimazza I, Hift RJ. Prevalence of breast tuberculosis: Retrospective analysis of 65 patients attending a tertiary hospital in Durban, South Africa. S Afr Med J. 2015;105(10):866–869.
4. Mehta G, Mittal A, Verma S. Breast Tuberculosis - Clinical spectrum and management. Indian J Surg. 2010;72(6):433–437.
5. Chikkannaiah P, Vani BR, Benachinmardi K, Murthy VS. Axillary lymph node tuberculosis masquerading as inflammatory breast carcinoma in an immune-compromised patient. International Journal of STD & AIDS. 2016;27(2):149–151.
6. Meerkotter D, Spiegel K, Page-Shipp LS. Imaging of tuberculosis of the breast: 21 cases and a review of the literature. J Med Imaging Radiat Oncol. 2011;55(5):453–460.
7. Karstaedt AS. Extrapulmonary tuberculosis among adults: Experience at Chris Hani Baragwanath Academic Hospital, Johannesburg, South Africa. SAMJ. 2014;104(1):22–24.
8. Hoogendoorn JC, Ranoto L, Muditambi N, Railton J, Maswanganyi M, Struthers HE, et al. Reduction in extrapulmonary tuberculosis in context of antiretroviral therapy scale-up in rural South Africa. Epidemiol. Infect. 2017;145:2500–2509.
9. Glaziou P, Sismanidis C, Floyd K, Raviglione M. Global epidemiology of tuberculosis.

Cold Spring Harb Perspect Med. 2015;5:1-17.

10. Narasimhan P, Wood J, Macintyre CR, Mathai D. Risk factors for tuberculosis. Pulmonary Medicine. 2013;2013:1–11.

11. Osei E, Der J, Owusu R, Kofie P, Axame WK. The burden of HIV on tuberculosis patients in the Volta region of Ghana from 2012 to 2015: implication for tuberculosis control. BMC Infect Dis. 2017;17(504):1–9.

12. Global Tuberculosis Control 2016, WHO, Geneva, 2016, www.who.int/tb/en

13. Lee JY. Diagnosis and treatment of extrapulmonary tuberculosis. Tuberc Respir Dis. 2015;78:47-–55.

14. Naing C, Mak JW, Maung M, Wong SF, Kassim AI. Meta-Analysis: the association between HIV infection and extrapulmonary tuberculosis. Lung. 2013;191(1):27–34.

15. Jaryal A, Raina R, Sarkar M, Sharma A. Manifestations of tuberculosis in HIV/AIDS patients and its relationship with CD4 count. Lung India. 2011;28(4):263–266.

16. Gupta RK, Lawn SD, Bekker L, Caldwell J, Kaplan R, Wood R. Impact of human immunodeficiency virus and CD4 count on tuberculosis diagnosis: analysis of city-wide data from Cape Town, South Africa. Int J Tuberc Lung Dis. 2013;17(8):1014–1022.

17. Chowdri NA, Parray FQ, Dar RA, Malik AA, Mushtaque M, Malik RA. Tubercular mastitis - A rare presentation. Int J Surg. 2010;8:398–400.

18. Baharoon S. Tuberculosis of the breast. Ann Thorac Med. 2008;3(3):110–114.

19. Kumar M, Chand G, Nag VL, Maurya AK, Rao RN, Agarwal S, et al. Breast tuberculosis in immunocompetent patients at tertiary care center: A case series. J Res Med Sci. 2012;17(2):199–202.

20. Jah A, Mulla R, Lawrence FD, Pittam M, Ravichandran D. Tuberculosis of the breast:

experience of a UK breast clinic serving an ethnically diverse population. Ann R Coll Surg Engl. 2004;86:416–419.

21. McKeown KC, Wilkinson KW. Tuberculous disease of the breast. The British Journal of Surgery. 1949;1936:420–429.

22. Longman CF, Campion T, Butler B, Suaris TD, Khanam A, Kunst H, et al. Imaging features and diagnosis of tuberculosis of the breast. Clincal Radiology. 2017;72:217–222.

23. Cakar B, Ciledag A. Retrospective analysis of seven breast tuberculosis cases. Exp Ther Med. 2016;12(7):3053–3057.

24. Marinopoulos S, Lourantou D, Gatzionis T, Dimitrakakis C, Papaspyrou I, Antsaklis A. Breast tuberculosis: Diagnosis, management and treatment. Int J Surg Case Rep. 2012;3:548–550.

25. Hiremath BV, Subramaniam N. Primary breast tuberculosis: Diagnostic and therapeutic dilemmas. Breast Dis. 2015;35:187–193.

26. Sakr AA, Fawzy RK, Fadaly G, Baky MA. Mammographic and sonographic features of tuberculous mastitis. Eur J Radiol. 2004;51:54–60.

27. Tewari M, Shukla HS. Breast tuberculosis: diagnosis, clinical features and management. Indian J Med Res. 2005;122(2):103–110.

28. Sinha RTK, Dey A, Agarwal S. Tuberculous mastitis diagnosed on cytology - case report of a rare entity. J Cytology. 2017;34(3):162–164.

29. National Tuberculosis Management Guidelines 2014. ISBN: 9781920031824.

30. Ramaema DP, Hift RJ. Differentiation of breast tuberculosis and breast cancer using diffusion-weighted , T2-weighted and dynamic contrast-enhanced magnetic resonance imaging. S Afr J Rad. 2018;22(2),a1377.

31. Sriram KB, Moffatt D, Stapledon R. Tuberculosis infection of the breast mistaken for granulomatous mastitis: a case report. Cases J. 2008;1(1):273–276.

32. Bhatty O, Waters D, Wilka N, Samuel S, Horne J, Vivekanandan R. A rare manifestation of tuberculosis presenting in the United States. Case Report in Infectious Diseases. 2016;2016:1–4.

Appendix A: Ethics Clearance Certificate

UNIVERSITY OF THE WITWATERSRAND JOHANNESBURG

R14/49 Dr D Mathew

HUMAN RESEARCH ETHICS COMMITTEE (MEDICAL)
CLEARANCE CERTIFICATE NO. M180830

NAME: (Principal Investigator)	Dr D Mathew
DEPARTMENT:	School of Clinical Medicine Department of Radiation Sciences Medical School University
PROJECT TITLE:	Breast Tuberculosis: A retrospective analysis of the disease burden among three tertiary hospitals in Johannesburg
DATE CONSIDERED:	31/08/2018
DECISION:	Approved unconditionally
CONDITIONS:	
SUPERVISOR:	Drs S Rayne and G Rubin
APPROVED BY:	Dr CB Penny, Chairperson, HREC (Medical)
DATE OF APPROVAL:	29/10/2018

This clearance certificate is valid for 5 years from date of approval. Extension may be applied for.

DECLARATION OF INVESTIGATORS

To be completed in duplicate and **ONE COPY** returned to the Research Office Secretary on 3rd floor, Phillip V Tobias Building, Parktown, University of the Witwatersrand, Johannesburg.

I/We fully understand the conditions under which I am/we are authorised to carry out the above-mentioned research and I/we undertake to ensure compliance with these conditions. Should any departure be contemplated from the research protocol as approved, I/we undertake to resubmit to the Committee. **I agree to submit a yearly progress report**. When a funder requires annual re-certification, the application date will be one year after the date of the meeting when the study was initially reviewed. In this case, the study was initially reviewed in **August** and will therefore reports and re-certification will be due early in the month of **August** each year. Unreported changes to the application may invalidate the clearance given by the HREC (Medical).

Principal Investigator Signature

03/11/18
Date

PLEASE QUOTE THE PROTOCOL NUMBER IN ALL ENQUIRIES