

https://dspace.org/

The behaviour and morphology of human oesophageal carcinoma cells in vivo and in vitro and a comparison with the normal.

Robinson, Kathleen Mary

2015
http://hdl.handle.net/10539/19215

Downloaded from a DSpace repository. https://dspace.org/

[illegible] PARISON [illegible] NORMAL

Kathleen Mary Robinson

A Thesis submitted to the Faculty of Science

University of the Witwatersrand, Johannesburg

for the degree of Doctor of Philosophy

Durban 1981

ABSTRACT

Carcinoma of the oesophagus is a major cause of death in the Black population of South Africa. To date, the condition is incompletely understood and no successful cure has been found. This investigation was performed to obtain as much information as possible from a laboratory investigation of oesophageal carcinoma.

The aims of this study were to establish _in vivo_ and _in vitro_ systems in which oesophageal carcinoma cells could be grown and compared with normal oesophageal cells and to fully characterise normal and malignant oesophageal cells in these systems and in the human host.

Resected tumour specimens and biopsies of normal and malignant oesophageal mucosa were cultured and classified according to their growth rate, pattern and potential _in vitro_. Ultrastructural studies (using both transmission and scanning electron microscopy) were performed on normal and malignant oesophageal cells _in vivo_ and _in vitro_. Cells from continuous oesophageal carcinoma cell lines were inoculated into nude mice and the resulting tumours and cell lines studied both _in vivo_ and _in vitro_ and compared with human tumours and cell lines

Tissue culture provided a useful technique for tumour investigation and for the continuous production of human oesophageal carcinoma cells. Ten continuous oesophageal carcinoma cell lines were established and a strong correlation between ability of malignant cells to grow for lengthy periods _in vitro_ and their tendency to invade and metastasize _in vivo_ noted. _In vitro_, cells in biopsy specimens resembled those from resected tumour specimens. Normal oesophageal mucosal cells did not form continuous cell lines and differed in growth rate and pattern from the carcinoma cells.

Normal and malignant oesophageal cells were ultrastructurally characterised and several ultrastructural differences noted between normal and malignant cells and between cells _in vivo_ and those _in vitro_. Intracytoplasmic desmosomes, abundant tono-

filaments, unidentified intranuclear and cytoplasmic particles and other unusual organelles were observed in some malignant cells while normal cells contained unremarkable organelles and were more uniform in morphology. Malignant cells displayed fewer and less regular surface projections than normal oesophageal cells *in vivo*, but were covered with abundant microvilli and lateral processes *in vitro* while cultured normal mucosal cells displayed few surface projections.

Eight of the nine continuous human oesophageal carcinoma cell lines tested produced carcinomas in nude mice. Different "take" rates and latency periods were recorded for each line and the carcinomas induced by the same and different lines varied in differentiation and infiltration of surrounding tissues. Although all lines were derived from metastasizing human tumours, metastasis was only noted in a single animal. When carcinomas of the nude mouse were cultured the resulting cell lines displayed similarities to the human cell lines which had been inoculated.

Thus, valid *in vivo* (nude mouse) and *in vitro* model systems for further studies on oesophageal carcinoma were established and normal and malignant oesophageal cells were ultrastructurally characterised.

DECLARATION

I declare that this thesis is my own, unaided work, except for some technical assistance as stated in the Preface. It is being submitted for the degree of Doctor of Philosophy in the University of the Witwatersrand, Johannesburg. It has not been submitted before for any degree or examination in any other University.

K Robinson

18th day of May, 1988.

PREFACE

The incidence of carcinoma of the oesophagus is high in certain population groups in South Africa. Increasing numbers of patients with this tumour, which is generally fatal, are seen annually in Durban. Since the disease cannot be fully investigated in the patient a model system for experimental work is needed. The aim of this study was to establish an *in vitro* system for studying and characterising normal and malignant oesophageal cells, to look for information of clinical importance and to increase the available knowledge concerning oesophageal carcinoma cells.

This study was carried out in the Department of Physiology of the University of Natal, Durban, and was funded largely by the National Cancer Association of South Africa to whom I am deeply indebted. I also owe much to Professor J.V.O. Reid for his enthusiam and interest in my work as well as his continuous encouragement.

I am grateful to my supervisors - Dr. C. Wallace of the Anatomy Department of the University of the Witwatersrand and Dr. J.J. Alexander of the National Institute for Virology. I thank Dr. Wallace for his comments and criticisms during the writing of this manuscript and Dr. Alexander for her helpful suggestions and encouragement both during the experimental work, and particularly while this manuscript was in preparation.

Without the aid of Professor I.B. Angorn and Mr. A.A. Haffejee of the Department of Surgery of the University of Natal, Durban, my work would not have been possible. Professor Angorn and Mr. Haffejee supplied me with all resected and biopsied specimens and information about the clinical staging and prognosis of the disease. They were extremely helpful and co-operative and displayed interest in my work at all times.

Acknowledgement and thanks are also due to Mr. M.A. Gregory of the Department of Physiology of the University of Natal, Durban, and

Mr. P. Evers of the Department of Physics of the same institution for their practical advice about specimen preparative procedures for transmission and scanning electron microscopy, respectively. I am also grateful to Mrs. S. Bux whose help in specimen processing and cutting and staining of thin sections for electron microscopy proved invaluable.

A special thank you to Miss L. Maistry who has worked with me for over two years and aided in much of the routine maintenance of cell cultures and specimen preparation for scanning electron microscopy. She has been a source of friendship and enthusiasm and I appreciate her help. In this respect I also thank Dr. K. Kasvalu for his willingness to help with the feeding of cell cultures.

I am grateful to Mr. S. Naidoo, Physiology Department, for his help with the construction and maintenance of the SPF-4 nude mouse colony and for autoclaving vast amounts of glassware which were washed by Mr. J. Vika.

I thank Dr. G. Blake for his help and advice concerning the Cluster Analysis and am indebted to the staff of the Medical Illustration Unit of the University of Natal, Durban, for photographs of the nude mice and help with some of the other illustrations.

I acknowledge the help and co-operation of Mr. S. Supersadh of the Research Institute for Diseases in a Tropical Environment and am grateful to him for the facilities made available to me for the filtration of medium.

I also extend sincere thanks to Mrs. J. Duursma of the Natal Institute for Immunology, who encouraged me during the initial problem period in establishing a tissue culture laboratory and who so readily loaned me equipment and media.

I am extremely grateful to Mr. G.H. Haffejee and staff of the Medical School Library for obtaining publications and checking references.

I wish also to thank my friends for their interest in this thesis, and finally, my mother who made it all possible and who has spent many painstaking hours typing and retyping this manuscript. I cannot thank her enough.

Material from many chapters of this thesis has already been published, or has been accepted for publication in the following:

Journal of Clinical Oncology 2, 125 - 136, 1980. Robinson, K.M., Maistry, L.A. and Angorn, I.B. Tissue culture and prognosis in carcinoma of the oesophagus.

Scanning Electron Microscopy / 1980 / II, 231 - 238. Robinson, K.M., Maistry, L., Evers, P. and Bux, S. Morphology of an esophageal carcinoma cell line before and after transplantation into nude mice.

Journal of Microscopy 120, 225 - 229, 1980. Evers, P., Robinson, K.M., Maistry, L. and Higginson, E. Description of a coverslip holder for, and observations on the critical point drying of cell cultures.

Carcinoma of the Esophagus - an international review (ed. C. Pfeiffer), Boca Raton: CRC Press. 1981 (in press). Rabin, H., Gonda, M.A., Benton, C.V. and Robinson, K.M. Cell culture studies of simian and human esophageal carcinomas.

Carcinoma of the Esophagus - an international review (ed. C. Pfeiffer), Boca Raton: CRC Press. 1981 (in press). Robinson, K.M. and Maistry, L. Scanning and transmission electron microscopy of continuous human esophageal carcinoma cell lines.

Journal of Pathology 1[illegible]1 (in press). Robinson, K.M. and Gregory, M.A. Transmission electron microscopy of human oesophageal carcinomas.

Scanning Electron Microscopy / 1981 / (in press). Robinson, K.M., Maistry, L. and Evers, P. Surface

features of normal and neoplastic human oligodyssal cells in vitro and in vivo.

Some of the results of the ultrastructural studies involving both transmission and scanning electron microscopy have been presented at the 16th, 17th, 18th and 19th Conferences of the Electron Microscopy Society of Southern Africa and have been published in abstract form in the several volumes of the Proceedings of this Society.

CONTENTS

PRELIMINARIES

TITLE i

ABSTRACT ii

DECLARATION iv

DEDICATION v

PREFACE vi

CONTENTS x

LIST OF TABLES xiv

LIST OF FIGURES xxii

		Page
[illegible]	... ...	1
[illegible]	ISEASE	1
[illegible]	[illegible]	1
[illegible]	Sex ratio	3
[illegible]	Aetiology	3
1. [illegible]	[illegible]	4
1. [illegible]	Tobacco	5
1. [illegible]	Alcohol	6
1. [illegible]	Dietary pattern	5
1. [illegible]	Genetic predisposition	7
1. [illegible]	Local oesophageal conditions ...	8
1. [illegible]	Oncogenic viruses	8
[illegible]	Summary	9
[illegible]	INTRODUCTION	10
[illegible]	THE THESIS	10
2. 1	Normal and malignant oesophagus *in vivo*	11
[illegible]	[illegible] and importance of an *in vitro* system	12
2. 2. 1	Culture of normal and malignant oesophageal cells	12
2. 3	Continuous oesophageal carcinoma cell lines	14
[illegible]	Correlation between *in vivo* and *in vitro* behaviour	15
2. 4. 1	Tissue culture and prognosis ...	15
2. 5	Correlation between biopsies and resected specimens	16
2. 6	Ultrastructural characterisation of cells *in vivo* and *in vitro*	17
2. 7	Possible association of a virus with human oesophageal carcinomas	18
2. 8	Human oesophageal carcinomas in athymic nude mice	19
2. 8. 1	Relationship between nude mouse tumours and those in the human host	20
2. 9	Summary	20
	MATERIALS AND METHODS	23
	TISSUE CULTURE MATERIALS	23
3. 1	Introduction	23
3. 2	Environment	23
3. 3	Apparatus	23
3. 4	Media	24
3. 4. 1	Minimum essential medium	24
3. 4. 2	Foetal calf serum	25

		Page
	... ...	25
	... ...	26
	... ...	34
	... ...	34
	... ...	38
	... ...	38
	... ...	38
	... ...	39
	... ...	[illegible]
	...ferential trypsinisation ...	41
	...anical scraping	42
	...cle removal during subcul-	42
	... ...	43
	...ells	45
	Cell counting	45
4.	Cells grown on coverslips and chamber slides	45
	Freezing of cells	46
	Treatment of contaminated cultures	46
	MATERIALS AND METHODS	47
	THE MAINTENANCE AND USE OF NUDE (ATHYMIC) MICE ...	47
5. 1	Mice used for this study	47
5. 2	SPF - 4 environment	47
5. 3	Animal maintenance	48
5. 4	Breeding	49
5. 5	Induction of tumours	51
5. 6	Tumour removal	51
5. 7	Tissue culture of tumours grown in nude mice	53
	MATERIALS AND METHODS	54
	PREPARATION OF CELLS FOR MICROSCOPY	54
6. 1	Light microscopy	54
6. 1. 1	In vivo specimens	54
6. 1. 2	Cultured cells	54
6. 2	Transmission electron microscopy	55
6. 2. 1	In vivo specimens	56
6. 2. 2	Cultured cells	56
6. 2. 2. 1	Cells removed from flasks and pelleted	56
6. 2. 2. 2	Cells growing in plastic flasks ...	56

Page

6. 3 Scanning electron microscopy ... ...

6. 3. 1 [illegible] specimens 57
6. 3. 2 Cultured cells 58

RESULTS 59

GROWTH AND BEHAVIOUR OF APPARENTLY NORMAL OESOPHAGEAL CELLS IN VITRO 59

7. 1 [illegible] 59
7. 2 Subculturing 60

RESULTS 63

IN VITRO PROPERTIES OF RESECTED OESOPHAGEAL CARCINOMA SPECIMENS 63

8. 1 Classification of resected tumour specimens 63

8. 1. 1 Category I 64
8. 1. 2 Category IIA 65
8. 1. 3 Category IIB 68
8. 1. 4 Category III 69
8. 1. 5 Category IV 75
8. 1. 6 Miscellaneous specimens 82

RESULTS 86

IN VITRO PROPERTIES OF OESOPHAGEAL CARCINOMA BIOPSY SPECIMENS 86

9. 1 Classification of biopsy specimens 86

9. 1. 1 Category I 87
9. 1. 2 Category IIA 88
9. 1. 3 Category IIB 89
9. 1 Category III 91
9. 1. 4 Category IV 92

10 DISCUSSION 96

COMPARISON OF TISSUE CULTURE DATA AND CORRELATION OF IN VIVO WITH IN VITRO features 96

10. 1 Summary of available data 96
10. 2 Cluster analysis 98
10. 3 Similarities between oesophageal carcinoma specimens 101
10. 3. 1 Resected tumour specimens ... 101
10. 3. 2 Biopsy specimens 101

10. 4 Similarities between some clinical and in vitro features of oesophageal carcinoma specimens 103

10. 4. 1 Resected tumour specimens ... 103
10. 4. 2 Biopsy specimens 106

			Page
	10. 6	Comparison of resected and biops, specimens	107
	[illegible]	[illegible] ...	109
	10. 7	Tissue culture and operative staging .	109
		[illegible] ...	109
		10. 7. 2 Biopsy specimens	111
	10. [illegible]	Tissue culture and clinical prognosis	113
		[illegible] ...	113
		10. [illegible] Biopsy specimens ...	115
	10. 9	Summary	115
11	DISCUSSION		116
	NORMAL AND MALIGNANT OESOPHAGEAL CELLS *IN VITRO*		116
	11. 1	Oesophageal carcinoma cell lines	116
	11. 2	Correlation between *in vivo* and *in vitro* features of oesophageal carcinoma specimens	119
		11. 2. 1 Tumour invasion and metastasis	119
		11. 2. 2 Tumour differentiation ...	120
		11. 2. 3 Lymphocyte infiltration ...	120
		11. 2. 4 Fibroblasts and tumour necrosis	121
		11. 2. [illegible] Giant cells	121
		11. 2. [illegible] Patients	122
	11. 3	Requirements of oesophageal cells for growth *in vitro*	122
	11. 4	Effects of tissue culture on cellular morphology and behaviour	123
	11. 5	Comparison of cultured normal and malignant oesophageal cells	124
	11. 6	Summary	125
12	RESULTS		126
	MORPHOLOGY OF NORMAL OESOPHAGEAL MUCOSA *IN VIVO*		126
	12. 1	Light microscopy	126
	12. 2	Transmission electron microscopy ...	127
	12. 3	Scanning electron microscopy	130
13	RESULTS		136
	MORPHOLOGY OF OESOPHAGEAL CARCINOMA SPECIMENS *IN VIVO*		136
	13. 1	Light microscopy	136
	13. 2	Transmission electron microscopy ...	137

			Page
		13. 2. 1 Nuclear features	137
		13. 2. 2 Desmosomes	137
		13. 2. 3 Tonofilaments	139
		13. 2. 4 Other cytoplasmic filaments ...	140
		13. 2. 5 Myelinoid figures and cytoplasmic bodies	142
		13. 2. 6 Other cytoplasmic organelles ..	147
	13. 3	Scanning electron microscopy	148
14	RESULTS		150
	MORPHOLOGICAL FEATURES OF CULTURED NORMAL HUMAN OESOPHAGEAL MUCOSAL CELLS		150
	14. 1	Light microscopy	150
	14. 2	Transmission electron microscopy	151
	14. 3	Scanning electron microscopy	152
15	RESULTS		156
	MORPHOLOGICAL FEATURES OF CULTURED HUMAN OESOPHAGEAL CARCINOMA CELLS		156
	15. 1	Light microscopy	156
	15. 2	Transmission electron microscopy	157
		15. 2. 1 Primary cultures	157
		15. 2. 2 Continuously growing oesophageal carcinoma cell lines ...	160
		15. 2. 2. 1 Stratification ..	161
		15. 2. 2. 2 Tonofilaments ...	161
		15. 2. 2. 3 Desmosomes ...	164
		15. 2. 2. 4 Nuclear features	165
		15. 2. 2. 5 Myelinoid bodies	170
		15. 2. 2. 6 Cytoplasmic rods and filaments ...	170
		15. 2. 2. 7 Other cytoplasmic organelles ...	171
	15. 3	Scanning electron microscopy	178
		15. 3. 1 Microvilli	179
		15. 3. 2 Lateral processes	179
		15. 3. 3 Other surface features	183
		15. 3. 4 Giant cells	183
	15. 4	Summary	183
16	DISCUSSION		185
	ULTRASTRUCTURE OF NORMAL AND MALIGNANT OESOPHAGEAL CELLS IN VIVO AND IN VITRO		185
	16. 1	A comparison of the ultrastructural features of normal and malignant oesophageal cells in vivo with those of corresponding cells in vitro	185

		Page
16. 1. 1	Normal oesophageal cells *in vivo* and *in vitro*	185
16. 1. 2	Malignant oesophageal cells *in vivo* and *in vitro*	187
16. 1. 2. 1	Pelleted cells ..	189
16. 1. 2. 2	Oesophageal carcinoma cells in flasks and on coverslips ...	190
16. 2	A comparison of some ultrastructural features of normal and malignant oesophageal cells	190
16. 2. 1	Stratification	191
16. 2. 2	Keratinisation	192
16. 2. 3	Desmosomes	193
16. 2. 4	Microplicae and intercellular ridges	194
16. 2. 5	Microvilli	196
16. 2. 6	Nuclear features	197
16. 2. 6. 1	Intranuclear particles	197
16. 2. 7	Cytoplasmic particles and granules	199
16. 2. 8	Annulate lamellae	199
16. 2. 9	Endoplasmic reticulum	200
16. 2.10	Cytoplasmic bodies	201
16. 2.11	Glycogen and lipid	201
16. 2.12	Mitochondria	202
16. 2.13	Golgi apparatus	202
16. 2.14	Microfilaments	203
16. 2.15	Associated micro-organisms ...	203
16. 3	Summary	204
17	RESULTS	207
	SOME PROPERTIES OF EXPERIMENTALLY INDUCED HUMAN OESOPHAGEAL CARCINOMAS IN THE NUDE MOUSE	207
17. 1	Tumour "take" rates	207
17. 2	Latency period before appearance of tumours	208
17. 3	Sex differences	210
17. 4	Tumour behaviour	210
17. 4. 1	Bilateral tumours	216
17. 5	Metastasis	217
17. 6	Tumour re[illegible]	218
17. 7	Tumour recurrence	220
17. 8	Histopathology of carcinomas in the nude mouse	220

			Page
	17. . 1	Hist pathological studies on a metastatic tumour	222
	17. 2	Tissue culture of tumours grown in the nude mouse	222
18	RESULTS		225
	ULTRASTRUCTURE OF HUMAN OESOPHAGEAL CARCINOMAS INDUCED IN NUDE MICE		225
	18. 1	Transmission electron microscopy	225
		18. 1. 1 Ultrastructural features indicative of tumour differentiation	225
		18. 1. 2 Intranuclear particles	236
		18. 1. 3 Cytoplasmic particles	239
		18. 1. 4 Other cytoplasmic organelles ...	240
		18. 1. 5 Invasive tumours	243
	18. 2	Scanning electron microscopy	245
		18. 2. 1 Nude mouse tumours in vivo ...	245
		18. 2. 2 Nude mouse tumour cells in vitro	246
19	DISCUSSION		251
	BEHAVIOUR AND MORPHOLOGY OF CELLS DERIVED FROM HUMAN OESOPHAGEAL CARCINOMAS IN NUDE MICE		251
	19. 1	Tumour "take" rates in athymic nude mice .	251
		19. 1. 1 Bilateral inoculation	254
	19. 2	Latency periods	254
	19. 3	Sex differences	255
	19. 4	Tumour infiltration into surrounding tissues	255
	19. 5	Metastasis	257
	19. 6	Tumour recurrence	
	19. 7	Differentiation of oesophageal carcinomas induced in nude mice	258
	19. 8	Intranuclear particles	259
	19. 9	Surface differences in cells of line Hcu 13 before and after passage through the nude mouse	260
	19.10	Summary	261
20	GENERAL DISCUSSION AND CONCLUSIONS		262
	MAJOR RESULTS AND THEIR RELEVANCE		262
	20. 1	Distinction between normal and malignant oesophageal cells	262

		Page
20. 1. 1	Significance of morphological and behavioural differences between normal and malignant oesophageal cells	263
20. 2	Establishment of ten continuous human oesophageal carcinoma cell lines	264
20. 2. 1	Significance of human oesophageal carcinoma cell lines	264
20. 3	Some *in vitro* features correlate with *in vivo* behaviour	264
20. 3. 1	Growth *in vitro* and clinical prognosis	265
20. 4	Biopsy specimens *in vitro* are representative of their tumours of origin *in vivo*	266
20. 4. 1	Clinical significance	266
20. 5	Normal and malignant cells undergo alterations during adaptation to *in vitro* conditions	266
20. 6	Continuous human oesophageal carcinoma cell lines are tumorigenic in nude mice	267
20. 7	All oesophageal carcinomas induced in nude mice by the inoculation of cells of continuous human oesophageal carcinoma cell lines resemble one another	267
20. 8	Carcinomas induced in nude mice show many similarities to their human tumours of origin	268
20. 9	Oesophageal carcinomas grown in nude mice can be successfully cultured	268
20.10	The presence of intranuclear and cytoplasmic particles in some oesophageal carcinoma cells suggests the possibility of viral involvement with carcinoma of the oesophagus	269
20.11	Summary of contributions to existing knowledge	269
REFERENCES	... ...	270
APPENDIX	... ...	299
	Program for Cluster Analysis	

LIST OF TABLES

		Page
Table 1	Some clinical information about the patients with squamous oesophageal tumours from which the specimens used in this study were obtained	27
Table 2	Some clinical information about the patients with suspected oesophageal tumours from which the oesophageal biopsy specimens used in this study were obtained	31
Table 3	Ages and sexes of the patients from whom specimens of apparently normal oesophagus were obtained during operative resections for carcinoma of the oesophagus	33
Table 4	Ages and sexes of the patients from whom the specimens diagnosed as adenocarcinoma and dysplasia were obtained.	34
Table 5	Results of the tissue culture of resected tumour specimens	64
Table 6	Category I Resected specimens - histopathology and patient survival	65
Table 7	Category IIA Resected specimens - histopathology and patient survival	66
Table 8	Category IIB Resected specimens - histopathology and patient survival	69
Table 9	Category III Resected specimens - histopathology and patient survival	70
Table 10	Some *in vitro* features of category III specimens	71
Table 11	Category IV Resected specimens - histopathology and patient survival	76
Table 12	Some *in vitro* features of the cell lines arising from eight resected oesophageal carcinoma specimens	77
Table 13	Results of the tissue culture of biopsy specimens	88
Table 14	Category I Biopsy specimens - histopathology and patient survival	89

		Page
Table 15	Category II Biopsy specimens – histopathology and patient survival	90
Table 16	Category III and IV Biopsy specimens – histopathology and patient survival . .	91
Table 17	Some *in vitro* features of Category III and IV oesophageal carcinoma biopsy specimens	93
Table 18	Accumulated data on all resected tumour specimens	97
Table 19	Accumulated data on 21 biopsy specimens	99
Table 20	Tumour differentiation and culture category Resected tumour specimens ... ... Biopsy specimens	110
Table 21	Operative staging and culture category Resected specimens ... ... Biopsy specimens	112
Table 22	Clinical prognosis and culture category Resected specimens ... ... Biopsy specimens	114
Table 23	Features of all continuous oesophageal carcinoma cell lines to date	117
Table 24	Ultrastructural features of oesophageal carcinoma tumour specimens *in vivo* ...	138
Table 25	Summary of ultrastructural features (TEM) of human oesophageal carcinoma cell lines	162
Table 26	Summary of surface features (SEM) of human oesophageal carcinoma cell lines ...	180
Table 27	Fate of oesophageal carcinoma cell lines inoculated into nude mice	209
Table 28	Some properties of experimentally induced carcinomas in nude mice	212
Table 29	Histological differentiation and infiltration of experimentally induced tumours in the nude mouse	221
Table 30	Tumour metastasis in Mouse X1	223
Table 31	Summary of some of the ultrastructural	

Page

features of nude mouse grown tumours arising as a result of the inoculation of cells of lines derived from poorly differentiated human tumours
A [illegible] ... 227
B Inoculation of Hcu 18 cells ... 228
C [illegible] 228

Table 32 Summary of some of the ultrastructural features of nude mouse grown tumours arising as a result of the inoculation of cells of lines derived from moderately differentiated human tumours 229

Table 33 Summary of some of the ultrastructural features of nude mouse grown tumours arising as a result of the inoculation of cells of lines derived from well differentiated human tumours
A Inoculation of Hcu 13 cells ... 230
B Inoculation of Hcu 33 cells ... 232
C Inoculation of Hcu 35 cells ... 232

Table 34 Summary of some of the ultrastructural features of nude mouse grown tumours arising as a result of the inoculation of cells from lines developed from mouse tumours induced by the inoculation of human oesophageal carcinoma cell lines
A Inoculation of 13.M1 cells 233
B Inoculation of 13.M5 and 13.M7 cells 234

Table 35 Summary of some ultrastructural and surface features of nine nude mouse tumours, their subcultures and the cell line, Hcu 13, from which they originated 247

LIST OF FIGURES

		Page
Fig. 1	A diagrammatic representation of the relationship between *in vivo* and *in vitro* studies ...	10
Fig. 2	Summary of investigations performed	22
Fig. 3	Light micrograph of a portion of a well differentiated human oesophageal carcinoma. Many keratinising cells and an epithelial pearl are evident. Haematoxylin and Eosin ..	35
Fig. 4	Light micrograph of a portion of a poorly differentiated human oesophageal carcinoma. Cell size varies, a giant cell (G) is present and there is no evidence of keratinisation. Haematoxylin and Eosin	35
Fig. 5	Light micrograph of a section of a well differentiated human oesophageal carcinoma showing little evidence of lymphocyte infiltration (+) into the stroma. Haematoxylin and Eosin	36
Fig. 6	Light micrograph of an area of a poorly differentiated human oesophageal carcinoma displaying marked (+++) lymphocyte infiltration. Haematoxylin and Eosin	37
Fig. 7	Diagrammatic representation of some of the steps involved in the initiation of an explant culture	39
Fig. 8	Plan of SPF-4 environment in which nude mice were housed	44
Fig. 9	One week old litter produced as a result of mating a Nu/nu female with a nu/nu male. The nude offspring can be readily identified	49
Fig. 10	Pregnant nu/nu mouse two days before parturition	50
Fig. 11	Emaciated appearance and enlarged lymph nodes in nude mouse four months after the inoculation of Hcu 18 cells	52
Fig. 12	Confluent sheet of normal epithelial cells (E) growing from explanted normal oesophageal mucosa after two weeks *in vitro*. Whorls of fibroblasts (F) are present adjacent to the epithelial cells	60

Page

Fig. 13 Interference micrograph of the regular, adherent epithelial cells present at the periphery of a sheet of normal human oesophageal cells after five days *in vitro* 62

Fig. 14 Interference micrograph showing epithelial cells surrounding an explant of normal human oesophageal mucosa. Refractile processes extend over and between the epithelial cells .. 64

Fig. 15 Interference micrograph of a large, irregular, vacuolated syncytial cell in a three week old culture of Hcu 25 cells 67

Fig. 16 Interference micrograph showing the large, irregular, epithelial cells containing centrally located dense material, which grew rapidly in a culture initiated from a lymph node metastasis in the patient from whom specimen Hcu 22 was obtained 68

Fig. 17 Continuous sheet of agranular epithelial cells in a 12 day old culture of the rapidly growing specimen, Hcu 31, as seen by interference microscopy 70

Fig. 18 Interference micrograph of a large mononucleate giant cell (G) surrounded by smaller carcinoma cells adjacent to an explant of specimen Hcu [illegible] 72

Fig. 19 Interference micrograph showing a giant cell from specimen Hcu 6 in the process of dividing and being replaced by smaller malignant cells 72

Fig. 20 The boundary between malignant epithelial cells (E) and fibroblasts (F) in a two week old culture of Hcu 16 cells as evident by interference microscopy. Fibroblasts encroached on the epithelial cells which became tightly packed and showed reduced mitotic activity 73

Fig. 21 Interference micrograph showing a tightly packed cluster of small, slow-growing epithelial cells in a subculture of Hcu 25 cells 74

Fig. 22 Interference micrograph of a confluent culture of polygonal Hcu 10 cells after three months *in vitro* 80

Fig. 23 Interference micrograph of Hcu 10 cells of varying form and size in a semi-confluent culture after seven months *in vitro*. Paranuclear

Page

granules and vesicles are evident in many of the cells 80

Fig. 24 Interference micrograph showing tightly adherent agranular Hcu 13 cells with prominent nucleoli growing in a confluent sheet after six months in vitro 81

Fig. 25 Interference micrograph of a portion of a culture of agranular adherent Hcu 13 cells after eight months in vitro. Scattered rounded mitotic figures (M) are evident .. 81

Fig. 26 Interference micrograph showing angular, loosely adherent Hcu 18 cells after six months in vitro 82

Fig. 27 Interference micrograph showing part of a sheet of adherent agranular Hcu 33 cells after one month in vitro. Some cells at the growing edge of the sheet display fine radiating processes (P) 83

Fig. 28 Interference micrograph showing rounded, predominantly agranular Hcu 35 cells of varying size after four months in culture 83

Fig. 29 Interference micrograph of elongated (fibroblastic) and rounded epithelial (carcinoma) cells in a six week old culture of Hcu. 37 cells 84

Fig. 30 Interference micrograph showing elongated and angular Hcu 39 cells after four months in vitro 84

Fig. 31 Interference micrograph showing large polyhedral agranular adenocarcinoma cells growing from an explant of specimen Hcu 7 after eight days in vitro. Small fibroblasts of varying morphology migrated more rapidly than did the epithelial cells 85

Fig. 32 Interference micrograph showing elongated epithelial cells of line B 17 after six months in vitro 92

Fig. 33 Results of Cluster analysis showing the dissected specimens (horizontal axis) which were statistically most similar to one another 102

		Page
	granules and vesicles are evident in many of the cells	80
Fig. 24	Interference micrograph showing tightly adherent agranular Hcu 13 cells with prominent nucleoli growing in a confluent sheet after six months in vitro	81
Fig. 25	Interference micrograph of a portion of a culture of agranular adherent Hcu 13 cells after eight months in vitro. Scattered rounded mitotic figures (M) are evident ..	81
Fig. 26	Interference micrograph showing angular, loosely adherent Hcu 18 cells after six months in vitro	82
Fig. 27	Interference micrograph showing part of a sheet of adherent agranular Hcu 33 cells after one month in vitro. Some cells at the growing edge of the sheet display fine radiating processes (P)	83
Fig. 28	Interference micrograph showing rounded, predominantly agranular Hcu 35 cells of varying size after four months in culture	83
Fig. 29	Interference micrograph of elongated (fibroblastic) and rounded epithelial (carcinoma) cells in a six week old culture of Hcu 37 cells	84
Fig. 30	Interference micrograph showing elongated and angular Hcu 39 cells after four months in vitro	84
Fig. 31	Interference micrograph showing large polyhedral agranular adenocarcinoma cells growing from an explant of specimen Hcu 1 after eight days in vitro. Small fibroblasts of varying morphology migrated more rapidly than did the epithelial cells	85
Fig. 32	Interference micrograph showing elongated epithelial cells of line B 17 after six months in vitro	92
Fig. 33	Results of Cluster analysis showing the resected specimens (horizontal axis) which were statistically most similar to one another	102

Page

Fig. 34 Results of Cluster analysis showing the biopsy specimens which were statistically most similar to one another 104

Fig. 35 Results of Cluster analysis showing features of the resected tumour specimens which were statistically linked 105

Fig. 36 Results of Cluster analysis showing features of the oesophageal carcinoma biopsy specimens which were statistically linked ... 107

Fig. 37 Light micrograph showing the stratified squamous epithelium of normal oesophageal mucosa 126

Fig. 38 Transmission electron micrograph of biopsied apparently normal human oesophageal cells. Aggregates of fine filaments replaced most cytoplasmic organelles in the superficially located cells. Variations in cytoplasmic density were related to the numbers of tonofilaments present 128

Fig. 39 Transmission electron micrograph showing the irregular cellular outlines of adjacent, superficially situated, normal oesophageal cells. Tonofilaments lie in close proximity to the opposed plasma membranes which are thickened at intervals 129

Fig. 40 Transmission electron micrograph of epithelial cells centrally located in normal oesophageal epithelium. Dense rod-like structures of diameter 45 nm and lengths of up to 400nm were present in the cytoplasm ... 130

Fig. 41 A low magnification scanning electron micrograph of the clearly defined microridges on the superficial surfaces of normal human oesophageal cells 131

Fig. 42 A higher magnification scanning electron micrograph showing more detail of the microridges on the superficial surfaces of normal oesophageal cells. Intercellular boundaries are prominent and elevated 131

Fig. 43 Scanning electron micrograph showing the variation in number, form and arrangement of microridges on the surfaces of adjacent normal oesophageal cells 132

		Page
Fig. 44	A scanning electron micrograph of superficial normal oesophageal mucosa showing some cells which are denuded of surface projections ...	132
Fig. 45	A high magnification scanning electron micrograph showing bulges (B) at irregular intervals along the microridges on a normal human oesophageal cell	133
Fig. 46	Prominent intercellular borders between adjacent superficially situated normal oesophageal cells as evident by scanning electron microscopy	134
Fig. 47	Scanning electron micrograph showing a cluster of micro-organisms associated with the surfaces of normal oesophageal cells	134
Fig. 48	Scanning electron micrograph of the region where the duct (D) of an oesophageal gland opens on to the surface of the normal oesophageal mucosa	135
Fig. 49	Light micrograph of Toluidine Blue-stained T 28 oesophageal carcinoma cells. The cells vary in size and density and several contain prominent nucleoli	136
Fig. 50	Transmission electron micrograph showing a cluster of 20 - 30 nm diameter particles within the nucleus of a T 24 cell	139
Fig. 51	Transmission electron micrograph showing well developed tonofilaments (Tf) and internalised desmosomes (ID) in a paranuclear position in a T 24 cell. The desmosomes range in diameter and several layers of cementing substance are present. Intracellular electron dense plaques (P) surrounded by electron lucent regions are evident	140
Fig. 52	Transmission electron micrograph showing bundles of interweaving tonofilaments occupying most of the cytoplasm of a T 28 cell ...	141
Fig. 53	Transmission electron micrograph of a T 22 cell containing a paranuclear accumulation of filamentous material (f). The filaments are 8-14 nm in diameter and differ from the larger cytoplasmic glycogen particles (G). A junctional area (J) between adjacent cells is well developed	142

		Page
Fig. 44	A scanning electron micrograph of superficial normal oesophageal mucosa showing some cells which are denuded of surface projections ...	132
Fig. 45	A high magnification scanning electron micrograph showing bulges (B) at irregular intervals along the microridges on a normal human oesophageal cell	133
Fig. 46	Prominent intercellular borders between adjacent superficially situated normal oesophageal cells as evident by scanning electron microscopy	134
Fig. 47	Scanning electron micrograph showing a cluster of micro-organisms associated with the surfaces of normal oesophageal cells	134
Fig. 48	Scanning electron micrograph of the region where the duct (D) of an oesophageal gland opens on to the surface of the normal oesophageal mucosa	135
Fig. 49	Light micrograph of Toluidine Blue-stained T 28 oesophageal carcinoma cells. The cells vary in size and density and several contain prominent nucleoli	136
Fig. 50	Transmission electron micrograph showing a cluster of 20 - 30 nm diameter particles within the nucleus of a T 24 cell	139
Fig. 51	Transmission electron micrograph showing well developed tonofilaments (Tf) and internalised desmosomes (ID) in a paranuclear position in a T 24 cell. The desmosomes range in diameter and several layers of cementing substance are present. Intracellular electron dense plaques (P) surrounded by electron lucent regions are evident	140
Fig. 52	Transmission electron micrograph showing bundles of interweaving tonofilaments occupying most of the cytoplasm of a T 35 cell ...	141
Fig. 53	Transmission electron micrograph of a T 22 cell containing a paranuclear accumulation of filamentous material (F). The filaments are 8-14 nm in diameter and differ from the larger cytoplasmic glycogen particles (G). A junctional area (J) between adjacent cells is well developed	142

Page

Fig. 54 Transmission electron micrograph showing multiple fine filaments forming a 2 - 4 µm band around the degenerating nucleus of a T 22 cell. The entire structure appears to lie within the cytoplasm of another cell 143

Fig. 5 Transmission electron micrograph showing fine filaments of diameter 8 - 12 nm in the cytoplasm of a T 24 cell which is situated close to the boundary between tumour cells and stroma. Membranous folds are present at intervals 144

Fig. 56 Transmission electron micrograph of bizarre, whorled, granular bodies (W) in the cytoplasm of a giant T 24 oesophageal carcinoma cell in vivo. Internalised desmosomes (ID) and aggregates of tonofilaments (Tf) are also present 145

Fig. 57 Transmission electron micrograph of a T 24 cell showing part of a whorled granular body with concentrically arranged 15 - 19 nm membranous profiles between which are located 16 - 19 nm particles. A central electron dense inclusion is present 145

Fig. 58 Transmission electron micrograph showing paired membranous profiles apparently in the process of forming a whorled cytoplasmic body (W) in a T 24 cell. Electron dense tonofilaments (Tf) are well developed 146

Fig. 59 Transmission electron micrograph showing a 3,4 µm diameter membrane-bound cytoplasmic body in a T 23 cell. The structure contains lipid (L), glycogen (G) and particulate matter 146

Fig. 60 Transmission electron micrograph showing portions of adjacent dark and light T 29 cells. Mitochondria (M) with tubular and circular cristae are present in the light cell. 147

Fig. 61 Scanning electron micrograph showing the sparse, irregular microplicae and scanty microvilli on the superficial surfaces of biopsied malignant oesophageal cells 149

Fig. 62 Transmission electron micrograph showing the stratified arrangement of normal human oesophageal cells in vitro. The more superficially situated cells contain more tonofilaments and fewer organelles than those located basally 151

Page

Fig. 63 Scanning electron micrograph of flattened normal oesophageal cells near the growing edge of a cell sheet. Cell boundaries are indistinct and sparse fine surface microvilli are present 153

Fig. 64 Scanning electron micrograph showing the branching attachment fibrils anchoring a normal oesophageal cell to the glass substrate 154

Fig. 65 Scanning electron micrograph of the complex, well developed intercellular interdigitations between adjacent normal oesophageal cells in vivo 154

Fig. 66 A fine meshwork of branching processes superficial to cultured normal oesophageal cells as revealed by scanning electron microscopy 155

Fig. 67 Transmission electron micrograph of cells in a primary culture initiated from an explant of specimen Hcu 50. Lipid droplets (L) are abundant and a myelinoid body (B) is present 155

Fig. 68 Transmission electron micrograph showing multilayered Hcu 13 cells growing on the plastic surface of a tissue culture flask after their fourth successful subculture. The more superficial and better differentiated cells contain bands of paranuclear tonofilaments (Tf) and are joined by numerous well developed desmosomes (D). Electron dense myelinoid bodies (MB) are prominent in the basal cells 163

Fig. 69 Transmission electron micrograph showing well developed tonofilaments which have replaced most other cytoplasmic organelles in a superficial cell of the line B5 after three months in vitro. Dense aggregates of paranuclear tonofilaments are present in the adjacent cell 164

Fig. 70 Transmission electron micrograph showing the thickened plasma membrane or marginal band bordering a highly differentiated Hcu 13 cell which is filled with a meshwork of fine filaments. This cell was prepared for electron microscopy by pelleting 165

Fig. 71 Transmission electron micrograph showing intracellular desmosomes with associated tonofilaments in the cytoplasm of a Hcu 13 cell after six months in vitro 166

Page

Fig. 72 Transmission electron micrograph of internalised hemi-desmosomes in a Hcu 33 cell after five months in vitro 166

Fig. 73 Transmission electron micrograph depicting the irregular nuclear outline in a cultured Hcu 13 cell. Profiles of annulate lamellae (AL) are present adjacent to the involuted nucleus 167

Fig. 74 Transmission electron micrograph of a portion of a Hcu 37 cell with clearly defined intranuclear particles, 35 nm in diameter, which are surrounded by clear halos 168

Fig. 75 Transmission electron micrograph showing a prominent cluster of 20 - 30 nm particles in a peripheral position in the nucleus of a Hcu 13 cell prepared for electron microscopy by pelleting after 15 passages. Bundles of tonofilaments in the cytoplasm reflect the retention of differentiated functions 169

Fig. 76 Transmission electron micrograph of a clearly defined cluster of intranuclear particles in a Hcu 13 cell after 25 passages 169

Fig. 77 Transmission electron micrograph showing two Hcu 18 cells in the process of completing telophase. The cells are joined by a Zwischenkörper with associated microtubules 170

Fig. 78 Transmission electron micrograph of regular electron dense cytoplasmic rods of diameter 45 nm in a Hcu 13 cell after 25 passages ... 172

Fig. 79 Transmission electron micrograph showing a group of dense cytoplasmic rods (40 - 45 nm in diameter) in both transverse and longitudinal section in a Hcu 37 cell 172

Fig. 80 Transmission electron micrograph showing cytoplasmic filaments or particles (P) which are 8 - 14 nm in diameter and lie adjacent to profiles of rough endoplasmic reticulum in a Hcu 37 cell 173

Fig. 81 Transmission electron micrograph showing cytoplasmic filaments of 8 - 14 nm diameter in both transverse and longitudinal section in a metaphase Hcu 18 cell 173

Page

Fig. 82 Transmission electron micrograph of a paracrystalline body (PB), which consists of parallel arrays of fine filaments, in close proximity to mitochondria in a cell of line Hcu 33 174

Fig. 83 Transmission electron micrograph of a filamentous paranuclear body in a Hcu 37 cell. Dense perichromatin granules are peripherally situated in the nucleus 174

Fig. 84 Transmission electron micrograph depicting a meshwork of fine filaments, between which are mitochondria, in the cytoplasm of a Hcu 10 cell prepared for electron microscopy by pelleting 175

Fig. 85 Transmission electron micrograph showing well developed annulate lamellae in the paranuclear cytoplasm of a cell of line Hcu 13 176

Fig. 86 Transmission electron micrograph showing profiles of opposed membranes forming confronting cisternae (C) in the paranuclear cytoplasm of a poorly differentiated Hcu 10 cell 176

Fig. 87 Transmission electron micrograph showing branching profiles of dilated electron dense rough endoplasmic reticulum in a rapidly growing Hcu 1[illegible] cell after four months <u>in vitro</u> ... 177

Fig. 88 Transmission electron micrograph showing spherical vesicles budding from the golgi apparatus in the cytoplasm of a Hcu 13 cell ... 177

Fig. 89 Transmission electron micrograph showing a dense particulate aggregate of glycogen in the cytoplasm of a B 17 cell 178

Fig. 90 Scanning electron micrograph showing cells of line Hcu 10 on the surfaces of which microvilli are well developed 181

Fig. 91 A high power scanning electron micrograph showing the arrangement of microvilli on the surface of a Hcu 10 cell 181

Fig. 92 Scanning electron micrograph showing well developed lateral processes extending between angular Hcu 18 cells 182

Fig. 93 Scanning electron micrograph of long branching lateral processes extending from the peripheral region of a Hcu 18 cell 182

		Page
Fig. 94	Scanning electron micrograph of cultured Hcu 13 cells which are connected by well developed intercellular bridges. Microvilli are fine and short	184
Fig. 95	A higher magnification scanning electron micrograph giving a more detailed view of the intercellular bridges which connect adjacent Hcu 13 cells	184
Fig. 96	Clearly defined mobile tumour nodule in a suprascapular position in a male mouse which was inoculated with Hcu 13 cells	207
Fig. 97	Large, clearly defined mobile tumour in M 25 induced as a result of the inoculation of Hcu 33 cells	211
Fig. 98	Large, lobulated suprascapular tumour infiltrating adjacent tissues in M 34 which was inoculated with Hcu 18 cells	215
Fig. 99	Large cystic tumour stretching the overlying skin in M 31 which was inoculated with B 5 cells	216
Fig.100	Bilateral tumours in M3 which was inoculated with Hcu 13 and Hcu 10 cells in the right and left suprascapular regions respectively. The tumour induced by the inoculation of Hcu 13 cells appeared sooner and grew more rapidly	217
Fig. 101	Emaciated mouse X1 with enlarged lymph nodes containing metastatic deposits of the line Hcu 18	218
Fig. 102	Mouse 21 five days after the removal of a large mobile tumour induced by the inoculation of Hcu 33 cells. A small skin nodule resembling a wart(W)was present anterior to the incision	219
Fig. 103	Transmission electron micrograph showing light and dark carcinoma cells of the moderately differentiated tumour 13.M . Enlarged dense nucleoli (Nu) and aggregates of paranuclear tonofilaments (Tf) are evident in the dark cells	226
Fig. 104	Transmission electron micrograph showing a dense paranuclear aggregate of tonofilaments in a cell from the metastatic tumour 18.X1 ...	235

Page

Fig. 105 Transmission electron micrograph showing portions of apparently healthy B5.M31 cells surrounding a necrotic cell which contains fine cytoplasmic filaments, a few dense bodies, but otherwise sparse organelles, and is bordered by a marginal band 236

Fig. 106 Transmission electron micrograph of the thickened plasma membranes bordering well differentiated 18.M25 cells which are filled with filamentous material. Modified desmosomes of varying morphology are present at intervals between the opposed membranes ... 237

Fig. 107 Transmission electron micrograph showing bundles of tonofilaments in the cytoplasm of a 13.M1.M10 tumour cell which also displays both intercellular desmosomes (D) and internalised desmosomes (ID) 238

Fig. 108 Transmission electron micrograph of an area of the nucleus of a 13.M1 tumour cell which contains a cluster of 20 - 30 nm intranuclear particles 238

Fig. 109 Transmission electron micrograph of a cluster of 20 - 30 nm particles in the cytoplasm of a cultured 13.M3 cell 239

Fig. 110 Transmission electron micrograph showing granules (G) of varying size and density in the cytoplasm of a cultured 13.M5 cell ... 240

Fig. 111 Transmission electron micrograph revealing rod-like structures which resemble mycoplasmas in the cytoplasm of a 13.M7 cell *in vivo* in the nude mouse 241

Fig. 112 Transmission electron micrograph showing whorls (W) of endoplasmic reticulum with associated ribosomes in a 13.M3 cell *in vivo*. Such structures occurred typically in close proximity to lipid droplets (L) 242

Fig. 113 Transmission electron micrograph depicting the aggregates of fine filaments (F) which occupied large areas of the cytoplasm of 13.M3 cells *in vivo* 243

Fig. 114 Transmission electron micrograph of an area where an induced carcinoma is invading adjacent muscle *in situ* in the nude mouse. A

Page

poorly differentiated 13.M9 cell containing dilated rough endoplasmic reticulum (ER) lies adjacent to a striated muscle fibre (SM) with clearly defined myofilaments ... 244

Fig. 115 Transmission electron micrograph of a bundle of collagen fibres (Co) which is surrounded by moderately differentiated 13.M9 cells in vivo 244

Fig. 116 Scanning electron micrograph showing the collagen (Co) and branching reticular fibres which comprise the capsule around a mobile carcinoma in a nude mouse 245

Fig. 117 Scanning electron micrograph showing nude mouse passaged Hcu 13 cells in primary culture. The malignant epithelial cells (E) which are regular in shape and possess few surface projections are bordered by elongated overlapping fibroblasts (F) of mouse origin 249

Fig. 118 Scanning electron micrograph of subcultured 13.M1 cells some of which show well developed surface projections while others are relatively denuded of superficial processes ... 250

[illegible]

[illegible]

[illegible] is a severe disease which generally [illegible] within a year ([illegible] and [illegible], 1973; Rose, [illegible]); the hopelessness being aggravated by the fact that often [illegible] the tumour is far advanced. The overall cure rate has been given as three per cent (Takita et al., 197[illegible]) and in some parts of the world oesophageal carcinoma is a major cause of death. The malignancy gradient increases from the [illegible] to the oesophagus (Rubin, 1973), so that oesophageal carcinoma is one of the most malignant of the gastrointestinal neoplasms (Fagelman et al., 1979). The majority of oesophageal cancers are located in the middle and lower thirds of the oesophagus ([illegible] and [illegible], 19[illegible]; Rubin, 1973; Cutler and Young, 197[illegible]; Botha et al., 1978; Yang, 1980). The disease is often associated with multiple primaries (Gillis and Carter, 1976) and metastasis to subdiaphragmatic areas has been reported in 50 per [illegible] of all lower third lesions (Fagelman et al., 1979).

INCIDENCE OF OESOPHAGEAL CARCINOMA

[illegible] incidence of carcinoma of the oesophagus varies [illegible] of any other type of alimentary tumour (Rose, 197[illegible]) [illegible] with large frequency differences are often in close [illegible]. The areas of highest incidence of carcinoma of the oesophagus are the Caspian littoral, including parts of Iran ([illegible] et al., 1977) and the Guriev regions of Russia (Kairak-[illegible] and Nasipov, 1980), Kazakhstan in Russia (Gillis and Carter, [illegible]), the northern regions of China (Miller, 1978; Yang, 1980) [illegible] of South East Africa (Cook, 1971). To complicate the [illegible], areas of high and low frequency may be found within the [illegible] of the oesophagus belt (Gillis and Carter, 1976)

and this tumour has a greater variation of frequency in Africa than any other(Cook and Burkitt, 1971; Warwick and Harington, 1973) as well as showing temporal variation (Gillis and Carter, 1976; Haas and Schottenfeld, 1976).

The incidence of carcinoma of the oesophagus seems to be increasing in many parts of the world and is said to have reached epidemic proportions in parts of the Transkei (Warwick and Harington, 1973; Rose and Mc Glashan, 1975). No adequate explanation has been found for this increase in incidence, and the increased mortality of the Black population of southern Africa shows little sign of slowing (Keen, 1972). The high incidence of oesophageal cancer is of recent origin in Blacks in South Africa (Keen, 1978) and has only been a clinical problem since 1950. Few cases of carcinoma of the oesophagus were reported before 1940 (Silber, 1978). This differs from the situation in China where records of the disease date back 2000 years (Wang, 1950).

In southern Africa carcinoma of the oesophagus occurs with the highest frequencies in men in the Cape Province, Transkei and Durban where it accounts for 16 - 30 per cent of diagnosed tumours (Cook, 1971; Gillis and Carter, 1976). The frequency of the disease appears to be increasing in most African populations of southern Africa and a six-fold increase was reported at Baragwanath Hospital near Johannesburg between 1950 and 1959 (Higginson and Oettle, 1960). Both urban and rural populations are at risk (Harington and Bradshaw, 1978). In Johannesburg there has been an increase from 10,3 per cent of all diagnosed African tumours in 1950 to 27,5 per cent in 1964 (Rose, 1976), while in parts of the Transkei carcinoma of the oesophagus accounts for 47 per cent of all diagnosed tumours in males (Rose, 1978). In the Transkei the incidence increases from areas of low incidence in the north east to areas of high incidence in the south with a rate of 116 per 100 000 (Rose, 1973). Although better diagnosis may be responsible for some of the statistical changes, the nature of the disease and the methods of diagnosis are such that much of the statistical change is likely to be due to genuine changes in distribution.

Although the disease has been claimed to affect older individuals (Case, 1961; Yan[illegible], 1[illegible]0) and m[illegible] studies have been done on people from 35 - 65 years of age, the ag[illegible] incidence o[illegible] t[illegible] tumour appears to be dropping and cases in teenage individuals have been reported (Rose, 1978; Brinton, 1980, perscomm.).

Many patients with this neoplasm are seen at King Edward VIII and King George V Hospitals in Durban each month and because of the very large population at risk further understanding of the causes of oesophageal carcinoma and its treatment are imperative.

1. 2 SEX RATIO

Although carcinoma of the oesophagus is commoner in males (Gillis and Carter, 1976), the male to female ratios vary tremendously in different parts of the world (Langman, 1971). The sex discrepancy is not very marked in the Transkei where the male to female ratio has been quoted as 1,5 : 1 (Cook, 1971). In the area of highest incidence in Iran and male to female ratio is 1 :1,59 (Rose, 1975) though this ratio varies with age (Sadeghi et al., 197[illegible]) and the sex ratio reverses as the incidence decreases (Rose, 197[illegible]). In China the male to female mortality ratio for carcinoma of the oesophagus is 2 : 1 (Mingxin et al., 1980) while in the high incidence areas of France the male to female radio is 30 : 1 and in American Negroes 4 : 1 (Rose, 19[illegible]8). In South Africa it has been suggested that Black men livi[illegible] in towns are more susceptible than their female counterparts (Rose 1978) and at both King Edward VIII and King George V Hospitals in Durban more male than female patients with oesophageal carcinoma[illegible] are seen.

1. 3 AETIOL[illegible]

As with most other tumours, the aetiology o[illegible] carcinoma of the oesophagus is still incompletely understood although it has been extensively investigated both in South Africa and in other high incidence areas. Many theories concerning aetiological agents have been proposed and the involvement of multiple factors with this disease has been suggested. Understanding the aetiology of

a disease is an important step towards its control and prevention. No unifying hypothesis explains the varied epidemiological picture presented by oesophageal cancer in different parts of the world and no single factor has been found which accounts for its diversity in geographical distribution and sex ratio or its changing frequency (Haas and Schottenfeld, 1978). Carcinoma of the oesophagus appears to be a disease of the environment (Gillis and Carter, 1976), though this relationship is very complex and the cultural environment and social customs and habits may also be extremely important.

The epidemiology and aetiology of carcinoma of the oesophagus have been extensively investigated by many workers throughout the world (for example: [illegible]; Cook, 1972; Cummings, 1973; Gatei et al., 1978; Nunn et al., 1978; Rose, 1973; Van Rensburg, 1978; Cook-Mozafarri et al., 1979; Levison et al., 1979; Tuyns et al., 1979). Numerous aetiological agents have been listed and a few of the more favoured ones are briefly discussed in the following sections.

1. 3. 1 Nitrosamines

Magee and Barnes (1956) demonstrated that dimethyl-nitrosamine was acutely hepatotoxic to a number of laboratory animal species. In recent years the presence of nitrosamines in food has been clearly demonstrated (Bogovski and Walker, 1973) and the possible role of nitrosamines as causative agents in oesophageal carcinoma investigated. However, although nitrosamines are potent carcinogens in many experimental animals (Warwick and Harington, 1973) their role in oesophageal carcinoma is still unclear. In China there is a correlation between fluctuating nitrate levels and incidence of oesophageal carcinoma (Yang, 1980) and, in addition, salivary nitrates are higher in patients with epithelial dysplasia or oesophageal carcinoma (Yang, 1980). In the Transkei high nitrite and nitrate concentrations in plant materials may be related to a soil molybdenum deficiency (Nunn et al., 1973) since molybdenum is a co-factor of the enzyme nitrate reductase which

affects nitrite and nitrate contents in plants (Yang, 1980). Areas with a high oesophageal tumour rate show decreased soil fertility (Schottenfeld, 1975). Plants treated with nutrients such as molybdenum contain far lower levels of nitrosamines (Nunn et al., 1978). Fungal contamination of food material may also promote synthesis of nitrosamines. The association between oesophageal cancer and presence of nitrosamines is currently being investigated in South Africa.

1. 3. 2 Tobacco

The incidence of and mortality rates from carcinoma of the oesophagus are two to six times greater in smokers (Wynder et al., 1975) than in non-smokers. On the other hand many patients who suffer from this disease have never smoked and the habit is unpopular in the Caspian littoral and in China (Yang, 1980). Though a higher risk in pipe smokers has been reported, Gillis and Carter (1976) claim that there is little difference in the relative risks among pipe, cigar and cigarette smokers. The population at higher risk includes those who chew tobacco and mixtures of betel quid and tobacco (Warwick and Harington, 1973). There is also a correlation between carcinoma of the oesophagus and the smoking of unprocessed sun-dried tobacco. Many smokers show hyperplasia of the oesophagus and trachea, a condition which may predispose to malignancy (Warwick and Harington, 1973). South African tobacco has a higher than usual content of nitrate and nitrosamines presumably because of frequent droughts (Warwick and Harington, 1973) and these substances may predispose to malignancy as suggested above. A habit among the Xhosa people (residents of the Transkei) is the sucking of alkaline pipe oil to get the maximum usage out of the tobacco (Warwick and Harington, 1973). This habit is especially common among the women and may be associated with the very high incidence of carcinoma of the oesophagus among females in the Transkei though the incidence is still less than in males.

1. 3. 3 Alcohol

The ingestion of large quantities of alcohol has also been tentatively associated with carcinoma of the oesophagus (Tuyns et al., 1979). Tobacco and alcohol may act synergistically (Wynder and Bross, 1961), as excessive exposure to tobacco and alcohol is often common in the same individual. However, the association with carcinoma of the oesophagus is not straightforward (Gillis and Carter, 1978), particularly as the local inhabitants of the Caspian littoral neither smoke nor drink alcohol.

A number of ways in which alcohol may act as a carcinogen have been suggested; it may have a dehydrating effect on the oesophagus and, in this way, damage it, or be a cause of malnutrition and work together with other factors, or may act as a solvent for carcinogens (Warwick and Harington, 1973). Maize beer, which is widely used in the Transkei may have some carcinogenic component (Cook, 1971) and the effects of Transkei beer on rats have been investigated (Van Rensburg, 1975), with equivocal results.

1. 3. 4 Dietary pattern

Diet is an obvious factor to be investigated in tumours of the alimentary tract (Lowenfels and Anderson, 1977) as all ingested substances have contact with the oesophagus. The dietary effect may be attributed either to the ingestion of carcinogenic agents such as nitrosamines and fungal toxins (Enomoto and Saito, 1972; Schoental, 1980) or to some dietary deficiency. After nitrosamines, which are potent site-specific oesophageal carcinogens, the mycotoxins represent a second major chemical group of suspects in the aetiology of oesophageal cancer (Mc Glashan, 1977).

In Africa there is an association between maize cultivation and oesophageal cancer (Cook, 1971). The predominant *Fusarium* species infecting maize in Southern Africa is also one of the fungi most frequently associated with foodstuffs in the high oesophageal carcinoma incidence regions in northern China and Chinese isolates of this species have been shown to induce the

formation of several carcinogenic nitrosamines (Mingxi [illegible], 1979). The fact that maize is deficient in tryptophan, an essential amino acid, may have some bearing on oesophageal carcinoma. Other dietary deficiencies may also be associated with oesophageal lesions, particularly since carcinoma of the oesophagus occurs frequently in people of the lower socio-economic classes (Joint Iran International Agency, 1977; Cook-Mozafarri [illegible], [illegible]; Ribet, [illegible]; Yang, [illegible]).

Vitamin A is associated with the maintenance of squamous epithelium and normal differentiation of epithelial cells and inhibits the differentiation of normal squamous epithelium (Chopra and Flaxman, 1975; Hogan, 1979) and a deficiency may cause metaplasia of the oesophagus and hyperkeratosis. However, since there is no particular lack of vitamin A in African populations its role in oesophageal carcinogenesis is tenuous. A deficiency of riboflavin may cause epithelial changes such as hyperplasia and atrophy as well as an increased mitotic rate (Warwick and Harington, 1973). Riboflavin deficiency is common in areas where diets are also low in nicotinic acid (Ribet, 1980) and the combined deficiency damages the oesophagus and may predispose to cancer of the oesophagus (Warwick and Harington, 1973). Zinc levels are lower in oesophageal cancer patients than in normal subjects (Yang, 1980) and it has been shown that a zinc deficiency may cause epithelial hyperplasia and result in an oesophageal lesion. Iron deficiency may also occasionally cause oesophageal lesions (Robbins, 1974). Therefore the possible role of dietary factors in the aetiology of oesophageal carcinoma cannot be ignored.

1. 3. 5 Genetic predisposition

Genetic differences which express themselves in altered susceptibilities to oesophageal neoplasms may account for differences in the distribution and sex ratio of carcinoma of the oesophagus. Ethnic variation is apparent in some areas though it is difficult to separate genetic, environmental and cultural factors (Gillis,

1978). In the Linxian province of China the disease has been recorded in close relatives and this observation may be attributed to the influence of a strong carcinogen in a family whose resistance is low (Yang, 1980). There is no other positive evidence of genetic susceptibility to this tumour (Gillis and Carter, 1976), nor is there correlation between blood group antigens and carcinoma of the oesophagus (Aird et al., 19[illegible]; Beasley, 19[illegible]4; Hartman and Staven, 19[illegible]4). The only presumed genetic association is with tylosis, an abnormal hardening of the palms and soles inherited as a dominant characteristic (Howell-Evans et al., 1958; Gillis, 1978), though even this association has been questioned (Langman, 1971).

1. 3. 6 Local oesophageal conditions

Carcinoma of the oesophagus has been linked with previous gastric surgery and stricture and achalasia of the cardiac region (Gillis and Carter, 1976) as well as other damage (e.g. burns) to the oesophagus. Cells in a damaged oesophagus show high proliferative activity and this may be linked to the malignant condition (Gillis and Carter 1976). The use of emetics which is a cultural habit practised by many of the inhabitants of the Transkei may be a predisposing factor for carcinoma of the oesophagus as constant usage of substances causing vomiting may result in over-exposure to gastric contents with resultant injury (Walwick and Harington, 1973) and subsequent rupture of the oesophagus.

1. 3. 7 Oncogenic viruses

As many animal viruses are oncogenic the possible role of a virus or viral agent in the aetiology of oesophageal cancer cannot be overlooked (Green, 1972). A number of viruses which induce tumours under experimental and natural conditions have been identified (Zur Hausen, 1980). Members of the Herpes virus group have been positively associated with natural cancer in human beings (Green, 1972, Zur Hausen, 1975 and 1980), several oncornaviruses (Types B, C and D) have been isolated from continuous human cell

lines (Green, 1972) and A and B particles have been observed in Hela cells (Gelderblom et al., 1974). An interesting finding in relation to oesophageal carcinoma was the recent identification of a C type retrovirus in a continuous oesophageal carcinoma cell line established from a Rhesus monkey (Rabin et al., 1977; Rabin et al., 1979; Rabin et al., 1981). A virus has also been implicated in outbreaks of carcinoma of the oesophagus in Masai cattle in a river valley in Kenya (Plowright et al., 1971; Jarrett, 1973) but there is no evidence as yet of viral involvement in man. The association between the possibility of virus infection in cattle and human cancer is difficult to define (Gillis, 1978) though Scottish families and individuals living in close proximity to cattle have developed cancer at various sites within the alimentary tract.

A viral aetiology could partially explain the apparently epidemic rise of oesophageal carcinoma in the Transkei and the fact that the disease is more prevalent in certain regions than in others. An oncogenic virus may act either alone or in conjunction with other co-factors such as genetic constitution, poor diet, environmental carcinogens or immune deficiencies.

1. 4 SUMMARY

Much remains to be learnt about the aetiology of oesophageal cancer and the genetic and environmental associations with this condition. The aetiology of cancer of the oesophagus is complex and understanding the epidemiology and aetiology of this disease may provide information which will be of eventual benefit to the patient. This is of particular relevance to South Africa and other parts of the world where there is a large population at risk.

2 INTRODUCTION.

THE THESIS

The main purpose of this investigation was to obtain information which would extend the current knowledge of oesophageal carcinoma and be of some relevance to patients afflicted with this condition. It was hoped that laboratory work would provide information of clinical relevance. Studies performed on normal and malignant oesophageal cells involved tissue culture, scanning and transmission electron microscopy of cells *in vivo* and *in vitro* and a comparison of malignant cell growth and morphology *in vitro*, and *in vivo* in a tolerant host. Wherever possible cell behaviour and morphology *in vitro* was compared with that *in vivo*. The inter-relationships between *in vivo* and *in vitro* studies are summarised in Fig. 1.

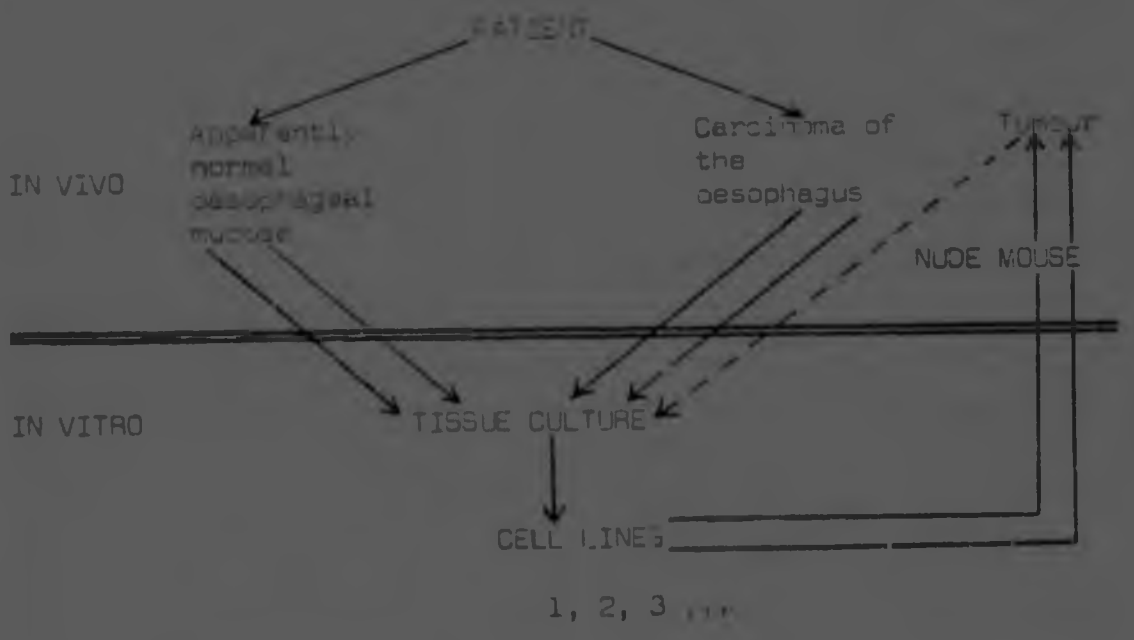

Fig. 1 A diagrammatic representation of the relationship between *in vivo* and *in vitro* studies.

2.1 NORMAL AND MALIGNANT OESOPHAGUS IN VIVO

Before attempting to interpret abnormal structure it is essential to characterise the normal so that any deviations from the normal can be recognised.

The normal human oesophageal mucosa consists of a stratified squamous non-keratinising epithelium which is continually renewed. Both the histology (Leeson and Leeson, 1970; Desmet and Tytgat, 1974; Ham, 1974; Rhodin, 1974; Bloom and Fawcett. 1975; Gardner and Dodds,1976; Hopwood et al., 1977; Junqueira et al., 1977; Logan et al., 1977; Weiss and Greep, 1977; Copenhaver et al., 1978) and the ultrastructure of the normal human oesophageal mucosa have been investigated (Rhodin, 1963; Desmet and Tytgat, 1974; Al Yassin and Toner, 1977; Hopwood et al., 1977; Logan et al., 1977; Hopwood et al., 1978; Logan et al., 1978), and surface studies (using scanning electron microscopy) on normal human oesophageal epithelium have also been performed (Ackerman et al., 1976; Al Yassin and Toner, 1977).

Although the ultrastructural changes in human oesophageal epithelium in oesophagitis have been reported (Hopwood et al., 1979), the ultrastructure of the malignant oesophagus in vivo has been largely neglected. While the light microscopy, histopathology and exfoliative cytology of carcinoma of the oesophagus are well documented (Meissner and Warren, 1971; Pearson and Le Roux, 1974; Robbins, 1974; Vilardell, 1974; Botha et al., 1978; Brinton, 1978) most ultrastructural studies (apart from a paper by Robinson and Gregory, 1981) reported in the literature relate to oesophageal carcinoma cells growing in vitro (Bey et al., 1978; Laboratory Section, Peking, 1976; Nishihira et al., 1979; Rabin et al., 1981; Robinson and Maistry, 1981). However it is not known what effects in vitro culture has on cellular ultrastructure.

Several studies have been carried out on general tumour ultrastructure in vivo (Ghadially, 1975; Gonda et al., 1976; Birbeck, 1976; Sobel and Marquet, 1980) as well as on morphological

changes during cancer development (Sugar, 1972) and on mechanisms of invasiveness (Tickle et al., 1978), and studies on oesophageal carcinoma cells may supplement existing knowledge.

Normal and malignant oesophageal cells were carefully studied in vivo, so that any effects of in vitro growth which were expressed morphologically could be recognised. The more that is learnt about the normal oesophageal mucosa and factors affecting it, the closer one may approach an understanding of the changes occurring in oesophageal carcinomas. Recognition of structural and other morphological features typical to malignant oesophageal cells may facilitate early detection of neoplastic and preneoplastic oesophageal lesions.

2. 2 USE AND IMPORTANCE OF AN IN VITRO SYSTEM

Since in vivo investigations are limited by moral and ethical considerations, a model system in which both normal and malignant oesophageal cells and the factors affecting them can be studied in a controlled environment is useful. Tissue culture provides one such system although the extent to which cell growth in vitro approximates that in vivo is not known.

2. 2. 1 Culture of normal and malignant oesophageal cells

The culture of normal and malignant epithelial cells is of biological relevance since epithelial cells perform differentiated functions, such as keratinization, which can be studied in vitro.

Because of its availability and the ease with which it initially grows in vitro human skin has been extensively cultured (Green et al., 1977; Fuchs and Green, 1978; Marcelo et al., 1978; Sun and Green, 1978; Spie and O'Brian, 1979). Serially cultivated human epidermal cells retain many differentiated functions and form stratified colonies, make cornified envelopes and synthesize keratin (Rheinwald and Green, 1975; Green, 1978). Both normal and highly differentiated malignant oesophageal cells may do likewise. Although normal oesophageal mucosa shows no true surface

[illegible] (Desmet and Tytgat, 1974), some of the sur- [illegible] may have keratohyaline granules and in the case of [illegible] of the well differentiated cells are [illegible]atinised.

[illegible] characteristics are often used to distin- [illegible] from malignant cells (Kirkland et al., 1979) and [illegible] these properties may be related to the process of [illegible]. A comparison of the in vitro growth [illegible] of normal and malignant oesophageal cells [illegible] further differences between these cell populations, and [illegible] in cases where diagnosis is difficult.

[illegible] cells in vitro may provide a useful model for [illegible] in vivo, provided the cells maintain, in vitro, [illegible] characteristics and specific functions of their tissue [illegible] (Voigt and Fusenig, 1979). Obtaining specimens of [illegible] oesophageal mucosa posed ethical problems and even when [illegible] of apparently normal oesophageal mucosa away from the [illegible] malignant lesions were obtained during operative re- [illegible] no guarantee that the mucosa was normal and did [illegible] premalignant changes. Specimens of oesopha- [illegible] removed during endoscopic examination for other condi- [illegible] may not be completely normal. In spite of these limi- [illegible], culture and investigation of apparently normal oesopha- [illegible] cells was attempted.

Although normal cells make the necessary adaptation to in vitro [illegible] (Auersperg and Finnegan, 1974), they have a limited [illegible] in vitro and normal adult cells rarely form continuous [illegible] lines. Syverton and McLaren in 1957 reported the [illegible] of an oesophageal cell strain from an explant of a [illegible] of a tracheo-oesophageal fistula from a one day old infant, [illegible] this cell strain was not further described and there are no [illegible] in the literature to cultured normal oesophageal [illegible].

CONTINUOUS OESOPHAGEAL CARCINOMA CELL LINES

The establishment of continuously growing cell [illegible] malignancies is infrequent (Giard et al., 1973; [illegible] and the success rate in establishing cell lines [illegible] cimens varies from one site to another ([illegible] lines derived from tumours of the [illegible] (Rounds, 1970; Bloom, 1972).

Seven continuously growing oesophageal [illegible] been reported in the literature, six from [illegible] al., 1976; Department of Cell Biology of the [illegible] the Chinese Academy of Medical Sciences (CICAMS), [illegible] tory Section, Peking, 1976; Nishihira et al., [illegible] and one from a Rhesus monkey (Rabin et al., [illegible]). [illegible] these cell lines (Bey et al., 1976; Laboratory Section, [illegible] 1976; and Rabin et al., 1978) were established [illegible] nant tumours which resulted in death of the host. The [illegible] is unknown for the patients from whom lines Eca 109 (Department of Cell Biology of CICAMS, 1976), EC 56 (Yang, 1980) and TE-1 [illegible] TE-2 (Nishihira et al., 1979) were established. The line [illegible] 562 was initially described as being of oesophageal origin [illegible] actually arose from the pleural fluid of an adult female with [illegible] metastatic adenocarcinoma that originated in the upper pharynx. (W.D. Petersen, Jr., pers comm.).

In this investigation both biopsy and resected specimens of oesophageal carcinomas were cultured in order to obtain continuously growing neoplastic cells to provide a basis for further work. The availability of more and different oesophageal carcinoma lines will increase the scope for investigation in this field, and comparison of lines established in South Africa, with those from elsewhere in the world may facilitate recognition of similarities or differences in the disease here and, for example, in China. The continuous lines provide a useful source of material for ultrastructural studies, investigations on tumorigenicity and metastasis, production of monoclonal antibodies and studies testing the efficacy of anticancer agents.

2. 4 CORRELATION BETWEEN IN VIVO AND IN VITRO BEHAVIOUR

The usefulness and importance of continuous malignant cell lines lies in their retaining *in vitro* the features typifying the neoplasm *in vivo*. Cells *in vitro* are growing in an artificial two-dimensional environment which may affect many cellular properties. Adaptational changes should be minimal in primary short-term cultures and the main advantage of such cultures is their relative normalcy and the absence of the morphological aberrations that develop in the course of long-term cultivation (Morasca *et al*., 1976; Vasiliev and Gelfand, 1977). A recognition of the adaptational changes that occur *in vitro* may aid in the understanding of cellular functions as normal and malignant cells may respond differently to varying environmental conditions. Consequently, the current study was undertaken to compare normal and malignant oesophageal cells *in vivo*, with similar cells *in vitro* after varying time intervals. Several oesophageal carcinoma specimens were studied as *in vitro* tumours, as primary cultures and as early and late passaged cultures in order to facilitate comparison of cells at all these stages, while primary cultures of normal oesophageal mucosa were also investigated. Furthermore normal and malignant cells were studied under closely similar conditions and growth patterns and morphology effectively compared.

2. 4. 1 Tissue culture and prognosis

Survival in malignant neoplasma may be influenced by clinical features such as the stage of the disease and the size of the lesion (Rubin, 1973) and by pathological features such as histological differentiation (Takita *et al*., 1977), blood vessel invasion (Salsbury, 1975) or lymphocyte infiltration as well as by competence of the immune system (Ioachim, 1976). Although Takita *et al*. (1977) suggested that in patients with oesophageal cancer, well-differentiated squamous tumours were associated with the best prognosis and Pearson and Le Roux (1974) claimed that undifferentiated tumours were characterised by a higher incidence of extra-oesophageal spread and increased incidence of venous

invasion (Salsbury, 1975), the association between histopathological differentiation and patient prognosis is unreliable. Gatei et al., (1978) found no correlation between prognosis and the degree of differentiation, age, sex or ethnic group of patients with oesophageal carcinoma.

Many tumours display a variable stromal infiltrate of plasma cells, lymphocytes, eosinophils and neutrophils which are thought to accumulate in response to specific antigenic stimulation. This infiltrate is proportional to the degree of desmoplastic reaction and may be inversely related to the degree of tumour differentiation (Ioachim, 1976). Lymphocyte infiltration, however, bears a variable relationship to patient prognosis. Improved survival has been associated with lymphocyte infiltration in breast carcinoma (Black et al., 1975) but not in melanoma (Balch et al., 1978). An association between plasma cell infiltration and squamous cell carcinomas has also been noted (Ioachim, 1976), but no work specific for oesophageal carcinoma has been performed.

The current study was undertaken to determine whether behaviour of tumour cells *in vitro* could be correlated with the extent of the disease *in vivo* and patient prognosis, as growth characteristics in tissue culture may reflect the malignant potential of solid tumours. The relationship between growth patterns *in vitro* and the degree of differentiation of the tumour and lymphocyte infiltration have been considered (Younghusband and Aluwihare, 1970).

In vivo invasiveness may be recognised by increased motility of malignant cells *in vitro* (Gershman et al., 1978). The appearance of cells cultured *in vitro* is consistent with their pleomorphic character *in vivo*, and may be useful in establishing the tissue of origin of anaplastic tumours (Kadin and Bensch, 1971). All tissue culture conditions were standardised in this study so that variations in growth pattern and rate and length of time *in vitro* could be attributed to properties of the malignant cells.

2.5 CORRELATION BETWEEN BIOPSIES AND RESECTED SPECIMENS

The development of fibre optic endoscopy, whereby a lesion can be

brushed and biopsied under direct vision has opened a new era in the evaluation, diagnosis and management of lesions of the upper gastrointestinal tract (Glazebash et al., 19[illegible]). Biopsy specimens are, of necessity, small and superficial and only representative of small portions of the tumours from which they are removed. As large number of cells are traumatised during the procedure the viability of cells from biopsy material is generally poor (Whitehead, 19[illegible]). If, however, the tumour cell population is fairly uniform and the cells growing *in vitro* from a biopsy specimen are representative of the tumour as a whole, then biopsy specimens may be of significance as an indication of clinical prognosis. Thus, if correlation can be demonstrated between the *in vitro* behaviour of tumour biopsies and *in vivo* invasiveness, an added criterion would be available to select patients for curative treatment including resections, radictherapy and chemotherapy. In order to establish the possible usefulness of cultured biopsy specimens, biopsied and resected tumour specimens of oesophageal carcinoma were grown *in vitro* and compared.

Growth *in vitro* of biopsy specimens may be used as added confirmation of malignancy when neoplastic changes are not satisfactorily evident in tumour material prepared for histopathological examination. Because of their availability biopsy specimens may provide material for further studies on oesophageal carcinoma cells. Biopsies of normal oesophageal mucosa provide additional information about normal oesophageal cells *in vivo*.

2.6 ULTRASTRUCTURAL CHARACTERISATION OF CELLS IN VIVO AND IN VITRO

Since the development of the commercial electron microscope, ultrastructural investigations have become an integral part of cell biology and pathology. The use of the electron microscope in the field of tumour biology is, however, limited and meticulous tissue processing is vital as artifact may intrude and lead to confusion. This is a particular difficulty when studying malignant specimens where little is known of the artifact free

brushed and biopsied under direct vision has opened a new era in the evaluation, diagnosis and management of lesions of the upper gastrointestinal tract (Kizilbash et al., 1980). Biopsy specimens are, of necessity, small and superficial and only representative of small portions of the tumours from which they are removed. As large numbers of cells are traumatised during the procedure the viability of cells from biopsy material is generally poor (Whitehead, 1978). If, however, the tumour cell population is fairly uniform and the cells growing *in vitro* from a biopsy specimen are representative of the tumour as a whole, then biopsy specimens may be of significance as an indication of clinical prognosis. Thus, if correlation can be demonstrated between the *in vitro* behaviour of tumour biopsies and *in vivo* invasiveness, an added criterion would be available to select patients for curative treatment including resections, radiotherapy and chemotherapy. In order to establish the possible usefulness of cultured biopsy specimens, biopsied and resected tumour specimens of oesophageal carcinomas were grown *in vitro* and compared.

Growth *in vitro* of biopsy specimens may be used as added confirmation of malignancy when neoplastic changes are not satisfactorily evident in tumour material prepared for histopathological examination. Because of their availability biopsy specimens may provide material for further studies on oesophageal carcinoma cells. Biopsies of normal oesophageal mucosa provide additional information about normal oesophageal cells *in vivo*.

2.6 ULTRASTRUCTURAL CHARACTERISATION OF CELLS IN VIVO AND IN VITRO

Since the development of the commercial electron microscope, ultrastructural investigations have become an integral part of cell biology and pathology. The use of the electron microscope in the field of tumour biology is, however, limited and meticulous tissue processing is vital as artifact may intrude and lead to confusion. This is a particular difficulty when studying malignant specimens where little is known of the artifact free

structure. Degenerate cells are a rich source of spurious "virus-particles" (Birbeck, 1976) and corresponding normal tissues do not always provide a satisfactory control. Bearing these problems in mind it is still possible to obtain valuable information with the aid of the electron microscope. Transmission electron microscopy elucidates the ultrastructure of cells, while scanning electron microscopy provides information about cell surfaces. Cell morphology may contribute to the demonstration of homology between cell lines *in vitro* and human cells *in situ* (Copeland *et al.*, 1976) and the usefulness of cell cultures lies in extrapolation of *in vitro* results to the *in vivo* situation. Cell surface morphology (microvilli and lateral processes) may be related to metastatic potential (Reith *et al.*, 1980) and studies on oesophageal cell surfaces may provide information about invasiveness. In this study cultured normal and oesophageal carcinoma cells were examined by both transmission and scanning electron microscopy and differences and similarities noted.

2.7 POSSIBLE ASSOCIATION OF A VIRUS WITH HUMAN OESOPHAGEAL CARCINOMAS

There has been little available evidence to support the hypothesis of viral involvement with oesophageal carcinoma. Although no viruses have been reported in human oesophageal carcinoma cell lines examined by electron microscopy (Bey *et al.*, 1976; Nishihira *et al.*, 1978), Rabin *et al.* (1978) observed budding and extracellular type C virus particles in a Rhesus monkey oesophageal carcinoma cell line. The discovery of a similar virus associated with human oesophageal carcinomas would open up many further fields of investigation which might lead to effective methods of preventing the disease, or at least allow for adequate screening and early recognition of the disease using immunological techniques. In this investigation all cell lines and many tumour specimens were examined by transmission electron microscopy in order to detect any features suggestive of viral involvement with this tumour.

2. E[illegible]MAN OESOPHAGEAL CARCINOMAS IN ATHYMIC NUDE [illegible]

Cultures initiated from human tumours need to be characterised by various techniques in order to determine whether they contain malignant or benign, non-neoplastic cells (Hajdu and Fogh, 1978). A possible method of characterisation is that of tumour production in an experimental host, such as the nude mouse, as tumorigenicity would prove the cell line to be of malignant origin. Growth of tumours in nude mice in conjunction with studies of corresponding cells *in vitro*, can provide an animal model system for in depth studies of the pathology of tumour cell type (Pettengill *et al.*, 1980).

Athymic (nude) mice do not possess functional T lymphocytes (Pantelouris, 1968) and accept not only normal tissues but also grafts of malignant tumours (Rygaard and Povlsen, 1969). Many tumours have been successfully grown in nude mice after the inoculation of malignant cells and cell lines (Giovanella *et al.*, 1974; Fogh and Hajdu, 1975). Tumours that grow in athymic mice show similarities in histopathology and cytology to the human tumour of origin (Povlsen and Rygaard, 1971; Visfeldt *et al.*, 1972; Katsuoka *et al.*, 1976; Povlsen, 1976) though some tumours obtained by inoculating cell lines may become increasingly differentiated in the nude mouse host (Sharkey *et al.*, 1978).

To study the properties of human oesophageal carcinoma cells *in vivo* in the nude mouse and to confirm the malignant nature of cell lines established from oesophageal carcinoma tumour specimens, cells from continuous oesophageal carcinoma cell lines were injected into adult nude mice. The three-dimensional environment in which the tumour grows in the nude mouse host more closely approximates that in the human host, though one unexpected finding has been that human tumours that invade and spread in the human host often behave like benign tumours in the nude mouse (Giovanella and Fogh, 1978; Hajdu and Fogh, 1978; Rygaard, 1978).

Nude mouse-grown tumours are assuming importance in research as they appear similar to those in the *in vivo* situation. These

tumours may provide valuable information in a number of investigations on the effects of anti-tumour agents such as drugs, radiation, etc. and other possible methods of treating human tumours.

2. 8. 1 Relationship between nude mouse tumours and those in the human host

As human oesophageal carcinomas induced in nude mice by the inoculation of continuous oesophageal carcinoma cell lines cannot be considered identical to those in their natural environment in the human host, in this investigation tumours grown in the nude mouse, human tumours and the cell cultures and lines derived from both, as well as cells from continuous human oesophageal carcinoma cell lines were examined by light microscopy and by both scanning and transmission electron microscopy in an attempt to understand the relationship between them. The nude mouse grown tumour cells, primary cultures of these cells and later subcultures (passages 3 - 5) were examined by the same techniques in order to detect surface and other adaptational changes and to gauge the usefulness of the nude mouse model for further studies on tumour cell properties and behaviour.

2. 9 SUMMARY

Investigations were performed on normal and malignant oesophageal cells using tissue culture as a central theme. Attempts were made to answer the following questions.

1 How do normal and malignant oesophageal cells differ *in vivo* and *in vitro*?

2 a Can continuous cell lines be established from human oesophageal carcinomas?

b Are all oesophageal carcinoma cell lines similar?

3 Is there any correlation between *in vitro* and *in vivo* behaviour of malignant oesophageal cells?

a Is it possible to make a prognosis about the disease in a patient from a specimen handled for tissue culture?

b Is there any correlation between histopathology, clinical staging of disease and growth *in vitro*?

4 Do resected and biopsied tumour specimens behave in a similar manner *in vitro*?

5 What ultrastructural alterations occur during adaptation to *in vitro* conditions?

6 Do human oesophageal carcinoma cell lines produce tumours in nude mice?

7 Are the nude mouse tumours similar when initiated by inoculation of cells from different oesophageal carcinoma cell lines?

8 Are carcinomas induced in nude mice similar to oesophageal carcinomas in patients?

9 a Do nude mouse tumours re-establish in tissue culture?

b If so, do the cells *in vitro* resemble the original cell line

(i) in early passage and

(ii) in late passage?

10 Is there any ultrastructural evidence which supports the theory of a viral aetiology in carcinoma of the oesophagus?

The major investigations performed in this study are summarised diagrammatically in Fig. 2.

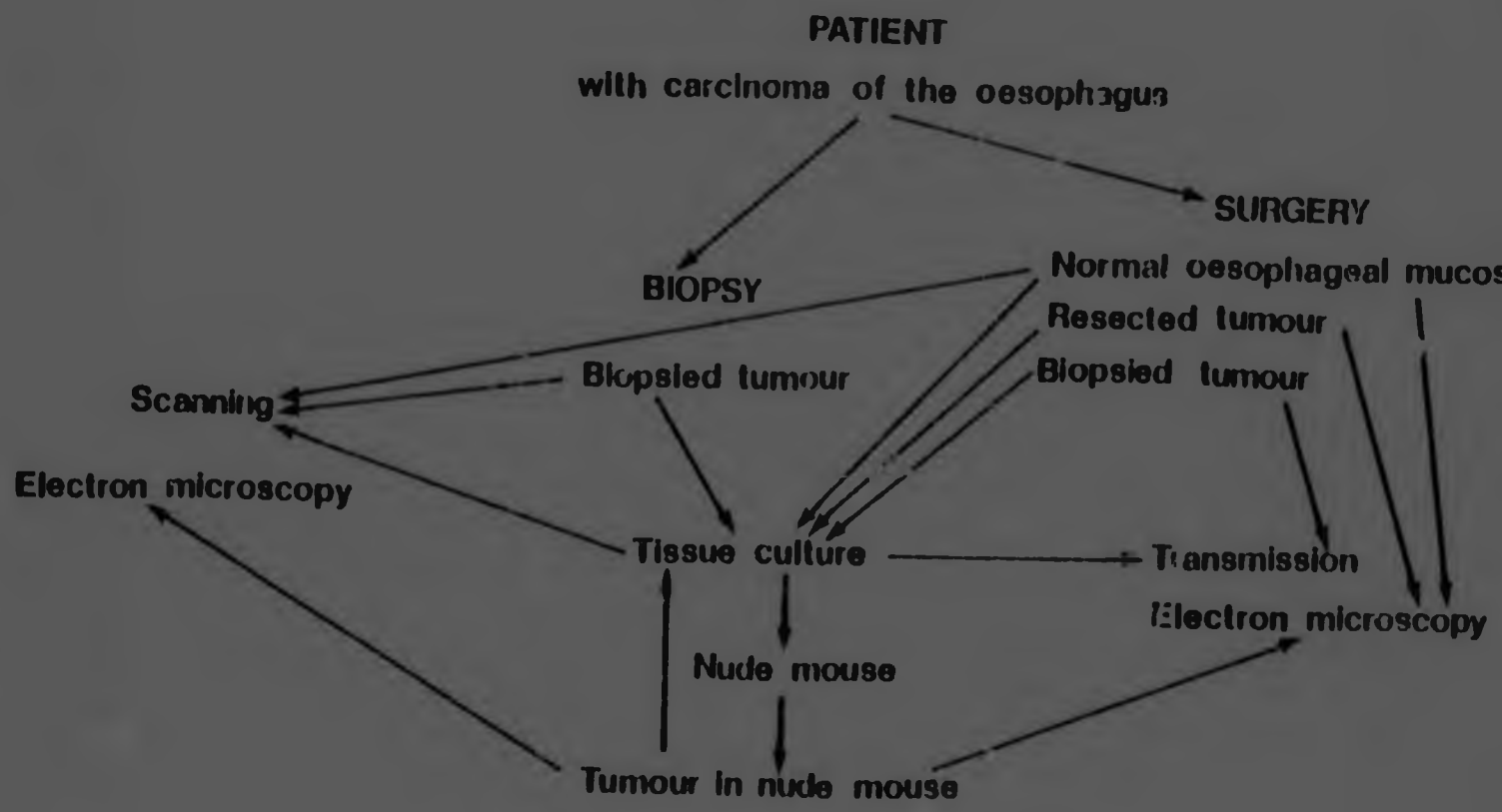

Fig. 2 Summary of investigations performed.

3 MATERIALS AND METHODS

TISSUE CULTURE MATERIALS

3.1 INTRODUCTION

In tissue culture, small fragments of tissue are placed in medium and allowed to develop (Paul, 1975). The environment and the composition of all media and other solutions must be kept constant to ensure reproducible results and the expression of biological differences against similar *in vitro* backgrounds.

3.2 ENVIRONMENT

The room used for tissue culture was sealed and decontaminated initially with Formaldehyde vapour (300 ml 40 per cent w/v formaldehyde and 100 g potassium permanganate).

A conventional tissue culture hood containing a TUV 30 W bactericidal lamp (Philips) and equipped with a spirit burner was used for all manipulations. The hood was swabbed several times daily with 70 per cent ethyl alcohol and regularly washed down with a 1:250 Hibitane solution (five per cent Chlorhexidine Gluconate B.P.)

All cultures were placed in a Gallenkamp 55 litre anhydric incubator and maintained at 37,5°C. The incubator was wiped down weekly with a 0,5 per cent solution of Hibitane.

3.3 APPARATUS

Glassware:

Preparation of new and used glassware, metal caps and rubber stoppers involved standard techniques as described by Paul (1975). Neutral Extran (Merck) at pH 7,5 was the detergent of choice; 22-mm² coverslips (Chance) were prepared for tissue culture by soaking in detergent, rinsing, then soaking in 1N HCl, followed by 1N NaOH, followed by rinsing in distilled deionised water and autoclaving in a glass petri dish with adjacent coverslips

[illegible] of tissue paper.

[illegible]rument:

[illegible] were wiped with carbon tetrachloride to remove [illegible] coating and then processed as for glassware. [illegible], apart from sterile disposable ware, was autoclaved [illegible] kilopascals at 121°C for 20 minutes before use.

[illegible] ware:

[illegible] Falcon and [illegible] plastic tissue culture flasks (25cm² [illegible]) were used as culture vessels. These flasks are made [illegible] specially treated to permit cell adhesion. Two [illegible] culture chamber slides were also frequently [illegible].

[illegible]

Minimum essential medium

[illegible] used was Eagle's (1959) Minimum Essential Medium (MEM) [illegible] and containing L-glutamine (Gibco Cat. No. F-15 [illegible] Cat. No. [illegible]) supplemented with 120 µg/ml Sodium [illegible] (Crystapen, Glaxo-Allenbury) and 100 µg/ml Strep-[illegible] (Glaxo-Allenbury). The antifungal agents Fungistatin ([illegible]) and Fungizone (Amphotericin B, Squibb) were [illegible] at concentrations of 100 µg/ml [illegible] µg/ml respectively. Amphotericin B had fewer adverse [illegible] than Nystatin and was the antifungal agent of choice. [illegible] containing an antifungal agent was routinely used for [illegible] and rinsing tissue specimens or when fungal contamination was suspected.

[illegible] powdered form was dissolved in distilled deionised water to which, [illegible] solution, 1,[illegible]g of $NaHCO_3$ were added per litre of medium. The medium was sterilised by nitrogen pressure [illegible] (25 – 35 kilopascals) through a series of Millipore [illegible] 1,2; 0,8; 0,45 and 0,22 µm, and then [illegible]. Samples of freshly filtered medium were incubated [illegible] before use to check sterility.

Hank's Balanced Salt Solution (BSS) was made up from powdered packets powdered medium (Flow) to each litre of which 0,35 g sodium bicarbonate were added before filtration.

3. 4. 2 Foetal calf serum

Most cultured cells require serum in the medium for optimum growth (Howard and Howard, 1965 ; Hassell and Engelhardt, 1977). Serum growth factors such as fetuin and serum albumin (Ham, 1970) and high molecular weight substances may be incorporated as nutrients or play a role in protecting cells (Whitaker, 1972).

During the first two and a half years of this work, Pentex (Miles Laboratory) foetal calf serum (FCS), filter sterilised, heat inactivated and mycoplasma screened was added to the filtered medium just before use to give a concentration of ten per cent. When the serum proved no longer available, Gibco FCS (Cat. No. 629) screened for virus and mycoplasma was used after heat inactivation at 56°C for one hour. This was later replaced by Flow FCS (Cat. No. 29-101-54). Slight differences in cell morphology and growth rates were evident with the different sera as different batches and types of FCS differ in the efficiency with which they promote growth (Parshad and Sanford, 1963; Kaighn, 1973).

3. 4. 3 Trypsin

The 0,25 per cent trypsin (Difco 1 : 250) solution was made up in calcium and magnesium free phosphate buffered saline at pH 7 - 7,5 (Hull et al., 1973), stirred thoroughly and left at 4°C overnight. Thereafter, the trypsin solution was again stirred and centrifuged at 1 500 r.p.m. to remove any undissolved material. The supernatant was filtered through the same combination of filters used for sterilizing medium (Section 3. 4. 1) and 50 ml aliquots were stored for up to nine months at -20°C and warmed to 37,5°C prior to use. For optimum dissociation of epithelial cells the 0,25 per cent trypsin solution was mixed 1 : 1 with a 0,1 per cent solution of EDTA/glucose in calcium and magnesium free PBS at pH 7,2 - 7,6 immediately before use. Both 0,25 per cent trypsin and 0,1 per cent EDTA

in 0,05 per cent EDTA/glucose were used in experimental work.

3. 5 TISSUE SPECIMENS

The letters Hcu refer to the series of resected human oesophageal carcinoma specimens used in this study (Table 1). All tumour specimens, specimens of apparently normal oesophagus and some involved lymph nodes were surgically removed during operative resections for carcinoma of the lower third of the oesophagus at King George V Hospital, Durban. Visual confirmation was obtained of the local extent of the tumour and the presence of nodal and visceral metastases.

Biopsy specimens (superficial tumour specimens) were obtained from patients with oesophageal tumours at the time of diagnostic oesophagoscopy or during surgery using 2mm Chevelier Jackson biopsy forceps introduced through a rigid Negus oesophagoscope. All biopsy specimens obtained in this way were designated B and numbered (Table 2).

Specimens of apparently normal oesophagus were designated Oes and a number given to correspond to the Hcu number of the patient from whom they were obtained (Table 3).

Patients received no drug therapy prior to operation except oral mycostatin where Candida infection was suspected. Pre-operative treatment consisted of dietary supplementation with Synthamin (Travasol, Baxter) - a 5,5 per cent or 8,5 per cent solution of amino acids and electrolytes, or two to three litres of Electrolyte No. 2 per day for four to five days. Some patients received Vitrum (Intralipid, Sabax) an isotonic soya bean preparation containing lecithin, egg yolk and glycerol.

Attempts were made to establish continuously growing cell lines from:

a) 46 oesophageal squamous carcinoma specimens (Table 1),
b) 36 superficial biopsy specimens of oesophageal carcinomas (Table 2),
c) 20 specimens of apparently normal oesophageal mucosa (Table 3),

TABLE 1 SOME CLINICAL INFORMATION ABOUT THE PATIENTS WITH SQUAMOUS OESOPHAGEAL TUMOURS FROM WHICH THE SPECIMENS USED IN THIS STUDY WERE OBTAINED

Date of operative resection	Culture number	Sex of patient	Age of patient	Operative Findings		
				Tumour	Nodes	Organ invasion
30. 8.76	Hcu 6	M	58	irresectable bulky tumour, infiltrating mediastinum	positive, fixed	stomach
23. 9.76	Hcu 8	M	48	6cm intramural tumour	positive, mobile, cervical	nil
5.11.76	Hcu 9	M	60	6cm intramural tumour	positive, mobile, small	nil
16.11.76	Hcu 10	F	40	4cm intramural tumour invading mediastinum	matted, coeliac	nil
8. 2.77	Hcu 13	M	50	3cm bulky tumour invading mediastinum	mobile, coeliac	stomach
17. 2.77	Hcu 14	M	60	2,5cm sclerotic lesion	negative	nil
18. 5.77	Hcu 16	M	38	8cm irresectable tumour invading mediastinum	positive, mobile, mediastinal and coeliac	stomach
18. 5.77	Hcu 17	-	-	untraceable	-	-
28. 7.77	Hcu 18	F	40	5cm tumour invading mediastinum	matted, coeliac	liver
25. 8.77	Hcu 20	F	50	untraceable	-	-
5.10.77	Hcu 21	M	57	3cm intramural tumour	widespread mediastinal and coeliac	nil

TABLE 1 (cont.)

Date of operative resection	Culture number	Sex of patient	Age of patient	Operative Findings		
				Tumour	Nodes	Organ invasion
21. 2.78	Hcu 22	M	67	4cm annular growth	negative	nil
18. 4.78	Hcu 23	F	58	5cm annular growth	negative	nil
19. 5.78	Hcu 24	M	52	4cm intramural tumour	positive, mobile, small	nil
16. 5.78	Hcu 25	F	45	5cm fungating tumour	negative	nil
23. 5.78	Hcu 26	M	60	data lost	-	-
13. 6.78	Hcu 27	F	56	3cm intramural tumour	negative	nil
25. 7.78	Hcu 28	M	58	4cm intramural tumour	positive, mobile	nil
27. 7.78	Hcu 29	M	52	4cm intramural tumour	negative	nil
15. 8.78	Hcu 30	M	41	3cm tumour infiltrating mediastinum	positive, mobile	nil
6. 9.78	Hcu 31	M	50	7,5cm tumour infiltrating mediastinum	widespread mediastinal and coeliac	left lung
26. 9.78	Hcu 32	M	52	5cm transmural tumour invading mediastinum	matted, coeliac	diaphram
30.10.78	Hcu 33	M	45	6,5cm fungating tumour invading mediastinum	coeliac and mediastinal	stomach and diaphram
31.10.78	Hcu 35	M	65	irresectable 5cm tumour invading mediastinum	mediastinal	lung

TABLE 1 (cont.)

Date of operative resection	Culture number	Sex of patient	Age of patient	Operative Findings		
				Tumour	Nodes	Organ invasion
14.11.78	Hcu 36	M	52	5cm tumour	coeliac	stomach
21.11.78	Hcu 37	F	60	large irresectable tumour from aortic arch to proximal stomach	widespread coeliac and mediastinal	liver
14.12.78	Hcu 38	M	52	3cm intramural tumour	negative	nil
7. 2.79	Hcu 39	M	70	3cm transmural tumour invading mediastinum	matted, coeliac	pancreas
6. 3.79	Hcu 40	M	35	2cm malignant ulcer	positive, mobile, small	nil
4. 5.79	Hcu 41	M	56	5cm intramural tumour	negative	nil
29. 5.79	Hcu 42	F	52	3 - 4cm intramural tumour	negative	nil
16.10.79	Hcu 43 B22	M	40	untraceable	-	-
15.11.79	Hcu 44 B23	M	69	6cm transmural growth	negative	nil
20.11.79	Hcu 45 B24	F	28	5cm transmural growth	negative	nil
29.11.79	Hcu 46 B25	F	50	5cm invasive tumour	positive	lung and aorta
8. 1.80	Hcu 47 B26	F	26	4cm intramural tumour	negative	nil
22. 1.80	Hcu 48 B27	M	59	3cm intramural tumour	positive, mobile gastric	nil
29. 1.80	Hcu 49 B28	M	68	7cm transmural tumour	positive, para-oesophageal	nil

TABLE 1 (cont.)

Date of operative resection	Culture number	Sex of patient	Age of patient	Operative findings		
				Tumour	Nodes /	Organ invasion
12. 2.80	Hcu 50 B29	M	59	5cm transmural tumour	positive, coeliac and gastric	nil
19. 2.80	Hcu 51 B30	M	41	8cm transmural tumour	extensive fixed	lung and pericardium
25. 2.80	Hcu 52 B31	M	49	5cm transmural tumour	negative	nil
11. 3.80	Hcu 53 P32	M	30	transmural tumour invading mediastinum	extensive, coeliac and cardiac	pleura
27. 3.80	Hcu 54 B33	M	49	untraceable	-	-
1. 4.80	Hcu 55 B34	M	39	transmural tumour invading vertebral column	fixed coeliac and mediastinal	liver (left lobe)
27. 5.80	Hcu 56 B35	M	53	5cm transmural tumour	negative	nil
24. 6.80	Hcu 57 B36	M	41	3cm transmural tumour	negative	nil

Average age of patients - 50 years Average age of male patients - 52,5 years
Average age of female patients - 45,9 years

/ Where not stated otherwise, the involved lymph nodes were local

TABLE 2 SOME CLINICAL INFORMATION ABOUT THE PATIENTS WITH SUSPECTED OESOPHAGEAL TUMOURS FROM WHICH THE OESOPHAGEAL BIOPSY SPECIMENS USED IN THIS STUDY WERE OBTAINED

Date on which biopsy performed	Culture number Hcu	B	Sex of patient	Age of patient	Radiographic findings
29. 5.79		1	M	68	5cm tumour confined to oesophagus
29. 5.79		2	M	57	7cm tumour invading mediastinum
29. 5.79	42	3	F	52	Data untrac[illegible]e
29. 5.79		4	F	60	No radiographs available
29. 5.79		5	M	65	8cm upper thoracic tumour with fistula into lung
5. 6.79		6	M	75	No radiographs available
5. 6.79		7	M	81	5cm tumour; no evidence of spread
5. 6.79		8	M	60	6cm tumour; no evidence of spread
5. 6.79		9	F	55	5cm tumour confined to oesophagus
5. 6.79		10	F	58	6cm tumour; no evidence of spread
12. 6.79		11	M	66	6cm tumour invading bronchus
12. 6.79		12	M	67	6cm tumour; no evidence of spread
12. 6.79		13	M	60	no radiographs available
12. 6.79		14	F	66	tumour not seen
12. 6.79		15	M	60	6cm tumour invading mediastinum
12. 6.79		16	F	55	4cm tumour confined to oesophagus
9.10.79		17	F	44	6cm tumour invading bronchus

TABLE 2 (cont.)

Date on which biopsy performed	Culture number Hcu	B	Sex of patient	Age of patient	Radiographic findings
9.10.79		18	F	28	5cm tumour invading trachea
9.10.79		19	M	52	5cm tumour invading mediastinum
9.10.79		20	F	35	no radiographs available
9.10.79		21	M	49	tumour not seen
16.10.79		22	M	40	6cm tumour invading trachea
15.11.79	44	23	M	69	∮ 6cm transmural tumour
20.11.79	45	24	F	28	∮ 5cm transmural tumour
29.11.79	46	25	F	50	∮ 5cm invasive tumour
8. 1.80	47	26	F	26	∮ 4cm tumour confined to oesophagus
22. 1.80	48	27	M	59	∮ 3cm tumour confined to oesophagus
29. 1.80	49	28	M	6	∮ 7cm transmural tumour
12. 2.80	50	29	M	59	∮ 5cm transmural invasive tumour
19. 2.80	51	30	M	41	∮ 8cm transmural tumour
25. 2.80	52	31	M	49	∮ 5cm transmural tumour
11. 3.80	53	32	M	39	∮ large tumour invading mediastinum
27. 3.80	54	33	M	49	no radiographs available
1. 4.80	55	34	M	38	∮ transmural tumour invading vertebral column
27. 5.80	56	35	M	53	∮ 5cm transmural tumour
24. 6.80	57	36	M	41	3cm transmural tumour

∮ Other operative findings appear in Table 1

Average age of patients - 54,2 years Average age of male patients - 56,8 years Average age of female patients - 48,9 years

TABLE 3 AGES AND SEXES OF THE PATIENTS FROM WHOM SPECIMENS OF APPARENTLY NORMAL OESOPHAGUS WERE OBTAINED DURING OPERATIVE RESECTIONS FOR CARCINOMA OF THE OESOPHAGUS

Date	Culture number	Sex	Age
14.12.78	Oes 38	M	52
7. 2.79	Oes 39	M	70
5. 3.79	Oes 40	M	35
1. 5.79	Oes 41	M	56
29. 5.79	Oes 42	F	52
16.10.79	Oes 43	M	40
15.11.79	Oes 44	M	69
20.11.79	Oes 45	F	28
29.11.79	Oes 46	F	50
8. 1.80	Oes 47	F	26
22. 1.80	Oes 48	M	59
29. 1.80	Oes 49	M	68
12. 2.80	Oes 50	M	59
19. 2.80	Oes 51	M	41
25. 2.80	Oes 52	M	49
11. 3.80	Oes 53	M	39
27. 3.80	Oes 54	M	49
1. 4.80	Oes 55	M	38
27. 5.80	Oes 56	M	53
24. 6.80	Oes 57	M	41

two adeno carcinoma specimens listed in Table 4.

TABLE 4: AGES AND SEXES OF THE PATIENTS FROM WHOM THE SPECIMENS DIAGNOSED AS ADENOCARCINOMA AND DYSPLASIA WERE OBTAINED

Date	Culture Number	Sex	Age	Histopathology
23. 9.76	Hcu 7	F	45	adenocarcinoma
30.11.76	Hcu 11	M	49	poorly differentiated adenocarcinoma
10. 3.77	Hcu 15	F	39	dysplasia only

Involved lymph nodes were obtained from those patients whose tumours were designated Hcu 22 and Hcu 23 and attempts made to culture these.

3. 6 HISTOPATHOLOGY

The histological grading of the tumour specimens as poorly, moderately or well differentiated was performed by pathologists at the Department of Health, Welfare and Pensions Pathology Laboratories, Durban and King Edward VIII Hospital, Durban, and depended on the degree of anaplasia and estimated growth rate (Meissner and Warren, 1971; Botha et al., 1978). Basically a tumour classified as histologically well differentiated contained numerous keratinising cells and few mitotic figures (Fig 3), while a poorly differentiated tumour was not keratinising, showed pleomorphism and displayed numerous mitotic features (Fig. 4). A correlation between tumour differentiation and the amount of cellular infiltrate has been described (Ioachim, 1976).

3. 7 LYMPHOCYTE INFILTRATION

As it has been suggested that patients with lymphocytes in their tumour present earlier, live longer and are more likely to have an associated "immune" reaction in the lymph nodes (Younghusband and Aluwihare, 1970), a record of the extent of lymphocyte infil-



Fig. 3 Light micrograph of a portion of a well differentiated human oesophageal carcinoma. Many keratinising cells and an epithelial pearl are evident. Haematoxylin and Eosin. Bar = 10 μm



Fig. 4 Light micrograph of a portion of a poorly differentiated human oesophageal carcinoma. Cell size varies, a giant cell (G) is present and there is no evidence of keratinisation. Haematoxylin and Eosin. Bar = 10 μm

[illegible] ding was [illegible] h [illegible] mour specimens con- [illegible] and having a relatively acellular [illegible]. Several specimens that fell [illegible] neutrophils in scattered areas. [illegible] lymphocyte infiltration through- [illegible] classified at ++. Such specimens [illegible] displayed abundant neutrophils and plasma cells. [illegible] abundant lymphocytes throughout the tumour [illegible] ied as +++ (Fig. 6). All grading of the [illegible] infiltration was performed without the [illegible] of any other features of the tumour [illegible]

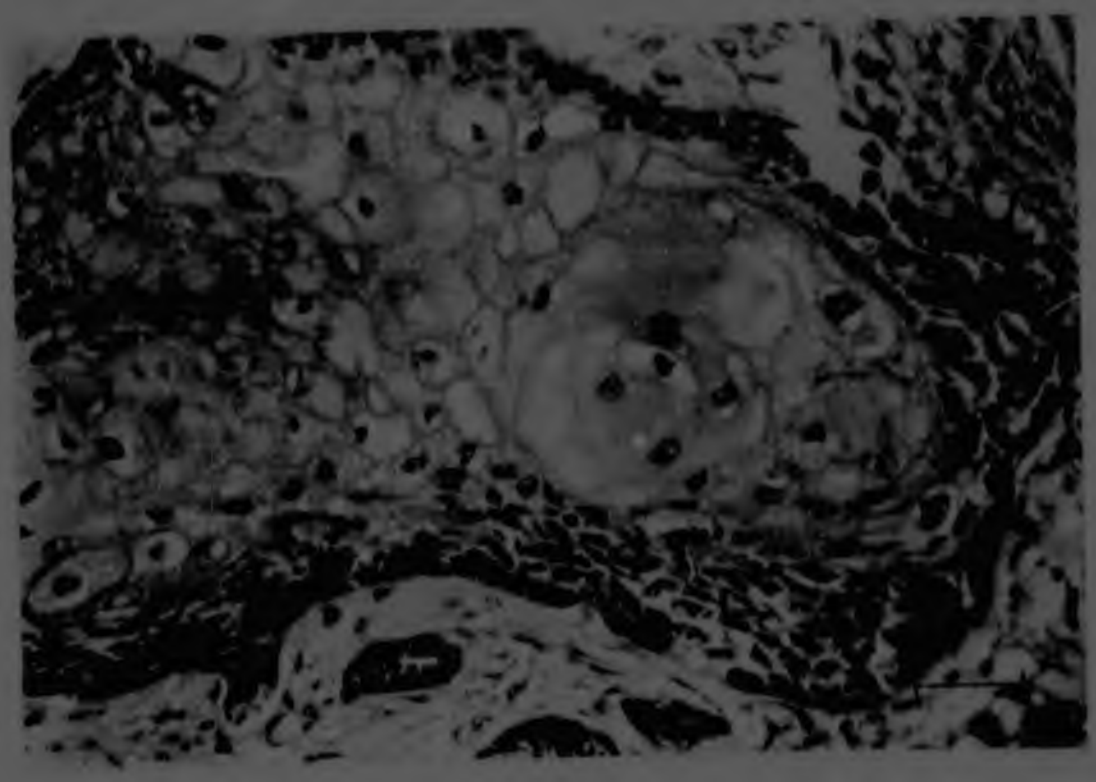

[illegible] graph of a [illegible] of a well differentiated [illegible] showing little evidence of [illegible] (+) into the stroma. [illegible] r = 10 μm

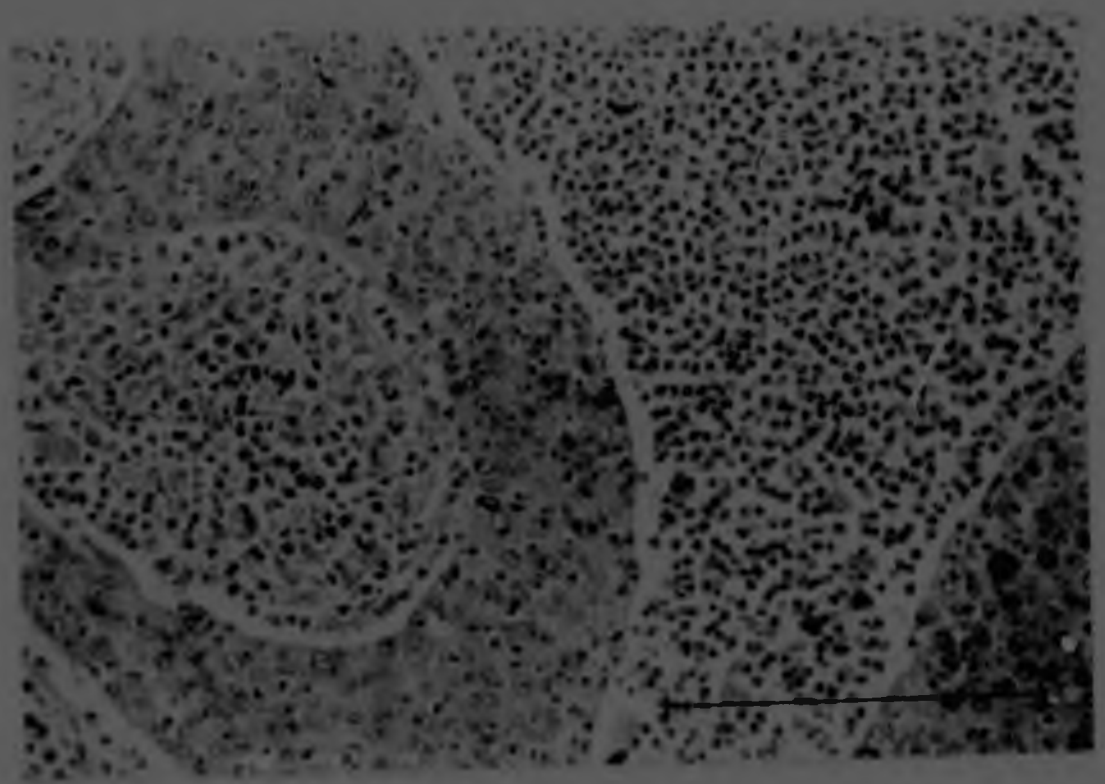

Fig. 6 Light micrograph of an area of a poorly differentiated human oesophageal carcinoma displaying marked (+++) lymphocyte infiltration. Haematoxylin and Eosin. Bar = 100 μm.

4 MATERIALS AND METHODS

TISSUE CULTURE - METHODS

4.1 ESTABLISHMENT OF CULTURES

Resected oesophageal carcinoma specimens (1,5 - 2,5 cm in diameter) selected from the central regions of the tumours, superficial biopsy specimens of oesophageal carcinomas and biopsy specimens of apparently normal oesophageal mucosa were aseptically collected in Macartney bottles containing 5 ml MEM with Amphotericin B or Nystatin, as initial fungal (most frequently Candida albicans) contamination was a problem. The presence of fungus has been reported in 90 per cent of patients with carcinoma of the oesophagus (CICAMS, 1978) and in many patients with premalignant changes (Xia and Zhan, 1978).

Specimens were maintained at ambient temperature and transported to the tissue culture laboratory within two to five hours of removal. Primary cultures were set up as soon as possible after arrival of the specimens, although the length of time between surgical removal of the tumour and initiation of the culture did not appear to be critical as most mammalian cells and tissue fragments survive for several hours at 30°C(Paul, 1975). Cell growth was obtained from two specimens which had been stored for up to four hours at 4°C and it was also possible to initiate cultures from tissue specimens which had been stored for up to four weeks at -30°C.

The method of setting up a primary culture varied according to the nature of the specimen. Preliminary work using the techniques described by Hull et al., 1973; Hayflick, 1965 and 1973; and Alexander et al., 1976 was done by the author on many normal and malignant tissues (kidney, skin, liver, nephroblastoma, neuroblastoma) before oesophageal carcinoma specimens were successfully cultured. Best growth from oesophageal carcinoma specimens was obtained using a dry explant technique - a modification of methods described by Martin (1973), Alexander et al.

(1976) and Klein (1976). Although techniques involving initial trypsinisation (Hull et al., 1973) gave good results with nephroblastomas (Robinson et al., 1980 a) normal and malignant oesophageal specimens failed to grow in vitro when these techniques were used and variations of the trypsinisation techniques have not been suitable for establishing continuously growing primary cultures from solid epithelial tumours (Vasiliev and Gelfand, 1977). Epithelial cells may be more prone to damage during initial trypsinisation than other cell types and the method of tissue disaggregation affects the quality and potential viability of primary culture (Whitaker, 1972).

4. 1. 1 Explant Technique

The procedures used in this technique are summarised in Fig. 7

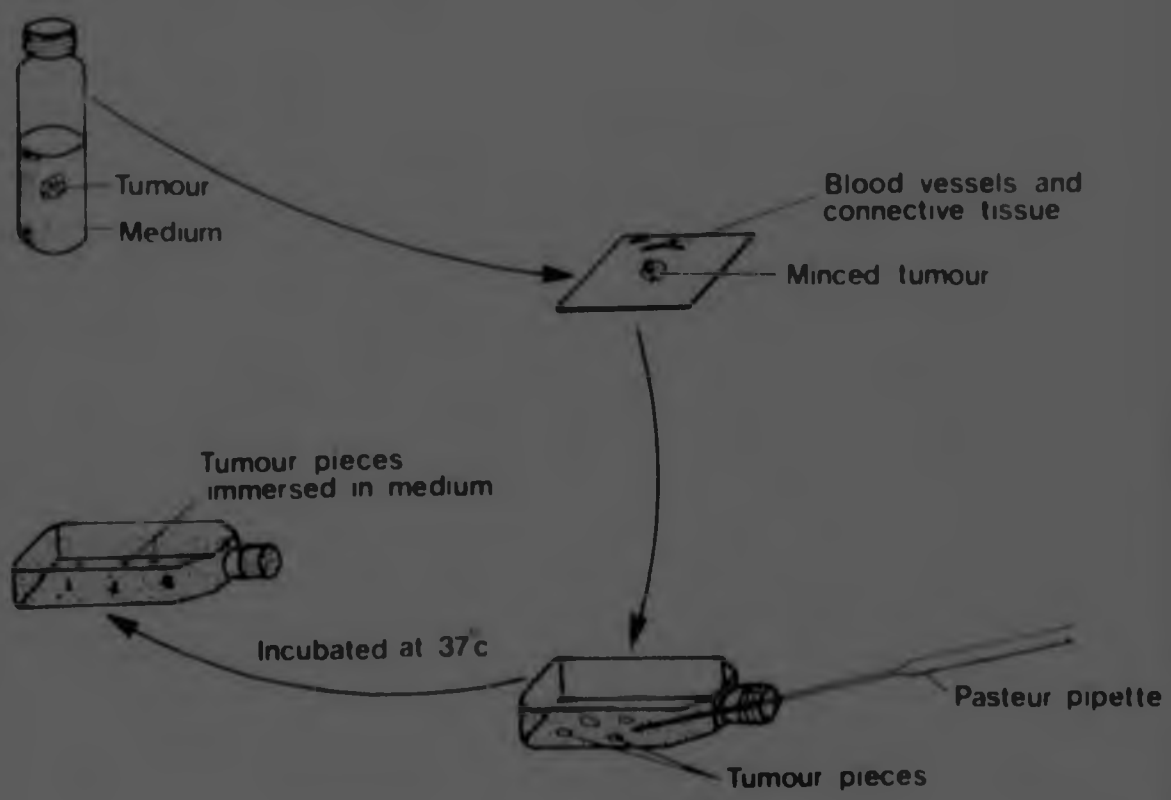

Fig. 7 Diagrammatic representation of some of the steps involved in the initiation of an explant culture.

On arrival in the laboratory, the specimens were carefully rinsed in three changes of MEM containing Amphotericin B or Nystatin. Each specimen was then placed on a stainless steel plate in a glass petri dish and visible blood vessels and areas of obvious connective tissue dissected away to prevent fibroblast overgrowth as far as possible. All manipulations were performed in a tissue culture hood. The specimens were then diced using scissors and forceps. As the best growth occurred when specimens were handled as little as possible, this was deemed preferable to the use of crossed scalpel blades. Small fragments of approximately 0,2mm² were transferred to the dry surfaces of sterile 25cm² plastic tissue culture flasks. The number of tissue fragments per flask was varied depending on the size of the explants. Usually eight to twelve pieces of tumour tissue were placed on the surface of each flask. The success of this technique varied from specimen to specimen. In some instances the tumours proved easy to dice, whereas other scirrhous tumours were subjected to mechanical trauma in efforts to obtain explants of suitable size.

Great care was taken not to smear the cells or explants across the plastic surfaces as the cells detached in this way did not grow. Using this dry explant technique, four to six flasks were set up for each specimen. The flasks were then placed on their sides and three ml of MEM containing FCS carefully added so as not to dislodge any of the explants.

The flasks were incubated vertically for 45 minutes to allow the explants to attach so that the explants and bases of the flasks remained dry though the medium did humidify the atmosphere within the flasks. The pH of new cultures was adjusted to 7,1 - 7,2, using the CO_2 produced by dry ice in a Macartney bottle which was held against the mouths of the flasks.

Thereafter the flasks were placed in a horizontal position so that the medium bathed the explants and incubation was continued.

After the initial gassing of cultures the pH, as shown by the colour of the phenol red in the medium, remained constant for two to three weeks, after which time regassing sometimes became necessary.

During this investigation the medium in the flasks was changed every three to five days though primary cultures were left undisturbed for five days before their first medium change.

4. 2 REMOVAL OF FIBROBLASTS

As all tumour specimens unavoidably contained some fibrous tissue or stroma, most cultured specimens showed outgrowths of elongated fibroblasts which bordered the slow-growing epithelial cells. The period required for the epithelial cells to adapt to *in vitro* conditions ranged from one week to several months. Once the epithelial cells were sufficiently established *in vitro* attempts were made to remove the fibroblasts. The timing of this step was important, as premature exposure of cultures frequently resulted in epithelial cell death. On the other hand, if the fibroblasts were allowed to persist, there was a danger that they might overgrow the epithelial cells, a phenomenon which occurred in several specimens.

Different techniques were used to remove fibroblasts, since the effectiveness of each technique varied from specimen to specimen.

4. 2. 1 Differential Trypsinisation

In several cultures frequent differential trypsinisation proved a deterrent to fibroblast growth. This technique is based on the principle that fibroblasts retract and begin detachment more readily in the presence of trypsin than do most epithelial cells (Owens, 1976). The working trypsin solution (Chapter 3. 4. 3) was used to rinse the flasks. Thereafter the flasks were incubated for 20 - 30 seconds with this solution and immediately the cells were first seen to detach the flasks were shaken gently to dislodge any other loosened cells. The trypsin solution, containing dislodged fibroblasts and a few epithelial cells, was decanted and fresh MEM with FCS added to the flasks to inactivate the trypsin. The flasks were gently shaken to remove any other loosened cells and this medium decanted. Fresh MEM with FCS was added to the flasks and incubation continued. This technique

generally served to check fibroblast growth.

The decanted solution (in a Macartney bottle) was centrifuged at 1 500 r.p.m. and the supernatant discarded. The pelleted cells were resuspended in fresh medium (the volume depending on the size of the pellet) and inoculated into new flasks. These flasks were gassed and the fibroblasts cultured so that fibroblast-conditioned medium could be produced if required. In addition, any epithelial cells inadvertently removed would also be cultured.

A problem with the trypsinisation technique was that, in some specimens, it had an unfavourable effect on the epithelial cells - in severe cases resulting in cell death. Epithelial damage was, however, reversible within a few days in most cultures as the epithelial cells soon flattened and continued dividing and the trypsinisation procedure could then be repeated.

Cultures with a heavy growth of fibroblasts required daily trypsinisation for a two to three week period to control the fibroblast population. As such severe and repeated treatment invariably had an adverse effect on the epithelial cells, other methods of fibroblast removal were attempted.

4. 2. 2 Mechanical scraping

The boundary between epithelial cells and fibroblasts was often distinctly visible to the naked eye when the flask was held against a light source, and extensive areas of fibroblast growth could be removed by scraping the cells off the tissue culture flask using a bent glass rod or pipette with rounded ends.

Care was required to avoid removing the adjacent epithelial cells or damaging the surface of the flask by scratching. The epithelial cells were not as severely traumatised as during trypsin treatment though pH adjustment was necessary in cultures where fibroblasts had been removed by this method.

4. 2. 3 Fibroblast removal during subculture

In some specimens, fibroblasts were most effectively removed during

subculturing. The rationale behind this method is that some epithelial cells reattach to the plastic surface more rapidly (within 20 minutes) after trypsinisation than do fibroblasts. Once most of the epithelial cells have attached (as detected by phase contrast microscopy) a large number of fibroblasts can be removed by decanting the medium, which contains any cells that have not yet attached to the plastic surface, and adding fresh medium.

The method of fibroblast removal was determined by the growth and morphology of the epithelial cells. Certain specimens with very heavy fibroblast growth required a combination of scraping and trypsinisation to remove these rapidly growing cells. Other cultures, in which the epithelial cells had not yet sufficiently adapted to *in vitro* conditions, would have been harmed by trypsinisation, and scraping was therefore the method of choice. The last few fibroblasts present in a particular culture were most easily removed during subculturing. The longer the epithelial cells were grown *in vitro*, the more resistant they generally became to the deleterious effects of trypsin.

As epithelial proliferation may be dependent upon fibroblast products (Green, 1977), medium conditioned by fibroblasts was used in an attempt to promote epithelial growth in two specimens (Hcu 22 and 25). Medium was added to flasks containing fibroblasts removed by trypsinisation, decanted after 24 hours and added to nearly pure epithelial cultures from the same patient. Such a conditioned medium which presumably contained some factors released by the fibroblasts (Owens, 1976), had a slight growth promoting effect on the epithelial cells. If pure fibroblast cultures from a particular specimen were not available, then medium conditioned by a mixed epithelial and fibroblast culture was used and also had beneficial effects. Media were not exposed to fibroblasts for more than 24 hours as fibroblasts remove many nutrients from the medium.

4. 3 SUBCULTURING

The necessary time for cell growth *in vitro* before subculturing

could be undertaken varied from one week to several months. The criteria used to determine whether or not a culture could be passaged depended on features such as cell density, rate of cell division and cell morphology. Rapidly multiplying cells were subcultured readily. Semi-confluent cell sheets (cells filling most of the available growing space in the flask) were most suitable for subculturing. Established cell lines were routinely passaged in the following way:-

The medium in the flask together with any detached cells was decanted. The flasks were rinsed in 0,125 per cent trypsin in 0,5 per cent EDTA/glucose or in 0,25 per cent trypsin. This was decanted and three to four ml of trypsin or the trypsin EDTA/solution added. The flasks were then incubated at 37°C for one and a half to five minutes. Cell detachment could be detected microscopically or with the naked eye, since detached cells gave a cloudy appearance to the trypsin solution. The flasks were shaken gently to loosen all cells and the contents of the flasks aseptically decanted into Macartney bottles. The flasks were rinsed with MEM containing FCS to remove any remaining loosened cells and this solution was added to the Macartney bottles.

Cell suspensions were centrifuged at 1 500 r.p.m. and the cell pellets resuspended in fresh nutrient medium. The contents of a single 25cm^2 flask were generally split into three new flasks, depending on rapidity of growth. Approximately 5 X10^5 to 1 X 10^6 cells were inoculated through a 20g needle into each new 25cm^2 flask.

Established cell lines were routinely passaged weekly. More slowly growing cultures were subcultured less frequently. As the flasks that had been trypsinised generally retained some cells, fresh medium was added to these flasks and incubation continued. In the new flasks the medium was routinely changed 24 hours after subculturing to remove any dead cells and debris.

Where passaging by trypsinisation proved difficult islands of epithelial cells were picked up using a bent pasture pipette and transferred to new flasks. This technique was necessary for the

initial subculturing of specimens Hcu 13 and Hcu 21. The islands of cells reattached within 30 minutes.

4. 4 OBSERVATION OF CELLS

Cultured cells were microscopically examined daily, initially using a Zeiss monocular microscope and closing down the iris diaphram to increase contrast and later using a CK II - Olympus phase contrast inverted microscope. A green and neutral density grey filter were routinely used.

All photographs were taken on a Zeiss photomicroscope 3. Live cells were photographed using interference microscopy, a green filter and Ilford pan F film (ASA 50) which was developed in 1 : 50 Rodinal for eight and a half minutes.

4. 5 CELL COUNTING

Cell numbers were determined using a haemocytometer (Bausch and Lomb); by the method described by Priest (1977) with slight modification. Before being introduced into the counting chambers, the cell suspensions to be counted were passed through 25g needles to obtain as even a suspension as possible. Confluent small ($25cm^2$) Falcon and Lux flasks generally contained $2 \times 10^5 - 4 \times 10^5$ cells, while the $75cm^2$ flasks held $8 \times 10^5 - 12 \times 10^5$ cells.

4. 6 CELLS GROWN ON COVERSLIPS AND CHAMBER SLIDES

Healthy cells from both primary and continuous lines to be viewed by light microscopy and scanning electron microscopy were trypsinised and the detached cells after centrifugation at 1 200 r.p.m. were resuspended in fresh medium containing FCS and the cell numbers adjusted to approximately 4×10^5 cells per ml. Two ml of this cell suspension were added to 30mm diameter Lux sterile petri dishes each containing a pre-treated (Chapter 3. 3) $22mm^2$ glass Chance coverslip. Each chamber of two-chambered Lab-tek tissue culture chamber slides was also inoculated with two ml of cell suspension. Some explant cultures were initiated on cover-

slips in petri dishes so that primary cultures could be further examined. The petri dishes and chamber slides were incubated for one to three days at 37°C within a sealed humidified desiccator. A closed system was used to prevent the pH from rising and to prevent evaporation of the medium.

4. 7 FREEZING OF CELLS

All lines and tumour specimens were stored in a Specht ultradeep-freeze at -80°C. The cells were frozen in the flasks in which they were growing in five ml of medium containing ten per cent dimethyl sulphoxide (DMSO) and ten per cent foetal calf serum (Bertolini and Diamond, 1976). The frozen cells were rapidly thawed when required and showed good viability.

4. 8 TREATMENT OF CONTAMINATED CULTURES

Primary cultures were frequently contaminated with yeasts, most notably Candida albicans. All cultures were examined daily in order to detect the presence of any micro-organisms at an early stage. Yeast spores were identified by a Gram stain (Humason, 1972). Contaminated cultures were treated as follows: the old medium was discarded and the flasks rinsed several times in MEM with Amphotericin B but without FCS. Heavily contaminated cultures were then incubated overnight in MEM without FCS but containing Amphotericin B (5 µg/ml) or Nystatin (100 µg/ml).

This treatment was repeated several times and, in many instances, the contaminating organisms were sucressfully removed. Cultures contaminated with bacteria were treated by repeated rinsing with MEM until the appropriate antibiotic, as determined by sensitivity tests performed in the Microbiology Department at King Edward VIII Hospital, was available.

5 MATERIALS AND METHODS

THE MAINTENANCE AND USE OF NUDE (ATHYMIC) MICE

As the nude mouse is an athymic mutant which lacks cell mediated immune responses this animal must be housed in a sheltered environment to prevent infection by foreign organisms.

5. 1 MICE USED IN THIS STUDY

A pair of nude homozygotes and six heterozyous mice of both sexes were obtained from Dr. E. Meyer of the Animal and Dairy Sciences Research Institute at Irene in March, 1975. The original nude mice at Irene were of BALB/c origin and were obtained from the Medical Research Council Laboratory at Carshalton, U.K. These were subsequently back crossed once with HA/Icr mice obtained from the University of Cape Town and the F_1 generation ramdomly bred. The animals were transported to Durban by air in a stainless steel filtered container.

5. 2 SPF - 4 ENVIRONMENT

All mice used in this investigation were housed in a specially created SPF - 4 environment (Fig. 8), the temperature of which was maintained at 23°C as the hairless animals have to be protected against extremes in temperature and humidity (Ediger and Giovanella, 1978).

Access to the SPF - 4 nude mouse colon, was strictly controlled and sterile precautions always adopted. The colony was kept under constant ultraviolet light (Phillips Germicidal lamps) and the air conditioner outlet and cage racks were covered with 0,5 µm washable filtering (F 400, Curtis Industrial). Although caps, masks, gowns and overshoes were used in the colony the use of gloves was avoided as contact with the rubber upset the animals. Hands and arms were thoroughly and repeatedly scrubbed in 1 : 250 Hibitane before handling the mice.

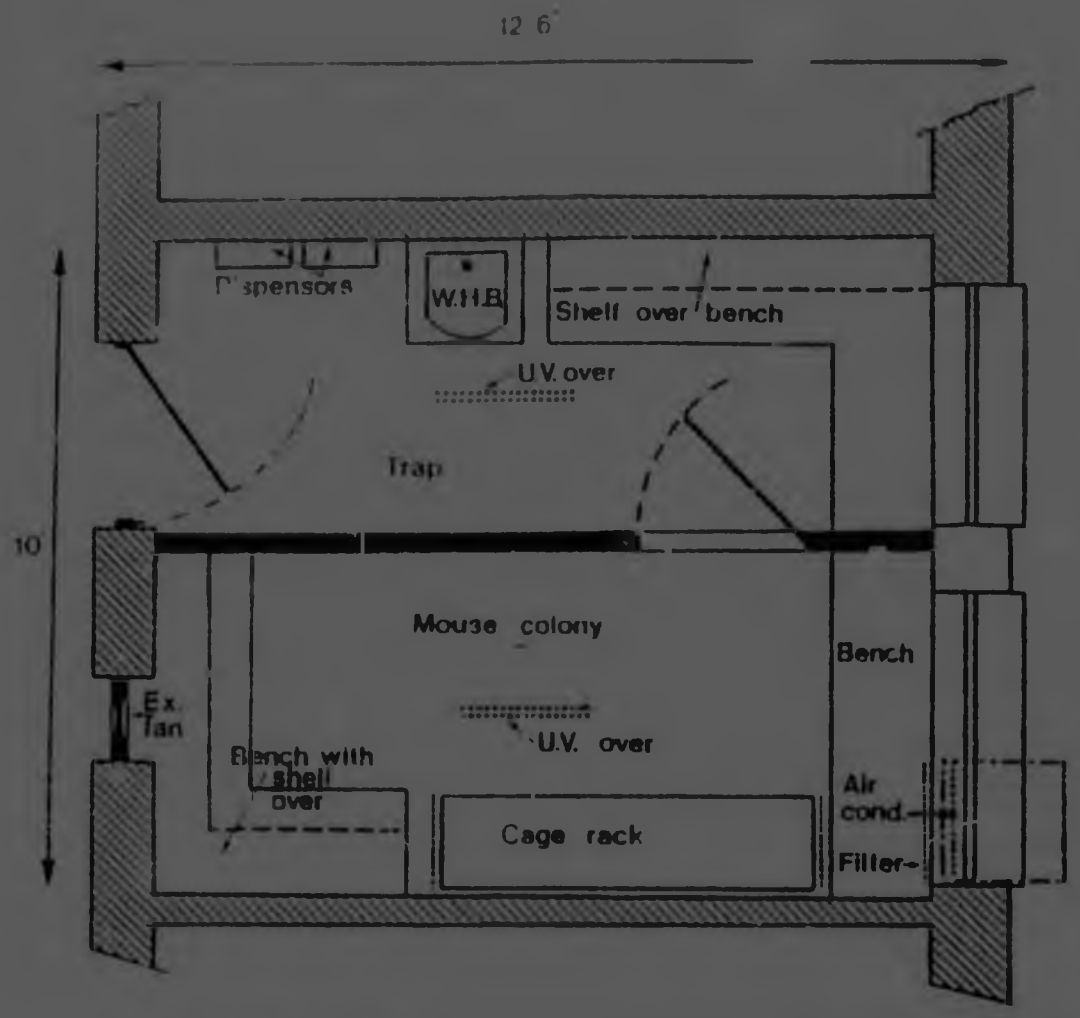

...IAL of SPF - 4 environment in which nude mice were ...oused.

...nt cages with metal meshed tops were washed, ... 1 : 750 Hibitane for 24 hours and then dried for a ... hours under ultraviolet light. Steril..., auto- ...laved rat pell..., water and vermiculite (bedding) were stored ... ready-to-use packets under the ultraviolet light.

ANIMAL MAINTENANCE

...intenance was minimal, the SPF - 4 environment only being ...ed when essential. The sterile water was changed twice ..., the cages, food and vermiculite once a week. The addition ... vitamin supplements and antibiotics to the water was unnecessary. ... housed under these conditions were healthy and several ... for ... months, while nude mice housed under

conventional animal colony [illegible]

Sporadic eye abscesses were a minor proble[illegible]. [illegible] fected eyes appeared otherwise healthy and the[illegible]t tr[illegible] lancing and cleaning of the abscesses which then [illegible]eldom [illegible] The animals were placid a[illegible]d easy to work with and fighti[illegible] littermates rarely occurred.

5. 4 BREEDING

The nude (nu/nu) and heterozygous "hairy" (Nu/nu) mice r[illegible]pr[illegible]d prolifically and breeding posed few problems. Initially he[illegible] zygotes were crosse with heterozygotes and large litters [illegible] 18 young resulted but only a small proportion of these offsprin was nude and there was no way of recognising the "hairy" hom[illegible] gotes (Nu/Nu). Once the number of nudes had increased, nu[illegible] males were then crossed with heterozygous females. [illegible] litters were produced and according to the principles of Mende[illegible] genetics half the offspring were hairy heterozygotes while [illegible] others were nude (Fig. 9).



Fig. 9 One week old litter produced as a result of matin[illegible] Nu/nu female with a nu/nu male. The nude offsprin[illegible] can be readily identified.

The hairy offspring were born slightly larger than the nudes, and grew more rapidly and could be separated from their mothers by the age of three weeks, while nude offspring were weaned one week later.

Pritchard and Micklem (1974) indicated that nude offspring derived from heterozygous females received some normal thymic influence *in utero*. Therefore, for nude mice to be free of possible thymic influence, homozygous recessive mice were mated so that the offspring were at least one generation removed from any possible thymic influence. Mating homozygous recessive (nu/nu) mice has the additional advantage that all the offspring are nude. All of the nude females used for breeding (Fig. 10) produced litters but not all were capable of feeding their young. For this reason, the nude mothers who produced milk were identified and used repeatedly.



Fig. 10 Pregnant nu/nu mouse two days before parturition.

Foster feeding using heterozygous females was not always successful. Nude females generally produced litters of six to eight though litters of up to 16 were observed. However, when the litters were larger than eight, the mothers frequently killed some of the young and cannibalisation of an entire litter of nude homozygotes

was not uncommon. In mixed litters homozygous nude mice were much more susceptible to cannibalism than their heterozygous littermates (Ediger and Giovanella, [illegible]).

5. 5 INDUCTION OF T[illegible]

In order to produce tumours in the nude mouse, rapidly growing healthy cells from nine of the continuous human oesophageal carcinoma lines as well as from four nude mouse passaged lines were removed from flasks by trypsinisation. Approximately 2×10^{6} cells in 0,25 ml of MEM without FCS were inoculated subcutaneously through a 20g needle into either the suprascapular or flank regions of adult (six weeks and older) male and female athymic nude mice. Generally four to eight littermates were inoculated with the same cell line and higher tumour take rates were obtained when the mice were inoculated at an early age. Three mice received bilateral inoculations of two different cell lines. While a single inoculation was the routine procedure adopted, some mice received repeated inoculations of the same cell line and animals in which no tumour growth was noted over lengthy periods were occasionally injected at a different site with cells of another continuous line. Some tumours resulted from this repeated inoculation. All inoculated mice were examined weekly for up to eight months to detect any signs of tumour development. The time of tumour appearance was noted and the variable latency periods recorded.

5. 6 TUMOUR REMOVAL

Tumour bearing nude mice were anaesthetised by intraperitoneal injection through a 25g needle of 0,25 ml Sagatal (Pentobarbitone Sodium - Maybaker) diluted 1 : 10 with sterile normal saline. Generally five to ten minutes elapsed before the anaesthetic took effect. The skin overlying the tumour was then swabbed with ten per cent ethyl alcohol and an incision made. The tumour was dissected away from the surrounding tissue, the main vessels supplying it cut and the tumour removed. Providing the tumour was

well encapsulated and had not infiltrated other organs, bleeding was minimal and the incision was sutured using Ethichrome No. 3. Post-operatively, the animals were wrapped up and kept warm and generally survived the trauma of surgery. Some animals were observed for six months after tumour removal. In other instances, where tumours had invaded through the thoracic or abdominal walls, or into adjacent bone, the animals were sacrificed.

All tumours were examined and the extent of the capsule, vascularity, colour and amount of adipose tissue present noted. Tumour specimens were routinely prepared for light microscopy in order to obtain histological confirmation of their malignant nature. The tumour specimens were graded with respect to degree of differentiation by Drs. Pirie and Akocjee of the Department of Pathology of the University of Natal. All freshly removed tumour specimens were also prepared for and examined by transmission electron microscopy (Chapter 6. 2) and sections of the tumours were frozen and stored at -80°C.

Widespread lymph node metastases and pronounced weight loss (Fig. 11) were evident on one occasion in the mouse designated X1 which had been inoculated with cells from the line Hcu 18.



Fig. 11 Emaciated appearance and enlarged lymph nodes in nude mouse four months after the inoculation of Hcu 18 cells.

The animal was sacrificed and specimens of liver, spleen, lung and kidney as well as all obviously involved lymph nodes were removed for histological examination.

5.7 [illegible] CULTURE OF TUMOURS GROWN IN [illegible]

Samples of all of the tumours successfully grown in nude mice were cultured either in flasks or on coverslips using the explant technique described in Chapter [illegible] 1. 1. Care was taken to strip off as much of the connective tissue capsule as possible and to dissect out any blood vessels when initiating the cultures in order to keep fibroblast growth to a minimum. The tumour specimens grew rapidly (within one week of culture initiation) and repeated subculturing (Chapter [illegible] 5) was possible. Primary cultures of the nude mouse passed tumour cells and early subcultures of these cells from several specimens were examined by both transmission and scanning electron microscopy. After two or three passages *in vitro*, cultures of the nude mouse passed tumour cells were frozen and stored at -80°C.

6 MATERIALS AND METHODS

PREPARATION OF CELLS FOR MICROSCOPY

6.1 LIGHT MICROSCOPY

6.1.1 In vivo specimens

Portions of all 46 resected oesophageal carcinomas, as well as 39 nude mouse tumour specimens were fixed in ten per cent formalin immediately after removal, dehydrated through graded alcohols, and embedded in paraffin wax. Sections (6 - 7 um thick) were stained routinely with haematoxylin and eosin (Humason, 1972).

Twelve human tumour specimens were examined in more detail and the stains used included two per cent Toluidine Blue (Humason, 1972) and 0,5 per cent Chrysoidin Y (Humason, 1972) to identify mast cells by their metachromatic staining reactions.

6.1.2 Cultured cells

Cultured normal and malignant human oesophageal cells as well as nude mouse passaged cells were grown in plastic flasks or on chamber slides or coverslips. The adherent cells were rinsed with pre-warmed Hank's BSS (37°C), fixed in ten per cent formalin for periods ranging from two to 48 hours and then rinsed thoroughly in tap water before being stained. A routine haematoxylin and eosin stain was performed on all continuous lines and some primary cultures of normal and malignant oesophageal cells.

In order to demonstrate the presence of lipid material, cultured cells on slides or in flasks were fixed and rinsed as above and stained for 20 minutes in three per cent freshly made up Scarlet R in 70 per cent ethyl alcohol. The cells were then rinsed in three changes of distilled water, counterstained with haematoxylin, and mounted in glycerol.

Cells from most specimens were also fixed in five ml May-Grunewald Solution (0,3 per cent in methanol) for ten minutes, rinsed with Sorenson's phosphate buffer at pH 6,8 and then stained with ten per cent Giemsa (Gurr's Rbu) in Sorenson's buffer for five to seven minutes, before being rinsed in running tap water and examined.

6.2 TRANSMISSION ELECTRON MICROSCOPY

6.2.1 In vivo specimens

Twelve freshly removed resected oesophageal carcinoma specimens, three specimens of apparently normal oesophageal mucosa and 30 specimens of tumours grown in nude mice as a result of the inoculation of human oesophageal carcinoma cells were roughly sliced and small pieces immediately placed in five ml Karnovsky's (1965) paraformaldehyde-glutaraldehyde fixative in pH 7,2 in 0,2M sodium cacodylate buffer and transported in this manner. On arrival in the laboratory all specimens were diced finely using scalpel blades, and then placed in fresh fixative for a further 45 minutes at room temperature, before being processed as follows:

washed in 0,2M cacodylate buffer	2 X 10 minutes
1% OsO_4 in distilled water at 4°C	60 minutes
washed in 0,2M cacodylate buffer	2 X 10 minutes
70 per cent ethyl alcohol	30 minutes
90 per cent ethyl alcohol	30 minutes
absolute alcohol I	30 minutes
absolute alcohol II	30 minutes
propylene oxide	30 minutes
araldite : propylene oxide 50 : 50	30 minutes
araldite I at 60°C	2 hours
araldite II at 60°C	2 hours
araldite at 60°C (embedded in beem capsules)	24 hours

Ultra-thin sections (60 - 80 nm) of the embedded specimens were cut on a Cambridge Huxley ultramicrotome and mounted on 200 mesh Veco copper grids. Thick sections were stained with one per cent Toluidine Blue in a 50 : 50 distilled water : acetone solution

Cells from most specimens were also fixed in five ml May-Grunswald Solution (0,3 per cent in methanol) for ten minutes, rinsed with Sorenson's phosphate buffer at pH 6,8 and then stained with ten per cent Giemsa (Gurr's R66) in Sorenson's buffer for five to seven minutes, before being rinsed in running tap water and examined.

6.2 TRANSMISSION ELECTRON MICROSCOPY

6.2.1 In vivo specimens

Twelve freshly removed resected oesophageal carcinoma specimens, three specimens of apparently normal oesophageal mucosa and 30 specimens of tumours grown in nude mice as a result of the inoculation of human oesophageal carcinoma cells were roughly sliced and small pieces immediately placed in five ml Karnovsky's (1965) paraformaldehyde-glutaraldehyde fixative in pH 7,2 in 0,2M sodium cacodylate buffer and transported in this manner. On arrival in the laboratory all specimens were diced finely using scalpel blades, and then placed in fresh fixative for a further 45 minutes at room temperature, before being processed as follows:

washed in 0,2M cacodylate buffer	2 X 10 minutes
1% OsO_4 in distilled water at 4°C	60 minutes
washed in 0,2M cacodylate buffer	2 X 10 minutes
70 per cent ethyl alcohol	30 minutes
90 per cent ethyl alcohol	30 minutes
absolute alcohol I	30 minutes
absolute alcohol II	30 minutes
propylene oxide	30 minutes
araldite : propylene oxide 50 : 50	30 minutes
araldite I at 60°C	2 hours
araldite II at 60°C	2 hours
araldite at 60°C (embedded in beem capsules)	24 hours

Ultra-thin sections (60 - 80 nm) of the embedded specimens were cut on a Cambridge Huxley ultramicrotome and mounted on 300 mesh Veco copper grids. Thick sections were stained with one per cent Toluidine Blue in a 50 : 50 distilled water : acetone solution

containing ten per cent borax. Thin sections on grids were stained with one per cent uranyl acetate followed by Reynold's (1963) lead citrate.

All sections were viewed using the Zeiss EM 10 B in the Physiology Department of the University of Natal. Photographs were taken at 60kV using Kodak electron image film (4463) which was subsequently developed for four minutes in D 19.

6. 2. 2 Cultured cells

6. 2. 2. 1 Cells removed from flasks and pelleted

Many authors (Leak et al., 1967, Kumegawa et al., 1968, Keen et al., 1972, Foa and Aubert, 1977) have prepared cultured cells for electron microscopy by removal from the flasks and centrifugation. In this study flasks containing cells of the lines Hcu 10, Hcu 13 and Hcu 18 were shaken to detach mitosing and loosely adherent cells and the medium containing these cells decanted and centrifuged at 1200 r.p.m. for five minutes. As the cells obtained in this way (mainly mitotic and desquamated cells) were not representative of the culture as a whole, cells from each of these lines were trypsinised and then centrifuged in an attempt to obtain a more representative cell sample, though the destructive effects of trypsin had then to be considered. The cell pellets were fixed in Karnovsky's fixative in 0,2M cacodylate and processed in a similar way to the in vivo specimens (6. 2. 1). Between each step the fluid (fixative, buffer, alcohol, etc.) was removed by centrifugation and aspiration.

6. 2. 2. 2 Cells growing in plastic flasks

Cultured normal, malignant and nude mouse passaged oesophageal carcinoma cells were fixed, dehydrated, embedded and sectioned in the flasks in which they were growing. The technique used was a modification of those described by Keen et al., 1973, and Perre and Foncin, 1977, has been reported by Robinson and Gregory (1977) and is summarised below.

containing ten per cent borax. Thin sections on grids were stained with one per cent uranyl acetate followed by Reynolds's (1963) lead citrate.

All sections were viewed using the Zeiss EM 10 B in the Physiology Department of the University of Natal. Photographs were taken at 60kV using Kodak electron image film (4463) which was subsequently developed for four minutes in D 19.

6. 2. 2 Cultured cells

6. 2. 2. 1 Cells removed from flasks and pelleted

Many authors (Leak et al., 1967, Kumegawa et al., 1968, Keen et al., 1973, Foa and Aubert, 1977) have prepared cultured cells for electron microscopy by removal from the flasks and centrifugation. In this study flasks containing cells of the lines Hcu 10, Hcu 13 and Hcu 14 were shaken to detach mitosing and loosely adherent cells and the medium containing these cells decanted and centrifuged at 1200 r.p.m. for five minutes. As the cells obtained in this way (mainly mitotic and desquamated cells) were not representative of the culture as a whole, cells from each of these lines were trypsinised and then centrifuged in an attempt to obtain a more representative cell sample, though the destructive effects of trypsin had then to be considered. The cell pellets were fixed in Karnovsky's fixative in 0,2M cacodylate and processed in a similar way to the *in vivo* specimens (6. 2. 1). Between each step the fluid (fixative, buffer, alcohol. etc.) was removed by centrifugation and aspiration.

6. 2. 2. 2 Cells growing in plastic flasks

Cultured normal, malignant and nude mouse passaged oesophageal carcinoma cells were fixed, dehydrated, embedded and sectioned in the flasks in which they were growing. The technique used was a modification of those described by Keen et al., 1973, and Perre and Foncin, 1977, has been reported by Robinson and Gregory (1977) and is summarised below.

The medium bathing apparently healthy primary explant cultures and semi-confluent or confluent cultures of oesophageal carcinoma cells was changed one day prior to processing for electron microscopy. Twenty-four hours later the selected flasks were rinsed twice with Hank's BSS at pH 7,8 - 7,2 at room temperature to remove dead cells, debris and all traces of FCS as any free protein would be precipitated by the fixative used. The cells were fixed in one per cent glutaraldehyde (Polaron 25 per cent w/w) in Hank's BSS at room temperature for 20 - 40 minutes and then rinsed twice in Hank's BSS. The cells in the flasks were sonicated for 30 minutes, rinsed in Hank's BSS and then dehydrated rapidly (ten minutes in each solution) through graded alcohols. As propylene oxide dissolved the flasks, a 50 : 50 alcohol : araldite mixture was then added and replaced by araldite I. The flasks containing araldite were incubated for 90 minutes at 50°C. The araldite was then changed and incubation continued at 60°C for 36 - 48 hours until polymerisation was complete.

The tops of the plastic flasks were cut off using a heated wire and 5 - 10mm blocks of the araldite-embedded cells on the plastic substrate cut using a small handsaw. The blocks were trimmed and vertical ultrathin (60 - 80nm) sections of the cells cut on a Cambridge Huxley ultramicrotome with the araldite on one side and the plastic of the flask on the other. These sections were mounted, stained and viewed as in 6. 2. 1. Both primary and continuous cultures were studied and cells from each of the ten human oesophageal carcinoma cell lines were investigated on at least five occasions.

6. 3 SCANNING ELECTRON MICROSCOPY

6. 3. 1 In vivo specimens

Four resected human oesophageal carcinoma specimens, two nude mouse carcinoma specimens and four superficial biopsy specimens each of normal human oesophageal mucosa and oesophageal mucosa containing ulcerating carcinomas were rinsed, trimmed and fixed

overnight in four per cent glutaraldehyde in Hank's BSS. Thereafter the specimens were dehydrated through 70 per cent, 90 per cent and absolute alcohol and critical point dried in specimen baskets in a Hitachi HCP I critical point dryer. Seven purges of CO_2 were applied over a period of one and a half to two hours and the final critical temperature of 45°C maintained for at least five minutes. Venting after drying was completed in ten minutes.

Immediately after drying the specimens were attached to stubs using double sided sellotape, coated with 20 nm gold in a Polaron E 5100 cool sputter coater and viewed using a Jeol JSM-35 scanning electron microscope and a 100 µm aperture. Accelerating voltages of 10 - 20 kV were used, the beam current was 20 nA and the tilt was not varied.

6.2.2 Cultured cells

The technique described by Evans et al (1980), Robinson et al. (1980b) and Maistry et al. (1980) was used in the current study and can be summarised as follows: healthy cell cultures grown on coverslips were prepared for scanning electron microscopy 48 - 72 hours after initiation of the cultures depending on the level of confluency reached. The cells were rinsed in Hank's BSS, fixed for one hour in four per cent glutaraldehyde in Hank's BSS for 20 - 40 minutes at room temperature, rinsed, dehydrated through graded alcohols and critical point dried using a specially designed drier (Evans et al., 1980) in a Hitachi HCP I dryer. Five two-minute purges were used over a period of one hour and the critical temperature of 45°C maintained for at least five minutes. Venting after drying was completed in ten minutes and the overall time in the dryer was at least 75 minutes.

Coverslips were attached to stubs using silver paint and cells coated with 60 : 40 gold : palladium from a distance of 10cm in a Jeol JFC 4 vacuum evaporator and viewed immediately using a Jeol JSM-35 scanning electron microscope and a 300 µm aperture. Accelerating voltages of 10 - 25 kV were used, the beam current was 1 nA and the tilt was varied from 0° - 60°.

RESULTS

GROWTH AND BEHAVIOUR OF APPARENTLY NORMAL OESOPHAGEAL CELLS IN VITRO

All 20 specimens of apparently normal human oesophageal mucosa that were cultured *in vitro* using the explant technique grew well regardless of whether the specimens were obtained from adult female or old or young donors. There was, however, no growth of epithelial cells when mucosal specimens were transferred to fresh tissue cultures. As all of the human mucosal specimens examined in this investigation revealed strikingly similar growth patterns, they will be grouped together for ease of description of their growth patterns *in vitro*.

7.1 GROWTH RATE AND PATTERN

The normal oesophageal cells grew rapidly from the explants of oesophageal mucosa and good epithelial growth was generally visible within two to three days of culture onset. The epithelial cells grew in continuous sheets around the explants from which they originated. Fibroblasts present in five of the specimens migrated more rapidly from the mucosal explants than did the epithelial cells and surrounded the regions of epithelial growth (Fig. 12). Large, flattened desquamated epithelial cells were present at intervals on the plastic and glass substrate used but appeared incapable of division and did not develop into colonies of multiplying cells. The growing epithelial cells which originated from the explants were poorly refractile, somewhat regular in size and tightly adherent to one another though some more loosely adherent cells were present near the growing edges of the cell sheets (Fig. 13). Many cells displayed nuclei in which nucleoli were sometimes evident. There was little evidence of cell division and no ciliated surface cells were observed by phase contrast microscopy. The epithelial cultures were initi-



Fig. 12 Confluent sheet of normal epithelial cells (E) growing from explanted normal oesophageal mucosa after two weeks in vitro. Whorls of fibroblasts (F) are present adjacent to the epithelial cells. Bar = 1 cm



Fig. 13 Interference micrograph of the regular, adherent epithelial cells present at the periphery of a sheet of normal human oesophageal cells after five days in vitro. Bar = 100 μm

layered and division probably took place in the deeper layers. Long branching processes were evident between the epithelial cells in many of the cultures studied. Such processes terminated near the growing edges of the epithelial sheets and did not make contact with the few peripheral fibroblasts. The processes were refractile and differed in appearance from those of elongated fibroblasts (Fig. 14).

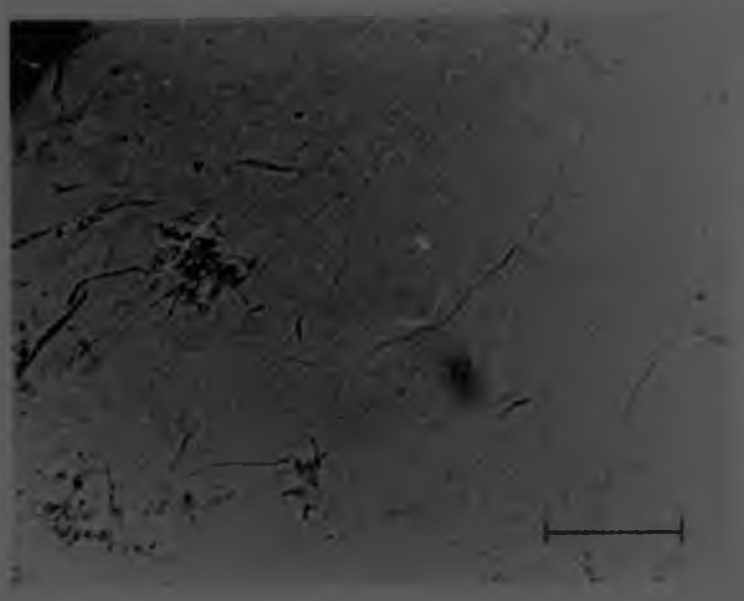

Fig. 14 Interference micrograph showing epithelial cells surrounding an explant of normal human oesophageal mucosa. Refractile processes extend over and between the epithelial cells. Bar = 100 μm

7.2 SUBCULTURING

The epithelial cells did not detach readily upon trypsinisation and it was impossible to obtain a single cell suspension as many cells remained clustered. Such groups of cells did not readily reattach to new flasks. Where passaging was successfully performed, the normal epithelial cells initially grew well, although fibroblast overgrowth was a problem in four specimens. Some normal oesophageal cells were subcultured five times before detaching from the flasks and dying. Many primary cultures became almost confluent in the flasks where they were growing and

layered and division probably took place in the deeper layers. Long branching processes were evident between the epithelial cells in many of the cultures studied. Such processes terminated near the wing edge of the epithelial sheets and did not make contact with the few peripheral fibroblasts. The processes were refractile and differed in appearance from those of elongated fibroblasts (Fig. 14).

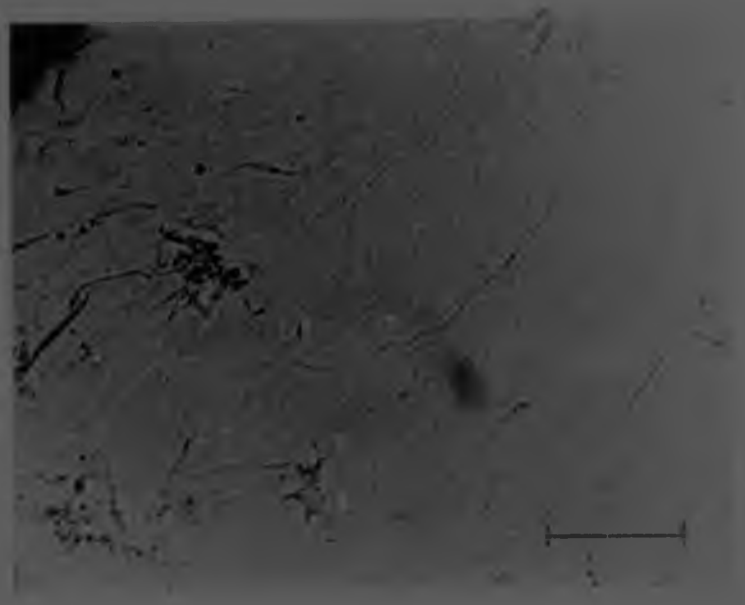

Fig. 14 Interference micrograph showing epithelial cells surrounding an explant of normal human oesophageal mucosa. Refractile processes extend over and between the epithelial cells. Bar = 100 μm

7. 2 SUBCULTURING

The epithelial cells did not detach readily upon trypsinisation and it was impossible to obtain a single cell suspension as many cells remained clustered. Such groups of cells did not readily reattach to new flasks. Where passaging was successfully performed, the normal epithelial cells initially grew well, although fibroblast overgrowth was a problem in four specimens. Some normal oesophageal cells were subcultured five times before detaching from the flasks and dying. Many primary cultures became almost confluent in the flasks where they were growing and

persisted for up to ten weeks. With increasing [illegible], the growth rate dropped and cell desquamation increased until finally all cells detached from the substrata.

All cultured normal oesophageal cells showed [illegible] and could be distinguished morphologically from cultured neoplastic cells.

RESULTS

IN VITRO PROPERTIES OF RESECTED HUMAN LARYNGEAL CARCINOMA SPECIMENS

The first cells to migrate from the explants were macrophages and white blood cells, followed by fibroblasts. Blood cells generally died and disappeared within three days and the macrophages a day or two later, while the fibroblasts persisted for varying lengths of time in spite of attempts to remove them.

In some cultures, epithelial growth was observed after 14 hours, whereas epithelial or fibroblast growth was evident only after seven days in other specimens.

8.1 CLASSIFICATION OF RESECTED TUMOUR SPECIMENS

The cultured tumour specimens were subdivided into four categories which were determined by some of their growth properties *in vitro* and defined as follows:

I Fibroblast growth only. No evidence of epithelial cell growth at any stage.

II Epithelial cells were present in sheets adjacent to the explants but were never successfully subcultured.

IIA Slow initial growth of epithelial cells.

IIB Rapid initial growth of epithelial cells.

Well-developed fibroblasts surrounded and frequently overgrew the epithelial cells.

III Epithelial cells formed clearly defined confluent sheets of cells which persisted *in vitro* for periods ranging from one to eight months. Subculture was possible but the cells survived only two to three passages.

IV. Continuous epithelial cell lines which could be successfully subcultured at regular intervals.

The numbers of specimens which fell into each category are given in Table 5. Out of a total of 46 tumour specimens received and cultured, in 36,[illegible] per cent were successfully subcultured but eight reached only Stage III, leaving eight continuously growing epithelial cell lines, this being a success rate of 17,4 per cent. Epithelial cells were observed in 28 (64,[illegible] per cent) of the cultured specimens of resected oesophageal carcinomas.

TABLE 5 RESULTS OF THE TISSUE CULTURE OF RESECTED TUMOUR SPECIMENS

Category	Characteristics	Number of specimens	Percentage of specimens
I	Fibroblasts only	7	15,2
IIA	Slow epithelial growth, no subculture	18	39,1
IIB	Rapid epithelial growth, no subculture	5	10,9
III	Substantial epithelial growth, subculture possible	8	17,4
IV	Continuous epithelial tumour cell line	8	17,4
		46	100

The data obtained from histopathological examination (degree of tumour differentiation and local lymphocyte infiltration) and patient progress at six months, are given in Tables 8 to 9 and 11 for each specimen of resected oesophageal carcinoma.

5.1.1 CATEGORY I

Most of the specimens (Table 6) that fell into this category were hard or scirrhous tumours. Specimen Hcu 29 was contaminated with fungus and discarded after two weeks *in vitro*, while cells from

IV Continuous epithelial cell lines which could be successfully subcultured at regular intervals.

The numbers of specimens which fell into each category are given in Table 5. Out of a total of 46 tumour specimens received and cultured, 16 or 34,8 per cent were successfully subcultured but eight reached only Stage III, leaving eight continuously growing epithelial cell lines, this being a success rate of 17,4 per cent. Epithelial cells were observed in 39 (84,8 per cent) of the cultured specimens of resected oesophageal carcinomas.

TABLE 5 RESULTS OF THE TISSUE CULTURE OF RESECTED TUMOUR SPECIMENS

Category	Characteristics	Number of specimens	Percentage of specimens
I	Fibroblasts only	7	15,2
IIA	Slow epithelial growth, no subculture	18	39,1
IIB	Rapid epithelial growth, no subculture	5	10,9
III	Substantial epithelial growth, subculture possible	8	17,4
IV	Continuous epithelial tumour cell line	8	17,4
		46	100

The data obtained from histopathological examination (degree of tumour differentiation and local lymphocyte infiltration) and patient progress at six months, are given in Tables 6 to 9 and 11 for each specimen of resected oesophageal carcinoma.

8. 1. 1 CATEGORY I

Most of the specimens (Table 6) that fell into this category were hard or scirrhous tumours. Specimen Hou 29 was contaminated with fungus and discarded after two weeks *in vitro*, while cells from

IV Continuous epithelial cell lines which could be successfully subcultured at regular intervals.

The numbers of specimens which fell into each category are given in Table 5. Out of a total of 46 tumour specimens received and cultured, 16 or 34,8 per cent were successfully subcultured but eight reached only Stage III, leaving eight continuously growing epithelial cell lines, this being a success rate of 17,4 per cent. Epithelial cells were observed in 39 (84,8 per cent) of the cultured specimens of resected oesophageal carcinomas.

TABLE 5 RESULTS OF THE TISSUE CULTURE OF RESECTED TUMOUR SPECIMENS

Category	Characteristics	Number of specimens	Percentage of specimens
I	Fibroblasts only	7	15,2
IIA	Slow epithelial growth, no subculture	18	39,1
IIB	Rapid epithelial growth, no subculture	5	10,9
III	Substantial epithelial growth, subculture possible	8	17,4
IV	Continuous epithelial tumour cell line	8	17,4
		46	100

The data obtained from histopathological examination (degree of tumour differentiation and local lymphocyte infiltration) and patient progress at six months, are given in Tables 6 to 9 and 11 for each specimen of resected oesophageal carcinoma.

8. 1. 1 CATEGORY I

Most of the specimens (Table 6) that fell into this category were hard or scirrhous tumours. Specimen Hcu 29 was contaminated with fungus and discarded after two weeks *in vitro*, while cells from

TABLE 6 CATEGORY I RE[illegible] - HISTOPATHOLOGY AND PATIENT SURVIVAL

Specimen number	Sex	Age	Differentiation	Lymphocyte infiltration	Prognosis at 6 months
Hcu 14	M	60	well	+	alive
Hcu 17	-	-	poor	-	unknown
Hcu 20	F	50	well	-	unknown
Hcu 26	M	60	well	-	unknown
Hcu 29	M	52	moderate	+++	alive
Hcu 45	F	29	well	-	alive - but re-admitted
Hcu 46	F	50	well	-	presumed dead

the other specimens survived for an average period of four to six months *in vitro* before senescence occurred. Cells from specimens Hcu 14 and Hcu 26 initially grew very slowly but growth rate increased after subculturing.

Fibroblasts from specimens Hcu 14, Hcu 20, Hcu 26 and Hcu 46 were sucressfully subcultured and grew well *in vitro*. Some cells displayed branching irregular processes, while others were small and uniform in outline. The cells from specimen Hcu 17 produced much debris, grew with haphazard orientation and displayed many branched processes. Several cells showed flattened central regions and paranuclear lipid droplets as demonstrated by the use of Scarlet R.

Subcultured fibroblasts from specimens Hcu 20 and Hcu 46 were orientated in bundles, producing a whorled effect while the fibroblasts in cultures of the specimens Hcu 14 and Hcu 46 grew in irregular aggregates.

8. 1. 2 CATEGORY IIA

Cells from the 18 specimens (Table 7) which fell into this category on the basis of their growth rate and pattern generally did not survive for long periods *in vitro*. The epithelial cells from

TABLE 7 CATEGORY IIA RESECTED SPECIMENS - HISTOPATHOLOGY AND PATIENT SURVIVAL

Specimen number	Sex	Age	Differen-tiation	Lymphocyte infiltration	Prognosis at 6 months
Hcu 22	M	67	well	+	alive
Hcu 23	F	58	moderate	++	alive
Hcu 25	F	45	well	+++	alive
Hcu 36	M	52	poor	-	unknown after 2 months
Hcu 38	M	52	moderate	-	alive
Hcu 40	M	35	moderate	++	alive
Hcu 41	M	56	well	+	alive
Hcu 42	F	52	well	-	post operative death
Hcu 43	M	40	-	-	unknown
Hcu 44	M	69	well	+	alive
Hcu 47	F	26	moderate	++	alive
Hcu 48	M	59	moderate	+	alive
Hcu 49	M	68	well	+++	alive at 4 months
Hcu 52	M	49	moderate	+	alive at 5 months
Hcu 53	M	09	well	-	unknown
Hcu 54	M	49	well	+	unknown
Hcu 56	M	53	moderate	++	alive at 3 months
Hcu 57	M	41	well	++	swallowing well

[illegible] imens disappeared within a month, while the fibroblasts [illegible] overgrew or replaced them occasionall. persisted for much longer periods.

Both granular and agranular cells of varying form and size were observed.

In cultures of specimen Hcu 25, some epithelial cells became increasingly large, multinucleated and vacuolated. The size increase appeared to occur as a result of cell fusion and many cells showed a syncytial appearance (Fig. 15). The giant cells became increasingly vacuolated and showed a "lacey" appearance while remaining essentially agranular.



Fig. 15 Interference micrograph of a large, irregular, vacuolated syncytial cell in a three week old culture of Hcu 25 cells. Bar = 100 µm

In most of the specimens, stratification of the epithelial cells which remained close to the initial explants was evident.

Involved lymph nodes from the same patients from whom specimens Hcu [illegible] and Hcu 23 were obtained were also cultured and fell into Category IIA on the basis of their growth rates and the cell types

present. The large irregular epithelial cells which grew from these specimens (Fig. 1[illegible]) possessed dense nuclear regions and were surrounded by pale peripheral regions with fine radiating processes. The large cells were loosely adherent and small l[illegible] dense cells were present at intervals. Angular overlapping fibroblasts present from an early stage eventually replaced the unusual cells.

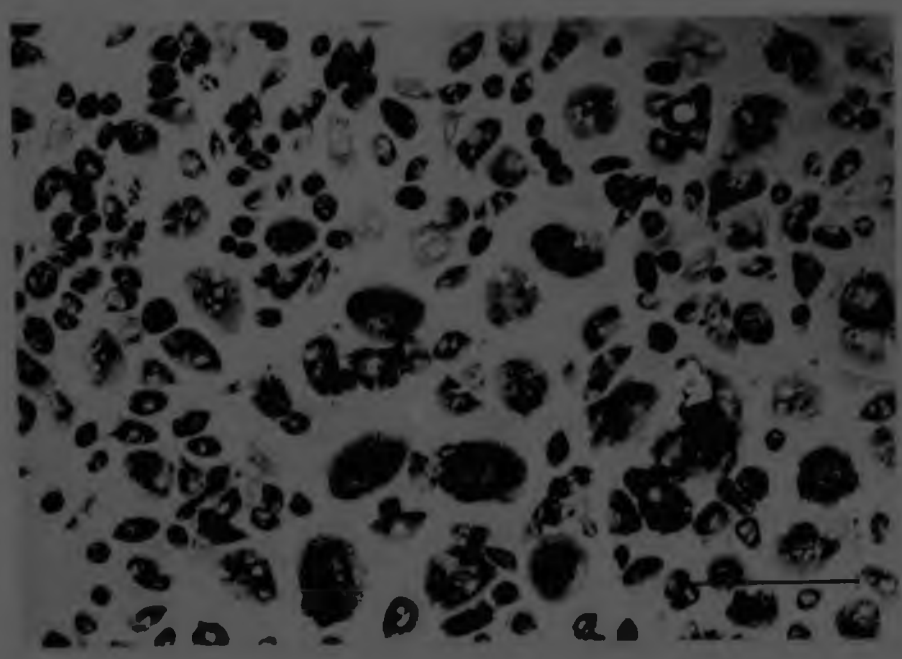

Fig. [illegible] Interference micrograph showing the large, irregular, epithelial cells, containing centrally located dense material, which grew rapidly in a culture initiated from a lymph node metastasis in the patient from whom specimen Hcu [illegible]2 was obtained. Bar = 100 μm

3. 1. 3 CATEGORY IIB

Cultured specimens that fell into this category (Table 8) initially grew rapidly but survived for only short periods in vitro. This was probably not related directly to the growth potential of the tumour specimens as four of the five specimens in this category were lost as a result of fungal contamination. Fungal spores originating in the patients and were present in flasks from the time of culture onset in spite of Amphotericin B treatment. The

TABLE 9 CATEGORY IIB REJECTED SPECIMENS - HISTOPATHOLOGY AND PATIENT SURVIVAL

Specimen number	Sex	Age	Differen-tiation	Lymphocyte infiltration	Prognosis at 6 months
Hcu 9	M	60	well	+	alive
Hcu 24	M	52	well	++	alive
Hcu 27	F	56	well	++	alive with recurrence
Hcu 51	M	41	moderate	+	alive with recurrence
Hcu 55	M	38	poor	-	unknown

epithelial cells in specimen Hcu 55 were overgrown and replaced by fibroblasts. All of the tumour specimens classified as category IIB were soft and easy to dice. Areas of necrosis were frequently present and numerous loosely adherent cells desquamated from the tumour pieces.

8. 1. 4 CATEGORY III

Specimens that were allocated to this category (Tables 9 and 10) were characterised by good growth of epithelial cells (Fig. 17) which grew in continuous sheets around the explants and survived for longer periods *In vitro* than did those of the Category II specimens. None of the specimens in this category reached the stage of being classified as a continuous cell line, though, according to Paul (1975) and Schaeffer (1979) they could be designated as primary cell lines since they had been successfully passaged. The term "cell line" implies that cultures from it consist of numerous lineages of cells originally present in the primary culture (Schaeffer, 1979).

Some properties of the epithelial cells growing from specimens in this category are summarised in Table 10. Large (50-90um) mononucleate giant cells with occasional processes were present in cultures derived from several specimens (Fig. 18). The nuclei of

TABLE 5 CATEGORY III RESECTED SPECIMENS - HISTOPATHOLOGY AND PATIENT SURVIVAL

Specimen number	Sex	Age	Differentiation	Lymphocyte infiltration	Prognosis at 6 months
Hcu 6	M	58	well	++	death, irresectable tumour
Hcu 8	M	48	well	++	death, with recurrence
Hcu 16	M	38	well	++	alive
Hcu 21	M	57	moderate	+	alive with recurrence
Hcu 38	M	58	moderate	+	alive with recurrence
Hcu 30	M	41	well	++	post operative death
Hcu 31	M	50	poor	+	alive with recurrence
Hcu 32	M	52	well	++	alive



Fig. 17 Continuous sheet of agranular epithelial cells in a 12 day old culture of the rapidly growing specimen, Hcu 31, as seen by interference microscopy. Bar = 100 µm

TABLE 9 CATEGORY III [illegible] - HISTOPATHOLOGY AND PATIENT SURVIVAL

Specimen number	Sex	Age	Differentiation	Lymphocyte infiltration	Prognosis at 6 months
Hcu 6	M	58	well	++	death, irresectable tumour
Hcu 8	M	48	well	++	death, with recurrence
Hcu 16	M	38	well	++	alive
Hcu 21	M	57	moderate	+	alive with recurrence
Hcu 38	M	58	moderate	+	alive with recurrence
Hcu 30	M	41	well	++	post operative death
Hcu 31	M	50	poor	+	alive with recurrence
Hcu 32	M	52	well	++	alive



Fig. 17 Continuous sheet of agranular epithelial cells in a 12 day old culture of the rapidly growing specimen, Hcu 31, as seen by interference microscopy. Bar = 100 µm

TABLE 10 SOME IN VITRO FEATURES OF CATEGORY II$_1$ SPECIMENS

Specimen number	Growth rate	Type of epithelial cells	Giant cells	Number of sub-cultures	Length of time in vitro	Reasons lost
Hcu 6	rapid	sheet of small, agranular cells	++	2	2½ months	bacterial contamination
Hcu 8	rapid	sheet of small, very granular cells	++	2	2½ months	bacterial contamination
Hcu 16	slow	islands and sheets of small densely packed very granular cells	-	3	8 months	electrical fault
Hcu 21	rapid	islands of small cells with few granules	+	1	4 months	senescence
Hcu 28	slow	islands of small, densely packed slightly granular cells	-	3	2 months	bacterial contamination
Hcu 30	slow	cords of small agranular cells	+	2	2 months	electrical fault
Hcu 31	rapid	cords of small agranular cells	+	1	4 months	senescence
Hcu 32	rapid	sheets of small cells with few granules	+	2	5 months	senescence



Fig. 18 Interference micrograph of a large mononucleate giant cell (G) surrounded by smaller carcinoma cells adjacent to an explant of specimen Hcu 6. Bar = 100 µm



Fig. 19 Interference micrograph showing a giant cell from specimen Hcu 6 in the process of dividing and being replaced by smaller malignant cells. Bar = 100 µm

the giant cells did not increase in size to the same extent as the cytoplasmic volume. The giant cells increased in size and divided several times in rapid succession and were replaced by smaller cells (Fig. 19). Giant epithelial cells in cultures of specimen Hcu 30 displayed prominent multiple nuclei and were much further from the explants than the densely packed smaller cells. In cultures of specimens Hcu 30 long branching processes were evident between and overlying the adherent epithelial cells.

Fibroblast overgrowth was a serious problem in several specimens (Fig. 20). Although fibroblasts were removed several times by trypsinisation and by scraping, piling up of the epithelial cells occurred where bands of fibroblasts were present and several epithelial cells detached. The fibroblasts were resistant to trypsin and on several occasions, the epithelial cells started to detach before the fibroblasts. Daily differential trypsinisation of specimens Hcu 8 and Hcu 30 was carried out after three weeks *in vitro*. On removal of the fibroblasts the epithelial cells appeared less adherent to one another and started to spread out slightly.



Fig. 20 The boundary between malignant epithelial cells (E) and fibroblasts (F) in a two week old culture of Hcu 16 cells as evident by interference microscopy. Fibroblasts encroached on the epithelial cells which became tightly packed and showed reduced mitotic activity. Bar = 100 μm

Successful subcultures of all specimens in category III were performed, but the cells grew extremely slowly and sometimes it took several months for a state approaching confluency to be reached. Many cells seemed to become static and accumulate granules and then to grow again for brief periods. In addition, many epithelial cells did not reattach readily in new plastic flasks, and those that did attach formed slow-growing islands of epithelial cells which only grew in close proximity to other epithelial cells (Fig. 2.). Cultures were treated with autologous fibroblast-conditioned medium in a further effort to promote growth (Chapter 4. 2. 2).



Fig. 21 Interference micrograph showing a tightly packed cluster of small, slow-growing epithelial cells in a subculture of Hcu 20 cells. Bar = 100 µm

In a culture (initiated from specimen Hcu 21) which had originally showed exclusively fibroblast growth, pockets of epithelial cells appeared after nine weeks *in vitro*. These cells started to multiply rapidly and replaced the adjacent fibroblasts in a very similar way to the process by which epithelial cells replaced fibroblasts in Hcu 18 (Chapter 3. 1. 5). These cells resembled those present in the continuous sheets both in size and extent of cyto-

plasmic granularity, but were less adherent to one another. Because of their features in common, they were assumed to have the same origin as the tightly packed cells. After removal of the fibroblasts they grew in similar islands to the other epithelial cells.

8. 1. 5 CATEGORY IV

All tumour specimens that fell into this category (Table 11) adapted well to *in vitro* conditions and became continuously growing cell lines which grew well for up to four and a half years *in vitro*. The definitions for continuous cell lines vary. According to Paul (1975) for a line to be classified as continuous, the cells must have been subcultured at least 70 times at intervals of three days. Other definitions refer to the ability of the cells to grow and be passaged after storage at -80°C. In this investigation all cultures classified as cell lines were frequently (every three to five days) and easily subcultured, consisted of fairly uniform populations of epithelial cells, and could be stored at -80°C for periods ranging from two weeks to 15 months and then thawed and successfully cultured. Although all eight of the oesophageal carcinoma cell lines were derived from clinically similar resected specimens from clinically similar sites, the lines differed morphologically from one another (Figs. 22 - 30) and some features of each are summarised in Table 12.

The tumours from which the continuous cell lines were established varied in their degree of differentiation (Table 11) and in size and invasiveness (Table 12). Lines Hcu 10 (Figs. 22 and 23), Hcu 18 (Fig. 26)and Hcu 37 (Fig. 29) which were derived from poorly differentiated tumours showed similarities in morphology and growth pattern *in vitro*. The cell line Hcu 39 (Fig. 30) was also similar in behaviour to these lines. Cell lines Hcu 13 (Figs. 24 and 25), Hcu 33 (Fig. 27) and Hcu 50 exhibited similarities to one another while line Hcu 35 (Fig. 28) showed some features which were reminiscent of line Hcu 37 and others which

TABLE 11 CATEGORY I [illegible] - HISTOLOGY AND PATIENT SURVIVAL

Specimen number	Sex	Age	Differentiatio	Lymphocyte infiltration	Prognosis at 6 months
Hcu 10	F	40	poor	++	death with recurrence
Hcu 13	M	50	well	+	death with recurrence
Hcu 18	F	40	poor	+++	alive with recurrence
Hcu 33	M	45	well	+	death with recurrence
Hcu 35	M	66	well	+	death, irresectable tumour
Hcu 37	F	60	poor	++	death, irresectable tumour
Hcu 39	M	70	well	++	alive
Hcu 50	M	59	moderate	+	alive at 3 months - no further record

resembled some properties of lines Hcu 10 and Hcu 33.

The cell line Hcu 13 was particularly resistant to most of the conditions which adversely affected the other cell lines and withstood temperatures of 4°C for up to three days and survived at 20°C for two weeks. The line Hcu 33 was also resistant to temperature fluctuation while cells of the lines Hcu 35 and Hcu 39 did not grow well when the temperature was varied.

In the line Hcu 37 cell form was variable and appeared to be influenced both by temperature and pH. Under adverse conditions and in sparse cultures the cells became more elongated, while a more rounded form was typical of healthy confluent cultures.

The cell line Hcu 37 was esteblished from a biopsy specimen removed under general anaesthetic from the stomach/liver area of

TABLE 1. CATEGORY IV [illegible] SPECIMENS - HISTOPATHOLOGY AND PATIENT SURVIVAL

Specimen number	Sex	Age	Differentiation	Lymphocyte infiltration	Prognosis at 6 months
Hcu 10	F	40	poor	++	death with recurrence
Hcu 13	M	50	well	+	death with recurrence
Hcu 18	F	40	poor	+++	alive with recurrence
Hcu 33	M	45	well	+	death with recurrence
Hcu 35	M	66	well	+	death, irresectable tumour
Hcu 37	F	60	poor	++	death, irresectable tumour
Hcu 39	M	70	well	++	alive
Hcu 50	M	59	moderate	+	alive at 3 months - no further record

resembled some properties of lines Hcu 10 and Hcu 33.

The cell line Hcu 13 was particularly resistant to most of the conditions which adversely affected the other cell lines and withstood temperatures of 4°C for up to three days and survived at 20°C for two weeks. The line Hcu 33 was also resistant to temperature fluctuation while cells of the lines Hcu 35 and Hcu 39 did not grow well when the temperature was varied.

In the line Hcu 37 cell form was variable and appeared to be influenced both by temperature and pH. Under adverse conditions and in sparse cultures the cells became more elongated, while a more rounded form was typical of healthy confluent cultures.

The cell line Hcu 37 was established from a biopsy specimen removed under general anaesthetic from the stomach/liver area of

TABLE 2 [illegible] IN VITRO FEATURES OF THE CELL LINES ARISING FROM EIGHT RESECTED BLADDER CARCINOMA SPECIMENS

Specimen number	Emergence of epithelial cells	Morphology of epithelial cells	Epithelial cell growth rate	Adherence of epithelial cells	Granularity epithelial cells	Giant cells
Hcu 10	initial continuous sheet	small polygonal and larger angular forms	initially slow, then moderate	initially tight, then loose	many granules	+++
Hcu 13	initial continuous sheet	small polygonal cells	moderate	tight	agranular	+
Hcu 18	elongated (180um) fibroblasts masking epithelial cells which emerged later	oval and elongated angular cells	moderate	loose	most cells granular	+++
Hcu 33	initial continuous sheet	polygonal cells of varying size	rapid	initially tight, then loose	agranular	++
Hcu 35	present, then masked by fibroblasts, then emerged	small, rounded and larger angular cells	moderate	moderate	both granular and agranular cells	++

TABLE 12 (cont.)

Specimen number	Emergence of epithelial cells	Morphology of epithelial cells	Epithelial cell growth	Adherence of epithelial cells	Granularity of epithelial cells	Giant cells
Hcu 37	initial continuous sheet	early rounded cells replaced by elongated angular forms	rapid	loose	both granular and agranular cells	++
Hcu 39	initially masked by fibroblasts, then emerged	both rounded and elongated forms	moderate	loose	granules in most cells	+++
Hcu 50	initial densely packed sheet	small polygonal cells	slow	tight	agranular	+

TABLE 12 (cont.) SOME IN VITRO FEATURES OF THE CELL LINES ARISING FROM EIGHT RESECTED OESOPHAGEAL CARCINOMA SPECIMENS

Specimen number	Time of first exposure to trypsin	Time of first subculture	Sensitivity to trypsin	Frozen at −80°C, thawed and regrown	Approximate time in vitro	Typical example
Hcu 10	4 weeks	4 months	+++	✓	$4\frac{1}{2}$ years	Figs. 22 and 23
Hcu 13	5 weeks	8 weeks	+	✓	$4\frac{1}{2}$ years	Figs. 24 and 25
Hcu 18	8 weeks	4 months	+++	✓	$3\frac{1}{2}$ years	Fig. 26
Hcu 33	6 weeks	9 weeks	+	✓	$2\frac{1}{2}$ years	Fig. 27
Hcu 35	3 weeks	9 weeks	++	✓	$2\frac{1}{2}$ years	Fig. 28
Hcu 37	6 weeks	8 weeks	+++	✓	$2\frac{1}{2}$ years	Fig. 29
Hcu 39	6 weeks	3 months	+++	✓ but poor viability	2 1/4 years	Fig. 30
Hcu 50	12 weeks	4 months	+	✓ but poor viability	1 year	–



Fig. 22 Interference micrograph of a confluent culture of polygonal Hcu 10 cells after three months *in vitro*.
Bar = 100 µm



Fig. 23 Interference micrograph of Hcu 10 cells of varying form and size in a semi-confluent culture after seven months *in vitro*. Paranuclear granules and vesicles are evident in many of the cells. Bar = 10 µm



Fig. 24 Interference micrograph showing tightly adherent agranular Hcu 13 cells with prominent nucleoli growing in a confluent sheet after six months *in vitro*.
Bar = 100 μm



Fig. 25 Interference micrograph of a portion of a culture of agranular adherent Hcu 13 cells after eight months *in vitro*. Scattered rounded mitotic figures (M) are evident. Bar = 100 μm



Fig. 26 Interference micrograph showing angular, loosely adherent Hcu 18 cells after six months in vitro.
Bar = 100 μm

irresectable tumour. The patient was opened in preparation for resection before the advanced state of the disease was recognised and this biopsy specimen was obtained under direct vision; consequently the use of an oesophagoscope was not necessary and for this reason specimen Hcu 37 is grouped with the other resected specimens. This specimen was also obtained before the work on superficial biopsies of oesophageal carcinomas was begun.

8. 1. 6 Miscellaneous specimens

Specimens Hcu 7 and Hcu 11 were derived from adenocarcinomas infiltrating the lower third of the oesophagus and the malignant glandular cells present in Hcu 7 differed from those occurring in squamous carcinomas. Cell attachment and growth occurred rapidly from explants of Hcu 7 and small refractile fibroblasts migrated from the explants. Large irregular polyhedral agranular epithelial cells subsequently appeared (fifth day) as did some smaller tightly adherent epithelial cells (Fig. 31). The epithelial



Fig. 27 Interference micrograph showing part of a sheet of adherent agranular Hcu 33 cells after one month *in vitro*. Some cells at the growing edge of the sheet display fine radiating processes (P). Bar = 100 µm



Fig. 28 Interference micrograph showing rounded, predominantly agranular Hcu 35 cells of varying size after four months in culture. Bar = 100 µm



Fig. 29 Interference micrograph of elongated (fibroblastic) and rounded epithelial (carcinoma) cells in a six week old culture of Hcu 37 cells. Bar = 100 μm



Fig. 30 Interference micrograph showing elongated and angular Hcu 39 cells after four months <u>in vitro</u>. Bar = 100 μm



Fig. 31 Interference micrograph showing large polyhedral agranular adenocarcinoma cells growing from an explant of specimen Hcu 7 after eight days *in vitro*. Small fibroblasts of varying morphology migrated more rapidly than did the epithelial cells. Bar = 100 um

cells persisted for seven weeks, at which stage the cultures were unfortunately lost as a result of bacterial contamination.

No epithelial cell growth occurred when specimen Hcu 11 was cultured and the fibroblasts originating from this specimen showed features similar to those described in Category I.

Although an oesophageal resection was performed on the patient from whom the specimen Hcu 13 was obtained, the histopathology report described dysplasia only, with no evidence of malignancy and only fibroblasts of normal morphology grew from explants of this specimen.

The *in vitro* and clinical properties of all resected oesophageal carcinoma specimens cultured in this investigation are listed in Table 18 in Chapter 10 and correlations between the various features given so that similarities between the specimens can be recognised.

9 RESULTS

IN VITRO PROPERTIES OF OESOPHAGEAL CARCINOMA BIOPSY SPECIMENS

Short term tissue culture of 36 oesophageal biopsy specimens, 18 of which were obtained during operative resection for carcinoma of the lower third of the oesophagus was attempted so that the *in vitro* behaviour of superficial biopsy specimens and deeper tumour specimens could be compared. The remaining 21 specimens were obtained during diagnostic oesophagoscopy.

Culture of biopsy specimens proved unsuccessful in four cases (B 7, B 10, B 12 and B 18) where not even fibroblasts grew. A further four specimens (B 3, B 6, B 14 and B 21) showed growth of epithelial cells of apparently normal morphology. The patients from whom B 14 and B 21 were taken were subsequently shown not to have tumours, while in the case of the other patients the biopsies may not have been deep enough to include tumour material. This is not unexpected as even in experienced hands only 40 - 50 per cent of biopsy fragments contain cancer cells (Dekker and Tytgat, 1977; Qizilbash and Stevenson, 1979). The growth patterns of oesophageal carcinoma biopsy specimens could be determined within two weeks of the initiation of a culture, permitting classification into categories similar to those applicable to resected tumour specimens.

9.1 CLASSIFICATION OF BIOPSY SPECIMENS

Growth characteristics of the biopsy specimens in short term culture permitted classification into four major categories, two of which were subdivided. These categories differ slightly from those used for resected specimens as allowance had to be made for those biopsy specimens from which apparently normal oesophageal cells grew. The categories were defined as follows:

I No growth of malignant oesophageal cells.

IA Epithelial cells of normal morphology present in continuous sheets surrounding the explants; sometimes bordered by fibroblasts.

IB No cell growth, or growth of fibroblasts of normal morphology only.

II Malignant epithelial cells present but never successfully subcultured.

IIA Slowly growing epithelial cells which did not survive for more than one month *in vitro*.

IIB Rapidly growing irregular epithelial cells which had a limited *in vitro* lifespan.

III Substantial epithelial growth. Subculture possible but limited to one to three passages.

IV Continuous epithelial cell lines successfully subcultured at intervals.

The numbers of specimens which fell into each category are given in Table 13. Specimens falling into categories III and IV could not be separated in a short term study, but had to be investigated for periods in excess of three weeks to determine whether or not a continuous oesophageal carcinoma cell line would result. Subculture was possible in 16,6 per cent of specimens only, a much lower proportion of biopsy specimens than tumour specimens thus being able to withstand passaging.

9. 1. 1 CATEGORY I

The specimens in Category IA (Table 14) showed growth of epithelial cells of apparently normal morphology which resembled the cells growing from cultured normal oesophageal mucosa described in Chapter 7.

The eight specimens (Table 14) that fell into Category IB showed either no evidence of cell growth (B 7, B 10, B 12, B 15) or only fibroblast growth (B 6, B 8, B 16, B 25) in spite of superficial oesophageal tissue being cultured. Those fibroblasts which grew

TABLE 13 RESULTS OF THE TISSUE CULTURE OF BIOPSY SPECIMENS

Category	Characteristics	Number of specimens	Percentage of specimens
I	No growth of malignant epithelial cells	11	30,5
IA	Fibroblasts and normal epithelial cells only	(3)	(8,3)
IB	No cell growth, or fibroblasts only	(8)	(22,2)
IIA	Slow epithelial growth, no subculture	16	44,4
IIB	Rapid epithelial growth, no subculture	3	8,3
III	Substantial epithelial growth, early subculture possible	3	8,3
IV	Continuous epithelial tumour cell line	3	8,3
		36	100

were refractile and overlapping and survived for up to four months in vitro.

9. 1. 2 CATEGORY IIA

The 16 specimens in Table 15 showed growth patterns which permitted their classification into Category IIA. A range of epithelial cell morphology was evident. Many giant cells were present in cultures of specimens B 1 and B 2 and were accompanied by clusters of numerous small epithelial cells of more uniform morphology. A range in cell size was also prominent in cultures of B 11 where the cells varied both in size and degree of granularity. Other cultures (B 4, B 20, B 22, B 27, B 32 and B 36) consisted of small tightly adherent epithelial cells surrounding the explant, while large cells were present in the growing regions. These were rapidly overgrown and replaced by fibroblasts or detached from the plastic substrata as a result

TABLE 14 CATEGORY I BIOPSY SPECIMENS - HISTOPATHOLOGY AND PATIENT SURVIVAL

Specimen number	Sex	Age	Differentiation	Clinical information
CATEGORY IA				
B 3	F	52	well	ϕ alive at six months
B 14	F	66	tumour negative	alive at six months
B 21	M	49	tumour negative	alive at six months
CATEGORY IB				
B 6	M	75	well	no data available
B 7	M	81	well	localised tumour, no follow up
B 8	M	60	well	localised tumour, no follow up
B 10	F	58	well	localised tumour, no follow up
B 12	M	67	well	localised tumour, no follow up
B 16	F	55	well	localised tumour, no follow up
B 18	F	28	moderate	invasive tumour, no follow up
B 24	F	28	well	ϕ alive at six months - but readmitted

ϕ Surgical resection performed

of senescence. Multiple prominent nucleoli were evident in many of the cultured cells.

9. 1. 3 CATEGORY II

Only three specimens (Table 15) showed rapid initial growth of epithelial cells. Small granular and agranular forms migrated rapidly (within one to four days of culture initiation) from the explants and formed clearly defined continuous sheets of epithelial cells. However, after three to four weeks *in vitro*, the cells showed retarded growth, lost their adhesion and detached from the flasks or were overgrown by the ubiquitous fibroblasts.

TABLE 15 CATEGORY II [illegible] - HISTOPATHOLOGY AND PATIENT SURVIVAL

Specimen number	Sex	Age	Differentiation	Clinical information
CATEGORY II A				
B 1	M	69	moderate	localised tumour, prognosis unknown
B 2	M	57	moderate	invasive tumour, no follow up
B 4	F	60	well	no data available
B 9	F	66	poor	localised tumour, alive at six months
B 11	M	69	moderate	invasive tumour, no follow up
B 20	F	62	well	no data available
B 24	F	63	well	ϕ alive at six months
B 25	F	50	poor	ϕ presumed dead
B 26	F	28	moderate	ϕ alive at six months
B 27	M	59	moderate	alive at six months
B 29	M	66	well	ϕ alive at four months
B 31	M	49	well	ϕ alive at five months
B 32	M	39	well	ϕ unknown
B 33	M	49	well	ϕ unknown
B 35	M	53	moderate	ϕ alive at three months
B 36	M	41	well	ϕ alive at three months
CATEGORY II B				
B 15	M	60	poor	invasive tumour, survival not expected
B 30	M	41	moderate	ϕ alive with recurrence
B 34	M	39	poor	ϕ no data available

ϕ Surgical resection performed

9. 1. 4 CATEGORY III

The three specimens (Tables 16 and 17) in this category grew well initially under *in vitro* conditions. Rapidly growing small epithelial cells appeared after two days *in vitro* and divided to form large halos around the explants. Specimen B 13 had an appearance somewhat different from most of the other cultured biopsy specimens in that many of the cells had a spindle-shape and refractile cytoplasmic granules. They were, however, distinct from fibroblasts and therefore were assumed to be epithelial cells of tumour origin. The granules disappeared after one month *in vitro* and the epithelial cells subsequently became more rounded and grew in cords rather than continuous sheets and resembled cells of line Hcu 35 (Chapter 8. 1. 5).

TABLE 16 CATEGORY III AND IV BIOPSY SPECIMENS - HISTOPATHOLOGY AND PATIENT SURVIVAL

Specimen number	Sex	Age	Differentiation	Clinical information
CATEGORY III				
B 13	M	60	well	no data available
B 19	M	52	poor	invasive tumour, no follow up
B 22	M	40	poor	invasive, death in four months
CATEGORY IV				
B 5	M	65	poor	dead
B 17	F	44	moderate	invasive tumour, survival not expected
B 29	M	59	moderate	ƒ alive at three months - no further record

ƒ Surgical resection performed

9. 1. 5 CATEGORY IV

The three specimens (Table 16) that fell into this category adapted well to *in vitro* conditions and developed into rapidly growing continuous oesophageal carcinoma cell lines, some features of which are summarised in Table 17. The cell line established from specimen B 29 has already been described as Hcu 50. Both superficial biopsy and deeper specimens of this tumour gave rise to continuously growing epithelial cells of very similar morphology and behaviour and because of the origin of these specimens in the same patient the lines are considered to be the same.

Epithelial cells from specimens B 5 and B 17 (Fig. 32) grew rapidly and formed cell lines with distinctive morphologies and growth patterns; thus bringing the total number of continuous oesophageal carcinoma cell lines established in this study up to ten.



Fig. 32 Interference micrograph showing elongated epithelial cells of line B 17 after six months *in vitro*. Bar = 100 µm

The successful culture of tumour biopsy specimens has prompted a prospective evaluation of growth characteristics in short term

TABLE 17 SOME IN VITRO FEATURES OF CATEGORY III AND IV OESOPHAGEAL CARCINOMA BIOPSY SPECIMENS

Specimen number	Emergence of epithelial cells	Morphology of epithelial cells	Epithelial cell growth rate	Adherence of epithelial cells	Granularity of epithelial cells	Giant cells
B 13	continuous sheet, then cords of cells	spindle shaped then rounded	rapid	tight	many granules	bi-nucleate only
[illegible]	continuous sheet around explant	small polygonal cells	rapid	tight	agranular	+
B 22	continuous sheet around explant	small polygonal cells	rapid	tight	agranular	+
B 5	adherent clusters and sheets of cells	angular and round cells	rapid	moderate	granular and agranular forms	++
B 17	irregular cords of cells	small, uniform rounded cells	rapid	moderate	mainly agranular	+
B 29	See Hcu 50 in Table 12					

TABLE 17 (cont.) SOME IN VITRO FEATURES OF CATEGORY III AND IV OESOPHAGEAL CARCINOMA BIOPSY SPECIMENS

Specimen number	Time of exposure to trypsin	Time of first subculture	Number of subcultures	Sensitivity to trypsin	Frozen at −80°C, thawed and regrown	Approximate time in vitro	Reason lost
B 13	2 weeks	2 weeks	2	sensitive	−	3 months	senescence
B 19	3 weeks	3 weeks	3	sensitive	−	3½ months	bacterial contamination
B 22	2 weeks	4 weeks	3	resistant	−	3 months	bacterial contamination
B 5	2 weeks	4 weeks	numerous	moderate	+	2 years	−
B 17	1 week	1 week	numerous	moderate	+	1½ years	−
B 29	See Hou 50 in Table 12						

tissue culture as an index of *in vivo* invasiveness. The growth patterns of tumour biopsy specimens can be determined within two weeks of the initiation of culture, permitting classification into categories similar to those applicable to resected tumour specimens.

Some properties of all of the biopsy specimens cultured in this investigation are summarised in Table 13.

10 DISCUSSION

COMPARISON OF TISSUE CULTURE DATA AND CORRELATION OF IN VIVO WITH IN VITRO FEATURES

In order to achieve the maximum benefit from the information obtained from *in vitro* studies and clinical investigations, it is essential to recognise similarities and correlations between properties of the oesophageal tumour specimens *in vivo* and the cells derived from them *in vitro*, as well as similarities between the different cells and cell lines arising from different tumour specimens.

10. 1 SUMMARY OF AVAILABLE DATA

To facilitate data comparison, Table 18 summarises the accumulated data on 46 of the oesophageal carcinoma specimens obtained during surgical resections and subsequently cultured, while the accumulated data for the remaining 21 biopsy specimens is given in Table 19. As all properties and their variations had to be reduced to simple terms for computer analysis the data are given values of 1 or 2 and the key to Tables 18 and 19 appears on pages 100 and 101.

10. 2 CLUSTER ANALYSIS

The accumulated data were processed by single-linkage cluster analysis (program in Appendix) to determine which clinical and *in vitro* properties of each specimen were most closely linked and also which specimens were most similar to one another. The results of the cluster analyses are summarised in Figs. 33 to 36. Resected specimens which were most similar appear clustered in Fig.33 while statistically similar biopsy specimens are shown in Fig. 34. Those features of the resected tumour specimens both *in vivo* and *in vitro* which appear to be most closely linked are shown in Fig. 35, while features of the biopsy specimens which appeared related are given in Fig. 36. As less clinical information concerning properties of the tumour, such as prognosis and lymph node in-

TABLE III ACCUMULATED DATA ON ALL RESECTED TUMORS

| Specimen number | | |

TABLE 18 (cont.) ACCUMULATED DATA ON ALL RESECTED TUMOUR SPECIMENS

Specimen number	Age	Sex	Size	Poor - well developed	Moderate - well developed	Lymphocytes	Lymph nodes	LN fixed or mobile	Organ invasion	Prognosis	Recurrence	Cell types	Subculture	Size of epithelial cells	Giant cells	Granularity of epithelial cells	Adhesion of epithelial cells	Growth rate	Fibroblasts	Time in culture	Established cell line
36	2	1	2	2	2	-1	2	-1	2	2	-1	2	2	1	1	2	1	1	2	1	2
37	2	2	2	1	-1	1	2	2	2	2	2	2	1	1	2	2	1	2	1	2	1
38	2	1	1	2	1	-1	1	-1	1	1	1	2	2	1	2	1	2	1	1	1	2
39	2	1	1	2	2	1	2	2	2	1	1	2	1	1	2	1	1	1	1	2	1
40	1	1	1	2	1	1	-1	-1	1	1	1	2	2	2	2	2	2	1	1	1	2
41	2	1	2	2	2	1	-1	-1	1	1	1	2	2	2	2	2	1	1	2	1	2
B 3 42	2	2	1	1	-1	-1	1	-1	1	2	1	2	2	2	2	2	1	1	2	1	2
43	1	1	-1	-1	-1	-1	-1	-1	-1	-1	-1	2	2	1	1	2	2	1	1	1	[illegible]
B23 44	2	1	2	2	2	1	1	-1	1	1	1	2	2	2	2	1	1	1	2	1	2
B24 45	1	2	2	2	2	-1	1	-1	1	1	2	1	2	-1	-1	-1	-1	-1	2	1	2
B25 46	2	2	2	1	-1	-1	2	-1	2	2	2	1	2	-1	-1	-1	-1	-1	1	1	2
B26 47	1	2	1	2	1	1	1	-1	1	1	1	2	2	2	2	1	1	1	2	1	2
B27 48	2	1	2	2	1	1	2	1	1	1	1	2	2	1	1	1	1	1	2	1	2
B28 49	2	1	2	2	2	2	2	-1	1	2	2	2	2	1	2	2	2	1	2	1	2
B29 50	2	1	2	1	-1	1	2	1	2	1	1	2	1	1	1	1	2	1	2	2	1
B30 51	1	1	2	2	1	1	2	2	2	1	2	2	2	1	1	1	1	2	1	2	2
B31 52	1	1	1	2	2	1	1	-1	1	1	1	2	2	2	1	1	1	1	1	1	2
B32 53	1	1	-1	2	1	-1	2	1	2	-1	-1	2	2	2	2	1	1	1	1	1	2
B33 54	1	1	-1	2	2	1	-1	-1	-1	-1	-1	2	2	1	1	1	2	1	2	2	2
B34 55	1	1	-1	1	-1	-1	2	2	2	-1	-1	2	2	1	2	2	2	2	1	1	2
B35 56	2	1	2	2	1	1	1	-1	1	1	1	2	2	1	2	1	1	1	2	1	2
B36 57	1	1	1	2	2	1	1	-1	1	-1	1	2	2	1	2	1	2	1	2	1	2

TABLE 19 [illegible] DATA ON [illegible]

Specimen number	Age	Sex	Size	Poor - well developed	Moderate - well developed	[illegible]	Size of epithelial cells	Giant cells	[illegible]	Adhesion of epithelial cells	Growth rate	Fibroblast	[illegible]	Established cell line	[illegible]
B 1	2	1	2	2	1	2	1	2	[illegible]	1	1	1	1	2	2
B 2	2	1	2	2	1	2	1	2	[illegible]	1	1	1	1	2	2
B 4	2	2	1	2	2	2	1	2	[illegible]	2	1	2	1	2	2
B 5	2	1	2	1	1	2	1	2	[illegible]	2	2	1	2	1	1
B 6	2	1	1	2	2	1	1	1	[illegible]	2	1	2	1	2	2
B 7	2	1	2	2	2	1	1	1	[illegible]	1	1	1	1	2	2
B 8	2	1	2	2	2	1	1	1	[illegible]	1	1	1	1	2	2
B 9	2	2	2	1	-1	2	1	2	[illegible]	1	1	1	1	2	2
B 10	[illegible]	2	2	2	2	1	1	1	[illegible]	1	1	1	1	2	2
B 11	2	1	2	2	1	2	2	2	[illegible]	2	1	1	1	2	2
B 12	2	[illegible]	1	2	2	1	1	1	[illegible]	1	1	1	1	2	2
B 13	2	1	1	2	2	2	1	2	[illegible]	2	1	2	1	2	1
B 14	2	2	1	1	1	1	1	1	[illegible]	1	2	1	2	2	2
B 15	2	1	2	1	1	2	1	2	[illegible]	1	2	2	1	2	2
B 16	2	2	1	2	2	1	1	1	[illegible]	1	1	1	1	2	2
B 17	1	2	2	2	1	2	1	2	[illegible]	2	2	1	2	1	1
B 18	1	2	2	2	1	1	1	1	[illegible]	1	1	1	1	2	2
B 19	2	1	2	1	1	2	1	2	[illegible]	1	2	1	2	2	1
B 20	2	2	1	2	2	2	1	2	[illegible]	2	1	2	2	2	2
B 21	1	1	1	1	1	2	1	2	[illegible]	2	1	2	2	2	2
B 22	1	1	2	1	1	2	2	2	[illegible]	1	2	1	1	2	1

The key to Tables 18 and 19 is as follows:

Clinical details	1. Age of patient	1 under 50 years 2 over 50 years
	2. Sex of patient	1 male 2 female
	3. Size of tumour	1 under 5cm 2 over 5cm
	4. Differentiation of tumour	1 poor 2 moderate and well
	5. Differentiation of tumour	1 moderate 2 well
	6. Lymphocyte infiltration into tumour	1 scanty - moderate 2 abundant
	7. Lymph nodes	1 negative 2 positive
	8. Lymph nodes	1 mobile 2 fixed
	9. Organ invasion	1 negative 2 positive
	10. Prognosis	1 alive at six months 2 dead at six months
	11. Recurrence	1 not evident at six months 2 evident at six months
Tissue culture	12. Cell types	1 fibroblasts only or fibroblasts accompanied by epithelial cells of normal morphology 2 apparently malignant epithelial cells and fibroblasts
	13. Subculturing	1 epithelial cells amenable to subculture 2 no subculture possible
	14. Size of epithelial cells	1 small 2 large
	15. Giant cells	1 absent 2 present
	16. Granularity of epithelial cells	1 agranular 2 granular
	17. Adhesion of epithelial cells	1 loose 2 tight
	18. Growth rate of epithelial cells	1 slow 2 rapid
	19. Fibroblasts	1 sparse and irregular 2 abundant and overlapping

20. Time [illegible] ture [illegible] less than three months
[illegible] more than three months

[illegible]. Established cell line 1 yes
2 no

[illegible] available or where neither category was applic-
[illegible] used.

[illegible] available for the biopsy specimens, six features (those numbered [illegible] - 11 on page 100) had to be omitted when performing the cluster analyses on these specimens.

[illegible] SIMILARITIES BETWEEN OESOPHAGEAL CARCINOMA SPECIMENS

Resected tumour specimens

[illegible] results of the cluster analysis (Fig. 33) those specimens [illegible] closely related (0,94) were Hcu 41 and Hcu 44, both [illegible] derived from well differentiated tumours and fell [illegible] IIA when cultured. The specimens Hcu 22, Hcu 48 [illegible] derived from well (Hcu 22) and moderately differentia- [illegible] were also closely related (0,89) to Hcu 41 and Hcu 44 [illegible] Category IIA growth characteristics, while specimens Hcu [illegible] and Hcu [illegible], which varied in histopathological differen- [illegible] growth patterns, also clustered with these specimens. [illegible] Hcu 23 and Hcu 38 both derived from moderately differen- [illegible] tumours and falling into Category IIA showed similarities [illegible] (0,89) as did specimens Hcu 54 and Hcu 57 (0,86) [illegible] similar degrees of differentiation and fell into the [illegible]. Specimens Hcu 29 and Hcu 37 although appearing [illegible] cluster analysis (0,86) differed both in degree of dif- ferentiation and culture category. Specimens Hcu 6 and Hcu 33 [illegible] showed many similarities (0,85) to each other although only Hcu 33 [illegible] continuous oesophageal carcinoma cell line and Hcu 6 was [illegible] two subcultures.

[illegible] specimens

[illegible] similarity co-efficients obtained for the biopsy

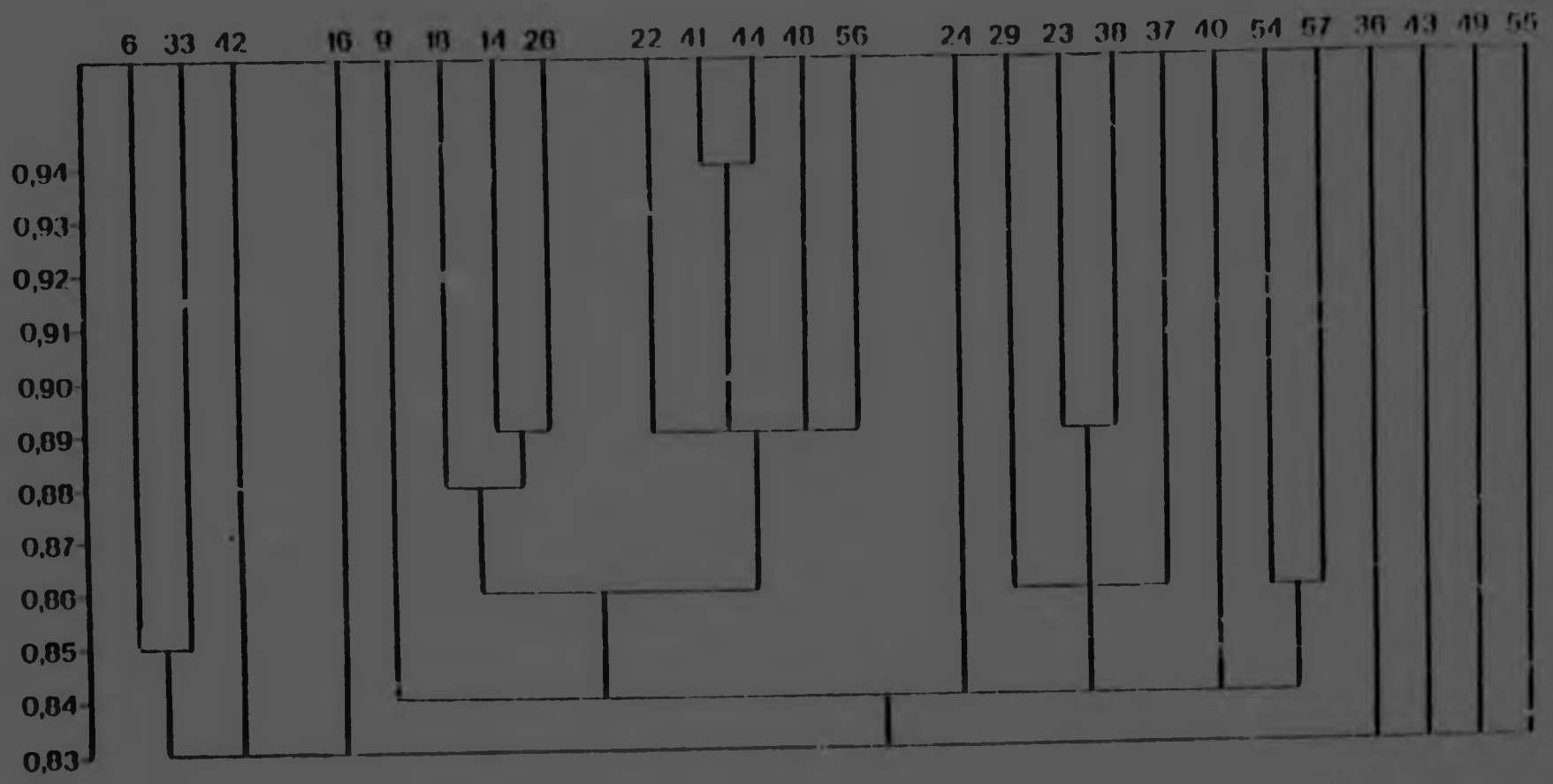

Fig. 33 Results of cluster analysis showing the resected specimens (horizontal axis) which were statistically most similar to one another

specimens appeared to be deceptively high (Fig. 34) since much data was either not available or not possible to give, e.g. in those cultures where no growth of epithelial cells occurred it was impossible to give information on features such as cellular granularity and size of epithelial cells. Bearing these limitations in mind the similarities between the various biopsy specimens should be accepted with caution.

Specimens B 6, B 7, B 8 and B 12 (Category I) appeared very closely related (1,00) and all showed growth of epithelial cells and were derived from histologically similar tumours. Specimens B 10, B 14 and B 16 (Category I) also appeared identical (1,00) but much data was missing or not available. Most of the specimens falling into Category I (B 6, B 7, B 8, B 10, B 12, B 14 and B 16) were linked at the 0,91 level and this seems reliable though the association of specimen B 17 with this cluster (0,87) is artificial and can be attributed to the lack of data on epithelial cell properties for specimens falling into Category I.

Specimens B 1, B 2 and B 11 all derived from moderately differentiated tumours which showed similar growth patterns in vitro and were classified as Category IIA were clustered (0,93) as were the specimens B 26 and B 34, the former growing more slowly in vitro (Category IIA) than the latter.

The clustering (0,91) of specimens B 15, B 19 and B 28 appears more significant as all of the required information was available.

10. 4 SIMILARITIES BETWEEN SOME CLINICAL AND IN VITRO FEATURES OF OESOPHAGEAL CARCINOMA SPECIMENS

10. 4. 1 Resected Tumour Specimens

When various features and properties of the 46 resected tumour specimens were compared (Fig. 35) those which were most closely linked (0,92) were the ability of a specimen to withstand subculture and the ability of cells from a specimen to develop into a continuous line. The clustering of tumour differentiation with these features appears artificial since several -1's appear in this

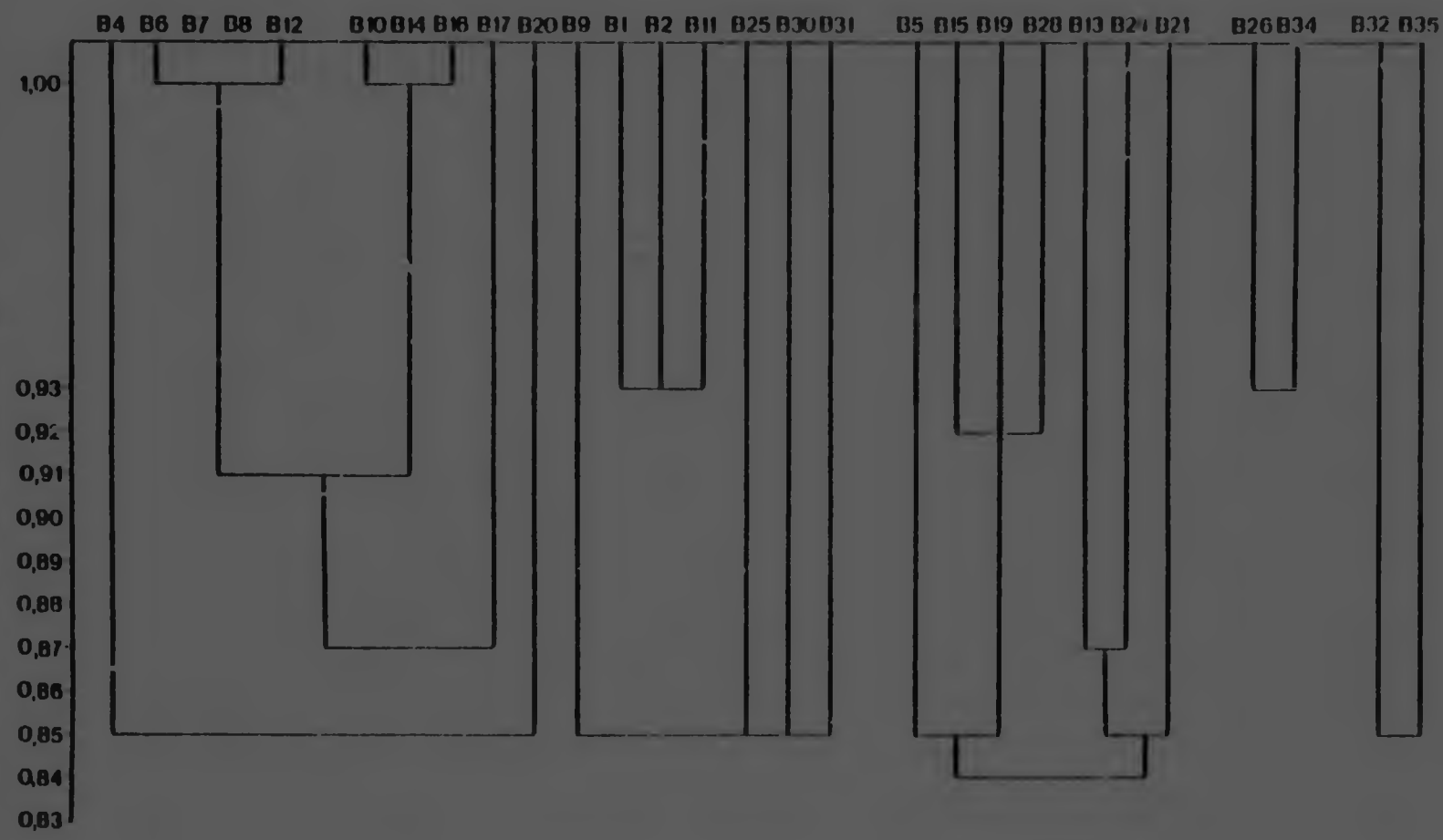

Fig. 34 Results of cluster analysis showing the biopsy specimens which were statistically most similar to one another.

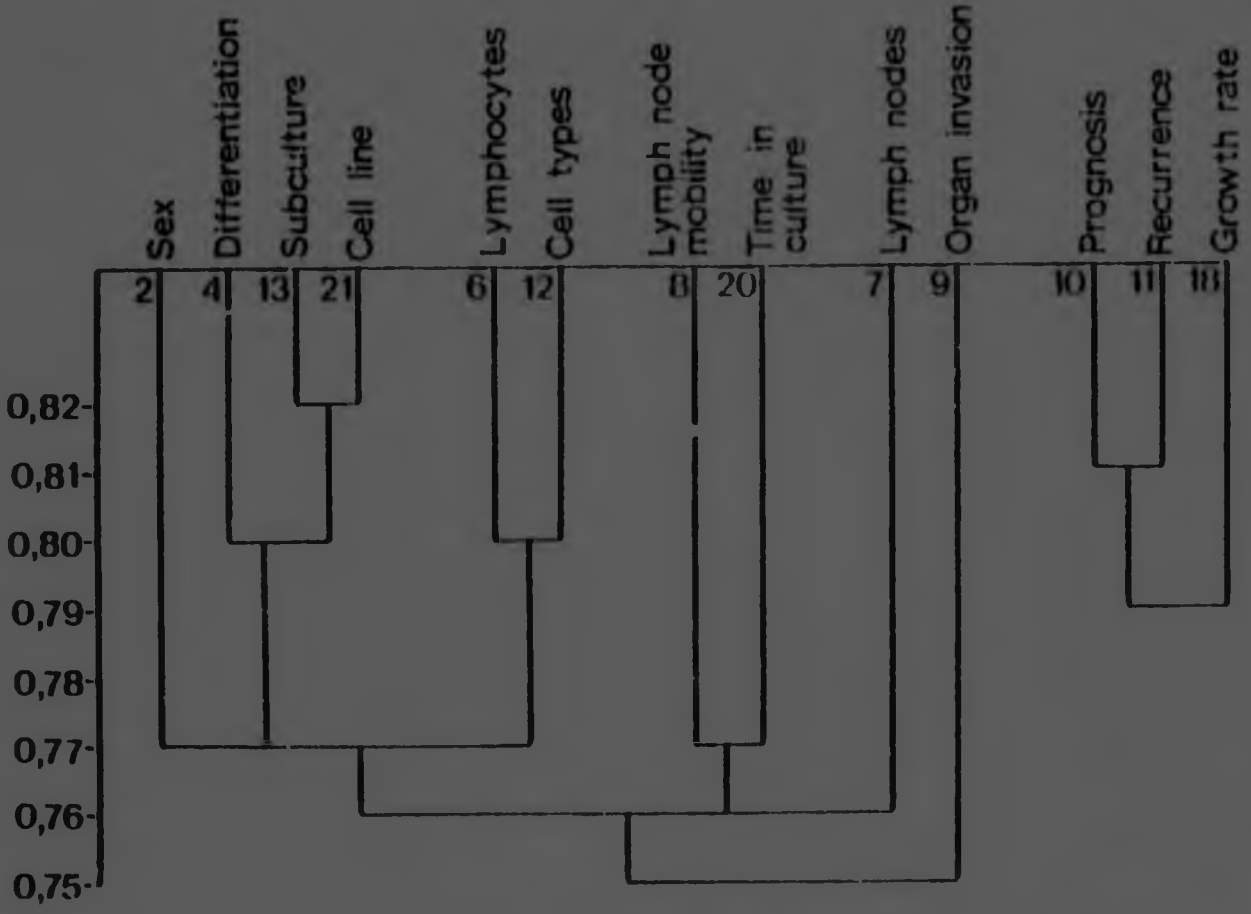

Fig. 35 Results of cluster analysis showing features of the rejected tumour specimens which were statistically linked.

feature (No. 5 on page 100 which only allows for the distinction between moderately and well differentiated tumours and the continuous cell lines were derived from tumours of varying differentiation. This association will thus be ignored.

Another clinically anticipated association was that between clinical prognosis and tumour recurrence (0,81). The *in vitro* growth rate of the tumour specimens was also linked with these features (0,79). This is a useful observation as the rate of epithelial cell growth *in vitro* may accurately reflect epithelial cell growth *in vivo* and thus information obtained from tissue culture studies may be relevant in the assessment of expected prognosis and tumour recurrence. If tumour recurrence can be accurately anticipated patients can be treated appropriately.

A less statistically significant (0,77) but still clinically significant association was that between lymph node mobility and time in culture. Those specimens derived from patients with tumours which had grossly invaded regional and other lymph nodes survived for longer periods *in vitro*.

10. 4. 2 Biopsy specimens

When clinical and *in vitro* features of the biopsy specimens were compared by cluster analysis the most closely related features (Fig. 36) were growth rate *in vitro* and the ability of cells to withstand subculture (0.86). Thus the epithelial cells which grew rapidly *in vitro* frequently survived subculture. Tumour differentiation was also artificially linked to this cluster though the association will be ignored for the reasons given in 10. 4. 1. The size of the epithelial cells and their ability to develop into a continuous epithelial cell line were related features (0,79) and cytoplasmic granularity clustered with these features (0,77). Unfortunately, much of the clinical data was inadequate and this hindered the search for associations between clinical and *in vitro* features.

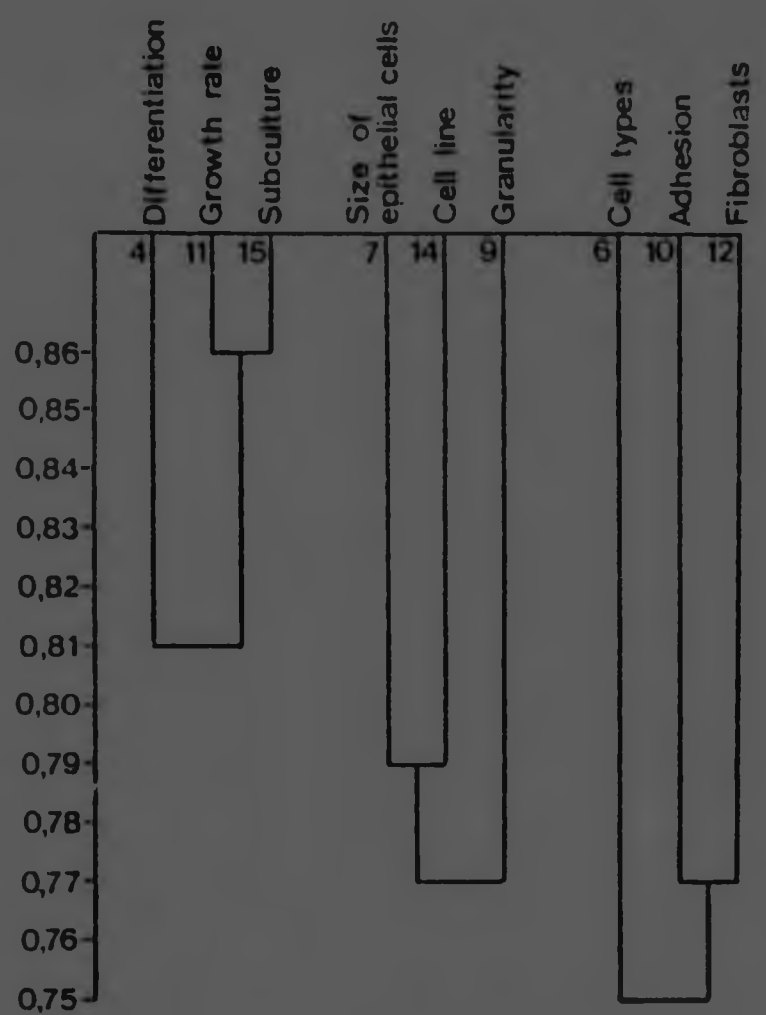

Fig. 36 Results of cluster analysis showing features of the oesophageal carcinoma biopsy specimens which were statistically linked.

10.5 COMPARISON OF RESECTED AND BIOPSY SPECIMENS

The growth characteristics of resected oesophageal carcinoma specimens and biopsy specimens are described in Chapters 8 and 9 and summarised in Tables 18 and 19. The in vitro growth patterns of cells from biopsy specimens were very similar to those from resected tumour specimens. Thus, the tumour cells present in a small superficial biopsy specimen may be representative of the tumour as a whole. In 15 instances superficial biopsy and resected tumour specimens of the same tumours were cultured separately and the results found to be identical.

Although each specimen behaved in a distinctive manner, several

common features emerged when the tumour and biopsy specimens were compared. Some specimens adapted rapidly and easily to culture conditions and could be successfully passaged after as short a time as two weeks (Hcu 37 and B 17), while, in other instances, sub-culture was successful after lengthy periods *in vitro* (Hcu 30 and Hcu 33).

The establishment of continuously growing cell lines from resected tumour and biopsy specimens of oesophageal carcinomas appears related more closely to properties of the tumour such as invasiveness *in vivo* than to the type of specimens cultured or the variations in tissue culture technique used. Subculture of tumour cells *in vitro* was possible for cells from those tumours which displayed clinically aggressive *in vivo* behaviour, typified by lymph node involvement and metastases to other sites.

The growth patterns of tumour biopsy specimens can be determined within one to two weeks of the initiation of culture, permitting classification into categories similar to those applicable to resected tumour specimens (Chapter 9). The culture of biopsy specimens may aid in some cases where diagnosis of malignancy is difficult, as normal and malignant oesophageal cells can be readily distinguished by their morphology and growth patterns *in vitro* (compare Figs. 13 and 18). Biopsy specimens may also be used to gauge *in vivo* invasiveness, though a tumour capable of invasion may not yet have metastasized in a particular patient. On the whole, though, the *in vitro* behaviour of biopsy specimens may facilitate the identification of patients with clinically undetected advanced disease and metastasis.

The introduction of routine cultures of biopsy specimens from patients with oesophageal carcinomas may be an important step towards the control and understanding of the disease since the recognition of correlation between properties of cultured tumour cells and behaviour and properties of these cells in the patient may provide important information about the most appropriate methods of treatment.

10. 6 TISSUE CULTURE AND DIFFERENTIATION

The associations between histopathological differentiation and tissue culture category for both resected and biopsy specimens are shown in Table 20. Well differentiated resected tumours which comprised the bulk of the tumours investigated showed no specific growth pattern *in vitro*. When biopsy specimens were cultured, however, most of the well differentiated tumours showed growth patterns typical of Categories I and IIA. Many of the moderately differentiated tumours (both biopsies and resected specimens) also revealed *in vitro* growth patterns typical of Categories I and IIA.

Anaplastic tumours comprised less than 20 per cent of the tumours studied and showed growth patterns typical of all *in vitro* categories, though approximately half of all anaplastic tumours fell into Categories III and IV.

In vivo (clinical) features such as prognosis and lymphocyte infiltration into the tumours did not correlate strongly with histopathological differentiation or the behaviour of the tumours in tissue culture, though prognosis was generally less favourable for patients with poorly differentiated tumours.

10. 7 TISSUE CULTURE AND OPERATIVE STAGING

Correlation exists between *in vivo* invasiveness and dissemination, and the ability of malignant cells to adapt to *in vitro* tissue culture conditions. The associations between operative staging and culture category for both resected and biopsy specimens appear in Table 21. As more clinical information about tumour extent and lymph node and organ invasion was available for patients undergoing operative resections, the *in vivo* and *in vitro* properties of resected specimens will be discussed more fully than similar properties of biopsy specimens.

10. 7. 1 Resected specimens

Full clinical information was not available for all patients whose

TABLE 20 TUMOUR DIFFERENTIATION AND CULTURE CATEGORY

RESECTED TUMOUR SPECIMENS

Number of specimens	Culture category	Histopathology			
		poorly differentiated	moderately differentiated	well differentiated	
7	I	1	1	5	
18	IIA	1	7	9	
5	IIB	1	1	3	
8	III	1	2	5	
8	IV	3	1	4	
		7	12	26	
	Percentage	15%	28%	57%	ø 98%

ø Differentiation of one specimen not known

BIOPSY SPECIMENS

Number of specimens	Culture category	Histopathology			
		poorly differentiated	moderately differentiated	well differentiated	
11	I	-	1	8	
16	IIA	2	6	8	
3	IIB	2	1	-	
3	III	2	-	1	
3	IV	1	2	-	
		7	10	17	
	Percentage	19%	28%	47%	øø 94%

øø 2 specimens tumour negative

resected tumour specimens showed Category I growth characteristics. In two patients the primary tumour was intramural and localised to the oesophagus, while transmural tumours were present in another two patients (Table 21), one tumour (Hcu 46) having spread to local lymph nodes as well as lungs and aorta. Thus the *in vitro* growth characteristics of Hcu 46 did not correlate with *in vivo* invasiveness.

Lymph node metastases were detectable microscopically in four of the five patients whose tumour specimens showed the rapid epithelial cell growth characteristic of Category IIB and liver invasion by Hcu 55 tumour cells was noted (Table 21).

In eight patients whose tumours showed Category III growth patterns *in vitro* the primary tumour was localised to the oesophagus in three patients and transmural tumours extended into the mediastinum in five patients. Nodal metastases were present in all eight patients, with widespread involvement and extranodal extension being evident in four patients in whom tumour invasion of the lungs, stomach and diaphragm was found (Table 21).

In all eight patients whose tumours showed Category IV growth patterns peri-oesophageal tumour extension was present (Table 21). Lymph node metastases were extensive in all patients and invasion of adjacent viscera occurred in six patients. Liver metastases were observed in two patients, with the stomach, lungs, pancreas and diaphragm being other involved sites. Thus, those tumours which had invaded in the human host adapted well to *in vitro* conditions.

10. 7. 2 Biopsy specimens

Biopsy specimens obtained from carcinomas localised to the oesophagus generally displayed Category IA, IB or IIA growth characteristics *in vitro* (Table 21) while transmural and extensively invasive tumour specimens grew more rapidly and for longer periods *in vitro* and fell into Categories IIA, IIB, III and IV. Those tumours from which the cell lines B 5 and B 17 were established showed involvement of lung tissue, while specimens B 19 and B 22

TABLE 21 OPERATIVE STAGING AND CULTURE CATEGORY

RESECTED SPECIMENS

Number of specimens	Culture category	Primary Tumour		Metastases	
		Localised (Intra-mural)	Invasive (Trans-mural)	Involved lymph nodes	Organ invasion
7	I ♂	2	2	1	1
18	IIA ♂♂	10	7	5	2
5	IIB	3	2	4	1
8	III	3	5	8	4
8	IV	-	8	8	6

♂ no data for three specimens

♂♂ no data for one specimen

BIOPSY SPECIMENS

Number of specimens	Culture category	Primary Tumour		Metastases
		Localised (Intra-mural)	Invesive (Trans-mural)	Organ invasion evident on radiographic examination
3	IA +	2 no tumour	-	-
8	IIB +	5	2	1
16	IIA ++	4	9	2
3	IIB	-	3	2
3	III	-	3	2
3	IV	-	3	2

+ no data for one specimen

++ no data for three specimens.

[illegible] withstood several subcultures *in vitro* (Category III) invaded the mediastinum and trachea respectively. Mediastinal and tracheal invasion were also observed in two of the tumours which were classified as Category IIB. Thus the clinically invasive tumours adapted well to *in vitro* conditions and such adaptation to tissue culture may be considered a sign of an invasive tumour.

[illegible] CULTURE AND CLINICAL PROGNOSIS

[illegible] patients who had undergone operative resections for oesophageal carcinomas were encouraged to return to hospitals and clinics for follow-up treatment many failed to do so. Consequently prognoses at six months after surgery are unknown for many patients. The available data are shown in Tables 5 to 9, [illegible] and are summarised in Table 22.

Resected specimens

There were adequate follow up for three of the patients whose tumours fell into Category I *in vitro*. One patient was presumed dead after efforts to trace her had failed and of the three patients who re-attended to allow assessment of prognosis two were well while the third was readmitted with suspected recurrence.

The prognosis appeared good for patients whose resected tumour specimens fell into Category II (Table 22). Thirteen were alive [illegible] months after surgery and the single death was due to post-operative complications. Two of the four patients whose tumours were classified as belonging to Category IIB showed tumour recurrence when they returned for routine checks (Table 22).

Of the patients whose tumours fell into Category III, one died of post-operative complications and a further two died from their tumours, while three of the five patients who survived to six months showed tumour recurrence (Table 22). The patient from whom Hcu 16 was obtained had his immune profile changed by being placed in positive nitrogen balance (Hafajee and Angorn, 1979) and this may be related to the fact that he appeared well at nine months after surgery.

TABLE 22 CLINICAL PROGNOSIS AND CULTURE CATEGORY

RESECTED SPECIMENS

Number of specimens	Culture category	Prognosis at six months			
		Alive	Dead	Tumour recurrence	No follow up
7	I	3	1	1	3
18	IIA	13	1	-	4
5	IIB	4	-	2	1
8	III	5	3	4	0
8	IV ♦	3	5	4	0

♦ incomplete follow up for one patient

BIOPSY SPECIMENS

Number of specimens	Culture category	Prognosis at six months			
		Alive	Dead	Tumour recurrence	No follow up
3	IA	3	0	-	0
8	IB	-	-	1	7
16	IIA	8	1	-	7
3	IIB	-	-	1	2
3	III	-	1	-	2
3	IV	1	1	-	1

Of the patients whose tumours showed Category IV growth features only three were alive at six months, and one of these showed evidence of tumour recurrence (Table 21). The patient from whom line Hcu 50 was obtained proved untraceable after three months. Three patients died as a result of tumour recurrence and the tumours in the other two were irresectable. Thus the patients whose tumour specimens were typified by Category III and IV growth patterns in vitro showed the lowest survival rate and association between tissue culture and prognosis is evident.

10. 8. 2 Biopsy Specimens

Limited clinical information was available for the patients from whom biopsy specimens were obtained and all the available data appear in Tables 14 to 16 and 22. Unfortunately the specimen number is small but there does appear to be a trend for tumours showing in vitro features of Categories I and II to be associated with better clinical prognosis than those falling into Categories III and IV.

10. 9 SUMMARY

In patients with tumours showing Category I and Category II growth patterns in tissue culture, the tumour was frequently localised to the oesophagus, lymph node metastases were absent or minimal and prognosis was better than in the case of specimens falling into other categories.

In patients whose tumours showed Category III and Category IV growth characteristics the tumour was in all instances more extensive, significant nodal metastases were present, recurrence more frequent and survival rates at six months much worse. In this investigation the successful establishment of a tumour cell line in 90 per cent of cases was from a tumour with gross metastases in lymph nodes, organ invasion and a poor prognosis. Lymphocyte infiltration did not correlate with the degree of differentiation, or the behaviour of the tumour in tissue culture and could not be correlated with patient survival at six months.

11 DISCUSSION

NORMAL AND MALIGNANT OESOPHAGEAL CELLS IN VITRO

11.1 OESOPHAGEAL CARCINOMA CELL LINES

The ten oesophageal carcinoma cell lines established in this investigation together with the seven continuously growing oesophageal carcinoma cell lines reported in the literature (Bey et al., 1976; Department of Cell Biology of CICAMS, 1976; Laboratory Section, Peking, 1978; Rabin et al., 1978; Nishihira et al., 1979; Yang, 1980) bring the current total to 17 oesophageal carcinoma cell lines, 16 of which are of human origin. This provides a large panel of cell lines for further studies on oesophageal carcinoma. Even though the tumour-bearing patients differed with respect to age, sex, race and environment, similarities were evident between many of the continuous oesophageal carcinoma cell lines.

Some features of all of the oesophageal carcinoma cell lines and clinical information about the tumours of origin in the human (and Rhesus monkey) patients are summarised in Table 23. Most of the cell lines were derived from invasive metastatic tumours of varying differentiation which resulted in death of the host (Robinson et al., 1980).

Cell lines derived from several of the well differentiated tumours consisted of cells which retained many of their differentiated functions *in vitro*. Such cells were generally small and tightly adherent to one another and grew in continuous sheets as typified by the cells of lines Hcu 13, Hcu 33, SNO (Bey et al., 1976) and TE-1 (Nishihira et al., 1979). The lines Hcu 36 and Hcu 39, although also derived from well differentiated tumours did not consist of such tightly adherent cells, and the cells of line Hcu 39 were angular and most closely resembled those present in lines Hcu 18 and Hcu 10 which were derived from poorly differentiated

TABLE 23 FEATURES OF ALL CONTINUOUS [illegible] CARCINOMA CELL LINES TO DATE

Designation	Author(s)	Date of culture initiation	Place	Patient from whom originated			Tumours from which established	Lymph nodes	Prognosis	Hetero transplantation	Other
				Age	Sex	Race					
S N O	Bey et al.	July, 1972	Johannesburg, S. Africa	62	M	Zulu	biopsy sample of well differentiated 6,5cm long tumour	metastases	death within ten months, bronchopneumonia	successful into nude mice (pers. comm.)	
ECA 109	Cancer Institute of the Chinese Academy of Medical Sciences (CICAMS)	December, 1973	Linxian, China	37	F	Chinese	explant of resected oesophagus	-	-	successful into irradiated newborn rats	[illegible]
CA ES - 17	Lab. Section, Peking	June, 1974	Peking, China	65	M	Chinese	metastic cancerous tissue in supraclavicular lymph node	metastases	death within six months of lymph node excision	successful in irradiated newborn rats	no virus-like particles
EC 56	CICAMS	1975	Linxian, China	35	M	Chinese	lymph node	-	-	-	
8 16 A	Rabin et al.	1971	Frederick, U.S.A.	mature 11	M	Rhesus monkey	metastic pancreatic lymph node	metastases	sample obtained at necropsy	unsuccessful inoculation of nude mice	budding and extracellular type C virus 110nm
T E - 1	Nishihira et al.	January, 1976	Tohoku, Japan	59	M	Japanese	well differentiated tumour of mid-oesophagus	-	-	successful in irradiated nude mice	secretes carcinoembryonic antigen (CEA)
T E - 2	Nishihira et al.	December, 1976	Tohoku, Japan	47	M	Japanese	poorly differentiated tumour of mid-oesophagus	-	alive - no evidence of recurrence	successful in irradiated nude mice	secretes CEA
Icu 10	Robinson	November, 1976	Durban, South Africa	40	F	Zulu	poorly differentiated 4cm tumour invading mediastinum	metastases	death with recurrence	successful into nude mice	

TABLE 23 (cont.)

Designation	Author(s)	Date of culture initiation	Place	Patient from whom originated			Tumours from which established	Lymph nodes	Prognosis	Heterotransplantation	Other
				Age	Sex	Race					
Hcu 13	Robinson	February, 1977	Durban, South Africa	50	M	Zulu	well differentiated 3cm invasive tumour	metastases	death with recurrence	successful into nude mice	[illegible] intranuclear particles
Hcu 18	Robinson	July, 1977	Durban, South Africa	40	F	Zulu	poorly differentiated 5cm transmural tumour	metastases	alive with recurrence	successful into nude mice	8-14nm cytoplasmic filaments
Hcu 33	Robinson	October, 1978	Durban, South Africa	45	M	Zulu	well differentiated [illegible] fungating tumour	metastases	death with recurrence	successful into nude mice	
Hcu 35	Robinson	October, 1978	Durban, South Africa	66	M	Zulu	well differentiated 5cm invasive tumour	metastases	dead, irresectable tumour	successful into nude mice	
Hcu 37	Robinson	November, 1978	Durban, South Africa	60	F	Zulu	poorly differentiated irresectable tumour	metastases	dead, irresectable tumour	transient tumours in nude mice	8-14nm cytoplasmic filaments
Hcu 39	Robinson	February, 1979	Durban, South Africa	70	M	Zulu	well differentiated 3cm tumour invading mediastinum	metastases	alive at six months	successful into nude mice	
B 5	Robinson	May, 1979	Durban, South Africa	68	M	Zulu	biopsy of poorly differentiated tumour	metastases	dead	successful into nude mice	
B 17	Robinson	October, 1979	Durban, South Africa	44	F	Zulu	biopsy of moderately differentiated tumour	metastases	dead	successful into nude mice	
Hcu 50	Robinson	February, 1980	Durban, South Africa	59	M	Zulu	moderately differentiated tumour	metastases	alive for three months	successful into nude mice	

tumours. The epithelial carcinoma cells in specimens Hcu 18, Hcu 25 and Hcu 39 required lengthy periods to adapt to *in vitro* conditions and may have been dependent on the presence of fibroblasts for their successful growth. The line B 5, although derived from a tumour classified as poorly differentiated, showed morphological similarities to cells of lines derived from well differentiated tumours. Thus, either the cells present in the biopsy specimen were not representative of the tumour as a whole, or conditions *in vitro* may have resulted in selection and preferential growth of cells displaying well differentiated features. Cell cultures are not necessarily representative of the tumour of origin because of cell selection and possibly alteration of individual cells (Marcel, 1979). Furthermore, it is possible to derive several different cell lines from a single tumour, as most tumours consist of mixed populations of cells. In spite of this, the cells cultured from resected tumour and biopsy specimens from the same patients showed many similarities and the lines Hcu 50 and B 20 established from specimens of the same tumour were identical with respect to all features examined. This observation substantiates the use of biopsy specimens, as *in vitro* potential appears independent of the site and size of the tumour specimen used to initiate cultures.

11. 2 CORRELATION BETWEEN IN VIVO AND IN VITRO FEATURES OF OESOPHAGEAL CARCINOMA SPECIMENS

Various properties of tumour cells may affect their ability to grow *in vitro* and ability to thrive *in vitro* may reflect the behaviour of malignant cells in the host organism (Marcel, 1979).

11. 2. 1 Tumour invasion and metastasis

In this investigation subculture was possible in most tumours displaying invasive *in vivo* behaviour and all of the continuous oesophageal carcinoma cell lines were established from extensive invasive tumours generally showing significant nodal and organ metastases, recurrence after surgical removal and, in many instances,

resulting in death of the patients.

The cell lines SNO (Bey et al., 1976), Ca ES-17 (Laboratory Section, Peking, 1976), EC-GG (Yang, 1980) and 816A (Rabin et al., 1978) were also established from invasive tumours which had metastasized to lymph nodes. Invasion of lymph nodes has been associated with a poor prognosis in patients with oesophageal carcinoma (Younghusband and Aluwihare, 1970) and other tumours (Jereb et al., 1980), but the association of lymph node involvement in carcinoma of the oesophagus and ability of the cells to survive for lengthy periods in vitro has not previously been reported. This observation differs from that of Rühl (1959) who found no association between tumour cell growth in culture and behaviour in vivo in patients with prostatic carcinoma.

11.2. 2 Tumour differentiation

The ten continuous human oesophageal carcinoma cell lines established in this study were derived from tumours of varying size and histological differentiation as were those described in the literature (Table 23). There was thus no correlation between in vitro growth and tumour size and differentiation. In this respect oesophageal carcinomas differ from ovarian and breast carcinomas where establishment of satisfactory cultures is more likely from advanced, well differentiated tumours (Limburg and Heckman, 1968; Dendy et al., 1970).

Although the Esophageal Cancer Research Group, Peking (1977) reported a relationship between the pathological type of early oesophageal squamous carcinoma and clinical symptoms, an association of histopathology and in vitro growth was not evident. This may be explained by the fact that the precise histological grading of tumours is often unsatisfactory (Willis, 1967) as areas of varying differentiation may be present.

11. 2. 3 Lymphocyte infiltration

Lymphocyte infiltration of oesophageal carcinomas has been asso-

ciated with earlier presentation, the absence of dissemination and a more favourable prognosis (Younghusband and Aluwihare, 1980), yet, in the present series, the degree of lymphocyte infiltration into the tumour mass bore no relationship to the extent of the disease, patient prognosis or tissue culture characteristics. The concentration of stromal cells did not influence the *in vitro* behaviour of the malignant cells. The presence of tumour infiltrating macrophages and lymphocytes may, however, reflect an immune response taking place within the tumour and influence prognosis of the disease by controlling dissemination (Eccles and Alexander, 1974; Wood and Gillespie, 1975; Lauder *et al*., 1977). Nonetheless, the number of lymphocytes and macrophages present within the tumour mass may not be a true reflection of the host's response to the malignancy as many macrophages and lymphocytes may be confined to the stroma adjacent to the tumour (Svennevig and Svaar, 1979).

11. 4 Fibroblasts and tumour necrosis

Cultures derived from scirrhous tumours did not grow well *in vitro*. Fibroblast overgrowth of epithelial cells was related to the connective tissue content of the tumour specimens. Best cancer cell growth occurred from soft, non-necrotic tumour specimens as tumour necrosis may affect tumour cell viability and ability to survive *in vitro* (Giard *et al*., 1973).

11. 2. 5 Giant cells

The presence or absence of giant cells was not linked with any clinical features of the oesophageal carcinomas other than tumour differentiation. Giant cells were particularly abundant in the cell lines derived from poorly differentiated tumours, though these cells were observed in all of the continuous lines and in many primary cultures where they were frequently located towards the edges of epithelial sheets.

Oesophageal carcinoma giant cells are not an *in vitro* artifact

as they were frequently observed in malignant oesophageal specimens *in vivo* (Chapter 13) and Alexandrova *et al*. (1980) have reported increased ploidy and changes in DNA content to correspond to epithelial cell dedifferentiation in oesophageal dysplasia and carcinoma *in situ*.

The number of giant cells present in a tumour or cell line may reflect its malignant potential and ability to withstand adverse conditions (Brodsky and Uryvaeva, 1977; Geisinger *et al*., 1978). The fact that giant cells divide shows that they are capable of continued growth and it is unlikely that they are a sign of impending degeneration as reported by Littlefield and Mailhes (1975).

11. 2. 6 Patients

In this study the ages and sexes of the patients had no effect on the ability of a tumour specimen to grow *in vitro*. The effects, if any, of race could not be determined since all of the patients were Zulu. The continuous oesophageal carcinoma cell lines did, however, show similarities to those derived from Chinese - ECA 109, Ca ES-17 and EC- - (Department of Cell Biology of CICAMS, 1976; Laboratory Section, Peking, 1976; Yang, 1980) and Japanese - TE-1 and TE-2 (Nishihira *et al*., 1979) patients (Table 23).

11. 3 REQUIREMENTS OF OESOPHAGEAL CELLS FOR GROWTH IN VITRO

The tissue culture conditions used in this investigation satisfied the requirements of some malignant oesophageal cells for lengthy periods and normal oesophageal cells for short periods *in vitro*.

The medium used does not appear to be critical and oesophageal carcinoma specimens have been successfully cultured in several different media and continuously growing cell lines established from cells growing in Eagle's MEM, M 199, McCoy's Medium 5 A and RPMI 1640 (Bey *et al*., 1976; Laboratory Section, Peking, 1976; Rabin *et al*.,1978; Nishihira *et al*., 1979) supplemented with foetal calf serum and sometimes pyruvate and insulin.

Factors such as the method of culture initiation (explant tech-

nique) and length of time before the first subculture was performed did influence success as did properties of the tissue specimens. Cells derived from well differentiated tumours were better able to withstand the effects of trypsin and sometimes required fairly lengthy periods (up to ten minutes) of exposure to this enzyme before cell detachment occurred, while poorly differentiated cells detached more rapidly (two minutes).

Epithelial cells may be dependent on factors produced by fibroblasts (Green, 197., for their successful growth *in vitro* and the use of fibroblast conditioned medium did promote oesophageal carcinoma cell growth in primary cultures. Several fibroblasts were present in cultures of normal oesophageal cells but their growth promoting effect was minimal. The presence of fibroblasts and the use of fibroblast conditioned medium did not have any obvious stimulatory effects on the growth of normal oesophageal cells *in vitro* nor did it prolong their lifespan. Both normal tissue and malignant tumours of different tissue origin may have specific individual requirements for growth *in vitro* (Alexander *et al.*, 1976).

11.4 EFFECTS OF TISSUE CULTURE ON CELLULAR MORPHOLOGY AND BEHAVIOUR

Malignant oesophageal cells showed some morphological and behavioural similarities when examined both *in vivo* and *in vitro* and giant cells were observed in both environments. Thus, morphological patterns similar to those of the original tumour were maintained in culture and cell populations in a primary culture are thought to reflect accurately the cell population in the original tumour (Hosick, 1976; Morasca *et al.*, 1976). The observed variability in the growth of cultures derived from malignant tumours and those from normal mucosa may be related to properties of the tissues of origin (Smith, 1978). Normal oesophageal cells underwent few morphological changes prior to degeneration and early subcultures of these cells closely resembled primary cultures and retained many of their *in vivo* properties. With increasing time

in culture, certain cellular properties of malignant cells were altered. After repeated exposure to trypsin the cells in many of the lines became less tightly adherent and because they were no longer so closely packed a size increase was evident as the cells spread out over larger areas. Granularity and growth rate also altered during the transition from tumour explant to primary cell line to continuous cell line.

In the present study lipid droplets were prominent in many rapidly growing, apparently healthy cells derived mainly from poorly differentiated tumours. The amount of lipid present in the cultured cells was not dependent on the nutritional status of the patients from whom the tumours were removed and dietary supplementation of the patients had no obvious effect on the amount of lipid present in primary cultures of tumour cells. Although degeneration has been reported to begin with the accumulation of lipid vacuoles within cultured cells (Rousseau et al., 1970) and the accumulation of lipid droplets has also been described in hypoxic cells (Gordon et al., 1977), in this study many of the cells containing lipid were growing well under in vitro conditions and the accumulation of lipid material may be related to de novo synthesis (Howard and Howard, 1975).

11. 5 COMPARISON OF CULTURED NORMAL AND MALIGNANT OESOPHAGEAL CELLS

Although normal oesophageal cells initially grew more rapidly in vitro than did oesophageal carcinoma cells their finite growth potential precluded the establishment of any continuous cell lines. Few mitotic figures were evident and cell division occurred in the basal layers of the stratified normal mucosal cultures. Rounded mitotic cells were present throughout the cultures of malignant oesophageal cells and the stratified structure more varied. The normal oesophageal cells from all specimens were similar morphologically and giant cells were not evident in primary cultures though they were occasionally observed during cell senescence. The presence of giant cells may be related to

malignant, and the ability to adapt to *in vitro* conditions as specimens containing malignant cells survived for longer periods *in vitro* than those lacking these cells. The observed differences between normal and malignant oesophageal cells *in vitro* allowed for early recognition of malignant cells after short periods *in vitro*.

11. SUMMARY

The ten continuous human oesophageal carcinoma cell lines established in this study were all derived from invasive tumours, as were other oesophageal carcinoma cell lines reported in the literature. Both biopsied and resected specimens displayed *in vitro* features dependent on their *in vivo* behaviour, though no associations between tumour differentiation, lymphocyte infiltrate and *in vitro* behaviour were noted. Cultured specimens of normal and malignant oesophageal tissue could be distinguished easily on the basis of morphology and length of time *in vitro*.

12 RESULTS

MORPHOLOGY OF NORMAL OESOPHAGEAL MUCOSA IN VIVO

12. 1 LIGHT MICROSCOPY

The histological structure of all specimens of normal oesophageal mucosa examined by light microscopy in this investigation closely corresponded to that described in the literature (Leeson and Leeson, 1970; Desmet and Tytgat, 1974; Rhodin, 1974; Bloom and Fawcett, 1975; Gardner and Dodds, 1976; Hopwood et al., 1977; Junqueira et al., 1977; Logan et al., 1977; Weiss and Greep, 1977; Copenhaver et al., 1978). The stratified squamous non-keratinised epithelia of all normal mucosal specimens comprised layers of cells of varying morphology. Cylindrical basophilic cells of the basal layer were covered by several intermediate layers of polyhedral cells, above which were the flattened cells of the superficial layers (Fig. 37).



Fig. 37 Light micrograph showing the stratified squamous epithelium of normal oesophageal mucosa. Bar = 100 µm

[illegible] TRANSMISSION ELECTRON MICROSCOPY

Although the cells present in the specimens of normal oesophageal mucosa from five different individuals did vary slightly, many common features were observed. Ultrastructural differences were evident between cells of the various layers of the mucosa; cytoplasmic organelles such as mitochondria, golgi apparatus and endoplasmic reticulum were best developed in the basally located cells and virtually absent from those more superficially situated. Few tonofilaments were present in the basal cells, but as the cells became increasingly differentiated tonofilaments became more abundant and many cells near the lumenal surface were packed with filaments of varying density (Fig. 38). These cells displayed complex outlines and the plasma membrane was thickened at intervals (Fig. 39). Corresponding areas of plasma membrane thickening were generally present on adjacent cells and may represent regions where desmosomes were situated. Such thickenings were also well developed on the lumenal surfaces of superficially located cells though marginal band formation was not observed. In the superficial layers of the mucosa intercellular spaces frequently appeared dilated and contained debris.

Well developed intercellular desmosomes with tonofilaments inserting into dense attachment plaques and clearly defined layers of intercellular cementing substance were numerous between prickle cells of the intermediate layer. All desmosomes had a normal morphology and no intracytoplasmic desmosomes were observed in any of the cells examined. Cells in this layer contained aggregates of glycogen and tonofilaments. Glycogen and lipid deposits were also present in the superficial surface cells. The nuclei in some of the cells of the superficial layers frequently displayed margination and clumping of their chromatin. Isolated swollen, apparently degenerating mitochondria with fragmented cristae occurred in the superficial cells, while intact mitochondria were present in the basal cells.

Rod-like structures of diameter 45 nm which resembled the mycoplasmas described by Maistry and Robinson (1990) were occasionally

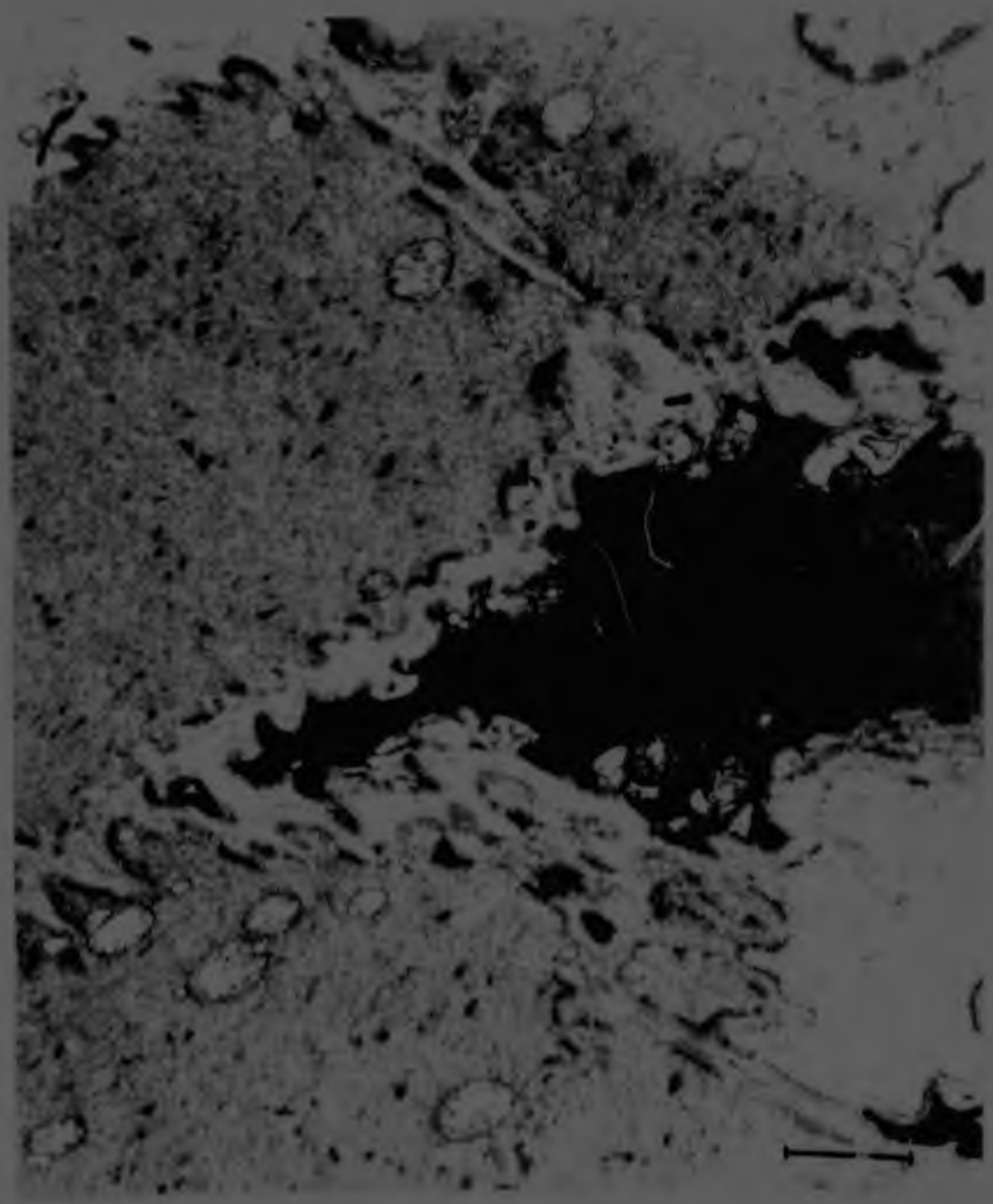

Fig. 38 Transmission electron micrograph of biopsied apparently normal human oesophageal cells. Aggregates of fine filaments replaced most cytoplasmic organelles in the superficially located cells. Variations in cytoplasmic density were related to the numbers of tonofilaments present. Bar = 1 μm

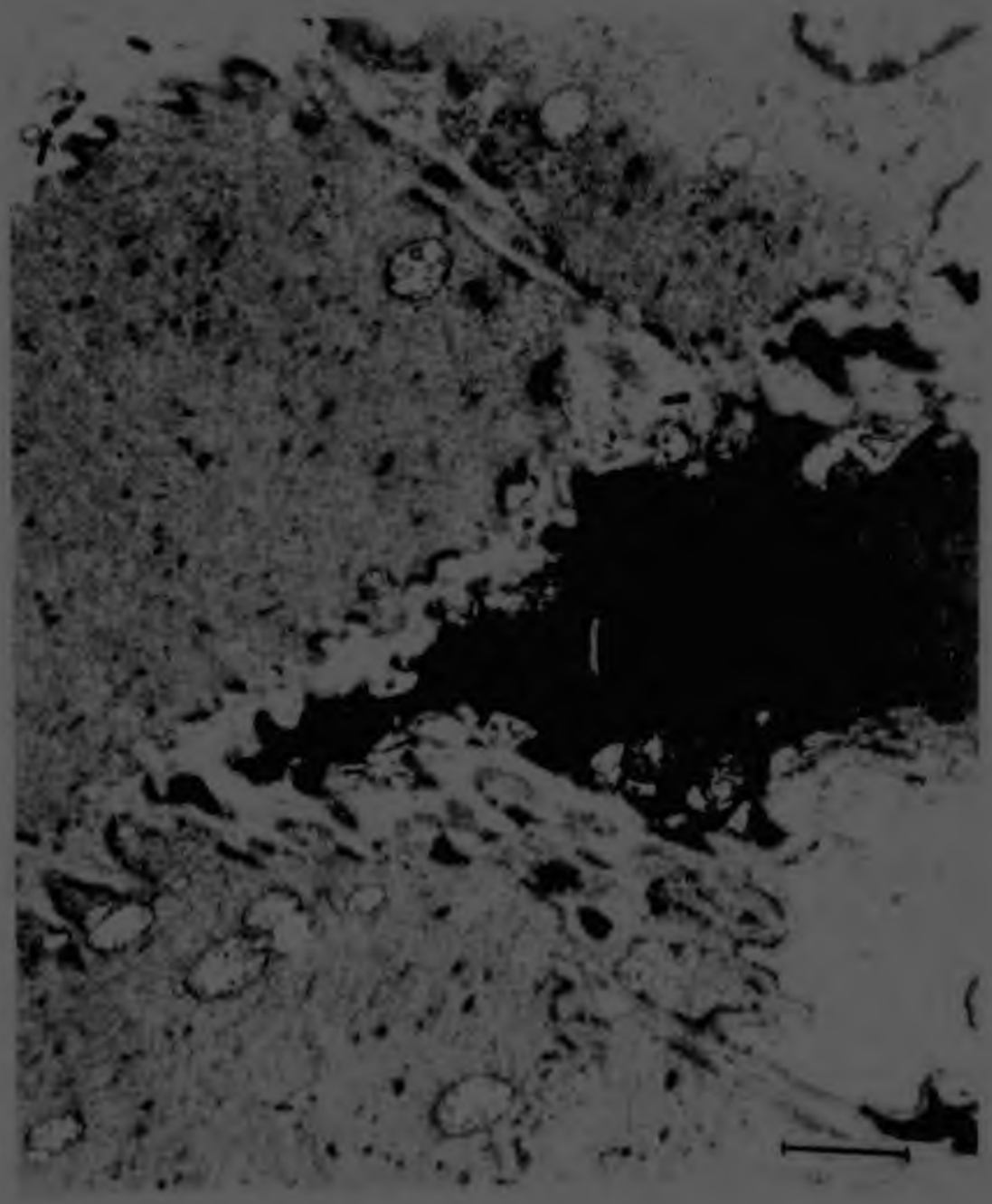

Fig. 3 Transmission electron micrograph of biopsied apparently normal human esophageal cells. Aggregates of fine filaments replaced most cytoplasmic organelles in the superficially located cells. Variations in cytoplasmic density were related to the numbers of tonofilaments present. Bar = 1 μm



Fig. 20 Transmission electron micrograph showing the irregular cellular outlines of adjacent, superficially situated, normal oesophageal cells. Tonofilaments lie in close proximity to the opposed plasma membranes which are thickened at intervals. Bar = 1 μm

observed in the intercellular spaces between apparently normal oesophageal cells and several cells contained large numbers of these structures (Fig. 40). This was the only respect in which the oesophageal mucosal specimens observed in this study differed from those reported by Desmet and Tytgat (1974); Al Yassin and Toner (1977) and Hopwood et al. [illegible].

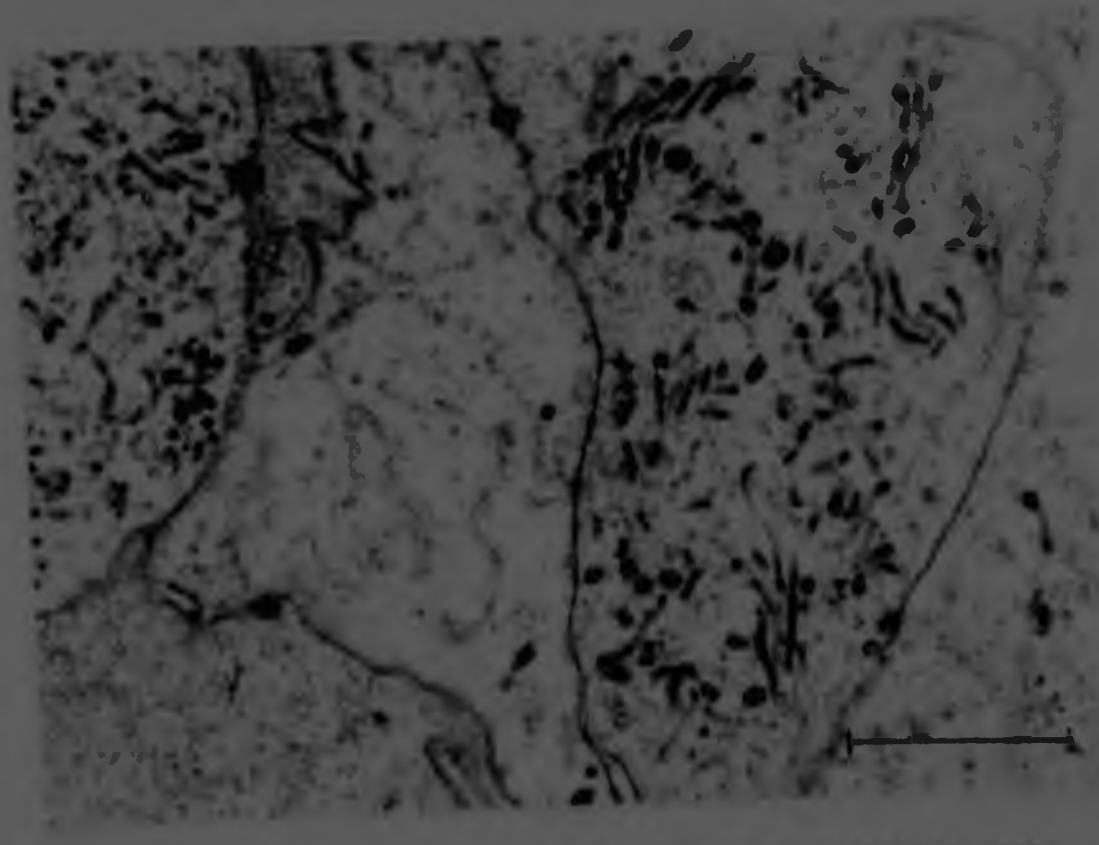

Fig. 40 Transmission electron micrograph of epithelial cells centrally located in normal oesophageal epithelium. Dense rod-like structures of diameter 45nm and lengths of up to 400 nm were present in the cytoplasm. Bar = 1 μm

12. 3 SCANNING ELECTRON MICROSCOPY

The superficial oesophageal cells present in all five specimens of normal human oesophageal mucosa studied were flat polygonal epithelial cells, the surfaces of which were convoluted by numerous microridges or microplicae (Figs. 41 and 42). The microplicae were generally orientated in parallel rows, though variations in this pattern were encountered. The arrangement and distribution of microplicae varied from specimen to specimen and also from cell



Fig. 41 A low magnification scanning electron micrograph of the clearly defined microridges on the superficial surfaces of normal human oesophageal cells. Bar = 10 μm



Fig. 42 A higher magnification scanning electron micrograph showing more detail of the microridges on the superficial surfaces of normal oesophageal cells. Intercellular boundaries are prominent and elevated. Bar = 10 μm

cu cells within the same specimen as can be seen in Figs. 43 and 44



Fig. 43 Scanning electron micrograph showing the variation in number, form and arrangement of microridges on the surfaces of adjacent normal oesophageal cells. Bar = 10 µm

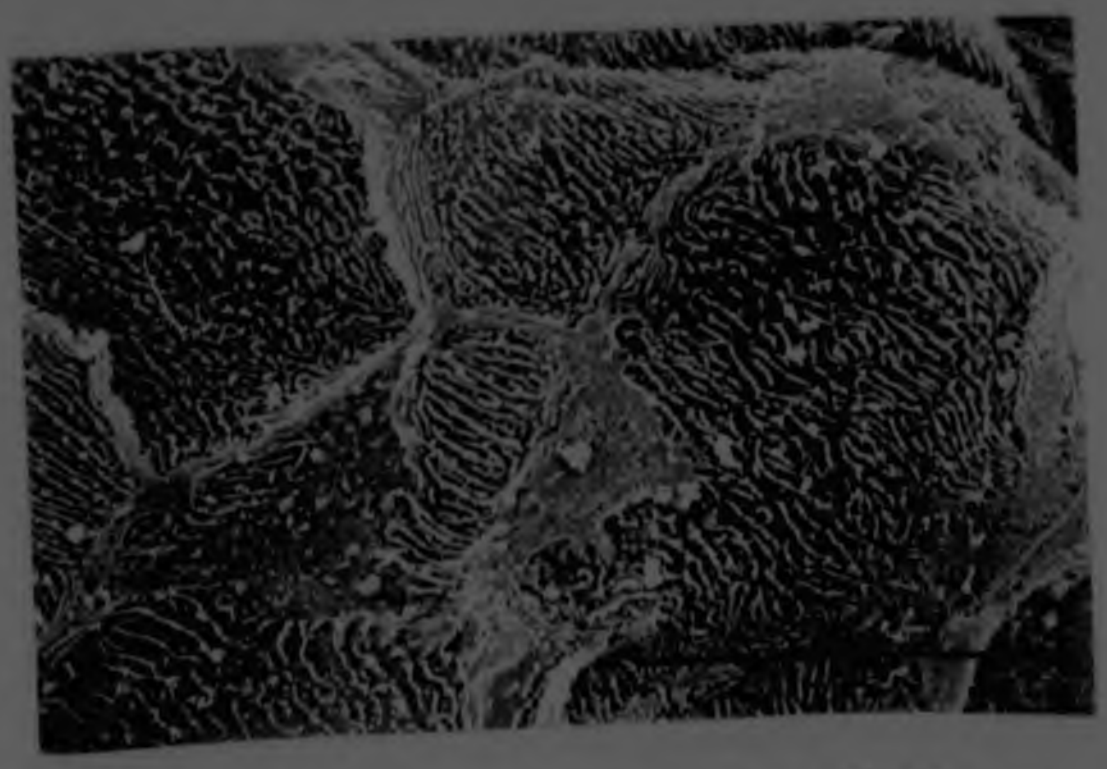

Fig. 44 A scanning electron micrograph of superficial normal oesophageal mucosa showing some cells which are devoided of surface projections. Bar = 10 µm

were adjacent cells show striking differences in the number and size of their surface projections. Interdigitations and coniunctions between branching microplicae of abutting cells appeared likely. The width of the microplicae ranged from approximately 0,1 – 0,2 µm and their height and length varied. Some microplicae were of regular diameter, while others displayed oval or spherical bulges at irregular intervals (Fig. 45).

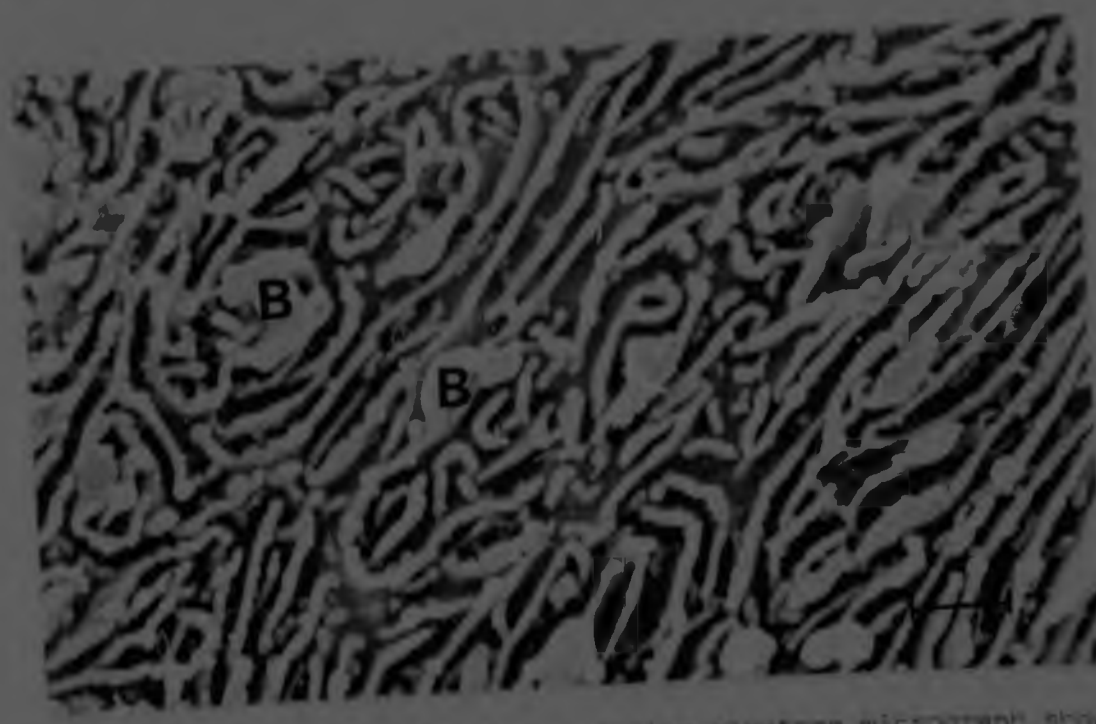

Fig. 45 A high magnification scanning electron micrograph showing bulges (B) at irregular intervals along the microridges on a normal human oesophageal cell. Bar = 1 µm.

The borders between adjacent epithelial cells were distinct and frequently elevated (Figs. 42 and 46) and this was considered a sign of impending desquamation. Many cells appeared to detach from the underlying cells, starting at the site of an intercellular elevation. The cells lying beneath such desquamating cells did not possess as many microplicae as the more superficially located cells. Numerous micro-organisms such as bacteria of 1 – 3 µm in length and fungal spores were observed in close association with the surfaces of the normal oesophageal cells (Fig. 47). The number of such organisms varied from specimen to specimen.

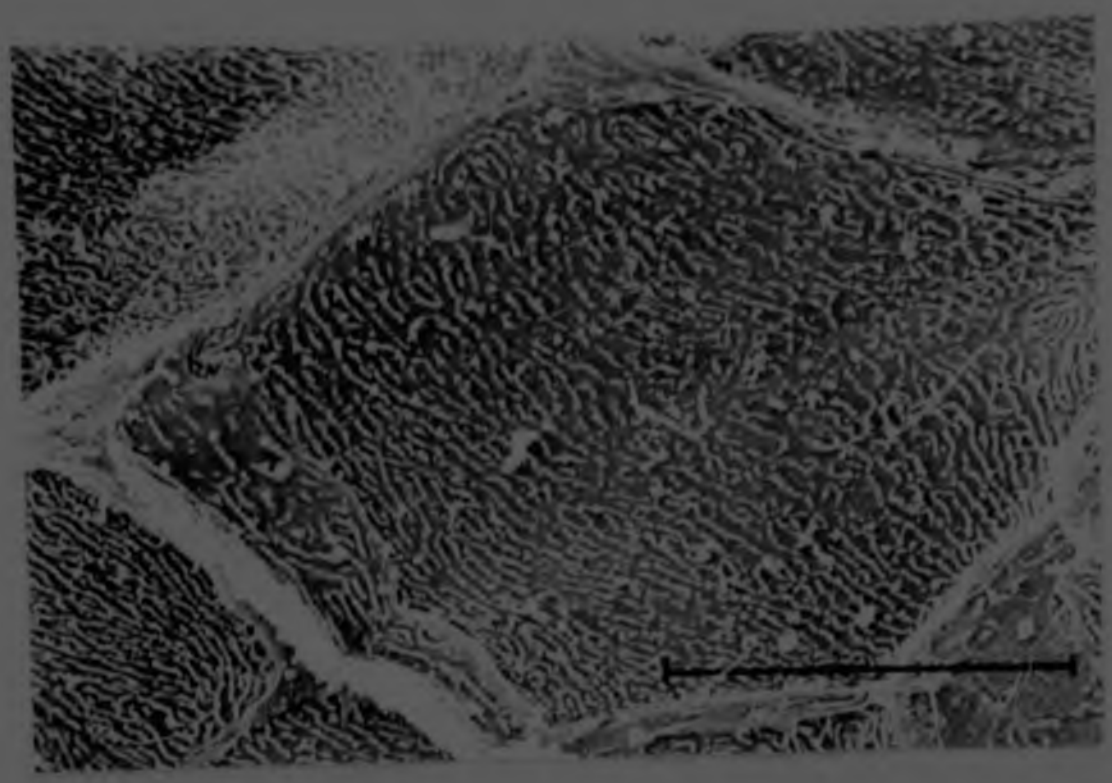

Fig. 46 Prominent intercellular borders between adjacent superficially situated normal oesophageal cells as evident by scanning electron microscopy. Bar = 10 µm

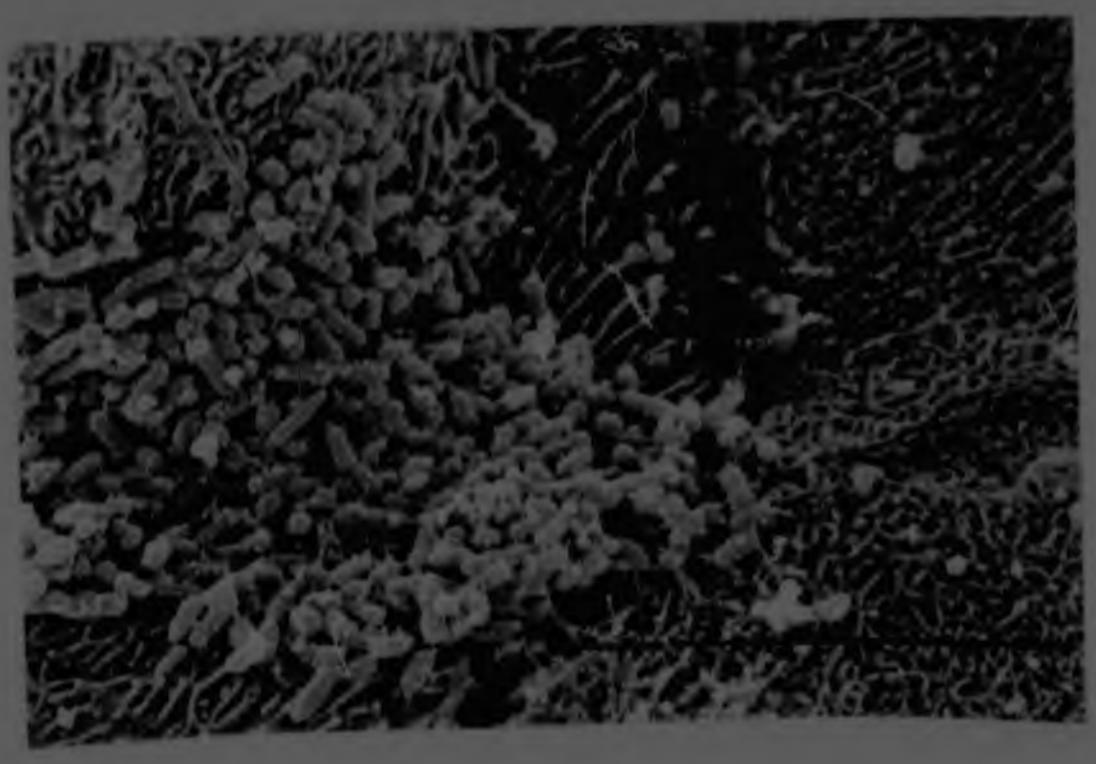

Fig. 47 Scanning electron micrograph showing a cluster of microorganisms associated with the surfaces of normal oesophageal cells. Bar = 10 µm

There was little mucus and debris present considering the size of [illegible] oesophageal [illegible] were infrequently observed. When present, they [illegible] as apparent "holes" of regular outlines in the surface epithelium (Fig. 48).

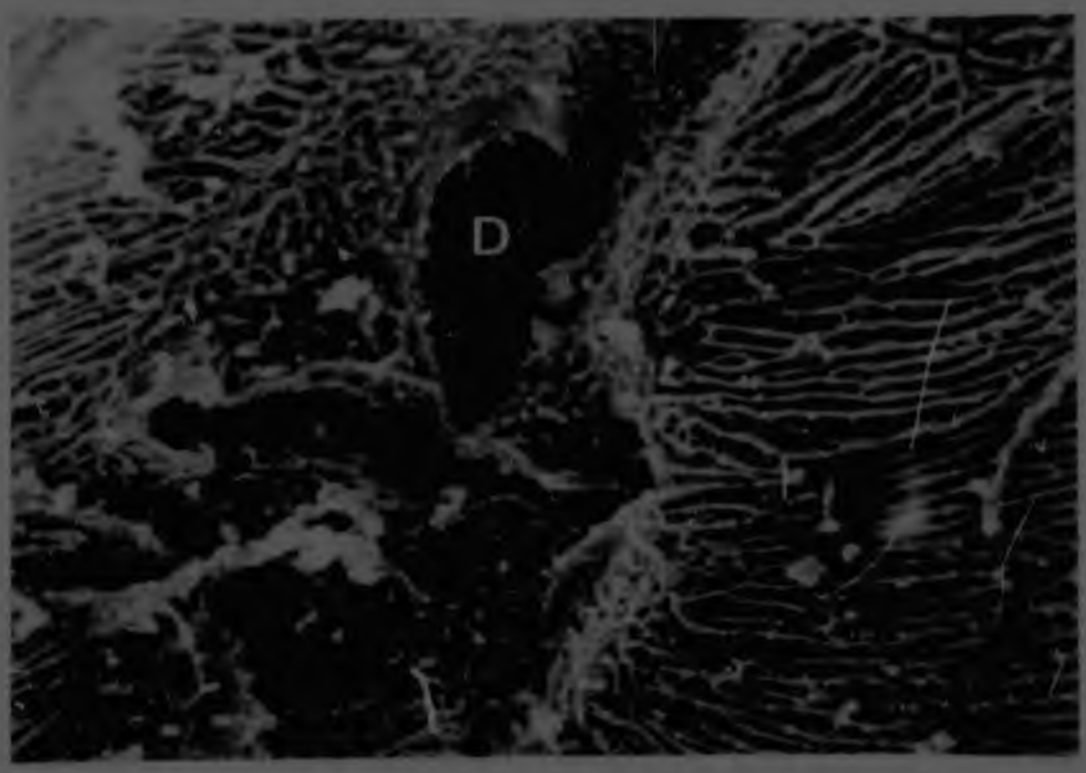

Fig. 48 Scanning electron micrograph of the region where the duct (D) of an oesophageal gland opens on to the surface of the normal oesophageal mucosa. Bar = 5 µm

MORPHOLOGY OF OESOPHAGEAL CARCINOMA SPECIMENS IN VIVO

Oesophageal carcinoma tumour specimens consist of scattered groups [illegible] showing great diversity of size, morphology and [illegible] Robinson and Gregory, 1978; and Robinson and [illegible]. In this investigation foci of keratinisation [illegible]), areas of necrosis and a generally cellular [illegible] abnormalities of desmoplastic reaction were ob- [illegible]). Abundant metachromatic mast cells were [illegible] staining reactions with Toluidine Blue and [illegible] the stroma surrounding several specimens but their [illegible] correlate obviously with any other features of [illegible] specimens. Many cells exhibited prominent nucleoli, [illegible] paranuclear material and others an apparently [illegible] cytoplasm (Fig. 49). Both mono- and multi-



Fig. 49 Light micrograph of Toluidine Blue-stained T 28 oesophageal carcinoma cells. The cells vary in size and density and several contain prominent nucleoli. Bar = 10 µm

nucleate giant cells were present in most of the spec

13. [illegible]

Ultrastructural features of the cells in twelve tumour spec[illegible] are summarised in Table 24.

13. 2. 1 Nuclear features

Nuclear morphology varied from specimen to specimen and even within the same specimen. Some nuclei were invaginated and contained inclusions while others were regular in size and outline. Both single and multiple nucleoli were prominent in all tumours examined.

Intranuclear particles ranging in diameter from 20 - 30nm were present in clusters in several cells from specimens T 24 and T 35 (Fig. 50). Similar particles were also observed in a continuous human oesophageal carcinoma cell line (Chapter 15) and in specimens of human oesophageal carcinomas grown in the nude mouse (Chapter 18).

13. 2. 2 Desmosomes

A range in desmosome number, morphology and position was evident in the different specimens examined (Table 24). Desmosomes were most prominent in the well differentiated tumours where they were present at regular intervals and closely associated with tonofilaments. However, intercellular desmosomes were present in most specimens and consisted of two dense attachment plaques 15nm thick separated by a 35nm interval within which the intercellular contact layer, intermediate layers and light layers were situated. In some specimens desmosomes ranged in diameter from 60 - 90nm and showed variation in the thickness and number of layers present.

Intracellular or internalised desmosomes were typically present in paranuclear positions in T 23, T 24, T 25, T 27, T 28 and T 35. These structures occurred at intervals (Fig. 51) with no evidence of cell membranes between them. Several bands of cementing

TABLE V ULTRASTRUCTURAL FEATURES OF CANINE MAMMARY TUMOUR SPECIMENS IN VIVO

Tumour number	Differentiation	Tonofilaments	Desmosomes[1]	Nucleus	Chromatin	Nuclear pertinin	RER	Golgi	Fat	Glycogen	Mitochondria	Microfilaments	Other
T 22	+++	++	I	irregular, inclusions	fine	-	+	+	+	+++	++	+++	myelinoid bodies, cytoplasmic filaments
T 23	++	++	I,E	inclusions	clumped	large, irregular	+ dilated	+	+	+	++ pale	+++	vacuolated cytoplasm
T 24	+++	+++	I,E	invaginated	clumped	0-fine	++	+	—	++	+	+	cytoplasmic granules, filaments and dense bodies
T 25	+++	+++	E	invaginated	clumped	-	+	+	—	++	+	+	vacuolated cytoplasm
T 26	+++	+++	I	invaginated	fine	-	+	+	—	++	+ pale	--	myelinoid bodies
T 28	+	+	I,E	regular	clumped	-	++ dilated	++	—	+	++ swollen	+	cytoplasmic filaments
T 29	+++	—	E	invaginated	fine	-	+	++	—	—	++ doughnut forms	—	membranous bodies
T 31	+	—	E	regular	fine	-	+	+	—	—	+++ pale	+	-
T 32	+++	++	I,E	regular	fine	-	+	+	—	—	+ pale	++	aggregates of free ribosomes
T 33	+++	+	E	regular, inclusions	clumped	0-fine	+ dilated	+++	—	—	++ pale	+++	cytoplasmic filaments, membranous whorls, concentric cisternae
T 34	+++	+++	E	invaginated	fine	-	++	+	—	—	+ pale	+++	myelinoid bodies
T 35	+++	+++	I	invaginated, inclusions	clumped	large, irregular	+	+	—	+	+	+++	fine cytoplasmic granules

[1] I - Internalised / intracytoplasmic desmosomes
E - External / intercellular desmosomes



Fig. 50 Transmission electron micrograph showing a cluster of 20 - 30nm diameter particles within the nucleus of T 24 cell. Bar = 1 μm

substance were evident between the attachment plaques which were associated with tonofilaments. Intracellular electron-dense circular plaques surrounded by lighter peripheral regions were present at intervals and may represent sections through the cell membrane attachment of adjacent cells parallel to the cell membrane or different planes of section of the intracellular desmosomes present within a single cell.

13. 2. 3 Tonofilaments

There was a strong correlation between histological grading of the tumours and tonofilament number.

Cells of the well differentiated tumours contained abundant electron dense tonofilaments, generally in a paranuclear position.

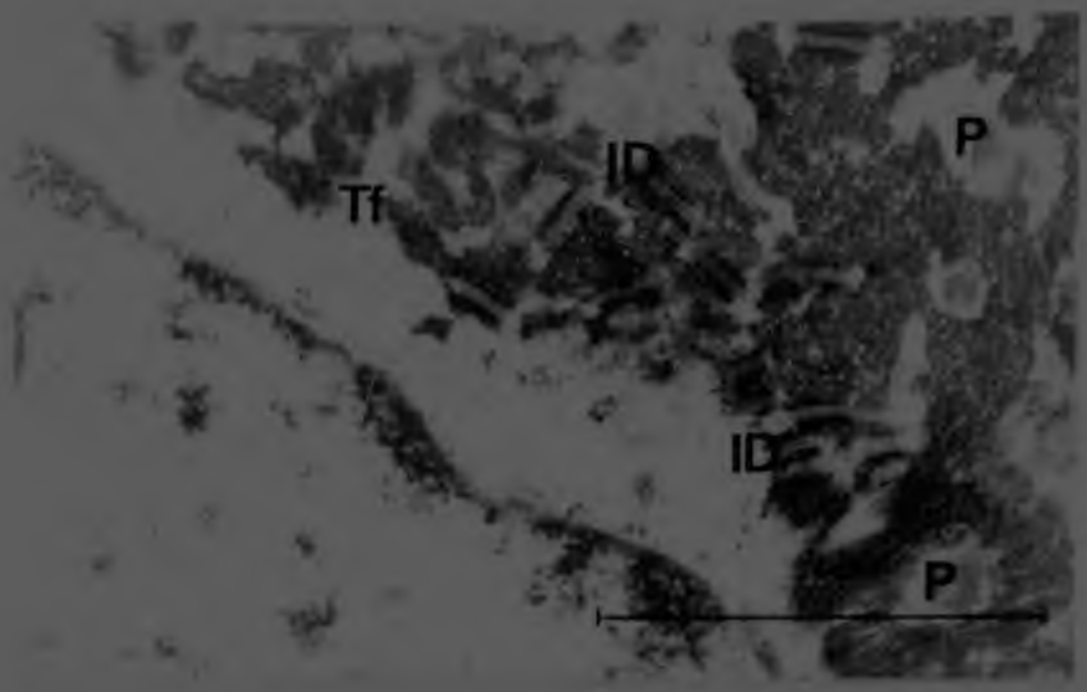

Fig. 51 Transmission electron micrograph showing well developed tonofilaments (Tf) and internalised desmosomes (ID) in a paranuclear position in a T 24 cell. The desmosomes range in diameter and several layers of cementing substance are present. Intracellular electron dense circular plaques (P) surrounded by electron lucent regions are evident. Bar = 1 μm

T 33 possessed fewer tonofilaments than expected on the basis of the histopathological differentiation reported and these structures were not observed in T 29. Some cells from T 35 contained masses of interweaving tonofilaments which replaced most other organelles, and filled the cytoplasm (Fig. 52).

13. 2. 4 Other cytoplasmic filaments

Aggregates of fine filaments which ranged in diameter from 8 - 14nm (fine and intermediate filaments) and differed from tonofilaments, both in arrangement and electron density, were present in several specimens. Paranuclear aggregates of these fine filaments were prominent in T 22 (Fig. 53) and were often in close proximity to aggregates of glycogen. Similar filaments were better developed and more abundant in degenerating cells from T 22 where they formed bands of 2 - 4 μm diameter around involuted nuclei (Fig. 54).



Fig. 32 Transmission electron micrograph showing bundles of interweaving tonofilaments occupying most of the cytoplasm of a T-5 cell. Bar = 1 μm

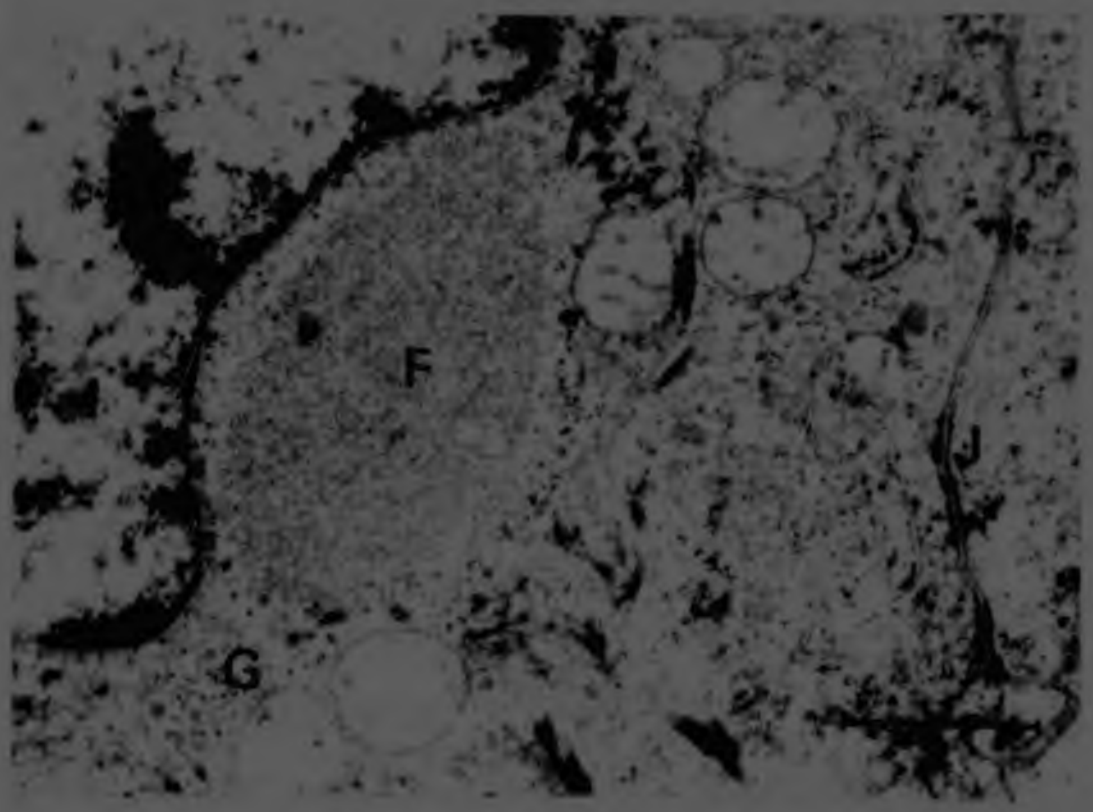

Fig. 20 Transmission electron micrograph of a T 22 cell containing a paranuclear accumulation of filamentous material (F). The filaments are 8 - 14 nm in diameter and differ from the larger cytoplasmic glycogen particles (G). A junctional area (J) between adjacent cells is well developed. Bar = 1 µm



Fig. 54 Transmission electron micrograph showing multiple fine filaments forming a 2 - 4 µm band around the degenerating nucleus of a T 22 cell. The entire structure appears to lie within the cytoplasm of another cell. Bar = 1 µm

Occasional desmosomal remnants were present at intervals in the filamentous meshwork.

Filamentous bundles and membranous folds were prominent in T 24 and occupied large areas of the cytoplasm in some cells (Fig. 55). Membranous folds and irregular spaces were present between the filaments.

13. 2. 5 Myelinoid figures and cytoplasmic bodies

Bizarre, whorled cytoplasmic bodies were seen in a paranuclear position in a giant cell from T 24 (Fig. 56). These structures ranged in diameter from 1,6 - 1,8 µm and consisted of concentrically arranged membranous profiles between which were located particles 16 - 19 nm in diameter (Fig. 57). Although these bodies were within the limits of resolution of the light microscope they

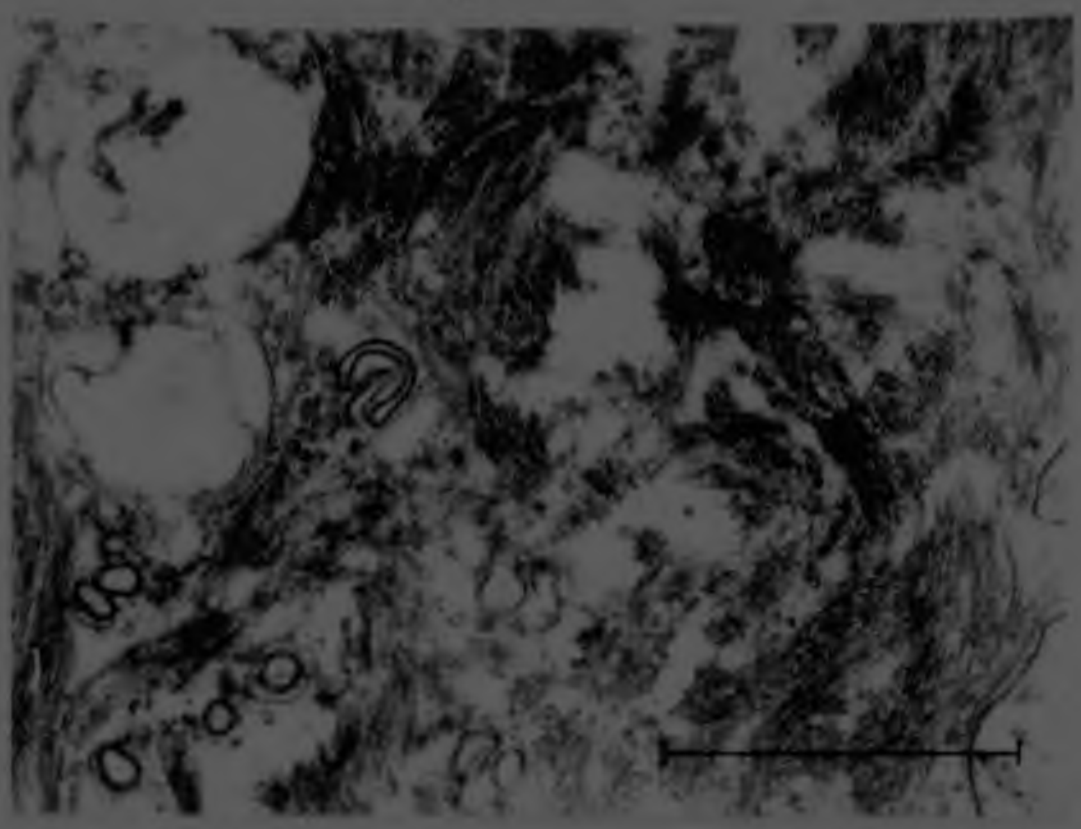

Fig. 55 Transmission electron micrograph showing fine filaments of diameter 8 - 12 nm in the cytoplasm of a T 24 cell which is situated close to the boundary between tumour cells and stroma. Membranous folds are present at intervals. Bar = 1 µm

were not evident by light microscopy as being either strikingly eosinophilic or basophilic. Other cytoplasmic bodies as seen in T 24 were thought to represent developing forms and consisted of paired membranous profiles (15 - 19 nm in diameter) with associated 15 - 20 nm particles, becoming arranged in a concentric fashion (Fig. 58). Numerous myelinoid figures of varying form and size (up to 2,2 µm in diameter) were observed in cells from most specimens, as were aggregates of glycogen and fat droplets. Lenis cytoplasmic bodies (3 - 4 µm in diameter) containing lipid glycogen, other particulate matter, membranous debris and hollow vesicles (Fig. 59) were also frequently present.



Fig. 56 Transmission electron micrograph of bizarre, whorled, granular bodies (W) in the cytoplasm of a giant T 24 oesophageal carcinoma cell in vivo. Internalized desmosomes (ID) and aggregates of tonofilaments (Tf) are also present. Bar = 1 µm

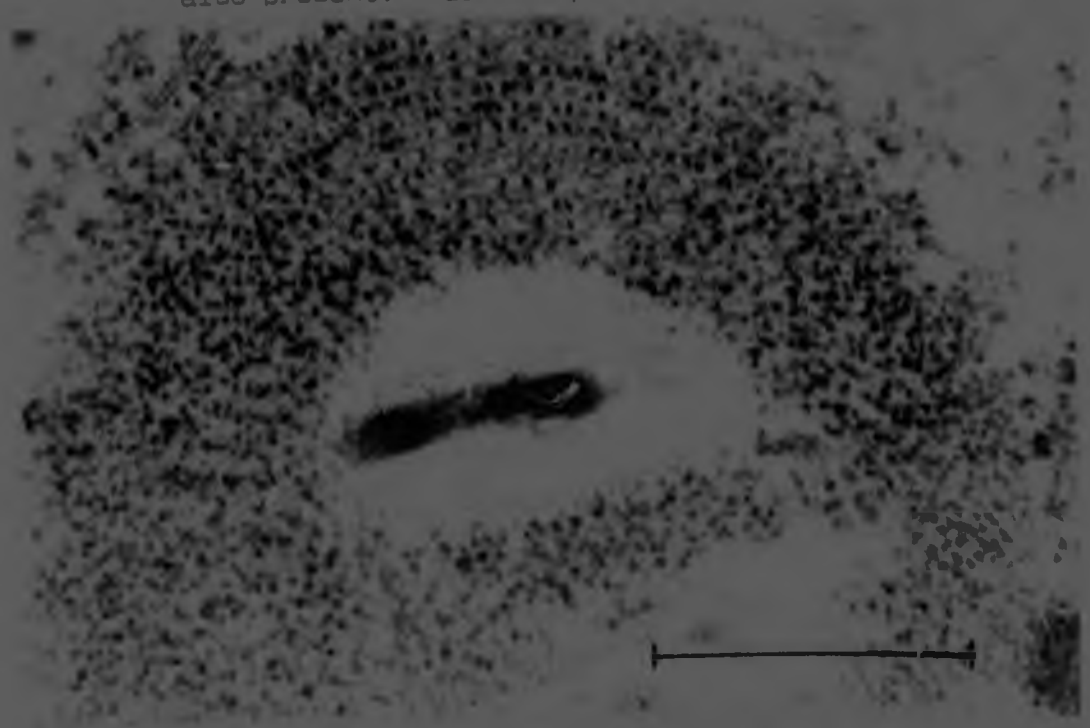

Fig. 57 Transmission electron micrograph of a T 24 cell showing part of a whorled granular body with concentrically arranged 15 - 19 nm membranous profiles between which are located 16 - 19 nm particles. A central electron dense inclusion is present. Bar = 0,5 µm

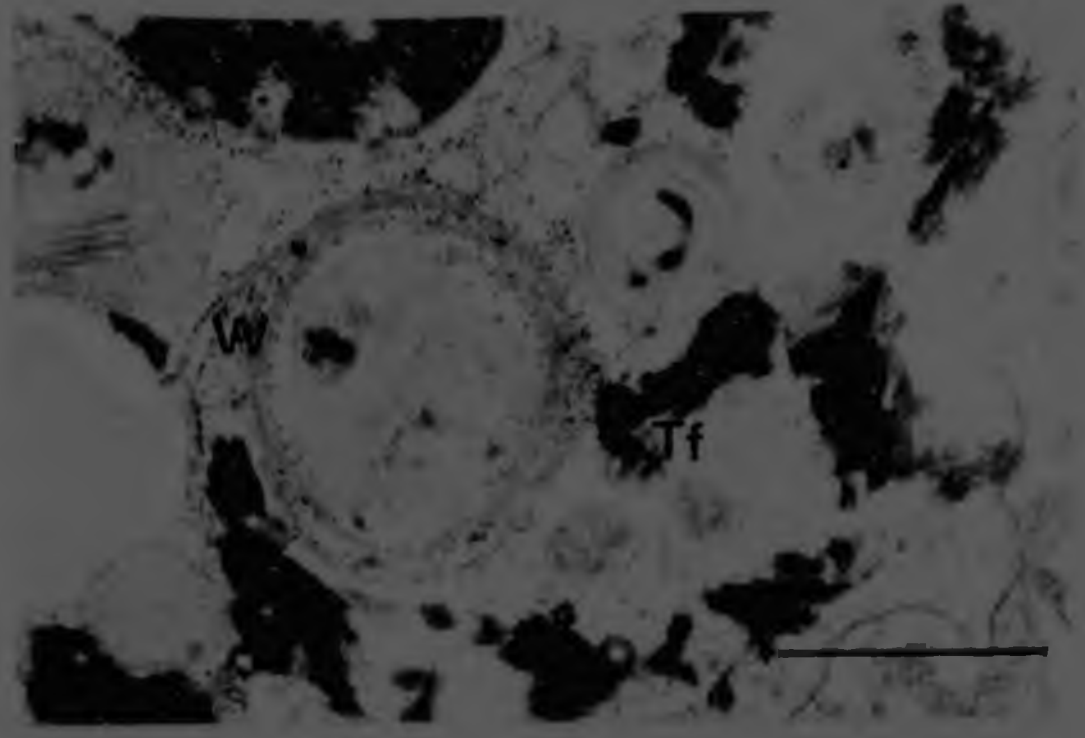

Fig. 53 Transmissior electron micrograph showing paired membranous profiles apparently in the process of forming a whorled cytoplasmic body (W) in a T 24 cell. Electron dense tonofilaments (Tf) are well developed. Bar = 1 µm

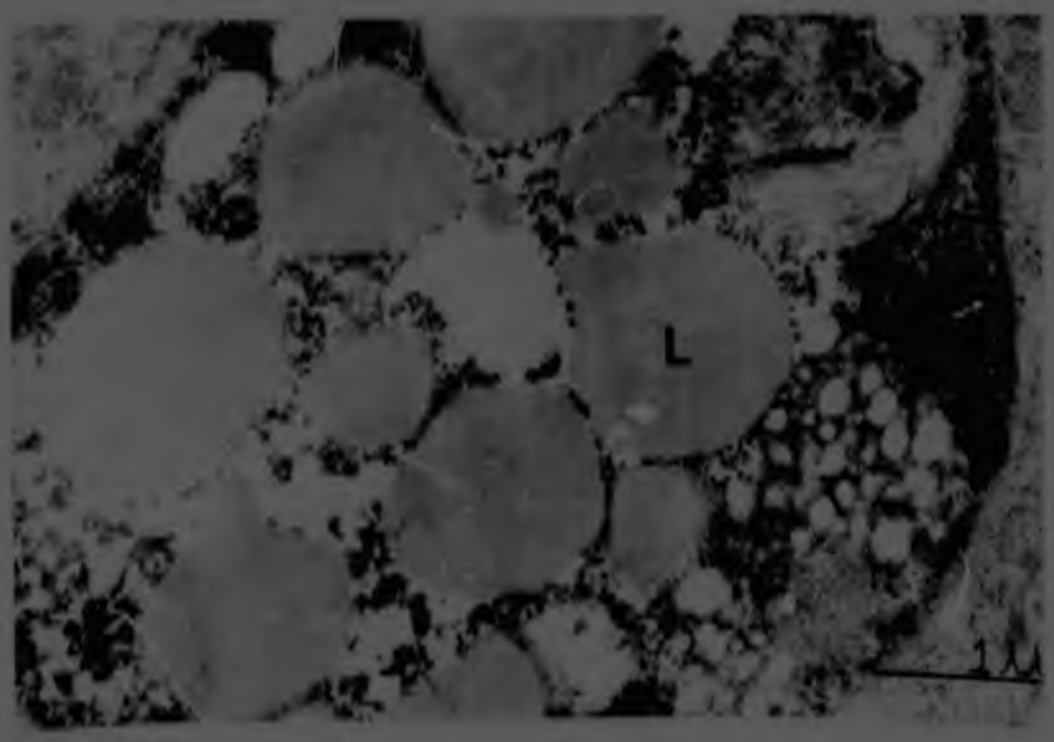

Fig. 54 Transmission electron micrograph showing a 3,4 µm diameter membrane bound cytoplasmic body in a T 23 cell. The structure contains lipid (L) glycogen (G) and particulate matter. Bar = 1 µm

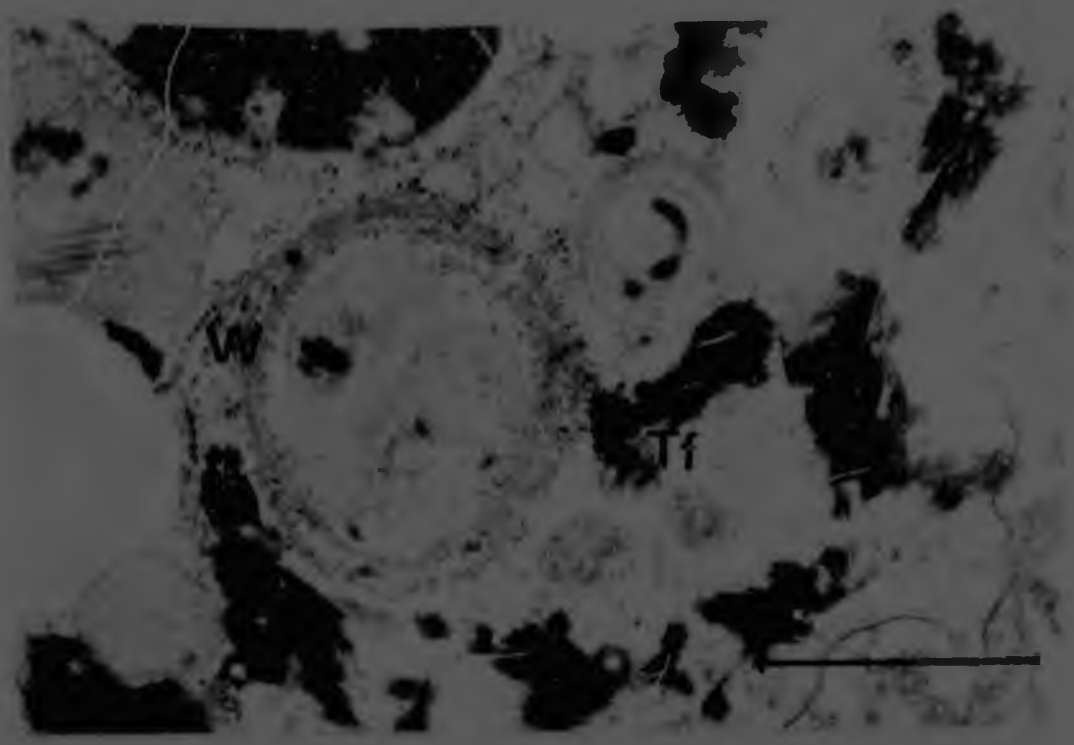

Fig. 58 Transmission electron micrograph showing paired membranous profiles apparently in the process of forming a whorled cytoplasmic body (W) in a T 24 cell. Electron dense tonofilaments (Tf) are well developed. Bar = 1 µm

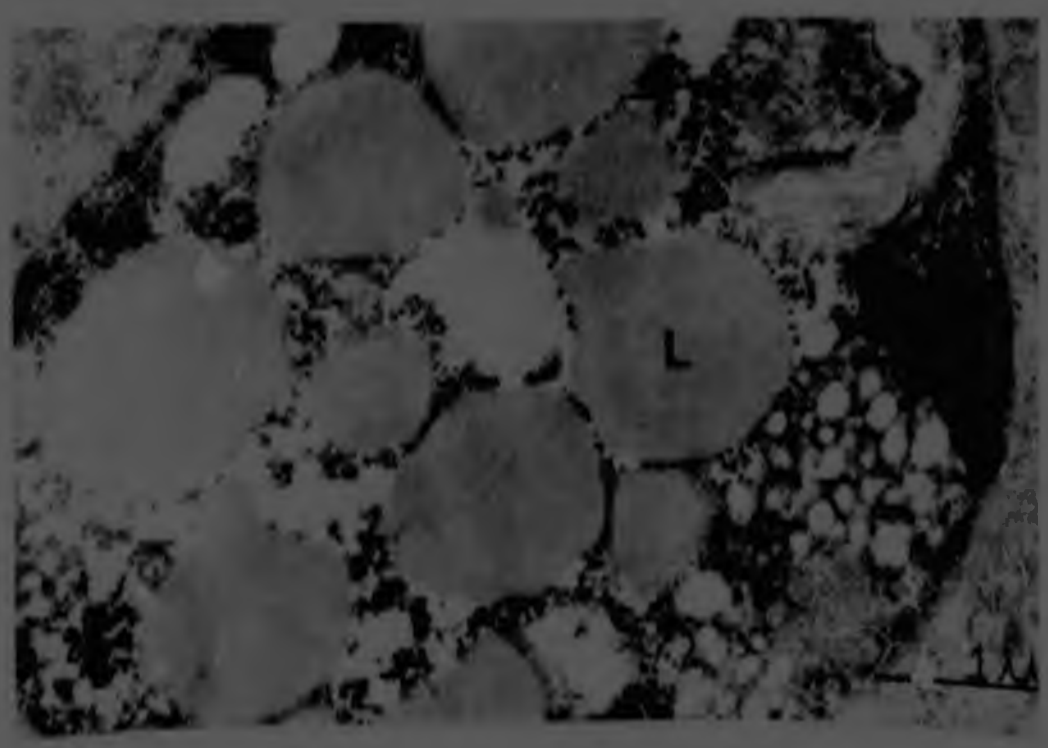

Fig. 59 Transmission electron micrograph showing a 3,4 µm diameter membrane bound cytoplasmic body in a T 23 cell. The structure contains lipid (L) glycogen (G) and particulate matter. Bar = 1 µm

13. 2. 2 Other cytoplasmic organelles

In general, the oesophageal carcinoma cells *in vivo* were deficient in cytoplasmic organelles and appeared pale (electron lucent) and sometimes vacuolated, though tumours T 23, T28 and T 31 consisted of populations of both dark and light cells. Cytoplasmic organelles were better developed in the poorly differentiated tumours, and were most prominent in T 29.

Mitochondria of varying morphology were present in the tumour specimens. Some cells contained pale mitochondria with few cristae while the mitochondria of specimens T 29 and T 31 possessed internal vesicles. Those of T 29 (Fig. 60) were similar to doughnut mitochondria described by Ghadially (1975), though these may not be true doughnut forms but merely contain concentric cristae.



Fig. 60 Transmission electron micrograph showing portions of adjacent dark and light T 29 cells. Mitochondria (M) with tubular and circular cristae are present in the light cell. Bar = 1 µm

The rough endoplasmic reticulum was occasionally dilated, and the amount of golgi apparatus present varied from specimen to specimen. No annulate lamellae or confronting cisternae were observed, but this may have been due to sampling error, rather than to their total absence from oesophageal carcinoma specimens *in vivo*, as only small areas of each tumour specimen could be examined by transmission electron microscopy.

In summary, oesophageal carcinoma cells *in vivo* showed varying morphology and were characterised by bizarre cytoplasmic bodies, intracellular desmosomes and filamentous aggregates. These malignant cells could be distinguished readily from corresponding normal human oesophageal cells.

13. 3 SCANNING ELECTRON MICROSCOPY

Examination of the cut surfaces of four resected tumour specimens provided little information on the surface features of oesophageal carcinoma cells. More useful information was obtained by examining the small artifact-free surfaces of four superficial tissue specimens of oesophageal carcinomas which had ulcerated through to the lumen of the oesophagus. At low magnifications there were no marked differences between the superficial surfaces of specimens of normal and malignant oesophageal mucosa. Differences were, however, evident when the cell surfaces were viewed at higher magnifications.

Although many malignant cells possessed fine surface projections or microplicae (Fig. 61) these structures were not as well developed or clearly defined nor as complexly arranged as those on normal oesophageal cells (Figs. 41 -). The microplicae present were not uniformly distributed over the cell surfaces and neither the cells with microplicae nor those lacking these structures displayed the raised lateral edges and prominent cell boundaries typical of normal oesophageal cells. There was little evidence for cell desquamation and these specimens appeared less regular and "organised" than those of normal oesophageal mucosa. Many of the surface cells in the malignant biopsy specimens were

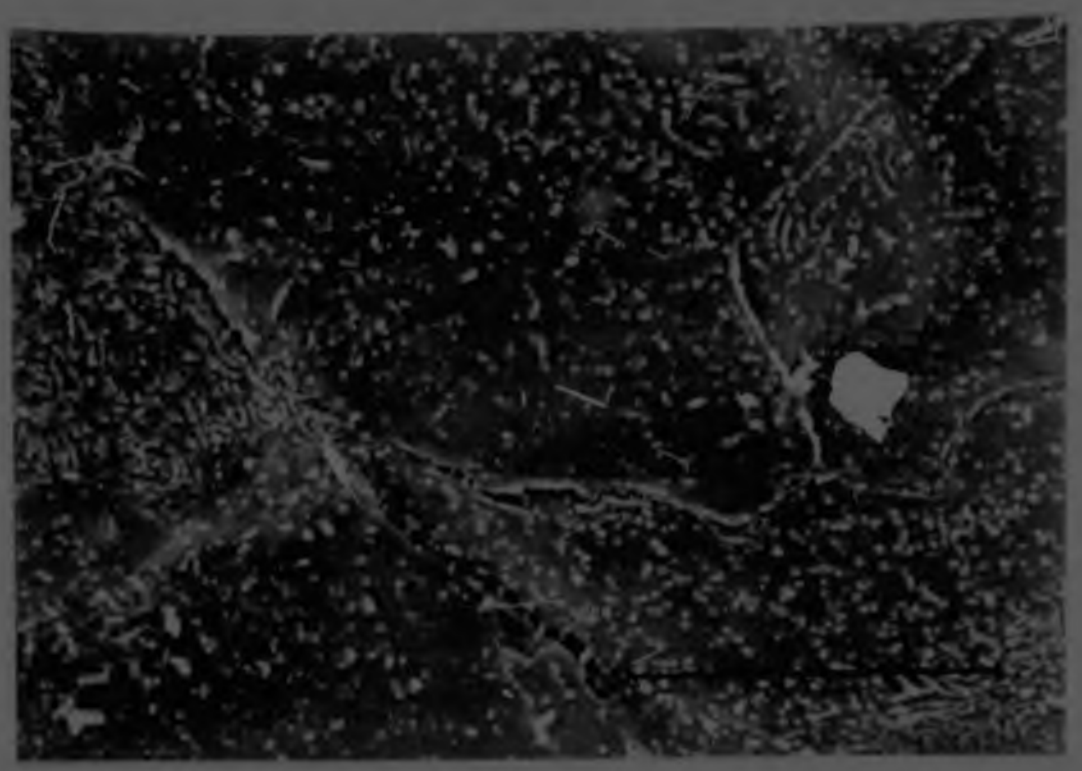

Fig. 61 Scanning electron micrograph showing the sparse, irregular microplicae and scanty microvilli on the superficial surfaces of biopsied malignant oesophageal cells. Bar = 10 μm

rounded and differed in this respect, in packing arrangement and also in size from the typical large flattened squames present on the superficial surfaces of normal oesophageal mucosa (Fig. 61). Micro-organisms of varying form were detected on the surfaces of some of the superficial oesophageal carcinoma cells.

Although there were some similarities between the surface features of normal and malignant human oesophageal cells when these cells were examined by scanning electron microscopy, distinct surface differences which should facilitate the distinction between normal and malignant oesophageal cells were recognised.

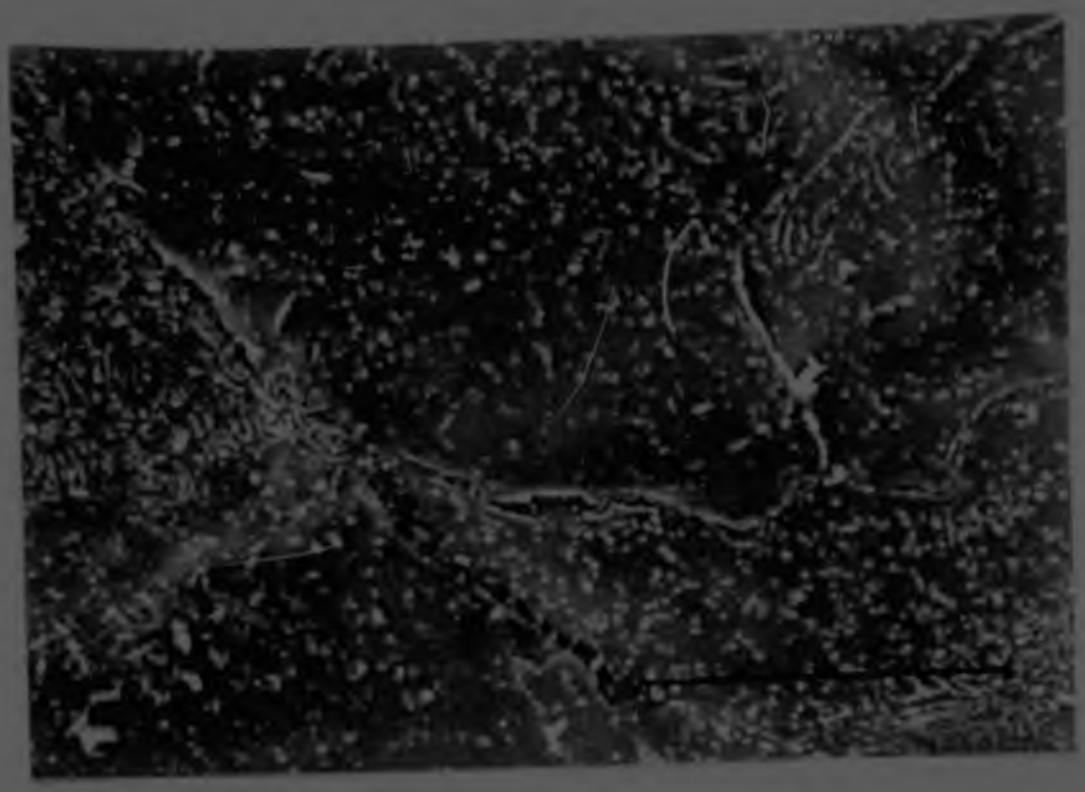

Fig. 61 Scanning electron micrograph showing the sparse, irregular microplicae and scanty microvilli on the superficial surfaces of biopsied malignant oesophageal cells. Bar = 10 μm

rounded and differed in this respect, in packing arrangement and also in size from the typical large flattened squames present on the superficial surfaces of normal oesophageal mucosa (Fig. 61). Micro-organisms of varying form were detected on the surfaces of some of the superficial oesophageal carcinoma cells.

Although there were some similarities between the surface features of normal and malignant human oesophageal cells when these cells were examined by scanning electron microscopy, distinct surface differences which should facilitate the distinction between normal and malignant oesophageal cells were recognised.

14 RESULTS

MORPHOLOGICAL FEATURES OF CULTURED NORMAL HUMAN OESOPHAGEAL MUCOSAL CELLS

As normal cells have a finite lifespan and do not adapt readily to *in vitro* conditions to become established lines (Gierd *et al.*, 1970), it was only possible to examine primary cultures and early subcultures of normal oesophageal cells in this investigation.

14. 1 LIGHT MICROSCOPY

All 20 specimens of apparently normal human oesophageal mucosa (Table 3) grown for short periods *in vitro* showed similarities when examined by phase contrast and interference microscopy as well as by conventional light microscopy (haematoxylin and eosin, May Grunewald-Giemsa). Few morphological differences between primary cultures and early subcultures of oesophageal cells were evident. The cultured epithelial cells showed some morphological similarities to those derived from a tracheo-oesophageal fistula and cultured by Syverton and McLaren (1958), though, in the current study, the cells were closer together and appeared to be more tightly adherent to one another.

The cultured mucosal cells were stratified and there was little evidence of desquamation of the superficial cells. The normal cells were fairly uniform in size and morphology though larger cells were present near the growing edges of the cell sheets (Fig. 13). Nuclei were generally present and regular in outline and multiple nucleoli not observed [Chapter 7]. Neither giant cells nor rounded refractile mitotic figures were evident. Fine refractile branching processes were present at intervals overlying the epithelial cells (Fig. [illegible] in most of the mucosal cultures.

14. 2 TRANSMISSION ELECTRON MICROSCOPY

Five specimens of cultured normal (apparently non neoplastic) oesophageal mucosa were examined by transmission electron microscopy. Since all of the specimens were consistently similar, this area of investigation was not extended further. The cultured oesophageal mucosal cells all grew in a stratified fashion (Fig. 62) and these cells, *in vitro*, showed many ultrastructural similarities to normal oesophageal epithelial cells *in vivo* as described by Hopwood *et al*., 1978. Cell borders were complex and numerous interdigitating lateral processes were observed. Desmosomes were all external or intercellular and functioned in cell attachments. Although keratinisation did not appear to be taking place and no marginal bands, membrane coating granules or keratohyaline granules were recognised, the more superficial cells were more highly differentiated and contained aggregates of fine filaments. Such



Fig. 62 Transmission electron micrograph showing the stratified arrangement of normal human oesophageal cells *in vitro*. The more superficially situated cells contain more tonofilaments and fewer organelles than those located basally. Bar = 1 µm

filaments were not as electron dense as the tonofilaments observed in tumour specimens of well differentiated oesophageal carcinomas in vivo (Chapter 13). Aggregates of glycogen were present in many of the superficial cells. Free ribosomes were numerous and other cytoplasmic organelles were normal in morphology. Few autophagic vesicles or lamellar bodies were recognised.

14. 3 SCANNING ELECTRON MICROSCOPY

Five specimens of normal oesophageal mucosa were grown on glass coverslips and examined by scanning electron microscopy. All of the observed cells possessed morphologically similar features and will be grouped together in the description which follows.

The flattened oesophageal cells growing from the mucosal explants appeared well preserved and sporadic fine projections or microvilli, as well as some complex lateral interdigitations were observed. In order to visualise what little surface detail there was and to overcome the poor contrast it was necessary to tilt the specimens to 60° and to use accelerating voltages of 20 - 25 kV.

The explants themselves were not well preserved and many cells in these regions appeared to have degenerated. Charging and movement of these regions was a problem. Adherent cells which had migrated some distance from the explants were best examined. Refractile rounded mitotic cells with surface blebs were not observed. The flattened epithelial cells were packed in a crazy paving arrangement, though many cell boundaries were indistinct. Cells in the central regions of the epithelial sheets showed virtually no surface detail apart from a slight elevation overlying the nucleus. There was no evidence of microplicae or microridges (Fig. 63) and the surfaces of all cultured normal oesophageal cells showed few elevations (Fig. 63) and thus differed markedly from those of normal oesophageal cells in vivo (Chapter 12). Occasional short stubby microvilli, some of which showed fine branching, were observed and cells which appeared to have fairly numerous microvilli were found adjacent to cells which possessed apparently no surface detail.



Fig. 63 Scanning electron micrograph of flattened normal oesophageal cells near the growing edge of a cell sheet. Cell boundaries are indistinct and sparse fine surface microvilli are present. Bar = 10 µm

An undulating growing edge which correlated well with that observed by interference microscopy (Fig. 13) was present around most of the explants (Fig. 63) and the cells in these regions showed slightly more surface detail and appeared less tightly adherent to the substrata. Where these cells had lifted off the substrate thick and branched attachment fibrils or lateral processes were present (Fig. 64). There was no evidence for the existence of clearly defined leading edges or lamellipodia. While lateral processes or attachment fibrils were fine and well preserved on some of the normal oesophageal cells bordering the region of growth, intercellular interdigitations, on the other hand, were considerably thicker and shorter and some cell junctions appeared complex and showed networks of fine processes (Fig. 65). In the regions of the explants there were several large and prominent apparently dead cells lying above the monolayer. Such cells exhibited branching processes of diameter 0,2 µm with bulges at intervals.

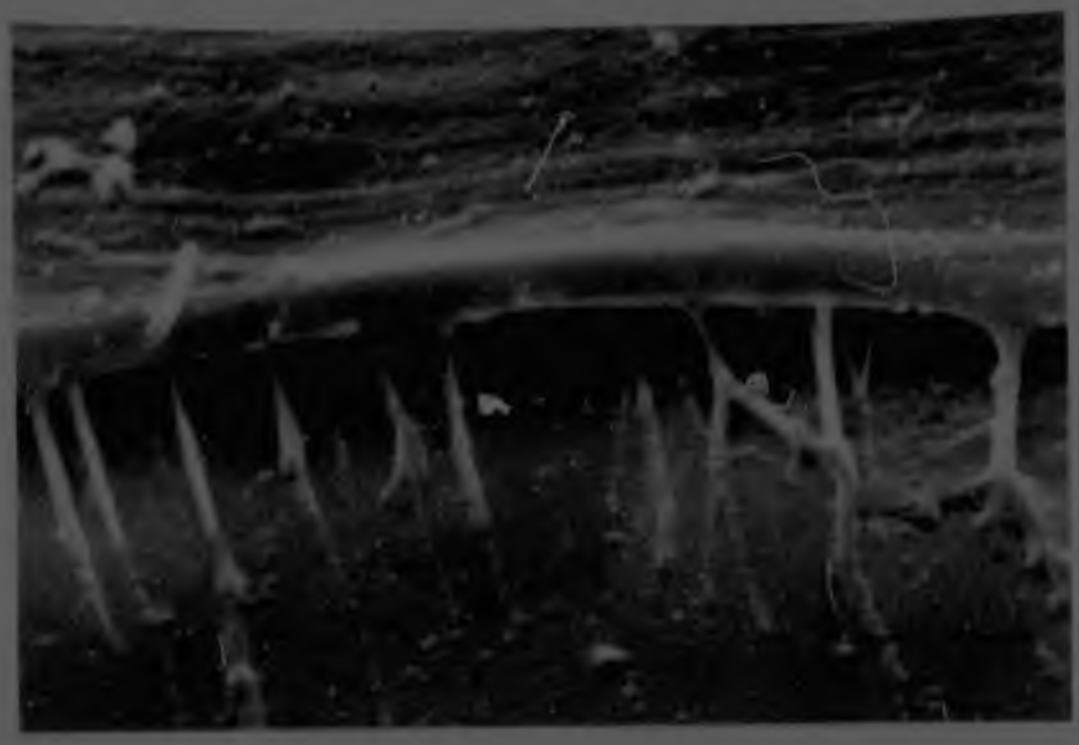

Fig. 64 Scanning electron micrograph showing the branching attachment fibrils anchoring a normal oesophageal cell to the glass substrate. Bar = 1 μm.



Fig. 65 Scanning electron micrograph of the complex, well developed intercellular interdigitations between adjacent normal oesophageal cells <u>in vivo</u>. Bar = 1 μm

made contact with a number of cells and terminated near the growing edges of the cell sheet. Similar processes were observed by scanning microscopy (Fig. 10), though these were larger (1 - 2 μm) and did not make contact with all of the epithelial cells. Such processes have not been described in normal oesophageal mucosa *in vivo*.



Fig. 10 A fine meshwork of branching processes superficial to cultured normal oesophageal cells as revealed by scanning electron microscopy. Bar = 10 μm

15 RESULTS

MORPHOLOGICAL FEATURES OF CULTURED HUMAN OESOPHAGEAL CARCINOMA CELLS

Since neoplastic cells from several oesophageal carcinoma specimens grew well *in vitro* (Chapters 8 and 9), it was possible to examine both primary cultures of malignant oesophagus, as well as ten continuously growing oesophageal carcinoma cell lines at different passage levels.

15. 1 LIGHT MICROSCOPY

All successful primary and continuous cultures of malignant epithelial cells obtained in this investigation were examined live by interference and phase contrast microscopy (Figs. 15 - 31) and, fixed and stained, by conventional light microscopy. The carcinoma cells from different specimens varied in size, granularity and degree of adhesion to the substrate (Tables 18 and 19).

All specimens were examined as primary cultures and features such as epithelial cell size, adherence and morphology noted (Tables 18 and 19). Those cultures which persisted and became continuous lines were further examined at three monthly intervals.

The ten oesophageal carcinoma cell lines were derived from tumours of varying differentiation and showed distinct morphologies and growth patterns which facilitated their identification. The epithelial cells comprising the cell lines Hcu 13, Hcu 33, Hcu 35, Hcu 50 and B 17 (derived from well and moderately (Hcu 50 and B 17) differentiated oesophageal carcinomas) exhibited similar growth patterns. Rounded, non-refractile, agranular cells were present, either as islands of closely packed cells, or in layered form with the cells tightly adherent to one another. Cells from lines Hcu 10, Hcu 18, Hcu 37, Hcu 39 and B 5 were more angular and not as densely packed, nor as tightly adherent as those in the

former lines. Cells from the lines Hcu 10, Hcu 13, Hcu 37, Hcu 39 and B 5 contained many paranuclear lipid droplets identified by Scarlet R staining. Lipid material was also present in some cells of lines Hcu 13 and Hcu 33. Such droplets were particularly abundant in giant cells and were also recognised in the cells of many primary cultures.

Although mono- and multinucleated giant cells were present in all of the cell lines, their number and arrangement varied from line to line. They were most numerous and reached sizes of up to 130 μm in lines Hcu 10 and Hcu 13 (Chapter 8). In the line Hcu 13, multinucleated giant cells were dominant and cells with up to six nuclei were observed, though most of these large cells contained three or four nuclei. The giant cells present in lines Hcu 10 and Hcu 35 were predominantly monocleated. Most of the giant cells showed an eosinophilic staining reaction but the few observed in line Hcu 33 were strikingly basophilic. Giant cells of varying morphology were also noted in many of the primary cultures which did not develop into continuous cell lines.

With the exception of cells from the line Hcu 18 which showed a dramatic change in type and morphology during the first few months *in vitro*, few morphological changes were evident when cells from the lines were stained with May-Grunewald Giemsa and examined at intervals.

5. 2 TRANSMISSION ELECTRON MICROSCOPY

5. 2. 1 Primary cultures

The number of primary cultures prepared for and examined by transmission electron microscopy was limited by their availability. Although explants of each tumour specimen were placed in a minimum of four flasks, good growth of epithelial cells was typically only present in one or two flasks of each specimen. The growing cells were left in tissue culture for as long as possible in order to determine their potential *in vitro*. In those specimen where growth occurred in three or more flasks, the contents of one

lar were prepared for electron microscopy. Thus, primary cultures of the tumour and biopsy specimens Hcu 18, Hcu 21, Hcu 23, Hcu 32, Hcu 35, Hcu 50, B 1, B 2, B 5 and B 13 were examined by transmission electron microscopy.

The epithelial cells in those primary cultures derived from well differentiated tumours (Hcu 32, Hcu 35, B 13) displayed abundant tonofilaments and desmosomes, though the number of tonofilaments decreased significantly with increasing time in culture. Tonofilaments were also observed in cells of specimens Hcu 21, Hcu 23, Hcu 50, B 1, B 2 and B 5 where they typically were situated in a paranuclear position. Cells from specimen B 5 possessed far more tonofilaments than expected on the basis of histological grading (poorly differentiated). Intercellular desmosomes of normal morphology were present and well developed in cells of all the primary cultures except Hcu 18, while internalised desmosomes were present in cultures of specimens Hcu 32 and B 5.

From an early stage the cultured cells in most specimens assumed a stratified form with piling up of cells particularly prominent adjacent to the tumour explants. Ultrastructural features associated with keratinisation were observed in the cultures derived from Hcu 32 and B 13. The cells were packed with tonofilaments and several superficial cells developed prominent marginal bands, became completely cornified and desquamated. The surface cells in contact with the culture medium displayed varying numbers of microvilli and many cells showed complex lateral interfaces with projections extending into the intercellular spaces. Electron dense myelinoid bodies of varying size and morphology were prominent in all primary cultures and other large bodies containing particulate debris were observed, particularly in the layer of cells in contact with the substrate. Lipid droplets were frequently associated with these structures. Large aggregates of lipid material were prominent in Hcu 50 cells (Fig. 67). Mitochondria in all of the specimens appeared dense and well preserved and the vacuolated forms noted in <u>in vivo</u> specimens (Chapter 13. 2. 6) were not observed. Other cytoplasmic organelles present in these specimens were of normal morphology. Nuclear outlines were regu-

lar in all specimen, though dense irregular nuclear in[illegible] were evident in cells fro[illegible] Hcu 23 and B 2.

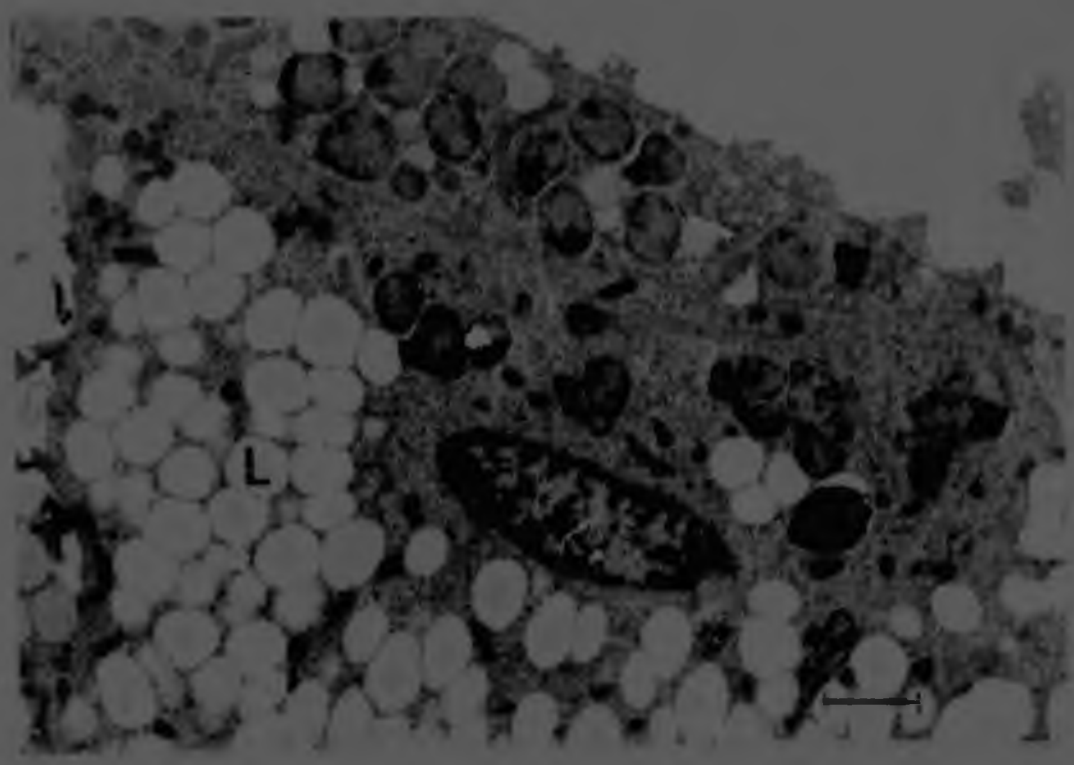

Fig. 67 Transmission electron micrograph of cells in a primary culture initiated from an explant of speciman Hcu 50. Lipid droplets (L) are abundant and a myelinoid body (B) is present. Bar = 1 μm

The cells present in primary cultures of the tumour explant from which the cell line Hcu 18 originated differed in several respects from those in the specimens described above and also from cells of the continuous line Hcu 18. Stratification was minimal and elongated cells of 100 μm and more in length containing branching profiles of smooth endoplasmic reticulum which extended virtually throughout their entire length were present. Generally two or three profiles ran parallel to one another and this smooth endoplasmic reticulum was continuous with the extensively branched dilated rough endoplasmic reticulum in several regions. Many ribosomes were associated with the rough endoplasmic reticulum which was filled with opaque material. The golgi complex was dilated in some regions where it approached rough endoplasmic

reticulum. Aggregates of microfilaments were present in the peripheral regions of the cells and pinocytotic vesicles were abundant both at the superficial cell surfaces and along the surfaces where cells made contact with the plastic substrate. Desmosomes and tonofilaments were absent, as were myelinoid bodies. Smaller, more rounded cells with ultrastructural features (desmosomes, tonofilaments) more typical of epithelial cells appeared after nine weeks in vitro and rapidly replaced the large cells. The smaller cells were connected by complex lateral borders and interdigitations and showed some similarities to cells of the early primary cultures in that they retained numerous profiles of electron dense rough endoplasmic reticulum.

Connective tissue cells were frequently present in primary cultures and many elongated fibroblasts with well developed rough endoplasmic reticulum were identified in positions away from the explants from which they originated.

Although early primary cultures showed many similarities to the in vivo tumours from which they originated, the cultured cells then began to lose some of their specialised features, such as abundant tonofilaments and desmosomes and morphological changes accompanied the transition from a primary culture to a subcultured cell strain or to a continuous cell line.

15. 2. 2 Continuously growing oesophageal carcinoma cell lines

Apparently healthy cells from all ten of the continuously growing human carcinoma of the oesophagus cell lines were prepared for transmission electron microscopy in situ in the flasks in which they were growing (Chapter 6. 2. 2. 2) on at least three separate occasions after varying periods in vitro. Lines Hcu 10, Hcu 13 and Hcu 18 were each examined on six separate occasions and were further studied after being prepared for electron microscopy by pelleting (Chapter 6. 2. 2. 1).

Those cells prepared by pelleting assumed rounded forms though complex surface microvilli persisted. Some pelleted specimens

were difficult to study as many hard residues in the pellets which frequently consisted of keratinised and degenerating cells made cutting of thin sections difficult.

Although there were differences between cell lines derived from different tumours, some basic features common to all oesophageal carcinoma cell lines did emerge. Some of the ultrastructural features which characterised each cell line are summarised in Table [illegible]. Cells from the same tumour line in different flasks and viewed at different times varied slightly in appearance, though on the whole, cell morphology remained constant over a number of passages.

15. 2. 2. 1 Stratification

Cells of the oesophageal carcinoma lines which at one time were thought to be growing in monolayers were actually arranged in a stratified fashion (Fig. 61). All specimens revealed cell layering with the number of layers ranging from 2 - 8, the well differentiated lines being more complexly stratified. In cell line Hcu 18 only two layers of cells were evident and elongated thin cytoplasmic processes formed a superficial layer over the more rounded basal cells.

A layered arrangement was also observed in cells prepared by centrifugation where a smooth outer surface around the pellet was provided by a layer of cells containing numerous dense mitochondria. This suggests that even when the normal arrangement of cells is disrupted by trypsinisation, some cells assume a superficial position. The typical stratified arrangement of the cells in the flasks resembled the *in vivo* situation as the more superficial cells were better differentiated than the basal cells attached to the plastic substrata.

15. 2. 2. 2 Tonofilaments

Tonofilaments which represent insoluble differentiation products of both keratinising and non-keratinising epithelia (Lazarides,

TABLE 25 SUMMARY OF ULTRASTRUCTURAL FEATURES (TEM) OF [illegible]

Cell line	Nucleus	Chromatin	Nucleoli	RER	Annulate lamellae	Golgi	[illegible]	Tono-filaments	Cytoplasmic rods	Glycogen	Fat	Others
Hcu 10	regular with inclusions	fine	dense	++	+	+++	I	+	–	–	+	Confronting cisternae filamentous bundles
Hcu 13	irregular, with 20-30nm particles	marginated	multiple	+	+	+++	I, E	+++	40 nm	–	–	lamellar bodies
Hcu 18	regular	fine	dense	+++	+	+++	E	+	8 – 14nm	–	+	abundant endoplasmic reticulum
Hcu 33	regular and irregular forms	fine	dense	+++	+	++	I, E	+++	40 nm	small aggregates	+	myelinoid bodies, crystalline inclusions
Hcu 35	regular	coarse	dense, particulate	++	–	++	I	+	–		+	many free ribosomes
Hcu 37	irregular, with [illegible] particles	clumped	dense	+++	+	++	I	–	8 – 14nm and 40 nm	–	+	myelinoid figures
Hcu 39	regular	fine	varying	+++	–	++	I	–	–	–	+	profiles of [illegible] endoplasmic reticulum
B 5	regular	fine	sparse	+	–	++	I, E	+++	8 – 14nm	many aggregates	+	fine cytoplasmic filaments, [illegible] cytoplasmic granules
B 17	irregular, with inclusions	fine	dense	+	–	+++	I, E	++	–	peripheral aggregates	–	[illegible] cytoplasmic granules
Hcu [illegible]	regular, with inclusions	fine	dense, particulate	+++	–	++	I	+	–	–	++	whorled bodies

I – Internalised / intracytoplasmic desmosomes

E – External / intercellular desmosomes

TABLE 25 SUMMARY OF ULTRASTRUCTURAL FEATURES (TCM) OF HUMAN OESOPHAGUS CARCINOMA CELL LINES

Cell line	Nucleus	Chromatin	Nucleoli	RER	Annulate lamellae	Golgi	Desmosomes	Tonofilaments	Cytoplasmic rods	Glycogen	Fat	Other
Hcu 10	regular with inclusions	fine	dense	++	+	+++	E	+	–	–	+	Confronting cisternae, filamentous bodies
Hcu 13	irregular, with 20–30nm particles	marginated	multiple	+	+	+++	I, E	+++	30 nm	–	–	lamellar bodies
Hcu 18	regular	fine	dense	+++	+	+++	E	+	8 – 14nm	–	+	abundant endoplasmic reticulum
Hcu 33	regular and irregular forms	fine	dense	+++	+	++	I, E	+++	40 nm	small aggregates	+	myelinoid bodies, crystalline inclusions
Hcu 35	regular	coarse	dense, particulate	++	–	++	E	+	–	–	+	many free ribosomes
Hcu 37	irregular, with 20–30nm particles	clumped	dense	+++	+	++	E	–	8 – 14nm and 40 nm	–	+	myelinoid figures
Hcu 39	regular	fine	varying	+++	–	++	E	–	–	–	+	profiles of smooth endoplasmic reticulum
B 5	regular	fine	sparse	+	–	++	I, E	+++	8 – 14nm	many aggregates	+	fine cytoplasmic filaments, 30nm cytoplasmic granules
B	irregular, with inclusions	fine	dense	+	–	+++	I, E	++	–	peripheral aggregates	–	myelinoid figures, cytoplasmic granules
Hcu 90	regular, with inclusions	fine	dense, particulate	+++	–	++	E	+	–	–	++	whorled bodies

I – Internalised / intracytoplasmic desmosomes

E – External / intercellular desmosomes

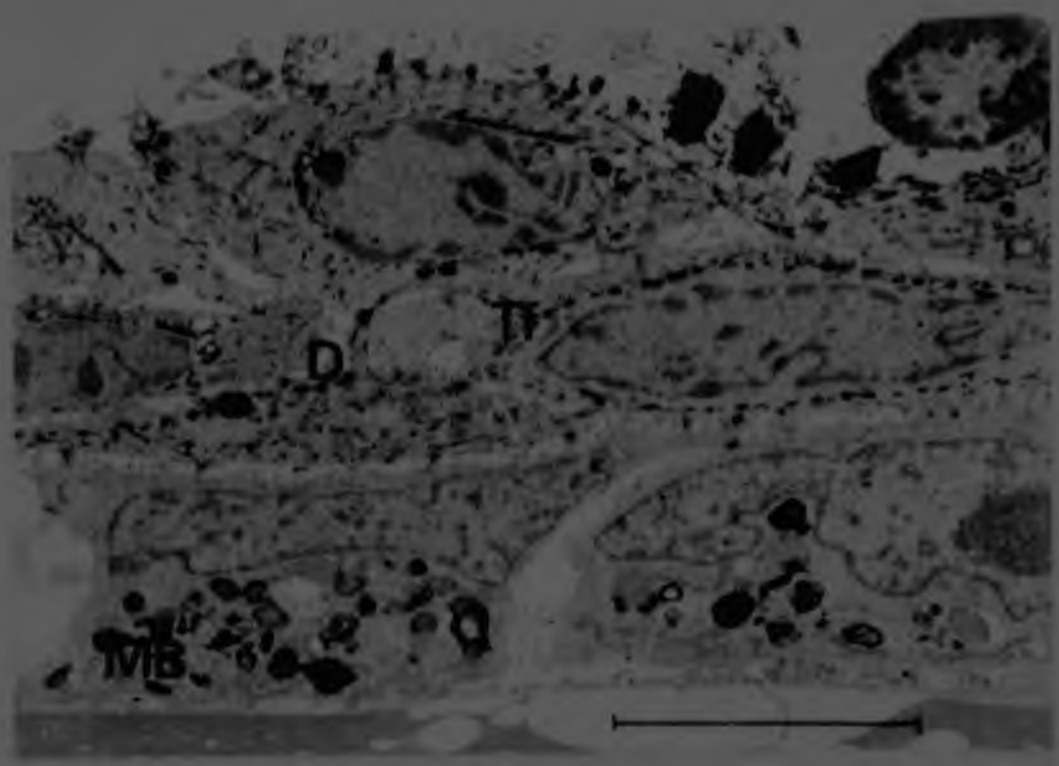

Fig. 68 Transmission electron micrograph showing multilayered Hcu 13 cells growing on the plastic surface of a tissue culture flask after their fourth successful subculture. The more superficial and better differentiated cells contain bands of paranuclear tonofilaments (Tf) and are joined by numerous well developed desmosomes (D). Electron dense myelinoid bodies (MB) are prominent in the basal cells. Bar = 5 μm

1950) were observed in cells of all of the oesophageal carcinoma lines, with the exception of lines Hcu 37 and Hcu 39, but were not as abundant as those present in some of the primary cultures studied. Aggregates of tonofilaments were particularly pronounced in association with desmosomes and were most abundant in cells of lines derived from well differentiated tumours (Hcu 13, Hcu 33 and Hcu 35). Tonofilaments were also particularly prominent in line B 5, derived from a poorly differentiated tumour, where they formed dense paranuclear bands. Tonofilaments accumulated in cells away from the basal layer (Fig. 69) and the superficial cells frequently appeared to lose all cytoplasmic organelles at the expense of filament accumulation and acquired a prominent marginal band of dense material which increased the thickness of

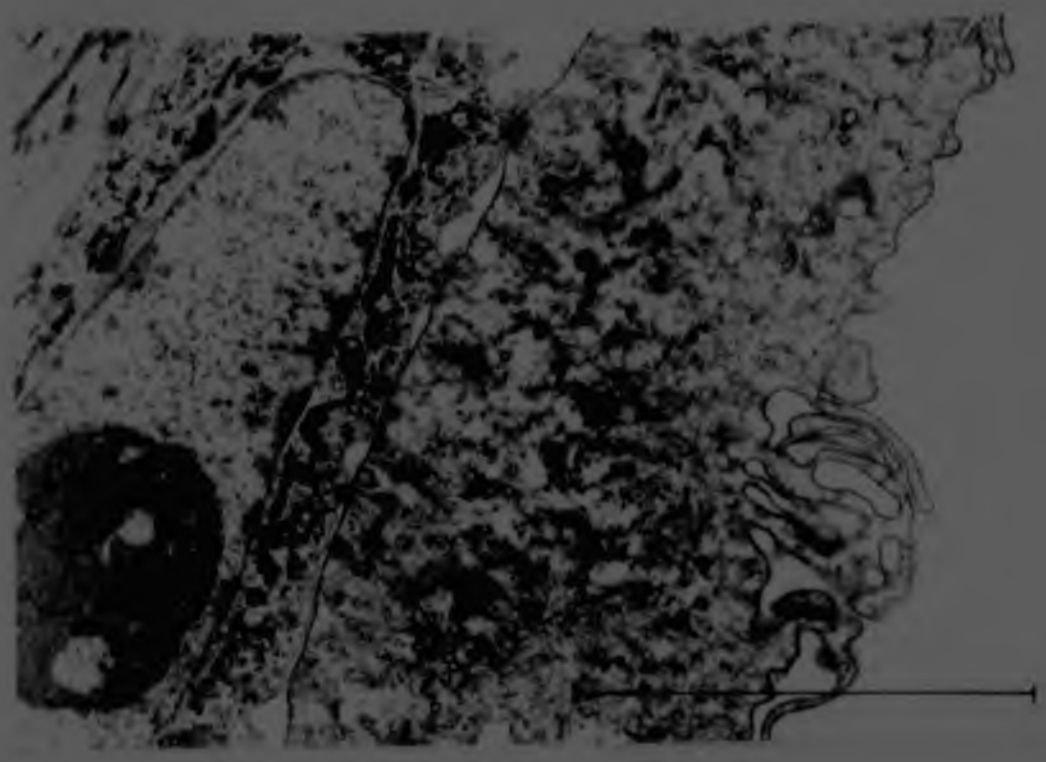

Fig. 69 Transmission electron micrograph showing well developed tonofilaments which have replaced most other cytoplasmic organelles in a superficial cell of the line B 5 after three months *in vitro*. Dense aggregates of paranuclear tonofilaments are present in the adjacent cell. Bar = 1 µm

the plasma membrane (Jessen, 1970). Keratinised cells were most numerous in lines Hcu 13 and Hcu 33 and many of the pelleted cells from the line Hcu 13 had well developed marginal bands surrounding a meshwork of fine filaments (Fig. 70).

13. 2. 2. 3 Desmosomes

The presence of desmosomes in cells of all of the continuous cell lines provided confirmation of the epithelial nature of the cultured cells. Large numbers of desmosomes were anticipated as a large desmosome field is unique to the oesophagus (Hopwood *et al.*, 1978). A range of desmosome morphology was observed (Robinson and Maistry, 1981) and many desmosomes differed in the number of bands visible in the cementing substance between the thickened outer



Fig. 70

Transmission electron micrograph showing the thickened plasma membrane or marginal band bordering a highly differentiated Hcu 13 cell which is filled with a meshwork of fine filaments. This cell was prepared for electron microscopy by pelleting. Bar = 0,1 µm

plasma membranes of the joined cells while other desmosomes seemed to be missing the layer of cementing substance.

Most cells were separated from the plastic surfaces of the flasks in which they were growing and had hemidesmosomes at infrequent points of contact. Cells from the lines Hcu 13, Hcu 33, B 5 and B 17 contained internalised desmosomes which were similar to those observed in tumour specimens in vivo and associated with aggregates of tonofilaments (Fig. 71) while cells from line Hcu 33 contained apparently internalised hemidesmosomes (Fig. 72). Cells prepared by pelleting revealed fewer desmosomes than those sectioned in situ in the flasks in which they were growing.

15. 2. 2. 4 Nuclear features

Nuclear features, such as shape and degree of chromatin condensation of the oesophageal carcinoma cell lines examined in this study are summarised in Table 25. Nuclear outlines were complex (Fig. 73) in many of the lines and variations in chromatin distribution



Fig 71

Transmission electron micrograph showing intracellular desmosomes with associated tonofilaments in the cytoplasm of a Hcu 13 cell after six months *in vitro*.
Bar = 0,1 µm



Fig. 72 Transmission electron micrograph of internalised hemidesmosomes in a Hcu 33 cell after five months *in vitro*.
Bar = 0,1 µm



Fig. 73 Transmission electron micrograph depicting the irregular nuclear outline in a cultured Hcu 13 cell. Profiles of annulate lamellae (AL) are present adjacent to the involuted nucleus. Bar = 1 µm

were observed. Occasional nuclear inclusions were present in lines Hcu 33 and Hcu 50. Irregular nuclei and filamentous nuclear inclusion bodies have been described as a feature of normal oesophageal cells (Desmet and Tytgat, 1974). Most of the interphase Hcu 13 cells examined presented marked margination of chromatin while smaller proportions of cells in the other lines showed this phenomenon.

A number of electron dense intranuclear particles or granules was observed. The larger particles (35 nm in diameter) present in cell line Hcu 37 (Fig. 74) were identified as perichromatin granules (Ghadially, 1975) which are normal nuclear components. Interchromatin granules were also present in most specimens. In the cell line Hcu 13 striking intranuclear particles of diameter 20 - 30 nm were present in clearly defined clusters of 20 - 40 particles (Figs. 75 and 76) in a peripheral position in the nuclei.

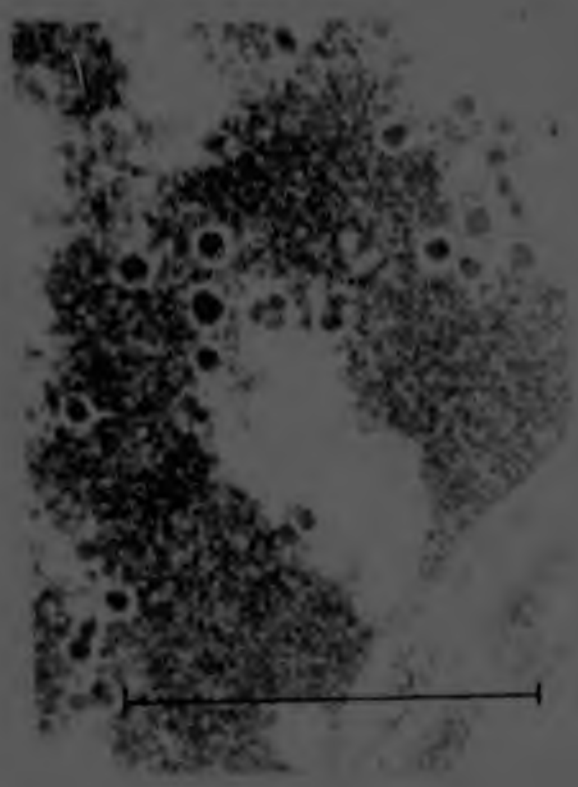

Fig. 74

Transmission electron micrograph of a portion of a Hcu 37 cell with clearly defined intranuclear particles, 36 nm in diameter, which are surrounded by clear halos. Bar = 1 µm

These asymmetrical structures (Fig. 76) were not always observed when cells from line Hcu 13 were studied but seemed to occur at intervals. When present they were located in some 50 per cent of sectioned nuclei. This implies that they occupy a fairly large area of the nucleus as in each thin section only a small portion of the nucleus is viewed. Their cyclical occurrence appeared unrelated to the nutritional status or degree of confluency of the cultures. Similar particles were also seen in T 24 and T 33 in vivo (Chapter 13. 2. 1).

There was much evidence of mitotic activity and several dividing cells were observed with condensed chromosomes attached to spindle microtubules or at the beginning of chromosome condensation prior to spindle formation. A late stage of division is shown in Fig. 77 where two cells in the process of completing cyto-kinesis are joined by the Zwischenkörper (Tobias, 1956).

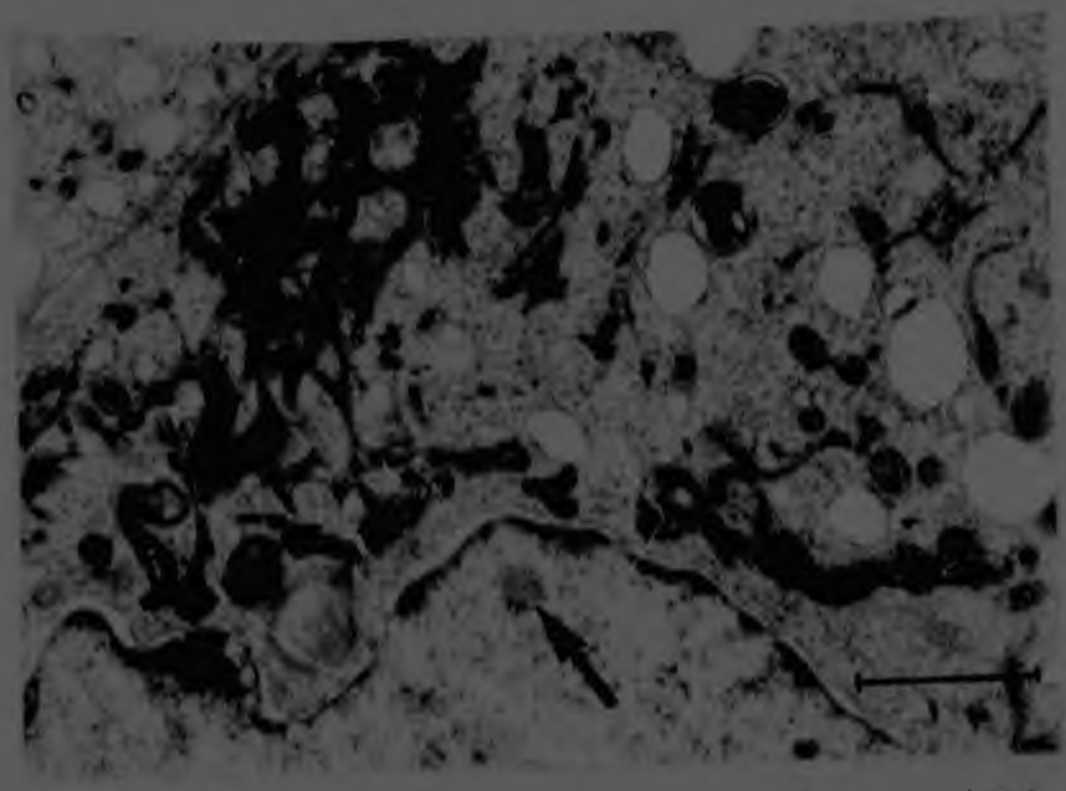

Transmission electron micrograph showing a prominent cluster of 20 - 30 nm particles in a peripheral position in the nucleus of a Hcu 13 cell prepared for electron microscopy by pelleting after 15 passages. Bundles of tonofilaments in the cytoplasm reflect the retention of differentiated functions. Bar = 1 µm

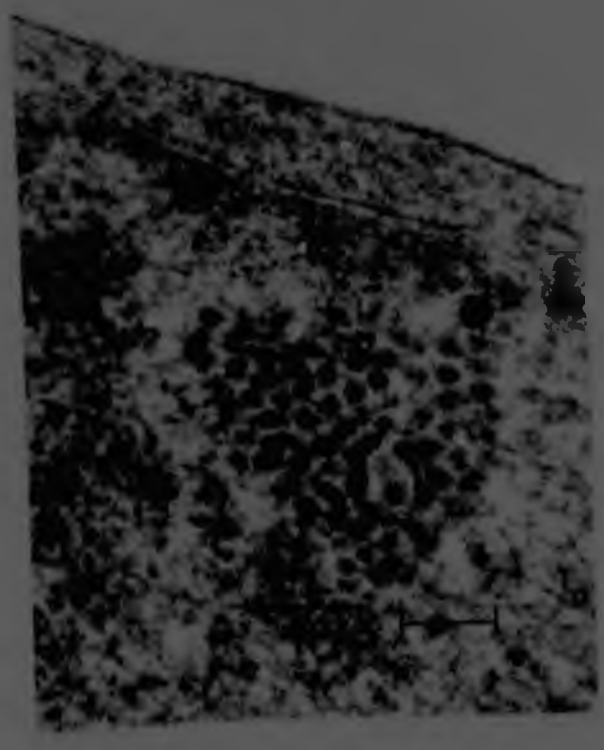

Fig. 76

Transmission electron micrograph of a clearly defined cluster of intranuclear particles in a Hcu 13 cell after 25 passages.
Bar = 0,1 µm

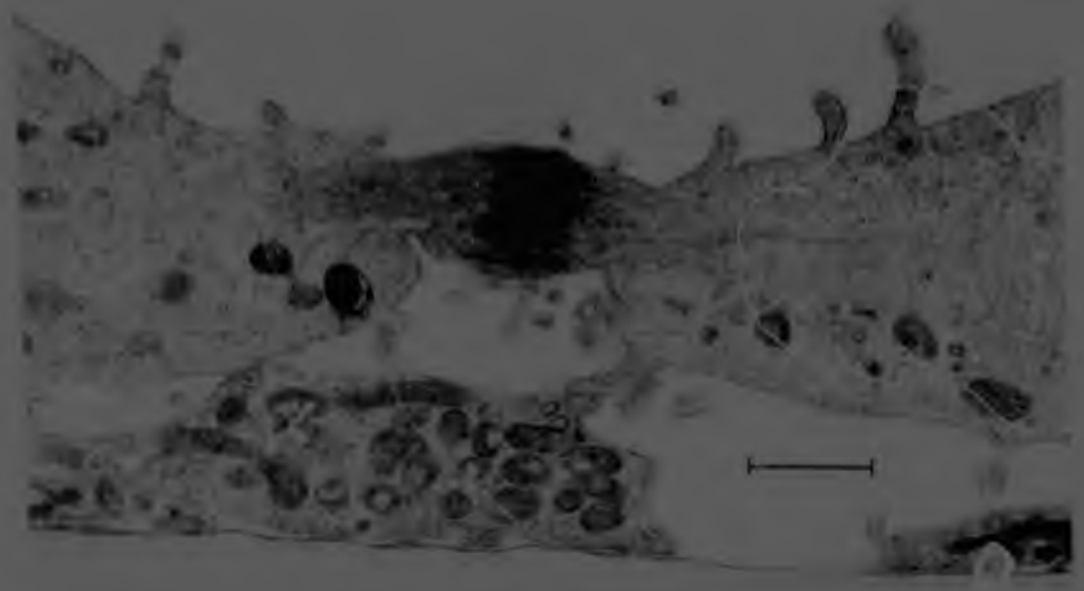

Fig. 77 Transmission electron micrograph showing two Hcu 13 cells in the process of completing telophase. The cells are joined by a Zwischenkörper with associated microtubules. Bar = 1 µm

15. 2. 2. 5 Myelinoid bodies

Myelinoid or dense lamellar bodies were present in several cells of all of the different lines and were abundant in slow growing and confluent cultures. They assumed a variety of forms (being of different size, density and substructure) depending on the stage of differentiation reached. Whorled inclusions were more pronounced in the more superficial cells, while dense bodies predominated in the cells attached to the substrate. These structures were sometimes associated with lipid droplets, but there was no evidence for the presence of glycogen in association with myelinoid figures.

15. 2. 2. 6 Cytoplasmic rods and filaments

Dense aggregates of cytoplasmic rods (approximately 40 nm in diameter) were observed at intervals in cell lines Hcu 13, Hcu 3

and Hcu 37. These structures differed from lamellar bodies in being more regular, clearly defined and having a definite sub-structure. The component sub-units were all of similar dimensions and seperated by small spaces (Figs. 79 and 79). The aggregates of rods did not appear to be membrane bound and were frequently present in close association with mitochondria.

Small, elongated, clearly defined, electron dense cytoplasmic structures which resembled those present in T 22 (Chapter 13. 8. 4) were observed in lines Hcu 18, Hcu 33, Hcu 37 and B 8. These structures were 8 - 14 nm in diameter, of different density to ribosomes and differed from tonofilaments in occurrence and arrangement (Fig. 80). They were visible in both transverse and longitudinal section and seemed to follow a wavy course (Fig. 81). Though the 8 - 14 nm filaments were observed on several occasions in metaphase cells, they were also present, albeit in smaller numbers, in interphase cells.

In lines Hcu 33 and Hcu 37, these structures were observed in association with paracrystalline bodies which consisted of arrays of apparently similar fine filaments (Figs. 82 and 83). Paracrystalline bodies, however, varied both in their overall dimensions and in the dimensions of their component structures. Other microfilaments (5 - 7 nm diameter), microtubules (25 nm diameter) and intermediate filaments (10 nm diameter) were recognised (Fig. 84) and transient filaments or tubular bundles were prominent in paranuclear positions at intervals in cells from lines Hcu 10 and Hcu 13. Aggregations of microfilament were evident forming the cytoskeleton of some cells of lines Hcu 18, B 5 and B 17. Microfilaments were abundant in those regions where the cells were close to the plastic substrata, were sparse in the centrally located cells and present in some of the superficially situated cells.

15. 2. 2. 7 Other cytoplasmic organelles

In most of the lines, the mitochondria appeared rounded and dense with clearly defined cristae. Two morphologically distinct cell populations were evident in early cultures of line Hcu 13. One

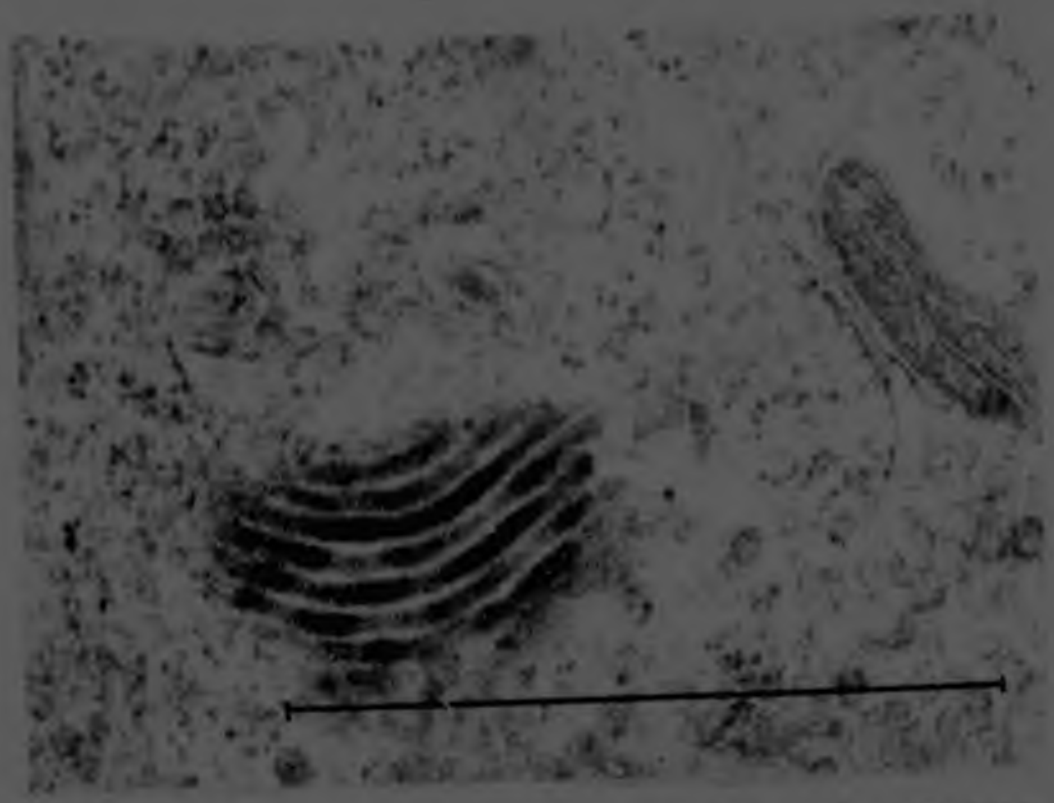

Fig. 78 Transmission electron micrograph of regular electron dense cytoplasmic rods of diameter 45 nm in a Hcu 13 cell after 25 passages. Bar = 1 μm

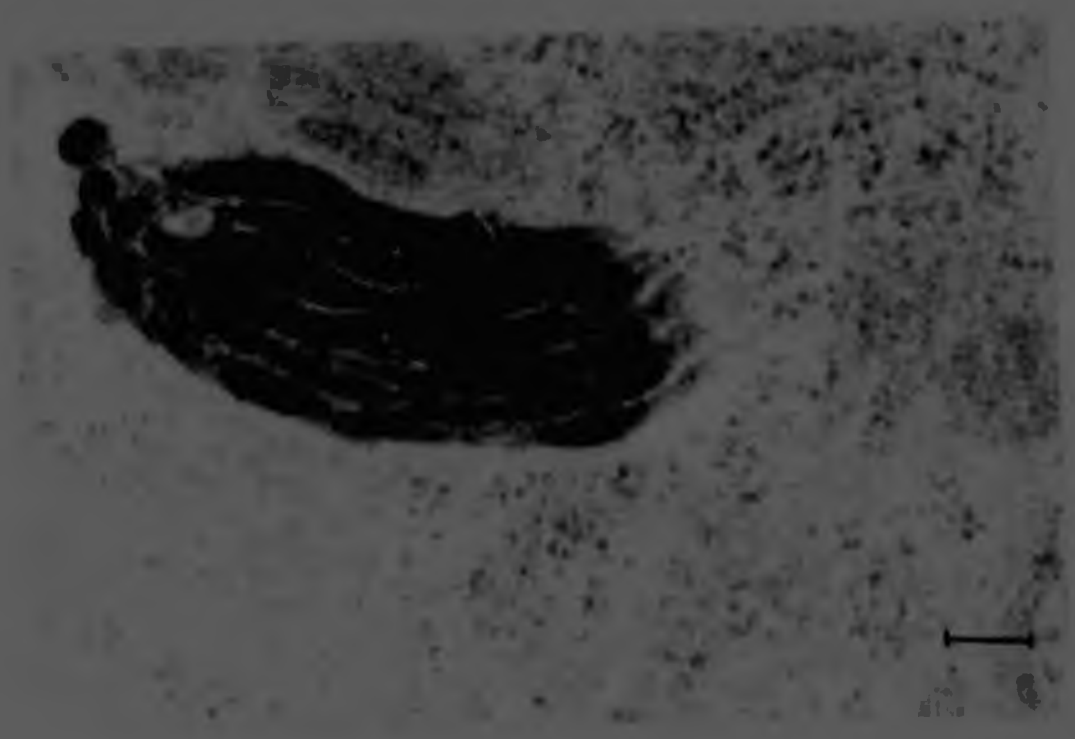

Fig. 79 Transmission electron micrograph showing a group of dense cytoplasmic rods (40 - 45 nm in diameter) in both transverse and longitudinal section in a Hcu 37 cell. Bar = 0,1 μm

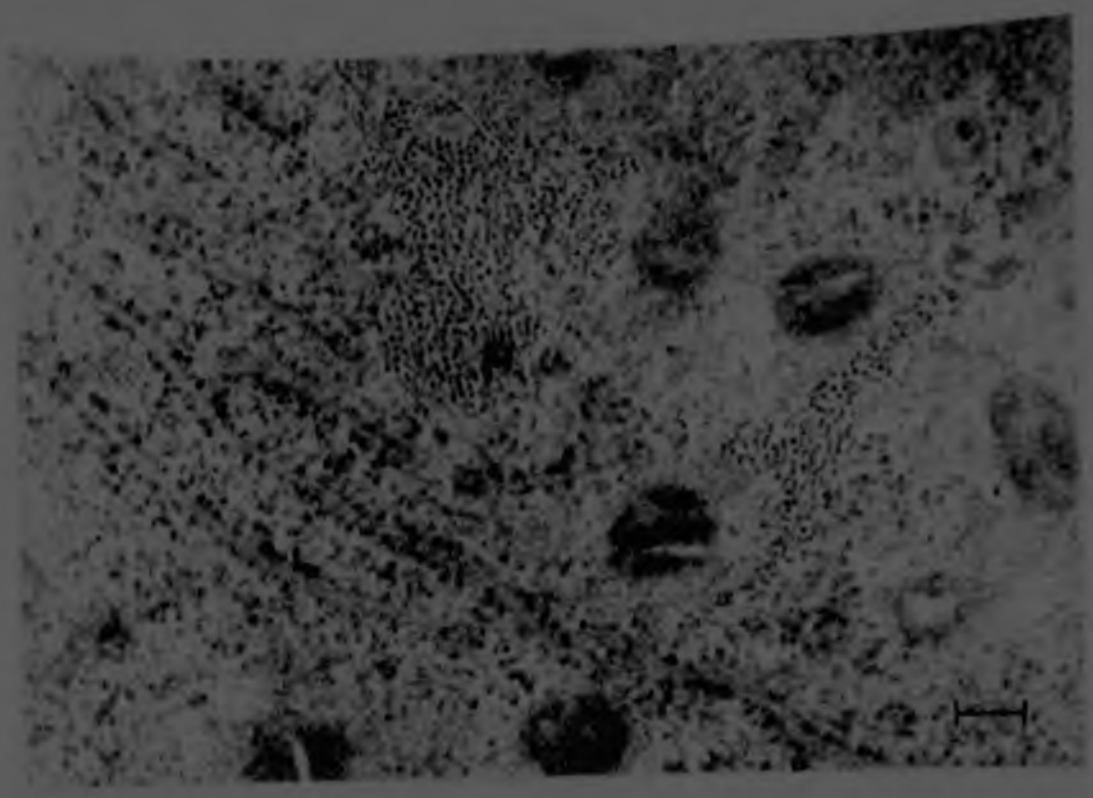

Fig. 80 Transmission electron micrograph showing cytoplasmic filaments or particles (P) which are 8 - 14 nm in diameter and lie adjacent to profiles of rough endoplasmic reticulum in a Hcu 37 cell. Bar = 0,1 µm

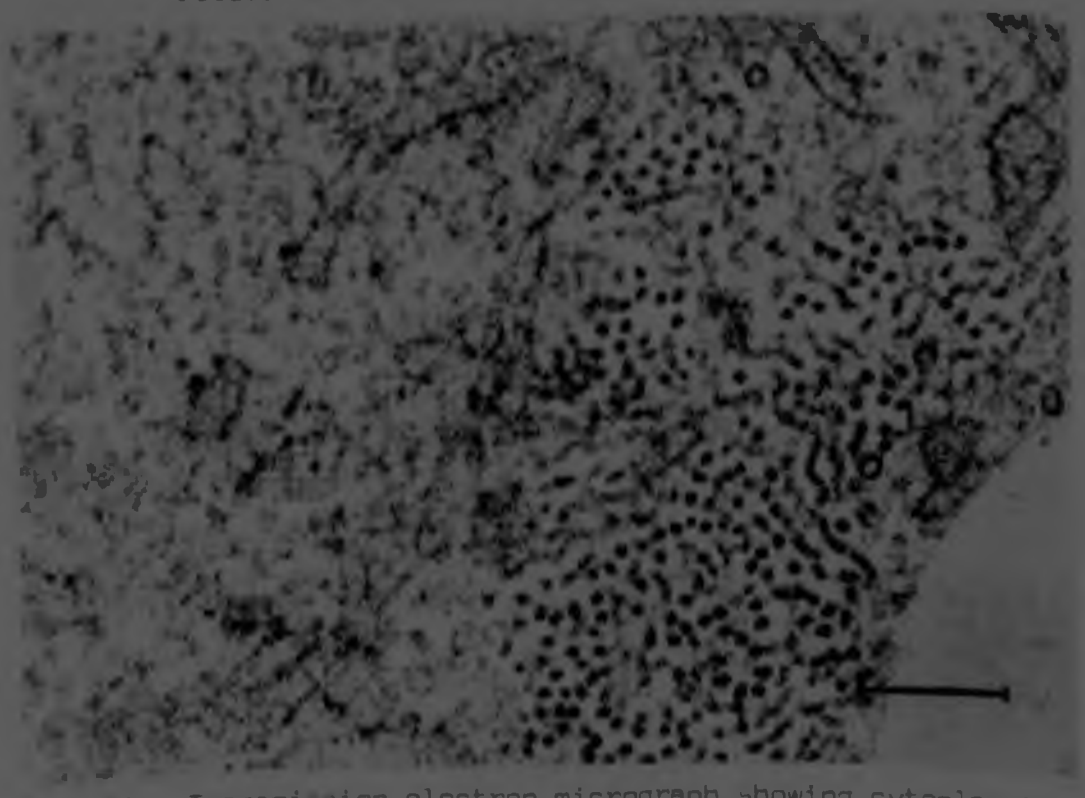

Fig. 81 Transmission electron micrograph showing cytoplasmic filaments of 8 - 14 nm diameter in both transverse and longitudinal section in a metaphase Hcu 18 cell. Bar = 0,1 µm

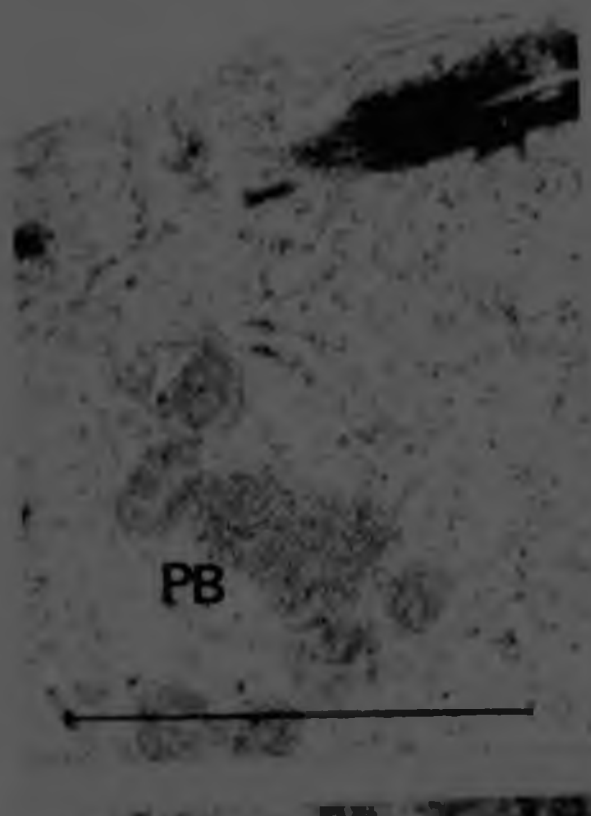

Fig. 82

Transmission electron micrograph of a paracrystalline body (PB), which consists of parallel arrays of fine filaments, in close proximity to mitochondria in a cell of line Hcu 33. Bar = 1 µm



Fig. 83

Transmission electron micrograph of a filamentous paranuclear body in a Hcu 37 cell. Dense perichromatin granules are peripherally situated in the nucleus. Bar = 0,5 µm

cell population contained numerous dense mitochondria in an electron dense cytoplasm populated by free ribosomes, while the second cell population had an overall pale appearance and fewer mitochondria. Cells of the line which subsequently emerged contained dense mitochondria and few free ribosomes.

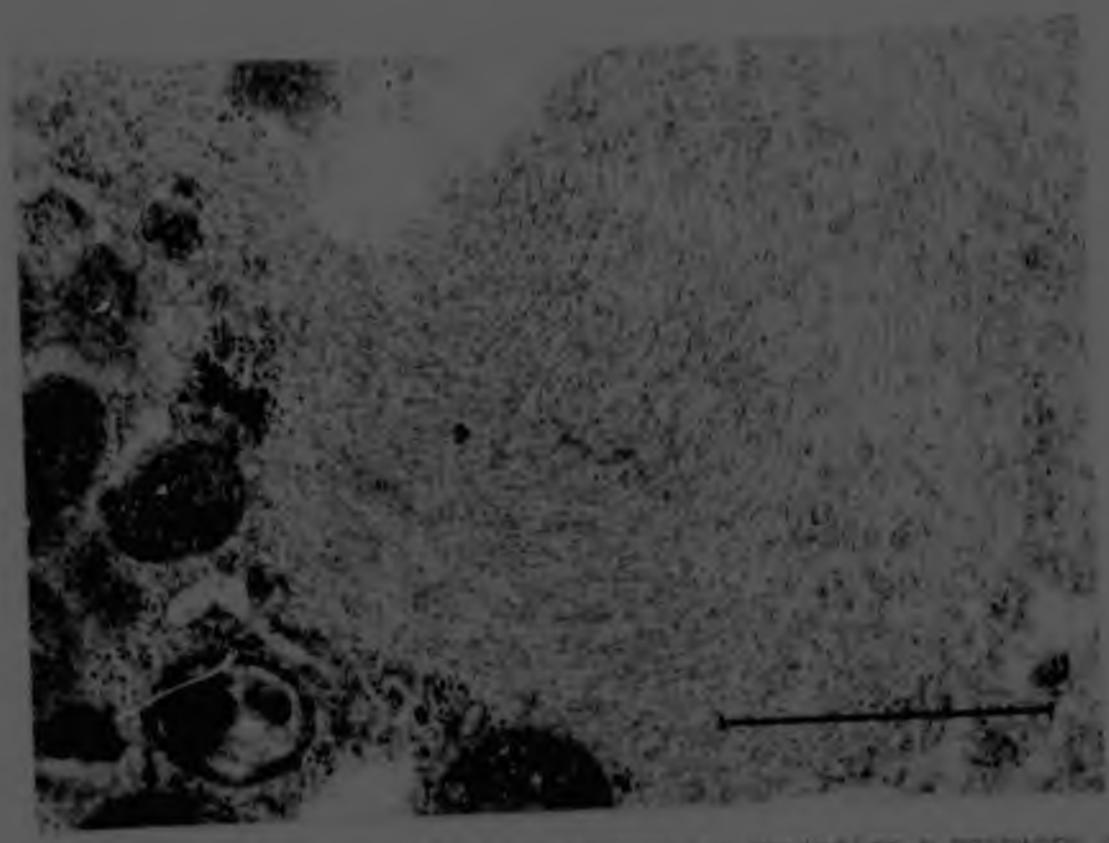

Fig. 84 Transmission electron micrograph depicting a meshwork of fine filaments, between which are mitochondria, in the cytoplasm of a Hcu 10 cell prepared for electron microscopy by pelleting. Bar = 1 μm

All of the cell lines contained apparently normal cytoplasmic organelles in varying proportions, while structures such as annulate lamellae were present in cell lines Hcu 10, Hcu 18 and Hcu 37, all derived from poorly differentiated rapidly growing tumours and also, in greater abundance, in line Hcu 13 derived from a well differentiated squamous carcinoma (Figs. 73 and 85). Intracytoplasmic confronting cisternae were observed in the rapidly growing line Hcu 10 (Fig. 86) and the rough endoplasmic reticulum was particularly well developed, dense and dilated in line Hcu 18 (Fig. 87).

Marked hypertrophy of the golgi complex was observed in all of the lines examined and active budding of the golgi apparatus was frequently seen, particularly in the lines Hcu 13 and Hcu 33 (Fig. 88). Rounded cytoplasmic granular structures of varying size were occasionally observed. Some 45 nm particles which may represent membrane coating granules were present in small groups near



Fig. 85 Transmission electron micrograph showing well developed annulate lamellae in the paranuclear cytoplasm of a cell of line Hcu 13. Bar = 0,1 µm



Fig. 86

Transmission electron micrograph showing profiles of opposed membranes forming confronting cisternae (C) in the paranuclear cytoplasm of a poorly differentiated Hcu 10 cell. Bar = 1 µm

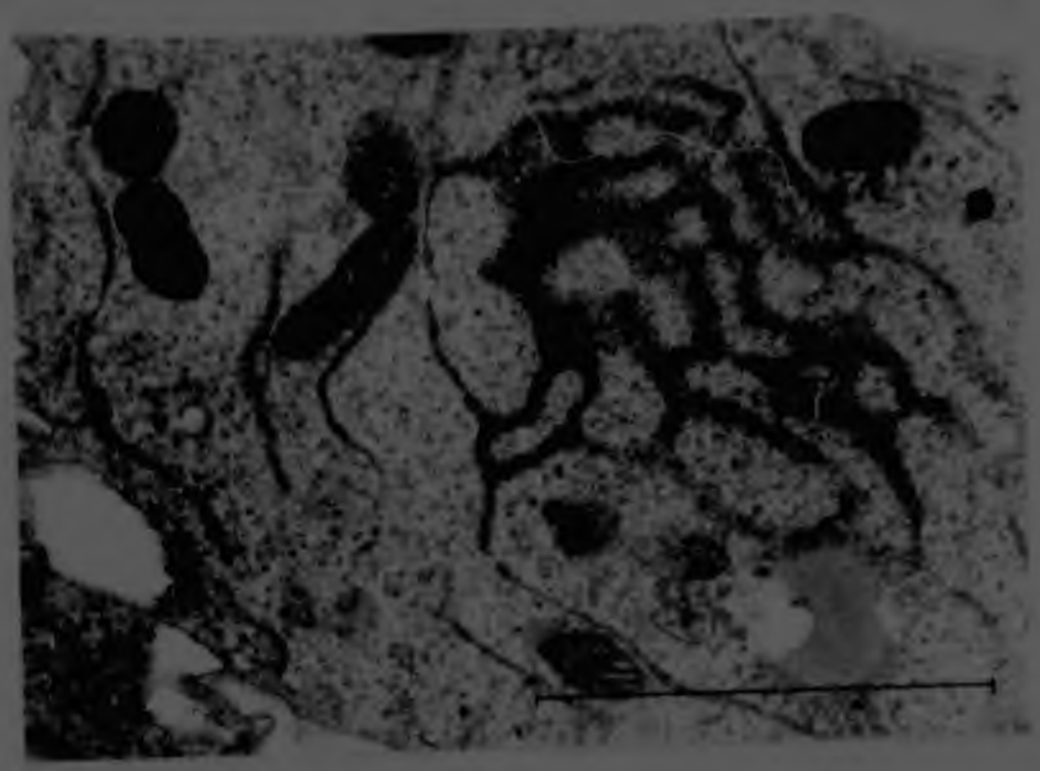

Fig. 37 Transmission electron micrograph showing branching profiles of dilated electron dense rough endoplasmic reticulum in a rapidly growing Hcu 13 cell after four months *in vitro*. Bar = 1 μm

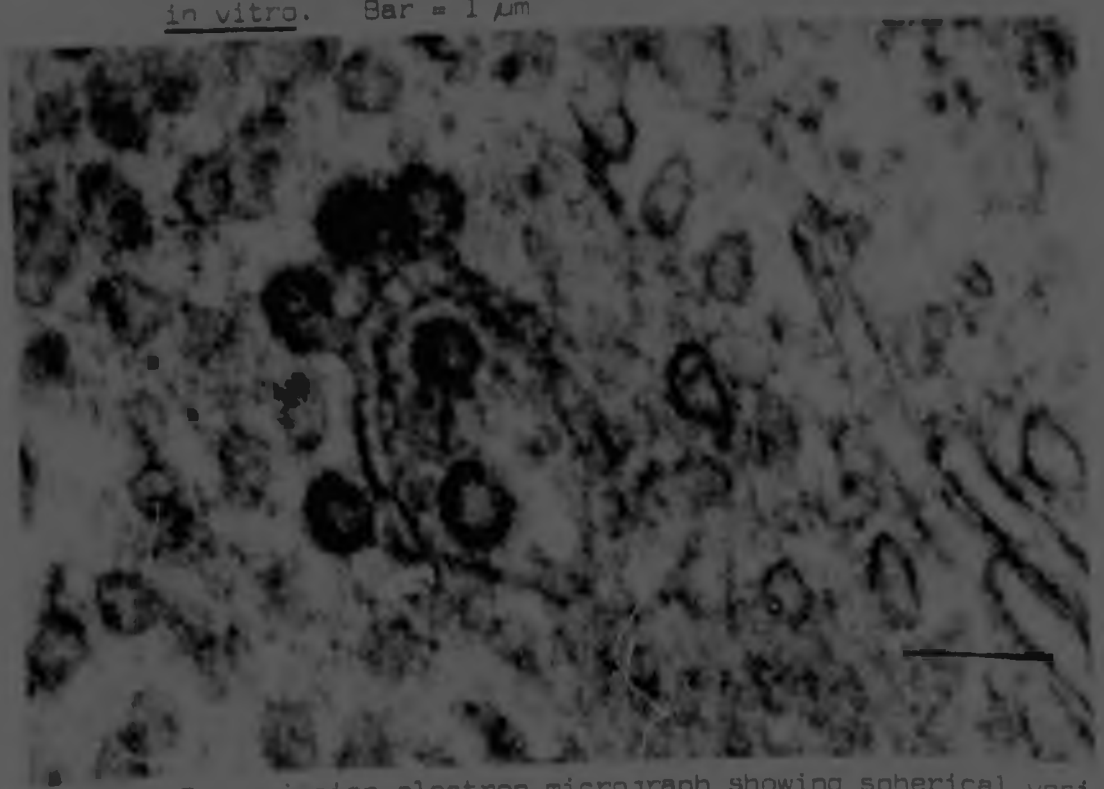

Fig. 38 Transmission electron micrograph showing spherical vesicles budding from the golgi apparatus in the cytoplasm of a Hcu 13 cell. Bar = 0,[illegible] μm

regions of cell contact in cells from line B 5. Glycogen was evident in pockets in the superficial cells from lines Hcu 50, B 5 and B 17 (Fig. 89).



Fig. 89 Transmission electron micrograph showing a dense particulate aggregate of glycogen in the cytoplasm of a B 17 cell. Bar = 1 µm

14. 3 SCANNING ELECTRON MICROSCOPY

Although many attempts were made to initiate primary explant cultures of oesophageal carcinoma cells on glass coverslips, tumour explants, unlike those of normal oesophageal mucosa, did not attach readily to the glass substrata and those few which did, became detached during specimen preparation. It was, therefore, not possible to examine primary cultures of human oesophageal carcinomas by scanning electron microscopy.

When all of the oesophageal carcinoma cell lines, with the exception of Hcu 50, were prepared for and examined by scanning electron microscopy each line showed unique morphological features

which are summarised in Table 2[illegible] and which enabled the lines to be distinguished from one another. Cell shape and grouping varied and cells from all of the oesophageal carcinoma cell lines were characterised by numerous surface projections (microvilli, lateral processes and blebs) and could readily be distinguished from cultured normal oesophageal cells.

15. 3. 1 Microvilli

Although no consistent differences between the surface features of well and poorly differentiated cell lines were recognised, microvilli appeared longer and more abundant in lines from poorly differentiated tumours. Microvilli were most numerous and best developed on cells from line Hcu 10 (Figs. 90 and 91) where these long branched structures frequently overlapped regular spherical indentations thought to represent pinocytotic vesicles. Microvilli were abundant on the cells of line B 17 while elongated forms were prominent in lines Hcu 35 and Hcu 37 (Table 2[illegible]).

In most of the lines microvilli were confined to the more central regions of the cells and, with the exception of line Hcu 10, were not distributed over the entire cell surface. Large flattened giant cells generally lacked microvilli while these structures were more prominent on the smaller rounded and angular cells. Thus, the greater the surface area covered the fewer the microvilli that were present.

15. 3. 2 Lateral processes

Long radiating lateral processes which differed from microvilli in being longer and confined to cell peripheries were particularly prominent in lines Hcu 18, Hcu 33, Hcu 35 and Hcu 37 (Fig. 92). These lateral processes were occasionally branched (Fig. 93) and in lines Hcu 18 and Hcu 37 frequently possessed small blebs at intervals and had slightly expanded rounded tips. Line Hcu 33 possessed long thin contacts which were well preserved.

TABLE 20 SUMMARY OF SURFACE FEATURES (SEM) OF HUMAN OESOPHAGEAL CARCINOMA CELL LINES

Cell line	Cell shape	Cell grouping	Giant cells	Microvilli (number, length)	Lateral processes	Cell contacts	Blebs
Hcu 10	irregular rounded and fusiform	even layer	numerous	numerous, long and short forms	long and branched	loose bridging of intercellular spaces	peripheral
Hcu 13	pleomorphic, occasionally rounded	clusters	moderate	moderate short	long	numerous well developed intercellular bridges	occasional
Hcu 18	pleomorphic	even layer	numerous	moderate, fine and short	fine and exceptionally long	loose bridging and some overlap	moderate
Hcu 36	irregular and rounded cells	clusters	moderate	moderate, fine and short	fine and long	long interconnecting processes	numerous
Hcu 35	angular	even layer	occasional	numerous, long	fine and long	well developed intercellular bridges	occasional
Hcu 37	pleoform	even layer	few	moderate, long	fine and long with blebs at intervals	very long interconnecting processes	variable
Hcu 39	angular and rounded	even layer	moderate	moderate, short	fine and long	well developed bridging and overlap	sparse
B 5	angular	clusters	occasional	moderate, short	few, short	few areas of close contact	occasional
B 17	angular and rounded forms	clusters	occasional	abundant	fine, short	interconnecting processes	occasional



Fig. 90 Scanning electron micrograph showing cells of line Hcu 10 on the surfaces of which microvilli are well developed. Bar = 10 μm

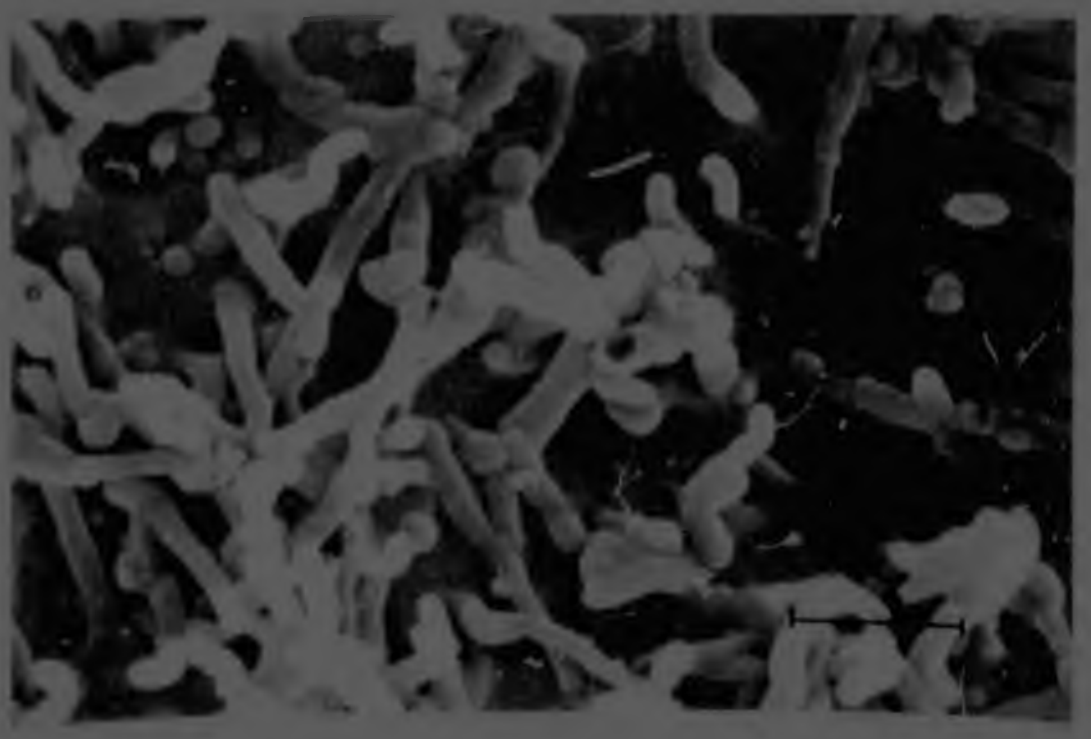

Fig. 91 A high power scanning electron micrograph showing the arrangement of microvilli on the surface of a Hcu 10 cell. Bar = 1 μm



Fig. 92 Scanning electron micrograph showing well developed lateral processes extending between angular HCu 15 cells. Bar = 10 μm

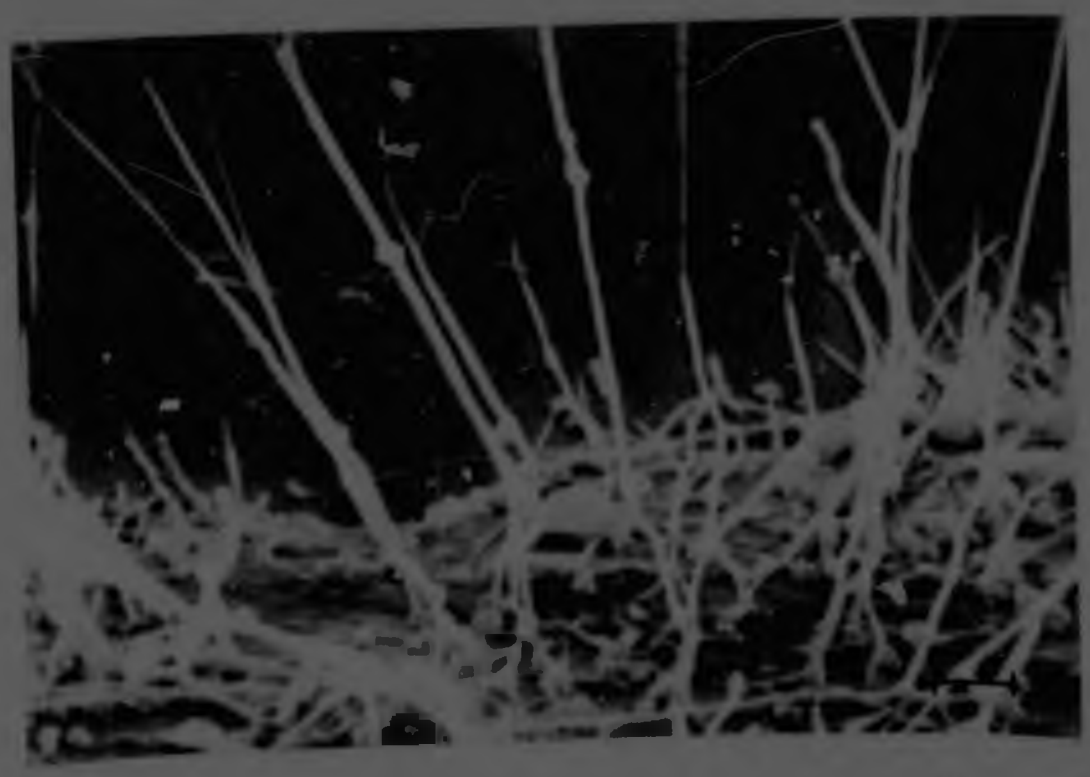

Fig. 93 Scanning electron micrograph of long branching lateral processes extending from the peripheral region of a HCu 18 cell. Bar = 1 μm

15. 3. 3 Other surface features

Areas of cell contact varied in their degree of development from one line to the next, and were responsible for some of the recognisable differences when cells from the various lines were examined by scanning electron microscopy (Table). Cell contacts (intercellular bridges) were particularly well developed in the well differentiated line, Hcu 13 (Figs. 94 and 95) where prominent cytoplasmic processes bridged the intercellular spaces. Where such processes made contact with those from adjacent cells, numerous well developed desmosomes were observed by transmission electron microscopy.

Blebs were of variable occurrence and were most pronounced on rounded mitotic cells in all of the lines.

15. 3. 4 Giant cells

By scanning electron microscopy and stereo imaging the giant cells present in all of the cell lines were seen to be "lower" or closer to the substrata than the adjacent smaller cells and to cover a large surface area. Thus the volume increase in the giant cells may not be as large as is suggested by their area increase and once the cells reach a certain size they "spread out" and adhere more strongly to the substrata.

15. 4 SUMMARY

Ultrastructural and surface features of cells of primary cultures of malignant oesophageal cells and of the continuous oesophageal carcinoma cell lines established in this investigation were studied and each of the continuous cell lines characterised morphologically. Similarities between the lines were noted as well as the presence of structures such as intranuclear particles, cytoplasmic rods and filaments, intracytoplasmic desmosomes, filamentous aggregates and annulate lamellae.



Fig. 94 Scanning electron micrograph of cultured Hcu 13 cells which are connected by well developed intercellular bridges. Microvilli are fine and short. Bar = 10 μm

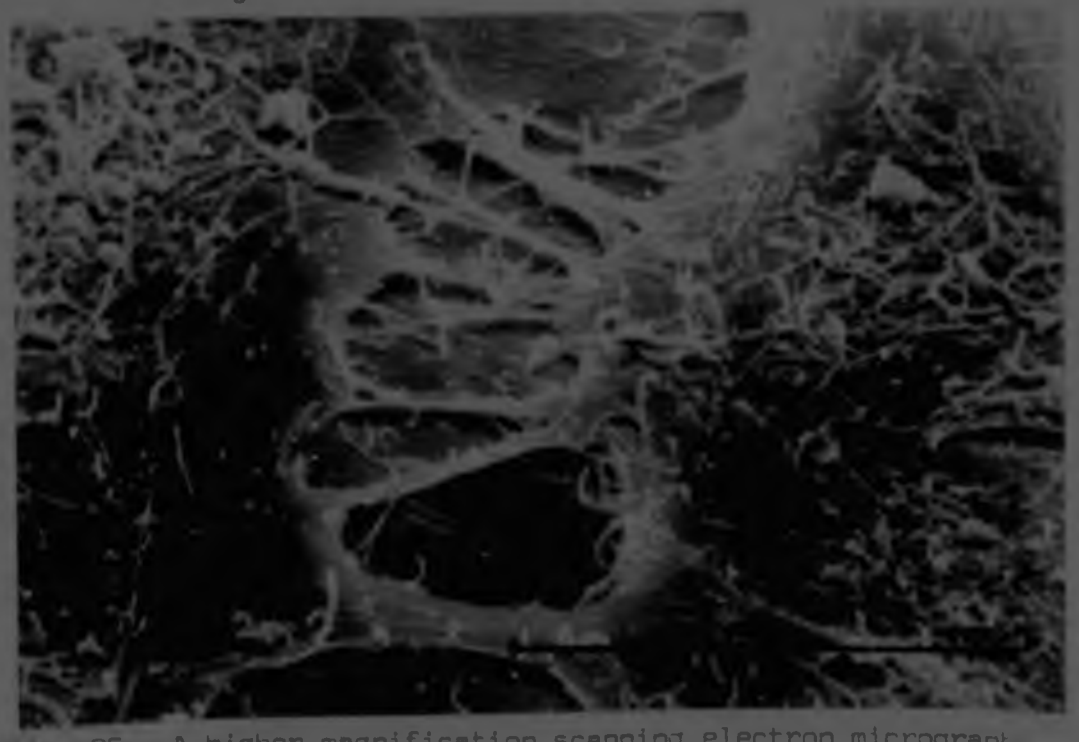

Fig. 95 A higher magnification scanning electron micrograph giving a more detailed view of the intercellular bridges which connect adjacent Hcu 13 cells. Bar = 10 μm

16. DISCUSSION

ULTRASTRUCTURE OF NORMAL AND MALIGNANT OESOPHAGEAL CELLS IN VIVO AND IN VITRO

16. 1 A COMPARISON OF THE ULTRASTRUCTURAL FEATURES OF NORMAL AND MALIGNANT OESOPHAGEAL CELLS IN VIVO WITH THOSE OF CORRESPONDING CELLS IN VITRO

When normal or malignant cells are cultured for long periods of time they may undergo adaptational changes and lose functional and morphological characteristics (Schlesinger et al., 1976). Therefore, the appearance of cells cultured for short periods *in vitro* is often more consistent with their character *in vivo*, than is the morphology of cells from continuously growing cell lines. The information obtained from short-term tissue culture of malignant specimens has been used to establish the tissue of origin of anaplastic tumours (Kadin and Bensch, 1971) and to identify morphological features associated with *in vivo* invasiveness (Gershman *et al.*, 1978.)

Cells growing in a primary culture should most closely approximate those in the tissue of origin, since such cells have not been repeatedly exposed to the proteolytic effects of the enzyme trypsin which appears to cause membrane change (Ricard and Hay, 1976) and to affect the structural integrity of the bilayered cell membranes (Anghileri and Dermietzel, 1976). Some changes are, however, expected during adaptation to the *in vitro* environment.

16. 1. 1 Normal oesophageal cells in vivo and in vitro

The epithelial cells growing in all of the primary cultures of normal oesophageal mucosa differed in several respects from those *in vivo*, although they did retain a stratified arrangement and some differentiated functions. As normal oesophageal mucosal

cells survived for only limited periods *in vitro*, only primary cultures and no continuous lines could be investigated ultrastructurally.

The most marked changes which occurred during adaptation to the *in vitro* environment were those involving the cell membrane (Chapters 12 and 14). In all specimens the superficial cell surfaces in contact with the tissue culture medium differed markedly from those abutting on the lumen of the oesophagus *in vivo*. Normal oesophageal epithelial cells *in vitro* showed no evidence of microplicae and the lateral cell borders were not elevated. Instead of microridges the surfaces of cultured apparently normal oesophageal cells were interrupted by short, sparse, stubby microvilli.

A possible explanation for the reduction in ordered surface activity of cultured normal oesophageal cells is that the extra membrane used for the formation of microridges *in vivo* was used to increase the surface area *in vitro*. Alternatively, the presence of aequeous medium bathing the superficial cells *in vitro* might be responsible for the cell surface alterations. By transmission electron microscopy oesophageal cells *in vitro* appeared more uniform than those *in vivo*. Cell differentiation *in vitro* was not as advanced as *in vivo*, the numbers of tonofilaments and other filamentous aggregates being reduced, though cell borders were complex and desmosomes remained well developed. The observed decrease in differentiation may account for the absence of microridges, as the accumulation of semi solid filamentous material *in vivo* may cause the cytoplasm to become rigid and the cell membrane convoluted.

Glycogen, which was typically present in the superficial cells of oesophageal mucosa *in vivo*, persisted *in vitro*. There were no marked alterations in the morphology of other cytoplasmic organelles and cells from different specimens had a consistent morphology *in vitro*. Thus, normal oesophageal cells *in vitro* were easily characterised to allow for future recognition.

The attachment fibrils extending from cultured oesophageal cells

at the growing edge of the cell sheet to the substrate had no homologue *in vivo*. Another feature which appeared confined to the *in vitro* situation was the presence of fine branching networks of processes which extended for large distances over the surfaces of many oesophageal cells in contact with the culture medium and which were observed in all specimens. Such processes, which have not been previously described, may represent fibrin or some connective tissue fibre or be providing innervation for the oesophageal cells *in vitro*. The rounded structures which were superficial to the epithelial cell sheet and from which these processes originated may be dying or desquamated cells or some form of nerve cell. The fine processes observed by scanning electron microscopy had similar locations to the larger projections which extended over the epithelial cell sheets and which were resolved by light microscopy (Chapter 7), though the size discrepancy is difficult to explain.

16. 1. 2 Malignant oesophageal cells *in vivo* and *in vitro*

As the cells growing from many specimens of oesophageal carcinomas had an indefinite *in vitro* lifespan it was possible to examine both primary and continuous epithelial cell cultures derived from oesophageal carcinomas and to compare the cultured malignant cells with those *in vivo*.

All of the tumour specimens examined *in vivo* were somewhat different from one another, though well differentiated tumours showed similarities to one another and generally displayed abundant tonofilaments, while poorly differentiated anaplastic forms typically contained dilated rough endoplasmic reticulum and numerous cytoplasmic organelles and retained the ability to differentiate further.

Ultrastructural features such as multiple nucleoli, invaginated nuclei and nuclear inclusions have been described in other malignant specimens *in vivo* (Ghadially, 1975; Birbeck, 1978; Sobel and Marquet, 1980) and are probably related to abnormal nuclear metabolism. Structures such as tonofilaments are abundant in keratinising epithelia (Green, 1977; Hopwood *et al*., 1978) and

their presence is, therefore, to be expected in poorly differentiated keratinising carcinoma cells.

There were many similarities between the oesophageal carcinoma cells growing in primary culture and corresponding cells *in vivo*. Differentiated features such as tonofilaments and both intercellular and intracytoplasmic desmosomes were prominent. However, no bizarre vacuolated cells with whorled bodies were noted in primary cultures and the cells were more electron dense than those *in vivo* since cytoplasmic organelles were more numerous. These morphological changes may be indicative of functional adaptation to growth conditions in an altered environment or be related to selection of the less differentiated or specialised carcinoma cells as those better equipped to survive *in vitro*.

The continuously growing oesophageal carcinoma cell lines, although derived from clinically similar tumours and anatomically similar sites, showed a range of features *in vitro* (Chapter 15). Cell lines derived from well differentiated tumours (with the exception of line Hcu 39) showed some similarities in growth pattern, stratification and degree of adherence (as revealed by the abundance of desmosomes), while those derived from poorly differentiated tumours were not as complexly stratified and were characterised by loosely packed angular cells, displaying fewer desmosomes and tonofilaments and relatively more surface projections. There was, therefore, some correlation between features observed *in vitro* by scanning and transmission electron microscopy and tumour differentiation *in vivo*, this fact indicating that cells *in vitro* retain some of the features which characterise them *in vivo*.

All of the primary cultures and continuous cell lines had distinct and unique morphologies, as did the oesophageal carcinomas *in vivo*. Such features may be related to the genetic properties of the tumours and the individuals in which they were growing.

Malignant oesophageal cells *in vitro* showed more evidence of surface activity and long intercellular contacts than those *in vivo* and this may be related to the way in which carcinoma cells adapt

to the artificial *in vitro* environment.

In spite of the observed differences between carcinoma cells *in vivo* and *in vitro*, a thorough investigation of continuously growing cell lines may provide information which is of relevance and eventual benefit to the patient.

Specimen preparative procedure affected cell selection and morphology and ultrastructural differences were observed between the cells of continuous lines which were prepared for electron microscopy by pelleting and those which were prepared in the flasks or on the coverslips where they were growing.

16. 1. 2. 1 Pelleted cells

Although all other oesophageal carcinoma cell lines examined by transmission electron microscopy have been prepared by trypsinisation or scraping, centrifugation and pelleting (Bey *et al*., 1975; Laboratory Section, Peking, 1975; Nishihira *et al*., 1979), there are some problems inherent to this technique.

The debris present in all pelleted specimens was concentrated during centrifugation and not washed away as was the case for cells fixed in their flasks. Furthermore, preparation of pelleted cells involved selection of cells, Those pellets which were prepared by vigorously shaking flasks and collecting the detached cells had high proportions of desquamated partially keratinised cells as well as numerous mitotic cells since such cells were not firmly anchored to the substrata. Cells removed by trypsinisation ma, have been damaged (Anghileri and Dermietzel, 1976) and the cell population altered. Thus, the study of cells prepared by pelleting compliments, but cannot replace, the morphological examination of cells *in situ* in their *in vitro* environment.

The reduced microvilli and decreased numbers of desmosomes in pelleted cells may be attributed to disruption of the cell membrane and intercellular contacts during centrifugation and trypsinisation. The layering of pelleted cells is an unusual phenomenon and difficult to explain. The peripheral cells may be per-

forming a protective function by surrounding the cells more centrally located in the pellets, or the layered appearance may result from morphological changes during centrifugation.

16. 1. 2. 2 Oesophageal carcinoma cells in flasks and on coverslips

A more representative population of cells was presumed to be present in the specimens which were prepared in the flasks or on the coverslips where they were growing, though some loosely adherent cells were removed during solution changes and rinsing.

All primary and continuous cultures of oesophageal carcinoma cells prepared *in situ* for scanning and transmission electron microscopy maintained their typical *in vitro* growth patterns. Layering of the cells of the primary cultures was evident and determined cellular features to a certain extent, as did position in relation to the explant; the larger dividing cells being located near the growing regions, while small, tightly packed cells surrounded the explants.

16. 2 A COMPARISON OF SOME ULTRASTRUCTURAL FEATURES OF NORMAL AND MALIGNANT OESOPHAGEAL CELLS

The major differences between normal and malignant oesophageal cells *in vivo* were the presence or absence of surface microridges, the degree of differentiation expressed by the cells and the presence of altered cytoplasmic organelles. Normal oesophageal cells, both *in vivo* and *in vitro*, formed a more uniform population and fewer morphological variations were noticed than in malignant oesophageal cells. Normal oesophageal cells were polygonal and uniform in shape and size, while the malignant cells showed variation in shape with frequent giant cells being observed. Normal cells were spread out and had a large area of contact, either with underlying cells or with the substrata. Malignant cells, with the exception of the giant cells, were not as closely in contact with the substrata or underlying cells and had smaller surface areas. The short sparse micro-

villi on cultured normal oesophageal cells resembled those on [illegible] and this may be related to the large amount of membrane in contact with the substrate. Other malignant cells had more numerous, long and sometimes branching microvilli which may be related to an abundance of cell membrane components or the absence of microridges.

Lateral processes were observed on occasional normal cells near growing regions, but were frequently encountered as extensions of malignant cells. Normal oesophageal cells did not possess long intercellular processes as they were tightly adherent and grew in close proximity to one another with adjacent cells being connected by short and complex interdigitations. Malignant cells of the continuous lines, with the exception of line Hcu 13, had few areas of close interdigitation and the long and branching lateral processes present on most cells seemed to play a role in intercellular communication. The increased surface activity associated with all of the malignant cells in contrast to cultured normal oesophageal cells, may be associated with the increased metabolism of the neoplastic condition.

10. 2. 1 Stratification

Both normal and malignant oesophageal cells grew in a stratified fashion *in vitro*. This was not unexpected as oesophageal cells have their origin in stratified squamous epithelium. Normal skin (Sun and Green, 1976; Green et al., 1977; Opie and O'Brien, 1979) and vaginal epithelium (Sobel *et al.*, 1979) also maintain a stratified form *in vitro*, and it is doubtful that true monolayer cultures may be derived from sites of normal stratified epithelium. Stratification of cells of oesophageal carcinoma cell lines has not previously been described as other workers (Bey *et al.*, 1976; Nishihira *et al.*, 1979) have examined pelleted cells. Cell stratification *in vitro* may be a manifestation of a cellular attempt to maintain *in vivo* growth relationships.

In this study, those cell lines and primary cultures derived from well differentiated tumours were more complexly stratified than

those from poorly differentiated tumours.

The apparent absence of mitotic figures from stratified cultures of normal oesophageal epithelium viewed by interference and scanning electron microscopy may be attributed to the fact that cell division occurred in the basal layers, as in cultured skin (Rheinwald, 1979). In the cultures of malignant cells, however, mitoses were observed among the superficially situated cells.

16. 2. 2 Keratinisation

The processes of keratinisation and desquamation occurred in cells of the well differentiated primary cultures and continuous oesophageal carcinoma cell lines. In many cultures the superficially situated cells were more highly differentiated and contained abundant tonofilaments (Sobel et al., 1979; Voigt and Fusenig, 1979), a phenomenon which is also evident in normal oesophageal cells in vivo (Dermet and Lytgat, 1974), where filaments accumulate at the expense of other organelles. Tonofilaments were most abundant in primary cultures of normal and malignant oesophageal cells, though, since the normal oesophageal mucosa is a non-keratinising structure in man, the tonofilaments were also not as well developed as those in keratinising epithelia (Zelickson and Hartman, 1962).

True keratinisation occurred in some of the carcinoma cells and marginal band formation was most prominent in Hcu 13 and B 5. The dense material forming the thickened plasma membranes was continuous with the attachment plaques of the desmosomes and formed a detergent insoluble layer of protein beneath the plasma membrane (Sun and Green, 1976). The marginal band or cornified envelope serves as a sack to contain keratin proteins after the keratinocyte dies (Rheinwald, 1979).

The morphological indications for keratinisation were most pronounced in tightly adherent cells of semi-confluent cultures and keratinisation in vitro is in some way dependent on the supportive and nutritive effects of adjacent epithelial cells (Knowles and

[illegible]. The cells of the poorly differentiated lines were [illegible] contact with one another and showed no evidence of [illegible]sation.

16. [illegible] Desmosomes

The large number of desmosomes present in all normal oesophageal [illegible] and oesophageal carcinoma specimens is to be expected, as a large desmosome field is unique to the normal oesphagus (Rhodin, [illegible]; Hopwood et al., 1978). These junctional areas may be significant in the maintenance of a patent barrier between the lumen of the oesophagus and the deep-lying cells.

Though some workers ([illegible], 1974; Tickle et al., 1973; Trump et al., 1980) have noted a decrease in the number of desmosomes in malignant tissues, Pauli et al. (1978) noted that a higher percentage of the cell surface in carcinomas was occupied by desmosomes and that there was an increase in desmosome size as a result of squamous differentiation of the tumours.

Although internalised desmosomes were not observed in any of the normal oesophageal mucosal specimens examined in this study intracytoplasmic desmosomes are not unique to malignant tissue but have been observed in the functional layer of normal human oesophageal epithelium (Al Yassin and Toner, 1977, Hopwood et al., 1978) and in dyskeratotic epithelial cells in benign skin conditions such as [illegible] disease (Seiji and Mizuno, 19[illegible]) and keratoacanthomas ([illegible] and Wilborn, 1980).

In vivo intracytoplasmic desmosomes may be formed by endocytosis and retraction into small vacuoles (Al Yassin and Toner, 1977). Little is known of the fate of desmosomes and these structures have never been observed in a partially broken down state (Logan et al., 1978). Oesophageal desmosomes must be removed as there are fewer desmosomes in the superficial cells of normal oesophageal mucosa than in basal cells (Al Yassin and Toner, 1977). The desmosomes of the upper functional layer apparently lack the intercellular dense line (Logan et al., 1978) and appear to be degenerating or changing in structure. Surface oesophageal cells

are continually being replaced and intercellular adhesions are disrupted for desquamation to occur.

Internalised desmosomes and occasional intracytoplasmic hemidesmosomes were a feature of cultured malignant oesophageal cells. In malignant tissue, internalisation of desmosomes may be a cytoplasmic process which is responsible for decreased cellular adhesion, a property of carcinomas (Sugar, 1972; Birbeck, 1975), and thus related to metastatic potential and tumour invasion. However, although intercellular desmosomes were present in several specimens, the malignant cells remained tightly adherent to one another. In vitro, internalisation of desmosomes may have resulted from passaging as desmosomes may be endocytosed following trypsin treatment (Overton, 1968). This phenomenon could also occur during cell fusion when previously external areas of cell membrane become internal (Ghadially, 1980) as in the formation of polyploid giant cells (Brodsky and Uryvaeva, 1977). However, not all of the intracytoplasmic desmosomes observed were in giant cells and the paranuclear position of the internalised desmosomes and the absence of ingested cell membrane does not support this theory.

Desmosomes appear to be foci for organisation of cytoskeletal elements within the cell and are important in the determination of cell shape and internal organisation (Dembitzer et al., 1980). Cell degeneration has a role in the development of loss of cohesion (Sugar, 1972) and this is probably the process by which the superficial cells are shed from keratinised surfaces and may have some bearing on tumour spread. However, changes in intercellular junctions may be unrelated to the potential of tumours to invade (Pauli et al., 1978) and host factors may be the primary determinants of the capacity of malignant cells to metastasize.

16. 2. 4 Microplicae and intercellular ridges

The presence or relative absence of microplicae was an important criterion which facilitated the distinction between normal and malignant oesophageal cells in vivo. Failure of microridge develop-

ment may be related to the rapid growth and turnover of the malignant cells, or to ultrastructural features such as the number and arrangement of microfilaments, most notably, tonofilaments.

Microplicae have been described on the surface cells of other normal stratified squamous epithelia (Ackerman et al., 1976; Sobel et al., 1979) and in various stages of epidermoid metaplasia of the nasal mucosa (Boysen and Reith, 1980). These structures may reduce the frictional area between the plasma membranes of adjacent cells and function to trap lubricating fluids such as mucin (Kessel and Kardon, 1979). The variation in arrangement, size and number of the microplicae which is difficult to explain on a functional basis may be related to tonofilament distribution. By transmission electron microscopy oesophageal cells containing abundant tonofilaments displayed irregular surfaces. When surface cells desquamated and detached from underlying cells, the underlying cells did not display many surface microridges, as such underlying cells may still have been acquiring tonofilaments and becoming increasingly differentiated.

The absence of microplicae from cultured normal oesophageal cells may be related to the different environment, and consequently modified cellular functions which lead to the decreased differentiation expressed by cultured cells. As described by Ackerman et al. (1976), many of the normal oesophageal cells *in vivo* were bordered by prominent intercellular ridges which resembled those present between normal bladder urothelial cells *in vitro* (Heatfield et al., 1980). These regions may represent either tight contacts or areas where the cells are beginning to detach. Carr et al. (1974) reported that the curling at the edges of some oesophageal cells was a sign of impending degeneration though the mechanism by which the normally tight intercellular adhesions are broken is unclear. Intercellular ridges were poorly developed in cultures of normal oesophageal mucosa and there was little evidence of desquamation. Malignant oesophageal cells *in vivo* also lacked prominent intercellular ridges and areas of cell contact were not well defined. This may be related to the fact that malignant oesophageal cells were not as flattened or as closely

opposed as the normal oesophageal cells.

16. 2. 5 Microvilli

Microvilli and other surface projections were particularly prominent on cultured neoplastic oesophageal cells. In normal oesophageal cells microvilli and microplicae were mutually exclusive. In vivo, microplicae were the prominent surface projections on normal oesophageal cells but these processes were replaced in vitro by microvilli.

The cell lines exhibiting the best developed microvilli (Hcu 10, Hcu 18, Hcu 37) all originated from invasive anaplastic tumours. As in the case of other malignant cells (Gondos et al., 1979) the observed microvilli were widely distributed and showed variation in appearance. Although environment influences cell form to a large extent (Westbrook et al., 1975) cell surface variations are also related to membrane and genetic properties of the cells and each of the nine oesophageal carcinoma cell lines studied by scanning electron microscopy showed unique surface features which allowed it to be readily identified. The varying surface features observed from line to line may be related to genetic differences, differentiation and malignant potential. Although there are no specific surface features characteristic for malignancy, importance has been placed on the significance of microvilli and their role in neoplastic change (Boysan and Reith, 1980; Reith et al., 1980; Wanson et al.,.1980). Cell surface changes in addition to other features must be associated with malignant transformation as the cell surface plays an important role in the regulation of cell growth, movement and intercellular communication (Abercrombi and Ambrose, 1962; Brightman and Reese, 1969). The postulated association of microvillus length and tumour potential (Reith et al., 1980) does not always apply as microvillus length and number may increase with increasing time in culture (Heatfield et al., 1980). In general, cell lines with numerous microvilli are less adhesive and more easily dispersed than those without (Cooper and Fisher, 1968).

Microvilli appear to have an important role in malignancy and alteration of the surfaces of cells from five continuous human oesophageal carcinoma cell lines (Hcu 10, Hcu 13, Hcu 18, Hcu 33, Hcu 37) by an alkyl-lysophospholipid caused a decrease in the number of microvilli and surface projections (Maistry et al., 1980), decreased tumorigenicity and resulted in cell death, an effect which was specific for malignant cells.

16. 2. 6 Nuclear features

Normal and malignant cells showed variations in nucleolar morphology but no constant ultrastructural difference, apart from nucleolar enlargement in malignant cells, was noted. Margination of chromatin, a phenomenon observed in virally infected cells (McNulty et al., 1978) was frequently observed in the nuclei of cells from the line Hcu 13 in vitro. Irregular nuclei are a feature of normal oesophageal cells (Desmet and Tytgat, 1974) and nuclei and nucleoli in tumour cells are generally large and irregular in shape (Busch and Smetana, 1974; Birbeck, 1976; Ghadially, 1980). Some of the nuclear inclusions observed in tumour specimens in vivo correspond to the nuclear bodies, consisting of aggregates of microfibrillar material and reaching diameters of 100 - 600 nm which have been described in normal oesophageal cells in vivo (Al Yassin and Toner, 1977), in other keratinising cells (Wier et al., 1971) and in squamous cell carcinomas (Granboulan et al., 1963; Patrizi and Middelkamp, 1969).

16. 2. 6. 1 Intranuclear particles

The clearly defined intranuclear particles observed in cells of line Hcu 13 were morphologically similar to those described by Lutzner (1967) as replicating wart virus, while also bearing some resemblance to herpes virus particles. Such particles were not present in all specimens of the line Hcu 13 that were prepared for transmission electron microscopy and there was definite indication of cyclical production, a phenomenon which tallies with Hallauer and Kronauer's (1962) observation that infected cell strains show

microvilli appear to have an important role in malignancy and alteration of the surfaces of cells from five continuous human oesophageal carcinoma cell lines (Hcu 10, Hcu 13, Hcu 18, Hcu 33, Hcu 37) by an alkyl-lysophospholipid caused a decrease in the number of microvilli and surface projections (Maistry et al., 1982), decreased tumorigenicity and resulted in cell death, an effect which was specific for malignant cells.

16. 2. 6 Nuclear features

Normal and malignant cells showed variations in nucleolar morphology but no constant ultrastructural difference, apart from nucleolar enlargement in malignant cells, was noted. Margination of chromatin, a phenomenon observed in virally infected cells (McNulty et al., 1978) was frequently observed in the nuclei of cells from the line Hcu 13 in vitro. Irregular nuclei are a feature of normal oesophageal cells (Delmet and Tytgat, 1974) and nuclei and nucleoli in tumour cells are generally large and irregular in shape (Busch and Smetana, 1974; Birbeck, 1976; Ghadially, 1980). Some of the nuclear inclusions observed in tumour specimens in vivo correspond to the nuclear bodies, consisting of aggregates of microfibrillar material and reaching diameters of 100 - 600 nm which have been described in normal oesophageal cells in vivo (Al Yassin and Toner, 1977), in other keratinising cells (Wier et al., 1971) and in squamous cell carcinomas (Granboulan et al., 1963; Patrizi and Middelkamp, 1969).

16. 2. 6. 1 Intranuclear particles

The clearly defined intranuclear particles observed in cells of line Hcu 13 were morphologically similar to those described by Lutzner (1967) as replicating wart virus, while also bearing some resemblance to herpes virus particles. Such particles were not present in all specimens of the line Hcu 13 that were prepared for transmission electron microscopy and there was definite indication of cyclical production, a phenomenon which tallies with Hallauer and Kronauer's (1962) observation that infected cell strains show

alternating cycles during which virus can be detected. Many specimens which showed no indication of viral activity or intranuclear particles may actually have contained virus material which was not detectable at the time of examination.

The intranuclear particles in line Hcu 13 were clustered and stood out more distinctly from the rest of the nuclear material than those termed interchromatin granules and described in various tumours (Busch, 1974; Ghadially, 1975). Furthermore, the observed intranuclear particles were smaller than the 30 - 35 nm diameter perichromatin granules (Busch, 1974; Ghadially, 1975, 1980) which appear at the margin of heterochromatin and euchromatin (De Harven, 1973).

The particles observed in this investigation bore no resemblance to the C-type particles observed in an oesophageal carcinoma cell line established from a tumour in a Rhesus monkey (Rabin et al., 1978) and no other particles similar to C-type viruses were observed. Ultrastructural studies of other human oesophageal carcinoma cell lines have not revealed the presence of any virus-like structures (Bay et al., 1974; Nishihira et al., 1979; Yang, 1980) and no virus particles have been positively identified in normal oesophageal cells.

If the observed 20 - 30 nm diameter particles do represent viral material this does not necessarily imply that a virus is the cause of carcinoma of the oesophagus - it may be a secondary effect, a latent passenger virus, or an artifact of tissue culture. The possibility of the presence of a virus in the human oesophageal carcinoma cell line Hcu 13, is currently being investigated by Dr. H. Rabin, Frederick Cancer Research Centre, Frederick, U.S.A. (Rabin et al., 1981) and Dr. H. Zur Hausen, Institut für Virologie in Zentrum für Hygiene, Freiburg, Germany. Even if these structures do not represent viral material, they are definitely indicative of altered metabolism. They may not, however, be of significance as many normal cells have been shown to contain particulate organisms of virus size, but poorly understood function (De Harven, 1973). The interpretation of such particles in human material is

usually highly contentious and the results of many such studies have been disappointing despite the fact that more electron microscopy time has probably been spent on searching for virus particles in human tumours than in any other field of ultrastructural research in relation to cancer (Birbeck, 197). Nonetheless, the possible role of a virus in carcinoma of the oesophagus cannot be overlooked.

16. 2. 7 Cytoplasmic particles and granules

The aggregates of 8 - 14 nm cytoplasmic rods present in lines Hcu 18, Hcu 33, Hcu 37 and B 5 resembled the filamentous vermicillar bodies described by Ghadially (1975). Such bodies may represent deranged viral core production, or be associated with abnormal protein metabolism. Although similar fine tubular coils (12 - 15 nm in diameter) have been described in nasopharyngeal tumour cells (Arnold and Huth, 1979), the appearance of particles or granules is not necessarily concomitant with virus activity but may represent a non-specific cellular response to several diseases (Rybicka, 1978).

The 40 nm dense cytoplasmic rods which occurred in aggregates in the lines Hcu 13, Hcu 33 and Hcu 37 may represent some form of degenerating mitochondria, be a specialised type of myelinoid body or indicate altered metabolism or viral activity. Such structures were often encountered in the same cultures as the 8 - 14 nm filamentous rods.

The oval 60 nm granules present in some specimens of normal and malignant oesophageal cells (B 5) resembled membrane coating granules. Although Zelickson and Hartmann (1962) recognised no keratohyaline granules in non-keratinising mucosa, membrane coating granules have been observed in human oesophageal mucosa (Al Yassin and Toner, 1977; Hopwood et al., 1977). These granules may, therefore, be related to differentiation of the oesophageal cells and appear independently of malignant change

16. 2. 8 Annulate lamellae

Annulate lamellae were only observed in cultured passaged neo-

plastic oesophageal cells. These structures have been described in many normal, altered, preneoplastic and rapidly multiplying cell populations (Kumegawa et al., 1965) and many authors (Merkow et al., 1970; Krishan, 1971; Maul, 1977) have suggested that viruses and viral agents causing cell fusion are responsible for an increase in annulate lamellae. This increase may be a cellular response concomitant with virus replication or be a secondary manifestation of viral toxicity (Merkow et al., 1970). The increasing number of reports of annulate lamellae in neoplastic cells further suggests that they have an unknown role in some neoplastic cells (Sun and White, 1979) and their presence in a variety of cell types indicates a more important role in the activity of cells than was initially supposed. Annulate lamellae may result from a disturbance in the host cell caused by interaction with a virus or be related to rapid growth and differentiation, as may well-developed rough endoplasmic reticulum, golgi complexes and myelinoid figures.

16. 2. 9 Endoplasmic reticulum

The amount of endoplasmic reticulum varied from specimen to specimen This organelle was present in the basal cells of normal oesophageal mucosa *in vivo*, in some cultured normal oesophageal cells *in vitro* and in many cells of some carcinomas *in vivo*. Well developed endoplasmic reticulum (as seen in line Hcu 18) has been considered an expression of cell differentiation and functional activity (Ghadially, 1975) and an inverse relationship between the amount of rough endoplasmic reticulum and growth rate and malignancy of a tumour suggested (Oberling and Bernhard, 1961; Bernhard, 1969). In cells of the continuous carcinoma cell lines there was much variation in the amount of rough endoplasmic reticulum present and no obvious correlation between the amount of this organelle and any other ultrastructural feature noted.

The observation that complex endoplasmic reticulum may be a characteristic cellular response to the protein synthetic requirements of virus replication (Parkin and Brunning, 1978) was not strongly

supported. The line Hcu 13 which showed some possible evidence of virus activity displayed very little rough endoplasmic reticulum. This organelle was, however, prominent in cells of the lines Hcu 18, Hcu 33 and Hcu 37, all of which contained fine cytoplasmic rods.

16. 2. 10 Cytoplasmic bodies

Myelinoid bodies were present in oesophageal carcinoma cells *in vivo* and in both cultured normal and neoplastic oesophageal cells, but were more numerous and larger in cells of the malignant oesophageal lines. In cultures of both normal and neoplastic cells, the myelinoid bodies were relatively more abundant in the basally located cells and sparse in the superficial cells. These structures were more abundant in older or confluent cultures and are probably associated with storage, degenerative changes or hypertrophy of endoplasmic reticulum. Similar concentric lamellar bodies have been described in a variety of pathologically altered cells (Shadially, 1975) which include those with viral infections (Albot and Jerequel, 1962; Miyai *et al*., 1963).

The bizarre cytoplasmic bodies present in T 24 may represent abnormal accumulations of ribosomes with associated endoplasmic reticulum which produce the protein required for use in tumour cell growth (Sobel and Marquet, 1970) or be sites of viral synthesis. The whorled bodies *in vivo* bore some morphological resemblance to glycogen-membrane complexes (Le Beux, 1969; Corvaja *et al*., 1971), though they differed from these bodies in size and substructure.

16. 2. 11 Glycogen and lipid

Glycogen particles were present in both normal and malignant oesophageal cells *in vivo* and *in vitro*. Glycogen may be an important energy source of the superficial cells where mitochondria have degenerated. Accumulations of glycogen have been reported in epidermal keratinocytes (Breathnach, 1971), in surface oesophageal cells during hyperplasia (Dreyer, 1980) and in all layers of the

normal oesophagus (Hopwood et al., 1979). Glycogen bodies were best developed in lines B 5 and B 17 and may have had a storage function, or have been related to differentiation.

The role played by the lipid in many of the oesophageal carcinoma cells in vivo and in vitro is uncertain. Lipid droplets were most abundant in giant cells, this fact suggesting that they represent some cellular response to stress. Alternatively, the lipid droplets may represent an energy store. Lipid droplets have not been described in normal oesophageal cells in vivo and were also not observed in the cells in primary cultures of normal oesophageal mucosa which may have different metabolic rates from cultures of malignant cells.

16. 2. 12 Mitochondria

The mitochondria in both normal and malignant oesophageal cells in vivo were round and vacuolated while denser forms were present in all specimens in vitro. The changes may be attributed to osmotic and metabolic effects of the in vitro environment.

The cup-shaped and doughnut mitochondria seen in T 29 may represent a degenerative phenomenon prior to the formation of myelinoid bodies or be an adaptive change as the increased mitochondrial surfaces of such mitochondria may facilitate exchanges between the cytoplasm and the mitochondria (Ghadially, 1975).

16. 2. 13 Golgi apparatus

The golgi apparatus was better developed in malignant than in normal oesophageal cells. Golgi activity was increased in vitro and the golgi apparatus was prominent and well developed in most of the lines examined. Marked hypertrophy of the golgi complex has been described as a characteristic of some well differentiated tumours (Ghadially, 1975). In this study even the anaplastic and rapidly growing tumour specimens exhibited well developed golgi complexes, and there did not appear to be a correlation between growth rate and golgi development. The tremendous activity of

the golgi complex can also be accounted for on the basis of a virus hypothesis as animal cell lines grown *in vitro* generally increase many of their transport activities upon transformation by tumour viruses (Nicholson *et al.*, 1975).

16. 2. 14 Ultrafilaments

Aggregates of fine and intermediate filaments were frequently observed in malignant oesophageal cells both *in vivo* and *in vitro*. Filamentous aggregates *in vivo* may be related to abnormal keratinisation or represent atypical basement membrane material as has been recognised in numerous other pre-invasive and invasive carcinomas (Frithiof, 1972; Tarin, 1972). The filamentous aggregations seen in T 22 and T 24 represent bizarre basement membrane formations which may be a protective response mounted by the host (Frithiof, 1972).

Accumulations of microfilaments *in vitro* may be related to altered functional requirements of the neoplastic cells or be a manifestation of loss of control of production of these structures and therefore a further result of abnormal metabolism, or an adaptation to *in vitro* conditions as Sattler *et al.* (1978) observed an increase in the complexity of microfilaments with increasing time in culture. The paracrystalline bodies present in two specimens resembled those described by Nishihira *et al.* (1979) but their function is unclear. None of these structures was observed in normal oesophageal cells.

16. 2. 15 Associated micro-organisms

The number of micro-organisms associated with normal and malignant oesophageal cells *in vivo* varied from specimen to specimen and may reflect the diet and state of health of the individuals. The association of micro-organisms with oesophageal cells was expected since all ingested material makes contact with the oesophagus.

Many individuals harbour mycoplasmas in the oral cavity and on mucous membranes (McGarrity *et al.*, 1978) and mycoplasmas have been

complex can also be accounted for on the basis of a [illegible] animal cell lines grown in vitro generally increase many of their transport activities upon transformation by [illegible] viruses (Nicholson et al., 1975).

Microfilaments

Aggregates of fine and intermediate filaments were frequently observed in malignant oesophageal cells both in vivo and in vitro. Filamentous aggregates in vivo may be related to abnormal keratinisation or represent atypical basement membrane material as has been recognised in numerous other pre-invasive and invasive carcinomas (Frithiof, 1972; Tarin, 1972). The filamentous aggregations seen in T 22 and T 24 represent bizarre basement membrane formations which may be a protective response mounted by the host (Frithiof, 1972).

Accumulations of microfilaments in vitro may be related to altered functional requirements of the neoplastic cells or be a manifestation of loss of control of production of these structures and therefore a further result of abnormal metabolism, or an adaptation to in vitro conditions as Sattler et al. (1978) observed an increase in the complexity of microfilaments with increasing time in culture. The paracrystalline bodies present in two specimens resembled those described by Nishihira et al. (1979) but their function is unclear. None of these structures was observed in normal oesophageal cells.

Associated micro-organisms

The number of micro-organisms associated with normal and malignant oesophageal cells in vivo varied from specimen to specimen and may reflect the diet and state of health of the individuals. The association of micro-organisms with oesophageal cells was expected since all ingested material makes contact with the oesophagus.

Many individuals harbour mycoplasmas in the oral cavity and on mucous membranes (McGarrity et al., 1[illegible]) and mycoplasmas have been

successfully cultured from material obtained from t[illegible] wa[illegible] from patients with oesophageal carcinomas (Maistry, 1960) and from healthy subjects (Maistry, pers comm.). Normal oesophageal cells in vivo may, in some way, eliminate mycoplasmas and these organisms were observed in intracellular positions in the cyto-plasm of oesophageal mucosal cells. Alternatively the mycoplasmas may grow and multiply within the cells.

Extracellular mycoplasmas were occasionally observed associated with malignant oesophageal cells in vivo and in vitro and there were no consistent differences between normal and malignant human oesophageal cells as far as associated micro-organisms were con-cerned.

16. 3 SUMMARY

The morphological investigation of normal and malignant human oesophageal cells in vivo and in vitro led to the recognition of both similarities and differences between the cell populations studied and an awareness of some of the structural changes which occurred during adaptation to the in vitro environment.

Although no single feature diagnostic for all oesophageal carcino-mas was observed, the following differences facilitated the dis-tinction between normal and malignant oesophageal cells:

1. In vivo the superficial cells of normal oesophageal mucosa were characterised by regular arrays of surface microplicae. These structures were reduced in number and less regular in form on malignant oesophageal cells in vivo.
2. While cultured normal oesophageal cells were flattened and possessed few surface extentions, many oesophageal carcinoma cells in vitro displayed abundant microvilli of varying length, in addition to well-developed radiating lateral processes.
3. Normal oesophageal mucosal cells, both in vivo and in vitro, were regular in form and specimens from different individuals were of similar morphology. Car-

cinoma cells varied in size and morphology from specimen to specimen, and within the same specimen. Although morphological differences were less pronounced *in vitro*, cells from each of the ten continuous lines could be ultrastructurally distinguished.

4. Normal oesophageal mucosal cells were highly differentiated but did not keratinise either *in vivo* or *in vitro*. Malignant cells exhibited a range of differentiation and keratinised squames bordered by marginal bands were present in several specimens both *in vivo* and *in vitro*.
5. The organelles present in normal oesophageal cells were unremarkable, but bizarre structures and altered cytoplasmic organelles were observed in malignant cells *in vivo* and in cultures. Structures such as whorled bodies, intracytoplasmic desmosomes, annulate lamellae, confronting cisternae and intranuclear particles may be related to the abnormal metabolism of the malignant cells.

The ultrastructural differences observed between normal and malignant cells may facilitate the recognition of premalignant changes and be an aid in early diagnosis.

Cell structure changed during adaptation to culture conditions and normal and malignant oesophageal cells *in vitro* differed from those *in vivo* in a number of ways:

1. Surface projections - the microplicae present on normal oesophageal cells *in vivo* were absent *in vitro* while the sparse microvilli present on cultured normal oesophageal cells were not observed *in vivo*. The opposite effect was observed in oesophageal carcinoma cells; those *in vitro* displayed more abundant surface projections than those *in vivo*.
2. Intercellular junctions - in specimens of both normal and malignant oesophageal mucosae desmosomes and junctional regions were better developed *in vivo* than *in vitro*.

3. Differentiation - there was a tendency for all cells to become less differentiated *in vitro*.
4. Morphological variation - both cultured normal and malignant oesophageal cells were more uniform in appearance than those *in vivo*.
5. Cytoplasmic organelles - cultured cells were more electron dense and contained more prominent organelles than those *in vivo*. In particular, myelinoid bodies were more frequently encountered in cultured cells.
6. Fibrous networks - the fine branching fibrils which made contact with a number of cultured normal oesophageal cells were not evident *in vivo*.

In spite of these differences a strong correlation with the tissue of origin persisted and all of the continuous cell lines displayed features which justified them being classified as oesophageal carcinoma cell lines.

Several features which indicate a possible viral involvement with carcinoma of the oesophagus were observed. These included:

1. Prominent 20-30 nm intranuclear particles in Hcu 13, T 24 and T 35 cells.
2. Bundles of 8 - 14 nm cytoplasmic rods in Hcu 18, Hcu 33, Hcu 37 and 8 5 cells.
3. Aggregates of electron dense 40 nm cytoplasmic rods in Hcu 13,Hcu 33 and Hcu 37 cells.
4. Well developed annulate lamellae in Hcu 10, Hcu 13, Hcu 18, Hcu 33 and Hcu 37 cells.
5. Increased protein synthesis as suggested by the well developed rough endoplasmic reticulum and golgi complexes in several specimens.
6. Margination and clumping of chromatin in many nuclei.
7. Giant cells which may have arisen as a result of a virus-induced fusion process.

Thus, ultrastructural studies provided much useful information about normal and malignant oesophageal cells *in vivo* and *in vitro*.

17. RESULTS

SOME PROPERTIES OF EXPERIMENTALLY INDUCED HUMAN OESOPHAGEAL CARCINOMAS IN THE NUDE MOUSE

17. 1 TUMOUR "TAKE" RATES

During this investigation 124 athymic mice of both sexes were inoculated; 96 with cells from nine different continuous human oesophageal carcinoma cell lines and 28 with four lines from oesophageal carcinomas induced in nude mice by the inoculation of cells from human oesophageal carcinoma cell lines. The inoculated mice were examined for periods of up to eight months and any mass which appeared at the site of inoculation and did not regress scored as a tumour (Fig. 96).



Fig. 9[illegible] Clearly defined [illegible]ile tumour nodule in a suprascapular position in a male mouse which was inoculated with Hcu 13 cells.

Clearly recognisable tumours (..2) developed in 3[illegible] of the animals; an overall "take" of 31,[illegible] per cent. Although tumour "take" rates varied depending on the cell line inoculated (Table 27), distinct tumour masses (Figs. 96 - 100) grew in nude mice as a direct result of the introduction of oesophageal carcinoma cells from eight of the nine lines. Cells from the lines Hcu 13 and Hcu 33, both derived from well differentiated human tumours appeared to be the most tumorigenic with "take" rates of 90 per cent and 80 per cent respectively. The human oesophageal carcinoma cell lines which showed differentiated features, such as abundant tonofilaments (Hcu 13, Hcu 33 and B 6) in vitro were more tumorigenic than those derived from poorly or moderately differentiated tumours (Hcu 10, Hcu 18, Hcu 37 and B 17) or those (Hcu 35 and Hcu 39) which, although being derived from well differentiated tumours, failed to exhibit differentiated functions such as the formation of abundant tonofilaments in vitro. Inoculated cells of the line Hcu 37 did not give rise to tumours which persisted in the nude mouse. Eight to ten days after the inoculation of cells from line Hcu 37 several small tumours were evident at the site of inoculation. Such tumours grew for five to eight days and then spontaneously regressed and disappeared. Another strange phenomenon was that the animals inoculated with cells of this line all developed patches of hair which disappeared after the tumours regressed.

The cell strains 13.M1, 13.M5, 13.M7 and 13.M9, and 13.M1.M11 derived from tumours induced in the nude mouse as a result of the inoculation of cells of line Hcu 13 varied in their tumorigenicity. The strain 13.M1, derived from a well differentiated tumour in the nude mouse was the most tumorigenic (71,4 per cent "take"), while cells from the strain 13.M9 derived from a poorly differentiated mouse tumour (also induced by inoculation of Hcu 13 cells) failed to induce tumour formation in five animals inoculated.

17. 2 LATENCY PERIOD BEFORE APPEARANCE OF TUMOURS

The latency or lag period may depend on a number of factors, such

TABLE 27 FATE OF OESOPHAGEAL CARCINOMA CELL LINES INOCULATED INTO NUDE MICE

Cell line	Number of mice inoculated	Number of resulting tumours	Percentage take of tumours	Range of latency periods
Hcu 10	12 †	5 †	41,7%	6 weeks - 6½ months
Hcu 13	10 †	9 †	90 %	6 weeks - 4 months
Hcu 18	14	4 ††	28,5%	2½ - 4 months
Hcu 33	5	4	80 %	2 - 4 months
Hcu 35	13	3	23 %	4 - 6 weeks
Hcu 37	15	0 †††	0	(8 - 10 days)
Hcu 39	5	1	20 %	2 months
B 5	8	3	37,5%	2 - 8 months
B 17	17	4	23,5%	2 - 4 months
13.M1	7	5	71,4%	1½ - 3 months
13.M5	6	3	50 %	2 - 5 months
13.M7	3	1	33,3%	1½ months
13.M9	5	0	0	-
13.M1.M11	7	0	0	-

† Three mice inoculated bilaterally with cells of lines Hcu 10 and Hcu 13

†† 1 metastatic tumour

††† Several small tumours appeared 8 - 10 days after inoculation and then subsequently regressed and disappeared.

as the number and viability of cells inoculated, the type of cells and the tumorigenic properties of the cells, or the age and health of the animals inoculated. In this investigation the latency periods were fairly long; the average latency being two to four months (Tables 27 and 28). Excluding line Hcu 37, the shortest latency period (one month) was recorded when cells of the line Hcu 35 were introduced into nude mice, while the longest latency periods(eight months) were noted after inoculation of B 5 cells. There was no obvious correlation between tumorigenicity as scored by tumour"take"rates and latency periods before tumour appearance.

17. 3 SEX DIFFERENCES

In view of the small population (124) of nude mice available for use in this investigation both male and female athymic animals were randomly inoculated with oesophageal carcinoma cells. Slightly over half of the mice (73/124 - 58,8 per cent) used in this study were males and 64 per cent (25/39) of the animals which developed tumours were males, thus the tumour "take" rate was 34 per cent for males and 27,4 per cent for females.

Pregnancy did not appear to affect the tumour inducing capacity of the cell lines inoculated and several female athymic mice which were inoculated at six weeks of age subsequently became pregnant and developed tumours while pregnant. Neither the sex of the animals nor the condition of pregnancy had any obvious effect on the latency period before the tumours appeared or the morphology and behaviour of the resultant tumours. Furthermore, the tumours did not affect the pregnancies, the offspring of tumour-bearing mothers showed no obvious abnormalities, and tumour-bearing mothers were sometimes capable of feeding their young.

17. 4 TUMOUR BEHAVIOUR

After their first appearance most of the tumours grew rapidly in the loose areolar subcutaneous tissue at the site of inoculation and within four to eight weeks reached diameters of one to two cm.

Although all 41 of the non-metastatic tumours in the nude mice were derived from similar cell lines obtained from clinically similar human invasive tumours from similar sites, the resulting tumours in the nude mice differed. Experimentally induced carcinomas in the nude mice could be broadly subdivided into those (23) which were well encapsulated and mobile and those (19) infiltrating skin and underlying tissues (Table 28). In several instances cells from a single cell line (e.g. Hcu 13) gave rise to fixed and mobile tumours in different animals, so the degree of invasion of surrounding tissues was not related exclusively to the cell line inoculated. Line Hcu 33 was the only cell line which consistently (in four animals) gave rise to well encapsulated mobile tumours in the nude mouse. Such tumours grew rapidly and in six weeks reached diameters of two to three cm, at which stage they were still fully mobile and had no attachment to the overlying skin (Fig. 97).



Fig. 97 Large, clearly defined mobile tumour in M 28 induced as a result of the inoculation of Hcu 33 cells.

Many tumours which infiltrated surrounding tissues frequently became complexly lobulated (Fig. 98). Invasion of muscle, skin

Although all 41 of the non-metastatic tumours in the nude mice were derived from similar cell lines obtained from clinically similar human invasive tumours from similar sites, the resulting tumours in the nude mice differed. Experimentally induced carcinomas in the nude mice could be broadly subdivided into those (13) which were well encapsulated and mobile and those (13) infiltrating skin and underlying tissues (Table 28). In several instances cells from a single cell line (e.g. Hcu 13) gave rise to fixed and mobile tumours in different animals, so the degree of invasion of surrounding tissues was not related exclusively to the cell line inoculated. Line Hcu 33 was the only cell line which consistently (in four animals) gave rise to well encapsulated mobile tumours in the nude mouse. Such tumours grew rapidly and in six weeks reached diameters of two to three cm, at which stage they were still fully mobile and had no attachment to the overlying skin (Fig. 97).



Fig. 97 Large, clearly defined mobile tumour in N 28 induced as a result of the inoculation of Hcu 33 cells.

Many tumours which infiltrated surrounding tissues frequently became complexly lobulated (Fig. 98). Invasion of muscle, skin

TABLE 29 SOME PROPERTIES OF EXPERIMENTALLY INDUCED CARCINOMAS IN NUDE MICE

Mouse Number	Cell line inoculated	Differentiation of human cell line	Sex of mouse	Age of mouse when inoculated	Latency period	Age of mouse when tumour removed	Differentiation of mouse tumour	Tumour infiltration
M 1	Hcu 13	well	M	2 months	3 months	6 months	well	+
M 2	Hcu 10 Hcu 13	poor well	M	6 weeks	6 weeks	4 months	poor well	– –
M 3	Hcu 10 Hcu 13	poor well	M	6 weeks	6 weeks	4 months	poor well	– +
M 4	Hcu 10 Hcu 13	poor well	M	6 weeks	6 weeks	4 months	well well	+ –
M 5	Hcu 13	well	M	2 months	3 months	6 months	moderate	+
M 6	Hcu 13	well	F	2 months	3½ months	7 months	well	–
M 7	cu 13	well	M	4 weeks	2 weeks	2 months	moderate	+
M 8	Hcu 13	well	F	3 months	4 months	8 months	moderate	–
M 9	Hcu 13	well	M	4 weeks	4 months	6 months	poor	+
M 10	13.M1	well	M	3 months	1 month	5 months	poor	–
M 11	13.M1	well	F	2 months	4 months	7 months	poor	+
M 12	13.M1	well	M	2½ months	2 months	6 months	well	+

Author Robinson K M
Name of thesis The behaviour and morphology of Human Oesophageal Carcinoma cells in In Vivo and In Vitro and a comparison with the normal 1981

PUBLISHER:
University of the Witwatersrand, Johannesburg
©2013

LEGAL NOTICES:

Copyright Notice: All materials on the University of the Witwatersrand, Johannesburg Library website are protected by South African copyright law and may not be distributed, transmitted, displayed, or otherwise published in any format, without the prior written permission of the copyright owner.

Disclaimer and Terms of Use: Provided that you maintain all copyright and other notices contained therein, you may download material (one machine readable copy and one print copy per page) for your personal and/or educational non-commercial use only.

The University of the Witwatersrand, Johannesburg, is not responsible for any errors or omissions and excludes any and all liability for any errors in or omissions from the information on the Library website.