

https://dspace.org/

An early experience of total hip arthroplasty done through direct anterior approach: an adult of cases done at Helen Joseph hospital

Iqbal, Mohammad Nasir

2016

http://hdl.handle.net/10539/22531

Downloaded from a DSpace repository. https://dspace.org/

An early experience of total hip arthroplasty done through direct anterior approach: An audit of cases done at Helen Joseph Hospital.

Mohammad Nasir Iqbal

A research report submitted to the Faculty of Health Sciences, University of the Witwatersrand, in fulfilment of the requirements for the degree

Of

Master of Medicine

Johannesburg, 2016

Declaration

I, Mohammad Nasir Iqbal declare that this research report is my own work. It is being submitted for the degree of Master of Medicine in the University of the Witwatersrand, Johannesburg. It has not been submitted before for any degree or examination at this or any other university.



11th day of November, 2016.

Abstract

Study design: A retrospective audit of all cases of total hip arthroplasty done at Helen Joseph hospital through the direct anterior approach.

Background: Total hip arthroplasty is among the most successful and reliable procedures used to treat various hip arthritides. It improves the quality of life by relieving pain and improving function. There are various factors that affect the outcome following surgery. One important factor is the choice of the surgical approach used. The direct anterior approach to the hip is minimally invasive with fewer complications and faster rehabilitation compared to other commonly used surgical approaches to the hip joint.

Aim: The aim of this study was to evaluate intra-operative complications, early post-operative complications and time to mobilization in Total Hip Arthroplasty done using a Direct Anterior Approach and thus determine the length of hospital stay.

Methods: This study was a retrospective analysis of the records of all the cases of total hip arthroplasty done using a direct anterior approach from January 2013 to June 2015. Intraoperative complications and times of mobilization were evaluated.

Results: Out of thirty (30) cases, twenty one (21) cases met the inclusion criteria with 11 male and 10 female patients. The average perioperative blood loss was 440ml and the average time of surgery was 145min. No intra-operative fracture, case of deep vein

thrombosis, injury to lateral femoral cutaneous nerve and postoperative hip dislocation occurred in this series. The average time to mobilization was 6.14 days and the average length of hospital stay was 10.28 days.

Conclusion These results are good and comparable to international studies in spite of the learning curve faced by surgeons when using a new approach.

Acknowledgements

I am thankful to the God almighty for the good health that was necessary to complete this research for Master of Medicine in the Department of Orthopaedic Surgery.

I wish to express my sincere thanks to Dr Prakash Kana, my supervisor, for providing me with all the necessary facilities for the research.

I place on record, my sincere thank you to Professor MT Ramokgopa, academic head of Orthopaedic Surgery for the continuous encouragement and input to this project that made it possible.

I take this opportunity to express gratitude to all of the Department's faculty members for their help and support. I also thank my parents and my wife, Dr Rabia Abid, for the unceasing encouragement, support and care.

Table of contents

Declaration ……ii

Abstract ……iii

Acknowledgements……v

Table of contents ……vi

List of Figures ……vii

List of Tables ……viii

Nomenclature ……ix

1. Literature review……1
2. Problem statement……6
3. Aims and objectives ……8
4. Materials and Methods……9
5. Surgical technique……11
6. Results ……15
7. Discussion ……19
8. Conclusion ……23
9. Appendices

   Appendix A: Postgraduate Approval letter ……24

   Appendix B: Ethics Clearance Letter ……25

   Appendix C: Data Collection Sheet and Link Sheet ……26

   Appendix D: Hospital Permission Letter……28

   Appendix E: Data Collection (Recorded)……29
10. References ……31

List of Figures

Figure	Title	Page
Figure 1.	Position of patient on table	11
Figure 2.	Bony landmarks and position of skin incision	12
Figure 3.	Deep dissection of incision	12
Figure 4.	Gender distribution in study	15
Figure 5.	Spectrum of hip pathology included in study	16
Figure 6.	Peri-operative blood loss	16
Figure 7.	Time to mobilization in days	18
Figure 8.	Total hospital stay in ward	18
Figure 9	Pre-operative x-rays of a 63 year old female patient (Figure 9-a) with avascular necrosis of the femoral head of the right hip and post-operative x-rays (Figure 9-b) after total hip replacement done through the direct anterior approach.	21

List of Tables

Table	Title	Page
Table1.	Patient selection criteria for study	10
Table 2.	Physiotherapy protocol at Helen Joseph Hospital after total hip Arthroplasty.	14
Table 3.	Summary of results	17

Nomenclature

AVN: Avascular Necrosis

BMI: Body Mass Index

DAA: Direct Anterior Approach

DVT: Deep Vein Thrombosis

HJH: Helen Joseph Hospital

LFCN: Lateral Femoral Cutaneous Nerve

NOF: Neck of Femur Fracture

OA: Osteoarthritis

THA: Total Hip arthroplasty

1. Literature Review

Standard primary total hip arthroplasty (THA) improves the quality of life by relieving pain and enhancing function in patients with end stage arthritic conditions of the hip[1].

Hip Joint Arthroplasty constitutes a major advancement in the treatment of diverse pathological conditions of the hip such as primary arthritis, secondary osteoarthritis, and neck of femur fracture[1,2]. Since 1960 after the first total hip replacement, advancements in surgical techniques and instrumentation have greatly improved the outcome of total hip replacement[1]. Total hip replacement is entirely biomechanical compared to other procedures that include hip fusion, proximal femoral osteotomy and excision arthroplasty[1].

While performing total hip arthroplasty, the diseased cartilage and bone is excised. The joint is implanted with metallic prosthetic components. The option of cementing or not cementing the component depends on the quality of bone on the femoral and acetabulum side. Two articulating surfaces of the femoral and acetabulum component makes up the bearing surface and the most commonly used bearing surface is metal head on a highly cross-linked polyethylene liner[1,2]. Common complications of total hip arthroplasty include intra-operative fractures, dislocation, excessive blood loss, deep vein thrombosis, pulmonary embolism, component loosening and peri-prosthetic joint infection[1,2,15,26,33].

The success of total hip arthroplasty is dependent on several factors but surgical exposure of the hip is an important factor in performing functionally successful total hip arthroplasty[3]. Common approaches used by orthopaedic surgeons include the direct anterior (Smith-Peterson), anterolateral (Watson-Jones), posterior, lateral (Modified Hardinge) and the direct anterior approach[3, 4]. The lateral or posterior surgical approach is more commonly used in total hip arthroplasty. The posterior surgical approach is considered easier and has less surgical trauma to soft tissue but the exposure of the acetabulum is more difficult compared to the lateral approach which provide good exposure at a cost of injury to the hip abductor muscles[4,5].

The posterior surgical approach was initially reported with a dislocation rate of 4.5 %. This rate is higher than the dislocation rate reported for an anterior or lateral approach which is 0.5–2 %[5]. However, recent arthroplasty literature has shown that dislocation rates are reduced to 0.5 % after repairing the posterior capsule, as well as the soft tissue. Currently the dislocation rates are similar when using a posterior or a lateral approach [5, 6].

Another systemic review in 2006 by Jolles et al and a meta-analysis by the same author concluded that there are no significant differences in dislocation rates, postoperative pain, Trendelenburg gait and functional outcome when comparing the posterior surgical approach with the lateral surgical approach to the hip for total hip arthroplasty. However, the lateral approach was associated with lower rates of sciatic nerve damage [4,7]. Jolles et al in their meta-analysis also concluded that neither surgical approach is superior over the other and a multicentre randomized controlled trial will provide a good level of evidence regarding the superiority of one surgical approach over the other[4].

Lindgren et al in 2012 conducted a comparative study and reviewed 90,662 hip replacements. They reported a higher dislocation rate with the posterior approach[5].

Belen et al in 2016 looked at the amount of muscle damage and its impact on functional outcome postoperatively. The authors reported no differences in functional outcome between the direct anterior approach and the direct lateral approaches at long term follow up. However, there were higher levels of inflammatory markers in patients grouped with the direct lateral group as compared to those in the direct anterior group [8]. A prospective randomized trial by Mjaaland et al in 2015 compared the level of inflammatory markers, the intensity of pain and the consumption of pain medication in two types of surgical approaches. They found that the level of inflammatory markers were high in the direct anterior group, the intensity of postoperative pain, as well as use of pain medication, was less compared to the direct lateral group[9].

Restrepo et al in a prospective randomized trial in 2010 reported that the direct anterior surgical approach can be performed with a smaller incision, minimal soft tissue damage and less blood loss. It allows for a shorter rehabilitation time[10]. Parvizi et al in a comparative study in 2011 reported similar results and concluded that the direct anterior approach (DAA) was an independent predictor of less peri-operative blood loss and thus there was less need for allogeneic blood transfusions[11].

In contrast, randomized controlled trials and comparative studies found no significant differences with regards to nerve damage, functional outcome and gait pattern at one year when comparing hip replacement done using the DAA versus the lateral approach· Early postoperative function was better and patients had shorter hospitalization when

total hip arthroplasty was done using the direct anterior approach. Rehabilitation time was also shorter in these patients [10,12,13].

With advancements in surgical instrumentation, the surgical technique has been improving over time and now minimally invasive approaches, such as the direct anterior surgical approach, are being used to perform total hip arthroplasty[14]. Minimally invasive surgical approaches offer several potential benefits. These benefits include reduced blood loss and pain, less soft tissue damage, and a shorter hospital stay, as well as faster rehabilitation [13,15].

The direct anterior approach is a true inter-nervous & inter-muscular approach to the hip and was first described by German surgeons in 1881. Later on, the same surgical approach was published by Smith-Peterson in 1940 and by Hueter in 1950[2,13,15,17]. Recently, the direct anterior approach has been named the Hueter anterior approach to the hip in the literature[16,18.] The anatomy of the hip anteriorly technically allows this muscle-sparing approach to go through muscle intervals for exposure of hip joint (Figure 3a and 3b). The patient lies supine on a table and an incision 2 cm lateral from the anterior superior iliac spine is made which extends 8 to 12 cm vertically downward (Figure 1 and 2). After the fascia incision, the muscle interval between the Sartorius muscle medially and the tensor fascia lata muscle laterally is identified while protecting lateral femoral cutaneous nerve medially. The anterior hip capsule is identified and incised to allow for exposure of the hip joint after retracting the rectus femoris laterally. Some surgeons prefer to retract the rectus femoris medially to expose the hip joint[17].

Light and Keggi (2004) published the first study on the use of the Direct Anterior Approach for Total Hip Arthroplasty in a series of 104 procedures that required little or

no muscle dissection[16]. There is an increase in the interest among surgeons of learning the DAA as this technique preserves soft tissue and has a lower dislocation risk [18, 19].

Elective Total Hip Arthroplasty in patients with a body mass index (BMI) of more than 40 is not recommended by the "American Association of Hip and Knee Surgeons Evidence-based Committee" and this is also applicable for Total Hip Arthroplasty done through the DAA. With any hip pathology which needs extensive surgical exposure, the use of another approach may be a better option [19].

A special positioning traction table is used to facilitate the exposure of the femur adequately but many surgeons use a standard table for total hip arthroplasty when using a DAA [17,19, 20].

Rehabilitation time is short as there is minimal soft tissue trauma and less pain. Taunton et al in a randomized trial in 2014 compared the direct anterior and mini-posterior surgical approaches. Patient recovery was faster after the DAA compared to the mini-posterior approach. The time to ambulation without an assistive device was six days shorter in DAA than in the mini-posterior approach[14]. Recovery after surgery is fast when compared to other surgical approaches in the first six weeks, but no difference was found after a six week to three month follow up. Complications have also been reported such as lateral femoral cutaneous nerve injury, haematoma formation, wound complication, component malposition & loosening, intra-operative fractures and anterior dislocation when using the direct anterior approach [2, 14,15, 16, 18, 19, 20].

2. Problem statement

Total joint arthroplasty has revolutionized the treatment of end-stage joint arthritis. Total hip arthroplasty is among the most successful procedures in Orthopaedic Surgery done for various end-stage painful hip conditions.

The functional outcome of the procedure depends on various important factors such as the type of pathology, the level of pre-operative mobility, patient co-morbidities, experience of surgeon, surgical approach, accurate implantation of prosthesis and post-operative rehabilitation.

Surgical approach is an important factor in the final outcome of total hip arthroplasty. There are various surgical approaches which are used by surgeons each having merits and demerits. Common surgical approaches to the hip are anterolateral, lateral, posterior and a direct anterior surgical approach.

A lateral surgical approach to the hip violates abductor muscles while a posterior surgical approach was initially reported to have a high dislocation rate although the current literature has reported a similar outcome in terms of dislocation if posterior structures are repaired when the posterior surgical approach is used.

The direct anterior approach is gaining popularity because of its inter-nervous and inter-muscular nature. Abductor muscles are preserved and there is no violation of the posterior hip structure as happens when using the posterior surgical approach.

The direct anterior approach also offers faster recovery and shorter hospital stay because of faster rehabilitation in patients but the learning curve is an important factor for any surgeon when learning a surgical approach to achieve good outcome.

The aim of this study was to evaluate intra-operative and early post-operative outcomes of total hip arthroplasty done through the direct anterior approach at one of our local state hospitals affiliated with the University of the Witwatersrand.

3. Aims & Objectives

The aim of the study was to evaluate intra-operative complications, early post-operative complications and time to mobilization in Total Hip Arthroplasty done via the Direct Anterior Approach and thus determine the length of hospital stay.

The objectives of this study were to document intra-operative complications, early postoperative complications, time to mobilization and length of hospital stay.

4. Materials and Methods

A retrospective review of medical records of patients who underwent total hip replacement through the direct anterior approach at Helen Joseph Hospital (HJH) from January 2013 to June 2015 was undertaken. Helen Joseph hospital is a teaching hospital for the University of the Witwatersrand, Johannesburg and on average 45 total hip replacements are done on a yearly basis through different surgical approaches mainly lateral, posterior and direct anterior surgical approaches.

All cases were done by a single surgeon who had surgical training on the direct anterior approach before he started operating through this approach for total hip arthroplasty. Thirty patients were identified and 21 patients met the inclusion criteria (Table 1). Seven patients did not meet the inclusion criteria as their clinical records were incomplete.

Intraoperative blood loss was recorded on the anaesthesia charts as assessed by counting surgical swabs and suction drain collection in theatre while post-operative blood loss was assessed through postoperative drain collection. Intraoperative femoral fractures were checked after femoral broaching, trialling and implantation of the femoral stem. Similarly, intraoperative acetabulum fractures were checked after reaming, trialling and implantation of the acetabulum cup. The lateral femoral cutaneous nerve was assessed on day 1 postoperative by the orthopaedic registrar by testing for sensation on the lateral aspect of the thigh. Postoperative dislocation was assessed clinically as well as

radiologically by obtaining post-operative radiographs. Time to mobilization was calculated from day one postoperatively until patients were fully mobilized according to the physiotherapy protocol shown in Table 2. Patients were assessed clinically for any signs and symptoms of symptomatic deep vein thrombosis. The duration of the surgical procedure was noted on the consent form by the assistant nurse. All patients in the ward underwent wound inspection under sterile conditions to determine if there was any sign of superficial or deep wound sepsis on the day of discharge from hospital. Another sterile dressing was applied after wound inspection before discharge.

Table 1: Patient selection criteria for the study.

Inclusion Criteria
• All Primary THA done for traumatic & non-traumatic conditions of hips via direct anterior approach
Exclusion Criteria
• Patients with multiple co-morbidities who are not fit for anaesthesia & surgery • Inadequate hospital records • Patients with neuromuscular and neurocognitive disorders

5. Surgical Technique

The patient is positioned in a supine position on a special orthopaedic traction table. This position allows for adduction and hyperextension of the extremity that will be operated on (Fig 1). A skin incision is made approximately 2 cm lateral and inferior from the anterior superior iliac spine and extends 8 to 12 cm vertically downwards (Fig 2). After the incision of deep fascia, the muscle interval between the tensor fascia lata muscle laterally and the Sartorius muscle medially is identified. A tissue retractor is placed into the muscle interval. The ascending branch of the lateral femoral circumflex artery is identified and ligated.



Figure 1: A patient placed supine on a table with traction on the right limb.



Figure 2: Skin incision has been marked on the left hip after the patient has been placed on a traction table. The greater trochanter and superior anterior iliac spine have also been marked.

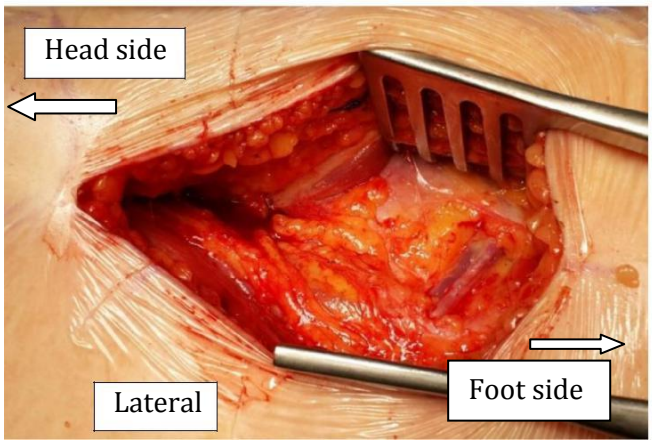

Figure 3a

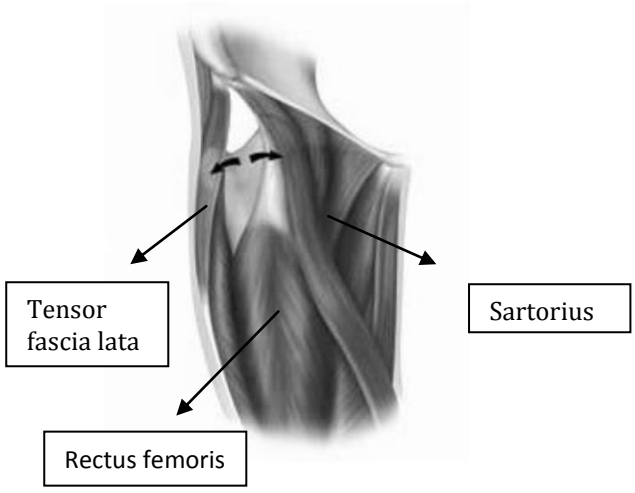

Figure 3b

Figure 3a & 3b: Deep dissection after skin incision on the right hip. Sartorius muscle has been retracted medially and tensor fascia lata muscle laterally with a retractor.

Next, the muscle interval between the gluteus medius muscle laterally and the rectus femoris muscle medially is identified. The anterior hip capsule is identified, incised and retracted. The femoral neck is resected using preoperative templates after the femoral head is dislocated. The acetabulum is reamed and a trial component implantation is performed with direct visualization. While doing the femoral preparation, the operated extremity is externally rotated, extended, and adducted to allow axial access to the proximal femur. Capsular release, as well as releases around the greater trochanter, is performed to expose the proximal femur.

The placement of the femoral implant trial is done and is followed by trial reduction. The final leg length is evaluated by comparing it with the other side using an electrocautery cable. The final femoral implants are inserted. The wound is washed and a drain is left inside. The wound is closed in layers and sterile dressing is applied.

Table 2: Standard Physiotherapy protocol at HJH after total hip arthroplasty.

Day 1 Postoperative	Isometric gluteus squeeze & heel slide Sit over edge of bed keeping hip flexion less than 90˚ Mobilize to chair & sit with affected side knee straight & hip in flexion less than 90˚ Keep abduction pillow between legs in sitting Standing with walking frame & balance
Day 2-7 Postoperative	Standing, toe raises and slow marching Progress to crutches if able to do that Increase walking distance each day Encourage independent transfers & activity of daily living

6. Results

A total of 30 patients were included in the study however, only 21 patients met the inclusion criteria. Nine patients did not meet inclusion criteria due to inadequate hospital records. Of the 21 patients included, 11 were male and 10 were female with age ranging from 50 to 80 years. Three types of hip pathology (Fig-5) were found among the patients who were receiving total hip arthroplasty using the direct anterior approach. The average time of surgery was 145 minutes (range 90 to 210 minutes) and the average total blood loss was 440ml (range 100ml to 220ml), which included intraoperative and postoperative blood loss. There were no patients with intraoperative fractures in this series. The bearing surface used was a metal head and highly cross-linked high polyethylene liner in a metal acetabular cup in all cases. The results are shown in Figures 4-8 and Table 3.

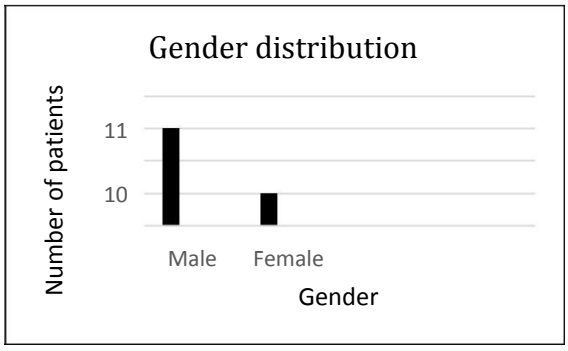

Figure 4: Gender distribution in the Study

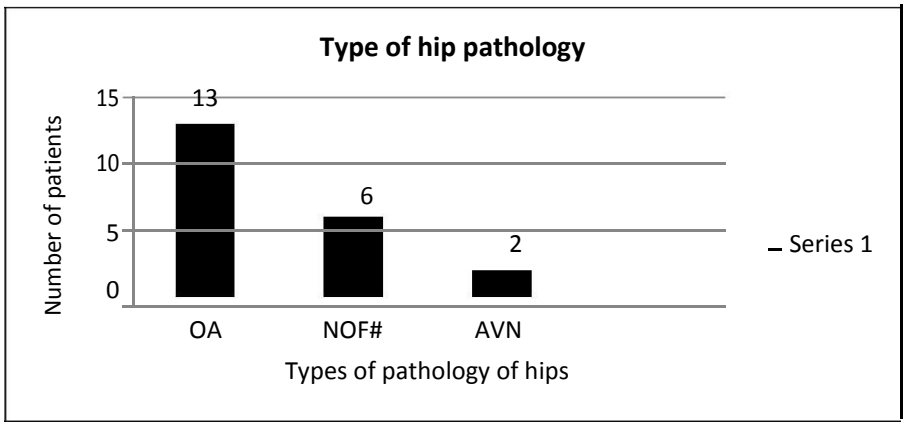

Abbreviations

OA: Osteoarthritis

NOF: Neck of femur fracture

AVN: Avascular necrosis

Figure 5: Types of hip pathology included in the Study

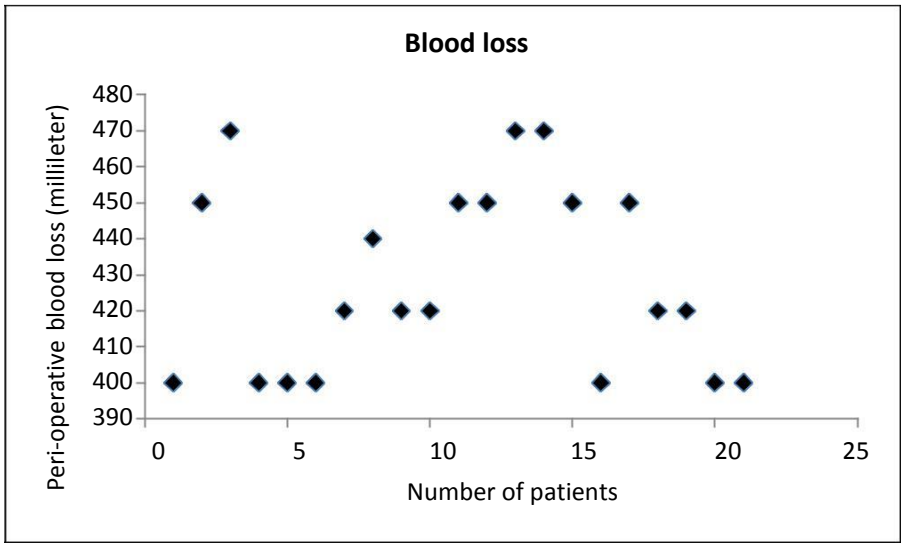

Figure 6: Peri-operative blood loss in all patients

Table 3: Summary of results

Hip Dislocation	Nil
Fracture around ankle joint	Nil
Average blood loss	440ml
Average time of surgery	145min
Intra-operative fractures	Nil
Injury to LFC nerve	Nil
Bearing surface	Metal on HMWPE
Superficial & deep wound sepsis	Nil
Postoperative dislocation	Nil
Postoperative DVT	Nil
Average post-operative hospital stay	6.14 days
Average length of hospital stay	10.28 days

There was no case of post-operative dislocation as assessed clinically as well as radiologically. No case of superficial or deep wound sepsis was reported. There was no case of symptomatic deep vein thrombosis & pulmonary embolism. None of the patients developed complications from the traction table like fracture around the ankle. The lateral femoral cutaneous nerve was intact in all patients on day one postoperative.

The average time to mobilization was 6.14 days (range 3-13 days) as all patients were subjected to the standard protocol of mobilization post total hip replacement as illustrated in Table 2.

The average length of stay was 10.28 days ranging from 5 to 27 days. The longest stay was 27 days for a patient who presented with a neck of femur fracture together with three co-morbidities.

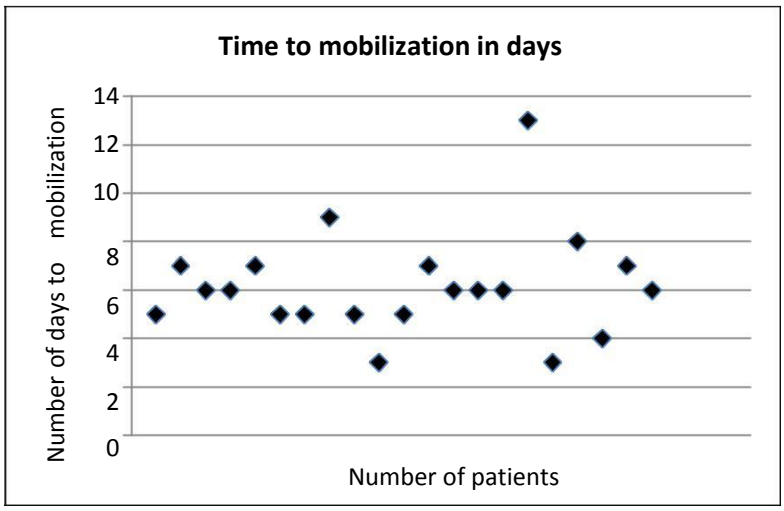

Figure 7: Time to mobilization in days

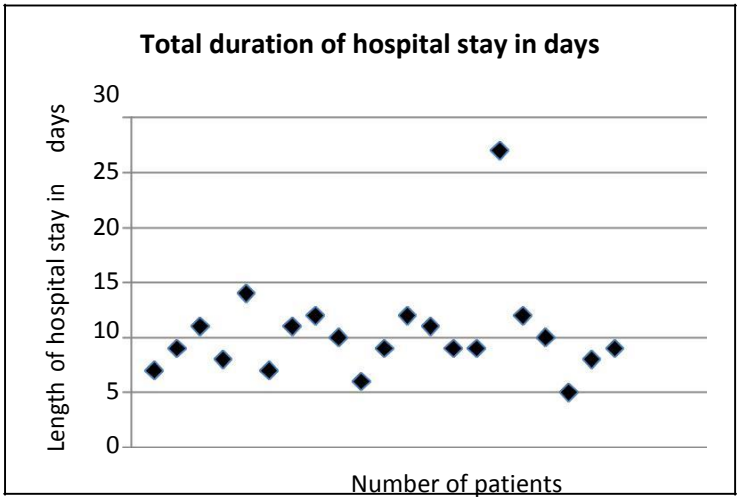

Figure 8: Total hospital stay in days

7. Discussion

With the advancements in instrumentation, new surgical techniques have been developed which is associated with complications. These complications include neurovascular injury, intraoperative fractures and component malposition[21,22]. It is compulsory to have information regarding the risk and predisposing factors for various complications which increases the risk of complications. This study is a retrospective analysis of consecutive, non-selected primary unilateral total hip arthroplasties. Minimal injury to the soft tissue, maintenance of normal abductor muscle function, as well as stability of the hip, are rationale behind the use of this surgical approach to perform total hip arthroplasty [21,22,23,24]. The surgical approach is inter-nervous and does not require release of any muscles or tendons. There is minimal evidence in the orthopaedic literature for an increased complication rate when using direct anterior surgical approach compared to the lateral approach [15,16,18,19].

The overall complication rate was zero percent in the twenty-one cases included in this study. The average blood loss, including intraoperative and postoperative, was 440ml. None of the patients required a blood transfusion. Hallert et al (2012) reported an average blood loss of 496ml in a retrospective study of 200 hip cases done through the direct anterior approach. Alecci et al (2011) in their study compared the direct anterior approach with the standard lateral approach and reported a blood loss of 450ml with the direct anterior approach versus 655ml with the standard lateral approach. A

possible reason for no blood transfusion in the current series may be due to the small size of the patient population [12,25].

The average time for this procedure (DAA) in the current series was 145min (range 80-180min) which is longer than reported in the literature. Kreuzer et al (2011) reported an average operative time of 105.7min in their study on 57 hips which is far shorter than reported in this study. Alecci et al (2011) reported an average operative time of 81±15min and similarly Hallert et al (2012) reported an average operative time of 114min in their study of 200 hips done through the direct anterior approach. In this study, the longer operative time might be due to a learning curve in a new approach to total hip arthroplasty[12,25,26].

Perforation of the femoral canal, greater trochanteric and calcar fractures have been well described in the literature[27,28,29]. Also, the use of the special traction table for the direct anterior approach is associated with ankle fractures[27]. No intra-operative fractures or fractures around the ankle due to the traction table were reported in this study. However, up to 10% risk of intra-operative fracture has been reported in the literature when a direct anterior approach was used. The reason for no fractures may be due to the small sample size used in this study.

A dislocation rate of 0.96% to 1.5% has been reported with DAA[28,30]. In this study, there was no dislocation reported postoperatively. The small population size of the study may also be the reason for the 0% dislocation rate reported in this study.



(a)



(b)

Figure 9: Pre-operative x-rays of a 63 year old female patient (Figure 9-a) with avascular necrosis of the femoral head of the right hip and post-operative x-rays (Figure 9-b) after total hip replacement done through the direct anterior approach.

There were no patients with lateral femoral cutaneous nerve injury in this study. Goulding et al (2010) reported a 1% to 67% incidence of LFCN injuries in their study when a direct anterior approach to the hip was used. The large variation may result from differences in interrogation of patients postoperatively. Most paresthesia largely resolves and few patients have reported functional limitation[31].

Local wound complication has been described given the moist nature of the groin area but this complication typically resolves with wound care alone. There were no cases of local wound complications in this study.

Postoperative mobilization is important in determining the length of hospital stay in total hip arthroplasty. The major advantage of the direct anterior surgical approach is a

faster recovery and many studies support this outcome[13,14,18,19,20]. In this study, the average postoperative mobilization time was 6.14 days (range 3-13 days). The reason for this prolonged duration as compared to those quoted in the literature is the unavailability of physiotherapists over the weekend and the general shortage of physiotherapists in our hospital. Rodriguez et al (2014) reported 3.05 days of postoperative mobilization in their study and found no difference comparing the direct anterior approach with the posterior approach. The average hospital stay in this study was 10.28 days which is longer compared with other studies. One patient who was admitted with a neck of femur fracture stayed more than 27 days due to multiple medical co-morbidities. Poehling-Monaghan et al (2015) in their comparative study reported no difference in length of hospital stay between the direct anterior and posterior approach[32]. In their study, the mean hospital stay of patients was 2.2 days and ranged from 1-9 days which is shorter compared to the patients included in this study.

The limitations of this study include the retrospective nature of the study and the small sample size because of the small number of Total Hip Arthroplasties done through the direct anterior approach at Helen Joseph Hospital as well as inadequate records of seven patients who were excluded from the study. However, all patients were operated on by a single surgeon. The learning curve is another factor to consider when analyzing the results of this study.

8. Conclusion

In conclusion, the results are good in terms of intra-operative and early complications of total hip arthroplasty done through the direct anterior approach, taking the learning curve as a major predictor of outcome when using a minimally invasive direct anterior approach to the hip.

9. Appendices

Appendix A: Postgraduate Approval letter

UNIVERSITY OF THE
WITWATERSRAND,
JOHANNESBURG

Private Bag 3 Wits, 2050
Fax: 027117172119
Tel: 02711 7172076

Reference: Ms Thokozile Nhlapo
E-mail: thokozile.nhlapo@wits.ac.za

17 March 2015
Person No: 712735
PAG

Dr MN Iqbal
22 Parklane Village
1 Parklane Road
2193
South Africa

Dear Dr Iqbal

Master of Medicine: Approval of Title

We have pleasure in advising that your proposal entitled *A retrospective study of Total Hip Arthroplasty done through direct anterior approach* has been approved. Please note that any amendments to this title have to be endorsed by the Faculty's higher degrees committee and formally approved.

Yours sincerely

Mrs Sandra Benn
Faculty Registrar
Faculty of Health Sciences

Appendix B: Ethics Clearance Letter

R14/49 Dr Mohammad Nasr Iqbal

HUMAN RESEARCH ETHICS COMMITTEE (MEDICAL)

CLEARANCE CERTIFICATE NO. M150310

NAME: (Principal Investigator)	Dr Mohammad Nasr Iqbal
DEPARTMENT:	Orthopaedic Surgery Helen Joseph Hospital
PROJECT TITLE:	A Retrospective Study of Total Hip Arthroplasty Done Through Direct Anterior Approach
DATE CONSIDERED:	27/03/2015
DECISION:	Approved unconditionally
CONDITIONS:	
SUPERVISOR:	Dr P Kana
APPROVED BY:	Professor P Cleaton-Jones, Chairperson, HREC (Medical)
DATE OF APPROVAL:	11/11/2015

This clearance certificate is valid for 5 years from date of approval. Extension may be applied for.

DECLARATION OF INVESTIGATORS

To be completed in duplicate and **ONE COPY** returned to the Secretary in Room 10004, 10th floor, Senate House, University.
I/we fully understand the conditions under which I am/we are authorized to carry out the above-mentioned research and I/we undertake to ensure compliance with these conditions. Should any departure be contemplated, from the research protocol as approved, I/we undertake to resubmit the application to the Committee. **I agree to submit a yearly progress report**.

Principal Investigator Signature _____ Date _____

PLEASE QUOTE THE PROTOCOL NUMBER IN ALL ENQUIRIES

Appendix C: Data Collection Sheet and Link Sheet

A Retrospective study of total hip arthroplasty done through direct anterior approach

DATA LINK SHEET (MMed Project/M150310)

Study code:

Hospital number: Diagnosis:

Forename: Surname:

Implant & type of bearing surfaces:

Co-morbidities:

Duration of operation: Intra-op blood loss:

Intra-operative fracture:

Lateral cutaneous nerve injury (sensations post op):

Post-operative blood loss (drain):

Wound complications:

Mobilization:

Day 1:

Day2:

Day3:

Day4:

Post Op measurements:

Cup inclination:

Femoral stem (varus/vagus):

A Retrospective study of total hip arthroplasty done through direct anterior approach

DATA COLLECTION SHEET (MMed Project/M150310)

Study code:

Diagnosis:

Date of admission: Date of operation:

Date of discharge:

Implant & type of bearing surfaces:

Co-morbidities:

Duration of operation: Intra-op blood loss:

Intra-operative fracture:

Lateral cutaneous nerve injury (sensations post op):

Post-operative blood loss (drain):

Wound complications:

Mobilization:

Day 1:

Day2:

Day3:

Day4:

Appendix D: Hospital Permission Letter

GAUTENG PROVINCE
REPUBLIC OF SOUTH AFRICA

Helen Joseph Hospital
Enquiries: Dr. M.R. Billa
Chief Executive Officer
Tel: (011) 489-0306/1087
Fax: (011)726-5425
Email:Raymond.Billa@gauteng.gov.za

PERMISSION TO CONDUCT RESEARCH AT HELEN JOSEPH HOSPITAL			
PRINCIPAL RESEARCHER: Dr MN Iqbal			
FULL NAME: Mohammad Nasir Iqbal			
DESIGNATION: Registrar			
CONTACT NUMBER: 076 551 1833			
E-MAIL ADDRESS: drburkhia@yahoo.com			
DEPARTMENT: Orthopaedics			
HEAD/S OF DEPARTMENT/S: Prof Ramogopa			
TITLE OF RESEARCH: A retrospective study of total hip arthroplasty using direct anterior approach			
OBJECTIVES OF RESEARCH:			
(1) To find out number of intraoperative and early post-operative complications in THR done through direct anterior approach.			
(2) To find out time to mobilization and length of hospital stay			
STUDY SITE/S Helen Joseph Hospital			
BRIEF OUTLINE OF METHODOLOGY It is retrospective study of patient done THR through direct anterior approach from 01/01/2012 to 30/06/2014 involving evaluation of inpatient and outpatient records.			
EXPECTED START DATE Soon after ethics approval		**EXPECTED DURATION 1year**	
ETHICS CLEARANCE	YES	NO	PENDING √
CONFLICTS OF INTEREST	YES	NOV	DETAILS:
COSTS TO HOSPITAL AND/OR OTHERS	YES	NOV	
SOURCE OF FUNDING self funded			
SIGNATURE OF RESEARCHER & DATE			
PERMISSION GRANTED	YES √	NO	
J. R. Kirby	G.D. KIRBY MB, BCh MP 199753	Clinical Manager	12 SEP 2014 17/09/2014
SIGNATURE (CLINICAL MANAGER /CEO)	**NAME IN PRINT & DESIGNATION**		**OFFICIAL STAMP & DATE**

Appendix E: Data Collection (Recorded)

Data collection of all 21 patients included in study

Study code	Date of admission	Date of operation	Date of discharge	Bearing surface	Co-morbidities	Duration of surgery	Intra-operative blood loss
M00020	13/05/2013	14/05/2013	19/05/2013	M/P	nil	1240-1500	100ml
M00021	24/02/2014	25/02/2014	03/03/2014	M/P	nil	0815-1030	120ml
M00022	11/05/2015	15/05/2015	21/05/2015	M/P	HTN	0800-1030	110ml
M00023	26/05/2015	27/05/2015	03/06/2015	M/P	HTN	1120-1530	100ml
M00024	07/06/2014	12/06/2014	20/06/2014	M/P		0815-1135	100ml
M00025	28/01/2014	29/01/2014	04/02/2014	M/P	HTN, Hypothyroidism	0810-1105	100ml
M00026	06/02/2014	11/02/2014	16/02/2014	M/P		0850-1030	120ml
M00027	19/10/2013	22/10/2013	31/10/2013	M/P	HTN,Gout	1145-1445	120ml
M00028	11/11/2013	15/11/2013	20/11/2013	M/P	HTN	0815-1010	100ml
M00029	08/12/2013	10/12/2013	13/12/2013	M/P	HTN,COPD	0840-1100	100ml
M00030	14/05/2013	17/05/2013	22/05/2013	M/P	HTN	0825-1105	130ml
M00031	08/11/2013	12/11/2013	19/11/2013	M/P	HTN	1025-1235	100ml
M00032	10/10/2013	15/10/2013	21/10/2013	M/P	HTN	0830-1030	120ml
M00033	11/08/2013	13/08/2013	19/08/2013	M/P	HTN	1400-1635	150ml
M00034	27/07/2013	30/07/2013	05/08/2013	M/P	Dyslipidemia	1230-1430	150ml
M00035	26/12/2012	08/01/2013	21/01/2013	M/P	HTN, DM, Asthma	0830-1200	200ml
M00036	02/09/2013	10/09/2013	13/09/2013	M/P	HTN	1320-1525	150ml
M00037	18/11/2013	19/11/2013	27/11/2013	M/P	HTN	0805-1005	100ml
M00038	31/08/2013	30/09/2013	04/09/2013	M/P	IHD	0800-1005	120ml
M00039	27/10/2013	29/10/2013	05/11/2013	M/P	HTN	1105-1330	220ml
M00040	28/04/2013	30/04/2013	06/05/2013	M/P	HTN	0800-1030	200ml

Abbreviations = M/P, Metal on highly cross-linked polyethylene
NOF#, Neck of femur fracture
AVN, Avascular necrosis
OA, Osteoarthritis
HTN, Hypertension
IHD, Ischemic heart disease
DM, Diabetes Mellitus

Data collection of all 21 patients included in study

Study code	Intra-operative fracture	Post-operative blood loss	lateral cutaneous nerve injury	Mobilization	wound complication	Diagnosis	Length of hospital stay in days
M00020	nil	100ml	nil	day-5	nil	OA Lt	7
M00021	nil	150ml	nil	day-7	nil	OA Rt	9
M00022	nil	160ml	nil	day-6	nil	NOF#	11
M00023	nil	100ml	nil	day-6	nil	OA Rt	8
M00024	nil	100ml	nil	day-7	nil	NOF#	14
M00025	nil	100ml	nil	day-5	nil	OA Rt	7
M00026	nil	100ml	nil	day-5	nil	AVN Rt	11
M00027	nil	120ml	nil	day-9	nil	OA Rt	12
M00028	nil	120ml	nil	day-5	nil	OA Rt	10
M00029	nil	120ml	nil	day-3	nil	NOF#	6
M00030	nil	120ml	nil	day-5	nil	NOF#	9
M00031	nil	150ml	nil	day-7	nil	OA Rt	12
M00032	nil	150ml	nil	day-6	nil	OA Rt	11
M00033	nil	120ml	nil	day-6	nil	OA Rt	9
M00034	nil	100ml	nil	day-6	nil	OA Lt	9
M00035	nil	100ml	nil	day-13	nil	NOF#	27
M00036	nil	100ml	nil	day-3	nil	OA Lt	12
M00037	nil	120ml	nil	day-8	nil	AVN Lt	10
M00038	nil	100ml	nil	day-4	nil	NOF#	5
M00039	nil	200ml	nil	day-7	nil	OA Rt	8
M00040	nil	250ml	nil	day-6	nil	OA Lt	9

Abbreviations = M/P, Metal on highly cross-linked polyethylene
NOF#, Neck of femur fracture
AVN, Avascular necrosis
OA, Osteoarthritis
HTN, Hypertension
IHD, Ischemic heart disease
DM, Diabetes Mellitus

10. References

(1) Harris WH, Sledge CB. **Total hip and total knee replacement (1).** N Engl J Med. 1990 Sep 13; 323(11):725-31.

(2) Mark BC, Robert DB, Declan RN, Duane M. **Total Hip Arthroplasties: A Study of Postoperative Course and Early Complications**. J Bone Joint Surg Am, 1974 Mar; 56(2):273-284.

(3) Anthony MD, Anton YP, Timothy JL, Branislav J**. Mini-Incision Technique for Total Hip Arthroplasty with Navigation.** J Arthroplasty, 2003 Feb; 18(2):123-128.

(4) Jolles BM, Bogoch ER. **Surgical approach for total hip arthroplasty: direct lateral or posterior?** J Rheumatology, 2004 Sep; 31(9):1790–1796.

(5) Lindgren V, Garellick G, Kärrholm J, Wretenberg P. **The type of surgical approach influences the risk of revision in total hip arthroplasty**. Acta Orthop, 2012 Dec; 83(6):559–565.

(6) Kwon MS, Kuskowski M, Mulhall KJ, Macaulay W, Brown TE, Saleh KJ. **Does surgical approach affect total hip arthroplasty dislocation rates**? Clin Orthop Relat Res, 2006 Jun; 447:34–38.

(7) Jolles BM, Bogoch ER. **Posterior versus lateral surgical approach for total hip arthroplasty in adults with osteoarthritis**. Cochrane Database Syst Rev, 2006.

(8) Mjaaland KE, Kivle K, Svenningsen S, Pripp AH, Nordsletten L. **Comparison of Marker for Muscle Damage, inflammation and Pain Using Minimally Invasive Direct Anterior Versus Direct Lateral Approach in Total Hip Arthroplasty**: **A Prospective, Randomized Controlled Trial**: J Orthop Res. 2015 May; 33:1305-1310.

(9) Belén DA, Juan SG, Alejandro LU, Eliana B, Fernando AL. **No differences between direct anterior and lateral approach for primary total hip arthroplasty related to muscle damage or functional outcome:** Int orthop. 2016 Jan; 10:1-6.

(10) Restrepo C, Parvizi J, Pour AE, Hozack WJ. **Prospective randomized study of two surgical approaches for total hip arthroplas**ty. J Arthroplasty, 2010 Aug; 25(5):671-9.

(11) Javad P, Mohammad RR, Mehrad J, Guillaume C, Scott V, Peter FS, William JH. **Does the surgical approach in one stage bilateral total hip arthroplasty affect blood loss?** Int Orthop, 2013 Dec; 37(12):2357-2362.

(12) Alecci V, Valente M, Crucil M, Minerva M, Pellegrino CM, Sabbadini DD. **Comparison of primary total hip replacements performed with a direct anterior approach versus the standard lateral approach: perioperative findings**. J Orthop Traumatol, 2011 Sep; 12(3):123–129.

(13) Müller M, Schwachmeyer V, Tohtz S, Duda GN, Perka C, Heller MO. **The direct lateral approach: Impact on gait patterns, foot progression angle and pain in comparison with a minimally invasive anterolateral approach**. Arch Orthop Trauma Surg, 2012 May; 132(5):725–731.

(14) Michael JT, Bohannon M, Susan MO, Bryan DS**. Direct Anterior Total Hip Arthroplasty Yields More Rapid Voluntary Cessation of All Walking Aids: A Prospective, Randomized Clinical Trial.** J Arthroplasty, 2014 Sep; 29(9 Suppl):169-72.

(15) Thomas DG, Pieter V, Geert DL. **Direct anterior total hip arthroplasty complications and early outcome in a series of 300 cases.** Acta Orthop Belg, 2013 Apr; 79(2):166-173.

(16) Kennon R, Keggi J, Zatorski LE, Keggi KJ. **Anterior approach for total hip Arthroplasty: Beyond the minimally invasive technique**. J Bone Joint Surg Am, 2004 Dec; 86(suppl 2): 91–97.

(17) Petis S, Howard JL, Lanting BL, Vasarhelyi EM. **Surgical approach in primary total hip arthroplasty: anatomy, technique and clinical outcome**: Can J surg. 2015 Apr; 58(2):128-139.

.

(18) Benoit B, Gofton W, Beaule PE. **Hueter anterior approach for hip resurfacing: assessment of the learning curve.** Orthop Clin North Am, 2009 Jul; 40(3)**:**357-363.

(19) Post ZD, Orozco F, Diaz-Ledezma, Hozack WJ, Ong A. **Direct Anterior Approach for Total Hip Arthroplasty: Indications, Technique, and Results**. J Am Acad Orthop Surg, 2014 Sep; 22(9):595-603.

(20) Rodriguez JA, Deshmukh AJ, Rathod PA, Greiz ML, Deshmane PP, Hepinstall MS, Ranawat AS.**Does the Direct Anterior Approach in THA Offer Faster Rehabilitation and Comparable Safety to the Posterior Approach**? Clin Orthop Relat Res, 2014 Feb; 472(2):455–463.

(21) Bremer AK, Kalberger F, Pfirrman CWA, Dora C. **Soft-tissue changes in abductor muscles and tendons after total hip replacement**. J Bone Joint Surg Br, 2011 Jul; 93(7):886–889.

(22) Mayr E, Nogler M, Benedetti MG, Kessler O, Reinthaler A, Krismer M, Leardini A. **A prospective randomized assessment of earlier functional recovery in THA patients treated by minimally invasive direct anterior approach: a gait analysis study**. Clin Biomech, 2009 Dec; 24(10):812–818.

(23) Masonis J, Thompson C, Odum S: **Safe and accurate: learning the direct anterior total hip arthroplasty.** Orthopaedics, 2008 Dec; 31(12 suppl 2):129-135.

(24) Nakata K, Nishikawa M, Yamamoto, K Hirota S, Yoshikawa H. **A clinical comparative study of the direct anterior with mini-posterior approach: two consecutive series**. J Arthroplasty, 2009 Aug; 24(5):698-704.

(25) Hallert O, Li Y, Brismar H, Lindgren U. **The direct anterior approach: initial experience of a minimally invasive technique for total hip arthroplasty**. J Orthop Surg Res, 2012 Apr 25; 7:17-23.

(26) Kreuzer S, Leffers K, Kumar S. **Direct Anterior Approach for Hip Resurfacing: Surgical Technique and Complications.** Clin Orthop Relat Res, 2011 Jun; 469(6):1574-1581.

(27) Matta JM, Shahrdar C, Ferguson T. **Single incision anterior approach for total hip arthroplasty on an orthopaedic table**. Clin Orthop Relat Res, 2005 Dec; 441:115-124.

(28) Sariali E, Leonard P, Mamoudy P. **Dislocation after total hip arthroplasty using Hueter anterior approach**. J Arthroplasty, 2008 Feb; 23(2):266-72.

(29) Jewett BA, Collis DK: **High complication rate with anterior total hip arthroplasties on a fracture table**. Clin Orthop Relat Res, 2011 Feb; 469(2):503-507.

(30) Siguier T, Siguier M, Brumpt B: **Mini incision anterior approach does not increase dislocation rate: A study of 1037 total hip replacements**. Clin Orthop Relat Res, 2004 Sep; 426:164-173.

(31) Goulding K, Beaulé PE, Kim PR, Fazekas A**: Incidence of lateral femoral cutaneous nerve neuropraxia after anterior approach hip arthroplasty**. Clin Orthop Relat Res**,** 2010 Sep; 468(9):2397-2404.

(32) Poehling-Monaghan KL, Kamath AF, Taunton MJ, Pagnano MW. **Direct Anterior versus Miniposterior THA With the Same Advanced Perioperative Protocols: Surprising Early Clinical Results**. Clin Orthop Relat Res, 2015 Feb; 473(2):623–631.

(33) James T. N, John C. D, Stephen J. I. **What's New in Hip Replacement**: J Bone Joint Surg Am. 2015 Sep; 97(18):1543-1551.