

https://dspace.org/

Yield of percutaneous core needle biopsies in musculoskeletal tumours

Chuene, Mabua Arthur

2022

https://hdl.handle.net/10539/35404

Downloaded from a DSpace repository. https://dspace.org/

YIELD OF PERCUTANEOUS CORE NEEDLE BIOPSIES IN MUSCULOSKELETAL TUMOURS



UNIVERSITY OF THE
WITWATERSRAND,
JOHANNESBURG

Dr. Mabua Arthur Chuene

A research report submitted to the Faculty of Health Sciences, University of the Witwatersrand, Johannesburg, in partial fulfilment of the requirements for the degree of Master of Medicine in Orthopaedic Surgery.

Johannesburg, 2022

DECLARATION

I Mabua Arthur Chuene declare that this research report is my own, unaided work. It is being submitted for the Degree of Master of Medicine in the branch of Orthopaedic Surgery at the University of the Witwatersrand, Johannesburg. It has not been submitted before for any degree or examination at any other University.



(Signature of candidate)

08 day of August 2022 in Parktown

DEDICATION

This research report is wholeheartedly dedicated to my loving wife, Sekedi and my delightful son, Mabua. I will forever be grateful for your infinite support, encouragement and patience. To my beloved grandparents and parents, thank you for nurturing my aspirations. To my siblings, I reiterate, a strong work ethic is a master key.

ACKNOWLEDGEMENTS

Special thanks to my supervisors, Dr. Marule Paul Kgagudi and Dr. Maxwell Jingo for the continued motivation and support. Your kindness and inspiration are unmeasurable. Thank you very much for playing a vital role in shaping my future. I will forever remain indebted to you. I salute you!

Table of contents

List of figures v

List of tables vi

Nomenclature vii

Glossary viii

Abstract ix

Chapter 1: Introduction and background 1

Chapter 2: Research methodology

1. Aim and objectives 8
2. Research design 8
3. Research site 8
4. Study population 8
5. Sample size calculation 9
6. Data collection 9
7. PCNB technique at CHBAH 10
8. Compliance with ethical standards 11
9. Study strengths and limitations 12

Chapter 3: Results 13

Chapter 4: Discussion 28

Chapter 5: Conclusion and recommendations 35

References 36

Appendices

Appendix A: Data collection sheet 38

Appendix B: Ethics clearance certificate 39

Appendix C: Letter of approval for extension of data collection window 40

Appendix D: Letter of permission to conduct research, CEO CHBAH 41

Appendix E: Letter of permission to access theatre registry 42

Appendix F: Letter of permission to conduct research, Academic Head, Department of Orthopaedics, University of Witwatersrand 43

Appendix G: Letter of permission to access histopathological results, NHLS 45

LIST OF FIGURES

CHAPTER TWO

Figure 2.1: Jamshidi needle set 10

CHAPTER THREE

Figure 3.1: Clinical presentation 15

Figure 3.2: Type of lesion 15

Figure 3.3: Primary lesion in 49 patients based on clinical and radiological assessment 21

Figure 3.4: Nature of lesion in 40 patients with a diagnostic PCNB 21

Figure 3.5: Common PCNB for primary bone lesions 22

LIST OF TABLES

CHAPTER ONE

Table 1.1: Complications of open biopsy 2

Table 1.2: Principles of biopsy in musculoskeletal tumours 4

Table 1.3: Advantages and disadvantages of PCNB and open biopsy 6

CHAPTER THREE

Table 3.1: Gender and clinical outcomes of the study population 14

Table 3.2: Anatomical distribution of lesions 16

Table 3.3: Diagnostic nature and number of biopsies of the study population 17

Table 3.4: Histopathological diagnoses of diagnostic PCNB 18

Table 3.5: Non-diagnostic PCNB and alternate sampling methods 20

Table 3.6: Frequency of diagnosed tumours 23

Table 3.7: PCNB diagnosis compared to the final definitive diagnosis 25

Table 3.8: Sensitivity, Specificity, PPV and NPV 26

Table 3.9: Number of diagnostic and non-diagnostic PCNB according to lesion type for 48 bone tumours 26

NOMENCLATURE

AKA	Above Knee Amputation
CHBAH	Chris Hani Baragwanath Academic Hospital
COVID-19	Coronavirus Disease 2019
CT	Computed Tomography
FNA	Fine Needle Aspiration
HIV	Human Immunodeficiency Virus
LL	Lower Limb
LSS	Limb-Salvage Surgery
MRI	Magnetic Resonance Imaging
NICE	National Institute for Health and Clinical Excellence
NHLS	National Health Laboratory Service
PCNB	Percutaneous Core Needle Biopsy
UL	Upper Limb
US	Ultrasonography

GLOSSARY

En bloc	As a whole
Registrar	Medical practitioner undergoing Specialist training in a particular discipline of medicine

ABSTRACT

Background: A biopsy is a crucial step in the diagnosis of musculoskeletal tumours. Percutaneous core needle biopsy (PCNB) was developed as an alternative technique to open biopsy. The diagnostic yield and accuracy are comparable, with an added benefit of low complication rates.

Objectives: To determine the diagnostic yield of PCNB in musculoskeletal tumours and to determine the commonest tumour diagnosed at Chris Hani Baragwanath Academic Hospital (CHBAH). To document complications related to PCNB in our context.

Study methods: We retrospectively reviewed clinical records of 49 patients who underwent PCNB for a musculoskeletal tumour at CHBAH between January 2016 and January 2022. Histopathological findings were used to establish the diagnostic potential of PCNB. These findings were compared to a final resection specimen or an alternate tissue biopsy result when available. Procedure-related complications were documented when present. Statistical analysis of data was performed using STATA software package version 11 (StataCorp, College, Texas, United States of America, July 2009).

Results: Overall, diagnostic yield was 81.6% (40 of 49). When distinguished, the yield was 81.3% (39 of 48) and 100% (1 of 1) for bone and soft tissue tumours, respectively. Of the 49 PCNB, 22 had a comparative specimen with a diagnostic accuracy of 86.4%. Sensitivity and specificity were 89.5% (17 of 19) and 100% (3 of 3), respectively. The commonest musculoskeletal tumour diagnosed was osteosarcoma (n = 20). Complication rate of PCNB was 2.0% (1 of 49), consisting of post-biopsy haematoma formation.

Conclusion: PCNB technique is effective, safe and accurate in bone tumours. It is associated with low complication rates and osteosarcoma remains the commonest bone sarcoma.

CHAPTER 1: INTRODUCTION AND BACKGROUND

When a diagnosis of a musculoskeletal tumour is suspected, extensive history-taking, thorough clinical examination, and an informed selection of haematological and imaging studies are pivotal to initial patient evaluation [1,2,3]. Despite specific tell-tale signs and obvious radiological features of certain tumours, a tissue biopsy is often a fundamental step in making a histopathological diagnosis [1-8]. Rarely, a biopsy is tentatively omitted in clinically and radiologically unequivocal non-aggressive benign lesions (e.g. latent osteochondroma or enchondroma) [1,6]. The purpose of an optimum biopsy is to obtain a representative tissue sample without increasing the risk of morbidity and complications [1,5]. The information gathered from such a procedure is invaluable in formulating an optimal patient management strategy [1-6]. Firstly, the nature of the tumour can be identified (i.e. benign or malignant) and secondly, the predominant cell type can indicate the tissue of origin (i.e., bone or soft tissue and primary or metastatic) [1-6]. Ancillary information amongst others, includes the degree of cell differentiation, tumour grading, tumour subtype, presence and absence of a concurrent infection [1,3-5]. The importance of a correct and distinct histopathological diagnosis from a tissue sample is signified by the diverse treatment plans that are tailored and only effective in certain musculoskeletal tumours [1].

The key to improving patients' quality of care lies in the multidisciplinary collaboration between the orthopaedic oncologist, radiologist and pathologist [2,3,5,7,9,10]. Different techniques for tissue sampling in musculoskeletal tumours have been described and include fine needle aspiration (FNA), percutaneous core needle biopsy (PCNB) and open biopsy. Each technique has pros and cons which influence preference, but the diagnostic accuracy is a critical parameter in determining the choice [2]. Open biopsy is the conventional gold standard for obtaining adequate tissue samples for histopathological diagnosis [1-3,5,6,9-16]. However, the associated high financial costs and unattractive surgical complications make it less desirable [2,3,5,6,11,12,17,18]. The complication rate for open biopsy has been reported to be as high as 19% in some studies [1,2,6,9,11,13,14,16]. These complications are listed in Table 1.1 [1-18]. Wound healing problems seen with open biopsies pose the greatest threat to expediting life-saving and limb-saving treatment, especially, when neoadjuvant or adjuvant chemo-radiation therapy is necessary in aggressive malignant tumours [3,6,8-10]. Another important

complication related to an open biopsy is the potential for tumour seeding which is associated with deleterious consequences [3,6,8-10]. The sequelae of such a complication can be devastating to both the patient and the treating clinician [3,6,8-10]. For the patient, this could mean loss of limb or even life [3,6,8-10].

Table 1.1: Complications of open biopsy [1-18]

1	Wound dehiscence and infection
2	Vascular injury
3	Nerve injury
4	Haemorrhage
5	Pathological bone fractures
6	Tumour seeding and spread
7	Haematoma formation
8	Seroma formation
9	Fistulas
10	Tumour fungation
11	Amputation
12	Death

The use of percutaneous FNA technique in musculoskeletal tumours was first described by Bradley Coley et al. in 1931 [2,17]. FNA is deemed ineffective in the diagnosis of musculoskeletal tumours as it only provides cytological material and lacks the ability to allow evaluation of tissue architecture [1,2]. This is further supported by the associated high false negative rates [1,2]. It has since evolved and modified to improve diagnostic yield and accuracy [1,3-6,9,11,15-18]. Introduced in 1938, PCNB technique has become increasingly popular, because it mitigates against FNA shortcomings and it offers a safer alternative to open biopsy [2,5,6,910,13-18]. PCNB yields cylindrical tissue blocks which allow the pathologist to determine tissue structure and cellular interrelation, thereby enhancing the diagnosis of histologic subtypes and tissue grades [5]. Meticulous surgical planning is crucial, thus, careful analysis of imaging studies prior to embarking on PCNB is mandatory [10,12,14]. Although plain radiographs provide a vast amount of information about the bone lesion in question, additional imaging is usually necessary for assessment of soft tissue involvement. It is crucial to recognise that a biopsy is the culminating stage in making a diagnosis and it does not serve as a shortcut, thus it should be delayed until the lesion in question is fully staged [11,12,14].

Ultrasonography (US) identifies the peripheral vascular areas of the tumour that are more likely to yield a representative sample as compared to the avascular, sclerotic and necrotic central areas [1,2,5,10,17]. A Computed Tomography (CT) scan better delineates cortical bone destruction, bone erosion and lesion matrix calcification [3,18]. Magnetic Resonance Imaging (MRI) is the modality of choice to outline neurovascular structures from the tumour, tumour boundaries, interfaces and myofascial planes [2,3]. Contrast material-enhanced CT/MRI can serve a similar purpose as that of US [2,3].

For malignant primary tumours, such information is necessary to guide proper surgical planning regarding placement of biopsy site and minimising the risk of tumour seeding [3,14]. This stage in patient management is crucial and can be the difference between limb ablation and limb-sparing surgical procedures [3,14]. Due to improvements in chemotherapy and radiation therapy, the management trend is towards limb-salvage surgery (LSS) [1,3,10,14]. This type of treatment strategy can be compromised by complications associated with the tissue sampling procedure itself. In the majority of cases, this is due to seeding of tumour cells across multiple anatomical compartments or adjacent to major neurovascular structures [1,14]. Unlike malignant tumours, sampling of benign tumours is relatively safe because tumour contamination is not of major concern [3]. The above factors and their potential impact, make PCNB a very attractive alternative sampling technique in musculoskeletal tumours [1-3,6-10,14,19,20].

Traditionally, all musculoskeletal tumours are treated as if they are malignant until proven otherwise [1]. It is therefore important that sarcoma treatment principles be adhered to when embarking on a biopsy irrespective of the technique (see Table 1.2). Ideally, it must be carried out in a dedicated tumour centre as per the National Institute for Health and Clinical Excellence (NICE) guidelines and advisably by the experienced orthopaedic oncologist who is going to carry out the definitive surgery [4,6,10]. The frequency of major errors and complications increases significantly if a biopsy is performed in a referring centre compared to an oncology centre [1]. Mankin et al. indicated that the errors related to incision placement occurred three to eight times frequently in the non-treating, referring facility [16]. An incorrectly performed biopsy would have a negative effect on the overall survival of the patient [1,2]. The biopsy track must be positioned strategically in line with the planned future surgical incision for the definitive surgical resection [1,4,8,10,18]. It is crucial to do so because biopsy tracks (and drain

path if one is used) are considered contaminated and therefore associated with tumour seeding and recurrences [4]. Furthermore, recurrences especially in osteogenic sarcomas, are associated with 5-year survival rates as low as 29% despite radical chemotherapy and radiation [4].

Table 1.2: Principles of biopsy in musculoskeletal tumours [3,4,6,10,12]

1	Biopsy should be performed in a dedicated musculoskeletal oncology centre or in consultation with an orthopaedic oncologist who is going to perform the definitive surgery
2	Use strategically placed longitudinal incisions
3	When a tourniquet is used, it should be deflated prior to wound closure to ensure haemostasis and prevention of haematoma formation
4	Limb exsanguination with Esmarch bandage is contraindicated
5	Maintain meticulous haemostasis
6	Do not expose neurovascular structures
7	The periphery of the tumour is the most viable and representative part
8	In bone tumours, the extraosseous component of the tumour is as representative
9	If using a drain, it must exit near (± 1cm) and in line with the incision
10	Culture all suspected tumours and biopsy all suspected infections
11	Perform the biopsy through the involved anatomical compartment

The biopsy track, immediate surrounding tissue and the tumour itself are resected en bloc during the definitive surgery [1,3,4,10,12]. Poorly planned incisions may also compromise major neurovascular and vital myotendinous structures thus negatively affecting limb function [1,4,12]. These increase the risk of converting a salvageable limb to one that requires amputation in 5-8% of patients or may force the treating orthopaedic oncologist to perform more radical complex resections and further increase treatment related morbidity [4,12]. These poorly planned biopsies do not only preclude LSS but also compromises the function of the stump in cases of limb ablation [1]. In certain instances, a potentially curative treatment is converted into a palliative treatment [12]. It is also worth noting that the presence of pulmonary metastasis is not a free ticket to ignoring the sarcoma biopsy principles due to the constant emergence of new surgical innovations. Pulmonary metastatectomy is curative in 25% of cases provided the eligibility criteria is met [25].

Image-based guidance PCNB techniques have become popular in most specialized oncology orthopaedic centres [3,12,18]. Imaging modalities provide real time imaging and improve the yield and accuracy of the technique [7,14,17]. Common modalities include US, fluoroscopy, CT scan and MRI [3,12]. Fluoroscopy is commonly employed in sampling bone tumours as it is readily accessible in most institutions and it is easy to use [4]. Although non-invasive, MRI is not easily accessible and requires special sampling equipment [4]. CT guided PCNB technique is preferred because of improved diagnostic yields and low complication rates compared to the standard PCNB [1,7,13,14,17,18]. A CT scan allows for better visualisation of anatomy and lesions [4,13,17]. Although the value of CT scan is well documented in the literature, this imaging technique is not always readily available particularly in third world countries. CT scan guided-PCNB diagnostic yields vary between 69% and 87.4% [18]. Due to equipment constraints, high volumes of patients, shortage of staff and the burden of trauma at Chris Hani Baragwanath Academic Hospital (CHBAH), CT scan use is often reserved for immediate life-threatening situations. In addition, the associated high cost makes the use of a CT scan guided-biopsy an impractical task in resource-constrained health institutions.

The diagnostic yield of PCNB is reported to be higher in bone tumours than in soft tissue tumours [16,19]. Crenn et al. reported a diagnostic yield of 84.7% in bone tumours in a cohort of 166 patients [19]. The technique provided a clear histopathological diagnosis and resulted in a subsequent clear therapeutic strategy [19]. They concluded that the technique is a favoured choice as a first-line diagnostic tool in primary bone tumours [19]. Qi et al. reported a diagnostic yield of 96% associated with high accuracy, sensitivity and specificity for the diagnosis of soft tissue tumours, particularly when distinguishing malignant from benign tumours [20]. The technique was deemed effective and safe in suspected soft tissue tumours, especially when performed under image guidance [20].

Compared to open biopsy, PCNB is associated with a low risk of complications [1,3,4,6,8,11]. Kasraeian et al. reported that the complication rate can be as high as 7.4% [5]. Advantages of PCNB amongst others, include reduced morbidity and mortality, shortened length of hospital stay and decreased number of follow up visits for wound checks (see Table 1.3) [1,3,4,6,8,11]. It can also be carried out under local anaesthetics thus eliminating risks associated with regional and general anaesthesia [1,4,10,16]. The PCNB technique is also advantageous for deep-seated musculoskeletal lesions which cannot be safely accessed with an open biopsy (e.g. vertebral

column or pelvis) [10,14]. This procedure is not without controversies. Kasraeian et al. reported a PCNB diagnostic accuracy of 45.6% compared to 100% in open biopsy of soft tissue tumours when compared to the final diagnosis as determined by the evaluation of resected specimen in collaboration with the final clinical impression [5]. PCNB provided a limited examination of the architectural structure of the sampled tissue not amenable to special tests or stains, making an accurate histopathological diagnosis difficult [1-3,9,5,11]. Inaccurate diagnosis is not uncommon particularly in the more heterogeneous soft tissue tumours (e.g. haemangiomas and synovial sarcomas) [1-3,9,5,11]. It is recommended that a non-diagnostic PCNB be repeated or followed by an open biopsy to minimise false negative results [5,10,11,13]. This is because an incorrect diagnosis could lead to catastrophic therapeutic consequences and poor patient outcomes [5,10,11]. Tong et al. recommends that a patient with a negative PCNB yield be monitored closely and that if there are any notable discrepancies among clinical, radiological and PCNB findings, incisional biopsy must be performed to ascertain the diagnosis [13]. It is important to note that not all PCNB misdiagnoses can be corrected by an open biopsy [13,16]. Open biopsies are non-diagnostic in approximately 5% of cases [16]. It is worth noting that most of the studies in literature reporting 100% for both diagnostic yield and accuracy are often combined with intraoperative frozen sections [14].

Table 1.3: Advantages and disadvantages of PCNB and open biopsy [1,3,4,6,8,11,12]

Advantages	
PCNB	**Open biopsy**
Simple Quick Cost-effective Provides safe access to deep-seated tumours Low complication rates	Large tissue specimen enables a broad range of ancillary studies
Disadvantages	
Small quantity of tissue Often requires a skilled pathologist to make an accurate diagnosis	Time consuming Invasive High complication rates

More and more studies suggest a comparable diagnostic accuracy for PCNB and open biopsy [1,8,10,16]. Pohlig et al. reported a diagnostic accuracy of 100% for PCNB *versus* 93.3% for an open biopsy in a retrospective study done on bone sarcomas [10]. A high diagnostic accuracy

in open biopsies is reported when sampling is coupled with intraoperative frozen sections analysis pending definitive histopathological diagnosis [5,16]. Image-guided PCNB is necessary in deep-seated lesions to minimise complications [10,14]. Taupin et al. recommended PCNB as the first line diagnostic technique in patients with a suspected osteosarcoma due to high sensitivity and specificity [8].

The overall diagnostic accuracy of PCNB of bone and soft tissue tumours ranges between 64.4% and 100% [1,2,5,10]. It is higher for bone tumours than soft tissue tumours [11]. The wide range is due to the non-homogenous spectrum of most studies conducted. Great variation in sample size, type and size of the biopsy needle, number of samples taken and variety of bone and soft tissue tumours all play a great role [1]. The inclusion of more homogenous metastatic tumours by some authors resulted in higher diagnostic accuracy as compared to the more heterogeneous primary sarcomas [1]. In addition, some studies excluded non-diagnostic samples, which gives false accuracy rates. The conflicting results in the reviewed literature and a lack of South African statistics on the topic formed the basis of our study.

In this study, we hypothesised that PCNB technique is an effective diagnostic tool in musculoskeletal tumours and that the diagnostic yield is comparable to that of an open biopsy particularly for bone tumours.

CHAPTER 2: RESEARCH METHODOLOGY

2.1. AIM

This study aimed to establish the diagnostic strength of PCNB in musculoskeletal tumours at CHBAH.

2.2. OBJECTIVES

The objectives of the study were:

- To document the diagnostic yield of PCNB in musculoskeletal tumours.
- To determine the commonest musculoskeletal tumour diagnosed at CHBAH.
- To document complications related to PCNB in our context.

2.3. RESEARCH DESIGN

This was a retrospective observational study that comprised of reviewing patients' clinical records and histopathological results.

2.4. RESEARCH SITE

This study was conducted at the Orthopaedic department at CHBAH.

2.5. STUDY POPULATION

All patients who underwent PCNB at the CHBAH Tumour and Sepsis Unit between 01 January 2016 and 31 January 2022 were included in the study. The indicated study period was chosen because the Unit was established in 2016 and record keeping of PCNB procedures was a challenge in the years prior. Patients with incomplete clinical records and those with the diagnosis of infection alone were excluded from the study. Of the latter, 15 were solely diagnosed with an infection, two of which were osseous Tuberculosis (TB).

2.6. SAMPLE SIZE CALCULATION

A power analysis was performed in conjunction with a biostatistician prior to embarking on the study.

In a similar previous study of 134 cases of PCNB in musculoskeletal tumours, a diagnostic yield of 88% was reported. Using this generic information, we calculated sample size using the formula [21].

Sample size = $Z_{1-\alpha/2}^2\, p(1- p)/d^2$

$= [1.96^2 \times 0.88(1- 0.88)]/(0.05^2)$

$= 155.7 \approx 156$

where $Z_{1-\alpha/2}$ is standard normal variate at 5% type 1 error ($p < 0.05$), 1.96,

p is the expected proportion in population based on a previous study and

d as the absolute error or precision of 5% (0.05).

With a likelihood of 50% of missing patients' clinical records or incomplete data, sample size was then estimated to decline to 78.

2.7. DATA COLLECTION

All patients who underwent a PCNB were identified from the Tumour and Sepsis Unit theatre registry. Upon identification from theatre registry, the patient's clinical records were then subsequently retrieved from the hospital records office. Data was reviewed by the primary researcher (Dr. M.A. Chuene) and the primary supervisor (Dr. M.P. Kgagudi). Data collected from the clinical records included patients' demographics (i.e. age and gender), clinical presentation (i.e. pain, mass or both), radiological characteristics (i.e. lytic, sclerotic or mixed) of the tumour, anatomical location involved, histopathological diagnosis and complications related to the procedure. Histopathological results were retrieved from the National Health Laboratory Services (NHLS) LabTrak electronic system using the patient's hospital details (i.e. hospital number, name, surname and date of birth). All these data were entered on a data collection sheet (see Appendix A). Histopathological results of the PCNB were then compared to those of definitive tumour resection specimen or alternate biopsy if available, to establish

diagnostic accuracy. The nature (benign *versus* malignant) and tissue of origin (soft tissue *versus* bone) of the tumour were also documented.

2.8. PCNB TECHNIQUE AT CHBAH

All biopsies were performed by or in consultation with two orthopaedic surgeons experienced in musculoskeletal tumours. Different orthopaedic health institutions use different core biopsy needles for specific different reasons. The needle of choice at CHBAH for percutaneous core biopsy was the Jamshidi (see Figure 1.1). The needle set consisted of an outer cannula, an inner trocar and/or a stylet [6,10]. Needle sizes used range from 10 to 14 gauge. Prior to PCNB, radiography, CT and MRI were requested and reviewed by a radiologist and an orthopaedic surgeon experienced in musculoskeletal tumours. An informed consent was obtained in all cases prior to taking the patient to the operating room. With the patient under appropriate anaesthesia (regional or general, depending on the age of the patient and anatomical location), the preparation and draping were performed in a standard fashion. The biopsy needle was then passed through a meticulously planned surgical approach (longitudinal stab incision) until the trocar met the lesion [10,12]. With rotatory motion, the lesion was penetrated, and the trocar removed, the cannula was further advanced to the core of the lesion to obtain cylindrical tissue block [6,10,12].



Figure 2.1: Jamshidi needle set

The handle was attached to the end of the cannula for improved grip. The mallet was used to gently tap the cannula to aid with purchase especially in hard sclerotic bone lesions. The cannula was withdrawn, and the cylindrical tissue block pushed out using a stylet [10,12]. The trocar was then replaced into the cannula and the procedure repeated through the same incision but at a different trajectory for diverse sampling [1,2,6,10,11]. An average of 3 (minimum 1 and maximum 11) different tissue samples was regarded as adequate in reducing the risk of a non-diagnostic biopsy. In some cases, less than 3 specimens were obtained as it was deemed unsafe to proceed with further sampling (e.g. risk of fracture or tumour contamination of adjacent neurovascular structures). The diagnostic yield and accuracy of the technique is increased by the number of samples from various areas of the tumour. Furthermore, the precision of this technique in the majority of bone tumours was further enhanced by the use of fluoroscopy as an image-guidance modality. The rest of the biopsies were performed anatomically, especially if the soft tissue component of the tumour was significant and easily palpable. The skin was then closed with a one or two nylon sutures.

All specimens were fixed in 10% of formalin and sent to the laboratory for processing and analysis. Haematoxylin and Eosin (H&E) staining was performed routinely and additional auxiliary tests included if deemed appropriate by the interpreting pathologist. The sections were reviewed by a pathology registrar and a pathologist with experience in orthopaedic oncology. By virtue of academic affiliations of the hospital, several registrars and pathologists were responsible for pathologic processing and interpretation. If there was a concern for infection, additional tissue samples were placed in an appropriate sterile container and sent for microscopy, culture and sensitivity (MC&S).

2.9. COMPLIANCE WITH ETHICAL STANDARDS

Ethics clearance was obtained from the Human Research Ethics Committee (HREC) (Medical), University of the Witwatersrand and permission to conduct the study was initially granted for the period 01 January to 18 June 2020. Clearance certificate number: **M200726** (see Appendix B). Due to a small study population, an extension to collect data was sought and granted (see Appendix C). Permission to conduct the study at CHBAH was obtained from Chief Executive Officer's (CEO) office and from the University of Witwatersrand Orthopaedic Surgery's academic head of department (HOD) (see Appendices D, E and F). Permission to access

histopathological results was sought and granted (see Appendix G). Personal details of patients were kept confidential and study numbers were used to identify participants.

2.10. STUDY STRENGTHS AND LIMITATIONS

Our study has several limitations. The main limitation of the study was the low number of PCNB performed for soft tissue tumour and as a result no conclusions can be drawn. Secondly, not all patients had a final diagnosis derived from an alternate sampling method or surgical specimen and thus diagnostic accuracy was determined from only a proportion of study population. Due to the retrospective nature of the study, it was not always possible to establish the presence or absence of complications related to PCNB.

The other limitation is the fact that the number of biopsies taken was not standardised and ranged between one and eleven. Also, none of the lesions biopsied were in the spinal region solely because in our institution, these lesions are referred to a dedicated Spine Unit. The establishment of diagnostic accuracy in our study varied, from comparing the PCNB diagnosis to that derived from either a definitive surgical specimen or biopsy of the primary tumour in cases of metastatic bone disease.

Additionally, due to the involvement of several registrars and pathologists in specimen processing and interpretation, analysis of effect, if any, of their experience on diagnostic yield cannot be ascertained. Despite the aforementioned limitations, we strongly believe that our study provides clinically valuable information regarding PCNB.

CHAPTER 3: DATA ANALYSIS AND INTERPRETATION OF RESULTS

3.1. STATISTICAL DATA ANALYSIS

Data collected were loaded onto Excel spreadsheet, coded and cleaned for statistical analysis software. The data were analysed using STATA software package version 11 (StataCorp, College, Texas, United States of America, July 2009). A biostatistician with a background knowledge of clinical medicine was employed to help analyse the data in more detail. Discrete variables were calculated in percentages and continuous variables using medians. Proportions were compared using Fisher's exact test. A *P*-value less than 0.05 was considered statistically significant. Histological results were categorised into benign *versus* malignant and bony *versus* soft-tissue tumours. A PCNB was considered diagnostic if the pathologists were able to establish a distinct histopathological diagnosis from the biopsy specimen provided. It was however considered non-diagnostic if the tissue specimen obtained was normal or insufficient for a formal histopathological diagnosis to be made. In simple terms, it was defined as the proportion of cases where the PCNB yielded a positive histopathological result (i.e. either malignant or benign).

The diagnostic yield was calculated as the number of diagnostic biopsies (benign and malignant) divided by total number of all biopsies performed (diagnostic and non-diagnostic) using the following formula:

$$d_y = \frac{diagnostic\ biopsies}{diagnostic\ biopsies + non - diagnostic\ biopsies}$$

where,

- d_y is diagnostic yield
- Diagnostic biopsy is defined as a biopsy which yields a positive meaningful histopathological diagnosis (i.e. either malignant or benign tumour),
- Non-diagnostic biopsy is defined as a biopsy which is insufficient to make a formal histopathological diagnosis or one which yields normal tissue or an inconclusive result or a tumour-like lesion.

Diagnostic accuracy was determined for cases in which a comparative specimen was available. The final diagnosis of primary musculoskeletal sarcomas was established after surgical resection and by a diagnostic surgical biopsy (i.e. incisional or excisional) of the primary tumour in cases of metastatic bone disease. The PCNB diagnosis was considered accurate if it correlated with the final diagnosis.

3.2. Study population

The study population comprised a total number of 49 (49 patients) percutaneous core needle biopsies and of those 51% (*n* = 25) were males and 49% (*n* = 24) females (see Table 3.1). Median age of the patients was 27 years, ranged between 3 to 67 years. Of the 49 percutaneous core needle biopsies performed, 48 were for evaluation of an unknown primary tumour and one case was for a suspected local recurrence of a previously resected malignant tumour.

Table 3.1: Gender of the study population

Variable	**Number of subjects (*n*)**	**Percentage (%)**
Male	25	51
Female	24	49

3.3. Clinical presentation

Majority of patients (37%; *n* = 18) presented with a history of a painless mass, followed by those that complained of a painful mass (33%; *n* = 16) and those with pain only (22%; *n* = 11), respectively. Fortunately, only four patients (8%; *n* = 4) presented with a fracture (see Figure 3.1).

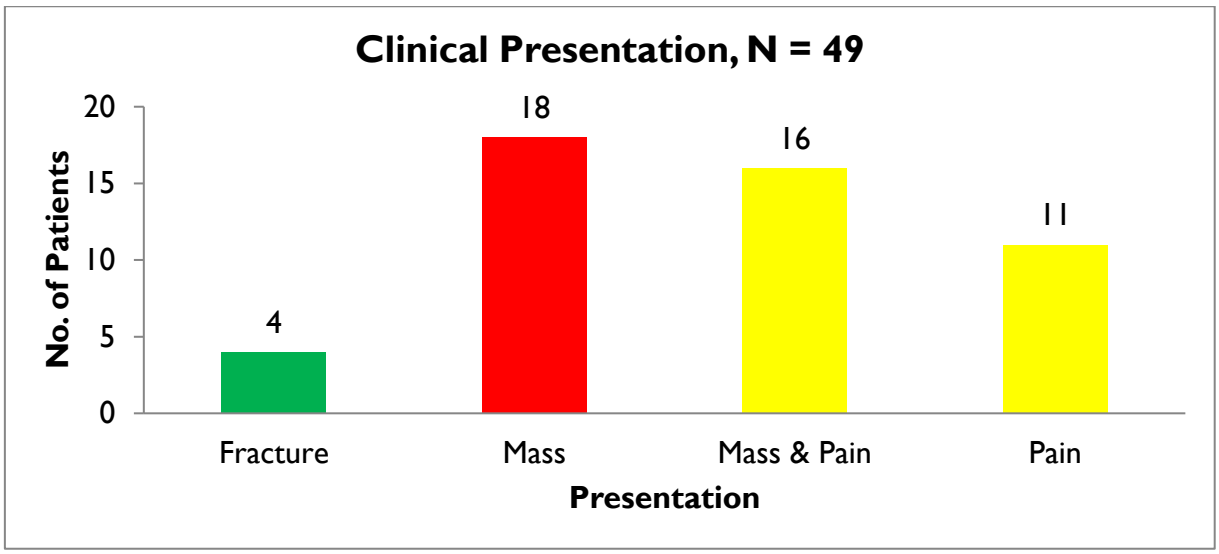

Figure 3.1: Clinical presentation: symptoms

3.4. Type of the lesion

Out of the 49 patients, 48 presented primarily with a bone lesion and one, with a soft tissue lesion. Out of the 48 that presented with bone lesions, radiographic appearance was lytic in 75% of the lesions (*n* = 36), mixed in 19% of cases (*n* = 9) and sclerotic in the remainder (6%; *n* = 3) (see Figure 3.2). There was no bone infiltration or calcifications of the mass in one patient with a soft tissue lesion thus, no radiographic description.

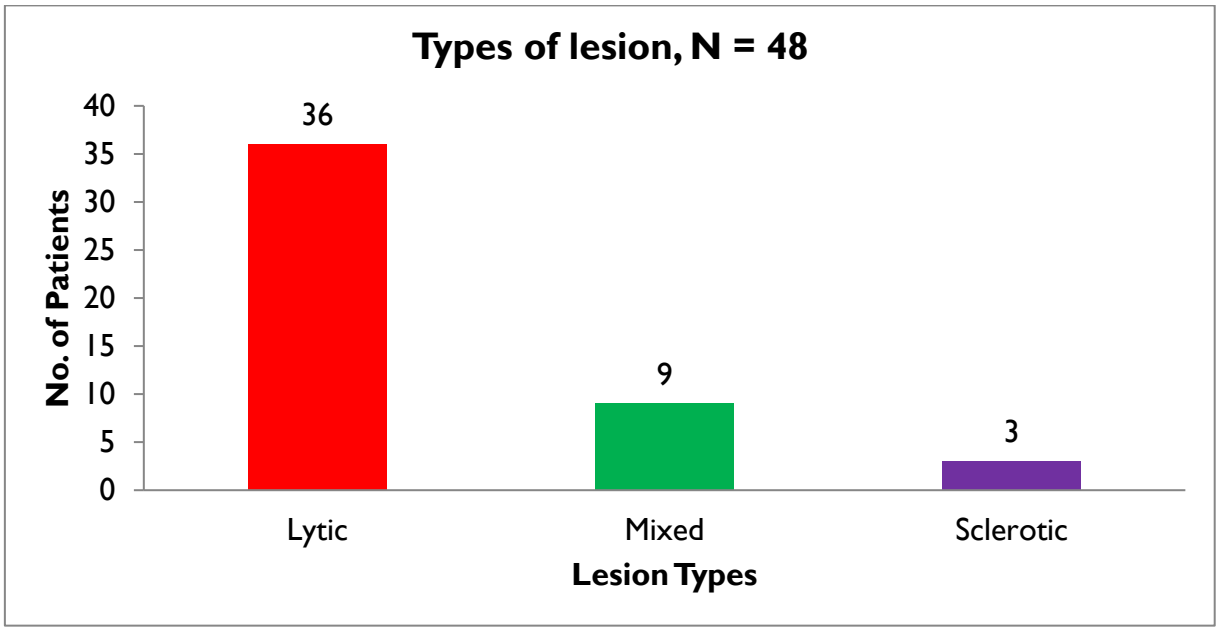

Figure 3.2: Type of the lesion

3.5. Anatomical distribution of biopsy sites

The most common anatomical site biopsied was the lower limb in 63.3% (*n* = 31), followed by the pelvis in 18.4% (*n* = 9) and the upper limb in 18.4% (*n* = 9) (see Table 3.2). The most commonly affected bone was the femur (*n* = 21) and the most common portion, the distal femur (*n* = 15), followed by the proximal femur (*n* = 5). Only one of the 21 lesions in the femur was located in the shaft. Second to the femur, was the proximal tibia (*n* = 5) and lastly, the proximal fibula (*n* = 4). The pelvic lesions were evenly distributed in the acetabulum (*n* = 3), sacrum (*n* = 2) and the hemipelvis (*n* = 2). Two of the remainder of the pelvic lesions were also located in the hemipelvis but, were noted to be invading the sacroiliac joint. In the upper limb, majority of the lesions were located in the proximal humerus (*n* = 4), followed by the clavicle (*n* = 2). Two lesions in the forearm, were located in the radius (*n* = 2). The only soft tissue tumour biopsied was located in the distal thigh (*n* = 1).

Table 3.2: Anatomical distribution of lesions

Location (*n* = 49)	**Anatomical site**	**Number of subjects (*n*)**	**Percentage (%)**
Lower limb	Proximal Femur	5	10.2
	Femur Shaft	1	2.0
	Distal Femur	15	30.6
	Proximal Tibia	5	10.2
	Proximal Fibula	4	8.2
	Distal thigh (soft tissue tumour)	1	2.0
	Total lower limb	**31**	**63.3**
Pelvis	Acetabulum	3	6.1
	Hemipelvis (mainly, the ilium)	2	4.1
	Hemipelvis & Sacroiliac joint	2	4.1
	Sacrum	2	4.1
	Total pelvis	**9**	**18.4**
Upper limb	Clavicle	2	4.1
	Distal Radius	2	4.1
	Proximal Humerus	4	8.2
	Humerus shaft	1	2.0
	Total upper limb	**9**	**18.4**

3.6. Diagnostic yield

The overall diagnostic yield of the 49 PCNB in our study was 81.6% calculated using the formula:

$$d_y = \frac{Diagnostic\ \ biopsies}{Diagnostic\ biopsies + non-diagnostic\ biopsies}$$

$$= \frac{40}{40+9} \text{ x } 100$$

= 81.6%.

PCNB tissue sample allowed for a clear histopathological diagnosis in 40 of the 49 cases (see Tables 3.3 and 3.4). All additional data including clinical and radiological information were available to aid pathologists in making a correct diagnosis. In some cases, special staining was performed to confirm the diagnosis if needed.

Table 3.3: Diagnostic nature and number of biopsies of the study population

Diagnostic nature	**Frequency**	**Percentage (%)**
Diagnostic biopsy	40	81.6
Non-diagnostic biopsy	9	18.4
Total	**49**	**100**

Table 3.4: Histopathological diagnoses of diagnostic PCNB

PCNB Clinical Outcomes	**Number (*n*)**
Conventional Osteoblastic Osteosarcoma	7
Conventional Chondroblastic Osteosarcoma	5
Conventional High-Grade Osteosarcoma	4
Conventional (Mixed Fibroblastic & Osteoblastic) Osteosarcoma	2
Conventional (Mixed Fibroblastic & Chondroblastic) Osteosarcoma	1
Giant-cell-rich Osteosarcoma	1
Ewing's Sarcoma	3
Plasmacytoma	2
Large B-Cell Lymphoma	1
Plasmablastic Lymphoma	1
Recurrent Hodgkin's Lymphoma	1
Metastatic Gastric Adenocarcinoma	1
Metastatic Renal Clear Cell Carcinoma	1
Metastatic Follicular Thyroid Carcinoma	1
Metastatic Papillary Thyroid Carcinoma (Follicular Variant)	1
Metastatic Colorectal Adenocarcinoma	1
Leiomyosarcoma	1
Giant Cell Tumour of Bone	3
Periosteal Chondroma	1
Focal Granuloma	1
Chondromyxoid Fibroma	1
Grand Total	**40**

Of the 49 PCNB performed, only nine were non-diagnostic (see Table 3.5). Of the nine non-diagnostic biopsies, samples were not representative in eight cases. Of these, normal tissue was reported in six cases and a reactive bone diagnosis issued for one case. Derivation from the fracture was reported in the last non-representative sample. In the remaining case (i.e. last of the nine), atypical cells were identified but the sample did not allow the pathologists to make a meaningful diagnosis.

Based on the clinical and imaging findings, an alternate sampling method was employed in all but four patients, to safe-guard against missing an underlying harmful lesion (see Table 3.5). Unfortunately, three patients were lost to follow up without a clear final diagnosis, one so after an unsuccessful repeat PCNB. One other such patient was lost to follow up during the peak of the third wave of Coronavirus Disease-2019 (COVID-19). A decision was taken to closely monitor one patient clinically and radiologically. The latter patient presented with features suggestive of a benign lesion, and the tissue samples taken, were then reviewed by two senior pathologists on two separate occasions. They both queried a diagnosis of an enchondroma, a benign cartilaginous tumour.

An incisional biopsy was performed for one patient who presented with a low energy fracture through an expansile cystic lesion noted on MRI. The findings were consistent with that of PCNB diagnosis of derivation from fracture site. Of note, this patient had multiple risk factors for secondary osteoporosis. Two patients subsequently underwent excisional biopsy. Of these, one was a patient with a pathological neck of femur fracture undergoing a total hip replacement. The resected head was sent for histopathological assessment and showed no infiltrative malignancy. In one other patient post excisional biopsy, the specimen yielded a benign tumour (periosteal chondroma). In the last patient with a non-representative sample, an ultrasound guided PCNB was performed and revealed an osteoblastic osteosarcoma. For one patient with an inadequate but otherwise representative specimen, PCNB was repeated and yielded metastatic thyroid carcinoma.

Table 3.5: Non-diagnostic PCNB and alternate sampling methods

PCNB outcome	**confirmatory sampling method**	**Confirmatory sampling method outcome**	**Final diagnosis**
Lesion not represented in tissue examined	Repeat PCNB	Reactive plasmacytosis with no infiltrative malignancy	Lost to follow up
Normal tissue	None		Lost to follow up
Reactive plasmacytosis	Excisional biopsy	Necrotic bone	No infiltrative malignancy
Trilinear haematopoiesis	Repeat PCNB	Follicular thyroid carcinoma	Metastatic thyroid carcinoma
Necrotic bone	Excisional biopsy	Benign chondrogenic neoplasm	Periosteal chondroma
Atypical cells	Repeat PCNB (Ultrasound-guided)	Conventional osteoblastic osteosarcoma	Osteosarcoma
Lamellar bone	None		Benign lesion, query enchondroma
Viable lamellar bone	None		Lost to follow up
Derivation form fracture site	Incisional biopsy	Derivation from fracture site	Low energy fracture

3.7. Primary lesion and nature of the lesion

A lesion in bone was diagnosed in 98% (*n* = 48/49) of the study population with only one soft tissue lesion diagnosis based on a combination of clinical and radiological assessment (see Figure 3.3).

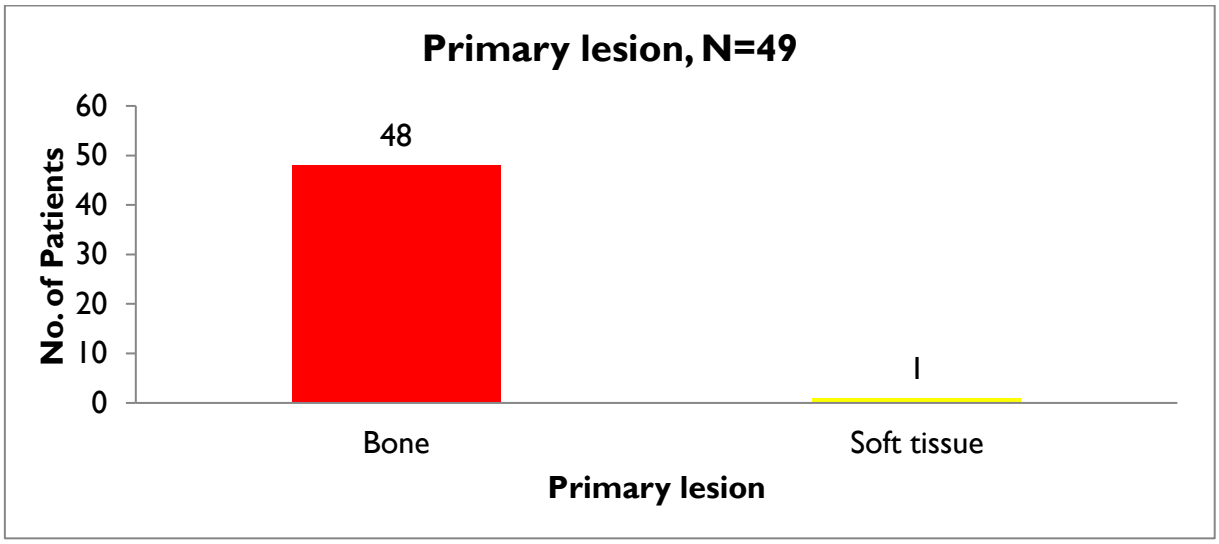

Figure 3.3: Primary lesion in 49 patients based on clinical and radiological assessment

Out of the 40 diagnostic PCNB cases, 85% (*n* = 33 bone and *n* = 1 soft tissue) of patients were diagnosed with a malignant tumour and 15% (*n* = 6 bone and *n* = 0 soft tissue) with a benign tumour (see Figure 3.4).

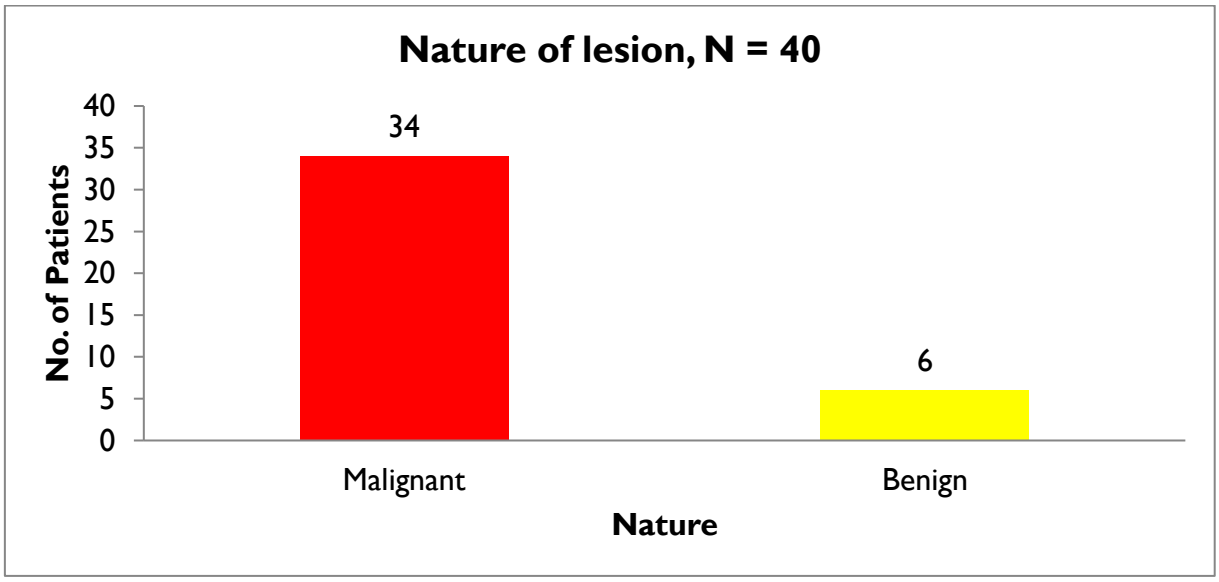

Figure 3.4: Nature of lesion in 40 patients with a diagnostic PCNB

Of the 33 malignant bone tumours diagnosed, 28 were primary bone tumours and five were metastases to bone. The most commonly diagnosed malignant primary bone tumour was osteosarcoma (*n* = 20), followed by Ewing's sarcoma (*n* = 3) and lymphoma (*n* = 3), respectively. Plasmacytoma (*n* = 2) was the least commonly diagnosed primary bone tumour (see Table 3.6 and Figure 3.5).

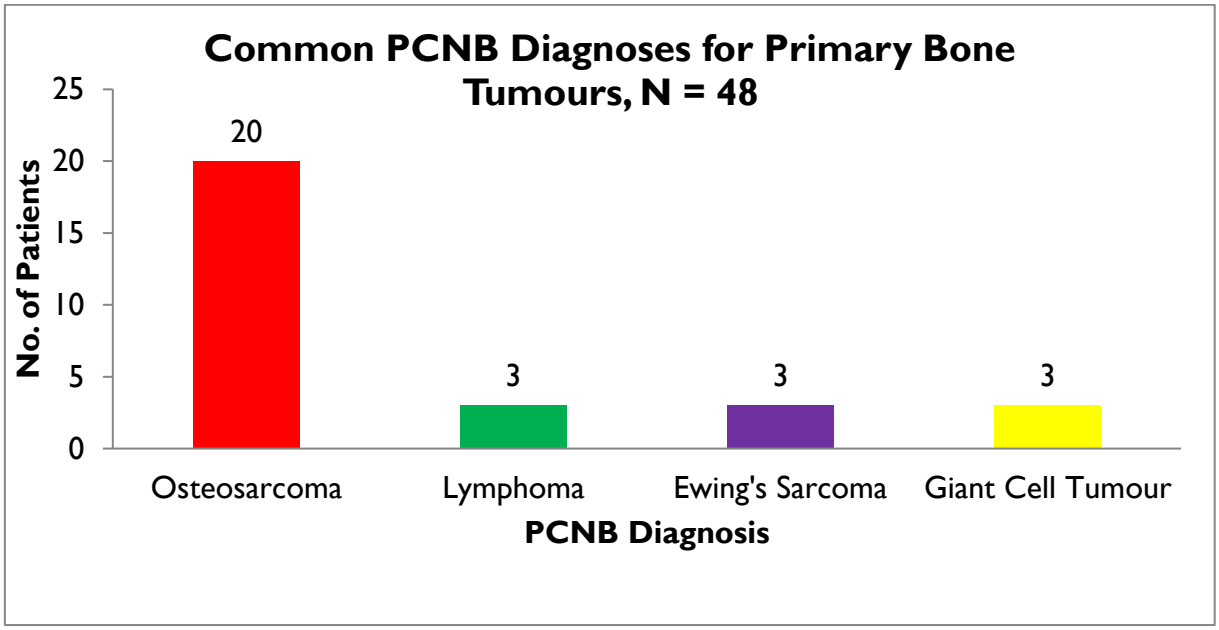

Figure 3.5: Common PCNB diagnoses for primary bone lesions

Conversely, thyroid carcinoma (*n* = 2) and adenocarcinoma constituted the most commonly diagnosed metastatic bone tumours (see Table 3.6). Clear cell carcinoma was the least commonly diagnosed metastatic bone disease. The one patient with a malignant soft tissue tumour was diagnosed with leiomyosarcoma (see Table 3.6). No benign soft tissue tumours were diagnosed in this study. The most commonly diagnosed benign bone lesion was giant cell tumour of bone (*n* = 3) (see Table 3.6). There was one case of each of focal granuloma, periosteal chondroma and chondromyxoid fibroma.

Table 3.6: Frequency of diagnosed tumours

Malignant primary bone tumour (*n* = 28)	Osteosarcoma	20
	Ewing's sarcoma	3
	Lymphoma	3
	Plasmacytoma	2
Benign primary bone tumour (*n* = 6)	Giant cell tumour	3
	Chondroma	1
	Focal granuloma	1
	Chondromyxoid fibroma	1
Metastatic bone tumour (*n* = 5)	Thyroid carcinoma	2
	Adenocarcinoma	2
	Clear cell carcinoma	1
Malignant primary soft tissue tumour (*n* = 1)	Leiomyosarcoma	1

3.8. Diagnostic accuracy

To determine diagnostic accuracy, 23 of the 40 diagnostic PCNB cases that could not be confirmed by a comparative specimen, were excluded. Only 17 cases met the inclusion criteria and were analysed. All 17 cases were related to bone tumours. Of these, two cases were benign and 15 cases were malignant. In the two benign tumours, PCNB showed giant cell tumour of bone subsequently confirmed by specimens obtained intraoperative during intralesional curettage. In the patients with malignant lesions on PCNB, 13 had primary bone tumours and two had metastatic bone disease. In the latter, incisional and excisional biopsies were performed and confirmed adenocarcinoma and follicular thyroid carcinoma, respectively.

In the 13 patients with malignant primary bone tumours, four patients underwent tumour resections and diagnoses of one chondrosarcoma, and three osteosarcomas were confirmed. Limb ablation surgery was performed in six cases and all confirmed the diagnosis of

osteosarcoma. One patient had a previous open biopsy which showed Ewing's sarcoma and PCNB was subsequently done to evaluate the effects of neoadjuvant chemotherapy. PCNB findings were consistent with the effects of the chemotherapy. The remaining two patients had repeat PCNB and the histopathological findings were consistent with the initial biopsies. One of these patients was known with Ewing's sarcoma and deteriorated to stage four cancer despite neoadjuvant chemotherapy. The repeat PCNB in this case did not show any effects of chemotherapy. In the last case, the patient was known with Hodgkin's lymphoma from a previous lymph node biopsy and PCNB findings correlated with the initial diagnosis.

Out of the nine patients with non-diagnostic PCNB (see Table 3.5), five met the inclusion criteria for determining diagnostic accuracy. Three out of four that were excluded, were lost to follow up without a clear diagnosis. A decision was taken to clinically monitor the fourth patient without an alternate sampling method as the lesion was deemed benign. In the remaining five patients that were included, one patient underwent an excisional biopsy which showed a periosteal chondroma. In one case, the initial PCNB failed to diagnose metastatic thyroid carcinoma. While in another case, the PCNB specimen revealed a necrotic bone, but a subsequent resection specimen confirmed bone necrosis. The latter patient sustained a displaced pathological neck of femur fracture treated with a total hip replacement (THR). The resected femoral head showed only necrosis, presumably, a case of avascular necrosis. Assuming that the latter diagnosis is correct, a tumour was successfully excluded by PCNB. In another case, PCNB showed reactive plasmacytosis which was confirmed by a subsequent excisional biopsy which ruled out malignant infiltration. In the last case, the patient sustained a low energy fracture, and PCNB showed derivation from the fracture site which was subsequently confirmed by an incisional biopsy. The latter patient was a middle-aged female known with a longstanding Human Immunodeficiency virus (HIV) on antiretrovirals.

The final diagnoses of all 22 cases (17 diagnostic and five non-diagnostic) were correlated with the initial diagnoses proposed by PCNB to determine diagnostic accuracy (see Table 3.7).

Table 3.7: PCNB diagnosis compared to the final definitive diagnosis

PCNB diagnosis	Lesion site	Type of surgical specimen	Final definitive diagnosis
Conventional osteoblastic osteosarcoma	LL (Proximal tibia)	Above knee amputation (AKA)	Conventional osteoblastic osteosarcoma
Metastatic adenocarcinoma	Pelvis (Acetabulum)	Gastric incisional biopsy	Adenocarcinoma
Ewing's sarcoma	LL (Femur)	Previous open biopsy	Ewing's sarcoma
Metastatic thyroid carcinoma	Pelvis (Acetabulum)	Thyroidectomy	Papillary thyroid carcinoma
Osteosarcoma	LL (Proximal femur)	Hip disarticulation	Chondroblastic osteosarcoma
Chondrosarcoma	LL (Proximal femur)	Tumour resection	Chondrosarcoma
Conventional osteosarcoma	LL (Proximal tibia)	Tumour resection	Conventional osteosarcoma
Ewing's sarcoma	LL (Tibia)	Repeat core needle	Ewing's sarcoma
Giant cell tumour of bone	LL (Distal femur)	Curettage	Giant cell tumour of bone
Hodgkin's Lymphoma	LL (Distal femur)	Lymph node biopsy & repeat PCNB	Hodgkin's lymphoma
Conventional osteoblastic osteosarcoma	LL (Distal femur)	Limb ablation (AKA)	Conventional osteoblastic osteosarcoma
Giant cell tumour of bone	LL (Distal femur)	Curettage	Giant cell tumour of bone
Conventional Chondroblastic osteosarcoma	LL (Proximal Tibia)	Tumour resection	Conventional Chondroblastic osteosarcoma
Conventional Osteoblastic Osteosarcoma	LL (Distal Femur)	AKA	Conventional osteoblastic osteosarcoma
Conventional Osteoblastic Osteosarcoma	LL (Femur shaft)	Total femur resection	Conventional Osteoblastic Osteosarcoma
Conventional Osteoblastic Osteosarcoma	UL (Proximal humerus)	UL forequarter amputation	Conventional Osteoblastic Osteosarcoma
Conventional high-grade osteosarcoma	UL (Distal radius)	Above elbow amputation	Conventional high-grade osteosarcoma
Reactive plasmacytosis	LL (Proximal humerus)	Excisional biopsy	No infiltrative malignancy
Trilinear haematopoiesis	Pelvis (Ilium)	Follicular thyroid carcinoma	Metastatic thyroid carcinoma
Atypical cells	LL (Proximal tibia)	Repeat PCNB (Ultrasound-guided) & tibial resection	Conventional osteoblastic osteosarcoma
Necrotic bone	LL (Proximal femur)	Excisional biopsy	Periosteal chondroma
Derivation from fracture site	LL (Proximal femur)	Incisional biopsy	Derivation from fracture site

All but three of the 22 final diagnoses correlated with the PCNB findings. PCNB positively and correctly identified a musculoskeletal tumour in 17 cases (n = 17). PCNB correctly ruled out a musculoskeletal tumour in three patients (n = 3). PCNB incorrectly ruled out a tumour in the remaining two patients (n = 2). Assuming that these final diagnoses are correct, diagnostic accuracy was calculated at 86.4% (19 of 22). Sensitivity and specificity of PCNB were 89.5% (17 of 19) and 100% (3 of 3), respectively. Positive predictive value (PPV) and negative predictive value (NPV) were calculated at 100% and 60%, respectively (see Table 3.8). False negative rate for PCNB was calculated at 10.5% (2 of 19).

Table 3.8: Sensitivity, Specificity, PPV and NPV

	Tumour	**No tumour**	**Total (*n*)**
Positive PCNB	17	0	17
Negative PCNB	2	3	5
Total	19	3	22

The number of diagnostic and non-diagnostic PCNB for different lesion types is indicated in Table 3.9. The percentage of lytic tumours was 76.9% (30 of 39) for diagnostic PCNB and 66.7% (6 of 9) for non-diagnostic biopsies. For sclerotic tumours, it was 5.1% (2 of 39) and 11.1% (1 of 9) for diagnostic PCNB and non-diagnostic PCNB, respectively. Lastly, the percentage in mixed tumours was 17.9% (7 of 39) and 22.2% (2 of 9) for diagnostic PCNB and non-diagnostic PCNB, respectively. Diagnostic PCNB included more lytic tumours (30 0f 39), followed by mixed tumours (7 of 39). Only two of 39 diagnostic PCNB were in sclerotic tumours. Non-diagnostic PCNB included more lytic tumours (6/9), followed by mixed tumours (2/9). Only one of the nine non-diagnostic PCNB was in a sclerotic tumour (1/9). The difference in proportions amongst the three groups (lytic *versus* mixed *versus* sclerotic) was compared using the Fisher's exact test. The difference was not statistically significant (p = 0.524). The difference between lytic *versus* sclerotic lesions was also sought and found to be statistically not significant (p = 0.457)

Table 3.9: Number of diagnostic and non-diagnostic PCNB according to lesion type for 48 bone tumours

	Diagnostic (*n* = 39)	**Non-diagnostic (*n* = 9)**
Lytic (n = 36)	30/39 (76.9%)	6/9 (66.7%)
Mixed (n = 9)	7/39 (17.9%)	2/9 (22.2%)
Sclerotic (n = 3)	2/39 (5.1%)	1/9 (11.1%)

3.9. Complications

Out of the 49 PCNB performed, there were no major complications. However, one patient (2.0%) developed a haematoma immediately post-operatively, which did not require any form of special medical treatment other than a compression bandage and observation. The haematoma subsequently resolved and did not result in alteration of the course of patient management. All patients were followed up as per standard protocol after the procedure, to evaluate for late complications.

CHAPTER 4: DISCUSSION

Recent studies increasingly show that diagnostic yield and accuracy of PCNB is comparable to that of an open biopsy in musculoskeletal tumours. Our study supports the new evidence as we obtained a diagnostic yield of 81.6% and diagnostic accuracy of 86.4%. In addition to the appealing diagnostic strength of PCNB, this technique is associated with few complications. No major complications were observed in our study.

4.1 Diagnostic yield

In our study, PCNB yielded adequate tissue samples to allow pathologists to make a histopathological diagnosis in 81.6% (40 of 49) of the cases. Although this is a combined diagnostic yield for both bone and soft tissue, when distinguished, the yield is 82.9% (39 of 48) and 100% (1 of 1), respectively. The diagnostic yield of 100% for soft tissue is most likely skewed and not clinically significant as only one such case was analysed. This reasoning is further supported by the fact that, most high-powered studies have shown that PCNB in bone lesions yield better and is more accurate than in soft tissue lesions [1,2,5]. Another explanation for the low number of PCNB cases in soft tissue tumours is the fact that, in the reported literature, the success of the procedure was enhanced by the use of sophisticated image-guidance modalities [5,6,16-18,20].

In our setting, resources such as CT and MRI are very scarce and are in most cases, reserved for imaging of immediate life and/or limb-threatening conditions. Therefore, we generally opt for an anatomically planned open biopsy in majority of suspected soft tissue tumour cases to maximise the chance of obtaining a representative sample. PCNB might easily be repeated without a significant increase in morbidity or complications specifically when the initial sample is non-diagnostic [13,26]. Majority of our non-diagnostic PCNB indicated a non-representative sample and this can be mitigated by employing some form of image-guidance modality during a repeat PCNB, if available resources allow. Diagnoses from PCNB are considered reliable as evidenced by the high diagnostic accuracy as determined by final diagnoses made from surgical specimens. Our findings are in agreement with those from similar previous studies as follows, Wu et al. in their high-powered study, reported a diagnostic yield of 91.6% in bone lesions and 89.3% in soft tissue lesions which proved not to be statistically significant. They also indicated

the lack of difference in results between malignant and benign tumours (bone and soft tissue lesions) [22]. Crenn et al. reported a diagnostic yield of 84.7% in a retrospective monocentric study of 196 patients with primary bone tumours [19]. Similarly, Li et al. reported a diagnostic yield of 81.5% in another retrospective study involving 162 patients [18].

Unlike other studies that reported higher diagnostic yields, the majority of the tumours diagnosed in our study were primary bone tumours, which tend to be heterogenous. Inclusion of the more homogenous metastatic bone tumours results in a higher-than-average diagnostic yields as they are likely to contain diagnostic tumour cells [2]. In some studies, the diagnostic yield of PCNB was enhanced by the incorporation of intraoperative frozen section to confirm that a diagnostic material has been obtained [1,16]. Although previous similar studies have been conducted in varies institutions worldwide, we strongly believe that our study at our institution (the largest hospital in Africa and the third largest in the world) provides additional beneficial data tailored to resource-constrained institutions especially in the South African context.

4.2 Diagnostic accuracy

We obtained a diagnostic accuracy of 86.4% in our study specifically for bone tumours. The outcome of PCNB correlated well with the final definitive diagnoses derived from the surgical specimens. Our results are consistent with that published in recent literature. Crenn et al. reported PCNB diagnostic accuracy of 91.7% in a study which evaluated 197 cases of primary bone tumours [19]. In a retrospective study of 77 patients, Pohlig et al. reported a diagnostic accuracy of 100% for PCNB and 93.3% for open biopsy [6]. Although the PCNB results were superior, they were however not statistically significant ($p > 0.05$), further cementing the evidence that there is no difference in accuracy between the two sampling techniques [1,6]. In our study, no conclusions can be drawn for PCNB in soft tissue tumours as only one such procedure was performed and thus, the information obtained is of no statistical or clinical value. The reported diagnostic accuracy in literature for soft tissue tumours varies from 45.6% to 100%. The main reason for this wide range is exclusion of non-diagnostic samples by some authors which improves apparent accuracies [5]. In the aforementioned cited study by Pohlig et al., the authors indicated a diagnostic accuracy of 92.9% and 98.0% for PCNB and open biopsy, respectively.

In contrast, Kasraeian et al. reported overall diagnostic accuracy of PCNB of 45.6% in soft tissue tumours in a level one prospective diagnostic study which comprised of 57 patients [5]. Their study compared FNA, followed by PCNB and then incisional biopsy of the same mass [5]. However, the study only included palpable masses and excluded deep-seated masses which has a potential to skew the results [5].

Furthermore, the heterogenous nature of the studies in recent literature adds to the discrepancies in diagnostic yield and diagnostic accuracy. The use of more advanced image-guidance modalities (e.g. contrast CT and MRI scan) compared to anatomically based PCNB, aggravate the already existing disparity. In our study, none of the tumours were erroneously diagnosed as benign and turned out to be malignant at surgical resection or vice versa. We also did not observe any discrepancies between the diagnoses derived from diagnostic PCNB when compared to the final diagnoses derived from surgical specimens.

4.3 Non-diagnostic PCNB

This non-diagnostic rate is somehow in line with those reported in some studies. Pramesh et al. reported a non-diagnostic rate of 11% in a prospective study of 137 core biopsies using a Jamshidi needle [24]. Taupin et al. reported a non-diagnostic rate of 6.8% in a retrospective analysis of 73 patients with osteosarcoma [8]. The majority of the non-diagnostic PCNB (n = 5) in our study, were due to the non-representation of the suspected lesion in the sampled tissue, which highlights the importance of diverse sampling.

Part of the explanation for a non-representative sample is the tendency for musculoskeletal sarcomas to outstrip their blood supply as they enlarge leading to areas of central necrosis [5]. This is because sarcomas grow centripetally and therefore have viable cells in the periphery [10]. This shortcoming can easily be mitigated by the use of suitable image-guidance during a repeat PCNB to identify parts of the tumour that will yield diagnostic biopsy material [17]. This strategy is employed to maximise the amount of biopsy tissue that is potentially representative.

Rarely, an open biopsy is required for sufficient tissue sampling, however, this is associated with significant complications and morbidity. Similarly, Li et al. in a retrospective study

evaluating factors influencing diagnostic yield of CT-guided PCNB for bone lesions, attributed the common reason for a non-diagnostic biopsy to necrosis and reactive bone, respectively [18].

Expectedly, in our study, the average number of biopsy cores obtained in the non-diagnostic group was two (range 1 to 3), which is lower than the recommended by published literature. Tong et al. recommended that a patient with a negative yield be monitored closely and that if there are any notable discrepancies among clinical, radiological and biopsy findings, an open biopsy must be performed to ascertain the diagnosis [13]. It is important to note that not all PCNB misdiagnoses can be corrected by open biopsy [13,16]. Non-diagnostic open biopsies occur in approximately 5% of cases where it is performed primarily [16].

Taupin et al. embarked on a retrospective study of 73 patients with osteosarcoma in an attempt to identify criteria that may predict a failed core needle biopsy and were unable to establish any significant predictors of failure, even sclerotic lesions with more than 50% bone condensation [8]. This is in contrast to the earlier findings by Wu et al., where they found that diagnostic yields are higher in lytic lesions as compared to sclerotic ones. They also indicated that histological architecture (heterogeneous *versus* homogeneous) of the original tumour to be a significant variable. The more heterogenous soft tissue tumours (e.g. liposarcoma and synovial sarcoma) had a lower diagnostic yield compared to the more homogenous metastatic bone tumours [6]. In our study, the majority (6 of 9) of non-diagnostic PCNB were in lytic lesions. One explanation for this result is the fact that 75% (36 of 48) of all bone tumours were lytic in nature. However, when comparing proportions amongst the three groups (sclerotic *versus* mixed *versus* lytic), 33.3% (1 of 3) of sclerotic lesions were non-diagnostic compared to 22.2% (2 of 9) and 16.7% (6 of 36) for mixed and lytic lesions, respectively. However, this difference was not statistically significant ($p = 0.524$).

4.4 Common musculoskeletal tumour in our setting

In our study, the most commonly diagnosed malignant tumour was osteosarcoma ($n = 20$) followed by lymphoma ($n = 3$) and Ewing's sarcoma ($n = 3$). The common frequency of osteosarcoma in our study is consistent with the findings in previous similar reports. Taupin et al. stated that osteosarcoma is the most frequent malignant bone tumour in adolescents and young adults and represents 15% of all primary tumours confirmed by biopsy [8]. The commonest benign tumour diagnosed in our study was giant cell tumour of bone ($n = 3$), this is

consistent with most reports in literature [2,19]. Within the orthopaedic fraternity, it is widely accepted that multiple myeloma is most common primary malignancy of bone. Although this is true; the diagnosis is often made via a constellation of clinical signs, haematological investigations and imaging, supplemented by urine investigations. Rarely, a biopsy of a single suspicious lesion is undertaken and in which case, a solitary plasmacytoma is diagnosed. In our study only two patients were diagnosed with plasmacytoma of bone.

4.5 Lesion type

Previous studies in the reviewed literature indicated that diagnostic yield is higher in lytic lesions compared to sclerotic lesions. The most common cited reason for this discrepancy is that sclerotic lesions are masked by a tough reactive sclerosis making the tumour relatively acellular [18]. Li et al. reported a diagnostic yield of 89.9% and 48.5% in lytic and sclerotic bone lesions, respectively [18]. In the cited study, the authors also reported that a lytic lesion is 12 times likely to have a definitive diagnosis than a sclerotic lesion [18]. In our study, of the nine non-diagnostic PCNB, two were in sclerotic lesions, six were performed in lytic lesions and the remainder in a mixed lesion. The possible explanation for these contradicting results is the under-representation of sclerotic lesions in the study population (n = 3).

4.6 Non-diagnostic biopsies and alternating sampling methods

In our study, PCNB was non-diagnostic in 9 (18.4%) where pathologists could not make a definitive histopathological diagnosis. Diagnosis was subsequently obtained in five out nine of the non-diagnostic biopsies either through a repeat PCNB or surgical excision. This is comparable to data published in recent reports with non-diagnostic rates up to 16% [19]. Skrzynski et al. in a prospective analysis of 62 patients reported a non-diagnostic rate of 13% (8 of 62) [25]. In our study, out of the nine non-diagnostic PCNB, the lesion in question was not represented in six. Normal tissue was reported in five, necrotic bone in one case, fracture derivation in one case and reactive plasmacytosis in the remainder. In the last case, atypical cells were identified but the sample was not adequate to allow the pathologists to make a clear meaningful diagnosis [25].

Based on the clinical and imaging findings, an alternate sampling method was employed to safe-guard against missing an underlying aggressive lesion. Unfortunately, three patients were

lost to follow up without a tissue diagnosis, one so after a repeat PCNB. One patient underwent a confirmatory incisional biopsy which correlated with PCNB diagnosis of fracture derivation and patient's final diagnosis confirmed as a low energy fracture of the proximal femur. A decision was taken to monitor one patient following a rigorous biopsy specimen examination by two senior pathologists on separate occasions. The lesion in the latter patient was deemed benign hence no further investigations. Two patients subsequently underwent excisional biopsy. Of these, one was a patient with a pathological neck of femur fracture undergoing a total hip replacement. The resected head was sent for histopathological assessment and showed bone necrosis and normal trilinear haematopoiesis. In the other patient post excisional biopsy, the specimen yielded a benign tumour. In the last patient with a non-representative sample, an ultrasound guided biopsy was undertaken and revealed an osteoblastic osteosarcoma. In the only patient with an inadequate but otherwise representative specimen yet non-diagnostic, PCNB was repeated and yielded metastatic thyroid carcinoma.

Most published studies recommend a repeat PCNB or an open biopsy in the event of a non-diagnostic initial PCNB to make a diagnosis [13,26]. Some authors advise against the indiscriminate use of PCNB, especially in soft tissue lesions as they are notorious for their heterogenous nature which demands an evaluation of tissue architecture for histopathological diagnosis [1,5,9]. Amongst these tumours, are haemangiomas, schwannomas, liposarcomas and synovial sarcomas. A surgical biopsy is recommended in these cases when such diagnoses are suggested by clinical and imaging evaluation [9].

4.7 Complications

The prime advantage of PCNB is the associated low complication rates. The overall complication rate observed in our study was 2.0% (n = 1) which consisted of only a haematoma that resolved spontaneously. The low complication rate in our study is partly attributable to strict adherence to sarcoma biopsy principles. The danger associated with a large haematoma is its ability to dissect through soft tissues and subcutaneous tissues and contaminate a large part of the extremity, rendering limb salvage attempts futile [1]. Our findings are consistent with complication rates reported in earlier studies. In most of the studies, complication rates less than 1% have been reported [10,13]. Tong et al. in their retrospective study comprised of 341 patients, reported a complication rate of 0.29% (1 of 341) when evaluating the diagnostic

value of PCNB in acral bone tumours [13]. Their complication included a haematoma, which did not require any form of specialised intervention other than a simple pressure dressing, similar to our case [13]. However, Kasraeian et al. indicated that core biopsy complications ranged between 0% and 7.4% and amongst the most commonly reported were haematoma, bleeding and infection [5].

It is important to also note that although the process of acquiring a tissue sample does not directly promote metastatic spread, it increases the risk of local dissemination and therefore local recurrence [1,3]. Recent improvements in the management of malignant musculoskeletal tumours regarding chemotherapy and radiation therapy have resulted in a trend towards limb-salvage surgery instead of the old-fashioned limb ablation [3]. This type of treatment strategy can be compromised by complications associated with the sampling procedure itself [1,3]. In the majority of cases, this is due to seeding of tumour cells across multiple anatomical compartments or adjacent to major neurovascular structures [1,3]. Unlike malignant tumours, sampling benign tumours is relatively safe because tumour contamination is not of major concern unless a benign-aggressive tumour (e.g. giant cell tumour of bone) is involved [3]. Compared to PCNB, complication rates in open biopsy are reported to be as high as 17.3% [2]. Unfortunately, up to 8.5% of these adversely affect patient's prognosis [3].

Additionally, due to the simplicity of the procedure, it can be performed on outpatient basis further expanding costs savings. Previous cost analysis studies comparing estimations costs in CT-guided biopsy and open surgical biopsy proved the cost-effectiveness of PCNB in most musculoskeletal tumours [7]. The procedure is expected to be even more economical when fluoroscopy is used for image-guidance in lieu of the more expensive and radiotoxic CT scanner.

CHAPTER 5: CONCLUSION

PCNB is safe, effective and associated with fewer complications in bone tumours and selected soft tissue tumours. The diagnostic yield and diagnostic accuracy of such a procedure, especially in bone lesions, is high and comparable to the gold standard i.e., open biopsy. A negative PCNB especially in the event of a suspected malignancy, should be regarded as not exclusionary. As a result, non-diagnostic PCNB should be repeated or an alternate sampling method employed such that detrimental consequences of a missed diagnosis can be circumvented. PCNB is not only accurate in providing a diagnosis but, it is also of notable clinical value and facilitates optimal clinical management. Open biopsy must be reserved for unsuccessful PCNB or when clinical and imaging manifestations are inconsistent with PCNB results in difficult cases. Further high-powered multicentre studies will allow for solidified recommendations in resource-strained institutions.

5.1. RECOMMENDATIONS

- We recommend that PCNB be performed as first-line tool to obtain sampling specimen in musculoskeletal tumours particularly of osseous origin.
- We recommend that PCNB be repeated or open biopsy performed when the initial PCNB is non-diagnostic.

REFERENCES

1. Errani C, Traina F, Perna F, Calamelli C, Faldini C. Current concepts in the biopsy of musculoskeletal tumours. The Scientific World Journal. 2013; 2013: 1-7
2. Gharehdaghi M, Khooei A, Moradi A, Shoorin HR, Kachooei AR, Seyf P et al. 103 case to case compare of Core Needle biopsy results with open biopsy one in skeletal tumor. Life science journal. 2013; 10: 245-250
3. Liu PT, Valadez SD, Chivers SF, Roberts CC, Beauchamp CP. Anatomically based guidelines of core needle biopsy of bone tumors: implications for limb-sparing surgery. RadioGraphics. 2007; 27: 189-205
4. Fraser-Hill MA, Renfrew DL. Percutaneous needle biopsy of musculoskeletal lesions: 1. Effective Accuracy and Diagnostic Utility. AJR. 1992; 158: 810-812
5. Kasraeian S, Allison DC, Ahlmann ER, Fedenko AN, Menendez LR. A comparison of fine-needle aspiration, core biopsy and surgical biopsy in the diagnosis of extremity soft tissue masses. Clinical orthopaedics and related research. 2010; 468:2992-3002
6. Pohlig F, Kirchhoff C, Lenze U, Schauwecker J, Burgkart R, Rechl H et al. Percutaneous core needle biopsy *versus* open biopsy in diagnostics of bone and soft tissue sarcoma. European journal of medical research. 2012; 17: 29
7. Logan PM, Conell DG, O'conell JX, Munk PL, Janzen DL. Image-Guided Percutaneous biopsy of musculoskeletal tumors: An algorithm for selection of specific biopsy techniques. AJR. 1996; 166: 137-141
8. Taupin T, Decouvelaereb AV, Vaz G, Thiessea PC. Accuracy of core needle biopsy for the diagnosis of osteosarcoma. Diagnostic and interventional imaging. 2016; 97: 325-329
9. Sung K, Seo S, Shon M. Diagnostic value of needle biopsy for musculoskeletal lesions. International orthopaedics. 2009; 33: 1701-1706
10. Agarwal M, Puri A. Biopsy for musculoskeletal tumours – An orthopaedic surgery guide. The journal of Maharashtra orthopaedic association. 2006; 4: 162- 169
11. Seng C, Png W, Tan MH. Accuracy of core needle biopsy for musculoskeletal tumours. Journal of orthopaedic surgery. 2013; 21: 92-95
12. Gharehdaghi M. biopsy in musculoskeletal tumours. ABJS. 2014; 2: 128-129
13. Tong Z, Zhang M, Chen B, Zhu Y, Wei J, LI X. use of percutaneous core needle biopsy for diagnosing acral bone tumors. Journal of bone oncology. 2017; 6: 32-36
14. Jamshidi K, Bagherifard A. Biopsy of musculoskeletal tumours; current concepts review. Shafa ortho Journal. 2015; 2(1): e452

15. Zile S. Kundu. Classification, imaging, biopsy and staging of osteosarcoma. Indian journal of Orthopaedics. 2014; 48(3): 238-246
16. Adams SC, Potter BK, Pitcher DJ, Temple T. office-based core needle biopsy of bone and soft tissue malignancies. Clinical orthopaedics and related research. 2010; 468(10): 2774-2780
17. Torriani M, Etchebehere M, Amstalden EMI. Sonographically guided core needle biopsy of bone and soft tissue tumors. Journal of ultrasound in medicine. 2002; 21:275-281
18. Li Y, Du Y, Luo TY, Yang HF, Yu JH, Xu XX. Factors influencing diagnostic yield of CT-guided percutaneous core needle for bone lesions. Clinical Radiology. 2014; 69: 43-47
19. Crenn V, Vezole L, Bouhamama A, Meurgey A, Karanian M, Marec-Bérard P et al. Percutaneous Core Needle Biopsy Can Efficiently and Safely Diagnose Most Primary Bone Tumours. Diagnostics. 2021; 11:1552
20. Qi D, Zhao M, Hu T, Zhang G. Diagnostic yield of percutaneous core needle biopsy in suspected soft tissue lesions of extremities. Journal of International Medical Research. 2019; 47: 2599-2606
21. Charan J, Biswas T. How to calculate sample size for different study designs in medical research? Indian Journal of Psychological Medicine. 2013
22. Wu JS, Goldsmith JD, Horwich PJ, Shetty SK, Hochman MG (2008) Bone and soft-tissue lesions: what factors affect diagnostic yield of image-guided core-needle biopsy? Radiology 248:962–970
23. RA Sardenberg, de Figueiredo LP, Haddad FJ, Gross JL, Younes RN. Pulmonary metastatectomy from soft tissue sarcomas. Clinical Science. 2010;65(9):871-876
24. Pramesh CS, Deshpande MS, Pardiwala DN, Argawal MG, Puri A. Core needle biopsy for bone tumours. European Journal of Surgical Oncology. 2001; 27: 668-671
25. Skrzynski MC, Biermann JS, Montag A, Simon MA. Diagnostic accuracy and charge-savings of outpatient core needle biopsy compared with open biopsy of musculoskeletal tumors. The Journal of Bone and Joint Surgery. 1996; 78:644–649.
26. Wu SJ, McMahon CJ, Lazano-Calderon S, Kung JW. Utility of Repeat Core Needle Biopsy of Musculoskeletal Lesions With Initially Nondiagnostic Findings. American Journal of Roentgenology. 2017; 208:609-616

APPENDIX A: DATA COLLECTION SHEET

Patient ID	
Age	
Gender ▪ Male ▪ Female	
Presentation ▪ Pain ▪ Mass ▪ Fracture	
Lesion type ▪ Lytic ▪ Sclerotic ▪ Mixed	
Location ▪ Upper limb ▪ Lower limb ▪ Pelvis ▪ Other	
Core needle biopsy results ▪ Diagnostic ▪ Non-diagnostic	
Open biopsy results ▪ Diagnostic ▪ Non-diagnostic	
Definitive specimen ▪ Yes ▪ No ▪ Correlation	
Primary lesion ▪ Soft tissue ▪ Bone	
Nature ▪ Benign ▪ Malignant	
Complication/s	
Final diagnosis	

APPENDIX B: ETHICS CLEARANCE CERTIFICATE

UNIVERSITY OF THE WITWATERSRAND, JOHANNESBURG

R14/49 Dr Mabua Arthur Chuene

HUMAN RESEARCH ETHICS COMMITTEE (MEDICAL)

CLEARANCE CERTIFICATE NO. M200726

NAME: (Principal Investigator)	Dr Mabua Arthur Chuene
DEPARTMENT:	Orthopaedic Surgery Chris Hani Baragwanath Academic Hospital
PROJECT TITLE:	Yield of percutaneous core needle biopsies in musculoskeletal tumours
DATE CONSIDERED:	31/07/2020
DECISION:	Approved unconditionally
CONDITIONS:	
SUPERVISOR:	Dr Paul Kgagudi and Dr Maxwell Jingo
APPROVED BY:	CB Penny Dr CB Penny, Chairperson, HREC (Medical)
DATE OF APPROVAL:	01/12/2020

This clearance certificate is valid for 5 years from date of approval. Extension may be applied for.

DECLARATION OF INVESTIGATORS

To be completed in duplicate and **ONE COPY** returned to the Research Office Secretary on the Third Floor, Faculty of Health Sciences, Phillip Tobias Building, 29 Princess of Wales Terrace, Parktown, 2193, University of the Witwatersrand. I/we fully understand the conditions under which I am/we are authorized to carry out the above-mentioned research and I/we undertake to ensure compliance with these conditions.Should any departure be contemplated, from the research protocol as approved, I/we undertake to resubmit the application to the Committee. I **agree to submit a yearly progress report**. The date for annual re-certification will be one year after the date of convened meeting where the study was initially reviewed. In this case, the study was initially reviewed in **July** and will therefore be due in the month of **July** each year. Unreported changes to the application may invalidate the clearance given by the HREC (Medical).

Principal Investigator Signature

12/12/2020
Date

PLEASE QUOTE THE PROTOCOL NUMBER IN ALL ENQUIRIES

APPENDIX C: LETTER OF APPROVAL FOR EXTENSION OF DATA COLLECTION WINDOW

UNIVERSITY OF THE WITWATERSRAND, JOHANNESBURG

HUMAN RESEARCH ETHICS COMMITTEE (MEDICAL)

2022/02/14

Dr MA Chuene
School of Clinical Medicine
Department of Surgery
Division of Orthopaedic Surgery
Medical School
University

Sent by e-mail to: chuenemabua@gmail.com

Dear Dr Chuene

Re: **Protocol Ref No:** M200726
Protocol Title: *Yield of percutaneous core needle biopsies in musculoskeletal tumours*
Principal Investigators: Dr MA Chuene

I refer to your letter of 2022/02/02.

I confirm that we have noted and approve of your proposal to extend your data collection window to include records up to and including 2022/01/31.

Thank you for keeping us informed.

Yours Sincerely

.....
Mr I Burns
For the Human Research Ethics Committee (Medical)

.....
Dr CB Penny, Chairperson, Human Research Ethics Committee (Medical)

APPENDIX D: LETTER OF PERMISSION TO CONDUCT RESEARCH AT CHBAH

GAUTENG PROVINCE
HEALTH
REPUBLIC OF SOUTH AFRICA

MEDICAL ADVISORY COMMITTEE

CHRIS HANI BARAGWANATH ACADEMIC HOSPITAL

PERMISSION TO CONDUCT RESEARCH

Date: 6th July 2020

TITLE OF PROJECT:

Yield of percutaneous core needle biopsies in musculoskeletal tumours.

UNIVERSITY: Witswatersrand

Principal Investigator: Dr MA Chuene

Department: Orthopaedic Surgery

Supervisor : Dr PM Kgagudi

Permission Head Department (where research conducted): Yes

The Medical Advisory Committee recommends that the said research be conducted at Chris Hani Baragwanath Academic Hospital. The CEO / management of Chris Hani Baragwanath Academic Hospital is accordingly informed and the study is subject to:-

- **Permission having been granted by the Committee for Research on Human Subjects of the University of the Witwatersrand.**
- The Hospital will not incur extra costs as a result of the research being conducted on its patients within the hospital
- The MAC will be informed of any serious adverse events as soon as they occur
- Permission is granted for the duration of the Ethics Committee Approval.

.....
Recommended
(On behalf of the MAC)
Date: 6/7/2020

.....
Approved/~~Not Approved~~
Hospital Management
Date: 09/07/2020

APPENDIX E: LETTER OF PERMISSION TO ACCESS DATA FROM THEATRE REGISTRY

health and social development
Department: Health and Social Development
GAUTENG PROVINCE

Chris Hani Baragwanath
Academic Hospital
P.O. Bertsham
Soweto
2013
16 September 2020

To whom it may concern

This document is to prove that Chuene Mabua Arthur student number: 0604517R has been granted permission to access data from surgical theatre register at Chris Hani Baragwanath Academic Hospital for his research.

Project title: Yield of percutaneous core needle biopsies in musculoskeletal tumours.
Aim: to establish the diagnostic yield of percutaneous core needle biopsies in musculoskeletal tumours
Objectives: To determine the diagnostic yield of percutaneous core needle biopsy in musculoskeletal tumours at Chris Hani Baragwanath Academic Hospital Orthopaedic Tumour and Sepsis Unit
To determine the commonest musculoskeletal tumour diagnosed at CHBAH
To document complications related to percutaneous core needle biopsy in our context
Study population: Patients who underwent a percutaneous core needle biopsy at the Tumour and Sepsis Unit
Site: Chris Hani Baragwanath Academic Hospital, Orthopaedic Tumour and Sepsis Unit
Study period: 01 January 2016 to 18 June 2020
Study design: Retrospective

Theater Matron/ Gatekeeper
Chris Hani Baragwanath

APPENDIX F: LETTER OF PERMISSSION TO CONDUCT RESEARCH FROM ACADEMIC HEAD OF DEPARTMENT

LETTER OF APPLICATION FOR PERMISSION TO CONDUCT A RESEARCH STUDY AT CHRIS HANI BARAGWANATH ACADEMIC HOSPITAL

Dr MA Chuene
Orthopaedic Surgery Department
University of Witwatersrand
Johannesburg

18/06/2020

Head of Department Orthopaedic Surgery

Chris Hani Baragwanath Academic Hospital

Diepkloof

Johannesburg

RE: APPLICATION TO CARRY OUT RESEARCH AT CHRIS HANI BARAGWANATH ACADEMIC HOSPITAL, ORTHOPAEDIC TUMOUR AND SEPSIS UNIT

Dear Prof Ramokgopa

I am a postgraduate student training in the Division of Orthopaedic Surgery, University of Witwatersrand (Student Number: 0604517R, Cell phone Number: 0733568692) as a registrar, towards a Master of Medicine [MMED (Ortho)] degree.

As part of our training, we are expected to complete a research study, to be formulated into our report.

The details of my proposed study are as follows:

Title: Yield of percutaneous core needle biopsies in musculoskeletal tumours

Aim: To establish the diagnostic yield of percutaneous core needle biopsies in musculoskeletal tumours

Objectives:

To determine the diagnostic yield of percutaneous core needle biopsy in musculoskeletal tumours at Chris Hani Baragwanath Hospital, Orthopaedic Tumour and Sepsis Unit

To determine the commonest musculoskeletal tumour diagnosed at Chris Hani Baragwanath Academic Hospital

To document complications related to percutaneous core needle biopsy in our context

Study population: Patients who underwent a percutaneous core needle biopsy at the Orthopaedic Tumour and Sepsis Unit

Setting: Chris Hani Baragwanath Academic Hospital, Orthopaedic Tumour and Sepsis Unit

Study period: 01 January 2016 to 18 June 2020

Study design: Retrospective

My supervisors are Dr MP. Kgagudi and Dr M. Jingo, contact details: cell 078 4288229 and 076 7916768 respectively.

I hereby request your good office to grant me the permission to go ahead with the proposed study. I am looking forward to a prompt and positive reply.

Kind regards

Dr MA Chuene

Signature: _____

Email: chuenemabua@gmail.com

Approved
PROF MT RAMOKGOPA
02/07/2020.

APPENDIX G: LETTER OF PERMISSION TO ACCESS HISTOPATHOLOGICAL RESULTS

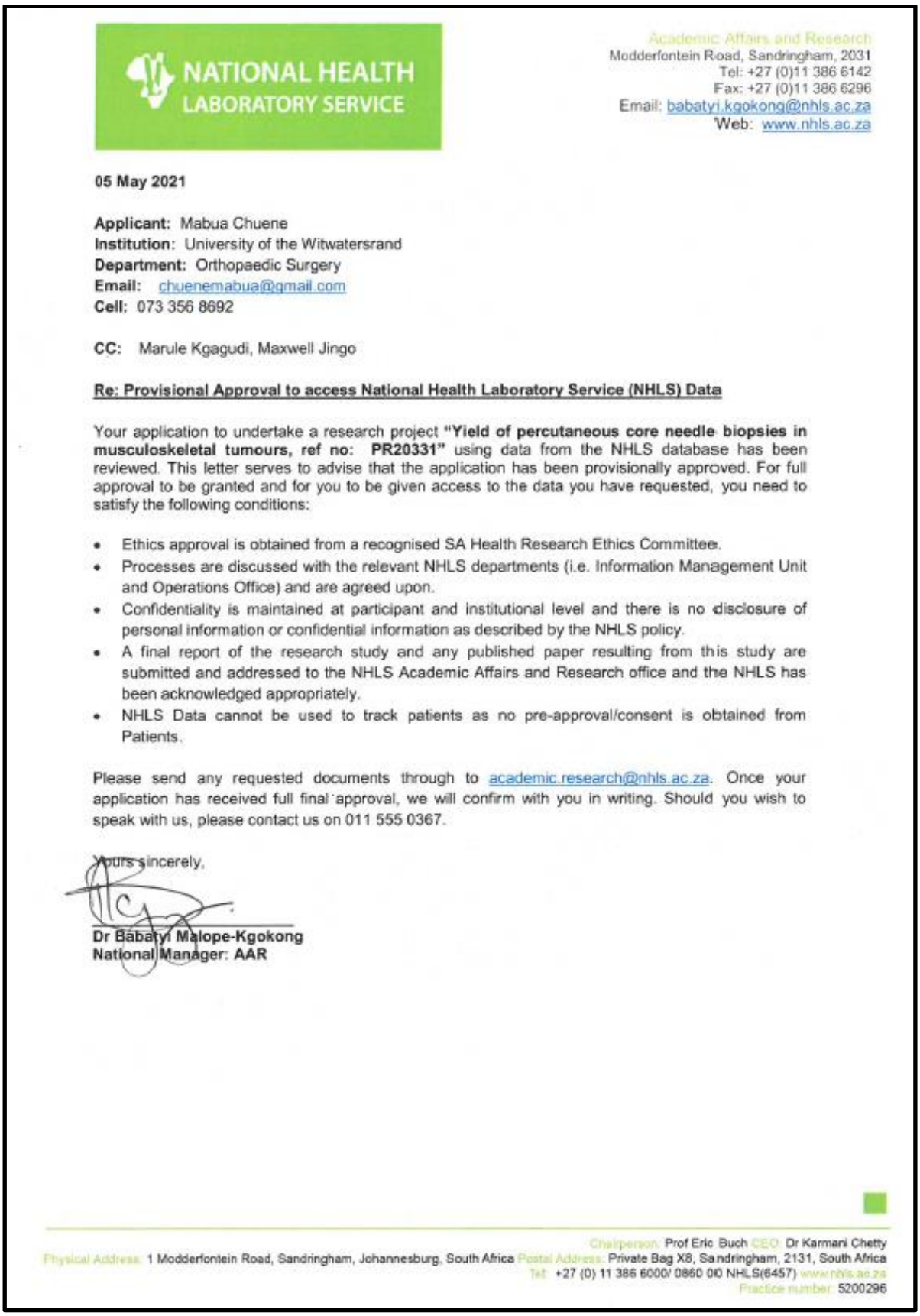

NATIONAL HEALTH LABORATORY SERVICE

Academic Affairs and Research
Modderfontein Road, Sandringham, 2031
Tel: +27 (0)11 386 6142
Fax: +27 (0)11 386 6296
Email: babatyi.kgokong@nhls.ac.za
Web: www.nhls.ac.za

05 May 2021

Applicant: Mabua Chuene
Institution: University of the Witwatersrand
Department: Orthopaedic Surgery
Email: chuenemabua@gmail.com
Cell: 073 356 8692

CC: Marule Kgagudi, Maxwell Jingo

Re: Provisional Approval to access National Health Laboratory Service (NHLS) Data

Your application to undertake a research project **"Yield of percutaneous core needle biopsies in musculoskeletal tumours, ref no: PR20331"** using data from the NHLS database has been reviewed. This letter serves to advise that the application has been provisionally approved. For full approval to be granted and for you to be given access to the data you have requested, you need to satisfy the following conditions:

- Ethics approval is obtained from a recognised SA Health Research Ethics Committee.
- Processes are discussed with the relevant NHLS departments (i.e. Information Management Unit and Operations Office) and are agreed upon.
- Confidentiality is maintained at participant and institutional level and there is no disclosure of personal information or confidential information as described by the NHLS policy.
- A final report of the research study and any published paper resulting from this study are submitted and addressed to the NHLS Academic Affairs and Research office and the NHLS has been acknowledged appropriately.
- NHLS Data cannot be used to track patients as no pre-approval/consent is obtained from Patients.

Please send any requested documents through to academic.research@nhls.ac.za. Once your application has received full final approval, we will confirm with you in writing. Should you wish to speak with us, please contact us on 011 555 0367.

Yours sincerely,

Dr Babatyi Malope-Kgokong
National Manager: AAR