

https://dspace.org/

Epidemiology clinical profiles and prognostic value of COVID19related cutaneous manifestations in African populations a rapid narrative review

Peter Nyasulu; J Tamuzi

WILEY-BLACKWELL
https://hdl.handle.net/10539/41037
WOS

Downloaded from a DSpace repository. https://dspace.org/

Check for updates

International Journal of Dermatology

Review

Epidemiology, clinical profiles, and prognostic value of COVID-19-related cutaneous manifestations in African populations: a rapid narrative review

Peter S. Nyasulu, MScMed, PhD, MACE[1,2] and Jacques L. Tamuzi, MBChB, MPH, MSc[1]

[1]Division of Epidemiology and Biostatistics, Department of Global Health, Faculty of Medicine and Health Sciences, Stellenbosch University, Cape Town, South Africa; and [2]Division of Epidemiology & Biostatistics, School of Public Health, Faculty of Health Sciences, University of the Witwatersrand, Johannesburg, South Africa

Correspondence
Peter S. Nyasulu, MSCMED, PHD, MACE
Division of Epidemiology and Biostatistics
Department of Global Health
Faculty of Medicine and Health Sciences
Stellenbosch University
Cape Town
South Africa
E-mail: pnyasulu@sun.ac.za

Conflict of interest: None.

Funding source: None.

doi: 10.1111/ijd.16872

Abstract

Background Skin manifestations' true prognostic value, and clinical and epidemiological pictures in SARS-CoV-2 infection in African populations are poorly described and understudied. More familiarity with COVID-19 cutaneous manifestations may aid in early clinical diagnosis or guide prognosis.

Methods In this literature review, we looked for potential studies published from December 2019 to March 2023 on COVID-19 cutaneous lesions in African populations. Our key questions were focused on the prognostic values of cutaneous manifestations related to COVID-19.

Results Our findings show that cutaneous manifestations of COVID-19 vary by country and severity of COVID-19, primarily multisystem inflammatory syndrome (MIS). Significant differences were also found between various dermatological lesions, primarily MIS, erythema multiforme-like, livedoid, vesicular, or varicella-like rashes, urticarial, maculopapular or morbilliform rashes, and chilblain-like or pernio-like rashes. There were 47.5% (115/242) of MIS cases reported in nine published African studies. Our findings also revealed that MIS may be diagnosed in 2–7 days due to early onset rash. Advanced age, obesity, diabetes, cardiovascular disease, HIV, tuberculosis, asthma, atopic disease, underweight, malnutrition, and malignancy were found to be associated with COVID-19 cutaneous manifestations in African populations.

Conclusions COVID-19-related skin manifestations in African populations are important as a driving force in COVID-19 prognosis.

Introduction

Cutaneous manifestations of COVID-19 are characteristic signs or symptoms of the coronavirus disease 2019 that occur in the skin. Cutaneous manifestations have been reported worldwide in patients infected with coronavirus disease 2019 (COVID-19). COVID-19 is caused by severe acute respiratory syndrome coronavirus type 2 (SARS-CoV-2) and presents with skin manifestations.[1,2] According to a review of the literature, cutaneous manifestations of COVID-19 have not been well documented, and studies in the African population showed to be lacking. In fact, many factors may interact to cause COVID-19 cutaneous manifestations. COVID-19 severity, comorbidities, preexisting dermatological conditions, gender, race, ethnicity, medications, drug interactions, allergies, and genetic factors are among those factors. This implies that cutaneous manifestations of COVID-19 in African populations may differ significantly from other settings in terms of epidemiology, clinical manifestations, and prognostics. Interestingly, skin lesions that appear before general symptoms or are the only sign of positive COVID-19 could be early indicators of disease, asymptomatic virus carriers, or warning signs of COVID-19 severity. Furthermore, some types of lesions appear before the more typical COVID-19 symptomatology, and some types of lesions are associated with a worse prognosis and disease progression.[3,4] One of the worst prognosis of COVID-19 symptomatology associated with skin lesions is multisystem inflammatory syndrome in children (MIS-C).

Cases of MIS-C or multisystem inflammatory syndrome in adults (MIS-A) are diagnosed late in African populations because the diagnosis is based primarily on hematological and biochemical parameters. MIS-C or MIS-A, on the other hand, encompasses a wide range of cutaneous manifestations that

International Journal of Dermatology 2024, **63**, 10–22 © 2023 The Authors. *International Journal of Dermatology* published by Wiley Periodicals LLC on behalf of the International Society of Dermatology.
This is an open access article under the terms of the Creative Commons Attribution-NonCommercial License, which permits use, distribution and reproduction in any medium, provided the original work is properly cited and is not used for commercial purposes.

may be considered precursors to MIS-C or MIS-A. As a result, predicting a more serious or severe course of SARS-CoV-2 infection would be easier. Furthermore, Africa has a high prevalence of human immunodeficiency virus/acquired immunodeficiency syndrome (HIV/AIDS), tuberculosis, and malnutrition.[5–8] Comorbidities and COVID-19 may interact in a variety of ways that may result in cutaneous manifestations. In COVID-19/HIV co-infected patients, cutaneous manifestations of herpes zoster (HZ), Kaposi sarcoma, histoplasmosis, and reactivation of latent varicella zoster virus (VZV) infection have already been reported.[9,10] Furthermore, depending on skin tone, the appearance and manifestation of any cutaneous pathology can vary.[11] Inflammatory skin conditions can manifest differently in people with darker skin than in people with lighter skin.[11] This implies that COVID-19 dermatological lesions in African populations should be sought because they can be heterogeneous, frequent, and varied. However, cutaneous manifestations related to COVID-19 are poorly described and understudied in African populations. Cutaneous manifestations may play a significant role in early detection of COVID-19 and may predict COVID-19 severity and mortality.

Literature review

From the current literature reviewed, the estimated incidence of cutaneous manifestations secondary to COVID-19 ranges between 4 and 20.4%.[12] A survey involving 11,544 people found that 17% of SARS-CoV-2 patients had skin manifestations as their initial symptom and 21% had skin symptoms as their only clinical evidence of illness.[13] The cutaneous manifestations reported around the world were mainly maculopapular, urticarial, pseudo-chilblain, and livedoid and papulovesicular rashes.[14,15] According to a review of 998 patients, the most prevalent cutaneous patterns were chilblain-like lesions (40.2%), maculopapular lesions (22.7%), urticarial lesions (89.9%), vesicular lesions (64.4%), and livedoid lesions (28.8%).[1,16] Another review including 34 studies around the world showed that acral lesions were the most common category identified (40.4% of all cases), followed by erythematous maculopapular rashes (21.3%), vesicular rashes (13.0%), urticarial rashes (10.9%), other ill-defined rashes (4.3%), vascular rashes within the spectrum of livedo/purpura/necrosis (4%), erythema multiforme-like eruptions (3.7%), and unspecified erythematous rashes (2.1%).[17] Finally, a review of 369 children and adolescents with cutaneous manifestations found that the most common COVID-19 cutaneous symptoms in this age group were chilblain-like lesions (67.5%), followed by erythema multiforme-like (31.7%) and to a varying degree varicella-like lesions (0.8%).[18] This appraisal of published literature showed that gathering dermatology-related data about geographical differences in the morphology and prevalence of reported COVID-19-associated cutaneous manifestations is essential in each country and region, particularly on the African continent.

Methods

In this narrative review, we looked for potential studies published from December 2019 to March 2023 on COVID-19 cutaneous lesions in African populations. Our key questions were focused on the prognostic values of cutaneous manifestations related to COVID-19 among African populations. In addition, this review also looks at the burden of cutaneous manifestations related to COVID-19 in Africa. We conducted a search in PubMed, Medline, Google Scholar, medRxiv, and bioRxiv using: "COVID-19" OR "2019 novel coronavirus" OR "Coronavirus disease 2019" OR "novel coronavirus" AND "skin" OR "rash" OR "cutaneous" OR "dermatology" OR "epidermis" OR "dermis" AND "African" OR "African Peoples" OR "African Peoples". Furthermore, we looked at studies that were conducted in other settings and incorporated COVID-19 risk factors associated with cutaneous symptoms that could be applicable to African populations. We included case reports, case series, and cohort studies. The distribution of included studies in African countries is depicted in Figure 1. We presented the findings narratively as well as with Tables 1–3 and Figures 1–3.

Epidemiologic characteristics of COVID-19 cutaneous manifestations in African populations

At the start of the COVID-19 pandemic, the prevalence of skin lesions was 0.2%, but the types of lesions and their characteristics were poorly described.[3,19] The reported frequency of dermatological changes ranged from 5 to 20% as the COVID-19 pandemic progressed.[3,20] Sachdeva et al. conducted a review of the literature on 72 COVID-19-related cutaneous manifestations and found that 12.5% of patients presented with cutaneous lesions prior to the onset of symptoms.[21] As a result, the occurrence of COVID-19-related cutaneous manifestations has steadily increased, paralleling the global spread of SARS-CoV-2. This could be explained by a variant of concerns (VOCs), as one study found that cutaneous manifestations were significantly more common in the Delta wave than in the Omicron wave.[22]

It is unknown how common COVID-19 cutaneous manifestations are in Africa. The prevalence of cutaneous manifestations in African populations was reported in five studies conducted on the continent. In Nigeria, two studies reported 7/161 (4.35%)[23] and 11/140 (7.86%) COVID-19 cutaneous manifestations.[24] In contrast, MIS-A reported a high incidence of cutaneous manifestations in South Africa with 58/68 (85.3%),[25] 10/20 (50%) in Kenya,[26] and Nachega et al. found a 6.3% (31/453) prevalence of COVID-19-related cutaneous manifestations in six Sub-Saharan African countries, including South Africa, the Democratic Republic of the Congo, Kenya, Uganda, Nigeria, and Ghana.[27] As a result, the prevalence of COVID-19

© 2023 The Authors. *International Journal of Dermatology* published by Wiley Periodicals LLC on behalf of the International Society of Dermatology.

13654632, 2024, 1, Downloaded from https://onlinelibrary.wiley.com/doi/10.1111/ijd.16872 by South African Medical Research, Wiley Online Library on [28/02/2024]. See the Terms and Conditions (https://onlinelibrary.wiley.com/terms-and-conditions) on Wiley Online Library for rules of use; OA articles are governed by the applicable Creative Commons License

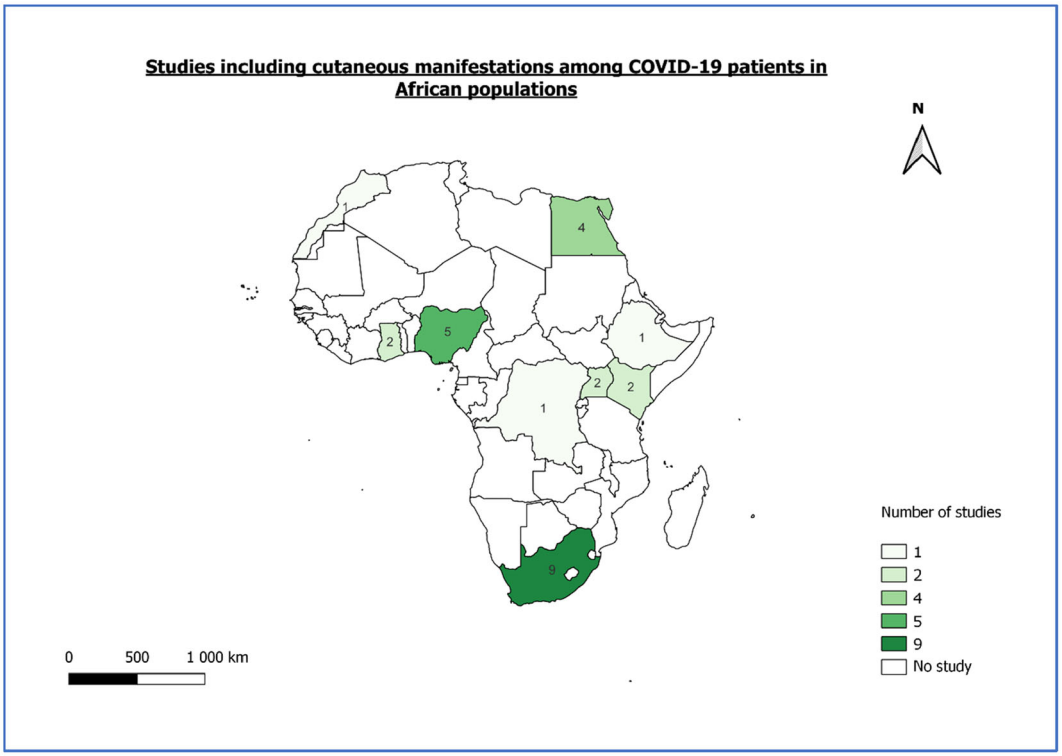

Figure 1 Studies that included cutaneous manifestations related to COVID-19 among African populations

cutaneous manifestations may vary significantly depending on the setting and COVID-19 severity. MIS-C or MIS-A were found to have a higher rate of COVID-19-related skin manifestations than other COVID-19 states in our study. According to an Egyptian study, 20.5% of asymptomatic COVID-19 patients had cutaneous lesions, 54.5% had mild COVID-19, 20.5% had moderate COVID-19, and 4.5% had severe COVID-19.[28] According to Table 2, MIS-C/Kawasaki-like disease or MIS-A is frequently associated with cutaneous manifestations in African COVID-19 patients. Risk factors such as age distribution, cardiovascular disease, diabetes, obesity, chronic lung disease, HIV, tuberculosis (TB), malnutrition, asthma, atopic diseases, and malignancy may also influence the epidemiology of COVID-19 cutaneous manifestations (Figure 2).

However, the epidemiology of cutaneous manifestations in African COVID-19 patients should be viewed with limitations. This is due to insufficiently informative reports on COVID-19 cutaneous manifestations and a scarcity of studies. Furthermore, the inability to perform a comprehensive dermatological examination, photographic record, histopathological and/or immunohistochemical analysis, and a scarcity of dermatologists in Africa to characterize COVID-19 cutaneous involvement are other challenges that impact the epidemiology of cutaneous manifestations in Africa. The clinical manifestations and outcomes of MIS-C in African populations highlight the importance of enhanced early diagnosis, treatment, reporting, and data collection to inform policymakers.

Pathophysiology of COVID-19 on cutaneous manifestations

The pathophysiology of COVID-19 is multifactorial, involving the innate immune system, humoral response, hypercoagulability, monocytic/macrophagic activation, and a significant increase in cytokines ("cytokine storm").[29,30] According to a study, the pathophysiological process that causes pulmonary involvement can also occur in the skin.[30] Skin manifestations in COVID-19 patients are attributed to inflammatory mediator overactivation, resulting in a cytokine storm and endothelial damage.[11,29] Direct viral effects on the endothelium and viral-induced vasculitis are the primary causes of cutaneous manifestations in COVID-19 patients.[11,31] Skin manifestations have been classified into two types based on pathophysiology: (1) inflammatory, as an immune response to viral nucleotides and (2) vascular, as a result of vasculitis, vasculopathy, and thrombosis.[29,32] Viral infections are associated with the activation of both innate and adaptive immune responses in terms of inflammation.[29] Endothelial damage caused by SARS-CoV-2 in the skin could be one of the pathogenesis's key mechanisms.[33] The monocytic-macrophage system exacerbates the immune response, resulting in a severe systemic inflammatory response.[29] Mast cell and basophil activation by viruses could explain lesions like urticaria and exanthems.[29] SARS-CoV-2 infection causes urticarial lesions by binding to the angiotensin-converting enzyme 2

 © 2023 The Authors. *International Journal of Dermatology* published by Wiley Periodicals LLC on behalf of the International Society of Dermatology.

13654632, 2024, 1, Downloaded from https://onlinelibrary.wiley.com/doi/10.1111/ijd.16872 by South African Medical Research, Wiley Online Library on [28/02/2024]. See the Terms and Conditions (https://onlinelibrary.wiley.com/terms-and-conditions) on Wiley Online Library for rules of use; OA articles are governed by the applicable Creative Commons License

Table 1 Clinical presentation of SARS-CoV-2-associated cutaneous manifestations in African populations

Cutaneous manifestation	Demographic characteristics	Clinical presentation	Topography	References
Multisystem inflammatory syndrome	Age range: 2.3–51 years. Males: 57.14% (80/140) Females: 42.86% (60/140)	Polymorphous pale rash on the trunk and flexors, swelling and scaling of the extremities, mucositis, chapped lips, etc.	Face, upper limbs, trunks, oral, hands, feet, palmar, plantar, and generalized rash	Demissie 2022; Onyeaghala 2021; Egbu 2020; Parker 2020; Sokunbi 2022; van Heerden 2022; Moodley 2021; Balkaran 2022; Ndudane 2020; Butters 2021; Sylverken 2021; Piloya 2022; Haoudar 2021; Webb 2020; Nachega 2022; Aly 2022; Ibrahim 2022
Erythema multiforme-like	Age range: 2.3–88 years. Males: 54.14% Females: 45.86%	Pale spots, papules, and blurred plates with target (3 rings) or with target (2 rings) of various sizes with bleeding and crusting in the left.	Chest, upper limb, lower limb, and generalized rash	Anaba 2021; Sokunbi 2022; Otrofanowei 2021
Livedoid	Age range: <5 years –88 years. Males: 49.7% Females: 50.3%	Livedo reticularis: symmetrical lacy starchy spots along the blood vessels forming a pale central ring. Livedo racemosa: irregular and asymmetrical blackish patches along the veins.	Chest, upper limb, lower limb, trunk, palms, and generalized rash	Anaba 2021; Farouk 2020; Chinniah 2023
Vesicular or varicella-like	Age range: 3–88 years. Males: 48.95% Females: 51.05%	Small monomorphic vesicles scattered on the trunk with mild or asymptomatic itching, pain, and burning sensation.	Chest, upper limb, lower limb, trunk, palms and generalized rash	Anaba 2021; Mostafa 2022; Otrofanowei 2021
Urticarial	Age range: 3–88 years. Males: 47.65% Females: 52.35%	Migratory, itching, swelling, bumps of varying size within 24 hours, without bruising or pigmentation ± Angioedema	Chest, upper limb, lower limb, trunk, palms, and generalized rash	Anaba 2021; Ndudane 2020; Farouk 2020; Mostafa 2022; Otrofanowei 2021; Chinniah 2023
Maculopapular or morbilliform	Age range: 3–70 years. Males: 44.1% Females: 55.9%	Itchy erythema in normal areas of the skin on the trunk and limbs.	Face, legs, trunk, and palms, and generalized rash	van Heerden 2022; Moodley 2021; Balkaran 2022; Mostafa 2022; Otrofanowei 2021; Piloya 2022; Chinniah 2023
Chilblain-like or pernio-like	Age range: 3–70 years. Males: 48.33% Females: 51.67%	Dull, erythematous papules, nodules, plaques, or, rarely, vesicular formations appear on the surface of the wing	Generalized, trunk, and palms	Mostafa 2022; Migowa 2022; Chinniah 2023

(ACE2) receptor and entering the cell via endocytosis, disrupting the ACE2 activity pathway, resulting in an increase in angiotensin II, disruption of antioxidant and vasodilatory molecules, and complement activation.[16,34] Similarly, Colmenero et al. found viral particles in the endothelium of erythema pernio-like lesions in children.[33] COVID-19 viral infection may cause lymphocytic vasculitis like thrombophilic arteritis caused by immune complex-activated cytokines.[21,35,36] The immune response to infection also activates Langerhans cells, resulting in vasodilation and spongiosis.[21,35,36] The presence of ACE2, the primary receptor for SARS-CoV-2 entering skin cells, may explain some of the vascular skin lesions associated with COVID-19 infection due to a significant immune antiviral response.[37,38] Maculopapular eruptions may be caused by SARS-CoV-2 particles and immune complex deposition that damage dermal vessels and cause lymphocytic vasculitis. These viral proteins have the ability to target Langerhans cells as well as keratinocytes.[16,39] Maculopapular exanthems are also commonly caused by drug hypersensitivity and T-cell-mediated delayed hypersensitivity. They can, however, occur as a result of a drug-induced and virus-induced immune stimulation interaction.[40,41] The emergence of morbilliform eruptions in viral infections other than COVID-19 is attributed to the activity of $CD4^+$ and $CD8^+$ T cells and cytokines against virally infected keratinocytes, endothelial cells, and fibroblasts. The main mechanism in drug-induced maculopapular rashes is the type IV hypersensitivity reaction, which involves T cells.[41] Varicella-like lesions develop because of a direct viral effect on keratinocytes. The SARS-CoV-2 spike protein receptor, ACE2, has been found to be expressed in basal keratinocytes.[16,39]

© 2023 The Authors. *International Journal of Dermatology* published by Wiley Periodicals LLC on behalf of the International Society of Dermatology.

13654632, 2024, 1, Downloaded from https://onlinelibrary.wiley.com/doi/10.1111/ijd.16872 by South African Medical Research, Wiley Online Library on [28/02/2024]. See the Terms and Conditions (https://onlinelibrary.wiley.com/terms-and-conditions) on Wiley Online Library for rules of use; OA articles are governed by the applicable Creative Commons License

Table 2 Characteristics of cutaneous manifestations and prognostic value in African populations

Study ID/ country	Age/sex	Topography	Risk factors/comorbidities	Cutaneous manifestations/rash onset	Outcomes
Anaba 2021/ Nigeria	The mean age of the patients was 54.4 ± 14.4 years (range 16–88 years); 54.7% were male.	Affected anatomical part whole body 2 (28.6%), chest 1 (14.2%), upper limb 1 (14.2%), lower limb 3 (43.0%)	Advanced age	Purpura: 2 patients (28.6%), Scaly patch: 1 patient (14.3%), Exanthema 1 patient (14.3%); Blister: 2 patients (28.4) and Urticaria 1 patient (14.3%)	71.4% of cutaneous manifestation patients had severe COVID-19 and 28.6% had moderate COVID-19
Demissie 2022/ Ethiopia	A 10-year girl	Oral, hands, and feet	Lower age	MIS-C: mucocutaneous inflammations/2 days rash onset	Severe COVID-19 and death
Onyeaghala 2021/Nigeria	A 12-year-old girl	Face, upper limbs, and trunks	Lower age	MIS-C: Pruritic rash/3 days rash onset	Severe COVID-19 and discharged
Egbu 2020/ Nigeria	A 37-year-old man	Widely distributed over the trunk	N/A	MIS-A: skin-colored papules that were perifollicular/1 week onset	Severe COVID-19 and discharged
Parker 2020/ South Africa	Three patients aged 15, 22, and 27 years	Generalized?	MIS-C	Mucocutaneous involvement resembling a viral exanthem	Severe COVID-19 and discharged
Sokunbi 2022/ Nigeria	Twenty-eight children and adolescents with a median age of 7.5 (IQR: 2.3–9.4) years. 16 males and 12 females	Palmar and plantar generalized	MIS-C	Palmar and plantar erythema occurred in 75.0% of children. Generalized polymorphous rash seen in 21 patients (75.0%) included desquamating rash in 23 patients (82.1%)/early diagnostic as erythema multiforme	Three children with critical COVID-19 were admitted to the ICU and others with severe COVID-19
van Heerden 2022/South Africa	Eleven patients with MIS had a median age of 20 years (range 14 –51 years). Six females and five males	Generalized	MIS-C or MIS-A (all), obesity (2), HIV (1), previous TB (1), and diabetes mellitus (1)	Mucocutaneous lesions described included a generalized erythematous maculopapular rash. Eight patients (72.7%) had generalized rash	All with severe and critical COVID-19 were admitted to the ICU
Moodley 2021/ South Africa	A 21-year-old man	Generalized	MIS-C	Generalized maculopapular rash/ before hospital admission	Severe COVID-19 and discharged
Balkaran 2022/ South Africa	A 30-year-old female	Legs	MIS-A	A transient nontender erythematous macular rash/before hospital admission	Severe COVID-19 and discharged
Ndudane 2020/ South Africa	A 14-year-old female	Face, trunk, back, and all the limbs	MIS-A	Erythematous urticarial rash/before hospital admission	Severe COVID-19 and discharged
Butters 2021/ South Africa	Sixty-eight children with MIS-C. children under 14 years old	Generalized	MIS-C	Rash: (85.3%)	Severe COVID-19 and discharged
Farouk 2020/ Egypt	A 33-year-old female	On the trunk, the skin lesions were extended to the upper and lower limbs including the palms	Hypertension	Morbilliform skin rash, erythematous patches, and urticarial lesions fading on pressure with itching/1 day before	Severe COVID-19 and discharged
Mostafa 2022/ Egypt	A total of 44 COVID-19-positive patients presented with skin affection. Their age ranged from 3 to 70 years, with a mean ± SD of 36.9 ± 16.7 years. (56.8%) females and 19 (43.2%) males	Generalized, trunk, and palms	Seven (15.9%) patients had associated comorbidity (four [9.1%] had diabetes mellitus, one [2.3%] had hypertension, one [2.3%] had hypothyroidism, one [2.3%] had leukemia, and one [2.3%] had systemic lupus erythematosus)	Urticaria: (24, 54.5%), followed by herpes simplex: (seven, 15.9%), herpes zoster: (four, 9.1%), papulosquamous: (three, 6.9%), papulovesicular: (two, 4.6%), acral lesions: (two, 4.6%), leukocytoclastic vasculitis: (one, 2.3%), and Kawasaki-like disease: (one, 2.3%)/before the onset of COVID-19 symptoms	Asymptomatic COVID-19: 20.5%, mild: 54.5%, moderate: 20.5%, severe: 4.5%
Otrofanowei 2021/Nigeria	Eleven confirmed with COVID-19. Male: female ratio of (2.3:1)	Face and trunk being the most affected sites and the commonest finding being papular eruptions	Hypertension: 43 diabetes mellitus/ impaired glucose tolerance: 32 asthma; 12 others: papillary urticaria, hepatitis B virus infection, thyroid disease, bronchitis, gastrointestinal disorders; 5 with chronic kidney disease, 4 with atopic/allergic dermatitis, 4 with rhinitis, and 4 with malignant tumors	Purpura: 1 Papular eruption: 6 Perifollicular eruptions: 1 Macular eruption: 1 Maculopapular eruption: 1 Petechiae: 1 Vesicular eruption: 1/early onset	Moderate and severe COVID-19

 © 2023 The Authors. *International Journal of Dermatology* published by Wiley Periodicals LLC on behalf of the International Society of Dermatology.

13654632, 2024, 1, Downloaded from https://onlinelibrary.wiley.com/doi/10.1111/ijd.16872 by South African Medical Research, Wiley Online Library on [28/02/2024]. See the Terms and Conditions (https://onlinelibrary.wiley.com/terms-and-conditions) on Wiley Online Library for rules of use; OA articles are governed by the applicable Creative Commons License

Table 2 Continued

Study ID/ country	Age/sex	Topography	Risk factors/comorbidities	Cutaneous manifestations/rash onset	Outcomes
Sylverken 2021/ Ghana	A 10-year-old male	Generalized	MIS-A	These signs raised a high suspicion for Kawasaki syndrome with differentials of COVID-19 infection and infectious mononucleosis/ before hospital admission	Severe COVID-19 and discharged
Piloya 2022/ Uganda	A 9-year-old female	Generalized	MIS-A	Generalized maculopapular nonitchy skin rash/7 days after the onset	Severe COVID-19 and discharged
Migowa 2022/ Kenya	Twenty children aged median (IQR) 3 (15.0) years from children were male (14 of 20)	Generalized	Children age inflammatory disorder hypertension/chronic cardiac disease asthma/chronic pulmonary disease	Peripheral cutaneous inflammation: (50%)	There were no documented mortalities
Haoudar 2021/ Marocco	Five children. The median age of the children was 7.8 years; three of them were boys	Generalized	Children age	MIS-A criteria for Kawasaki disease were met in all of them with a complete presentation	Severe COVID-19 and discharged
Webb 2020/ South Africa	Twenty-three children. Mean age of 6.59 (4.75 –8.43). 17 (73.9%) were males	Generalized	Children age	MIS-A with 20 (87.0%) with rash	All children have survived
Nachega 2022/ South Africa, DRC, Kenya, Uganda, Nigeria, Ghana	Thirty-one children. Median age (IQR): 5.9 (1.7–11.1). 52.4% were males	N/A	Cancer hypertension, chronic kidney disease chronic neurological disorders cardiac disease chronic lung disease hematological disorders HIV infection, and active tuberculosis	31/453 (6.3%) rash and 18/297 (6.1) of MIS-C	N/A
Aly 2022/Egypt	Six children and adolescents. Their mean age was 10.5 years (range 6–13 years)	N/A	All were underweight. All with diabetes mellitus type 1	Dermatologic lesions (rash, mucositis, or a Kawasaki-like presentation)	Critical COVID-19
Ibrahim 2022/ Egypt	Thirty-one pediatric patients (18 boys and 13 girls) with MIS-C, mean age 9 years (range 6–11), 16 of whom were in the 5 –10 years age group	N/A	Nine patients (30%) had two cases of acute lymphocytic leukemia type B (ALL) and one case each of concurrent diabetes mellitus (DM), myeloblastoma, hemophagocytic lymphohistiocytosis (HLH), Down's syndrome, seizure disorder, open heart surgery, and autism spectrum disorder	MIS-A with rash evident in 21 patients (67.7%)	Died 3 (9.7%)
Chinniah 2023/ South Africa	Twenty-nine children with MIS-C. The mean age was 55 (SD: ±45) months with 17 (59%) ≤5 years, 13 (45%) males and 25 (86%) Black-African	Generalized rash	Eight (28%) had preexisting medical conditions, including one (3%) with congenital heart disease, one (3%) with systemic juvenile idiopathic arthritis, one (3%) with HIV, three (10%) with moderate acute malnutrition, and two (7%) with obesity	MIS-A with rash 19 (65%). Erythematous maculopapular rash over trunk and limbs, diffuse erythroderma, urticarial lesions with pruritis, hand and foot edema, desquamation, perioral erythema, lip cracking, and bilateral bulbar conjunctival injection/early clinical stage	The mortality was 20.6%

Cutaneous manifestations can also be attributed to COVID-19-induced microthromboses that originate in distal organs and may potentially reduce blood flow to the cutaneous microvasculature, resulting in manifestations like livedo reticularis.[21,40,42] The virus can cause cutaneous lesions either directly or indirectly via vascular dysfunctions like thrombotic vasculopathy.[38] In addition, COVID-19 viral infection may result in vasculitis.[21] SARS-CoV-2 binding to ACE2 causes acantholysis and dyskeratosis.[16] SARS-CoV-2-related chilblain/pernio-like lesions (CBLL) can be explained by tissue damage caused by immune complex depositions in blood vessels, peripheral thrombotic microangiopathy caused by increased interferon type 1 (IFN-1) signaling, and/or secondary ischemia due to vascular damage.[16,43,44] Acral ischemia could be a manifestation of COVID-19 link to hypercoagulation.[45] Hypercoagulation may cause small blood clots to lodge in blood vessels, causing acral cyanosis and gangrene.[29,45] In contrast, acral erythema and chilblain-like lesions in older patients are thought to be caused by acral ischemia caused by insufficient type 1 IFNs.[45]

The MIS-C associated with SARS-CoV-2 infection is caused by an overactive innate immune response, which causes similar pathologic abnormalities in affected internal organs and

© 2023 The Authors. *International Journal of Dermatology* published by Wiley Periodicals LLC on behalf of the International Society of Dermatology.

13654632, 2024, 1, Downloaded from https://onlinelibrary.wiley.com/doi/10.1111/ijd.16872 by South African Medical Research, Wiley Online Library on [28/02/2024]. See the Terms and Conditions (https://onlinelibrary.wiley.com/terms-and-conditions) on Wiley Online Library for rules of use; OA articles are governed by the applicable Creative Commons License

Table 3 Cutaneous signs of COVID-19, age group, timeframe, and prognostic value in African populations

Cutaneous manifestations	Time of onset	Prognostic value	References
Multisystem inflammatory syndrome	2–7 days rash onset and before hospital admission	Severe COVID-19 and death Severe COVID-19 and discharged Severe COVID-19 and discharged Severe COVID-19 and discharged	Demissie 2022; Onyeaghala 2021, Sokunbi 2022; Piloya 2022
Erythema multiforme-like	1-day rash onset	Three children with critical COVID-19 were admitted to the ICU and others with severe COVID-19 Severe COVID-19 and discharged	Sokunbi 2022; Farouk 2020
Livedoid	N/A	–	–
Vesicular or varicella-like	N/A	–	–
Urticarial	Before the onset of COVID-19 symptoms and hospital admission	Severe COVID-19 and discharged. Asymptomatic COVID-19: 20.5%, mild: 54.5%, moderate: 20.5%, severe: 4.5%	Ndudane 2020; Mostafa 2022
Maculopapular or morbilliform	Early onset and before hospital admission	Severe COVID-19 and discharged. Moderate and severe COVID-19. The mortality was 20.6%	Moodley 2021; Otrofanowei 2021; Chinniah 2023
Chilblain-like or pernio-like	N/A	–	–

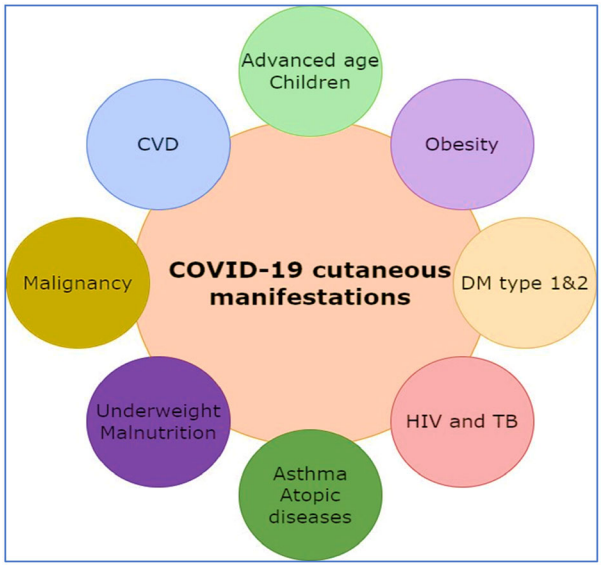

Figure 2 Risk factors of COVID-19 cutaneous manifestations in African populations

skin.[16] The association of MIS-C or MIS-A with COVID-19 cutaneous manifestations is well documented. However, the immunophysiology of MIS-C or MIS-A in relation to cutaneous lesions is poorly understood. Despite being one of the most significantly elevated markers in MIS-C, IL-27 was recently reported as one of several cytokines that were significantly upregulated.[46,47] Although this observation was limited to seven MIS-C patients, it does support the cytokine findings from another study.[46]

This review focuses on African populations, where HIV, tuberculosis, and malnutrition were identified as COVID-19 risk factors on top of noncommunicable diseases such as cardiovascular diseases, obesity, diabetes mellitus, atopic asthma, and malignancies as in the rest of the world. There has been speculation that the systemic inflammation caused by chronic HIV infection, active tuberculosis, and malnutrition could distort the immune response to SARS-CoV-2, resulting in increased severity. Indeed, new evidence suggests that HIV, TB, and malnutrition all increase the risk of COVID-19 mortality.[48–50] As described in the section on risk factors and comorbidities associated with COVID-19 cutaneous manifestations, this could lead to other immunopathological pathways triggering COVID-19-related cutaneous manifestations in African populations that could be different from the rest of the world.

Risk factors and comorbidities associated with COVID-19 cutaneous manifestations have been documented in patients ranging in age from 2 months to 89 years.[11] COVID-19 cutaneous manifestations ranged in African populations from 2.3 to 88 years old, according to studies. The age and gender distribution may differ significantly depending on the type of cutaneous manifestations. This review discovered that MIS was more common in children than in adults. This implies that age is a risk factor for cutaneous manifestations.

In addition, advanced age, obesity, diabetes, cardiovascular disease, HIV, tuberculosis, asthma, atopic disease, underweight, malnutrition, and malignancy were found to be associated with COVID-19 cutaneous manifestations in African populations (Figure 2). Our findings are consistent with those of other studies conducted in different contexts,[2,3,51] with the exception of HIV, tuberculosis, and malnutrition as risk factors

 © 2023 The Authors. *International Journal of Dermatology* published by Wiley Periodicals LLC on behalf of the International Society of Dermatology.

13654632, 2024, 1, Downloaded from https://onlinelibrary.wiley.com/doi/10.1111/ijd.16872 by South African Medical Research, Wiley Online Library on [28/02/2024]. See the Terms and Conditions (https://onlinelibrary.wiley.com/terms-and-conditions) on Wiley Online Library for rules of use; OA articles are governed by the applicable Creative Commons License

for COVID-19 cutaneous manifestations (Figure 2). The emphasis is on HIV because COVID-19 and HIV may interact in a variety of pathways to cause cutaneous manifestations.

COVID-19 may coexist with other AIDS-related conditions, such as opportunistic infections (OIs), in people living with HIV who have advanced disease and profound immunosuppression.[52,53] COVID-19 has also been linked to a significant decrease in CD4 count.[48] Wang et al. investigated the levels of lymphocyte subsets in whole blood using flow cytometry. COVID-19 patients were found to have significantly lower levels of total lymphocytes, $CD4^+$ T cells, $CD8^+$ T cells, B cells, and NK cells.[54,55] Furthermore, steroids used to treat COVID-19, specifically MIS-C and MIS-A, may cause immunodeficiency. These can cause dermatological OIs like varicella-zoster virus, chickenpox, disseminated histoplasmosis, Kaposi Sarcoma (KS), and other AIDS-related immunosuppression skin manifestations. Even though our study found HIV to be a risk factor for COVID-19 skin manifestations, dermatological lesions associated with HIV and COVID-19 interactions were not described. HIV infected with lower CD4 count may be at increased risk of COVID-19-related cutaneous manifestations. However, case studies from other settings have been described, establishing characteristics of cutaneous manifestations in COVID-19/HIV co-infected people. Gardini et al.[56] reviewed the literature and described a case report of KS in a COVID-19/HIV co-infected patient. The researchers hypothesized that KS in COVID-19 was caused by interleukin-6 (IL-6) activity and steroid-induced immunodeficiency, with IL-6 activity and steroid-induced immunodeficiency both playing important roles in the emergence of KS. Systemic viral infections, such as HIV, and even the virus itself, stimulate IL-6 production via a paracrine process. It then promotes inflammation and B cell proliferation, which favors B cell cancers.[56] Despite the limited data available, HZ is now being reported as a co-infection in COVID-19 patients.[10,50–52,57–59] HZ is a reactivation of a primary varicella-zoster virus (VZV) infection (chickenpox). Older age and immunosuppression can cause the reactivation of dormant VZV infection.[10]

A case of monkeypox in a COVID-19/HIV co-infected patient has also been reported.[60] As a result, clinicians should be aware of the possibility of co-infection with SARS-CoV-2 and monkeypox virus, particularly in subjects who have recently traveled to monkeypox outbreak areas.[60] A study that included three cases of COVID-19 and monkeypox co-infection revealed the characteristic vesicular and ulcerative lesions in the genital region along with enlargement of lymph nodes.[61]

Furthermore, while drugs inhibit viral replication by targeting SARS-CoV-2 RNA polymerase, only remdesivir strongly induces Kaposi's sarcoma herpesvirus (KSHV) and Epstein–Barr virus (EBV) lytic reactivation. These findings suggest that using remdesivir to treat COVID-19 patients who already have an oncogenic herpesvirus infection may pose a risk.[62] Reactivation of these preexisting infections may increase viral pathogenesis and tumorigenesis, especially in immunocompromised patients who are already at increased risk of KSHV/EBV-associated cancers.[62]

The severity of COVID-19 in children and young adolescents in sub-Saharan Africa may differ from that in other settings due to the higher burden of childhood diseases such as malnutrition. The malnutrition heatmap indicates that malnutrition may be a precipitating factor of fatal COVID-19 in many sub-Saharan African countries.[63] Malnourished COVID-19 children were found to be more likely to die in the hospital compared to well-nourished children.[50] This could be due to disease-related hyperinflammation and immunosuppression.[63–65] A systematic review found that the mortality risk in malnourished COVID-19 children was 10 times higher than in well-nourished children.[50,66] This could explain the risk of MIS-C and the frequency of cutaneous manifestations described in the immunopathological section.

Clinical manifestations of COVID-19-related cutaneous manifestations

Different authors have now classified clinical manifestations of COVID-19-related cutaneous manifestations. We classified them as follows in this study: Erythema multiforme-like, livedoid, vesicular, or varicella-like rashes, urticarial, maculopapular, or morbilliform rashes, and chilblain-like or pernio-like rashes. Table 1 summarizes the demographics, clinical presentations, and topography of COVID-19-related cutaneous manifestations. Several studies in African populations have reported MIS-C and MIS-A or Kawasaki-like disease.[25–27,67–81] Figure 3 represents 47.5% (115/242) of MIS-C and MIS-A cases reported in nine published African studies. MIS was more common in men between the ages of 2.3 and 51 years.[25–27,67–81] Polymorphous maculopapular eruptions on the trunk and flexural areas, acral erythema, extremity swelling, desquamation, mucositis, and fissured lips are all examples of MIS dermatological lesions.[25–27,67–81] MIS lesions were mostly generalized or on the face, upper limbs, trunks, oral, hands, feet, palmar, and plantar surfaces in African populations (Table 1). Cases of MIS-C have been described as occurring after the peak of the epidemic and resembling both Kawasaki disease and toxic shock.[70,82,83] Shock and/or other signs of severe organ dysfunction associated with inflammation, such as severe abdominal pain, conjunctival injection, rash, and, most importantly, renal and cardiac dysfunction, distinguish MIS.[70] The severity of MIS-C has also been reported to be higher in Black-African children living in Europe, the United Kingdom, and the America, as well as children from lower socioeconomic backgrounds.[84–86] This could be a plausible explanation for our study's high rate of MIS-C, implying that MIS-C has a genetic or ethnic origin.

In our review, urticarial rash accounted for 12.4% (30/242) of the cases (Figure 3). Urticarial rashes were more common in females (52.35%) than males (47.65%), and the study population ranged in age from 3 to 88 years (Table 1). Urticarial rashes were distinguished by migratory, pruritic, edematous, and variably sized wheals that appeared within 24 hours without bruising or hyperpigmentation.[23,24,28,75,84] Maculopapular

© 2023 The Authors. *International Journal of Dermatology* published by Wiley Periodicals LLC on behalf of the International Society of Dermatology.

13654632, 2024, 1, Downloaded from https://onlinelibrary.wiley.com/doi/10.1111/ijd.16872 by South African Medical Research, Wiley Online Library on [28/02/2024]. See the Terms and Conditions (https://onlinelibrary.wiley.com/terms-and-conditions) on Wiley Online Library for rules of use; OA articles are governed by the applicable Creative Commons License

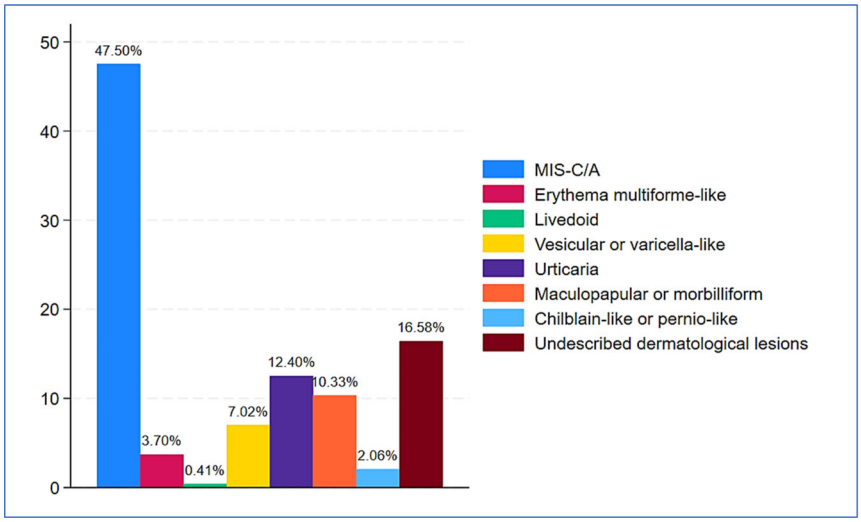

Figure 3 Distribution of COVID-19-related cutaneous manifestations in African populations

dermatitis, also known as morbilliform dermatitis, is characterized by erythematous macules with areas of normal-appearing skin on the trunk and extremities as well as pruritus.[87] In African populations, maculopapular cutaneous manifestations accounted for 10.33% (25/242) of COVID-19-related cutaneous manifestations (Table 1). Our review also revealed that maculopapular or morbilliform rash occurred in 55.9% of females aged 3–70 years (Table 1). Furthermore, the vesicular or varicella-like rash was found in 7.02% (17/242) of African populations (Figure 3). Vesicular or varicella-like rash ranged in age from 3 to 88 years and was slightly more common in females (51.05%) (Table 1). Vesicular or varicella-like rashes in African populations were small, scattered monomorphic vesicles on the trunk with mild or absent pruritus, pain, or a burning sensation. In African populations, the vesicular or varicella-like rash was mostly found in the chest, upper limb, lower limb, trunk, palms, and generalized rash.

Our findings reveal that 3.7% (9/242) of the cases had an erythema multiforme-like rash (Figure 3). The age range of erythema multiforme-like rash was 2.3 years to 88 years, with males accounting for 54.14% of all cases (Table 1). Erythema multiforme-like rash was defined as target with three rings or targetoid with two rings confluent macules, papules, and plaques of varying sizes with hemorrhages and central crusts. The most common cutaneous manifestations were in the chest, upper and lower limbs, as well as a generalized rash (Table 2).

Chilblain-like and livedoid cutaneous manifestations were less common in African studies, with 2.06% (5/242) and (0.41%) 1/242, respectively, being reported (Figure 3). This does not necessarily imply that the lesions were less common. However, many African studies only described COVID-19-related cutaneous manifestations that appeared early. In our study, pseudochilblains appeared later, either alone or in conjunction with ischemic/blistering lesions.[83] Because most African studies described clinical characteristics at admission, it is possible that the chilblain-like rash rate was lower in this review. Furthermore, we found no ischemic/gangrenous lesions that appeared late in the disease course. Clinical manifestations of COVID-19 cutaneous manifestations in African populations have not been well described, and our findings may not accurately reflect the true clinical manifestations of COVID-19 cutaneous manifestations in African populations. COVID-19 cutaneous manifestations are not limited to the lesions, as our findings demonstrate. Because of the multiple comorbidities associated with skin lesions in African populations, we can expect to see even more variety of skin lesions in African populations as the literature on COVID-19 cutaneous manifestations evolves.

Prognostic value of COVID-19 cutaneous manifestations

The prognostic value of COVID-19-related cutaneous manifestations in African populations is shown in Table 3. Cutaneous manifestations of COVID-19 do not occur in all infected individuals, but clinicians should be aware of this, as it may be the first sign of infection in asymptomatic or minimally symptomatic patients.[11,17] They could also be used as a prognostic marker for disease severity.[11,17] Skin lesions may appear before or after hospitalization. COVID-19-related cutaneous manifestations at the onset may have a significant prognostic value because they may correlate with COVID-19 severity and mortality. According to one study, vesicular bullous lesions can appear early or late in the COVID-19 course.[88] Similarly, acute urticaria was observed in COVID-19 patients early in the disease course, mostly in young adults with mild to moderate infection and no associated angioedema; similar findings have been reported in the literature.[58,89,90] Our review showed that the urticarial rash started before the onset of COVID-19 symptoms and hospital admission in African

 © 2023 The Authors. *International Journal of Dermatology* published by Wiley Periodicals LLC on behalf of the International Society of Dermatology.

13654632, 2024, 1, Downloaded from https://onlinelibrary.wiley.com/doi/10.1111/ijd.16872 by South African Medical Research, Wiley Online Library on [28/02/2024]. See the Terms and Conditions (https://onlinelibrary.wiley.com/terms-and-conditions) on Wiley Online Library for rules of use; OA articles are governed by the applicable Creative Commons License

populations. Mostafa et al. showed that urticarial rash was found in 20.5% of asymptomatic, 54.5% of mild, 20.5% of moderate, and 4.5% of severe COVID-19 in Egypt.[28]

The itching was severe and did not respond well to standard antihistamine doses, but the inclusion of systemic steroids in the COVID-19 management protocol contributed to a better urticaria outcome.[90] Furthermore, in critically ill patients, fixed livedo racemosa, retiform purpura, and true acral ischemia were observed, correlating with previous findings.[2,58,91] In contrast, skin manifestations associated with COVID-19 may be the first sign of infection in asymptomatic or mild symptomatic symptoms.[11] They could also be used as a prognostic marker for disease severity.[11,17]

Our findings revealed that MIS may be diagnosed in 2–7 days due to early onset rash (Table 3). This means that early dermatological examination is important in children hospitalized for COVID-19 because it may reveal early external skin inflammation as opposed to late interior inflammation. Also, the findings show that MIS was associated with severe COVID-19 in African populations. Although 123 of the cases were recovered, one of them died (Table 3). The maculopapular or morbilliform rash was reported in the early onset and before COVID-19 hospital admission (Table 3). In African populations, maculopapular or morbilliform rash had a prognostic value of moderate-to-severe COVID-19. However, a South African study found that children with maculopapular or morbilliform rash died at a rate of 20.6%,[84] whereas chilblain-like or pernio-like cutaneous manifestations have been shown to have a significant prognostic value in COVID-19-related cutaneous manifestations; none of the studies included in this review highlighted this fact. This may be explained by the fact that most of the cutaneous manifestations were described at the time of admission for COVID-19 patients. Most studies did not describe cutaneous manifestations during and after hospitalization. This implies that dermatologists should be involved in the routine clinical diagnosis and management of COVID-19 in African countries. Due to the scarcity of dermatologists in African settings, medical doctors and nurses should also be trained in identifying COVID-19 cutaneous manifestations with poor prognostic values. This will improve future studies related to COVID-19 cutaneous manifestations in African populations.

In resource-limited settings such as sub-Saharan Africa, where biochemical and hematological investigations may be difficult to obtain, the prognostic value of cutaneous manifestations may play a significant role in predicting COVID-19 outcomes. The presence of erythema multiforme-like, maculopapular, and MIS rash associated with COVID-19 at the onset of the disease or before hospital admission predicts COVID-19 severity and mortality in African populations, according to our findings. However, as other studies have shown, the rash was present in asymptomatic COVID-19 patients in our study.[11,17] Thus, the prognostic value of cutaneous manifestations may be useful in preventing COVID-19 worse outcomes by identifying early skin lesions as described above, as well as preventing disease spread by identifying asymptomatic COVID-19 cases via cutaneous manifestations.

Conclusion

To the best of our knowledge, this is the first comprehensive review of COVID-19-related cutaneous manifestations in African populations. This study found that cutaneous manifestations associated with COVID-19 infection in African populations are understudied in terms of epidemiological profiles, clinical characteristics, and prognostic values. Because of sociodemographic parameters and comorbidities specific to the African continent, cutaneous manifestations related to COVID-19 may differ from other settings. Our findings show that cutaneous manifestations of COVID-19 vary by country and severity of COVID-19, primarily MIS. Significant differences were also found between various dermatological lesions, primarily MIS, erythema multiforme-like, livedoid, vesicular, or varicella-like rashes, urticarial, maculopapular, or morbilliform rashes, and chilblain-like or pernio-like rashes. This could be due to poor dermatological examination in African COVID-19 patients. Furthermore, cutaneous manifestations were mostly described at the time of admission, with no ongoing process of late dermatological lesions like chilblain or pernio-like rash. However, cutaneous manifestations' prognostic value may be useful in preventing COVID-19 worse outcomes by identifying early skin lesions as described above, as well as preventing disease spread by identifying asymptomatic COVID-19 cases via cutaneous manifestations. As a result, dermatologists and clinicians should consider the prognostic values of cutaneous manifestations in African populations. In Africa, more research on the epidemiology, clinical features, and prognosis of COVID-19-related manifestations in HIV, TB, and malnutrition is needed.

Author Contributions

Peter S. Nyasulu conceived the review. **Peter S. Nyasulu** and **Jacques L. Tamuzi** searched potential peer-reviewed manuscripts. **Peter S. Nyasulu** and **Jacques L. Tamuzi** drafted the manuscript. **Peter S. Nyasulu** and **Jacques L. Tamuzi** edited the manuscript. The authors approved the last version.

Data Availability Statement

All Data and materials are available in this manuscript.

References

1 Jia JL, Kamceva M, Rao SA, Linos E. Cutaneous manifestations of COVID-19: a preliminary review. *J Am Acad Dermatol*. 2020;**83**:687–90.
2 Freeman EE, McMahon DE, Lipoff JB, Rosenbach M, Kovarik C, Desai SR, et al. The spectrum of COVID-19-associated dermatologic manifestations: an international registry of 716

© 2023 The Authors. *International Journal of Dermatology* published by Wiley Periodicals LLC on behalf of the International Society of Dermatology.

13654632, 2024, 1, Downloaded from https://onlinelibrary.wiley.com/doi/10.1111/ijd.16872 by South African Medical Research, Wiley Online Library on [28/02/2024]. See the Terms and Conditions (https://onlinelibrary.wiley.com/terms-and-conditions) on Wiley Online Library for rules of use; OA articles are governed by the applicable Creative Commons License

patients from 31 countries. *J Am Acad Dermatol*. 2020;**83**(4):1118–29.
3 Fernández-Lázaro D, Garrosa M. Identification, mechanism, and treatment of skin lesions in COVID-19: a review. *Viruses*. 2021;**13**(10):1916.
4 Jamshidi P, Hajikhani B, Mirsaeidi M, Vahidnezhad H, Dadashi M, Nasiri MJ. Skin manifestations in COVID-19 patients: are they indicators for disease severity? A systematic review. *Front Med*. 2021;**8**:634208.
5 UNAIDS. Fact sheet – Latest global and regional statistics on the status of the AIDS epidemic. 2023. [cited 2023 Feb 27]. Available from: https://www.unaids.org/en/resources/documents/2023/UNAIDS_FactSheet
6 World Health Organization. *Global tuberculosis report 2022*. Geneva: Licence:CC BY-NC-SA 3.0 IGO; 2022. [cited 2023 Feb 27]. Available from: https://www.who.int/publications/i/item/9789240061729
7 Ewunie TM, Hareru HE, Dejene TM, Abate SM. Malnutrition among the aged population in Africa: a systematic review, meta-analysis, and meta-regression of studies over the past 20 years. *PLoS One*. 2022;**17**(12):e0278904.
8 Kurtz A, Grant K, Marano R, Arrieta A, Grant KJ, Feaster W, et al. Long-term effects of malnutrition on severity of COVID-19. *Sci Rep*. 2021;**11**(1):14974.
9 Lesko CR, Bengtson AM. HIV and COVID-19: intersecting epidemics with many unknowns. *Am J Epidemiol*. 2021;**190**(1):10–6.
10 Daodu J, Basuli D, Parikh A. A rare case of AIDS co-infected with COVID-19 presenting with disseminated Herpes zoster complicated with CMV and Varicella zoster virus meningoencephalitis. *Acta Biomed*. 2022;**93**(6):e2022326.
11 Akuffo-Addo E, Nicholas MN, Joseph M. COVID-19 skin manifestations in skin of colour. *J Cutan Med Surg*. 2022;**26**(2):189–97.
12 Carrascosa JM, Morillas V, Bielsa I, Munera-Campos M. Cutaneous manifestations in the context of SARS-CoV-2 infection (COVID-19). *Actas Dermosifiliogr (Engl Ed)*. 2020;**111**(9):734–42.
13 Visconti A, Bataille V, Rossi N, Kluk J, Murphy R, Puig S, et al. Diagnostic value of cutaneous manifestation of SARS-CoV-2 infection. *Br J Dermatol*. 2021;**184**(5):880–7.
14 Kadhim DA, AL-Junaiyeh HA. Cutaneous manifestations in COVID-19 patients admitted to al-hussein teaching hospital in Dhi-Qar Province. *Herpes*. 2021;**9**(7.75):0–25.
15 Elmas ÖF, Demirbaş A, Özyurt K, Atasoy M, Türsen Ü. Cutaneous manifestations of COVID-19: a review of the published literature. *Dermatol Ther*. 2020;**33**(4):e13696.
16 Huynh T, Sanchez-Flores X, Yau J, Huang JT. Cutaneous manifestations of SARS-CoV-2 infection. *Am J Clin Dermatol*. 2022;**23**(3):277–86.
17 Daneshgaran G, Dubin DP, Gould DJ. Cutaneous manifestations of COVID-19: an evidence-based review. *Am J Clin Dermatol*. 2020;**21**:627–39.
18 Pasquini Neto R, Mazzo FA, Vieira FD, Bueno GD, Previdi JV, Silva LR, et al. COVID-19 cutaneous manifestations in children and adolescents: a systematic review. *Rev Paul Pediatr*. 2022;**40**:e2021134.
19 Guan WJ, Ni ZY, Hu Y, Liang WH, Ou CQ, He JX, et al. Clinical characteristics of coronavirus disease 2019 in China. *N Engl J Med*. 2020;**382**(18):1708–20.
20 Singh H, Kaur H, Singh K, Sen CK. Cutaneous manifestations of COVID-19: a systematic review. *Adv Wound Care*. 2021;**10**(2):51–80.
21 Bryan A, Samant H, Asarkar A, Nathan CAO, Khandelwal A. Cutaneous manifestations in COVID-19-positive African American patients. *Ochsner J*. 2022;**22**(1):22–5.
22 Visconti A, Murray B, Rossi N, Wolf J, Ourselin S, Spector TD, et al. Cutaneous manifestations of SARS-CoV-2 infection during the Delta and Omicron waves in 348 691 UK users of the UK ZOE COVID Study app. *Br J Dermatol*. 2022;**187**(6):900–8.
23 Anaba EL. Prevalence and pattern of acute dermatological manifestations of the novel COVID-19 infection at a COVID-19 treatment center in Sub-Saharan Africa. *Dermatol Ther*. 2021;**34**:e14953.
24 Otrofanowei E, Akinkugbe AO, Otike-Odibi BI, Ayanlowo OO, Akase IE, Karami M, et al. Covid 19: a prospective observational study on the cutaneous manifestations of patients in Lagos, Nigeria. *West Afr J Med*. 2021;**38**(10):944–51.
25 Butters C, Abraham DR, Stander R, Facey-Thomas H, Abrahams D, Faleye A, et al. The clinical features and estimated incidence of MIS-C in Cape Town, South Africa. *BMC Pediatr*. 2022;**22**(1):241.
26 Migowa AN, Samia P, Shah J, Del Rossi S, Kenei C, Malande OO, et al. *Management of Multisystem Inflammatory Syndrome in Children (MIS-C) in resource limited settings: The Kenyan Experience*. United States: Research Square; 2022.
27 Nachega JB, Sam-Agudu NA, Machekano RN, Rabie H, van der Zalm MM, Redfern A, et al. Assessment of clinical outcomes among children and adolescents hospitalized with COVID-19 in 6 Sub-Saharan African countries. *JAMA Pediatr*. 2022;**176**(3):e216436.
28 Mostafa PIN, Alieldin LG, El-Kalioby M. Can skin affection be a clue to COVID-19? Results from a dermatology outpatient clinic in Egypt. *J Egypt Women's Dermatol Soc*. 2022;**19**(2):108.
29 Criado PR, Abdalla BMZ, de Assis IC, van Blarcum de Graaff Mello C, Caputo GC, Vieira IC. Are the cutaneous manifestations during or due to SARS-CoV-2 infection/COVID-19 frequent or not? Revision of possible pathophysiologic mechanisms. *Inflamm Res*. 2020;**69**(8):745–56.
30 Seque CA, Porro AM, Tomimori J. Skin manifestations associated with COVID-19. *An Bras Dermatol*. 2022;**97**(1):75–88.
31 Kubanov AA, Deryabin DG. Skin manifestations in COVID-19 provide a clue for disease's pathophysiology understanding. *J Eur Acad Dermatol Venereol*. 2021;**35**:e3–4.
32 Suchonwanit P, Leerunyakul K, Kositkuljorn C. Cutaneous manifestations in COVID-19: lessons learned from current evidence. *J Am Acad Dermatol*. 2020;**83**:e57–60.
33 Colmenero I, Santonja C, Alonso-Riaño M, Andina D, Rodríguez Peralto JL, Requena L, et al. SARS-CoV-2 has not been detected directly by electron microscopy in the endothelium of chilblain lesions: reply from authors. *Br J Dermatol*. 2020;**184**:186–7.
34 Abuelgasim E, Dona ACM, Sondh RS, Harky A. Management of urticaria in COVID-19 patients: a systematic review. *Dermatol Ther*. 2021;**34**(1):e14328.
35 Sachdeva M, Gianotti R, Shah M, Bradanini L, Tosi D, Veraldi S, et al. Cutaneous manifestations of COVID-19: report of three cases and a review of literature. *J Dermatol Sci*. 2020;**98**(2):75–81.
36 Gianotti R, Zerbi P, Dodiuk-Gad RP. Clinical and histopathological study of skin dermatoses in patients affected by COVID-19 infection in the Northern part of Italy. *J Dermatol Sci*. 2020;**98**:141–3.
37 Poduri R, Joshi G, Jagadeesh G. Drugs targeting various stages of the SARS-CoV-2 life cycle: exploring promising

 © 2023 The Authors. *International Journal of Dermatology* published by Wiley Periodicals LLC on behalf of the International Society of Dermatology.

13654632, 2024, 1, Downloaded from https://onlinelibrary.wiley.com/doi/10.1111/ijd.16872 by South African Medical Research, Wiley Online Library on [28/02/2024]. See the Terms and Conditions (https://onlinelibrary.wiley.com/terms-and-conditions) on Wiley Online Library for rules of use; OA articles are governed by the applicable Creative Commons License

drugs for the treatment of Covid-19. *Cell Signal*. 2020;**74**:109721.
38 Mohseni Afshar Z, Babazadeh A, Hasanpour A, Barary M, Sayad B, Janbakhsh A, et al. Dermatological manifestations associated with COVID-19: a comprehensive review of the current knowledge. *J Med Virol*. 2021;**93**(10):5756–67.
39 Rongioletti F, Ferreli C, Sena P, Caputo V, Atzori L. Clinicopathologic correlations of COVID-19-related cutaneous manifestations with special emphasis on histopathologic patterns. *Clin Dermatol*. 2021;**39**(1):149–62.
40 O'Hehir RE, Holgate ST, Sheikh A. *Middleton's allergy essentials E-book*. Amsterdam, The Netherlands: Elsevier Health Sciences; 2015.
41 Mahdiabadi S, Rajabi F, Tavakolpour S, Rezaei N. Immunological aspects of COVID-19-related skin manifestations: revisiting pathogenic mechanism in the light of new evidence. *Dermatol Ther*. 2022;**35**(10):e15758.
42 Marzano AV, Cassano N, Genovese G, Moltrasio C, Vena GA. Cutaneous manifestations in patients with COVID-19: a preliminary review of an emerging issue. *Br J Dermatol*. 2020;**183**(3):431–42.
43 Colmenero I, Hoeger PH. Vascular tumours in infants. Part II: vascular tumours of intermediate malignancy [corrected] and malignant tumours. *Br J Dermatol*. 2014;**171**(3):474–84.
44 Damsky W, Peterson D, King B. When interferon tiptoes through COVID-19: pernio-like lesions and their prognostic implications during SARS-CoV-2 infection. *J Am Acad Dermatol*. 2020;**83**:e269–70.
45 Schwartzberg L, Lin A, Jorizzo J. Cutaneous manifestations of COVID-19. *Cutis*. 2021;**107**(2):90–4.
46 Spracklen TF, Mendelsohn SC, Butters C, Facey-Thomas H, Stander R, Abrahams D, et al. IL27 gene expression distinguishes multisystem inflammatory syndrome in children from febrile illness in a South African cohort. *Front Immunol*. 2022;**13**:992022.
47 Huang JJ, Gaines SB, Amezcua ML, Lubell TR, Dayan PS, Dale M, et al. Upregulation of type 1 conventional dendritic cells implicates antigen cross-presentation in multisystem inflammatory syndrome. *J Allergy Clin Immunol*. 2022;**149**(3):912–22.
48 Tamuzi JL, Ayele BT, Shumba CS, Adetokunboh OO, Uwimana-Nicol J, Haile ZT, et al. Implications of COVID-19 in high burden countries for HIV/TB: a systematic review of evidence. *BMC Infect Dis*. 2020;**20**(1):744.
49 Ssentongo P, Heilbrunn ES, Ssentongo AE, Advani S, Chinchilli VM, Nunez JJ, et al. Epidemiology and outcomes of COVID-19 in HIV-infected individuals: a systematic review and meta-analysis. *Sci Rep*. 2021;**11**(1):6283.
50 Abate SM, Chekole YA, Estifanos MB, Abate KH, Kabthymer RH. Prevalence and outcomes of malnutrition among hospitalized COVID-19 patients: a systematic review and meta-analysis. *Clin Nutr ESPEN*. 2021;**43**:174–83.
51 Freeman EE, McMahon DE, Lipoff JB, Rosenbach M, Kovarik C, Takeshita J, et al. Pernio-like skin lesions associated with COVID-19: a case series of 318 patients from 8 countries. *J Am Acad Dermatol*. 2020;**83**(2):486–92.
52 The International AIDS Society. *COVID-19 and HIV: what you need to know*. Geneva, Switzerland: International AIDS Society; 2021.
53 Bertolini M, Mutti MF, Barletta JA, Falak A, Cuatz D, Sisto A, et al. COVID-19 associated with AIDS-related disseminated histoplasmosis: a case report. *Int J STD AIDS*. 2020;**31**(12):1222–4.
54 Wang F, Nie J, Wang H, Zhao Q, Xiong Y, Deng L, et al. Characteristics of peripheral lymphocyte subset alteration in COVID-19 pneumonia. *J Infect Dis*. 2020;**221**(11):1762–9.
55 Algaadi SA. Herpes zoster and COVID-19 infection: a coincidence or a causal relationship? *Infection*. 2022;**50**(2):289–93.
56 Gardini G, Odolini S, Moioli G, Papalia DA, Ferrari V, Matteelli A, et al. Disseminated Kaposi sarcoma following COVID-19 in a 61-year-old Albanian immunocompetent man: a case report and review of the literature. *Eur J Med Res*. 2021;**26**(1):152.
57 Lidhoo P, Unemori P, Leslie KS, Maurer T. Disseminated herpes zoster with increased CD4 counts in 3 HIV-infected patients. *J Am Acad Dermatol*. 2009;**61**(2):345–7.
58 Galván Casas C, Català A, Carretero Hernández G, Rodríguez-Jiménez P, Fernández-Nieto D, Rodríguez-Villa Lario A, et al. Classification of the cutaneous manifestations of COVID-19: a rapid prospective nationwide consensus study in Spain with 375 cases. *Br J Dermatol*. 2020;**183**(1):71–7.
59 Ertugrul G, Aktas H. Herpes zoster cases increased during COVID-19 outbreak. Is it possible to have a relation? *J Dermatolog Treat*. 2022;**33**:1180.
60 Nolasco S, Vitale F, Geremia A, Tramuto F, Maida CM, Sciuto A, et al. First case of monkeypox virus, SARS-CoV-2, and HIV co-infection. *J Infect*. 2023;**86**:e21–3.
61 El-Qushayri AE, Reda A, Shah J. COVID-19 and monkeypox co-infection: a rapid systematic review. *Front Immunol*. 2022;**13**:1094346.
62 Chen J, Dai L, Kendrick S, Post SR, Qin Z. The anti-COVID-19 drug remdesivir promotes oncogenic herpesvirus reactivation through regulation of intracellular signaling pathways. *Antimicrob Agents Chemother*. 2022;**66**(3):e0239521.
63 Mertens E, Peñalvo JL. The Burden of malnutrition and fatal COVID-19: a global burden of disease analysis. *Front Nutr*. 2020;**7**:619850.
64 Butt AA, Kartha AB, Masoodi NA, Azad AM, Asaad NA, Alhomsi MU, et al. Hospital admission rates, length of stay, and in-hospital mortality for common acute care conditions in COVID-19 vs. pre-COVID-19 era. *Public Health*. 2020;**189**:6–11.
65 Mentella MC, Scaldaferri F, Gasbarrini A, Miggiano GAD. The role of nutrition in the COVID-19 pandemic. *Nutrients*. 2021;**13**(4):1093.
66 Ting THY, Lo THM, Lo WWT, Ding Q, Yuk DKL, Hui E, et al. Inadequate energy, and protein intake, underweight and malnutrition are associated with in-hospital mortality among COVID-19 rehabilitation patients during the omicron outbreak in Hong Kong. *Aging Med (Milton)*. 2022;**5**(3):204–10.
67 Demissie M, Deribessa SJ, Bacha T. A typical case of multisystem inflammatory syndrome in a 10-yearold girl with COVID-19: a case report from Ethiopia. *Ethiop J Health Sci*. 2022;**32**:873–7.
68 Onyeaghala C, Alasia D, Eyaru O, Paul N, Maduka O, Osemwegie N, et al. Multisystem inflammatory syndrome (MIS-C) in an adolescent Nigerian girl with COVID-19: a call for vigilance in Africa. *Int J Infect Dis*. 2021;**105**:124–9.
69 Egbu E, Ihemedu C, Egbu AC, Eze UA, Onuwaje M. Multisystemic manifestations of COVID-19 in a 37-year-old Nigerian man: a case report. *Int J Ophthalmol Clin Res*. 2020;**7**:121.
70 Parker A, Louw EH, Lalla U, Koegelenberg CFN, Allwood BW, Rabie H, et al. Multisystem inflammatory syndrome in adult COVID-19 wards at Tygerberg Hospital, Cape Town, South Africa. *SAMJ S Afr Med J*. 2020;**110**(9):957–8.

© 2023 The Authors. *International Journal of Dermatology* published by Wiley Periodicals LLC on behalf of the International Society of Dermatology.

13654632, 2024, 1, Downloaded from https://onlinelibrary.wiley.com/doi/10.1111/ijd.16872 by South African Medical Research, Wiley Online Library on [28/02/2024]. See the Terms and Conditions (https://onlinelibrary.wiley.com/terms-and-conditions) on Wiley Online Library for rules of use; OA articles are governed by the applicable Creative Commons License

71 Sokunbi O, Akinbolagbe Y, Akintan P, Oyeleke G, Kusimo O, Owowo U, et al. Clinical presentation, and short-term outcomes of multisystemic inflammatory syndrome in children in Lagos, Nigeria during the COVID-19 pandemic: a case series. *EClinicalMedicine*. 2022;**49**:101475.

72 van Heerden J, Nel J, Moodley P, Govender P, Hooijer J, Ickinger C, et al. Multisystem inflammatory syndrome (MIS): a multicenter retrospective review of adults and adolescents in South Africa. *Int J Infect Dis*. 2021;**111**:227–32.

73 Moodley P, Tsitsi JML, Reddy DL, Debising M, Ickinger C. A case of multisystem inflammatory syndrome in an African adolescent male: case report. *Pan Afr Med J*. 2021;**38**:174.

74 Balkaran S, Surdut SP, Rose DM, Freercks R. Multisystem inflammatory syndrome in an adult (MIS-A) due to SARS-CoV-2 infection presenting to a South African hospital. *BMJ Case Rep*. 2022;**15**(2):e246587.

75 Ndudane A, Beba L, Elmezughi K, Ekpebegh C, Dubula T. A 14-year-old female with multi-organ failure and cutaneous manifestations of COVID-19: a case report from Mthatha, South Africa. *PAMJ-Clin Med*. 2020;**4**(37):37.

76 Sylverken J, Afari P, Martyn-Dickens C, Owusu SA, Oppong E, Akwetey F, et al. Atypical Kawasaki syndrome in COVID-19 infection: a case report of a multisystem inflammatory syndrome in a child (MIS-C). *Ghana Med J*. 2021;**55**:64–7.

77 Piloya T, Nakiyingi L, Kimuli I, Kayima J, Lubega J, Sekabira J, et al. SARS-CoV-2-associated multisystem inflammatory syndrome in a child in Uganda: a paediatric experience in a resource-limited setting. *Case Rep*. 2022;**2022**:7811891.

78 Haoudar A, Chekhlabi N, Eljazouly M, El Kettani C, Dini N. Severe SARS-CoV-2 infection: a multisystem inflammatory syndrome in moroccan children. Cureus 2021;**13**:e12991.

79 Webb K, Abraham DR, Faleye A, McCulloch M, Rabie H, Scott C. Multisystem inflammatory syndrome in children in South Africa. *Lancet Child Adolesc Health*. 2020;**4**:e38.

80 Aly HH, Fouda EM, Kotby AA, Magdy SM, Rezk AR, Nasef MWA. COVID-19-related multisystem inflammatory syndrome in children presenting with new-onset type 1 diabetes in severe ketoacidosis: a case series. *Diabetes Care*. 2022;**45**(4):983–9.

81 Ibrahim HM, Mohammad SA, Fouda E, Abouelfotouh K, Habeeb NM, Rezk AR, et al. Clinical characteristics and pulmonary computerized imaging findings of critically ill egyptian patients with multisystem inflammatory syndrome in children. *Glob Pediatr Health*. 2022;**9**:2333794X221085386.

82 Dufort EM, Koumans EH, Chow EJ, Rosenthal EM, Muse A, Rowlands J, et al. Multisystem inflammatory syndrome in children in New York State. *N Engl J Med*. 2020;**383**(4):347–58.

83 Verdoni L, Mazza A, Gervasoni A, Martelli L, Ruggeri M, Ciuffreda M, et al. An outbreak of severe Kawasaki-like disease at the Italian epicentre of the SARS-CoV-2 epidemic: an observational cohort study. *Lancet*. 2020;**395**(10239):1771–8.

84 Chinniah K, Bhimma R, Naidoo KL, Archary M, Jeena P, Hoosen E, et al. Multisystem inflammatory syndrome in children associated with SARS-CoV-2 infection in KwaZulu-Natal, South Africa. *Pediatr Infect Dis J*. 2023;**42**(1):e9–e14.

85 Abrams JY, Oster ME, Godfred-Cato SE, Bryant B, Datta SD, Campbell AP, et al. Factors linked to severe outcomes in multisystem inflammatory syndrome in children (MIS-C) in the USA: a retrospective surveillance study. *Lancet Child Adolesc Health*. 2021;**5**(5):323–31.

86 Broad J, Forman J, Brighouse J, Sobande A, McIntosh A, Watterson C, et al. Post-COVID-19 paediatric inflammatory multisystem syndrome: association of ethnicity, key worker and socioeconomic status with risk and severity. *Arch Dis Child*. 2021;**106**(12):1218–25.

87 Shams S, Rathore SS, Anvekar P, Sondhi M, Kancherla N, Tousif S, et al. Maculopapular skin eruptions associated with Covid-19: a systematic review. *Dermatol Ther*. 2021;**34**(2):e14788.

88 Muhammad A, Iftikhar N, Mashhood A, Virdi G, Ud Din H, Akbar A, et al. Dermatological manifestations of COVID-19 in patients reporting to a tertiary care hospital in Rawalpindi, Pakistan. *Cureus*. 2021;**13**(10):e18973.

89 Morey-Olivé M, Espiau M, Mercadal-Hally M, Lera-Carballo E, García-Patos V. Cutaneous manifestations in the current pandemic of coronavirus infection disease (COVID 2019). *An Pediatr (Engl Ed)*. 2020;**92**:374–5.

90 AL-Junaiyeh HA, Kadhim DA. Cutaneous manifestations in COVID-19 patients admitted to Al-Hussein Teaching Hospital in Dhi-Qar Province. *Univ Thi-Qar J Med*. 2021;**22**(2):1–12.

91 Magro C, Mulvey JJ, Berlin D, Nuovo G, Salvatore S, Harp J, et al. Complement associated microvascular injury and thrombosis in the pathogenesis of severe COVID-19 infection: a report of five cases. *Transl Res*. 2020;**220**:1–13.

 © 2023 The Authors. *International Journal of Dermatology* published by Wiley Periodicals LLC on behalf of the International Society of Dermatology.

13654632, 2024, 1, Downloaded from https://onlinelibrary.wiley.com/doi/10.1111/ijd.16872 by South African Medical Research, Wiley Online Library on [28/02/2024]. See the Terms and Conditions (https://onlinelibrary.wiley.com/terms-and-conditions) on Wiley Online Library for rules of use; OA articles are governed by the applicable Creative Commons License