

https://dspace.org/

Is true caries diagnosis possible as we approach 2000?

Grossman, E. S.; Hargreaves, J. A.; Cleaton-Jones, P. E.; et al.

1998

http://hdl.handle.net/10539/20291

Grossman, E. S., Hargreaves, J. A., Cleaton-Jones, P. E., et al. 1998. Is true caries diagnosis possible as we approach 2000? Microscopy society of Southern Africa; 28:73

Downloaded from a DSpace repository. https://dspace.org/

IS TRUE CARIES DIAGNOSIS POSSIBLE AS WE APPROACH 2000?

E.S. Grossman, J.A. Hargreaves, P.E. Cleaton-Jones, D. Cortés and N.P. Daya

MRC/WITS Dental Research Institute, Johannesburg

Dental caries has traditionally been treated when it has affected the dentine and requires restoration[1]. However the modern practitioner would like to intervene with preventive treatment before a filling is needed[2,3]. The correct diagnosis of caries is central to the entire discipline of dental science, yet clinicians continue to grapple with fundamentals of how to interpret initial signs of demineralisation and to recognise the disease in its early stages. The traditional diagnostic tools of a mirror and sharp probe appears to be too crude an instrument to diagnose incipient caries. This has led to a development of alternative, improved caries diagnostic methods such as fibreoptic transillumination (FOTI). New caries diagnostic methods need to be evaluated by confirming the extent of caries, preferably by histological validation. This can easily be done in *in vitro* laboratory studies, however caries diagnosis *in vitro* is much easier than within the mouth as one is able to create optimal visual conditions to examine specimens. Generally validation of *in vivo* diagnosis relies on weaker comparative (eg. radiograph) or majority consensus methods.

This validation study compared FOTI caries diagnosis undertaken within training manikin heads in a well simulated clinical *in vitro* situation with histology.

Two hundred and fourteen human teeth were mounted in nine training manikins to simulate the *in vivo* situation. The teeth represented the full gamut of caries from apparently intact teeth to macroscopic caries and filled teeth. On two separate occasions the teeth were examined using FOTI by four qualified dentists. Thereafter the teeth were removed from the manikins, embedded individually in clear polyester resin and serially sectioned with a diamond blade disc saw at a cutting interval of 350μm. Both sides of the resulting 2008 sections were examined dry in incident and transmitted light using a Wild M420 Makroskop and the buccal, lingual, mesial, distal and occlusal surfaces assessed for caries using a score system of 0-7 which denoted an increasing severity of caries. All sections (229) from one of the manikins were re-examined to test for reproducibility. The data were examined using a Probit analysis with $P < 0.05$ to determine the accuracy of the diagnostic procedure. This study reports on the results obtained on occlusal surfaces only.

Examiner reproducibility for histology was 96%. Figure 1 shows the accuracy of sound and unsound diagnoses of occlusal tooth surfaces. Sound scores predominate until the crossover between histological score 5 and 6 which indicates caries in the outer and inner dentine respectively. Diagnosis of sound occlusal surfaces had an accuracy of between 84-97% (score 0). However when it came to enamel caries (score 3+4) accuracy dropped to 0-33%, dentine caries (score 5+6) was correctly diagnosed between 33-91% and restored surfaces 80% (score 7). There was a significant difference between diagnosis recorded and histological scores. No significant difference was found between dentists or replicates.

The variation in diagnostic accuracy obtained in this study should not be regarded as poor performance by the dentists or that the FOTI detecting system is flawed. Instead, this *in vitro* study illustrates the difficulties encountered by the practitioner when the crucial decision (is the disease present or absent) is made when there is international disagreement on the interpretation of caries in the initial stages. The diagnosis was made under non-optimal circumstances associated with caries detection within the oral cavity by using manikins to simulate clinical conditions. Finally the diagnosis was validated by exacting histological criteria rather than error prone comparative methods.

It appears that the realm of incipient caries remains obscure as we approach the year 2000. Intensive investigation of early demineralisation is required to surmount the interpretive difficulties which are central to caries diagnosis. Subsequent re-education and calibration of practitioners will be essential to ensure accurate and consistent diagnosis of the disease in its early stages. Only then can sophisticated instrumentation such as FOTI be fairly evaluated as a caries diagnostic tool.

References

1. Sheiham, A. (1977) Lancet 27, 442.
2. Kidd, E.A., Ricketts, D.N. & Pitts, N.B. (1993) J. Dent. 21, 323.
3. Ismail, A.I. (1997) Community Dent. Oral. Epidemiol. 25, 13.

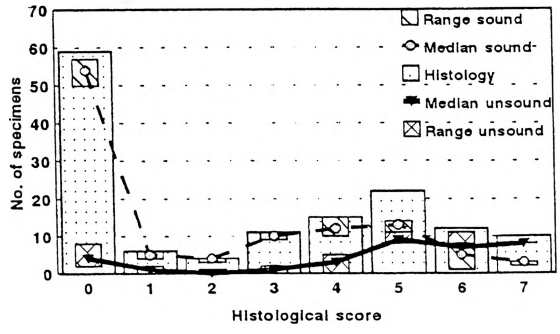

Fig. 1. The bar indicates the number of teeth in each histological score grouping; the boxes show the range of un/sound scores registered by the examiners; the lines indicate the median of the un/sound diagnosis.