

https://dspace.org/

# The frequency of thyroid gland invasion in advanced laryngeal malignancy: an audit of total laryngectomy histological specimens

**Makepeace, A H**

**2017**
http://hdl.handle.net/10539/23405

Downloaded from a DSpace repository. https://dspace.org/

# THE FREQUENCY OF THYROID GLAND INVASION IN ADVANCED LARYNGEAL MALIGNANCY: AN AUDIT OF TOTAL LARYNGECTOMY HISTOLOGICAL SPECIMENS.

**Dr AH Makepeace, 722272, MMed (MFOSENT560)**

**Supervised by: Dr Y Atiya MBBCh, MMed (Wits), FCORL (SA)**

**Otorhinolaryngology Consultant**

**Chris Hani Baragwanath Academic Hospital**

## Dedication

I dedicate this work to my family:

To my longsuffering husband, Murray, who has made endless sacrifices in order for me to pursue my career and who gives me constant encouragement to be my best. Throughout the writing of this dissertation, he has only shown love and support for me.

To my children, Harrison and Erin, who may be oblivious to how much they have given up for me to continue with this work, but inspire me every day to strive for better.

## Declaration

### Candidate:

This dissertation is my original work and has not been presented to another University or institution of higher learning.

Signed: Date:

Dr AH Makepeace

MBChB (UCT) FCORL (SA)

### Supervisor:

This dissertation is submitted as a final copy as the University's Academic and Clinical supervisor.

Signed: Date:

Dr Y Atiya

MBBCh (Wits) MMed (ORL) (Wits) FCORL (SA)

Specialist ENT – Head & Neck Surgeon

Department of Otorhinolaryngology

Chris Hani Baragwanath Hospital & University of the Witwatersrand

## Former Head of Department:

This dissertation is submitted as a final copy with my approval.

Signed: Date:

Professor PC Modi

Academic Head

Division of Otorhinolaryngology - Head and Neck Surgery

Department of Neurosciences

School of Clinical Medicine

Faculty of Health Sciences

University of the Witwatersrand

## Acknowledgements

I would like to extend my thanks to the following people in acknowledgement for their help with this work.

- To my supervisor, Dr Y Atiya, for his continued support, patience and invaluable feedback.
- To Dr MRI Ahmed, for giving me permission to conduct this study in the department of otorhinolaryngology at Chris Hani Baragwanath Hospital.
- To Professor Modi, former Head of Department of the ENT department at the University of Witwatersrand for his support and direction.
- To Professor Hale of the National Health Laboratory Service, for allowing me access to their database.
- To Dr Sugeshnee Pather of the Department of Anatomical Pathology, for her guidance, support and assistance in finding the appropriate histological results.
- To my sister, Jessica Joyner, who offered advice and assistance.
- Lastly, and not least, to my family who supported me through the process, not only in working on this dissertation, but in continuing my career of choice.

## List of figures:

Figure 1: Histological types found in laryngectomy specimens Page 11
Figure 2: Distribution of sex between sample patients Page 12
Figure 3: Race groups of sample patients Page 13
Figure 4: Thyroid gland involvement in laryngectomy specimens Page 14
Figure 5: Anatomic subsites involved by tumour and the relative involvement of the thyroid gland Page 15

## List of abbreviations

| | |
|---|---|
| AJCC | American Joint Committee on Cancer |
| CHBAH | Chris Hani Baragwanath Academic Hospital |
| NHLS | National Health Laboratory Services |
| SCC | Squamous cell carcinoma |
| TNM | Tumour Node Metastases |
| Wits | University of the Witwatersrand |

## Definitions

Laryngeal tumours can be classified according to primary subsite as either supraglottic, glottis, subglottic or transglottic. Transglottic tumours represent tumours which involve all 3 subsites, although some older literature defines it as tumours which cross the laryngeal ventricle in a vertical direction.[1–3] For the sake of clarity, in this study, we refer to transglottic tumours as involving all 3 subsites.

# Contents

**Dedication** ..... i

**Declaration** ..... ii

**Candidate:** ..... ii

**Supervisor:** ..... ii

**Head of Department:** ..... iii

**Acknowledgements** ..... iv

**List of figures:** ..... v

**List of abbreviations** ..... vi

**Definitions** ..... vi

**ABSTRACT** ..... ix

Background ..... ix

Aim ..... ix

Methods ..... ix

Results ..... x

Conclusion ..... x

**CHAPTER 1 – INTRODUCTION** ..... 1

**CHAPTER 2 - LITERATURE REVIEW** ..... 2

2.1 Epidemiology ..... 2

2.2 Staging and prognosis ..... 3

2.3 Historical perspective ..... 3

2.4 Anatomical considerations ..... 4

2.4.1 Basic applied anatomy. ..... 4

2.4.2 The paraglottic spaces. ..... 5

2.4.3 The pre-epiglottic space ..... 5

2.4.4 Anatomic basis of extralaryngeal spread of carcinoma ..... 5

**CHAPTER 3 - MATERIALS AND METHODS** ..... 7

3.1 Hypothesis ..... 7

3.2 Study objectives ..... 7

3.3 Study Design ..... 7

3.4 Study location ..... 7

3.5 Study period ..... 7

3.6 Study population ..... 8
3.7 Data collection ..... 8
3.8 Data analysis ..... 9
3.9 Ethics ..... 9
3.10 Funding ..... 10
3.11 Potential limitations. ..... 10
**CHAPTER 4 – RESULTS** ..... 11
4.1 Study sample ..... 11
4.2 Demographic data ..... 11
4.2.1 Age ..... 11
4.2.2 Sex ..... 12
4.2.3 Race ..... 12
4.3 Thyroid gland involvement ..... 13
4.3 Thyroid gland involvement and correlation to anatomical subsites. ..... 14
**CHAPTER 5 – DISCUSSION** ..... 16
5.2 Age ..... 16
5.3 Sex ..... 16
5.4 Race ..... 17
5.5 Thyroid gland involvement ..... 17
5.5.1 Thyroid gland involvement associated with anterior commissure tumour ..... 17
5.5.2 Thyroid gland involvement associated with subglottic extension. ..... 18
5.5.3 Thyroid gland involvement associated with transglottic tumours. ..... 18
5.4 Summary ..... 19
**CHAPTER 6 - LIMITATIONS** ..... 20
**CHAPTER 7 - RECOMMENDATIONS AND FURTHER RESEARCH** ..... 21
**CHAPTER 8 - REFERENCES** ..... 22
**Appendix 1** ..... 25
**Appendix 2** ..... 27
**Appendix 3** ..... 28
**Appendix 4** ..... 29

## ABSTRACT

### Background

Thyroid gland involvement in advanced laryngeal malignancies is a rare entity, mostly resulting from direct contiguous spread from anterior and inferior tumours. Reported practice is to perform a hemithyroidectomy at the time of laryngectomy. However, this results in pointless excision of functional tissue and the added morbidity of hypothyroidism post operatively.

### Aim

The aim of this study is twofold: firstly, to assess the frequency of thyroid gland involvement in laryngectomy specimens from Chris Hani Baragwanath Hospital, and secondly, to determine any association between the anatomical subsites of tumour and thyroid gland involvement.

### Methods

This is a retrospective clinical audit of histological reports on laryngectomy specimens collected over a 10 year period from January 2005 and December 2014. The study was conducted at Chris Hani Baragwanath Hospital, affiliated to the University of the Witwatersrand, in South Africa. ENT operating registries and the laboratory database were used to access all records of total laryngectomies done over the 10 year period. Seventy-three laryngectomies were done, 9 were excluded as no thyroid tissue was included in the sample and 1 was excluded due to inadequate demographic detail. Thus a total of 63 histological reports were included in the study. Data extracted included age, race, sex, pathological stage of tumour, thyroid gland involvement and anatomical subsites involved by tumour (subglottis, anterior commissure and transglottic tumours).

Data was analysed using standard statistical methods including a Fischer-exact test and an ANOVA association test. Statistica software was used.

## Results

Four of the 63 cases had thyroid gland involvement (6.35%). The majority of the patients were black males in the age group 50 to 60 years of age. The tumours were all advanced laryngeal malignancies and only 2 of the 63 cases were found to have a diagnosis of adenosquamous carcinoma and chondrosarcoma.

None of the anatomical subsites were found to be statistically significant in association with thyroid gland involvement, however, this result was thought to be skewed due to the small number of tumours involving the thyroid gland.

## Conclusion

In accordance with South African and international studies on the same topic, thyroid gland involvement in laryngeal tumours is a rare occurrence. Due to the complications of performing a thyroidectomy and the hypothyroidism that accompanies it, a thyroidectomy should not always be performed. However, due to the recurrence rates and poor prognosis of patients with stomal recurrence (associated with thyroid gland involvement), thyroidectomy still needs to be considered. Based on known anatomical pathways of extralaryngeal spread of tumours via the anterior commissure, paraglottic spaces and those tumours involving the subglottis, selected patients require thyroidectomy at the time of laryngectomy to achieve adequate oncological margins.

# CHAPTER 1 – INTRODUCTION

In the Republic of South Africa, cancer of the larynx is placed fifth in prevalence among black men.[4] In the ENT department at Chris Hani Baragwanath Academic hospital, laryngeal carcinoma is a common and important reason for admission to the ENT ward, the majority of cases having advanced disease. Laryngectomy is a relatively common operation performed in our department and in the majority includes a form of thyroidectomy. Very few studies have been conducted in third world countries and only 1 in South Africa to determine the incidence of thyroid gland involvement in advanced squamous cell carcinoma of the larynx.[2]

# CHAPTER 2 - LITERATURE REVIEW

## 2.1 Epidemiology

Thyroid gland invasion in advanced laryngeal squamous cell carcinoma (SCC) of the larynx is a seemingly rare occurrence, however, literature reports of incidence vary widely - between 0 and 30%[5] Current practice is to perform some form of thyroidectomy (eg. hemithyroidectomy with or without isthmectomy, or even total thyroidectomy) at the time of total laryngectomy for appropriate candidates.[5,1,6] However, this can result in significant morbidity, in the form of hypothyroidism. Even with a hemithyroidectomy, a 23-63 percent incidence of hypothyroidism exists.[7–9] At the ENT department of Chris Hani Baragwanath Academic Hospital (CHBAH), thyroid resection as part of the oncologic procedure has a common sense approach based on the known behaviours of laryngeal squamous cell carcinoma. The left and/or right lobe/s of the gland is/are encompassed in the oncologic resection based on computed tomography scan evidence of infiltration, patients with advanced transglottic tumours, patients with clinical evidence of anterior commissure infiltration, and clinical evidence of malignant attachment of the thyroid gland to the thyroid cartilage at the time of surgery.[5,7,8]

Hemithyroidectomy or subtotal thyroidectomy is recommended for cases in which palpable pathology is present within the gland, subglottic tumours or glottic tumours with subglottic extension of more than 1cm.[10] However, it should not be a routine procedure when performing a total laryngectomy in order to avoid post-operative morbidity and complications.[11,12]

A literature review shows incidence rates of thyroid gland invasion of between 0% and 30%, with the largest sample involving 343 patients. [5,13,14] Meta-analysis of the literature shows an overall incidence of 8.42% invasion of the thyroid gland.[5,1,6–9,13,14] Of note, is the study published in 1997, which is more applicable to our setting as it is based on a South African context.[2] The study looked at cT3 laryngeal tumours in which a total laryngectomy was performed, and routine hemithyroidectomy was undertaken at that time. The sample size was 102 total laryngectomies of which 73 had thyroid tissue sampled, and 2 were found to have thyroid gland

involvement (2.7%) Morbidity of hemithyroidectomy, anatomic variants or predispositions and oncological adequacy were discussed. Fagan concluded that thyroidectomy should only be performed in selected patients undergoing total laryngectomy, and that this should be based on intra-operative assessment of the thyroid gland, thyroid capsule and outer surface of the larynx and trachea. He also suggested frozen section in difficult to determine cases. In the absence of thyroid gland involvement clinically, both lobes of the thyroid should be spared. If the thyroid is invaded, a total thyroidectomy should be performed and if the tumour extends into the subglottis, a total thyroidectomy should be performed. By adopting this approach, the morbidity of hypothyroidism post-operatively can be avoided and improve the quality of life of laryngectomies, but locoregional control and survival are not compromised.

## 2.2 Staging and prognosis

Invasion of the thyroid gland is classified as stage T4a under AJCC TNM classification (appendix 1), unless distant metastases has occurred. The 3 and 5 year disease free survival period in T4a tumours is approximately 45 and 30-35% respectively. However, reported 3 and 5 year survival rate in patients with thyroid gland invasion is 0-22%, significantly worse than that without.[8,9,13,14] Also, stomal recurrence is reported much more frequently in patients with thyroid gland involvement,[1,13] and the prognosis and 5 year survival of patients with stomal recurrence is much lower,[12] which lends to the argument that thyroidectomies should be performed in select cases when proceeding with a total laryngectomy.

Local and systemic effects of hypothyroidism can have deleterious effects on quality of life for patients undergoing total laryngectomy but because the prognosis and risk of stomal recurrence is so high in patients with thyroid gland involvement, consideration for thyroidectomy needs to be thorough, experienced and incorporate pre and intra-operative decision making.[6,12]

## 2.3 Historical perspective

In 1955, Ogura published an article discussing surgical management of SCC of the larynx.[15] Ten percent of his study patients had thyroid gland invasion. His conclusion

was that the thyroid gland is “a likely metastatic feature” of SCC of the larynx. He recommended that all patients undergoing total laryngectomies should also undergo routine ipsilateral hemithyroidectomy and isthmectomy to ensure adequate control of the tumour. In 1973, Harrison concurred with this recommendation.[16]

This approach started coming under scrutiny when surgeons began the move towards organ preserving surgery and were faced with the morbidity of hypothyroidism. In 1979, Sessions noted that less than 1% of cases had thyroid gland invasion from SCC of the larynx and advocated only performing thyroidectomies in select cases.[17] In recent years, there has been an evolving trend to perform “organ-preservation” surgery and thus allow anatomical structures to maintain their form and function. This aims to avoid long term morbidity associated with en bloc excisions of head and neck cancer.

## 2.4 Anatomical considerations

Invasion of the thyroid gland from laryngeal SCC is mostly as a result of direct or contiguous spread, or rarely by lymphatic spread.[5,14]

### 2.4.1 Basic applied anatomy.

The larynx in humans, is situated in the neck opposite the third to sixth vertebrae in men, and slightly higher in women and children.[18] The skeletal framework of the larynx is made up of a variety of cartilages, held together by muscles, ligaments and membranes to allow a very exact movement to perform the function of both airway protection and the ability to produce voice. The larynx is lined with a mucous membrane which is contiguous with the mucous membrane lining of the pharynx and oesophagus above and behind the larynx, as well as the trachea below it.[18]

The largest cartilage is the thyroid cartilage which is composed of two laminae fused in the midline anteriorly. The inner aspects of the laminae are covered by loosely attached mucous membranes. The midline is of importance in the spread of carcinomas and is the site of attachment for the thyroepiglottic ligament superiorly and the vestibular and vocal ligaments on either side of the midline further inferiorly. Also, the thyroarytenoid, thyroepiglottic and vocalis muscles attach to the inner midline of the thyroid cartilage. The fusion of the anterior edges of the two vocal

ligaments forms the anterior commissure tendon, a very important route of spread for carcinoma.

The cricothyroid membrane is attached to the medial border of the inferior aspect of the thyroid cartilage and extends to the cricoid cartilage.

### 2.4.2 The paraglottic spaces.

Paraglottic spaces are paired on either side of the larynx. They are bound superiorly by the quadrangular membrane, inferiorly, the medial margin is the conus elasticus.[10] It runs the length of the larynx and includes the supraglottis, the glottis and the subglottis. It is an hourglass shape and contains the substance of the larynx, namely the air-filled ventricles and saccules and the rima glottis. Spread of tumours is impeded somewhat by the hour-glass shape formed by the indentation of the ventricles. However, Reinke's space within the mucosa of the larynx allows for tumour spread with little resistance.[10]

### 2.4.3 The pre-epiglottic space

The pre-epiglottic space is the superior most space within the larynx. It is demarcated anteriorly by the thyroid cartilage and thyrohyoid membrane; superiorly by the hyoid and the mucous membranes of the valleculae; posterolaterally it is contiguous with the paraglottic spaces. It is filled with fat and traversed by lymph and blood vessels.[10] Due to the nature of its contents and its relationship with the paraglottic spaces, this pre-epiglottic space is an important route of spread for carcinoma.

### 2.4.4 Anatomic basis of extralaryngeal spread of carcinoma

Laryngeal SCC exits the framework of the larynx in a contiguous manner through so-called "weak spots". These include along the collagen bundles where the connective tissue membranes attach to the cartilage. It is thought that as the cancer extends into the collagen, the collagen bundles expand, resulting in a direct pathway for the spread of cancer through the perichondrium.[19] This can explain the route of extension into the thyroid gland via the cricothyroid membrane and the anterior commissure. Also, a defect is found at the site where Broyle's ligament inserts into the inner perichondrium at the anterior angle of the thyroid cartilage. The defect in

the protective perichondrium results in a further pathway for spread of tumour. Once the tumour has breached the protective layer, it can spread throughout the cartilage and beyond the larynx. Thus any tumours in which there is spread to the anterior commissure, cricothyroid membrane or if there is perichondrial compromise, should be suspect for extralaryngeal spread to the thyroid gland based on anatomical proximity.[13]

Subglottic tumours, defined as extending more than 10mm from the free vocal cord edge,[10] are associated with a very high thyroid gland involvement rate. Route of spread is thought to be through the gaps between the cartilaginous rings going through boundaries of cartilaginous frame work. Tumour spread is found to be primarily through the paraglottic spaces into the regions bound medially by the conus elasticus and laterally by the laryngeal cartilages. Subglottic spread is further associated with paratracheal, pretracheal and prelaryngeal lymph node metastases, all of which are in close anatomical proximity to the thyroid gland.[13]

Transglottic tumours are likely to spread inferiorly due to the lack of cartilaginous impedence. As tumour spread passes inferiorly through the paraglottic space, it is halted medially by the conus elasticus and thus is diverted laterally through the cricothyroid membrane, and exits the larynx towards the thyroid gland.[13]

Lastly, it is also found that tumour spread is increased by ossified cartilage, thought to be due to interruption of normal vascularity.[18] Thus in older patients, extralaryngeal spread is more likely.

In conclusion, tumours involving the subglottis, anterior commissure and advanced transglottic tumours are associated with a higher incidence of thyroid gland involvement.[6,7,13,14,13,18]

# CHAPTER 3 - MATERIALS AND METHODS

## 3.1 Hypothesis

Infiltration of the thyroid gland is not common, and therefore does not warrant thyroidectomy in all cases.

## 3.2 Study objectives

- To determine the frequency of thyroid gland extension of advanced malignancy of the larynx in total laryngectomy specimens.
- To determine the association between thyroid gland involvement and tumour involving specific anatomical subsites:
    - subglottis
    - anterior commissure
    - transglottic tumours

## 3.3 Study Design

The study was a retrospective clinical audit.

## 3.4 Study location

The study was performed at the Chris Hani Baragwanath Academic Hospital in Diepkloof, Soweto, South Africa. This is a tertiary level teaching hospital which is under the jurisdiction of the Gauteng Department of Health and is the largest of the teaching hospitals affiliated to the University of the Witwatersrand.

## 3.5 Study period

The study covered the time period from January 2005 until December 2014 (10 years)

### 3.6 Study population

The study included all patients who underwent total laryngectomy for advanced laryngeal malignancy within the study period. On average, 8 laryngectomies were performed each year.

Inclusion criteria:

- All patients with advanced laryngeal malignancy who underwent total laryngectomy with some form of thyroid gland resection, as part of their treatment.

Exclusion criteria

- Patients in whom a laryngectomy was performed for other indications than malignancy.
- Patients in which no thyroidectomy was performed.

### 3.7 Data collection

Patients were identified from three sources:

- The ENT operating theatre register
- The ENT ward admissions register and discharge summaries
- The National Health Laboratory System electronic data base (LabTrack and Disa systems)

Cases were identified using the operating theatre register primarily, to identify the names and details of the patients who had undergone total laryngectomies within the study period. Details and missing information were corroborated and found from the ward register. The NHLS database was then used to retrieve the details of the histological reports from these cases and subsequently categorized as:

- Full histological reports
- Laryngectomy specimen including thyroid tissue
- Laryngectomy specimen not including thyroid tissue
- Incomplete or incorrect information, in which insufficient information was available in order to include in the case series.

The following data was recorded for each patient: (Data collection sheet: appendix 2)

- Age
- Sex
- Race
- Date of surgery
- Histological result
- Involvement of thyroid gland
- Involvement of anatomic subsites

All information was recorded electronically using Microsoft Excel.

### 3.8 Data analysis

Histological results were statistically analysed using:

- A Fischer exact test to determine frequency distribution of thyroid gland invasion.
- An ANOVA association test was used to assess the incidence as it is a multivariate observation. The different anatomical subsites made up the categories and the final outcome is thyroid gland invasion as determined histologically.
- A probability (p) value of less than 0.05 was regarded as significant.
- Above tests were incorporated into the Statistica software program.
- Microsoft Excel for comparison of samples, summary of statistics.
- Microsoft Word for final documentation and presentation.

### 3.9 Ethics

Ethics approval was obtained from the Human Research Ethics Committee of the University of the Witwatersrand, clearance certificate number M150440 (appendix 3). As this is a retrospective clinical audit, no patient consent was needed.

Signed, written approvals was obtained from the relevant authorities at the CHBAH (appendix 4), as well as the Head of Department of Anatomical Pathology at the NHLS (appendix 5), to obtain histological reports from the data bases.

### 3.10 Funding

Funding was needed for printing and binding of the study only. This was obtained from the applicant.

### 3.11 Potential limitations.

- Retrospective study
- Inadequate records
- Inadequate patient numbers

# CHAPTER 4 – RESULTS

## 4.1 Study sample

A total of 74 laryngectomies were performed in the time period January 2005 until December 2014. Of these, 8 were excluded as there was either no thyroidectomy performed, or the histological report did not include mention of the thyroid gland and one case was excluded due to insufficient demographic and histological information. Thus a total of 65 total laryngectomy specimens were analysed.

Sixty three of the cases (96.83%) underwent total laryngectomy for the diagnosis of squamous cell carcinoma. One patient was diagnosed with adenosquamous carcinoma (1.59%) and another with chondrosarcoma. (1.59%)

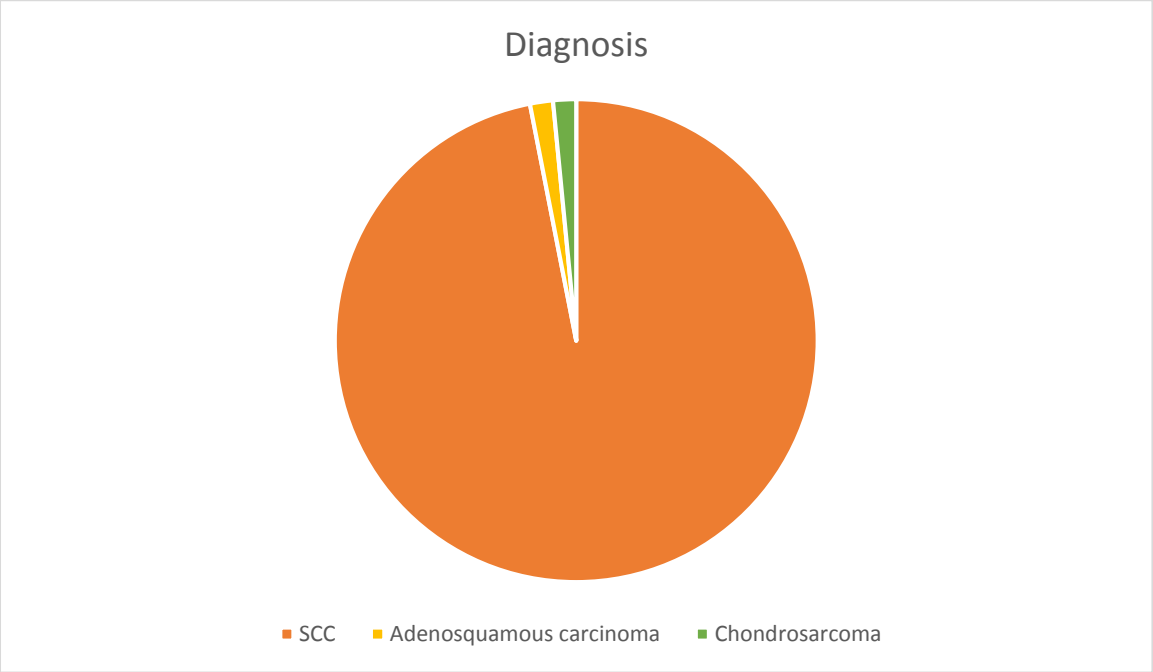


Figure 1. Histological types found in laryngectomy specimens

## 4.2 Demographic data

### 4.2.1 Age

The age ranged from 30 years of age to 76 years with a mean age of 58.4 and a median of 59 (SD9.25). The majority of patients (n=22) fell into the group of patients

between 60 and 69 years of age. Of note, the youngest patient (age 30) to undergo a total laryngectomy was diagnosed with chondrosarcoma.

The mean age of patients with tumours involving the thyroid gland was 61 years (SD: 5.77) and that of the patients with no thyroid involvement was 58 (SD: 9.36). However, a t-test revealed no statistical significant difference between these two groups (p=0.65) and the possibility of skewed data due to a small number of thyroid gland involvement must be considered.

### 4.2.2 Sex

Males presented the majority of the patient at 95.24% (n=60), where females made up 4.76% (n=3). The male to female ratio is thus 20:1

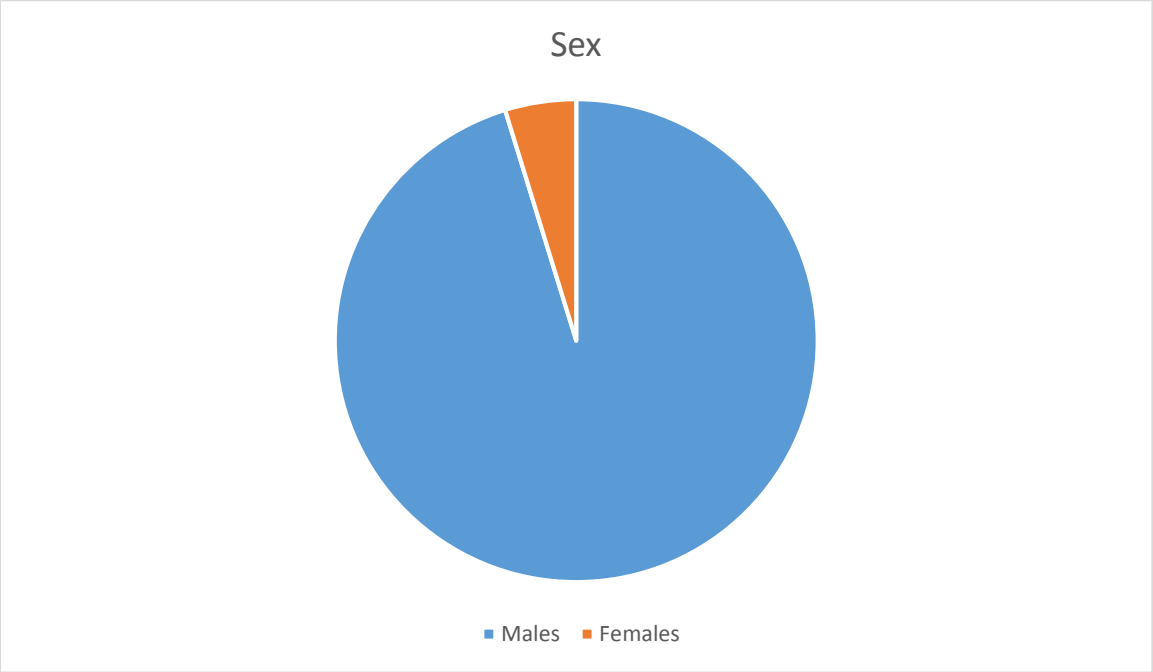


Figure 2: Distribution of sex between sample patients

### 4.2.3 Race

The sample was comprised of majority of black patients (n=53, 83.87%). There were 9 white patients and 1 Asian patient comprising 14.52% and 1.61% respectively. All patients with thyroid gland involvement were in the black population.

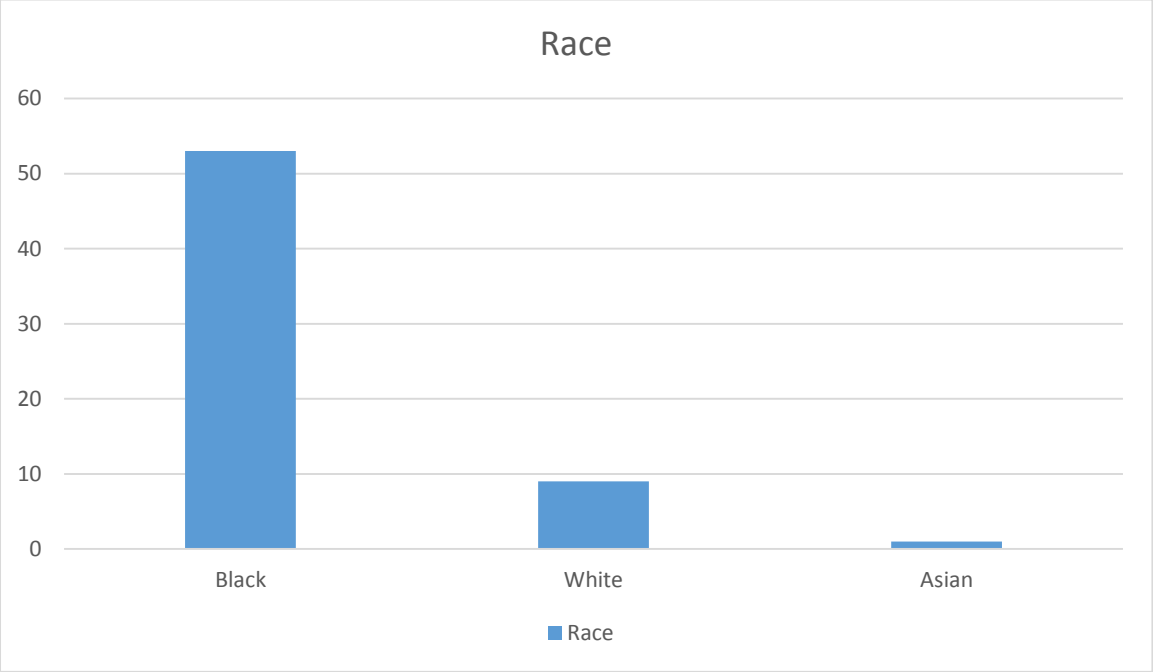


Figure 3: Race groups of sample patients

### 4.3 Thyroid gland involvement

Of the 63 patients analysed, 4 had thyroid gland invasion by laryngeal malignancy (6.35%) and 59 did not (93.35%) All 4 cases were in males, comprising 6.66% of the male subjects. Ninety three percent of male patients did not have thyroid gland involvement. No (n=0) female patients had thyroid gland involvement. All cases (n=4) with thyroid gland involvement were in patients with squamous cell carcinoma.

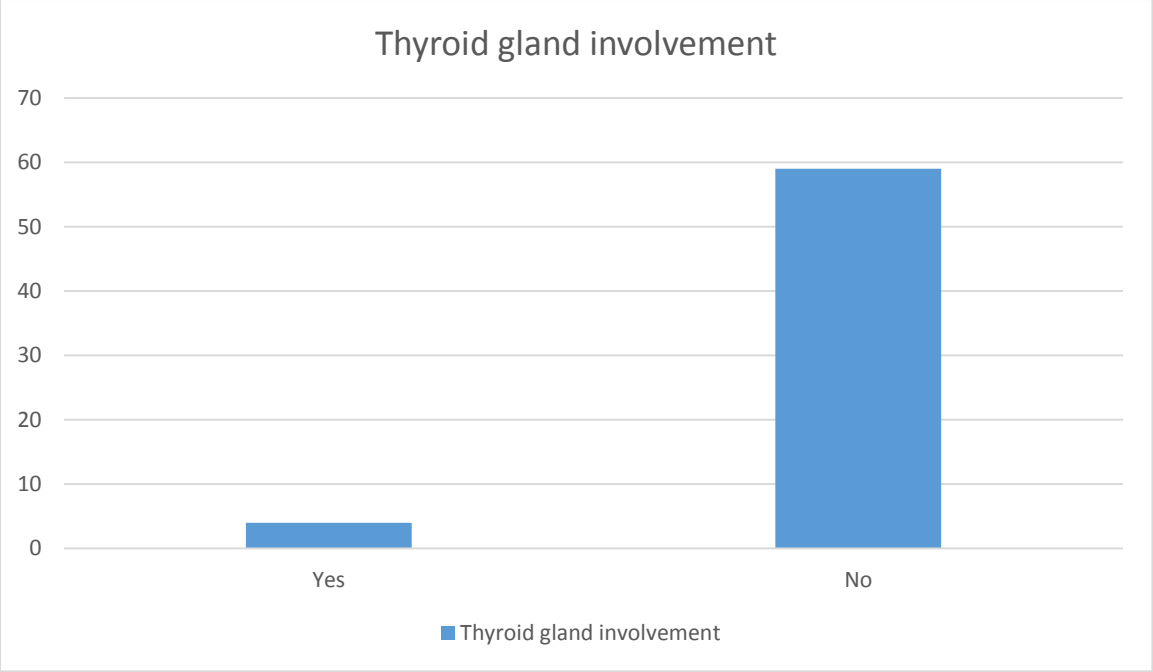


Figure 4: Thyroid gland involvement in laryngectomy specimens

### 4.3 Thyroid gland involvement and correlation to anatomical subsites.

As an association with thyroid gland involvement, multivariate tests were applied to distinguish any correlation with specific anatomical subsites, namely the anterior commissure, subglottis and transglottic tumours. None of the associations were found to be statistically significant.

Fifty two of the 63 cases had anterior commissure involvement (82.54%). All 4 cases with thyroid gland involvement, were also involving the anterior commissure. (7.69% of tumours involving anterior commissure) (p=0.341840)

Forty one of the 63 cases had subglottic extension (65.08%) and 22 did not (34.92%). Three of the cases with thyroid gland involvement were extending to the subglottis, and 1 was not. (p=0.667136)

Forty seven of the 63 cases were transglottic tumours (74.60%) involving the supraglottis, glottis and subglottis. As 1 case did not extend into the subglottis, 3 of the 4 were defined as transglottic tumours. (p=0.227884)

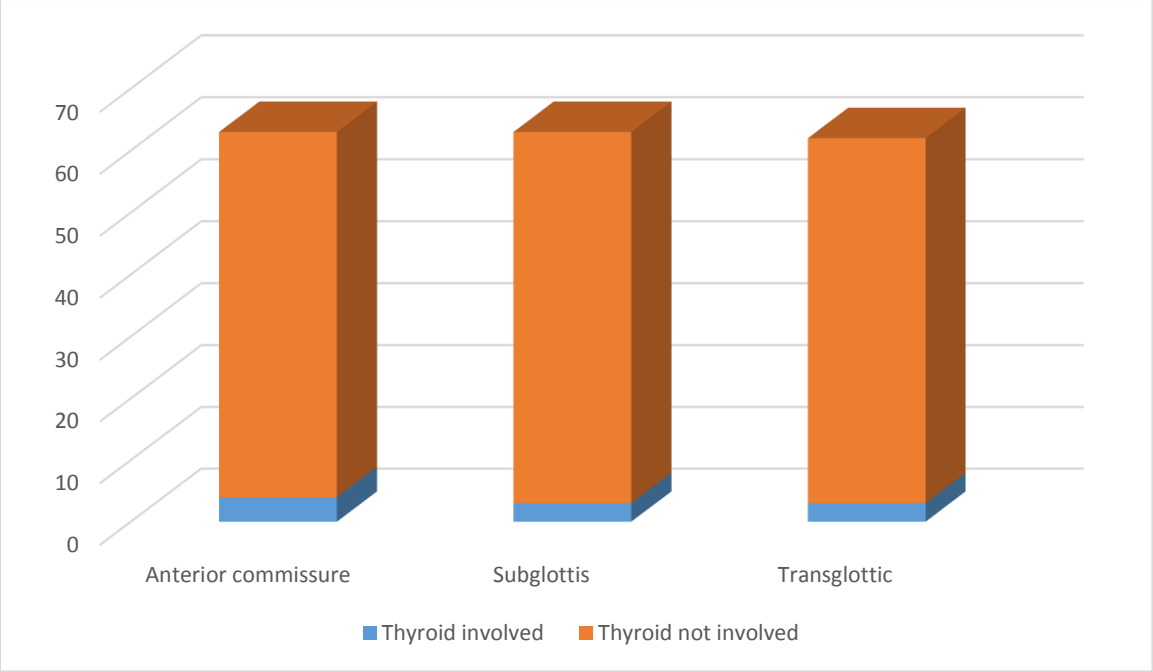


Figure 5: Anatomic subsites involved by tumour and the relative involvement of the thyroid gland.

# CHAPTER 5 – DISCUSSION

The aim of the study was, firstly to assess the frequency of thyroid gland involvement in advanced laryngeal malignancies and secondly, to assess any association between thyroid gland involvement and anatomical subsites, namely the anterior commissure, subglottis and any transglottic tumours. Gorphe et al recommended in October 2015 that in their department the following cases carried a high risk for extralaryngeal spread and thus warranted a thyroidectomy:

- Subglottic primary site or wide bilateral subglottic extension from a glottis primary site
- Glottis tumour with anteroinferior submucosal spread that reaches the cricothyroid membrane
- Transfixion of the inferior third of the thyroid cartilage
- Anteroinferior extralaryngeal spread
- Radiological evidence of thyroid gland invasion[14]

By examining some of the same anatomical subsites, we can determine any similarities in our study population.

## 5.2 Age

The mean age of 58 years in our study is similar to that of Fagan and of international studies,[2,5,7,8,13,14] where mean age ranged from 54 to 62 years. With the risk of malignancy increasing with older age,[10,18] it is not surprising that the majority of our studied patients fell into the 60 - 70 year age group.

## 5.3 Sex

As with all other articles on this topic, the majority of patients are male (>90% overall). The risk of having a laryngeal malignancy is associated with male sex, cigarette smoking and advancing age.[18] Although cigarette smoking was not studied in this situation, it is known that more men are smokers than women.[4]

Thus our study seems to represent the high risk group of patients for laryngeal malignancies.

### 5.4 Race

International studies do not compare frequency of laryngeal malignancy and thyroid gland involvement by race,[1,6–8,12–14,20] and race was not included in the South African study.[2] Our study showed a majority of black patients. Considering the location of the study, this is indicative of the population served by Chris Hani Baragwanath Academic Hospital and as indicated as a limitation of this study, may not represent the patient profile of laryngeal malignancies worldwide.

### 5.5 Thyroid gland involvement

In our study, 4 out of 63 patients (6.35%) had thyroid gland involvement. Overall incidence in the literature reviewed shows a frequency of 8.42%, indicating that our study population had a similar frequency of thyroid gland involvement. With the consideration of the effects of performing a thyroidectomy, as well as the risks associated with residual disease and positive surgical margins, thyroidectomy at the time of laryngectomy remains controversial.

#### 5.5.1 Thyroid gland involvement associated with anterior commissure tumour

Although our study shows no statistical significance regarding the association between thyroid gland involvement and anterior commissure tumour, it is noteworthy that all 4 cases of thyroid gland involvement had anterior commissure tumour. From an anatomic and pathological point of view, it is understood that the anterior commissure does allow spread of tumour to extralaryngeal structures and considering the anatomic position of the thyroid, it is still regarded as a method of extension of tumour to the thyroid gland.[12,13] At present, in our department, it is recommended to do an ipsilateral hemithyroidectomy in patients with tumours extending into the anterior commissure. This is also correlated clinically in terms of radiological findings and intra-operative palpation. Literature does recognize that the anterior commissure is a gateway for laryngeal tumour spread,[12–14] and most authors agree that should the anterior commissure be involved, that an elective hemithyroidectomy at the time of laryngectomy is justified. With this in mind, and the high percentage of anterior commissure tumours involving the thyroid gland in our

study, it is sensible to continue to perform an ipsilateral hemithyroidectomy at the time of laryngectomy in advanced laryngeal malignancies.

### 5.5.2 Thyroid gland involvement associated with subglottic extension.

It has been shown that subglottic tumours extend beyond the laryngeal framework through the spaces in between the tracheal rings and through the cricothyroid membrane.[2,1,6–9,12–14,20] Although not all statistically significant, it is thought that in patients with tumours which extend beyond 15mm into the subglottis, should have routine thyroidectomies at the time of laryngectomy. As the cricothyroid membrane is thought to be the main route of spread of laryngeal tumour to the extralaryngeal areas anteriorly,[1,13] and is situated within the subglottic area, it is anatomically sound to do a thyroidectomy in these cases in order to achieve an oncological margin. In our study, 3 of the 4 thyroid gland involved tumours extended into the subglottis, however, this was not found to be statistically significant. Considering the poor outcome in recurrent laryngeal tumours and the poor prognosis of those patients with stomal recurrence, associated with subglottic tumours, it is advised to do a total thyroidectomy in subglottic tumours.[1,2,8,13]

### 5.5.3 Thyroid gland involvement associated with transglottic tumours.

Transglottic tumours are defined as involving the supraglottis, glottis and subglottis.[3] In Fagan's study, it was found that all patients in which the thyroid gland was involved, had transglottic tumours.[2] In our study, 3 out of 4 patients with thyroid gland involvement also had transglottic tumours. International studies found high percentages of thyroid gland involved tumours to be transglottic: Nayak et al found 73% of their cases to be transglottic.[8] Mourad et al found that of 7 patients who had thyroid gland involvement, 5 had transglottic tumours.[13] Transglottic tumours are associated with advanced disease and thus the risk of extralaryngeal spread is increased. Transglottic tumours are also associated with paraglottic space invasion which increases the chance of thyroid gland involvement,[1] thus these tumours have a higher propensity to need a hemithyroidectomy. In our setting, we find a high percentage of our patients have advanced disease with the majority of cases being transglottic.

## 5.4 Summary

Our study finds that the results are similar to those of Fagan's South African based study,[2] as well as comparable to international studies performed on the same basis: that thyroid gland invasion by advanced laryngeal malignancies is rare. Although our findings are not statistically significant, anatomical subsites rendering higher risk of thyroid gland extension of tumour are still thought to impact on the decision to perform thyroidectomies or not at the time of laryngectomy. Gorphe et al recommended in October 2015 that in their department the following cases carried a high risk for extralaryngeal spread and thus warranted a thyroidectomy:

- Subglottic primary site or wide bilateral subglottic extension from a glottis primary site
- Glottis tumour with anteroinferior submucosal spread that reaches the cricothyroid membrane
- Transfixion of the inferior third of the thyroid cartilage
- Anteroinferior extralaryngeal spread
- Radiological evidence of thyroid gland invasion[14]

## CHAPTER 6 - LIMITATIONS

It is accepted that there are certain limitations as this is a retrospective audit of histological data.

The sample size over 10 years is small, with only 63 cases included in this study. In comparison to other studies in specialised centres, this number is comparable.

The study only looks at patients in one hospital, serving a very large area incorporating majority black patients. Other population groups may not be adequately represented.

Compared to the one other South African study of this nature, the sex profile of the study group is similar in that the patients are mostly male. The mean age is also comparable but there was no discussion of race by Fagan.[2]

Histological material was easily accessible but was not always reported in a uniform manner, creating difficulty in extracting data from the reports.

## CHAPTER 7 - RECOMMENDATIONS AND FURTHER RESEARCH

In order for us to adopt such protocols, further research incorporating higher numbers of patients, needs to be undertaken in order for a population specific risk profile to be determined. To achieve this, a prospective multicentre trial should be done.

Histological variables, such as degree of differentiation and keratinisation in squamous cell carcinoma also need to be considered.

Case specific surgical plans still need to be made.

## CHAPTER 8 - REFERENCES


1. Mendelson AA, Al-Khatib TA, Julien M, Payne RJ, Black MJ, Hier MP. Thyroid gland management in total laryngectomy: Meta-analysis and surgical recommendations. *Otolaryngol - Head Neck Surg*. 2009;140:298-305. doi:10.1016/j.otohns.2008.10.031.

2. Fagan JJ, Kaye P V. Management of the thyroid gland with laryngectomy for cT3 glottic carcinomas. *Clin Otolaryngol Allied Sci*. 1997;22:7-12. http://www.ncbi.nlm.nih.gov/pubmed/9088672.

3. Benninger MS. Scott-Brown's Otorhinolaryngology: Head and Neck Surgery 7Ed. In: *Scott-Brown's Otorhinolaryngology: Head and Neck Surgery 7Ed*.; 2008:1439-1447. doi:10.1201/b15118.

4. Fact sheet on Cancer of the Larynx. CANSA – The Cancer Association of South Africa website. http://www.cansa.org.za/south-african-cancer-statistics/. Published September 2015, based on National Cancer Registry report 2011. Accessed February 2016.

5. Elliott MS, Odell EW, Tysome JR, et al. Role of thyroidectomy in advanced laryngeal and pharyngolaryngeal carcinoma. *Otolaryngol - Head Neck Surg*. 2010;142(6):851-855. doi:10.1016/j.otohns.2010.02.006.

6. Ceylan A, Köybaşioğlu A, Yilmaz M, Uslu S, Asal K, Inal E. Thyroid gland invasion in advanced laryngeal and hypopharyngeal carcinoma. *Kulak burun bogaz Ihtis Derg KBB J Ear Nose Throat*. 2004;13:9-14.

7. Gerbez MK, Aikalin M, Tasar S, et al. Clinical effectiveness of thyroidectomy on the management of locally advanced laryngeal cancer. *Auris Nasus Larynx*. 2014;41:69-75. doi:10.1016/j.anl.2013.10.004.

8. Nayak SP, Singh V, Dam A, et al. Mechanism of Thyroid Gland Invasion in Laryngeal Cancer and Indications for Thyroidectomy. *Indian J Otolaryngol Head Neck Surg*. 2013;65(July):69-73. doi:10.1007/s12070-012-0530-9.

9. Dequanter D, Shahla M, Paulus P, Vercruysse N, Lothaire P. The Role of Thyroidectomy in Advanced Laryngeal and Pharyngolaryngeal Carcinoma. *Indian J Otolaryngol Head Neck Surg*. 2013;65:181-183. doi:10.1007/s12070-012-0555-0.

10. Flint P, Cummings C, Haughey B, Lund V, Niparko J, Richardson M. *Cummings Otolaryngology Head & Neck Surgery*.; 2010:2963. http://discovery.ucl.ac.uk/933877/.

11. Dadas B, Uslu B, Cakir B, Ozdoğan HC, Caliş AB, Turgut S. Intraoperative management of the thyroid gland in laryngeal cancer surgery. *J Otolaryngol*. 2001;30:179-183. http://www.ncbi.nlm.nih.gov/pubmed/11771049.

12. Sparano A, Chernock R, Laccourreye O, Weinstein G, Feldman M. Predictors of thyroid gland invasion in glottic squamous cell carcinoma. *Laryngoscope*. 2005;115:1247-1250. doi:10.1097/01.MLG.0000165454.75480.EA.

13. Mourad M, Saman M, Sawhney R, Ducic Y. Management of the thyroid gland during total laryngectomy in patients with laryngeal squamous cell carcinoma. *Laryngoscope*. 2015;125:1835-1838. doi:10.1002/lary.25263.

14. Gorphe P, Ben Lakhdar A, Tao Y, Breuskin I, Janot F, Temam S. Evidence-based management of the thyroid gland during a total laryngectomy. *Laryngoscope*. 2015;125:2317-2322. doi:10.1002/lary.25417.

15. Ogura J. Surgical pathology of cancer of the larynx. *Laryngoscope*. 1955;65:867-926.

16. Harrison D. Thyroid gland in the management of laryngopharyngeal cancer. *Arch Otolaryngol*. 1973;97:301-302.

17. Sessions DG. Surgical pathology of cancer of the larynx and hypopharynx. *Laryngoscope*. 1976;86:814-839. doi:10.1288/00005537-197606000-00009.

18. Payne S, Miles D. Scott-Brown’s Otorhinolaryngology: Head and Neck Surgery. *Scott-Brown’s Otorhinolaryngol Head Neck Surg*. 2008:34-46. doi:10.1201/b15118-6.

19. Yeager VL, Archer CR. Anatomical routes for cancer invasion of laryngeal cartilages. *Laryngoscope*. 1982;92:449-452. http://www.ncbi.nlm.nih.gov/pubmed/7070185.

20. Dadas B, Uslu B, Cakir B, Ozdogan HC, Calis AB, Turgut S. Intraoperative management of the thyroid gland in laryngeal cancer surgery. *J Otolaryngol*. 2001;30:179-183. http://www.ncbi.nlm.nih.gov/entrez/query.fcgi?cmd=Retrieve&db=PubMed&dopt=Citation&list_uids=11771049.

## Appendix 1

| **Primary Tumour (T)** | |
|---|---|
| TX | Primary tumour cannot be assessed. |
| T0 | No evidence of primary tumour. |
| Tis | Carcinoma *in situ*. |
| ***Supraglottis*** | |
| T1 | Tumour limited to one subsite of supraglottis with normal vocal cord mobility. |
| T2 | Tumour invades mucosa of more than one adjacent subsite of supraglottis or glottis or region outside the supraglottis (e.g., mucosa of base of tongue, |
| | vallecula, medial wall of pyriform sinus) without fixation of the larynx. |
| T3 | Tumour limited to larynx with vocal cord fixation and/or invades any of the following: postcricoid area, pre-epiglottic space, paraglottic space, and/or inner cortex of thyroid cartilage. |
| T4a | Moderately advanced local disease. |
| | Tumour invades through the thyroid cartilage and/or invades tissues beyond the larynx (e.g., trachea, soft tissues of neck including deep extrinsic muscle of the tongue, strap muscles, thyroid, or oesophagus). |
| T4b | Very advanced local disease. |
| | Tumour invades prevertebral space, encases carotid artery, or invades mediastinal structures. |
| ***Glottis*** | |
| T1 | Tumour limited to the vocal cord(s) (may involve anterior or posterior commissure) with normal mobility. |
| T1a | Tumour limited to one vocal cord. |
| T1b | Tumour involves both vocal cords. |
| T2 | Tumour extends to supraglottis and/or subglottis and/or with impaired vocal cord mobility. |

| | |
|---|---|
| T3 | Tumour limited to the larynx with vocal cord fixation and/or invasion of paraglottic space and/or inner cortex of the thyroid cartilage. |
| T4a | Moderately advanced local disease. |
| | Tumour invades through the outer cortex of the thyroid cartilage and/or invades tissues beyond the larynx (e.g., trachea, soft tissues of neck including deep extrinsic muscle of the tongue, strap muscles, thyroid, and oesophagus). |
| T4b | Very advanced local disease. |
| | Tumour invades prevertebral space, encases carotid artery, or invades mediastinal structures. |
| ***Subglottis*** | |
| T1 | Tumour limited to the subglottis. |
| T2 | Tumour extends to vocal cord(s) with normal or impaired mobility. |
| T3 | Tumour limited to larynx with vocal cord fixation. |
| T4a | Moderately advanced local disease. |
| | Tumour invades cricoid or thyroid cartilage and/or invades tissues beyond the larynx (e.g., trachea, soft tissues of neck including deep extrinsic muscles of the tongue, strap muscles, thyroid, or oesophagus). |
| T4b | Very advanced local disease. |
| | Tumour invades prevertebral space, encases carotid artery, or invades mediastinal structures. |

## Appendix 2

The frequency of thyroid gland invasion in advanced laryngeal malignancy: An audit of total laryngectomy histological specimens.

Dr AH Makepeace

722272

**Data capture sheet**

| | |
|---|---|
| Patient number | |
| Age | |
| Sex | |
| Race | |
| Date of surgery | |
| Diagnosis | |
| Thyroid gland inclusion | |
| Pathological staging | |
| Thyroid | |
| Anterior commissure | |
| Subglottis | |
| Transglottic | |

## Appendix 3

R14/49 Dr Alison Makepeace

**HUMAN RESEARCH ETHICS COMMITTEE (MEDICAL)**

**CLEARANCE CERTIFICATE NO. M150449**

| | |
|---|---|
| **NAME:** (Principal Investigator) | Dr Alison Makepeace |
| **DEPARTMENT:** | Neurosciences<br>Chris Hani Baragwanath Academic Hospital |
| **PROJECT TITLE:** | Advanced Transglottic Squamous Cell Carcinoma and the Incidence of Thyroid Gland Involvement: An Audit of Hisyological Specimens |
| **DATE CONSIDERED:** | 24/04/2015 |
| **DECISION:** | Approved unconditionally |
| **CONDITIONS:** | |
| **SUPERVISOR:** | Dr Y Atiya |
| **APPROVED BY:** | Professor P Cleaton-Jones Chairperson, HREC (Medical) |
| **DATE OF APPROVAL:** | 05/06/2015 |

**This clearance certificate is valid for 5 years from date of approval. Extension may be applied for.**

**DECLARATION OF INVESTIGATORS**

To be completed in duplicate and **ONE COPY** returned to the Secretary in Room 10004, 10th floor, Senate House, University.

I/we fully understand the conditions under which I am/we are authorized to carry out the above-mentioned research and I/we undertake to ensure compliance with these conditions. Should any departure be contemplated from the research protocol as approved, I/we undertake to resubmit the application to the Committee. **I agree to submit a yearly progress report.**

Principal Investigator Signature Date

PLEASE QUOTE THE PROTOCOL NUMBER IN ALL ENQUIRIES

## Appendix 4

health and social development
Department: Health and Social Development
GAUTENG PROVINCE

**DR MRI AHMED**
**TEL NO. 933-8118**

**CHRIS HANI BARA ACADEMIC HOSPITAL**
**P.O. BERTSHAM**
**2013**
**31 March 2015**

**To whom it may concern,**

**Re: MMED research study: ADVANCED TRANSGLOTTIC SQUAMOUS CELL CARCINOMA AND THE INCIDENCE OF THYROID GLAND INVOLVEMENT: AN AUDIT OF HISTOLOGICAL SPECIMENS**

I, Dr MRI Ahmed, HOD of the ENT Department at Chris Hani Baragwanath Academic Hospital hereby give permission to Dr AH Makepeace to conduct the above mentioned retrospective study at this hospital, in our department as part of her MMed requirements.

Kind regards

.....
**Signature**

.....
**Date**

GAUTENG PROVINCE
HEALTH
REPUBLIC OF SOUTH AFRICA

**CHRIS HANI BARAGWANATH ACADEMIC HOSPITAL**
IN THE OFFICE OF THE CEO
Enquiries: Ms. Thabile Ndlovu
Tel : (011) 933- 9145
Fax: (011) 938-1005
Email: Thabile.Ndlovu2@gauteng.gov.za

**To** : Dr. A Makepeace
(M150440)

**From** : Dr. Sandile Mfenyana
CEO: CHBA hospital

**Date** : 25 May 2015

**Re** : ADVANCED TRANSGLOTTIC SQUAMOS CELL CARCINOMA AND THE INCIDENCE OF THYROID GLAND INVOLVEMENT: AN AUDIT OF HISTOLOGICAL SPECIMENS

Your application to request permission to conduct Advanced Transglottic Squamous Cell Carcinoma and the Incidence of Thyroid Gland Involvement: An audit of Histological Specimens at Chris Hani Baragwanath Academic Hospital is approved by the CEO: Dr. Sandile Mfenyana

Hoping that the Institution (CHBAH) will meet the requirements of the study concerned.

Wishing you well in your future endeavors

Regards,



DR. SCB Mfenyana
CEO: CHBA Hospital

NATIONAL HEALTH LABORATORY SERVICE
UNIVERSITY OF THE WITWATERSRAND - JOHANNESBURG

SCHOOL OF PATHOLOGY
Division of Anatomical Pathology

P.O. Box 1038, Johannesburg 2000
Tel : +27-11-489-8477
+27-11-489-8479
Fax: +27-11-489-8512

Division of Anatomical Pathology
Faculty of Health Sciences
York Road
Parktown e-mail : martin.hale@nhls.ac.za

Professor MJ Hale MBChB (Rhodesia) FCPath (SA), LRCP, LRCS, LRCP&S (Edinburgh & Glasgow)
Professor & Head: Division of Anatomical Pathology,

Human Research Ethics Committee (Medical)
University of the Witwatersrand
Johannesburg
20000

April 22, 2015

**Re: Consent for access to NHLS database**

This letter serves to confirm that the Department of Anatomical Pathology at the University of the Witwatersrand and NHLS is happy to assist Dr Ali Makepeace with the study entitled "Advanced transglottic squamous cell carcinoma and the incidence of thyroid gland involvement: An audit of histological samples".

Notwithstanding the requirement that research projects should comprise the researchers work only, it is recognized that publication of such work is encouraged. In the event that the information used comprises the diagnosis only then joint authorship from a member of staff in the Department of Anatomical Pathology would not be expected. However should additional information be extracted from the report for purposes of further interpretation such as morphological details and immunohistochemical profiles, it would be expected that this would be done in conjunction with a member of staff in the Department of Anatomical Pathology and that joint authorship would follow in resulting publications. Dr Makepeace will be in contact with the Department of Anatomical Pathology in respect of this.

Assuring you of the Department of Anatomical Pathology's co-operation in this and future research projects.

With best wishes.

**Yours sincerely,**

**Professor MJ Hale**
**Head: Department of Anatomical Pathology**

13/05/2015
**Date**