

https://dspace.org/

Clinical, histological and microbiological study of hand-excavated carious dentine in extracted permanent teeth

Bönecker, M.; Grossman, E.; Cleaton-Jones, P. E.; et al

2003

http://hdl.handle.net/10539/20317

Bönecker,M., Grossman,E., Cleaton-Jones,P.E., et al. 2003. Clinical, histological and microbiological study of hand-excavated carious dentine in extracted permanent teeth. Journal of the South African dental association;58(7):273-278

Downloaded from a DSpace repository. https://dspace.org/



Clinical, histological and microbiological study of hand-excavated carious dentine in extracted permanent teeth

Clinical, histological and microbiological study of hand-excavated carious dentine in extracted permanent teeth
SADJ August 2003
Vol. 58 No. 7 pp 273 – 278

M Bönecker,
E Grossman,
PE Cleaton-Jones,
R Parak

M Bönecker, DDS, MSc, PhD
Post-Doctoral fellow, Dental Research Institute, MRC/University of Witwatersrand, present address Odontopediatria - Universidade de São Paulo, Brazil

E Grossman, PhD
Specialist Scientist, Dental Research Institute, MRC/University of Witwatersrand

PE Cleaton-Jones, BDS MB BCh PhD DSc(Dent)
Director, Dental Research Institute, MRC/University of Witwatersrand

R Parak, FSMLT
Chief Research Technologist, Dental Research Institute, MRC/University of Witwatersrand

Address for correspondence:
Prof P Cleaton-Jones, Dental Research Institute, Private Bag 3, WITS, 2050.
Tel (011) 717-2229, fax (011) 717-2121
e-mail: cleatonjonesp@dentistry.wits.ac.za

ABSTRACT

Changes in cultivable flora in dentine samples collected before and after hand excavation were examined in association with clinical status of the cavity surface, light microscopy and scanning electron microscopy (SEM). Thirty-five extracted permanent molar teeth with an occlusal caries lesion were excavated with hand instruments according to the atraumatic restorative treatment (ART) approach.

Excavation pressure, dentine colour and consistency were recorded at the dentine-enamel junction (DEJ) prior to carious dentine removal and at the cavity floor after the final excavation; a microbiological sample of dentine was taken at both stages.

Twelve restored teeth; six with positive and six with negative bacterial growth on the second sample, were selected for light microscopy and SEM.

The hand-excavation removed tooth structure was soft, irreversibly damaged, dark and highly infected. Hand excavation reached dentine of. .increased hardness with a more normal colour to provide a sound structural base for restoration. Light and SEM examination of the cavity floor showed infected dentinal tubules in all 12 teeth examined. Linear logistic analysis showed a statistical association between light-yellow dentine on the cavity floor and an absence of bacterial growth (P=0,006). This short-term in vitro study showed that caries-producing bacteria remained in dentine close to the cavity floor in 26/35 teeth despite clinical observations that indicated a suitably prepared cavity floor.

INTRODUCTION

Recent systematic reviews on dental caries trends in developing countries have shown that the filled teeth component (f or F) was almost zero and the untreated decayed teeth component (d or D) predominated.[1-3] The poor infrastructure and lack of dental clinics mean that restorative care is rarely provided for those living in such regions. Therefore, appropriate restorative and preventive techniques should be established based on the needs of the population and the presiding socio-economic conditions. The atraumatic restorative treatment (ART) method caters for such needs through manual removal of infected tooth material and cavity filling with glass-ionomer cements. After opening a cavity with hand instruments, the superficial parts of the necrotic and demineralised dentine are removed with excavators.[4]

Good ART filling survival rates have been reported in longitudinal clinical studies in the permanent dentition in Asia[5] and Africa,[6,7] as well as in the primary dentition in Africa.[8] However, critics of the ART approach maintain that hand instruments cannot remove all carious dentine thereby prompting the resumption of the carious process.[9] In order to convince sceptics about ART, laboratory studies are needed to complement clinical results.

Bacterial survival has been examined when other operative techniques have been used to remove carious tooth tissue such as stepwise excavation[10] and round burs.[11] These studies have reported a marked reduction in bacterial growth as a consequence. Similar studies have not been undertaken using the ART approach.

The aim of the present study was to examine changes in the cultivable flora in dentine samples collected before and after cavity preparation using hand instruments as well as associations between microbiological status, clinical dentine alterations of the cavity surface, light microscopy and SEM observations.

MATERIALS AND METHODS

Thirty-five permanent first and second molar teeth, freshly extracted for reasons other than caries, were selected from teeth made available from dental clinics and hospitals in and around Johannesburg, South Africa.

Ethics clearance to use extracted teeth was obtained from the Committee for Research on Human Subjects of the University of the Witwatersrand. (Clearance 11/5/90). The criterion for tooth selection was the presence of a primary carious lesion on the occlusal surface that included dentine involvement. Immediately after the extraction the teeth were stored in a reduced transport fluid[12] with added 15% glycerol (v/v) and 20% foetal calf serum (v/v), and kept in the refrigerator for no more than 24 hours.

Each tooth root was mounted up to the cervical margin with plaster in a specially machined copper ring that fitted flush on the weighing tray of a single pan laboratory balance (Sartorius-Werke GMBH, Göttingen, Germany).

Data Obtained Before Restoration

Measurement of the excavating pressure

The ring containing the tooth was fitted to the weighing tray and the balance tared to zero. Using new excavators re-sharpened between teeth, carious tissue was removed as recommended for ART[4] and the excavating pressure used by the operator (MB) was noted at three stages of the procedure:

- at the initial stage of the excavation when the first dentine sample was obtained just below the dentino-enamel junction (DEJ);
- at the end of the excavation when the hard dentine surface was reached and checked by a probe;
- when the second dentine sample was obtained from the hard cavity floor. The pressure recorded was the maximum mass registered on the balance during the excavation stroke. The excavation stroke was repeated in duplicate at each stage and the average mass recorded as the pressure used for that stage for each tooth.

Clinical recordings

A five-point scale (light yellow, yellow, light brown, brown and black) was used for the visual colour evaluation of the dentine.[10] The consistency of the dentine was classified as very soft (probe penetrates dentine with easy fragment loss of demineralised tissue), soft (probe penetrates tissue with no resistance when removing probe), medium hard (slight resistance when removing probe) or hard (comparable to unaffected dentine) according to Kidd et al.[11] While the observations were recorded throughout each excavation, two stages received specific attention. Dentine colour and consistency were noted at the DEJ prior to the start of carious dentine removal and at the cavity floor after the final excavation.

Microbiological samples and processing

Two microbiological samples of dentine were taken on the same day during the excavation using two different, sterile, newly sharpened excavators. One sample was obtained from the surface of the central demineralised dentine area immediately below the DEJ prior to excavation and another from the central dentine once a hard cavity floor was reached. Dentine samples were transferred to test tubes containing a semi-solid, enriched sodium-thioglycollate broth (Biolab Diagnostics, Midrand, South Africa). The test tubes were then incubated at 37 °C for a maximum of five days and bacterial growth was accessed by the presence of turbidity and a change in colour indicating a drop in pH. Once all the samples were gathered and the stages completed, the cavities were restored with glass ionomer cement with conditioning as specified for ART[4] using Ketac®-Molar ART (ESPE Dental AG, Seefeld, Germany) according to the manufacturer's instructions. From the start of tooth mounting to the completion of a restoration took approximately one hour.

Examination After Restoration

Twelve restored teeth were randomly selected for light and SEM examination; six from the twenty-six teeth with positive growth in the second sample and six from the nine teeth with no bacterial growth in the second sample. Each of these teeth was fractured in a longitudinal plane midway through the restored cavity. The correct fracture plane was ensured by cutting a shallow directional groove on the tooth surface, with a diamond bur and high-speed hand piece, into which a scalpel blade was placed then hit with a hammer.

One half of each restored specimen was used for light microscopy, the other for SEM.

Light microscope examination

Each of the 12 specimen halves was fixed for 48 hours in 10% buffered formalin and then decalcified in buffered formic hydrochloric acid ((sodium citrate (0,03 M), formic acid (1,6 N) and hydrochloric acid (0,65 N)). The decalcification end-point was determined by radiography (Röntgenapparat D9; A.G. Karlsruhe-Durlach, Germany).

Following a 19½-hour processing schedule the samples were dehydrated, cleared and processed to wax. Longitudinal 4 µm mesio-distal sections were mounted onto aminopropyltriethoxysilane-coated slides and every tenth section stained with Erlich's haematoxylin and alcoholic eosin.

A representative section from each of the 12 teeth was stained with Brown & Brenn's modification of Gram's stain to determine whether organisms were present in the dentine.[13] Stained sections were examined and representative photomicrographs taken.

Colour slides

The remaining 12 specimen halves were examined in a Wild M400 Photo Makroskop (Wild Heerbrugg Ltd, Heerbrugg, Switzerland) for features of interest. The fractured surface had areas of discoloured dentine and enamel, which were of a different colour from the hard dentine tissue of the cavity floor. Photographic slides of the fractured surface of each specimen half were taken using the Wild M400 Photo Makroskop and Fujichrome ASA 50 slide film (Fuji Film, United States). The magnification for each slide varied in order to obtain a photographic field which best encompassed the fractured excavated cavity and surrounding discoloured enamel and dentine. Once developed according to standard procedures the 35 mm slides were glass-mounted and projected flat onto white paper in a darkened room using an established method.[14] The margins of the excavated cavity, discoloured dentine and enamel areas were outlined, and the tissue marked and identified according to colour as previously described for the excavated cavity. Thereafter, the tracings were measured using a Kontron Videoplan image analysing system (Kontron-Messgeräte, Germany).

The following were recorded:

1. Length (mm) of dentine cavity margin.
2. Length (mm) of dentine cavity margin with discoloured dentine expressed as a percentage of the total dentine cavity margin.

The reproducibility of 14 repeated length measurements was calculated. The mean measurement was 2,06 mm (SD 1,92) with a mean difference between first and second measurements of 0,007 mm and 95% confidence limits of -0,015 to 0,029 mm.

Scanning electron microscopy

Following photography each tooth specimen was mounted on an aluminium SEM specimen stub with double-sided adhesive tape and Dag so that the fractured surface was uppermost. After coating with a double layer (carbon then gold palladium) the specimens were viewed in a JEOL 840 SEM (JEOL Ltd. 1-2Musashino 3-chome, Akishimo, Tokyo 196, Japan) at 20 kV. Particular attention was paid to the restoration dentine interface and the dentinal tubules running longitudinally from the treated cavity. Photomicrographs were taken of features of interest.

Analysis of data

Data were analysed with SAS (Version 6,12 for Windows, SAS institute, Cary, N.C., United States) with the critical level of statistical significance set at $P<0,05$. A linear logistic analysis (Proc CATMOD) was used to evaluate the effect of independent variables (pressure, cavity size, dentine

THE PERFECT SYNTHESIS OF PERFORMANCE AND SPEED





xeno®

HIGH PERFORMANCE BONDING GETS EASY

TECHNOLOGY	**SELF ETCHING**
DENTINE ADHESION	20 - 31 MPa
ENAMEL ADHESION	20 - 31 MPa
TOTAL STEP	**1**
ETCHING STEP	0
RINSING STEP	0
CAVITY CLASSES	ALL

Xeno®III is proven to offer high bond strength on dentine and enamel, by 4 of the world's leading universities and institutions: Haller Bernd, University of Ulm; Powers John M., University of Texas, Houston; Latta Mark A., School of Dentistry, Creighton University, Omaha; PameijerCornelis H., DLC International, Simsbury.

Dentsply South Africa
197 Biggarsberg Road
PO Box 1325
Glenvista Ext 6
2058 Johannesburg
Tel: 011 4323390
Fax: 011 4323391
Web: www.dentsplymea.com

First in Dentistry

DENTSPLY SOUTH AFRICA

Table I. Frequency of bacterial growth by sample and clinical characteristics for the 35 teeth examined.

dentine sample	dentine consistency	dentine colour										total
		light yellow		yellow		light brown		brown		black		
		+	-	+	-	+	-	+	-	+	-	
first	soft											10
	medium			1		3		6				23
	hard			5		8		9		1		2
				2								
second	hard	4	8	16	1	6						35

\+ bacterial growth, - no bacterial growth

Table II. Presence of bacteria by bacterial growth and clinical status of the first and second samples, light microscopy (LM), scanning electron microscopy (SEM) as well as discoloured length of the cavity floor of the 6 teeth with positive and the 6 with negative bacterial growth in the second sample.

bacterial growth		dentine consistency		dentine colour		LM	SEM	Discoloured dentine
1st	2nd	1st	2nd	1st	2nd			%
+	+	M	H	Y	Y	+	+	25.9
+	+	M	H	LB	LY	+	+	11.7
+	+	M	H	LB	Y	+	+	51.9
+	+	M	H	LB	Y	+	+	66.0
+	+	M	H	B	Y	+	+	40.9
+	+	H	H	Y	LY	+	+	19.0
+	–	S	H	Y	LY	+	+	10.1
+	–	M	H	Y	LY	+	+	0
+	–	M	H	B	LY	+	+	13.3
+	–	M	H	B	LY	+	+	0
+	–	M	H	B	LY	+	+	16.1
+	–	H	H	Y	LY	+	+	46.8

\+ positive, - negative ; LY= light yellow, Y= yellow, LB= light brown, B=brown; S= soft, M= medium hard, H= hard

hardness and colour) on the dependent variables (initial and final microbiological growth) in all 35 teeth. The reproducibility of measurements was calculated to 95% confidence limits.

RESULTS

The data collected from the 35 teeth in the study are summarised in Table I.

Clinical observations

Cavity size

Five teeth presented with very small cavities (a small single spot): 8 had small cavities (less than 1/3 of the occlusal surface); 13 had medium cavities (1/3 of the occlusal surface); and 9 had large cavities (2/3 of the occlusal surface).

Dentine consistency

A total of 10 lesions were classified as soft, 23 as medium hard and only 2 as hard at the initial excavation at the DEJ. No lesions were classified as very soft. All lesions were hard at the final excavation and no pulp exposures occurred.

Dentine colour

Dentine colour at the initial sample was yellow = 8; light brown = 11; brown = 15 and black =1. At the second sample taken from the base of the cavity the predominant dentine colour was yellow = 17, light yellow = 12 and light brown = 6. Only one lesion did not change colour during excavation and remained yellow.

No statistically significant relationship emerged in comparisons between each of the independent variables - cavity size, initial and final colour, and consistency.

Excavation pressure

The mean pressure when the first dentine sample was collected was 322,8 g (95% CI: 270,7 - 374,9) and the median 300 g. By contrast the mean and median pressure at the second dentine sample collection was significantly greater at 794,2 g (95% CI: 745,7 - 842,9) and 800 g respectively (P=0,0001). There was no association between pressure of excavation and dentine consistency or colour.

Microbiological observations

While the dentine at the cavity floor was judged to be hard in all 35 teeth considerable variation in bacterial growth was apparent when the second dentine sample was analysed. Nine (26%) of the 35 samples were negative while 26/35 (74%) were positive (Table I). There was a statistically significant association between the presence of light yellow dentine on the cavity floor after the final excavation and negative bacterial growth in the second dentine sample (P = 0,006).

Microscopy

All 12 teeth selected for light microscopy and SEM presented with bacterial invasion of the dentine at the cavity floor (Table II) whether or not there was a positive bacterial growth.

Light microscope examination

Brown & Brenn-stained sections of the excavated cavity showed a complex picture of bacterial penetration (Fig. 1). The majority of invading bacteria was present in the dentine adjacent to the cavity margin.

Dentine devoid of bacteria could be found immediately adjacent to these infected areas although occasionally bacteria were observed in deeper parts of dentine. No breakdown of the intertubular dentine was noted. Some specimens presented with single isolated bacteria and were associated with light yellow dentine on the bottom of the excavated cavity.

Colour slides

Discoloured areas were generally in close contact with the excavated cavity wall although in 3/12 specimens such discoloured areas were remote from the excavated cavity. The percentage of discoloured dentine per dentine cavity length ranged from 0 to 66% (Table II). The percentage of discoloured dentine was higher in specimens with bacterial growth and with darker dentine at the second sample but the specimen number was too small for meaningful statistical comparison.

Scanning electron microscopy

All specimens showed bacteria within the



Figure1: Longitudinal section of dentine under the cavity floor prepared with ART. Dark-staining micro-organisms are seen in some of the dentinal tubules. Brown and Brenn X 1,000.

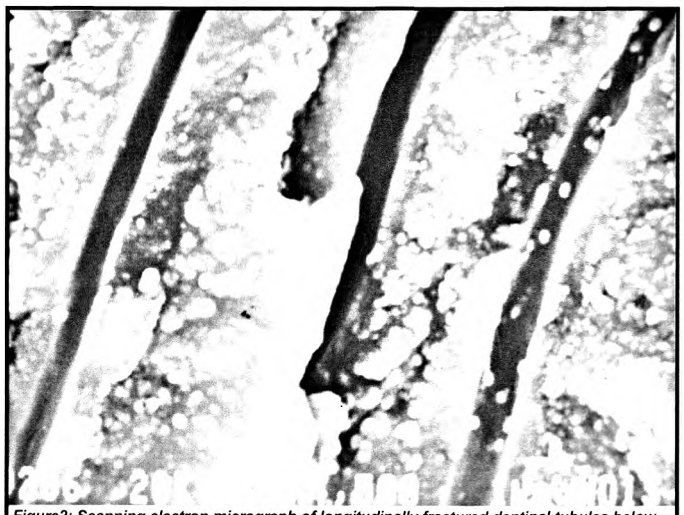

Figure2: Scanning electron micrograph of longitudinally fractured dentinal tubules below the cavity floor. Micro-organisms are present in one tubule. X 4,500.

dentinal tubules. The number of dentine tubules with bacteria growth was generally limited although micro-organisms were present 0,1 to 0,7 mm from the bottom of the excavated cavity. The ultrastructure of the fractured infected dentine appeared normal. In areas where the plane of fracture permitted dentinal tubules to be extensively followed it could be seen that tubules containing bacteria ran adjacent to tubules devoid of bacteria (Figure II).

DISCUSSION

When judged on clinical criteria, the hand excavation seemed to remove all carious tooth structure that was soft, irreversibly damaged, dark and highly infected. This tissue when tested for microbiology at the superficial dentine sample was positive in all cases. At the second dentine sample three quarters of the specimens tested positive. At this stage cavity preparation effectively reached dentine of increased hardness with a more normal colour and provided a sound structural base for restoration.

However, sectioned material showed that up to 66% of the cavity surface remained discoloured and both light and SEM examination of the cavity floor showed infected dentinal tubules in all samples observed. Taken together, the results demonstrate that while excavation does not completely remove all micro-organisms from the cavity floor, it does reduce the numbers something also shown by Massara et al.[15] The same researchers, using SEM and coupled X-ray energy dispersion spectroscopy, have shown a significant increase in calcium in excavated dentine samples after glass ionomer cement application.[15]

It is likely that many of the micro-organisms found in the histological examination and SEM examinations are not viable due to the antimicrobial effects of the glass ionomer cement and conditioner as well as sealing of the cavity from the exterior. In addition the methodology of the study was such that fixation was not undertaken until some time after extraction. In the case of SEM especially this could have resulted in fewer organisms being detected than would have actually been present. Ultrastructural observations on infected dentine tubules in our study were very similar to what was previously described by examiners who checked the presence of bacteria after excavation[16-18] or studied aspects of bacterial invasion.[19-21]

The varying presence of organisms in tubules as shown in Figure II suggest that micro-niches exist within infected dentine which may or may not encourage bacterial growth. Resumption of caries is thought to be more a function of a favourable environment than the numbers of organisms present.

It seems that there is no clinical means of directly detecting the extent of bacterial invasion in dentine nor its cariogenic potential. This is not a new finding and has perplexed practitioners of ART for some time.[10] Studies applying different operative treatment to manage carious lesions could not demonstrate correlation between the colour of lesions and its state of demineralisation or infectivity either.[10, 11] According to Banerjee et al. colour perception is very subjective and is affected by many factors such as ambient lighting, state of hydration, natural history of the lesion, age of the lesion as well as its state of activity.[21] Kidd et al.[22] have demonstrated that soft lesions yielded significant more bacteria than medium and hard lesions although according to Banerjee et al.[21] hardness is relative and its assessment will vary between operators.

Our data on excavation pressure has quantified this 'hardness' for the first time. Recently, it has been suggested in a small in vivo study that fluorescent in situ hybridisation may be a useful technique for the detection of bacteria in carious dentine.[23]

Although in our study the association between the presence of light-yellow dentine on the cavity floor after the final excavation of eight teeth and its negative bacteria growth was not supported by the histological observations it is important to mention that Bjorndal et al. demonstrated that light yellow dentine walls were without bacterial growth after final excavation when the stepwise technique was performed.[10]

The results of this work have important implications in the operative management of dental caries. It should be emphasised that this study confirms the view that it is not possible to tell by clinical examination of the cavity floor if the last traces of infected dentine have been removed. Concern about the survival of micro-organisms in deep carious lesions may often lead to unnecessary exposure of the pulp during final excavation.[1]

There is strong evidence to support the concept that the partly demineralised, minimally infected inner carious dentine can safely be left behind,[4] specially if the restorative material is cariostatic and seals the cavity like the glass ionomer cement used in ART approach.

From the present data it appears that a layer of discoloured dentine be best allowed to remain for pulp protection under such circumstances.

CONCLUSIONS

Caries-producing bacteria remained in close proximity to the cavity floor after manual excavation. This was despite clinical observations based on colour, dentine softness and microbial incubation that indicated a suitably prepared cavity floor. Further work needs to be done to establish what the contribution of these organisms are in the longevity of the ART restoration.

ACKNOWLEDGMENT

The authors should like to thank staff of the Lilian Ngoyi Oral Health Clinic in Soweto, from the Division of Restorative Dentistry at the Johannesburg General Hospital and Ms Cheryl Toi of the Dental Research Institute for their help in this investigation.

REFERENCES

1. Cleaton-Jones, P and Fatti, P. Dental caries trends in Africa. *Community Dent Oral Epidemiol* 1999; **27**:316-320.
2. Cleaton-Jones, P. Dental caries trends in 5- to 6-year-old and 11- to 13-year-old children in two UNICEF-designated regions: sub-Saharan Africa, and Middle East and North Africa, 1970-2000. *J Israel Dent Ass* 2000;**18**:11-22.
3. Bonecker, M and Cleaton-Jones, P. Trends in dental caries in Latin American and Caribbean 5 to 6- and 11- to 13-year-old children: a systematic review 1970 - 2000. *Community Dent Oral Epidemiol* 2003; 31:in press.
4. Frencken, J E and Holmgren, C J. *Atraumatic restorative treatment (ART) for dental caries*. Nijmegen: STI Book b.v. 1999:1-106.
5. Phantumvanit, P, Songpaisan, Y, Pilot, T, and Frencken, J. Atraumatic restorative treatment (ART): a three-year community field trial in Thailand - survival of one-surface restorations in the permanent dentition. *J Public Health Dent* 1996; **56**:141-145.
6. Frencken, J E, Makoni, F and Sithole, W D. ART restorations and glass-ionomer sealants in Zimbabwe after 3 years. *Community Dent Oral Epidemiol* 1998; **26**:372-381.
7. Mickenautsch, S, Kopsala, J, Rudolph, M J and Ogunbodede, E O. Clinical evaluation of the ART approach and materials in peri-urban farm schools of the Johannesburg area. *SADJ* 2000; **55**:364-368.
8. Louw, A J, Sarvan, I, Chikte, U M E and Honkala E. One-year evaluation of atraumatic restorative treatment and minimum intervention techniques on primary teeth. *SADJ* 2002; *57*:366-371.
9. Weerheijm, K L and Groen, H J. The residual caries dilemma. *Community Dent Oral Epidemiol* 1999; **27**:436-441.
10. Bjorndal, L, Larsen T and Thylstrup A. A clinical and microbiological study of deep carious lesions during stepwise excavation using long treatment intervals. *Caries Res* 1997; **31**:411-417.
11. Kidd, E A M, Joyston-Bechal, S and Beighton D. Microbiological validation of assessments of caries activity during cavity preparation. *Caries Res* 1993; **27**:402-408.
12. Syed, S A and Loesche W J. Survival of human dental plaque flora in various transport media. *Applied Microbiol* 1972; **24**:638-644.
13. Brown, J H and Brenn, L. A method for the differential staining of gram-positive and gram-negative bacteria in tissue section. *Bull Johns Hopkins Hosp* 1931; **48**:69-73.
14. Volchansky, A, Austin, J C and Cleaton-Jones, P. A simple viewing table for clinical and research use. *J Dent Ass* S Afr 1975; **30**:769.
15. Massara, M L, Alves, J B and Brandão, P R G. Atraumatic restorative treatment: clinical, ultrastructural and chemical analysis. *Caries Res* 2002; **30**:430-436.
16. Shovelton DS. A study of deep carious dentine. *Int Dent J* 1968; **18**: 283-296
17. Crone, F L. Deep dentinal caries from a microbiological point of view. *Int Dent J* 1968; **18**:481-488.
18. Olgart L, Brännström M, Johnson G. Invasion of bacteria into dentinal tubules. Experiments in vivo and in vitro. *Acta Odont Scand* 1974; **32**:61-70.
19. Michelich V J, Schuster G S and Pashley, D H. Bacterial penetration of human dentin in vitro. *J Dent Res* 1980; **59**:1398-1403.
20. Adriaens, P A, Claeys, G W and de Boever, J A. Scanning electron microscopy of dentin caries. Experimental in vitro studies with Streptococcus mutans. *Scanning Microscopy* 1987; **1**:671-680.
21. Banerjee, A, Watson, T F and Kidd E A M. Dentinal caries: take it or leave it? *Dental Update* 2000; **27**:272-276.
22. Kidd, E A M, Ricketti, D N J and Beighton D. Criteria for caries removal at the enamel-dentine junction: a clinical and microbiological study. *Brit Dent J* 1996; **180**:287-291.
23. Banerjee A, Yasseri M, Munson M. A method for the detection and quantification of bacteria in human dentine using fluorescent in situ hybridization. *J Dent* 2002; **30**:359-363.



X 2 Full time Dental Surgeons
Yorkshire – North England

Leeds is one of the most progressive and cosmopolitan cities in the UK. It maintains a steady level of growth and success, and continues to offer career opportunities to professional people from all sectors. Our practices are based in areas which service both National Health and Private patients thus ensuring there is full patient list on a daily basis, which in turn offers both financial and professional rewards.

The practices are equipped with up to date and modern facilities, and are supported by fully trained personnel. It is a privately owned practice which enables potential for continued growth and expansion, so partnerships are a definite option.

We are seeking 2 full time dentists (may consider part-time) to occupy 10 sessions each per week (37.5 hours). The earning potential equates to a minimum of approximately £52000 (572000R) per annum.

Interested candidates must have a valid work visa, and hold an international dental qualification (references will be required).

To start September – October 2003

For more information Contact Alan McGlaughlin BDS on 0044 113 2622303 or 00447818 444774 email amcglaughlin@hotmail.com