

https://dspace.org/

Morphometric Analysis of the Supraorbital Foramen in the South African Population

Ramkissoon, Kajal

2024

University of the Witwatersrand, Johannesburg

https://hdl.handle.net/10539/46770

Ramkissoon, Kajal . (2024). Morphometric Analysis of the Supraorbital Foramen in the South African Population [Master`s dissertation, University of the Witwatersrand, Johannesburg]. WIReDSpace. https://hdl.handle.net/10539/46770

Downloaded from a DSpace repository. https://dspace.org/

Morphometric Analysis of the Supraorbital Foramen in the South African Population

by

Student name: Kajal Ramkissoon

Registered degree: MSc Dent in Maxillofacial & Oral Surgery
Student Number: 604069

Faculty of Health Sciences,
University of the Witwatersrand,
Johannesburg

Supervisors

Prof Risimati Ephraim Rikhotso

BDS, MDent, FCMFOS(SA), PhD
Department of Maxillofacial & Oral Surgery
University of the Witwatersrand
E-mail address: risimati.rikhotso@wits.ac.za
Tel: 011 717 2130

Dr Muhammad Bobat

BDS (Wits), MDent (Wits), FCMFOS (SA)
Department of Maxillofacial & Oral Surgery
University of the Witwatersrand
E-mail address: drbobat@gmail.com
Tel: 011 717 2130

Dr Akaashni Bhika

BChD, BSc (MedSci). BScHons (Cell Biology), MSc (Anat) (UP)
School of Anatomical Sciences
University of the Witwatersrand
E-mail address: akaashni.bhika@wits.ac.za
Tel: 011 717 2136

UNIVERSITY OF THE WITWATERSRAND, JOHANNESBURG

FACULTY OF HEALTH SCIENCES

A research report submitted to the Faculty of Health Sciences, University of the Witwatersrand, Johannesburg, in fulfilment of the requirements for the degree of Master of Science in Dentistry (Maxillofacial & Oral Surgery).

Johannesburg 2024

Declaration

"I, Kajal Ramkissoon, declare that this research report is my own, unaided work. It is being submitted for the Degree of Master of Science in Dentistry (MSc Dent) at the University of the Witwatersrand, Johannesburg. It has not been submitted before for any degree or examination at any other University."



Dr Kajal Ramkissoon

On this 26th day of July 2024 in Parktown, Johannesburg

Dedication

To my loving husband, Kishen, who has walked this path with me, the long nights and tireless days, thank you for your support and understanding.

Abstract

The supraorbital notch (SON) or supraorbital foramen (SOF) is located at the level of the supraorbital rim, housing the supraorbital neurovascular bundle which supplies the scalp, forehead, skin and muscles of the upper eyelid.

In this study, 108 dry skulls were examined, to determine these morphometric data: width of SON/SOF and position of SON/SOF relative to the nasal midline and frontozygomatic suture. Left and right sides were compared and differences between the sexes were considered.

In a South African population, SON (44%) was the most commonly identified passageway, followed by the SOF (27%), absent SON/SOF (19%), double foramen (5%), co-occurrence (4%), and double notch (1%) respectively.
This study localised the SON/SOF approximately 26.87 mm ± 4.21 from the nasal midline to SON/SOF in females, and 28.20 mm ± 3.68 in males. When using the frontozygomatic suture as a reference point, SON/SOF lies 28.42 mm ± 3.00 medially in females and 29.83 mm ± 2.80 in males. The positional distances were significantly greater in males than females. No significant differences were observed between the left and right side. The width of SON was approximately 4.16 mm ± 1.81, and diameter of SOF was approximately 2.60 mm ± 1.14.

The findings of this study are relevant to surgeons when operating in the supraorbital region. Accurate anatomical knowledge of neurovascular architecture and foramina localisation can help avoid iatrogenic injury during administration of local anaesthetic, retraction of musculocutaneous scalp flaps or surgical dissection of the supraorbital region.

Acknowledgments

I would like to express my deepest appreciation to Prof Rikhotso for his wisdom and insightfulness throughout this research project. His words have never failed to inspire me.

This endeavour would not have been possible without my mentor Dr Bobat for his patience and faith in me. Thank you for always believing in me, guiding me, and helping me find the end of the tunnel.

Words cannot express my gratitude to Dr Akaashni Bhika for her steadfast support and encouragement throughout this project. Thank you for pushing me beyond my boundaries and sharing a spirit of excellence.

I would like to extend my sincere thanks to Dr Brendon Billings for welcoming me in the School of Anatomy and sharing his expertise.

Thank you to Mr Mashudu Mulaudzi for accommodating my requests with patience and efficiency.

Table of Contents

Declaration iii

Dedication iv

Abstract v

Acknowledgments vi

List of Figures x

List of Tables xi

List of abbreviations and symbols xii

1. Introduction and Literature Review 1

1.1. Introduction 1

1.2. Literature review 4

1.2.1 MRI imaging 5

1.2.2 3-Dimensional Computed Tomography 5

1.2.3 Macerated skull observations 6

1.2.4 Cadaver dissections 6

1.3. Significance of study 8

2. Aim and Objectives 9

2.1. Aim 9

2.2. Objectives 9

3. Methodology 10

3.1. Ethics 10

3.2. Study design 10

3.3. Study population 10
3.4. Measurements 11
3.4.1. Definition of measurements 12
3.5. Study Reliability 14
3.6. Sample size 14
3.7. Sampling 15
3.8. Data collection 15
3.9. Data analysis 15
4. Results 19
4.1. Demographics 19
4.2. Frequency distribution of morphologies 20
4.3. Morphometrics of SON/SOF in females 24
4.3.1. Dimensions of SON/SOF in females 24
4.3.2. Position of SON/SOF in females 24
4.3.2.1. Distance of midpoint of SON/SOF to nasal midline in females 25
4.3.2.2. Distance of SON/SOF to the frontozygomatic point in females 25
4.4. Morphometrics of SON/SOF in males 26
4.4.1. Dimensions of SON/SOF in males 26
4.4.2. Position of SON/SOF in males 26
4.4.2.1. Distance from midpoint of SON/SOF to nasal midline in males 27
4.4.2.2. Distance from midpoint SON/SOF to frontozygomatic point in males 27
4.5. Morphometrics of SON/SOF in females versus males 28
4.5.1. Dimensions of SON/SOF in females versus males 28
4.5.2 Position of SON/SOF in females versus males 28

4.5.2.1 Distance from midpoint of SON/SOF to nasal midline in females versus males....28
4.5.2.2. Distance from midpoint SON/SOF to frontozygomatic point in females varus males....29
5. Discussion....30
5.1. Demographics....30
5.2. Frequency distribution of morphologies of SON/SOF in the South African population....31
5.3. Morphometrics of SON/SOF....33
5.4. Position of SON/SOF....33
6. Conclusion....36
7. Limitations....38
8. Future studies....38
References....39
Appendix A: Data collection form....43
Appendix B: Approval of title....44
Appendix C: Ethics Waiver....45
Appendix D: Turnitin report....46

List of Figures

Figure 1: Illustrates the supraorbital foramen and supraorbital notch

Figure 2: Osteometric measurements

Figure 3: Frequency distribution of morphology

Figure 4 (a-f): Images depict variations of SON/SOF

Figure 5: Frequency distribution amongst sexes

List of Tables

Table 1: Definition of passageways
Table 2: Compilation of different measurements of SON/SOF
Table 3: Definition of measurements and landmarks
Table 4: Data analysis
Table 5: Intraclass Correlation Coefficient results
Table 6: Width of SON/SOF seen in females.
Table 7: Position of SON/SOF seen in females.
Table 8: Width of SON/SOF seen in males.
Table 9: Position of SON/SOF seen in males
Table 10: Width of SON/SOF seen in females versus males
Table 11: Position of SON/SOF seen in females versus males
Table 12: Data collection form

List of abbreviations and symbols

%	:	percentage
±	:	plus-minus
3D-CBCT	:	3-dimensional cone-beam computed tomography
CT	:	computed tomography
CBCT	:	cone-beam computed tomography
CN V	:	cranial nerve five
FZR	:	frontozygomatic point
mm	:	millimeter
MRI	:	magnetic resonance imaging
NM	:	nasal midline
n^{th}	:	the position of a term in a sequence
SOF	:	supraorbital foramen
SON	:	supraorbital notch

1. Introduction and Literature Review

1.1. Introduction

The supraorbital foramen (SOF) is an elongated bony aperture above the orbit and below the forehead. When the passage is encircled by bony cartilage, it is referred to as the supraorbital foramen, however, when partly enclosed in bone, it is called the supraorbital notch (SON) (Osunwoke *et al*., 2012). The supraorbital foramen or supraorbital notch is located along the supraorbital margin on the frontal bone (Woo *et al*., 2013). The terminal point houses the supraorbital nerve, artery and vein. This nerve forms the largest branch of the frontal nerve, extending from the ophthalmic division of the trigeminal nerve (Cranial Nerve V). The supraorbital nerve is bounded by the orbital roof and levator palpebrae muscle (Vargas, 2017). The nerve subdivides into two branches: a medial (superficial) branch which journeys through the frontal foramen or notch, providing sensation to the medial part of the upper eyelid, medial forehead, and bridge of the nose; and a thicker lateral (deep) branch which usually exits through the SON/SOF and providing sensory innervation to the skin of the forehead (extending from parietal to temporal regions) (Haładaj, 2019). The supraorbital artery forms a branch of the ophthalmic artery, originating from the internal carotid artery. After passing through SON/SOF, it separates into the superficial and deep branches that supply muscles and skin of the forehead, scalp and upper eyelid. The supraorbital vein joins the supratrochlear vein at the medial angle of the eye to form the angular vein which continues through the face as the facial vein (Ashwini *et al*., 2012).

The human skull achieves skeletal maturity through a superior–inferior gradient of maturation. Albert *et al.* (2019) reported that total horizontal growth peaks around 17 years of age in males and 15 years of age in females; whilst complete vertical growth extends beyond 15 years of age in both sexes (Albert *et al.,* 2019). According to Bastir *et al.* (2006), 19 years of age is an acceptable chronological estimate of biological maturity and adulthood (Bastir *et al.,* 2006).

Whilst craniofacial growth is technically continual beyond 20 years of age, the extent and rate of growth remains negligible and most likely attributed to bone remodelling (Albert *et al.*, 2019).

Comprehensive knowledge of regional anatomy of the supraorbital nerve, vessels, and exit passageway is crucial in combination with modern diagnostic and therapeutic methods and surgical procedures in the supraorbital region (Haładaj, 2019). This includes procedures such as the corneal neurotization, anterior orbital approach, supraorbital injections, treatment of migraine headaches, fronto-glabellar reconstruction flap, upper eyelid surgeries (e.g., blepharoplasty) and any procedure requiring incisions in the forehead endoscopic facial therapies (Haładaj, 2019).

Surgeons operating in this region may be reluctant to perform surgical procedures due to the increased risk of injury to the supraorbital nerve and causing loss of sensation (Woo *et al*., 2013). Effective and precise analgesia can only be achieved with a thorough understanding of the position of the nerve and its point of exit. Excessive retraction and dissection near the neurovascular bundle can result in scarring, leading to painful neuralgias. Clinicians need to be cognizant of the anatomical position and dimensions of the SON/SOF when diagnosing and treating conditions in the region, such as supraorbital neuralgia (Woo *et al*., 2013).

Previous studies have indicated variation in location and morphology of the SON/SOF amongst different population groups such as Caucasian, Black, Japanese, Kenyans, Hispanic, Korean and Thai (Ilayperuma *et al*., 2014). In addition, these characteristics may differ between populations and within inhabitants of the same geographical location (Ilayperuma *et al*., 2014).

Table 1: Definition of passageways

Number of passageways	**Types of passages**	**Definition**
Single opening	Supraorbital foramen	A canal of 360° connecting the orbital space to the frontal region, including the orbital rim that transmits supraorbital artery, vein and nerve (de Souza Ferreira *et al*., 2017).
	Supraorbital notch	Arc of at least 180 degrees, creating an opening transmitting vessels (de Souza Ferreira *et al*., 2017)
Double opening	Double supraorbital foramen	Two conduits transmitting the supraorbital vessels (Rehman, 2023).
	Double supraorbital notch	Two indentations in the supraorbital region transmitting the supraorbital nerve, artery, and vein (Rehman, 2023).
	Co-occurrence	Simultaneous appearance of a foramen and notch on the supraorbital rim (Rehman, 2023).

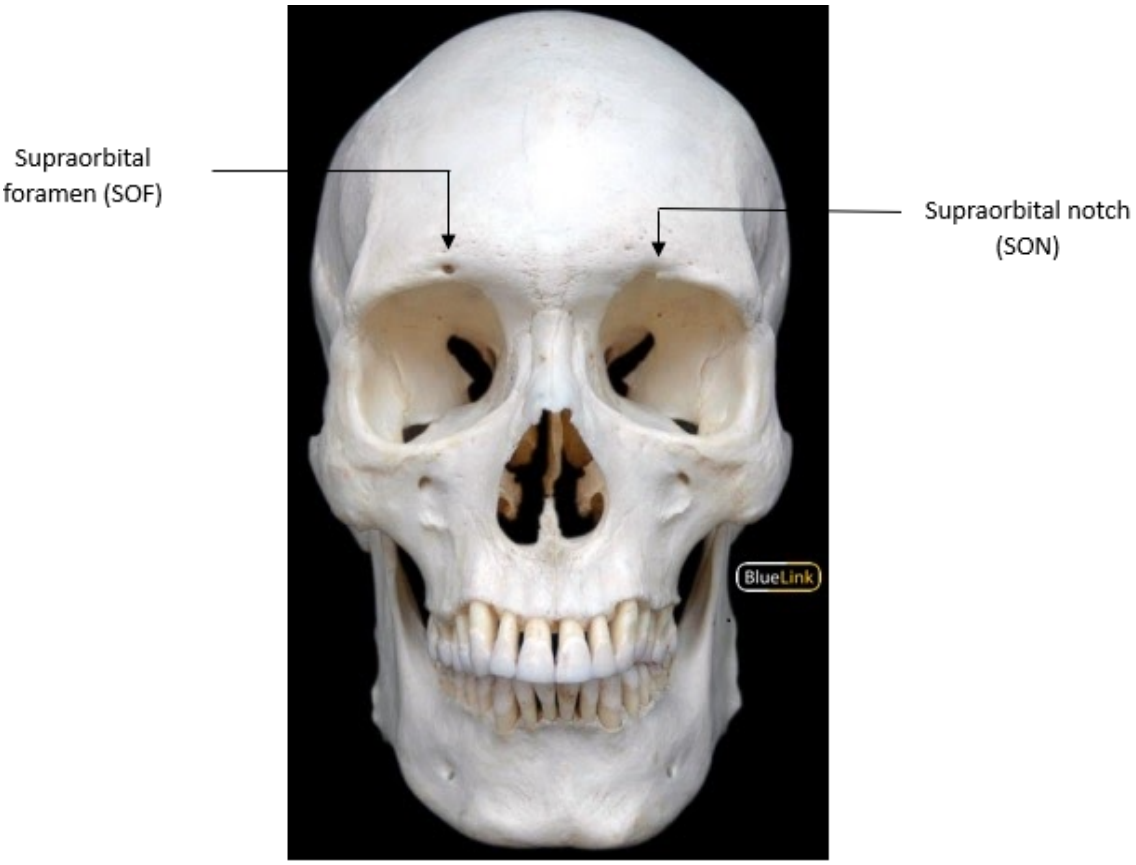

Figure 1: Illustrates the supraorbital foramen and supraorbital notch. Adapted from Alsup and Fox (2023)

1.2. Literature review

Various techniques have been used to study morphometrics of the supraorbital foramen. This section will review studies utilising cadaveric dissections, observations of human skulls, intraoperative findings, and radiographic imaging as a tool to locate and illustrate current findings.

1.2.1 MRI imaging

In a study by Tsutsumi *et al.* (2019) 90 patients underwent contrast magnetic resonance imaging (MRI). The images identified the SON/SOF in 99% of cases on the left and 98% on the right sides. The distance recorded from the nasal midline to the SON/SOF was 22.8 mm ± 3.07 on the left and 22.6 mm ± 3.08 on the right side. The study did not distinguish between the SOF and SON. The SON/SOF was described as an "enhanced, triangular or linear-shaped structure continuous with the superior alveolar artery (SOA) posteriorly and blended with the skin anteriorly." According to Tsutsumi *et al.* (2019), the reported length from the nasal midline to the SON/SOF and depth from the skin to the SON/SOF were consistent with other studies, and therefore, MRI is recognised as a useful tool for locating the SON/SOF.

1.2.2 3-Dimensional Computed Tomography

Woo *et al.* (2013) used three-dimensional computed tomography (3D-CT) images to examine SON/SOF variations in the Korean population. The sample included 395 people. A single notch was most commonly identified, on the right (39.5% of images), and left sides (42.3% of images). The SON/SOF was absent in 39 participants on the right side and 46 on the left side.

The simultaneous appearance of the SON and SOF was noted in 20 people on the left and 25 people on the right sides. The absence of the SON or SOF was observed in 11.7% of candidates on the left and 9.9% on the right side. The presentation of a solitary

foramen in the Korean population was notably higher than other studies (Woo *et al.,* 2013).

1.2.3 Macerated skull observations

Maceration is a form of controlled putrefaction, whereby soft tissue is removed from bones by dissection, placed in boiling water, cleaned & degreased, dried, soaked in hydrogen peroxide, and then dried again. This produces a dry skull (Dayal *et al*., 2009). Ilayperuma *et al.* (2014) used 180 adult dry skulls to determine the morphometrics of the SON/SOF in the adult Sri Lankan population. Sex variations regarding the location of the SON/SOF from the nasion were observed (female: 24.40 mm ± 2.76; male: 26.12 mm ± 3.89). Following most studies, the SON (64.81%) was identified more frequently than the SOF (35.19%). In terms of presentation, 20.37% displayed bilateral supraorbital foramina, 55.56% had bilateral supraorbital notches, whereas 24.07% presented with a foramen on one side and a notch on the contralateral side. Accessory foramina had been identified in 6.48% of the sample (Ilayperuma *et al*., 2014).

1.2.4 Cadaver dissections

Ashwini *et al.* (2019) studied 83 adult human skulls of South Indian origin. The mean distance from the frontozygomatic suture to SON/SOF was 28.7 mm on the left and 29.34 mm on the right side. Interestingly, notches were more frequently present on the right side and foramina occurred more frequently on the left side. The mean distance from the

nasal midline to the SON/SOF was 22.22 mm. In contrast, Jeong *et al.* (2010) examined 30 anterolateral scalps in the Korean population. No significant difference between the right to left side or sex was recorded. The supraorbital nerve emerged from the foramen approximately 5 mm below the supraorbital rim (range: 4-6 mm) and 29 mm lateral to the midline (range: 25-33 mm). This represents a greater length from the nasal midline to the SON/SOF than other studies (Jeong *et al*., 2010).

A report by Haladaj *et al.* (2019), distinguished an additional singular exit on the supraorbital margin: “wide and shallow depression on the medial, rounded part of the supraorbital margin was defined as a frontal notch”. Of a sample of 50 wet specimens, a well-developed supraorbital notch occurred more often than the single-opening supraorbital foramen. This was confirmed in macerated skulls (50 specimens). A double opening depicting the cooccurrence of the SOF and SON simultaneously was observed in equal measures (18%) in wet specimens and macerated skulls. The double SOF was recorded in less than 5% of wet specimens and dry skull cases. The mean width of the SON was observed at 5.16 mm and the diameter of the SOF was 2.56 mm in the case of a single opening (Haładaj, 2019).

Osunwoke *et al.* (2012) analysed the SON/SOF in the south Nigerian population. No significant difference was noted between shape, width and length of the SON/SOF in females and males. Further to this, the notches examined varied in shape from narrow keyholes to broad flat designs. In contrast, the foramina were ovoid in shape displaying a wider base. In agreement with most studies, there were more notches than foramina

across sexes. The width of the SON was relatively higher in both males (5.21 mm ± 1.65 right; 5.40 mm ± 1.89 left) and females (4.97 mm ± 0.18 right; 5.00 mm ± 0.20 left), compared to other studies (Osunwoke, 2012).

Table 2: Compilation of measurements of SON/SOF as reported in previous studies. Adapted from Ashwini *et al.* (2012)

Modality	**Sample size**	**Author**	**Distance Nasion-SON/F (mm)**		**Distance SON/F-frontozygomatic suture (mm)**		**Mean (mm)**	
			Right	Left	Right	Left	Width SON	Diameter SOF
MRI-imaging	90	Tsutsumi *et al.* 2019	22.60 ±3.08	22.80 ±3.07	-		-	-
Macerated skulls	180	Ilayperuma *et al.* 2014	25.42 ±2.49	24.64 ±3.16	-		4.52 ±1.80	
Macerated skulls	100	Sharma *et al*. 2014	21.94 ±0.32	20.11 ±0.73	28.64 ±0.32	28.58 ±0.23		
3D-CT	395	Woo *et al*. 2013	-	-	-		2.34 ±0.78	3.37 ±1.71
Cadaver	83	Ashwini *et al*. 2012	22.20 ±0.39		29.34 ±0.32			

1.3. Significance of study

Most studies stressed that the position and arrangement of the exit passageways of the supraorbital nerve were inconsistent and therefore interracial and interpopulation diversity may exist.

The data generated from this study could be used to assist forensic scientists and anthropologists, in characterization and localisation of these structures and provide recommendations to clinicians operating in the supraorbital region specific to the South African population.

This may be useful as a morphological description of human skeletal remains for the identification in forensic sciences, as well as assist anaesthetists and surgical disciplines for providing accurate nerve blocks and planning surgical flaps that avoid injury to the supraorbital neurovascular bundle (Cuerrier-Richer, 2022).

2. Aim and Objectives

2.1. Aim

To assess the morphological characteristics of the supraorbital foramen in the South African population.

2.2. Objectives

1. To determine the existence of various morphologies of the supraorbital notch/foramen across the population and sexes of interest.
2. To determine the width of the supraorbital notch and/or diameter of the supraorbital foramen on human skulls.
3. To determine the distance from the nasal midpoint to the midpoint of the supraorbital notch or foramen.
4. To determine the distance from the midpoint of the supraorbital notch/foramen to the frontozygomatic point.

3. Methodology

3.1. Ethics

The crania of the study were used in compliance with the South African National Health Act 61 of 2004. An ethics clearance waiver issued to the School of Anatomical Sciences, University of the Witwatersrand was obtained W-CBP-220504-01 (Appendix D).

3.2. Study design

Cross-sectional study

3.3. Study population

The study population included dry skulls from The Raymond A. Dart Collection of Modern Cadaveric Human Skeletons of the School of Anatomical Sciences at the University of the Witwatersrand (Dayal *et al*., 2009). In this study, the dry skull was defined as a skull including cranial bones & facial bones, without the mandible and calvaria. Presence or absence of teeth did not form part of the inclusion/exclusion criteria. The sample included 108 skulls. Only specimens of known population affinity, age and sex were included. As defined by Statistics South Africa (2022), South African population categories include White, Coloured, African and Asian/Indian. This study adopted the definition as described by the South African census (namely SA African, SA White, SA Coloured and SA Asian/Indian) (Statistics South Africa, 2022)

Inclusion criteria:

- Skulls from a South African population as defined above.
- Skulls of persons older than 20 years of age.
- Skulls without calvaria and mandible were included.

Exclusion criteria:

- Skulls with fractures, deformities, damage, or pathology in the area of interest were excluded.
- Skulls with unknown demographics were excluded.
- Incomplete skulls (skulls missing bones of interest: frontal, nasal and zygomatic bone) were excluded.

3.4. Measurements

Digital vernier callipers were used to measure:

- The width of SON or diameter of SOF.
- The distance from the frontozygomatic point to the midpoint of SON/SOF.
- The distance from the midpoint of the SON/SOF to nasal midline.

Only skulls presenting with a notch, foramen or co-occurrence were recorded and measured. Skulls presenting with a double foramen, double notch or absent were only recorded.

3.4.1. Definition of measurements

Table 3: Definition of measurements and landmarks. Adapted from Tomaszewska *et al.* (2012)

Landmark/Measurement	Abbreviation	Description
Nasion	n	A bony depression at the midpoint where the two nasal bones and the frontal bone intersect.
Frontozygomatic point	FZR	The most medial and anterior point of the frontozygomatic suture in the plane of the lateral orbital rim.
Nasal midline	NM	Straight line from the nasion extending superiorly
Nasal midline-supraorbital notch	NM-SON	Straight line measurement from the nasal midline to the midpoint of the supraorbital notch.
Supraorbital notch-frontozygomatic point	SON-FZR	Straight line measurement from the midpoint of the supraorbital notch to the most medial and anterior point of the frontozygomatic suture.
Midpoint of supraorbital notch		Determined as half the width of the supraorbital notch
Nasal midline-supraorbital foramen	NM-SOF	Straight line measurement from the nasal midline to the midpoint of the supraorbital foramen.
Supraorbital notch	SON	Supraorbital passageway at the superior and medial edge of the orbit in the frontal bone, partially covered by bone.
Supraorbital foramen	SOF	Small aperture at the central margin above the orbit that transmits supraorbital artery, vein and nerve.
Width of supraorbital notch		The maximum horizontal width of the SON.
Diameter of supraorbital foramen		The greatest transverse diameter of the SOF.
Supraorbital foramen – frontozygomatic point	SOF-FZR	Straight line measurement from the midpoint of the supraorbital foramen to the most medial and anterior point of the frontozygomatic suture.
Midpoint of the supraorbital foramen		Determined as half the diameter of the supraorbital foramen

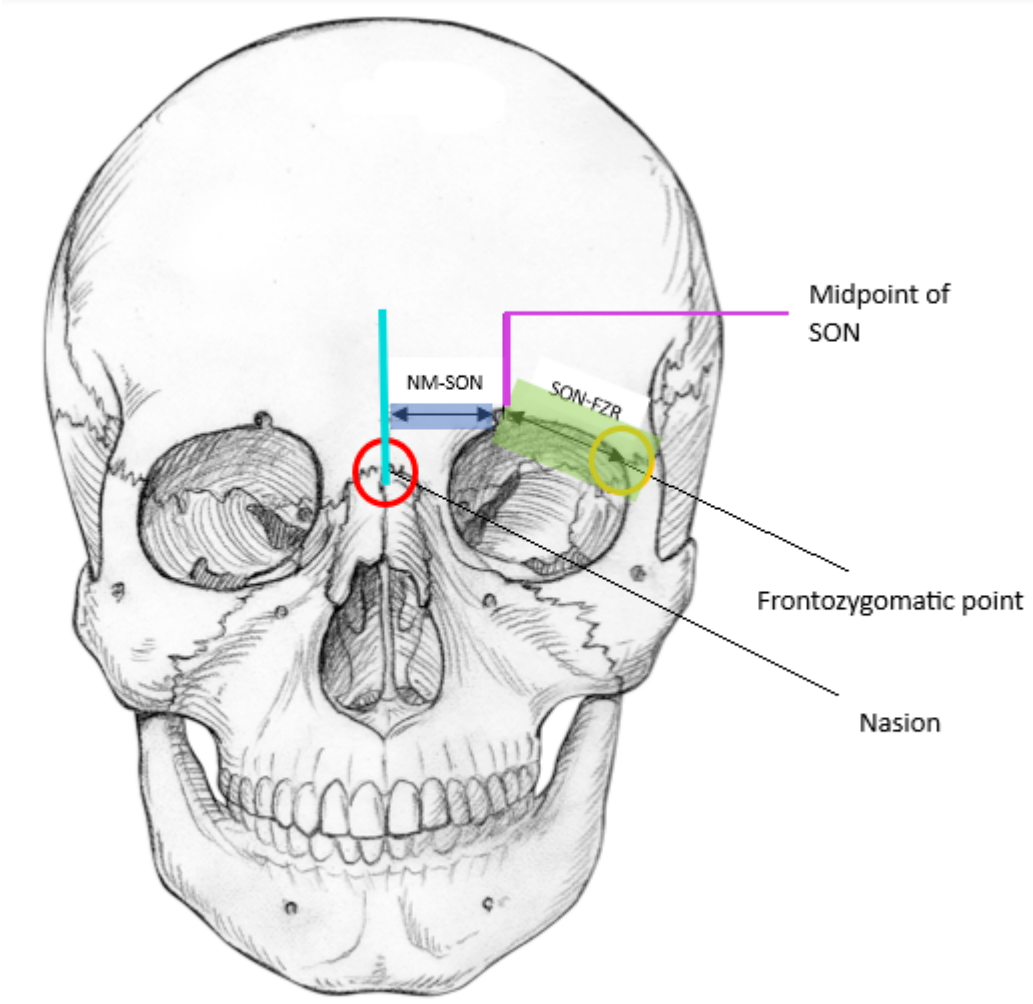

Figure 2: Osteometric measurements. Adapted from Ashwini *et al*. (2012).

3.5. Study Reliability

The researcher (1st observer) measured the entire sample population. Measurements were repeated 3 times and the mean was recorded (intra-observer reliability). A second observer (supervisor) conducted independent measurements on one-third of the sample (interobserver measurements) using the same calipers and method as the 1st observer.

A single set of instruments was used to ensure reliability.

Intraclass Correlation Coefficient (ICC) was used to quantify the agreement between observers' measurements (interobserver reliability).

3.6. Sample size

The required sample size was calculated and required 104 macerated skulls.

Sample size calculation:

Confidence level of 95% = z score of 1.96

$n = [(z\ score \times \sigma) / precision)]^2$

$= [(1.96 \times 1.3) / 0.25]^2$

$= 104$

3.7. Sampling

Probability sampling techniques were used to reduce bias (Ehrlich & Joubert, 2014). Systematic sampling offers each element in the population a known and equal probability of selection. Every nth (the position of a term in a sequence) specimen was included in the study sample. This ensured the sample is representative of the population.

Systematic Sampling Formula for interval (i) = N/n = 2 605/104 = 25.048≈ 25.

Every 25th skull was included.

3.8. Data collection

Data was recorded on the data capture form (Appendix A).

The following data was recorded: epidemiological data (age, sex and population affinity); diameter of the SOF, width of the SON; distance from the SON/SOF to the nasal midline and distance from the SON/SOF to the frontozygomatic point.

3.9. Data analysis

Data was captured on Microsoft Excel and then exported to SPSS (Version 28) statistical software for statistical tests.

Table 4: Data analysis

Objective	**Statistical analysis**
To determine the existence of various morphologies of the supraorbital notch/foramen across the population and sexes of interest.	Descriptive statistics of the data was utilised to determine the minimum, maximum, mean and standard deviation of the groups under analysis. Thereafter, a Shapiro-Wilk test was used to test for normality distribution of the data. A t-test was used to analyse differences observed in the measurements between right and left sides of the skull and the differences observed between sexes where the data was normally distributed. A Mann-Whitney U test was used if data was non-parametric. The significance level was set at $p<0.05$.
To determine the width of the supraorbital notch and/or diameter of the supraorbital foramen on human skulls.	Descriptive statistics of the data was utilised to determine the minimum, maximum, mean and standard deviation of the groups under analysis. Thereafter, a Shapiro-Wilk test was used to test for normality distribution of the data. A t-test was used to analyse differences observed in the measurements between right and left sides of the skull and the differences observed between sexes where the data was normally distributed.

	A Mann-Whitney U test was used if data was non-parametric. The significance level was set at $p<0.05$.
To determine the distance from the nasal midline to the supraorbital notch or foramen.	Descriptive statistics of the data was utilised to determine the minimum, maximum, mean and standard deviation of the groups under analysis. A Shapiro-Wilk test was used to test for the normality distribution of the data. A t-test was used to analyse differences observed in measurements between right and left sides of the skull and the differences observed between sexes where the data was normally distributed. A Mann-Whitney U test was used if data was non-parametric. The significance level was set at $p<0.05$.
To determine the distance from the midpoint of the supraorbital notch/foramen to the frontozygomatic point.	Descriptive statistics of the data was utilised to determine the minimum, maximum, mean and standard deviation of the groups under analysis. Thereafter, a Shapiro-Wilk test was used to test for the normality distribution of the data. A t-test was used to analyse differences observed in the measurements between the right and left sides of the skull and the

	differences observed between sexes where the data was normally distributed. A Mann-Whitney U test was used if data was non-parametric. The significance level was set at $p<0.05$.

4. Results

4.1. Demographics

The study population consisted of 108 specimens, 54 males and 54 females. The age of the crania ranged from 20 years to 90 years, with a median age of 50 years old.

The population affinity of the sample consisted of 73 Black, 25 White and 10 Coloured specimens. The reliabilities for each measurement were above 0.8, indicating good reliability (Table 5).

Table 5: Intraclass Correlation Coefficient results of the study

Statistical test	**Intraclass Value**	**Decision**
Intraclass Correlation Coefficient: Width notch right side	0.983	Excellent reliability
Intraclass Correlation Coefficient: Width notch left side	0.823	Good reliability
Intraclass Correlation Coefficient: Distance to nasal midline right side	0.934	Excellent reliability
Intraclass Correlation Coefficient: Distance to nasal midline left side	0.934	Excellent reliability
Intraclass Correlation Coefficient: Distance to frontozygomatic point right side	0.883	Good reliability
Intraclass Correlation Coefficient: Distance to frontozygomatic point left side	0.885	Good reliability

4.2. Frequency distribution of morphologies

When comparing the frequency in the distribution of morphologies in a South African population (Figure 3), SON (44%) was the most commonly identified passageway, followed by the SOF (27%), absent SON/SOF (19%), double foramen (5%), co-occurrence (4%), and double notch (1%) respectively (figure 3 and figures 4a-f).

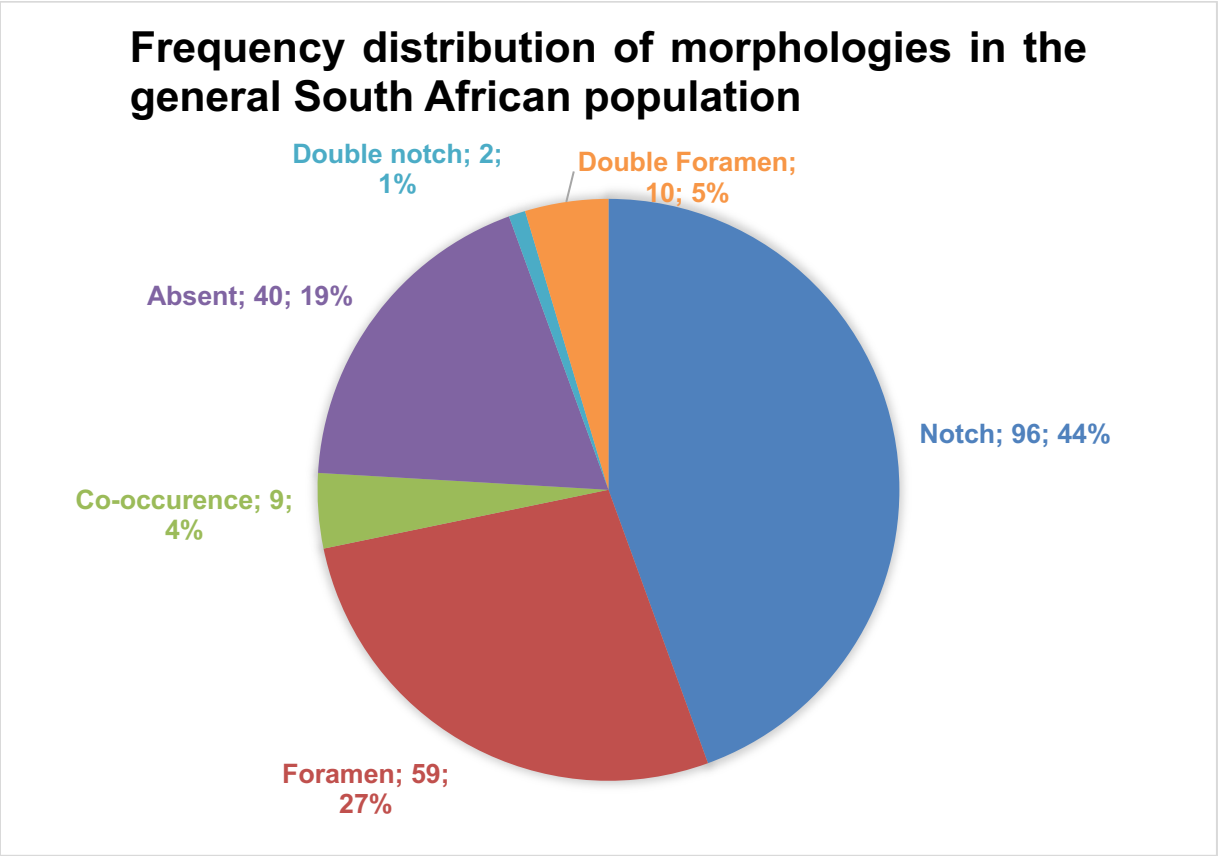

Figure 3: Frequency distribution of morphology in the general South African population indicated by the morphology, number out of 108 samples, and the percentage.



Figure 4 (a): image depicts absent SON/SOF



Figure 4(b): image depicts SON



Figure 4(c): Image depicts SOF



Figure 4(d): Image depicts double foramen



Figure 4(e): Image depicts co-occurrence



Figure 4(f): Image depicts double notch

Figure 4: Images depict the different morphologies seen: (a) supraorbital notch (SON), (b) absent SON/SOF; (c) SOF; (d) double foramen; (e) co-occurrence; (f) double notch

Figure 5 indicates the frequency distribution of morphologies between sexes. Females showed a greater frequency of notches (25.46%) than males (14.82%). The width of SON was larger in females (mean: 4.28 mm ± 2.04) than males (mean: 3.99 mm ± 1.45). Statistical analysis revealed no significant differences ($p = 0.87$). Similarly, females (14.81%) also presented with a greater count in foramina than males (12.5%). The mean diameter of SOF in females was 2.75 mm ± 1.04, and mean diameter in males was 2.41 mm ± 1.25. No significant differences were noted ($p = 0.33$). Females (2.78%) presented with double the amount of co-occurrence than males (1.39%). The mean diameter in co-occurrence in females was 2.37 mm ± 0.94, and the mean diameter in males was 3.65 mm ± 2.38. No significant differences were recorded ($p = 0.053$). Males (13.89%) had more skulls devoid of SON/SOF when compared to females (4.62%). In the sample, no double foramen was observed in males, whereas three were identified among females. A double notch was present in 3.24% of male crania and 0.93% of female crania.

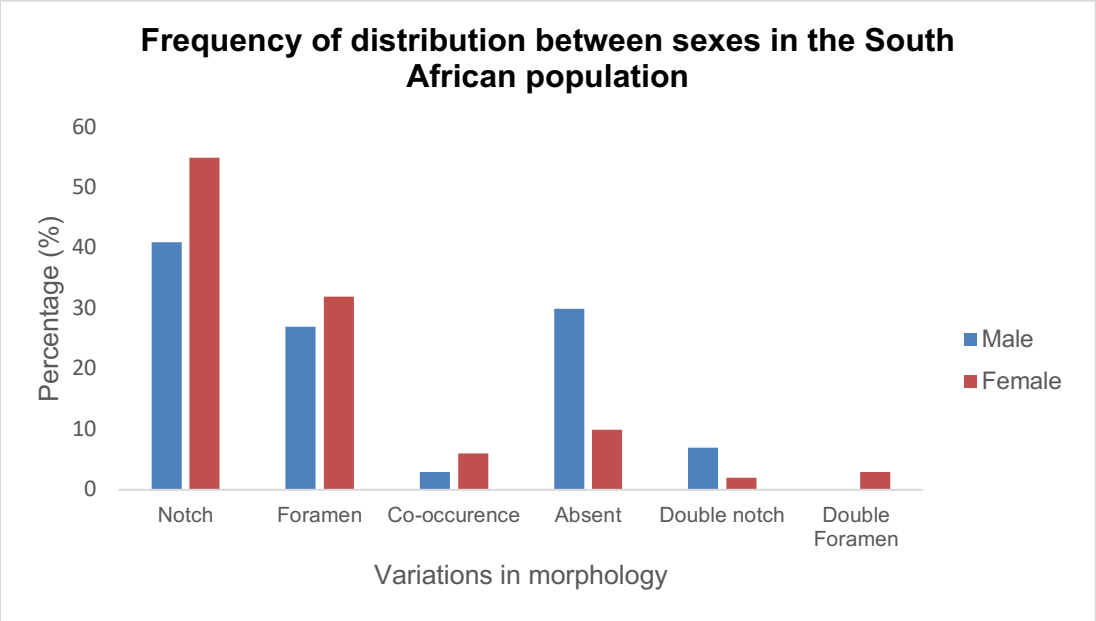

Figure 5: Frequency distribution amongst sexes in the South African population.

4.3. Morphometrics of SON/SOF in females

This study determined the dimensions of SON/SOF in South African females and males; and compared the left and right sides and differences between sexes.

4.3.1. Dimensions of SON/SOF in females

When comparing the width of SON or diameter of SOF in South African females (Table 6). The study revealed a minimum width of SON/SOF of 1.10 mm, maximum of 9.8 mm (mean: 3.88 mm ± 2.19) on the right side. Whilst the left side shows a minimum width of SON/SOF of 0.71 mm and, a maximum of 8.25 mm (mean: 3.40 mm ± 1.49). There were no significant differences between left and right sides (p = 0.46)

Table 6: Width of SON/SOF seen in females

	Width of SON/ Diameter of SOF (mm)	
	Right side	Left side
Min	1.10	0.71
Max	9.80	8.25
Mean	3.88	3.40
Median	3.35	3.04
Standard deviation	2.19	1.49

4.3.2. Position of SON/SOF in females

The study investigated the position of SON/SOF in relation to structures in the anterior cranium.

4.3.2.1. Distance of midpoint of SON/SOF to nasal midline in females

Table 7 indicates the distance from the midpoint of SON/SOF to the nasal midline ranged from 17.96 mm to 34.83 mm (mean: 26.53 mm ± 3.74) on the right side; and 18.26 mm to 40.52 mm (mean: 27.18 mm ± 4.11) on the left side.

The study found a median of 26.48 mm on the right side and 27.02 mm on the left side. There were no significant differences between left and right sides in South African females (p = 0.10).

4.3.2.2. Distance of SON/SOF to the frontozygomatic point in females

In addition, the study identified the distance from the SON/SOF to the frontozygomatic point at a range of 21.87 mm to 35.67 mm on the right side (mean: 28.72 mm ± 2.72) and 21.79 mm to 35.02 mm on the left side (mean: 29.01 mm ± 3.24). The median was recorded as 28.1 mm on the right, and 28.09 mm on the left side. (Table 7). No significant differences between left and right sides were noted (p = 0.28).

Table 7: Position of SON/SOF in females

	Distance to nasal midline (NM-SOF) (NM-SON) (mm)		Distance to frontozygomatic point (SOF-FZR) (SON-FZR) (mm)	
	Right side	Left side	Right side	Left side
Min	17.96	18.26	21.87	21.79
Max	34.83	40.52	35.67	35.02
Mean	26.53	27.18	28.72	29.01
Median	26.48	27.02	28.10	28.09
Standard deviation	3.74	4.11	2.72	3.24

4.4. Morphometrics of SON/SOF in males

4.4.1. Dimensions of SON/SOF in males

Table 8 indicates the dimensions of SON/SOF in males. The width of the SON or diameter of SOF ranged from 0.69 mm to 9.60 mm (mean: 3.47 mm ± 1.74) on the right side. The left side ranged from 0.97 mm to 6.31 mm (mean: 3.36 mm ± 1.50). No significant differences were observed between the left and right sides ($p = 0.78$). The median was 3.39 mm on the right side and 3.19 mm on the left side.

Table 8: Width of SON/SOF seen in males

	Width of SON/ Diameter of SOF (mm)	
	Right side	Left side
Min	0.69	0.97
Max	9.60	6.31
Mean	3.47	3.36
Median	3.39	3.19
Standard deviation	1.74	1.50

4.4.2. Position of SON/SOF in males

In this study, the length between the SON/SOF and two anatomical points were measured: nasal midline and frontozygomatic point.

4.4.2.1. Distance from midpoint of SON/SOF to nasal midline in males

The distance between SON/SOF ranged from 17.3 mm to 35.67 mm (28.35 mm ± 4.07) on the right side, and 20.13 mm to 33.84 mm (28.04 mm ± 3.24) on the left side. The median was reported as 28.62 mm on the right and 28.29 mm on the left side (Table 9). No significant differences were observed between right and left sides (p = 0.63).

4.4.2.2. Distance from midpoint SON/SOF to frontozygomatic point in males

Table 9 indicates the distance from the SON/SOF to the frontozygomatic point. The right side presented with a minimum of 23.08 mm to a maximum 35.23 mm (mean: 29.46 mm ± 2.55). The left side shows a minimum of 23.97 mm to a maximum of 40.36 mm (mean: 30.25 mm ± 3.04). No significant differences were noted between the left and right sides (p = 0.580).

Table 9: SON/SOF position in males

	Distance to nasal midline (NM-SOF) (NM-SON) (mm)		Distance to frontozygomatic point (SOF-FZR) (SON-FZR) (mm)	
	Right side	Left side	Right side	Left side
Min	17.30	20.13	23.08	23.97
Max	35.67	33.84	35.23	40.36
Median	28.62	28.29	29.58	29.81
Standard deviation	4.07	3.24	2.55	3.04

4.5. Morphometrics of SON/SOF in females versus males

In this study, dimensions and relative position of SON/SOF were compared between South African males and females.

4.5.1. Dimensions of SON/SOF in females versus males

Table 10 indicates the width or diameter of SON/SOF ranged from 0.71 mm to 9.80 mm (mean: 3.60 mm ± 1.87) in females. In males, the width or diameter of SON/SOF ranged from 0.69 mm to 9.06 mm (mean: 3.42 mm ± 1.62). Statistical analysis revealed no significant differences between males and females ($p = 0.46$).

Table 10: Width of SON/SOF seen in the female & male sample

	Width of SON/ Diameter of SOF (mm)	
	Females	Males
Min	0.71	0.69
Max	9.80	9.06
Mean	3.60	3.42
Median	3.09	3.32
Standard deviation	1.87	1.62

4.5.2 Position of SON/SOF in females versus males

4.5.2.1 Distance from midpoint of SON/SOF to nasal midline in females versus males

The distance of SON/SOF-NM ranged from 17.96 mm to 40.52 mm (mean: 26.87 mm ± 4.21) in females. In males, the distance ranged from 17.30 mm to 35.67 mm (28.20 mm

± 3.68). Table 11 outlines the descriptive statistics of the position of SOF/SON in males versus females. Statistical analysis revealed males displayed significantly larger SON/SOF-NM distance than females (p = 0.008).

4.5.2.2. Distance from midpoint SON/SOF to frontozygomatic point in females varus males

The distance from SON/SOF to the frontozygomatic point ranged from 21.79 mm - 35.67 mm (mean: 28.42 mm ± 3.00) in females. The corresponding distance in males ranged from 23.08 mm – 40.36 mm (29.83 mm ± 2.80) and was statistically greater than the distance from SON/SOF to the frontozygomatic point in females (p = 0.002)

Table 11: SOF/SON position in males vs females

	Distance to nasal midline (NM-SOF) (NM-SON) (mm)		Distance to frontozygomatic point (SOF-FZR) (SON-FZR) (mm)	
	Females	Males	Females	Males
Min	17.96	17.30	21.79	23.08
Max	40.52	35.67	35.67	40.36
Median	26.87	28.41	28.10	29.83
Mean	26.87	28.20	28.42	29.63

5. Discussion

The study sought to determine the prevalence of various morphologies of the SON/SOF along with the dimensions of the SON/SOF and position relative to the nasal midline and frontozygomatic point, in the South African population. This may assist surgeons operating in the supraorbital region to avoid injury to neurovascular structures, and aid forensics in identifying human skeletal remains.

5.1. Demographics

A total of 108 skulls were included in the study, this was deemed sufficient as sample size calculations were performed, where it was found that a minimum of 104 skulls were required to represent the population. Similar studies, by Osunwoke *et al.* (2012) used 120 dry skulls and Sharma *et al.* (2014) used 100 skulls to analyse the morphometrics of the supraorbital foramen (Osunwoke *et al.*, 2012; Sharma *et al.*, 2014).

The study population consisted of an expansive age range of 20 to 90 years old. This is comparable to a study by Tomaszewska *et al.* (2012), which included a sample with an age range of 22 to over 70 years of age. In the present study, the sex profiles were equal, which allows for meaningful comparisons. The population affinity observed was primarily Black (67.59%) followed by White (23.15%) and lastly Coloured (9.26%). No Indian specimens were included in this study. This is attributed to The Raymond A. Dart Collection of Modern Cadaveric Human Skeletons housing fewer South African Coloured and Indian specimens. Selection bias may also be a factor as dry skulls were acquired from a wide range of sources, such as archaeological sites, donations from amateur collectors, police cases and cadavers used in teaching (Dayal *et al.*, 2009).

5.2. Frequency distribution of morphologies of SON/SOF in the South African population

A wide range of studies exist, reporting on the relative position and size of the SON/SOF. In general, most studies found the notch to be more prevalent (Ilayperuma *et al*., 2014). In the present study, the SON was observed in 44% of dry skulls, SOF in 27%, absent in 19% and accessory foramina in 10% of the specimens. According to Ashwini *et al.* (2012), a study examining 83 adult skulls revealed that SON (69.87%) appeared more than double that of SOF (28.91%). Similar findings were reported by Haładaj (2019) and Voljevica *et al.* (2022). In contrast, a report by Çini and Ozdemir (2022) recorded SOF (69.00%) at a greater frequency distribution than SON (17.00%). The presence of a foramen rather than a notch suggests that the supraorbital neurovascular bundle is in a relatively stable position and thereby at greater risk during surgical dissection, as it is more likely to be stretched during retraction. Therefore, extra care must be exercised during reflection of flaps, where the supraorbital foramen is present (Chrcanovic *et al*., 2011). According to Tomaszewska *et al.* (2012), frequency of SON is greater in warmer climate regions than in cold regions. The study identified a high frequency of SOF (35.4%) in cold climates, and a low frequency of SOF (18.8%) in warm conditions. The frequency of SON was greater in warm climates (59%) and lowest in cold climates (44%). This would provide a larger exit route for the supraorbital vessels and may be due to thermoregulatory processes. The supraorbital vein is more exposed and therefore susceptible to heat loss when passing through the SON (Tomaszewska *et al*., 2012). The warm climatic conditions could be a possible factor in the greater frequency of SON than other exit passageways in our study.

Moodley *et al.* (2023) described the appearance of a fascial band, that bridges the opening of the SON, enclosing the neurovasculature. This may be a site for nerve compression and induce further neuralgia to innervated areas (Moodley *et al*., 2023).

In this study, SON/SOF was absent in 13.89% of males and 4.63% of females. Without SON/SOF, the supraorbital vasculature is more susceptible to injury due to the sharp supraorbital margin (Voljevica *et al*., 2022). Osunwoke *et al.* (2012), reported absent SON/SOF in 8.33% of males and 4.17% of females. According to Tezer *et al.* (2017), the foramen and absent SON/SOF cannot be palpated, however, the notch can be palpated during physical examination. In our study, 19% of cases identified an absence of SON/SOF, in the South African population. The risk of neurovascular damage is thus greater in subperiosteal interventions, such as endoscopic facelifts and migraine surgeries, when there is an absence of SON/SOF (Tezer *et al*., 2017). Haładaj (2019) examined both wet and dry specimens, identifying co-occurrence in 18% of the sample (Haładaj, 2019). This is a higher prevalence than the present study, where only 4% of the sample found a co-occurrence of notch and foramen. The population studied by Haladaj (2019) was primarily Caucasian which could explain why these differences exist (Haładaj, 2019). The double notch and double foramen have only been observed in a small portion of the sample. In the current study, the double foramen has only been identified in (1.39%) females, and none in males. Osunwoke *et al.* (2012) reported double foramina in 11.11% in males, and 4.17% in females. This shows a smaller prevalence of accessory foramina in our study. Very few studies have reported the incidence of double notches. Hong *et al.* (2021) conducted a study using 3D CT images and identified 0.8% double notches on the right side and 0.4% on the left side. In this study, only 3.7% of double notches were found on the right side in females, which is considerably higher than the study conducted by Hong *et al.* (2021). There were no double foramen identified in males, which is similar to the study conducted by Hong *et al.* (2021). Knowledge of the presence of accessory foramina is important to surgeons as additional nerve bundles may emerge from these openings. The occurrence of accessory supraorbital nerves, may render anaesthetic blocks unsuccessful (Moodley *et al*., 2023).

5.3. Morphometrics of SON/SOF

In the current study, the mean width of SON or diameter of SOF on the right side is 3.88 mm ± 2.19 on the right side and 3.40 mm ± 1.49 on the left side in females. In males, the mean width of SON/SOF was recorded as 3.47 mm ± 1.74 and 3.36 mm ± 1.5 on the left side respectively. Ashwini *et al.* (2012) reported a mean transverse diameter of 5.17 mm ± 0.35 on the right side and 5.58 mm ± 0.45 on the left side. A review by Ilayperuma *et al.* (2014) identified a transverse diameter of 4.60 mm ± 1.67 in males, and 4.28 mm ± 1.06 in females. Therefore, the size of SON/SOF in this study is smaller in diameter than in other studies (Ashwini *et al*., 2012; Ilayperuma *et al*., 2014). The difference in our findings might be due to population affinity differences between the studied populations (Dzopalic *et al*., 2016). No significant differences were found between the left and right sides, in our study. Further to this, in accordance with a study by Osunwoke *et al.* (2012), no significant differences between SON/SOF in males and females were identified (Osunwoke, 2012).

5.4. Position of SON/SOF

Various studies have been used to determine position of the SON/SOF (Osunwoke, 2012; Woo *et al*., 2013). In our study, the distance from the nasal midline to SON/SOF was 27.36 mm ± 3.97 on the right and 27.54 mm ± 4.11 on the left side, in combined sexes. Voljevica *et al.* (2022) reported the distance SON-NM / SOF-NM, as 24.45 mm ± 2.75 on the right and 23.79 mm ± 3.45 on the left. Ilayperuma *et al.* (2014) observed a mean distance of 25.42 mm ± 2.49 on the right and 24.64 mm ± 3.16 on the left side (Ilayperuma *et al*., 2014). This indicates that our study had a greater distance SON-NM / SOF-NM distance than other studies (Ilayperuma *et al*., 2014; Voljevica *et al*., 2022). In addition, Ilayperuma *et al*., (2014) described sex differences in the position of SON/SOF, in concert with our study. The study emphasized the importance of applying anatomical variation data to each subject within a population (Ilayperuma *et al*., 2014). Males displayed a significantly greater SON-NM / SOF-NM distance than females, in our study. On average,

female individuals are smaller in cranial size and overall more gracile in comparison to males. De Bove *et al.* (2023) explained that the glabellar region, nasal region and supraorbital torus are sexually dimorphic (Del Bove *et al*., 2023). This may explain the greater SON-NM / SOF-NM distance in males than females.

In our study, the mean SON-FZR / SOF-FZR on the right side in females is 28.27 mm ± 2.72 and 29.46 mm ± 2.55 in males. The left side mean is 29.01 mm ± 3.24 in females and 30.25 mm ± 3.04 in males. Ashwini *et al.* (2012) reported a mean of 29.34 mm ± 0.32 on the right, and 28.7 mm ± 0.29 on the left side. Voljevica *et al.* (2022) found a mean of 28.30 mm ± 2.56 in males and 27.16 mm ± 2.74 in females. These findings indicate that the data does not deviate markedly from previous studies. Ashwini *et al.* (2012) suggested SON-FZR / SOF-FZR to be a more reliable parameter, as it can be accurately located on the skin. The frontozygomatic suture can be palpated on the skin at a notch along the lateral orbital margin, along the plane of the end of the palpebral fissure (Ashwini *et al*., 2012).

In our study, the distances of SON-NM / SOF-NM and SON-FZR / SOF-FZR was significantly larger in males than females. Similar findings of shorter distance in females than males have been previously reported by Agthong *et al.* (2005), whereby NM-SOF was smaller on the left side in females. Thus, our findings suggest that sex should be considered when locating SON/SOF, as the distance to midline may be greater in males than in females (Agthong *et al*., 2005). The shape of the human cranium and distribution of supraorbital structures may be influenced by genetic and environmental factors (Dzopalic *et al*., 2016).

Palamenghi *et al.,* (2021) explored the potential of cranial non-metric traits, such as SON/SOF. The study determined that SON/SOF was not sufficiently unique to be regarded as individualising. Whilst our study did identify significant positional differences

of SON/SOF, between males and females, a larger sample size is required to evaluate the accuracy of this tool, as a sex estimator (Palamenghi et al., 2021).

6. Conclusion

The study examined macerated human skulls with the aim of providing valuable information to surgeons when operating in the supraorbital region. Accurate anatomical knowledge of neurovascular architecture and foramina localisation can help avoid iatrogenic injury during the administration of local anaesthetic, retraction of musculocutaneous scalp flaps or surgical dissection of the supraorbital region. In a South African population, the SON was the most commonly identified passageway, followed by the SOF. Based on the literature, the shape of the human cranium and the distribution of the supraorbital structures may be influenced by genetic and environmental factors. The warm climatic conditions may account for the greater frequency of SON than other exit passageways in our study.

The presentation of accessory foramina is relatively uncommon in the South African population. If an unsuccessful or incomplete nerve block is encountered, one should consider the possibility of accessory foramina or the absence of a foramen or notch. Injury to any branch of the supraorbital nerve that exits through these accessory foramina may result in sensory deficits.

The relatively large absence of SON/SOF was unique in this study. Careful planning should be followed in these cases, as the supraorbital vessels are more inclined to injury due to the sharp supraorbital margin.

The positional distances were significantly greater in males than females, when using the nasal midline and frontozygomatic point as landmarks. Females exhibit a smaller cranial size and the frontonasal region is sexually dimorphic. No significant differences were observed between the left side and right side in both sexes. These variations should be considered along with necessary precautions when operating in the region.

In forensic sciences, further research must be conducted to validate the use of the SON/SOF when identifying individuals. When this data is available, the morphological features and positional data may be used for sex estimation, or to narrow down potential

matches and strengthen tentative or presumptive identifications, in conjunction with other methods.

Based on the findings, it is recommended that surgeons operating in the supraorbital region consider the following guidelines:

1. Pre-operative examination must include palpation in the supraorbital region to identify SON/SOF, as the SON is a palpable structure.
    a. If SON is palpated – maintain a 2mm safety zone around the area.
    b. If no SON is palpated and there is a risk of injury to structures based on the procedure performed – consider using adjunct tools (CT/CBCT/MRI imaging) as appropriate.
    c. If no obvious SON/SOF is identified ensure informed consent and comprehensive counselling of the patient regarding greater risk of injury to structures in the region is obtained.
2. Reference points measured (i.e., nasal midline and frontozygomatic point) can aid intraoperative orientation as well as planning surgical incision placement and needle insertion for nerve blocks.
3. Consider location variations of SON/SOF amongst sexes.
4. If an unsuccessful or incomplete nerve block is encountered, one should consider the possibility of accessory foramina or the absence of foramen or notch.
5. Careful dissection techniques and possible use of magnifying aids/loupes/nerve stimulators to aid in dissection, and prevent injury.

7. Limitations

The Raymond A. Dart Collection of Modern Cadaveric Human Skeletons houses a considerably small sample size of South African Coloured specimens and even fewer South African Indian skulls. This introduces sampling bias as these groups were less likely included in the study. Incorporating probability sampling techniques reduced the possibility of bias.

8. Future studies

The incorporation of advanced imaging, such as CBCT, will increase reliability and more accurate measurement of parameters. This will support the anatomical data and strengthen findings.

References

Alsup, B. K., Fox, G. M. (2023). BlueLink Images, *University of Michigan Medical School*.

Agthong, S., Huanmanop, T., & Chentanez, V. (2005). Anatomical variations of the supraorbital, infraorbital, and mental foramina related to gender and side. *Journal of Oral Maxillofacial Surgery*, *63*(6), 800-804.

Albert, M. A., Payne, A. L., Brady, S. M., & Wright, C. (2019). Craniofacial Changes in Children-Birth to Late Adolescence. *ARC Journal of Forensic Science*, *4*(1).

Ashwini, L. S., Mohandas Rao, K. G., Saran, S., & Somayaji, S. N. (2012). Morphological and Morphometric Analysis of Supraorbital Foramen and Supraorbital Notch: A Study on Dry Human Skulls. *Oman Medical Journal*, *27*(2), 129-133.

Bastir, M., Rosas, A., & O'Higgins, P. (2006). Craniofacial levels and the morphological maturation of the human skull. *Journal of Anatomy*, *209*(5), 637-654.

Chrcanovic, B. R., Abreu, M. H., & Custodio, A. L. (2011). A morphometric analysis of supraorbital and infraorbital foramina relative to surgical landmarks. *Surgical and Radiologic Anatomy*, *33*(4), 329-335.

Cuerrier-Richer, E. (2022). Missing and murdered indigenous women and girls in Canada: a new population affinity assessment technique to aid in identification using 3D technology. *Forensic Science Research*, *7*(3), 427-439.

Dayal, M. R., Kegley, A. D., Strkalj, G., Bidmos, M. A., & Kuykendall, K. L. (2009). The History and Composition of the Raymond A. Dart Collection of Human Skeletons at the University of the Witwatersrand, Johannesburg, South Africa. *American Journal of Physical Anthropology 140*(2), 324-335.

Del Bove, A., Menéndez, L., Manzi, G., Moggi-Cecchi, J., Lorenzo, C., & Profico, A. (2023). Mapping sexual dimorphism signal in the human cranium. *Scientific Reports*, *13*(1).

de Souza Ferreira, M. R., de Farias Campina, R. C., Magalhães, C. P., & Valença, V. C. (2017). Supraorbital foramen or notch and its relationship with the supraorbital nerve in human. *Headache Medicine*, *8*, 130-133.

Dzopalic, T., Ignjatovic, J., Stojanov, D., Popovic, J., & Bjelakovic, M. D. (2016). *Evaluation of Variability of Supraorbital Notches and Foramina Using Three-Dimensional Computed Tomography Volume Rendering* RAD Conference Proceedings.

Ehrlich, R., & Joubert, G. (2014). Epidemiology : A Research Manual for South Africa *3rd*. (Oxford University Press Southern Africa).

Haładaj, R., Polguj, M., Topol, M. (2019). Anatomical Variations of the Supraorbital and Supratrochlear Nerves: Their Intraorbital Course and Relation to the Supraorbital Margin. *Medical Science Monitor 25*, 5201-5210.

Hong, J. H., Kim, J. S., & Shin, H. K. (2021). Studies of Supraorbital Notch and Foramen Using 3-Dimensional Facial Bone CT Scans. *Pain Physician 24*, 1273-1278.

Ilayperuma, I., Nanayakkara, G., & Palahapitiya, N. (2014). Supraorbital Notch/Foramen in Sri Lankan Skulls: Morphometry and Surgical Relevance. *International Journal of Morphology*, *32*, 435-439.

Jeong, S. M., Park, K. J., Kang, S. H., Shin, H. W., Kim, H., Lee, H. K., & Chung, Y. G. (2010). Anatomical Consideration of the Anterior and Lateral Cutaneous Nerves in the Scalp. *Journal of Korean Medical Science*, *25*(4), 517-522.

Moodley, S., Ishwarkumar, S., & Pillay, P. (2023). Localisation of the supraorbital, infraorbital and mental foramina: A review. *Translational Research in Anatomy*, *32*.

Osunwoke, E. A., Nlewem, C., Achinike, P.N. (2012). Morphometric Study of the Supraorbital Notches and Foramina in Adult Human Skulls in South-South Nigeria. *The Nigerian Health Journal*, *12*.

Palamenghi, A., Borlando, A., De Angelis, D., Sforza, C., Cattaneo, C., & Gibelli, D. (2021). Exploring the potential of cranial non-metric traits as a tool for personal identification: the never-ending dilemma. *International Journal of Legal Medicine*, *135*(6), 2509-2518.

Sharma, N., Varshney, R., Faruqi, N. A., & Ghaus, F. (2014). Supraorbital Foramen - Morphometric Study and Clinical Implications in Adult Indian Skulls. *Acta Medica International*, *1*(1).

Statistics South Africa. (2022). *Mid-year Population Estimates,*. (Statistical Release P0302,). Pretoria

Rehman, 2023. Foramen vs. Notch — What's the Difference?, Ask difference. [Accessed from: https://www.askdifference.com/foramen-vs-notch/]

Tezer, M. S., Elvan, O., Gilan, I. Y., Türkegün, M., Esen, K., & Özgür, A. (2017). Radiological Management of the Exiting Points of Supraorbital Region Neurovascular Bundles. *International Journal of Morphology*, *35*(4), 1391-1395.

Tomaszewska, A., Kwiatkowska, B., & Jankauskas, R. (2012). The localization of the supraorbital notch or foramen is crucial for headache and supraorbital neuralgia avoiding and treatment. *The Anatomical Record 295*(9), 1494-1503.

Tsutsumi, S., Ono, H., Ishii, H., & Yasumoto, Y. (2019). Visualization of the Supraorbital Notch/Foramen Using Magnetic Resonance Imaging. *Journal of Clinical Neuroscience 62*, 212-215.

Vargas, A., Astorga, P., Rioseco, T. (2017). Anatomy Applied to Block Anesthesia for Maxillofacial Surgery. In *Dental Anatomy* (pp. Ch. 4). IntechOpen.

Voljevica, A., Talovic, E., Sahinovic, M., & Pleho-Kapic, A. (2022). Morphometric Analysis of the Supraorbital Foramen and Notch in the Population of Bosnia and Herzegovina. *Acta Medica Academic Journal*, *51*(2), 92-98.

Woo, S. W., Lee, H. J., Nahm, F. S., Lee, P. B., & Choi, E. J. (2013). Anatomic Characteristics of Supraorbital Foramina in Korean Using Three-Dimensional Model. *The Korean Journal of Pain*, *26*(2), 130-134.

Appendix A

Table 12: Data collection form adapted from Haładaj (2019)

Skull number	Sex	Age	Population affinity	Type of passage		Width (notch) or diameter (foramen) (mm)		Distance to nasal midline (mm)		Distance to frontozygomatic point (mm)	
				Right	Left	Right	Left	Right	Left	Right	Left
1											
3											
4											
5											
6											
7											
8											
9											

UNIVERSITY OF THE WITWATERSRAND, JOHANNESBURG

FACULTY OF HEALTH SCIENCES

Appendix B: Approval of title

UNIVERSITY OF THE WITWATERSRAND, JOHANNESBURG

Private Bag 3 Wits, 2050
Fax: 027117172119
Tel: 02711 7172076

Reference: Mrs Sandra Benn
E-mail: sandra.benn@wits.ac.za

23 November 2023
Person No: 604609
PAG

Dr K Ramkissoon
40 GREY STREET
Kensington B
2194
South Africa

Dear Dr Kajal Ramkissoon

Master of Science in Dentistry: Approval of Title

We have pleasure in advising that your proposal entitled *Morphometric analysis of the supraorbital foramen in the South African population* has been approved. Please note that any amendments to this title have to be endorsed by the Faculty's higher degrees committee and formally approved.

Yours sincerely

Mrs Sandra Benn
Faculty Registrar
Faculty of Health Sciences

Appendix C: Ethics Waiver

SCHOOL OF ANATOMICAL SCIENCES ETHICS WAIVER CLEARANCE LETTER

Faculty of Health Sciences
School of Anatomical Sciences
University of the Witwatersrand
Johannesburg

Re: In terms of Chapter 8, sections 62-64 of the National Health Act No 61 of 2003 donated bodies and their tissues may be used for, among other purposes, health, and research. Use of such Material is subject only to permission from the responsible person in the School of Anatomical Sciences – the Head or person designated by the Head of School.

Human Research Ethics Committee (Medical) Clearance Certificate:

W-CBP-220504-01

This letter serves to confirm that the Head of School, based in the School of Anatomical Sciences, Faculty of Health Sciences, has reviewed the research proposal entitled:

Morphometric Analysis of the Supraorbital Foramen in the South African Population

by principal investigator: **KAJAL RAMKISSOON**

and supervisor/collaborators: **Prof RE Rikhotso, Dr MA Bobat, Dr A Bhika**

and has granted approval for the ethics waiver to conduct the above-mentioned research study.



13.12.2023

Professor Amadi O. Ihunwo
Head of School: Anatomical Sciences
[B.Med.Sci (Hons), M.Sc., Ph.D]
Email: Amadi.Ihunwo@wits.ac.za

Dated

School of Anatomical Sciences
7 York Rd, Parktown, 2193, South Africa, Private Bag 3, WITS 2050
Tel: +27 11 717 2405/2305 | www.wits.ac.za/anatomicalsciences/
IYUNIVESITHI YASEWITWATERSRAND | YUNIVESITHI YA WITWATERSRAND

Appendix D: Turnitin report

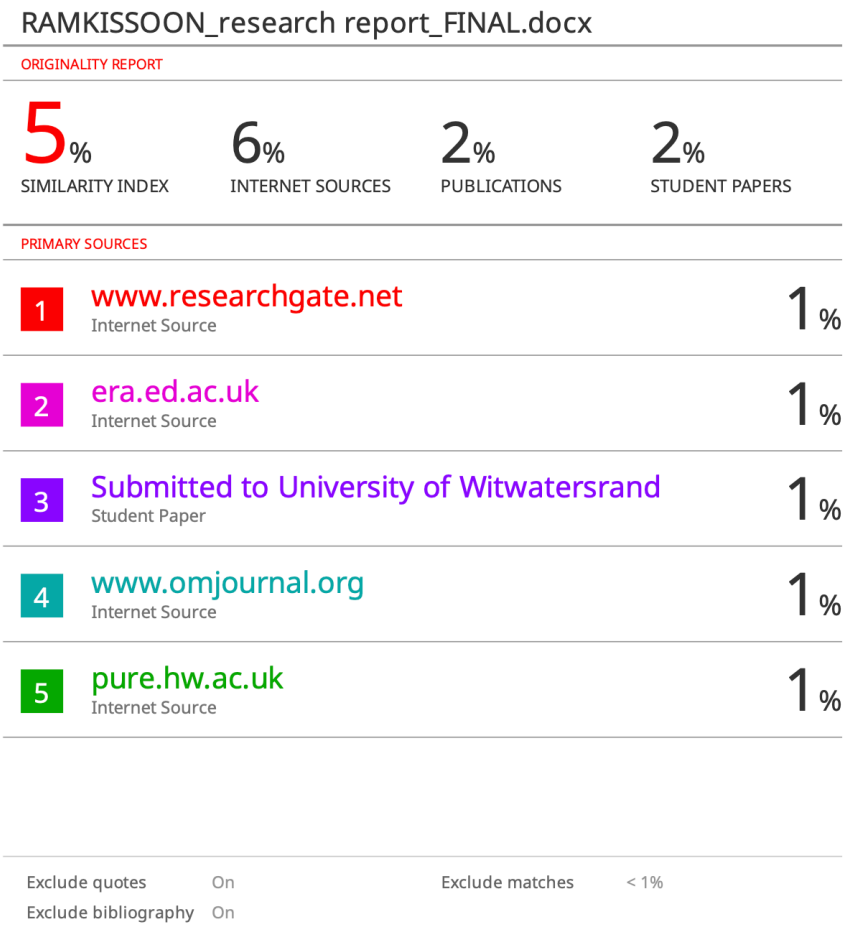

RAMKISSOON_research report_FINAL.docx

ORIGINALITY REPORT

5%	6%	2%	2%
SIMILARITY INDEX	INTERNET SOURCES	PUBLICATIONS	STUDENT PAPERS

PRIMARY SOURCES

1	www.researchgate.net Internet Source	1%
2	era.ed.ac.uk Internet Source	1%
3	Submitted to University of Witwatersrand Student Paper	1%
4	www.omjournal.org Internet Source	1%
5	pure.hw.ac.uk Internet Source	1%

Exclude quotes	On	Exclude matches	< 1%
Exclude bibliography	On		