

https://dspace.org/

Findings in computed Tomography brain scans of patients referred with first-episode Psychosis

Van Wyk, Matthys Johannes

2013-03-19
http://hdl.handle.net/10539/12570

Downloaded from a DSpace repository. https://dspace.org/

FINDINGS IN COMPUTED TOMOGRAPHY BRAIN SCANS OF PATIENTS REFERRED WITH FIRST-EPISODE PSYCHOSIS

Matthys Johannes van Wyk

Dissertation submitted to the Faculty of Health Sciences, University of the Witwatersrand, in partial fulfilment of the requirements for the degree of

Master of Medicine

in the Division of

Diagnostic Radiology

Johannesburg

2012

DECLARATION

I, Matthys Johannes van Wyk, declare that this dissertation is my own work. It is being submitted for the degree of Master of Medicine in the branch of Diagnostic Radiology at the University of the Witwatersrand, Johannesburg. It has not been submitted before for any degree or examination at this or any other university.

_____

22 July 2012

DEDICATION

In memory of my father

Thys van Wyk

1932-2007

PRESENTATIONS ARISING FROM THIS STUDY

The results of this study were delivered as an oral presentation at the Radiological Society of Southern Africa's MDCT Essentials course (26 – 28 August 2011) at Sandton Convention Centre, Johannesburg.

ABSTRACT

Psychosis, the inability to separate subjectivity and reality, can be either functional or organic. Organic psychoses are attributed to physical brain conditions, excluded by imaging. CT scanning requires evaluation regarding the detection of organic pathology in South Africa, with its high TB and HIV prevalence and resource limitations.

Aim

To determine the prevalence of structural brain abnormalities detected on CT in patients referred with a first-episode psychosis to a tertiary hospital in Johannesburg, South Africa.

Materials & Methods

One hundred and twelve CT brain scan reports of patients referred over a two-year period, after a first-episode psychosis, were retrospectively reviewed. Demographic data, HIV status, space-occupying lesions (SOL), ventricle size, abnormal calcifications and features of raised intra-cranial pressure were recorded.

Results

Eighty-eight of 112 patients were included in the sample [46 (52.3%) males; mean age 37 years; range 16 – 67 years]. Eleven (20.8%) of the 53 patients evaluated for HIV tested positive. Of the 77 patients tested for syphilis, three (3.9%) tested positive. Sixteen (18.8%) patients had abnormalities on CT. Only two (2%) were deemed significant findings (a hypodensity in the left cerebral peduncle and features of mesiotemporal sclerosis). Three (3.4%) patients had enlarged ventricles. Seven (8%) patients had age-inappropriate involutional changes. Six patients (6.8%) had old calcified granulomata. No SOLs were detected. None had features of raised intra-cranial pressure.

Conclusion

The yield of abnormalities in CT brain scans in patients referred with a first-episode psychosis at our institution is high. However, only a small percentage of these are significant, can be attributed to the psychosis or affect management.

ACKNOWLEDGEMENTS

Prof Victor Mngomezulu – supervisor

Prof Savvas Andronikou for his critical and creative analysis of the text

Mrs Barbara Dadswell for retrieving the reports

Prof Elena Libhaber for her patient and kind help with the statistical analysis

My loving wife, Carol, for her unwavering love and support

TABLE OF CONTENTS

DECLARATION……..…...ii

DEDICATION……iii

PRESENTATION…….……..……iv

ABSTRACT…….v

ACKNOWLEDGEMENTS……....vi

TABLE OF CONTENTS……...……..…..vii

LIST OF FIGURES…….x

LIST OF TABLES……...xi

ACRONYMS…...……...…xii

PREFACE.....xiv

1.0 LITERATURE REVIEW……...1

1.1 Psychosis……1

1.1.1 Psychosis classification……2

1.1.2 Demographics……..2

1.1.3 Etiology……2

1.2 First-episode psychosis……...…3

1.2.1 Definition…….3

1.2.2 Diagnostic work-up for first-episode psychosis……...4

1.3 Brain imaging……4

1.3.1 CT……4

1.3.2 MRI……12

1.3.3 Yield of brain imaging……...12

1.4 International psychosis work-up guidelines…….....……...14

1.5 Infection and psychosis……..……..……17

1.5.1 HIV ……17

1.5.2 Tuberculosis……..……...18

1.5.3 Syphilis……..……...18

2.0 INTRODUCTION…….……19

2.1 Rationale…….……19

2.2 Aim…….19

2.3 Objectives……..20

2.4 Scope of the research study……....20

3.0 METHODOLOGY……21

3.1 Study design.....21

3.2 Sample…….21

3.3 Inclusion and exclusion criteria……..……21

3.4 Method……22

3.5 Data analysis and statistical methods……..22

4.0 RESULTS……...26

4.1 Index episode……...26

4.2 Demographics……..26

4.3 HIV status……29

4.4 Syphilis serology…….29

4.5 CT brain findings……30

4.5.1 Raised intra-cranial pressure……..30

4.5.2 Ventricular size and shape……30

4.5.3 Involutional changes…….……30

4.5.4 Abnormal calcifications…….30

4.5.5 Space-occupying lesions……31

4.5.6 Other findings……31

4.6 Change in management……...31

5.0 DISCUSSION……...……..……33

5.1 Demographics……...33

5.2 Index episode……...33

5.3 HIV status……33

5.4 Syphilis serology……..34

5.5 CT brain findings……34

5.5.1 Raised intracranial pressure……...34

5.5.2 Ventriculomegaly……...35

5.5.3 Involutional changes……..35

5.5.4 Abnormal calcifications……35

5.5.5 Space-occupying lesions……....36

5.6 Impact of CT brain scans ……...36

5.7 Limitations of the study……37

6.0 CONCLUSION……38

7.0 REFERENCES……39

8.0 APPENDICES……...……...43

8.1 Data collection sheet……..……..44

8.2 Ethics approval clearance certificate ...……45

LIST OF FIGURES

Figure **Page**

4.1 Gender distribution of findings……....27

4.2 Distribution of findings by age…….28

LIST OF TABLES

Table **Page**

1.1 Compilation and summary of studies evaluating the CT brain findings in patients with first-episode psychosis.…….…….. 6

1.2 Inclusion criteria for CT brain of patients with psychosis. ……...16

3.1 Original and modified classification of Goulet……. 25

4.1 Summary of demographic results of 88 patients. ……..26

4.2 The influence of HIV status on scans results…….....29

4.3 Stratification of the impact of scans results according to the modified Goulet classification…….……...…….. 31

ACRONYMS

AC0P0	Abnormal finding on CT brain with unlikely relation to clinical picture or psychosis
AC+P0	Abnormal finding on CT brain with a likely relation to clinical picture but not to the psychosis
AC+P+	Abnormal finding on CT brain with likely relation to clinical picture and psychosis
CMJAH	Charlotte Maxeke Johannesburg Academic Hospital
CNS	Central Nervous System
CSF	Cerebrospinal fluid
CT	Computed Tomography
CTB	Computed Tomography of the Brain
EEG	Electroencephalogram
FBC	Full blood count
FEP	First-episode psychosis
HIV	Human Immunodeficiency Virus
LFT	Liver Function Test
MRI	Magnetic Resonance Imaging
MSE	Mental State Examination
NCC	Neurocysticercosis
RANZCP	Royal Australian and New Zealand College of Psychiatrists
RPR	Rapid plasma reagent test
TB	Tuberculosis
TFT	Thyroid Function Test

TLE	Temporal Lobe Epilepsy
TPHA	*Treponema pallidum* haem-agglutination assay
U&E	Urea and creatinine
UK	United Kingdom

CHAPTER 1:
LITERATURE REVIEW

This review will define and classify psychosis. It will give an outline of its demographics, etiology and investigation. We will critically evaluate the use of CT and MRI and discuss the CT brain imaging findings in psychotic patients. The current international guidelines on the diagnostic work-up of a first-episode psychosis (FEP) will be discussed as well as the yield of brain imaging in this group of patients. We will briefly discuss the role that HIV, syphilis and tuberculosis play in patients with FEP.

1.1 PSYCHOSIS

There are different definitions of psychosis documented in the literature.

According to Kaplan and Sadock's Synopsis of Psychiatry, the most common psychiatric use of the term psychosis refers to the "severe impairment of social and personal functioning characterised by social withdrawal and inability to perform the usual and occupational roles". They further elaborate to define psychosis as "[the] inability to distinguish reality from fantasy; impaired reality testing, with the creation of a new reality (as opposed to neurosis: mental disorder in which reality testing is intact; behaviour may not violate gross social norms, but is relatively enduring or recurrent without treatment)."(1)

Stedman's Medical Dictionary, on the other hand, defines psychosis as,

> "A mental disorder causing gross distortion or disorganization of a person's mental capacity, affecting response, and capacity to recognize reality, communicate, and relate to others to the degree of interfering with his capacity to cope with the ordinary demands of everyday life" (2).

1.1.1 Psychosis classification

Psychosis is a symptom and not a diagnosis in itself. The psychoses are divided into two major groups depending on their origin: 1) those related to organic brain syndromes and 2) those that have some functional component and are not clearly organic by nature (3).

1.1.2 Demographics

In the United Kingdom (UK) most psychotic episodes (83.3%) occur in the 15-59 year age group followed by 16.5% in the age group older than 60 years. The least percentage (0.2%) occurs in those younger than 14 years of age (4). The majority of the patients in the UK were male (59%) (4). South African data of mentally ill inpatients scanned that presented either with (i) a first episode psychosis or (ii) psychosis and features of a delirium, focal physical or neurological signs, and/or abnormal special investigation results,correlate with these age and gender trends (5).

1.1.3 Etiology

Etiology differs by gender and age. In younger patients the cause is more commonly functional in nature whilst in the elderly organic causes are more prevalent (4, 5).

Although there is renewed debate about the classification of the psychoses (6) functional psychoses include schizophrenia, bipolar mood disorder and mania, and form the majority of the psychoses (3).

In the UK the incidence of organic pathology resulting in psychosis is estimated to be between five and ten percent (4).

Organic psychoses can be attributed to physical medical conditions such as previous head trauma, encephalitis or a space-occupying brain lesion (for example, a tumour) (7).

A viral etiology for psychosis has been suggested. Psychotic symptoms may be caused by limbic encephalitis secondary to Epstein-Barr, cytomegalovirus, rubella, herpes simplex, measles and HIV viruses (8).

In Alzheimer's disease, psychosis is often a non-cognitive condition that accompanies dementia whereas in Parkinson's disease, treatment with anti-parkinsonian drugs is the most frequent cause of psychotic symptoms (9).

People with multiple sclerosis rarely develop psychotic symptoms (8).

Psychosis in epilepsy does occur and is episodic rather than continuing with normal interictal periods (10).

Organic psychoses are commonly of acute onset and where a space-occupying lesion is the cause associated, neurological manifestations are usually found. These might include cranial nerve paralyses, motor neuron impairment, sensory loss as well as speech and hearing difficulties (7).

Unusual features such as an acute onset and delirium characterise organic psychoses and may lead the clinician to suspect an organic rather than a functional cause. Some of these patients presenting with psychosis may have obvious underlying psychiatric pathology, may have used psychosis-inducing agents or have a history of previous head trauma (7).

For many of these patients, however, the cause of their psychosis will be unknown.

1.2 FIRST-EPISODE PSYCHOSIS

1.2.1 Definition

Also known as an index-episode psychosis, it refers to the first time that an individual experiences a psychotic episode. It is sometimes difficult to determine the exact time of onset.

In practice this translates into an individual who presents to healthcare with psychosis and who has never previously presented to healthcare with psychosis (11). There is however no consensus operational definition for first episode psychosis (11).

Studies revealed that early intervention (within three to five years) resulted in symptom improvement, lower relapse rates and promoted functional recovery (12).

1.2.2 Diagnostic work-up for first-episode psychosis

In addition to the routine physical, mental and neurological assessment, laboratory examinations are also conducted. These include: full blood count (FBC); renal function and electrolytes (U&E); liver functions (LFT); thyroid function tests (TFT); human immunodeficiency virus (HIV) status; and syphilis (TPHA and RPR). Furthermore cerebrospinal fluid (CSF) is evaluated biochemically and cytologically. Some cases may require an encephalogram (EEG) (13).

1.3 BRAIN IMAGING

Pathology may sometimes be missed when relying solely on the standard tests (misidentification syndrome) and thus CT and MRI may prove useful to diagnose organic pathology where it has been missed in the initial standard examinations. If all these tests yield no positive findings, it is assumed that the patient has functional psychosis (4).

1.3.1 CT

CT of the brain adds information on the structure of the brain, meninges and soft tissues of the head. Computed tomography uses ionising radiation to produce multiple axial two-dimensional slices through the brain recorded by an array of detectors. The resultant images can be reconstructed into various planes of visualisation. It produces superior images of the bones and hard tissues compared to other imaging modalities. It may reveal pathologies such

as space-occupying lesions, abnormal calcifications, involutional changes, cerebrospinal fluid space abnormalities and even meningitis.

a) Findings on CT in patients with psychosis

A number of studies have described CT changes noted in the brains of patients with first-episode psychosis (5, 14-20) (Table 1.1). Most of these changes are equivocal and non-specific (20).

These findings are likely to be influenced by factors such as age, gender, age of onset of psychosis, clinical symptoms, length and stage of illness and exposure to neuroleptics (21).

Table 1.1: Compilation and summary of studies evaluating the CT brain findings in patients with first-episode psychosis (constructed from references 3, 11-17).

Study	Normal n(%)	AC0P0* n(%)	AC+P0* n(%)	AC+P+* n(%)
Beresford (16) 1986	106 (68)	22 (14.1) 6 cerebral atrophy 2 cerebral and cerebellar atrophy 2 ventricular enlargement 2 superior cerebellar vermis atrophy 1 bifrontal atrophy 1 enlarged third ventricle 1 old surgical lesion 2 frontal lobe atrophy 1 old craniotomy 1 orbit mucocoele 1 midfrontal hypodensity left 1 parietal calcification left 1 focal Sylvian fissure atrophy	18 (11.5) 2 ventricular outflow obstruction 1 right frontal and left occipital infarcts 1 patchy post fossa encephalomalacia 1 small frontal haematomas 1 subdural haematoma 1 middle cerebral artery distribution encephalomalacia right 1 putamen infarct right 1 lacunar infarcts in putamen and internal capsule 1 occipital infarct right 2 putamen infarct left 2 MCA territory atrophy left 1 left frontal infarct 1 frontal encephalomalacia 1 left occipital infarct 1 cerebral and cerebellar encephalomalacia	10 (6.4) 1 focal parietal atrophy 1 encephalomalacia next to right lateral ventricle 1 parietal and temporal lobe atrophy right 1 right head of caudate infarct 1 frontal and temporal hypodensity left 1 temporal lobe stroke left 1 temporal lobe atrophy 1 metastatic lesion to left parietal lobe 1 anterior parietal encephalomalacia left 1 brain stem stroke
Battaglia and Spector (15) 1988	42 (93.3)	2 (4.4) 2 atrophy (mild)	1 (2.2) 2 possible frontal white matter infarct	1 (2.2) 1 possible left caudate infarct
Ananth (17) 1993	25 (73.5)	8 (23.5) 1 mild central atrophy 1 mild cerebral atrophy 1 right frontal area of density 1 generalised atrophy 1 bifrontal atrophy 1 prominent sulci 1 asymmetrical Sylvian fissures 1 mild atrophy left frontal lobe	0 (0)	1 (2.9) 1 post parietal and occipital attenuation
Gerwitz et al. (14) 1994	93 (55.4)	71 (42.3) 67 cortical atrophy (diffuse) 2 arachnoid cysts 1 ventricular enlargement 1 venous angioma	2 (1.2) 1 right subcortical parieto-temporal infarct 1 ischaemic changes (diffuse)	4 (2.4) 1 moderately large right temporal arachnoid cyst 1 parietal and subinsular infarcts (bilateral) 1 parietal ischaemic changes (bilateral) 1 colloid cyst obstructing foramen of Munro
Bain (20) 1998	123 (96.9)	3 (2.4) 1 subcortical right frontal calcification 2 arachnoid cysts	1 (0.8) 1 possible pineal tumour	0 (0)
Agzarian (18) 2006	377 (95)	14 (3.5) 5 cortical atrophy 5 arachnoid cysts 1 calcified choroid plexus in 4th ventricle 3 non specific abnormalities disproved on MRI	6 (1.5) 3 small vessel ischaemic changes 1 small right cerebellar cavernoma 1 small calcified meningeoma 1 colloid cyst without hydrocephalus	0 (0)
Hirano (19) 2006	88 (75.2)	18 (15.4) 10 old infarcts 3 age indeterminate infarcts 2 lipoma 1 hygroma 1 chronic subdural 1 post traumatic calcification	11 (9.4) 3 acute infarct 3 intracranial haemorrhage 1 subdural haematoma 3 meningeoma 1 pituitary adenoma	0 (0)
Jeenah (5) 2007	35 (63.6)	8 (14.4) 7 global cerebral atrophy 1 blow-out fracture of the orbit	6 (11) 6 old infarct +/- calcification	6 (11) 6 pituitary adenoma, TB granuloma, neurocysticercosis

*(AC0P0) Abnormal finding on CT brain with unlikely relation to clinical picture or psychosis,

(AC+P0) Abnormal finding on CT brain with a likely relation to clinical picture but not to the psychosis

(AC+P+) Abnormal finding on CT brain with likely relation to clinical picture and psychosis

Ventriculomegaly

Malla et al. found mild enlargement of the ventricles, the right temporal horn being larger than the left (21). Ventriculomegaly on CT was also documented by Hoffler et al. (22). Third ventricle prominence was noted in patients with schizophrenia but not in other psychotic disorders (23). Ichimiya and others, however, describe third ventricle enlargement as an inconsistent finding (21, 24).

In refractory temporal lobe epilepsy (TLE), mesial temporal sclerosis is the most common pathologic entity found and is seen in as many as 60% to 80% of cases (25). Shukla et al. compared two groups of 62 with TLE and 90 with generalised epilepsy respectively and found that there was a statistically significant higher incidence of psychosis in the TLE group (26). Wyler describes atrophy and chronic herniation of the mesial temporal structures over the free edge of the tentorium in seventeen patients who had a CTB prior to temporal lobectomy (27).

Cerebral atrophy

Malla et al. found mild enlargement of cortical sulci in psychotic patients but noted that younger patients did not exhibit a significantly greater level of cerebral atrophy (21). Variance in the findings was mostly explained by age and not by variables such as clinical syndrome types, duration of illness or gender (21). Tsai and Tsuang studied 135 psychiatric patients' brain scans. Of these nearly fifteen had atrophy (28). In a study by Evans on 100 consecutive psychiatric in- and outpatients, 66% had atrophy (29). Larson et al. found that 35% of a group of 123 patients with psychosis had atrophy (30). Some authors found the atrophy in the frontal and central brain regions to be progressive over a five-year period but Malla et al. found, if after controlling for the effect of age, the atrophy did not progress as a result of disease evolution (21, 31). They did, however, report progressive enlargement of the sylvian

fissure due to chronic illness (21). In first-episode psychosis the left sylvian fissure appeared more prominent than the right (21). Other inconsistent findings reported include focal reduction in the size of the frontal lobes and involvement of the cerebellum (24).

Infarcts

In the elderly, organic pathology such as infarcts may result in psychotic behaviour. Anderson et al. reported on two cases of elderly females presenting with acute psychosis with occipital and subcortical infarcts respectively (32). They also noted that patients with a psychiatric history are more prone to psychosis following a stroke and that it is rarely reported owing to under recognition (32).

Space-occupying lesions

Asselman et al. noted that thirteen percent of 75 HIV positive patients with new neurological and psychiatric symptoms presented with a space-occupying lesion; one related to toxoplasmosis and nine of uncertain etiology (33). In a post-mortem study in 1978, Cole reported that in South African psychiatric patients the prevalence of space-occupying lesions was 15.5% (34). These lesions included: subdural haematomas, primary CNS neoplasms, a metastatic neoplasm, a hamartoma, tuberculomas, parasitic tapeworm cysts and an abscess (34).

Brain tumours causing psychosis are rare and their prevalence on CT in the psychiatric population is about 1.2% (35). Three percent of the necropsy material studied by Cole had intracranial neoplasms (34).

Traumatic brain injury

In a group of brain-injured troops from Finland, nearly 10% developed psychotic symptoms within 5 years (8). Only one patient in the series studied by Cole had evidence of head injury – a recent fall, resulting in a subdural haemorrhage (34).

Arachnoid cysts

Some anecdotal reports of patients presenting with first-episode psychosis and arachnoid cyst have been published (36, 37). The authors either did not ascribe the psychosis to the presence of the arachnoid cyst (36), or had difficulty in deciding whether or not the lesion was significant (37).

Meningitis

Cryptococcal meningitis is a known cause of psychosis (38). It was the cause of neuropsychiatric deterioration in 24% of 75 patients who were HIV positive and had been recently started on antiretrovirals (33).

b) Advantages of CT

Availability

CT scanners are relatively widely available in the world (39). In South Africa it is the case in larger cities where secondary and tertiary hospitals are found. There is, however, a discrepancy between public and private distribution of these scanners.

During 2005/2006 in the Western Cape Province of South Africa there were seven CT scanners available in 32 public hospitals and 24 CT scanners for 29 private hospitals. This means that a CT scanner was available for every 4.5 public hospitals and 1.2 for private

hospitals. During this period a total of 28 281 CT examinations were requested in the public sector while 36 519 CT examinations were ordered in the private sector (40).

Cost

The cost is less than that of MRI but remains relatively high. In 2009 a non-contrasted CT brain cost around R1 681.70; a contrasted CT of the brain cost in the order of R2 470.90 and a pre- and post-contrast scan cost the patient R3 005.50. An MRI cost between R4 736.90 and R7 724.60 depending on whether or not contrast was used (41).

Quickness

It is a relatively quick procedure, compared to MRI and takes between 15 to 30 minutes to acquire brain images depending on whether or not contrast was given. This results in fewer movement artifacts (39, 42).

Additional findings

Additional findings or pathologies in the surrounding tissues of the head might be serendipitously picked up in imaging the brain.

Non-invasiveness

Unlike a biopsy, a CT is a non-invasive method to exclude pathology. Moreover, unlike MRI, it is not contra-indicated in patients with pacemakers or metallic implants (39).

c) Limitations and disadvantages of CT

Patient factors

For optimal visualisation, the patient must be able to lie still.

The average radiation dose to which people in the US are exposed has doubled over the past 30 years (43). Ionising radiation is a well-known cause of deleterious effects in high doses and may even be carcinogenic. The life-time risk of cancer from a single brain CT is low (1: 10 000 for those older than fifteen but younger than 20) but higher in the young (42). For this reason it is contra-indicated in pregnancy.

CT has poorer soft-tissue contrast ability and fails to diagnose lesions with the same density as the surrounding tissue (39). In order to visualise these lesions and diagnose infection, iodinated contrast medium is often injected intravenously. It is not without any risk however. These compounds may cause permanent renal impairment and damage (39).

Some patients may be allergic and can react fatally to the iodine in these contrast agents (44).

Equipment factors

There are a number of equipment related factors that can affect the quality of the scan and some that result in artifacts (45).

There is 90% - 100% accuracy for mass lesions greater than 2.5 cm in diameter (46, 47).

CT is also unable to diagnose some of the causes of psychosis such as dementia and epilepsy. In dementia, however, CT scanning is done to screen such patients for potentially treatable conditions such as hydrocephalus, meningeoma and subdural haematoma (46).

The number of CT scans of the brain conducted annually in South Africa is unknown (48).

In our setting we are overburdened by requests for CT of various parts of the body. The great demand for CT results in long waiting lists and sometimes an unfortunate delay in an urgent CT. Complicating this matter, the old and overused equipment requires regular servicing and sometimes replacement of a faulty component.

1.3.2 MRI

Compared to CT, MRI is a relatively new imaging modality.

a) Advantages

MRI has exquisite grey-white matter resolution. Unlike CT, it is possible to image in various planes. The coronal views are especially valuable in evaluating the frontal and limbic regions. 3-D reconstruction of brain structures is possible (49). MRI is useful in, among others, morphometric brain studies, evaluation of brain tissue and metabolic function as well as in examining the cerebral blood flow (49).

No ionising radiation is used. MRI poses minimal risk to the patient (49).

b) Disadvantages

Compared to CT, MRI is quite expensive (41). Its availability is limited to larger medical centres and cities. It is estimated that there were 2 MRI scanners for 32 public hospitals compared to 16 MRI scanners available to the 29 private hospitals during 2005/2006 in the Western Cape Province of South Africa (40).

Patients with claustrophobia find the scanning unbearable (42, 49).

MRI is contra-indicated in patients with pacemakers, certain implants, metallic foreign bodies and aneurysm clips (49).

1.3.3 Yield of brain imaging

Several studies have been conducted on imaging to determine the incidence of organic pathology that could be the cause of psychosis (5, 14, 16-20).

In an exploratory study of 55 psychiatric patients by Jeenah and Moosa (see Table 1) at Chris Hani Baragwanath Hospital in South Africa, 20 (36.4%) patients had abnormal CT brain scans (5). The abnormalities detected included blow-out fracture of the orbit (1%), old infarcts (6%), global cerebral atrophy (7%) and mass lesions (6%). These masses included: pituitary adenoma, TB granuloma and neurocysticercosis. There was a significant correlation between abnormalities and advancing patient age. Fifteen of the abnormal scans were of patients with a first-episode psychosis (5). The authors recommended further study with a larger sample size to determine the necessity for scanning all first-episode psychotic patients (5).

The systematic review by Albon et al. of 25 studies found that in most studies, structural neuro-imaging identified very little that would influence patient management that was not suspected, based on a medical history and/or physical examination and there were more incidental findings (35). They found that in these studies only around 0,5% of patients had findings on CT that would have affected clinical management (35). In a study by Strahl et al. reports of 237 consecutive patients who provided a history of first-episode psychosis revealed no focal brain lesion that could be responsible for the psychosis. Unrelated findings included small vessel ischaemic changes, arachnoid cysts, cerebral atrophy and normal variants in 17.6% of patients (36). None of these findings led to a change in management (36). Ebdrup et al. reviewed eight papers, including a total of 625 CT and 214 MRI scans. On CT, the incidence of potentially causal brain abnormalities was 0.8% and on MRI 3.3% (50). The findings had limited clinical consequences, however, and thus they concluded that there is no support for performing routine CT scans of first-episode psychotic patients (50). Hirano et al. reported that the overall yield of CT brain scans in elderly unselected hospitalised patients is low (19). They, however, did not consider elderly psychotic patients. The same conclusions were made by, among others, Bain (20) and Agzarian (18). The tendency noted from these

studies is that most of the CT scans conducted for first-episode psychosis are normal. This is followed by findings of an abnormality without any impact on the clinical or psychiatric manifestations. Findings that were believed to influence either the clinical or psychiatric picture ranged between 0 and 11.5%. The highest number of abnormal imaging findings related to psychosis was observed in the study by Jeenah and Moosa (5). They did, however, have one of the smaller sample sizes (i.e. 55). The study with the greatest sample size (i.e. 397) was conducted by Agzarian (18). These findings confirmed the hypothesis that the abnormal findings in patients with a first-episode psychosis is very low and that the majority of scans are normal (18).

1.4 INTERNATIONAL PSYCHOSIS WORK-UP GUIDELINES

Guidelines for the work-up of first-episode psychosis vary among countries. The Royal Australian and New Zealand College of Psychiatrists (RANZCP) advocates a neuro-imaging of the new onset psychotic patient, while Britain is more conservative in their approach and do not suggest an initial CT of the brain (4, 51). Although the RANZCP advocates neuro-imaging in first-episode psychosis, they acknowledge that currently no evidence is available that routine imaging alters outcome or clinical management (4, 51). They furthermore acknowledge that CT has a low yield for screening psychotic patients. They highlight the fact that MRI has been reported to have significant yield detecting clinically important findings but that no yield is available for patients that underwent screening MRI for psychosis (51).

The American group of Hollister suggested the following as sound, high yield indications for brain imaging in psychiatric patients: 1) history of previous head trauma, stroke, neurological disease, Alzheimer's disease or multi-infarct dementia; 2) abnormal neurological signs or organic mental signs (e.g. cognitive decline or confusion); or 3) a first psychotic episode after the age of 50 years (52). They found brain scanning not to be rewarding in patients with a

history of alcohol or substance abuse, mental disorders lacking additional neuropsychiatric abnormalities, or for the evaluation of seizure disorders or abnormal EEG patterns (52). The study dates back to 1996, relying on old CT technology and no MRI at their disposal. Moreover, the sample consisted of only 68 patients and did not study first-episode psychotic patients *per se*.

Tsai et al. recommended that those psychiatric patients who had normal mental state examination (MSE); neurological examination (NE); EEG and Bender Gestalt test (BIP), could safely be excluded from having organic pathology requiring imaging by CT. Those who had normal ME and NE but abnormal BIP or EEG could also be excluded if they were 40 years or younger with no history of head injury (28). Once again the study evaluates general psychiatric patients and did not exclusively investigate patients with FEP.

In a review article by Goodstein in 1986, broad inclusion criteria for CT scanning of the brain in general psychiatric patients are suggested: 1) when symptoms of a significantly disabling psychiatric disease do not fit the classical descriptions for the illness; 2) where there is a high index of suspicion of a space-occupying brain lesion due to specific evaluation findings; and 3) If the CT findings, whether positive or normal will potentially influence management, rather than merely satisfy the clinician's academic curiosity (47).

Goodstein suggested numerous specific inclusion criteria for CT of the brain (Table 2.2).

Table 1.2: Inclusion criteria for CT brain of patients with psychosis (Table constructed from reference 10).

Clinical	***Treatment response***
Atypical psychiatric presentation.	Refractory or atypical response to usually effective doses of psychiatric medication or electroconvulsive therapy.
Atypical pre-hospital course in an otherwise "classic" psychiatric diagnosis.	Unexplained delirium during or persisting after an ECT treatment.
Severe affective illness or psychosis with no family history of such a disease.	***Symptoms***
Unusually rapid deterioration of the psychiatric illness.	True vertigo.
Late onset of psychosis.	Incontinence not due to infection or other easily identifiable causes.
Abrupt onset of psychosis.	Ataxia not caused by intoxication or other identifiable causes.
Abrupt personality change.	Fluctuating or persistent delirium not due to drugs, alcohol, medicines or pyrexia.
Adult onset seizures.	Ear pain with a discharge not accounted for by local infection.
Mental retardation	Unusual symptomatic headaches.
Unexplained rage or aggression	
Major decline in intellectual function and memory	
Stupor	
Gross head trauma	
Immunosuppression	
Anticoagulation	
Pseudodementia	
Abnormal EEG	
Focal CNS findings suggesting intracranial pathology	

1.5 INFECTION AND PSYCHOSIS

Infectious diseases remain the leading cause of death in South Africa. The chief infective disease culprits are HIV and TB (53). Due to the high prevalence of these diseases, a closer look at their relation to psychosis and the imaging findings thereof is necessitated.

1.5.1 HIV

It has been demonstrated that HIV *per se* may be associated with psychosis (54-56). First-episode psychosis in HIV positive patients occurred in 0.2%-15% of patients. Säll et al. reviewed the files of 38 South African black male, HIV positive mine workers and found the incidence of psychosis to be 29% (57). CT scans were only conducted in 24% of these patients and only in 4 were some kind of pathological finding found. Three patients, who had concurrent features of dementia, demonstrated cerebral atrophy, wide ventricles and sulci on CT. The fourth patient had a lesion in the pituitary fossa (57). In another South African prospective observational cohort study of 75 HIV positive patients, reported by Asselman et al., 12% presented with psychosis (33). In the majority (five patients) Efavirenz (an antiretroviral agent) was thought to be the cause (33) as it is known to cause psychotic side-effects (58). The highest incidence of psychosis was reported among patients in later stages of HIV disease and with HIV associated dementia. In one study 15% of 46 patients with HIV associated dementia presented with psychosis (59). This suggests that psychosis is a direct effect of the HIV infection on the CNS. Various hypotheses have been constructed to explain the pathogenesis of first-episode psychosis in HIV positive patients: subcortical neurodegeneration due to HIV itself or in the presence of other viral infections; psychosis secondary to HIV encephalopathy; brain damage from another underlying opportunistic infection, or an underlying dementia (60). The following factors contributed to the

development of psychosis in HIV positive patients: untreated HIV infection, cognitive impairment, dementia and a history of psychiatric disease or substance abuse (58).

1.5.2 Tuberculosis

In the study by Asselman, 36% of the 75 HIV positive patients started on antiretrovirals had neurological deterioration secondary to TB. All patients diagnosed with tuberculoma had a negative serum immunoglobulin G (IgG) analysis for *Toxoplasma* species (33) and thus immunological studies were not an accurate assessment of CNS infection with tuberculosis. In a case report, Woodroof ascribed a patient's psychotic symptoms to structural damage from an intracranial tuberculoma (62). There is, however, a paucity of data in the literature on the association between patients suffering from first-episode psychosis and cerebral tuberculosis.

1.5.3 Syphilis

CNS involvement with concurrent syphilis infection is a common cause for neuropsychiatric symptoms (57). However, in a group of South African mine workers reviewed by Säll et al., 53% of the HIV positive patients were tested for syphilis and only two tested positive (57). The RPR test is used for screening and a confirmatory TPHA test is conducted (61).

CHAPTER 2:
INTRODUCTION

2.1 RATIONALE

The general opinion of CT brain scans done on first-episode psychotic patients, in order "to rule out organic pathology", is that it does not yield a great amount of information. This creates a preconceived notion that these scans, on the whole, will be normal and therefore may impact on the bias of the reader. New imaging techniques e.g. magnetic resonance imaging (MRI) may be more appropriate but are not cost effective in our resource limited setting. The use of CT, when the yield of significant pathology is low, is even less appropriate as it exposes patients to high doses of radiation.

2.2 AIM

The purpose of this research study is to determine the utility of CT brain scans in first episode psychosis patients (referred from a tertiary hospital psychiatry service in Johannesburg, South Africa) based on abnormal findings.

2.3 OBJECTIVES

The objectives of this study are divided in to primary and secondary objectives.

Primary objectives:

To:

2.3.1 determine the prevalence of abnormalities on CT brain scans;

2.3.2 categorise the abnormalities as either: i) bearing no clinical significance, ii) with clinical significance, but unlikely to cause the patient's psychosis or iii) with clinical significance, and possibly contributing to the patient's psychosis.

Secondary objectives:

To:

2.3.3 determine the prevalence of human immunodeficiency virus (HIV) and syphilis in the study population;

2.3.4 stratify the abnormalities according to age, gender and HIV status.

2.4 SCOPE OF THE RESEARCH STUDY

The study will only focus on patients referred as a first-episode psychosis from the psychiatric service at the Charlotte Maxeke Johannesburg Academic Hospital (CMJAH).

The CMJAH is a tertiary hospital serving not only the immediate Johannesburg population but also patients from around the Gauteng Province.

CHAPTER 3:

METHODOLOGY

In this chapter we will explain the type of study and discuss the study material and methods used to gather and analyse the data. Inclusion and exclusion criteria will be mentioned and the descriptors of the dataset will be defined.

3.1 STUDY DESIGN

This is a retrospective descriptive review of reports and patient records in one South African tertiary referral centre (CMJA Hospital in Johannesburg).

3.2 SAMPLE

A consultant radiologist reviewed the CT brain scan reports of patients referred with a first-episode psychosis. One hundred and twelve of these reports in conjunction with patient records and laboratory results review were dealt with.

3.3 INCLUSION AND EXCLUSION CRITERIA

The study included CT reports spanning a period of fourteen months (January 2009 to March 2010) of patients referred after a first episode of psychosis at the Charlotte Maxeke Johannesburg Academic hospital (CMJAH) for the purposes of ruling out organic pathology.

At the time of the original reading, the radiologists were blind to the clinical details with the exception of the history provided by the referring clinician on the request form.

Only patients who had a true index psychotic episode were included. False referrals were excluded from the study. One hundred and twelve patients' reports and folders were reviewed. Twenty-four patients had to be excluded owing to the fact that they did not present

with a true first-episode psychotic episode. A patient was regarded to have a first psychotic episode if folder or discharge summary review revealed no previous admission for psychosis was made, the patient received no antipsychotics in the past and collateral history revealed no prior psychotic episode.

3.4 METHOD

All the scans reviewed in this study were conducted in a standardised manner, as is routine practice in the department. Non-contrast, computed tomograms were performed on one of two CT machines in the department and reported by various radiology consultants and registrars.

3.5 DATA ANALYSIS AND STATISTICAL METHODS

Data was recorded in an Excel spreadsheet and statistical analysis was performed using the Statistica 8.0 package. Data was summarised as mean (SAD) or median (range) when distribution was normal or not normal respectively and variables were measured in a continuous scale. Categorical data is shown as frequencies, percentages and with a 95% Confidence Interval.

For comparison between categorical variables a Chi-square or Fisher Exact Test when adequate was used. Significance was set at 0.05.

The following data was extracted:

a) Demographics

The patients' gender and age were recorded.

b) Index episode

From the record or discharge summary it was ascertained whether the current psychotic episode was indeed the index or first episode

c) HIV status

The HIV status was recorded either as a) positive, b) negative or c) not tested.

If the patient tested positive for HIV, the CD4 count (cells/μL) was also evaluated.

d) Syphilis status

Both the RPR and TPHA test results were documented and recorded either as a) positive, b) negative or c) not tested.

e) CT brain findings

i) Features of raised intra-cranial pressure

If the surface sulci, ventricles and/or basal cisterns were attenuated and/or the foramen magnum was crowded, the patient was deemed to have raised intra-cranial pressure. It was recorded as either a) present or b) absent.

ii) Ventricular size and shape

Ventricular size was recorded as either a) normal; b) attenuated; c) enlarged but not hydrocephalic; d) hydrocephalic; e) asymmetric or f) in keeping with normal pressure hydrocephalus. If the ventricles were asymmetric, the location of the asymmetry was noted if described (e.g. posterior horn of the left lateral ventricle).

iii) Involutional changes

Involutional changes were recorded as either absent or present. If present, they were classified as either being age appropriate or age inappropriate.

The principles of Le May (63) were applied retrospectively to the report findings recorded regarding the following features: From the fourth decade there is gradual widening of the

third ventricle, sylvian and interhemispheric fissures, superficial sulci and basal cisterns (63). After the sixth decade, enlargement of the lateral ventricles is the most striking feature (63). Regressional changes are a normal aging process but highly variable (63).

Involution occurring before the age of 50 years was regarded as being age inappropriate. Thereafter the changes were deemed to be age appropriate depending on their degree. The consultant radiologist reviewing the scan subjectively assessed the degree of involution.

iv) Abnormal calcification

Calcifications that are not considered as forming part of the normal or normal ageing brain were recorded. These were further characterised as being either a) granulomata (TB or old Neurocysticercosis); b) post traumatic or c) uncharacterised.

v) Space-occupying lesions

A space-occupying lesion was considered present if it occupied space and impinged on adjacent structures. Abnormal calcifications did not form part of this category and were recorded separately.

f) Change in management

The study of Goulet (42) served as the basis for our modified classification of abnormal CT brains (Table 3.1).

Table 3.1: Original and modified classification of Goulet

Original classification of Goulet (42)	Modified classification of Goulet
1. Normal. 2. Abnormal, with no clinical impact: benign or non-specific findings with no implication on diagnosis, management, or treatment. We included in this category all findings such as atrophy, fissure enlargement, benign cysts, and other similar matters. 3. Abnormal, with implication on management or treatment, but an unlikely causal link to psychotic symptoms. This group included findings warranting neurological investigation or treatment, such as the unexpected finding of an arterio-venous malformation, but with a high unlikelihood that treatment would influence the course of the psychosis. 4. Abnormal, with implication on management or treatment, and a possible causal link to psychotic symptoms. This group included the neurological syndromes mentioned by Weinberger, lesions in key cerebral regions already mentioned (temporal lobes, diencephalon, and basal ganglia), and demyelinating diseases.	1. Normal. 2. Abnormal, benign or non-specific findings bearing no influence on the diagnosis, management or treatment. In this category, amongst others, the following is included: atrophy, fissure prominence, benign cysts and the like. (AC0P0) 3. Abnormal, with ramifications for management or treatment, but an unlikely causal link to psychotic symptoms. This group included findings requiring further neurological investigation or treatment, but with a low likelihood that treatment would affect the course of the psychosis. (AC+P0) 4. Abnormal, with implication on management or treatment and a possible causal link to psychotic symptoms. This group included lesions in key cerebral regions such as the temporal lobes, diencephalon and basal ganglia. (AC+P+)

CHAPTER 4:

RESULTS

This chapter will present the results of the data collection according to index episode, demographics, HIV status, syphilis serology and CT brain findings.

4.1 INDEX EPISODE

Only 88 patients (78.6%) actually presented with an index episode while 24 (21.4%) had a history of previous psychotic episodes.

4.2 DEMOGRAPHICS

The total of 88 patients included in the sample is comprised 46 (52.3%) males and 42 (47.7%) females (Table 4.1). No statistically significant difference was found between the prevalence of abnormalities when correlated with gender (χ^2 test p=0.8405) (Figure 4.1).

Table 4.1: Summary of the demographic results of 88 patients

Variable		Total (n=88)	Abnormal (n=16)	Normal (n=72)
Gender	**Male**	46 (52.3%)	8 (17.4%)	38 (82.6%)
	Female	42 (47.7%)	8 (19%)	34 (81%)
Age group (years)	**16-30**	34 (38.6%)	3 (8.8%)	31 (91.2%)
	31-60	50 (56.8%)	12 (24%)	38 (76%)
	>60	4 (4.6%)	1 (25%)	3 (75%)

Figure 4.1: Gender distribution of findings

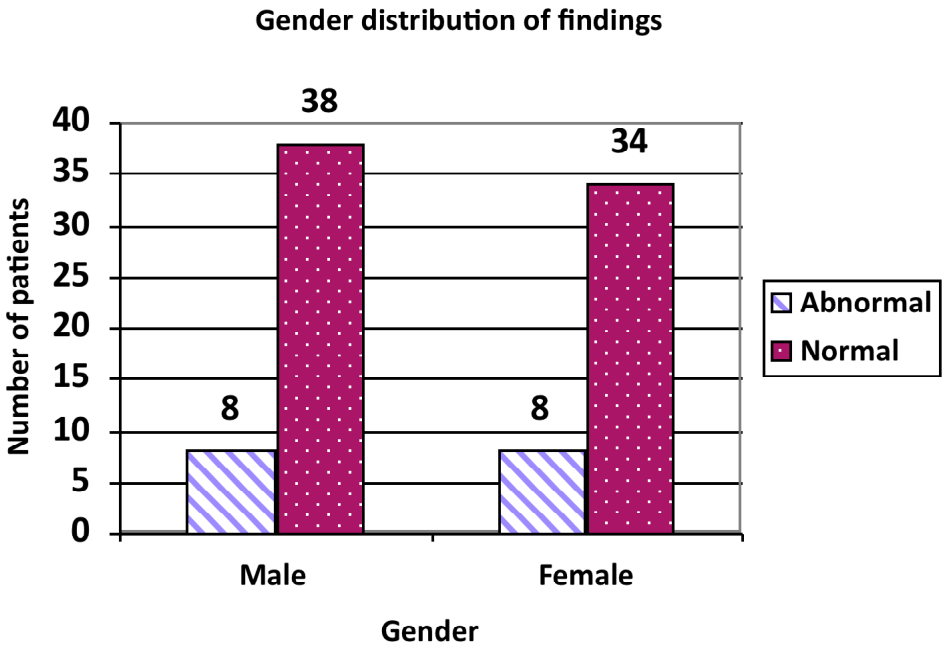

The mean age of these patients was 37 years (SD ± 13) and ranged from 16 to 67 years. There was no statistically significant difference between the prevalence of abnormalities when correlated with age (Fisher's Exact Test[1] p = 0.1433) (Figure 4.2).

[1] Fisher's Exact Test was used, instead of the χ^2 test, owing to the small sample numbers.

Figure 4.2: Distribution of findings by age

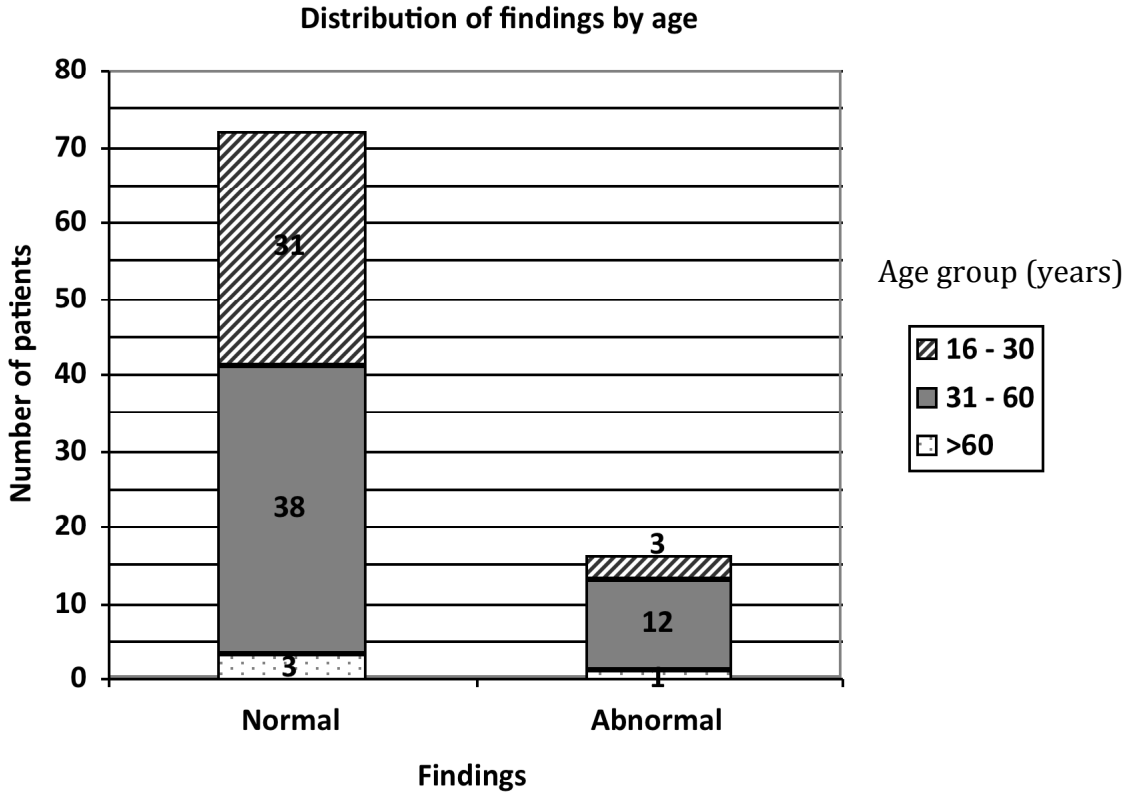

In order to evaluate the relationship between age group and abnormalities without the influence of HIV, we evaluated the HIV negative group. Once again no statistically significant difference between age groups where CT abnormalities were found (Fisher's Exact Test p=0.3598).

4.3 HIV STATUS

Only 53 patients were submitted to HIV testing.

Eleven (20.8%) patients tested HIV positive; 42 (79.2%) tested HIV negative.

Of the eleven HIV positive patients, the mean CD4 count was 301 cells/μL (SD ± 230) and ranged between 41 cells/μL and 707 cells/μL. The median CD4 count was 231 cells/μL. The highest prevalence of HIV is in the age group 31 – 60. The relationship between the prevalence of abnormalities and HIV appears to be slightly higher in this group, but not statistically significant (Fisher's Exact Test p = 0.6634) (Table 4.2).

Table 4.2: The influence of HIV status on scans results

	Scan result	
HIV status	**Normal**	**Abnormal**
HIV + (n = 11)	8	3
HIV – (n = 42)	37	5

Only 53 patients were submitted to HIV testing.
The table reflects the scan results of the tested patients only.

4.4 SYPHILIS SEROLOGY

Seventy-seven patients were tested for syphilis. The remaining 11 were not submitted to testing.

Three patients (3.9%) tested RPR positive. Seventy-four (96.1%) tested negative. There was no statistically significant correlation between the RPR positive patients and abnormal CT brain scans (Fisher's Exact Test p = 0.4496)

Six patients (7.8%) had a positive TPHA reaction; 71 (92.2%) negative.

4.5 CT BRAIN FINDINGS

4.5.1 Raised intracranial pressure

None of the patients' scans displayed features of raised intracranial pressure.

4.5.2 Ventricular size and shape

The ventricles were normal in 85 (96.6%) patients. Three (3.4%) patients had enlarged but not hydrocephalic ventricles.

4.5.3 Involutional changes

Most of the patients, 80 (90.9%), had no involutional changes reported. Age appropriate involutional changes were described in one (1.1%) patient while seven (8%) patients had age inappropriate involutional changes. In most (five) of the patients with involutional changes, the affected area was not specified. In two patients, focal parietal and in another one left hemi-atrophy were described.

4.5.4 Abnormal calcifications

Six patients (6.8%) had abnormal intracranial calcifications. Of these, two were regarded as old neurocysticercosis and four calcifications were not specified.

The location of the old neurocysticerci calcifications was not specified. The non-specified calcifications were located in the left basal ganglia, the right frontal and temporal lobes as well as in the left frontal lobe.

4.5.5 Space-occupying lesions

Only one (1.1%) patient demonstrated a space-occupying lesion. This was described as a hypodense lesion in the left cerebral peduncle and further imaging via MRI was recommended.

4.5.6 Other findings

Scalp nodules were noted on the scan of one patient and a working diagnosis of possible neurofibromatosis was made. A biopsy was suggested. No intracranial features of neurofibromatosis were documented.

4.6 CHANGE IN MANAGEMENT

The brain scans were normal in 72 (81.8%) cases.

Abnormalities were described in 16 (18.2%) patients' scans.

These abnormalities and their clinical importance are listed in Table 4.3.

Table 4.3: Stratification of the impact of scans results according to the modified Goulet classification

Classification	Number (%)	Findings [number of patients]
Normal	72 (82%)	
AC0P0	14 (16%)	▪ Old neurocysticercosis [2] ▪ Age inappropriate involution changes [7] ▪ Enlarged ventricles [3] ▪ Unspecified granulomata [4]
AC+P0	1 (1%)	Hypodensity in the left cerebral peduncle [1]
AC+P+	1 (1%)	CT features of left mesiotemporal sclerosis [1]

Some patients had more than one anomaly, which explains why the sum of the findings results in a total slightly greater than the total number of abnormalities. Percentages, however, express proportion of subjects, not a proportion of all abnormalities.

Fourteen (15.9%) of the 16 abnormalities were graded to be without any clinical impact and thought to have no implication on the diagnosis, management or treatment of the patient. These abnormalities were thought not to contribute to the patient's psychosis.

One (1.1%) patient had abnormalities that may have had possible implications on management and treatment but were not deemed to have a causal link to the patient's psychosis. This abnormality was a hypodense lesion in the left cerebral peduncle.

One (1.1%) patient had an abnormality (left mesiotemporal sclerosis suggestive of temporal lobe epilepsy) that most likely impacted on further management and was thought possibly to contribute to the patient's psychotic state.

CHAPTER 5:

DISCUSSION

This chapter discusses the results of the research presented in the previous chapter. These are viewed in conjunction with the preceding literature review in order to provide answers to the stated aim and objectives.

5.1 DEMOGRAPHICS

The gender distribution was nearly equal and matched that of similar studies elsewhere (5, 64).

Age distribution also matched international samples. The youngest patient in our population was 16 years of age. Most of the abnormalities occurred in the groups younger than 60 years of age.

5.2 INDEX EPISODE

An important observation is that 21.4% of all the cases referred as a first-episode psychosis turned out to have had a prior psychotic episode.

We postulate that reasons for this might include improper or incomplete history taking by the examining clinician, inappropriate imaging referral or deliberate falsifying of the history in order to obtain a CT brain that would otherwise be denied. A MEDLINE search however, did not reveal any existing literature on the falsification of history in order to obtain medical imaging. This referral practice might be a topic for future investigation.

5.3 HIV STATUS

Although only 11 patients tested HIV positive, 39.8% of the 88 patients were not subjected to HIV testing. The reasons for this might include refusal by the patient to be tested, a low clinical suspicion by the examining clinician or non-adherence to work-up protocols.

The mean CD4 count of the HIV positive patients was not particularly low (301 cells/μL). Whether or not the patients received antiretroviral medication was not investigated.

It does not seem, at least from this data, that an HIV positive patient has a proclivity to the development of an acute first-episode psychosis as noted in a Nigerian study where HIV positive patients had significantly higher rates of affective-, anxiety and psychotic disorders compared to their healthy controls (64). The authors found that both the lack of social support as well as the stage of disease contributed to the psychiatric manifestations (64).

5.4 SYPHILIS SEROLOGY

There was discordance between the RPR and TPHA tests as seven patients tested positive on RPR but ten patients on TPHA. Discrepant syphilis results require further confirmatory tests. None such tests were recorded in the NHLS laboratory database. As the RPR test is the first screening test that would prompt further confirmatory testing, concordant positive RPR and TPHA tests were regarded as positive for syphilis. Three (3.4%) patients tested positive for both RPR and TPHA and were deemed to have syphilis. This is in agreement with the findings of Säll (57).

Eleven patients (12.5%) were not submitted to syphilis testing. Once again the reasons for this might include: patient refusal, a low clinical index of suspicion by the examining clinician or non-adherence to departmental work-up protocols.

5.5 CT BRAIN FINDINGS

5.5.1 Raised intracranial pressure

None of the patients displayed structural features of raised intracranial pressure. Frequently scans are requested to exclude features of raised intracranial pressure so that the clinician can perform a lumbar puncture without the risk of brain herniation.

5.5.2 Ventriculomegaly

Although ventriculomegaly (65) and ventricular asymmetry (36) is a known pathologic feature of CT brain scans in patients with psychosis, in our population only 3.4% of the patients had abnormal ventricular configuration. Reasons for this low figure might include: subtle ventriculomegaly, which might be missed; an apparently insignificant finding that is disregarded or not mentioned in the report. General radiologists might not be aware of the significance of ventriculomegaly in this subset of patients.

5.5.3 Involutional changes

Our findings are similar to those of Malla et al. (21). Only nine percent of patients had involutional changes and it is *per se* not a predictor or marker for psychosis.

The CT diagnosis of mesiotemporal sclerosis is doubtful, as computed tomography is an insensitive tool for the workup of medically refractory epilepsy. Surrounding bone and beam hardening artifact contributes to the poor visualisation of this area. Bronen and co-workers (66) concluded that CT is not useful in the diagnostic imaging evaluation of refractory epilepsy compared to MRI. In their study, the sensitivity of MRI was superior (95%) compared to that of CT (32%). The ability of MRI to locate mesial temporal sclerosis was uncontested when compared to CT (98% vs 2%).

5.5.4 Abnormal calcifications

Of the six patients with abnormal calcifications, two were deemed to be old neurocysticerci granulations whilst the other calcifications were not ascribed to any specific etiology. Tuberculosis is prevalent in South Africa and thus a possible cause; however, no active tuberculomas were recorded. The relationship between calcifications and psychosis is not established.

5.5.5 Space-occupying lesions

The hypodense lesion in the left cerebral peduncle was the only non-calcific mass lesion noted in the brain. The precise nature of this lesion was not clear and further imaging via MRI was suggested. This lesion was regarded as clinically significant but the causality to the patient's psychosis was not proven.

5.6 IMPACT OF CT BRAIN SCANS

CT has established itself as an invaluable and relatively affordable tool in the initial evaluation of intracranial pathology. It is not without shortcomings however. It is unable to match the superb soft tissue differentiation of MRI. In a setting where the prevalence of clinically significant pathology is low, the question should be asked whether this practice should continue unaltered.

This research makes a contribution by validating findings from numerous previous studies (18-20) that found a low yield of clinically significant findings that might also be related to the patient's psychosis. The majority of the abnormalities included ventricular prominence and involutional changes that would not necessarily affect the patient's management.

In this study the sample size is small, *albeit* nearly double the numbers of similar studies conducted in a nearby institution (5). It is a retrospective analysis of various consultant-reviewed reports that begs the question about the consistency and standardised manner in which these scans were reported.

This study at least supports the recommendations by Hollister for CT brain imaging (52). The following are regarded as sound indications for a CT of the brain in a patient with a first-episode psychosis: history of previous head trauma, stroke, neurological disease, Alzheimer's

disease or multi-infarct dementia; abnormal neurological signs or organic mental signs (e.g. cognitive decline or confusion); or a first psychotic episode after the age of 50 years.

Furthermore, this study did not support the general idea that patients infected with HIV or syphilis have a higher prevalence of psychosis.

5.7 LIMITATIONS OF THE STUDY

Study design

The significance of this study is hampered by its retrospective design. It could not have taken account for the multiple readers, different scanners used, inconsistent scan settings and scan protocols.

System or practice limitations

These include poor record keeping and insufficiently detailed reports as well as inconsistency in the grading of involution and ventricle size.

Sample size

All these factors contributed to the small sample size. Several hundred patients should be included owing to the relative infrequency of true-positive findings.

Population

The population only includes patients referred from one tertiary hospital's psychiatric service.

CHAPTER 6:
CONCLUSION

The yield of abnormalities in CT brain scans in patients referred with a first-episode psychosis at our institution is high. However, only a small percentage of these are significant, can be attributed to the psychosis or affect management.

Is further research needed after all the published evidence? The relevance of further study seems valid if future research consists of several hundred patients, are designed as prospective, multicentre and double blind evaluated studies. Attempts at classifying abnormalities should be made along the groups described by Goulet (42).

If ventricle size is to be described, objective evaluation of ventriculomegaly must be made, as the descriptive approach is vague and non-specific.

The clinical significance of findings should be evaluated in consultation with a psychiatrist, neurologist and/or neurosurgeon.

A comparison should be made between the findings on CT and MRI. We believe that MRI might shed more light on the underlying pathology of first-episode psychosis than CT.

The cost-effectiveness of imaging patients with FEP should be evaluated.

An interesting observation made was that of the apparent falsification of the patient's history in order to obtain a CT scan. This practice is not described in the literature and warrants further investigation.

7. REFERENCES

1. Typical Signs and Symptoms of Psychiatric Illness Defined. In: Kaplan HI, Sadock BJ, editors. Kaplan and Sadock's Synopsis of Psychiatry. 8th ed. Baltimore, Maryland: Williams & Wilkins; 1998. p. 281 - 302.
2. Stedman's medical dictionary. 25th ed: Williams & Wilkins. Stedman's medical dictionary.
3. Wong KE. A practical approach to the management of psychoses. Singapore Med J. 1993 Aug;34(4):346-8.
4. Excellence NIfHaC. Structural neuroimaging in first-episode psychosis. NICE technology appraisal guidance 136. London2011. p. 1-24.
5. Jeenah FY, Moosa MY. CT scans in psychiatric patients - an exploratory study at Chris Hani Baragwanath Hospital. S Afr J Psych. 2007 February;13(1):22-5.
6. Allardyce J, Gaebel W, Zielasek J, van Os J. Deconstructing Psychosis conference February 2006: the validity of schizophrenia and alternative approaches to the classification of psychosis. Schizophr Bull. 2007 Jul;33(4):863-7.
7. Dilsaver SC. Differentiating organic from functional psychosis. Am Fam Physician. 1992 Mar;45(3):1173-80.
8. Falkai P. Differential diagnosis in acute psychotic episode. Int Clin Psychopharmacol. 1996 May;11 Suppl 2:13-7.
9. Mintzer J, Targum SD. Psychosis in elderly patients: classification and pharmacotherapy. J Geriatr Psychiatry Neurol. 2003 Dec;16(4):199-206.
10. Tucker GJ, Price TR, Johnson VB, McAllister T. Phenomenology of temporal lobe dysfunction: a link to atypical psychosis--a series of cases. J Nerv Ment Dis. 1986 Jun;174(6):348-56.
11. Breitborde NJ, Srihari VH, Woods SW. Review of the operational definition for first-episode psychosis. Early Interv Psychiatry. 2009 Nov;3(4):259-65.
12. Shiers D, Lester H. Early intervention for first episode psychosis. BMJ. 2004 Jun 19;328(7454):1451-2.
13. Shefrin A, Puddester D, Greenham S, Bisnaire L, Gandy H. What Investigations Are Ordered in Patients with First-episode Psychosis? Jefferson Journal of Psychiatry. 2006;Volume 20(Number 1):4 - 12.
14. Gewirtz G, Squires-Wheeler E, Sharif Z, Honer WG. Results of computerised tomography during first admission for psychosis. Br J Psychiatry. 1994 Jun;164(6):789-95.
15. Battaglia J, Spector IC. Utility of the CAT scan in a first psychotic episode. Gen Hosp Psychiatry. 1988 Nov;10(6):398-401.
16. Beresford TP, Blow FC, Hall RC, Nichols LO, Langston JW. CT scanning in psychiatric inpatients: clinical yield. Psychosomatics. 1986 Feb;27(2):105-12.
17. Ananth J, Gamal R, Miller M, Wohl M, Vandewater S. Is the routine CT head scan justified for psychiatric patients? A prospective study. J Psychiatr Neurosci. 1993;18(2):69 - 73.
18. Agzarian MJ, Chryssidis S, Davies RP, Pozza CH. Use of routine computed tomography brain scanning of psychiatric patients. Australas Radiology. 2006;50:27-8.
19. Hirano LA, Bogardus ST, Jr., Saluja S, Leo-Summers L, Inouye SK. Clinical yield of computed tomography brain scans in older general medical patients. J Am Geriatr Soc. 2006 Apr;54(4):587-92.

20. Bain BK. CT scans of first-break psychotic patients in good general health. Psychiatr Serv. 1998 Feb;49(2):234-5.
21. Malla AK, Mittal C, Lee M, Scholten DJ, Assis L, Norman RM. Computed tomography of the brain morphology of patients with first-episode schizophrenic psychosis. J Psychiatry Neurosci. 2002 Sep;27(5):350-8.
22. Hoffler J, Braunig P, Kruger S, Ludvik M. Morphology according to cranial computed tomography of first-episode cycloid psychosis and its long-term-course: differences compared to schizophrenia. Acta Psychiatr Scand. 1997 Sep;96(3):184-7.
23. Iacono WG, Smith GN, Moreau M, Beiser M, Fleming JA, Lin TY, et al. Ventricular and sulcal size at the onset of psychosis. Am J Psychiatry. 1988 Jul;145(7):820-4.
24. Ichimiya T, Okubo Y, Suhara T, Sudo Y. Reduced volume of the cerebellar vermis in neuroleptic-naive schizophrenia. Biol Psychiatry. 2001 Jan 1;49(1):20-7.
25. Puppala P, Thakore H, Edelman MJ. Case report of mesial temporal sclerosis with seizures and psychosis: an interface between psychiatry and neurology. Prim Care Companion J Clin Psychiatry. 2009;11(1):37-8.
26. Shukla GD, Katiyar BC, Nigam P. Temporal lobe epilepsy. (A phenomenological study of 70 cases). J Indian Med Assoc. 1979 Oct;73(7-8):118-23.
27. Wyler AR, Bolender NF. Preoperative CT diagnosis of mesial temporal sclerosis for surgical treatment of epilepsy. Ann Neurol. 1983 Jan;13(1):59-64.
28. Tsai L, Tsuang MT. How can we avoid unnecessary CT scanning for psychiatric patients. J Clin Psychiatry. 1981 Dec;42(12):452-4.
29. Evans NJ. Cranial computerized tomography in clinical psychiatry: 100 consecutive cases. Compr Psychiatry. 1982 Sep-Oct;23(5):445-50.
30. Larson EB, Mack LA, Watts B, Cromwell LD. Computed tomography in patients with psychiatric illnesses: advantage of a "rule-in" approach. Ann Intern Med. 1981 Sep;95(3):360-4.
31. Madsen AL, Karle A, Rubin P, Cortsen M, Andersen HS, Hemmingsen R. Progressive atrophy of the frontal lobes in first-episode schizophrenia: interaction with clinical course and neuroleptic treatment. Acta Psychiatr Scand. 1999 Nov;100(5):367-74.
32. Anderson KE, Starr JM, Lindley RI. Acute psychosis in two elderly patients. Postgrad Med J. 1998 Sep;74(875):569-70.
33. Asselman V, Thienemann F, Pepper DJ, Boulle A, Wilkinson RJ, Meintjes G, et al. Central nervous system disorders after starting antiretroviral therapy in South Africa. AIDS. 2010 Nov 27;24(18):2871-6.
34. Cole G. Intracranial space-occupying masses in mental hospital patients: necropsy study. J Neurol Neurosurg Psychiatry. 1978 Aug;41(8):730-6.
35. Albon E, Tsourapas A, Frew E, Davenport C, Oyebode F, Bayliss S, et al. Structural neuroimaging in psychosis: a systematic review and economic evaluation. Health Technol Assess. 2008 May;12(18):iii-iv, ix-163.
36. Strahl B, Cheung YK, Stuckey SL. Diagnostic yield of computed tomography of the brain in first episode psychosis. J Med Imaging Radiat Oncol. 2010 Oct;54(5):431-4.
37. da Silva JA, Alves A, Talina M, Carreiro S, Guimaraes J, Xavier M. Arachnoid cyst in a patient with psychosis: Case report. Ann Gen Psychiatry. 2007;6:16.
38. Sa'adah MA, Araj GF, Diab SM, Nazzal M. Cryptococcal meningitis and confusional psychosis. A case report and literature review. Trop Geogr Med. 1995;47(5):224-6.

39. Gupta A, El-Hais M, Pansari K, Syed M. An observational study of CT scanning in psychiatric patients. Progress in Neurology and Psychiatry. 2007:24-31.
40. Strachan M. Imbalance between public and private radiological services in the Western Cape of South Africa [Dissertation]. Cape Town: University of Stellenbosch; 2007.
41. National reference price list for radiologists. In: Health Do, editor. Pretoria: Government publishers; 2009.
42. Goulet K, Deschamps B, Evoy F, Trudel JF. Use of brain imaging (computed tomography and magnetic resonance imaging) in first-episode psychosis: review and retrospective study. Can J Psychiatry. 2009 Jul;54(7):493-501.
43. Brenner DJ, Hricak H. Radiation exposure from medical imaging: time to regulate? JAMA. 2010 Jul 14;304(2):208-9.
44. Namasivayam S, Kalra MK, Torres WE, Small WC. Adverse reactions to intravenous iodinated contrast media: a primer for radiologists. Emerg Radiol. 2006 Jul;12(5):210-5.
45. Barrett JF, Keat N. Artifacts in CT: recognition and avoidance. Radiographics. 2004 Nov-Dec;24(6):1679-91.
46. Naidich TP, Solomon S, Leeds NE. Computerized tomography in neurological evaluations. JAMA. 1978 Aug 11;240(6):565-8.
47. Goodstein RK. Guide to CAT scanning in hospital psychiatry. Overview of clinical practice and criteria for use. Gen Hosp Psychiatry. 1985 Oct;7(4):367-76.
48. Rabie JA, Otto S, le Roux AJ. Is computed tomography of the brain necessary in patients with clinically suspected depressed skull fracture and no focal neurological deficit? S Afr J Radiol. 2010;14(2):28-30.
49. Andreasen NC. Brain Imaging: Applications in Psychiatry. Andreasen NC, editor. Washington, DC: American Psychiatric Press Inc; 1989.
50. Ebdrup BH, Lublin H, Akeson P, Glenthoj B. [Patients with first-episode psychosis should not be scanned routinely]. Ugeskr Laeger. 2011 Feb 14;173(7):484-9.
51. Royal Australian and New Zealand College of Psychiatrists clinical practice guidelines for the treatment of schizophrenia and related disorders. Aust N Z J Psychiatry. 2005 Jan-Feb;39(1-2):1-30.
52. Hollister LE, Shah NN. Structural brain scanning in psychiatric patients: a further look. J Clin Psychiatry. 1996 Jun;57(6):241-4.
53. Bradshaw D, Pillay-Van Wyk V, Laubscher R, Nojilana B, Groenewald P, Nannan N, et al. Cause of death statistics for South Africa: Challenges and possibilities for improvement: Medical Reseasrch council, unit Bod;2010.
54. Hinkin CH, Castellon SA, Atkinson JH, Goodkin K. Neuropsychiatric aspects of HIV infection among older adults. J Clin Epidemiol. 2001 Dec;54 Suppl 1:S44-52.
55. Sewell DD. Schizophrenia and HIV. Schizophr Bull. 1996;22(3):465-73.
56. de Ronchi D, Faranca I, Forti P, Ravaglia G, Borderi M, Manfredi R, et al. Development of acute psychotic disorders and HIV-1 infection. Int J Psychiatry Med. 2000;30(2):173-83.
57. Sall L, Salamon E, Allgulander C, Owe-Larsson B. Psychiatric symptoms and disorders in HIV infected mine workers in South Africa. A retrospective descriptive study of acute first admissions. Afr J Psychiatry (Johannesbg). 2009 Aug;12(3):206-12.
58. Owe-Larsson B, Sall L, Salamon E, Allgulander C. HIV infection and psychiatric illness. Afr J Psychiatry (Johannesbg). 2009 May;12(2):115-28.

59. Navia BA, Price RW. The acquired immunodeficiency syndrome dementia complex as the presenting or sole manifestation of human immunodeficiency virus infection. Arch Neurol. 1987 Jan;44(1):65-9.
60. Dolder CR, Patterson TL, Jeste DV. HIV, psychosis and aging: past, present and future. AIDS. 2004 Jan 1;18 Suppl 1:S35-42.
61. Egglestone SI, Turner AJL. Serological diagnosis of syphilis. Commun Dis Public Health. 2000 September;3(3):158-62.
62. Woodroof A, Gleason O. Psychiatric symptoms in a case of intracranial tuberculosis. Psychosomatics. 2002 Jan-Feb;43(1):82-4.
63. LeMay M. Radiologic changes of the aging brain and skull. AJR Am J Roentgenol. 1984 Aug;143(2):383-9.
64. Adewuya AO, Afolabi MO, Ola BA, Ogundele OA, Ajibare AO, Oladipo BF. Psychiatric disorders among the HIV-positive population in Nigeria: a control study. J Psychosom Res. 2007 Aug;63(2):203-6.
65. Fannon D, Tennakoon L, Sumich A, O'Ceallaigh S, Doku V, Chitnis X, et al. Third ventricle enlargement and developmental delay in first-episode psychosis: preliminary findings. Br J Psychiatry. 2000 Oct;177:354-9.
66. Bronen RA, Fulbright RK, Spencer DD, Spencer SS, Kim JH, Lange RC, et al. Refractory epilepsy: comparison of MR imaging, CT, and histopathologic findings in 117 patients. Radiology. 1996 Oct;201(1):97-105.

8. APPENDICES

8.1 DATA COLLECTION SHEET

NO	PT ID	AGE	GENDER	RPR	HIV	CD4	RICP	SOL	Ventricle size	Involution	Location	Calc	Calc Nature	ABN GRADE
			1 = M 2 = F	1 = + 2 = - 3 = N/T	1 = + 2 = - 3 = N/T		0 = no 1 = yes	0 = no 1 = yes	1=normal 2=attenuated 3=enlarged 4=HC 5=Asymmetry 6=NP HC	1=none 2=AGE + 3=AGE -	0 = N/A 1=frontal 2=parietal 3=temporal 4=occipital 5=general 6=N/S 7= L hemi-A 8= R hemi-A	0 = no 1 = yes	1=NCC 2=TB 3=N/S 0=N/A	0=normal 1=A+C0P0 2=A+C+P0 3=A+C+P+
1	1	22	1	2	2		0	0	1	1	0	0	0	0
2	2	17	2	2	2		0	0	1	1	0	0	0	0
3	3	22	1	2	3		0	0	1	1	0	0	0	0
4	5	40	2	3	2		0	0	1	1	0	0	0	0
5	6	22	1	2	3		0	0	1	1	0	0	0	0
6	7	43	2	2	1	510	0	0	1	1	0	0	0	0
7	8	41	2	2	3		0	0	1	1	0	0	0	0
8	9	24	1	2	2		0	0	1	1	0	0	0	0
9	10	48	2	2	2		0	0	1	1	0	0	0	0
10	11	32	2	2	2		0	0	1	1	0	1	1	1
11	12	33	1	2	1	115	0	1	1	1	0	0	0	2
12	13	20	1	3	3		0	0	1	1	0	0	0	0
13	15	51	2	1	2		0	0	1	1	0	0	0	0
14	18	41	1	2	3		0	0	1	3	2	0	0	1
15	19	23	2	2	2		0	0	1	1	0	0	0	0
16	21	36	2	3	3		0	0	1	1	0	0	0	0
17	22	26	2	3	2		0	0	1	1	0	0	0	0
18	23	40	2	2	2		0	0	1	1	0	0	0	0
19	24	42	1	2	2		0	0	1	1	0	0	0	0
20	25	25	1	3	3		0	0	1	1	0	0	0	0
21	26	22	2	2	2		0	0	1	1	0	0	0	0
22	27	27	2	2	2		0	0	1	1	0	0	0	0
23	28	33	1	3	3		0	0	1	1	0	0	0	0
24	29	46	1	2	2		0	0	1	1	0	0	0	0
25	30	45	1	2	3		0	0	1	1	0	0	0	0
26	31	46	1	2	2		0	0	1	1	0	0	0	0
27	32	53	1	2	2		0	0	1	1	0	0	0	0
28	33	49	2	1	2		0	0	1	1	0	1	3	1
29	34	46	2	3	3		0	0	3	1	0	0	0	3
30	35	49	1	3	3		0	0	1	1	0	0	0	0
31	36	23	1	2	2		0	0	1	1	0	0	0	0
32	37	21	2	2	1	231	0	0	1	1	0	0	0	0
33	38	47	2	2	3		0	0	1	1	0	0	0	0
34	40	38	2	2	1	179	0	0	1	3	6	1	3	1
35	41	49	1	2	3		0	0	3	1	0	0	0	1
36	42	16	1	2	3		0	0	1	1	0	0	0	0
37	43	22	2	2	2		0	0	1	1	0	0	0	0
38	44	50	1	2	3		0	0	1	3	7	0	0	1
39	45	42	2	2	2		0	0	1	1	0	0	0	0
40	46	45	1	2	3		0	0	1	1	0	0	0	0
41	47	31	2	2	1	179	0	0	1	1	0	0	0	0
42	48	18	2	2	2		0	0	1	1	0	0	0	0
43	49	19	1	2	2		0	0	1	1	0	0	0	0
44	50	42	2	2	2		0	0	1	1	0	0	0	0
45	51	39	2	2	3		0	0	3	1	0	0	0	1
46	52	32	1	3	3		0	0	1	1	0	0	0	0
47	53	30	2	2	2		0	0	1	1	0	0	0	0
48	54	47	1	2	3		0	0	1	1	0	0	0	0
49	55	47	1	2	3		0	0	1	1	0	0	0	0
50	56	42	2	2	2		0	0	1	1	0	1	3	1
51	57	60	2	2	2		0	0	1	1	0	0	0	0
52	59	25	1	2	3		0	0	1	1	0	1	1	1
53	61	42	1	2	3		0	0	1	1	0	0	0	0
54	62	31	1	2	3		0	0	1	1	0	0	0	0
55	63	23	1	2	3		0	0	1	1	0	0	0	0
56	64	45	2	2	1	230	0	0	1	1	0	0	0	0
57	65	53	2	2	2		0	0	1	1	0	0	0	0
58	66	21	1	2	2		0	0	1	1	0	0	0	0
59	68	47	2	2	1	41	0	0	1	1	0	0	0	0
60	69	40	1	2	3		0	0	1	1	0	0	0	0
61	70	62	1	2	3		0	0	1	1	0	0	0	0
62	71	28	2	3	3		0	0	1	1	0	0	0	0
63	72	45	2	2	3		0	0	1	1	0	0	0	0
64	73	50	1	2	2		0	0	1	1	0	0	0	0
65	74	65	2	2	2		0	0	1	1	0	0	0	0
66	75	64	1	2	2		0	0	1	1	0	0	0	0
67	76	31	1	2	3		0	0	1	1	0	0	0	0
68	77	20	1	2	2		0	0	1	1	0	0	0	0
69	78	41	1	2	3		0	0	1	1	0	0	0	0
70	80	48	1	2	3		0	0	1	1	0	0	0	0
71	81	21	1	2	3		0	0	1	3	6	0	0	1
72	82	22	1	2	1	621	0	0	1	1	0	0	0	0
73	83	20	1	2	2		0	0	1	1	0	0	0	0
74	84	33	2	2	1	109	0	0	1	3	6	1	3	1
75	85	26	2	2	2		0	0	1	1	0	0	0	0
76	88	33	1	2	1	707	0	0	1	1	0	0	0	0
77	89	47	2	1	2		0	0	1	1	0	0	0	0
78	92	25	2	3	3		0	0	1	1	0	0	0	0
79	93	24	2	2	1	264	0	0	1	1	0	0	0	0
80	94	67	2	2	3		0	0	1	2	6	0	0	1
81	95	40	1	2	3		0	0	1	1	0	0	0	0
82	97	22	2	2	2		0	0	1	1	0	0	0	0
83	100	27	1	2	2		0	0	1	3	2	0	0	1
84	101	50	1	2	2		0	0	1	1	0	0	0	0
85	103	53	1	2	2		0	0	1	3	6	0	0	1
86	104	23	2	2	2		0	0	1	1	0	0	0	0
87	109	25	2	2	2		0	0	1	1	0	0	0	0
88	111	25	1	2	2		0	0	1	1	0	0	0	0

N/T = not tested, HC = hydrocephalus, NP HC = normal pressure hydrocephalus, AGE + = age appropriate involution,
AGE - = age inappropriate involution, L hemi-A = L sided hemi-atrophy, R hemi-A = R sided hemi-atrophy, NS = not specified,
N/A = not assessed, NCC = neurocysticercosis, TB = tuberculosis

8.2 ETHICS APPROVAL CLEARANCE CERTIFICATE

UNIVERSITY OF THE WITWATERSRAND, JOHANNESBURG
Division of the Deputy Registrar (Research)

HUMAN RESEARCH ETHICS COMMITTEE (MEDICAL)
R14/49 Dr MJ van Wyk

CLEARANCE CERTIFICATE	**M10215**
PROJECT	Findings in Computed Tomography Brain Scans of Patients Presenting with First Episode Psychosis
INVESTIGATORS	Dr MJ van Wyk.
DEPARTMENT	Diagnostic Radiology Department
DATE CONSIDERED	26/02/2010
DECISION OF THE COMMITTEE*	Approved unconditionally

Unless otherwise specified this ethical clearance is valid for 5 years and may be renewed upon application.

DATE 26/02/2010 **CHAIRPERSON** .....
(Professor PE Cleaton-Jones)

*Guidelines for written 'informed consent' attached where applicable
cc: Supervisor : Prof V Mngomezulu

DECLARATION OF INVESTIGATOR(S)

To be completed in duplicate and **ONE COPY** returned to the Secretary at Room 10004, 10th Floor, Senate House, University.
I/We fully understand the conditions under which I am/we are authorized to carry out the abovementioned research and I/we guarantee to ensure compliance with these conditions. Should any departure to be contemplated from the research procedure as approved I/we undertake to resubmit the protocol to the Committee. **I agree to a completion of a yearly progress report.**

PLEASE QUOTE THE PROTOCOL NUMBER IN ALL ENQUIRIES...