

https://dspace.org/

Variation sexual dimorphism and enlargement of the frontal sinus with age in adult South Africans

Victoria A. Greening; E Hernandez; Carrie S. Mongle; Brendon Billings; V Mngomezulu ...

https://hdl.handle.net/10539/42545
WOS

Downloaded from a DSpace repository. https://dspace.org/

Check for updates

Received: 6 July 2023 | Revised: 3 December 2023 | Accepted: 14 December 2023

DOI: 10.1002/ajpa.24899

RESEARCH ARTICLE

AMERICAN JOURNAL OF BIOLOGICAL ANTHROPOLOGY

WILEY

Variation, sexual dimorphism, and enlargement of the frontal sinus with age in adult South Africans

Victoria A. Greening[1] | Emily Hernandez[1] | Carrie S. Mongle[1,2] | Brendon K. Billings[3] | Victor Mngomezulu[4] | Ian J. Wallace[5] | Frederick E. Grine[1,6]

[1]Department of Anthropology, Stony Brook University, Stony Brook, New York, USA

[2]Turkana Basin Institute, Stony Brook University, Stony Brook, New York, USA

[3]Human Variation and Identification Research Unit, School of Anatomical Sciences, Faculty of Health Sciences, University of the Witwatersrand, Johannesburg, South Africa

[4]Department of Diagnostic Radiology, Charlotte Maxeke Johannesburg Academic Hospital, Johannesburg, South Africa

[5]Department of Anthropology, University of New Mexico, Albuquerque, New Mexico, USA

[6]Department of Anatomical Sciences, School of Medicine, Stony Brook University, Stony Brook, New York, USA

Correspondence
Frederick E. Grine, Department of Anthropology, Stony Brook University, Stony Brook, NY 11794-4364, USA.
Email: frederick.grine@stonybrook.edu

Funding information
Leakey Foundation

Abstract

Objectives: To document frontal sinus volume (FSV) in a sample of sub-Saharan Africans with a view to evaluating claims that such populations exhibit comparatively small sinuses. This study also addresses questions related to sexual dimorphism, incidence of sinus aplasia, and the possibility that FSV continues to increase through adulthood.

Materials and methods: FSV was measured from CT scans of adult crania from the Dart Collection. Sex and age were known for each individual. Linear cranial dimensions were used to compute a geometric mean from which a scaled FSV was computed for each cranium.

Results: FSV does not differ significantly between sexes, but females exhibit a higher incidence of aplasia. There is considerable variation in FSV in this sample, with the average ranking among the higher means reported for other population samples. The incidence of FS aplasia falls within the range of values recorded for other population samples. Although our study is cross-sectional rather than longitudinal, there is strong evidence that FSV continues to increase with age throughout adulthood.

Discussion: The FSV mean of our sample contradicts the notion that sub-Saharan Africans possess small sinuses. In a global context, geography (climate and altitude) does not appear to be related to FSV. The absence of sexual dimorphism in our sample is unexpected, as significant dimorphism has been reported for most other population samples. Our results support other indications that the frontal sinus continues to expand throughout adulthood, especially in females, and that it is likely due to bone resorption.

KEYWORDS
aplasia, ontogeny, osteoporosis, sexual dimorphism

1 | INTRODUCTION

The bones that surround the nasal cavity of the human cranium characteristically possess pneumatic sinuses that develop through reabsorption of the cartilaginous nasal capsule (Butaric, Buck, et al., 2022; Nambiar et al., 1999). In hominins, sinuses occur in the frontal, maxillae, sphenoid and ethmoid; while maxillary and sphenoidal sinuses are present in all hominoids, the frontal and ethmoid sinuses are found only in hominines (Cave & Haines, 1940; Ward & Brown, 1986). Among the paranasal sinuses, the frontal has garnered the most

 © 2024 Wiley Periodicals LLC.

interest in anthropological and forensic contexts (Balzeau et al., 2022; Besana & Rogers, 2010; Butaric, Buck, et al., 2022; Butaric, Richman, & Garvin, 2022; Christensen & Hatch, 2018; Cox et al., 2009; Keir, 2009; Kim et al., 2013; Patil et al., 2012; Quatrehomme et al., 1996; Rae & Koppe, 2004; Tatlisumak et al., 2007; Uthman et al., 2010).

A number of purported structural and physiological functions have been ascribed to the paranasal sinuses (see Márquez, 2008 for a detailed review). In particular, the frontal sinus has been argued to serve as a means by which the cranium is lightened and speech resonance is maximized (e.g., Davis et al., 1996), to provide protection for the brain (e.g., Davis et al., 1996), to act as a nasal defense against invading microorganisms through the production of nitric oxide (Cardell, 2002; Lundberg, 2008; Lundberg et al., 1995), or to assist in the maintenance of internal cranial temperature and to humidify inhaled air (Gannon et al., 1997; Eckert-Mobius, 1933; Negus, 1957).

It has also been hypothesized that the frontal sinus of modern humans is an evolutionary remnant—in the sense of the Spandrels of Gould and Lewontin (1979)—that serves no function at all (Keir, 2009; Negus, 1957). Balzeau et al. (2022) have suggested that while the large supraorbital tori of early hominin species may have allowed the frontal sinus to develop isometrically with endocranial size, pneumatization is constrained in recent *Homo sapiens* owing to the greatly reduced size of these frontal superstructures. However, Butaric, Buck, et al. (2022) have argued that although such features likely influence taxonomic differences in frontal sinus expansion, they are likely not the only factor involved.

1.1 | Climate and geography

Among the various hypotheses that have been advanced in relation to the function(s) of the frontal sinus, those that have seemingly received the most attention pertain to climate and geography (e.g., Asirdizer et al., 2017; Balzeau et al., 2022; Butaric, 2013; Butaric et al., 2020; Hanson & Owsley, 1980; Koertvelyessy, 1972; Lynnerup et al., 1999; Noback et al., 2016; Selcuk et al., 2015; Tastemur et al., 2022). While the majority of these aforementioned studies have reported a correlation between frontal sinus size and climate, some (e.g. Butaric et al., 2020; Hanson & Owsley, 1980; Koertvelyessy, 1972; Noback et al., 2016) have observed it to be smaller or to be more frequently absent in individuals that inhabit cold-climates (e.g., Greenlanders and Alaskan Inuit). Asirdizer et al. (2017), by contrast, observed frontal sinus volumes to be larger in a population living in a colder climate and at higher altitude than one in a warmer climate and lower altitude.

On the other hand, Selcuk et al. (2015) found no significant difference in frontal sinus volumes in relation to either climate or altitude in two Turkish populations, and Balzeau et al. (2022), who examined frontal sinus size in a number of recent human samples with a worldwide distribution, concluded that while there are significant size differences between different geographic regions, these differences are not related to climate. Butaric, Buck, et al. (2022) reached a similar conclusion, that clear climatic adaptive trends are not apparent among recent human populations.

At the same time, however, despite the high degree of variability in frontal sinus size that tends to characterize most recent human populations (Balzeau et al., 2022), there are some notable trends that seem to differentiate populations from different geographic regions. For example, Butaric, Buck, et al. (2022) observed that sub-Saharan Africans tend, on average, to exhibit smaller frontal sinuses than other populations. However, the number of sub-Saharan populations for which frontal sinus volumes have been recorded is rather limited by comparison to other continental regions. Thus, Butaric, Buck, et al. (2022): table 11.4 were able to list only three studies of sub-Saharan populations—two on West Africans and one restricted to South African Nguni-speakers (Zulu)—in comparison to the 34 samples of populations from the Middle East, Europe, South and East Asia and South and Central America for which volumetric determinations from CT scans have been published.

1.2 | Sexual dimorphism

Sexual dimorphism in body size may serve strategic evolutionary fitness goals, where intrasexual competition puts reproductive pressure on males to be larger than females (Kleisner et al., 2021). Sexual dimorphism affects craniofacial size and morphology in modern humans (e.g., de Villiers, 1968a; Franklin et al., 2005, 2013; İşcan et al., 1995; Kimmerle et al., 2008; Krüger et al., 2015; Steyn & İşcan, 1998; Toneva et al., 2022; Uytterschaut, 1986; Wood & Lynch, 1996), although it is clear that differences between the sexes may be population-specific for various traits (e.g., Milella et al., 2021). It is, therefore, unsurprising that sexual dimorphism in frontal sinus size has been extensively investigated (e.g., Abate et al., 2022; Ekşi et al., 2021; Zulkiflee et al., 2022 and references therein). Most studies contend that significant sexual dimorphism in frontal sinus volume is prevalent (e.g., Butaric, Buck, et al., 2022; Čechová et al., 2019; Shireen et al., 2019; Tatlisumak et al., 2017; Uthman et al., 2010; Vance, 2021), although other studies have reported an absence of significant dimorphism (e.g., Goyal et al., 2013; Nethan et al., 2018; Robles et al., 2020). It is possible that high inter-individual variation of the frontal sinus may result in a lower degree of average sexual dimorphism. Overall, sexual dimorphism of the frontal sinus may differ by population and different methods of its assessment may influence results. In considering sexually dimorphic morphological features that may relate to the frontal sinus, Zollikofer et al. (2008) suggested that a prominent glabella, in conjunction with a well-defined supra-glabellar depression, is often associated with small and/or absent frontal sinuses.

While sexual dimorphism in frontal sinus volume has been rather extensively investigated in Middle Eastern, European, and East Asian population samples, it has yet to be reported for any sub-Saharan African sample.

26927691, 2024, 4, Downloaded from https://onlinelibrary.wiley.com/doi/10.1002/ajpa.24899 by University Of Witwatersrand, Wiley Online Library on [20/10/2024]. See the Terms and Conditions (https://onlinelibrary.wiley.com/terms-and-conditions) on Wiley Online Library for rules of use; OA articles are governed by the applicable Creative Commons License

1.3 | Frontal sinus growth

The frontal sinus develops from ethmoidal cells at about 2 years of age, becoming evident via plain film radiography typically at about 5 to 8 years of age (Dolan, 1982; Duque & Casiano, 2005; Tatlisumak et al., 2007). Frontal sinus enlargement typically displays an adolescent growth spurt (e.g., Gagliardi et al., 2004), but there is disagreement over the age at which it ceases growth and how this may differ among males and females.

Overall, most studies assert that frontal sinus pneumatization is largely completed at about 18–20 years of age (Brown et al., 1984; Fatu et al., 2006; Rennie et al., 2017; Sardi et al., 2018; Spaeth et al., 1997; Yun et al., 2011), but it may occur earlier in females (Brown et al., 1984; Gagliardi et al., 2004; Sardi et al., 2018). Prossinger (2001) predicted adult size to be attained somewhat later at 23.6 years in males and 19 years in females on the basis of a sigmoid growth function developed for a sample of 3 to 11-year-old children. Similarly, Karakas and Kavakli (2005) reported an increase in volume in individuals over the age of 25, and frontal sinus enlargement has been documented into the third or fourth decade (e.g., McLaughlin et al., 2001; Tatlisumak et al., 2008). Indeed, Tatlisumak et al. (2016) have reported an increase in size into the sixth decade in females, although they observed a decrease from about the fourth decade in males. It is, however, difficult to envision the mechanism by which the frontal sinus would shrink in the absence of abnormal adult bone growth such as might be evident in Paget's Disease, melorheostosis, or ossific tumors.

It is important to note that all the age-based studies conducted to date, save for those by Brown et al. (1984) and Gagliardi et al. (2004), have been conducted on cross-sectional samples rather than longitudinal series. Both Brown et al. (1984) and Gagliardi et al. (2004) measured lateral flat plane cephalograms, and the ontogenetic series examined did not extend beyond the end of ossific fusion of the wrist (Gagliardi et al., 2004) or 24 years of age (Brown et al., 1984). As such, as noted by Butaric, Campbell, et al. (2022), the actual specific growth patterns exhibited by individuals remain poorly known. Only the longitudinal study of Brown et al. (1984) examined the development of the frontal sinus beyond the end of adolescent growth. Brown et al. (1984) observed that only seven out of 28 (i.e., 25%) individuals over the age of 24 showed any increase in size, and this was less than three millimeters.

Bone fragility, which results from a reduction in bone mass and density (Tranquilli Leali et al., 2009), has been cited as a potential cause of sinus enlargement among elderly individuals (Fatu et al., 2006; Landsberg & Friedman, 2001; Nambiar et al., 1999; Shapiro & Schorr, 1980). However, it has also been argued that age-related degenerative processes decrease frontal sinus volume instead (Akhlaghi et al., 2016).

1.4 | Assessment of frontal sinus volume—Some caveats

The size of the frontal sinus has been assessed by obtaining both linear and volumetric measurements utilizing different techniques. Either flat-plane AP and/or ML radiographs, or CT scans are most commonly employed to determine size. Comparability of data among different studies depends heavily upon the technique that each study employed.

A number of studies have recorded linear dimensions from flat-plane radiographs (e.g., Buckland-Wright, 1970; Hanson & Owsley, 1980; Nethan et al., 2018; Rubiera-Bullen et al., 2010; Ruiz & Wafae, 2004; Wolfowitz, 1974), and from CT scans (e.g., Akhlaghi et al., 2016; Asirdizer et al., 2017; Aslier et al., 2016; Pondé et al., 2003; Tatlisumak et al., 2008, 2016; Uthman et al., 2010; Yun et al., 2011).

Linear variables may be determined by employing either "anatomical" or "projected" dimensions of the sinus cavities (Butaric, Buck, et al., 2022), and while the former more accurately reflect the actual size of the sinus, almost all studies have utilized 'projected' values. Very few (e.g., Motawei et al., 2016) have used 'anatomical' values. Volumes may be estimated through the application of standard geometric formulae to linear dimensions (e.g., Asirdizer et al., 2017; Emirzeoglu et al., 2007; Karakas & Kavakli, 2005; Tatlisumak et al., 2016).

Sinus volume may also be estimated using centroid size from CT scans (e.g., Maddux & Butaric, 2017) or by using their ellipsoid diameters (e.g., Adibelli et al., 2011), although both methods will undoubtedly overestimate the actual volume (Adibelli et al., 2011). Sinus volume may be measured more accurately by reconstructing 3D models through CT scan segmentation (e.g., Butaric, 2015; Butaric, Buck, et al., 2022).

Although CT scan segmentation will provide the most accurate determination of sinus volume, the determination of the inferior boundary of the frontal sinus varies considerably even among studies that have used this methodology. Because the frontal sinus is pneumatized initially as an upwards expansion of the ethmoidal air cells, they may be continuous and difficult to delineate from one another. For example, Yun et al. (2011, p. 463) observed that in a number of specimens in their study "the inferior border of the frontal sinus adjacent to the ethmoid sinus was not distinct." This is clearly illustrated by Rennie et al. (2017, Figure 1) in their 3D reconstruction of the paranasal sinuses. Here the frontal and ethmoidal are broadly continuous, and are demarcated from one another by a horizontal line the level of which is wholly undefined by any ossific landmark. Because the delineation of the frontal from the ethmoidal sinuses may not always be straightforward, a variety of landmarks have been employed to define the inferior limit of the frontal sinus. In some studies (e.g., Hanson & Owsley, 1980; Kim et al., 2013; Koertvelyessy, 1972), a "horizontal" line tangent to the upper margins of the orbits has been used as the "baseline," while others (e.g., Rubiera-Bullen et al., 2010; Wolfowitz, 1974; Yun et al., 2011) have employed the nasofrontal suture to define this boundary. Aslier et al. (2016, p. 925) employed the lower border of the frontal ostium, which they defined as "the narrowest cross-sectional area over [the inferior section of the] frontal recess." This point is located in the medial aspect of the frontal sinus floor and is continuous with the frontal sinus infundibulum, which may be situated below the level

26927691, 2024, 4, Downloaded from https://onlinelibrary.wiley.com/doi/10.1002/ajpa.24899 by University Of Witwatersrand, Wiley Online Library on [20/10/2024]. See the Terms and Conditions (https://onlinelibrary.wiley.com/terms-and-conditions) on Wiley Online Library for rules of use; OA articles are governed by the applicable Creative Commons License

of the cribriform plate, and therefore difficult to define. Butaric, Buck, et al. (2022) employed the level of the infundibulum to define the inferior extent of the frontal sinus. Noback et al. (2016: 2) defined the lower border of the frontal sinus "at the level of the frontal process," although they failed to define what the 'frontal process' actually refers to.

The inferior boundary of the frontal sinus has also been identified as coincident with the junction of the crista galli and the cribriform plate of the ethmoid (e.g., Nethan et al., 2018; Ruiz & Wafae, 2004; Schuller, 1943). This seems to be perhaps the most reasonable anatomical landmark in that it is not only easily identified radiographically, but the cribriform plate forms the roof of the ethmoid bone. As such, any pneumatic space superior to it is reasonably identified as the frontal sinus.

Clearly, the use of these different landmarks by which to determine the lower border of the frontal sinus will impact the resultant measurement of its size. For example, the use of the superior margin of the orbit, which is situated well above the level of the cribriform plate, will result in the loss of any of the frontal sinus that may exist in the interorbital process of the frontal bone. This serves as a caveat on the limitations of comparisons among results from various studies in which different definitions of the inferior border of the frontal sinus have been employed. Unfortunately, a significant number of studies have failed to specify the method that was used to determine the frontal from the ethmoidal sinus. Indeed, among the 21 studies listed by Butaric, Buck, et al. (2022: Table 11.4) that reported frontal sinus volumes as determined from CT scans, only four (Aslier et al., 2016; Kim et al., 2013; Noback et al., 2016; Yun et al., 2011) provided information on the method. The data from these studies must be treated with caution when comparing reported volumes.

Another potential limitation to the comparison of frontal sinus volumes that have been recorded for different population samples arises from the variation in overall cranial size that may be evident between populations from different parts of the globe. For example, Matsumura et al. (2022) assessed regional diversity in cranial form based on skulls from 148 ethnic groups worldwide and observed that the greatest variation detected was in overall size, with the second largest variation being in the length/breadth proportion of the neurocranium. This same caveat pertains to the examination of sexual dimorphism in frontal sinus size, since male and female crania tend to be dimorphic in overall size (e.g., Gonzalez et al., 2011; Toneva et al., 2022) in conjunction with differences in overall body size.

Frontal sinus size is most often treated as an absolute value. Very few studies have attempted to scale it against cranial size, and among those that have, it is often scaled against a single cranial measurement, such as the distance between the lateral most points on the zygomaticofrontal sutures (i.e., frontomolare temporale; Rae et al., 2011), between the two frontomolare (e.g., Noback et al., 2016), or between glabella and frontomolare temporale (e.g., Butaric et al., 2020; Butaric, Buck, et al., 2022). While this may provide the only scaling factor that is available for damaged fossils, scaling via a single linear measurement is not ideal (Buck et al., 2019; Rae & Koppe, 2000).

1.5 | Purpose of this study

In this study, we assess the notion that sub-Saharan Africans possess small frontal sinuses in comparison to other globally distributed populations (e.g., Butaric, Buck, et al., 2022; Rennie et al., 2017). As noted above, while volumetric data have been recorded from CT scans for numerous ($n = 34$) samples of Middle Eastern, European, Asian and South American populations, we examine a population sample of black South Africans to add to the meager number of indigenous sub-Saharan samples that are currently available ($n = 3$). Data from this study will also be used to investigate questions regarding the expression of sexual dimorphism in frontal sinus volume. We also provide cross-sectional age-related data to address the question of whether the frontal sinus continues to expand in size into adulthood.

2 | MATERIALS

2.1 | The indigenous black South African population sample

The present study is based on an initial sample of 161 crania from cadaveric skeletons in the Raymond A. Dart Collection, School of Anatomical Sciences, Faculty of Health Sciences, University of the Witwatersrand Medical School, Johannesburg, South Africa. The sex, year of death, and linguistic ("tribal") identity are known for every individual comprising this sample (Dayal et al., 2009). All crania were from adult individuals (i.e., ≥18 years) and free of any obvious pathologies. While it is probable that the actual ontogenetic age was known for a good number of individuals, this is likely to have been estimated for at least some. We employed actual/estimated ontogenetic age at death to ensure that our sample was not biased toward aged adults.

The sample is comprised by individuals who are speakers of the "S" group Bantu languages. In South Africa, this is composed of two principal branches, the Sotho-Tswana (Sesotho and Setswana) (S (0) 0.30) and the Zunda-Nguni (isiXhosa and isiZulu) (S (0) 0.40) (Bailey, 1995; Guthrie, 1967–1971; Maho, 2009). Sesotho and Setswana speaking individuals are represented in roughly equal numbers, constituting some 38% of the entire sample, whereas isiXhosa and isiZulu-speaking individuals are considerably more abundant, forming 62% of the sample. These proportions are roughly in keeping with their current embodiment in South Africa, where the Sotho-Tswana represent about 16% and the Zunda-Nguni nearly 39% of the black population at large (South African Census 2011). These South African individuals are closely related genetically (Choudhury et al., 2017; González-Santos et al., 2015; Henn et al., 2011; Schuster et al., 2010). Although there is some genetic divergence among Bantu-speakers across sub-Saharan Africa due to differential regional gene flow and founder effects, a common majority western Africa ancestry links most of these populations (González-Santos et al., 2015).

26927691, 2024, 4, Downloaded from https://onlinelibrary.wiley.com/doi/10.1002/ajpa.24899 by University Of Witwatersrand, Wiley Online Library on [20/10/2024]. See the Terms and Conditions (https://onlinelibrary.wiley.com/terms-and-conditions) on Wiley Online Library for rules of use; OA articles are governed by the applicable Creative Commons License

2.2 | Excluded crania—The final sample

In the vast majority of crania examined, the calotte had been removed from the base using a narrow blade electric bone saw during anatomical dissections at the School of Anatomical Sciences, University of the Witwatersrand. However, in only two (2) instances did this compromise our ability to accurately reconstruct the frontal sinus.

Following Butaric et al. (2020); Butaric, Buck, et al. (2022) individuals with total (i.e., bilateral) frontal sinus aplasia were excluded from the sample-mean calculation of frontal sinus volume. This appears to be a standard procedure adopted by others, since inclusion of crania with aplasia would entail including data points of "0.00 mL." Three (3) crania in our sample exhibited unilateral aplasia but, because they possessed a frontal sinus, they were included in the calculation of the sample statistics on volume. In the current sample, seven (7) individuals (one male and six females) were excluded from the initial sample owing to bilateral frontal sinus aplasia. However, we appraise the incidence of aplasia in this sample in a comparative context inasmuch as it is a relevant factor when considering the variability of frontal sinus expression in any population.

Finally, there is some evidence that a complete persistent metopic suture affects the presence and/or size of a frontal sinus (Guerram et al., 2014; Nikolova et al., 2016, 2018) Despite the claim by Bilgin et al. (2013) that no reasonable explanation has been provided for this association, it is perhaps a reasonable expectation insofar as a complete suture extending from nasion to bregma will result in a wide separation of the left and right pneumatic spaces. On the other hand, while the suture itself should theoretically not affect the superior expansion of either sinus, there may be an indirect relationship between a persistent metopic suture and sinus size if the mechanisms that result in persistent metopism also affect the development of the frontal sinuses (Nikolova et al., 2019). Regardless, and in light of the evidence published to date, we excluded two (2) individuals (both female) who exhibited persistent full metopism from the sample.

The exclusion of the aforementioned individuals ($n = 11$) from the initial sample of 161 crania, resulted in a final sample of 150 crania from which the frontal sinus volumes were measured. The sample is roughly evenly divided between male ($n = 82$) and female ($n = 68$) individuals (Table 1). These individuals represent seven ontogenetic groups based on age at time of death: (1) 18–30 years, (2) 31–40 years, (3) 41–50 years, (4) 51–60 years, (5) 61–70 years, (6) 71–80 years, and (7) 81–90 years. The sample evinces no noticeable ontogenetic age bias other than the expected small numbers of very elderly individuals.

TABLE 1 The ontogenetic age distribution of the South African sample for which the volume of the frontal sinus was measured.

Age bin	Female	Male
18–30	14	14
31–40	12	17
41–50	13	13
51–60	12	10
61–70	12	12
71–80	5	14
81–90	0	2
TOTAL	68	82

3 | METHODS

Each skeleton was CT scanned in a Philips Brilliance 16P in the Department of Diagnostic Radiology, Charlotte Maxeke Johannesburg Academic Hospital, Johannesburg. The cranium was positioned in the horizontal plane on a Styrofoam block and scanned coronally from occipital to frontal. Scanner settings employed were 140 kVp, with a tube current of 30 mA. Slice thickness was 0.8 mm with a reconstruction increment of 0.5 mm. Images were reconstructed using the "Sharp" kernel algorithm.

3.1 | Frontal sinus volume determination

The stacked CT scan images of the crania were manually segmented by two of us (VG and EH) in Avizo 2021.1 to measure the absolute volume of the frontal sinus (A_{FSV}). Image segmentation was accomplished by filling in the empty space of the sinus void, the borders of which were clearly defined on each slice. The inferior border of the frontal sinus was defined as the horizontal plane coincident with the top of the cribriform plate of the ethmoid as defined by the crista galli. Intra- and interobserver error rates were assessed through the re-segmentation and measurement of the A_{FSV} for 5 crania by both researchers.

A specimen from our current sample in which the segmented frontal sinus has been embedded within the 'ghosted' cranium is shown in Figure 1. This serves to illustrate that the frontal sinus commonly extends below the level of the supraorbital margins. It also demonstrates the absence of any demonstrable effect that the saw cut through the neurocranium had on the reconstruction of the frontal sinus.

3.2 | The scaling factor

The stacked CT scan images of each cranium were visualized as an isosurface rendering in Aviso 2021.1. The rendering was manipulated to produce direct lateral, anterior (facial) and superior views. Four linear measurements were recorded for each cranium using a 2D measurement tool in Avizo 2021.1: (1) Maximum cranial length (MCL) between glabella and opisthocranion was measured from the lateral view, (2) maximum cranial breadth (MCB) between the left and right euyria was measured from the superior view, (3) frontal chord length (FCL) between glabella and bregma was measured from the superior view, and (4) minimum frontal breadth (MFB) from left frontotemporale to right frontotemporale was measured from the anterior view

26927691, 2024, 4, Downloaded from https://onlinelibrary.wiley.com/doi/10.1002/ajpa.24899 by University Of Witwatersrand, Wiley Online Library on [20/10/2024]. See the Terms and Conditions (https://onlinelibrary.wiley.com/terms-and-conditions) on Wiley Online Library for rules of use; OA articles are governed by the applicable Creative Commons License

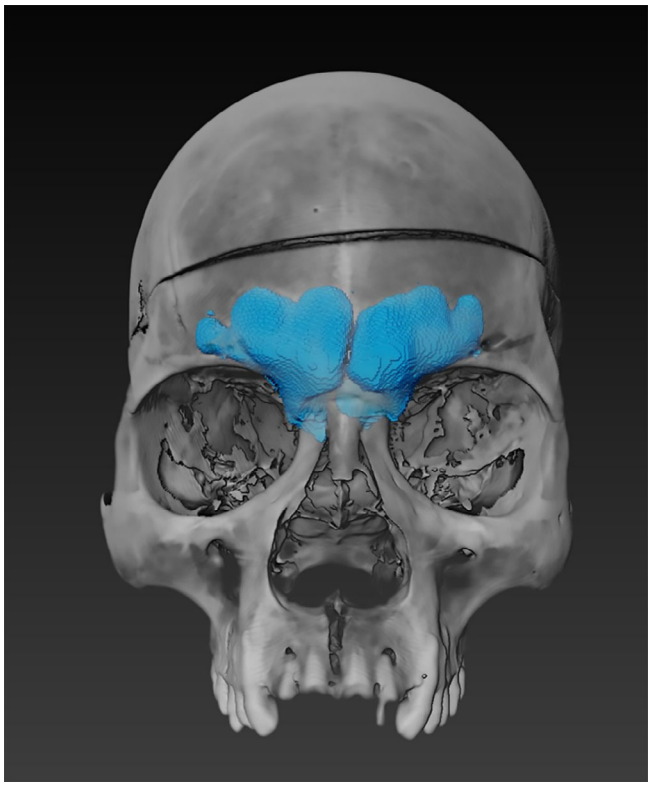

FIGURE 1 The segmented frontal sinus (blue) in a "ghosted" surface volume rendering of a cranium illustrates that the inferior margin of the sinus, as determined by the cribriform plate, extends below the supraorbital margin.

(Figure 2). These four measurements provide a picture of the overall size of the cranium with special reference to the breadth and length of the frontal bone.

These four measurements were used to compute the geometric mean (GM) (Jungers et al., 1995) of cranial size according to the formula:

$$GM = \sqrt[4]{MFB * MCL * FCL * MCB}.$$

The GM was used to scale the absolute frontal sinus volume (A_{FSV}) by dividing the cube root of the A_{FSV} by the GM according to the formula:

$$S_{FSV} = \frac{\sqrt[3]{Volume}}{GM}.$$

Thus, for each cranium we obtained an absolute frontal sinus volume (A_{FSV}) as well as a scaled frontal sinus volume (S_{FSV}).

3.3 | Data analysis

All analyses were completed using R v4.1.3 (R Core Team, 2014). Two-sample t-tests were used to examine differences in the GM, the AFSV and SFSV values between sexes. The possible relationship between ontogenetic age and frontal sinus volume was evaluated using regression models to better appreciate what effect increasing age has on the GM, the A_{FSV} and S_{FSV} values in this sample. Additionally, the A_{FSV} values of the male, female and combined sex series were compared to those published for other population samples where A_{FSV} values were determined from segmentation of CT scans.

The current data on A_{FSV} were tested for normality of distribution using a Shapiro–Wilk test. The results ($W = 0.989$, $p = 0.29$) indicate that the distribution of the A_{FSV} values for the South African sample does not differ significantly from a normal distribution.

The extent of sample variability in relation to the sample mean for each measured variable was expressed as the coefficient of variation (CV). This was calculated according to the standard formula CV = SD / sample mean x 100 (Sokal & Rohlf, 1995). Although the use of the CV to inform the degree of phenotypic plasticity of quantitative traits has been questioned by Pélabon et al. (2020), the dimensional scale of the frontal sinus is the same order of magnitude in the current and all other human populations, which permits its use for meaningful comparisons among studies (Lande, 1977).

4 | RESULTS

4.1 | Intra- and interobserver error rates

To examine inter-observer error, a two-sample t-test between the measured volumes collected by each researcher (10 crania total) revealed a difference that is not statistically significant ($p = 0.98$). The percentage difference between the absolute scan volumes computed by the two observers (interobserver error rate) was 3.1%. Intra-observer error was assessed by each observer remeasuring their own scans for five crania. The percentage differences among scans recorded by each observer (intra-observer error rate) were 2.25% and 2.29%. The differences between the intra-observer error rates for the two observers were not statistically significant (p-values of 0.91 and 0.98 respectively). As such, we felt confident in combining the metrical data recorded by the two observers.

4.2 | Geometric mean

The values obtained for the four cranial variables that constitute the GM are recorded in Table 2. As expected, the male means are larger than those for females, and the differences are statistically significant in all four instances. The means obtained by us from surface volume renderings of the crania closely match those recorded by de Villiers (1968b) directly with calipers on crania from a substantially larger series of specimens from the same collection. The only exception to this pertains to the frontal chord; the values reported by de Villiers (1968b) are for the chord as measured between nasion and bregma, as defined by the Biometric School (S'2) (Pearson & Davin, 1924) and by Martin and Saller (1957); Bräuer (1988) [M29]. This difference is, of course, understandable, since nasion is generally further distant than glabella from bregma.

26927691, 2024, 4, Downloaded from https://onlinelibrary.wiley.com/doi/10.1002/ajpa.24899 by University Of Witwatersrand, Wiley Online Library on [20/10/2024]. See the Terms and Conditions (https://onlinelibrary.wiley.com/terms-and-conditions) on Wiley Online Library for rules of use; OA articles are governed by the applicable Creative Commons License

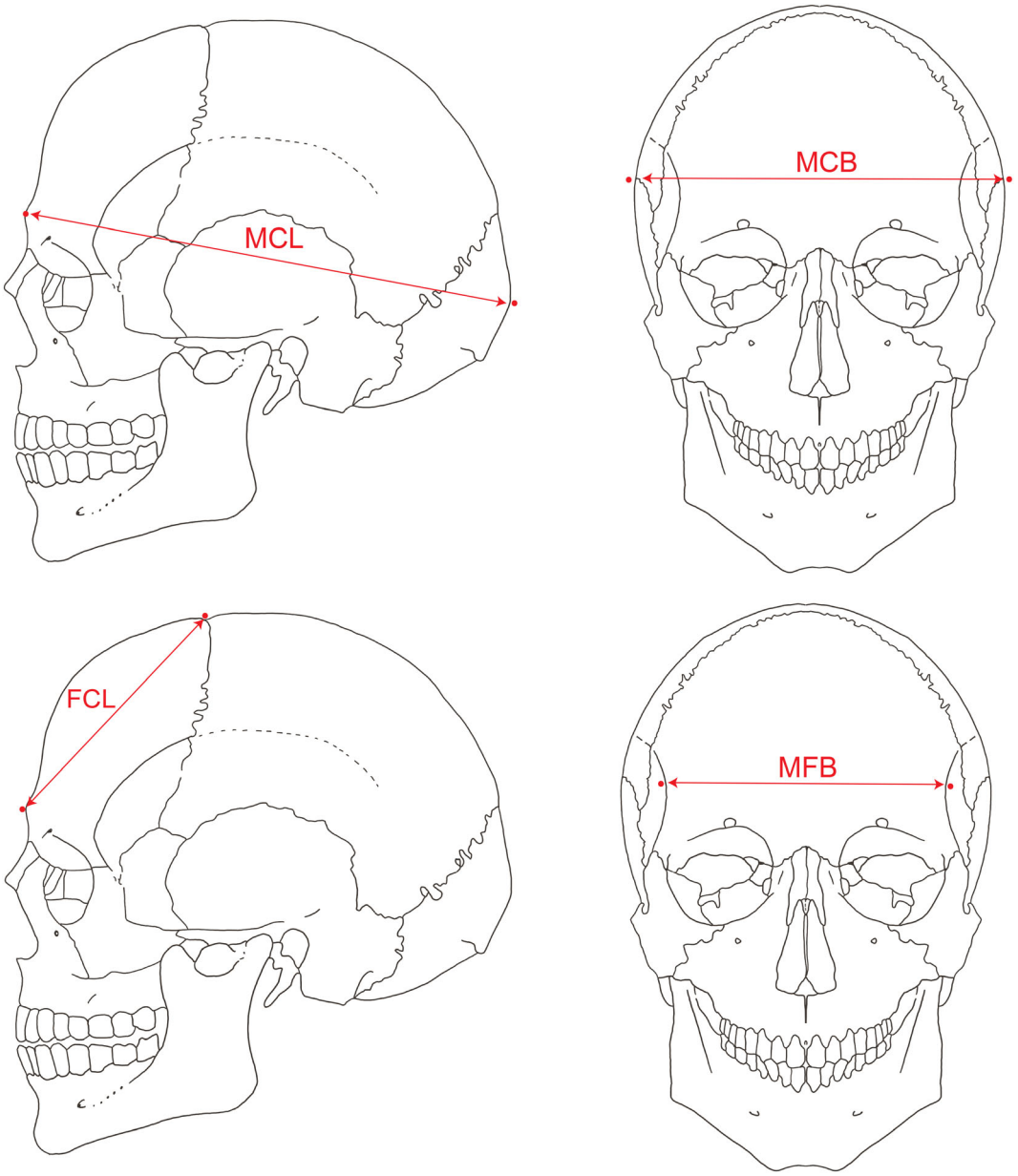

FIGURE 2 The four linear measurements employed in the calculation of the geometric mean of cranial size. FCL, frontal chord length; MCB, maximum cranial breadth; MCL, maximum cranial length; MFB, minimum frontal breadth.

As might be expected from the foregoing, the male and female GM means differ significantly ($t = 4.38$; $p < 0.01$). Moreover, the positive relationship between the GM and individual ontogenetic age is statistically significant for females ($t = 3.61$; $p = 0.001$). Although this relationship in males is not statistically significant ($t = 0.95$; $p = 0.35$), it is statistically significant for the combined sex sample ($t = 3.26$; $p = 0.001$) (Figure 3). Thus, older individuals tend to possess larger crania in this sample.

4.3 | Frontal sinus aplasia

The incidence of complete, bilateral frontal sinus aplasia in the current South African sample is recorded in Table 3. While not terribly common, it affects a notably higher proportion of females (8.1%) than males (1.2%). The overall incidence in this population sample is approximately 5%. As expected, there is no relationship between aplasia and ontogenetic age.

4.4 | Absolute volume of the frontal sinus (A_{FSV})

The A_{FSV} values obtained for the present sample are recorded in Table 4. There is no statistically significant difference between the male and female means ($t = 1.73$; $p = 0.09$). While the female sample exhibits a statistically significant relationship between age and A_{FSV} ($t = 2.99$; $p < 0.01$) (Figure 4a), there is no such relationship among males ($t = -0.06$; $p = 0.95$). However, the combined sex sample

26927691, 2024, 4, Downloaded from https://onlinelibrary.wiley.com/doi/10.1002/ajpa.24899 by University Of Witwatersrand, Wiley Online Library on [20/10/2024]. See the Terms and Conditions (https://onlinelibrary.wiley.com/terms-and-conditions) on Wiley Online Library for rules of use; OA articles are governed by the applicable Creative Commons License

TABLE 2 Linear variables used to calculate the geometric means for the South African sample.

	N	Mean	SD	Obs. Range
Male				
Maximum cranial length	82	187.8	5.81	167–192
	571*	186.3		
Maximum cranial breadth	82	132.4	5.91	119–149
	560*	134.2		
Frontal chord	82	107.7	4.98	95–118
	559*	113.5		
Minimum frontal breadth	82	97.2	4.34	86–106
	580*	97.7		
Female				
Maximum cranial length	68	182.0	6.89	167–202
	150*	180.8		
Maximum cranial breadth	68	130.2	4.71	118–141
	150*	132.2		
Frontal chord	68	105.2	4.75	96–115
	148*	110.7		
Minimum frontal breadth	68	95.5	4.65	85–109
	159*	94.0		
Combined sex				
Maximum cranial length	150	185.2	6.93	167–202
Maximum cranial breadth	150	131.4	5.49	118–149
Frontal chord	150	106.6	5.02	95–118
Minimum frontal breadth	150	96.5	4.58	85–109

Note: The t-test and probability values for the male vs. female comparisons for the following measurements are: Maximum Cranial Length $t = 5.59$; $p < 0.0001$; Maximum Cranial Breadth $t = 2.48$; $p = 0.0141$; Frontal Chord $t = 3.13$; $p = 0.0021$; Minimum Frontal Breadth $t = 2.31$; $p = 0.0222$.
*The values indicated with an asterisk are those recorded by de Villiers (1968b). Note that the frontal chord measured by de Villiers (1968a) extended from nasion to bregma rather than from glabella to bregma as in our series. Hence it has a somewhat larger value.

reveals a marginally significant relationship between age and an increase in A_{FSV} ($t = 1.98$; $p = 0.05$) (Figure 4b).

4.5 | Scaled volume of the frontal sinus (S_{FSV})

The S_{FSV} values recorded for the current sample are reported in Table 4. As with the absolute volumes, there is no statistically significant difference between the scaled means of males and females ($t = -1.3$; $p = 0.20$). As was the case for the absolute volumes, the female sample exhibits a statistically significant relationship between age and S_{FSV} ($t = 2.6$; $p = 0.01$) (Figure 4c), there is no such relationship among males ($t = 0.11$; $p = 0.91$). Unlike the case for the absolute volumes, however, there is no significant relationship between age and S_{FSV} with regard to the combined sex sample ($t = 1.7$; $p = 0.09$) (Figure 4d).

5 | DISCUSSION

The present study sought to address several issues related to the variation in the frontal sinus volume among individuals in a population of Bantu-speaking South Africans. These pertain to the expression of sexual dimorphism, the question of the possible increase in frontal sinus volume into adulthood, and the size and incidence of aplasia of the frontal sinus in a sub-Saharan African population in relation to other global population samples.

5.1 | Sexual dimorphism

Sexual dimorphism affects craniofacial size and morphology among black South Africans (de Villiers, 1968a, 1968b; Franklin et al., 2005; Krüger et al., 2015), as attested to by the significant differences in the linear cranial variables and the GM of those variables recorded here. With reference to the size of the frontal sinus, the majority of studies have reported significant sexual dimorphism for numerous population samples (e.g., Abate et al., 2022; Butaric, Buck, et al., 2022; Čechová et al., 2019; Ekşi et al., 2021; Shireen et al., 2019; Tatlisumak et al., 2017; Uthman et al., 2010; Vance, 2021; Zulkiflee et al., 2022), although the absence of significant dimorphism has been reported in some studies of populations from Korea (Yun et al., 2011) and India (Goyal et al., 2013; Nethan et al., 2018), and in a study of very small sample sizes ($n = 10$ individuals each) of white, black and Chinese inhabitants of the United Kingdom (Robles et al., 2020).

In the South African sample investigated here, there is an absence of significant differences between males and females in both the absolute (A_{FSV}) and scaled (S_{FSV}) volumes, despite the presence of a significant difference in overall cranial (and especially frontal bone) size. It might be surmised that this could be owing to high levels of individual variation in frontal sinus size that characterize this sample, with CVs for males and females of 73.5% and 100.8% respectively. Table 5 records the CVs for other population samples in which the frontal sinus volume was measured from CT scan segmentation (of either dried crania or living patients), and for which separate male and female sample statistics were recorded. As such, these data are among the most comparable to our own. The only population sample reported to date in which there is no significant sexual dimorphism in frontal sinus size (i.e., the Korean sample of Yun et al., 2011) has a male CV of over 100%. However, the Korean sample published by Kim et al. (2013) that presents significant sexual dimorphism has a female CV of 107.3%. Indeed, all of the samples that evince significant sexual dimorphism are characterized by high CVs.

5.2 | Ontogenetic age and frontal sinus development

Frontal sinus enlargement typically displays an adolescent growth spurt (e.g., Gagliardi et al., 2004), but there is disagreement over how

26927691, 2024, 4, Downloaded from https://onlinelibrary.wiley.com/doi/10.1002/ajpa.24899 by University Of Witwatersrand, Wiley Online Library on [20/10/2024]. See the Terms and Conditions (https://onlinelibrary.wiley.com/terms-and-conditions) on Wiley Online Library for rules of use; OA articles are governed by the applicable Creative Commons License

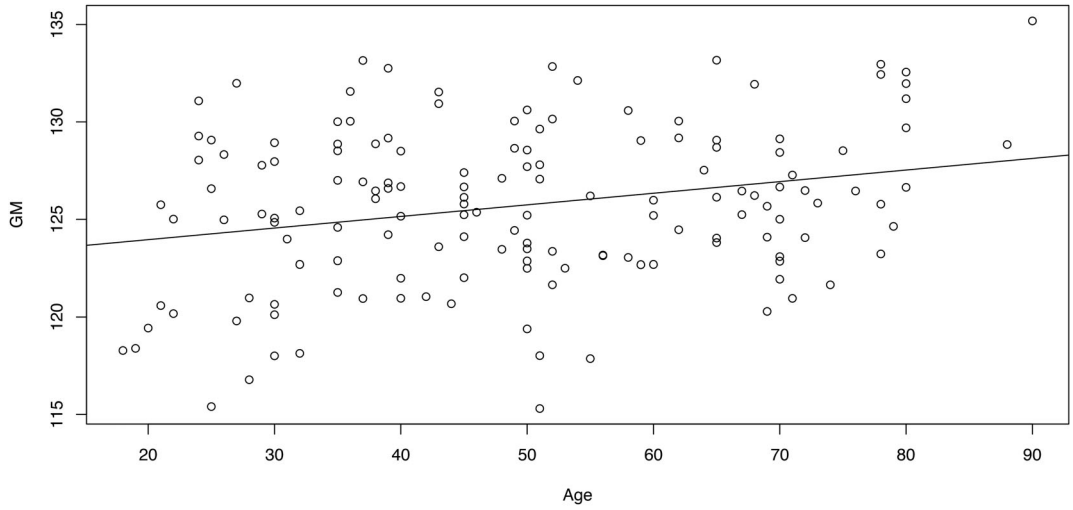

FIGURE 3 The geometric mean (GM) of the combined sex South African cranial sample in relation to ontogenetic age (in years). Generalized least squares $r^2 = 0.07$; adjusted GLS $r^2 = 0.06$).

TABLE 3 Incidence of bilateral (complete) frontal sinus aplasia in the South African sample*.

Age bin	Female	Aplastic	Male	Aplastic	Combined	Aplastic
18–30	14	0	14	0	28	0
31–40	14	2	17	0	31	2
41–50	13	0	13	0	26	0
51–60	13	1	10	0	23	1
61–70	14	2	13	1	27	3
71–80	5	0	14	0	19	0
81–90	1	1	2	0	3	1
Total	74	6 (8.1%)	83	1 (1.2%)	157	7 (4.5%)

*Note that this sample contains the seven aplastic individuals that were excluded from the final measured sample as recorded in Table 1.

growth may differ among males and females and the age at which it ceases to enlarge.

As noted above, most studies have asserted that frontal sinus pneumatization is largely completed at about 18–20 years of age (Brown et al., 1984; Fatu et al., 2006; Rennie et al., 2017; Sardi et al., 2018; Spaeth et al., 1997; Yun et al., 2011), although Prossinger (2001) predicted that adult size is attained somewhat later at 23.6 years in males, Karakas and Kavakli (2005) reported an increase in its volume after 25, and McLaughlin et al. (2001) and Tatlisumak et al. (2008) documented its increase into the third or fourth decade in males and the sixth decade in females. However, except for the studies by Brown et al. (1984) and Gagliardi et al. (2004), all of these ontogenetic studies have been conducted on cross-sectional rather than longitudinal samples. Unfortunately, the ontogenetic series examined by Gagliardi et al. (2004) did not extend beyond the end of ossific fusion of the wrist (i.e., ca. 17–20 years [Ebeye et al., 2021; Soliman et al., 2022]), and the study by Brown et al. (1984) did not extend beyond 24 years of age. Thus, as observed by Butaric, Buck, et al. (2022), the actual growth patterns exhibited by individuals into adulthood remains poorly known.

The results of the present cross-sectional study indicate that females, but not males, exhibit a statistically significant relationship between age and A_{FSV} ($p < 0.01$), as well as S_{FSV} ($p = 0.01$).

Bone fragility, which results from a reduction in bone mass and density (Tranquilli Leali et al., 2009), has been cited as a potential cause of sinus enlargement among elderly individuals (Fatu et al., 2006; Landsberg & Friedman, 2001; Nambiar et al., 1999; Shapiro & Schorr, 1980). As women are more likely to be affected by age-related bone loss (Alswat, 2017; Hannan et al., 2000), our results would appear to be concordant with the notion that the frontal sinus continues to expand throughout adulthood, especially in females. That this enlargement is likely due to bone resorption is perhaps exemplified by the 80-year-old female in our sample who exhibits a very large frontal sinus with an S_{FSV} of 0.28 mL. This value is somewhat more than 3 SD above the means not only of the female sample, but also the male sample (Table 4). As such, this value exceeds 99.7% of both statistical samples.

A previous CT study of the long bones (humerus and femur) of this individual show notable cortical bone thinning consistent with advanced osteoporosis (Wallace et al., 2020) (Figure 5). The mid-

26927691, 2024, 4, Downloaded from https://onlinelibrary.wiley.com/doi/10.1002/ajpa.24899 by University Of Witwatersrand, Wiley Online Library on [20/10/2024]. See the Terms and Conditions (https://onlinelibrary.wiley.com/terms-and-conditions) on Wiley Online Library for rules of use; OA articles are governed by the applicable Creative Commons License

TABLE 4 The absolute and scaled frontal sinus volumes (ml) recorded for black South Africans.

	N	Mean	SD	CV
Absolute volume (A_{FSV})				
Males	82	9.29	6.83	73.5
Females	68	7.73	7.79	100.8
Combined sex	150	8.58	7.40	86.3
Scaled volume (S_{FSV})				
Males	82	0.15	0.04	26.7
Females	68	0.14	0.04	28.6
Combined sex	150	0.15	0.04	26.7

diaphyseal cross-sectional geometric properties of total subperiosteal area (mm^2) and cortical area (mm^2) for the humerus and femur of this individual and the other South Africans from the Dart Collection were calculated by Wallace et al. (2020) from DICOM files using the BoneJ plugin (Doube et al., 2010) for ImageJ software (NIH, Bethesda, MD). A comparison of cortical to total subperiosteal area (percent cortical area) provides an indication of relative cortical thickness or the cross-sectional internal resistance of a bone to compression and tension (Wainwright et al., 1976).

Although DEXA (dual energy x-ray absorptiometry) scans of the lumbar spine and/or hip and/or distal forearm and the resultant T-scores of bone mineral density (BMD) are most commonly employed in the diagnosis of osteoporosis (Blake & Fogelman, 2007; Hans et al., 2006), assessment of cortical thickness and/or trabecular density from CT scans may provide similar results as they can provide an accurate measure of bone strength and cortical thickness (Keaveny et al., 2020). Osteoporosis is, afterall, defined by the Surgeon General of the USA as "a skeletal disorder characterized by compromised bone strength, predisposing to an increased risk of fracture" (United States Department of Health and Human Services, 2004) and by the International Osteoporosis Foundation as "a condition where bones become thin and lose their strength" (International Osteoporosis Foundation, 2020). Indeed, assessment of CT scans has been shown to be as effective as DEXA scans in the diagnosis of osteoporosis and prediction of fracture (Engelke et al., 2023; Johannesdottir et al., 2018; Keaveny et al., 2020)

The total subperiosteal and cortical areas of the humerus of this particular individual are 286.1 mm^2 and 126.6 mm^2, and the percent cortical area is 44.2. The corresponding averages recorded by Wallace et al. (2020: Table 1) for a small sample ($n = 4$) of females ≥80 years of age are 271.0 mm^2 and 133.0 mm^2. As such, this particular individual possesses a humerus that is larger than average for her age group in overall cross-sectional area, but small in cortical area. Similarly, the overall cross-sectional area of the humerus of this individual is moderately large in comparison to values for the entire combined sex sample, whereas her percent cortical area is notably low (Table 6 and Figure 6) The total subperiosteal and cortical areas of the femur of this particular individual are 474.4 mm^2 and 243.7 mm^2 respectively, and the femoral percent cortical area is 51.4. The corresponding

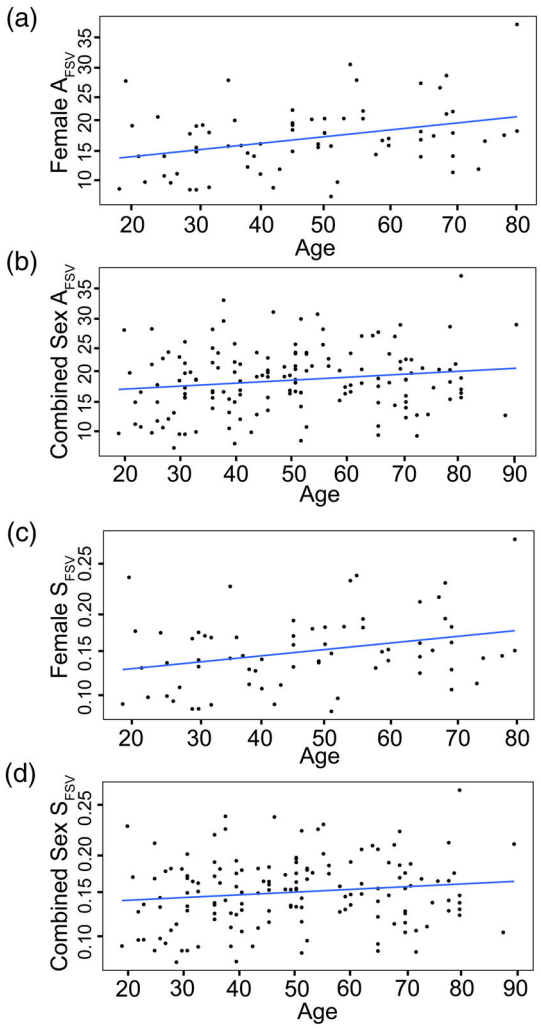

FIGURE 4 The relationship between frontal sinus volume and ontogenetic age (in years) in the South African sample. (a) The relationship between A_{FSV} and age in the female sample. GLS $r^2 = 0.12$; adjusted GLS $r^2 = 0.11$. (b) The relationship between A_{FSV} and age in the combined sex sample. GLS $r^2 = 0.03$; adjusted GLS $r^2 = 0.02$. (c) The relationship between S_{FSV} and age in the female sample. GLS $r^2 = 0.09$; adjusted GLS $r^2 = 0.08$. (d) The relationship between S_{FSV} and age in the combined sex sample. GLS $r^2 = 0.02$; adjusted GLS $r^2 = 0.01$. For the female sample, because there is no data beyond the 80th year, we have adjusted the X axis in plots (a and c) to clearly display the available data.

averages recorded by Wallace et al. (2020): Table 1) for a small sample ($n = 4$) of females ≥80 years of age are 495.0 mm^2 and 253.0 mm^2. As such, this particular individual possesses a femur that is but exiguously smaller than average for her group in overall cross-sectional area, and also small in cortical area. Similar to the humerus, the overall cross-sectional area of the femur of this individual is of moderate size in comparison to values for the entire combined sex sample, whereas her percent cortical area is notably low (Table 6 and Figure 6). As such, we are reasonably confident in regarding this individual as having suffered from at least moderate if not severe osteoporosis. The bone loss that characterizes osteoporosis is not restricted to the cortices of long

26927691, 2024, 4, Downloaded from https://onlinelibrary.wiley.com/doi/10.1002/ajpa.24899 by University Of Witwatersrand, Wiley Online Library on [20/10/2024]. See the Terms and Conditions (https://onlinelibrary.wiley.com/terms-and-conditions) on Wiley Online Library for rules of use; OA articles are governed by the applicable Creative Commons License

TABLE 5 Variation and sexual dimorphism of absolute frontal sinus volume in global population samples.

Population sample	Sex	*N*	Mean	SD	CV	Sex diff.	Reference
German	M	24	10.2	6.2	60.8	Significant	1
	F	23	5.5	3.5	63.6		
Czech	M	58	13.6	8.4	62.1	Significant	2
	F	45	8.0	5.0	62.5		
Romanian	M	15	10.2	6.5	63.8	Significant	3
	F	15	5.0	2.4	49.2		
Korean	M	60	3.2	3.3	95.8	Significant	4
	F	59	2.1	2.2	107.3		
Korean	M	35	8.5	3.8	104.4	Non	5
	F	33	8.2	3.6	44.1		
Japanese	M	10	11.6	4.2	36.1	Significant	6
	F	10	4.6	3.2	69.7		
Brazilian	M	41	13.0	8.2	63.2	Significant	7
	F	57	8.0	6.1	75.7		
South African	M	82	9.3	6.8	73.5	Non	This study
	F	68	7.7	7.8	100.8		

Note: References: 1, Schumacher et al. (1972); 2, Čechová et al. (2019); 3, Benghiac et al. (2017); 4, Kim et al. (2013); 5, Yun et al. (2011); 6, Karawai et al. (1999); 7, Pondé et al. (2003). The CV (Coefficient of Variation) = SD / Mean x 100.

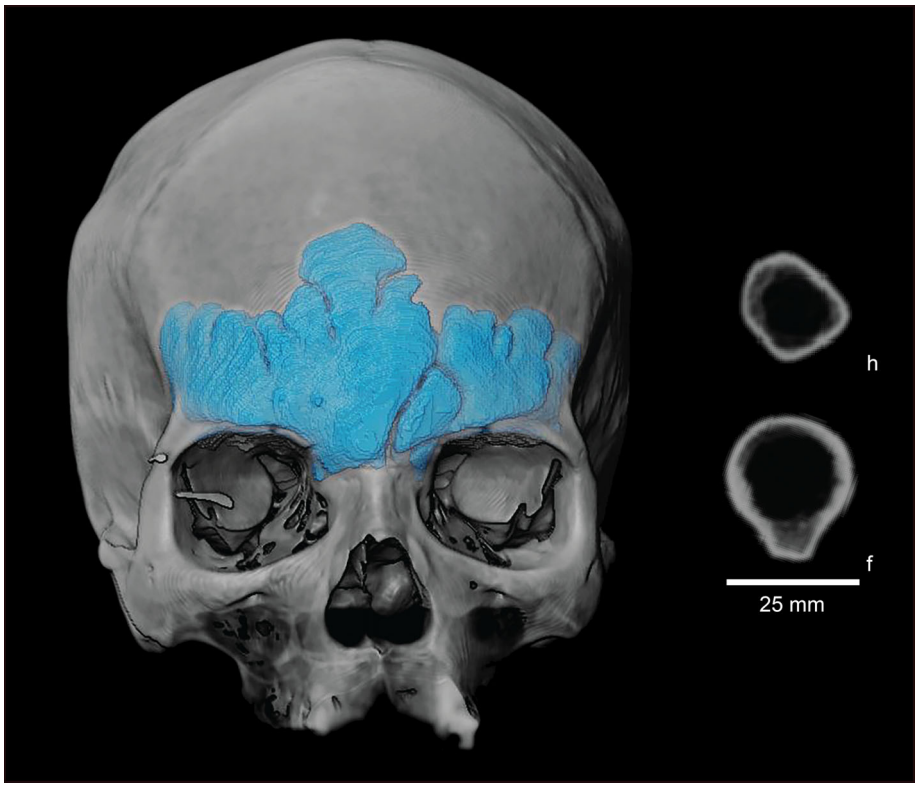

FIGURE 5 The frontal sinus and the midshaft CT scans of the humerus (h) and femur (f) of an 80 year-old female in the South African sample. The frontal sinus is one of the largest (S_{FSV} = 0.28 ml) in the current sample, and the thin long bone cortices are almost certainly concordant with advanced osteoporosis.

bone diaphyses, but rather may affect the entire skeleton where osteoclastic resorption outpaces remodeling osteoblastic deposition. Such endosteal resorption can conceivably affect the frontal bone as easily as the humerus and femur, in which case there will be concomitant enlargement of the frontal sinus.

5.3 | Population differences in frontal sinus size and incidences of total frontal sinus aplasia

Although adaptation to climate and/or altitude does not appear to be a driving factor behind frontal sinus size (Balzeau

26927691, 2024, 4, Downloaded from https://onlinelibrary.wiley.com/doi/10.1002/ajpa.24899 by University Of Witwatersrand, Wiley Online Library on [20/10/2024]. See the Terms and Conditions (https://onlinelibrary.wiley.com/terms-and-conditions) on Wiley Online Library for rules of use; OA articles are governed by the applicable Creative Commons License

TABLE 6 Long bone cortical properties of the 80 year-old female in relation to the black South African sample recorded by Wallace et al. (2020).

Humerus	*n*	X	SD	Obs. Range
Periosteal area				
Old female	1	286.1		
Combined sex sample	222	297.19	58.12	187.3–535.0
Cortical area				
Old female	1	126.6		
Combined sex sample	222	196.95	44.65	101.1–344.8
Percent cortical area				
Old female	1	44.30		
Female sample	105	63.65	11.17	35.7–88.1
Male sample	117	69.54	10.21	40.0–91.0
Combined sex sample	222	66.73	11.06	35.7–91.0
Femur	***n***	**X**	**SD**	**Obs. Range**
Periosteal area				
Old female	1	474.40		
Combined sex sample	222	520.09	83.52	153.2–796.7
Cortical area				
Old female	1	243.70		
Combined sex sample	222	371.81	69.00	170.8–647.2
Percent cortical area				
Old female	1	51.40		
Female sample	105	69.75	8.02	47.9–84.3
Male sample	117	73.19	6.51	43.9–83.9
Combined sex sample	222	71.56	7.45	43.9–84.3

et al., 2022; Butaric, Buck, et al., 2022), and despite the relatively high degree of variation that tends to characterize most populations, there are significant differences in frontal sinus volume among populations that inhabit different geographic regions of the globe (Balzeau et al., 2022; Butaric, Buck, et al., 2022).

One such trend observed by Butaric, Buck, et al. (2022), was a tendency for sub-Saharan African populations to exhibit comparatively small frontal sinuses. Unfortunately, the number of sub-Saharan populations for which frontal sinus volumes have been recorded is limited to three samples.

To establish comparability of reported sinus volumes, it is necessary to delineate those studies that measured sinus volume by segmentation of CT scans versus those that calculated sinus volume from linear measurements recorded from CT scans inasmuch as the latter method will result in larger values (i.e., reporting the size of the box into which the sinus could fit). Ideally, it would also be necessary to separate those studies that measured sinus volume by segmentation according to the manner in which they defined the inferior extent of the frontal sinus. Unfortunately, of the 18 relevant published studies, only four provided any information pertaining to the definition of this boundary (Aslier et al., 2016; Kim et al., 2013; Noback et al., 2016; Yun et al., 2011), and each of these employed a different boundary. Only that used by Aslier et al. (2016)—the lower border of the frontal ostium—appears to coincide with the definition that we have employed. Nevertheless, it is perhaps instructive to examine the distribution of sinus volumes among the populations examined by these studies in order to discern whether any geographic trends might be discerned that are not affected by methodological differences.

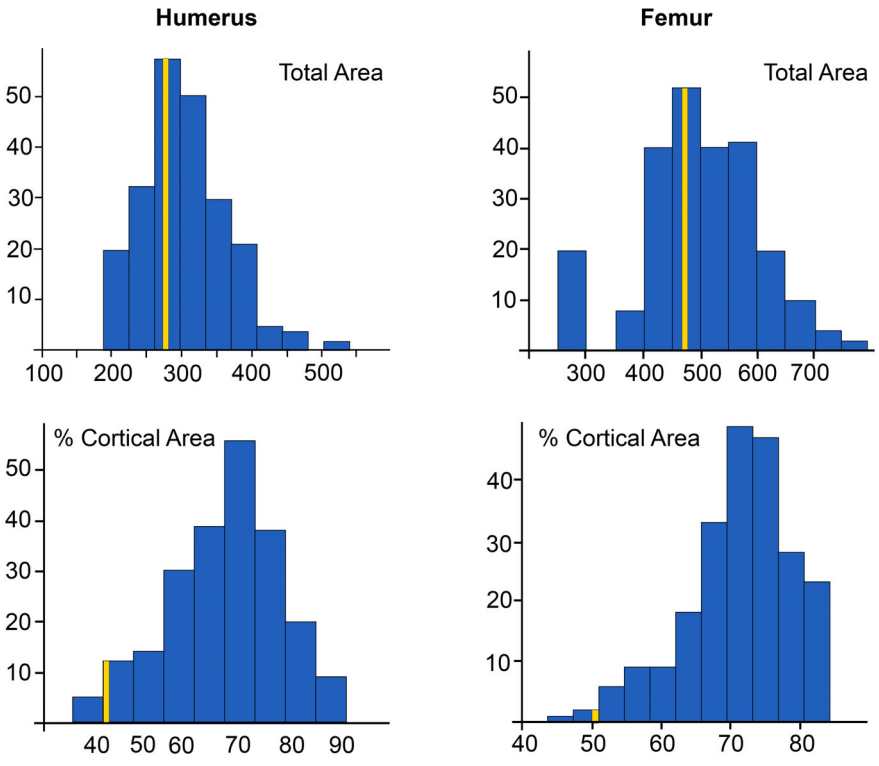

FIGURE 6 The combined sex South African sample distributions of total subperiosteal area and percent cortical area for the humerus and femur (data recorded by Wallace et al., 2020). The 80 year-old female values are indicated by the yellow bars. The Y-axis records frequencies, the x-axis of the total area graphs is in mm^2 and the x-axis of the percent cortical area graphs is in %.

26927691, 2024, 4, Downloaded from https://onlinelibrary.wiley.com/doi/10.1002/ajpa.24899 by University Of Witwatersrand, Wiley Online Library on [20/10/2024]. See the Terms and Conditions (https://onlinelibrary.wiley.com/terms-and-conditions) on Wiley Online Library for rules of use; OA articles are governed by the applicable Creative Commons License

TABLE 7 Frontal sinus volumes recorded for combined sex recent human population samples (direct volumetric measurement from segmented CT scans).

Population	*n*	Vol.	SD	CV%	Reference
Sub-Saharan African					
South African Nguni	330	7.65	–	–	Rennie et al. (2017)
South African	150	8.58	7.40	86.2	This Study
West African	27	6.09	3.39	55.7	Butaric, Buck, et al. (2022)
West African	13	5.12	2.22	43.4	Buck et al. (2019)
North African					
Sudanese (Nubian)	35	2.74	1.63	59.5	Noback et al. (2016)
Sudanese (Nubian)	16	3.88	–	–	Butaric, Buck, et al. (2022)
Middle Eastern					
Turkish[a]	35	6.07	3.51	57.8	Karakas and Kavakli (2005)
Turkish	78	7.47	–	–	Aslier et al. (2016)
European					
Croatian	18	5.22	4.28	82.0	Butaric et al. (2020)
Czech[a]	103	10.77	6.70	62.2	Čechová et al. (2019)
French	69	7.30			Michel et al. (2015)
German[a]	47	7.85	4.85	61.8	Schumacher et al. (1972)
Lithuanian	11	4.31	3.28	76.1	Buck et al. (2019)
Romanian[a]	30	7.56	4.46	59.0	Benghiac et al. (2017)
South African	38	7.52	–	–	Rennie et al. (2017)
Western European	11	7.76	5.19	66.9	Buck et al. (2019)
South Asian					
Indian	10	7.30	6.38	87.4	Buck et al. (2019)
East Asian					
Mongolian (Urga)	19	4.11	3.01	73.2	Butaric et al. (2020)
Chinese	9	5.35	3.53	66.0	Buck et al. (2019)
Korean[a]	68	8.39	3.74	44.6	Yun et al. (2011)
Japanese[a]	20	8.11	3.70	45.6	Kawarai et al. (1999)
North-East Asian					
Chukchian	12	4.12	2.38	57.8	Butaric et al. (2020)
South-East Asian					
Malaysian	10	5.40	2.33	43.1	Buck et al. (2019)
Australasian					
Tasmanian	8	4.17	3.94	94.5	Buck et al. (2019)
South & Central American					
Mexican	10	3.34	2.55	76.4	Buck et al. (2019)
Brazilian[a]	98	10.51	7.15	68.0	Pondé et al. (2003)
Peruvian	10	2.71	2.12	78.2	Buck et al. (2019)
North American					
Greenland	7	3.74	4.16	111.2	Buck et al. (2019)
Greenland	15	3.00	2.64	88.0	Butaric et al. (2020)
Greenland Inuit	32	0.66	0.55	83.3	Noback et al. (2016)
Oceanian					
Hawaiian	11	6.28	4.36	69.4	Buck et al. (2019)

Note: Volumes are recorded in ml (=cm^3).

[a]The combined sex values have been recorded as an average of the published male and female means.

26927691, 2024, 4, Downloaded from https://onlinelibrary.wiley.com/doi/10.1002/ajpa.24899 by University Of Witwatersrand, Wiley Online Library on [20/10/2024]. See the Terms and Conditions (https://onlinelibrary.wiley.com/terms-and-conditions) on Wiley Online Library for rules of use; OA articles are governed by the applicable Creative Commons License

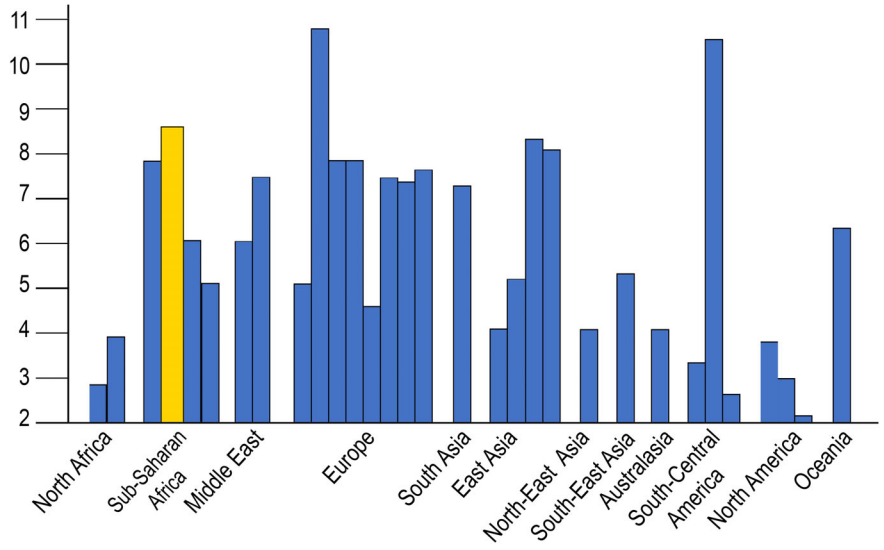

FIGURE 7 A_{FSV} values recorded for global population samples. The data for the individual samples are recorded in Table 7. The order of the individual population samples from left to right is the same as in Table 7. The yellow column = South African sample of this study. The Y axis is in ml.

TABLE 8 Incidences of bilateral (total) frontal sinus aplasia recorded for recent human population samples.

Population	Male		Female		Combined sex		Reference
	N	%	*N*	%	*N*	%	
Sub-Saharan African							
South African	83	1.2	74	8.1	157	4.5	This study
Nigeria					24	50.0	Amusa et al. (2011)
African*					189	2.1	Butaric et al. (2020)
Middle Eastern							
Turkey	610	1.3	590	5.1	1200	3.8	Aydınlıoğlu et al. (2003)
Turkey	190	0.2	220	0.5	410	0.7	Çakur et al. (2011)
Turkey					74	4.1	Yüksel Aslier et al. (2016)
Jordan	85	7.0	82	1.2	167	4.2	Al-Balas et al. (2020)
Saudi Arabia	226	3.5	223	3.1	449	3.3	Assiri and Alroqi (2021)
Iran	271	7.0	294	9.5	565	8.3	Danesh-Sani et al. (2011)
European							
Poland					63	3.2	Balzeau et al. (2021)
Germany					2820	3.4	Nowak and Mehls (1977)
Romania					30	0.0	Benghiac et al. (2017)
Spain					40	7.5	Balzeau et al. (2021)
European**					129	1.6	Butaric et al. (2020)
South Asian							
India	170	1.2	210	1.4	380	1.3	Choudhary et al. (2015)
India	100	9.0	100	4.0	200	6.5	Soman et al. (2016)
India	390	1.8	340	3.2	730	2.5	Moideen et al. (2017)
East Asian							
Asian***	119	3.4					Butaric et al. (2020)
Australasian							
Oceania****					91	7.7	Butaric et al. (2020)
Pacific					71	19.7	Balzeau et al. (2021)
North American							
Arctic*****					244	13.1	Butaric et al. (2020)

26927691, 2024, 4, Downloaded from https://onlinelibrary.wiley.com/doi/10.1002/ajpa.24899 by University Of Witwatersrand, Wiley Online Library on [20/10/2024]. See the Terms and Conditions (https://onlinelibrary.wiley.com/terms-and-conditions) on Wiley Online Library for rules of use; OA articles are governed by the applicable Creative Commons License

TABLE 8 (Continued)

Population	Male		Female		Combined sex		Reference
	N	%	*N*	%	*N*	%	
Alaska					78	14.6	Balzeau et al. (2021)
Greenland					48	15.4	Balzeau et al. (2021)

*The African sample of Butaric et al. (2020) includes crania of West Africans, South Africans, Nubians, and African-Americans. The numbers of Nubian and African-American crania are not given.
**The European sample of Butaric et al. (2020) includes crania from Austria, Germany, Netherlands, "Yugoslavia," Scandinavia, and the United States.
***The Asian sample of Butaric et al. (2020) includes crania from Buriat, China, Mongolia, Nepal, and Tibet.
****The Oceania sample of Butaric et al. (2020) includes crania from Australia, New Zealand, and New Guinea.
*****The Arctic sample of Butaric et al. (2020) includes crania from North-West Canada, Alaska, and Greenland.

The frontal sinus volumes that have been recorded from the measurement of segmented CT scans of living patients and of dried crania for 31 population samples are recorded in Table 7. These comparisons are of absolute volumes and, as such, do not take into account differences in overall cranial size among different populations. Nevertheless, it is evident that sub-Saharan African populations for which data have been recorded do not exhibit comparatively small frontal sinus volumes. Unfortunately, two of the four samples derive from South Africa, and the other two from "West Africa," which leaves a vast geographic area of sub-Saharan Africa unsampled. Nevertheless, rather than sub-Saharan Africans, it is the (Sudanese) Nubians of North Africa together with the inhabitants of Greenland who appear to possess some of the smallest frontal sinus volumes, although their values are closely approximated by several other populations (e.g., Peruvian, Mexican, Chuchkian, and Tasmanian samples). Although the Nubians are African by definition, they have both prehistorically and historically predominantly occupied the Nile Valley (Kirwan, 1974; Török, 2008; Wendorf & Schild, 1976); hence they cannot be regarded as sub-Saharan. The mean frontal sinus volumes for the samples reported in Table 7 are illustrated graphically in Figure 7. This serves to emphasize the inter-population variation within geographic regions, such as Europe, East Asia, and Central-South America. One caveat, of course, pertains to the fact that at least some of this apparent variability may be owing to different methods having been employed by different studies to define the extent of the frontal sinus.

One rather striking aspect of the data recorded in Table 7 is the comparatively high CVs exhibited by all of the samples, where the sample standard deviations range from 43% to over 100% of the corresponding mean. Although, as noted above, the appropriateness of employing the CV to inform the degree of phenotypic plasticity of quantitative traits has been questioned (Pélabon et al., 2020), it provides a simple means by which to describe the level of variability within a population that is independent of the absolute quantitative values of the observed trait (Sokal & Rohlf, 1995). Indeed, a CV calculated from small sample sizes, such as $n < 20$, which affect a good number of the samples recorded in Table 7, can be biased to *underestimate* relative variation (Schillaci & Schillaci, 2022). The study of West African crania by Buck et al. (2019) is an exception to this generalization because they employed V*, which is a CV adjusted for small sample size. Nevertheless, the data recorded in Table 7 emphasizes the variation in frontal sinus volume within recent human populations.

While individuals with complete (i.e., bilateral) frontal sinus aplasia were not included in the calculation of the average frontal sinus volume for the sample owing to the problem of employing zero values in such computations (Butaric et al., 2020; Butaric, Buck, et al., 2022), the incidence of aplasia should be recorded in any study of frontal sinus size inasmuch as it speaks to the development of paranasal pneumatic spaces in the individuals comprising the population being sampled.

The incidence of bilateral frontal sinus aplasia in the black South African sample is compared with those recorded for other population samples from around the globe in Table 8. While an incidence of 4.5% is nearly double the frequency reported by Butaric et al. (2020) for an "African" sample, their sample included individuals from Nubia and the United States. Still, neither of our values even begins to approach the inordinately high incidence of 50% reported by Amusa et al. (2011). It is at least 2.5 times greater than the next highest incidence of 19.7% reported by Balzeau et al. (2021) for a Pacific population sample, and we suspect that this may be owing to the fact that Amusa et al. (2011) did not rely on radiographs or CT scans, but rather on physical examination of dried crania using an endoscope. Interestingly, the North American samples exhibit among the highest incidences of aplasia, and this is concordant with their comparatively low frontal sinus volumes (Table 7 and Figure 7).

The South African aplasia incidence is comparable to the values recorded for European population samples, and their frontal sinus volumes are also of comparable magnitude. In other words, the South African population appears to possess neither comparatively small frontal sinuses, and nor does it appear to have a notable incidence of aplasia by comparison with the values reported for other global population samples.

6 | CONCLUSIONS

This study entailed an analysis of frontal sinus volume in an indigenous black South African population sample. Although it has been claimed that sub-Saharan African populations exhibit comparatively small frontal sinuses in relation to other global populations, the data

26927691, 2024, 4, Downloaded from https://onlinelibrary.wiley.com/doi/10.1002/ajpa.24899 by University Of Witwatersrand, Wiley Online Library on [20/10/2024]. See the Terms and Conditions (https://onlinelibrary.wiley.com/terms-and-conditions) on Wiley Online Library for rules of use; OA articles are governed by the applicable Creative Commons License

on absolute sinus volume for the present sample do not support such a conclusion. Rather, it is evident that the four sub-Saharan African populations for which data have been recorded do not exhibit comparatively small frontal sinus volumes in comparison to the other 27 global samples for which volumes have been reconstructed from CT scans. Unfortunately, two of the four sub-Saharan samples derive from South Africa, and the other two from "West Africa," which leaves a vast geographic area of sub-Saharan Africa unsampled. Nevertheless, rather than sub-Saharan Africans, it is the (Sudanese) Nubians of North Africa and the inhabitants of Greenland who appear to possess some of the smallest volumes. Although geography (i.e., climate and altitude) does not appear to be a driving factor, there are significant size differences between populations that inhabit different geographic regions.

The South African sample exhibits considerable variability in both absolute and scaled frontal sinus volume and, in this respect, it is not unlike all other global populations, where standard deviation ranges from 43% to over 100% of the corresponding sample mean value. The South African aplasia incidence is comparable to the values recorded for other (e.g., European) population samples. Thus, the black South African population does not appear to be characterized by the possession of comparatively small frontal sinuses, and nor does it appear to have a notable incidence of aplasia by comparison with the values reported for other global population samples. This sample also does not appear to be unusually variable in frontal sinus size.

The present sample does not display significant sexual dimorphism in either absolute or scaled frontal sinus volume. This result is rather unexpected in light of the presence of significant dimorphism in overall cranial size in this South African population. In this respect, the present sample differs from the vast majority of global population samples, in which significant dimorphism has been recorded.

Although most studies have asserted that frontal sinus pneumatization is largely completed at about 18–20 years of age, some have either predicted or reported its increase into the fourth decade in males and the sixth decade in females. Unfortunately, the majority of studies of sinus enlargement, like ours, are cross-sectional rather than longitudinal. However, the present study finds evidence for a significant relationship between increasing adult age and the absolute size of the frontal sinus among South African blacks and, more particularly among females. In this respect, increasing bone fragility, especially among post-menopausal females suggests itself as a potential cause. This is perhaps exemplified by at least one aged (80-year-old) female in our sample, who exhibits a very large sinus together with evidence of notable cortical bone loss in her postcranial bones. As such, our results support claims that the frontal sinus not only continues to expand throughout adulthood, especially in females, but that it is likely due to bone resorption. An increased risk of cranial fractures due to the loss of bone density may be another symptom of osteoporosis.

AUTHOR CONTRIBUTIONS

Victoria A. Greening: Formal analysis (equal); investigation (equal); writing – original draft (equal); writing – review and editing (equal). **Emily Hernandez:** Formal analysis (equal); investigation (equal). **Carrie S. Mongle:** Conceptualization (equal); formal analysis (equal); investigation (equal); writing – original draft (equal); writing – review and editing (equal). **Brendon K. Billings:** Writing – review and editing (equal). **Victor Mngomezulu:** Investigation (equal); writing – review and editing (equal). **Ian J. Wallace:** Writing – original draft (equal); writing – review and editing (equal). **Frederick E. Grine:** Conceptualization (lead); formal analysis (equal); investigation (equal); methodology (equal); supervision (equal); writing – original draft (equal); writing – review and editing (equal).

ACKNOWLEDGMENTS

We thank Tea Jashashvili and Queen Letsoalo for their assistance with the CT scanning. We thank James Rossie for comments on an early draft of the manuscript, for references and discussions related to paranasal sinuses, and Dr. Katharine Thompson for her assistance with the illustrations. We are grateful to Antoine Balzeau, two anonymous reviewers and the editor, Trudy Turner for their cogent comments which have served to improve this manuscript. This study was supported by a grant from the Leakey Foundation. We would like to acknowledge the donors for the generous gift of their remains that made this research possible.

CONFLICT OF INTEREST STATEMENT

The authors declare no conflicts of interest.

DATA AVAILABILITY STATEMENT

The data that support the findings of this study are available from the corresponding author upon reasonable request. The CT scans can be accessed through a request to the Raymond A. Dart Collection of Modern Human Skeletons, School of Anatomical Sciences, Faculty of Health Sciences, University of the Witwatersrand (Brendon.Billings@wits.ac.za).

ORCID

Carrie S. Mongle https://orcid.org/0000-0002-5474-0501
Ian J. Wallace https://orcid.org/0000-0002-1837-5260
Frederick E. Grine https://orcid.org/0000-0002-5310-9005

REFERENCES

Abate, A., Gaffuri, F., Lanteri, V., Fama, A., Ugolini, A., Mannina, L., & Maspero, C. (2022). A CBCT based analysis of the correlation between volumetric morphology of the frontal sinuses and the facial growth pattern in Caucasian subjects. A cross-sectional study. *Head & Face Medicine*, *18*, 4. https://doi.org/10.1186/s13005-022-00308-3

Adibelli, Z. H., Songu, M., & Adibelli, H. (2011). Paranasal sinus development in children: A magnetic resonance imaging analysis. *American Journal of Rhinology & Allergy*, *25*, 30–35.

Akhlaghi, M., Bakhtavar, K., Moarefdoost, J., Kamali, A., & Rafeifar, S. (2016). Frontal sinus parameters in computed tomography and sex determination. *Legal Medicine*, *19*, 22–27.

Al-Balas, H. I., Nuseir, A., Alzoubi, F., Alomari, A., Bani-Ata, M., Almehzaa, S., & Aleshawi, A. (2020). Prevalence of frontal sinus aplasia in Jordanian individuals. *Journal of Craniofacial Surgery*, *31*, 2040–2042.

Alswat, K. A. (2017). Gender disparities in osteoporosis. *Journal of Clinical Medicine Research*, *9*, 382–387.

26927691, 2024, 4, Downloaded from https://onlinelibrary.wiley.com/doi/10.1002/ajpa.24899 by University Of Witwatersrand, Wiley Online Library on [20/10/2024]. See the Terms and Conditions (https://onlinelibrary.wiley.com/terms-and-conditions) on Wiley Online Library for rules of use; OA articles are governed by the applicable Creative Commons License

Amusa, Y. B., Eziyi, J. A., Akinlade, O., Famurewa, O. C., Adewole, S. A., Nwoha, P. U., & Ameye, S. A. (2011). Volumetric measurements and anatomical variants of paranasal sinuses of Africans (Nigerians) using dry crania. *International Journal of Medicine and Medical Sciences*, *3*, 299–303.

Asirdizer, M., Ttlisumak, E., Bora, A., Tarhan, S., Yilmaz, O. G., Hekimoglu, Y., Kartal, E., & Keskin, S. (2017). The possible effects of altitude and climate on the development of the frontal sinus in adults. *International Journal of Morphology*, *35*, 571–577.

Aslier, N. G. Y., Karabay, N., Zeybek, G., Keskinoğlu, P., Kiray, A., Sütay, S., & Ecevit, M. C. (2016). The classification of frontal sinus pneumatization patterns by CT-based volumetry. *Surgical and Radiologic Anatomy*, *38*, 923–930.

Assiri, K. S., & Alroqi, A. S. (2021). Frequency of frontal sinus aplasia among Saudi Arabian population. *Saudi Medical Journal*, *42*, 228–231.

Aydınlıoğlu, A., Kavaklıı, A., & Erdem, S. (2003). Absence of frontal sinus in Turkish individuals. *Yonsei Medical Journal*, *44*, 215–218.

Bailey, R. (1995). The Bantu languages of South Africa: Towards a socio-historical perspective. In R. Mesthrie (Ed.), *Language and social history: Studies in South African sociolinguistics* (pp. 19–38). David Philip.

Balzeau, A., Abelard-Ball, L., Kubicka, A. M., Noûs, C., & Buck, L. T. (2021). Frontal sinus variation in extant species of the genera *Pan*, *Gorilla* and *Homo*. *Bulletins et Mémoires de la Société d'Anthropologie de Paris*, *33*, 27–52.

Balzeau, A., Albessard-Ball, L., Kubicka, A. M., Beaudet, A., Santos, E., Bienvenu, T., Arsuaga, J. L., Asfaw, B., Berger, L., Bermúdez de Castro, J. M., Carlson, K., Clarke, R. J., Daura, J., Filippo, A., Gorgoulis, V. G., Grine, F. E., Harvati, K., Hawks, J., Herries, A., … Buck, L. (2022). Frontal sinuses and human evolution. *Science. Advances*, *8*, eabp9767. https://doi.org/10.1126/sciadv.abp9767

Benghiac, A. G., Budacu, C., Moscalu, M., Ioan, B. G., Moldovanu, A., & Haba, D. (2017). CBCT assessment of the frontal sinus volume and anatomical variations for sex determination. *Romanian Journal of Legal Medicine*, *25*, 174–179.

Besana, J. L., & Rogers, T. L. (2010). Personal identification using the frontal sinus. *Journal of Forensic Science*, *55*, 584–589.

Bilgin, S., Kantarcı, U. H., Duymus, M., Yildirim, C. H., Ercakmak, B., Orman, G., Gunenc Beser, C., Kaya, M., Gok, M., & Akbasak, A. (2013). Association between frontal sinus development and persistent metopic suture. *Folia Morphologica*, *72*, 306–310.

Blake, G. M., & Fogelman, I. (2007). The role of DXA bone density scans in the diagnosis and treatment of osteoporosis. *Postgraduate Medical Journal*, *83*, 509–517.

Bräuer, G. (1988). Osteometrie. In R. Knussmann (Ed.), *Anthropologie. Handbuch der vergleichenden Biologie des Menschen. Band I. Wesen und Methoden der Anthropologie. Teil 1. Wissenschaftstheorie, Geschichte, morphologische Methoden* (pp. 160–232). Gustav Fischer.

Brown, W. A. B., Molleson, T. I., & Chinn, S. (1984). Enlargement of the frontal sinus. *Annals of Human Biology*, *11*, 221–226.

Buck, L. T., Stringer, C. B., MacLarnon, A. M., & Rae, T. C. (2019). Variation in paranasal pneumatization between mid-late Pleistocene hominins. *Bulletins et Mémoires de la Société d'Anthropologie de Paris*, *31*, 14–33.

Buckland-Wright, J. C. (1970). A radiographic examination of frontal sinuses in early British populations. *Man*, *5*, 512–517.

Butaric, L., Buck, L., Balzeau, A., du Plessis, A., & Grine, F. E. (2022). The paranasal sinuses of the Hofmeyr cranium. In F. E. Grine (Ed.), *Hofmeyr: A Late Pleistocene human skull from South Africa* (pp. 179–211). Springer.

Butaric, L. N. (2013). Ecogeographic patterns of maxillary sinus variation among *Homo sapiens*: Environmental adaptation or architectural by-product? (PhD Dissertation). Texas A&M University.

Butaric, L. N. (2015). Differential scaling patterns in maxillary sinus volume and nasal cavity breadth among modern humans. *The Anatomical Record*, *298*, 1710–1721.

Butaric, L. N., Campbell, J. L., Fischer, K. M., & Garvin, H. M. (2022). Ontogenetic patterns in human frontal sinus shape: A longitudinal study using elliptical Fourier analysis. *Journal of Anatomy*, *241*, 195–210.

Butaric, L. N., Jones, G. C., & Garvin, H. M. (2020). Revisiting global patterns of frontal sinus aplasia utilizing computed tomography. *Forensic Science International*, *315*, 110458.

Butaric, L. N., Richman, A., & Garvin, H. M. (2022). The effects of cranial orientation on forensic frontal sinus identification as assessed by outline analysis. *Biology*, *11*(1), 62. https://doi.org/10.3390/biology11010062

Çakur, B., Sumbullu, M. A., & Durna, N. B. (2011). Aplasia and agenesis of the frontal sinus in Turkish individuals: A retrospective study using dental volumetric tomography. *International Journal of Medical Sciences*, *8*, 278–282.

Cardell, L. O. (2002). The paranasal sinuses and a unique role in airway nitric oxide production? *American Journal of Respiratory and Critical Care Medicine*, *166*, 131–132.

Cave, A. J. E., & Haines, R. W. (1940). The paranasal sinuses of anthropoid apes. *Journal of Anatomy*, *74*, 493–523.

Čechová, M., Dupej, J., Brůžek, J., Bejdová, S., Horák, M., & Veleminská, J. (2019). Sex estimation using external morphology of the frontal bone and frontal sinuses in a contemporary Czech population. *International Journal of Legal Medicine*, *133*, 1285–1294.

Choudhury, A., Ramsay, M., Hazelhurst, S., Aron, S., Bardien, S., Botha, G., Chiusa, E. R., Christoffels, A., Gamieldien, J., Sefid-Dashti, M. J., Joubert, F., Meintjes, A., Mulder, N., Ramesar, R., Rees, J., Scholtz, K., Sengupta, D., Soodyall, H., Venter, P., Warnich, L., & Pepper, M. S. (2017). Whole-genome sequencing for an enhanced understanding of genetic variation among South Africans. *Nature Communications*, *8*, 2062.

Choudhary, S., Pasricha, N., Sehgal, G., Siddiqui, M. S., Khanduri, S., Srivastava, M. R., Prasad, M., & Bedi, R. S. (2015). Aplasia of frontal sinus: CT study. *International Journal of Anatomy and Research*, *3*, 1620–1623.

Christensen, A. M., & Hatch, G. M. (2018). Advances in the use of frontal sinuses for human identification. In K. Latham, E. Bartelink, & M. Finnegan (Eds.), *New perspectives in forensic human skeletal identification* (pp. 227–240). Academic.

Cox, M., Malcolm, M., & Faigrieve, S. I. (2009). A new digital method for the objective comparison of frontal sinuses for identification. *Journal of Forensic Science*, *54*, 761–772.

Danesh-Sani, S. A., Bavandi, R., & Esmaili, M. (2011). Frontal sinus agenesis using computed tomography. *Journal of Craniofacial Surgery*, *22*, e48–e51.

Davis, W. E., Templer, J., & Parsons, D. S. (1996). Anatomy of the paranasal sinuses. *Otolaryngologic Clinics of North America*, *29*, 57–74.

Dayal, M. R., Kegley, A. D. T., Štrkalj, G., Bismos, M. A., & Kuykendall, K. L. (2009). The history and composition of the Raymond A. Dart collection of human skeletons at the University of the Witwatersrand, Johannesburg, South Africa. *American Journal of Physical Anthropology*, *140*, 324–335.

de Villiers, H. (1968a). Sexual dimorphism of the skull of the South African Bantu-speaking Negro. *South African Journal of Science*, *64*, 118–124.

de Villiers, H. (1968b). *The skull of the South African Negro. A biometrical and morphological study*. Witwatersrand University Press.

Dolan, K. D. (1982). Paranasal sinus radiology, part IA: Introduction and the frontal sinuses. *Head and Neck Surgery*, *4*, 301–311.

Doube, M., Kłosowski, M. M., Arganda-Carreras, I., Cordelières, F. P., Dougherty, R. P., Jackson, J. S., Schmid, B., Hutchinson, J. R., & Shefelbine, S. J. (2010). BoneJ: Free and extensible bone image analysis in ImageJ. *Bone*, *47*, 1076–1079.

Gannon, P. J., Doyle, W. J., Ganjian, E., Marquez, S., Gnoy, A., Gabrielle, H. S., & Lawson, W. (1997). Maxillary sinus mucosal blood flow during nasal vs tracheal respiration. *Archives of Otolaryngology: Head and Neck Surgery*, *123*, 1336–1340.

Duque, C. S., & Casiano, R. R. (2005). Surgical anatomy and embryology of the frontal sinus. In S. Kountakis, B. Senior, & W. Draf (Eds.), *The frontal sinus* (pp. 21–32). Springer.

26927691, 2024, 4, Downloaded from https://onlinelibrary.wiley.com/doi/10.1002/ajpa.24899 by University Of Witwatersrand, Wiley Online Library on [20/10/2024]. See the Terms and Conditions (https://onlinelibrary.wiley.com/terms-and-conditions) on Wiley Online Library for rules of use; OA articles are governed by the applicable Creative Commons License

Ebeye, O. A., Okoro, O. G., & Ikubor, J. E. (2021). Radiological assessment of age from epiphyseal fusion at the wrist and ankle in southern Nigeria. *Forensic Science International Reports*, *3*, 100164. https://doi.org/10.1016/j.fsir.2020.100164

Eckert-Mobius, A. (1933). Vergleichend anatomisch-physiologische studie uber sinn und Zweck der Nasennebenhohlen des Menschen und der Saugetiere. *Archiv für Ohren-Nasen Und Kehlkopfheilkunde*, *134*, 288–307.

Ekşi, M. Ş., Güdük, M., & Usseli, M. I. (2021). Frontal bone is thicker in women and frontal sinus is larger in men: A morphometric analysis. *Journal of Craniofacial Surgery*, *32*, 1683–1684.

Emirzeoglu, M., Sahin, B., Bilgic, S., Celebi, M., & Usun, A. (2007). Volumetric evaluation of the paranasal sinuses in normal subjects using computer tomography images: A stereological study. *Auris Nasus Larynx*, *34*, 191–195.

Engelke, K., Chaudry, O., & Bartenschlager, S. (2023). Opportunistic screening techniques for analysis of CT scans. *Current Osteoporosis Reports*, *21*, 65–76.

Fatu, C., Puisoru, M., Rotaru, M., & Truta, A. M. (2006). Morphometric evaluation of the frontal sinus in relation to age. *Annals of Anatomy-Anatomischer Anzeiger*, *188*, 275–280.

Franklin, D., Cardini, A., Flavel, A., & Kuliukas, A. (2013). Estimation of sex from cranial measurements in a western Australian population. *Forensic Science International*, *229*, 158.e1–158.e8.

Franklin, D., Freedman, L., & Milne, N. (2005). Sexual dimorphism and discriminant function sexing in indigenous South African crania. *Homo*, *55*, 213–228.

Gagliardi, A., Winning, T., Kaidonis, J., Hughes, T., & Townsend, G. C. (2004). Association of frontal sinus development with somatic and skeletal maturation in aboriginal Australians: A longitudinal study. *Journal of Comparative Human Biology*, *55*, 39–52.

Gonzalez, P. N., Bernal, V., & Perez, S. I. (2011). Analysis of sexual dimorphism of craniofacial traits using geometric morphometric techniques. *International Journal of Osteoarchaeology*, *21*, 82–91.

González-Santos, M., Montinaro, F., Oosthuizen, O., Oosthuizen, E., Busby, G. B. J., Anagnostou, P., Destro-Bisol, G., Pascali, V., & Capelli, C. (2015). Genome-wide SNP analysis of southern African populations provides new insights into the dispersal of bantu-speaking groups. *Genome Biology and Evolution*, *7*, 2560–2568.

Gould, S., & Lewontin, R. (1979). The spandrels of San Marco and the Panglossian paradigm: A critique of the adaptationist programme. *Proceedings of the Royal Society of London B*, *205*, 581–598.

Goyal, M., Acharya, A. B., & Sattur, A. P. (2013). Are frontal sinuses useful indicators of sex? *Journal of Forensic and Legal Medicine*, *20*, 91–94.

Guerram, A., Minor, J., Renger, S., & Bierry, G. (2014). The size of the human frontal sinuses in adults presenting complete persistence of the metopic suture. *American Journal of Physical Anthropology*, *154*, 621–627.

Guthrie, M. (1967–1971). *Comparative Bantu: An introduction to the comparative linguistics and prehistory of the Bantu languages* (Vol. 1–4). Gregg International Press.

Hannan, M. T., Felson, D. T., Dawson-Hughes, B., Tucker, K. L., Cupples, L. A., Wilson, P. W. F., & Kiel, D. P. (2000). Risk factors for longitudinal bone loss in elderly men and women: The Framingham osteoporosis study. *Journal of Bone and Mineral Research*, *15*, 710–720.

Hans, D., Downs, R. W., Duboeuf, F., Greenspan, S., Jankowski, L. G., Kiebzak, G. M., & Petak, S. M. (2006). Skeletal sites for osteoporosis diagnosis: The 2005 ISCD official positions. *Journal of Clinical Densitometry*, *9*, 15–21.

Hanson, C. L., & Owsley, D. W. (1980). Frontal sinus size in Eskimo populations. *American Journal of Physical Anthropology*, *53*, 251–255.

Henn, B. M., Gignoux, C. R., Jobin, M., Granka, J. M., Macpherson, J. M., Kidd, J. M., Rodriguez-Botigue, L., Ramachandran, S., Hon, L., Brisbin, A., Lin, A. A., Underhill, P. A., Comas, D., Kidd, K. K., Norman, P. J., Parham, P., Bustamante, C. D., Mountain, J. L., & Feldman, M. W. (2011). Hunter-gatherer genomic diversity suggests a southern African origin for modern humans. *Proceedings of the National Academy of Sciences USA*, *13*, 51–54.

International Osteoporosis Foundation. (2020). Osteoporosis. http://wwwiofbonehealthorg/osteoporosis

İşcan, M. Y., Yoshino, M., & Kato, S. (1995). Sexual dimorphism in modern Japanese crania. *American Journal of Human Biology*, *7*, 459–464.

Johannesdottir, F., Allaire, B., & Bouxsein, M. L. (2018). Fracture prediction by computed tomography and finite element analysis: Current and future perspectives. *Current Osteoporosis Reports*, *16*, 411–422.

Jungers, W. L., Falsetti, A. B., & Wall, C. E. (1995). Shape, relative size, and size-adjustments in morphometrics. *Yearbook of Physical Anthropology*, *38*, 137–161.

Karakas, S., & Kavakli, A. (2005). Morphometric examination of the paranasal sinuses and mastoid air cells using computed tomography. *Annals of Saudi Medicine*, *25*, 41–45.

Kawarai, K. F., Teruhiro, O., Kazunori, N., Mehmet, G., Masaaki, F. Y., & Masuda, Y. (1999). Volume quantification of healthy paranasal cavity by three-dimensional CT imaging. *Acta Oto-Laryngologica*, *119*, 45–49.

Keaveny, T. M., Clarke, B. L., Cosman, F., Orwoll, E. S., Siris, E. S., Khosla, S., & Bouxsein, M. L. (2020). Biomechanical computed tomography analysis (BCT) for clinical assessment of osteoporosis. *Osteoporosis International*, *31*, 1025–1048.

Keir, J. (2009). Why do we have paranasal sinuses? *Journal of Laryngology & Otology*, *123*, 4–8.

Kim, D., Lee, U., Park, S., Kwak, D., & Han, S. (2013). Identification using frontal sinus by three-dimensional reconstruction from computed tomography. *Journal of Forensic Sciences*, *58*, 5–12.

Kimmerle, E. H., Ross, A., & Slice, D. (2008). Sexual dimorphism in America: Geometric morphometric analysis of the craniofacial region. *Journal of Forensic Sciences*, *53*, 54–57.

Kirwan, L. P. (1974). Nubia and Nubian origins. *Geographical Journal*, *140*, 43–51.

Kleisner, K., Tureček, P., Roberts, S. C., Havlíček, J., Valentova, J. V., Akoko, R. M., Leongómez, J. D., Apostol, S., Varella, M. A. C., & Saribay, S. A. (2021). How and why patterns of sexual dimorphism in human faces vary across the world. *Scientific Reports*, *11*, 5978. https://doi.org/10.1038/s41598-021-85,402-3

Koertvelyessy, T. (1972). Relationships between the frontal sinus and climatic conditions: A skeletal approach to cold adaptation. *American Journal of Physical Anthropology*, *37*, 161–172.

Krüger, G. C., L'Abbe, E. N., Stull, K. E., & Kenyhercz, M. W. (2015). Sexual dimorphism in cranial morphology among modern South Africans. *International Journal of Legal Medicine*, *129*, 869–875.

Lande, R. (1977). On comparing coefficients of variation. *Systematic Zoology*, *26*, 214–217.

Landsberg, R., & Friedman, M. A. (2001). Computer-assisted anatomical study of the nasofrontal region. *Laryngoscope*, *111*, 2125–2130.

Lundberg, J. O. (2008). Nitric oxide and the paranasal sinuses. *Anatomical Record*, *291*, 1479–1484.

Lundberg, J. O., Farkas-Szallasi, T., Weitzberg, E., Rinder, J., Lidholm, J., Änggård, A., Hökfelt, T., Lundberg, J. M., & Alving, K. (1995). High nitric oxide production in human paranasal sinuses. *Nature Medicine*, *1*, 370–373.

Lynnerup, N., Homøe, P., & Skovgaard, L. T. (1999). The frontal sinus in ancient and modern Greenlandic Inuit. *International Journal of Anthropology*, *14*, 47–54.

Maddux, S. D., & Butaric, L. N. (2017). Zygomaticomaxillary morphology and maxillary sinus form and function: How spatial constraints influence pneumatization patterns among modern humans. *Anatomical Record*, *300*, 209–225.

Maho, J. (2009). NUGL online: The online version of the new updated Guthrie list, a referential classification of the Bantu languages. http://goto.glocalnet.net/mahopapers/nuglonline.pdf

26927691, 2024, 4, Downloaded from https://onlinelibrary.wiley.com/doi/10.1002/ajpa.24899 by University Of Witwatersrand, Wiley Online Library on [20/10/2024]. See the Terms and Conditions (https://onlinelibrary.wiley.com/terms-and-conditions) on Wiley Online Library for rules of use; OA articles are governed by the applicable Creative Commons License

Márquez, S. (2008). The paranasal sinuses: The last frontier in craniofacial biology. *Anatomical Record*, *291*, 1350–1361.

Martin, R., & Saller, K. (1957). *Lehrbuch der Anthropologie.In systematische Darstellung mit besonderer Berücksichtigung der anthropologische Methoden*. Stuttgart, Gustav Fischer.

Matsumura, H., Tanijiri, T., Kouchi, M., Hanihara, T., Friess, M., Moiseyev, V., Stringer, C., & Miyahara, K. (2022). Global patterns of the cranial form of modern human populations described by analysis of a 3D surface homologous model. *Scientific Reports*, *12*(13), 826. https://doi.org/10.1038/s41598-022-15883-3

McLaughlin, R. B., Rehl, R. M., & Lanza, D. C. (2001). Clinically relevant frontal sinus anatomy and physiology. *Otolaryngologic Clinics of North America*, *34*, 1–22.

Michel, J., Paganelli, A., Varoquaux, A., Piercecchi-Marti, M. D., Adalian, P., Leonetti, G., & Dessi, P. (2015). Determination of sex: interest of frontal sinus 3-D reconstructions. *Journal of Forensic Sciences*, *60*, 269–273.

Milella, M., Franklin, D., Belcastro, M. G., & Cardini, A. (2021). Sexual differences in human cranial morphology: Is one sex more variable or one region more dimorphic? *Anatomical Record*, *304*, 2789–2810.

Moideen, S. P., Khizer, H. A. M., Mohan, M., Regina, M., Sheriff, R. M., & Moideen, C. P. (2017). Incidence of frontal sinus aplasia in Indian population. *International Journal of Otorhinolaryngology and Head and Neck Surgery*, *3*, 108–111.

Motawei, S. M., Wahba, B. A., Aboelmaaty, W. M., & Tolba, E. M. (2016). Assessment of frontal sinus dimensions using CBCT to determine sexual dimorphism amongst Egyptian population. *Journal of Forensic Radiology and Imaging*, *6*, 8–13.

Nambiar, P., Naidu, M. D., & Subramaniam, K. (1999). Anatomical variability of the frontal sinuses and their application in forensic identification. *Clinical Anatomy*, *12*, 16–19.

Negus, V. (1957). The function of the paranasal sinuses. *AMA Archives of Otolaryngology*, *66*, 430–442.

Nethan, S. T., Sinha, S., & Chandra, S. (2018). Frontal sinus dimensions: an aid in gender determination. *Acta Scientific Dental Sciences*, *2*, 2–6.

Nikolova, S., Toneva, D., & Georgiev, I. (2016). A persistent metopic suture – Incidence and influence on the frontal sinus development (preliminary data). *Acta Morphologica et Anthropologica*, *23*, 85–92.

Nikolova, S., Toneva, D., Georgiev, I., & Lazarov, N. (2018). Digital radiomorphometric analysis of the frontal sinus and assessment of the relation between persistent metopic suture and frontal sinus development. *American Journal of Physical Anthropology*, *165*, 492–506.

Nikolova, S., Toneva, D., Georgiev, I., & Lazarov, N. (2019). Relation between metopic suture persistence and frontal sinus development. In T. C. Wang (Ed.), *Challenging issues on paranasal sinuses* (pp. 3–23). IntechOpen. https://doi.org/10.5772/intechopen.79376

Noback, M. L., Samo, E., van Leeuwen, C. H. A., Lynnerup, N., & Harvati, K. (2016). Paranasal sinuses: A problematic proxy for climate adaptation in Neanderthals. *Journal of Human Evolution*, *97*, 176–179.

Nowak, R., & Mehls, G. (1977). Die apllasien der sinus maxillaries und frontales unter besenderer Berucksichtigung der pneumatization bei spalttragern. *Anatomischer Anzeiger*, *142*, 441–450.

Patil, N., Karjodkar, F. R., Sontakke, S., Sansare, K., & Salvi, R. (2012). Uniqueness of radiographic patterns of the frontal sinus for personal identification. *Imaging Science in Dentistry*, *42*, 213–217.

Pearson, K., & Davin, A. (1924). On the biometric constants of the human skull. *Biometrika*, *16*, 328–363.

Pélabon, C., Hilde, C. H., Einum, S., & Gamelon, M. (2020). On the use of the coefficient of variation to quantify and compare trait evolution. *Evolution Letters*, *4*, 180–188.

Pondé, J. M., Metzger, P., Amaral, G., Machado, M., & Prandini, M. (2003). Anatomic variations of the frontal sinus. *Minimally Invasive Neurosurgery*, *46*, 29–32.

Prossinger, H. (2001). Sexually dimorphic ontogenetic trajectories of frontal sinus cross sections. *Collegium Antropologicum*, *25*, 1–11.

Quatrehomme, G., Fronty, P., Sapanet, M., Grévin, G., Bailet, P., & Ollier, A. (1996). Identification by frontal sinus pattern in forensic anthropology. *Forensic Science International*, *83*, 147–153.

R Core Team. (2014). *R: A language and environment for statistical testing*. R Foundation for Statistical Computing.

Rae, T. C., & Koppe, T. (2000). Isometric scaling of maxillary sinus size in Hominoidea. *Journal of Human Evolution*, *38*, 411–423.

Rae, T. C., & Koppe, T. (2004). Holes in the head: Evolutionary interpretations of the paranasal sinuses in catarrhines. *Evolutionary Anthropology*, *13*, 211–223.

Rae, T. C., Koppe, T., & Stringer, C. B. (2011). The Neanderthal face is not cold adapted. *Journal of Human Evolution*, *60*, 234–239.

Rennie, C. O., Haffajee, M. R., & Satyapal, K. S. (2017). Development of the paranasal air sinuses in a South African population utilizing three-dimensional (3D) reconstructed models. *European Journal of Anatomy*, *21*, 197–209.

Robles, M., Rando, C., & Morgan, R. M. (2020). The utility of three-dimensional models of paranasal sinuses to establish age, sex, and ancestry across three modern populations: A preliminary study. *Australian Journal of Forensic Sciences*, *54*, 326–345.

Rubiera-Bullen, I. R. F., Rubira, C. M. F., Sarmento, V. A., & Azevedo, R. A. (2010). Frontal sinus size on facial plain radiographs. *Journal of Morphological Sciences*, *27*, 77–81.

Ruiz, C. R., & Wafae, N. (2004). Anatomo-radiological and morphometrical study of the frontal sinus in humans. *Brazilian Journal of Morphological Sciences*, *21*, 53–56.

Sardi, M. L., Joosten, G. G., Pandiani, C. D., Gould, M. M., Anzelmo, M., & Ventrice, F. (2018). Frontal sinus ontogeny and covariation with bone structures in a modern human population. *Journal of Morphology*, *279*, 871–882.

Schillaci, M. A., & Schillaci, M. E. (2022). Estimating the population variance, standard deviation, and the coefficient of variation: Sample size and accuracy. *Journal of Human Evolution*, *171*(103), 230.

Schuller, D. E. (1943). The roentgenologic evaluation of the frontal sinus. *The Laryngoscope*, *53*, 145–157.

Schuster, S. C., Miller, W., Ratan, A., Tomsho, L. P., Giardine, B., Kasson, L. R., Harris, R. S., Petersen, D. C., Zhao, F., & Qi, J. (2010). Complete Khoisan and Bantu genomes from southern Africa. *Nature*, *463*, 943–948.

Schumacher, G. H., Heyne, K. J., & Fanghanel, R. (1972). Zur Anatomie der menschlichen Nasennebenhohlen. 2. Volumetrie. *Anatomischer Anzeiger*, *130*, 132–157.

Selcuk, O. T., Erol, B., Renda, L., Osma, U., Eyigor, H., Gunsoy, B., Yagci, B., & Yilmaz, D. (2015). Do altitude and climate affect paranasal sinus volume? *Journal of Cranio-Maxillo-Facial Surgery*, *43*, 1059–1064.

Shapiro, R., & Schorr, S. (1980). A consideration of the systemic factors that influence frontal sinus pneumatization. *Investigative Radiology*, *15*, 191–202.

Shireen, A., Goel, S., Ahmed, I. M., Sabeh, A. M., & Mahmoud, W. (2019). Radiomorphometric evaluation of the frontal sinus in relation to age and gender in Saudi population. *Journal of International Society of Preventative & Community Dentistry*, *9*, 584–596.

Sokal, R. R., & Rohlf, F. J. (1995). *Biometry. The principles and practice of statistics in biological research* (3rd ed.). Freeman.

Soliman, K. E. A., Al Sheri, F., & AlThaqufi, O. J. (2022). Age correlation of epiphyseal union around wrist joint and its correlation with chronological age: A radiological study in Qassim population, Saudi Arabia. *Australian Journal of Forensic Sciences*, *55*, 605–620. https://doi.org/10.1080/00450618.2022.2043437

Soman, B. A., Sujatha, G. P., & Lingappa, A. (2016). Morphometric evaluation of the frontal sinus in relation to age and gender in subjects residing in Davangere. *Karnataka. Journal of Forensic Dental Sciences*, *8*, 57. https://doi.org/10.4103/0975-1475.176945

Spaeth, J., Krugelstein, U., & Schlöndorff, G. (1997). The paranasal sinuses in CT-imaging: Development from birth to age 25. *International Journal of Pediatric Otorhinolaryngology*, *39*, 25–40.

26927691, 2024, 4, Downloaded from https://onlinelibrary.wiley.com/doi/10.1002/ajpa.24899 by University Of Witwatersrand, Wiley Online Library on [20/10/2024]. See the Terms and Conditions (https://onlinelibrary.wiley.com/terms-and-conditions) on Wiley Online Library for rules of use; OA articles are governed by the applicable Creative Commons License

Steyn, M., & İşcan, M. Y. (1998). Sexual dimorphism in the crania and mandibles of South African whites. *Forensic Science International*, *98*, 9–16.

Tastemur, Y., Ozturk, A., Sabanciogullari, A., Salk, I., Tetiker, H., Altun, A., & Sabanciogullari. (2022). The relationship between anatomical variations and paranasal sinus volumes with climate and altitude. *Cumhuriyet Medical Journal*, *44*, 420–429.

Tatlisumak, E., Asirdizer, M., Bora, A., Hekimoglu, Y., Etli, Y., Gumus, O., & Keskin, S. (2017). The effects of gender and age on forensic personal identification from frontal sinus in a Turkish population. *Saudi Medical Journal*, *38*, 41–47.

Tatlisumak, E., Ataç, M. S., & Koc, S. (2016). Sexual dimorphism in cranial size among contemporary Turkish adults. *Homo*, *67*, 283–294.

Tatlisumak, E., Ovali, G. Y., Asirdizer, M., Aslan, A., Ozyurt, B., Bayindir, P., & Tarhan, S. (2008). CT study on morphometry of frontal sinus. *Clinical Anatomy*, *21*, 287–293.

Tatlisumak, E., Ovali, G. Y., Aslan, A., Asirdizer, M., Zeyfeoglu, Y., & Tarhan, S. (2007). Identification of unknown bodies by using CT images of frontal sinus. *Forensic Science International*, *166*, 42–48.

Toneva, D. H., Nikolova, S. Y., Tasheva-Terzieva, E. D., Zlatareva, D. K., & Lazarov, N. E. (2022). Sexual dimorphism in shape and size of the neurocranium. *International Journal of Legal Medicine*, *136*, 1851–1863.

Török, L. (2008). The frontier region between ancient Nubia and Egypt 3700–500 AD. Probleme der Ägyptologie. In *Between two worlds* (p. 29). Brill.

Tranquilli Leali, P., Doria, C., Zachos, A., Ruggiu, A., Milia, F., & Barca, F. (2009). Bone fragility: Current reviews and clinical features. *Clinical Cases in Mineral and Bone Metabolism*, *6*, 109–113.

U.S. Department of Health and Human Services. (2004). Bone health and osteoporosis: A report of the surgeon general. U.S. Department of Health and Human Services, Office of the Surgeon General, Rockville, MD.

Uthman, A. T., Al-Rawi, N. H., Al-Naaimi, A. S., Tawfeeq, A. S., & Suhail, E. H. (2010). Evaluation of frontal sinus and skull measurements using spiral CT scanning: An aid in unknown person identification. *Forensic Science International*, *197*, 124.e1–124.e7.

Uytterschaut, H. T. (1986). Sexual dimorphism in human skulls. A comparison of sexual dimorphism in different populations. *Human Evolution*, *1*, 243–250.

Vance, H. A. (2021). The influence of ancestry, sex, and age on the morphology of the frontal sinus in black and white individuals. (MA Thesis). University of Montana.

Wainwright, S. A., Biggs, W. D., Currey, J. D., & Gosline, J. M. (1976). *Mechanical design in organisms*. Halsted Press.

Wallace, I. J., Marsh, D., Otárola-Castillo, E., Billings, B. K., Mngomezulu, V., & Grine, F. E. (2020). Secular decline in limb bone strength among South African Africans during the 19th and 20th centuries. *American Journal of Physical Anthropology*, *172*, 492–499.

Ward, S. C., & Brown, B. (1986). The facial skeleton of *Sivapithecus indicus*. In D. R. Swindler & J. Erwin (Eds.), *Comparative primate biology* (Vol. 1, pp. 413–452). Alan R. Liss.

Wendorf, F., & Schild, R. (1976). *Prehistory of the Nile Valley*. Academic.

Wolfowitz, B. L. (1974). Pneumatization of the skull of the southern African Negro. (PhD Thesis). University of the Witwatersrand, Johannesburg.

Wood, C. G., & Lynch, J. M. (1996). Sexual dimorphism in the craniofacial skeleton of modern humans. In L. F. Marcus, M. Corti, A. Loy, G. J. P. Naylor, & D. E. Slice (Eds.), *Advances in morphometrics. NATO ASI series* (Vol. 284, pp. 407–414). Springer.

Yun, I. S., Kim, Y. O., Lee, S. K., & Rah, D. K. (2011). Three-dimensional computed tomographic analysis of frontal sinus in Asians. *Journal of Craniofacial Surgery*, *22*, 462–467.

Zollikofer, C. P. E., Ponce de León, M. S., Schmitz, R. W., & Stringer, C. B. (2008). New insights into mid-late Pleistocene fossil hominin paranasal sinus morphology. *Anatomical Record*, *291*, 1506–1516.

Zulkiflee, N. D. I., Alias, A., Singh, M. K. C., Pritam, H. M. H., Chung, E., Sakaran, R., Zaidun, N. H., & Choy, K. W. (2022). Sexual dimorphism of frontal sinus: A 2- dimensional geometric morphometric analysis on lateral skull radiographs. *Forensic Imaging*, *29*(200), 506. https://doi.org/10.1016/j.fri.2022.200506

How to cite this article: Greening, V. A., Hernandez, E., Mongle, C. S., Billings, B. K., Mngomezulu, V., Wallace, I. J., & Grine, F. E. (2024). Variation, sexual dimorphism, and enlargement of the frontal sinus with age in adult South Africans. *American Journal of Biological Anthropology*, *183*(4), e24899. https://doi.org/10.1002/ajpa.24899

26927691, 2024, 4, Downloaded from https://onlinelibrary.wiley.com/doi/10.1002/ajpa.24899 by University Of Witwatersrand, Wiley Online Library on [20/10/2024]. See the Terms and Conditions (https://onlinelibrary.wiley.com/terms-and-conditions) on Wiley Online Library for rules of use; OA articles are governed by the applicable Creative Commons License