

https://dspace.org/

The clinical presentation and management of South African children with osteogenesis imperfecta

Oduah, George Onuwa

2016-10-25
http://hdl.handle.net/10539/21285

Downloaded from a DSpace repository. https://dspace.org/

THE CLINICAL PRESENTATION AND MANAGEMENT OF SOUTH AFRICAN CHILDREN WITH OSTEOGENESIS IMPERFECTA

Dr George Onuwa Oduah

A research report submitted to the Faculty of Health Sciences, University of the Witwatersrand, Johannesburg, in partial fulfilment for the degree of Master of Medicine in Orthopaedic Surgery (MMed Orth)

Johannesburg © 2015

DECLARATION

I, Dr George Onuwa Oduah, declare that this thesis is my own work. It is being submitted for the degree of Master of Medicine in Orthopaedic Surgery at the University of the Witwatersrand, Johannesburg. It has not been submitted before for any degree or examination at this or any other university.

Signature ……. Date …….

DEDICATION

I dedicate this project to Olisebuluwa, the God Almighty

PRESENTATIONS ARISING FROM THIS STUDY

Management of Osteogenesis Imperfecta at the Chris Hani Baragwanath Hospital presented at the 59TH Congress of the South African Orthopaedic Association, Sun City, North West Province, South Africa, on the 3rd of September 2013.

ABSTRACT

Background:

Osteogenesis imperfecta (OI) is a genetically inherited metabolic bone disorder that results in multiple fractures and deformities in children. The treatment of OI has undergone tremendous improvement in the last two decades world-wide.

Aims:

To review the clinical presentation and management of fractures in children with osteogenesis imperfecta.

Methods:

A retrospective audit of patients treated for OI at Chris Hani Baragwanath Academic Hospital (CHBAH), from January 2000 to December 2011 was performed.

Results:

Seventy eight patients with OI were reviewed. The male to female ratio was 1:1.1. The median age at presentation was 20 months. The patients were classified according to the Sillence classification. The majority of patients were type III (49%) and type IV (29%). Twenty patients (26%) had a first degree relative with OI.

All the patients received bisphosphonate and of these patients, 73 (94%) received intravenous bisphosphonate therapy and the remaining 6% received oral bisphosphonates. The most common long bone fractures were of the femur (93 fractures) and tibia (60 fractures).

Sixty six long bones (49 patients) received intramedullary rodding (IM). The mean age at time of surgery was 7 years. The indication for osteotomy and IM rodding was fracture of

the long bones. Fifty one long bones out of the sixty six long bones rodded (77%) underwent revision surgery for complications - 49% (25/51) had rod migration, 39% (20/51) had peri-implant fractures and 12% (6/51) had rod breakage.

Conclusion:

An ongoing multidisciplinary approach to the management of children with OI is of paramount importance. The prevalence of complications in those patients operated was high but compares favourably with the international literature. Use of elongating rods may further reduce the rate of re-rodding. There is an urgent need to improve the level of awareness of this rare condition amongst health professionals in order to facilitate prompt diagnoses and early referral.

ETHICS CLEARANCE

Ethics Clearance certificate number: M120415

ACKNOWLEDGEMENTS

I am grateful to both supervisors, Dr Gregory Firth and Dr Kebashni Thandrayen, for their assistance throughout the course of this project.

I will like to thank the Head of school of Clinical Medicine and the previous Head of Orthopaedic Surgery, Prof M. Lukhele and the current Head of Orthopaedic Surgery Prof M. T Ramokgopa for their support.

I am grateful to Ms Busisiwe Mabaso for helping with the data collection and photography.

TABLE OF CONTENTS

Title Page ……..…… i

Declaration ……..……..... ii

Dedication…….…….……..… iii

Presentation Arising From This Study……..…….. iv

Abstract …….……...……..… v

Ethics Clearance ……..vii

Acknowledgements ……..……..viii

Table of Contents …….... ix

List of Figures …….……...…….. xiii

List of Tables ……..…….…..……..... xvi

Nomenclature …….…….……..xvii

Chapter One ……...…….…….……. 1

1.0 Introduction …….……..….……..…….. 1

1.1 Historical Background …….……..…...…… 1

1.2 Prevalence of Osteogenesis Imperfecta……..…….…….……...…… 1

1.3 Clinical Manifestations …….……..……....1

1.4 Classifications …… 2

1.5 Treatment ……...……... 6

1.5.1 Medical Treatment …….…….…….…….. 6

1.5.2 Surgical Treatment …….……..……..…. 7

1.5.3 Simple versus Telescoping Rod ……..…….…….……..… 8

1.5.4 Complications of IM Rodding…….…….… 8

1.5.5 Justification for This Study ……...……..…… 9

Chapter Two …….. 10

2.0 Materials and Methods …….……... 10

2.1 Aim.…….…….…… 10

2.2 Objectives …….....…….…...……..… 10

2.3 Study Design ……..…….. 10

2.4 Methods ……...……. 10

2.5 Inclusion Criteria ……..……..……. 11

2.6 Exclusion Criteria ……...…….……. 11

2.7 Statistical Analysis …….…….…….…….. 11

2.8 Ethical Considerations…….. 11

2.9 Management of OI at CHBAH. ……..... 12

2.10 Non-Operative Treatment of Fractures. ...…….…….……14

2.11 Operative Treatment...…….……... 15

2.12 Indications for Operative Treatment. …… 15

2.13 Choice of IM Devices……;…… 15

2.14 Preoperative Preparation …… 16

2.15 Technique of IM Rodding ……..…….….... 16

2.16 Open Technique ……...…….. 16

2.17 Correction of Coxa Varus…….……...…….….. 21

2.18 Postoperative Rehabilitation……..……. 25

Chapter Three ……..…….…….. 27

3.0 Results …….……. 27

3.10 Demographic Data……...…….27

3.20 Clinical Results……...……..…….. 29

3.30 Types of Osteogenesis Imperfecta……..…….…….……...34

3.40 Average Number Of Fractures……...……. 35

3.50 Pattern of Fracture Distribution…….…….…. 36

3.60 Treatment Results..……..…..……..……37

3.61 Medical Treatment ……...……..…… 37

3.62 Non-Operative Treatment ……...……..…….…….37

3.63 Operative Treatment ……..……..…… 39

3.64 Complications of Rodding….……. 39

3.65 Indications for Rod Revision……..……..…… 45

Chapter Four…….……46

4.0 Discussion…..…….…….…….. 46

Chapter Five……..…….……. 51

5.0 Conclusions…..…….……..…….. 51

6.0 References……..…… 53

7.0 Appendices..……..…… 57

7.1 Appendix A: Data Collection Form …….…… 57

7.2 Appendix B: Ethics Clearance Certificate …….…….. 63

7.3 Appendix C: Plagiarism Screen Report…….…….. 64

LIST OF FIGURES

Figures	Title	Page
Figure 2.1:	This is an intraoperative clinical picture illustrating the extensive lateral approach and the multiple osteotomy of the right femur in a child with OI	18
Figure 2.2:	Intra-operative photograph illustrates the “shish kebab” method of IM rodding	19
Figure 2.3:	Postoperative radiograph of left tibia following multiple osteotomies and IM fixation with the William’s rod.	20
Figure 2.4:	Radiograph illustrates bilateral bowing of the femurs and coxa varus.	22
Figure 2.5:	This is an intraoperative clinical picture illustrating the correction of coxa varus. Note the two parallel K wires going into the neck and head of the femur.	23
Figure 2.6:	Post-operative radiograph of the right femur following IM rodding with FD rod and tension band wire fixation for correction of coxa varus	24
Figure 2.7:	This clinical picture illustrates a below knee cast and an anti-rotation bar in the immediate postoperative period following IM rodding (using Fassier Duval rod) of the left femur in a child with OI.	26

Figure 3.1:	A map of South Africa illustrating the distribution of patients from the different provinces.	28
Figure 3.2:	Photograph illustrates blue sclera and triangular face in a two-year-old female child with type III osteogenesis imperfecta	30
Figure 3.3:	Photograph illustrates sun set appearance of a three-year-old male child with type III osteogenesis imperfecta complicated with hydrocephalus as a result of basilar invagination. Note the blue sclerae, the triangular facies and the sun setting appearance of the eyes as a result of raised intracranial pressure.	31
Figure 3.4	Radiograph of a five-year-old child with type III OI illustrating a transverse fracture of the right femur and bowing deformity of both femurs. Note the malunited fractures of both femurs and the transverse growth arrest lines (of Harris's) as a result of bisphosphonate use.	32
Figure 3.5	Photograph illustrates limb length discrepancy as a result of differential bowing of the femurs and coxa vara of the left hip	33
Figure 3.6	Illustrates the number of fractures in various parts of the body	36
Figure 3.7	Flow Diagragm for Fractures and Intramedulary Rodding	37
Figure 3.8	Radiograph of a right forearm fracture treated in a POP in a child with OI.	38
Figure 3.9	Radiograph illustrates proximal rod migration from the left	40

femur

Figure 3.10 Photograph illustrates tenting of the skin from rod migration out of the bone, a complication of IM rodding 41

Figure 3.11 Radiograph illustrates peri-implant fracture at the distal end of the rod 42

Figure 3.12 Radiograph illustrates rod breakage and right femur fracture at same level 43

Figure 3.13 Radiograph illustrates bilateral rodding of both femurs with proximal migration of the rod in the left femur. Note the coxa varus on the left femur and the tension band construct for the correction of coxa varus on the right femur with the K wire backing out. 44

Figure 3.14 A Flow Chart of reasons for rod revision 45

LIST OF TABLES

Tables	Titles	Pages
Table 1.1:	The different types of OI, mutations and the characteristic clinical features	5
Table 2.1	Pamidronate dosage (maximum dose: 60mg/d)	13
Table 2.2	Dilution of pamidronate	13
Table 2.3	Zoledronic acid dosage (4MG/5ML VIAL, Maximum single dose not >4mg)	14
Table 3.1:	The frequency of the various types of osteogenesis imperfecta	34
Table 3.2:	Average number of fractures in the different types of OI	35

NOMENCLATURE

CEO ……..…. Chief Executive Officer

CHBAH...……..…..…… Chris Hani Baragwanath Academic Hospital

DEXA …… Dual Energy X-ray Absorptiometry

DHS……..…….……..Dynamic Hip Screw

FD rods ……..……..…. Fassier Duval rods

FLOOP …….…. Flow Volume Loop

K-wire ……..…….Kirschner wire

OI …….…….. Osteogenesis Imperfecta

POP ……..…….. Plaster Of Paris

IM …….…….. Intramedullary

HREC …….....……Human Research Ethics Committee

CHAPTER ONE

1.0 INTRODUCTION

1.1 HISTORICAL BACKGROUND

The first scientific description of osteogenesis imperfecta (OI) was provided by Swedish army surgeon Olaus Jakob Ekman in 1788 (1). In his PhD thesis entitled *Congenital Osteomalacia*, Ekman described hereditary bone fragility in three family generations (2). Vrolik in 1849 was the first man to coin the term “osteogenesis imperfecta’’ meaning ´abnormally formed bone’ (1, 3). The presence of Wormian bone mosaic of the skull, abnormal teeth colourations and bowed legs in an Egyptian mummy from 1000 BC suggests that the disease has been with man since the ancient times (3). Legend has it that Ivar Benlos, “Ivar the Boneless”; the eldest son of the Danish legendary King Regnar Lodbrog who led the Scandinavian invasion of England in the 9th century had OI. He was reported to have had legs as soft as cartilage, so that he was unable to walk and had to be carried about on a shield into battle. However these assumptions could not be confirmed as his skeleton was exhumed and burned by William the Conqueror (3).

1.2 PREVALENCE OF OSTEOGENESIS IMPERFECTA

OI has been described in every race and continent of the world. The prevalence of OI is approximately 16 cases per million index patients (3). It comprises of a phenotypically and genotypically heterogeneous group of inherited disorders (3).

1.3 CLINICAL MANIFESTATIONS

The major clinical manifestations of OI are frequent, multilevel fractures that cause limb deformities. Frequent fractures resulting from bone fragility lead to malunion and bowing,

which render the bone more prone to recurrent fractures. The bowing of bone may occur even in the absence of a fracture or in the presence of multiple micro-fractures. Musculoskeletal deformities are induced by defects in types IA1 and IA2 collagen, which is the primary component of the protein matrix in bone, tissues, and organs. Bone tissue anomalies are the most visible manifestation of OI (3).

Extra-skeletal tissues and organs affected by type I collagen defects include the sclerae, dentin, ear, skin, vessels, capillaries, and heart valves (1). Dentinogenesis imperfecta is seen in about 30% of children with OI and the teeth have a characteristic soft and translucent brownish appearance (3). The teeth are carious, shortened, susceptible to cracking and the enamel wears easily (3).

The blue sclerae in OI is as a result of increased translucency of the cornea, thus revealing the underlying uveal pigment and blood vessels (3).

1.4 CLASSIFICATIONS

Several classifications have been adopted to describe in detail the clinical subtypes of OI in order to permit our appreciation of the natural history of the disorder, and to guide the clinician in the treatment of osteogenesis imperfecta (3). The first classification of OI was provided by Looser, in 1906 (4). He classified OI into two types using the timing of the first fracture as a basis for his classification: *congenita* (fractures at birth) and *tarda* (fractures after the perinatal period), with the congenital type having a poorer prognosis (3).

OI tarda was later sub-classified by Seedorff in 1949, into *gravis* (fracture occurring within the first year of life) and *levis* (fractures occurring after the first year of life) (3). He noted that tarda gravis was associated with the development of severe deformities and disability (3).

However, Sillence, in 1979, was the first to provide an extensive classification of OI, which is still in use today (5). He classified OI into four types using genetic and clinical criteria as the basis for his classification (type I, mild; type II, lethal in the perinatal period; type III, severe, with progressive deformity in the absence of surgical intervention; type IV, moderate to severe) (5). Sillence predicted that OI could be classified into more than 12 types (5).

Glorieux and colleagues described type V OI in 2000 (6). They described seven patients with type IV OI, who were different from other type IV OI patients and called this disease 'entity OI type V' (6). The characteristic features of this group included hypertrophic callus development after fracture, calcification of the interosseous membrane at the forearm and hyperdense metaphyseal bands. Blue sclerae and dentinogenesis imperfecta were absent. Glorieux and colleagues described this disease as a new form of an autosomal dominant type of OI (6).

Glorieux and colleagues also described type VI OI in 2002 (7), which is characterized by frequent fractures, vertebral compression, long-bone deformity, normal coloured sclerae, and the absence of dentinogenesis imperfecta. Serum alkaline phosphatase is elevated on laboratory analysis. Histologic data show an abundance of osteoid, unmineralized bone matrix in the absence of hypocalcaemia (7).

Also in 2002, Ward and colleagues reported the clinical, radiological and histological features of eight patients (four children and four adults) with a different form of autosomal recessive OI (8). They called this form of the disease OI type VII, in accordance with the already established numeric classification for OI forms (8).

The type VII OI has a moderate to severe phenotype, characterized by fractures at

birth, blue sclerae, and early deformity of the lower extremities. Other features include coxa vara, osteopenia and rhizomelia. Histomorphometrically, it is similar to OI type I in that there is decreased cortical width and trabecular number, increased bone turnover, and preservation of the birefringent pattern of lamellar bone (8).

OI Types VIII to type XV, like previously described types of OI, were subsequently described in the order in which they were discovered and have an autosomal recessive inheritance pattern (9). Type XV also has autosomal dominant pattern of inheritance and it was identified in families with early osteoporosis (9). The different types of OI, mutations and the phenotypes are illustrated in table 1.1(9)

Arthrogryposis multiplex congenita has been described in patients with OI. A condition known as Bruck syndrome (10). These OI patients may presents with flexion contractures and pterygia at the elbows or knees, adducted thumbs, bilateral equinovarus feet, and torticollis (10).

Table 1.1: The different types of OI, mutations and the phenotypes (9)

Type of OI	Inheritance	Phenotype	Genetic defect
I	AD	Mild	COL1A1
	X-linked	Mild	PLS3
II	AD	Lethal	COL1A1 orCOL1A2
III	AD	Progressive deformity	COL1A1 orCOL1A2
IV	AD	Moderate	COL1A1 orCOL1A2
V	AD	Moderate, hypertrophic callus and ossification of the interosseous membrane	IFITM5
VI	AR	Moderate to severe	SERPINF1
VII	AR	Severe to lethal	CRTAP
VIII	AR	Severe to lethal	LEPRE1
IX	AR	Severe to lethal	PPIB
X	AR	Severe	SERPINH1
XI	AR	Progressive deformity, contractures	FKBP10
XII	AR	Moderate	SP7
XIII	AR	Severe	BMP1
XIV	AR	Variable severity	TMEM38B
XV	AR AD	Variable severity Early-onset osteoporosis	WNT1

Sillence et al proposed in 1979 that there is genetic heterogeneity in OI (5). In recent years, there have been some interesting discoveries concerning new genes that are responsible for the newly classified types of OI (11, 12). At present 17 genetic causes of OI and closely related disorders have been identified and more causes may be found in the future (12).

1.5 TREATMENT

1.5.1 MEDICAL TREATMENT

The management of OI before the 1990s essentially entailed rehabilitation, physiotherapy, and corrective surgery (13). The overall aim was for each patient to reach his or her potential in terms of mobility and functional capabilities (1, 8). Several forms of medical therapy such as vitamin D, fluoride, and calcitonin have been tried to enhance bone quality with no significant benefit (14).

Recent studies have shown that cyclical intravenous therapy with bisphosphonates improves the clinical course in children and adolescents with moderate to severe forms of OI (1). The rationale for the use of bisphosphonates, which are effective anti-resorptive agents, was seen in Glorieux's histomorphometric studies, which revealed a high bone turnover rate in patients with OI (14). The disuse bone loss which is caused by impaired ambulation also contributes to frequent fractures, deformities, and chronic pain (14).

Montpetit et al showed that a single cycle of intravenous pamidronate in children with severe forms of OI increased their isometric grip strength remarkably and this increase was maintained for up to 2 years (15). It has been shown in several studies that the cyclic intravenous use of pamidronate in children with severe OI results in increase in bone density, decrease in fracture rate and decreased bone pain and increased ambulation (15,

16). Zoledronic acid is the preferred bisphosphonate in some institutions because studies have shown that regulation of bone formation and repairs are better at low concentrations (17). The improvement in lumbar spine bone mineral density at 12 months has been shown to be better with the use of zoledronic acid compared to pamidronate (16). Histomorphometric studies have shown that the reduced osteoclast activity with zoledronic acid treatment results in gains in cortical thickness and trabecular bone (1) and volume (14).

1.5.2 SURGICAL TREATMENT

Fractures can occur in OI patients even while they are on bisphosphonate therapy. Surgical fracture stabilization is therefore necessary in order to achieve pain relief and early rehabilitation. Multilevel osteotomy, realignment and IM rodding is invaluable in correction of deformities of long bone.

The use of plate osteosynthesis is contraindicated for fracture fixation in osteogenesis imperfecta because of the risk for stress fractures at the superior and inferior end of the plate and inadequate screw fixation (18)

Guidelines for the management of acute fractures in children living with OI are yet to be established and the standard treatment of fractures of long bones consists mostly of intramedullary (IM) rodding with a number of devices that are currently available (19). The common problem encountered with IM devices is the difficulty of rod insertion across a physis through a narrow and deformed medullary canal (20).

The main objectives of surgical treatment of OI are to reduce disability and correct deformity, to enable the child to achieve relative independence in activities of daily living and to attain the greatest degree of mobility that is possible (3).

1.5.3 SIMPLE VERSUS TELESCOPIC ROD

Sofield and Millar introduced the concept of multiple osteotomies and IM rodding to realign bones for children with OI in 1959 (21). This so called ‘shish kebab’ technique reduced the frequency of fractures and achieved an acceptable correction of deformity of the extremities. Nonexpendable rods such as Rush nails, William’s and Kuntscher’s rods were used for the ‘shish kebab’ technique. These rods can be outgrown resulting in angulation and fracture in areas of the bone that are no longer splinted beyond the extremities of the rod (21). In an effort to solve this problem, Bailey and Dubow designed the first expandable telescopic rod in 1963 (13). As anticipated, the time interval between the initial operation and revision has increased remarkably with the use of this device (13).

1.5.4 COMPLICATIONS OF IM RODDING

There are however other potential problems with the use of IM rods, such as a much higher need for revision surgeries to ensure adequate rod elongation (13). Zionts reported both major and minor complications with the use of Bailey-Dubow rods in a series of 15 children with OI (13). The major complications included external migration, absence of elongation with fracture, internal migration with fracture, injury of the physis, bent rod, rod displacement into the joint, backing out of the proximal femoral rod, and severe external rotation. Minor complications included internal migration without fracture, absence of elongation, detachment of the T-piece, and superficial infection (13).

1.5.5 JUSTIFICATION FOR THIS STUDY

OI in South Africa is mainly treated in tertiary hospitals. The prospect of an average South African child with OI receiving adequate treatment and improved quality of life depends on accurate diagnosis and prompt referral to a dedicated OI clinic. The treatment of children with OI has undergone tremendous improvement in the last two decades worldwide. It remains to be established whether the results of our treatment are comparable to those of the rest of the world.

CHAPTER TWO

2.0 MATERIALS AND METHODS

2.1 AIM:

To review the clinical presentation of fractures in South African children with osteogenesis imperfecta and their management and outcome at the Chris Hani Baragwanath Academic Hospital (CHBAH), Soweto, South Africa.

2.2 OBJECTIVES:

1. To determine the rate, pattern and distribution of fractures in this population of patients with osteogenesis imperfecta.

2. To determine the type, indication, timing, outcomes and complications of surgical treatment in the same population.

2.3 STUDY DESIGN:

A retrospective audit of patients treated for osteogenesis imperfecta was done using an existing pool of patients in the Paediatric Department (Metabolic Unit) at CHBAH, from January 2000 till December 2011.

2.4 METHODS:

All the information was retrieved from the hospital files and from the stored radiographs of each patient. A data collection form (Appendix A) designed by the principal investigator was completed for each patient. The information that was gathered from the hospital file included the following: demographic data, the clinical presentation (signs and symptoms) and the type of treatment received and the outcome of the treatment, which was assessed

clinically and radiologically. The data collection was also inclusive of the complications of surgical interventions such as rod migration, re-fracture and reoperations.

2.5 INCLUSION CRITERIA:

1. The diagnoses of OI were made based on clinical and radiological features assessed by expert Consultants in the field of Paediatric Metabolic Bone disease.

2.6 EXCLUSION CRITERIA:

1. Patients with insufficient medical records.

2.7 STATISTICAL ANALYSIS:

Data was entered into Microsoft Excel spreadsheets and was subsequently imported into Statistica statistical software version 10.0 (Statsoft, USA). Standard statistical calculations were performed. Parametric, continuous variables were described using means and standard deviations. Medians and interquartile ranges were used for non-parametric data. Categorical variables were described using frequencies and percentages.

2.8 ETHICAL CONSIDERATIONS:

The University of the Witwatersrand's Human Research Ethics Committee (HREC) granted ethical approval. Ethics clearance number: M120415 (Certificate is attached as Appendix B).

The data collection form did not contain any information that would make it possible to identify the patients in the study such as the name, date of birth, hospital number or physical address. A written permission was given by the Chief Executive Officer (CEO) of the CHBAH to audit the data.

2.9 MANAGEMENT OF OSTEOGENESIS IMPERFECTA AT CHBAH

The management of children with osteogenesis imperfecta in our institution, CHBAH, is on a multi-disciplinary basis. This involves the paediatricians, orthopaedic surgeons, radiologists, geneticists, physiotherapists, occupational therapists, nurses and social workers. There is an active interaction amongst the various disciplines. There is as yet no existing combined multi-disciplinary clinic, but we look forward to establishing this in the future.

There is a weekly-dedicated OI clinic at the Metabolic Bone Disease Clinic at CHBAH. The patients are seen by paediatricians who are knowledgeable in the field of Metabolic Bone Disease and Paediatric Endocrinology and Metabolism. Patients are referred by local clinics, general practitioners and orthopaedic surgeons. The referral regions of the patients are mainly from the Gauteng, Mpumalanga and North West provinces.

The initial clinical assessment and clinical workup is done in the dedicated OI clinic. The history of OI in a first degree relative is enquired as well as the occurrence and frequency of fractures. The presenting clinical features are documented.

The parents and caregivers are educated on the condition and allowed to ask questions. A communication link is established between the clinic and caregivers. The caregivers are allowed to call the clinic to ask questions and book clinic appointments. Parents in need of social support are referred to the social workers. Patients with fractures or deformities are referred to the Paediatric Orthopaedic clinic, usually on the same day as the Metabolic Clinic.

All the patients received bisphosphonate therapy. Prior to 2008, patients received pamidronate therapy and thereafter the choice of bisphosphonate was zoledronic acid.

Most of the patients received intravenous zoledronic acid (94%). Only a few of the patients were given oral bisphosphonates (6%).

The pamidronate regime is as follows (Table 2.1 and 2.2) (22):

Table 2.1 Pamidronate dosage (maximum dose: 60mg/d) (22)

AGE	DOSAGE	FREQUENCY
<2 years	0.5mg/kg/day for three days	2 monthly
2.1-3 years	0.75mg/kg/day for three days	3 monthly
>3.1 years	1.0mg/kg/day for three days	4 monthly

Table 2.2 Dilution of Pamidronate (22)

Pamidronate (mg)	Normal saline (ml)	Administration rate (ml/h)
0-5	50	15
5-10	100	30
10-15	150	45
15-25	250	75
25-50	500	150
50-60	600	180

The zoledronic acid regime is as follows (Table 2.3) (22):

Table 2.3 Zoledronic acid dosage (4mg/5ml Vial, maximum single dose not >4mg) (22)

AGE	DOSAGE AND FREQUENCY
≥ 3 months and < 1 year	0.025mg/kg diluted in 50mls NS over 30 minutes every 3 months
> 1 year	0.05mg/kg diluted in 100mls NS over 30 minutes every 6 months

The urea, creatinine, serum calcium, phosphate and alkaline phosphate levels are checked on a yearly basis. We do not stop the use of bisphosphonates if a fracture occurs and administer intravenous bisphosphonates at least four months postoperatively. Studies have however shown that bisphosphonates do not impair fracture healing but may impair the healing of osteotomies (23, 24). Baseline Dual Energy X-ray Absorptiometry (DXA) scans are done on all patients if feasible and thereafter on a yearly basis.

2.10 NON-OPERATIVE TREATMENT OF FRACTURES

A number of patients with long bone fractures were treated non-operatively. We do not apply any absolute indication for treating a fracture non-operatively. Each patient is treated individually. However, we tend to treat a fracture non-operatively if it involves the long

bones of the upper extremities, occurs before walking age i.e. less than two years of age and if the medullary canal is too small for rodding. The modalities of non-operative treatment include the use of back slab, circular Plaster of Paris (POP), gallows traction, skin traction or bed rest.

2.11 OPERATIVE TREATMENT

2.12 INDICATIONS FOR OPERATIVE TREATMENT

Our indications for operative treatment were lower limb long bone fractures in children older than two years of age.

2.13 CHOICE OF IM DEVICES: STATIC VERSUS TELESCOPIC RODS

The IM devices are broadly classified into two major categories: the Static rods (Williams' rods and Rush nails) and the telescoping or elongating rods (Sheffield, Baily-Dubow, and Fassier Duval). The choice of IM device is influenced by the clinical features, efficacy of the implant in preventing fractures, the frequency of complications, the technical details of surgery and the cost of the implant. In our institution, there are essentially two types of IM devices available for use. The devices are the Williams' rods and more recently we have been able to motivate for the Fassier Duval rods, which are relatively expensive.

Our current indication for the use of the FD rods is for the fixation of osteotomy or fractures of the femur in a child with OI who is already walking and has reasonable potential for growth. We have limited experience with the use of FD rods in the tibia but it is reported in the literature that the complication of elongating rods are relatively more common in the tibia compared to the femur (25).

A number of studies have shown that the uses of the newer elongating rods delay the need to revise these implants and lead to a significant reduction in implant complication (26). However, Wilkinson et al did not find any difference when they compared the rod revision interval between the elongating and the non-elongating rods (27).

2.14 PREOPERATIVE PREPARATION

Our preoperative protocol for patients with OI is similar to that for other elective paediatric procedures. We pay particular attention to the haemoglobin level as OI patients have the tendency for significant intraoperative and post-operative bleeding (28). Blood is cross-matched and ordered on standby. Preoperative chest X-ray is mandatory. Performing a FLOOP (Flow volume Loop) is a challenge in the very young patients. OI patients may have reduced lung capacity with under-developed lungs especially in the presence of kyphoscoliosis (29). The risk of hypermetabolic syndrome during surgery, which may manifest as heat intolerance or hyperthermia, hyperhidrosis, tachycardia, tachypnea and hypercarbia is discussed with the parents (1).

2.15 TECHNIQUE OF IM RODDING

2.16 OPEN TECHNIQUE

The usual surgical technique performed on the femur is the Sofield Millar technique via a lateral approach (21). The femur is almost completely exposed. The sites for the osteotomies are marked and the multiple osteotomies carried out with the oscillating saw. Figure 2.1 illustrates the multiple osteotomies. Care is taken to shorten the bone to avoid tension on the fragments.

When necessary the individual bony segments are removed and reamed individually. This method gave rise to the name “shish kebab” technique (figure 2.2)



Figure 2.1: This is an intraoperative clinical picture illustrating the extensive lateral approach and the multiple osteotomies of the right femur in a child with OI.

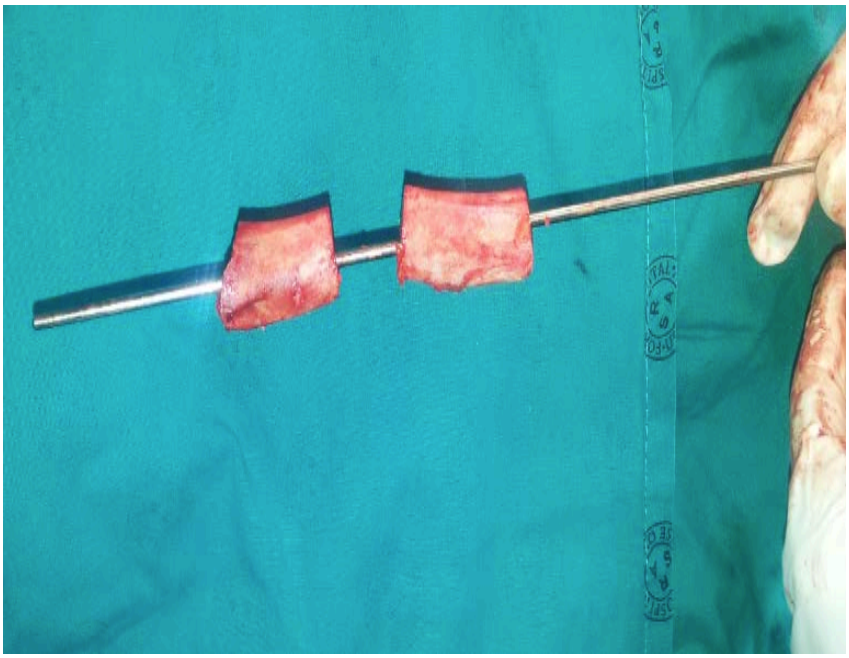

Figure 2.2: Intra-operative photograph illustrating

the “shish kebab” method of IM rodding.



Figure 2.3: Postoperative radiograph of left tibia following multiple osteotomies and IM fixation with the William's rod.

2.17 CORRECTION OF COXA VARA

Coxa vara is a neck shaft angle of less than 110 degrees (30). Figure 2.4 is an X-Ray illustrating bilateral coxa vara in a child with OI. The correction of coxa vara in patients with OI is technically difficult. The use of paediatric DHS (dynamic hip screw) or blade plate is not indicated because of the poor bone quality. There is the risk of fracture below the plate and screw fixation (30). There is often the need to correct the coxa vara and fix an ipsilateral mid shaft fracture or to do a multi-level osteotomy for deformity correction at the same operation. Fixing these two fractures with the same implant poses a formidable challenge.

Fassier and Glorieux were the first to describe the technique for the correction of coxa vara that is now widely adopted (30). Robertson et al also reported on the correction of coxa vara in four patients (five hips) with OI using this technique in South Africa (31). This technique entails the initial correction of the femoral deformity. The femur is rodded with William's rod or the FD rod with careful attention to place the femoral neck in valgus. Two parallel k-wires are inserted into the neck and head of the femur. The two K-wires are used as "joysticks" to achieve the correction of the desired neck shaft angle of greater than 130 degrees (30). The distal ends of the two K-wires are then bent and anchored to the femur with two cerclage wires creating a tension band effect (31). Figure 2.4 illustrates the postoperative radiograph following correction of coxa vara of the right femur.



Figure 2.4: Radiograph illustrating bilateral bowing of the femurs,

a right coxa vara deformity and bilateral sub-trochanteric femur fractures

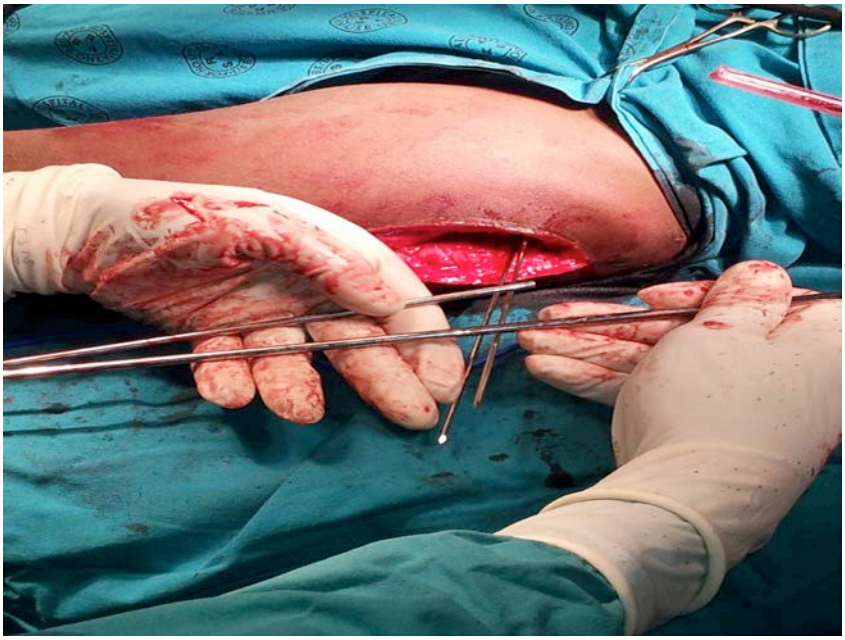

Figure 2.5: This is an intraoperative picture illustrating the correction of coxa vara. Note the two parallel K wires going into the neck and head of the femur.



Figure 2.6: Post-operative radiograph of the right femur following IM rodding with FD rod and tension band wire fixation for correction of coxa vara

2.18 POSTOPERATIVE REHABILITATION OF PATIENTS FOLLOWING INTRAMEDULLARY RODDING

In the immediate postoperative period following IM rodding, pain is controlled with oral paracetamol and valeron (tilidin hydrochloride) drops. There is a risk of rotation occurring at the osteotomy sites in the postoperative period because the IM rods have no locking mechanism. In order to avoid this complication, a below knee POP with an anti-derotation bar is applied for two weeks postoperatively (Figure 2.5). Our postoperative immobilization is usually two weeks to prevent postoperative osteopenia.



Figure 2.7: This clinical picture illustrates a below knee cast and an anti-derotation bar in the immediate postoperative period following IM rodding (using Fassier Duval rod) of the left femur in a child with OI.

CHAPTER THREE

3.0 RESULTS

3.10 DEMOGRAPHIC DATA

A total of 78 patients were seen within the period under review. The median age at presentation was 20 months (IQR 0-48). The male to female ratio was 1:1.1(37 males and 41 females). Twenty patients (26%) had a positive family history of a first degree relative with osteogenesis imperfecta. One of the patients (non-South African) with a positive family history is from a family with consanguineous marriage.

Our patients came from six different provinces out of the nine provinces in South Africa. The majority of the patients (59%) were from the Gauteng Province. Three patients came from other Southern African countries. Two patients came from Zimbabwe and one from Malawi. (Figure 3.1)

Of the total number of patients seen in our institution, the majority, 37(48%) were referred from the clinics; paediatricians and orthopaedists referred 14(18%) and 11(14%) patients respectively. The referring health care professionals were not documented in 16(20%) of the patients.



Figure 3.1: A map of South Africa illustrating the distribution of patients from the different provinces.

3.20 CLINICAL RESULTS

Most of the patients in our series presented with the typical features of OI. These included blue sclerae in 52.6% (41 patients). Figure 3.2 illustrates blue sclera in a two-year-old female child with type III OI. Dentinogenesis imperfecta was seen in 26.7% (21 patients). Triangular face was seen in 50.0% (39 patients). Figure 3.3 illustrates a triangular face in a three-year-old female child with type III OI. The other features include recurrent fractures (Figure 3.4) and lower limb deformities in 66.7% (52 patients). Figure 3.5 illustrates limb length discrepancy as a result of differential bowing of the femurs and coxa vara of the left hip.

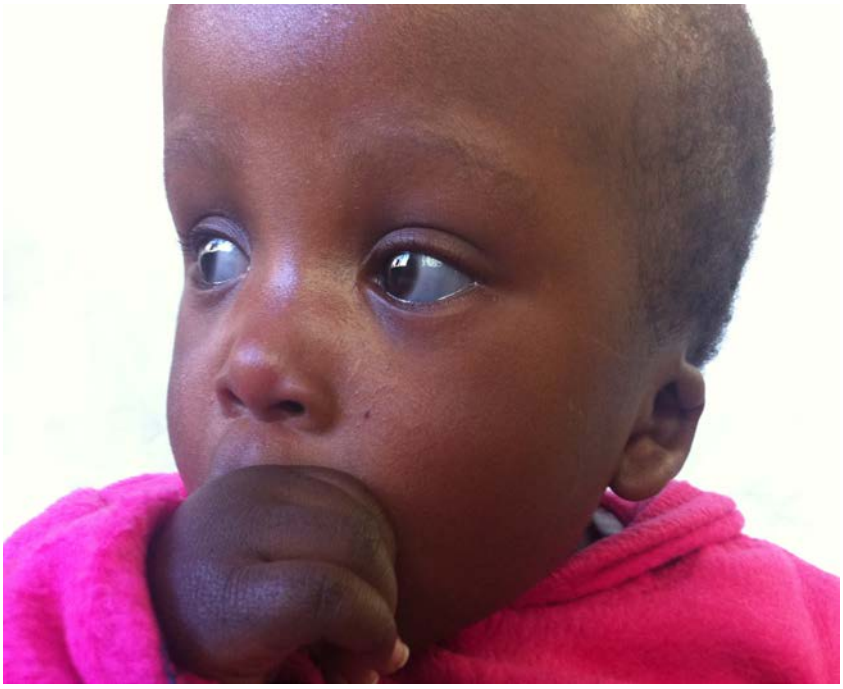

Figure 3.2: Photograph illustrates blue sclera and triangular face in a two-year-old female child with type III Osteogenesis Imperfecta.



Figure 3.3: Photograph illustrates sun set appearance of the eyes in a three-year-old male child with type III osteogenesis imperfecta complicated with hydrocephalus as a result of basilar invagination. Note the blue sclerae, the triangular face and the sun setting appearance of the eyes as a result of raised intracranial pressure.

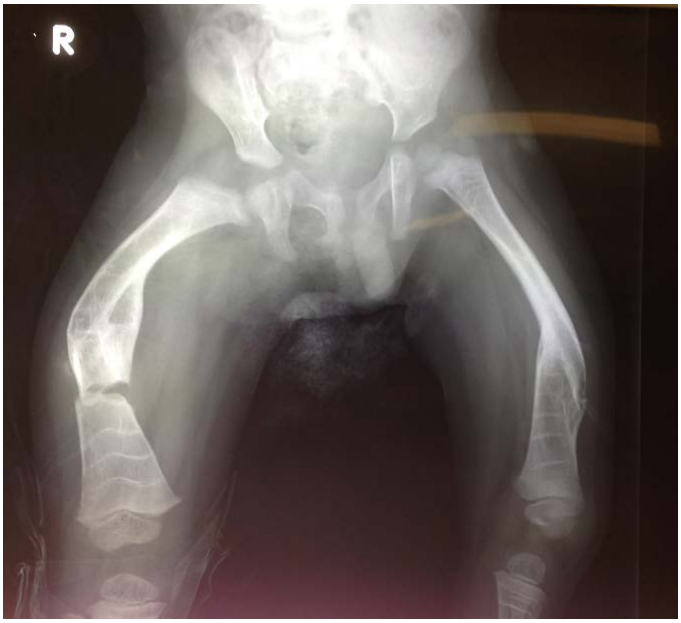

Figure 3.4: Radiograph of a five-year-old child with type III OI illustrating a transverse fracture of the right femur and bowing deformity of both femurs. Note the malunited fractures of both femurs and the transverse dense metaphyseal bands (‘Zebra lines’) as a result of bisphosphonate use (32)



Figure 3.5: Photograph illustrates limb length discrepancy as a result of coxa vara of the left hip.

3.30 TYPES OF OSTEOGENESIS IMPERFECTA

The patients were classified clinically using the original Sillence classification and the number and percentages of each type of OI are shown in Table 3.1 below. The majority of patients in this study were classified as type III and type IV, 38 (48.7%) and 23 (29.5%) patients respectively. There were no patients with Type II OI as they would have met their demise prior to referral to the Metabolic Bone clinic.

Table 3.1: The frequency of the various types of osteogenesis imperfecta

TYPE OF OI	**FREQUENCY (N =78)**
TYPE I	9(11.5%)
TYPE II	0(0%)
TYPE III	38(48.7%)
TYPE IV	23(29.5%)
BRUCKS SYNDROME	8(10.3%)

3.40 AVERAGE NUMBER OF FRACTURES

The total number of fractures from first reported fracture to the last clinic visit assessed by the researcher, was available for 65 patients. The average number of fractures from the first reported fracture till the last clinic visit differed according to the type of OI (Table 3.2 below) and the duration of follow-up for individual patients also varied. The mean duration of follow-up was lower in Type I (1.8 years (SD ±1.2)) and III (2.6 years (SD ±1.8)) OI patients compared to Type IV (4.2 years (SD ±2.4)) and Bruck syndrome (4.9 years (SD ± 2.7) [$p<0.05$ between Type I and IV; $p<0.01$ between Type I and Bruck syndrome]. Patients with Bruck syndrome had the longest duration of follow-up and this was significantly greater compared to Type I ($p<0.01$) and III ($p<0.01$) OI patients. In table 3.2 below, Type III OI patients had the highest average number of fractures compared to the other types of OI and this was significantly greater compared to Type IV and Bruck syndrome ($p<0.05$ and $p<0.01$ respectively)

Table 3.2: Average number of fractures in the different types of OI

TYPES OF OI	Average number of fractures (SD) †
TYPE I (n=6)	2.2 (0.75)
TYPE III (n=36)	3.2 (1.5)
TYPE IV (n=16)	2.3 (1.0)*
BRUCKS SYNDROME (n=5)	1.3 (0.7)**

* <0.05 between Type III and IV and ** p<0.01 between Type III and Brucks syndrome
†Average number of fractures is calculated based on the number of fractures in each child from the first time of a recorded fracture till last recorded visit and divided by the duration of follow-up (in years) during that time period. Thereafter the average number of fractures for each group/type of OI was calculated.

3.50 PATTERN OF FRACTURE DISTRIBUTION

A greater number of fractures occurred in the long bones of the lower extremities. The femur was the most frequent site of fracture followed by the tibia/fibula, and then the upper extremities combined, thereafter the ribs and lastly the spine. (Figure 3.6)

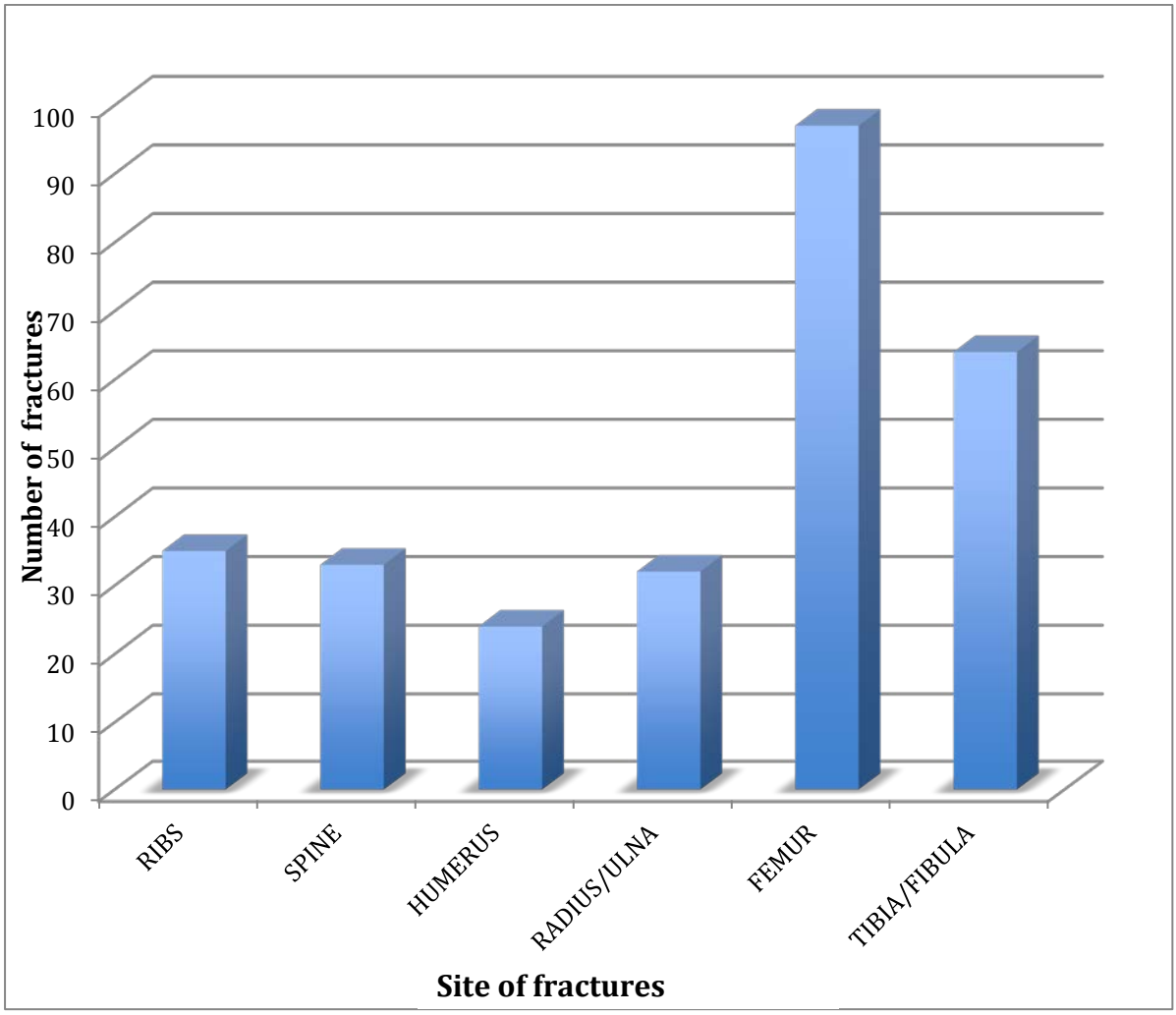

Figure 3.6: Illustrates the number of fractures in various parts of the body

3.60 TREATMENT RESULTS

3.61 MEDICAL TREATMENT

All the patients received bisphosphonates. Seventy three patients (94%) received intravenous bisphosphonate therapy and only five patients received oral bisphosphonate.

3.62 NON-OPERATIVE TREATMENT

All the patients received non-operative treatment at some stage in their management. Sixteen patients received only non-operative treatment (Figure 3.7). The modality of non-operative treatment included Plaster of Paris (POP) (figure 3.8), longitudinal skin traction, and Gallows' traction.

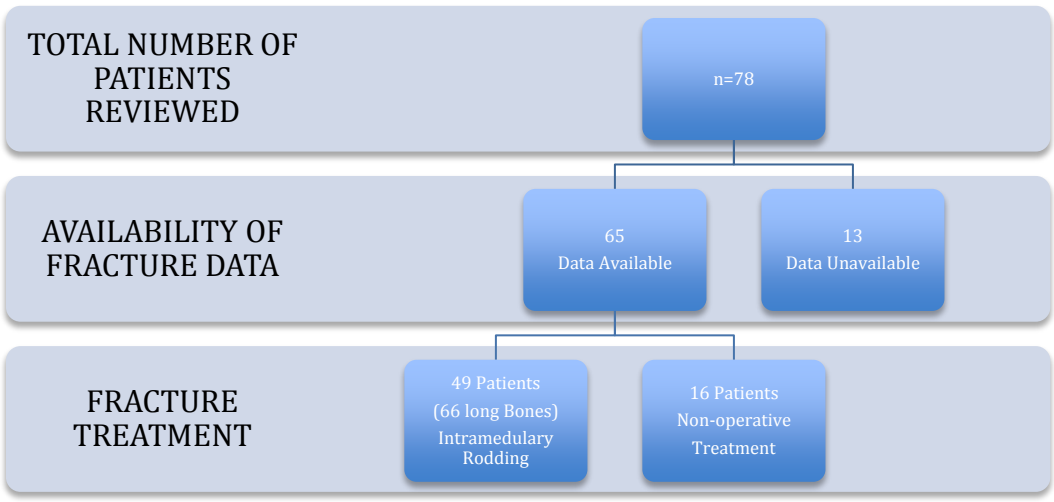

Figure 3.7: Flow Diagram for Fractures and Intramedullary Rodding



Figure 3.8: Radiograph of a right forearm fracture treated in a POP in a child with OI.

3.63 OPERATIVE TREATMENT

Sixty six long bones (49 patients) received intramedullary rodding. The mean age at time of surgery was 7 (SD ±2.6) years. The youngest age at rodding was 3 years and the oldest child was aged 14 years. The indications for IM rodding were repeated fractures of the same long bone and osseous deformities or a combination of osseous deformities and fractures.

3.64 COMPLICATIONS OF RODDING

The complications of IM rodding seen in our series included; rod migration (proximal and distal migration with or without tenting of the skin), rod breakage (with or without associated fractures) and peri-implant fractures as shown in figures 3.9 to 3.13 below. There were no infections.



Figure 3.9: Radiograph illustrates proximal rod

migration from the left femur with a new fracture at the junction of the rod and bone



Figure 3.10: Photograph illustrates tenting of the skin from rod migration out of the bone, a complication of IM rodding

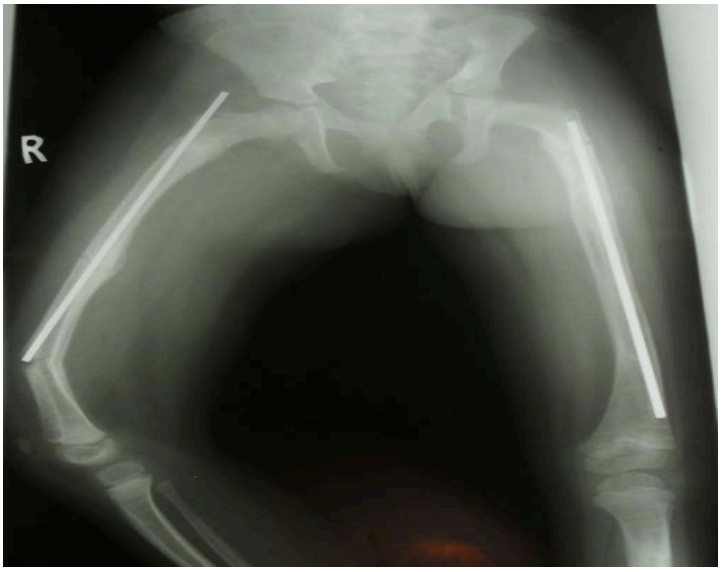

Figure 3.11: Radiograph illustrates peri-implant

fracture at the distal end of the rod of the right femur



Figure 3.12: Radiograph illustrates rod breakage and

right femur fracture at same level



Figure 3.13: Radiograph illustrates bilateral rodding of both femurs with proximal migration of the rod in the left femur. Note the tension band construct for the correction of coxa vara on the right femur with the K wire backing out

3.65 INDICATIONS FOR ROD REVISION

A total of 51 long bones out the 66 long bones rodded underwent single or repeated revisions for different indications. In 25 (49%) of these long bones, surgery had to be repeated because of rod migration. Another 20 (39%) of these long bones had peri-implants fractures and in six (12%) rod-breakage occurred. A summary of rod revision is shown in the figure 3.14 below.

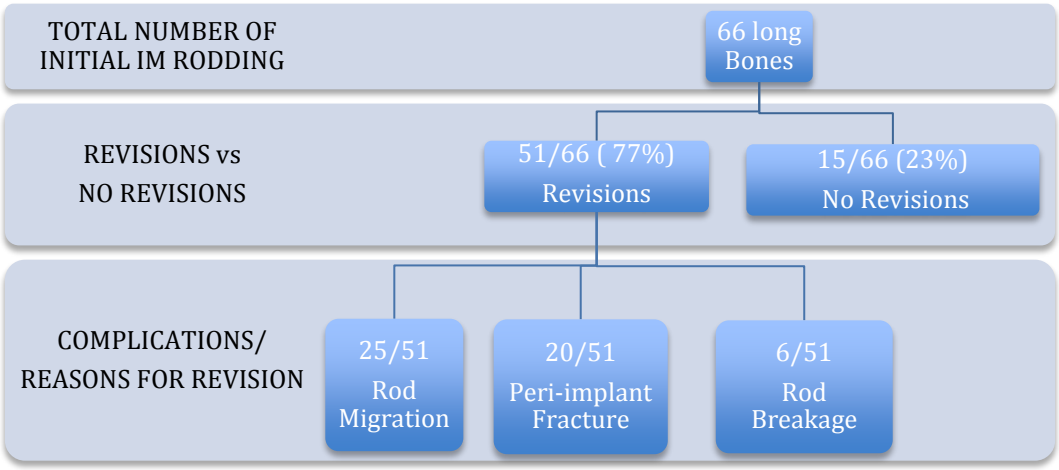

Figure 3.14: A Flow Chart of reasons for rod revision

CHAPTER FOUR

4.0 DISCUSSION

To my knowledge, this study is the only one that has comprehensively investigated the clinical presentation and surgical management of children with OI in South Africa. This study has one of the largest numbers of patients in a single series comprising of a total of 78 patients.

The patients came from six different provinces out of the nine provinces in South Africa. As expected, the majority of the patients (59 %) were from the Gauteng province where the study was done. The possible reason for the long distance referral is because there are only very few health facilities in South Africa that offer comprehensive management of patients with OI. Three of these patients came from the neighbouring countries of Malawi and Zimbabwe. The health care sectors in these countries are plagued with lack of geographic and financial accessibility and in some cases non-availability of quality health care (33).

The male to female ratio of OI was 1:1.1 (37 male and 41 female), indicating that there is no gender predilection in OI. Lin et al reported a male to female ratio of 1:2 (15 male and 33 female) (34). Patel et al (35) showed a 1:1.3 male to female ratio and Plotkin et al (36) reported a 1:0.9 male to female ratio.

Twenty patients (26%) had a positive family history of a first degree relative with Osteogenesis Imperfecta. Other studies have reported a higher percentage of a positive family history (35, 37). Greeley et al reported the presence of family history in 46% of patients OI (37). Patel et al reported a family history of 40.3% across all types of OI in a

cross-sectional multi-centre study (35). The reason for the reported lower percentage of a positive family history could be attributed to lower level of community awareness and community health care amongst the study population. In addition, the majority of the patients in this study were type III OI patients compared to the other studies where the majority of patients were Type IV (37) and the type I (35) (autosomal dominant inheritance pattern).

The median age at presentation was 20 months. In this study, less than 11% of infants were diagnosed in the first year of life. Greeley et al reported that 25% of infants were diagnosed before one year of age at the Shriners Children's Hospital in Canada, an international orthopaedic referral centre (37). This indicates that a lower number of patients with OI are diagnosed in the neonatal period in South Africa.
All the patients in this study were diagnosed and classified according to the Sillence classification by the presence of clinical characteristics. Greeley et al in 2013 diagnosed 72% of their patients from clinical characteristics (37) and suggested that special tests such as genetic and fibroblast testing are not necessary for diagnoses (37). In South Africa, genetic testing is not available and the diagnosis of OI is based on the family history, clinical presentation and radiological findings.

The majority of the patients in our series were type III (48.7%) and type IV (29.5%). In the study done by Greeley et al, the majority of their patients were type IV (35%) and type I (34%) (37). In a retrospective audit of Taiwanese children with OI, the majority of their OI were type I (40%) and type IV (40%) (34). A recent cross-sectional multi-centre study of OI revealed that type I was the most prevalent type (49%), followed by types IV(27%) and III (18%) (35). The reason for this disparity is not immediately obvious but clinical judgement and genetics could be responsible. Another explanation for the smaller number of patients with Type I OI presenting to CHBAH is that these patients do not fracture

frequently and have mild OI thus do not seek specialist medical care and are more likely to be seen at secondary health care facilities in South Africa.

More fractures occurred in the long bones of the lower extremities. The femur and tibia comprised more than 60% (93 femur fractures and 60 tibia fractures) of the total fractures. This is expected in the ambulant OI child, as these are the major weight bearing bones of the body. Greeley et al noted that the most common fractures at diagnosis were extremity fractures seen in 32% of patients (37).

The average number of fractures was highest in Type III OI patients, which was greater than the other types but only significantly higher than in type IV ($p<0.05$) and Bruck syndrome ($p<0.01$) patients. A meaningful comparison could not be made between Type I and III due to the small number of patients in the Type I group of patients. The average numbers of fractures being the greatest in type III OI is similar to the cross-sectional multicentre study of OI in North America (35).

Since all the patients were on bisphosphonate therapy, it was not possible to demonstrate the efficacy of bisphosphonates in this study, as there is no control group for comparisons. Furthermore, the majority of patients were commenced on bisphosphonate at the initial presentation after one month of calcium and vitamin D supplementation. This was probably due to the fact that most patients had IM rodding performed for lower limb fractures, which skews the effectiveness of bisphosphonates in preventing fractures.

Sixty six long bones (49 patients) received intramedullary rodding. Of these, the majority (96 %) were William's rods and the remaining 4% were FD rods. The FD rods are a small number compared to the William's rods because the FD rods were recently introduced for selected cases of femur fractures in children with good growth potential who are already walking. The basis of this practise is borne out of a study done in Johannesburg by Erken

(38). Erken recommended that elongating rods should be reserved for femur fractures in a child more than six years of age with a “reasonable” potential for growth (38). Furthermore, Zionts et al reported that elongating nails in the tibia were associated with a higher incidence of major complications compared with those of the femur (13), thus elongating rods in this Unit are preferentially the choice of IM rod used for the femurs. In this study, the mean age at time of surgery was 7 years. Long bone fractures in children younger than two years of age were treated non-operatively. This is because of the technical difficulty associated with the procedure. The incidence of complications is known to be higher in children less than five years of age when IM rods are implanted (13). In this study, only 16% of those patients that underwent surgery were less than five years of age, and they have all had at least a single revision at the time of this report.

The complications of IM rodding seen in our series was high (77%). As in every situation were non growing rods are implanted in growing children, if they are followed up for long enough, most if not all patients will develop complications that will necessitate revision surgery. Most of the complications of IM rodding documented in the literature were on extensible rods therefore a direct comparative analysis with our study is not possible because the patients with extensible rods are expected to have fewer complications and a longer time to revisions. Nonetheless the documented complication rates for these extensible rods remain equally high. Ziont et al documented a 100% complication rate with Bailey-Dubow extensible rods (13). Lang-Stevenson and Sharrard (39) and Gamble et al (40) reported complication rates of 64% and 69% respectively with use of Bailey-Dubow extensible rods. The use of IM rods is not without complications. In the majority of patients however, the long term benefits of IM rodding outweigh the risks. This advantage cannot be evaluated as it is not ethical to deny patients IM rodding if surgically and medically warranted.

There were a number of limitations in this study. It is a retrospective audit reliant on historical data collection so there will be missing data and X-Rays that will affect data analysis and the interpretation thereof. The information on ambulatory status was not well documented in the patients' records and thus was not used as an outcome measure to evaluate improvement after surgical management.

The strength of the study was the large number of patients that were studied from a large geographic region, treated with the same protocol regarding both medical and surgical management.

CHAPTER FIVE

5.0 CONCLUSION

The treatment of children with OI has undergone tremendous improvement in the last two decades worldwide. There have recently been more publications on the pathogenesis and treatment of OI than ever before (11, 16, 37, 41)

The salient findings of this study were that the majority of the patients in our series were type III (48.7%) and 26% of all patients had a positive family history. These results differ in comparison to other studies in which the majority of patients were Type I or Type IV OI and thus had reported a higher prevalence of a positive family history. The average number of fractures in this study was highest in type III OI patients and is in keeping with the literature as well as the Sillence classification of severity. All patients were treated with bisphosphonates and majority of the OI patients with lower limb long bone fractures initially received non operative treatment under the age of two years. Sixty six long bones (49 patients) received intramedullary rodding with a complication rate of 77% which is consistent with the literature.

This study was unable to assess the effectiveness of bisphosphonate therapy. The effectiveness of intramedullary fixation in fragility fractures has been demonstrated in several studies (42, 43) and the choice of IM device is still largely determined by surgeons' preference. We currently prefer using the simple non-expandable Williams' rods which are inexpensive and simple to use and the expandable FD rods are reserved for selected cases of femur fractures in children with a good growth potential who are walking.

The multidisciplinary approach adopted in the management of the OI patient, the cyclical bisphosphonate therapy, multiple osteotomies and intramedullary rodding of long bones

for fracture fixation and deformity correction as well as adequate and timely rehabilitation has tremendously improved the outlook of South African children with OI.

There is however the need for on-going public education and continuing medical education among health professionals on early diagnosis and prompt referral to centres equipped in the care of the child with OI.

Future prospects in the management of OI rely on the on-going research in gene therapy. However, currently the best available tools for managing the child with debilitating OI remain in the multidisciplinary approach with the use of bisphosphonate as well as prompt and adequate rodding of long bone fractures.

6.0 REFERENCES

1. Burnei G, Vlad C, Georgescu I, Gavriliu TS, Dan D. Osteogenesis imperfecta: diagnosis and treatment. The Journal of the American Academy of Orthopaedic Surgeons. 2008;16(6):356-66.

2. Peltier LF. The classic: congenital osteomalacia. Olaus Jacob Ekman. Clinical orthopaedics and related research. 1981(159):3-5.

3. Kocher MS, Shapiro F. Osteogenesis imperfecta. The Journal of the American Academy of Orthopaedic Surgeons. 1998;6(4):225-36.

4. van Dijk FS, Cobben JM, Kariminejad A, Maugeri A, Nikkels PG, van Rijn RR, et al. Osteogenesis Imperfecta: A Review with Clinical Examples. Molecular syndromology. 2011;2(1):1-20.

5. Sillence DO, Senn A, Danks DM. Genetic heterogeneity in osteogenesis imperfecta. Journal of medical genetics. 1979;16(2):101-16.

6. Glorieux FH, Rauch F, Plotkin H, Ward L, Travers R, Roughley P, et al. Type V osteogenesis imperfecta: a new form of brittle bone disease. Journal of bone and mineral research : the official journal of the American Society for Bone and Mineral Research. 2000;15(9):1650-8.

7. Glorieux FH, Ward LM, Rauch F, Lalic L, Roughley PJ, Travers R. Osteogenesis imperfecta type VI: a form of brittle bone disease with a mineralization defect. Journal of bone and mineral research : the official journal of the American Society for Bone and Mineral Research. 2002;17(1):30-8.

8. Ward LM, Rauch F, Travers R, Chabot G, Azouz EM, Lalic L, et al. Osteogenesis imperfecta type VII: an autosomal recessive form of brittle bone disease. Bone. 2002;31(1):12-8.

9. Valadares ER, Carneiro TB, Santos PM, Oliveira AC, Zabel B. What is new in Osteogenesis Imperfecta Classification ? Journal de Pediatria. 2014;90(6):536-41.

10. McPherson E, Clemens M. Bruck Syndrome (Osteogenesis Imperfecta with Congenital Joint Contractures): Review and Report on the First North American Case. Am J Med Genet. 1997(70):28-31.

11. Marini JC, Blissett AR. New genes in bone development: what's new in osteogenesis imperfecta. The Journal of clinical endocrinology and metabolism. 2013;98(8):3095-103.

12. Van Dijk FS, Sillence DO. Osteogenesis imperfecta: clinical diagnosis, nomenclature and severity assessment. American journal of medical genetics Part A. 2014;164A(6):1470-81.

13. Zionts LE, Ebramzadeh E, Stott NS. Complications in the use of the Bailey-Dubow extensible nail. Clinical orthopaedics and related research. 1998(348):186-95.

14. Glorieux FH. Experience with bisphosphonates in osteogenesis imperfecta. Pediatrics. 2007;119 Suppl 2:S163-5.

15. Montpetit K, Plotkin H, Rauch F, Bilodeau N, Cloutier S, Rabzel M, et al. Rapid increase in grip force after start of pamidronate therapy in children and adolescents with severe osteogenesis imperfecta. Pediatrics. 2003;111(5 Pt 1):e601-3.

16. Dwan K, Phillipi CA, Steiner RD, Basel D. Bisphosphonate therapy for osteogenesis imperfecta. The Cochrane database of systematic reviews. 2014;7:CD005088.

17. Yang X, Lu Y, Li Z, Wang Y, Zhao F, Han J. Low concentrations of zoledronic acid are better at regulating bone formation and repair. Intractable & rare diseases research. 2013;2(1):18-23.

18. Zeitlin L, Fassier F, Glorieux FH. Modern approach to children with osteogenesis imperfecta. Journal of pediatric orthopedics Part B. 2003;12(2):77-87.

19. Wolf H, Sarahrudi K, Vecsei V. Intramedullary osteosynthesis for fracture associated with osteogenesis imperfecta. Injury. 2009;40(3):315-20.

20. Nicolaou N, Bowe JD, Wilkinson JM, Fernandes JA, Bell MJ. Use of the Sheffield telescopic intramedullary rod system for the management of osteogenesis imperfecta: clinical outcomes at an average follow-up of nineteen years. The Journal of bone and joint surgery American volume. 2011;93(21):1994-2000.

21. Sofield HA, Millar EA. Fragmentation, realignment, and intramedullary rod fixation of deformities of the long bones in children. The Journal of bone and joint surgery American volume. 1959;p. 41:1371–91.

22. Pettifor JM, Thandrayen K. Rickets and metabolic bone disorders. In: RJ G, editor. Coovadia's paediatrics and child health. 7th ed. South Africa: Oxford University Press Southern Africa Limited; 2014. p. 224-41.

23. Munns CF, Rauch F, Zeitlin L, Fassier F, Glorieux FH. Delayed osteotomy but not fracture healing in pediatric osteogenesis imperfecta patients receiving pamidronate. Journal of bone and mineral research : the official journal of the American Society for Bone and Mineral Research. 2004;19(11):1779-86.

24. Pizones J, Plotkin H, Parra-Garcia JI, Alvarez P, Gutierrez P, Bueno A, et al. Bone healing in children with osteogenesis imperfecta treated with bisphosphonates. Journal of pediatric orthopedics. 2005;25(3):332-5.

25. Joseph B, Rebello G, Chandra KB. The choice of intramedullary devices for the femur and the tibia in osteogenesis imperfecta. Journal of pediatric orthopedics Part B. 2005;14(5):311-9.

26. Mulpuri K, Joseph B. Intramedullary rodding in osteogenesis imperfecta. Journal of pediatric orthopedics. 2000;20(2):267-73.

27. Wilkinson JM, Scott BW, Clarke AM, Bell MJ. Surgical stabilisation of the lower limb in osteogenesis imperfecta using the Sheffield Telescopic Intramedullary Rod System. The Journal of bone and joint surgery British volume. 1998;80(6):999-1004.

28. Wong RS, Follis FM, Shively BK, Wernly JA. Osteogenesis imperfecta and cardiovascular diseases. The Annals of thoracic surgery. 1995;60(5):1439-43.

29. Lavoie J. Anaesthic considerations in osteogenesis imperfecta. In: Chiasson R, Munns C, Zeitlin L, editors. Interdisciplinary treatment approach for children with osteogenesis imperfecta. Canada: Shriners hospital for children. p. 151-9.

30. Fassier F, Glorieux FH. Osteogenesis imperfecta. 2003. In: Surgical Techniques in Orthopaedics and Traumatology [Internet]. Paris: Elsevier SAS; [8p].

31. Robertson A, Younus AA, editors. A Surgical Technique for Coxa Vara in Osteogenisis Imperfecta. South African Orthopaedic Association 48th Congress; 2003; south Africa: J Bone Joint Surg Br.

32. Al Muderis M, Azzopardi T, Cundy P. Zebra lines of pamidronate therapy in children. The Journal of bone and joint surgery American volume. 2007;89(7):1511-6.

33. Peters DH, Garg A, Bloom G, Walker DG, Brieger WR, Rahman MH. Poverty and access to health care in developing countries. Annals of the New York Academy of Sciences. 2008;1136:161-71.

34. Lin HY, Lin SP, Chuang CK, Chen MR, Chang CY, Niu DM. Clinical features of osteogenesis imperfecta in Taiwan. Journal of the Formosan Medical Association = Taiwan yi zhi. 2009;108(7):570-6.

35. Patel RM, Nagamani SC, Cuthbertson D, Campeau PM, Krischer JP, Shapiro JR, et al. A cross-sectional multicenter study of osteogenesis imperfecta in North America - results from the linked clinical research centers. Clinical genetics. 2015;87(2):133-40.

36. Plotkin H, Rauch F, Bishop NJ, Montpetit K, Ruck-Gibis J, Travers R, et al. Pamidronate treatment of severe osteogenesis imperfecta in children under 3 years of age. The Journal of clinical endocrinology and metabolism. 2000;85(5):1846-50.

37. Greeley CS, Donaruma-Kwoh M, Vettimattam M, Lobo C, Williard C, Mazur L. Fractures at diagnosis in infants and children with osteogenesis imperfecta. Journal of pediatric orthopedics. 2013;33(1):32-6.

38. Erken EHW. Intramedullary Rodding in Osteogenesis Imperfecta. South African Orthopaedic Association 45th Congress; Johannesburg, South African 2000.

39. Lang-Stevenson AI, Sharrard WJ. Intramedullary rodding with Bailey-Dubow extensible rods in osteogenesis imperfecta. An interim report of results and complications. The Journal of bone and joint surgery British volume. 1984;66(2):227-32.

40. Gamble JG, Strudwick WJ, Rinsky LA, Bleck EE. Complications of intramedullary rods in osteogenesis imperfecta: Bailey-Dubow rods versus nonelongating rods. Journal of pediatric orthopedics. 1988;8(6):645-9.

41. Monti E, Mottes M, Fraschini P, Brunelli P, Forlino A, Venturi G, et al. Current and emerging treatments for the management of osteogenesis imperfecta. Therapeutics and clinical risk management. 2010;6:367-81.

42. Larsson S. Treatment of osteoporotic fractures. Scandinavian journal of surgery : SJS : official organ for the Finnish Surgical Society and the Scandinavian Surgical Society. 2002;91(2):140-6.

43. Sessa G, Evola FR, Costarella L. Osteosynthesis systems in fragility fracture. Aging clinical and experimental research. 2011;23(2 Suppl):69-70.

7.0 APPENDICES

7.1 APPENDIX A: Data Collection Form

Study number:_____ Initials: _____ Date: _____

SECTION A: DEMOGRAPHIC DATA

Age (years)…….. (Months) …….. Sex ……..

Residential Area ……

Province ……

SECTION B: CLINICAL PRESENTATION

Age at presentation (years) …….. Months ……

Date of First Presentation: ……

Referred: YES ….NO….. If YES, Referred by orthopaedist ….. GP……

Clinic …….. Peripheral Clinic …….. Paediatrician……..

Presenting Symptoms: ……

Blue Sclera: YES….NO……

Dentinogenesis Imperfecta: YES…… NO……..

Type of OI: ……

Family History of OI: YES: …… NO: …….. If YES,

first degree Relative: …… second degree relative: …… Not recorded: ……

Weight …….. Height …… BMI …….

Head Circumference …….

SECTION C

The Rate, Pattern and Distribution of Fractures and Pre op Radiograph Assessment

Fractures YES: ……. NO …… Age of First Fracture: ……..

Number of Fractures: <3 …… >3 ……..

Extremity Bones involved:

Humerus: ……(R) (L) Radius: …….(R) (L) Ulna: ……(R) (L)

Femur: ……(R) (L) Tibia: …….(R) (L)

Axial skeleton involved: Ribs …….. Spine ……

SECTION D

Medical management Bisphosphonates

Received Bisphosphonates? YES: …… NO: ……

Type of Bisphosphonates Given: ……

1(a) Date of commencement: …… 1(b) Period of Treatment: ……

2(a) Date of commencement: …… 2(b) Period of Treatment: ……

Number of Cycles ……

Total Duration of follow up ……

SECTION E

Outcomes and Complications of Surgical Treatment and Post Op Radiograph Assessment

Ambulation prior to Fracture/Surgery:

(a) Crawling/ Bom-shuffling : …….

(b) Cruising : ……..

(c) Walking: ……

(d) Crutch dependent……..

(e) Wheelchair dependent: ……..

Post Op Ambulatory Status:

(a) Ambulatory: ……..

(b) Non Ambulatory: ……...

(c) Independent: ……..

(d) Crutch dependent…….

(e) Wheelchair dependent: ……

Received Williams's Intramedullary Rod fixation, YES: …… NO: ……. If YES,

Number of Bones Rodded…….

(a) Intra-operative / Immediate Post-Operative Complications,

YES: ……. NO: …… Specify: ……

(b) Late Complications: Yes…….. No……..

Details: Loss of fixation……. Re-fracture: ……

New fracture: …….. Non-union: ……

Progressive Deformity: ……. Rod breakage: …….

Rod migration: …… Others: ……

(c) Re-Operation at same site: Yes: ……. No: ……..

2. (a) Intra-operative / Immediate Post-Operative Complications,

YES: ……. NO: …… Specify: ……

(b)Late Complications: Yes…….. No……..

Details: Loss of fixation……. Re-fracture: ……

New fracture: ……. Non-union: ……

Progressive Deformity: ……. Rod breakage: …….

Rod migration: …… Others: ……

(c)Re-Operation at same site: Yes: ……. No: ……..

3. (a) Intra-operative / Immediate Post-Operative Complications,

YES: ……. NO: …… Specify: ……

(b)Late Complications: Yes…….. No……..

Details: Loss of fixation……. Re-fracture: ……

New fracture: ……. Non-union: ……

Progressive Deformity: ……. Rod breakage: …….

Rod migration: …… Others: ……

(c) Re-Operation at same site: Yes: ……. No: ……..

(a) Intra-operative / Immediate Post-Operative Complications,

YES: ……. NO: …… Specify: ……

(b) Late Complications: Yes…….. No……..

Details: Loss of fixation……. Re-fracture: ……

New fracture: ……. Non-union: ……

Progressive Deformity: ……. Rod breakage: …….

Rod migration: …… Others: ……

(c) Re-Operation at same site: Yes: ……. No: ……..

7.2 APPENDIX B:

Ethics Clearance Certificate

UNIVERSITY OF THE WITWATERSRAND, JOHANNESBURG
Division of the Deputy Registrar (Research)

HUMAN RESEARCH ETHICS COMMITTEE (MEDICAL)
R14/49 Dr George O Oduah

CLEARANCE CERTIFICATE	**M120415**
PROJECT	The Clinical Presentation and Management of South African Children with Oesteogenesis Imperfecta
INVESTIGATORS	Dr George O Oduah.
DEPARTMENT	Department of Orthopaedics
DATE CONSIDERED	04/05/2012
DECISION OF THE COMMITTEE*	Approved unconditionally

Unless otherwise specified this ethical clearance is valid for 5 years and may be renewed upon application.

DATE 04/05/2012 **CHAIRPERSON** .....
(Professor PE Cleaton-Jones)

*Guidelines for written 'informed consent' attached where applicable
cc: Supervisor : Dr G Firth

DECLARATION OF INVESTIGATOR(S)
To be completed in duplicate and **ONE COPY** returned to the Secretary at Room 10004, 10th Floor, Senate House, University.
I/We fully understand the conditions under which I am/we are authorized to carry out the abovementioned research and I/we guarantee to ensure compliance with these conditions. Should any departure to be contemplated from the research procedure as approved I/we undertake to resubmit the protocol to the Committee. **I agree to a completion of a yearly progress report.**

PLEASE QUOTE THE PROTOCOL NUMBER IN ALL ENQUIRIES...

7.3 APPENDIX C:

Plagiarism Screen Report

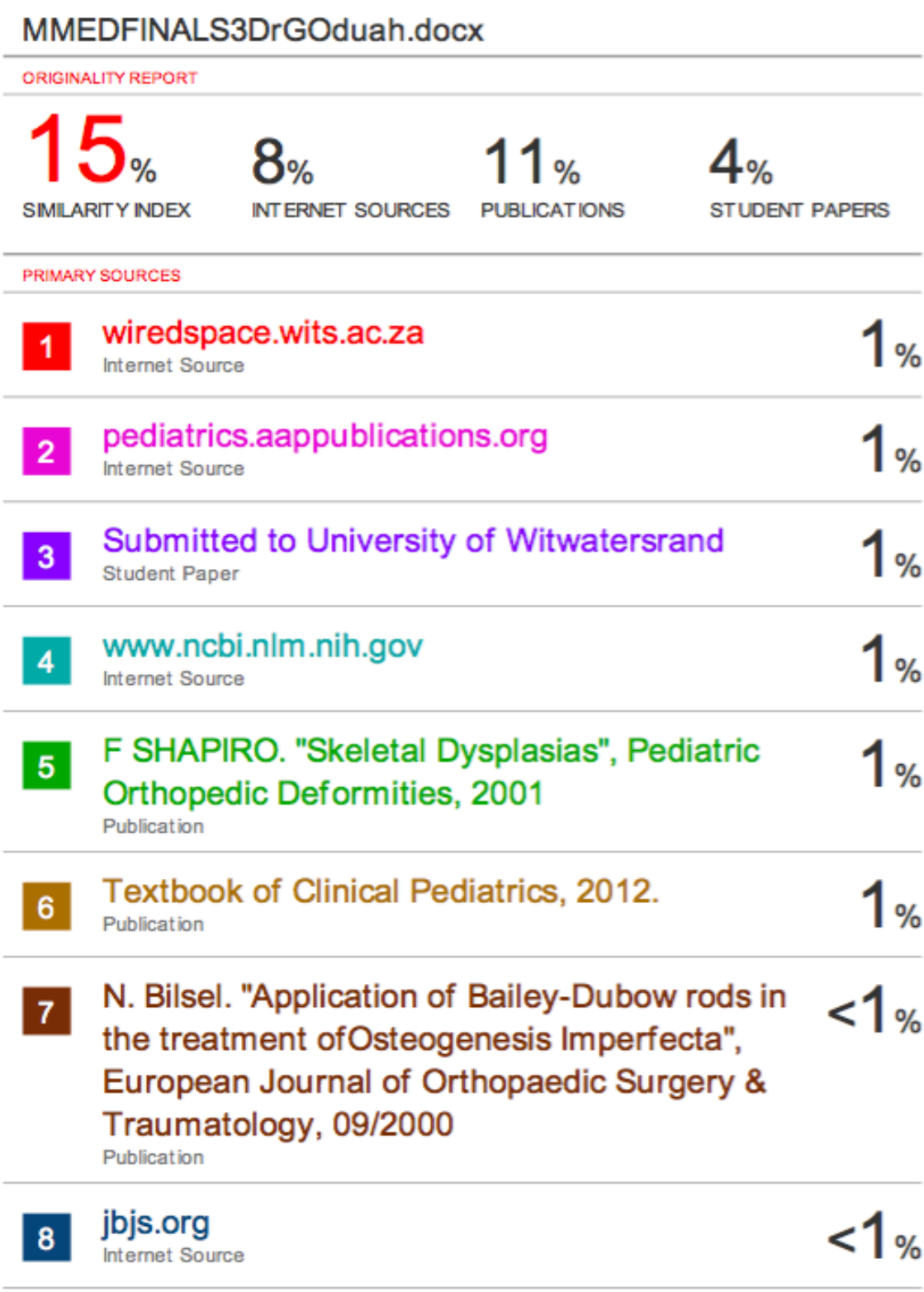

MMEDFINALS3DrGOduah.docx

ORIGINALITY REPORT

15%	8%	11%	4%
SIMILARITY INDEX	INTERNET SOURCES	PUBLICATIONS	STUDENT PAPERS

PRIMARY SOURCES

1	wiredspace.wits.ac.za Internet Source	1%
2	pediatrics.aappublications.org Internet Source	1%
3	Submitted to University of Witwatersrand Student Paper	1%
4	www.ncbi.nlm.nih.gov Internet Source	1%
5	F SHAPIRO. "Skeletal Dysplasias", Pediatric Orthopedic Deformities, 2001 Publication	1%
6	Textbook of Clinical Pediatrics, 2012. Publication	1%
7	N. Bilsel. "Application of Bailey-Dubow rods in the treatment ofOsteogenesis Imperfecta", European Journal of Orthopaedic Surgery & Traumatology, 09/2000 Publication	<1%
8	jbjs.org Internet Source	<1%