

https://dspace.org/

Space invaders roboticassisted prostate surgery

Sumayya Mayet

https://hdl.handle.net/10539/35376
SCOPUS

Downloaded from a DSpace repository. https://dspace.org/

Southern African Journal of Anaesthesia and Analgesia. 2021;27(6 Suppl 1):S1-55
https://doi.org/10.36303/SAJAA.2021.27.6.S1.2704
Open Access article distributed under the terms of the
Creative Commons License [CC BY-NC 3.0]
http://creativecommons.org/licenses/by-nc/3.0

South Afr J Anaesth Analg
ISSN 2220-1181 EISSN 2220-1173
© 2021 The Author(s)
FCA REFRESHER COURSE

Space invaders: robotic-assisted prostate surgery

S Mayet

Department of Anaesthesiology, University of the Witwatersrand, South Africa
Corresponding author, email: *shafs.mayet@gmail.com*

Keywords: robotic-assisted prostate surgery, minimally invasive

Minimally invasive surgery is gaining popularity. Thus, the field of robotic-assisted surgery is evolving and gaining momentum. Robotic-assisted techniques can overcome the shortcomings of conventional laparoscopic techniques. Some of the changes which need to be tackled with expertise to avoid complications include longer duration of surgery, limited access, prolonged insufflation of carbon dioxide, and extreme positions. Anaesthesiologists need to be aware of both the challenges of robotic-assisted surgery and the changes in surgical technique. Robotic-assisted surgery has found widespread application in urology, gynaecology, thoracic, otolaryngology, cardiac, paediatric and general surgery. This review aims to highlight the considerations for the patient presenting for robotic-assisted prostate surgery and will highlight issues in other areas of surgery.

History of robotic-assisted surgery[1]

Minimally invasive surgery began in the late 1980s. The Stanford Research Institute developed a prototype system in 1990 that allowed remote instrument manipulation and stereoscopic vision for use in endoscopic surgery. The United States Department of Defense then tried to use this technology to treat casualties of war to decrease military surgeons' risk and allow remote surgery. This proved problematic due to technological delays and failure. This application was not practically possible because of the problems of delay between input and response during signal transmission. However, this led to the development of the da Vinci Surgical System and was introduced into medical practice in 1999 by the Intuitive Surgical Corporation. There are currently more than 900 such systems in use throughout the world.

The da Vinci Surgical System[2]

This system is currently the most-commonly used and available in South Africa. It has four main components, namely:

1. The master console – the surgeon sits at the console and visualises the surgical field in three-dimensional view via a stereoscope. While in the console, the surgeon is unscrubbed. (See Figure 1.)
2. The actuator – this allows the surgeon to control foot pedals, diathermy, instruments, robotic arms and the camera.



Figure 1: Surgical console



Figure 2: The da Vinci robotic surgical manipulator



Figure 3: Visualisation tower with microphone and speakers

3. A robotic surgical manipulator – the surgeon controls the manipulator. (See Figure 2.)
4. A computer/visualisation tower – this allows for the integration of images from the camera and a monitor, allowing the other theatre staff to observe the surgeon's view. With the surgeon in the master console, a surgically scrubbed assistant is still required to insert and change instruments through the endoscopic ports. Communication can be difficult between the members of the team, so noise levels in the theatre are kept to a minimum. Microphones within the console and speakers within the video towers are used to enhance the surgeon's voice. (See Figure 3.)

Anaesthetic challenges in robotic-assisted surgery

Challenges due to the presence of a robot[3]

The robotic system acts as a telemanipulator. Unlike conventional surgery, the surgeon controls the machine from a distance. The surgeon is only scrubbed for brief periods of time, at the start of surgery to place ports and at the end of surgery to retrieve the specimen and close the port sites. The robot is big and bulky. It takes up quite a bit of space in the theatre, limiting space for the anaesthetist. Depending on the type of robotic-assisted surgery, the robot position may change. In robotic-assisted prostatectomies, the robot is docked (placed) at the foot of the bed but in transoral robotic surgery, the robot is docked at the head of the bed. Once the robot is docked, space and access to the patient is limited.[2,3] Thus, the presence of the robot poses multiple challenges to the anaesthetist, including limited theatre workspace as well as access to the patient.

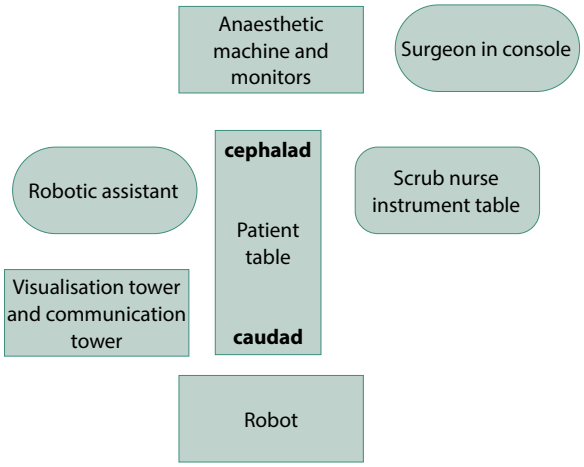

Figure 3: Theatre ergonomics in robotic-assisted prostatectomies

Table I: Advantages and disadvantages of robotic-assisted surgery[1,2,3]

Advantages	Disadvantages
Decreased pain scores	Expensive
Shorter hospital stay	Requires skill and expertise
Less wound infection	Operate using a two-dimensional image in a three-dimensional space
Improved surgical access (three-dimensional image)	Surgeon relies on visual cues to get a sense of force applied
Smaller incisions	Limited mobility and tactile feedback when operating
Decreased morbidity	Disastrous if patient moves
Early mobilisation	Difficult patient access once robot is locked into position
Continually evolving	Atelectasis, raised intracranial pressure
Elimination of physiological hand tremor	Endobronchial intubation
Improved dexterity	Venous air embolism
No workspace limitations	Aspiration risk
Avoidance of surgeon fatigue	System can fail
Decreased blood loss	Acute kidney injury
Decreased need for transfusions	Complications related to positioning: ocular and nerve injuries
Improved cosmetic outcomes	Surgical complications (e.g. perforation or penetration of structures)
	Difficult to access patient in event of cardiovascular collapse

Patient challenges

Patients are usually elderly with comorbidities which should be optimised as for any surgery.[4] Robotic-assisted pelvic surgery can safely be performed in the obese patient. However, the anaesthetist must consider that robotic-assisted prostate surgery predisposes obese patients to various haemodynamic changes and alters already-altered physiology in this patient population. In obese patients, elevations in carbon dioxide due to the pneumoperitoneum may be difficult to eliminate due to decreased lung and chest wall compliance and elevated airway pressures. This is compounded by the steep Trendelenburg position. Postoperatively, obesity predisposes patients to increased risk of respiratory depression and airway compromise.[5]

Extra caution should be taken with pressure points and padding in this patient population.

Challenges due to steep Trendelenburg, lithotomy position and use of laparoscopy

For adequate surgical exposure and the creation of space in the surgical workspace, the insufflation of carbon dioxide is required.[6]

Further challenges include the steep Trendelenburg position used as well as the lithotomy position.[1] Any patient with significant cardiovascular or respiratory compromise should be considered for either an open or a non-surgical intervention. However, as robotic techniques are being refined, patients with challenging physiology are increasingly being done with robotic assistance.

Table II: Physiological changes associated with pneumoperitoneum and steep Trendelenburg[4,7]

System	Physiological effects
Cardiovascular system	↑heart rate, ↑mean arterial pressure, ↑systemic vascular resistance, ↑right atrial pressure
	↓cardiac output, aortic compression
Respiratory system	Diaphragm displaced upward
	↓ pulmonary compliance
	↓ vital capacity
	Ventilation: perfusion mismatch
	↑ peak airway pressure
	Pulmonary congestion and oedema
	Hypercarbia
Miscellaneous	Catecholamine release, increased stress response
	Activation of renin–angiotensin system
	↓renal, splanchnic blood flow and cerebral blood flow
	Oedema of face, eyes, airway
	Nerve injuries and neuropraxias (e.g. brachial plexus)
	Endobronchial intubation, tube migration
	Emphysema due to CO_2 insufflation (subcutaneous)
	Capnomediastinum/capnothorax
	Gastro-oesophageal reflux

Conduct of anaesthesia

Airway and ventilation

The anaesthetic technique of choice is a general anaesthesia due to the use of steep Trendelenburg as well as laparoscopy. Therefore, an endotracheal intubation is also required to allow adequate ventilatory support.[1] A lung protective strategy of ventilation is employed.[4] Owing to carbon dioxide insufflation, the driving pressures are distributed more to the chest wall and less to the lungs. Therefore, accepting higher peak airway pressures may be necessary to prevent atelectasis and maintain adequate ventilation.[4]

Monitoring

Standard American Society of Anesthesiologists monitoring is used and includes blood pressure, electrocardiograph, pulse oximetry, capnography and temperature monitoring. A large bore intravenous access with long extension tubing is usually placed as access is limited once the procedure has started.[8]

Invasive monitoring is not routinely indicated unless the patients' medical condition dictates it.[4] All lines should be placed prior to docking of the robot. If a perioperative cardiovascular emergency arises, a transoesophageal echocardiography is a useful means of assessing cardiac function.[8]

Patient positioning and use of fluids[2,3,4]

Before the robot is docked, the anaesthetist must ensure proper patient padding and positioning. The use of gel pads, foam pads and body-fitting beanbags make positioning easier. Meticulous attention should be placed in protecting the face, eyes, peripheral nerves and pressure points. A non-slip mat is placed under the patient and cross body taping is used so the patient does not slide off the table.[4] Shoulder supports and a horizontal bar should be placed to protect the face from the robotic arms. Most robotic procedures require both arms of the patient to be padded and tucked to the side.

Eyes need to be closed and covered to avoid any ocular injuries. These can range from corneal abrasions (3%) to serious ischaemic optic neuropathy.[3] Chemosis, conjunctival oedema, laryngeal oedema and facial oedema can also occur frequently.[3]

Restrictive intraoperative fluid therapy may minimise these ocular complications.[3] This will also minimise cerebral oedema and minimise delayed awakening and confusion.[3] Other strategies to delay cerebral oedema include minimising the steep Trendelenburg position as well as using lower insufflation pressures. Both the steep position as well as the pneumoperitoneum increase the risk of regurgitation. Placement of a nasogastric tube is thus advised.

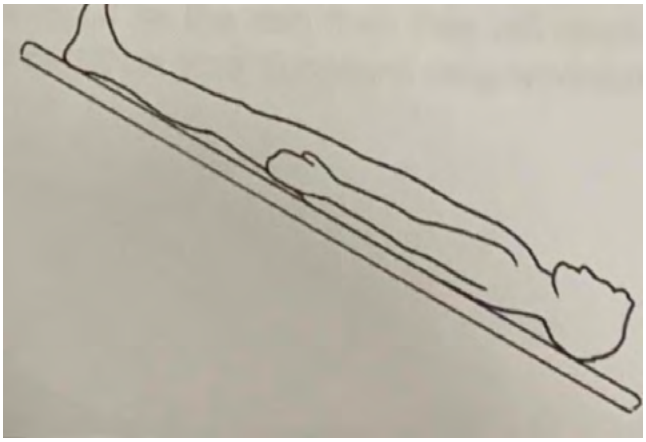

Figure 4: Steep Trendelenburg position with arms tucked in

Maintenance

Intravenous anaesthesia is used for induction and maintenance. It can be either volatile or intravenous based. Owing to the bulky nature of the robot, the anaesthetic workspace and access to the patient are limited. Prior to the docking of the robot, the patient is placed in the lithotomy position and an assessment of haemodynamic and pulmonary function is done by testing in a maximal Trendelenburg position. This test position is also used to check that the patient is well strapped in and will not slip off the table.[4] The steep Trendelenburg position also ensures that the bowel is moved out of the surgical field.[9]

It is imperative to maintain adequate muscle relaxation and, therefore, neuromuscular monitoring is advisable to maintain adequate muscle relaxation as any movement places the patient at risk of visceral or vascular injury.[3]

Hypothermia can occur due to prolonged operative time and should be aggressively treated using a warming blanket and fluid warmers.[7]

These patients are also at risk for deep vein thrombosis (0.5–0.6%) due to the reduction in flow to the lower limbs and compression on the iliac vessels and inferior vena cava. Therefore, sequential calf compression stockings are used.[3,7] A catheter is also inserted.

The abdominal cavity is insufflated with carbon dioxide to a pressure not exceeding 20 mmHg.[8] Newer literature is emerging where lower insufflation pressures of approximately 8–11 mmHg is being used to avoid pneumoperitoneum complications. The tube position with the steep low head position should always be checked to rule out endobronchial intubation.[8]

Even though the literature is controversial on the incidence of postoperative nausea and vomiting (PONV) in laparoscopic surgery, it has been proposed to routinely administer prophylaxis.[4]

A major advantage of robotic-assisted surgery is decreased postoperative pain and reduced opioid consumption. However, analgesia is imperative for early discharge in these patients. Pain can arise from port site incisions (somatic), the peritoneal stretch, manipulation of abdominal tissues (visceral), or even the shoulder tip due to residual carbon dioxide insufflation.[10] The pain is usually low intensity and can be managed parenterally.[3,4] There is a correlation between the amount of residual intraperitoneal carbon dioxide and postoperative pain scores. Therefore, it is imperative to aspirate gas at the end of the procedure and try to use lower insufflating pressures. Multimodal analgesia should be used and a regional technique can be employed. Neuraxial analgesia is debatable. Retrospective studies have suggested that epidural analgesia may delay ambulation and increase the length of hospital stay, thus defeating the advantages of using a robotic-assisted techniques in surgery.[4] The PROSPECT working group compared spinal morphine versus intravenous patient-controlled analgesia in laparoscopic cholecystectomies and concluded that although pain scores are lower in the spinal morphine group, the benefit does not outweigh the pruritus and respiratory depression of the intrathecal morphine.[11] Bae et al.[12] suggest that the use of spinal morphine has, however, decreased the use of systemic opiates. Intrathecal morphine provided more satisfactory analgesia without serious complications during the early postoperative period in patients undergoing robotic-assisted prostatectomies.[12]

The use of paravertebral blocks appears promising in patients undergoing laparoscopic cholecystectomy and studies need to look at its role in this surgery. Intraperitoneal instillation of local anaesthesia, like ropivicaine or bupivacaine, may reduce postoperative pain following laparoscopic surgery.[4]

Intraoperative blood loss is minimal and does not usually warrant a blood transfusion.[2]

Postoperative management

At the end of the procedure, the specimen is retrieved in the supine position and any neuromuscular blockade is fully reversed using sugammadex. Note any oedema of airways, or cerebral or facial oedema at the end of the procedure. Insufflation gases are switched off and the abdomen is decompressed.

Owing to fluid restriction, there is an increased likelihood of acute renal injury. It is thus important to adequately hydrate patients. Renal function must be monitored postoperatively.[4]

Gastric ileus and abdominal distension can occur. Management includes checking potassium levels and electrolyte levels, and replacing if necessary, as well as nasogastric tube decompression and hydration.

The lower limbs should be observed for the development of lower limb compartment syndrome due to the prolonged lithotomy position. However, Takechi et al.[13] looked at lower limb perfusion with near infrared spectroscopy and concluded that during the robotic-assisted prostatectomies, lower limb perfusion is maintained. Thus, correct patient positioning and assessment of vascular risk factors are more important to prevent lower limb compartment syndrome.[13]

The risk factors for venous thromboembolism (VTE) in these patients include presence of malignancy, age above 60, obesity, presence of thrombophilia, family history of VTE, use of hormone replacement therapy and anaesthetic time greater than 90 minutes.[14] The use of robotic-assisted surgery has resulted in a decreased incidence of postoperative VTE. The decision to administer pharmacologic thromboprophylaxis should be taken on an individual patient basis, weighing the risks and the benefits.[14] In our unit, pharmacologic prophylaxis is used routinely if no contraindication exists. Mechanical thromboprophylaxis is, however, always indicated and early postoperative mobilisation is encouraged.[14]

Surgical drains and nasogastric tubes should also be removed as soon as possible to hasten recovery and early discharge.

Other robotic procedures

The use of the robot is not exclusively for urological procedures like prostatectomies and cystoprostatectomies. Other uses include gynaecological procedures, thoracic surgery, transoral surgery and cardiac surgery.[8,15]

Gynaecological procedures[15]

Procedures such as hysterectomies, myomectomies, tubal re-anastomosis and radical hysterectomies have been performed with robotic assistance. The anaesthetic considerations are very similar to those of robotic-assisted prostatectomies.

Thoracic surgery[16]

Lobectomies, oesophageal tumours, mediastinal tumours and diaphragmatic plication are being done via robotic devices. The same preoperative considerations as for conventional thoracic surgery apply. It involves prolonged one-lung ventilation and a double lumen tube is indicated. Special attention should be given to positioning for the lateral decubitus position with the non- dependant arm abducted, increasing the risk for neurological injuries. An arterial line is advised. CO_2 insufflation considerations also apply.

Cardiovascular surgery[8,15]

The da Vinci Surgical System is used for mitral valve repairs, coronary revascularisations and atrial fibrillation ablations. Anaesthetic considerations include one-lung ventilation, creating a capnothorax, the use of transoesophageal echocardiography, prolonged cardio-pulmonary bypass and limited patient access. Robotic-assisted cardiovascular surgery allows for early mobilisation and avoids sternotomy.

Otolaryngology, head and neck surgery[2,8]

The da Vinci Surgical System is also used for transoral robotic surgery (TORS). Procedures include tongue base resections, oropharyngeal cancer resections and treatment of obstructive sleep apnoea.

Anaesthetic considerations include sharing a potentially difficult airway with the robot as well as injury to surrounding structures as there is limited supervision of the robotic arms during surgery.

Abdominal surgery

In Southern Africa, the robot is being used more frequently for abdominal surgery. Surgeons are being trained and the learning curve is quite steep. Not only hollow viscus, but solid abdominal surgery can be done robotically. The robotic cart is placed at the head side of the patient so access to the head is limited. A reverse Trendelenburg position is usually used. Operating times can be quite long.[8]

Paediatric surgery[15]

Robotic-assisted paediatric surgery is a bit trickier due to the limited workspace, thinner abdominal wall and risk of injury with port placement and manipulation. Procedures include patent ductus arteriosus closure, pyeloplasty and congenital hernia repair. Limitations currently include lack of correct port sizes and limited instrumentation selection.

Conclusion

In summary, even though robotic-assisted procedures are costly in countries like South Africa, their usage is increasing. The invasion of the robot in our theatre spaces does come with challenges. However, with the popularity of minimally invasive procedures and even enhanced recovery after surgery, robotic-assisted procedures are carving a niche in surgery. To future-proof ourselves as anaesthesiologists, we need to be aware of and equip ourselves with the knowledge in dealing with the challenges of patient selection, patient positioning, the presence of the robot in theatre, and how it impacts our anaesthetic.

Conflicts of interest

The author declares no conflict of interest.

ORCID

S Mayet https://orcid.org/0000-0001-8101-4436

References

1. Irvine M, Patil V. Anaesthesia for robot-assisted laparoscopic surgery. Continuing Education in Anaesthesia Critical Care & Pain. 2009;9(4):125-9. https://doi.org/10.1093/bjaceaccp/mkp020.
2. Iqbal H, Gray M, Gowrie-Mohan S. Anaesthesia for robot-assisted urological surgery [Internet]. London: World Federation of Societies of Anesthesiologists; 2019. Available from: https://resources.wfsahq.org/atotw/anaesthesia-for-robot-assisted-urological-surgery/.
3. Pathirana S, Kam PCA. Anaesthetic issues in robotic-assisted minimally invasive surgery. Anaesth Intensive Care. 2018;46(1):25-35. https://doi.org/10.1177/0310057X1804600105.
4. Joshi GP. Anesthesia for laparoscopic and abdominal robotic surgery in adults. UpToDate [Internet]. 2021. Available from: https://www.uptodate.com/contents/anesthesia-for-laparoscopic-and-abdominal-robotic-surgery-in-adults.
5. Dalton A. Obesity and robotic surgery. Anaesthesia Patient Safety Foundation [Internet]. 2018;33(2). Available from: https://www.apsf.org/article/obesity-and-robotic-surgery/.
6. Arslan M, Özgök A. Complications of robotic and laparoscopic urologic surgery relevant to anesthesia. Mini-invasive Surg. 2018;2(3):4. https://doi.org/10.20517/2574-1225.2017.31.
7. Carey B, Jones C, Fawcett W. Anaesthesia for minimally invasive abdominal and pelvic surgery. BJA Educ. 2019;19(8):254-60. https://doi.org/10.1016/j.bjae.2019.04.001.
8. Paranjabe S, Chhabra A. Anaesthesia for robotic surgery. Trends in Anaesthesia and Critical Care. 2014;4:25-31. https://doi.org/10.1016/j.tacc.2013.10.003.
9. Awad H, Walker C, Shaikh M, et al. Anesthetic considerations for robotic prostatectomy: a review of the literature. J Clin Anesth. 2012;24(6):494-504. https://doi.org/10.1016/j.jclinane.2012.03.003.
10. Batley SE, Prasad V, Vasdev N, Mohan-S G. Post-operative pain management in patients undergoing robotic urological surgery. Curr Urol. 2016;9(1):5-11. https://doi.org/10.1159/000442843.
11. Joshi GP, Bonnet F, Kehlet H. Evidence based postoperative pain management after laparoscopic surgery. Colorectal Dis. 2013;15:146-55. https://doi.org/10.1111/j.1463-1318.2012.03062.x.
12. Bae J, Kim HC, Hong DM. Intrathecal morphine for postoperative pain control following robot-assisted prostatectomy: a prospective randomized trial. J Anesth. 2017;31(4):565-71. https://doi.org/10.1007/s00540-017-2356-9.
13. Takechi K, Kitamura S, Shimizu I, Yorozuya T. Lower limb perfusion during robotic-assisted laparoscopic radical prostatectomy evaluated by near-infrared spectroscopy: an observational prospective study. BMC Anesthesiol. 2018;18(1):114. https://doi.org/10.1186/s12871-018-0567-8.
14. Hariharan U, Shah SB. Venous thromboembolism and robotic surgery: need for prophylaxis and review of literature. J Hematol Thrombo Dis. 2015;3(6):100D27. https://doi.org/10.4172/2329-8790.1000227
15. Lee J. Anesthetic considerations for robotic surgery. Korean J Anesthesiol. 2014;66(1):3. https://doi.org/10.4097/kjae.2014.66.1.3.
16. Zhang Y, Wang S, Sun Y. Anesthesia of robotic thoracic surgery. Ann Transl Med. 2015;3(5):71. https://doi.org/10.3978/j.issn.2305-5839.2015.03.03.