

https://dspace.org/

Error analysis of digital panoramic radiographs taken at the wits oral health centre

Tasseva, Hristinka Atanassova

2016-11-03
http://hdl.handle.net/10539/21366

Downloaded from a DSpace repository. https://dspace.org/

ERROR ANALYSIS OF DIGITAL PANORAMIC RADIOGRAPHS TAKEN AT THE WITS ORAL HEALTH CENTRE

Hristinka Atanassova Tasseva

A research report submitted to the Faculty of Health Sciences, University of the Witwatersrand, Johannesburg, in partial fulfilment of the requirements for the degree of Master of Science in Dentistry.

Johannesburg, 2016

DECLARATION

I, Hristinka Atanassova Tasseva declare that this research report is my own unaided work. It is being submitted for the degree of Master of Science in Dentistry at the University of Witwatersrand, Johannesburg. It has not been submitted before for any degree or examination at this or any other University.

…….

This 15th day of June 2016 in Johannesburg.

ABSTRACT

Aim: The aim of this research was to carry out a prospective analysis of digital panoramic positioning errors with a view to assessing how closely internationally recommended targets of Quality Assurance (QA) in Dental Radiology are met in the Radiology section of the Department of General Dental Practice (GDP), Wits Oral Health Centre (WOHC).

Method and Materials: Six hundred digital panoramic radiographs, taken as a sequential sample, were visually examined and evaluated for eleven (11) categories of prevalent positioning errors. All positioning faults were recorded based on assessment criteria and the diagnostic quality of each radiograph was determined on a scale of 1 to 3 and compared to British Dental Association (BDA) internationally recommended targets.

Random sub-samples of 20% were re-examined at two (2) weeks and four (4) weeks to determine intra-observer reliability, and once by an outside observer to determine inter-observer agreement.

Results: The most common positioning error was that the tongue was not placed against the palate (34.3%).

The percentage of "excellent" radiographs (34.5%) was significantly below the BDA standard of $\geq 70\%$ ($p<0.0001$).

The percentage of "diagnostically acceptable" radiographs (44.5%) was significantly above the BDA standard of $\leq 20\%$ ($p<0.0001$).

The percentage of "totally unacceptable" radiographs (21.0%) was significantly above the BDA standard of $\leq 10\%$ ($p<0.0001$).

In other words, the results for the quality of the digital panoramic radiographs for the Wits Oral Health Centre did not meet the BDA standards.

In conclusion, more meticulous training of students and operators is recommended.

ACKNOWLEDGEMENTS

I would like to thank the following people:

My mentor Eric Pepin for his guidance and support and for believing in me when I had doubts that I could achieve what I had done. His wise words: “Consistency is #1 Secret to learning and developing anything” motivated me throughout my study.

My supervisor Professor Brian Buch for his endless encouragement to believe in myself and to help me develop my professional skills; for his guidance and support, not only over the course of my studies, but any time I needed it.

Professor CP Owen for the invaluable guidance and help with corrections of my research protocol and title.

Dr Petra Gaylard for the statistical evaluation of my research efforts.

My daughter Dr Marina Dobreva, the Light of my life, for her invaluable criticism of my report, and kind support over the course of my studies.

My colleagues at the Wits Oral Health Center who have taken part in the production of the radiographs in this study and who have been personally supportive over the course of my studies.

Table of Contents

DECLARATION ii

ABSTRACT iii

ACKNOWLEDGEMENTS iv

Table of Contents v

LIST OF FIGURES vi

LIST OF TABLES vii

LIST OF ACRONYMS viii

CHAPTER 1 – INTRODUCTION AND LITERATURE REVIEW 1

1.1. Background 1

1.2. Literature Review 4

1.3. Conclusions 7

CHAPTER 2 – AIM AND OBJECTIVES 8

2.1. Aim of the Study 8

2.2. Objectives 8

2.3. Hypothesis 8

CHAPTER 3 – METHOD AND MATERIALS 9

3.1. Study Sample 9

3.2. Limitation of Study 10

3.3. Method and Materials 10

3.4. Statistical Analysis 15

CHAPTER 4 – RESULTS 17

CHAPTER 5 – DISCUSSION 23

5.1. Quantifying the Radiographic Faults 23

5.2. Categorising the Panoramic Radiographs According to BDA Internationally Recommended Targets. 37

CHAPTER 6 – CONCLUSION AND RECOMMENDATIONS 39

CHAPTER 7 - REFERENCES 41

APPENDIX A 45

APPENDIX B 46

APPENDIX C 47

APPENDIX D 48

APPENDIX E 49

APPENDIX F 50

LIST OF FIGURES

Figure 4.1 Prevalence of 11 categories of positioning errors.....17

Figure 4.2 Distribution of the number of positioning errors.....18

Figure 4.3 Diagnostic quality classification of digital panoramic radiographs.....19

Figure 5.1 Appearance of a diagnostically acceptable panoramic radiograph.....24

Figure 5.2 Tongue not placed against the palate.....24

Figure 5.3 Patient biting too far forward in relation to the focal trough.....26

Figure 5.4 Patient biting forward as a result of "lip support piece" inadequately used. ..27

Figure 5.5 Patient's head turned to one side.....28

Figure 5.6 Patient biting too far backward in relation to the focal trough.....30

Figure 5.7 Patient's chin not positioned on the chin rest (above).....31

Figure 5.8 Patient's chin not positioned on the chin rest (below).....32

Figure 5.9 Patient's chin positioned too high.....32

Figure 5.10 Patient's head tilted to one side.....33

Figure 5.11 Patient's chin positioned too low. 34

Figure 5.12 Partial upper metallic denture left in the mouth.....35

Figure 5.13 Failure to remove metallic earrings. 35

Figure 5.14 Slumped position of the patient.....36

Figure 5.15 Patient's movement during exposure.....37

LIST OF TABLES

Table 3.1 Positioning errors and criteria for assessment of each error (Based on Moore, 2002). 13

Table 3.2 Quality ratings for digital panoramic radiographs and their criteria for assessment (Modified from National Radiological Protection Board, 2001). 14

Table 4.1 Distribution of error types within the group of totally unacceptable radiographs. 20

Table 4.2 Statistical reliability for the diagnostic quality classification. 20

Table 4.3 Statistical reliability for the 11 different categories of positioning errors. 21

Table B1 Characteristics of the various studies. 46

Table D1 Example of data capturing sheet. 48

LIST OF ACRONYMS

BDA	British Dental Association
BDS	Bachelor of Dental Science
BOHSc	Bachelor of Oral Health Science
CI	Confidence Interval
GDP	General Dental Practice
IPS	In-plane Switching
JPEG	Joint Photographic Experts Group
LED	Light Emitting Diode
NRPB	National Radiological Protection Board
QA	Quality Assurance
SAS	Statistical Analysis System
SP	Storage Phosphor
TMJ	Temporo-mandibular Joints
USB	Universal Serial Bus
WOHC	Wits Oral Health Centre

CHAPTER 1 – INTRODUCTION AND LITERATURE REVIEW

1.1. Background

1.1.1. Panoramic Radiography

A panoramic radiograph is an extra-oral image that projects a modified tomographic area of the maxillary and mandibular arches with their corresponding dentition and surrounding structures, including certain mid-facial features viz. the maxillary sinuses, nasal cavity, Temporo-mandibular Joints (TMJ) and the lower part of the orbits. It is used exclusively in Dentistry as a routine screening view for all new patients (Scarfe & Williamson, 2015). Production of an image of both jaws without superimposition of structures has been a difficult task because of their unique shape. After many experimental tomographic machines applied to the dental arches, one that uses a narrow slit-collimated X-ray beam combined with rotational tomography has eventually been implemented to record a curved tomographic slice that follows the shape of the jaws. This slice is termed the "focal trough" (Whaites & Drage, 2013).

1.1.2. Focal Trough

The focal trough is a tomographic area, inherent in a specific machine, where the captured area of the patient's anatomical structures will display the most clarity and detail on the resultant film. Anatomical structures outside of this focal trough will appear out of focus and blurred or may present as "ghost" images: magnified or reduced in size, sometimes distorted (McDavid et al, 1983). Correct positioning of the patient's head within the panoramic machine is therefore critical (Murray & Whyte, 2002; Rondon et al, 2014). Standards for correct patient preparation and positioning are explained in section 3.3 of the current study.

All modern panoramic X-ray machines operate on a constantly moving centre of rotation, which describes a quasi-parabolic path. This ensures that the focal trough area coincides as closely as possible with the shape of the dental arches. The curved jaws are displayed as a flattened out panoramic projection. The path of rotation can be adjusted to conform to the focal trough of patients with different jaw sizes, including paediatric patients. This is achieved by adjustment through varying the shape of the moving centre of rotation. Different jaw shapes as well as levels of protrusion and retrusion may also be preselected to accommodate for orthodontic patients (See Appendix A, Fig. A2).

A series of lights projected onto the patient's face in the vertical and horizontal planes facilitate patient positioning within the panoramic machine. Care must be taken to ensure that the vertical light coincides accurately with the mid-sagittal plane. An incorrect mid-sagittal plane will result in distortion in the horizontal plane. By the same token the horizontal light must conform accurately with the Frankfort plane (a plane passing through the inferior margin of the orbit and the external auditory meatus) to avoid distortion in the vertical plane. Horizontal magnification is determined by the patient's positioning within the focal trough.

Incorrect calibration of the panoramic machine may lead to an incorrect path of rotation resulting in a focal trough not coinciding accurately with the shape of the dental arches. This would affect the image quality by altering the ratio between vertical and horizontal magnification of structures within the focal trough (Razmus et al, 1989). Implementation of a Quality Assurance programme requires regular appraisal of calibration during routine servicing of the panoramic machine.

1.1.3. Digitalization of Radiographic Images

As new technologies develop, one of the most useful to date is the digitalization of radiographic images (Angelopoulos et al, 2004). Digital panoramic radiographs are no exception. There are several advantages of digital over analogue radiography (Angelopoulos et al, 2004): it saves time, as chemical processing is not necessary; the elimination of darkroom facilities lowers the cost of a radiograph; the time saved enables the radiographic staff to attend to more patients; and patient exposure to radiation is reduced due to shorter exposure times. Further studies have also shown that many dentists do not utilise new technology and cause unnecessary radiation exposure to patients (Shahab et al, 2012).

Wastage of material, unnecessary expenditure and environmental pollution was a reality in the era of analogue radiography (Farman, 2007; White & Pharoah, 2009; Shahab et al, 2012). Digitalization, on the other hand, reduces environmental pollution. Furthermore, the requirement for large physical storage facilities is removed.

Overloading of the digital database can be obviated to some extent by image compression and can assist in the electronic transmission of images. A further advantage is the fact that the digital image is a dynamic entity that can be additionally modified in order to optimize diagnosis (Angelopoulos et al, 2004; Farman, 2007).

1.1.4. Retaking of Radiographs and Its Consequences

Retaking of radiographs is an unfortunate reality in teaching institutions, resulting in unnecessary radiation to patients (Rushton et al, 1999; Akarslan et al, 2003; Kaviani et al, 2008; Bissoon et al, 2012; Choi et al, 2012; Dhillon et al, 2012; Granlund et al, 2012; Peretz et al, 2012; Mayil et al, 2014; Rondon et al, 2014). The advantage of shorter exposure times would therefore be negated should a retake be necessary.

However, storage of diagnostic data on magnetic or optical media raises the issue of overloading the database thereby reducing the speed of access of the image especially if the clinic is a busy one (White & Pharoah, 2009). The file size of dental radiographs varies but the average for an extra-oral radiograph is of the order of 6 megabytes (Angelopoulos et al, 2004; White & Pharoah, 2009). If one assumes an approximate turnover of 12,000 panoramic radiographs in a year at the Wits Dental Hospital with a retake figure of up to 30%, being a teaching hospital, this would place a considerable burden on the database as well as the patients. Hence a significant reduction in repeat radiographs will reduce database overload and patient exposure.

A change from analogue to digital imaging has resulted in considerable time-saving by radiographers. A study done by Wenzel & Møystad in 2001 estimated that the average time saved by sensor users was 36 min/day and that by storage phosphor (SP) users was 25 min/day. This advantage would be lost should retakes occur.

1.2. Literature Review

Numerous studies have analysed the quality and have quantified various errors and further assessed the reasons for retakes of panoramic radiographs (Schiff et al, 1986; Glass et al, 1994; Rushton et al, 1999; Akarslan et al, 2003; Kaviani et al, 2008; Bissoon et al, 2012; Choi et al, 2012; Dhillon et al, 2012; Granlund et al, 2012; Peretz et al, 2012; Mayil et al, 2014). See Appendix B, Table B1.

1.2.1. Analogue Radiographs

Two of those studies performed by Choi et al (2012) and Mayil et al (2014) assessed mainly the quality of non-digital panoramic radiographs. They utilised a similar clinical image quality evaluation chart. In addition, Choi et al (2012) analysed the ‘parameters that influence

the overall image quality', while Mayil et al (2014) identified the specific errors responsible for 'diagnostically inadequate images'. In most cases the analysed panoramic errors were due to positioning, processing, exposure factors, and anatomic abnormalities. They graded the image quality of panoramic positioning errors without stipulating the most common error and the percentage thereof.

Two other investigations carried out by Rushton et al (1999) and Akarslan et al (2003) on analogue panoramic radiographs concentrated more on various positioning and processing errors. In addition Akarslan et al (2003) included 'superimposition of hyoid bone', 'vertebral column superimposed on anterior teeth', and 'narrowed anterior teeth' as stand-alone categories. These in the majority of other studies are considered as features of standard positioning errors. Nonetheless these studies analysed errors in detail and outlined those most commonly encountered.

The study carried out by Kaviani et al in 2008 considered positioning errors as 'the most common errors' (78%) and focused on processing and exposure errors as well as anatomic abnormalities.

In those studies evaluating analogue panoramic radiographs failure to position the tongue against the palate was a predominant error according to Schiff et al (1986) with 34.7% for 'films made by trained technician' and 25.7% for 'films selected at random'; Rushton et al (1999) reported this error at 71.6%; Akarslan et al (2003) at 46.3%; and Bissoon et al (2012) reported it as 62% for a dental hospital. According to Glass et al (1994) the most common error was positioning the chin too high at 41.3%; Kaviani et al (2008) reported head twist as the most common error at 39.5%. Bissoon et al (2012) reported rotation of the head (74%) as the most common error for their private practice sample.

1.2.2. Digital Radiographs

Studies that concentrated specifically on digital panoramic radiographs, described in great depth the positioning faults encountered during taking of radiographs (Dhillon et al, 2012; Granlund et al, 2012; Peretz et al, 2012). They classified positioning errors in up to 12 categories and ascribed a percentage to the various faults. The most common error was failure to position the tongue against the palate. Dhillon et al (2012) reported it as 55.7%; Granlund et al (2012) as 79%; and Peretz et al (2012) reported it as 60.1% for the mixed dentition and 52.7% for the permanent dentition.

In most studies (Rushton et al, 1999; Kaviani et al, 2008; Choi et al, 2012; Dhillon et al, 2012; Mayil et al, 2014) the quality of the radiograph was taken into account and was put into either three or four categories. With three categories, the radiograph was termed excellent or optimal for diagnostic interpretation, diagnostically acceptable, or diagnostically unacceptable. In the case of four categories (Choi et al, 2012 & Mayil et al, 2014) the diagnostically acceptable category was further divided into adequate for diagnosis and poor but diagnosable.

Two studies (Bissoon et al, 2012 and Granlund et al, 2012) mentioned only radiographs without faults and their percentage; therefore they did not state how many radiographs were diagnostically unacceptable.

1.2.3. Quality Assurance

The working party of the British Dental Association (BDA) was tasked with producing guidance notes for internationally recommended targets of Quality Assurance in Dental Radiology. They used the following subjective quality rating system, which specified minimum targets for quality of radiographs that should be achieved in three years of

implementation of any Quality Assurance (QA) programme (National Radiological Protection Board, 2001):

- Excellent - not less than 70%.
- Diagnostically acceptable - not greater than 20%.
- Unacceptable - not greater than 10%.

1.3. Conclusions

The BDA guidelines were developed in response to the inconsistencies in the literature over the methods used to evaluate the quality of radiographs. As no studies have been carried out in South Africa using the guidelines, it was decided that a measurement of the quality of panoramic radiographs taken in the WOHC would be of value. Results would assist not only in training but also in the prevention of retakes.

CHAPTER 2 – AIM AND OBJECTIVES

2.1. Aim of the Study

The aim of this research was to carry out a retrospective analysis of digital panoramic positioning errors with a view to assessing how closely internationally recommended targets of Quality Assurance in Dental Radiology at the Wits Oral Health Centre are met.

2.2. Objectives

2.2.1. Quantify the radiographic faults in order to identify the most common panoramic positioning error/s.

2.2.2. Categorise the panoramic radiographs according to BDA internationally recommended targets of Quality Assurance in Dental Radiology (National Radiological Protection Board, 2001).

2.3. Hypothesis

The hypothesis is that the quality of panoramic radiographs taken at the WOHC conforms to the BDA quality assurance targets.

CHAPTER 3 – METHOD AND MATERIALS

3.1. Study Sample

The study population comprised 600 digital panoramic radiographs taken as a sequential sample from 9th July 2015 at the Radiology section of General Dental Practice Department, Wits Oral Health Centre. All 600 radiographs were taken within a period of 13 working days. Twenty percent of the above-mentioned sample (120 radiographs) were sub-sampled by random sampling for the determination of intra- and inter-observer agreement.

The sample size of 600 is sufficient for the estimation of a 50% proportion of an error with 5% precision, and the estimation of a 5% proportion of an error with 2% precision (based on the 95% confidence interval). Sample size for proportions was determined using the formula:

$$n = Z^2 P (1-P)/d^2$$

where

n = sample size, Z = Z-statistic for the chosen level of confidence,

P = expected prevalence or proportion, d = precision (Daniel, 1999).

For all kappa-like agreement coefficients, the required number of subjects (n) depends on the relative error (r), the number of subjects in the entire population (N) and the difference $p_a - p_e$ between the overall agreement probability p_a and the chance agreement probability p_e as follows:

$$n=n^*/ (1 + n^*/N),$$

where

$$n^*= 1/r^2(p_a – p_e)^2$$

Assuming that N is very large, and that the chance-agreement probability is 0, the overall agreement probability is at least 0.5, and a relative error of 20%, the required n is 100. The chosen sample size of 120 is thus adequate for the purposes of this study (Gwet, 2008).

3.1.1. Inclusion Criteria

Radiographs of all patients referred to the Radiology Section of Wits Oral Health Centre regardless of age, gender, either dentate or edentulous, were included in the study.
Patients with pathological conditions or trauma in the maxillofacial region were not excluded.
Only original (not repeat) radiographs were eligible for inclusion in the study.

3.1.2. Exclusion criteria

There were no exclusion criteria stipulated for the study sample.

3.2. Limitation of Study

It should be noted that certain skeletal abnormalities, e.g. facial hypertrophy may be mistaken for a positioning error by an inexperienced observer. However minor anatomical abnormalities are usually apparent on a radiograph and not erroneously recorded as a positioning error.

3.3. Method and Materials

The study was conducted in the Radiology Section of Wits Oral Health Centre after obtaining an ethical clearance from the Human Research Ethics Committee (Medical): Clearance certificate number M150642 (08/07/2015), and approval to utilize the resources in the Radiology section of Wits Oral Health Centre from Hospital Research and Ethics Committee: Reference number HREC/Oct/2015/01 (See APPENDIX E and F).

The digital panoramic radiographs were taken by the following operators:

Three full-time radiographers with a minimum of 3 years' experience (one with 11 years' experience) in the dental radiography field.

One part-time/sessional radiographer and one part-time/sessional oral hygienist with 19 and 6 years' experience in the dental radiography field respectively.

Dental students (in the third and fourth year of their Bachelor of Dental Science Degree).

Oral hygiene students (in the second year of their Bachelor of Oral Health Science Degree).

All the students fell under the supervision of four trained dentists in the Radiography and Radiology field.

No operator was aware of the on-going data collection for the current study.

Three Digital Panoramic X-ray machines: SIRONA ORTHOPHOS XG 5/ Ceph; SIRONA ORTHOPHOS XG^{Plus} DS/Ceph; and SIRONA ORTHOPHOS XG 3D/Ceph (see APPENDIX A, Fig. A1) were used to capture the images.

All the above machines are calibrated on a regular basis by an experienced professional technician.

The following standards for patient preparation and correct positioning within the panoramic machine have been set-up and are in routine use by operators in the Radiology section:

i. Patient is instructed to remove all dentures, appliances, and jewellery (see APPENDIX C, Fig. C1), and clothing that may interfere with the equipment.
ii. Operator explains the procedure to the patient.
iii. Bite block or lip support is covered with plastic protective sleeve and parts of the machine in contact with patient's head or hands are disinfected.
iv. Patient is instructed to stand upright and to hold the hand grips.
v. The machine is adjusted to patient's height so that the bite block is in front of

the mouth aperture.

vi. The patient is instructed to place the chin on the chin rest and bite with the front teeth in the groove of the bite block. If "lip support piece" is used, the patient's base of nose should be placed against it, or between the chin and lower lip if lower anterior teeth are present.

vii. Frankfort horizontal plane (a plane passing through the inferior margin of the orbit and the external auditory meatus) is aligned with the horizontal light beam and parallel to the floor (see APPENDIX C, Fig. C2).

viii. Mid-sagittal plane is aligned with the central light line/beam (see APPENDIX C, Fig. C2).

ix. Cervical spine is straight; shoulders are relaxed, not interfering with the machine.

x. Operator closes the temple and forehead supports.

xi. Patient is instructed to keep the tongue against the palate, close his /her lips, and to remain still during the exposure.

The captured image is saved automatically on the patient's database and cannot be deleted by any of the operators.

Each radiograph was numbered and exported to a Universal Serial Bus (USB) Flash Drive in a Joint Photographic Experts Group (JPEG) format.

Each radiograph was then visually examined on a high-resolution screen (2560 X 1600 pixels) with a build-in Retina Display: 13.3-inch (diagonal) light emitting diode (LED) backlit display with in-plane switching (IPS) technology, and in subdued lighting.

All positioning errors were recorded according to the criteria stipulated in Table 3.1.

The statistical analysis as outlined in 3.4. below was used in order to calculate the percentage of each fault and thereby identify the most common positioning error.

Table 3.1 Positioning errors and criteria for assessment of each error (Based on Moore, 2002).

	Positioning errors	Criteria for assessment
a	Patient biting too far forward in relation to the focal trough.	Small, narrow and blurred anterior teeth. Superimposition of cervical spine on rami or cervical spine visible on sides of film.
b	Patient biting too far backward in relation to the focal trough.	Wide, blurred anterior teeth, ghosting of mandible and cervical spine, condyles close to edges of the film.
c	Patient's chin positioned too low.	Excessive curving of occlusal plane, V-shaped. Blurred image of roots of lower anterior teeth. Narrowing of intercondylar distance, condyles at top of film.
d	Patient's chin positioned too high.	Flattening or reverse curvature of occlusal plane. Blurred image of roots of upper anterior teeth. Lengthening of intercondylar distance, condyles at edges of the film. Shadow of hard palate superimposed on apices of maxillary teeth.
e	Patient's head turned to one side.	Unequal right/left magnification, teeth narrow on one side and wide on the other. Overlap of contact points and uneven blurring throughout arches. Nasal structures not clear.
f	Patient's head tilted to one side.	Mandible appears tilted on the film. Unequal distance between mandible and chin rest at a given point on right and left sides.
g	Tongue not placed against the palate.	Relative radiolucency between dorsum of tongue and palatal vault obscuring apices of maxillary teeth.
h	Patient movement during exposure.	Wavy outline of cortex of inferior border of mandible. Blurring of image above the wavy cortical outline.
i	Failure to remove metallic objects in the head, neck, and orofacial region, e.g. upper and/or lower partial dentures, tongue bar, nose ring, spectacles, hair clips, earrings, necklace, lead apron above collar line.	Evidence of prostheses, tongue bar, nose ring, spectacles, hair clips, earrings, necklace on the film. Ghost images of jewellery. White opacity in palate (from tongue bar). Pyramid - shaped opacity at bottom of film (caused by lead apron).
j	Patient's chin not positioned on the chin rest.	Excessive distance between the chin and chin rest resulting in top of condyles being cut off. Alternatively patient's chin being cut off.
k	Slumped position of the patient.	Ghost image (pyramid shaped opacity) of cervical spine superimposed on midline region of the film.

The diagnostic quality of the assessed 600 digital panoramic radiographs was determined on a scale of 1 to 3 where 1 is faultless/ excellent, 2 is diagnostically acceptable despite the positioning error, and 3 is totally unacceptable. For every point on that scale of errors there is a quality assurance associated percentage given in the guidelines of the Department of Health England, National Radiological Protection Board (2001). For a quality-rating, targets and criteria for assessment see Table 3.2.

A comparison was made between the percentages calculated for Wits Oral Health Centre and the percentages given by NRPB**.**

Table 3.2 Quality ratings for digital panoramic radiographs and their criteria for assessment (Modified from National Radiological Protection Board, 2001).

Rating	Quality	Percentage	Criteria
		Target	
1	Faultless/ excellent	Not less than 70%	No positioning error/s
2	Diagnostically acceptable	Not greater than 20%	Diagnostic radiograph despite positioning error/s
3	Unacceptable	Not greater than 10%	Positioning error/s that render the radiograph non diagnostic

Two (2) random sub-samples of 20% of the original sample (2x120 radiographs) were selected using a Research Randomizer form (Urbaniak and Plous, 1997-2008).
One of the sub-samples was re-examined at 2 weeks and the second sub-sample at 4 weeks to determine their diagnostic quality, to quantify the errors, and thus determine the intra-observer reliability.

Another random sub-sample of 20% of the original sample (120 radiographs) was selected in the same way and evaluated by an outside observer once to determine the inter-observer agreement on the diagnostic quality and quantification of error/s on the radiographs.

A Microsoft® Excel® for Mac 2011 spreadsheet was used to capture the data (see APPENDIX D, Table D1).

Data preparation/cleaning was performed in consultation with a statistician.

3.4. Statistical Analysis

Descriptive analysis of the data was carried out as follows:

Categorical variables were summarized by frequency and percentage tabulation, and illustrated by means of bar charts.

Percentage of the occurrence of the positioning errors was determined by the formula:

$$\%Error = R_e/R_t \times 100$$

where

R_e is the total number of a specific positioning error; R_t is the total number of radiographs.

The percentages of errors falling into the categories of faultless/excellent, diagnostically acceptable despite the positioning error, and totally unacceptable radiographs were calculated, to determine if these were within the range of international quality assurance standards (National Radiological Protection Board, 2001).

Percentages estimated for the quality rating of the radiographs were compared to the NRPB norms using the binomial test.

For the randomly selected sub-samples of the radiographs (inter- and intra-rater agreement), the Quality Rating (three categories) was assessed by Cohen's weighted kappa. Inter- or and intra-rater biases were assessed by the Stuart-Maxwell test.

Inter- and intra-rater agreement for the positioning errors (two categories) was assessed by Cohen's kappa. Inter- and/or intra-rater biases were assessed by Bowker's test of symmetry (Shoukri, 2004).

Data analysis was carried out using Statistical Analysis System (SAS). (SAS Institute Inc, 2002-2010).

The 5% significance level was used throughout, unless otherwise specified.

In other words, p-values <0.05 indicate significant results.

CHAPTER 4 – RESULTS

The results of the descriptive analysis of the positioning errors and the three (3) categories for diagnostic quality of the radiographs are presented in the figures below.

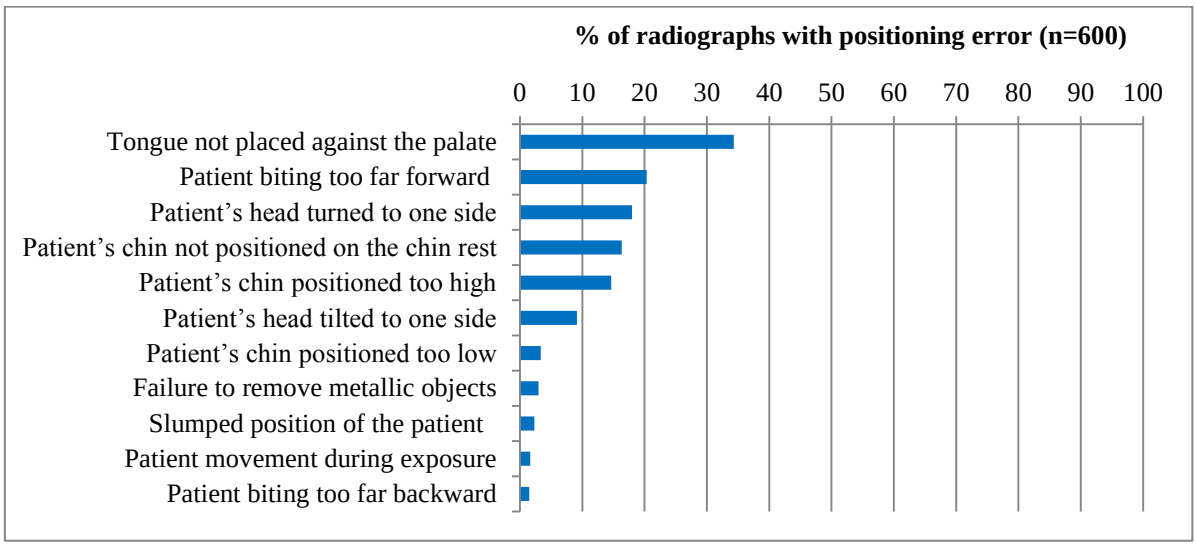

Figure 4.1 Prevalence of 11 categories of positioning errors.

Figure 4.1 shows the percentage of each type of positioning error in the sample size mentioned above (600). Eleven (11) categories of positioning errors were analysed based on specific criteria in order to identify the most common error. The most prevalent positioning error was found to be the tongue not being placed against the palate (34.3%) followed in descending order by:

- Patient biting too far forward in relation to the focal trough (20.3%).
- Patient's head turned to one side (18%).
- Patient's chin not positioned on the chin rest (16.3%).
- Patient's chin positioned too high (14.7%).
- Patient's head tilted to one side (9.2%).
- Patient's chin positioned too low (3.3%).

- Failure to remove metallic objects in the area of the head (3%).
- Slumped position of the patient (2.3%).
- Patient movement during exposure (1.7%).
- Patient biting too far backward in relation to the focal trough (1.5%).

The percentages of the above-mentioned 11 categories of positioning faults do not add up to 100% since some radiographs had no positioning errors while some had more than one positioning error.

Figure 4.2 shows the distribution of the number of positioning errors per radiograph in the sample size studied. 34.5% of the analyzed radiographs displayed no positioning errors, followed by 26.7% with two (2) and 23.8% with one (1) positioning error/s per radiograph. The remaining three (3), four (4) and five (5) positioning errors per radiograph had percentages of prevalence in the descending order of 12%, 2.7% and 0.3% respectively.

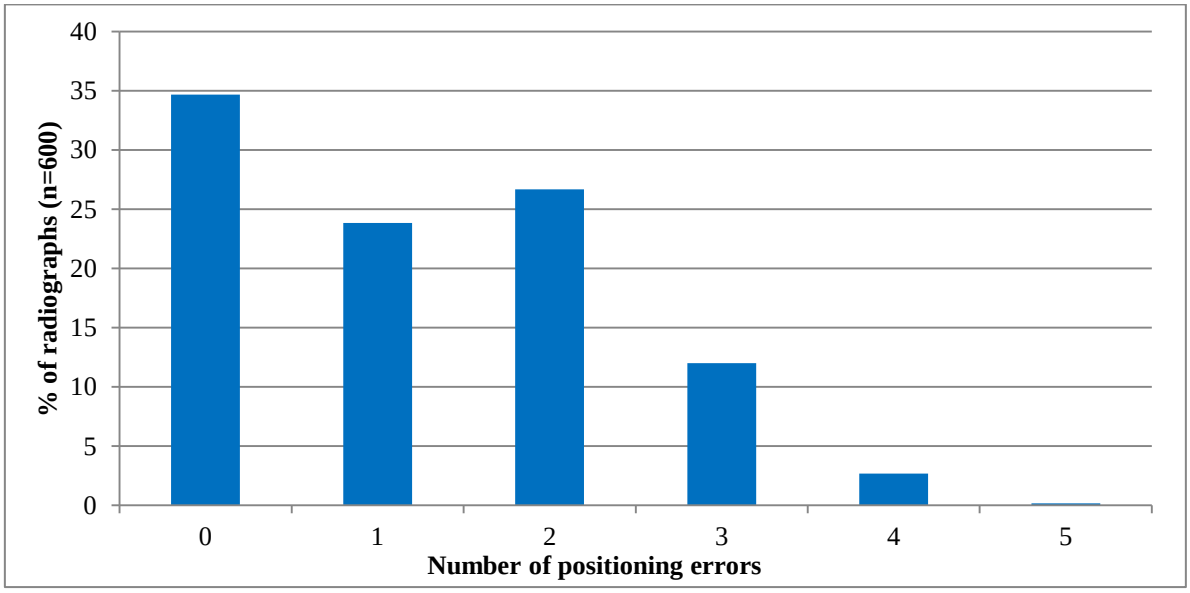

Figure 4.2 Distribution of the number of positioning errors.

The results for the classification of diagnostic quality of the six hundred (600) digital panoramic radiographs are shown below (Figure 4.3).

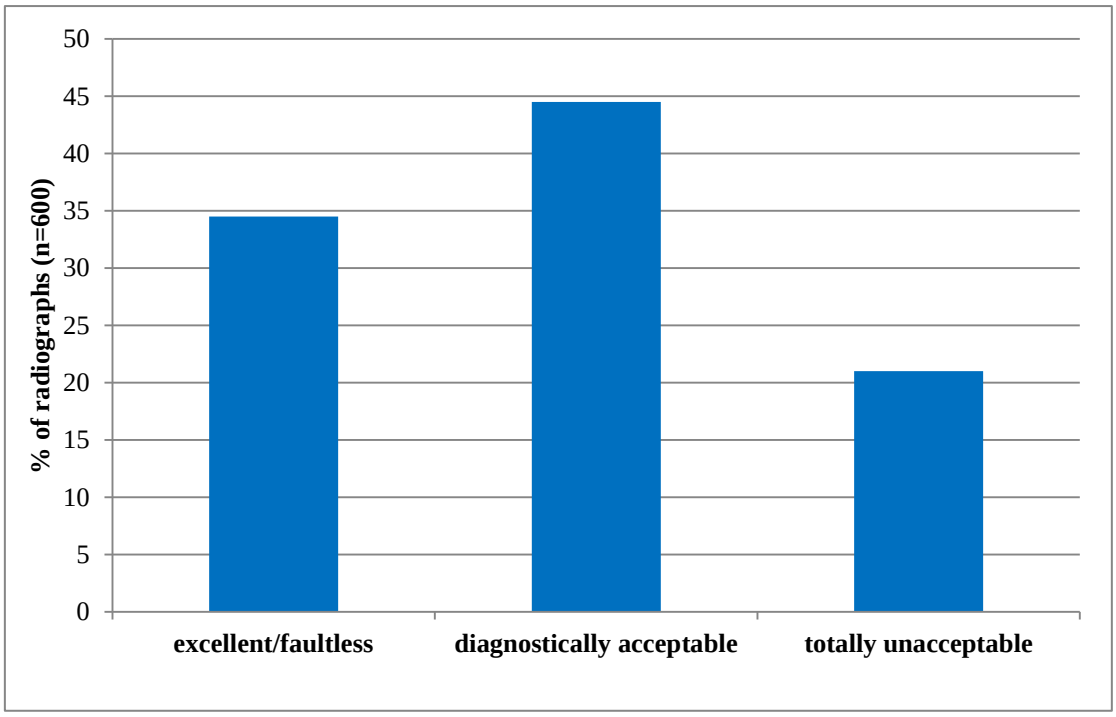

Figure 4.3 Diagnostic quality classification of digital panoramic radiographs.

Figure 4.3 shows the percentage of radiographs based on the three (3) diagnostic criteria. The most prevalent is diagnostically acceptable with a value of 44.5%, followed by excellent/faultless with a value of 34.5%. The lowest percentage for totally unacceptable radiographs displayed a value of 21%.

The distribution of positioning errors within the group of totally unacceptable radiographs is specified in table 4.1 below.

Table 4.1 Distribution of error types within the group of totally unacceptable radiographs.

Positioning errors (as per Table 3.1)	a	b	c	d	e	f	g	h	i	j	k
Numerical value (n)	92	6	9	19	32	12	52	8	8	41	1
Percentage	73	4.8	7.1	15	25.4	9.5	41.3	6.3	6.3	32.5	0.8

The intra-rater reliability at 2 and 4 weeks, and the inter-rater reliability are given in the tables below.

Table 4.2 Statistical reliability for the diagnostic quality classification.

Reliability measure	Raw agreement (%)	Cohen's weighted kappa	95% CI for kappa	Interpretation of kappa	p-value for Stuart-Maxwell test
Intra-rater at 2 weeks	100	1,00	1.00-1.00	perfect agreement	n/a
Intra-rater at 4 weeks	98,3	0,98	0.95-1.00	almost perfect agreement	1,00
Inter-rater	94,2	0,93	0.88-0.98	almost perfect agreement	0,72

Table 4.2 shows the statistical results for the diagnostic quality classification of intra- and inter-rater reliability.

The intra-rater reliability compared the main sample (600 radiographs) with randomly selected sub-samples of 120 radiographs at 2 weeks and 4 weeks.

Table 4.3 Statistical reliability for the 11 different categories of positioning errors.

Reliability measure	Positioning errors (as per Table 3.1)	Prevalence of positioning error	Raw agreement (%)	Cohen's kappa	95% CI for kappa	Interpretation of kappa	p-value for Bowker test
Intra-rater at 2 weeks	a	20,3	99,2	0,98	0.93-1.00	almost perfect agreement	0,32
	b	1,5	100	1,00	1.00-1.00	perfect agreement	n/a
	c	3,3	99,2	0,92	0.76-1.00	almost perfect agreement	0,32
	d	14,7	100	1,00	1.00-1.00	perfect agreement	n/a
	e	18,0	100	1,00	1.00-1.00	perfect agreement	n/a
	f	9,2	100	1,00	1.00-1.00	perfect agreement	n/a
	g	34,3	99,2	0,98	0.95-1.00	almost perfect agreement	0,32
	h	1,7	100	1,00	1.00-1.00	perfect agreement	n/a
	i	3,0	100	1,00	1.00-1.00	perfect agreement	n/a
	j	16,3	97,5	0,92	0.82-100	almost perfect agreement	0,08
	k	2,3	99,2	0,85	0.57-1.00	almost perfect agreement	0,32
Intra-rater at 4 weeks	a	20,3	100	1,00	1.00-1.00	perfect agreement	n/a
	b	**1,5**	98,3	0,66	0.21-1.00	**substantial agreement**	1,00
	c	3,3	100	1,00	1.00-1.00	perfect agreement	n/a
	d	14,7	100	1,00	1.00-1.00	perfect agreement	n/a
	e	18,0	99,2	0,96	0.90-1.00	almost perfect agreement	0,32
	f	9,2	97,5	0,87	0.72-1.00	almost perfect agreement	0,08
	g	34,3	96,7	0,93	0.86-1.00	almost perfect agreement	0,32
	h	1,7	100	1,00	1.00-1.00	perfect agreement	n/a
	i	3,0	100	1,00	1.00-1.00	perfect agreement	n/a
	j	16,3	95,8	0,85	0.72-0.98	almost perfect agreement	0,18
	k	**2,3**	99,2	0,80	0.41-1.00	**substantial agreement**	0,32
Inter-rater	a	20,3	97,5	0,92	0.84-1.00	almost perfect agreement	0,56
	b	**1,5**	99,2	0,80	0.41-1.00	**substantial agreement**	0,32
	c	3,3	100	1,00	1.00-1.00	perfect agreement	n/a
	d	14,7	96,7	0,90	0.80-1.00	almost perfect agreement	0,32
	e	18,0	98,3	0,93	0.84-1.00	almost perfect agreement	0,16
	f	9,2	98,3	0,88	0.72-1.00	almost perfect agreement	1,00
	g	34,3	93,3	0,84	0.74-0.95	almost perfect agreement	0,16
	h	1,7	100	1,00	1.00-1.00	perfect agreement	n/a
	i	3,0	100	1,00	1.00-1.00	perfect agreement	n/a
	j	16,3	93,3	0,78	0.63-0.92	**substantial agreement**	0,16
	k	**2,3**	98,3	0,49	0.00-1.00	**moderate agreement**	0,16

Table 4.3 shows the statistical reliability for the different categories of positioning errors. The intra- and inter-rater agreement is excellent on the whole, and there is no evidence of intra- or inter-rater bias.

There are a few cases of ‘substantial’ or ‘moderate’ agreement (marked in blue, see Table 4.3).

CHAPTER 5 – DISCUSSION

This study met the specified objectives of:

i. Quantifying the radiographic faults in order to identify the most common panoramic positioning error/s, and
ii. Categorising the panoramic radiographs according to BDA internationally recommended targets of Quality Assurance in Dental Radiology (National Radiological Protection Board, 2001).

The intra- and inter-rater agreement for the diagnostic quality classification was excellent, and there was no evidence of intra- or inter-rater bias. (Table 4.2)

The intra- and inter-rater agreement for positioning errors was excellent on the whole, and there was no evidence of intra- or inter-rater bias. There were some cases of 'substantial' or 'moderate' agreement. These were cases where the positioning error was very rare (<3%), where kappa is not very reliable. There was one case of 'substantial' agreement where the positioning error was not that uncommon (positioning error 'j'). This may warrant further investigation, though it must be noted that kappa is still quite high (0.78). (Table 4.3)

5.1. Quantifying the Radiographic Faults

In order to identify a positioning error it is imperative to be familiar with the features of a diagnostically acceptable panoramic radiograph (Fig. 5.1).

A booklet published by Eastman Kodak Company (Moore, 2002), "Successful Panoramic Radiography" specifies how a normal panoramic radiograph should appear: 'the mandible is U-shaped, the condyles are positioned about an inch inside the edges of the film. The occlusal plane exhibits a slight curve or "smile line", upwards. The roots of the maxillary and mandibular teeth are readily visible with minimal distortion. Magnification is equal on both sides of the midline'.

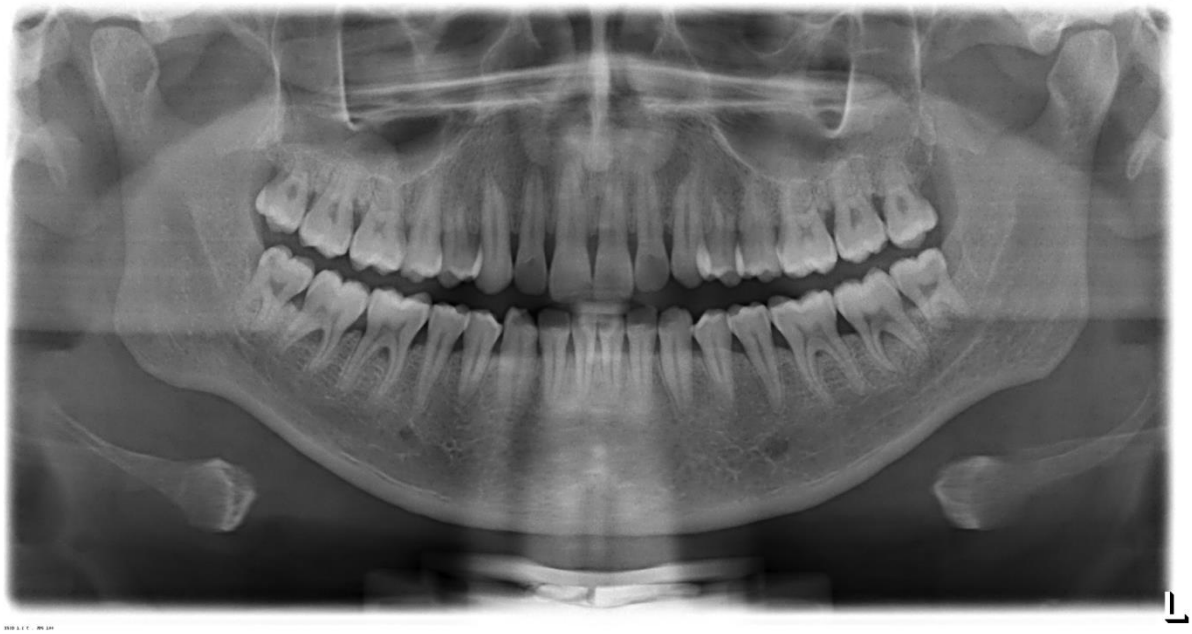

Figure 5.1 Appearance of a diagnostically acceptable panoramic radiograph.

In addition an excellent panoramic radiograph should be free from any of the positioning errors.

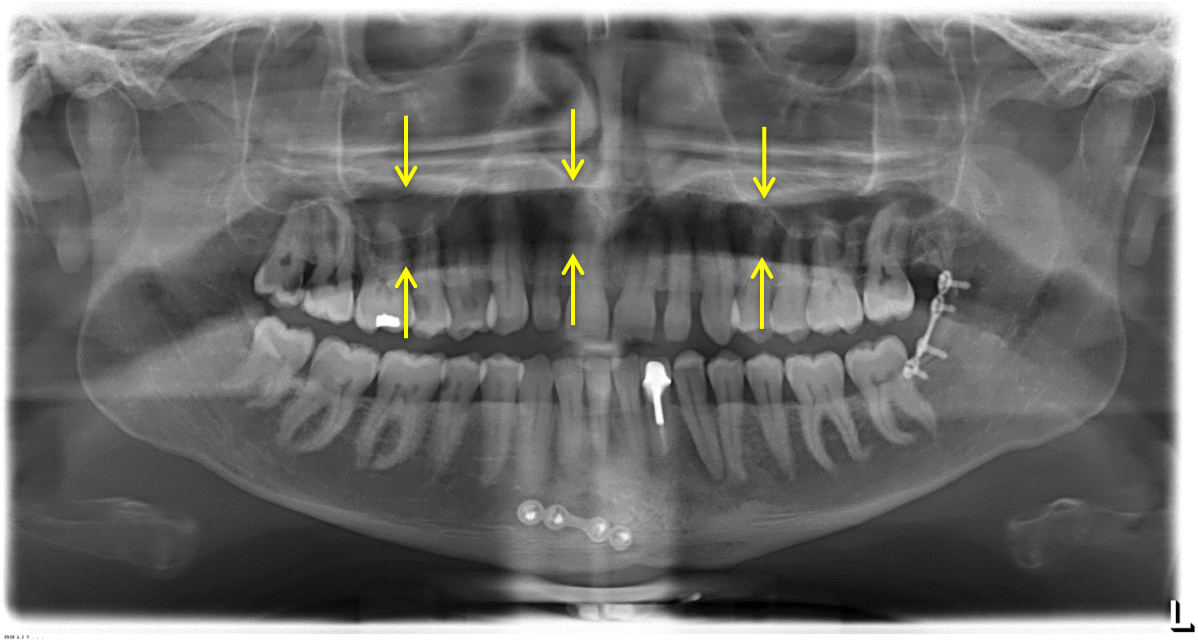

Figure 5.2 Tongue not placed against the palate.

The most common patient positioning error identified from the assessed digital panoramic radiographs in the current study was the tongue not being placed against the palate (34.3 %).

The possible reasons may have been that the patient did not receive an instruction from the operator to place and keep the tongue against the roof of the mouth throughout the exposure; or the patient did not comply with the instruction from the operator; or that initially the patient complied with the instruction, but consequently relaxed the tongue unconsciously and lowered it for part of the exposure.

The air space between the dorsum of the tongue and the palatal vault creates a band of radiolucent shadow overlying the apical area of the maxillary teeth and may interfere with the diagnostic interpretation of any periapical, periodontal, or bone pathology present in the shadowed area (Fig. 5.2).

It was observed by the researcher that the above positioning error was most prevalent in patients with an anterior open bite and higher in edentulous and partially dentate patients.

This positioning error was also found to be the most common one in numerous other studies. Schiff et al (1986) report the same prevalence for that particular positioning error (34.7%) for 'films made by trained technician' and a lower prevalence than the current study (25.7%) for 'films selected at random'. For their studies percentages fell between the range 46.3% to 79%, which is approximately 0.4 to 2.3 times higher than in the current study. The explanation is most likely that as WOHC is a teaching institution, when a panoramic radiograph is taken by a student, each and every patient positioning is assessed by the supervisor and monitored during exposure. Constant reiteration to the students, as well as instructions given to the patients is part of their assessment and appears to help reduce the percentage for that particular error in comparison with other studies.

The second most common positioning error was found in this study to be the patient biting too far forward in relation to the focal trough with a prevalence of 20.3% (Fig. 5.3).



Figure 5.3 Patient biting too far forward in relation to the focal trough.

This positioning error is more readily observed when taking a panoramic radiograph of an edentulous, partially dentate patient with missing anterior teeth, and if a "lip support piece" is used as a guide for correct positioning. Nevertheless it is difficult to position such a patient so that the maxillary and mandibular arches fall in the region of the focal trough area as dental/ anatomical variations (missing/remaining teeth and bone loss) play a significant role in positioning.

In a dentate patient, biting too far forward instead of on the designated groove in the bite block causes the anterior teeth to shift forward. They therefore fall out of the focal trough area and closer to the image receptor with resultant blurring and narrowing (i.e. distortion in the horizontal plane) of the anterior teeth. Generalized narrowing of the structures of both arches is also observed, as is overlapping of premolars (Fig. 5.3).

In extreme cases superimposition of the cervical spine on the rami and condyles of mandible is seen.

A contribution to the prevalence for this error in the current study is acknowledged to be the fact that in 47 out of 600 patients a “lip support piece” was used when positioning a fully dentate patient. In the majority of cases this caused a shift of the facial structures forward with the consequent positioning fault (Fig. 5.4). Although the use of the “lip support piece” is imperative for a patient with inability to open his/her mouth (e.g. trauma in the anterior maxillary and mandibular regions, trismus, inter-maxillary fixation of the jaws, or a patient with severe orthodontic malocclusion), this was not necessarily the case in the current study.

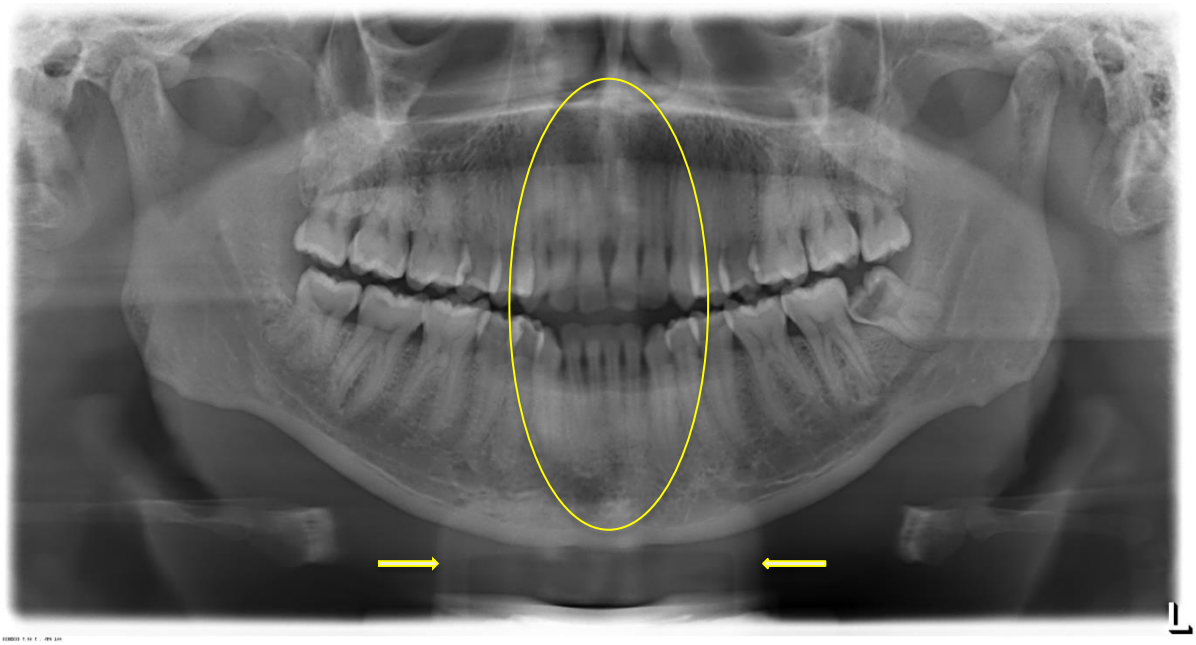

Figure 5.4 Patient biting forward as a result of “lip support piece” inadequately used.

In other studies the range of prevalence was found to be between 9.8% and 34.7%. This error was also reported as the second most common error in the studies of Glass et al (1994) at 34.7% for edentulous patients and Peretz et al (2012), in the case of mixed dentition at 24.5%.

The third most common positioning error in this study was “patient’s head turned to one side” with a prevalence of 18% (see Fig. 5.5).

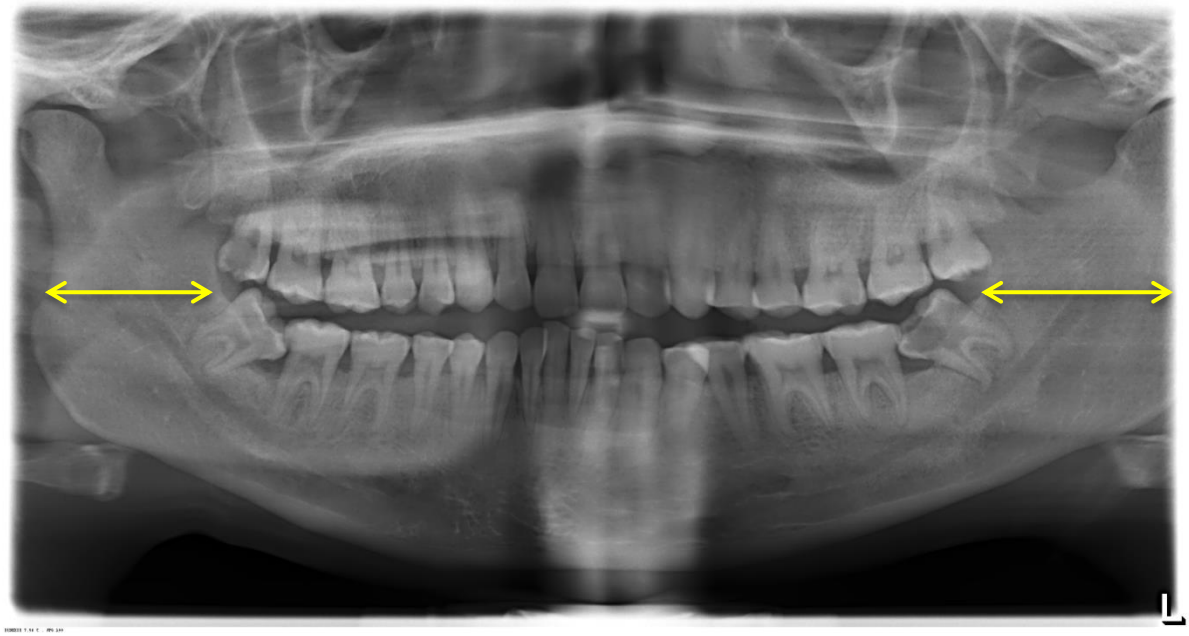

Figure 5.5 Patient's head turned to one side.

This positioning error is a result of incorrect alignment of facial structures with the mid-sagittal plane. As seen from the above example there is unequal right/left magnification of dental and bony structures. On the side to which the head has been twisted, the teeth appear wide, while on the opposite side they appear narrow. The rami and condyles of the mandible differ in size too. Uneven blurring is seen across the arches. The nasal structures are not clear.

Anatomical variation between the left and right side of the facial structures may be observed in some patients despite the correct alignment of the patient within the machine. However the size of the teeth bilaterally would be similar.

In comparison with other studies it was found that this positioning error was in the similar range of prevalence in one study only (17.4%, Dillon et al, 2012). Other studies reported either very low prevalence (0.7% for mixed dentition and 4.8% for permanent dentition, Peretz et al, 2012), or higher prevalence (39.5%, Kaviani et al, 2008; 74% in private practice and 58.8% in dental hospital, Bissoon et al, 2012).

The inclusion of edentulous patients in the current study was found to contribute to its prevalence.

The least common positioning error showed no particular pattern of occurrence. In this study the error was that of the patient biting too far backward in relation to the focal trough at 1.5% occurrence.

In other studies the least common positioning errors were as follows: “patient moving during exposure” (2%, Rushton et al, 1999; 2.4%, Kaviani et al, 2008; 1.6%, Dhillon et al, 2012); “patent wears jewellery” (8% private practice and 1.2% dental hospital, Bissoon et al, 2012); “bite guide not used” (0.7%**,** Perez et al, 2012 for permanent dentition) and “head turned to one side” (0.7%**,** Perez et al, 2012 for mixed dentition).

Reports of “widening of anterior teeth” (1.3%, Akarslan et al, 2003), and “tempomandibular joints not on the image” (2%, Granlund et al, 2012), are not, according to the criteria of the current study, regarded as specific positioning errors. This is rather a consequence of the patient biting too far backwards, or the patient’s chin tilted too low and not on the chin rest.

A radiograph with a positioning error of the patient biting too far backward in relation to the focal trough is characterized by wide and blurred anterior teeth, ghosting of the mandible and cervical spine, condyles appearing close to, or cut off the edges of the film. In general all structures appear magnified. Those radiographic features are a consequence of maxillary and mandibular anterior teeth having moved away from the image receptor and falling out of the area of the focal trough (see Fig. 5.6).



Figure 5.6 Patient biting too far backward in relation to the focal trough.

In the current study the positioning errors that fell between the most and least prominent ones were: patient's chin not positioned on the chin rest (16.3%), patient's chin positioned too high (14.7%), patient's head tilted to one side (9.2%), patient's chin positioned too low (3.3%), failure to remove metallic objects in the area of the head (3%), slumped position of the patient (2.3%), and patient movement during exposure (1.7%), all of which had a low range of prevalence.

When the patient's chin was not positioned on the chin rest (see Fig. 5.7) as a stand-alone error may not decrease the diagnostic quality of a panoramic radiograph unless the distance between the chin and chin rest is excessive, in which case the image of the condyles will be cut off from the top of the radiograph. This will render the radiograph non diagnostic for gross pathology of the condyles (e.g. osteoarthritis).

The fairly high prevalence of this error may be due to the fact that some patients tend to lift their chins after correct positioning. Proper instructions must therefore be given to the patient before exposure.

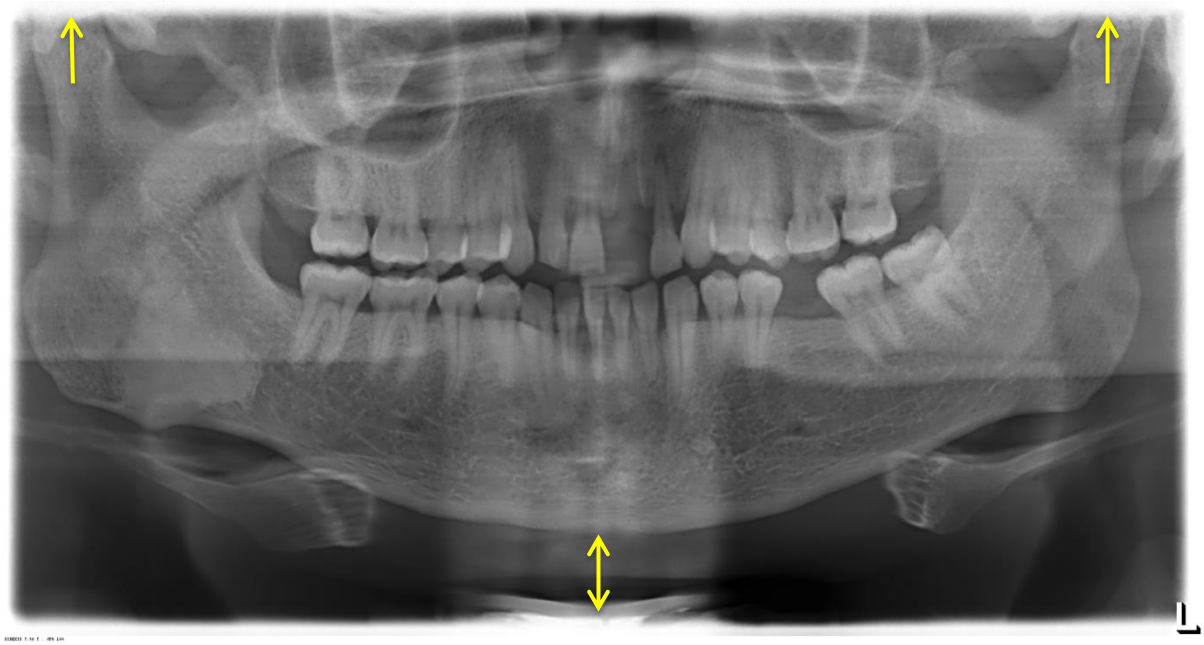

Figure 5.7 Patient's chin not positioned on the chin rest (above).

In a small minority of cases with the aforementioned positioning error the patient's chin was tipped down below the chin rest with the result that the chin appeared cut off from the bottom of the panoramic image (see Fig. 5.8).

The same positioning error was reported to have a considerably higher prevalence for the permanent dentition (47.9%), and as being the second most common positioning error in the study of Peretz et al (2012). In the same study the prevalence for a mixed dentition was slightly reduced (11.9%) in comparison to the current study.



Figure 5.8 Patient's chin not positioned on the chin rest (below).

Figure 5.9 shows an example of patient's chin being positioned too high. Flattening or reverse curvature of the occlusal plane is seen. The roots of the upper anterior teeth appear blurred. Condyles are closer to the edge of the film or may be cut off. The radiopaque shadow of the hard palate may be superimposed over the apices of maxillary teeth.

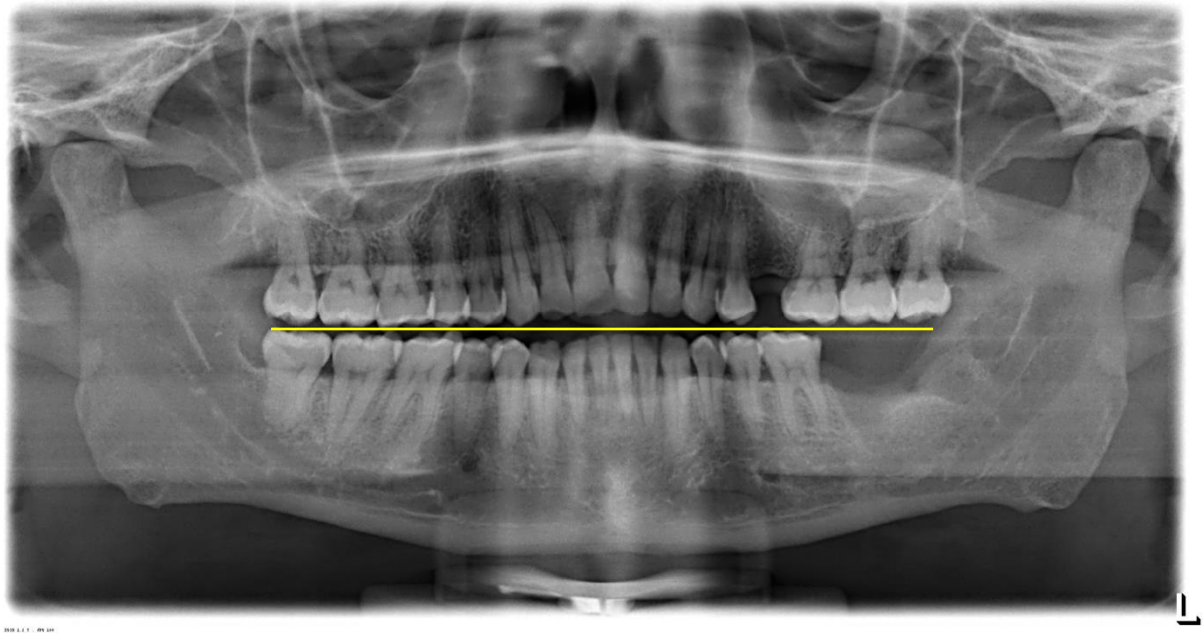

Figure 5.9 Patient's chin positioned too high.

This positioning error has been reported as the most common one in the study of Glass et al (1994) at 41.3% prevalence. It also has a variable prevalence in different studies ranging from 9.34% to 41.3%. In the current study, at 14.7%, the prevalence is about 1/3 of the highest reported prevalence range from other studies.

Elevating of the patient's chin may be intentional on the part of the operator in cases where patients possess short necks and broad shoulders and in patients with sustained fracture/s of the symphyseal region of the mandible. This prevents the rotating unit from impacting on the patient's shoulder/s, or in the latter case resulting in a clearer image of the fracture line/s.

The error of the patient's head tilted to one side, which was 9.2%, is slightly lower than that reported by Dhillon et al, 2012 (12.7%) and Peretz et al, 2012 (12.6% and 14.4% for mixed and permanent dentition respectively).

The distinguishing feature on the panoramic radiograph is the unequal distance between the mandible and chin rest at a given point on right and left sides. The mandible appears tilted to one side (see Fig. 5.10).

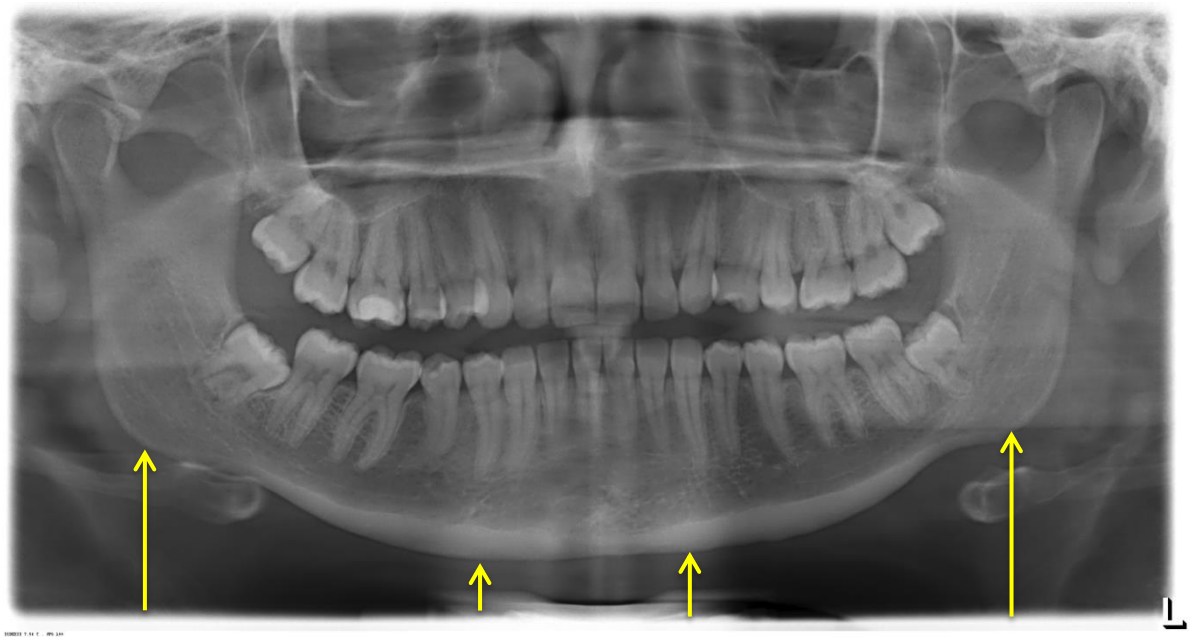

Figure 5.10 Patient's head tilted to one side.

Figure 5.11 shows an example of a panoramic radiograph of the patient's chin positioned too low.

Excessive and V-shaped curving of the occlusal plane is observed, the roots of the lower anterior teeth are blurred and narrowing of the intercondylar distance is seen.

Condyles appear at top of the film and superimposition of contact points mainly in the premolar region is seen.

In the current study the prevalence of this error, at 3.3%, was found to be the lowest by comparison with other studies.



Figure 5.11 Patient's chin positioned too low.

Failure to remove metallic objects in the head, neck and orofacial region**,** e.g. upper and/or lower partial dentures (Fig. 5.12), tongue bar, nose ring, spectacles, hair clips, earrings (Fig. 5.13), necklace, lead apron above collar line, will display a radiopaque shadow of the object on the panoramic radiograph. In addition ghost images of jewellery, e.g. earrings, necklace, nose ring, will be seen on the opposite side, magnified and in a higher horizontal plane

(Fig. 5.13). A lead apron will produce a pyramid - shaped opacity at the bottom of the film.

Granlund et al (2012), report a similar prevalence for that particular error (3%). The overall prevalence reported in various studies for this error is very low.

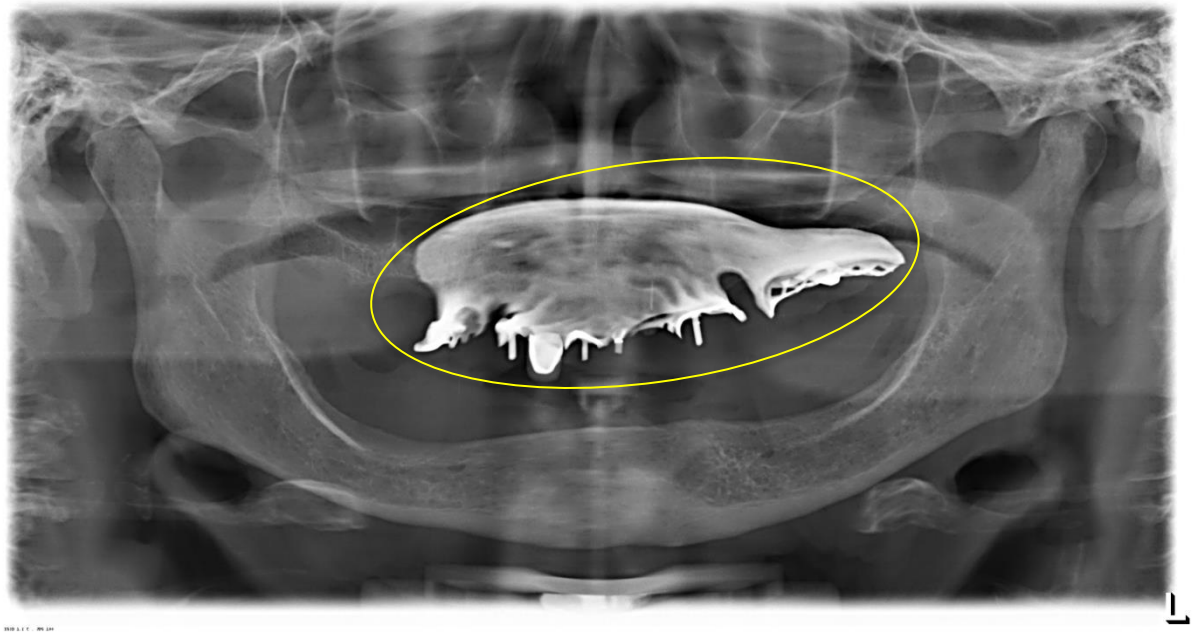

Figure 5.12 Partial upper metallic denture left in the mouth.

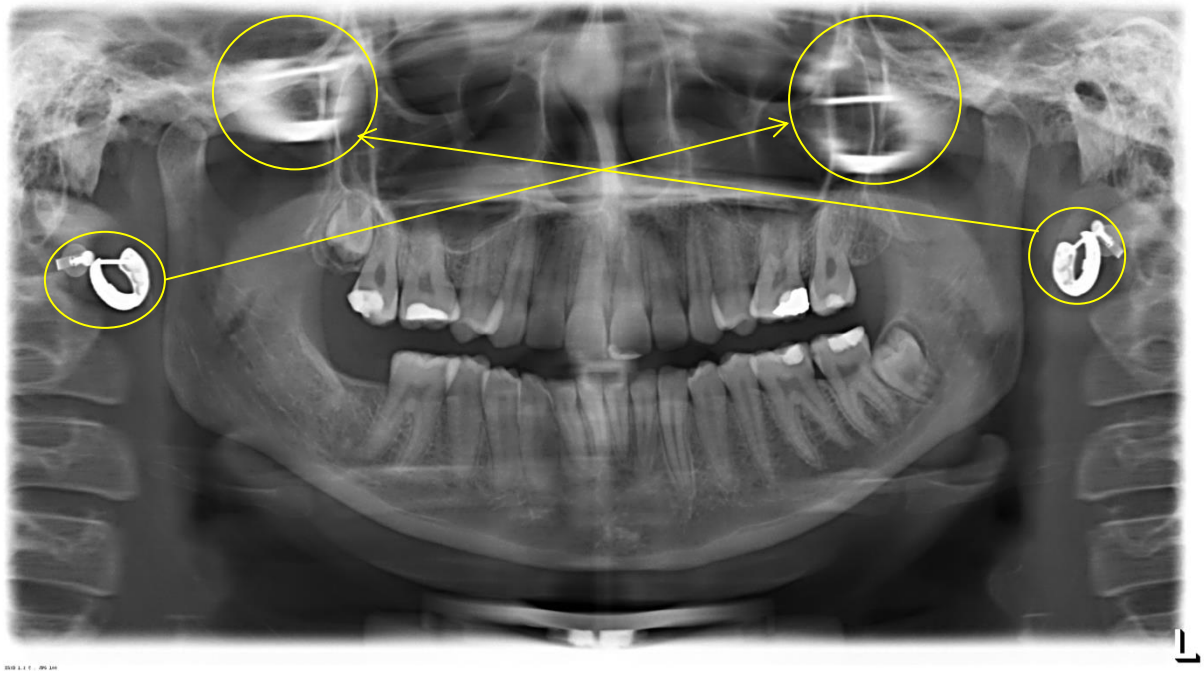

Figure 5.13 Failure to remove metallic earrings.

A slumped position of the patient creates a ghost image (pyramid-shaped opacity) of the cervical spine superimposed on the midline region of the film (see Fig. 5.14).

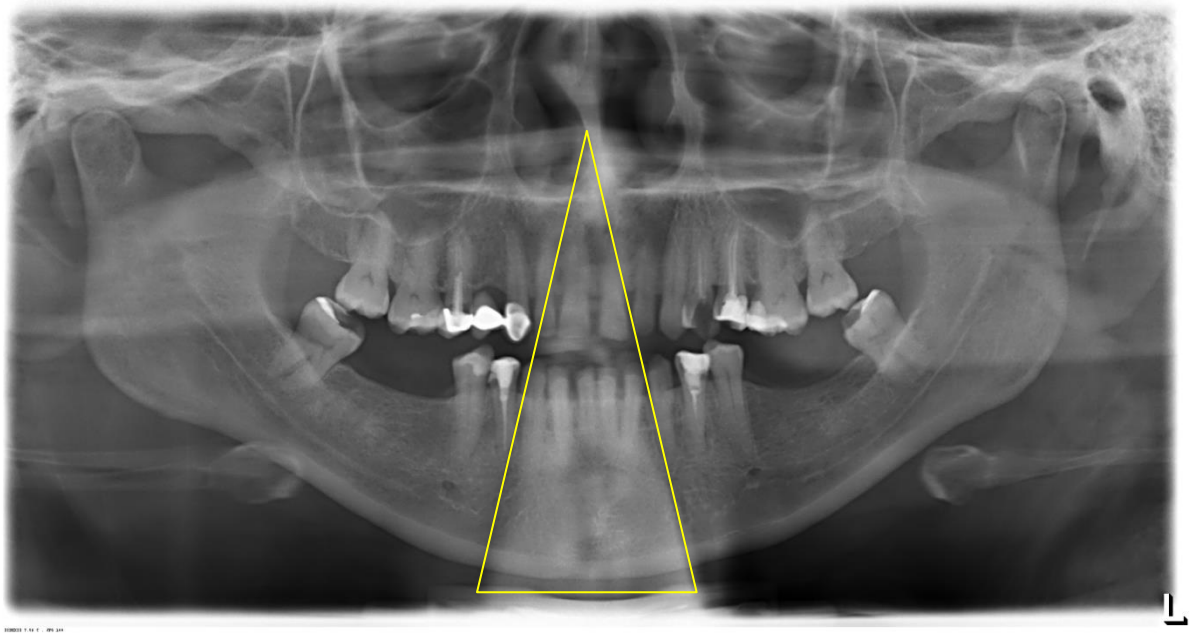

Figure 5.14 Slumped position of the patient.

A relatively high prevalence of this positioning error was reported in other studies (Bissoon et al, 2012, with 25.8% for private practice and 16% for a dental hospital; Dhillon et al, 2012, with 35%; Peretz et al, 2012, with 23.3% for a permanent dentition). The current study shows a very low prevalence of 2.3% similar to the study of Peretz et al (2012) for mixed dentition (2.1%). Slumped position of the patient is an obvious error that is readily noticed by an operator before exposure. However the few cases encountered were probably from patients with abnormalities of the cervical spine.

Patient movement during exposure was an error with a very low prevalence, not only in the current study (1.7%), but also in all reviewed studies (Fig. 5.15).

It should be noted that errors of patient movement during exposure and failure to remove metallic objects in the head, neck and orofacial region are not regarded as positioning faults as

such but are rather related to inadequate patient preparation (e.g. proper patient observation and instructions to remove metallic objects and to keep still during the exposure).

The few incidents of patient movement encountered during exposure resulted from extremely apprehensive patients and small children, hence the importance of better communication with the patient.

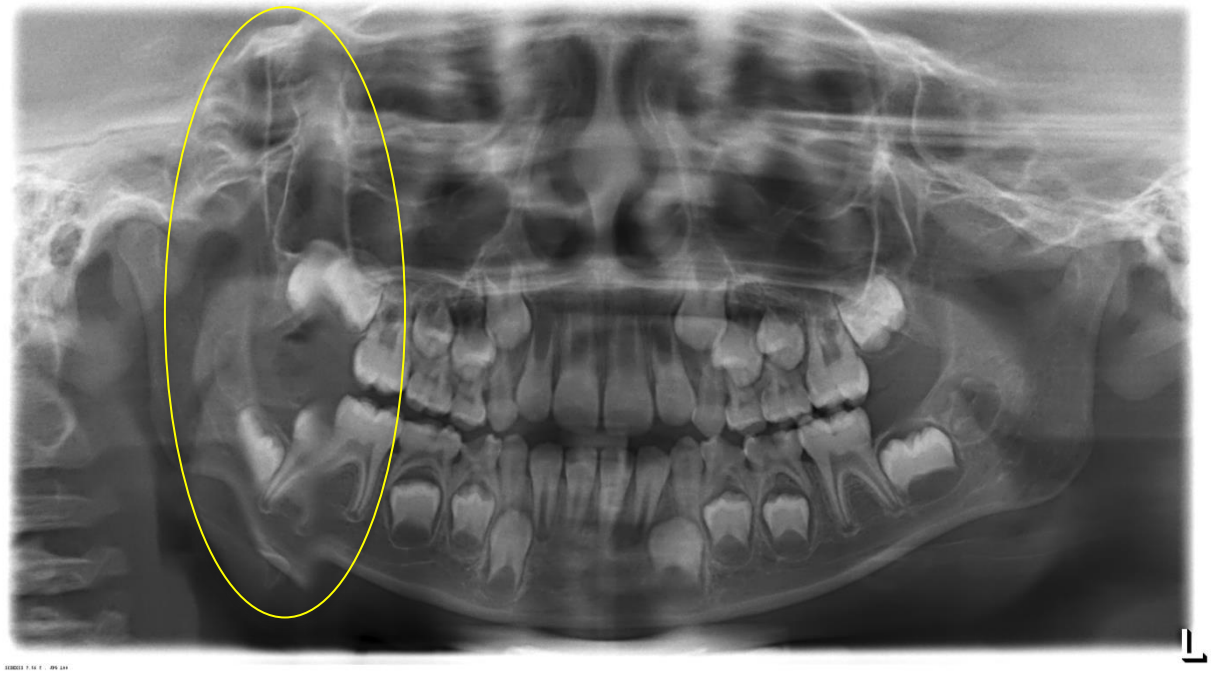

Figure 5.15 Patient's movement during exposure.

5.2. Categorising the Panoramic Radiographs According to BDA Internationally Recommended Targets.

Figure 4.3 shows the percentage of radiographs based on the three diagnostic criteria.

In the first category ("faultless/excellent") the BDA has set a target of ≥ 70 % ($p < 0.0001$), which no published study has met to date. The current study is no exception with a value of 34.5%, however it is still the second highest value from the results published to date, inclusive of Dhillon et al, 2012 (11%) and Granlund et al, 2012 (4%) for digital panoramic radiographs; and for analogue panoramic radiographs in the studies of: Schiff et al, 1986 (20.3%); Rumberg et al, 1996 (33%); Rushton et al, 1999 (0.8%); Akarslan et al, 2003 (37.61%);

Kaviani et al, 2008 (7.6%); Bissoon et al, 2012 (4.2% for private practice and 5.8% for dental hospital); and Mayil et al, 2014 (18.7%).

The number of "diagnostically acceptable" radiographs (44.5%) in this study is significantly above the recommended standard of ≤ 20% ($p < 0.0001$), but nevertheless closer to the target, than Rushton et al, 1999 (66.2%), Kaviani et al, 2008 (92.4%), and Dhillon et al, 2012 (64.1%).

The percentage of "totally unacceptable" radiographs (21%) is significantly above the BDA recommended target of ≤ 10% ($p < 0.0001$) but despite being lower than many other studies it needs to improve notably to reach the set target.

The improved results in the current study by comparison with other studies is believed to be a consequence of having trained operators in the Radiology section and constant supervision of the inexperienced operators like dental and oral hygiene students. Nevertheless comprehensive training should be provided for identified areas of deficient knowledge and practice to achieve the targets set by the BDA.

It was observed by the researcher and also confirmed from the results of this study that the positioning error of 'patient biting too far forward in relation to the focal trough' constituted the highest percentage of the totally unacceptable radiographs, whereas the slumped position of the patient was the least prevalent (Table 4.1).

CHAPTER 6 – CONCLUSION AND RECOMMENDATIONS

Sequential sample of six hundred (600) digital panoramic radiographs were visually examined, and eleven categories of positioning errors identified, the quality of radiographs assessed and compared with BDA internationally recommended targets of Quality Assurance in Dental Radiology (National Radiological Protection Board, 2001).

The primary objective of the study to evaluate the most common positioning error/s was met and seen in the context of previous studies. The most common positioning error was found to be "tongue not placed against the palate" and it was decided that improved communication with the patient is necessary to ensure compliance with this instruction.

The second most common positioning error "patient biting too far forward" would also benefit from the same general advice during communication and patent positioning.

Apart from those radiographs, which showed no positioning errors, remaining radiographs commonly had one or two positioning errors, some having as many as five.

The percentage of "faultless/excellent" radiographs was significantly below the BDA standard while the percentage of "diagnostically acceptable" radiographs was significantly higher. The percentage of "totally unacceptable" radiographs however was significantly higher than the recommended standard. In other words, the results did not meet the BDA targets and the hypothesis is therefore rejected.

Nevertheless the current study provides a valuable input for Quality Assurance (QA) in the Radiology Section of WOHC as:

i. It can be regarded as a preliminary study for the implementation of a viable QA program.

ii. In recognizing the most common positioning errors, students and operators can receive relevant training to improve their knowledge and skills for better results.

iii. The study can be expanded to include other variables (e.g. data for individual operators and analyzing their most common faults).

iv. It can also be expanded on a National level by involving all Dental Schools and comparing the results.

Improving the quality of the radiographs will lead to fewer retakes and will thus avoid overloading of the database.

In addition, patient's exposure to radiation will be reduced and operators will be enabled to attend to more patients.

CHAPTER 7 - REFERENCES

Akarslan ZZ, Erten H, Güngör K, Çelik I. Common errors on panoramic radiographs taken in a dental school. J Contemp Dent Pract 2003; 4(2):24-34.

Angelopoulos C, Bedard A, Katz JO, Karamanis S, Parissis N. Digital panoramic radiography: an overview. Semin Orthod 2004; 10(3):194-203.

Bissoon AK, Whaites E, Moze K, Naidu R. Evaluation of common operator errors in panoramic radiography in Trinidad and Tobago: a comparison of formally vs informally trained operators. West Indian Med J 2012; 61(7):733-738.

Choi BR, Choi DH, Huh KH, Yi WJ, Heo MS, Choi SC et al. Clinical image quality evaluation for panoramic radiography in Korean dental clinics. Imaging Sci Dent 2012; 42(3):183-190.

Daniel WW. Biostatistics: A Foundation for Analysis in the Health Sciences. 7th ed. New York: John Wiley & Sons; 1999.

Dhillon M, Raju SM, Sankalp V, Tomar D, Mohan RS, Lakhanpal M et al. Positioning errors and quality assessment in panoramic radiography. Imaging Sci Dent 2012; 42(4):207-212.

Farman AG (Ed.). Panoramic radiology: Seminars on maxillofacial imaging and interpretation. 1st ed. Springer; 2007.

Glass BJ, Seals RR Jr, Williams EO. Common errors in panoramic radiography of edentulous patients. J Prosthodont 1994; 3(2):68-73.

Granlund CM, Lith A, Molander B, Gröndahl K, Hansen K, Ekestubbe A. Frequency of errors and pathology in panoramic images of young orthodontic patients. Europ J Orthod 2012; 34(4):452-457.

Gwet KL. Computing inter-rater reliability and its variance in the presence of high agreement. Br J Math Stat Psychol 2008; 61(1):29-48.

Kaviani F, Johari M, Esmaeili F. Evaluation of common errors of panoramic radiographs in Tabriz faculty of dentistry. JODDD 2008; 2(3):99-101.

Mayil M, Keser G, Pekiner FN. Clinical image quality assessment in panoramic radiography. MÜSBED 2014; 4(3):126-132.

McDavid VD, Langlais RP, Welander U, Morris CR. Real, double, and ghost images in rotational panoramic radiography. Dentomaxillofac Radiol 1983; 12(2):122-128.

Moore WS (Editor). Dental Radiography Series: Successful Panoramic Radiography. Eastman Kodak Company 2002; 6-14.

Murray D & Whyte A. Dental panoramic tomography: what the general radiologist needs to know. Clin Radiol 2002; 57:1-7.

National Radiological Protection Board. Guidance notes for dental practitioners on the safe use of X-ray equipment. 2001: p33. [Accessed 25 October 2014]. Available from: https://www.gov.uk/government/uploads/system/uploads/attachment_data/file/337178/misc_pub_DentalGuidanceNotes.pdf.

Peretz B, Gotler M, Kaffe I. Common errors in digital panoramic radiographs of patients with mixed dentition and patients with permanent dentition. Int J Dent 2012; 2012:584138.

Razmus TF, Glass BJ, McDavid WD. Comparison of image layer location among panoramic machines of the same manufacturer. Oral Surg Oral Med Oral Pathol 1989; 67(1):102-108.

Rondon RHN, Pereira YCL, Nascimento GC. Common positioning errors in panoramic radiography: A review. Imaging Sci Dent 2014; 44(1):1-6.

Rumberg H, Hollender L, Oda D. Assessing the quality of radiographs accompanying biopsy specimens. J Am Dent Assoc 1996; 127(3):363-368.

Rushton VE, Horner K, Worthington HV. The quality of panoramic radiographs in a sample of general dental practices. Brit Dent J 1999; 186(12):630-633.

SAS Institute Inc., SAS Software, version 9.3 for Windows, Cary, NC, USA: SAS Institute Inc. (2002-2010).

Scarfe WC & Williamson GF. Practical panoramic radiography. Revised 2015. [Accessed 26 October 2014]. Available from: www.dentalcare.com/en-US/dental-education/continuing-education/ce71/ce71.aspx.

Schiff T, D'Ambrosio J, Glass BJ, Langlais RP, McDavid VD. Common positioning and technical errors in panoramic radiography. J Am Dent Assoc 1986; 113:422-426.

Shahab S, Kavosi A, Nazarinia H, Mehralizadeh S, Mohammadpour M, Emami M. Compliance of Iranian dentists with safety standards of oral radiology. Dentomaxillofac Radiol 2012; 41(2):159-164.

Shoukri MM. Measures of interobserver agreement. 2nd ed. Chapman & Hall/ CRC Biostatistics Series, Boca Raton; 2004.

Urbaniak GC & Plous S. Research Randomizer Form. 1997-2008. [Accessed 21 November 2014]. Available from: http://www.randomizer.org/form.htm.

Wenzel A & Møystad A. Experience of Norwegian general dental practitioners with solid state and storage phosphor detectors. Dentomaxillofac Radiol 2001; 30(4):203-208.

White SC & Pharoah MJ. Oral Radiology: Principles and Interpretation. 6th ed. Missouri: Mosby Elsevier; 2009.

Whaites E & Drage N. Essentials of dental radiography and radiology. 5th ed. Churchill Livingston: Elsevier; 2013.

APPENDIX A



Figure A1 Orthophos XG 3D/Ceph.



A **B**

Figure A2 Control panel with an open submenu for preselection of:
A. Different jaw shape and **B.** Levels of protrusion and retrusion.

APPENDIX B

Table B1 Characteristics of the various studies.

	Dhillon et al (2012)		Peretz et al (2012)		Kaviani et al (2008)		Bissoon et al (2012)				Granlund at al (2012)		Rushton et al (1999)		Akarslan et al (2003)		Mayil et al (2014)		Choi at al (2012)	
							Private prac	Dental Hosp	Private prac	Dental Hosp			Not digital		Not digital		Not digital		Not digital	
Positioning error	Total of 1872 images	100%	Mixed dent (%)	Perm dent (%)	Total of 250 images	100%	Total of 500 images	Total of 500 images	100%	100%	Total of 1287 images	100%	Total of 1813 images	100%	Total of 460 images	100%	Total of 150 images	100%	Total of 297 images	100%
Failiure to position tongue against palate/Tongue not on palate	993	55,7	60,1	52,7					68,6	62	972	79	1298	71,6	213	46,3				
Slumped position	624	35	2,1	23,3					25,8	16			267	14,7						
Patient positioned backward	534	30	16,8	24,7					24,4	3,4										
Patient positioned forward	326	18,3	24,5	10,3					17	9,8										
Chin tipped high/upwards/Oclusal plane tipped up	319	17,9	22,4	19,2					32,6	10,4	137	11			43	9,34				
Head is turned to one side/Head twisted/Rotation	310	17,4	0,7	4,8	77	39,5			74	58,8										
Chin tipped low/downwards/Oclusal plane tipped down	289	16,2	16,1	15,8					15,8	32,2	116	9			62	13,47				
Head is tilted to the side	227	12,7	12,6	14,4																
Patient movement during exposure	28	1,6	2,1	1,4		2,4							35	2	15	3,26				
Chin not on chin rest			11,9	47,9																
Bite guide not used			0	0,7	11	5,6														
Patient wears jewellery/Artifacts/Radiopaque artifact			5,6	3,4	8	3,2			8	1,2	37	3	164	9	24	5,21				
Insufficient extension of neck																				
Opening of lips																				
Widening of anterior teeth											35	3			6	1,3				
Blurring of anterior theeth											66	5			32	6,95				
Rotation of the head to the right											160	13								
Rotation of the head to the left											417	34								
Lower border of mandible off image											850	69								
Temporomadibular joints not on the image											26	2								
Anterior posterior positioning errors													1066	58,8						
Absence of orientation (left/right) markers													642	35,4						
Oclusal plane errors													568	31,3						
Incorect sagittal plane													508	28						
Lower border of mandible off film													164	9						
Poor film/screen contact													60	3,3						
Overlap of upper and lower teeth													56	3,1						
Superimposition of hyoid bone															121	26,3				
Vertebral column superimposed on anterior teeth															102	22,17				
Asymetrical placement of teeth															53	11,52				
Other miscellaneous errors															45	9,78				
Superimposition of spine on other structures															26	5,65				
Narrowed anterior teeth															26	5,65				
Vertical overlap of anterior teeth															11	2,39				
Types of errors						**%**											**150 imag tota**	**%**	**No of errors**	**%**
Errors in positioning						78											103	84,4	139	
Errors in processing/Film development						69,2											15	12,3	135	
Due to radiographic unit						3,2											4	3,3	50	
Due to anatomic abnormality																	0		13	
Quality	**Number**	**%**			**Number**	**%**	**Number**	**Number**	**%**	**%**	**Number**	**%**	**Number**	**%**	**Number**	**%**	**Number**	**%**	**288 imag total**	
Excellent/Optimal for diagnostic interpretation	196	11			19	7,6	21	29	4,2	5,8	51	4		0,8	173	37,61	28	18,7	17	
Diagnostically acceptable	1,142	64,1												66,2						
Diagnostically unacceptible	444	24,9		40%	26 out of 231	10.4 out of 92.4								33			5	3,3	9	
Adequate for diagnosis																	80	53,3	153	
Poor but diagnosable																	37	24,7	109	

APPENDIX C



Figure C1 Patient removing jewellery.



Figure C2 Correct positioning of patient according to the horizontal and vertical light line

APPENDIX D

Table D1 Example of data capturing sheet.

Assigned No	MAIN_Q	TWO_Q	FOUR_Q	INTER_Q	MAIN_a	TWO_a	FOUR_a	INTER_a	.	.	.	MAIN_k	TWO_k	FOUR_k	INTER_k
1	2				0							0			
2	1	1			0	0						0	0		
3	2		3		1		1					0		0	
4	2			1	0			0				1			1
5	1		1		0		0					0		0	
6	1			1	0			0				0			0
7	3	3			1	1						0	0		
8	2	2			0	0						1	1		
9	3		3		1		1					1		1	
10	1				0							0			
11	2			3	0			0				0			1
12	2		2		0		0					1		1	
.															
.															
.															
600	2	2			0	0						1	1		

APPENDIX E

Ethical Clearance Certificate (Human Research Ethics Committee).

R14/49 Dr Hristinka Tasseva

HUMAN RESEARCH ETHICS COMMITTEE (MEDICAL)

CLEARANCE CERTIFICATE NO. M150642

NAME: (Principal Investigator)	Dr Hristinka Tasseva
DEPARTMENT:	Wits Oral Health Centre Charlotte Maxeke Johannesburg Academic Hospital
PROJECT TITLE:	Error Analysis of Digital Panoramic Radiographs taken at the Wits Oral Health Centre
DATE CONSIDERED:	26/06/2015
DECISION:	Approved unconditionally
CONDITIONS:	
SUPERVISOR:	Prof Brian Buch
APPROVED BY:	Professor P Cleaton-Jones, Chairperson, HREC (Medical)
DATE OF APPROVAL:	08/07/2015

This clearance certificate is valid for 5 years from date of approval. Extension may be applied for.

DECLARATION OF INVESTIGATORS

To be completed in duplicate and **ONE COPY** returned to the Secretary in Room 10004, 10th floor, Senate House, University.
I/we fully understand the conditions under which I am/we are authorized to carry out the above-mentioned research and I/we undertake to ensure compliance with these conditions. Should any departure be contemplated, from the research protocol as approved, I/we undertake to resubmit the application to the Committee. **I agree to submit a yearly progress report**.

Principal Investigator Signature Date

PLEASE QUOTE THE PROTOCOL NUMBER IN ALL ENQUIRIES

APPENDIX F

Ethical Clearance Certificate (Hospital Research and Ethics Committee).



WITS Oral Health Centre
Private Bag X15, BRAAMFONTEIN, 2017
Enquiries: Ms ME Huygen
Tel: 011 717 2130
Fax: 086 765 4436
e-mail: Liza.Huygen@wits.ac.za

October 5, 2015

Dr H Tasseva
School of Oral Health Sciences
University of the Witwatersrand
Johannesburg

Regarding: "Error Analysis of Digital Panoramic Radiographs Taken at the Wits Oral Health Centre"

Reference: HREC/OCT2015/01

It is my pleasure to grant final approval to utilize the resources in the radiology section of the Wits Oral Health Centre in order to conduct your research with the above title. The Hospital Research and Ethics Committee allocated a unique reference number to this application - Kindly quote this reference number in all future correspondence regarding this research topic.

Please note that the Hospital Research and Ethics Committee should be informed of the estimated date the research will commence, as well as regular status reports until the research have been concluded. Within a month after conclusion of the research project, a written report must be submitted to the Head of School / CEO, summarizing the final results / outcome as well as recommendations made based on the research conducted.

Regards,

Prof P Hlongwa
CEO / Head of School