

https://dspace.org/

Adenomyoepithelioma of the breast, a single-institution study of 17 cases

McCusker, Casey

2019
https://hdl.handle.net/10539/29126

Downloaded from a DSpace repository. https://dspace.org/

Adenomyoepithelioma of the breast, a single-institution study of 17 cases



Dr. Casey McCusker
Student Number: 1585560

A research report in submissible format of a paper, in submission to the Faculty of Health Sciences, University of the Witwatersrand, Johannesburg, in partial fulfilment of the requirements for the degree of Master of Medicine in the branch of Anatomical Pathology

Johannesburg, 2019

Declaration

UNIVERSITY OF THE WITWATERSRAND, JOHANNESBURG

FACULTY OF HEALTH SCIENCES

PLAGIARISM DECLARATION TO BE SIGNED BY ALL HIGHER DEGREE STUDENTS

SENATE PLAGIARISM POLICY: APPENDIX ONE

I CASEY JULIA MCCUSKER (Student number: 1565560) am a student registered for the degree of MMED (ANAT PATH) in the academic year 2019.

I hereby declare the following:

- I am aware that plagiarism (the use of someone else's work without their permission and/or without acknowledging the original source) is wrong.
- I confirm that the work submitted for assessment for the above degree is my own unaided work except where I have explicitly indicated otherwise.
- I have followed the required conventions in referencing the thoughts and ideas of others.
- I understand that the University of the Witwatersrand may take disciplinary action against me if there is a belief that this is not my own unaided work or that I have failed to acknowledge the source of the ideas or words in my writing.
- I have included as an appendix a report from "Turnitin" (or other approved plagiarism detection) software indicating the level of plagiarism in my research document.

Signature: [signature] Date: 09/04/2019

Declaration: Student's contribution to article(s) and agreement of co-author(s)

I, Casey Julia McCusker, student number [1585560], declare that this Research Report is my own work and that I contributed adequately towards research findings published in the article(s) stated below which are included in my Research Report .

Signature of Student ..... CMcusker .....

Date 13 September 2018

Name of Primary Supervisor: Dr. Kirstin Janine Fearnhead

Signature of Primary Supervisor
..... KJF ..... **Date** 15/9/18 .....

Agreement by co-authors: By signing this declaration, the co-authors listed below agree to the use of the article(s) by the student as part of his/her Thesis/Dissertation/ Research Report. In cases where the student is not the 1st author of a published article, the primary supervisor must explain (under comments) why the student is entitled to use the paper for his/her degree purposes.

Article 1: Title: Adenomyoepithelioma of the breast, a single-institution study of 17 cases

Journal name, year, volume and page numbers: Human Pathology, in submission

Authors	Name	Signature	Date
1st author	Casey Julia McCusker	CMcusker	15/9/18
2nd author	Kirstin Janine Fearnhead	KJF	15/9/18
3rd author	Sarah Rayne	SRayne.	12/9/18
4th author	N/A		
5th author	N/A		
6th author	N/A		

Comments by primary supervisor:

.....
None.....

.....
.....

Letter stating role of candidate in writing paper

Histopathology Department

3rd floor, Division of Anatomical Pathology

Wits Medical School

University of the Witwatersrand

7 York Road

Parktown, Johannesburg, 2193

13 September 2018

Letter to confirm contribution of candidate for a research report by submissible format of a paper for the degree : MMed

Dear Sir/Madam,

This letter serves to confirm my and my supervisor's contributions to submission of a paper.

I confirm that I proposed this research project and state my role in writing this paper: research proposal, ,data collection, reviewing of histopathology slides (50%), interpretation of results (80%) and writing of the manuscript (100%).

My supervisors assisted in the following:

Dr. Kirstin Fearnhead reviewed the histopathology slides (50%), assisted with interpretation of results (20%), supervised the proposal and manuscript (60%), reviewed the proposal (60%) and manuscript (80%) and assisted with compiling the report (50%). Prof. Sarah Rayne assisted with clinical information and insights (100%), supervised the proposal and manuscript (40%) and reviewed the proposal (40%) and manuscript (10%). Dr. Pamela Michelow reviewed the manuscript (10%) and assisted with compiling the report (50%).

Signed : Dr. K. Fearnhead :
Prof. S. Rayne :
Dr. P. Michelow :

Yours Sincerely,

Dr Casey McCusker :

Dedication

To Jack and Aidan.

Presentations and publications arising from this study

Presentations: none.

Publication: I intend to submit this manuscript to the journal Human Pathology.

Roles of principal investigator, supervisor and co-supervisor: Dr Casey McCusker proposed this research project, undertook data collecting, reviewing of histopathology slides and writing of the manuscript. Dr Kirstin Fearnhead reviewed the histopathology slides, assisted with interpretation of results and supervised, reviewed the proposal and manuscript and assisted with compiling the report. Professor Sarah Rayne assisted with clinical information and insights and supervised and reviewed the proposal and manuscript. Dr Pamela Michelow reviewed the manuscript and assisted with compiling the report.

Abstract

Adenomyoepitheliomas (AME) are rare tumours of the breast. Although they are benign, features such as local recurrence, malignant transformation and metastases are described. The objective is to report our findings on a case series of AME of the breast. A cross-sectional retrospective descriptive study was performed on cases with a diagnosis of AME. Clinical, radiological and histopathologic findings were studied. Seventeen cases were identified in 13 patients, with a median age of 50 years (34 to 79 years), in an 18-year time period from 2000 to 2018. The AMEs ranged in size from 1mm to 150mm. Intratumoural heterogeneity was evidenced by a combination of 2 and 3 low-power architectural patterns (solid, cystic, nodular) and high-power architectural patterns (papillary, pseudopapillary, trabecular, tubular), an admixture of subtypes (tubular, lobular and spindle cell) and myoepithelial cell phenotypes (spindle cell, plasmacytoid, epithelioid and clear cell). In summary, we present a case series of 17 cases of AME in which clinical features, radiological findings and histopathological features, including immunohistochemistry are detailed. Of note, we expand the size range and document unusual associations in 4 cases of lobular carcinoma in-situ (LCIS), necrotising granulomatous inflammation, clincial extension onto the chest wall and a rare case of AME with carcinoma (epithelial and myoepithelial carcinoma).

Acknowledgements

Dr Kirstin Fearnhead for her utmost dedication to this project, timeous reviews and invaluable knowledge.

Prof Sarah Rayne for her beneficial insight, interest and clinical expertise.

Prof Mario Altini for his assistance with initiating this report.

Dr Pamela Michelow for reviewing the manuscript and assistance with compiling this report.

Dr Sarah Nietz, consultant surgeon and Dr Jackie Smilg, consultant radiologist at the Breast Imaging Unit at Charlotte Maxeke Johannesburg Academic Hospital (CMJAH), histopathologists Dr Zama Mtshali (CMJAH) amd Dr Aubrey Madliwa (Lancet Laboratories) for the AME with carcinoma; histopathologist Dr Sugeshnee Pather at Chris Hani Baragwanath Academic Hospital (CHBAH) for the cases of AME.

Mr Eric Liebenberg for assistance with the editing of images.

Fadila Ebrahim and Helen Nxumalo for assistance with retrieval of cases.

Table of contents

Declaration ii

Letter stating role of candidate in writing paper iv

Dedication v

Presentations and publications arising from this study vi

Abstract vii

Acknowledgements viii

Table of contents ix

Nomenclature xi

List of figures xii

List of tables ..... xix~~xix~~xiv

Section 1: Author Guidelines 1

Section 2: Draft article to Human Pathology, submission for original contribution 21

2.1 Title page 21

2.2 Abstract 23

2.3 Manuscript 24

2.3.1. Introduction 24

2.3.2 Materials and methods 24

2.3.2.1 Study design and study sample 24

2.3.2.2 Inclusion and exclusion criteria 24

2.3.2.3 Methods 24

2.3.3. Results 25

2.3.3.1 Clinical features of AME 25

2.3.3.2 Case reports 27

2.3.4 Discussion 29

2.3.5. Conclusion 32

2.3.6 Acknowledgements 32

2.4 Lists of tables and figures 33

2.4.1 List of tables 33

2.4.2 List of figures with captions 38

2.5 References 49

Section 3: Appendices **52**
3.1 Ethics approval 52
3.2 Ethics amendment approval letter 53
3.3 Postgraduate assessor group approval 54
3.4 Postgraduate assessor group approval corrections 55
3.5 Appointment of supervisors 57
3.6 Addition of supervisor 58
3.7 Turn-it-in similarity report 59
3.8 Plagiarism declaration 61
Section 4 : Research Proposal **62**
4.1. Background and introduction 64
4.2. Aims 68
4.3. Objectives 68
4.4. Methods 68
4.5. Funding 70
4.6. Ethics 70
4.7. Time scale 70
4.8. Task allocation 71
4.9. Anticipated difficulties 71
4.10. References 71

Nomenclature

AME:	Adenomyoepithelioma
ALH:	Atypical lobular hyperplasia
BI-RADS:	Breast Imaging Reporting and Data System
DCIS:	Ductal carcinoma in-situ
FNA:	Fine needle aspirate
H&E:	Haematoxylin and Eosin
CHBAH:	Chris Hani Baragwanath Academic Hospital
CMJAH:	Charlotte Maxeke Johannesburg Academic Hospital
LCIS:	Lobular carcinoma in-situ
SNOMED:	Systematized Nomenclature Of Medicine
WHO:	World Health Organisation

List of figures

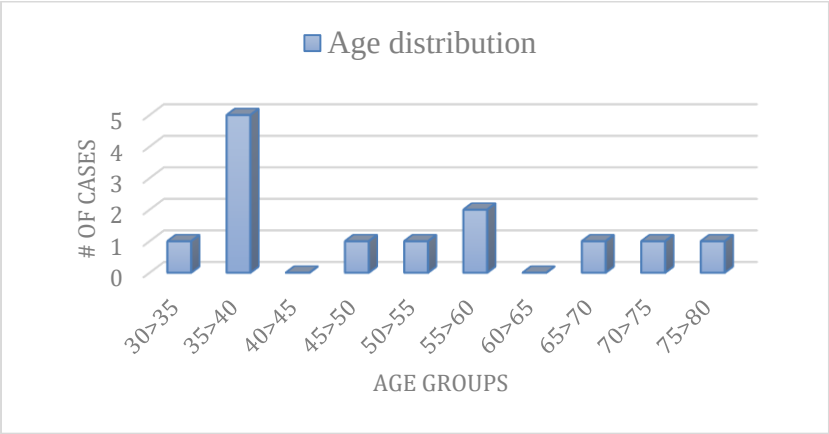

Fig. A.1 Histogram showing age distribution as number of cases per 5 year age groups in 13 patients with AME

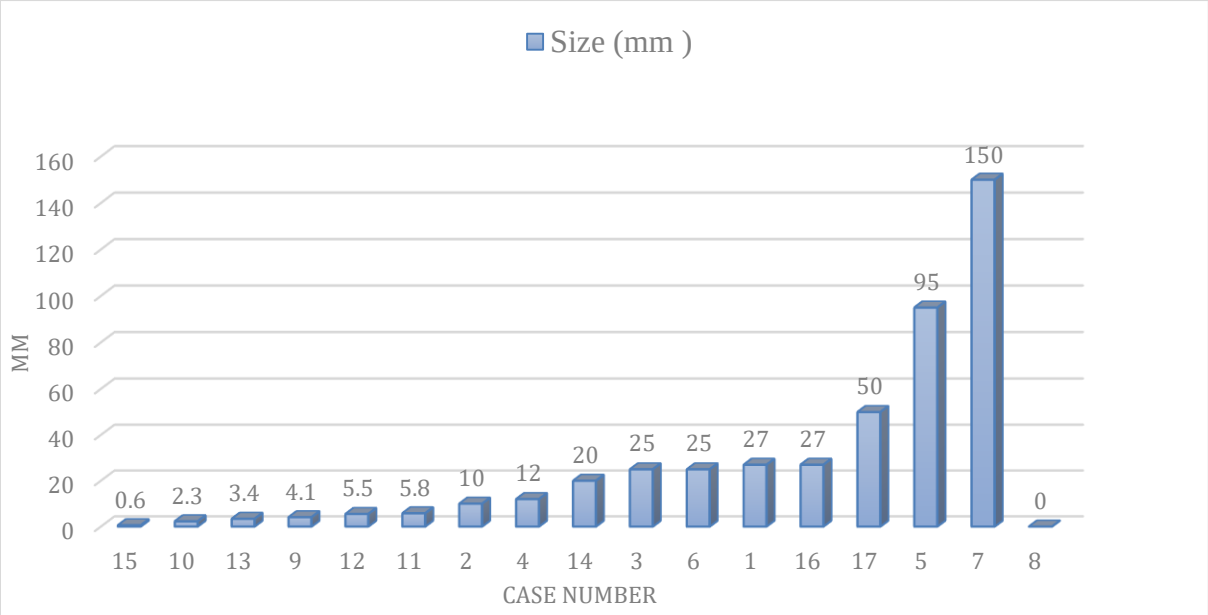

Fig. A.2 Histogram showing size of AME in each case

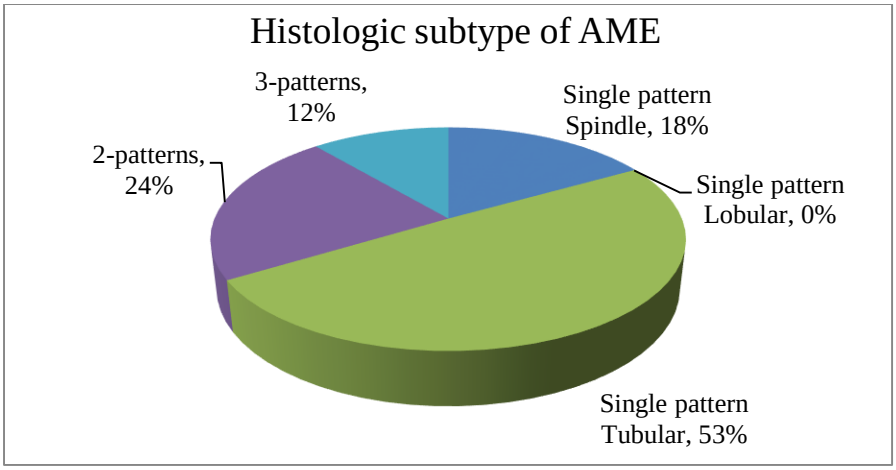

Fig. A.3 Histologic subtypes of AME with single, 2- and 3-patterns

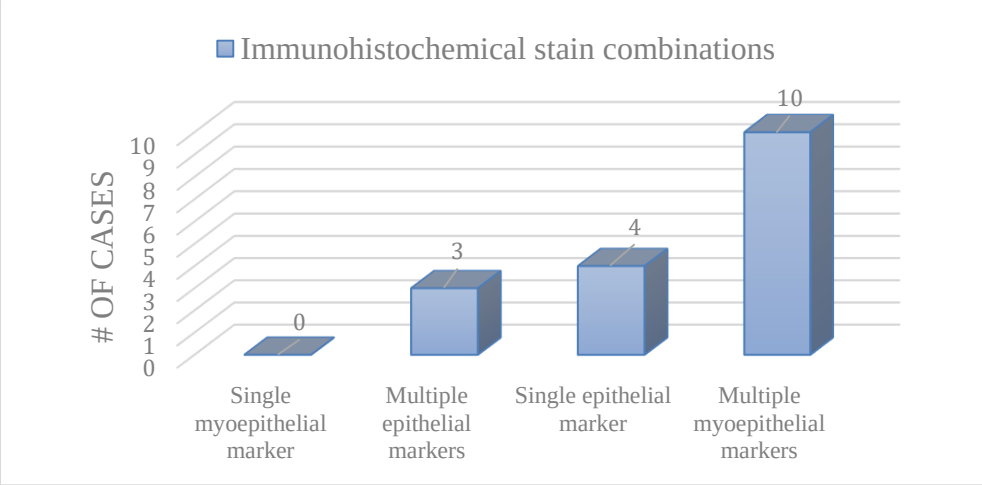

Fig. A.4 Use of single or multiple epithelial and myoepithelial immunohistochemical (IHC) stains in cases where IHC was performed

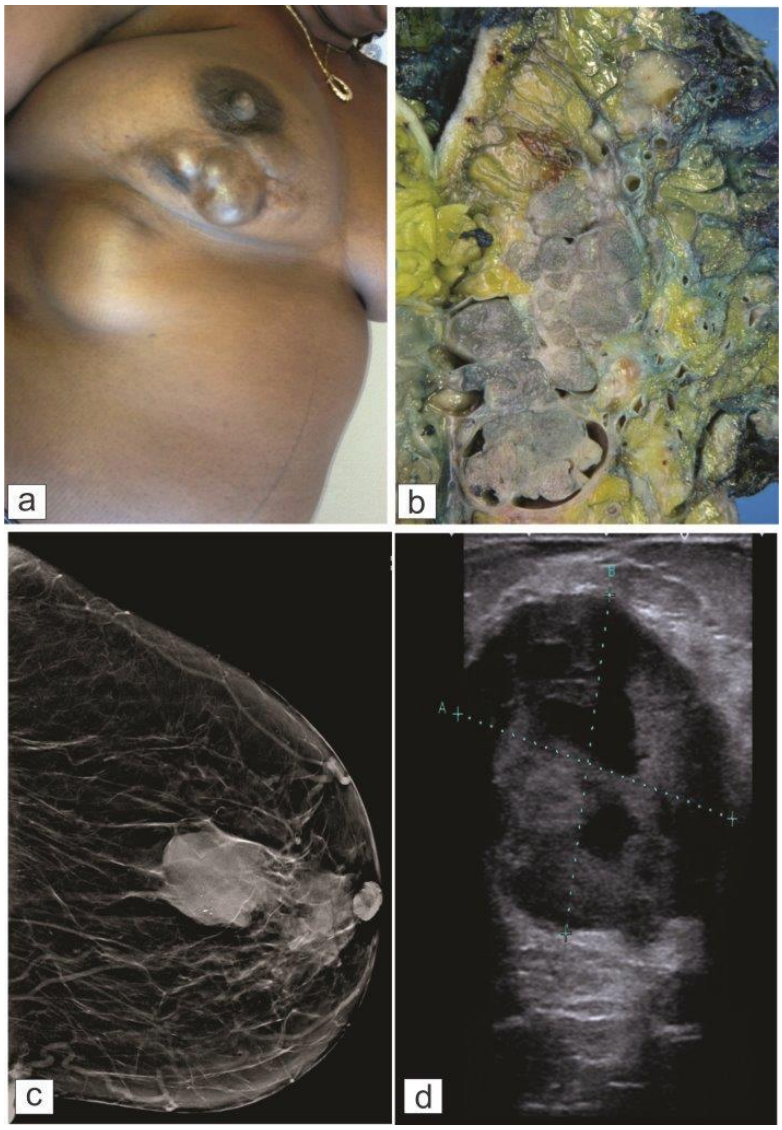

Fig. A.5 Clinical, macroscopic and radiological images of selected cases

a. Photograph of a right breast mass with clinical extension onto the chest wall 4 years following needle core biopsy (case 5).

b. Macroscopic photograph of the largest AME in our series, demonstrating solid papillary-like and cystic components (case 5) of the tumour.

c. Mammogram image of AME with carcinoma (case 17), showing a mass with ill-defined margins and calcifications, BI-RADS 5.

d. Ultrasound image of AME with carcinoma (case 17), showing an irregular solid and cystic mass.

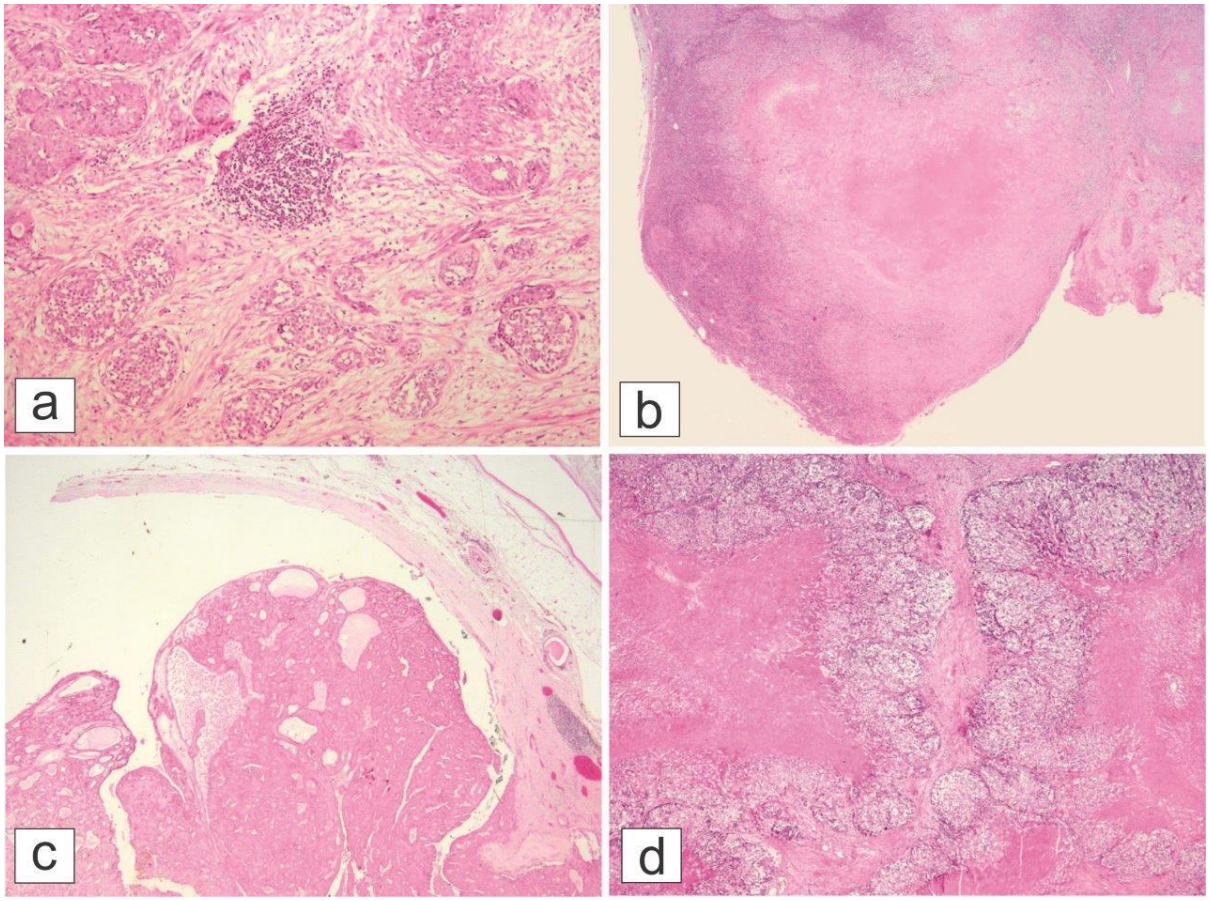

Fig. A.6 Histopathologic photomicrographs of selected cases

a. Photomicrograph showing AME with colonisation of lobules by LCIS (case 3), haematoxylin and eosin (H&E) stain, original magnification x100.
b. Photomicrograph of nodal tuberculosis in a patient with AME (case 4), H&E stain x20.
c. Photomicrograph of largest AME with cystic and papillary areas (case 5), H&E stain x20.
d. Photomicrograph of AME with carcinoma, showing malignant epithelial and myoepithelial components and extensive tumour necrosis (case 17), H&E stain x40.

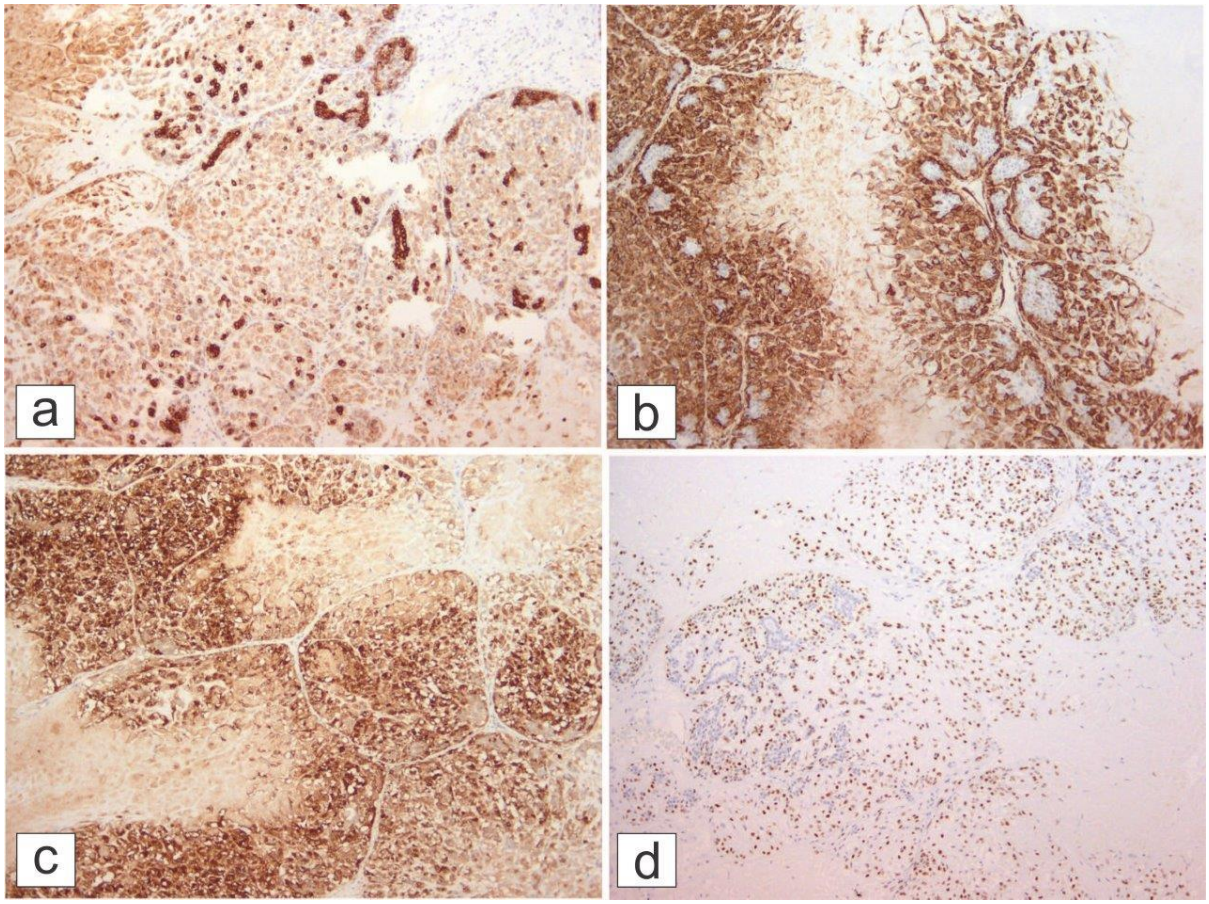

Fig. A.7 Immunohistochemical photomicrographs of selected cases

Photomicrograph of AME with carcinoma, immunohistochemical stains (case 17), original magnification x100:

a. AE1/3, showing strong-intensity positive cytoplasmic staining of the epithelial component and weak-intensity positive cytoplasmic staining of the myoepithelial component.
b. SMA, showing negative staining of the epithelial component and strong-intensity positive cytoplasmic staining of the myoepithelial component.
c. S100, showing weak positive cytoplasmic staining of the epithelial component (interpreted as negative) and strong-intensity positive cytoplasmic and nuclear staining of the myoepithelial component.
d. p63, showing negative staining of the epithelial component and strong-intensity positive nuclear staining of the myoepithelial component.

Lists of tables

Table. A.1. Adenomyoepithelioma, clinical (demographics and specimen details) and radiological (ultrasound, mammogram, and other, including BI-RADS) results

Case	Age	Laterality	Specimen	Symptoms	Episode	Size (mm)	Mammogram	Ultrasound	Other
1	58	R	NCB;WLE	Mass	Initial	27	N	N	N/A
2	38	R	LPT	Mass	Initial	20	Lobulated, cystic	Cystic, hypoechoic	N/A
3	37	R	M + ALND	Unk	Initial	25	N	N	N/A
4	35	R	LPT + LNBx	Mass	Initial	12	N	N	N/A
5	39	R	NCB;WLE	Mass onto chest wall clinically	Initial	150	N	N	N/A
6	34	L	Re-excision	None	Prev bgn phyllodes	18	N	N	MRI: fibroadenomas
7	79	L	LPT	Mass	Initial	55	N	N	N/A
8	70	L	NCB	Mass	Initial	U	Lobulated	Solid	BI-RADS 2
9-13	54	L	BBR	Macromastia	Initial	4,1;2,3;5,8;5,5;3,4	N	N	N/A
14	36	L	LPT	Unk	Initial	20	N	N	N/A
15	45	R	BBR	Macromastia	Initial	0.6	N	N	N/A
16	58	R	NCB	Mass, mastalgia	Initial	27	Lobulated	Lobulated,irreg marg, PAS	BI-RADS 4b
17	69	L	NCB;M+ALND	Mass	Initial	50	Ill-def marg, bgn calcs	Irreg solid and cystic	BI-RADS 5

Abbreviations: R: right; Unk: unknown; L: left; NCB: needle core biopsy; WLE: wide local excision; LPT: lumpectomy; M + ALND: mastectomy and axillary lymph node dissection; LNBx: lymph node biopsy; BBR: bilateral breast reduction; Prev: previous; bgn:benign; N: no report available; Ill-def: ill-defined; calcs: calcifications; Irreg: irregular; marg: margins; PAS: posterior acoustic shadowing; N/A: not applicable

Table. A.2. Adenomyoepithelioma, histopathologic and immunohistochemical (epithelial and myoepthelial) findings

Case	LP Arch	HP Arch	Subtype	Border	Myoepithelial phenotype	Margins	MF	Other features / Co-existing pathology	Immunohistochemistry*
1	So, Cy, No	Pp	Sp	Infilt	Sp, Epith	Ex	0	Seb C, FC, AM / UDH	Ep: AE1/3 +3/3; My: p63 +1/3, s100 +3/3, MSA +2/2, SMA +3/3
2	No	Tu	Tu	Infilt	Sp, Epith, CC	At	1	PC / None	Ep: AE1/3 +3/3; My: p63 +3/2, s100 +3/3, SMA +3/3, CD10 +3/3
3	So, No	Tu, Trab	Tu	Push	Sp	Ex	0	None/ LCIS, CCC, ADH	Ep: AE1/3 +3/3; My: SMA +3/3, CD10 +3/2, GFAP +3/3
4	No,	Tu, Trab	Sp	Push	Sp	Ex	0	None / MTB	None
5	So, Cy, No	Pap, Pp ,Tu	Tu, Lo	Push	Sp, CC	At	1	Infarction / None	Ep: MNF116 +3/3, Cam5.2 +3/3; My: p63 +3/2, SMA +3/3, CK5/6 +3/2, H-cal +2/3
6	Cy, No	Pp	Tu	Push	Sp, Epith	Ex	5	AM / FA, PT	Ep: none; My: p63 +3/3, s100 +3/3, CD10 +3/3.
7	So, No	Trab	Sp	Push	Sp, Epith,	At	0	Myxchndr / None	Ep: EMA +2/2, CEA +1/3; My: s100 +2/3, MSA +1/3, SMA +1/3
8	So	Trab	Tu	Unk	Epith, CC	N/A	0	None / None	Ep: EMA +3/3; My: s100 +3/3; MSA +1/2
9	So, No	Tu	Tu	Push	Sp, Epith	Ex	1	None / IDP, CS	Ep: none; My: p63 +3/3, s100 +3/3, MSA +3/3; SMA +3/3
10	No	Tu	Tu, Lo	Infilt	Sp	Ex	0	FC, AM / FA	None
11	So, No	Tu	Tu	Infilt	Sp, Epith	Ex	0	FC, AM, DC / None	None
12	No	Tu	Tu, Lo	Push	Sp	Ex	0	FC, AM / None	None
13	So, No	Pp	Tu	Infilt	Sp	Ex	0	FC, AM, DC / None	None
14	So, Cy, No	Pp, Tu	Sp, Tu	Push	Sp, CC	Ex	2	PC / None	None
15	No	Tu	Tu	Push	Sp	Ex	2	None / None	None
16	No	Tu	Tu	N/A	Sp	N/A	0	FC / CS	Ep: none; My: p63 +3/3, CK5/6 +3/3
17	No	Tu	Sp, Tu, Lo	Push	Sp, Epith, CC	Ex	10	Malignancy / CCC,ADH	Ep:AE1/3 +3/3, EMA +2/2; My: p63 +3/3, s100 +3/3, SMA +3/3, CD10 +3/3

Abbreviations: LP arch: low-power architecture; HP arch: high-power architecture; MF: mitotic figures/10 high-power field; So: solid; Cy: cystic; No: nodular; Pap: papillary; Pp: pseudopapillary, Tu: tubular; Trab: trabecular; Sp: spindle; Lo: lobular; Infilt: infiltrating; Push: pushing; Unk: unknown; N/A: not applicable; Epith: epithelioid; CC: clear cell; Ex: excised; Seb C: sebaceous cells; FC: foam cells; AM: apocrine metaplasia; UDH: usual duct hyperplasia; PC: psammomatous calcification; LCIS: lobular carcinoma in situ; CCC: columnar cell change; ADH: atypical duct hyperplasia; MTB: mycobacterial infection; FA: fibroadenoma; PT: phyllodes tumour; Myxchndr: myxochondroid; IDP: intraductal papilloma; CS: collegenous spherulosis; DC: dystrophic calcification; Ep: epithelial markers; My: myoepithelial markers; +: positive; *quantification of positive immunohistochemical result: proportion (0 = none, 1 = 1-10%, 2 = 11-50%, 3 = >50%) / intensity (0 = none, 1 = weak, 2 = moderate, 3 = strong)

Table. A.3 Frequency table illustrating clinical, radiological and histopathologic findings

	Frequency	Percentage (%		Frequency	Percentage (%)
Laterality	n=17		**Margins**	n=17	
Right	7	42	Excised	12	71
Left	10	59	At margins	3	18
Symptoms	n = 13		N/A	2	12
Mass	8	62	**Mitotic figures**	n=17	
Unknown	2	15	0-2	15	88
Macromastia	2	15	5	1	6
Mastalgia	1	8	10	1	6
Asymptomatic	1	8	**Other features**	n=17	
Mammogram findings	n=13		Absent	5	29
No report available	9	69	Present	12	70
Lobulated/cystic	1	8	Malignancy	1	6
Lobulated	2	15	**Co-existing pathology**	n=17	
Ill-defined	1	8	Absent	9	53
Ultrasound	n=13		Present	8	47
No report available	9	69	**Immunohistochemistry**	n=10	%
Cystic, solid	1	8	None	7	70
Cystic, hypoechoic	1	8	AE1/AE3	4	40
Lobulated	1	8	CAM 5.2	1	10
Irregular margins	2	15	MNF116	1	10
Posterior acoustic shadowing	1	8	EMA	3	30
Low power architecture	n=17		CEA	1	10
Single pattern	8	47	SMA	7	70
2-patterns	6	35	MSA	5	50
3-patterns	3	18	CD10	4	40
High power architecture	n=17		p63	7	70
Single pattern	13	76	GFAP	1	10
2-patterns	3	18	CK5/6	2	20
3-patterns	1	6	H-caldesmon	1	10
			S100	7	70

Table. A.4. Adenomyoepithelioma, a summary of the published case series of AME

Case series	Author	Year	Total number	Total number of AME	Recurrent	Malignant	Metastasis
1	Rosen et al [5]	1987	18	18	2	0	0
2	Decorsiere et al [6]	1988	U	17	U	U	U
3	Tavassoli [7]	1991	31	27	2	2	1
4	Loose et al [8]	1992	6	6	3	2	1
5	McClaren et al [3]	2005	35	23	0*	0	0
6	Hayes [9]	2011	25	12	2	13	4
7	Moritz [10]	2016	14	10	0	4	ND

Abbreviations: U, unknown; ND, not documented

*Only 12 of the 23 patients were followed up

Section 1: Author Guidelines



HUMAN PATHOLOGY

TABLE OF CONTENTS

- **Description p.1**
- **Impact Factor p.1**
- **Abstracting and Indexing p.1**
- **Editorial Board p.2**
- **Guide for Authors p.5 DESCRIPTION**

AUTHOR INFORMATION PACK

ISSN: 0046-8177

Human Pathology is designed to bring authoritative information of clinicopathologic significance to human disease to the laboratory and clinical physician. It presents information drawn from morphologic and clinical laboratory studies with direct relevance to the understanding of human diseases. Papers published concern morphologic and clinicopathologic observations, reviews of diseases, analyses of problems in pathology, significant collections of case material and advances in concepts or techniques of value in the analysis and diagnosis of disease. Theoretical and experimental pathology and molecular biology pertinent to human disease are included. This critical and authoritative journal is well illustrated with exceptional reproductions of photomicrographs and microscopic anatomy.

Benefits to authors We also provide many author benefits, such as free PDFs, a liberal copyright policy, special discounts on Elsevier publications

and much more. Please click here for more information on our author services.

Please see our Guide for Authors for information on article submission. If you require any further information or help, please visit our Support Center

IMPACT FACTOR 2017: 3.125 © Clarivate Analytics Journal Citation Reports 2018

ABSTRACTING AND INDEXING

Current Contents (Life Sciences, Clinical Medicine) BIOSIS Previews EMBASE MEDLINE®

PubMed Science Citation Index Science Citation Index Expanded Scopus

EDITORIAL BOARD

Editor-in-Chief

R.V. Lloyd

European Editor

V. Eusebi

Managing Editor

C. Reyes

Editorial Assistant

J. Costello

Senior Associate Editors

L. Cheng, L.A. Erickson

Associate Editors

A.T. Deyrup, M. Alba Greco, V.A. Li Volsi, D. Powell, M.T. Tetzlaff

Editorial Board

S.A. Abdulkadir, L.V. Abruzzo, P.A. Adegboyega, A.M. Adesina, C.E. Alpers, M.B. Amin, D.A. Arber, G. Ayala, H. Battifora, M.S. Brandwein-Gensler, M.P. Bronner, P. Brousset, D.G. Buehler, P.T. Cagle, I. Chervoneva, R. Chetty, K.R. Cho, H.S. Cooper, M.T. Curtis, J.E. Dahlstrom, B. Davidson, B. Delahunt, R.A. DeLellis, B.R. DeYoung, Y. Dobashi, J.R. Downing, D.E. Elder, A.K. El-Naggar, J.I. Epstein, O.O. Fadare, G. Fan, M.J. Finegold, C.D.M. Fletcher, A. Fogo, A. Folpe, M.P. Foschini, K. Foucar, J.R. Goldblum, F. Gorstein, J.K. Greenson, J. Gu, J. Guarner, E.T. Hedley-Whyte, C.S. Herrington, J.L. Hornick, R.H. Hruban, E.D. Hsi, W. Huang, P.

Huettner, P. Hui, P.A. Humphrey, J.L. Hunt, O.H. Iwenofu, J. Jessurun, S. Kakar, A. Khoor, C.G. Kleer, M.J. Klein, G. Klöppel, T. Krausz, M. Krishna, S. La Rosa, A.K.Y. Lam, W.C. Lambert, L.A. Langford, C. Larsen, J. Lasota, W.D. Lawrence, E.Y. Lee, X. Li, P. Lin, I.C. Low, A. Mahajan, M. Mahalingam, J.C. Manivel, A.M. Marchevsky, E.J. Mark, R.S. Markin, K. Matkowskij, P.A. McCue, A.M. McNicol, J. Medeiros, M. Michal, G.K. Michalopoulos, M. Miettinen, S.E. Mills, K. Mittal, K. Mukai, J.L. Myers, Y. Natkunam, G.J. Netto, Y.E. Nikiforov, A. Noffsinger, M.R. Nucci, R.D. Odze, T.J. O'Leary, E. Oliva, A. Oliveira, A. Orazi, R.Y. Osamura, A.O. Osunkoya, J. Palazzo, Y-K Park, A.S. Patchefsky, S.C. Peiper, Y. Peng, E. Perlman, A. Perry, M.L. Prasad, J. Prat, R.W. Redline, M.B. Resnick, R. Riddell, J.K. Ro, R.A. Robinson, F.J. Rodriguez, JR Rosai, J.N. Rosenbaum, P. Ruiz, P.M. Sadow, J. Said, S.J. Schnitt, D.A. Schwartz, R.B. Shah, L.M. Sholl, K Shroyer, G.P. Siegal, M. Skacel, D.C. Snover, M.H. Stoler, S.H. Swerdlow, J.R. Torrealba, W.D. Travis, M. Tretiakova, H.V. Vinters, R. Virmani, R. Watson, R.S. Weinstein, L.M. Weiss, B.M. Wenig, T.M. Wheeler, M.R. Wick, E.J. Wilkinson, H. Xu, X. Xu, E. Yakirevich, M.M. Yeh, S.A. Yousem, L. Zhang, W. Zheng

Editors Emeriti

F. Gorstein, 1988-2005 **B. M. Wagner**, 1970-1988

GUIDE FOR AUTHORS

Introduction

Manuscripts are considered for publication in *Human Pathology* provided that they have never been published and are not under simultaneous review by another journal.

Chris Reyes, Managing Editor cmreyes@wisc.edu. Additional contact information for inquiries: Tel: 608-262-1868 Department of Pathology and Laboratory Medicine University of Wisconsin–Madison 1300 University Ave., 521 SMI Madison, WI 53706-1510, USA

BEFORE YOU BEGIN

Ethics in publishing

Please see our information pages on Ethics in publishing and Ethical guidelines for journal publication.

Human and animal rights

If the work involves the use of human subjects, the author should ensure that the work described has been carried out in accordance with The Code of Ethics of the World Medical Association (Declaration of Helsinki) for experiments involving humans; Uniform Requirements for manuscripts submitted to Biomedical journals. Authors should include a statement in the manuscript that informed consent was obtained for experimentation with human subjects. The privacy rights of human subjects must always be observed.

All animal experiments should comply with the ARRIVE guidelines and should be carried out in accordance with the U.K. Animals (Scientific Procedures) Act, 1986 and associated guidelines, EU Directive 2010/63/EU for animal experiments, or the National Institutes of Health guide for the care and use of Laboratory animals (NIH Publications No. 8023, revised 1978) and the authors should clearly indicate in the manuscript that such guidelines have been followed.

Declaration of interest

All authors must disclose any financial and personal relationships with other people or organizations that could inappropriately influence (bias) their work. Examples of potential competing interests include employment, consultancies, stock ownership, honoraria, paid expert testimony, patent applications/registrations, and grants or other funding. Authors must disclose any interests in two places: 1. A summary declaration of interest statement in the title page file (if double-blind) or the manuscript file (if single-blind). If there are no interests to declare then please state this: 'Declarations of interest: none'. This summary statement will be ultimately published if the article is accepted. 2. Detailed disclosures as part of a separate Declaration of Interest form, which forms part of the journal's official records. It is important for potential interests to be declared in both places and that the information matches. More information.

Submission declaration and verification

Submission of an article implies that the work described has not been published previously (except in the form of an abstract, a published lecture or academic thesis, see 'Multiple, redundant or concurrent publication' for more information), that it is not under consideration for publication elsewhere, that its publication is approved by all authors and tacitly or explicitly by the responsible authorities where the work was carried out, and that, if accepted, it will not be published elsewhere in the same form, in English or in any other language, including electronically without the written consent of the copyright- holder. To verify originality, your article may be checked by the originality detection service Crossref Similarity Check.

Preprints

Please note that preprints can be shared anywhere at any time, in line with Elsevier's sharing policy. Sharing your preprints e.g. on a preprint server will not count as prior publication (see 'Multiple, redundant or concurrent publication' for more information).

Changes to authorship

Authors are expected to consider carefully the list and order of authors **before** submitting their manuscript and provide the definitive list of

authors at the time of the original submission. Any addition, deletion or rearrangement of author names in the authorship list should be made only **before** the manuscript has been accepted and only if approved by the journal Editor. To request such a change, the Editor must receive the following from the **corresponding author**: (a) the reason for the change in author list and (b) written confirmation (e-mail, letter) from all authors that they agree with the addition, removal or rearrangement. In the case of addition or removal of authors, this includes confirmation from the author being added or removed.

Only in exceptional circumstances will the Editor consider the addition, deletion or rearrangement of authors **after** the manuscript has been accepted. While the Editor considers the request, publication of the manuscript will be suspended. If the manuscript has already been published in an online issue, any requests approved by the Editor will result in a corrigendum.

Registration of clinical trials

Registration in a public trials registry is a condition for publication of clinical trials in this journal in accordance with International Committee of Medical Journal Editors recommendations. Trials must register at or before the onset of patient enrolment. The clinical trial registration number should be included at the end of the abstract of the article. A clinical trial is defined as any research study that prospectively assigns human participants or groups of humans to one or more health-related interventions to evaluate the effects of health outcomes. Health-related interventions include any intervention used to modify a biomedical or health-related outcome (for example drugs, surgical procedures, devices, behavioural treatments, dietary interventions, and process-of-care changes). Health outcomes include any biomedical or health-related measures obtained in patients or participants, including pharmacokinetic measures and adverse events. Purely observational studies (those in which the assignment of the medical intervention is not at the discretion of the investigator) will not require registration.

Copyright

Upon acceptance of an article, authors will be asked to complete a 'Journal Publishing Agreement' (see more information on this). An e-mail will be sent to the corresponding author confirming receipt of the manuscript together with a 'Journal Publishing Agreement' form or a link to the online version of this agreement.

Subscribers may reproduce tables of contents or prepare lists of articles including abstracts for internal circulation within their institutions. Permission of the Publisher is required for resale or distribution outside the institution and for all other derivative works, including compilations

and translations. If excerpts from other copyrighted works are included, the author(s) must obtain written permission from the copyright owners and credit the source(s) in the article. Elsevier has preprinted forms for use by authors in these cases.

For gold open access articles: Upon acceptance of an article, authors will be asked to complete an 'Exclusive License Agreement' (more information). Permitted third party reuse of gold open access articles is determined by the author's choice of user license.

Author rights

As an author you (or your employer or institution) have certain rights to reuse your work. More information.

Elsevier supports responsible sharing

Find out how you can share your research published in Elsevier journals.

Role of the funding source

You are requested to identify who provided financial support for the conduct of the research and/or preparation of the article and to briefly describe the role of the sponsor(s), if any, in study design; in the collection, analysis and interpretation of data; in the writing of the report; and in the decision to submit the article for publication. If the funding source(s) had no such involvement then this should be stated.

Funding body agreements and policies

Elsevier has established a number of agreements with funding bodies which allow authors to comply with their funder's open access policies. Some funding bodies will reimburse the author for the gold open access publication fee. Details of existing agreements are available online.

After acceptance, open access papers will be published under a noncommercial license. For authors requiring a commercial CC BY license, you can apply after your manuscript is accepted for publication.

Open access

This journal offers authors a choice in publishing their research:

Subscription

• Articles are made available to subscribers as well as developing countries and patient groups through our universal access programs. • No open access publication fee payable by authors. • The Author is entitled to post the accepted manuscript in their institution's repository and make this public after an embargo period (known as green Open

Access). The published journal article cannot be shared publicly, for example on ResearchGate or Academia.edu, to ensure the sustainability of peer- reviewed research in journal publications. The embargo period for this journal can be found below. ***Gold open access***

• Articles are freely available to both subscribers and the wider public with permitted reuse. • A gold open access publication fee is payable by authors or on their behalf, e.g. by their research funder or institution.

Regardless of how you choose to publish your article, the journal will apply the same peer review criteria and acceptance standards.

For gold open access articles, permitted third party (re)use is defined by the following Creative Commons user licenses:

Creative Commons Attribution-NonCommercial-NoDerivs (CC BY-NC-ND)

For non-commercial purposes, lets others distribute and copy the article, and to include in a collective work (such as an anthology), as long as they credit the author(s) and provided they do not alter or modify the article.

The gold open access publication fee for this journal is **USD 3300**, excluding taxes. Learn more about Elsevier's pricing policy: https://www.elsevier.com/openaccesspricing.

Green open access

Authors can share their research in a variety of different ways and Elsevier has a number of green open access options available. We recommend authors see our green open access page for further information. Authors can also self-archive their manuscripts immediately and enable public access from their institution's repository after an embargo period. This is the version that has been accepted for publication and which typically includes author-incorporated changes suggested during submission, peer review and in editor-author communications. Embargo period: For subscription articles, an appropriate amount of time is needed for journals to deliver value to subscribing customers before an article becomes freely available to the public. This is the embargo period and it begins from the date the article is formally published online in its final and fully citable form. Find out more.

This journal has an embargo period of 12 months.

Elsevier Researcher Academy

Researcher Academy is a free e-learning platform designed to support early and mid-career researchers throughout their research journey. The "Learn" environment at Researcher Academy offers several interactive modules, webinars, downloadable guides and resources to guide you

through the process of writing for research and going through peer review. Feel free to use these free resources to improve your submission and navigate the publication process with ease.

Language (usage and editing services)

Please write your text in good English (American or British usage is accepted, but not a mixture of these). Authors who feel their English language manuscript may require editing to eliminate possible grammatical or spelling errors and to conform to correct scientific English may wish to use the English Language Editing service available from Elsevier's WebShop.

Submission

Our online submission system guides you stepwise through the process of entering your article details and uploading your files. The system converts your article files to a single PDF file used in the peer-review process. Editable files (e.g., Word, LaTeX) are required to typeset your article for final publication. All correspondence, including notification of the Editor's decision and requests for revision, is sent by e-mail.

Submit your article

Please submit your article via http://ees.elsevier.com/yhupa.

Referees

Please submit the names and institutional e-mail addresses of several potential referees. For more details, visit our Support site. Note that the editor retains the sole right to decide whether or not the suggested reviewers are used.

PREPARATION

Peer review

This journal operates a single blind review process. All contributions will be initially assessed by the editor for suitability for the journal. Papers deemed suitable are then typically sent to a minimum of two independent expert reviewers to assess the scientific quality of the paper. The Editor is responsible for the final decision regarding acceptance or rejection of articles. The Editor's decision is final. More information on types of peer review.

Use of Word Processing Software

It is important that the file be saved in the native format of the wordprocessor used. The text should be in single-column format. Keep the layout of the text as simple as possible. Most formatting codes will be

removed and replaced on processing the article. In particular, do not use the wordprocessor's options to justify text or to hyphenate words. However, do use bold face, italics, subscripts, superscripts, etc. When preparing tables, if you are using a table grid, use only one grid for each individual table and not a grid for each row. If no grid is used, use tabs, not spaces, to align columns. The electronic text should be prepared in a way very similar to that of conventional manuscripts (see also the Guide to Publishing with Elsevier: http://www.elsevier.com/guidepublication). Note that source files of figures, tables and text graphics will be required whether or not you embed your figures in the text. See also the section on Electronic artwork.

To avoid unnecessary errors you are strongly advised to use the 'spell-check' and 'grammar-check' functions of your wordprocessor. The manuscript should be a Microsoft Word (or compatible) file comprising title page, abstract (except announcements, correspondence, and book reviews), manuscript text, references, and table/figure legends. Authors should not embed figures, tables, or supplementary material into the manuscript fi le; these should be submitted separately.

Journal Style

Unless otherwise noted, the style of *Human Pathology follows AMA Manual of Style*, 10th ed. (http://www.amamanualofstyle.com). Formatting, such as Greek letters, italics, super- and subscripts, may be used; such elements must be consistently formatted throughout the manuscript, including tables and legends. Gene symbols should be italicized, whereas proteins are in Roman text. We encourage authors to follow HUGO (http://www.genenames.org/) and Universal Protein Resource nomenclature (http://www.uniprot.org/). Authors should avoid abbreviations in the title and minimize their use in the abstract and main text, particularly for diseases. All abbreviations should be defined the first time they appear in the abstract and text. Standard abbreviations that follow the Unified Medical Language System (https://uts.nlm.nih.gov/home.html) are preferred. Otherwise, a list of definitions for nonstandard abbreviations should be provided on a separate page following the abstract.

Article structure

Subdivision - numbered sections

Divide your article into clearly defined and numbered sections. Subsections should be numbered 1.1 (then 1.1.1, 1.1.2, ...), 1.2, etc. (the abstract is not included in section numbering). Use this numbering also for internal cross-referencing: do not just refer to 'the text'. Any subsection may be given a brief heading. Each heading should appear on its own separate line.

Original Contributions should not exceed 12 pages of text, 30 pages total, including references, tables and figures. References should be limited to 35 and the abstract to 250 words. A maximum of 8 figures/tables will ordinarily suffice to illustrate key points. Manuscripts that exceed these limits, at the discretion of the editorial team, will be returned without review. The typical **Original Contribution** will be organized into Introduction, Materials and Methods, Results, Discussion, and possibly Conclusions/Concluding Remarks.

Case Studies must provide new information. Clinically significant observations based on new or developing technology will receive special consideration. Imaginative applications of established methods are also encouraged. Brevity is required: **Case Studies** must not be more than 12 pages, including references, tables, and figures. The following restrictions apply: 150-word abstract, 15 references, 3 figures/tables. The Case History/Report should be included under Materials and Methods followed by a brief description of whatever tissue manipulations and/or immunologic and molecular techniques were employed. Authors should not provide a literature review.

Human Pathology encourages **Letters to the Editor**, which will be published at the discretion of the editor as space permits and are subject to editing and abridgment for length. Letters should be limited to approximately 500 words and 5 references maximum. Usually, only correspondence responding to items previously published in *Human Pathology* are considered for publication, and we typically invite the authors of the original item to submit a Reply to the Letter to the Editor.

Book Reviews, Current Topics, Editorials, Pathology Education, Perspectives in Pathology, and **Progress in Pathology** are published by invitation only. **Announcements** of conferences and similar events of interest to the readership of *Human Pathology* should be sent to the Managing Editor at least 3 months before the first day of the month of desired publication.

Appendices

If there is more than one appendix, they should be identified as A, B, etc. Formulae and equations in appendices should be given separate numbering: Eq. (A.1), Eq. (A.2), etc.; in a subsequent appendix, Eq. (B.1) and so on. Similarly for tables and figures: Table A.1; Fig. A.1, etc.

Essential Title Page Information

• ***Title.*** Concise and informative. Titles are often used in information-retrieval systems. Avoid abbreviations and formulae where possible. • ***Author names, degree, and affiliations*** (including postal codes). Where the family name may be ambiguous (e.g., a double name), please indicate this clearly. Present the authors' affiliation addresses (where the

actual work was done) below the names. Indicate all affiliations with a lower- case superscript letter immediately after the author's name and in front of the appropriate address. Provide the full postal address of each affiliation, including the country name and, if available, the e-mail address of each author.

• ***Corresponding author.*** Clearly indicate who will handle correspondence at all stages of refereeing and publication, also post-publication. **Ensure that phone numbers (with country and area code) are provided in addition to the e-mail address and the complete postal address. Contact details must be kept up to date by the corresponding author.**

• ***Present/permanent address.*** If an author has moved since the work described in the article was done, or was visiting at the time, a 'Present address' (or 'Permanent address') may be indicated as a footnote to that author's name. The address at which the author actually did the work must be retained as the main, affiliation address. Superscript Arabic numerals are used for such footnotes. Finally, provide 5-7 keywords; a running head that condenses the full title; and conflict of interest and funding disclosures.

Abstract

A concise and factual abstract is required. The abstract should state briefly the purpose of the research, the principal results and major conclusions. An abstract is often presented separately from the article, so it must be able to stand alone. For this reason, References should be avoided, but if essential, then cite the author(s) and year(s). Also, non-standard or uncommon abbreviations should be avoided, but if essential they must be defined at their first mention in the abstract itself.

Graphical abstract

Although a graphical abstract is optional, its use is encouraged as it draws more attention to the online article. The graphical abstract should summarize the contents of the article in a concise, pictorial form designed to capture the attention of a wide readership. Graphical abstracts should be submitted as a separate file in the online submission system. Image size: Please provide an image with a minimum of 531 × 1328 pixels (h × w) or proportionally more. The image should be readable at a size of 5 × 13 cm using a regular screen resolution of 96 dpi. Preferred file types: TIFF, EPS, PDF or MS Office files. You can view Example Graphical Abstracts on our information site. Authors can make use of Elsevier's Illustration Services to ensure the best presentation of their images and in accordance with all technical requirements.

Highlights

Highlights are a short collection of bullet points that convey the core findings of the article. Highlights are optional and should be submitted in a separate editable file in the online submission system. Please use 'Highlights' in the file name and include 3 to 5 bullet points (maximum 85 characters, including spaces, per bullet point). You can view example Highlights on our information site.

Keywords

Immediately after the abstract, provide a maximum of 6 keywords, using American spelling and avoiding general and plural terms and multiple concepts (avoid, for example, 'and', 'of'). Be sparing with abbreviations: only abbreviations firmly established in the field may be eligible. These keywords will be used for indexing purposes.

Formatting of funding sources

List funding sources in this standard way to facilitate compliance to funder's requirements:

Funding: This work was supported by the National Institutes of Health [grant numbers xxxx, yyyy]; the Bill & Melinda Gates Foundation, Seattle, WA [grant number zzzz]; and the United States Institutes of Peace [grant number aaaa].

It is not necessary to include detailed descriptions on the program or type of grants and awards. When funding is from a block grant or other resources available to a university, college, or other research institution, submit the name of the institute or organization that provided the funding.

If no funding has been provided for the research, please include the following sentence:

This research did not receive any specific grant from funding agencies in the public, commercial, or not-for-profit sectors.

Artwork

Image manipulation

Whilst it is accepted that authors sometimes need to manipulate images for clarity, manipulation for purposes of deception or fraud will be seen as scientific ethical abuse and will be dealt with accordingly. For graphical images, this journal is applying the following policy: no specific feature within an image may be enhanced, obscured, moved, removed, or introduced. Adjustments of brightness, contrast, or color balance are acceptable if and as long as they do not obscure or eliminate any information present in the original. Nonlinear adjustments (e.g. changes

to gamma settings) must be disclosed in the figure legend.

Electronic artwork General points

Make sure you use uniform lettering and sizing of your original artwork Embed the used fonts if the application provides that option. Aim to use the following fonts in your illustrations: Arial, Courier, Times New Roman, Symbol, or use fonts that look similar. Number the illustrations according to their sequence in the text. Use a logical naming convention for your artwork files. Provide captions to illustrations separately. Size the illustrations close to the desired dimensions of the published version. Submit each illustration as a separate file. A detailed guide on electronic artwork is available on our website: http://www.elsevier.com/artworkinstructions **You are urged to visit this site; some excerpts from the detailed information are given here.** *Formats* If your electronic artwork is created in a Microsoft Office application (Word, PowerPoint, Excel) then please supply 'as is' in the native document format. Regardless of the application used other than Microsoft Office, when your electronic artwork is finalized, please 'Save as' or convert the images to PDF (note the resolution requirements for line drawings, halftones, and line/halftone combinations given below): Color or grayscale photographs (halftones), keep to a minimum of 300 dpi. Bitmapped (pure black & white pixels) line drawings, keep to a minimum of 1000 dpi. Combinations bitmapped line/half-tone (color or grayscale), keep to a minimum of 500 dpi. Vector drawings, embed all used fonts (EPS optional). **Please do not:** Supply files that are optimized for screen use (e.g., GIF, BMP, PICT, WPG); these typically have a low number of pixels and limited set of colors; Supply files that are too low in resolution; Submit graphics that are disproportionately large for the content.

Color Artwork

Figures should be submitted as individual high-resolution graphics files in EPS or TIF format when possible. Art should be created with graphics software such as Photoshop or Illustrator, not presentation software such as PowerPoint, CorelDraw, or Harvard Graphics. If, together with your accepted article, you submit usable color figures then Elsevier will ensure, at no additional charge, that these figures will appear in color on the Web (e.g., ScienceDirect and other sites) regardless of whether or not these illustrations are reproduced in color in the printed version. Color images must be CMYK, with **minimum resolution of 300 DPI for photos and at least 1200 DPI for line art** (eg, graphs, flow charts, schema). Instructions for electronic artwork submission are available at http://www.elsevier.com/artworkinstructions. Ideally, individual panels of a given figure are arranged in the order they are cited in the text and labeled as a single alphabetical series. Labels should appear as capital letters without background shape. Color art charges apply for the print

edition: $300 for the first color figure and $50 for each additional color figure; art is reproduced in color on the Web free of charge. Higher contrast images are suggested for black and white reproduction in print.

Illustration services

Elsevier's WebShop offers Illustration Services to authors preparing to submit a manuscript but concerned about the quality of the images accompanying their article. Elsevier's expert illustrators can produce scientific, technical and medical-style images, as well as a full range of charts, tables and graphs. Image 'polishing' is also available, where our illustrators take your image(s) and improve them to a professional standard. Please visit the website to find out more.

Figure Captions

Ensure that each illustration has a caption. Supply captions separately, not attached to the figure. A caption should comprise a brief title (**not** on the figure itself) and a description of the illustration. Keep text in the illustrations themselves to a minimum. The legend for each figure should describe the panels in alphabetical order. It is not necessary to assign labels to panels in the figure if they are not cited and discussed individually in the text and legend. Where appropriate, authors should include information on staining and magnification, as well as any abbreviations or objects such as arrows that appear in the image.

Tables

Number tables consecutively in accordance with their appearance in the text. Be sparing in the use of tables and ensure that the data presented in tables do not duplicate results described elsewhere in the article. Tables should be formatted as Word or Excel (or compatible) tables. Avoid vertical rules. Each table should have a brief descriptive legend. Column headers and row stubs should also be brief, and data should be decimal or left aligned as appropriate. All abbreviations should be defined in a single footnote that begins with "Abbreviations:" and should be arranged either alphabetically or in order of appearance. Superscript lower-case letters should be used to denote additional footnotes, and asterisks or footnote letters for statistically significant data instead of values in bold.

References

Citation in Text

References should be arranged in order of citation and numbered consecutively. In-text citations should be formatted in the running text without superscript, enclosed in square brackets, and located to the left of punctuation. All references in the reference list must be cited in the text, and vice versa. If using EndNote (or comparable software) to format

references, authors should remove field codes from the entire manuscript before submission because these automated features are lost in conversion during article layout. Otherwise, authors should simply type the reference number in square brackets in the text and manually type the reference list. “Personal communications” and “unpublished observations” should be indicated within the text but excluded from the reference list. Citation of a reference as 'in press' implies that the item has been accepted for publication. Any references cited in the abstract must be given in full. All author/editor names should be listed when fewer than 7; otherwise, insert “et al” after **third** name.

Reference links

Increased discoverability of research and high quality peer review are ensured by online links to the sources cited. In order to allow us to create links to abstracting and indexing services, such as Scopus, CrossRef and PubMed, please ensure that data provided in the references are correct. Please note that incorrect surnames, journal/book titles, publication year and pagination may prevent link creation. When copying references, please be careful as they may already contain errors. Use of the DOI is highly encouraged.

A DOI is guaranteed never to change, so you can use it as a permanent link to any electronic article. An example of a citation using DOI for an article not yet in an issue is: VanDecar J.C., Russo R.M., James D.E., Ambeh W.B., Franke M. (2003). Aseismic continuation of the Lesser Antilles slab beneath northeastern Venezuela. Journal of Geophysical Research, https://doi.org/10.1029/2001JB000884. Please note the format of such citations should be in the same style as all other references in the paper.

Web references

As a minimum, the full URL should be given and the date when the reference was last accessed. Any further information, if known (DOI, author names, dates, reference to a source publication, etc.), should also be given. Web references can be listed separately (e.g., after the reference list) under a different heading if desired, or can be included in the reference list.

Data references

This journal encourages you to cite underlying or relevant datasets in your manuscript by citing them in your text and including a data reference in your Reference List. Data references should include the following elements: author name(s), dataset title, data repository, version (where available), year, and global persistent identifier. Add [dataset] immediately before the reference so we can properly identify it as a data reference. The [dataset] identifier will not appear in your published

article.

Reference management software

Most Elsevier journals have their reference template available in many of the most popular reference management software products. These include all products that support Citation Style Language styles, such as Mendeley and Zotero, as well as EndNote. Using the word processor plug-ins from these products, authors only need to select the appropriate journal template when preparing their article, after which citations and bibliographies will be automatically formatted in the journal's style. If no template is yet available for this journal, please follow the format of the sample references and citations as shown in this Guide. If you use reference management software, please ensure that you remove all field codes before submitting the electronic manuscript. More information on how to remove field codes.

Users of Mendeley Desktop can easily install the reference style for this journal by clicking the following link: http://open.mendeley.com/use-citation-style/human-pathology When preparing your manuscript, you will then be able to select this style using the Mendeley plug- ins for Microsoft Word or LibreOffice.

Reference style *Text:* Indicate references by number(s) in square brackets in line with the text. The actual authors can be referred to, but the reference number(s) must always be given. *List:* Number the references (numbers in square brackets) in the list in the order in which they appear in the text. *Examples:* Reference to a journal publication: [1] Van der Geer J, Hanraads JAJ, Lupton RA. The art of writing a scientific article. J Sci Commun 2010;163:51–9. https://doi.org/10.1016/j.Sc.2010.00372. Reference to a journal publication with an article number: [2] Van der Geer J, Hanraads JAJ, Lupton RA. The art of writing a scientific article. Heliyon. 2018;19:e00205. doi:10.1016/j.heliyon.2018.e00205 Reference to a book: [3] Strunk Jr W, White EB. The elements of style. 4th ed. New York: Longman; 2000. Reference to a chapter in an edited book: [4] Mettam GR, Adams LB. How to prepare an electronic version of your article. In: Jones BS, Smith RZ, editors. Introduction to the electronic age, New York: E-Publishing Inc; 2009, p. 281–304. Reference to a website: [5] Cancer Research UK. Cancer statistics reports for the UK, http://www.cancerresearchuk.org/ aboutcancer/statistics/cancerstatsreport/; 2003 [accessed 13 March 2003]. Reference to a dataset: [dataset] [6] Oguro M, Imahiro S, Saito S, Nakashizuka T. Mortality data for Japanese oak wilt disease and surrounding forest compositions, Mendeley Data, v1; 2015. https://doi.org/10.17632/ xwj98nb39r.1.

Note shortened form for last page number. e.g., 51–9, and that for more

than 6 authors the first 6 should be listed followed by 'et al.' For further details you are referred to 'Uniform Requirements for Manuscripts submitted to Biomedical Journals' (J Am Med Assoc 1997;277:927–34) (see also Samples of Formatted References).

Journal abbreviations source

Journal names should be abbreviated according to the List of Title Word Abbreviations.

AudioSlides

The journal encourages authors to create an AudioSlides presentation with their published article. AudioSlides are brief, webinar-style presentations that are shown next to the online article on ScienceDirect. This gives authors the opportunity to summarize their research in their own words and to help readers understand what the paper is about. More information and examples are available. Authors of this journal will automatically receive an invitation e-mail to create an AudioSlides presentation after acceptance of their paper.

Data visualization

Include interactive data visualizations in your publication and let your readers interact and engage more closely with your research. Follow the instructions here to find out about available data visualization options and how to include them with your article.

Supplementary material

Supplementary material such as applications, images and sound clips, can be published with your article to enhance it. Submitted supplementary items are published exactly as they are received (Excel or PowerPoint files will appear as such online). Please submit your material together with the article and supply a concise, descriptive caption for each supplementary file. If you wish to make changes to supplementary material during any stage of the process, please make sure to provide an updated file. Do not annotate any corrections on a previous version. Please switch off the 'Track Changes' option in Microsoft Office files as these will appear in the published version.

Research data

This journal encourages and enables you to share data that supports your research publication where appropriate, and enables you to interlink the data with your published articles. Research data refers to the results of observations or experimentation that validate research findings. To facilitate reproducibility and data reuse, this journal also encourages you to share your software, code, models, algorithms, protocols, methods and

other useful materials related to the project.

Below are a number of ways in which you can associate data with your article or make a statement about the availability of your data when submitting your manuscript. If you are sharing data in one of these ways, you are encouraged to cite the data in your manuscript and reference list. Please refer to the "References" section for more information about data citation. For more information on depositing, sharing and using research data and other relevant research materials, visit the research data page.

Data linking

If you have made your research data available in a data repository, you can link your article directly to the dataset. Elsevier collaborates with a number of repositories to link articles on ScienceDirect with relevant repositories, giving readers access to underlying data that gives them a better understanding of the research described.

There are different ways to link your datasets to your article. When available, you can directly link your dataset to your article by providing the relevant information in the submission system. For more information, visit the database linking page.

For supported data repositories a repository banner will automatically appear next to your published article on ScienceDirect.

In addition, you can link to relevant data or entities through identifiers within the text of your manuscript, using the following format: Database: xxxx (e.g., TAIR: AT1G01020; CCDC: 734053; PDB: 1XFN).

Mendeley Data

This journal supports Mendeley Data, enabling you to deposit any research data (including raw and processed data, video, code, software, algorithms, protocols, and methods) associated with your manuscript in a free-to-use, open access repository. Before submitting your article, you can deposit the relevant datasets to *Mendeley Data*. Please include the DOI of the deposited dataset(s) in your main manuscript file. The datasets will be listed and directly accessible to readers next to your published article online.

For more information, visit the Mendeley Data for journals page.

Data statement

To foster transparency, we encourage you to state the availability of your data in your submission. This may be a requirement of your funding body or institution. If your data is unavailable to access or unsuitable to post, you will have the opportunity to indicate why during the submission

process, for example by stating that the research data is confidential. The statement will appear with your published article on ScienceDirect. For more information, visit the Data Statement page.

Submission Checklist

Consult the submission checklist (http://ees.elsevier.com/yhupa/img/Hum_Pathol_submission_checklist.pdf). The following list will be useful during the final checking of an article prior to sending it to the journal for review. Please consult this Guide for Authors for further details of any item.

Ensure that the following items are present:

One author has been designated as the corresponding author with contact details: • E-mail address • Full postal address • Phone numbers

All necessary files have been uploaded, and contain: • Keywords • All figure captions • All tables (including title, description, footnotes) Further considerations

• Manuscript has been 'spell-checked' and 'grammar-checked' • References are in the correct format for this journal • All references mentioned in the Reference list are cited in the text, and vice versa • Permission has been obtained for use of copyrighted material from other sources (including the Web) • Color figures are clearly marked as being intended for color reproduction on the Web (free of charge) and in print, or to be reproduced in color on the Web (free of charge) and in black-and-white in print • If only color on the Web is required, black-and-white versions of the figures are also supplied for printing purposes For any further information please visit our customer support site at http://support.elsevier.com.

AFTER ACCEPTANCE

Online proof correction

Corresponding authors will receive an e-mail with a link to our online proofing system, allowing annotation and correction of proofs online. The environment is similar to MS Word: in addition to editing text, you can also comment on figures/tables and answer questions from the Copy Editor. Web-based proofing provides a faster and less error-prone process by allowing you to directly type your corrections, eliminating the potential introduction of errors.

If preferred, you can still choose to annotate and upload your edits on the PDF version. All instructions for proofing will be given in the e-mail we send to authors, including alternative methods to the online version and PDF. We will do everything possible to get your article published quickly

and accurately. Please use this proof only for checking the typesetting, editing, completeness and correctness of the text, tables and figures. Significant changes to the article as accepted for publication will only be considered at this stage with permission from the Editor. It is important to ensure that all corrections are sent back to us in one communication. Please check carefully before replying, as inclusion of any subsequent corrections cannot be guaranteed. Proofreading is solely your responsibility.

Offprints

The corresponding author will, at no cost, receive a customized Share Link providing 50 days free access to the final published version of the article on ScienceDirect. The Share Link can be used for sharing the article via any communication channel, including email and social media. For an extra charge, paper offprints can be ordered via the offprint order form which is sent once the article is accepted for publication. Both corresponding and co-authors may order offprints at any time via Elsevier's Webshop. Corresponding authors who have published their article gold open access do not receive a Share Link as their final published version of the article is available open access on ScienceDirect and can be shared through the article DOI link.

AUTHOR INQUIRIES

Visit the Elsevier Support Center to find the answers you need. Here you will find everything from Frequently Asked Questions to ways to get in touch. You can also check the status of your submitted article or find out when your accepted article will be published.

Section 2: Draft article to Human Pathology, submission for original contribution

2.1 Title page

Title:

Adenomyoepithelioma of the breast, a single-institution study of 17 cases.

Authors:

Dr. Casey Julia McCusker (MBChB)[a], Dr. Kirstin Janine Fearnhead (MBChB, FCPath (Anat), MMed)[a] and Prof. Sarah Louise Rayne (BSc, MBChB, MRCS, MMed, FCS)[b]

[a]Division of Anatomical Pathology, School of Pathology, Faculty of Health Sciences, University of the Witwatersrand / National Health Laboratory Service, 7 York Road, Johannesburg, South Africa, 2193

[b]Helen Joseph Breast Care Clinic, Netcare Breast Care Centre, Department of Surgery, Faculty of Health Sciences, University of the Witwatersrand, Johannesburg, South Africa, 2193

Corresponding author at :

Division of Anatomical Pathology, School of Pathology, Faculty of Health Sciences, University of the Witwatersrand / National Health Laboratory Service, 7 York Road, Johannesburg, South Africa, 2193. Phone number: +27828765451, email address: casey.mccusker@nhls.ac.za (CJ McCusker)

Keywords:

Breast; breast tumour; adenomyoepithelioma; adenomyoepithelial carcinoma; malignant adenomyoepithelioma; malignant AME.

Conflict of interest:

None.

Financial disclosure:

This research did not receive any specific grant from funding agencies in the public, commercial or not-for-profit sectors.

2.2 Abstract

Adenomyoepitheliomas (AME) are rare tumours of the breast. Although they are benign, features such as local recurrence, malignant transformation and metastases are described. The objective is to report our findings on a case series of AME of the breast. A cross-sectional retrospective descriptive study was performed on cases with a diagnosis of AME. Clinical, radiological and histopathologic findings were studied. Seventeen cases were identified in 13 patients, with a median age of 50 years (34 to 79 years), in an 18 year time period from 2000 to 2018. The AMEs ranged in size from 1mm to 150mm. Intratumoural heterogeneity was evidenced by a combination of 2 and 3 low-power architectural patterns (solid, cystic, nodular) and high-power architectural patterns (papillary, pseudopapillary, trabecular, tubular), an admixture of subtypes (tubular, lobular and spindle cell) and myoepithelial cell phenotypes (spindle cell, plasmacytoid, epithelioid and clear cell). In summary, we present a case series of 17 cases of AME in which clinical features, radiological findings and histopathological features, including immunohistochemistry are detailed. Of note, we expand the size range and document unusual associations in 4 cases of lobular carcinoma in-situ (LCIS), necrotising granulomatous inflammation, clinical extension onto the chest wall and a rare case of AME with carcinoma (epithelial and myoepithelial carcinoma).

2.3 Manuscript

2.3.1. Introduction

Adenomyoepithelioma (AME) is a rare, benign biphasic tumour comprising epithelial-lined spaces surrounded by a proliferation of myoepithelial cells [1]. It was first described in the breast by Hamperl in 1970 who suggested the term AME [2]. The World Health Organisation (WHO) 2012 classifies AME of the breast as a benign epithelial-myoepithelial lesion. Malignancy may arise in an AME and the WHO further subtypes AME with carcinoma (malignant adenomyoepithelioma) according to the line of differentiation of the malignant component: luminal epithelium, myoepithelium or both (epithelial-myoepithelial carcinoma) [1]. The aim of this study is to report on a case series of AME of the breast and elucidate further characteristics of this tumour by documenting our cases of AME and comparing them to those in the literature, describing the variability in the histopathology and noting co-existing disease, including malignancy.

2.3.2 Materials and methods

2.3.2.1 Study design and study sample

A cross-sectional retrospective descriptive study took place at the Division of Anatomical Pathology of the School of Pathology at the University of the Witwatersrand, Johannesburg, South Africa. The study sample was obtained from the archives at the Charlotte Maxeke Johannesburg Academic Hospital (CMJAH) and Chris Hani Baragwanath Academic Hospital (CHBAH) and included cases from these hospitals as well as Helen Joseph Hospital, Tsepong Hospital, Kopanong Hospital and Pietersburg Hospital. Using Systematized Nomenclature of Medicine (SNOMED) codes of ‘myoepithelioma’ and ‘myoepithelial carcinoma’, as there were no SNOMED codes available for adenomyoepithelioma, a search for adenomyoepithelioma was undertaken in these search results and cases of AME of the breast from 2000 to 2018 were identified and retrieved.

2.3.2.2 Inclusion and exclusion criteria

Male and female patients, of any age, who had a histological diagnosis of AME of the breast, were included in the study. Cases with slides and/or paraffin embedded tissue blocks which were not retrievable were excluded.

2.3.2.3 Methods

Demographics (age at diagnosis, gender, laterality, type of specimen), clinical presentation (symptoms, episode and follow up if applicable) and radiological findings in terms of mammography (tumour location, margins and characteristics), ultrasound features and BI-RADS (Breast Imaging Reporting and Data System) score (1-5), were either recorded from the histopathology reports or from patient files, where possible. The available Haematoxylin and Eosin (H&E) and immunohistochemical stained slides of the cases were examined retrospectively by both investigators independently and then reviewed together. A positive immunohistochemical result was further assessed in terms of proportion and intensity (proportion was evaluated as 0 = no staining observed, 1 = 1-10%, 2 = 11-50% and 3=51-100% and intensity was evaluated as 1+ = weak, 2+ = moderate and 3+ = strong). A consensus opinion was sought if warranted. The diagnosis of AME and any concomitant pathology was reviewed critically in each case, and cases were classified histologically according to low- and high-power architectural patterns, histological subtype (as per the subtypes described to date in the literature), myoepithelial cell phenotype, tumour borders, presence or absence of increased mitotic count (defined in this study as more than 3 mitotic figures per 10 high power fields), cytologic atypia, adequacy of excision and any co-existing pathologies [1]. Permission to undertake this study was obtained from the Human Research Ethics Committee (Medical), Faculty of Health Sciences, University of the Witwatersrand in Johannesburg.

2.3.3. Results

2.3.3.1 Clinical features of AME

A total of 15 patients with a reported diagnosis of AME of the breast were identified, of which two (11%) were excluded as the review findings did not concur with the original diagnosis of AME. The final study cohort was 17 tumours in 13 patients, of which 12 had a single tumour and 1 had 5 separate and histologically distinct AMEs in the same breast. 15 tumours (88%) showed benign AME and 2 (11%) showed associated carcinoma (lobular carcinoma in-situ and AME with carcinoma. All patients were female, ranging in age from 34 to 79 years (median age, 50 years ; interquartile range, 27 years) (Fig. A.1) . The clinical, radiologic, histopathologic and immunohistochemical findings are provided in Table. A.1 and Table. A.2. A frequency table summarising certain aspects of the data is provided in Table. A.3. Furthermore, the size of the tumours (median size, 12mm ; interquartile range ,

23.25mm) and combination of histopathologic patterns present and combination of immunohistochemical markers are further qualified in Fig(s). A. 2-4, respectively.

2.3.3.2 Case reports

2.3.3.2.1 Case 3: colonisation of an AME by LCIS

- 37-year-old female.
- Right upper inner and outer quadrant breast mass.
- Needle core biopsy: lobular carcinoma in-situ.
- Mastectomy and axillary lymph node dissection: 25mm circumscribed, tan mass
- Histopathology: Fig. A.6a, AME with colonisation by extensive LCIS.
- Additional histopathologic findings: columnar cell change and atypical ductal hyperplasia.
- No invasive carcinoma or metastasis.

2.3.3.2.2 Case 4: co-existing *Mycobacterium tuberculosis* infection

- 35-year-old female, HIV-positive, pre-treatment, with pulmonary tuberculosis, on treatment for 3 months.
- Right breast nodule, 0.5cm x 0.5cm, non-tender.
- Right axillary lymphadenopathy, multiple matted lymph nodes.
- Lumpectomy and axillary lymph node dissection: Fibro-fatty breast parenchyma 12x10x7mm with no nodule macroscopically identified and lymph node 25x18x15mm with caseous necrosis on cut section.
- Histopathology: Fig. A.6b, AME in the breast and necrotising granulomatous inflammation in the lymph nodes, in keeping with *Mycobacterium tuberculosis* infection.

2.3.3.2.3 Case 5: late presentation of a large AME with chest wall extension

- 39-year-old female.
- Multinodular right breast mass with clinical extension below the inframammary fold onto the chest wall, Fig. A.5a.
- Needle core biopsy: benign proliferation of epithelial and myoepithelial cells, AME included in the differential diagnosis.
- Lost to follow-up for 4 years.
- Repeat needle core biopsy: benign neoplasm.
- Fine needle aspirate (FNA): cyst fluid with foam cells, no malignancy.
- Wide local excision: Fig. A.5b, 150mm, large, multinodular, cystic tumour with involvement of surface skin. On section, solid (firm, white, “cauliflower-like” areas) and cystic (serous and bloody fluid with clot) tumour with multiple satellite nodules.
- Microscopy: Fig. A.6c, AME with cystic degeneration. No malignancy.
- Margins involved by tumour.
- No invasive carcinoma or metastasis.
- Post-excision follow-up:
    - 1 year: mastalgia, mammogram planned. No report available.
    - 2 years: back pain localised to scapula, with pruritis and dyspnoea.
    - On examination, tenderness localised to the scar. Mammogram planned. No additional histologic specimens received.

2.3.3.2.4 Case 17: AME with carcinoma

- 69-year-old female.
- Left lower outer quadrant breast mass, BI-RADS 5.
- Needle core biopsy: invasive mammary carcinoma, triple negative molecular phenotype, metaplastic carcinoma was considered.
- Mastectomy and axillary lymph node dissection: 50mm well-circumscribed, cream-coloured tumour with surrounding haemorrhage and necrosis.
- Microscopy: Fig. A.6d, AME with carcinoma (malignant epithelial and myoepithelial components (epithelial-myoepithelial carcinoma) with residual, peripheral AME, confirmed on immunohistochemistry, Fig. A.7a-d.
- Additional histopathologic findings: intraductal papilloma, columnar cell change and atypical ductal hyperplasia.
- Margins uninvolved by tumour.

2.3.4 Discussion

In normal breast tissue and benign lesions, epithelial and myoepithelial components form the breast duct epithelium. Under neoplastic conditions, there is variation in the histologic appearance and immunophenotypic expression of myoepithelial cells, depending on whether the epithelial or myoid phenotype is expressed [2]. The combination of epithelial and myoepithelial cells can occur with considerable architectural and cytological heterogeneity within AMEs and poses diagnostic difficulty, which may be compounded by the limited representation of lesional tissue on a needle core biopsy [3, 4]. Immunohistochemical investigation is essential in order to correctly classify the lesion [4].

To the best of our knowledge, in the literature there are approximately 266 AME, 91 AME with carcinoma and 24 AME with other associated carcinoma (such as synchronous ductal carcinoma in-situ, invasvie carcinoma of no special type and invasive lobular carcinoma), the majority as individual case reports and 7 cases series (Table. A.4) [3, 5-10]. Forty-nine AME with carcinoma were reviewed and reclassified according to the WHO 2012 classification by Xu et al [11]. We contribute a large case series, of 15 AME and 2 AME with associated carcinoma, with 4 case reports highlighting noteworthy findings. Our case of AME with carcinoma can be classified according to the WHO 2012 as epithelial-myoepithelial carcinoma; this is the second most common subtype in 49 cases of malignant AME described in the literature [11].

AME typically presents as a solitary, palpable nodule of variable duration, measuring 3mm to 70mm, in mostly females aged 22-92 years (mean age of 59 years in the largest series) and our series concurs. We report 3 patients with unusual findings, including the largest and smallest AME [3, 4, 12]. Case 5, represents the largest benign AME to date, spanning a size of 150mm, with extension out of the anatomic confines of the breast and inferiorly onto the chest wall [4]. As the excision biopsy was performed 4 years following the initial diagnostic needle core biopsy, we postulate that it is due to delayed primary management that this AME reached a large size and infiltrated into adjacent structures; this underscores the worrisome behaviour sometimes encountered in AME. AME was an incidental finding in 2 patients who underwent bilateral breast reductions for macromastia, 1 having a single AME, measuring 1mm (the smallest in the literature to date), and the other having 5 completely separate benign AMEs in the same breast. Han and Peng address multicentric AME in a report of a patient with 1 benign AME, 1 atypical AME and 1 AME with DCIS in the same breast [13]. When comparing our case of AME with carcinoma (case 17) to those reviewed by Xu et al.,

our case, with a maximum diameter of 50mm is less than the maximum size of up to 170mm [11].

Radiological findings were available for 6 of 17 cases and are listed, along with the clinical findings, in Table. A.1. The mammogram and ultrasound images of the AME with carcinoma are present in Fig. A.5c and Fig. A.5d, respectively. The mammography and ultrasound findings of the remaining 5 AMEs with available imaging were consistent with what is described in the literature. Mammography reveals a dense, round to lobulated, often circumscribed (but sometimes ill-defined) mass, resembling a fibroadenoma, occasionally having a cystic appearance [4, 8, 14, 15]. Calcifications are regarded as a suspicious finding when seen on imaging, but are rare, and were not seen in our series [16]. Ultrasound reveals a round or oval, solid mass with a hypoechoic or complex echogenic texture and posterior or combined acoustic enhancement, which indicate the nature of the cellular composition of the tumour) [9, 12, 17, 18]. Two of our benign AME cases were accorded a BI-RADS score: one of 2 and the other of 4b. A BI-RADS 2 score correlates with benign findings and a BI-RADS 4b assessment is indeterminate, meaning radiologically, there were no 'suspicious for' or 'highly suggestive' of features of malignacy in our benign AMEs.

The well-described wide range in appearance of AME on low-power architecture (solid, cystic, nodular), high-power architecture (papillary, pseudopapillary, trabecular and tubular), variable morphologic subtypes (tubular, lobular and spindle) (summarised in Figure. A.3) and diverse appearance of the myoepithelial cells (spindle, clear cell, epithelioid, plasmacytoid) were present in our case series (Table. A.2) [4, 6, 12]. In our study, similar to the findings of Tavassoli, a preponderance of a tubular pattern was found [7]. Other pathologic features including focal metaplastic change, a sebaceous cell population, myxochondroid background and apocrine metaplasia were infrequent findings in our series. Foam cells were identified, a finding which has been described in FNA series, and in a single case report on histopathology of AME with squamous and sebaceous metaplasia [6, 8, 9, 13]. On microscopy, our AME with carcinoma is consistent with most cases in the series by Xu et al, showing cytological atypia in both epithelial and myoepithelial components, necrosis and a mitotic count of 10 per 10 high-power fields [11].

Regarding immunohistochemistry, a panel approach which confirms the dual phenotype of AME is advised [4]. Although none of our cases used the same combination of immunohistochemical stains, the presence of both components was confirmed (Table. A.2). The number of cases using a single and/or multiple epithelial and myoepithelial markers is

demonstrated in Figure. A.4. As described in the literature, staining of the epithelial cells with cytokeratin, epithelial lumen with EMA and staining of myoepithelial component with the following markers: p63, 34βE12, CK5/6, CK14, CD10 and actins (smooth muscle actin and muscle specific actin), highlights the tumour's biphasic nature. S100 may mark-both components [3, 4, 19]. Regarding the hormonal profile, oestrogen receptor and progesterone receptor may show weak, patchy positive staining and HER2 is negative. The Ki-67 proliferation index is moderate and is commonly higher in the myoepithelial component [1].

An association between AME and pulmonary *Mycobacterium tuberculosis* infection was made in a case report of bilateral AME in a young female patient, attributed to immunosuppression following treatment with Imatinib [20]. Case 4 illustrates an HIV positive female with an AME that presented as a breast nodule and lymphadenopathy. The clinical differential diagnosis of the latter included tuberculous lymphadenitis and lymphoma. Nodal tuberculosis was confirmed on histopathology and is attributed to the patient's immunosuppressed state.

Co-existing AME and phyllodes tumour is exceedingly rare: 1 case reports AME and benign phyllodes in the same tumour and 1 case reports separate malignant AME and malignant phyllodes in the same breast [9, 21]. Case 6 describes a patient who underwent re-excision of a benign phyllodes tumour, and the re-excision specimen showed an AME, along with multiple fibroadenomas.

Lobular neoplasia and AME have been infrequently documented [8, 22, 23]. Hayes listed a case of AME and lobular carcinoma in-situ (LCIS)/atypical lobular hyperplasia (ALH) in a case series, which to our knowledge is the only other case of co-existing AME and LCIS [9]. Zhang reported AME and co-existing ALH and provided diagnostic clues for accurate diagnosis with resultant management implications [22]. Our case (case 3) adds to the literature another AME with associated lobular neoplasia. Association with ductal carcinoma in-situ (DCIS) and invasive carcinoma of no special type is more frequently reported, however none of our cases showed either association [8, 9, 13, 24-26].

Axillary lymph node metastasis of both AME and AME with carcinoma, of either epithelial, myoepithelial or both components, has been described but was not documented in our series [6, 8, 27] however this is a limitation of our study as lymph nodes were submitted in 2 out of 17 (12%) cases. Distant metastasis of AME with carcinoma is by haematogenous spread and sites include lung, liver, bone, thyroid, kidney, thoracic wall and brain [11, 12].

Simple excision of most AME is curative and the recommended treatment of AME with carcinoma is wide local excision with adequate margins [6, 12]. Local recurrence has been reported and may be attributed to multinodular growth, intraductal extension of a lesion or incomplete excision [8]. Our study was limited by a lack of follow-up information and we would further benefit from this clinical correlation. As AME was present at margins in 2 cases, follow-up specifically with regards to recurrence would be valuable. The long-term follow-up for our patient of AME with carcinoma is still to be determined.

2.3.5. Conclusion

In summary, we present 17 cases of AME and emphasize the histological heterogeneity of AME, which may cause diagnostic confusion, and reiterate the value of an immunohistochemical panel including myoepithelial and epithelial markers in avoiding misdiagnosis.

2.3.6 Acknowledgements

Prof Mario Altini for assistance with initiating this report, Dr Pamela Michelow for reviewing the manuscript, Dr Sarah Nietz, consultant surgeon and Dr Jackie Smilg, consultant radiologist at the Breast Imaging Unit at CMJAH, histopathologists Dr Zama Mtshali (CMJAH) and Dr Aubrey Madliwa (Lancet Laboratories) for contributing the AME with carcinoma; histopathologist Dr Sugeshnee Pather (CHBAH) for the cases of AME contributed from this hospital, Mr Eric Liebenberg for assistance with the images and Fadila Ebrahim and Helen Nxumalo for assistance with retrieval of cases.

2.4 Lists of tables and figures

2.4.1 List of tables

Table. A.1: Adenomyoepithelioma, clinical (demographics and specimen details) and radiological (ultrasound, mammogram, and other, including BI-RADS) results

Table. A.2: Adenomyoepithelioma, histopathologic and immunohistochemical (epithelial and myoepthelial) findings

Table. A.3 Frequency table illustrating clinical, radiological and histopathologic findings

Table. A.4: Adenomyoepithelioma, a summary of the published case series of AME

Table. A.1. Adenomyoepithelioma, clinical (demographics and specimen details) and radiological (ultrasound, mammogram, and other, including BI-RADS) results.

Case	Age	Laterality	Specimen	Symptoms	Episode	Size (mm)	Mammogram	Ultrasound	Other
1	58	R	NCB;WLE	Mass	Initial	27	N	N	N/A
2	38	R	LPT	Mass	Initial	20	Lobulated, cystic	Cystic, hypoechoic	N/A
3	37	R	M + ALND	Unk	Initial	25	N	N	N/A
4	35	R	LPT + LNBx	Mass	Initial	12	N	N	N/A
5	39	R	NCB;WLE	Mass onto chest wall clinically	Initial	150	N	N	N/A
6	34	L	Re-excision	None	Prev bgn phyllodes	18	N	N	MRI: fibroadenomas
7	79	L	LPT	Mass	Initial	55	N	N	N/A
8	70	L	NCB	Mass	Initial	U	Lobulated	Solid	BI-RADS 2
9-13	54	L	BBR	Macromastia	Initial	4,1;2,3;5,8;5,5;3,4	N	N	N/A
14	36	L	LPT	Unk	Initial	20	N	N	N/A
15	45	R	BBR	Macromastia	Initial	0.6	N	N	N/A
16	58	R	NCB	Mass, mastalgia	Initial	27	Lobulated	Lobulated,irreg marg, PAS	BI-RADS 4b
17	69	L	NCB;M+ALND	Mass	Initial	50	Ill-def marg, bgn calcs	Irreg solid and cystic	BI-RADS 5

Abbreviations: R: right; Unk: unknown; L: left; NCB: needle core biopsy; WLE: wide local excision; LPT: lumpectomy; M + ALND: mastectomy and axillary lymph node dissection; LNBx: lymph node biopsy; BBR: bilateral breast reduction; Prev: previous; bgn:benign; N: no report available; Ill-def: ill-defined; calcs: calcifications; Irreg: irregular; marg: margins; PAS: posterior acoustic shadowing; N/A: not applicable

Table. A.2. Adenomyoepithelioma, histopathologic and immunohistochemical (epithelial and myoepthelial) findings.

Case	LP Arch	HP Arch	Subtype	Border	Myoepithelial phenotype	Margins	MF	Other features / Co-existing pathology	Immunohistochemistry*
1	So, Cy, No	Pp	Sp	Infilt	Sp, Epith	Ex	0	Seb C, FC, AM / UDH	Ep: AE1/3 +3/3; My: p63 +1/3, s100 +3/3, MSA +2/2, SMA +3/3
2	No	Tu	Tu	Infilt	Sp, Epith, CC	At	1	PC / None	Ep: AE1/3 +3/3; My: p63 +3/2, s100 +3/3, SMA +3/3, CD10 +3/3
3	So, No	Tu, Trab	Tu	Push	Sp	Ex	0	None /LCIS, CCC, ADH	Ep: AE1/3 +3/3; My: SMA +3/3, CD10 +3/2, GFAP +3/3
4	No,	Tu, Trab	Sp	Push	Sp	Ex	0	None / MTB	None
5	So, Cy, No	Pap, Pp ,Tu	Tu, Lo	Push	Sp, CC	At	1	Infarction / None	Ep: MNF116 +3/3, Cam5.2 +3/3; My: p63 +3/2, SMA +3/3, CK5/6 +3/2, H-cal +2/3
6	Cy, No	Pp	Tu	Push	Sp, Epith	Ex	5	AM / FA, PT	Ep: none; My: p63 +3/3, s100 +3/3, CD10 +3/3.
7	So, No	Trab	Sp	Push	Sp, Epith,	At	0	Myxchndr / None	Ep: EMA +2/2, CEA +1/3; My: s100 +2/3, MSA +1/3, SMA +1/3
8	So	Trab	Tu	Unk	Epith, CC	N/A	0	None / None	Ep: EMA +3/3; My: s100 +3/3; MSA +1/2
9	So, No	Tu	Tu	Push	Sp, Epith	Ex	1	None / IDP, CS	Ep: none; My: p63 +3/3, s100 +3/3, MSA +3/3; SMA +3/3
10	No	Tu	Tu, Lo	Infilt	Sp	Ex	0	FC, AM / FA	None
11	So, No	Tu	Tu	Infilt	Sp, Epith	Ex	0	FC, AM, DC / None	None
12	No	Tu	Tu, Lo	Push	Sp	Ex	0	FC, AM / None	None
13	So, No	Pp	Tu	Infilt	Sp	Ex	0	FC, AM, DC / None	None
14	So, Cy, No	Pp, Tu	Sp, Tu	Push	Sp, CC	Ex	2	PC / None	None
15	No	Tu	Tu	Push	Sp	Ex	2	None / None	Ep: none; My: None
16	No	Tu	Tu	N/A	Sp	N/A	0	FC / CS	Ep: none; My: p63 +3/3, CK5/6 +3/3
17	No	Tu	Sp, Tu, Lo	Push	Sp, Epith, CC	Ex	10	Malignancy /CCC,ADH	Ep:AE1/3 +3/3, EMA +2/2; My: p63 +3/3, s100 +3/3, SMA +3/3, CD10 +3/3

Abbreviations: LP arch: low-power architecture; HP arch: high-power architecture; MF: mitotic figures/10 high-power field; So: solid; Cy: cystic; No: nodular; Pap: papillary; Pp: pseudopapillary, Tu: tubular; Trab: trabecular; Sp: spindle; Lo: lobular; Infilt: infiltrating; Push: pushing; Unk: unknown; N/A: not applicable; Epith: epithelioid; CC: clear cell; Ex: excised; Seb C: sebaceous cells; FC: foam cells; AM: apocrine metaplasia; PC: psamommatous calcification; LCIS: lobular carcinoma in situ; CCC: columnar cell change; ADH: atypical duct hyperplasia; MTB: mycobacterial infection; FA: fibroadenoma; PT: phyllodes tumour; Myxchndr: myxochondroid; IDP: intraductal papilloma; CS: collegenous spherulosis; DC: dystrophic calcification; Ep: epithelial markers; My: myoepithelial markers; +: positive; *quantification of positive immunohistochemical result: proportion (0 = none, 1 = 1-10%, 2 = 11-50%, 3 = >50%) / intensity (0 = none, 1 = weak, 2 = moderate, 3 = strong).

Table. A.3 Frequency table illustrating clinical, radiological and histopathologic findings

	Frequency	Percentage		Frequency	Percentage
Laterality	n=17		**Margins**	n=17	
Right	7	42	Excised	12	71
Left	10	59	At margins	3	18
Symptoms	n = 13		N/A	2	12
Mass	8	62	**Mitotic figures**	n=17	
Unknown	2	15	0-2	15	88
Macromastia	2	15	5	1	6
Mastalgia	1	8	10	1	6
Asymptomatic	1	8	**Other features**	n=17	
Mammogram findings	n=13		Absent	5	29
No report available	9	69	Present	12	70
Lobulated/cystic	1	8	Malignancy	1	6
Lobulated	2	15	**Co-existing pathology**	n=17	
Ill-defined	1	8	Absent	9	53
Ultrasound	n=13		Present	8	47
No report available	9	69	**Immunohistochemistry**	n=10	%
Cystic, solid	1	8	None	7	70
Cystic, hypoechoic	1	8	AE1/AE3	4	40
Lobulated	1	8	CAM 5.2	1	10
Irregular margins	2	15	MNF116	1	10
Posterior acoustic shadowing	1	8	EMA	3	30
Low power architecture	n=17		CEA	1	10
Single pattern	8	47	SMA	7	70
2-patterns	6	35	MSA	5	50
3-patterns	3	18	CD10	4	40
High power architecture	n=17		p63	7	70
Single pattern	13	76	GFAP	1	10
2-patterns	3	18	CK5/6	2	20
3-patterns	1	6	H-caldesmon	1	10
			S100	7	70

Table. A.4. Adenomyoepithelioma, a summary of the published case series of AME.

Case series	Author	Year	Total number	Total number of AME	Recurrent	Malignant	Metastasis
1	Rosen et al [5]	1987	18	18	2	0	0
2	Decorsiere et al [6]	1988	U	17	U	U	U
3	Tavassoli [7]	1991	31	27	2	2	1
4	Loose et al [8]	1992	6	6	3	2	1
5	McClaren et al [3]	2005	35	23	0*	0	0
6	Hayes [9]	2011	25	12	2	13	4
7	Moritz [10]	2016	14	10	0	4	ND

Abbreviations: U, unknown; ND, not documented

*Only 12 of the 23 patients were followed up

2.4.2 List of figures with captions

Fig. A.1 Histogram showing age distribution as number of cases per 5 year age groups in 13 patients with AME

Fig. A.2 Histogram showing size of AME in each case Fig. A.3 Histologic subtypes of AME with single, 2- and 3-patterns

Fig. A.4 Use of single or multiple epithelial and myoepithelial immunohistochemical (IHC) stains in cases where IHC was performed

Fig. A.5. Clinical, macroscopic and radiological images of selected cases

a. Photograph of a right breast mass with clinical extension onto the chest wall 4 years following needle core biopsy (case 7).
b. Macroscopic photograph of the largest AME in our series, demonstrating solid and cystic components (case 7) of the tumour.
c. Mammogram image of AME with carcinoma (case 17), showing a mass with ill-defined margins and calcifications, BI-RADS 5.
d. Ultrasound image of AME with carcinoma (case 17), showing an irregular solid and cystic mass.

Fig. A.6. Histopathologic photomicrographs of selected cases

a. Photomicrograph showing AME with colonisation of lobules by LCIS (case 3), haematoxylin and eosin (H&E) stain, original magnification x100.
b. Photomicrograph of nodal tuberculosis in a patient with AME (case 4), H&E stain x20.
c. Photomicrograph of largest AME with cystic and papillary areas (case 7), H&E stain x20.
d. Photomicrograph of AME with carcinoma, showing malignant epithelial and myoepithelial components and extensive tumour necrosis (case 17), H&E stain x40.

Fig. A.7. Immunohistochemical photomicrographs of selected cases

Photomicrograph of AME with carcinoma, immunohistochemical stains (case 17), original magnification x100:

a. AE1/3, showing strong-intensity positive cytoplasmic staining of the epithelial component and weak-intensity positive cytoplasmic staining of the myoepithelial component.
b. SMA, showing negative staining of the epithelial component and strong-intensity positive cytoplasmic staining of the myoepithelial component.
c. S100, showing , showing weak positive cytoplasmic staining (interpreted as negative) and strong-intensity positive cytoplasmic and nuclear staining of the myoepithelial component.
d. p63, showing negative staining of the epithelial component and strong-intensity positive nuclear staining of the myoepithelial component.

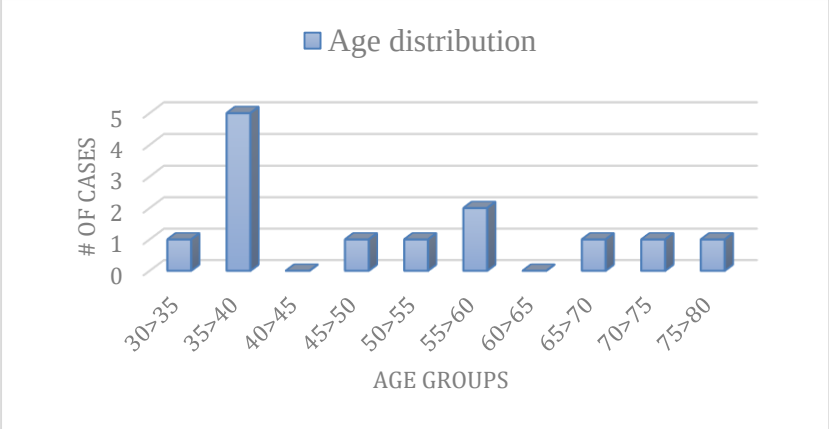

Fig. A.1 Histogram showing age distribution as number of cases per 5 year age groups in 13 patients with AME

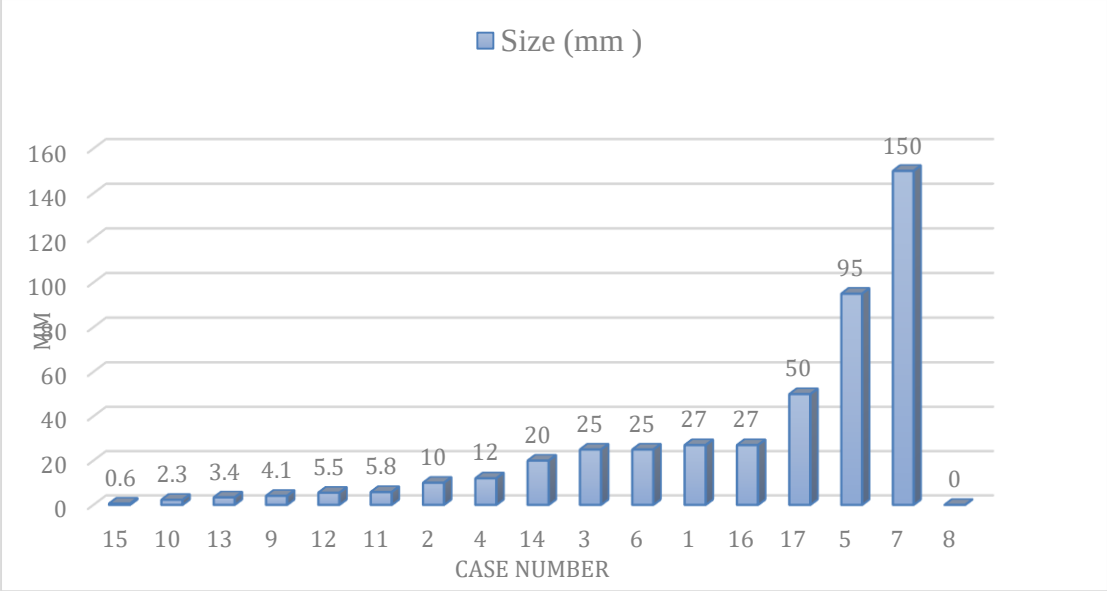

Fig. A.2 Histogram showing size of AME in each case

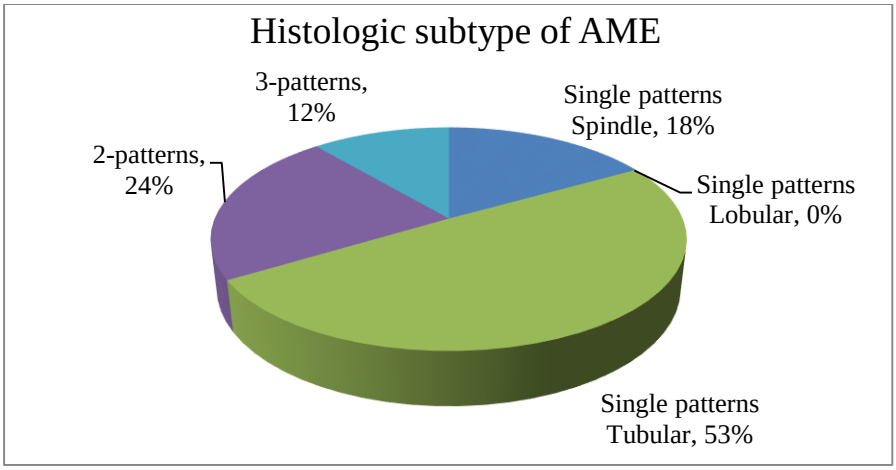

Fig. A.3 Histologic subtypes of AME with single, 2- and 3-patterns

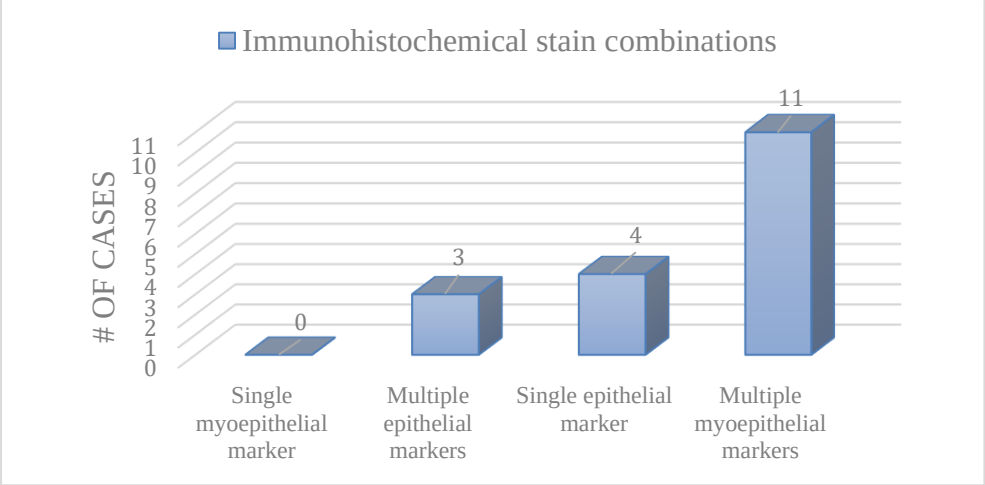

Fig. A.4 Use of single or multiple epithelial and myoepithelial immunohistochemical (IHC) stains in cases where IHC was performed

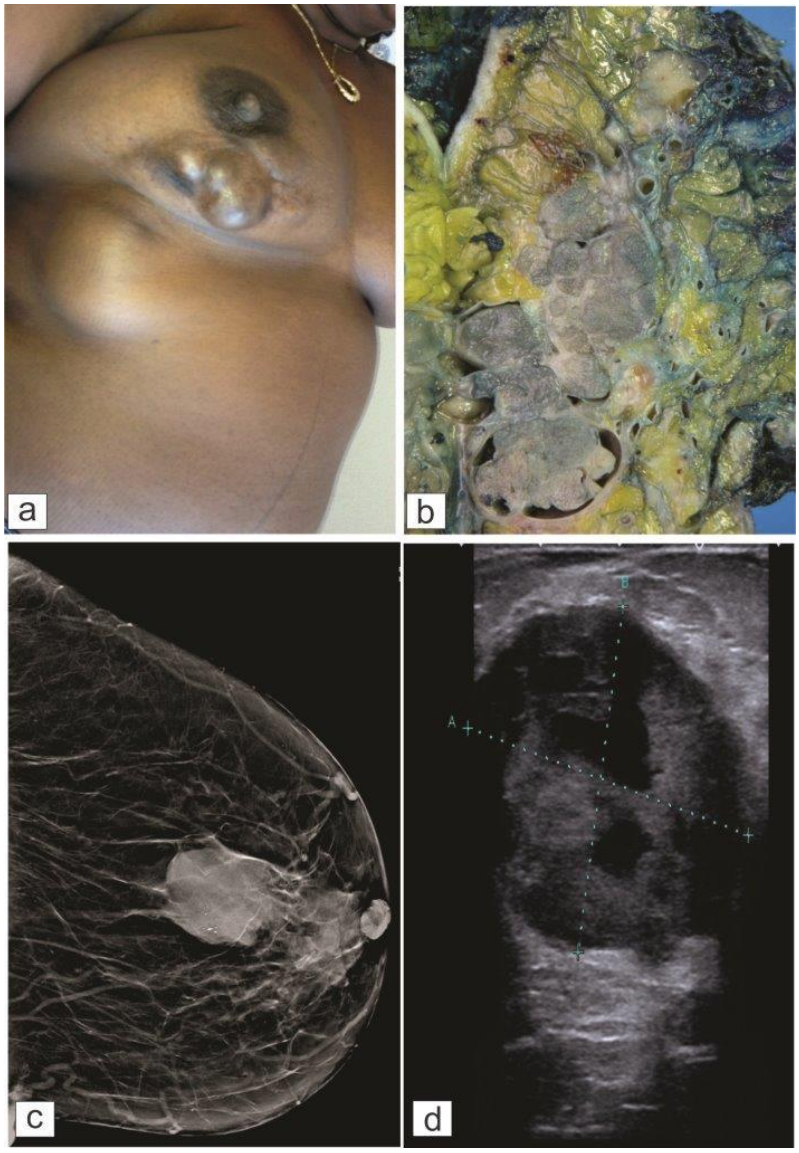

Fig. A.5 Clinical, macroscopic and radiological imgaes of selected cases

a. Photograph of a right breast mass with clinical extension onto the chest wall 4 years following needle core biopsy (case 5).
b. Macroscopic photograph of the largest AME in our series, demonstrating solid (papillary-like) and cystic components (case 5) of the tumour.
c. Mammogram image of AME with carcinoma (case 17), showing a mass with ill-defined margins and calcifications, BI-RADS 5.
d. Ultrasound image of AME with carcinoma (case 17), showing an irregular solid and cystic mass.

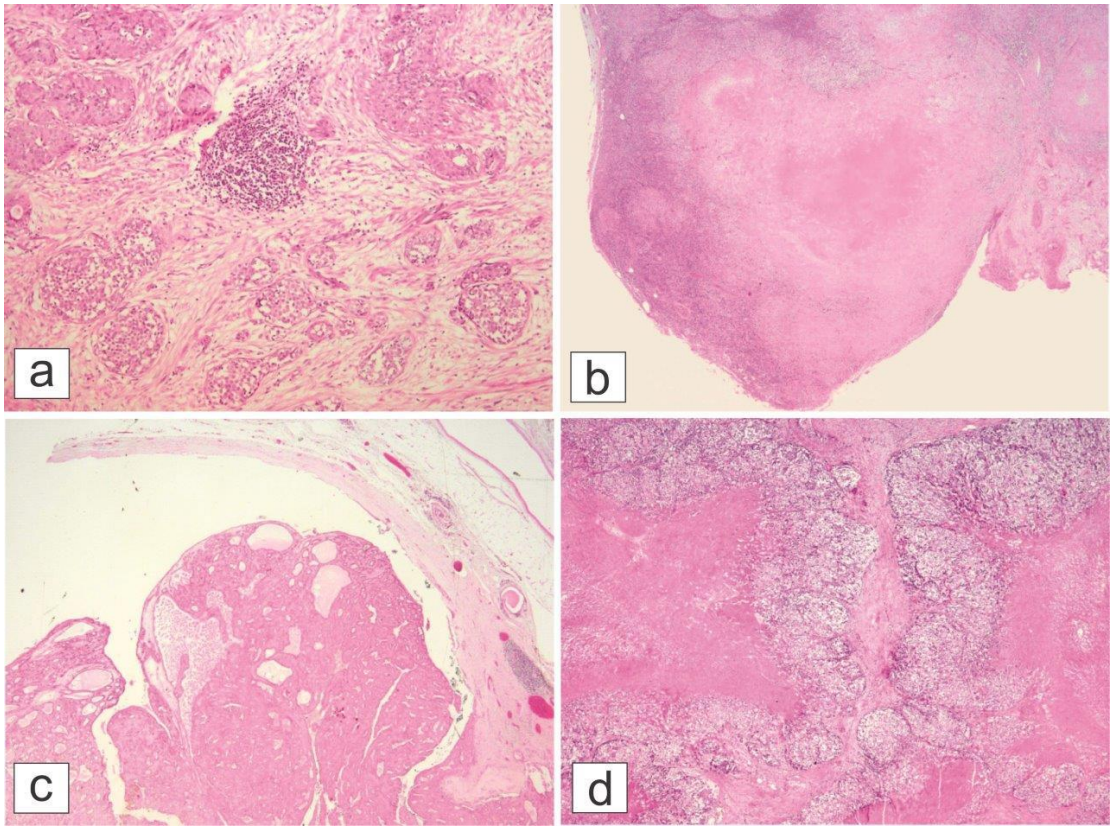

Fig. A.6 Histopathologic photomicrographs of selected cases

a. Photomicrograph showing AME with colonisation of lobules by LCIS (case 3), haematoxylin and eosin (H&E) stain, original magnification x100.
b. Photomicrograph of nodal tuberculosis in a patient with AME (case 4), H&E stain x20.
c. Photomicrograph of largest AME with cystic and papillary areas (case 5), H&E stain x20.
d. Photomicrograph of AME with carcinoma, showing malignant epithelial and myoepithelial components and extensive tumour necrosis, (case 17), H&E stain x40.

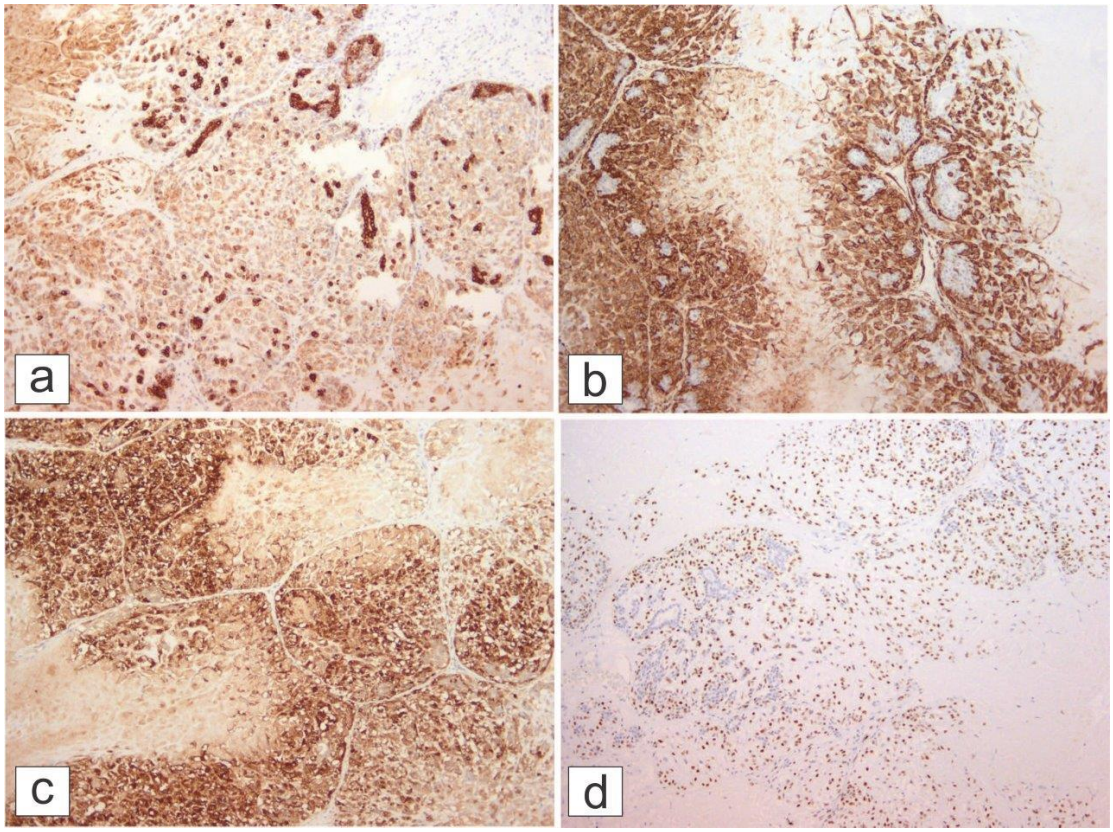

Fig. A.7 Immunohistochemical photomicrographs of selected cases

Photomicrograph of AME with carcinoma, immunohistochemical stains (case 17), original magnification x100:

a. AE1/3, showing positive strong-intensity positive cytoplasmic staining of the epithelial component and weak-intensity positive cytoplasmic staining of the myoepithelial component.
b. SMA, showing negative staining of the epithelial component and strong-intensity positive cytoplasmic staining of the myoepithelial component.
c. S100, showing , showing weak positive cytoplasmic staining and negative nuclear staining of the epithelial component (interpreted as negative) and strong-intensity positive cytoplasmic and nuclear staining of the myoepithelial component.
d. p63, showing negative staining of the epithelial component and strong-intensity positive nuclear staining of the myoepithelial component

2.5 References

1. Schmidt F, Tan PH, Dabbs D, Jones L. Myoepithelial and epithelial-myoepithelial lesions. In: Lakhani SR, Ellis IO, Schnitt SJ, Hoon J, and van de Vijver MJ, editors. WHO Classification of Tumours of the Breast, Lyon: IARC; 2012, p. 120-123.
2. Hamperl H. The myothelia (myoepithelial cells): Normal state; regressive changes; hyperplasia; tumors. Curr Top Pathol 1970;53:161-220. https://doi.org/10.1007/978-3-662-30514-0_3
3. McLaren BK, Smith J, Schuyler PA, Dupont WD, Page DL. Adenomyoepithelioma: clinical, histologic, and immunohistologic evaluation of a series of related lesions. Am J Surg Pathol 2005;29:1294-9.
4. Yoon JY, Chitale D. Adenomyoepithelioma of the breast: a brief diagnostic review. Arch Pathol Lab Med 2013;137:725-9. https://doi.org/10.5858/arpa.2011-0404-RS
5. Rosen PP. Adenomyoepithelioma of the breast. Hum Pathol 1987;18:1232-7.
6. Decorsiere JB, Thibaut I, Bouissou H. Adeno-myoepithelial proliferation in the breast. Ann Pathol 1988;8:311-6.
7. Tavassoli FA. Myoepithelial lesions of the breast. Myoepitheliosis, adenomyoepithelioma, and myoepithelial carcinoma. Am J Surg Pathol 1991;15: 554-68.
8. Loose JH, Patchefsky AS, Hollander IJ, Lavin LS, Cooper HS, Katz SM. Adenomyoepithelioma of the breast. A spectrum of biologic behavior. Am J Surg Pathol 1992;16:868-76.
9. Hayes MM. Adenomyoepithelioma of the breast: a review stressing its propensity for malignant transformation. J Clin Pathol 2011;64:477-84. https://doi.org/10.1136/jcp.2010.087718
10. Moritz AW, Wiedenhoefer JF, Profit AP, Jagirdar J. Breast adenomyoepithelioma and adenomyoepithelioma with carcinoma (malignant adenomyoepithelioma) with associated breast malignancies: A case series emphasizing histologic, radiologic, and clinical correlation. Breast 2016;29:132-9. https://doi.org/10.1016/j.breast.2016.07.018
11. Xu J, Tang X, Iida Y,et al. Adenomyoepithelioma with carcinoma of the breast: A report of two cases and a review of the literature. Pathol Res Pract 2016;212:130-

4. https://doi.org/10.1016/j.prp.2015.09.008
12. Brogi E. Myoepithelial neoplasms. In: Hoda SA, Brogi E, Koerner FC, Rosen PP, editors. Rosen's Breast Pathology, Philadelphia: Wolters Kluwer; 2014, p. 153-174.
13. Han JS, Peng Y. Multicentric adenomyoepithelioma of the breast with atypia and associated ductal carcinoma in situ. Breast J 2010;16:547-9. https://doi.org/10.1111/j.1524-4741.2010.00954.x
14. Trojani M, Guiu, M, Trouette H, De Mascarel I, Cocquet M. Malignant adenomyoepithelioma of the breast. An immunohistochemical, cytophotometric, and ultrastructural study of a case with lung metastases. Am J Clin Pathol 1992; 98:598-602.
15. Laforga JB, Aranda FI, Sevilla F. Adenomyoepithelioma of the breast: report of two cases with prominent cystic changes and intranuclear inclusions. Diagn Cytopathol 1998;19:55-8. https://doi.org/10.1002/(SICI)1097-0339(199807)19:1<55::AID-DC11>3.0.CO;2-7
16. Ruiz-Delgado ML, Lopez-Ruiz JA, Eizaguirre B, Saiz A, Astigarraga E, Fernandez-Temprano Z. Benign adenomyoepithelioma of the breast: imaging findings mimicking malignancy and histopathological features. Acta Radiol 2007;48:27-9. https://doi.org/10.1080/02841850601080432
17. Adejolu M, Wu Y, Santiago L, Yang WT. Adenomyoepithelial tumors of the breast: imaging findings with histopathologic correlation. AJR Am J Roentgenol 2011;197:W184-90. https://doi.org/10.2214/ajr.10.6064
18. Lee WY. Fine needle aspiration cytology of adenomyoepithelioma of the breast: a case indistinguishable from phyllodes tumor in cytologic findings and clinical behavior. Acta Cytol 2000;44:488-90.
19. Tan PH, Ellis IO. Myoepithelial and epithelial-myoepithelial, mesenchymal and fibroepithelial breast lesions: updates from the WHO Classification of Tumours of the Breast 2012. J Clin Pathol 2013;66:465-70. https://doi.org/10.1136/jclinpath-2012-201078
20. Bajpai J, Punatar SB, Gupta A, Badwe R, Gupta S. Bilateral adenomyoepithelioma of breast. J Cancer Res Ther 2013;9:523-5. https://doi.org/10.4103/0973-1482.119370
21. Buch A, Rout P, Makhija P. Adenomyoepithelioma with phyllodes tumor--a rare

combination in a solitary breast lump. Indian J Pathol Microbiol 2006;49:259-61.

22. Zhang S, Huo L, Arribas E, Middleton LP. Adenomyoepithelioma of the breast with associated atypical lobular hyperplasia: a previously unrecognized association with management implications. Ann Diagn Pathol 2015;19:20-3. https://doi.org/10.1016/j.anndiagpath.2014.11.002
23. Honda Y, Iyama K. Malignant adenomyoepithelioma of the breast combined with invasive lobular carcinoma. Pathol Int 2009;59:179-84. https://doi.org/10.1111/j.1440-1827.2009.02347.x
24. Kamei M, Daa T, Miyawaki M, Suehiro S, Sugio K. Adenomyoepithelioma of the breast coexisting with ductal carcinoma in situ: a case report and review of the literature. Surg Case Rep 2015;1:81. https://doi.org/10.1186/s40792-015-0083-8
25. Warrier S, Hwang S, Ghaly M, Matthews A. Adenomyoepithelioma with ductal carcinoma in situ: a case report and review of the literature. Case Rep Surg 2013;2013:521417. https://doi.org/10.1155/2013/521417
26. Kuroda N, Fujishima N, Ohara M, et al. Coexistent adenomyoepithelioma and invasive ductal carcinoma of the breast: presentation as separate tumors. Med Mol Morphol 2008;41:238-42. https://doi.org/10.1007/s00795-008-0376-0
27. Nadelman CM, Leslie KO, Fishbein MC. “Benign," metastasizing adenomyoepithelioma of the breast: a report of 2 cases. Arch Pathol Lab Med 2006;130:1349-53. https://doi.org/10.1043/1543-2165(2006)130[1349:bmaotb]2.0.co;2

Section 3: Appendices

3.1 Ethics approval

R14/49 Dr Casey Julia McCusker and Dr Sarah Rayne

HUMAN RESEARCH ETHICS COMMITTEE (MEDICAL)

CLEARANCE CERTIFICATE NO. M170291

NAME: (Principal Investigator)	Dr Casey Julia McCusker and Dr Sarah Rayne
DEPARTMENT:	Anatomical Pathology Faculty of Health Sciences University of the Witwatersrand Medical School
PROJECT TITLE:	Adenomyoepithelioma of the Breast: Case Series
DATE CONSIDERED:	Adhoc
DECISION:	Approved unconditionally
CONDITIONS:	Sub-Study (M150884)
SUPERVISOR:	Dr Kirstin Janine Fearnhead
APPROVED BY:	Professor P. Cleaton-Jones,Chairperson, HREC (Medical)
DATE OF APPROVAL:	10/03/2017

This clearance certificate is valid for 5 years from date of approval. Extension may be applied for.

3.2 Ethics amendment approval letter

Division of Anatomical Pathology

3rd Floor

Faculty of Health Sciences

University of the Witwatersrand

7 York Road, Parktown

2193

28 February 2018

Dear Professor Cleaton-Jones,

I wish to amend my MMed protocol as follows, pertaining to methods (section 4):

A. 4.6 In addition, a review of patient's clinical files will be undertaken, where possible.
B. 4.3 Time period : year of study extended from March 2016 to March 2017.

Please find attached an updated version of my protocol. This does not affect my research tools, however the data sheet has been included for completeness sake. In addition, please find prior letter of approval/ethics clearance.

Kind regards,



Casey McCusker

Registrar, Anatomical Pathology, NHLS/WITS

3.3 Postgraduate assessor group approval

University of the Witwatersrand

UNIVERSITY OF THE WITWATERSRAND, JOHANNESBURG
FACULTY OF HEALTH SCIENCES
ASSESSORS MEETING

1585560

CANDIDATE: C. McCusker

Date of Assessor Group Meeting: 14th Sept. 2016 School / Department / Division: Pathology

(Yes) No Is the research question clearly identified and described?

Comments:

(Yes) No Not entirely

Is the design of the study and methods the methods used appropriate for the research question being asked?

Comments:
- ~~Aims~~ 11 cases have already been identified
- check typos
- put sub-headings in Introduction
- Submit others

Is the study feasible within:

i. the applicant's resources? (Yes) No

ii. the departments resources? (Yes) No

iii. the time frame? (Yes) No

3.4 Postgraduate assessor group approval corrections

4 October 2016

Dear Drs Fearnhead and Rayne,

RE : AMENDMENTS TO MMED (ANAT PATH) RESEARCH PROTOCOL FOLLOWING SCHOOL OF PATHOLOGY ASSESSORS MEETING

The following amendments were made to my MMed (ANAT PATH) Research Protocol following the assessors meeting on 14/09/2016:

1. Spelling errors:

   i. immunphenotypic amended to immunophenotypic
   Page 2, 2nd paragraph, line

   ii. myopeithelial amended to myoepithelial
   Page 3, last paragraph, 3rd line

   iii. epithelial-myoepithelail amended to epithelial-myoepithelial
   Page 9 , Reference 1

2. Headings added to the introduction, as follows:

   i. a) Clinical presentation
   Page 3, 3rd paragraph

   ii. b) Radiologic features
   Page 3, 4rd paragraph

   iii. c) Gross pathologic features
   Page 3, 3rd paragraph

   iv. d) Microscopic pathologic features

   Page 4, 1st paragraph

v. e) Immunohistochemistry

Page 5, 1st paragraph

vi. f) Differential diagnosis

Page 5, 5th paragraph

vii. g) Biologic behaviour and treatment

Page 6, 2nd paragraph

viii. h) Molecular characteristics

Page 6, 5th paragraph

I trust that these amendments are to your satisfaction and in keeping with the suggestions made by the assessors group.

Kind regards,



Casey McCusker

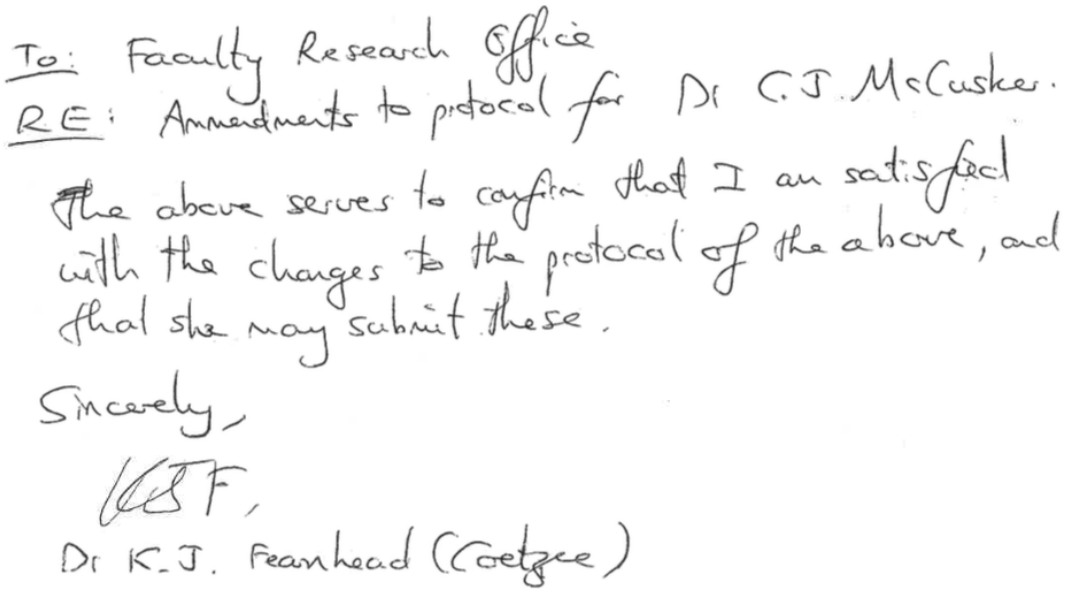

3.5 Appointment of supervisors

Postgraduate Office, Faculty of Health Sciences
Wits Medical School, 7 York Road, PARKTOWN, 2193, Johannesburg • Tel: (011) 717 2000 • Fax: (011) 717 2119

APPOINTMENT OF SUPERVISOR/S OF RESEARCH REPORT, DISSERTATION OR THESIS

Motivation / Reason for Appointment:

Both Drs Fearnhead and Rayne, a histopathologist and specialised breast surgeon respectively, have MMeds in their fields. They also both have a special interest and expertise in breast tumours. I have the utmost confidence that they will fulfil the role of Supervisor as expected by the Faculty.

Recommendation of Division / Department / School:

Dr Fearnhead: Division of Anatomical Pathology, School of Pathology, Faculty of Helath Sciences, Wits Medical School, University of the Witwatersrand

Dr Rayne : Department of Surgery, Faculty of Health Sciences, Wits Medical School, University of the Witwatersrand.

Student Surname and Initials: McCusker, C.J. Student Number: 1585560

Degree: MMed (Anat Path) Div / Dept / School: Division of Anatomical Pathology

Title: Adenomyoepithelioma of the breast: a case series.

Supervisor 1:	Dr Kirstin Janine Fearnhead (neé Coetzee)	
Supervisor Qualifications:	MBChB (UCT), FCPath SA(Anat), MMed (Anat Path)	
Supervisor Department:	Division of Anatomical Pathology	
Supervisor Telephone:	(011) 489 8491	E-mail: kirstin.coetzee@nhls.ac.za
Supervisor 2:	Dr Sarah Rayne	
Supervisor Qualifications:	BSc MBChB MRCS(Eng) MMed FCS(SA)	
Supervisor Department:	Department of Surgery	
Supervisor Telephone:	072 776 8553	E-mail: rayne.sarah@gmail.com

Student Signature: _____ **Supervisor 1** Signature: _____

Supervisor 2 Signature: _____

RECOMMENDATION BY HEAD OF ~~DIVISION~~ / DEPARTMENT / ~~SCHOOL~~:

HALE MJ (Surname and Initials) _____ (Signature) 14/9/2016 (Date)

APPROVAL BY ASSESSOR GROUP:

(On behalf of the FGSC) _____ (Signature) 14/9/2016 (Date)

FOR CIRCULATION TO THE FGSC

3.6 Addition of supervisor

UNIVERSITY OF THE WITWATERSRAND, JOHANNESBURG

Private Bag 3 Wits, 2050
Fax: 027117172119
Tel: 02711 7172076

Reference: Mrs Sandra Benn
E-mail: sandra.benn@wits.ac.za

14 August 2018
Person No: 1585560
SAC

Dr CJ McCusker
P.o Box 905-1072
Garsfontein
0042
South Africa

Dear Dr McCusker

Master of Medicine: Change of Supervisor

I would like to inform you that there has been a change in your supervision arrangements. *Kirstin Coetzee, Sarah Rayne, Pamela Michelow* will now be supervising you.

Please maintain regular contact with your Supervisor(s).

Yours sincerely

Mrs Sandra Benn
Faculty Registrar
Faculty of Health Sciences

3.7 Turn-it-in similarity report

turnitin

Digital Receipt

This receipt acknowledges that Turnitin received your paper. Below you will find the receipt information regarding your submission.

The first page of your submissions is displayed below.

Submission author:	Casey McCusker
Assignment title:	McCusker Casey(1585560)
Submission title:	1585560:MMed_article_for_turn_it_..
File name:	81e-80d3-49c6-b37c-4be246c3ed...
File size:	3M
Page count:	24
Word count:	4,579
Character count:	28,481
Submission date:	26-Sep-2018 03:13PM (UTC+0200)
Submission ID:	1008734340



Section 2: Draft article to Human Pathology, submission for original contribution:

2.1 Title page

Title:

Adenomyoepithelioma of the breast, a single-institution study of 17 cases.

Authors:

Dr. Casey Julia McCusker (MBChB)[a], Dr. Kirstin Janine Fearnhead (MBChB, FCPath (Anat), MMed)[a] and Prof. Sarah Louise Rayne (BSc, MBChB, MRCS, MMed, FCS)[b]

[a]Division of Anatomical Pathology, School of Pathology, Faculty of Health Sciences, University of the Witwatersrand / National Health Laboratory Service, 7 York Road, Johannesburg, South Africa, 2193

[b]Helen Joseph Breast Care Clinic, Netcare Breast Care Centre, Department of Surgery, Faculty of Health Sciences, University of the Witwatersrand, Johannesburg, South Africa, 2193

Corresponding author at :

Division of Anatomical Pathology, School of Pathology, Faculty of Health Sciences, University of the Witwatersrand / National Health Laboratory Service, 7 York Road, Johannesburg, South Africa, 2193. Phone number: +2782876451, email address: casey.mccusker@nhls.ac.za (CJ McCusker)

Keywords:

Breast; breast tumour; adenomyoepithelioma; adenomyoepithelial carcinoma; malignant adenomyoepithelioma; malignant AME.

Conflict of interest:

None.

Financial disclosure:

Copyright 2018 Turnitin. All rights reserved.

1585560:MMed_article_for_turn_it_in.docx

ORIGINALITY REPORT

9%	6%	8%	2%
SIMILARITY INDEX	INTERNET SOURCES	PUBLICATIONS	STUDENT PAPERS

PRIMARY SOURCES

1	www.ncbi.nlm.nih.gov Internet Source	1%
2	paduaresearch.cab.unipd.it Internet Source	<1%
3	Gail Faller. "Polyarteritis nodosa presenting with a leg mass", Acta Paediatrica, 12/1/2005 Publication	<1%
4	Puay Hoon Tan, Aysegul A. Sahin. "Atlas of Differential Diagnosis in Breast Pathology", Springer Nature, 2017 Publication	<1%
5	journals.sagepub.com Internet Source	<1%
6	"A Comprehensive Guide to Core Needle Biopsies of the Breast", Springer Nature, 2016 Publication	<1%
7	"Poster Presentations", Histopathology, 09/28/2010 Publication	<1%
8	Histopathology of the Salivary Glands, 2014. Publication	<1%
9	"Contrast-Enhanced Digital Mammography (CEDM)", Springer Nature America, Inc, 2018 Publication	<1%
10	Brendan Bebington, Elvira Singh, June Fabian, Christine Jan Kruger et al. "Design and methodology of a study on colorectal cancer in Johannesburg, South Africa", JGH Open, 2018 Publication	<1%
11	issuu.com Internet Source	<1%
12	www.bioline.org.br Internet Source	<1%
13	www.wjso.com Internet Source	<1%
14	www.archivesofpathology.org.pinnacle.allenpress.com Internet Source	<1%
15	"Soft Tissue Tumour Pathology", Histopathology, 2012. Publication	<1%
16	Ja Seung Koo. "Xanthogranulomatous mastitis: Clinicopathology and pathological implications", Pathology International, 04/2009 Publication	<1%
17	print.ispub.com Internet Source	<1%
18	www.ajronline.org Internet Source	<1%
19	journal.publications.chestnet.org Internet Source	<1%
20	jme.endocrinology-journals.org Internet Source	<1%
21	www.breast-cancer-research.com Internet Source	<1%
22	www.ajcp.com Internet Source	<1%
23	"Neuroendocrine Tumors: Review of Pathology, Molecular and Therapeutic Advances", Springer Nature, 2016 Publication	<1%
24	surgicalcasereports.springeropen.com Internet Source	<1%
25	www.science.gov Internet Source	<1%
26	Anthony W H Chan. "Renal myxoid tumour of uncertain malignant potential :", Pathology, 04/2011 Publication	<1%
27	lsdis.cs.uga.edu Internet Source	<1%
28	"Dermatopathology", Laboratory Investigation, 02/2011 Publication	<1%
29	E Mumba. "Human papillomaviruses do not play an aetiological role in Mullerian adenosarcomas of the uterine cervix", Journal of Clinical Pathology, 09/01/2008 Publication	<1%

Exclude quotes	On	Exclude matches	Off
Exclude bibliography	On		

3.8 Plagiarism declaration

UNIVERSITY OF THE WITWATERSRAND, JOHANNESBURG

FACULTY OF HEALTH SCIENCES

PLAGIARISM DECLARATION TO BE SIGNED BY ALL HIGHER DEGREE STUDENTS

SENATE PLAGIARISM POLICY: APPENDIX ONE

I Casey Julia McCusker (Student number: 1585560) am a student registered for the degree of MMed (Anat Path) in the academic year 2018.

I hereby declare the following:

- I am aware that plagiarism (the use of someone else's work without their permission and/or without acknowledging the original source) is wrong.
- I confirm that the work submitted for assessment for the above degree is my own unaided work except where I have explicitly indicated otherwise.
- I have followed the required conventions in referencing the thoughts and ideas of others.
- I understand that the University of the Witwatersrand may take disciplinary action against me if there is a belief that this is not my own unaided work or that I have failed to acknowledge the source of the ideas or words in my writing.
- I have included as an appendix a report from "Turnitin" (or other approved plagiarism detection) software indicating the level of plagiarism in my research document.

Signature:  Date: 27/09/2018

1

Section 4 : Research Proposal

ADENOMYOEPITHELIOMA OF THE BREAST: A CASE SERIES.

Research Protocol

Dr Casey Julia McCusker

MBChB (UP)

Student number: 1585560

Degree registered for: MMed (Anat Path)

Registrar, Anatomical Pathology, Division of Anatomical Pathology, School of Pathology, Faculty of Health Sciences, University of the Witwatersrand and National Health Laboratory Service (NHLS), Johannesburg.

Supervisor:

Dr Kirstin Janine Fearnhead (neé Coetzee)

MBChB (UCT), FCPath SA(Anat), MMed (Anat Path)

Anatomical Pathologist, Division of Anatomical Pathology, School of Pathology, Faculty of Health Sciences, University of the Witwatersrand and National Health Laboratory Service (NHLS), Johannesburg.

Co-supervisors:

Prof Sarah Louise Rayne

BSc MBChB MRCS(Eng) MMed FCS(SA)

Specialist Surgeon, Helen Joseph Breast Care Clinic, Netcare Breast Care Centre. Lecturer, Department of Surgery, Faculty of Health Sciences, University of the Witwatersrand, Johannesburg.

Dr Pamela Michelow

MBBCh MSc PGdip (HSE)

Cytopathologist, Division of Anatomical Pathology, School of Pathology, Faculty of Health Sciences, University of the Witwatersrand and National Health Laboratory Service (NHLS), Johannesburg.

4.1. Background and introduction

Adenomyoepithelioma (AME) is a rare, benign biphasic tumour comprising epithelial-lined spaces surrounded by a proliferation of myoepithelial cells [1]. It was first described in the breast by Hamperl in 1970 who suggested the term AME [2]. The World Health Organisation (WHO) 2012 classifies AME of the breast as a benign epithelial-myoepithelial lesion. Malignancy may arise in an AME and the WHO further subtypes AME with carcinoma (malignant adenomyoepithelioma) according to the location of the malignant component : luminal epithelium, myoepithelium or both (epithelial-myoepithelial carcinoma) [1].

In normal breast tissue and benign lesions, epithelial and myoepithelial components form the breast duct epithelium. Under neoplastic conditions, there is variation in the histologic appearance and immunophenotypic expression of myoepithelial cells, depending on whether the epithelial or myoid phenotype is expressed [2]. The combination of epithelial and myoepithelial cells can occur with considerable architectural and cytological heterogeneity within AME and poses diagnostic difficulty to the unwary, which may be compounded by the limited representation of lesional tissue on a needle core biopsy [3, 4]. Immunohistochemical investigation of the tumour, in order to correctly classify the lesion, is essential [4].

To the best of our knowledge, there are approximately 266 AME, 91 AME with carcinoma and 24 AME with other associated carcinoma, the majority as individual case reports and 7 cases series (Table. A.1) in the English language literature [3, 5-10].

A large number of AME with carcinoma were reviewed and reclassified according to the WHO 2012 classification by Xu et al [11].

AME affects mostly females and 2 rare cases are reported in male patients [4, 12, 13]. Patient age ranged between 22-92 years with a mean age of 59.1 years in the largest series [3]. The most common presentation of AME is a single, palpable, painless mass of variable duration [3, 4, 6, 14]. A single case of bilateral AME is reported [15].

Case series	Author	Year	Total number	Total number of AME	Recurrent	Malignant	Metastasis
1	Rosen et al [5]	1987	18	18	2	0	0
2	Decorsiere et al [6]	1988	U	17	U	U	U
3	Tavassoli [7]	1991	31	27	2	2	1
4	Loose et al [8]	1992	6	6	3	2	1
5	McClaren et al [3]	2005	35	23	0*	0	0
6	Hayes [9]	2011	25	12	2	13	4
7	Moritz [10]	2016	14	10	0	4	ND

Mammography of AME reveals a dense, round to lobulated, often circumscribed mass, resembling a fibroadenoma. Infrequently, ill-defined margins, calcifications and a cystic appearance are seen [4, 8, 14, 16-18]. Ultrasound reveals a round or oval, solid mass with a hypo- or complex echogenic texture and posterior or combined acoustic enhancement [9, 14, 19, 20]. Moritz et al, reported all AME in series of 14 cases as BI-RADS 4 or higher and the same series suggested that a definite diagnosis may not be possible radiographically.

AME ranges in size between 3mm to 70mm and AME with carcinoma may reach a much larger size, up to 170mm [4, 11]. AME may be round to lobulated, well circumscribed, firm or hard. Solid, cystic and nodular configurations have been described. At low-power, AME is circumscribed, comprises aggregated nodules without a discrete fibrous capsule and has a biphasic appearance due its dual epithelial-myoepithelial composition. High-power architecutre includes papillary,

pseudopapillary, trabecular and tubular and a combination of patterns can be seen [4, 6, 14, 21, 22]. Tavassoli subtyped AME into three variants, namely spindle-cell, tubular and lobular [6]. The cuboidal to columnar epithelial cells form round or ovoid glandular lumen invested by a proliferation of myoepithelial cells, which may assume a spindle, clear cell, plasmacytoid or epithelioid phenotype. Benign lesions may show a slightly increased mitotic activity, whereas malignant tumours show a marked increase, with rates varying between 10 and 40 mitoses per 10 high-power fields. Cytologic atypia with nuclear pleomorphism, prominent nucleoli, hyperchromasia and necrosis have been associated with tumours showing recurrence or may herald the development or presence of malignancy [6, 4, 11, 14]. Malignancy in an AME may arise either the epithelial, myoepithelial or both components [1, 8, 9].

Immunohistochemical staining of the epithelial cells with cytokeratin, epithelial lumen with EMA and staining of myoepithelial component with 2-3 of the following markers: p63, 34BE12, CK5/6, CK14, CD10 and actins (smooth muscle actin and muscle specific actin), highlights the tumour's biphasic nature. S100 may highlight both components [3, 4, 23]. Regarding the hormonal profile, oestrogen receptor and progesterone receptor may show weak, patchy positive staining and Her2-Neu is negative. The Ki-67 proliferation index is moderate and is commonly higher in the myoepithelial component [1, 4, 14]. Few studies evaluate the hormone receptor profile in AME and it is noted that salivary gland type tumours of the breast may express a triple negative phenotype, however exhibit low-grade behaviour [24].

Fine-needle aspiration of AME may be challenging and shows a cellular specimen comprising large clusters of epithelial and myoepithelial cells and single-lying cells with spindled and epithelioid morphology. Intranuclear cytoplasmic inclusions, foam cells and apocrine cells are infrequent findings [8, 14, 25-29]. AME with carcinoma shows hypercellular smears with loss of cohesion and a metachromatic matrix material, the latter is best appreciated on Diff-Quik stains [8, 25, 29, 30].

AME may be associated with squamous and sebaceous metaplasia [31, 32]. Concomitant AME and benign and malignant pathologies, namely collagenous spherulosis, phyllodes tumour, lobular neoplasia (atypical lobular neoplasia and invasive lobular carcinoma), ductal carcinoma in-situ (DCIS), invasive carcinoma of no special type, adenoid cystic carcinoma and low-grade adenosquamous carcinoma

are reported [8, 9, 33-46]. AME with carcinoma may rarely show heterologous osteogenic, spindle cell and carcinomatous differentiation [47].

Few studies have been undertaken to evaluate the molecular profile of AME [11]. Microsatellite instability for the D17S250 (17q11.2-BRCA1) microsatellite marker and loss of heterozygosity of the HPC1 gene have been reported [14]. Xu et al describe deletion of CDH1 and polysomy of CEP16 in myoepithelial cells by double fusion fluoresence in situ hybridisation (D-FISH). A report of a malignant AME with a lung metastasis shows a diploid DNA luminal epithelial population and tetraploid DNA myoepithelial cells. A point mutation of the p53 gene is reported, exclusively in the myoepithelial component [11].

Simple excision of most AME is curative and the recommended treatment of AME with carcinoma is wide local excision with adequate margins [6, 14]. Local recurrence has been reported and may be attributed to multinodular growth, intraductal extension of a lesion or incomplete excision [8]. Axillary lymph node metastasis of both AME and AME with carcinoma, in either or both components, has been described [6, 8, 48]. Distant metastasis of with AME with carcinoma is by haematogenous spread and sites include lung, liver, bone, thyroid, kidney, thoracic wall and brain [7, 16, 41, 44, 47, 49-57].

4.2. Aims

The aim of this study is to report a series of cases of AME of the breast, because this rare tumour may pose special considerations with respect to histological diagnosis and therapeutic management.

4.3. Objectives

1. To report a case series of AME of the breast.
2. To elucidate the clinical characteristic of this rare, benign tumour.
3. To describe the variability in the histology, including the immunohistochemical profile.
4. To document the co-occurrence of in-situ or invasive malignancy with these tumours.

4.4. Methods

4.4.1 Study Design

This will be a cross-sectional retrospective descriptive study.

4.4.2 Site of Study

The study will take place at the Division of Anatomical Pathology of the School of Pathology at the University of the Witwatersrand.

4.4.3 Time Period

All cases accessioned during the 18 year period from March 2000 to March 2018.

4.4.4 Study Sample

The study sample will be obtained from the Department of Anatomical Pathology at the Charlotte Maxeke Johannesburg and Chris Hani Baragwanath Academic Hospitals. Permission has been obtained from Professor MJ Hale to use the archives.

4.4.5 Inclusion and Exclusion Criteria

Inclusion criterion:

- Male and female patients, of any age, with a histological diagnosis of AME of the breast.

Exclusion criterion:

- Reported cases with a pathological diagnosis of AME with slides and/or paraffin embedded tissue blocks, which are not retrievable.

4.4.6 Methods

1. The cases reported during the study time frame will be identified by a computer-based record search. The cases are identifiable by a systematized nomenclature of medicine (SNOMED) code of 'myoepithelioma' and 'myoepithelial carcinoma' of the breast, entered into the NHLS database at the time of reporting of the specimens.
2. The reports of the cases identified will be obtained.
3. A second search using the patient's first name, surname, hospital number to correlate core biopsies and resection specimens will be performed.
4. The slides of the cases identified will be retrieved from the department's archival slide filing system.
5. The cases will be reviewed by both the principal investigator and the supervisor (Dr KJ Fearnhead).
6. The patient's clinical files will be reviewed, where possible.
7. The clinical and histologic parameters reviewed in the study will be recorded in the data sheet. See annexure A.

4.4.7 Statistical Analysis:

The study design aims to describe the clinico-pathological characteristics of a small group of rare, benign tumours of the breast that are presented in the form of a case series. The sample size is likely to be very small (<20 cases). The data will be expressed quantitatively as summary statistics and/or visually as graphs or tables.

The distribution of the data will be assessed and if, as anticipated, the distribution is not normal the median and interquartile ranges will be calculated. If on the other hand, the data distribution should be found to be normal, the range, mean and standard deviation will be calculated. Neither hypothesis testing nor use of inferential statistics is possible.

4.5. Funding

No funding will be needed.

4.6. Ethics

A project-specific application to the Human Research Ethics Committee (Medical) and Faculty of Health Sciences of the University of Witwatersrand, Postgraduate Office, will be submitted. There is blanket ethics approval (M150884) to use archived blocks, reports and slides in histological, IHC and molecular research.

The data sheet will be anonymous. Patient anonymity is paramount and to this end, the cases will be allocated a study number. A link will be created between the study number and the NHLS histology "case number", thus concealing the patient's identity. Patient confidentiality will be strictly maintained at all times. The patient's details will be kept anonymous and the patient's personal details will not be disclosed. This information will be kept in a locked cupboard in the registrar office at the Department of Anatomical Pathology, Medical School.

4.7. Time scale

	Jul '16	Aug '16	Sep '16	Oct '16	Nov '16	Dec '16	Jan '17	Feb '17	Mar '17	Apr '17
Presentation to department	12 Jul X									
Proposal to ethics			X							

Presentation to School of Pathology			14 Sep X							
Protocol submission		X								
Ethics approval				X						
Data retrieval/entry				X	X					
Data analysis						X	X			
Write-up								X	X	
Submission/ corrections										X

4.8. Task allocation

All data retrieval, assessment of histopathology reports, assessment and retrieval of clinical records and recording into data capture sheets, will be performed by the principle investigator, Dr CJ McCusker. The cases will be reviewed by both Dr McCusker and her supervisor, Dr Fearnhead.

4.9. Anticipated difficulties

Problems may be encountered in obtaining slides for the cases identified with AME as some of the 'older' cases may be irretrievable. If the slides are not available, the paraffin blocks may be retrieved and Haematoxylin and Eosin recuts obtained.

4.10. References

1. Schmidt F, Tan PH, Dabbs D, Jones L. Myoepithelial and epithelial-myoepithelial lesions. In: Lakhani SR, Ellis IO, Schnitt SJ, Hoon J, van de Vijver MJ, editors. WHO Classification of Tumours of the Breast, Lyon: IARC; 2012, p. 120-123.

2. Hamperl H. The myothelia (myoepithelial cells): Normal state; regressive changes; hyperplasia; tumors. Curr Top Pathol 1970;53:161-220. https://doi.org/10.1007/978-3-662-30514-0_3
3. McLaren BK, Smith J, Schuyler PA, Dupont WD, Page DL. Adenomyoepithelioma: clinical, histologic, and immunohistologic evaluation of a series of related lesions. Am J Surg Pathol 2005;29:1294-9.
4. Yoon JY, Chitale D. Adenomyoepithelioma of the breast: a brief diagnostic review. Arch Pathol Lab Med 2013;137:725-9. https://doi.org/10.5858/arpa.2011-0404-RS
5. Rosen PP. Adenomyoepithelioma of the breast. Hum Pathol 1987;18:1232-7.
6. Decorsiere JB, Thibaut I, Bouissou H. Adeno-myoepithelial proliferation in the breast. Ann Pathol 1988;8:311-6.
7. Tavassoli FA. Myoepithelial lesions of the breast. Myoepitheliosis, adenomyoepithelioma, and myoepithelial carcinoma. Am J Surg Pathol 1991;15: 554-68.
8. Loose JH, Patchefsky AS, Hollander IJ, Lavin LS, Cooper HS, Katz SM. Adenomyoepithelioma of the breast. A spectrum of biologic behavior. Am J Surg Pathol 1992;16:868-76.
9. Hayes MM. Adenomyoepithelioma of the breast: a review stressing its propensity for malignant transformation. J Clin Pathol 2011;64:477-84. https://doi.org/10.1136/jcp.2010.087718
10. Moritz AW, Wiedenhoefer JF, Profit AP, Jagirdar J. Breast adenomyoepithelioma and adenomyoepithelioma with carcinoma (malignant adenomyoepithelioma) with associated breast malignancies: A case series emphasizing histologic, radiologic, and clinical correlation. Breast 2016;29:132-9. https://doi.org/10.1016/j.breast.2016.07.018
11. Xu J, Tang X, Iida Y,et al. Adenomyoepithelioma with carcinoma of the breast: A report of two cases and a review of the literature. Pathol Res Pract 2016;212:130-4. https://doi.org/10.1016/j.prp.2015.09.008
12. Tamura G, Monma N, Suzuki Y, Satodate R, Abe H. Adenomyoepithelioma (myoepithelioma) of the breast in a male. Hum Pathol 1993;24:678-81. https://www.ncbi.nlm.nih.gov/pubmed/8389319

13. Berna JD, Arcas I, Ballester A, Bas A. Adenomyoepithelioma of the breast in a male. AJR Am J Roentgenol 1997;169:917-8. http://doi.org/10.2214/ajr.169.3.9275934
14. Brogi E. Myoepithelial neoplasms. In: Hoda SA, Brogi E, Koerner FC, Rosen PP, editors. Rosen's Breast Pathology, Philadelphia: Wolters Kluwer; 2014, p.153-174.
15. Bajpai J, Punatar SB, Gupta A, Badwe R, Gupta S. Bilateral adenomyoepithelioma of breast. J Cancer Res Ther 2013;9:523-5. http://doi.org/10.4103/0973-1482.119370
16. Trojani M, Guiu M, Trouette H, De Mascarel I, Cocquet M. Malignant adenomyoepithelioma of the breast. An immunohistochemical, cytophotometric, and ultrastructural study of a case with lung metastases. Am J Clin Pathol 1992; 98:598-602.
17. Laforga JB, Aranda FI, Sevilla F. Adenomyoepithelioma of the breast: report of two cases with prominent cystic changes and intranuclear inclusions. Diagn Cytopathol 1998;19:55-8. https://doi.org/10.1002/(SICI)1097-0339(199807)19:1<55::AID-DC11>3.0.CO;2-7
18. Ruiz-Delgado ML, Lopez-Ruiz JA, Eizaguirre B, Saiz A, Astigarraga E, Fernandez-Temprano Z. Benign adenomyoepithelioma of the breast: imaging findings mimicking malignancy and histopathological features. Acta Radiol 2007;48:27-9. https://doi.org/10.1080/02841850601080432
19. Adejolu M, Wu Y, Santiago L, Yang WT. Adenomyoepithelial tumors of the breast: imaging findings with histopathologic correlation. AJR Am J Roentgenol 2011;197:W184-90. http://doi.org/10.2214/ajr.10.6064
20. Lee JH, Kim SH, Kang BJ, Lee AW, Song BJ. Ultrasonographic features of benign adenomyoepithelioma of the breast. Korean J Radiol 2010;11:522-7. http://doi.org/10.3348/kjr.2010.11.5.522
21. Papaevangelou A, Pougouras I, Liapi G, Pierrakakis S, Tibishrani M, Setakis N. Cystic adenomyoepithelioma of the breast. Breast 2004;13:356-8. http://doi.org/10.1016/j.breast.2003.11.006
22. Hikino H, Kodama K, Yasui K, Ozaki N, Nagaoka S, Miura H. Intracystic adenomyoepithelioma of the breast--case report and review. Breast Cancer 2007;14:429-33. https://www.ncbi.nlm.nih.gov/pubmed/17986811

23. Tan PH, Ellis IO. Myoepithelial and epithelial-myoepithelial, mesenchymal and fibroepithelial breast lesions: updates from the WHO Classification of Tumours of the Breast 2012. J Clin Pathol 2013;66:465-70. https://doi.org/10.1136/jclinpath-2012-201078
24. Foschini MP, Morandi L, Asioli S, Giove G, Corradini AG, Eusebi V. The morphological spectrum of salivary gland type tumours of the breast. Pathology 2017;49:215-27. http://doi.org/10.1016/j.pathol.2016.10.011
25. Iyengar P, Cody HS, Brogi E. Pleomorphic adenoma of the breast: case report and review of the literature. Diagn Cytopathol 2005;33:416-20. http://doi.org/10.1002/dc.20364
26. Saad RS, Richmond L, Nofech-Mozes S, Ghorab Z. Fine-needle aspiration biopsy of breast adenomyoepithelioma: a potential false positive pitfall and presence of intranuclear cytoplasmic inclusions. Diagn Cytopathol 2012;40:1005-9. http://doi.org/10.1002/dc.21705
27. Chang A, Bassett L, Bose S. Adenomyoepithelioma of the breast: a cytologic dilemma. Report of a case and review of the literature. Diagn Cytopathol 2002; 26:191-6. https://www.ncbi.nlm.nih.gov/pubmed/11892027
28. Ng WK. Adenomyoepithelioma of the breast. A review of three cases with reappraisal of the fine needle aspiration biopsy findings. Acta Cytol 2002;46:317-24. http://doi.org/10.1159/000326728M.
29. Kurashina M. Fine-needle aspiration cytology of benign and malignant adenomyoepithelioma: report of two cases. Diagn Cytopathol 2002;26:29-34. https://www.ncbi.nlm.nih.gov/pubmed/11782084
30. Hock YL, Chan SY. Adenomyoepithelioma of the breast. A case report correlating cytologic and histologic features. Acta Cytol 1994;38:953-6. https://www.ncbi.nlm.nih.gov/pubmed/7992585
31. Cai RZ, Tan PH. Adenomyoepithelioma of the breast with squamous and sebaceous metaplasia. Pathology 2005;37:557-9. http://doi.org/10.1080/00313020500368394
32. Reis-Filho JS, Fulford LG, Crebassa B, Carpentier S, Lakhani SR. Collagenous spherulosis in an adenomyoepithelioma of the breast. J Clin Pathol 2004;57:83-6. https://www.ncbi.nlm.nih.gov/pmc/articles/PMC1770151/pdf/jcp05700083.pdf

33. Zhang S, Huo L, Arribas E, Middleton LP. Adenomyoepithelioma of the breast with associated atypical lobular hyperplasia: a previously unrecognized association with management implications. Ann Diagn Pathol 2015;19:20-3. http://doi.org/10.1016/j.anndiagpath.2014.11.002
34. Kamei M, Daa T, Miyawaki M, Suehiro S, Sugio K. Adenomyoepithelioma of the breast coexisting with ductal carcinoma in situ: a case report and review of the literature. Surg Case Rep 2015;1:81. https://doi.org/10.1186/s40792-015-0083-8
35. Warrier S, Hwang S, Ghaly M, Matthews A. Adenomyoepithelioma with ductal carcinoma in situ: a case report and review of the literature. Case Rep Surg 2013;2013:521417. https://doi.org/10.1155/2013/521417
36. Han JS, Peng Y. Multicentric adenomyoepithelioma of the breast with atypia and associated ductal carcinoma in situ. Breast J 2010;16:547-9. https://doi.org/10.1111/j.1524-4741.2010.00954.x
37. Guo W, Cao Y, Teng G, Liu J, Su J. Evolution and prognosis of breast osteosarcoma: A case report. Oncol Lett 2016;11:789-91. http://doi.org/10.3892/ol.2015.3921
38. Yang Y, Wang Y, He J, Pan G, Tuo X, Jiang A, Bian L. Malignant adenomyoepithelioma combined with adenoid cystic carcinoma of the breast: a case report and literature review. Diagn Pathol 2014;9:148. http://doi.org/10.1186/1746-1596-9-148
39. Li J, Yang GZ, Jin H, Ding HY. Pathologic diagnosis and differential diagnosis of low-grade adenosquamous carcinoma of breast and syringomatous adenoma of nipple. Zhonghua Bing Li Xue Za Zhi 2012;41:301-4. http://doi.org/10.3760/cma.j.issn.0529-5807.2012.05.004
40. Ohta M, Mori M, Kawada T, Maegawa H, Yamamoto S, Imamura. Y. Collagenous spherulosis associated with adenomyoepithelioma of the breast: a case report. Acta Cytol 2010;54:314-8.
41. Honda Y, Iyama K. Malignant adenomyoepithelioma of the breast combined with invasive lobular carcinoma. Pathol Int 2009;59:179-84. https://doi.org/10.1111/j.1440-1827.2009.02347.x
42. Kuroda N, Fujishima N, Ohara M,et al. Coexistent adenomyoepithelioma and invasive ductal carcinoma of the breast: presentation as separate tumors. Med Mol Morphol 2008;41:238-42. https://doi.org/10.1007/s00795-008-0376-0

43. Van Dorpe J, De Pauw A, Moerman P. Adenoid cystic carcinoma arising in an adenomyoepithelioma of the breast. Virchows Arch 1998;432:119-22.
44. Foschini MP, Pizzicannella G, Peterse JL, Eusebi V. Adenomyoepithelioma of the breast associated with low-grade adenosquamous and sarcomatoid carcinomas. Virchows Arch 1995;427:243-50. https://www.ncbi.nlm.nih.gov/pubmed/7496592
45. Van Hoeven KH, Drudis T, Cranor ML, Erlandson RA, Rosen PP. Low-grade adenosquamous carcinoma of the breast. A clinocopathologic study of 32 cases with ultrastructural analysis. Am J Surg Pathol 1993;17:248-58.
46. Buch A, Rout P, Makhija P. Adenomyoepithelioma with phyllodes tumor--a rare combination in a solitary breast lump. Indian J Pathol Microbiol 2006;49:259-61.
47. Simpson RH, Cope N, Skalova A, Michal M. Malignant adenomyoepithelioma of the breast with mixed osteogenic, spindle cell, and carcinomatous differentiation. Am J Surg Pathol 1998;22:631-6.
48. Nadelman CM, Leslie KO, Fishbein MC. “Benign," metastasizing adenomyoepithelioma of the breast: a report of 2 cases. Arch Pathol Lab Med 2006;130:1349-53. https://doi.org/10.1043/1543-2165(2006)130[1349:bmaotb]2.0.co;2
49. Michal M, Baumruk L, Burger J, Manhalova M. Adenomyoepithelioma of the breast with undifferentiated carcinoma component. Histopathology 1994;24:274-6. https://www.ncbi.nlm.nih.gov/pubmed/7515373
50. Kihara M, Yokomise H, Irie A, Kobayashi S, Kushida Y, Yamauchi A. Malignant adenomyoepithelioma of the breast with lung metastases: report of a case. Surg Today 2001;31:899-903. http://doi.org/10.1007/s005950170031
51. Rasbridge SA, Millis RR. Adenomyoepithelioma of the breast with malignant features. Virchows Arch 1998;432:123-30.
52. Cameron HM, Hamperl H, Warambo W. Leiomyosarcoma of the breast originating from myothelium (myoepithelium). J Pathol 1974;114:89-92. http://doi.org/10.1002/path.1711140206
53. Bult P, Verwiel JM, Wobbes T, Kooy-Smits MM, Biert J, Holland R. Malignant adenomyoepithelioma of the breast with metastasis in the thyroid gland 12 years after excision of the primary tumor. Case report and review of the literature. Virchows Arch 2000;436:158-66.

54. Jones C, Tooze R, Lakhani SR. Malignant adenomyoepithelioma of the breast metastasizing to the liver. Virchows Arch 2003;442:504-6. http://doi.org/10.1007/s00428-003-0806-2
55. Oka K, Sando N, Moriya T, Yatabe Y. Malignant adenomyoepithelioma of the breast with matrix production may be compatible with one variant form of matrix-producing carcinoma: a case report. Pathol Res Pract 2007;203:599-604. http://doi.org/10.1016/j.prp.2007.04.004
56. Murthy SS, Raju KV, Nair HG. Phyllodes Tumor in a Lactating Breast. Clin Med Insights Pathol 2016;9:13-7. http://doi.org/10.4137/CPath.S38476
57. Logie N, Hugh J, Paulson K, Pearcey R, King KM. Radiotherapy in the Multidisciplinary Management of Adenomyoepithelioma of the Breast with an Axillary Lymph Node Metastasis: A Case Report and Review of the Literature. Cureus 2017;9:e1380. http://doi.org/10.7759/cureus.1380