

https://dspace.org/

Comparison of ultrasound and magnetic resonance Imaging findings in patients with suspected placenta accreta spectrum at Chris Hani Baragwanath Academic Hospital

2024
https://hdl.handle.net/10539/37912

Downloaded from a DSpace repository. https://dspace.org/

Comparison of Ultrasound and Magnetic Resonance Imaging findings in patients with suspected placenta accreta spectrum at Chris Hani Baragwanath Academic Hospital.

By Sikhosonke Tsobo

22/2/2023

Registrar enrolled in the degree FC Rad Diag (SA), MMed
Student number: 0702920J
In the faculty of Health Sciences,
The University of Witwatersrand, Department of Radiology,
Johannesburg, South Africa

In the fulfilment of the requirements for the degree of Master of Medicine in the clinical Disciplines.

Supervised by:
Dr J Jeebodh (Consultant- Department of Obstetrics and Gynaecology-Chris Hani Baragwanath Academic Hospital)
Email: jjeebodh@gmail.com

Dr M Ramantsi (Consultant-Department of Diagnostic Radiology-Chris Hani Baragwanath Academic Hospital)
Email: mkgalaeng@icloud.com

Dr L Ngobese (Consultant-Division of Anatomical Pathology, Chris Hani Baragwanath Academic Hospital)
Email: Lungile.Ngobese@lancet.co.za

Declaration by candidate:

I hereby declare that this research paper is my own original work and has not been submitted before to any other institution for assessment purposes. I have acknowledged all sources and cited these in the reference section. There are no conflicts of interest in creating this research paper.

This paper was prepared in a "submissible" format in line with the guidelines of the South African Journal of Radiology.

Signed on this day 22 February 2023.



Sikhosonke Tsobo

Declaration by Supervisors:

The following people contributed as supervisors to the work undertaken by the candidate, Sikhosonke Tsobo, student number 0702920J, as part of their research paper entitled "Comparison of Ultrasound and Magnetic Resonance Imaging findings in patients with suspected placenta accreta spectrum at Chris Hani Baragwanath Academic Hospital." in fulfillment of the requirements for the degree of FC Rad Diag (SA) MMed.

Details of Candidate and Supervisors (including percentage contributions):

- Candidate: Sikhosonke Tsobo (50%)
- Supervisor 1: Jayshree Jeebodh (20%)
- Supervisor 2: Maureen Ramantsi (15%)
-Supervisor 3: Lungile Ngobese(15%)

Contribution of work by supervisors and candidate for the above-mentioned research paper: • The research paper is the original work of the candidate, Sikhosonke Tsobo, who drafted the protocol and final research paper for this study.

- Supervisors reviewed draft manuscripts of the protocol and the final research paper and provided guidance regarding research methodology, improvements to content, general conduct, and conceptual ideas.
- This proposal and the research paper were submitted to Turnitin concerning plagiarism. The plagiarism certificates were checked and are satisfactory.

Signed on this day _22_ of February____ 2023



Jayshree Jeebodh(Supervisor) Maureen Ramantsi(Supervisor) Lungile Ngobese(Supervisor)

Acknowledgements

I would like to thank and acknowledge the following persons:

My supervisors- Dr Jeebodh, Dr Ramantsi and Dr Ngobese for their time and dedication to helping develop and complete this project.

My sister Yomelela Tsobo and my friends Dr Keorapetse Diale and Mr Katlego Motlogelwa for assisting with editing and proofreading the article.

Ms Lucy Khofi from Wits Writing Centre for assisting with proofreading the article.

Ms Adatia Chifava for assistance with statistics and setting up the RedCAP data collection sheet.

Dedicated to my mother Thenjelwa, my wife Salizwa and my son Xhoba. Thank you for everything.

Table of Contents

Authors guidelines of the intended journal 9

Abstract 18

Introduction 19

Aims and objectives. 20

Research methods and study design 20

Ethical consideration 24

Results 25

Discussion 28

Limitations and strengths 30

Conclusion 31

Competing interests 32

Author(s) contributions 32

Funding information 32

Data availability statement 32

Disclaimer 32

Keywords used in this article 32

References 33

Appendix 1: Table of Abbreviations 36

Appendix2: Tables with legends 37

Appendix 3: Figures with legends 40

Appendix 4: Graphs with legends 45

Appendix 6: Turnitin Report 48

Appendix 7:Original protocol with extended literature review 53

Table of contents 55

1. Rationale 57

2. Introduction 57

2.1. Definitions 57

2.1.1 Placenta accreta spectrum 57

2.2. Clinical Presentation 57

2.3. Epidemiology 58

2.4. Risk factors 58

2.5. Diagnosing PAS 58

2.5.1. Ultrasound Findings 59

2.5.2. MRI findings 59

2.5.3. Surgical report findings 60

2.5.4 Histopathology report findings 60

2.5.5. Comparison of ultrasound and MRI prenatal diagnosis accuracy 61

2.5.5.1 Global literature 61

2.5.5.2 South African studies 61

2.5.5.3 Studies in the rest of Africa 61

2.5.6. Radiologist experience and accuracy of MRI findings 63

2.6. The project in context: Comparison to literature 63

3. Aims 63

4. Study Objectives 64

5. Methods 65

5.1. Setting 65

5.2. Research paradigm 65

5.3 Sample 65

5.3.1. Inclusion criteria 65

5.3.2. Exclusion criteria 65

5.4. Materials and Methods 66

5.5. Data collection 67

5.6. Reliability and validity 67

5.7. Bias 67

6. Data analysis and statistics 68

7. Ethics 68

7.1. Data Safety 68

8. Timing 69

9. Budget 70

10. Anticipated problems 70

11. References 71

..... 74

Authors guidelines of the intended journal

These guidelines are taken from the South African Journal of Radiology(SAJR) website: https://sajr.org.za/index.php/sajr/pages/view/submission-guidelines#part_1

Original Research Articles

An original article provides an overview of innovative research in a particular field within or related to the focus and scope of the journal, presented according to a clear and well-structured format.

Word limit	4000 words (excluding the structured abstract and references)
Structured abstract	250 words to cover a Background, Objectives, Method, Results and Conclusion
References	40 or less
Tables/Figures	no more than 10 Tables/Figure
Ethical statement	should be included in the manuscript
Compulsory supplementary file	ethical clearance letter/certificate

Style and format

File format

- Manuscript files can be in the following formats: DOC, DOCX, or RTF. Microsoft Word documents should not be locked or protected.
- LaTeX documents (.tex) should be converted into Microsoft Word (.doc) before submission online.
- Rich Text Format (RTF): Users of other word processing packages should save or convert their files to RTF before uploading. Many free tools are available that will make this process easier.

Length

Manuscripts should adhere to the author guidelines of the journal. There are restrictions on word count, number of figures, or amount of supporting information.

Font

Use a standard font size and any standard font family.

Special characters

Do not use the font named ‘Symbol’. To add symbols to the manuscript, use the Insert → Symbol function in your word processor or paste in the appropriate Unicode character. Refer to our AOSIS house style guide on mathematical and Unicode font guidelines.

Headings

Ensure that formatting for headings is consistent in the manuscript. Limit manuscript sections and sub-sections to four heading levels. To avoid confusion during the review and production process, ensure that the different heading levels used in your work are visually distinct from one another. The simplest way to achieve this is to use different font sizes and/or a combination of bold/italics for different heading levels.

Keywords

Identify eight keywords that represent the content of your manuscript and are specific to your field or sub-field. Test your keywords: when you enter your keywords into the various journal and academic databases like Google Scholar, do the results include papers similar to your topic? If not, revise the terms until they do.

Layout and spacing

Manuscript text should have a 1.5 line spacing.

Page and line numbers

Include page numbers and line numbers in the manuscript file. Use continuous line numbers (do not restart the numbering on each page).

Footnotes

Footnotes are not ideal. If your manuscript contains footnotes, move the information into the main text or the reference list, depending on the content.

Language

Manuscripts must be written in British English, according to the Oxford English Dictionary (avoid Americanisms [e.g. use ‘s’ and not ‘z’ spellings], and set your version of Microsoft Word default language to UK English). Refer to the AOSIS house style guide for more information.

Abbreviations

Define abbreviations upon first appearance in the text. Do not use non-standard abbreviations unless they appear at least three times in the text. Keep abbreviations to a minimum.

Illustrations

Illustrations fall into two categories:

- Figures: Photographs, drawings, diagrams, graphs, flowcharts, maps, etc.
- Tables and/or Boxes: Text and/or numbers arranged in orderly columns and rows.

Every time a Figure, Table and/or Box is presented in your manuscript, it should be referred to three times:

- In a legend, which includes a number, a title, and its source. The legend is placed below a Figure and above a Table and/or Box. The source section should consist of the in-text citation, creator or owner and its year of creation, and any other attribution required as stipulated by the permission received (person and place) to reproduce.
- In the body of your written manuscript. You should include an in-text citation and a sentence or two about the image explaining what it illustrates and why it is there.
- As a reference entry within your reference list.

AOSIS house style

The manuscript must adhere to the **AOSIS house style guide**.

References

Referencing style guide

The manuscript must adhere to the **Vancouver referencing style**.

Permission to use copyright material

The following information will assist you in understanding your responsibilities and in requesting permission to reproduce copyrighted material in your work. All permissions granted must be submitted to the journal together with your manuscript, and you must ensure that a clearly written source accompanies the work.

Your responsibilities

As the author, you are responsible for obtaining permission and paying any fees to use the third-party copyrighted material that your manuscript contains.

Material that will need clearance

Content not in the public domain or freely available to use under a license such as a creative commons license will require clearance. It includes the use of photographs, figures, maps,

tables, cartoons, advertisements, epigraphs and quotations that are over the limits referred to under 'Modification/adaptation of figures and tables'.

Web material

Image or text material on the Web may not be the intellectual property of the site hosting it. You must always identify the original copyright source and obtain explicit permission. Take particular care with photographs obtained from websites, blogs, Google image searches, YouTube, Wikimedia, etc.

Material previously published by you or your colleague

Check the contract with the other publisher to see whether, and under what conditions, the material can be reused in this AOSIS publication. If in any doubt, permission must be obtained.

Images of, or information about, identifiable individuals

It is your responsibility to obtain consent from patients and other individuals for the use of information, images, audio files, and video clips from which they may be identified. Bear in mind the following points:

- Masking a person's eyes is not an adequate or acceptable means of rendering an image anonymous.
- People may still be recognizable to individuals or their families, even if head/shoulders are not included.
- People may recognize themselves from clinical descriptions or case reports.

Modification/adaptation of figures and tables

Use the original figure as first published where appropriate. However:

- No clearance is required if you create figures or tables using factual data from copyrighted material.
- No clearance is required if, after you have created a single figure or table using data from two or more figures or tables, no single source comprises more than 75% of the new figure or table.
- No clearance is required if, after you have created a new figure or table by adding your own data to an existing figure or table, your data comprises more than 25% of the new figure or table.
- Clearance is required if you create a figure or table using parts from two or more third-party sources, and each part contains more than 75% of the content of the original figure/table part.

Quotations

For prose, permission is required for single quotations of over 400 words or multiple quotations from the same source that cumulatively total more than 800 words. But note that, even if below these limits, permissions must be cleared for quotations that represent the 'heart of the work' or a substantial portion of the overall original source material.

Clear before you submit your final manuscript

Permissions must be cleared before the final version of your manuscript is submitted for publication. If permission cannot be obtained, you should find an alternative or remove the material. Provide electronic copies of all consent forms obtained when you submit your final manuscript, numbered and named accordingly.

Ethical considerations

This section should include the statements of compliance with standards of research involving either animal or human involvement. If your study involves human subjects and/or animals, and if your manuscript includes case reports/case series, you need to provide the following:

- Authors must provide the name of the ethical approval committee/Institutional Review Board they have obtained consent from and approval number/ID.
- Authors should specifically mention if a waiver was obtained for the study and the reason for the waiver. They should confirm that the study was conducted in accordance with Helsinki Declaration as revised in 2013.
- Authors must state that written informed consent was obtained from the participants of the study (and the relevant document(s) must be provided when requested by the journal). If verbal informed consent was obtained, the reason(s) for the absence of written consent must be provided.
- For case reports/case series involving minor subjects/children/infants, authors should confirm that the statements of written informed consent from legally authorized representatives/parents/guardians are available; if verbal informed consent was obtained, reasons for this must be mentioned.
- Since patients have a right to privacy, identifying information (including patients' images, names, initials, or hospital numbers) should not be included in recordings, written descriptions, or photographs unless the information is essential for scientific purposes. In any case, written informed consent from the patient must be obtained for publication of these graphics in print and electronic form. If such consent has not been obtained, personal details of patients in any part of the paper and in any supplementary materials (including illustrations) must be removed before submission.

Subject	**Scenario**	**Suggested statement of compliance**
Animals: Include the statement of compliance with standards of research involving animals.	If your work includes animals, it is necessary to have a statement of compliance with research standards involving animals.	All procedures performed in studies involving animals followed all international, national, and/or institutional guidelines for the care and use of animals.
	If you publish an article and there are reasons to <u>believe</u> that	This article does not contain any studies involving animals

	you could have used animals but did not.	performed by any of the authors.
Humans: Include the statement of compliance with standards of research involving humans.	If your work does not include humans as subjects, you may finish the ethical statement to include.	This article does not contain any studies involving human participants performed by any of the authors.
	If your work involves humans as a subject, you had to receive ethics approval.	An application for full ethical approval was made to the [committee/Institutional Review Board] and ethics consent was received on [date]. The ethics approval number is [full ethics approval number].
	If your work involves humans as a subject, but you received an ethics waiver.	An application for full ethical approval was made to the [committee/Institutional Review Board] and ethics consent was received on [date]. The ethics waiver number is [full number]. The [committee/Institutional Review Board] issued an ethics waiver for the study because [reason for the ethics waiver].
	Additional statements: If your work involves humans, it is necessary to include one of the above and the following two additional statements.	All procedures performed in studies involving human participants were in accordance with the ethical standards of the institutional and/or national research committee and with the 1964 Helsinki Declaration and its

		later amendments or comparable ethical standards.[a] **Informed Consent:** [Written/Verbal] informed consent was obtained from all individual participants involved in the study. [If verbal informed consent was obtained, the reason(s) for the absence of written consent must be provided.]

[a], Do keep in mind: The necessary and sufficient condition is to conduct research in accordance with the **1964 Helsinki Declaration**. If your institution has no department that deals with ethics, then you should not mention institutional standards. If your country has no committee that deals with ethics, then you should not mention national standards.

Acknowledgements structure

Acknowledgements

The acknowledgement section follows the conclusions section and addresses formal, required statements of gratitude and required disclosures. It includes listing those who contributed to the work but did not meet authorship criteria, with the corresponding description of the contribution. Acknowledge anyone who provided intellectual assistance, technical help (including with writing and editing), or special equipment and/or materials. Authors are responsible for ensuring that anyone named in the Acknowledgements agrees to be named.

Also provide the following, each under their own subheading:

- Competing interests
- Author contributions
- Funding information
- Data availability statement
- Disclaimer

Competing interests

This section should list specific competing interests associated with any of the authors. If authors declare that no competing interests exist, the article will include a statement to this effect. Read our **policy on competing interests**.

Author contributions

All authors must meet the criteria for authorship as outlined in the **authorship** policy and **author contribution** statement policies.

Funding information

All research articles should have a funding acknowledgement statement included in the manuscript in the form of a sentence under a separate heading entitled 'Funding information'. The funding agency should be written out in full, followed by the grant number in square brackets.

The following are examples of a funding statement. If you use one of the examples, you should modify it to fit your specific relationship.

Data availability statement

All research articles should have a data availability statement included in the manuscript in the form of a sentence under a separate heading entitled 'Data availability statement'.

The following are examples of a data availability statement. If you use one of the examples, you should modify it to fit your specific relationship.

Disclaimer

A statement that the views expressed in the submitted article are his or her own and not an official position of the institution or funder.

Comparison of Ultrasound and Magnetic Resonance Imaging findings in patients with suspected placenta accreta spectrum at Chris Hani Baragwanath Academic Hospital.

Abstract

- **Background:** Placenta accreta spectrum (PAS) is a serious condition that is increasing in prevalence with an increase in the caesarean section rate. This condition is associated with significant haemorrhage. Accurate diagnosis and adequate surgical planning are associated with favourable outcomes. Ultrasound and MRI are used in prenatal diagnosis of this condition.
- **Objectives**: To compare ultrasound and MRI report findings with histopathology or surgical findings in patients with suspected PAS at Chris Hani Baragwanath Academic Hospital. To compare the diagnostic accuracy of PAS between the junior and senior (>5 years' experience) radiologists' MRI reports.
- **Method**: A retrospective comparison of 14 MRI and 18 ultrasound report findings of patients with suspected PAS were compared with histopathologic or surgical report findings. These imaging modalities' sensitivity, specificity, accuracy, true positive, true negative, false negative and false positive values were determined. The accuracy, sensitivity and specificity of MRI reports were determined based on radiologists' experience.
- **Results**: Ultrasound correctly diagnosed PAS in 10/18(56%) of the patient reports. MRI correctly diagnosed PAS in 6/14(43%) of reports. Ultrasound reports had sensitivity and specificity of 90.9% and 28.6%, respectively, while MRI reports had sensitivity and specificity of 20% and 75%, respectively. The senior radiologists correctly diagnosed PAS in 3/7(42%) of reports, while junior radiologists correctly diagnosed PAS in 4/6(67.7%) of MRI reports.
- **Conclusion**: There was no statistically significant difference in the accuracy of Ultrasound and MRI in diagnosing PAS. There was no statistically significant difference in diagnosis of PAS between junior and senior radiologists.

Introduction

Placenta accreta spectrum (PAS) is a complex disorder of placenta implantation due to endometrium-myometrial interface damage with subsequent absent re-epithelialisation and scarring resulting in an abnormally implanted and adherent placenta(1, 2). The abnormal attachment of the placenta leads to difficulty in placenta delivery with associated complications related to significant haemorrhage and, at times, a need for a hysterectomy (2).

Abnormal placenta attachment subtypes are classified according to the level of invasion at the placenta-myometrium interface, referred to as placenta accreta when the placenta has pathologically adhered to the superficial myometrium, placenta increta when there is an invasion into the myometrium and placenta percreta when there is penetration through the serosa with or without invasion of the surrounding pelvic or abdominal organs (3). The International Federation of Gynecology and Obstetrics (FIGO) recommends the use of the term "placenta accreta spectrum"(PAS) instead of the various subtypes individually. The term PAS ensures standardised nomenclature and is inclusive of the various subtypes (1)

The majority of patients with PAS are asymptomatic and are diagnosed for the first time during delivery(4). Previous caesarean section is the most common risk factor for PAS followed by placenta previa(5). Placenta previa is a placental abnormality whereby the placenta partially or completely obstructs the internal cervical os(6). Women with prior caesarean sections are nine times more likely to present with PAS (5, 7). Other risk factors for PAS include previous uterine surgery, advanced maternal age, multiparty, hypertension, smoking, uterine leiomyomas, previous uterine irradiation, in vitro fertilisation and placenta previa(8, 9).

The reported incidence of PAS has increased in parallel to an increased global caesarean section rate. Studies in the United States and the United Kingdom have reported an incidence of PAS to be 3 in 1000 deliveries(10). Chris Hani Baragwanath Academic Hospital's caesarean section rate has increased gradually with each passing year, from 39.8% in 2015 to 50% in 2019 (11).

Definitive management of PAS is a caesarean hysterectomy(12). Uterus-sparring conservative options are available for women who would like to preserve fertility; however, this depends on the availability of specialised surgical expertise and blood products(12). FIGO guidelines only recommend uterine sparring options in high-resource settings (12). A multidisciplinary team approach is recommended depending on the degree of adherence or invasion of the uterus(12). The multidisciplinary team typically comprises (amongst others) of obstetricians, diagnostic

radiologists, interventional radiologists, urologists and trauma surgeons. The involvement of a multidisciplinary team is associated with better outcomes and fewer complications (5, 12, 13). Prenatal diagnosis of PAS with imaging plays a vital role in the planning of surgery and the appropriate involvement of the various members of the multidisciplinary team (13).

Ultrasound is the primary investigation of choice for preliminary diagnosis in patients at high risk of PAS(9, 14). Magnetic resonance imaging (MRI) is recommended in patients with suspected PAS when the placenta cannot be adequately assessed by ultrasound, such as in obese patients, with multiple gestations, suspected extrauterine organ involvement and posterior placenta position(14) (9) (10).

A systematic review of 13 studies by Meng et al. reported ultrasound to be more specific and sensitive in comparison to MRI (15), whilst a systemic review by Dahmarde et al. made up of 17 studies reported MRI to be more specific and sensitive in comparison to ultrasound(16). The only similar study in South Africa was a 2004 prospective study at King Edward VIII hospital, Nelson R Mandela School of Medicine, Durban, KwaZulu Natal. The study reported ultrasound to be more specific and sensitive than MRI in diagnosing PAS (14).

Aims and objectives.

This study aimed to describe our current prenatal detection of PAS and determine our institute's imaging accuracy in diagnosing PAS. This may improve prepartum radiological diagnosis and motivate for appropriate use of the imaging modalities. These findings may improve surgical planning and inform the appropriate involvement of members of the multidisciplinary team in managing this complex life-threatening condition.

The study objectives were as follows:

Primary objective

1. To compare MRI and Ultrasound report findings in patients with suspected PAS.

   Secondary Objectives

   1.1. To compare MRI and ultrasound report findings with histopathology or surgical findings in the absence of histopathological reports.

   1.2. Compare junior and senior MRI radiologist reports with surgical and histological outcomes.

Research methods and study design

A retrospective, cross-sectional study was conducted at Chris Hani Baragwanath Academic Department of Diagnostic Radiology Hospital and Fetal Medicine Unit (FMU). Chris Hani Baragwanath Academic Hospital is a tertiary hospital situated in the south of Johannesburg,

South Africa. It serves the southern Gauteng province, which has a population of approximately 2 million people. Patients served are referred from surrounding midwife-operated Units (MOUs) and hospitals of various levels. According to departmental morbidity and mortality statistics, there were 23000 deliveries performed in 2019 at Chris Hani Baragwanath Academic Hospital with a 50% caesarean section rate (11).

The study sample retrospectively included all MRI and ultrasound reports from patients with suspected PAS that had attended Chris Hani Baragwanath Academic Hospital from 31 December 2019. Ultrasound and MRI report findings were compared to histopathological report findings as a gold standard or surgical report findings where the histopathological report findings were unavailable.

Chris Hani Baragwanath Hospital has a dedicated multidisciplinary team caring for all patients with suspected PAS. Patients at high risk for PAS had been identified at the antenatal care clinic and referred to the fetal medicine unit for examination with ultrasound grayscale and colour Doppler. Patients with inconclusive ultrasound findings, suspected extrauterine organ involvement, multiple gestations and posterior placentas had then been referred for MRI.

Ultrasound reports were obtained from an already existing database-PIA Fetal Database(GE-Viewpoint, Wessling, Germany) in the FMU.
The MRI reports were obtained from the hospital's Picture Archiving and Communications System (PACS)- AGFA IMPAX 6.5.1.5012011 (2007-2008). The histopathological reports were gathered from the National Health Laboratory Service (NHLS) Trakcare database. Intra-operative surgical findings for patients without histopathological reports were obtained from patient files in the hospital filing and storage department.

All ultrasound examinations had been performed and reported at the fetal medicine unit by a qualified fetal medicine super specialist. All MRI reports used had been reported or approved by a qualified radiologist. All MRI reports reported by a radiology registrar with no documented radiologist approval were excluded. Patient reports with unavailable histopathology or surgical reports were also excluded. The MRI reports available on the database were from 1 July 2017. Our cohort, therefore, only included MRI and ultrasound reports between 1 July 2017 and 31 December 2019.

The sonographic grayscale and colour doppler transabdominal and transvaginal examinations were performed with the GE VOLUSON S8 and Canon Aplio 400 TUS-A400. The transducers used for GE Voluson S8 were:

1. Endocavity(transvaginal) – GE E8C Microconvex Probe, bandwidth 4-10 MHz, with the application set to obstetrics.
2. Transabdominal -GE C1-5 2D Convex Probe, bandwidth 1-5MHz, application set to obstetrics.

The transducers used on the Canon Aplio 400:

1. Endocavity(transvaginal) probe-PVT781VT (11C3), bandwidth 4.0-9.0 MHz, application set to obstetrics.
2. Transabdominal probe-PVT-3575BT(6Cs1), bandwidth- 1.9-6.0 MHz, application set to obstetrics.

The MRI images were acquired with a 1.5T Siemens Magnetom Aera, 2015 with a body coil. The sequences acquired were T2 Half-Fourier Acquisition Single-shot Turbo spin Echo (HASTE) Sagittal, T2 HASTE Coronal, T2 HASTE Axial, T1 Volumetric Interpolated Breath-hold Examination (VIBE) Axial and T2 HASTE Axial Oblique.

Patient demographics, risk factors, ultrasound and MRI report findings were collected and entered into a predesigned datasheet on Research Electronic Data Capture (REDCap), as demonstrated in Figure 1. The reported presence of one or more of the following ultrasound or MRI signs was considered a positive diagnosis for that modality:

Ultrasound signs of abnormal invasion (17-20):

1. Low-lying gestational sac
2. Reduced myometrial thickness.
3. Intra-placental lacunae
4. Abnormal uterus-bladder interface.
5. Loss of retro-placental clear space.
6. Sub-placental vascularity on colour doppler
7. Exophytic uterine masses

Magnetic Resonance Imaging signs of abnormal invasion (21, 22):

1. Uterine bulging.
2. Heterogenous placenta signal intensity on T2 weighted sequence
3. Hypointense intra-placental bands on T2 weighted sequence
4. Focal interruption of the myometrium.
5. Thinning or disappearance of the myometrium.
6. Tenting of the urinary bladder.

Sensitivity, specificity, and positive and negative predictive values for both ultrasound and MRI reports were calculated by cross-tabulation of the binary index values with the gold standard, which is a histopathology report and, in its absence, surgical report findings.

The 95% confidence intervals were calculated around the sample estimates, and McNemar's test was used to compare the sensitivity and specificity of MRI against Ultrasound. The cut-off value for the probability (p-value) of McNemar's test was 0.05, a p-value <0.05 indicated a difference that would most likely not be by chance.

The radiologist's experience was gathered via a questionnaire sent to the radiologists via email. The radiologist's experience (months since qualification) was documented, and the accuracy of the MRI reports in relation to experience was described. The radiologists were divided into senior and junior radiologists. Senior radiologists were regarded as a radiologist with 60 months (5 years) or more as a qualified radiologist.

Ethical consideration

The study was approved by the University of Witwatersrand Human Research Ethics Committee (HREC). Clearance reference: M200260.

Results

Between 1 June 2017 and 31 December 2019, there were 35000 births at Chris Hani Baragwanath Academic Hospital. Of the 35000 births, 20 patients with suspected PAS were found on storage and databases with ultrasound and MRI reports.

One patient was excluded from the study due to missing surgical findings or histopathology reports resulting in 19 patients included in the study. There were 11 patients with histopathology reports and eight with surgical report findings. Out of the 19 patients, five MRI reports were excluded because one was missing an MRI report, and four MRI reports were reported by radiology registrars and were not approved by a qualified radiologist. Out of the 19 patients, one ultrasound report was excluded due to a missing ultrasound report. Therefore, a total of 14 MRI reports and 18 ultrasound reports formed part of the study. There were 13 cases that had both the MRI and ultrasound reports from the same patient. The breakdown of this cohort is represented in Figure 2.

The mean age of the patients was 30.95+/-7.01SD, mean gravidity was three and mean parity was two. Sixteen (84%) patients had placenta previa. Twelve (63%) of the patients had previous caesarean section, and seven (37%) patients had non-caesarean previous uterine surgery or procedures. There was one primigravida who had placenta previa and no other risk factors. The demographic and clinical characteristics of the patients in this study are represented in Table 1.

The earliest ultrasound study was performed at a gestational age of 21 weeks, 2 days and the latest ultrasound was done at a gestational age of 37 weeks, 3 days. The earliest MRI was performed at 21 weeks, 2 days, and the latest MRI was at a gestational age of 37 weeks, 3 days. The average gestational age at which ultrasound was performed was 30 weeks, 2 days and for MRI, it was 32 weeks, one day. The average time interval between the ultrasound and MRI was 13 days.

Ten ultrasound reports correctly diagnosed PAS and two correctly excluded PAS in correlation with histopathologic or surgical findings. Five ultrasound reports incorrectly diagnosed PAS, and one ultrasound report missed PAS in correlation to histopathologic or surgical findings.
There were six MRI reports that correctly diagnosed PAS and two that correctly excluded PAS in correlation with histopathologic or surgical findings. There were four MRI reports that incorrectly diagnosed PAS and two MRI reports missed PAS in correlation to histopathologic or surgical findings. The true positive, false positive, true negative and false negative values of the imaging modalities are represented in Table 2.

Out of the 13 patients that had both the ultrasound and MRI reports from the same patient; the ultrasound and MRI were discordant in six (46%) cases. Of the six discordant patients, three (50%) had PAS on histopathology reports or surgical report findings. Ultrasound correctly diagnosed PAS in two (67%) and correctly ruled out PAS in one (33%) patient. MRI correctly diagnosed PAS in one patient (33%) and correctly ruled out PAS in two patients (67%). The proportion of correctness for discordant cases is represented in Table 3.

Ultrasound had a sensitivity of 91% (95%Confidence interval (CI)-58.7-99.8%) and specificity of 29%(95%CI,4-71%). Ultrasound had a positive predictive value of 67% (95%CI,39-88%) and a negative predictive value of 67% (95CI, 9-99%). MRI had a sensitivity of 75% (95%Confidence interval (CI)-35-97%) and a specificity of 20%(95%CI,5-72%). MRI had a positive predictive value (PPV) of 60% (95%CI,26-88%) and a negative predictive value (NPV) of 33% (95CI, 1-90%). There was no statistically significant difference between the sensitivity of the ultrasound (91%) and the MRI (75%); p=0.564. There was no statistically significant difference between the specificity of ultrasound (28.57%) and MRI (20.00%); p>0.999. The sensitivity and specificity values are summarised in Table 4.

The most reported signs in true positive ultrasound reports were the presence of intraplacental lacunae in seven cases (70%) and abnormal uterine-bladder interface in six patients (60%). The percentage of ultrasound signs in true positive reports is demonstrated in Graph 1.

The most reported signs in true positive MRI reports were heterogenous placenta signal intensity on T2WI and focal interruption of the myometrium in 4 cases (66.7%) for each sign. The percentage of MRI signs in true positive reports is demonstrated in Graph 2. Figures 4 and 5 show some of the reported MRI findings from the patients in our cohort. Figure 6 shows a histopathology slide of a patient with placenta accreta from our cohort.

Seven different radiologists reported the MRI studies. One radiologist's experience could not be recorded as there was no response to our survey. Radiologists' experience could, therefore, only be determined for six of the seven radiologists and 13 of the 14 MRI reports. Two of the six radiologists were senior (>60months), and four were junior. Senior radiologists reported seven (54%) MRI reports, and junior radiologists reported six (46%) MRI reports. The most junior radiologist had two months of experience, and the most senior radiologist had 208 months (17 years) of experience.

Three (42.9%) MRI senior radiologists reports correctly diagnosed PAS, and one (14.3%) report correctly excluded PAS when compared with histopathologic or surgical findings. Two (28.6%)

senior radiologist MRI reports incorrectly diagnosed PAS, and one (14.3%) report incorrectly excluded PAS.

Four (66.7%) MRI junior radiologists reports correctly diagnosed PAS, and two (33.3%) incorrectly diagnosed PAS. The accuracy percentages, true positives, false positives, true negatives and false negatives are represented in Table 5.

Junior radiologists had a sensitivity of 100% in diagnosing PAS (95%Confidence interval (CI)-39.8%-100%) and a specificity of 0% (95%CI,0-84.2%). Junior radiologists had a positive predictive value of 66.7% (95%CI,66.7%-66.7%), and a negative predictive value could not be defined due to zero true negatives and false negatives. Senior radiologists had a sensitivity of 75% in diagnosing PAS (95%Confidence interval (CI)-19.4-99.4%) and a specificity of 33.3%%(95%CI,0.8-90.6%). Senior radiologists had a positive predictive value of 60% (95%CI,36-80%) and a negative predictive value of 50% (95CI, 8.8-91%). The sensitivity and specificity values are summarised in Table 6.

Discussion

Prenatal diagnosis of PAS is essential for surgical planning and is associated with reduced maternal and fetal morbidity and mortality (12). The most common and significant risk factors of PAS are previous caesarean section and placenta previa (5). The majority of patients in our study had placenta previa, previous caesarean section or both. This clinical and risk profile of patients in our study is similar to earlier studies by Chambon et al., Warshak et al., Dwyer et al., Lopes et al. and Maher et al. (7, 22-25).

Ultrasound is widely regarded as the primary diagnostic tool in patients with suspected PAS. MRI is recommended in patients with inconclusive ultrasound findings such as suspected extrauterine organ involvement, multiple gestations, obese patients, and posteriorly placed placenta (9, 10). Ultrasound is readily available, quick, cheaper and requires less expertise than MRI(9, 10, 14). Therefore, comparing these modalities is important in a resource-limited setting to ensure the appropriate use of these modalities in the workup of patients with suspected PAS.

Our study reported the specificity and sensitivity of ultrasound to be 29 % and 91%, respectively. Specificity and sensitivity for MRI were 20% and 75 %, respectively. The difference in the accuracy of the ultrasound and MRI reports was not statistically significant (p=0.791) when tested using Mcnemar's test. Findings reported in studies by Daney de Marcillac et al. and Chambon et al. were similar to our results (7, 26). Chambon et al. reported ultrasound specificity and sensitivity of 37% and 100%, respectively and MRI specificity and sensitivity of 50% and 77%, respectively (24). Daney de Marcillac et al. reported ultrasound specificity and sensitivity of 67% and 92%, respectively, and MRI specificity and specificity of 84% and 78%, respectively (26). A 2013 systematic review by Meng et al. also reported ultrasound to be more specific and sensitive than MRI. MRI had specificity and sensitivity of 88% and 82%, respectively; ultrasound had specificity and sensitivity of 95% and 83%, respectively (15).

Similar studies conducted in Egypt by Abdel Magied et al. and Hashem et al. reported differing results compared to ours. The study by Abdel Magied et al. of 23 patients reported ultrasound sensitivity and specificity of 63.6 % and 91.6%, respectively, whilst MRI reported sensitivity and specificity of 72.7% and 100%, respectively(27). A study by Hashem et al. of 25 patients reported ultrasound sensitivity and specificity of 68% and 79%, respectively. MRI reported sensitivity and specificity of 80 and 86%respectively (28).

A 2020 systematic review by Dahmarde et al. found MRI to be more specific and sensitive. MRI had specificity and sensitivity of 97% and 89%, respectively; ultrasound had specificity and sensitivity of 89% and 73%, respectively(16). The studies included in this cohort found MRI more accurate when the placenta was posteriorly positioned (16).

The afore-mentioned only other similar research comparing the accuracy of these imaging modalities in diagnosing PAS in South Africa was a 2004 prospective study by Moodley et al. comprising of 30 patients with placenta previa. Moodley et al. reported ultrasound specificity and sensitivity of 88% and 60%, respectively. Ultrasound Doppler sensitivity and specificity were reported to be 80% and 84%, respectively. The MRI sensitivity and specificity were reported to be 60% and 76%, respectively (14). Our study in comparison to study by Moodley et al. was similar in respect that our study cohort also had both ultrasound and MRI in a South African tertiary centre as well. The ultrasound findings in our cohort were not separated into gray scale and Doppler ultrasound findings as was done on the study by Moodley. The only risk factor considered in patient selection in the study by Moodley et al. was presence of placenta previa. Our study also differed in that it was a retrospective study, smaller in number and did not have ultrasound and MRI imaging in all patients. The prospective, deliberate ultrasound and MRI imaging of all placenta previa patients possibly yielded more patients for the study by Moodley et al. compared to our study.

Our study found reports by junior radiologists to be more accurate and to have higher specificity but much lower sensitivity than reports by senior radiologists. The differences were, however, not statistically significant. Our study's results agree with a study by Casagrande et al. (29). This study reported no statistically significant difference in the accuracy of PAS diagnosis between senior and junior general radiologists. This study reported that radiologists with experience in abdominal/pelvic MRI reporting were more accurate in the diagnosis of PAS in comparison to general MRI radiologist reports (29). Senior radiologists (>7 years of experience) with no specific abdominal/pelvic MRI reporting experience were found to have specificity and sensitivity of 64.3% and 80.4%, respectively (29). Junior radiologists in this study with no specific PAS reporting experience had specificity and sensitivity of 64.3% and 82.6%, respectively (29). The radiologists in our cohort had no known specific experience in abdominal/pelvic MRI reporting and were only compared by experience since qualification. This lack of specific abdominal or pelvic RMI reporting experience is likely the reason for lack of a difference between junior and senior radiologist reports.

A study by Alamo et al. showed that more experienced radiologists were more accurate than junior radiologists (30). The study showed senior radiologists had sensitivity and specificity of 90.90% and 75%, respectively, while junior radiologists had sensitivity and specificity of 81.8% and 61.8%, respectively(30). These results contradict the results of our study.

Limitations and strengths

The limitations of our study include a small number of patients, mainly due to the retrospective nature of the research and the limited data availability. The prevalence of placenta accreta is not known in our setting. Using the assumption of a prevalence of 8.6% from a study by Warshak et al. 2006, the sample size we required for a precision interval of 95%, with a margin error of 0.05 at 80% power, would have been 126 (22). The sample size of our study was only 19 patient reports, making it challenging to draw proper conclusions from the statistical findings. Compared to other studies by Abdel Magied et al., Hashem et al., Daney De Marcillac et al. and Chambon et al., our study had the smallest number of patients (7, 26-28). The study by Hashem et al. conducted in Egypt had the highest number of patients, with a total of 50 patients(28). The study by Daney Demarcillac had the lowest number with 22 patients(26). None of the comparable studies had the stipulated 126 patients.

Data availability constraints included the unavailability of MRI reports on PACS before June 2017. As imaging plays a significant role in this condition, the unavailability of image storage at the fetal medicine unit is a shortfall in our study. Image correlation of MRI and ultrasound images in our cohort would have been ideal, especially for patients in whom both modalities were truly positive for PAS when compared to histopathology or surgical findings. Our study was, however, primarily assessing report findings without reviewing images.

The radiologists reporting the MRI studies were not blinded to the ultrasound report findings, which may have led to unavoidable bias and improvement in the diagnostic accuracy of the MRI. Recording specific indications for patients referred for MRI could have further assisted in assessing the appropriateness of MRI in our cohort. This data was unfortunately unavailable from the ultrasound or MRI reports assessed. The data unavailability may have been due to the omission of the indication at the time of MRI reporting or to incomplete filling-in of the request forms when the MRI was requested.

One of the study's strengths was that all the reports analysed had histopathological or surgical repots to confirms or exclude PAS. The study findings reflect the different but essential roles of MRI and ultrasound in the presurgical work-up of patients with suspected PAS. These findings support the appropriate use of these modalities and the selection of multidisciplinary team members in a similar setting. As ours is only the second study in South Africa comparing imaging modality accuracy in patients with suspected PAS, it also highlights the clinical factors that contribute to the development of PAS in our patient population/ context. Recommendations

for future research based on our study could include prospective studies in patients with suspected PAS, the study of clinical outcomes and an analysis of management options.

Conclusion

Our study did not demonstrate statistically significant differences in the accuracy of ultrasound reports compared to MRI reports. These findings support the usefulness of ultrasound as an effective screening tool. MRI can help in select cases such as inconclusive ultrasound findings, suspected extrauterine organ involvement, posterior placenta and multiple gestations. Appropriate presurgical workup is also important in ensuring appropriate involvement of different multidisciplinary team members at the time of delivery, which is associated with better outcomes. Our study also did not demonstrate a statistically significant difference in accuracy between MRI reports by junior and senior radiologists.

Competing interests

The authors declare that they have no financial or personal relationship(s) that may have inappropriately influenced them in writing this article.

Author(s) contributions

Dr Sikhosonke Tsobo conceived the idea for the project, collected data and wrote the manuscript. Dr Jayshree Jeebodh, Dr Lungile Ngobese and Dr Maureen Ramantsi developed the idea and developed the final version of the manuscript as supervisors.

Funding information

The authors received no financial support for the research, authorship and /or publication of this article.

Data availability statement

The data supporting the findings of this study are available from the corresponding author, Dr Sikhosonke Tsobo, upon reasonable request.

Disclaimer

Views expressed in this submitted article are the author's own and not an official position of the institution.

Keywords used in this article

Placenta; creta; percreta; increta; accreta; PAS; previa; placentation

References

(1) Jauniaux E, Ayres-de-Campos D. 2018. FIGO consensus guidelines on placenta accreta spectrum disorders: Introduction. *Int J Gynaecol Obstet*, 140(3):261-64. DOI: 10.1002/ijgo.12406.

(2) Jauniaux E, Collins S, Burton GJ. 2018. Placenta accreta spectrum: pathophysiology and evidence-based anatomy for prenatal ultrasound imaging. *Am J Obstet Gynecol*, 218(1):75-87. DOI: 10.1016/j.ajog.2017.05.067.

(3) Silver RM, Barbour KD. Placenta accreta spectrum: accreta, increta, and percreta. (1558-0474 (Electronic)).

(4) Jauniaux E, Ayres-de-Campos D, Langhoff-Roos J*, et al.* 2019. FIGO classification for the clinical diagnosis of placenta accreta spectrum disorders. *Int J Gynaecol Obstet*, 146(1):20-24. DOI: 10.1002/ijgo.12761.

(5) Belfort MA, Shamshirsaz AA, Fox KA. 2018. The diagnosis and management of morbidly adherent placenta. *Semin Perinatol*, 42(1):49-58. DOI: 10.1053/j.semperi.2017.11.009.

(6) Riteau AS, Tassin M, Chambon G*, et al.* 2014. Accuracy of ultrasonography and magnetic resonance imaging in the diagnosis of placenta accreta. *PLoS One*, 9(4):e94866. DOI: 10.1371/journal.pone.0094866.

(7) Goh WA, Zalud I. 2016. Placenta accreta: diagnosis, management and the molecular biology of the morbidly adherent placenta. *J Matern Fetal Neonatal Med*, 29(11):1795-800. DOI: 10.3109/14767058.2015.1064103.

(8) Berkley EM, Abuhamad AZ. 2013. Prenatal diagnosis of placenta accreta: is sonography all we need? *J Ultrasound Med*, 32(8):1345-50. DOI: 10.7863/ultra.32.8.1345.

(9) Berkley EM, Abuhamad A. 2018. Imaging of Placenta Accreta Spectrum. *Clin Obstet Gynecol*, 61(4):755-65. DOI: 10.1097/grf.0000000000000407.

(10) Adam Y. An evaluation of the indications for caesarean sections at Chris Hani Baragwanath Academic Hospital2018. Available from: http://www.sajog.org.za/index.php/SAJOG/article/view/1226%J South African Journal of Obstetrics and Gynaecology

(11) Sentilhes L, Kayem G, Chandraharan E*, et al.* 2018. FIGO consensus guidelines on placenta accreta spectrum disorders: Conservative management. *International Journal of Gynecology & Obstetrics*, 140(3):291-98. DOI: https://doi.org/10.1002/ijgo.12410.

(12) Shamshirsaz AA, Fox KA, Salmanian B*, et al.* 2015. Maternal morbidity in patients with morbidly adherent placenta treated with and without a standardised multidisciplinary approach. *Am J Obstet Gynecol*, 212(2):218.e1-18.e9. DOI: https://doi.org/10.1016/j.ajog.2014.08.019.

(13) Moodley J, Ngambu Nf Fau - Corr P, Corr P. Imaging techniques to identify morbidly adherent placenta praevia: a prospective study. (0144-3615 (Print)).

(14) Meng X, Xie L, Song W. 2013. Comparing the diagnostic value of ultrasound and magnetic resonance imaging for placenta accreta: a systematic review and meta-analysis. *Ultrasound Med Biol*, 39(11):1958-65. DOI: 10.1016/j.ultrasmedbio.2013.05.017.

(15) Dahmarde H, Parooie F, Salarzaei M. 2020. Prenatal Diagnosis of Placental Invasion: A Systematic Review and Meta-analysis on Accuracy of Ultrasonography and MRI in Diagnosis of Placental Invasion. *Journal of Diagnostic Medical Sonography*, 36(5):446-61. DOI: 10.1177/8756479320929031.

(16) Pagani G, Cali G, Acharya G*, et al.* 2018. Diagnostic accuracy of ultrasound in detecting the severity of abnormally invasive placentation: a systematic review and meta-analysis. *Acta Obstet Gynecol Scand*, 97(1):25-37. DOI: 10.1111/aogs.13238.

(17) Comstock CH. 2005. Antenatal diagnosis of placenta accreta: a review. *Ultrasound Obstet Gynecol*, 26(1):89-96. DOI: 10.1002/uog.1926.

(18) Rac MW, Moschos E, Wells CE*, et al.* 2016. Sonographic Findings of Morbidly Adherent Placenta in the First Trimester. *J Ultrasound Med*, 35(2):263-9. DOI: 10.7863/ultra.15.03020.

(19) D'Antonio F, Timor-Tritsch IE, Palacios-Jaraquemada J*, et al.* 2018. First-trimester detection of abnormally invasive placenta in high-risk women: systematic review and meta-analysis. *Ultrasound Obstet Gynecol*, 51(2):176-83. DOI: 10.1002/uog.18840.

(20) Kilcoyne A, Shenoy-Bhangle AS, Roberts DJ*, et al.* 2017. MRI of Placenta Accreta, Placenta Increta, and Placenta Percreta: Pearls and Pitfalls. *AJR Am J Roentgenol*, 208(1):214-21. DOI: 10.2214/ajr.16.16281.

(21) Warshak CR, Eskander R, Hull AD*, et al.* 2006. Accuracy of ultrasonography and magnetic resonance imaging in the diagnosis of placenta accreta. *Obstet Gynecol*, 108(3 Pt 1):573-81. DOI: 10.1097/01.AOG.0000233155.62906.6d.

(22) Dwyer BK, Belogolovkin V, Tran L*, et al.* 2008. Prenatal diagnosis of placenta accreta: sonography or magnetic resonance imaging? *J Ultrasound Med*, 27(9):1275-81. DOI: 10.7863/jum.2008.27.9.1275.

(23) Lopes ES, Feitosa FEL, Brazil AV*, et al.* 2019. Assessment of Sensitivity and Specificity of Ultrasound and Magnetic Resonance Imaging in the Diagnosis of Placenta Accreta. *Rev Bras Ginecol Obstet*, 41(1):17-23. DOI: 10.1055/s-0038-1675803.

(24) Maher MA, Abdelaziz A, Bazeed MF. 2013. Diagnostic accuracy of ultrasound and MRI in the prenatal diagnosis of placenta accreta. *Acta Obstet Gynecol Scand*, 92(9):1017-22. DOI: 10.1111/aogs.12187.

(25) Daney de Marcillac F, Moliere S, Pinton A*, et al.* 2016. [Accuracy of placenta accreta prenatal diagnosis by ultrasound and MRI in a high-risk population]. *J Gynecol Obstet Biol Reprod (Paris)*, 45(2):198-206. DOI: 10.1016/j.jgyn.2015.07.004.

(26) Abdel Magied AM, Salah Eldin LA, Tohamey YM*, et al.* 2018. Placenta previa; MRI as an adjunct to ultrasound in assessment of suspected placental invasion. *The Egyptian Journal of Radiology and Nuclear Medicine*, 49(1):284-91. DOI: https://doi.org/10.1016/j.ejrnm.2017.12.010.

(27) Hashem LB, Salem DS, Hamed ST*, et al.* 2016. Role of MRI versus ultrasound in the assessment of placental abnormalities and diseases. *The Egyptian Journal of Radiology and Nuclear Medicine*, 47(2):641-58. DOI: https://doi.org/10.1016/j.ejrnm.2016.02.006.

(28) Ghezzi CLA, Silva CK, Casagrande AS*, et al.* 2021. Diagnostic performance of radiologists with different levels of experience in the interpretation of MRI of the placenta accreta spectrum disorder. *The British Journal of Radiology*, 94(1128):20210827. DOI: 10.1259/bjr.20210827.

(29) Alamo L, Anaye A Fau - Rey J, Rey J Fau - Denys A*, et al.* Detection of suspected placental invasion by MRI: do the results depend on observer' experience? , (1872-7727 (Electronic)).

Appendix 1: Table of Abbreviations

FMU-Fetal medicine unit.
HASTE- Half-Fourier Acquisition Single-shot Turbo spin Echo
MRI-Magnetic Resonance Imaging.
MOU-Midwife operated Unit
PAS-Placenta accreta spectrum.
VIBE- Volumetric Interpolated Breath-hold Examination
NHLS-National Health Laboratory Service

Appendix2: Tables with legends

Table 1: Table representing demographic and risk factor profiles of the patients with suspected PAS(included in the study).

Demographic and Clinical Characteristics	**mean(sd)**
Age (years)	30.95 (7.01)
Gravidity	3.21 (1.44)
Parity	2.00 (1.49)
Clinical risk factor profile:	**n (%);** N=19
Placenta Previa	16 (84.2)
Previous surgery:	
Previous caesarean section	12(63.2)
Previous non-caesarean uterine surgery or procedure(s).	7(37.0)
Previous caesarean section and other uterine surgery/procedure	5(26.3)
Placenta previa and previous caesarean section	9(47.4)
Placenta previa and caesarean section or other uterine surgery or procedure	11(57.9)

Table 2: Table demonstrating the accuracy of the MRI and ultrasound reports in patients with suspected PAS in comparison to histopathological or surgical findings

	True positive (n)	False positive (n)	True negative (n)	False negative (n)	Correct, n (%)	Incorrect n (%)
Ultrasound(N=18)	10	5	2	1	12(66.7)	6(33.3)
MRI(N=14)	6	4	2	2	8(57.1)	6(42.8)

Table 3: Table comparing the proportion of correctness for MRI vs ultrasound in discordant cases.

Histopathology/surgical findings	Ultrasound N=6		MRI N=6	
	Positive	Negative	Positive	Negative
Positive	1	1	2	1
Negative	2	2	2	1

Table 4: Table demonstrating the accuracy of ultrasound and MRI in the diagnosis of PAS

	Ultrasound n=18	**MRI n=14**
	(%)	(%)
Sensitivity	90.91	75.00
Specificity	28.57	20.00
Positive predictive value (PPV)	66.67	60.00
Negative predictive value (NPV)	66.67	33.33

Table 5: Table comparing the proportion of correctness for senior compared with junior radiologists

Radiologist Experience	Correct n (%)	Incorrect n (%)	True positive (n)	False positive (n)	True negative (n)	False negative (n)
Senior (N*=7)	4(57.1)	3(42.9)	3	2	1	1
Junior (N*=6)	4(66.7)	2(33.3)	4	2	0	0

*N=number of reports

Table 6: Table demonstrating the accuracy of junior and senior radiologist MRI reports in diagnosis of PAS compared to histopathological or surgical report findings

	Junior radiologists		Senior radiologists	
	N*=6	95% CI	N*=7	95% CI
Sensitivity	100	39.8-100	75	19.4-99.4
Specificity	0	0-84.2	33.3	0.8-90.6
Positive predictive value (PPV)	66.7	66.7-66.7	60.00	36-80
Negative predictive value (NPV)			50	8.8-91
***Number of reports by senior/junior radiologists**				

Appendix 3: Figures with legends

Figure 1: Data collection sheet for the patient ultrasound and MRI reports:

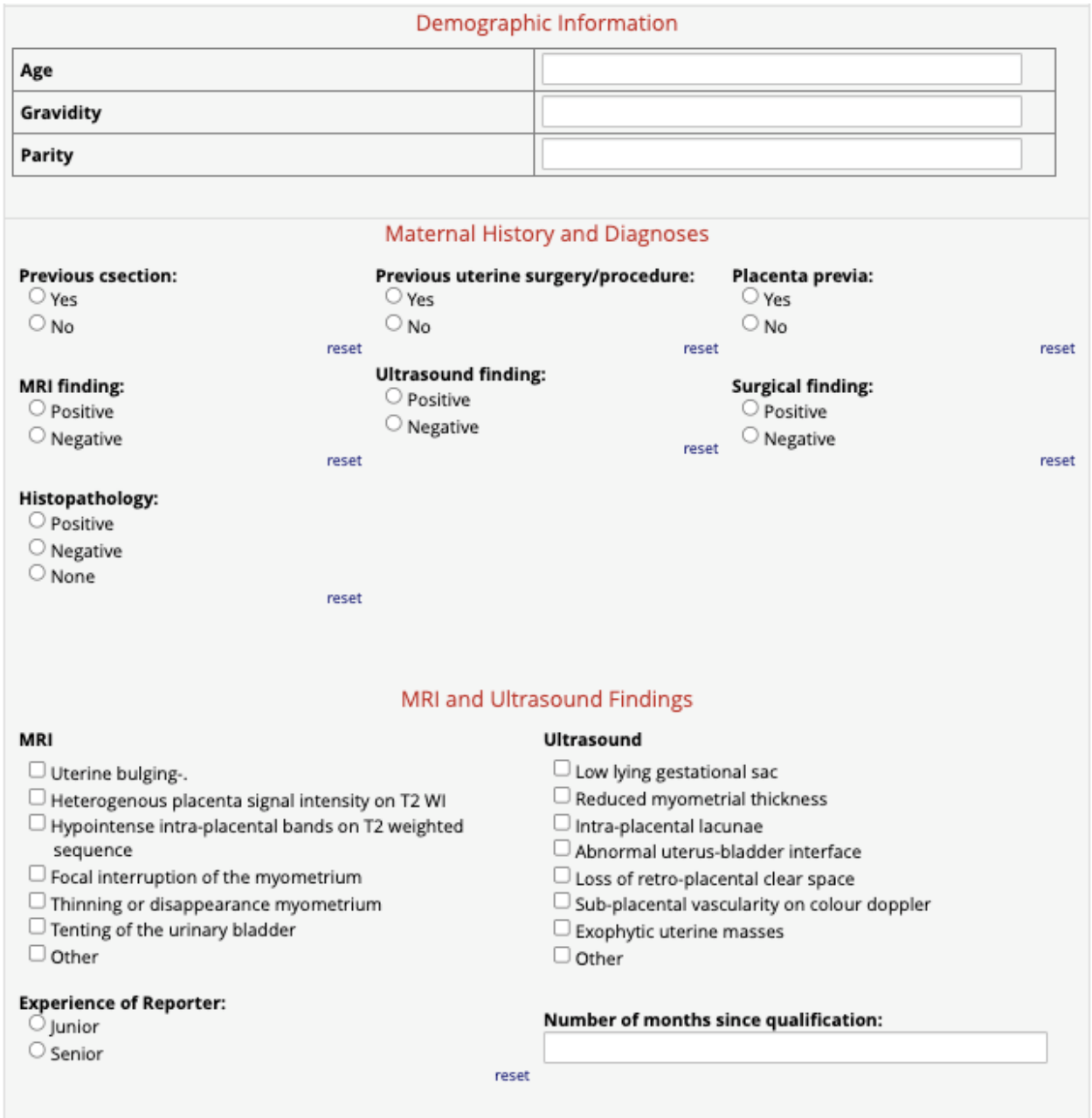

Demographic Information

Age	
Gravidity	
Parity	

Maternal History and Diagnoses

Previous csection: ○ Yes ○ No reset

Previous uterine surgery/procedure: ○ Yes ○ No reset

Placenta previa: ○ Yes ○ No reset

MRI finding: ○ Positive ○ Negative reset

Ultrasound finding: ○ Positive ○ Negative reset

Surgical finding: ○ Positive ○ Negative reset

Histopathology: ○ Positive ○ Negative ○ None reset

MRI and Ultrasound Findings

MRI

- ☐ Uterine bulging-.
- ☐ Heterogenous placenta signal intensity on T2 WI
- ☐ Hypointense intra-placental bands on T2 weighted sequence
- ☐ Focal interruption of the myometrium
- ☐ Thinning or disappearance myometrium
- ☐ Tenting of the urinary bladder
- ☐ Other

Ultrasound

- ☐ Low lying gestational sac
- ☐ Reduced myometrial thickness
- ☐ Intra-placental lacunae
- ☐ Abnormal uterus-bladder interface
- ☐ Loss of retro-placental clear space
- ☐ Sub-placental vascularity on colour doppler
- ☐ Exophytic uterine masses
- ☐ Other

Experience of Reporter: ○ Junior ○ Senior reset

Number of months since qualification:

None= no histopathology report was found.

Figure 2: Figure demonstrating study cohort selection with inclusions and exclusions

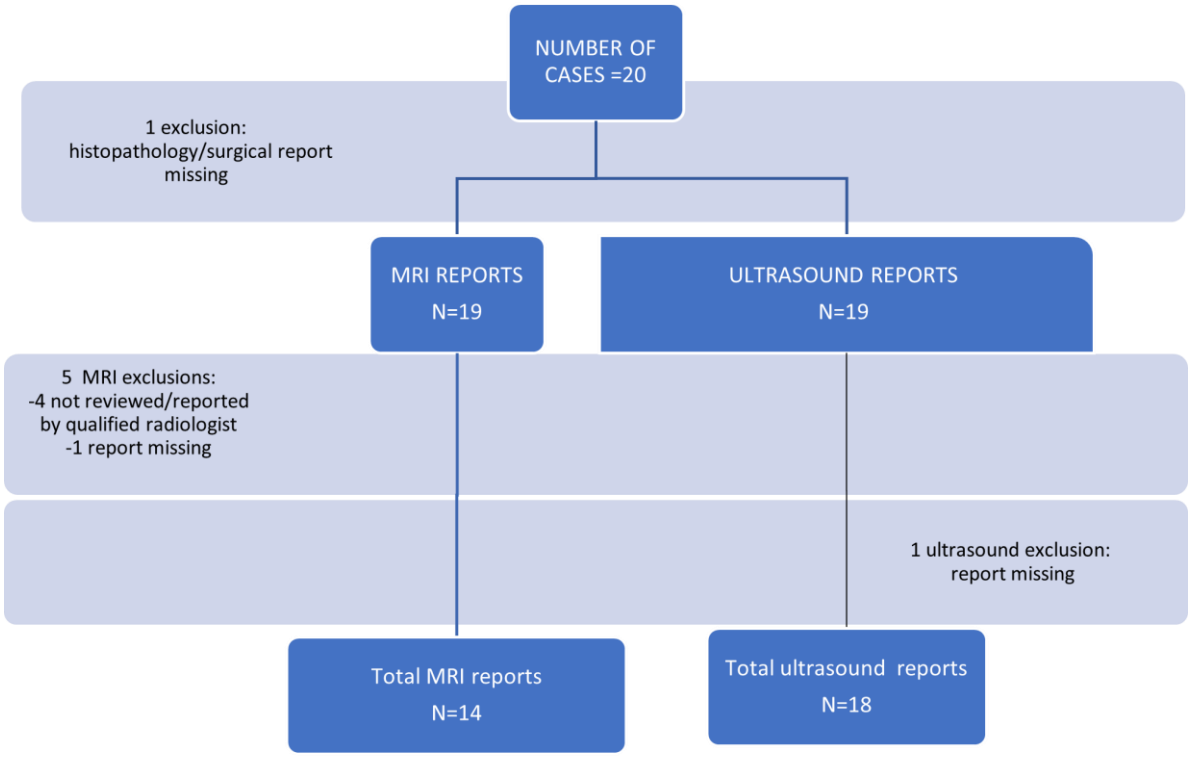

Figure 4: Axial(A) and Sagittal(B) T2WI Abdo-pelvic demonstrating right posterolateral focal interruption of the myometrium at the placenta/myometrium interface with placenta visualised in the right perirectal space, paravesical fossa and parailiac space(encased internal and external iliac vessels) in keeping with placenta percreta (arrows). Histopathology-proven case.

A

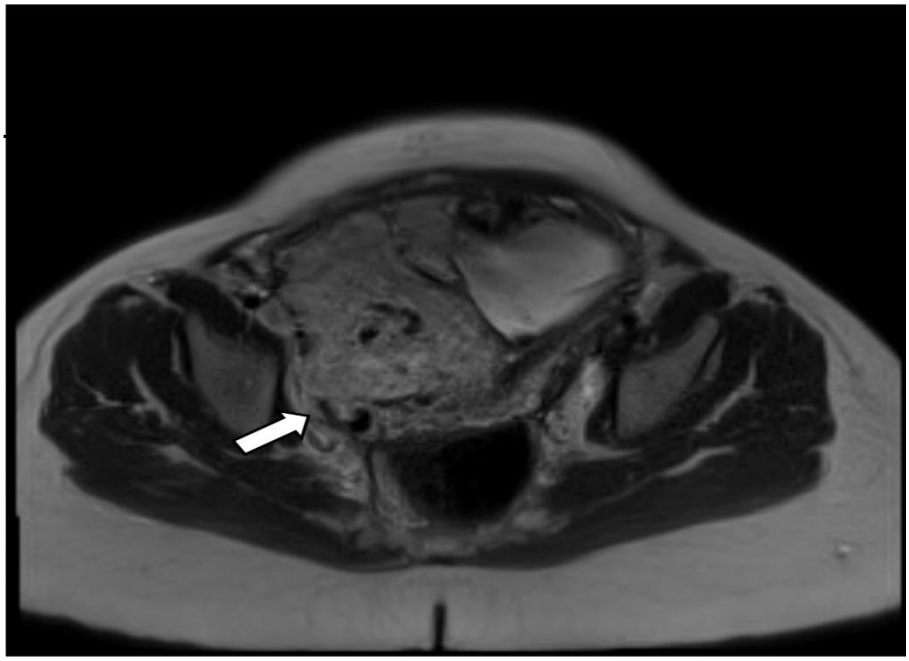

B

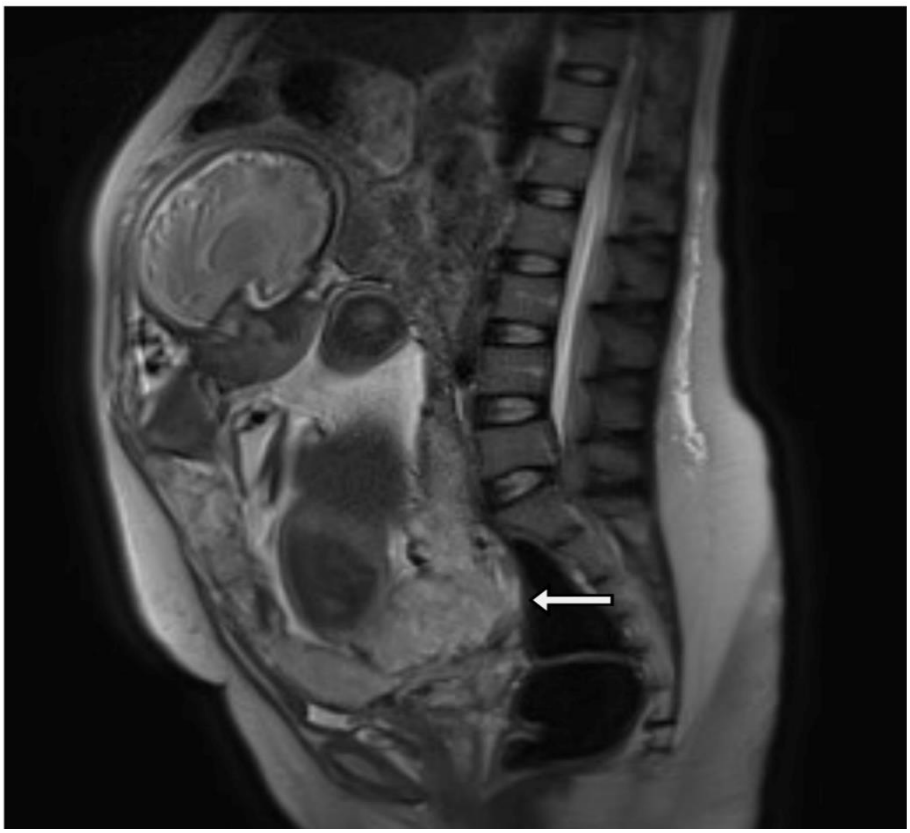

Figure 5: (A)sagittal and coronal(B) T2WI Abdo-pelvic MRI demonstrating anterior placenta focal uterine bulge and focal interruption of the myometrium at the placenta/myometrium interface. Histopathology-proven placenta increta.

A



B

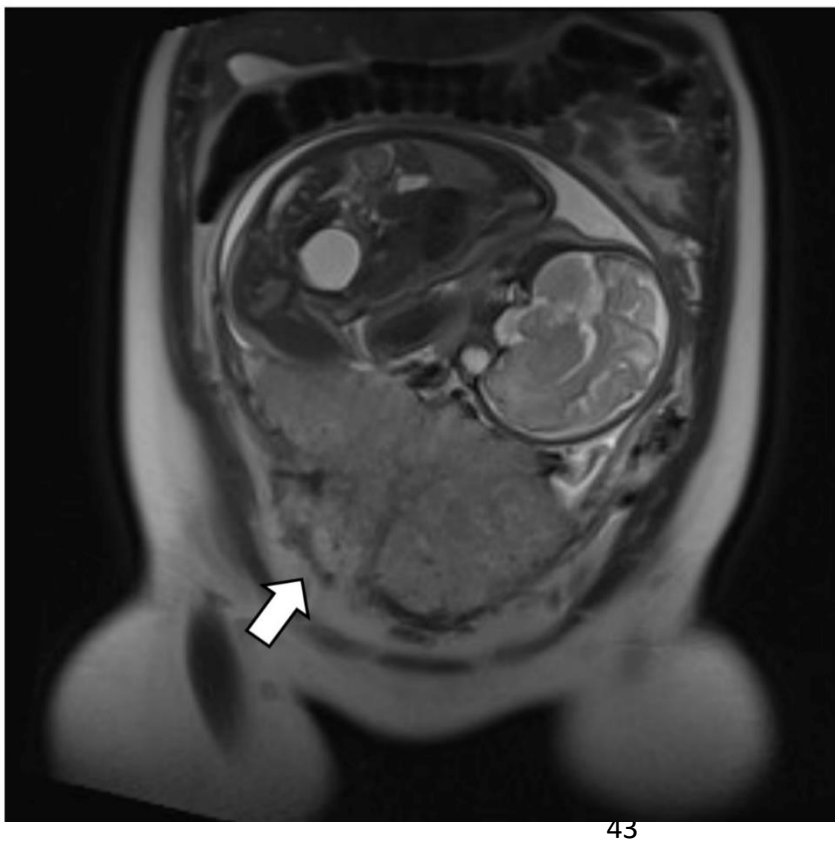

Figure 6: histopathology slide (10x magnification) demonstrating placenta accreta in one of the patients in our cohort. Chorionic villi (black arrow) are implanted directly on the surface of the myometrium (white star) without intervening decidua (Haematoxylin and eosin). Slide provided by Chris Hani Baragwanath Academic Hospital National Health Laboratory Service.

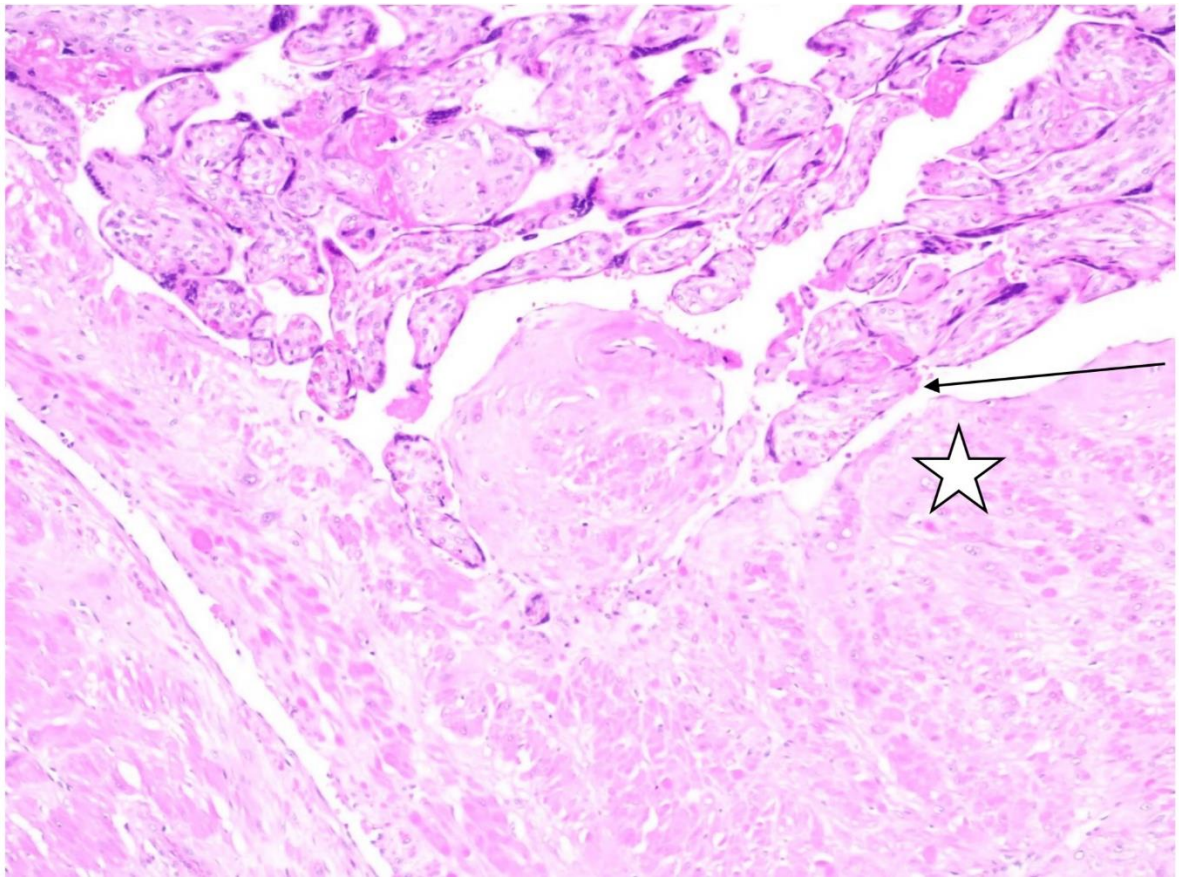

Appendix 4: Graphs with legends

Graph 1: Graphical representation of the signs reported in ultrasound true positive reports

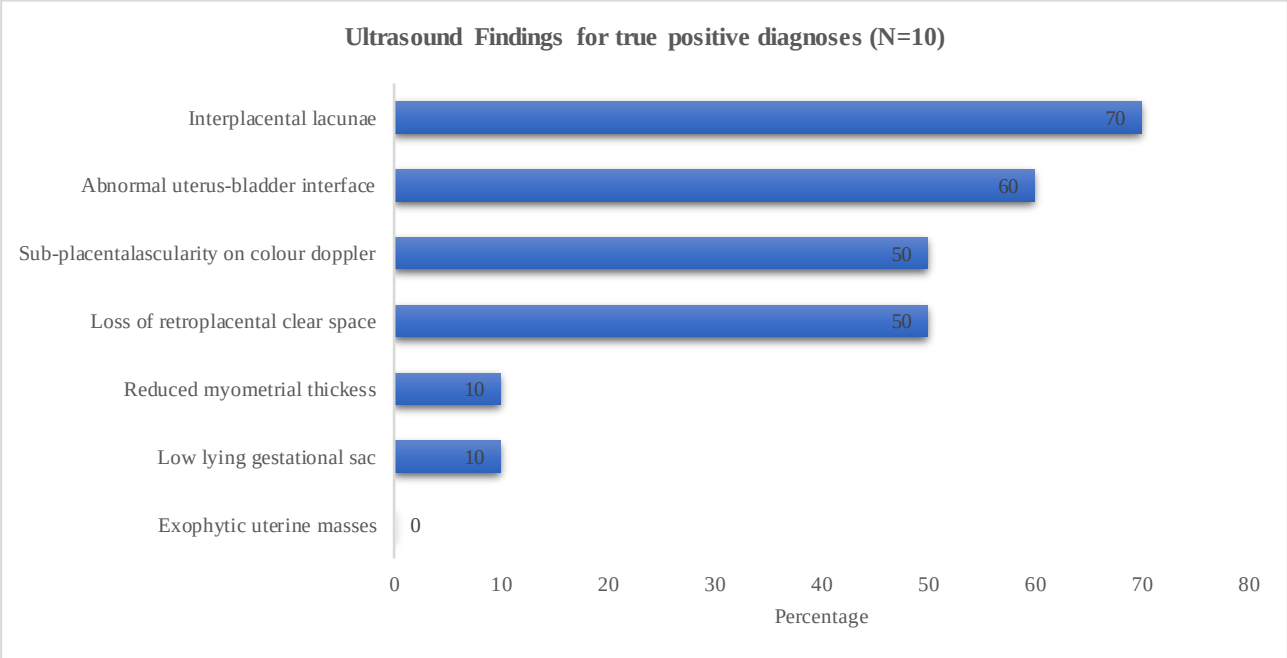

Graph 2: Graphical representation of the signs reported in MRI true positive reports

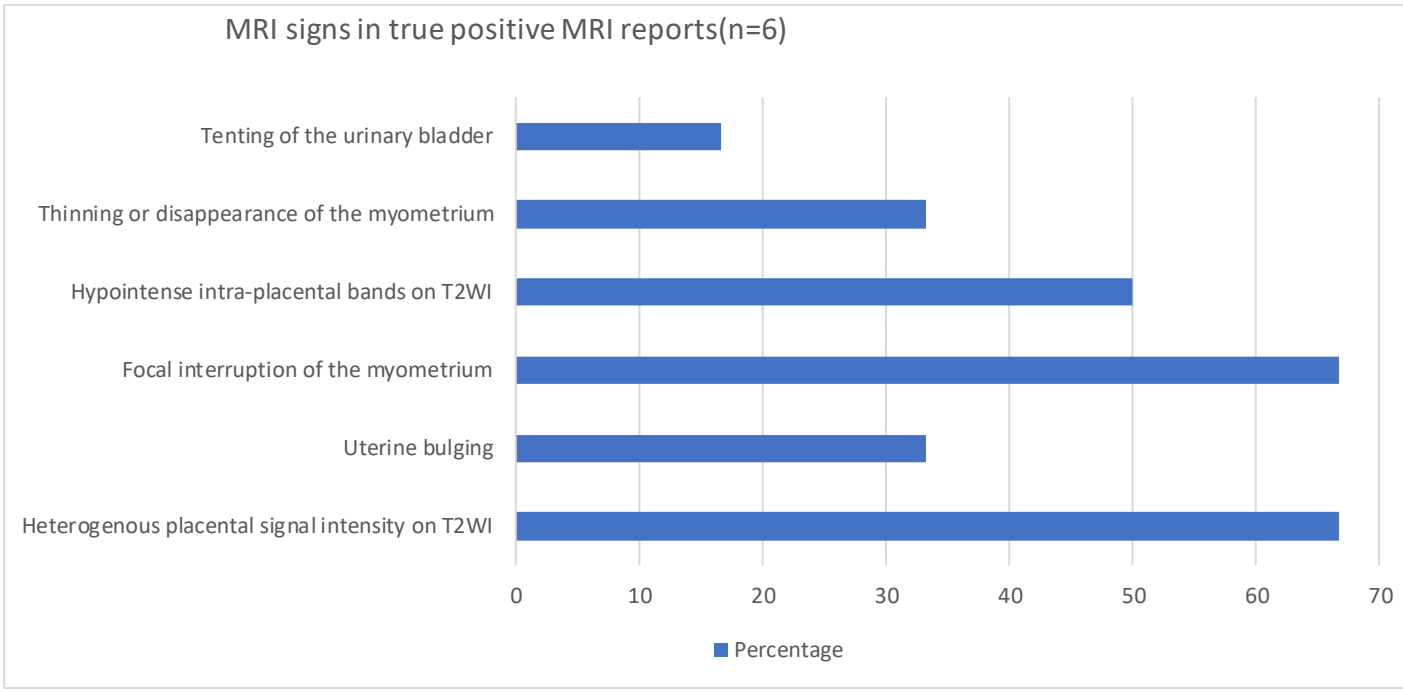

Appendix 5: Ethics Clearance Certificate

UNIVERSITY OF THE WITWATERSRAND JOHANNESBURG

R14/49 Dr S Tsobo

HUMAN RESEARCH ETHICS COMMITTEE (MEDICAL)
CLEARANCE CERTIFICATE NO. M200260

NAME: (Principal Investigator)	Dr S Tsobo
DEPARTMENT:	School of Clinical Medicine Department of Radiation Sciences Division of Diagnostic Radiology Medical School University
PROJECT TITLE:	Comparison of Ultrasound and Magnetic Resonance Imaging in patients with suspected Placenta Accreta Spectrum at Chris Hani Baragwanath Academic Hospital
DATE CONSIDERED:	2020/02/28
DECISION:	Approved unconditionally
CONDITIONS:	
SUPERVISOR:	Drs L Ngobese, J Jeebodh and M Ramantsi
APPROVED BY:	Dr CB Penny, Chairperson, HREC (Medical)
DATE OF APPROVAL:	2020/09/15

This clearance certificate is valid for 5 years from the date of approval. Extension may be applied for.

DECLARATION OF INVESTIGATORS

To be completed in duplicate and **ONE COPY** returned to the Research Office Secretary on the 3rd Floor, Phillip Tobias Building, Parktown, University of the Witwatersrand, Johannesburg.
I/we fully understand the conditions under which I am/we are authorized to carry out the above-mentioned research and I/we undertake to ensure compliance with these conditions. Should any departure be contemplated, from the research protocol as approved, I/we undertake to submit details to the Committee. I agree to submit a yearly progress report. When a funder requires annual re-certification, the application date will be one year after the date when the study was initially reviewed. In this case, the study was initially reviewed in **February** and will therefore reports and re-certification will be due early in the month of **February** each year. Unreported changes to the application may invalidate the clearance given by the HREC (Medical).

Principal Investigator Signature _____ Date _____

Appendix 6: Turnitin Report

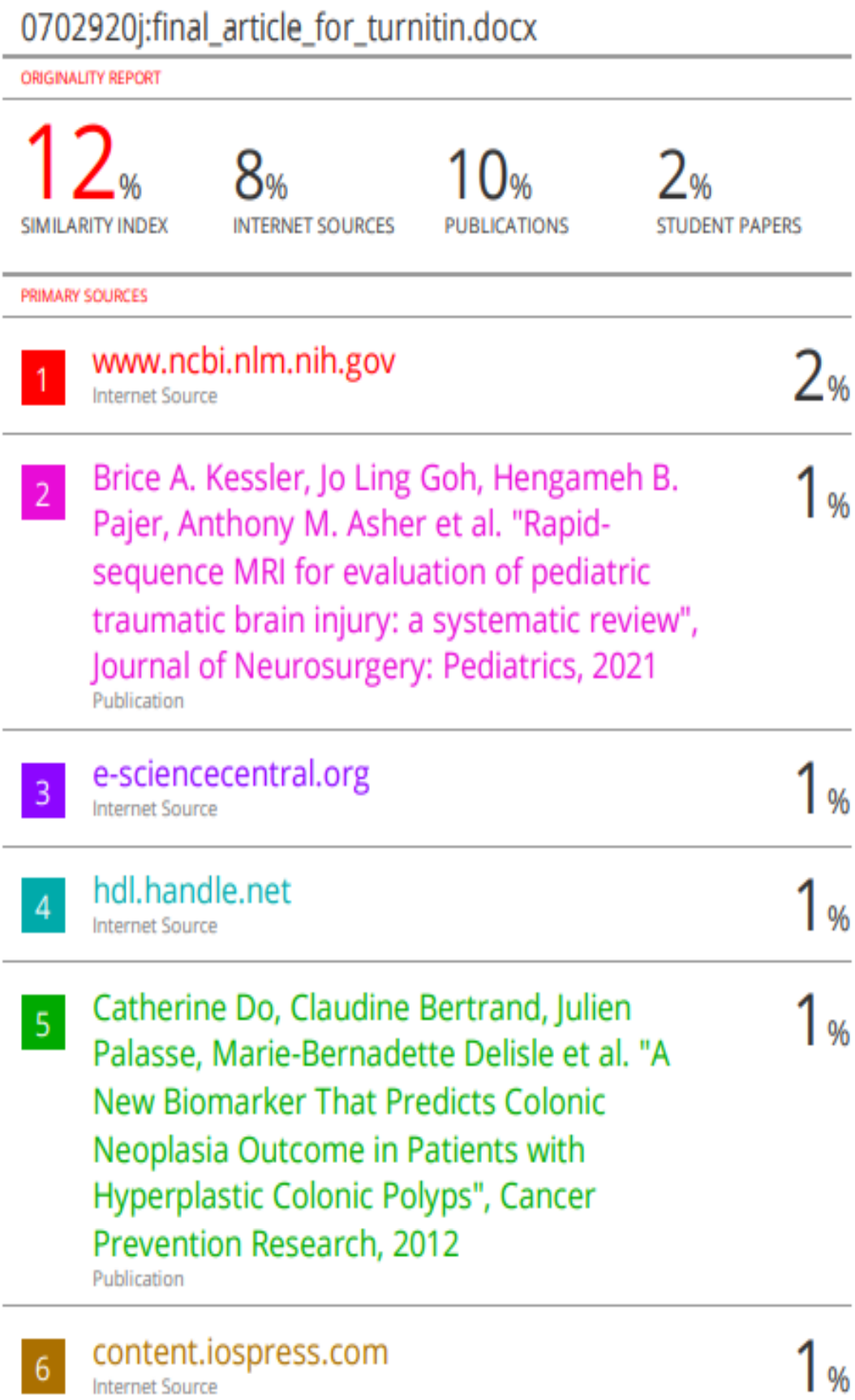

0702920j:final_article_for_turnitin.docx

ORIGINALITY REPORT

12%	8%	10%	2%
SIMILARITY INDEX	INTERNET SOURCES	PUBLICATIONS	STUDENT PAPERS

PRIMARY SOURCES

1	www.ncbi.nlm.nih.gov Internet Source	2%
2	Brice A. Kessler, Jo Ling Goh, Hengameh B. Pajer, Anthony M. Asher et al. "Rapid-sequence MRI for evaluation of pediatric traumatic brain injury: a systematic review", Journal of Neurosurgery: Pediatrics, 2021 Publication	1%
3	e-sciencecentral.org Internet Source	1%
4	hdl.handle.net Internet Source	1%
5	Catherine Do, Claudine Bertrand, Julien Palasse, Marie-Bernadette Delisle et al. "A New Biomarker That Predicts Colonic Neoplasia Outcome in Patients with Hyperplastic Colonic Polyps", Cancer Prevention Research, 2012 Publication	1%
6	content.iospress.com Internet Source	1%

7	"SIOP ABSTRACTS", Pediatric Blood & Cancer, 2019 Publication	<1 %
8	Mohammad Ali Mohseni-Bandpei, Masoomeh Nakhaee, Mohammad Ebrahim Mousavi, Ali Shakourirad et al. "Application of Ultrasound in the Assessment of Plantar Fascia in Patients With Plantar Fasciitis: A Systematic Review", Ultrasound in Medicine & Biology, 2014 Publication	<1 %
9	sajhivmed.org.za Internet Source	<1 %
10	F. D'Antonio, C. Iacovella, J. Palacios-Jaraquemada, C. H. Bruno, L. Manzoli, A. Bhide. "Prenatal identification of invasive placentation using magnetic resonance imaging: systematic review and meta-analysis", Ultrasound in Obstetrics & Gynecology, 2014 Publication	<1 %
11	M. R. Fisher, G. J. Criner, A. P. Fishman, P. M. Hassoun, O. A. Minai, S. M. Scharf, a. H. E. Fessler. "Estimating pulmonary artery pressures by echocardiography in patients with emphysema", European Respiratory Journal, 2007 Publication	<1 %

12	N Lack. "Comparison of non-invasive sampling methods for detection of HPV in rural African women", Sexually Transmitted Infections, 6/1/2005 Publication	<1 %
13	Karyn L Moshal, Neil McKerrow, Kimesh Naidoo. "Obstacles and inspirations, lessons and limitations in the management of paediatric HIV: specialist paediatric HIV services in the UK and the provincial paediatric HIV service in KwaZulu-Natal, South Africa", Paediatrics and Child Health, 2007 Publication	<1 %
14	journals.lww.com Internet Source	<1 %
15	www.worldwidejournals.com Internet Source	<1 %
16	www.repository.cam.ac.uk Internet Source	<1 %
17	www.thieme-connect.com Internet Source	<1 %
18	Christopher E. Orlikowski, D. Anthony Rocke. "THE COAGULOPATHIC PARTURIENT", Anesthesiology Clinics of North America, 1998 Publication	<1 %
19	academic.oup.com Internet Source	

		<1 %
20	obgyn.pericles-prod.literatumonline.com Internet Source	<1 %
21	www.ajronline.org Internet Source	<1 %
22	Submitted to Anglia Ruskin University Student Paper	<1 %
23	www.hexaflux-sms.com Internet Source	<1 %
24	Biao Yuan, Yi Yu. "High-resolution transmission electron microscopy of beam-sensitive halide perovskites", Chem, 2022 Publication	<1 %
25	www.cadth.ca Internet Source	<1 %
26	www.jrheum.org Internet Source	<1 %
27	Philip S. Lim, Marianne Greenberg, Mitchell I. Edelson, Karen A. Bell, Pamela R. Edmonds, Amy M. Mackey. "Utility of Ultrasound and MRI in Prenatal Diagnosis of Placenta Accreta: A Pilot Study", American Journal of Roentgenology, 2011 Publication	<1 %

28	Sitthipong Srisajjakul, Patcharin Prapaisilp, Sirikan Bangchokdee. "MRI of Placenta Accreta Spectrum: A Step-by-Step Approach", Korean Journal of Radiology, 2020 Publication	<1 %
29	Yuliya Pinevich, Adam Amos-Binks, Christie S Burris, Gregory Rule et al. "Validation of a Machine Learning Model for Early Shock Detection", Military Medicine, 2022 Publication	<1 %
30	cvip.computing.dundee.ac.uk Internet Source	<1 %
31	www.science.gov Internet Source	<1 %
32	F. Finazzo, F. D'antonio, G. Masselli, F. Forlani et al. "Interobserver agreement in MRI assessment of severity of placenta accreta spectrum disorders", Ultrasound in Obstetrics & Gynecology, 2020 Publication	<1 %

Exclude quotes	On	Exclude matches	< 5 words
Exclude bibliography	On		

Appendix 7:Original protocol with extended literature review

Comparison of Ultrasound and Magnetic Resonance Imaging findings in patients with suspected placenta accreta spectrum at Chris Hani Baragwanath Academic Hospital.

Sikhosonke Tsobo
Student number: 0702920J
Course registered for:
Fellowship of Diagnostic Radiology

Supervisors:
Dr J Jeebodh (Consultant- Department Of Obstetrics and Gynaecology-Chris Hani Baragwanath Academic Hospital)
Dr M Ramantsi (Consultant-Department of Diagnostic Radiology-Chris Hani Baragwanath Academic Hospital)
Dr L Ngobese(Consultant-Division of Anatomical Pathology, Chris Hani Baragwanath Academic Hospital)

Table of contents

Table of contents **55**

1. Rationale **57**

2. Introduction **18**

2.1. Definition 57

2.1.1 Placenta accreta spectrum 57

2.2. Clinical Presentation 57

2.3. Epidemiology 19

2.4. Risk factors 58

2.5. Investigations of PAS 58

2.5.1. Ultrasound Findings 59

2.5.2. MRI findings 59

2.5.3. Surgical report findings 60

2.5.4 Histopathology report findings 60

2.5.5. Comparison of ultrasound and MRI accuracy 61

2.5.6. Radiologist experience and accuracy of MRI findings 63

2.6. The project in context: Comparison to literature 63

3. Aims **63**

4. Study Objectives **64**

5. Methods **20**

5.1. Setting 20

5.2 Research paradigm 65

5.3 Sample 65

5.3.1. Inclusion criteria 65

5.3.2. Exclusion criteria 65

5.4. Materials and Methods 66

5.5. Data collection 67

5.6. Reliability and validity 23

5.7. Bias 67

6. Data analysis and statistics **68**

7. Ethics **23**

7.1. Data Safety 68

8. Timing **69**

9. Budget 70

10. Anticipated problems 70

11. References 32

1. Rationale

The purpose of the study is to describe and compare Magnetic Resonance Imaging(MRI) and ultrasound findings in patients with suspected placenta accreta spectrum (PAS) disorder at Chris Hani Baragwanath Academic Hospital using histopathology as a gold standard or surgical findings where histopathology report is absent.

2. Introduction

2.1. Definitions

2.1.1 Placenta accreta spectrum

Placenta accreta spectrum is a complex disorder of placentation whereby damage to the endometrium-myometrial interface and subsequent absent re-epithelialisation and scarring results in an abnormally adherent placenta(1-3). The abnormal attachment of the placenta leads to difficulty in placenta delivery with associated intrapartum and postpartum haemorrhage. (2, 3)

This disorder has previously had various names in literature such as placental adhesive disorder, abnormally adherent placenta, abnormal placental disorder, abnormally adherent placenta, placenta creta, placenta accreta etc (1, 4). Abnormal placenta attachment subtypes are classified according to the level of invasion at the placenta/myometrium interface(3). Placenta accreta whereby the placenta is attached to the myometrium without invading the myometrium(3). Placenta increta is when there is abnormal placenta attachment with an invasion of the myometrium(3). Placenta percreta is a subtype whereby there is placental invasion and attachment beyond the serosa into the surrounding pelvic or abdominal organs(3). The International Federation of Gynecology and Obstetrics (FIGO) recommends the term “placenta accreta spectrum”(PAS) instead of the various subtypes individually (1). The term PAS ensures standardized nomenclature and is inclusive of the various subtypes (1).

2.2. Clinical Presentation

Patients with PAS are largely asymptomatic and in some cases are diagnosed for the first time during vaginal delivery or caesarean section(4). Symptomatic presentation is related to the presence of placenta previa and level of invasion including vaginal bleeding, hypovolemic shock, hypotension, abdominal cramps and premature delivery (1, 4, 9).

2.3. Epidemiology

Studies have reported a global increase in the incidence of PAS with an associated increase in the caesarean section rate(31). In the USA, there has been an increased incidence of PAS from 1 in 30 000 births in 1937 to 1 in 553 births in 2005(31). This increased PAS incidence was associated with an increase in caesarean delivery rate which was reported to have increased from 12.5% to 23.5% between 1982 and 2002. (31)

2.4. Risk factors

The most common risk factor is a previous caesarean section(1, 4, 31). The risk of PAS is reported to be 8.7 times higher in patients with previous caesarean delivery and the risk increases with an increase in the number of previous caesarean sections (5, 7, 31). Other risk factors for abnormal placentation are previous uterine surgery, advanced maternal age, multiparty, hypertension, smoking, uterine leiomyomas, previous uterine irradiation, in vitro fertilisation and placenta previa (1, 3, 8, 9).

2.5. Diagnosing PAS

Due to a large number of asymptomatic presentations, clinical history and risk factor profile guide prenatal diagnosis of PAS (9). Prenatal diagnosis of PAS is made via ultrasound and MRI with varying levels of accuracy(15, 16).

Ultrasound is used as the primary investigation of choice in patients at risk of PAS(9, 10). Magnetic resonance imaging (MRI) use is recommended in cases where the placenta cannot be adequately assessed by ultrasound and surgical planning. These are cases such as posterior placenta position, suspected extrauterine invasion, obese patients and multiple gestations(5, 10).

The gold standard for diagnosis of PAS is histopathology (5). Histopathology findings are dependent on the specimen being examined and are laboratory-dependent(32). Various types of histology specimens that can be examined include hysterectomy, placenta and curettage specimens (32).

Definitive diagnosis of a morbidly adherent placenta can also be made intra-operatively or during vaginal delivery. Intra-operative findings of an adherent placenta have been regarded as the gold standard in studies where there was no available histopathology examination report (4). These intraoperative findings, however, tend to be subjective with inter-observer variability (4).

2.5.1. Ultrasound Findings

Transvaginal and transabdominal ultrasound approaches are both used in imaging patients with suspected PAS(10). The transvaginal approach is superior in the assessment of cervical and bladder invasion (10). Additional use of doppler examination improves the assessment of vascularity of the uterus and placenta(10).

A positive ultrasound diagnosis for placenta accreta spectrum on ultrasound must report on one or a some of the following features(17):

1. Low lying gestational sac is defined as a gestational sac which is positioned anteriorly in the uterus, within 2cm of the internal cervical os. (18, 20)
2. Reduced myometrial thickness is defined as focally thin myometrium(<1mm) underlying the gestational sac(17, 19).
3. Intra-placental lacunae are findings of both grayscale and doppler mode described as multiple, irregular placental anechoic lesions that demonstrate turbulent flow(17).
4. Abnormal uterus-bladder interface describes irregularity of the normally clear hyperechoic interface between the uterus and the bladder. (17, 20)
5. Loss of retro-placental clear space is defined as the absence or irregularity of the normally hypoechoic placenta-myometrial plane(17).
6. Sub-placental vascularity on colour doppler is defined as a large retro-placental colour Doppler signal (17)
7. Exophytic uterine masses are defined as placental tissue visualized through and beyond the uterine serosa and visualized in the urinary bladder(17).

Intraplacental lacunae is the most sensitive and specific ultrasound sign followed by loss of retroplacental clear space(17, 18). In a systematic review by Pagani et al., the sensitivity and specificity of intraplacental lacunae were 74.8-88.6% and 45.2-81.2% respectively depending on the PAS subtype (17). The sensitivity and specificity of loss of retroplacental clear space were 74.9-91.6% and 71.1%-92% depending on the PAS subtype (17). These signs are most accurate in the second and third semesters (20). Low anterior implantation of the gestational sac is the most sensitive and specific ultrasound sign in the first trimester(20). The sensitivity and specificity of low anterior implantation are 44.4% and 93.4% respectively(20).

2.5.2. MRI findings

A positive MRI diagnosis for placenta accreta spectrum on MRI must report on the following one or some of the following features (33)

1. Uterine bulging- is defined as a focal outward protrusion in the uterine contour(33).
2. Heterogenous placenta signal intensity on T2 weighted sequence is defined as loss of the normally homogenously intermediate signal of the placenta. (33, 34).

3. Hypointense intra-placental bands on the T2 weighted sequence are defined as thick, irregular, randomly distributed hypointense bands within the placenta extending from the myometrium into the placenta. (33, 34).
4. Loss of retroplacental clear space is described as interruption of the interface between placenta and myometrium on T2 weighted images- that is normally low signal intensity layers on either side of an intermediate signal intensity middle layer. (34).
5. Thinning or disappearance of the myometrium is described as a focal area of thinning in comparison to the rest of the myometrium.
6. Tenting of the urinary bladder describes a change in bladder shape with an impression on the bladder wall by the invading placenta and loss of the uterine-bladder interface (21).

A systemic review by Familiari et al reported dark intraplacental bands and heterogenous placental signal intensity as the most sensitive signs for PAS with sensitivities of 87.6% and 80.9% respectively(35). The most specific signs of PAS were bladder tenting and abnormal intraplacental vascularity with specificities of 81.5% and 83.2% respectively(35).

2.5.3. Surgical report findings

A positive surgical diagnosis for placenta accreta spectrum patient records must report on the following one or some of the following features(4):

1. Placenta separated completely.
2. Placenta partially separated(4).
3. Grossly adherent placenta(4).
4. Surgical diagnosis of a percreta: Visualization of placental tissue through the serosa(4).
5. Placental tissue is visualised invading the pelvic organs(4).

2.5.4 Histopathology report findings

A positive histopathologic diagnosis for placenta accreta spectrum in histopathology report must report on the following one or some of the following features:

1. partial or absence of the decidua basalis with placental villi adhering directly to, or invading the myometrium in postpartum hysterectomy specimen microscopic examination. (32).
2. Placenta microscopic examination shows a layer of myometrial fibres adherent to the placenta without intervening decidua (32).
3. In post-partum curettage samples, presence of chorionic villi and trophoblast without decidua in and amongst smooth muscle fibres (32).

2.5.5. Comparison of ultrasound and MRI prenatal diagnosis accuracy

2.5.5.1 Global literature

A 2020 systematic review of 17 studies by Dahmarde et al, found MRI to be more specific and sensitive. MRI had specificity and sensitivity of 97% and 89% respectively; ultrasound had specificity and sensitivity of 89% and 73% respectively(16). A 2013 systematic review by Meng et al, reported of 13 studies reported ultrasound to be more specific and sensitive in comparison to MRI. MRI had specificity and sensitivity of 88% and 82% respectively; ultrasound had specificity and sensitivity of 95% and 83% respectively (15).

2.5.5.2 South African studies

The only similar study in South Africa was a 2004 prospective study at King Edward VIII hospital, Nelson R Mandela School of Medicine, Durban, KwaZulu Natal. The study reported ultrasound to be more specific and sensitive compared to MRI in the diagnosis of PAS (14). The afore-mentioned only other similar study in South Africa by Moodley et al was a 2004 prospective study of 30 patients with placenta previa. Moodley et al. reported ultrasound specificity and sensitivity of 88% and 60% respectively. Ultrasound Doppler sensitivity and specificity were reported to be 80% and 84% respectively. The MRI sensitivity and specificity were reported to be 60% and 76% respectively (14).

2.5.5.3 Studies in the rest of Africa

Similar studies conducted in the rest of the continent include studies from Egypt by Abdel Magied et al. and Hashem et al. The study by Abdel Magied et al of 23 patients reported ultrasound sensitivity and specificity of 63.6 % and 91.6% respectively whilst MRI reported sensitivity and specificity of 72.7% and 100% respectively(27). A study by Hashem et al of 25 patients reported ultrasound sensitivity and specificity of 68% and 79% respectively. MRI reported sensitivity and specificity of 80 and 86%respectively (28).

As mentioned above, the studies similar to our project comparing the accuracy of ultrasound and MRI findings in PAS have reported various results; below is a table(Table 1) summarising their findings.

Table 1: comparison of similar studies comparing ultrasound and MRI accuracy in suspected Placenta accreta spectrum including the number of patients reviewed and the country of the study.

Author and year of study	Country	Number of patients	Ultrasound		MRI	
			Sensitivity	Specificity	Sensitivity	Specificity
Moodley, Ngambu and Corr 2004(14)	South Africa	30	60-80%	84-880%	60%	76%
Warshak et al 2006(22)	United States of America	39	77%	98%	88%	100%
Dwyer et al 2006(23)	United States of America	32	93%	71%	80%	65%
Maher et al 2012 (25)	Saudi Arabia	63	95.1%	95.5%	85.7%	76.9%
Chambon et al 2014 (7)	France	42	100%	37.5%	76.9%	50%
Daney de Marcillac et al 2016 (26)	France	22	92%	67%	84%	78%
Hashem et al. 2016 (28)	Egypt	25	68%	79%	80%	86%
Lopes et al 2018(24)	Brazil	37	88%	44%	92.9%	43%
Abdel Magied et al 2018 (27)	Egypt	23	63.64%	91.67%	72.73%	86.96%

2.5.6. Radiologist experience and accuracy of MRI findings

Studies that have investigated the influence of radiologist experience on the interpretation of MRI studies in PAS have found experienced readers to be more accurate.

A study by Alamo et al composed of 25 patients with suspected PAS reported sensitivity to be 90.9% and 81.8% for senior and junior radiologists respectively. Specificity was reported to be 75 % and 61.8% for senior and junior radiologists respectively. The junior readers in this study had experience of less than 3 years and the senior radiologist had experience of 5 or more years (30).

A similar study by Millischer et al. showed similar results with a reported sensitivity of 62.5% and 87.5% for junior and senior radiologists respectively. Specificity was reported to be 33.3% and 62.5% for junior and senior radiologists respectively. The junior radiologists in this study had experience of less than 2 years and the senior radiologists had experience of 5 or more years(36).

A study by Casagrande et al (29) found slightly different results from the above-mentioned studies. This study reported no statistically significant difference in the accuracy of PAS diagnosis between senior and junior general radiologists. This study reported that radiologists with experience in abdominal/pelvic MRI reporting were more accurate in the diagnosis of PAS in comparison to general MRI radiologist reports (29). Senior radiologists (>7 years of experience) with no specific abdominal/pelvic MRI reporting experience, were found to have specificity and sensitivity of 64.3% and 80.4% respectively (29) and junior radiologists in this study with no specific PAS reporting experience had specificity and sensitivity of 64.3% and 82.6% respectively (29).

2.6. The project in context: Comparison to literature

This study in the context of the literature will determine the findings of antenatal ultrasound and MRI imaging findings and compare these findings with histopathology or surgical findings as to the gold standard in our cohort of patients.

3. Aims

This study aims to describe our current prenatal detection of PAS and determine our institute's specificity and sensitivity in the diagnosis of PAS. These findings may improve reporting and antenatal diagnosis and hence, surgical planning of this life-threatening condition.

The institute already has a dedicated multi-disciplinary team involved in the care of all suspected patients with PAS.

4. Study Objectives

Primary objective

2. To compare MRI and Ultrasound findings in patients with suspected PAS.

Secondary Objectives

1. To compare MRI and ultrasound findings with histopathology or surgical findings(in the absence of histopathological reports).
2. Compare junior and senior MRI radiologist reports with surgical and histological outcomes.

5. Methods

5.1. Setting

Chris Hani Baragwanath Academic Hospital is a tertiary hospital situated in the south of Johannesburg and serves the southern Gauteng province with a population of approximately 2 million. Women served are referred from surrounding midwife-operated Units (MOUs)and hospitals of various levels. There are 23000 deliveries performed annually with a caesarean section rate of 39.8%. Mortality and Morbidity statistics for the previous year have, however, reported the caesarean section rate for the previous year to be 50%. (11)

5.2. Research paradigm

The research paradigm is a retrospective cross-sectional study comparing ultrasound and MRI report findings in patients with suspected Placenta Accreta spectrum. Histopathology report findings will be used as the gold standard. In cases in which there are no histopathology reports, surgical findings will be used as the gold standard instead.

5.3 Sample

The sample for the study will include all patients attending Chris Hani Baragwanath Academic Hospital Fetal medicine unit with suspected placenta accreta spectrum and patients in whom there was poor resolution due to a posterior placenta. The study period will be from the 1st of June 2017 to the 30th of June 2019.

5.3.1. Inclusion criteria

All patients with suspected or diagnosed PAS on ultrasound were referred for antenatal MRI(Magnetic resonance imaging).
Each MRI report is interpreted, reviewed or approved by a qualified radiologist.

5.3.2. Exclusion criteria

Lost records which may include antenatal, intrapartum or surgical notes, ultrasound reports, and MRI reports.
MRI studies not reported or approved by qualified radiologists will be excluded.

5.4. Materials and Methods

Patients who were referred for MRI for suspected PAS will be identified from a record file in the Fetal medicine unit. Patient files will be gathered from the filing and storage of the hospital to determine surgical findings. The MRI reports will be archived from the current Picture Archiving and Communications System (PACS)- AGFA IMPAX 6.5.1.5012011 (2007-2008) and the histopathological reports from the NHLS(National Health Laboratory Service) Labtrak database.

5.4.1. Reporters

The patients have had their ultrasounds performed and reported at the fetal medicine unit by a qualified fetal medicine specialist Dr Jayshree Jeebodh.

The MRI examination reports that will be considered are reports that have been reported or approved by a qualified radiologist.
A qualified radiologist will be defined as a person who has passed the Diagnostic Radiology Fellowship Final examination from the College of Medicine of South Africa(CMSA) or equivalent qualification approved by the Health Professionals Council of South Africa(HPCSA).
A senior radiologist will be defined as a qualified radiologist five or more years after obtaining a qualification as a radiologist.
A junior radiologist will be considered as a qualified radiologist less than 5 years after obtaining qualification as a radiologist.

5.4.2. Equipment

The sonographic transabdominal and transvaginal examinations were performed with the GE VOLUSON S8 and Canon Aplio 400 TUS-A400.
The transducers used for GE Voluson S8:
Endocavity(transvaginal) - GE E8C Microconvex Probe, bandwidth 4-10 MHz, with the application set to obstetrics.
Transabdominal -GE C1-5 2D Convex Probe, bandwidth 1-5MHz, application set to obstetrics.

The transducers used on the Canon Aplio 400:
Endocavity(transvaginal) probe-PVT781VT(11C3), bandwidth 4.0-9.0 MHz, application set to obstetrics
Transabdominal probe-PVT-3575BT(6Cs1), bandwidth- 1.9-6.0 MHz, application set to obstetrics

The MRI images are acquired with a 1.5T Siemens Magnetom Aera,2015 with a body coil. The sequences acquired are T2 Half-Fourier Acquisition Single-shot Turbo spin Echo (HASTE) Sagittal, T2 HASTE Coronal, T2 HASTE Axial, T1 Volumetric Interpolated Breath-hold Examination (VIBE) Axial and T2 HASTE Axial Oblique.

5.5. Data collection

All patients will be allocated a data collection sheet and assigned a research number to maintain anonymity. The MRI and ultrasound report data will be entered onto the data collection sheet for each patient(attached as Appendix 1).

5.6. Reliability and validity

The MRI reports, ultrasound reports and histopathology reports have been reported by trained and qualified radiologists, a fetal medicine specialist and histopathologists respectively.

5.7. Bias

Possible reporting bias due to radiologists not being blinded to the ultrasound findings which may affect the accuracy of MRI reports.

Unavoidable selection bias due to only high-risk patients that have been referred to the fetal medicine unit for prenatal imaging.

6. Data analysis and statistics

Sensitivity, specificity, positive predictive value, and negative predictive value will be calculated for ultrasound and MRI.
The sensitivity and specificity values for ultrasound and MRI will be compared with the McNemar Test.
The Radiologist's experience in years will be documented and the accuracy of the MRI reports in relation to experience.
The statistical analysis and interpretation will be done with the help of a biostatistician.

7. Ethics

The permission and ethical clearance for the study will be applied for with the University Of Witwatersrand Human Research Ethics Committee(HREC) Chris Hani Baragwanath Academic Hospital CEO office, Head of Department at National Health Laboratory Service(NHLS), Department of the Obstetrics and Gynaecology and Department of Diagnostic Radiology.

7.1. Data Safety

The patient details used for this research project will not be shared with any other parties that are not involved with the project or related project. There will be no publishing of patient personal details to any other parties.

8. Timing

Month of the Year	Dec	Jan	Feb	March	April	May	June	July	August
Literature search	x								
Reading literature	x	x							
Summarising literature	x	x							
Preparing Protocol	x	x							
Protocol Assessment			X						
Ethics application			X						
Collecting data						X			
Data analysis							X		
Writing up thesis							X	X	
Submit: marking									X
Writing up paper									X

9. Budget

The anticipated costs of the project are related to stationery which will be used to print and publish the paper. This will be self-funded.

Stationery: paper and printing	200
Total	**200**

10. Anticipated problems

The continuous AGFA PACS problems at Chris Hani Baragwanath Academic Hospital are a threat to the possible loss of data. The PACS problems are hopefully to be resolved and if not resolved should hopefully not cause loss of patient data.

Access to files of the patient may be limited due to large volumes of storage.

There is a possibility of low numbers of patients for the study over the specified time.

11. References

(1) Jauniaux E, Ayres-de-Campos D. 2018. FIGO consensus guidelines on placenta accreta spectrum disorders: Introduction. *Int J Gynaecol Obstet*, 140(3):261-64. DOI: 10.1002/ijgo.12406.

(2) Jauniaux E, Collins S, Burton GJ. 2018. Placenta accreta spectrum: patho physiology and evidence-based anatomy for prenatal ultrasound imaging. *Am J Obstet Gynecol*, 218(1):75-87. DOI: 10.1016/j.ajog.2017.05.067.

(3) Silver RM, Barbour KD. Placenta accreta spectrum: accreta, increta, and percreta. (1558-0474 (Electronic)).

(4) Jauniaux E, Ayres-de-Campos D, Langhoff-Roos J*, et al.* 2019. FIGO classification for the clinical diagnosis of placenta accreta spectrum disorders. *Int J Gynaecol Obstet*, 146(1):20-24. DOI: 10.1002/ijgo.12761.

(5) Belfort MA, Shamshirsaz AA, Fox KA. 2018. The diagnosis and management of morbidly adherent placenta. *Semin Perinatol*, 42(1):49-58. DOI: 10.1053/j.semperi.2017.11.009.

(6) Faiz AS, Ananth CV. 2003. Etiology and risk factors for placenta previa: an overview and meta-analysis of observational studies. *J Matern Fetal Neonatal Med*, 13(3):175-90. DOI: 10.1080/jmf.13.3.175.190.

(7) Riteau AS, Tassin M, Chambon G*, et al.* 2014. Accuracy of ultrasonography and magnetic resonance imaging in the diagnosis of placenta accreta. *PLoS One*, 9(4):e94866. DOI: 10.1371/journal.pone.0094866.

(8) Goh WA, Zalud I. 2016. Placenta accreta: diagnosis, management and the molecular biology of the morbidly adherent placenta. *J Matern Fetal Neonatal Med*, 29(11):1795-800. DOI: 10.3109/14767058.2015.1064103.

(9) Berkley EM, Abuhamad AZ. 2013. Prenatal diagnosis of placenta accreta: is sonography all we need? *J Ultrasound Med*, 32(8):1345-50. DOI: 10.7863/ultra.32.8.1345.

(10) Berkley EM, Abuhamad A. 2018. Imaging of Placenta Accreta Spectrum. *Clin Obstet Gynecol*, 61(4):755-65. DOI: 10.1097/grf.0000000000000407.

(11) Adam Y. An evaluation of the indications for caesarean sections at Chris Hani Baragwanath Academic Hospital2018. Available from: http://www.sajog.org.za/index.php/SAJOG/article/view/1226%J South African Journal of Obstetrics and Gynaecology

(12) Sentilhes L, Kayem G, Chandraharan E*, et al.* 2018. FIGO consensus guidelines on placenta accreta spectrum disorders: Conservative management. *International Journal of Gynecology & Obstetrics*, 140(3):291-98. DOI: https://doi.org/10.1002/ijgo.12410.

(13) Shamshirsaz AA, Fox KA, Salmanian B*, et al.* 2015. Maternal morbidity in patients with morbidly adherent placenta treated with and without a standardized multidisciplinary approach. *Am J Obstet Gynecol*, 212(2):218.e1-18.e9. DOI: https://doi.org/10.1016/j.ajog.2014.08.019.

(14) Moodley J, Ngambu Nf Fau - Corr P, Corr P. Imaging techniques to identify morbidly adherent placenta praevia: a prospective study. (0144-3615 (Print)).

(15) Meng X, Xie L, Song W. 2013. Comparing the diagnostic value of ultrasound and magnetic resonance imaging for placenta accreta: a systematic review and meta-analysis. *Ultrasound Med Biol*, 39(11):1958-65. DOI: 10.1016/j.ultrasmedbio.2013.05.017.

(16) Dahmarde H, Parooie F, Salarzaei M. 2020. Prenatal Diagnosis of Placental Invasion: A Systematic Review and Meta-analysis on Accuracy of Ultrasonography and MRI in Diagnosis of Placental Invasion. *Journal of Diagnostic Medical Sonography*, 36(5):446-61. DOI: 10.1177/8756479320929031.

(17) Pagani G, Cali G, Acharya G, *et al.* 2018. Diagnostic accuracy of ultrasound in detecting the severity of abnormally invasive placentation: a systematic review and meta-analysis. *Acta Obstet Gynecol Scand*, 97(1):25-37. DOI: 10.1111/aogs.13238.
(18) Comstock CH. 2005. Antenatal diagnosis of placenta accreta: a review. *Ultrasound Obstet Gynecol*, 26(1):89-96. DOI: 10.1002/uog.1926.
(19) Rac MW, Moschos E, Wells CE, *et al.* 2016. Sonographic Findings of Morbidly Adherent Placenta in the First Trimester. *J Ultrasound Med*, 35(2):263-9. DOI: 10.7863/ultra.15.03020.
(20) D'Antonio F, Timor-Tritsch IE, Palacios-Jaraquemada J, *et al.* 2018. First-trimester detection of abnormally invasive placenta in high-risk women: systematic review and meta-analysis. *Ultrasound Obstet Gynecol*, 51(2):176-83. DOI: 10.1002/uog.18840.
(21) Kilcoyne A, Shenoy-Bhangle AS, Roberts DJ, *et al.* 2017. MRI of Placenta Accreta, Placenta Increta, and Placenta Percreta: Pearls and Pitfalls. *AJR Am J Roentgenol*, 208(1):214-21. DOI: 10.2214/ajr.16.16281.
(22) Warshak CR, Eskander R, Hull AD, *et al.* 2006. Accuracy of ultrasonography and magnetic resonance imaging in the diagnosis of placenta accreta. *Obstet Gynecol*, 108(3 Pt 1):573-81. DOI: 10.1097/01.AOG.0000233155.62906.6d.
(23) Dwyer BK, Belogolovkin V, Tran L, *et al.* 2008. Prenatal diagnosis of placenta accreta: sonography or magnetic resonance imaging? *J Ultrasound Med*, 27(9):1275-81. DOI: 10.7863/jum.2008.27.9.1275.
(24) Lopes ES, Feitosa FEL, Brazil AV, *et al.* 2019. Assessment of Sensitivity and Specificity of Ultrasound and Magnetic Resonance Imaging in the Diagnosis of Placenta Accreta. *Rev Bras Ginecol Obstet*, 41(1):17-23. DOI: 10.1055/s-0038-1675803.
(25) Maher MA, Abdelaziz A, Bazeed MF. 2013. Diagnostic accuracy of ultrasound and MRI in the prenatal diagnosis of placenta accreta. *Acta Obstet Gynecol Scand*, 92(9):1017-22. DOI: 10.1111/aogs.12187.
(26) Daney de Marcillac F, Moliere S, Pinton A, *et al.* 2016. [Accuracy of placenta accreta prenatal diagnosis by ultrasound and MRI in a high-risk population]. *J Gynecol Obstet Biol Reprod (Paris)*, 45(2):198-206. DOI: 10.1016/j.jgyn.2015.07.004.
(27) Abdel Magied AM, Salah Eldin LA, Tohamey YM, *et al.* 2018. Placenta previa; MRI as an adjunct to ultrasound in assessment of suspected placental invasion. *The Egyptian Journal of Radiology and Nuclear Medicine*, 49(1):284-91. DOI: https://doi.org/10.1016/j.ejrnm.2017.12.010.
(28) Hashem LB, Salem DS, Hamed ST, *et al.* 2016. Role of MRI versus ultrasound in the assessment of placental abnormalities and diseases. *The Egyptian Journal of Radiology and Nuclear Medicine*, 47(2):641-58. DOI: https://doi.org/10.1016/j.ejrnm.2016.02.006.
(29) Ghezzi CLA, Silva CK, Casagrande AS, *et al.* 2021. Diagnostic performance of radiologists with different levels of experience in the interpretation of MRI of the placenta accreta spectrum disorder. *The British Journal of Radiology*, 94(1128):20210827. DOI: 10.1259/bjr.20210827.
(30) Alamo L, Anaye A Fau - Rey J, Rey J Fau - Denys A, *et al.* Detection of suspected placental invasion by MRI: do the results depend on observer' experience? , (1872-7727 (Electronic)).
(31) Jauniaux E, Chantraine F, Silver RM, *et al.* FIGO consensus guidelines on placenta accreta spectrum disorders: Epidemiology. (1879-3479 (Electronic)).
(32) Gersell DJ, Kraus FT. Diseases of the Placenta. Ch. In: Blaustein's Pathology of the Female Genital Tract, ed. by R J Kurman, L H Ellenson, B M Ronnett Boston, MA: Springer US, 2011, p. 999-1073.

(33) Noda Y, Kanematsu M, Goshima S*, et al.* 2015. Prenatal MR imaging diagnosis of placental invasion. 40(5):1273-78. DOI: 10.1007/s00261-014-0281-z.
(34) Varghese B, Singh N, George RA*, et al.* 2013. Magnetic resonance imaging of placenta accreta. *Indian J Radiol Imaging*, 23(4):379-85. DOI: 10.4103/0971-3026.125592.
(35) Familiari A, Liberati M, Lim P*, et al.* Diagnostic accuracy of magnetic resonance imaging in detecting the severity of abnormal invasive placenta: a systematic review and meta-analysis. (1600-0412 (Electronic)).
(36) Millischer AE, Salomon LJ, Porcher R*, et al.* 2017. Magnetic resonance imaging for abnormally invasive placenta: the added value of intravenous gadolinium injection. *Bjog*, 124(1):88-95. DOI: 10.1111/1471-0528.14164.

0702920j:for_turnitin.docx

ORIGINALITY REPORT

13%	9%	9%	2%
SIMILARITY INDEX	INTERNET SOURCES	PUBLICATIONS	STUDENT PAPERS

PRIMARY SOURCES

1	www.science.gov Internet Source	1%
2	M. R. Fisher, G. J. Criner, A. P. Fishman, P. M. Hassoun, O. A. Minai, S. M. Scharf, a. H. E. Fessler. "Estimating pulmonary artery pressures by echocardiography in patients with emphysema", European Respiratory Journal, 2007 Publication	1%
3	publications.aap.org Internet Source	1%
4	Andersen, K.. "Multi-detector CT-colonography in inflammatory bowel disease: Prospective analysis of CT-findings to high-resolution video colonoscopy", European Journal of Radiology, 200604 Publication	1%
5	F. D'Antonio, C. Iacovella, J. Palacios-Jaraquemada, C. H. Bruno, L. Manzoli, A. Bhide. "Prenatal identification of invasive placentation using magnetic resonance	1%

imaging: systematic review and meta-analysis", Ultrasound in Obstetrics & Gynecology, 2014
Publication

6	content.iospress.com Internet Source	1 %
7	www.e-sciencecentral.org Internet Source	1 %
8	Alessandra Familiari, Marco Liberati, Philip Lim, Giorgio Pagani et al. "Diagnostic accuracy of magnetic resonance imaging in detecting the severity of abnormal invasive placenta: a systematic review and meta-analysis", Acta Obstetricia et Gynecologica Scandinavica, 2018 Publication	1 %
9	www.medrxiv.org Internet Source	1 %
10	www.ncbi.nlm.nih.gov Internet Source	<1 %
11	Johannes Koren, Gerhard Gritsch, Susanne Pirker, Johannes Herta, Hannes Perko, Tilmann Kluge, Christoph Baumgartner. "Automatic ictal onset source localization in presurgical epilepsy evaluation", Clinical Neurophysiology, 2018 Publication	<1 %

12	hdl.handle.net Internet Source	<1 %
13	sajhivmed.org.za Internet Source	<1 %
14	"ESPGHAN 52nd Annual Meeting Abstracts", Journal of Pediatric Gastroenterology & Nutrition, 2019 Publication	<1 %
15	Brice A. Kessler, Jo Ling Goh, Hengameh B. Pajer, Anthony M. Asher et al. "Rapid-sequence MRI for evaluation of pediatric traumatic brain injury: a systematic review", Journal of Neurosurgery: Pediatrics, 2021 Publication	<1 %
16	Submitted to University of Portsmouth Student Paper	<1 %
17	link.springer.com Internet Source	<1 %
18	research-information.bris.ac.uk Internet Source	<1 %
19	www.ajronline.org Internet Source	<1 %
20	www.jrheum.org Internet Source	<1 %
21	Submitted to Anglia Ruskin University Student Paper	

		<1 %
22	academic.oup.com Internet Source	<1 %
23	etd.aau.edu.et Internet Source	<1 %
24	cvip.computing.dundee.ac.uk Internet Source	<1 %
25	worldwidescience.org Internet Source	<1 %
26	www.jmir.org Internet Source	<1 %
27	N Lack. "Comparison of non-invasive sampling methods for detection of HPV in rural African women", Sexually Transmitted Infections, 6/1/2005 Publication	<1 %
28	Rajesh Gupta, Robert Matthews, Lev Bangiyev, Dinko Franceschi, Mark Schweitzer. "PET/MR Imaging", Springer Science and Business Media LLC, 2018 Publication	<1 %
29	Eckhart Buchmann, Yasmin Adam, Jayshree Jeebodh, Ntombi Madondo, Edmore Marinda. "Association between HIV infection and amniotic fluid index at advanced gestation",	<1 %

International Journal of Gynecology & Obstetrics, 2013
Publication

Exclude quotes On
Exclude bibliography On
Exclude matches Off