

https://dspace.org/

Periodontal tissue regeneration by transforming growth factor - 3 (TGF-3) in papioursinus

Teare, June Ann

2006-11-14T11:14:11Z
http://hdl.handle.net/10539/1685

Downloaded from a DSpace repository. https://dspace.org/

PERIODONTAL TISSUE REGENERATION BY TRANSFORMING GROWTH FACTOR-β3 (TGF-β3) IN *Papio ursinus*

June Ann Teare

A dissertation submitted to the Faculty of Health Sciences, University of the Witwatersrand, Johannesburg, in fulfilment of the requirements for the degree of Master of Science in Medicine.

Johannesburg, 2006

I declare that, with the exception of the people accredited in the Acknowledgements section, this dissertation is my own unaided work. It is being submitted for the Degree of Master of Science in Medicine in the University of the Witwatersrand, Johannesburg. It has not been submitted before for any degree or examination in any other University.

_____

(Signature of candidate)

_____day of _____ 2006

ABSTRACT

This study, in non-human primates (*Papio ursinus*), evaluated the healing potential of recombinant human transforming growth factor-β3 (rhTGF-β3) when implanted in exposed periodontal furcation defects either by direct application to the defect or by transplantation of rhTGF-β3-instigated heterotopic bone as source of autogenous bone. Class II furcation defects were surgically created bilaterally in the first and second molars of both the mandible and the maxilla of four clinically healthy adult baboons. Simultaneously, autogenous bone was induced bilaterally within the *rectus abdominis* muscle of the baboons using rhTGF-β3. Forty days later, the periodontal defects were implanted with rhTGF-β3 in Matrigel® as delivery system, or rhTGF-β3 plus muscle tissue in Matrigel®, or with the harvested rhTGF-β3-induced autogenous bone. Sixty days after periodontal implantation, the animals were euthanased and the molars harvested together with the surrounding tissue. Histological analysis was performed by light microscopy and digital imaging computer software. The extent of regeneration was assessed by measuring area and volume of new alveolar bone, height of new alveolar bone and height of new cementum. The results, compared to controls, showed pronounced periodontal tissue regeneration in experimental defects. The most noteworthy healing was observed in defects implanted with heterotopically induced autogenous bone as well as those implanted with rhTGF-β3 plus muscle tissue. The findings of this study suggest that rhTGF-β3 applied directly to a defect, or rhTGF-β3-induced autogenous bone, transplanted to a defect, have significant regenerative capabilities in periodontal tissue regeneration of non-human primates *Papio ursinus.*

To Hans,

Robyn and Megan

ACKNOWLEDGEMENTS

I would like to thank Professor Ugo Ripamonti for surgical expertise and for making this research project possible.

I am indebted to Dr. Lentsha Nathaniel Ramoshebi for his enthusiasm, encouragement, guidance and infinite patience.

My appreciation to Professor Jean-Claude Petit, for surgical, photographic and radiographic skills.

My sincere thanks to the staff of Central Animal Service, University of the Witwatersrand, for expert animal care and technical skill.

My gratitude to the Medical Research Council for financial study support and the Bone Research Unit for the use of its facilities.

PAGE

DECLARATION ii

ABSTRACT iii

DEDICATION iv

ACKNOWLEDGEMENTS v

CONTENTS vi

LIST OF FIGURES xi

LIST OF TABLES xix

1. INTRODUCTION 1

2. LITERATURE REVIEW 7

2.1 Tissue Engineering for Periodontal Tissue Regeneration 7

2.1.1 Periodontal Ligament 8

2.1.2 Cementum 9

2.1.3 Alveolar Bone 10

2.1.4 Biological Problems in Periodontal Tissue Regeneration 11

2.2 Growth Factors for Periodontal Tissue Regeneration 12

2.2.1 Bone Morphogenetic Proteins in Periodontal Tissue Regeneration 13

2.2.2 Transforming Growth Factors-β in Periodontal Tissue Regeneration 16

2.2.3 Synergy of Bone Morphogenetic Proteins and Transforming Growth Factor-β for Tissue Engineering 18

2.3 Skeletal Muscle for Tissue Engineering 20

2.4 Delivery Systems for Periodontal Tissue Regeneration 21

3. AIM OF STUDY 28

4. MATERIALS AND METHODS 29

4.1 Animals 29

4.2 Implant Materials 29

4.2.1 Growth Factors 30

4.2.1.1 rhTGF-β3 30

4.2.1.2 rhOP-1 30

4.2.2 Muscle Tissue 30

4.2.3 Delivery System 31

4.2.3.1 Growth Factor-Reduced (GFR) Matrigel® Matrix **31**

4.2.3.2 Insoluble Collagenous Bone Matrix (ICBM) **31**

4.3 Preparation of Implants **31**

4.3.1 Matrigel®-Based Implants 31

4.3.2 ICBM-Based Implants 32

4.4 Surgery on Baboons **32**

4.4.1 Phase 1: Heterotopic Implantation of Molecular Signals for the Induction of Autogenous Bone and Preparation of Periodontal Defects 33

4.4.1.1 Heterotopic Surgery **33**

4.4.1.2 Periodontal Surgery **37**

4.4.2 Phase 2: Harvesting of Heterotopically Induced Autogenous Bone and Implantation of Periodontal Defects 37

4.4.2.1 Heterotopic Surgery **37**

4.4.2.2 Periodontal Surgery **42**

4.4.3 Phase 3: Euthanasia and Harvest of Periodontal Tissue 47

4.5 Photography and Radiography **47**

4.6 Tissue Processing of Periodontal Specimens **47**

4.7 Histomorphometric Analysis 48

4.7.1 Heterotopically Induced Autogenous Bone 48

4.7.2 Periodontal Defects 49

5. RESULTS 51

5.1 Heterotopic Implants for Autogenous Bone 51

5.1.1 Histological Observations 51

5.1.1.1 75 μg rhTGF-β3/Matrigel®-Induced Autogenous Bone 51

5.1.1.2 2.5 μg rhTGF-β3/25 μg rhOP-1/ICBM-Induced Autogenous 53

5.1.1.3 1.5 μg rhTGF-β3/25 μg rhOP-1/ICBM-Induced Autogenous 55

5.1.2 Histomorphometric Analysis 56

5.2 Periodontal Implants 62

5.2.1 Post-operative Observations 62

5.2.2 Radiographic Observations 63

5.2.3 Histological Observations 64

5.2.3.1 Matrigel® Control 64

5.2.3.2 rhTGF-β3 with Matrigel® as Carrier 66

5.2.3.3 rhTGF-β3 plus Muscle Tissue with Matrigel® as Carrier 68

5.2.3.4 75 μg rhTGF-β3/Matrigel®-Induced Autogenous Bone 72

5.2.3.5 2.5 μg rhTGF-β3/25 μg rhOP-1/ICBM-Induced Autogenous 75

5.2.4 Histomorphometric Analysis 77

6. DISCUSSION 90

7. CONCLUSION 98

8. REFERENCES 99

9. APPENDICES 129

Appendix 1. **Dilutions for rhTGF-β3** 129

Appendix 2. **Preparation of rhOP-1 Solutions** 130

Appendix 3. **Preparation of Insoluble Collagenous Bone Matrix (ICBM)** 131

Appendix 4. **Matrigel®-Based Implants** 132

Appendix 5. **ICBM-Based Implants** 133

Appendix 6. **Processing Schedule for K-Plast Resin Embedding** 134

Appendix 7. **Modified Goldner's Trichrome Staining Method** 135

LIST OF FIGURES

Page

Figure 4.1 Heterotopic implant site in the *rectus abdominis* muscle. Green arrow indicates pouch made to receive implant. …….. **34**

Figure 4.2 Application of Matrigel®-based implant in the *rectus abdominis* muscle. ……... **35**

Figure 4.3 Application of ICBM-based implant in the *rectus abdominis* muscle. ……... **35**

Figure 4.4 *Animals 1 and 3:* Surgical implant design for heterotopic implants. …… **36**

Figure 4.5 *Animals 2 and 4:* Surgical implant design for heterotopic implants. …… **36**

Figure 4.6 Harvested ossicle of autogenous bone from the *rectus abdominis* muscle. The yellow arrow indicates muscle fascia; the green arrow indicates underlying muscle tissue containing endochondral bone. ……. **41**

Figure 4.7 Fragmented ossicle of autogenous bone from the *rectus abdominis* muscle for transplantation. ……. **41**

Figure 4.8 Class II furcation defects in first and second maxillary molars prior to implanting with autogenous bone. ……. **43**

Figure 4.9 First and second maxillary molars after implanting with fragmented autogenous bone. …… **43**

Figure 4.10 *Animals 1 and 3:* Surgical implant design for periodontal implants.. **44**

Figure 4.11 *Animal 2:* Surgical implant design for periodontal implants. ...….. **45**

Figure 4.12 *Animal 4:* Surgical implant design for periodontal implants. ...…... **46**

Figure 5.1 *Autogenous bone:* Photomicrograph of a 75 µg rhTGF-β3/Matrigel®-induced ossicle showing mineralized bone (blue areas), 1.25x magnification. Modified Goldner's stain. …… **52**

Figure 5.2 *Autogenous bone:* Photomicrograph of a 75 µg rhTGF-β3/Matrigel®-induced ossicle showing bone and cartilage within autogenous bone graft material, 20x magnification. Modified Goldner's stain. …….. **52**

Figure 5.3 *Autogenous bone:* Photomicrograph of a 2.5 µg rhTGF-β3/25 µg rhOP-1/ICMB-induced ossicle showing bone content (blue areas), (**A**) 1.25x magnification; (**B**) 4x magnification. Modified Goldner's stain. …… **54**

Figure 5.4 *Autogenous bone:* Photomicrograph of a 2.5 µg rhTGF-β3/25 µg rhOP-1/ICMB-induced ossicle harvested from Animal 4 showing sparse distribution of bone (yellow arrows) and abundant residual carrier (white arrows) within autogenous bone graft material, 4x magnification. Modified Goldner's stain. **54**

Figure 5.5 Distribution of mineralized bone, osteoid, cartilage and carrier matrix within the harvested induced ossicles. Values are expressed in percentage. ……. **58**

Figure 5.6 First and second maxillary molars, showing periodontal healing, sixty days post-implantation, exhibiting areas of mild inflammation (green arrows). ... **62**

Figure 5.7 First and second mandibular molars, showing periodontal healing, sixty days post-implantation, exhibiting areas of mild inflammation (green arrows). ……. **62**

Figure 5.8 Radiographs of mandibular defects implanted with rhTGF-β3 plus muscle tissue in Matrigel® before (**A**) and after (**B**) healing. White arrows indicate notches at base of defects; yellow arrows (**B**) indicate height of bone after sixty day healing period. …… **63**

Figure 5.9 Radiographs of mandibular defects implanted with Matrigel® alone, before (**A**) and after (**B**) healing, showing little or no regeneration within the defects. White arrows indicate notches at base of defects; yellow arrows (**B**) indicate height of bone after sixty day healing period. …….. **63**

Figure 5.10 *Matrigel® control specimen:* Photomicrograph showing periodontal tissue regeneration in a control specimen, 1.25x magnification. Arrows indicate the notches made at time of implantation. Modified Goldner's stain. **65**

Figure 5.11 *Matrigel® control specimen:* Photomicrograph of new periodontal ligament in furcation defect area coronal to the notch (**A**) showing poorly organized periodontal ligament fibres arranged between cementum and alveolar bone, 20x magnification. In the same specimen, the area apical to the notch (**B**) shows Sharpey's fibres with good insertion, 20x magnification. Modified Goldner's stain. Yellow arrows indicate cementum, green arrows indicate periodontal ligament fibres and black arrows indicate alveolar bone. …….. **65**

Figure 5.12 *Periodontal tissue regeneration by rhTGF-β3 with Matrigel® carrier*: Photomicrograph of periodontal healing within furcation defect using rhTGF-β3 in Matrigel® as carrier, 1.25x magnification. Arrows indicate the notches made at time of implantation. Modified Goldner's stain. ……... **67**

Figure 5.13 *Periodontal tissue regeneration by rhTGF-β3 with Matrigel® carrier*: Histological section showing new periodontal ligament with repetitive pattern of capillaries along edge of alveolar bone (black arrows) and well-defined insertion of Sharpey's fibres (white arrows), 40x magnification. Modified Goldner's stain. .. **67**

Figure 5.14 *Periodontal tissue regeneration by rhTGF-β3 plus muscle tissue with Matrigel® carrier*: Photomicrographs showing newly formed alveolar bone within notched areas of furcation defects, 1.25x magnification. Arrows indicate the notches made at time of implantation. Modified Goldner's stain. ……. **69**

Figure 5.15 *Periodontal tissue regeneration by rhTGF-β3 plus muscle tissue with Matrigel® carrier:* Histological section showing new alveolar bone with osteoid, periodontal ligament, and cellular cementum, 10x magnification. Modified Goldner's stain. …….. **70**

Figure 5.16 *Periodontal tissue regeneration by rhTGF-β3 plus muscle tissue with Matrigel® carrier:* Histological section showing new alveolar bone with osteoid, periodontal ligament with prominent insertion of Sharpey's fibres, and cellular cementum, 20x magnification. Modified Goldner's stain. ……... **70**

Figure 5.17 *Periodontal tissue regeneration by rhTGF-β3 plus muscle tissue with Matrigel® carrier:* Histological section showing new periodontal ligament with insertion of Sharpey's fibres into newly formed alveolar bone, 40x magnification. Modified Goldner's stain. …….. **71**

Figure 5.18 *Periodontal tissue regeneration by rhTGF-β3 plus muscle tissue with Matrigel® carrier:* Histological section showing new periodontal ligament with vascularization and insertion of Sharpey's fibres into new cellular cementum, 40x magnification. Modified Goldner's stain. ……. **71**

Figure 5.19 *Periodontal tissue regeneration by autogenous bone (75 µg rhTGF-β3/Matrigel® ossicle):* Photomicrograph, 1.25x magnification, showing newly formed alveolar bone within furcation defects by rhTGF-β3/Matrigel® ossicle. Arrow indicates osteogenic invasion of the pulp cavity. ……... **73**

Figure 5.20 *Periodontal tissue regeneration by autogenous bone (75 µg rhTGF-β3/Matrigel® ossicle):* Histological section showing new alveolar bone, new periodontal ligament and new cellular cementum within the notched area of the defect, 10x magnification. Modified Goldner's stain. …….. **73**

Figure 5.21 *Periodontal tissue regeneration by autogenous bone (75 µg rhTGF-β3/Matrigel® ossicle):* Histological section showing insertion of Sharpey's fibres into cementoid matrix of cementum, 40x magnification. Modified Goldner's stain. ……... **74**

Figure 5.22 *Periodontal tissue regeneration by autogenous bone (75 µg rhTGF-β3/Matrigel® ossicle):* Histological section showing ankylosis within furcation defect at coronal margin, 10x magnification. Modified Goldner's stain. ……. **74**

Figure 5.23 *Periodontal tissue regeneration by autogenous bone (2.5 µg rhTGF-β3/25 µg rhOP-1/ICBM ossicle):* Photomicrograph, 1.25x magnification, showing newly formed alveolar bone within furcation defects by 2.5 µg rhTGF-β3/25 µg rhOP-1/ICBM ossicle. Arrows indicate notches made at time of surgery. **76**

Figure 5.24 *Periodontal tissue regeneration by autogenous bone (2.5 µg TGF-β3/25 µg rhOP-1/ICBM ossicle)*: Histological section showing new periodontal ligament with insertion of Sharpey's fibres, 40x magnification. Modified Goldner's stain. ……... **76**

Figure 5.25 Area of new alveolar bone compared to total defect as regenerated by the five implant variables. Values are expressed in percentage (%). ……..... **80**

Figure 5.26 Distribution of alveolar bone (mineralized bone plus osteoid) as regenerated by each of the five variables. Periodontal tissue regeneration by Matrigel®-based autogenous bone (75 µg rhTGF-β3/Matrigel® ossicle) yielded the most significant amount of alveolar bone (53.1 ± 4.9 %) when compared to the control (30.3 ± 5.4%) ($p < 0.05$). ……... **82**

Figure 5.27 Volume (%) of alveolar bone regenerated by each animal. The amount of alveolar bone regenerated by Animals 1, 2 and 3 is much greater than that regenerated by Animal 4. .....……. **84**

Figure 5.28 Comparison of the amount of alveolar bone regenerated in Animals 2 and 4 by rhTGF-β3/Matrigel® implants in periodontal implants. ……...…. **86**

Figure 5.29 Comparison of the amount of alveolar bone regenerated in periodontal defects in Animals 2 and 4 by 2.5 µg TGF-β3/25 µg rhOP-1/ICBM ossicles. ….. **87**

Figure 5.30 Comparison of the amount of alveolar bone regenerated in mandibular and maxillary implants. ……..... **88**

Figure 5.31 Amount (%) of alveolar bone regenerated in the first and second molars of the animals showing that the difference is not statistically significant. ……... **89**

LIST OF TABLES

Page

Table 4.1 *Animal 1:* Heterotopic implant doses and fate of implants after forty days. **38**

Table 4.2 *Animal 2:* Heterotopic implant doses and fate of implants after forty days. **39**

Table 4.3 *Animal 3:* Heterotopic implant doses and fate of implants after forty days. **39**

Table 4.4 *Animal 4:* Heterotopic implant doses and fate of implants after forty days. **39**

Table 4.5 Summary of fate of heterotopic implants. Both 75 µg rhTGF-β3/ Matrigel® implants (Animals 1 and 3) were harvested. All 2.5 µg rhTGF-β3/Matrigel® and 1.5 µg rhTGF-β3/Matrigel® implants were resorbed. Three 2.5 µg rhTGF-β3/25 µg rhOP-1/ICBM implants (Animals 2, 3 and 4) and two 1.5 µg rhTGF-β3/25 µg rhOP-1/ICBM implants (Animals 1 and 3) were harvested. **40**

Table 4.6 *Animals 1 and 3:* Location of periodontal implants and doses of implants. **44**

Table 4.7 *Animal 2:* Location of periodontal implants and doses of implants. ……. **45**

Table 4.8 *Animal 4:* Location of periodontal implants and doses of implants. ……. **46**

Table 5.1 Volume fraction (%) of bone (mineralized bone plus osteoid), cartilage and residual matrix in the seven ossicles of induced bone harvested from the *rectus abdominis* of the baboons. Values are expressed as mean and standard error of the mean (SEM); n indicates the number of ossicles harvested for each implant variable. ……. **59**

Table 5.2 Bonferroni's Multiple Comparison Test comparing 75 µg TGF-β3/Matrigel® ossicle (Column A), 2.5 µg TGF-β3/25 µg rhOP-1/ICBM ossicle (Column B) and 1.5 µg TGF-β3/25 µg rhOP-1/ICBM ossicle (Column C). There is no significant difference between the three types of ossicles ($p > 0.05$). ……..... **59**

Table 5.3 Volume fraction (%) of bone (mineralized bone plus osteoid) of ossicles induced with 75 µg TGF-β3/Matrigel® and transplanted to periodontal defects. The ossicles are similar in bone volume and neither contain residual carrier matrix. ..……..... **60**

Table 5.4 Volume fraction (%) of bone (mineralized bone plus osteoid) and carrier matrix of 2.5 µg TGF-β3/25 µg rhOP-1/ ICBM ossicles transplanted to periodontal defects. The ossicle from Animal 4 consists of less

osteogenic material and more carrier matrix than the ossicle harvest from Animal 2. ……..... **60**

Table 5.5 Volume fraction (%) of bone (mineralized bone plus osteoid), cartilage and residual carrier matrix of ossicles not transplanted to periodontal sites. ….... **61**

Table 5.6 Area of new alveolar bone compared to total defect size. Values are expressed in percentage (%); n indicates the number of defects per implant type. …….. **80**

Table 5.7 Histometric analysis of periodontal tissue regeneration in 32 furcation defects. Values (in mm) are given as mean ± SEM; n indicates the number of defects. N: apical border of the notches on the mesial and distal roots surfaces; F: fornix of the furcation defect; C: cementum; AB: alveolar bone. There was no significant difference detected by Dunnett's Multiple Comparison Test ($p > 0.05$) for N-F (mesial and distal values), or N-C (mesial). Significant differences were noted for: N-C (distal) control versus TGF-β3/Muscle implant ($p < 0.05$); N-AB (mesial) control versus TGF-β3/Muscle implant ($p < 0.05$), N-AB (distal) control versus TGF-β3/Muscle implant ($p < 0.01$); N-AB (distal) control versus AB/Matrigel® implant ($p < 0.01$). …..…… **81**

Table 5.8 Volume fraction (%) of bone, *i.e.,* mineralized bone (Md bone) plus osteoid, as regenerated by the five variables implanted in periodontal furcation

defects. Values are expressed as mean and standard error of the mean (SEM); n indicates the number of defects per implant variable. …….. **83**

Table 5.9 Dunnett's Multiple Comparison Test compares the control group (Column A) with the experimental groups: rhTGF-β3/Matrigel® (Column B), rhTGF-β3 plus muscle tissue in Matrigel® (Column C), Matrigel®-based autogenous bone (Column D), ICBM-based autogenous bone (Column E). Control (Column A) compared to Matrigel®-based autogenous bone (Column D) showed a significant difference ($p < 0.05$). .....…… **83**

Table 5.10 Alveolar bone regenerated within the periodontal furcation defects of each animal irrespective of implant type used. Animal 4 shows a distinct lack of regenerative capabilities compared to Animals 1, 2 and 3; n is the number of defects per animal. ……... **84**

Table 5.11 Bonferroni's Multiple Comparison Test compares the amount of alveolar bone regenerated in each of the four animals. There is a significant difference between Animal 1 and Animal 4 ($p < 0.001$), Animal 2 and Animal 4 ($p < 0.001$), and Animal 3 and Animal 4 ($p < 0.001$). ……... **85**

Table 5.12 Comparison of the amount of alveolar bone regenerated in periodontal defects in Animals 2 and 4 by rhTGF-β3 in Matrigel®. ……. **86**

Table 5.13 Comparison of the amount of alveolar bone regenerated in periodontal defects in Animals 2 and 4 by 2.5 µg TGF-β3/25 µg rhOP-1/ICBM ossicles. …. **87**

Table 5.14 Comparison of total amount of alveolar bone regenerated in mandibular implants compared to maxillary implants. There is no significant difference between mandibular (41.2 ± 3.9%) and maxillary (43.3 ± 4.9%) defects; n indicates the number of defects. …….. **88**

Table 5.15 Comparison of total amount of alveolar bone regenerated in first and second molars. There is no statistical difference between first (38.3 ± 4.4%) and second (46.2 ± 4.2%) molars; n indicates the number of molars; n indicates the number of molars. ……..……..... **89**

1. INTRODUCTION

Periodontal disease has been with mankind since time immemorial. Evidence of pre-pubertal periodontitis was identified in a 3-million-year-old fossilized maxilla of the early hominid, *Australopithecus africanus* (Ripamonti, 1988) and severe bone loss compatible with periodontitis was noted in the fossilized remains of *Homo heidelbergensis* in Mauer, Germany (Czarnetzki *et al.,* 2003).

Periodontal disease is characterized by inflammation of gingivae and adjacent dental attachment apparatus and is caused by subgingival colonization of oral pathogens (Anusaksathien and Giannobile, 2002), which inhabit dental plaque. Gingivitis, as the earliest indication of periodontitis, may be a separate disease, which in some patients will not advance to periodontitis (Listgarten *et al.,* 1985; Matthews, 2000).

Gingival diseases may be plaque-induced or non-plaque-induced gingival lesions (Armitage, 1999; Wiebe and Putnins, 2000; Kojović and Kesić, 2003). The latter include gingival diseases of specific bacterial origin such as *Neisseria gonorrhea, Treponema pallidum* and streptococci and those of viral origin such as herpetic gingivostomatitis (Armitage, 1999), which is a primary infection by the herpes simplex virus occurring mainly in infants (Keys and Bartold, 2000). Plaque-induced gingivitis is the most common form of gingivitis (Page, 1986; Coventry, 2000) and includes systemic factors associated with the endocrine system, certain medications and malnutrition (Armitage, 1999; Kojović and Kesić, 2003).

The pathogenesis of periodontitis is dependent on the interactions between host and micro-organism and may be complicated by genetic and environmental risk factors (Matthews, 2000; Kantarci and van Dyke, 2002). The development of periodontitis is associated with the progression of predominantly gram-positive bacterial flora to gram-negative anaerobes (Tanner *et al.,* 1979; Holt and Bramanti, 1991; Duncan *et al.,* 1996). A limited number of gram-negative species have been consistently linked with specific forms of periodontal disease: *Porphyromonas gingivalis* with chronic and severe adult periodontitis, and *Actinobacillus actinomycetemcomitans* with localized juvenile periodontitis (Haffajee and Socransky, 1994; Michalowicz *et al.,* 2000; Duncan *et al.,* 2003; Pussinen *et al.,* 2003) and *Prevotella intermedia* and spirochaetes such as *Treponema denticola* (Haffajee and Socransky, 1994; Duncan *et al.,* 2003) with acute necrotizing ulcerative gingivitis.

Periodontal tissue regeneration is the restoration of tooth-supporting structures of the periodontium, including alveolar bone, cementum and periodontal ligament (Nevins *et al.,* 2003). The process depends on the migration, adhesion, proliferation and differentiation of periodontal ligament fibroblasts (Pitaru *et al.,* 1984), which are the predominant cells of the soft connective tissue of the periodontium (McCulloch and Bordin, 1991; McCulloch, 1995) and which play a leading role in the homeostasis and regeneration of periodontal tissue (McCulloch, 1995; Miguel *et al.,* 2003).

Over the years, predictable and complete tissue regeneration of lost or damaged periodontium has remained the ultimate goal in periodontal surgical techniques.

Studies in animals and humans have demonstrated the potential for achieving this seemingly elusive objective. To date, regenerative techniques have included bone graft, root surface conditioning, guided tissue regeneration (GTR) and the use of osteogenic growth factors.

Bone Grafts

Bone grafts are used in advanced stages of periodontal destruction where the underlying alveolar bone has been severely depleted. There are several types of bone grafts that may be used in periodontal tissue regeneration, namely autogenous bone, allografts, alloplastic materials and xenografts. Autogenous bone is transplanted from one site to another within the same patient. It may be obtained from an extra-oral site such as the iliac crest or from an intra-oral site such as a healed extraction site. Disadvantages associated with using autogenous bone are the limited quantities of material available, donor site morbidity and the added discomfort for the patient of a second surgical site. Allografts are transplants between the same species and are subject to graft rejection as well as the transfer of disease (Salgado *et al.,* 2004). Freeze-dried bone allograft material has been shown to reduce the antigenicity of the allograft (Quattlebaum *et al.,* 1988) and demineralization of the bone prior to freeze-drying improves the osteogenicity of the allograft (Mellonig *et al.,* 1981) as the decalcifying process exposes the bone morphogenetic proteins (Urist and Strates, 1971). However, subsequent studies by Rummelhart *et al.* (1989) have shown no significant difference in periodontal bone-fill volume between freeze-dried bone allograft and demineralized freeze-dried bone allograft. Alloplastic materials include porous and non-porous hydroxyapaptite, tricalcium phosphate, polymers and glass-like materials.

Xenografts are transplants between two different species and once again, there is concern regarding the transfer of dangerous pathogens, although Ripamonti *et al.* (1996a; 2002a) have achieved successful periodontal regeneration in baboons using bovine insoluble collagenous bone matrix (ICBM) as delivery system for osteogenic growth factors.

Root Surface Conditioning

Root surface conditioning is the chemical treatment by agents such as citric acid, tetracycline hydrochloride or ethylenediaminetetraacetic acid (EDTA) whereby the root surface is rendered more conducive to the attachment of new periodontal tissue (Register and Burdick, 1975; 1976). Adhesive systems such as fibrin-fibronectin (Ripamonti *et al.,* 1987) or enamel matrix derivatives (Sculean *et al.,* 2000) may be used in conjunction with root conditioning for superior cellular attachment which in turn would lead to regeneration of cementum, periodontal ligament and alveolar bone.

Guided Tissue Regeneration (GTR)

Guided tissue regeneration is a surgical technique in which a barrier membrane is placed between the instrumented root surface and the gingival flap, allowing selective cellular repopulation of a wound-healing site (Nyman, 1982b). This technique allows periodontal ligament cells, which are slower to migrate and proliferate than gingival epithelium, to repopulate the root surface and to form new attachment (Melcher, 1976) followed by regeneration of cementum, periodontal ligament and alveolar bone. Using this technique, Nyman and co-workers carried out extensive studies in animals and humans, and achieved new attachment on

previously diseased root surfaces (Nyman *et al.,* 1982a; 1982b; Gottlow *et al.*, 1984; 1986; 1994; Karring *et al.*, 1993; Lindhe *et al.,* 1995).

Growth Factors

More recently, with the advent of protein isolation techniques, the application of osteoinductive growth factors has shown encouraging results in periodontal tissue regeneration (Giannobile, 1996). Growth factors that have been positively associated with periodontal healing and regeneration include platelet derived growth factor (PDGF), insulin-like growth factor (IGF), fibroblast growth factor (FGF) and members of the transforming growth factor-beta superfamily, namely the bone morphogenetic proteins (BMPs) and the mammalian transforming growth factors -β1, -β2, and -β3 (Graves and Cochran, 1994; Howell, *et al.,* 1996; McCauley and Somerman, 1998; Cochran and Wozney, 1999). BMPs have been used extensively by researchers to induce periodontal tissue regeneration in a variety of animal models (Ripamonti *et al.,* 1994; Sigurdsson *et al.,* 1995; Nevins *et al.,* 1996; Ripamonti and Reddi, 1997; Kinoshita *et al.,* 1997) as well as in human studies (Howell *et al.,* 1997; Cochran *et al.,* 2000) with varying degrees of success. Ripamonti *et al.* (2006) proposed that BMPs possess a structure/activity profile with BMP-2 exhibiting mainly osteogenic properties while osteogenic protein-1 (OP-1), also known as BMP-7, was mainly cementogenic in its activities. In keeping with this theory, BMP-2 periodontal regeneration studies by Ripamonti *et al.,* (2001) and Choi *et al.,* (2002) have demonstrated enhanced alveolar bone formation but with limited cementum formation, whilst OP-1 periodontal regenerative studies have shown limited osteogenesis with a superior cementogenic deposition (Ripamonti *et al.,* 1996a).

Very few periodontal regeneration studies using TGF-βs have been performed. TGF-β1 has been evaluated in dogs (Wikesjö *et al.,* 1998; Tatakis *et al.,* 2000) and sheep (Mohammed *et al.,* 1998) but with disappointing results. To date, very little is known about the regenerative capabilities of TGF-β3 within the periodontal context.

In this study, extra-oral autogenous bone was generated heterotopically in the *rectus abdominis* muscle in non-human primates of the genus *Papio ursinus,* using TGF-β3 in Matrigel® as delivery system, or by using a synergistic combination of TGF-β3 and OP-1 with an insoluble collagenous matrix (ICBM) as carrier. The newly generated bone was transplanted to surgically created Class II maxillary and mandibular defects of the respective animals. In addition, the tissue repair potential of TGF-β3, applied directly to periodontal defects, was examined.

2. LITERATURE REVIEW

2.1 Tissue Engineering for Periodontal Tissue Regeneration

Tissue engineering is based on soluble molecular signals, responding cells and biomaterial matrices for the repair and reconstruction of lost or diseased tissues (Langer and Vacanti, 1993; Reddi, 1994; Hubbell, 1995). It can be defined as the application of biological, chemical and the principles of engineering to repair and regenerate living tissues, using cells, biological factors and biomaterials, alone or in combination (Laurencin *et al.,* 1999).

Periodontal tissue regeneration involves the restoration of both hard and soft tissue components and for this unique process to take place, several cell types need to interact in a coordinated and choreographed manner: endothelial cells for angiogenesis, fibroblasts for soft connective tissue, cementoblasts for cementogenesis and osteoblasts for osteogenesis (Pitaru *et al*., 1994; Bartold *et al.*, 2000). The ideal treatment incorporates not only checking the destructive path of periodontal infection, but the replacement of lost periodontium. True periodontal regeneration is the reconstitution of periodontal attachment apparatus, requiring the formation of new cementum, new alveolar bone, and new periodontal ligament with the insertion of functionally oriented connective tissue fibres (Sharpey's fibres) in both the new cementum and the new alveolar bone (Lynch, 1992; Ripamonti and Reddi, 1994).

2.1.1 Periodontal Ligament

The periodontal ligament (PDL) is the dense, highly organized connective tissue found between the root surface and the alveolar bone. It forms a compact network that stretches between the cementum on the root surface and the surrounding alveolar bone and is firmly anchored by Sharpey's fibres. It plays a major role in the attachment of tooth to bone and consists mainly of fibroblast cells which play an important part in the development, function and regeneration of the tooth supporting apparatus (McCulloch, 1995; Beertsen *et al.*, 1997). Fibroblasts are able to remodel tissue by repopulating wounds and influencing the metabolism of other cell types (Häkkinen *et al.*, 2000), culminating in new fibrous attachment (McCulloch, 1995). Studies have shown that periodontal ligament cells, through unknown mechanisms, have the ability to differentiate into cementoblasts and osteoblasts, thereby forming cementum and alveolar bone (Roberts and Chase, 1981; McCulloch, 1985; Cho and Garant, 1989; Lin, 1994). The necessity of a functional PDL was emphasized in a study conducted by Löe and Waerhaug (1961) in which 58 teeth from dogs and monkeys were extracted and replanted. Thirteen teeth were replanted without PDL, 15 were air-dried for varying periods of time before being replanted and 30 were re-inserted immediately following extraction. All 30 teeth belonging to the latter group became reattached successfully. Those without PDL or with dried PDL showed limited areas of normal PDL and ankylosis occurred in both of these groups. The investigators concluded that an intact PDL is vital when replanting teeth. Younger (1893) had reached the same conclusion in 1892 when he read before the Second District Dental Society of Brooklyn, New York, his paper entitled "Some of the Latest

Phases in Implantation and Other Operations". At the time he had already experienced eight years of success in transplanting teeth. He claimed that the "*periodontal membrane*" was critical to the success of the operation. More recently, Ioannidou and Makris (2003) reported on a 12-year follow-up of an autogenous mandibular canine transplant. At the time of surgery, the 11-year old patient had undergone autotransplantation of an impacted mandibular canine, situated in the anterior sextant, to its normal position in the mandible. After 12 years the tooth continued to remain stable with no sign of ankylosis. Amongst the criteria listed for successful transplantation was the absence of trauma to the PDL.

2.1.2 Cementum

Cementum is one of the key tissues that support the tooth in the periodontium, the others being the periodontal ligament and alveolar bone. It consists of a thin layer of calcified tissue covering the entire dentine surface and is located between the soft periodontal tissue and the root surface. The main function of cementum is to give attachment to collagen fibres (Sharpey's fibres) of the periodontal ligament (Berkovitz *et al.*, 2002). Attachment loss occurs when cementum is severely damaged during the inflammatory process of periodontitis. Cementum is considered to be of pivotal importance in the initial process of periodontal development and regeneration (D'errico *et al.*, 1997). It may be cellular (containing cementocytes) or acellular. Enamel matrix proteins are involved in the formation of acellular cementum and they have the potential to induce regeneration of the same type of cementum (Hammarstrom, 1997). Studies carried out on the composition of cementum show that approximately 50% consists of

hydroxyapatite, the balance being collagen and non-collagenous proteins (Birkedal-Hansen *et al.*, 1997). Cementum is similar in composition to bone but at a microscopic level it becomes apparent that there are several distinct differences: cementum is avascular, has no innervation, does not undergo significant remodelling and has functions different to bone (D'errico *et al.*, 1997). At an ultra-structural level, cementoblasts *in vitro* respond to growth factors and promote mineralization (Somerman *et al.*, 1999; Zhao *et al.*, 2004). Protein extracts of cementum promote cell migration (Nishimura *et al.*, 1989), attachment (McAllister *et al.*, 1990; Somerman *et al.*, 1991), proliferation (Miki *et al.*, 1987) and protein synthesis (Somerman *et al.*, 1987) of gingival fibroblasts and periodontal ligament fibroblasts. These factors combined, play an important role in the formation and regeneration of gingival connective tissue (Miki *et al.*, 1987; Knox and Aukhil, 1988; McAllister *et al.*, 1990).

2.1.3 Alveolar Bone

Alveolar bone is that part of the mandible or maxilla that supports the teeth. The mandible and maxilla are formed by intramembranous ossification, which involves the initiation of bone by mesenchymal cells directly differentiating into osteoblasts with the subsequent synthesis of osteoid matrix and its mineralization. Most other skeletal components are formed primarily through endochondral ossification, which involves mesenchymal cells differentiating into chondroblasts to form cartilage, followed by vascular invasion and bone differentiation. Alveolar bone is dependent on the presence of teeth for its development and maintenance (Berkovitz *et al.,* 2002). Where teeth are absent, as in edentulous

patients, the alveolar bone is resorbed and the alveolar ridge becomes atrophic (Zernik *et al.,* 1997; Berkovitz *et al.,* 2002). Alveolar bone protects the teeth and provides attachment for the collagenous fibres of the periodontal ligament.

2.1.4 Biological Problems in Periodontal Tissue Regeneration

There are several biological problems involved in periodontal wound healing:

- One wound margin consists of vascularized gingival connective tissue, whereas the other margin is avascular calcified root surface (Wikesjö *et al.*, 1992).

- Initiation and promotion of osteogenesis from previously compromised tissue.

- Adhesion of the fibrin clot between the root surface and the gingival flap is crucial for the outcome of periodontal regeneration (Wikesjö *et al.*, 1992; Wikesjö *et al.*, 1995).

- Apical migration of epithelial cells, although this problem has been addressed by the utilization of a cell-occluding membrane (Nyman *et al.*, 1982a).

- Type of defect: 3-wall intrabony defects heal more completely than 2-wall defects, and these in turn heal better than 1-wall defects (Listgarten and Rosenberg, 1979).

Reconstructing these diverse tissues of the periodontal attachment unit has inspired researchers to explore many avenues in their quest for complete periodontal regeneration. However, to date, autogenous bone graft remains the gold standard for regenerating lost bone (Salgado *et al.,* 2004). Unfortunately, the limited amount of bone available, as well as donor site morbidity remains a major drawback for this technique. Inducing bone in a soft tissue site and transplanting it to a bony site is a novel way of generating autogenous bone on demand thereby circumventing the problems of limited quantity and donor site morbidity. A more abundant supply of autogenous bone, ready for transplantation, is certainly desirable and may become a viable alternative in the future. In recent years, progress in regenerative medicine has made recombinant growth factors available as an alternative treatment for periodontal tissue regeneration. These multifunctional biological mediators are able to regulate the proliferation and migration of various cell types and have been found to be beneficial within bony sites, including the periodontium (Anusaksathien and Giannobile, 2002).

2.2 Growth Factors for Periodontal Tissue Regeneration

Normal wound healing consists of three basic phases: inflammation, proliferation and remodelling and these occur in a predictable sequence of events reflecting a delicate balance of cellular and biochemical activity (Stadelman *et al.*, 1998). Acute wounds release growth factors which stimulate cell activity up to three times that observed in fibroblast cells grown in serum-free culture (Bennet and Schultz, 1993). Chronic wounds, however, do not have the same reaction due to reduced levels of growth factors (Bennet and Schultz, 1993; Cooper *et al.*, 1994). Growth

factors are able to stimulate cell migration, proliferation, differentiation and matrix synthesis, which are the basic necessities for rapid tissue repair (Greenhalgh, 1996) and have therefore become a possible alternative treatment for tissue repair and regeneration. Growth factors that have been identified as having a positive impact on periodontal healing and regeneration include:

- Platelet-derived growth factor (PDGF)
- Insulin-like growth factor (IGF)
- Fibroblast growth factor (FGF)
- Transforming growth factor-β1, -β2, and -β3 (TGF-βs)
- Bone morphogenetic proteins (BMPs) of the TGF-β superfamily

(Graves and Cochran, 1994; Howell, *et al.,* 1996; McCauley and Somerman, 1998; Cochran and Wozney, 1999).

For the purpose of this study only BMPs and TGF-βs will be discussed further.

2.2.1 Bone Morphogenetic Proteins in Periodontal Tissue Regeneration

In species ranging from *Drosophila melanogoster* (fruit fly) to humans, bone morphogenetic proteins (BMPs) play a critical role as signaling molecules during embryogenesis (Sykaras and Opperman, 2003). They are a unique group of morphogens within the transforming growth factor-β superfamily, which play a key role in the induction, maintenance and repair of bone (Sykaras and Opperman, 2003). BMPs, originally isolated from extracellular matrix of bone, are capable of

inducing heterotopic cartilage and bone when implanted in muscle (Urist, 1965). Over the years, scores of BMPs have been identified (Celeste *et al.,* 1990; Reddi, 1997), with BMPs -2 through -7 known to induce bone (Wang *et al.,* 1990).

During tooth morphogenesis, the enamel knot, which is a transitory signaling centre, regulates tooth initiation and shape (Jernvall *et al*., 1994; Vaahtokari *et al.*, 1996; Åberg *et al.*, 1997; Coin *et al.*, 2000; Nakashima and Reddi, 2003). BMPs -2, -4, and -7 were localized by immunohistochemical techniques within the enamel knot, together with Sonic hedgehog (SHH) and fibroblast growth factor (FGF-4). BMPs -2, -4, -5 and -7 induce and form dentine and enamel, and BMP-3 is distributed in the dental follicle cells only, which give rise to cementoblasts and ultimately cementum (Åberg *et al.*, 1997).

Significant discoveries have been made in the use of BMPs to manipulate periodontal tissue repair and regeneration (Ripamonti *et al.,* 1994; Ripamonti and Reddi, 1997; Giannobile *et al.,* 1998; Ripamonti *et al*., 2002a). Regenerative periodontal studies using different animal models and a variety BMPs and delivery systems have been very encouraging. Sigurdsson *et al.,* (1995) and Kinoshita *et al.* (1997) successfully achieved periodontal regeneration in dogs using recombinant human bone morphogenetic protein-2 (rhBMP-2) and a synthetic carrier. New alveolar bone and cementum were noted. Choi *et al.,* (2002), however, also in a canine model and using rhBMP-2 in an absorbable collagen sponge carrier, achieved alveolar bone regeneration but poor cementum and periodontal ligament. These studies show consistently good results for the regeneration of alveolar bone using rhBMP-2 as do other studies using the same recombinant protein in goats

(Nevins *et al.*, 1996), dogs (Toriumi *et al.*, 1991), baboons (Ripamonti *et al.*, 2001) and humans (Howell *et al.*, 1997; Cochran *et al.*, 2000). Ripamonti *et al.* (2006) indicated that BMPs are pleiotropic in nature and possess a structure/activity profile with BMP-2 having mainly osteogenic capabilities while OP-1 (BMP-7) is predominantly cementogenic in its actions (Ripamonti *et al.*, 2001; 2002a). In support of this theory, many other studies using OP-1 (BMP-7) have demonstrated osteogenesis with a healthy cementogenic component in a variety of animal models (Giannobile *et al.*, 1998; Ripamonti *et al.,* 2002a; Jin *et al.,* 2003). Helder *et al.* (1998), in a study using BMP-7-deficient mice, demonstrated a functional redundancy when no qualitative differences in dental development were noted; only a slight retardation of 0.5 to 1.0 day in dental development, which was related to the general growth retardation of these animals. It was therefore concluded that BMP-7 was not essential for tooth development.

Clinical trials using rhBMP-2 in an absorbable collagen sponge carrier (Howell *et al.,* 1997; Cochran *et al.,* 2000) have yielded encouraging results with the protein and carrier being well tolerated locally and systemically. Naturally-derived BMPs, then labelled as osteogenin, were the first BMPs to be used in a human periodontal study (Bowers *et al.,* 1991). When combined with demineralized freeze-dried bone allograft (DFDBA), and in a submerged environment, naturally-derived BMPs significantly enhanced regeneration of new attachment apparatus and alveolar bone when compared to controls. In the same study, naturally-derived BMPs plus collagen carrier showed no increase in bone or cementum. Osteogenin, purified to homogeneity is known as BMP-3 (Luyten *et al.,* 1989; Ripamonti *et al.,* 1992a). Recently, in a rat fenestration defect study, BMP-6 was applied to an

absorbable collagen sponge and resulted in new bone and cementum formation in a dose dependent manner (Huang *et al*., 2005). The authors claimed this to be the first study using BMP-6 in periodontal wound healing. Lately, BMP-12 has become the focus of attention for periodontal regeneration studies. In a canine study, Wikesjö *et al.* (2004) evaluated rhBMP-12 for periodontal regeneration, especially periodontal ligament formation. Recombinant human BMP-12 and rhBMP-2 were implanted on absorbable collagen sponge in periodontal defects and the results were compared after 8 weeks. More regenerated bone was observed in implants that had received rhBMP-2 but ankylosis was noted. Defects that had received rhBMP-12 showed less bone regeneration but exhibited a functionally oriented periodontal ligament, newly formed cementum and new alveolar bone. However, in a tooth replantation study using BMP-12, Sorensen *et al*. (2004) noted that a topical application of rhBMP-12 to teeth, which had been previously denuded of periodontal ligament, failed to re-establish new periodontal ligament.

2.2.2 Transforming Growth Factor-β in Periodontal Tissue Regeneration

Transforming growth factors-beta (TGF-βs) are members of a large superfamily of growth factors. They have the ability to promote or inhibit proliferation of many cell types in postnatal tissues and are modulators of cartilage and bone differentiation (Cox, 1995). Nimni (1997) hypothesized that the term 'growth factor' was probably a misnomer for these polypeptides because they did not always encourage growth but acted rather as the modulators of cellular activities. Latent TGF-β, activated by osteoclasts during bone resorption, stimulates

osteoblastic function and bone formation, suggesting that TGF-βs play a key role in bone remodeling (Rose *et al.*, 2004). The TGF-β family includes activins, inhibins, osteogenic proteins/bone morphogenetic proteins (OPs/BMPs) and four closely related TGF-β isoforms, namely TGF-β1, TGF-β2 and TGF-β3 which have been identified in mammals and TGF-β5 detected in amphibians.

TGF-βs have been detected in alveolar bone, periodontal ligament and cementum at all stages of development and therefore play a significant role in the morphogenesis of tooth development (Heikinheimo, 1993; Thesleff *et al.,* 1995; Gao *et al.,* 1998). Immunohistochemical localization of TGF-β1, -β2 and -β3 in mouse embryo suggest multifunctional roles for these isoforms (Pelton *et al*., 1991), especially during early tooth development (Ruch *et al.,* 1995; Thesleff *et al.,* 1995). Cassidy *et al.* (1997) concluded that TGF-β isoforms in dentine might provide a reservoir of growth factor that could be deployed in the processes leading to tissue repair. A TGF-β abrogation study on embryonic craniofacial morphogenesis (Chai *et al.*, 1994) demonstrated that TGF-β1 regulated chondrogenic cells, extracellular matrix and the development of Meckel's cartilage, TGF-β2 regulated tooth size, and TGF-β3 regulated Meckel's cartilage. TGF-β3-deficiency has also been linked to the incidence of maxillary cleft palate (Chai *et al*., 1997; Slayton *et al.*, 2003).

Several *in vitro* studies have shown that TGF-βs are able to stimulate fibroblast cell activity of the gingivae, promoting differentiation and proliferation (Anderson *et al.,* 1998; Galetti *et al.*, 2000; Marcopoulou *et al.*, 2003). Oates *et al.*, (1993) noted that these activities were increased by TGF-β in a dose-dependant manner. Bergue-Kirn *et al.* (1992) demonstrated that a TGF-β-like molecule present in

dentine could interact with other components to act as a modulator in the differentiation of odontoblasts. The effects of TGF-βs in periodontal repair in canine models has been unremarkable (Wikesjö *et al.,* 1998; Tatakis *et al.,* 2000). Mohammed *et al.* (1998) using TGF-β1 in a periodontal regeneration study in sheep found that positive results were only evident after a membrane barrier was added. The TGF-β3 isoform is one of the three mammalian TGF-β isoforms isolated from the TGF-β superfamily. It is considered to be far more potent as a regulator of functions associated with osteogenesis and angiogenesis than TGF-β1 or TGF-β2 (Cox *et al.,* 1994; Chien *et al.*, 1999), and the main isoform found in canine periodontium (Coelho *et al.,* 2004). In addition, it is reported to be a powerful inducer of bone when implanted in heterotopic sites in non-human primates (Ripamonti *et al.,* 2000). To date, few studies have been carried out using TGF-β3 for periodontal tissue regeneration.

2.2.3 Synergy of Bone Morphogenetic Proteins and Transforming Growth Factor-β for Tissue Engineering

Bliss (1939), as quoted by Greco *et al.* (1995), defined synergy as two agents acting in such a manner that neither one interferes with the other but each contributes to a common result. Greco *et al.* (1996) also stated that synergy between two or more entities was usually considered to be a positive attribute of the combination and that the observed effect was greater than that which is the known effect of each agent working alone.

Ripamonti *et al.* (1997) induced large ossicles in extraskeletal sites in primate models when harnessing the synergistic action of rhTGF-β1 combined with OP-1. The newly formed ossicles exhibited distinct morphological differences compared to those where rhOP-1 alone was used, showing large areas of endochondral development and extensive bone marrow formation. The same results were noted by Duneas *et al.* (1998) when a binary application of rhOP-1 and platelet-derived porcine TGF-β1 was used in calvarial sites in primates. Significant bone regeneration occurred when using the combination, whereas an application of TGF-β1 alone did not induce any bone formation in calvarial sites. Cho *et al*. (2002) examined the temporal patterns of mRNA expression for TGF-βs during fracture healing in mouse tibias over a 28-day period and concluded that several members of the TGF-β family are involved in fracture healing. Each had a distinct temporal expression pattern and played a unique role in the healing process, although some TGF-βs exhibited overlapping functions in promoting bone formation and differentiation.

When taking into account the complexities of tissues being regenerated such as those found in the periodontium (Howell *et al.,* 1996), synergistic activity may be needed for the optimal performance of morphogens/growth factors (Ripamonti *et al.*, 2001). Ripamonti *et al.* (1997) suggested that synergistic interaction might be a general activity in embryonic development and postnatal morphogenesis, an attribute that could be exploited in tissue engineering and postnatal regeneration. In an immunolocalization study by Thomadakis *et al.* (1999), the distribution of BMPs -2, -3, and -7 during root morphogenesis was examined in 12- to 18-day old mice. The complex expressions of BMPs during periodontal tissue morphogenesis

suggested that optimal therapeutic regeneration might entail the combined use of different BMPs**.**

2.3 Skeletal Muscle for Tissue Engineering

In 1970, Nogami and Urist reported that muscle-derived mesenchymal cells differentiated into cartilage and chondro-osseous tissue in cultures when foetal muscle tissue was placed on vessels made of demineralized rat bone matrix. In a similar *in vitro* study conducted by Sampath *et al.* (1984), mesenchymal cells were transformed into chondrocytes using minced embryonic skeletal muscle cultured on hemicylinders of demineralized bone. Using implants of minced skeletal muscle, Zacks and Sheff (1982), reported that nodules of cartilage and bone were induced in mouse limbs. These nodules arose when regeneration of muscle from minced muscle was unsuccessful. Subsequent studies have shown that skeletal muscle tissue contains cells which, when stimulated with a bone morphogenetic protein, are able to differentiate into osteoblasts (Lee *et al.,* 2001; Turgeman *et al.,* 2002; Lu *et al.,* 2003; Corsi *et al.,* 2004; Sun *et al.,* 2005) and that muscle-derived cells are able to complete the differentiation pathway that leads to the formation of bone (Mastrogiacomo *et al.,* 2005). Unpublished data by Ripamonti *et al.* reported that minced skeletal muscle tissue when combined with a morphogen and added to a bony defect site, encouraged bone repair.

In the present study, skeletal muscle, transplanted from the r*ectus abdominis* muscle of the baboon, was added to rhTGF-β3 with Matrigel® as carrier and implanted in periodontal defects.

2.4 Delivery Systems for Periodontal Tissue Regeneration

One of the most critical aspects of wound repair by growth factor intervention is the use of an optimal delivery system (Rose *et al*., 2004). In the event of an unsuitable carrier being chosen, the full potential of the osteogenic agent may not be achieved and doses above the therapeutic threshold may need to be employed (Li and Wozney, 2001). An experiment may be severely compromised if the delivery system is inadequate. Kuboki *et al.* (1998a) demonstrated that the inductive properties of BMPs might depend on the type of carrier used. In a periodontal regeneration experiment using cats and monkeys, a BMP cocktail was combined with either one or two layers of fibrous collagen membrane. Those defects that had received BMP cocktail and one layer of fibrous collagen membrane showed only partial periodontal regeneration with evidence of ankylosis. Defects that received BMP cocktail and two layers of fibrous collagen membrane showed alveolar bone, periodontal ligament and cementum with Sharpey's fibres and no ankylosis. In a canine periodontal regeneration study, Coelho *et al.,* (2003) noted the consequences of using an inappropriate delivery system. TGF-β3, as the main isoform in intramembranous bone of the mandible (Coelho *et al.*, 2004), showed minimal osteogenic regeneration when used in critical-sized defects with tricalcium phosphate (TCP) and polylactide acid (PLA) carriers. The authors concluded that TGF-β3, with its high capacity for stimulating mesenchymal cells at an angiogenic and osteogenic level, required a more efficacious delivery system.

The ideal delivery system should include the following criteria:

- It should serve as a three dimensional scaffold (Rose *et al.,* 2004) which has surface properties that allow for cell adhesion, angiogenesis and nerve regeneration (Li and Wozney, 2001; Rose *et al.,* 2004; Salgado *et al.,* 2004; Holmes, 2002). Studies in tissue engineering emphasize the importance of geometry of scaffolds in order to encourage cell attachment and differentiation (Ripamonti *et al.,* 1992a; van Eeden and Ripamonti, 1994; Magan and Ripamonti, 1996; Kuboki *et al.,* 1998b; Ripamonti *et al.,* 1999; Jin *et al.,* 2000; Ramoshebi *et al.,* 2002; Holmes, 2002; Ripamonti, 2004a). Scaffold degradation rate should be in step with the growth rate of the newly formed tissue (Salgado *et al.,* 2004; Hou *et al.,* 2004), ensuring that new mechanical properties gradually replace those of the scaffold.

- Growth factors incorporated within the delivery system should not be compromised during the manufacturing process which may involve high temperatures or organic solvents being used (Rose *et al.,* 2004). The protein dose concentration should remain within a therapeutic range over a specific time period to allow for successful tissue regeneration (Nimni, 1997). Rapid diffusion of growth factors should be prevented and released in a time-controlled manner, stimulating and sustaining tissue regeneration (Li and Wozney, 2001; Rose *et al.,* 2004; Hou *et al.,* 2004). In a rat study, Uludag *et al.* (2001) quantitated, by means of ^{125}I-labeling, the levels of ectopically implanted rhBMPs and demonstrated that carriers with a higher retention ability elicited more bone formation. In another rodent

experiment on the effects of carrier release kinetics, Talwar *et al.* (2001) compared fast and slow degrading gelatine carriers in rhBMP-2-induced periodontal healing. Rapid protein release resulted in increased bone formation whilst slow protein release promoted a significant increase in cementum.

- The carrier should be biocompatible, lacking in cytotoxicity, causing only minimal inflammation and immune responses (Li and Wozney, 2001; Hou *et al.,* 2004; Salgado *et al.,* 2004; Holmes, 2002).

- Production, purification and processing should be easy and cost-effective (Li and Wozney, 2001; Holmes, 2002).

- The carrier should be user friendly, amenable to modification, and have an element of malleability in order to adapt to different defect sizes and contours (Li and Wozney, 2001; Holmes, 2002). Mouldable materials are preferred as they have greater integration with surrounding tissue (Holmes, 2002).

Delivery systems may be naturally-derived or synthetic materials and include:

Autogenous bone graft, which provides osteogenic cells and osteoinductive proteins required for bone regeneration (Rose and Oreffo, 2002). It is bone taken from another part of the patient's own body and as such is in limited supply due to donor site morbidity. In a periodontal application it may be extra-oral, in which

case it is taken from the iliac crest, or intra-oral, which is usually obtained from the maxillary tuberosity or a healing extraction site (Simion and Fontana, 2004).

Allograft bone is bone taken from a donor of the same species as the intended recipient and is subject to immune rejection and infections, or the transmission of pathogens from donor to host, which may occur after transplantation (Salgado *et al.,* 2004). Demineralized freeze-dried bone allograft (DFDBA) and freeze-dried bone allograft (FDBA) are examples of allograft bone. Quattlebaum *et al.* (1988) however, claimed that the freeze-drying process of DFDBA significantly reduced its antigenicity making rejection less likely. DFDBA has been used in human periodontal regeneration studies by Blank and Levy (1999) and Nevins *et al.* (2003).

Xenografts are transplants between individuals of two different species. These may carry dangerous viruses or pathogens such as spongiform encephalopathies, which are capable of being transmitted from animals to humans (Scott *et al.,* 1999). Bovine insoluble collagenous bone matrix (ICBM) has been used successfully in periodontal defect sites in baboon experimental studies (Ripamonti *et al.*, 1996a; Ripamonti *et al.*, 2002a).

Alloplastic materials are synthetic materials such as hydroxyapaptite, tricalcium phosphate, glass-like materials and biodegradable polymers such as polylactic acid (PLA) or polyglycolic acid (PGA). Sigurdsson *et al.* (1995) used poly(D,L-lactide-co-glycolide) (PLGA), which are synthetic bio-degradable particles, as carrier for rhBMP-2 in a periodontal regeneration study in dogs.

Preformed scaffolds such as absorbable collagen sponges (ACS) have been used extensively as carriers for rhBMP-2-induced periodontal regeneration in dogs (Choi *et al.,* 2002), goats (Nevins *et al.,* 1996) and humans (Howell *et al.,* 1997; Cochran *et al.,* 2000). However, preformed scaffolds cannot be adapted with precision to conform to a bone defect site.

Injectable systems that solidify *in situ* are particularly attractive and have the following advantages:

- They are surgically less invasive to the patient (Ritter-Jones and Messersmith, 2002; Hou *et al.,* 2004).

- They can be used in areas that are difficult to access.

- The injected material is able to conform to the shape of the defect resulting in a three dimensional scaffold that is closely integrated with surrounding tissue (Ritter-Jones and Messersmith, 2002; Hou *et al.,* 2004).

- Growth factors may be incorporated (Holmes, 2002; Ritter-Jones and Messersmith, 2002; Hou *et al.,* 2004) and retained at an application site (Ululag *et al.,* 2001).

Solidification mechanisms for injectable scaffolds should occur under mild conditions so as to maintain high cell viability and molecular bioactivity as well as preventing any damage to surrounding tissue (Hou *et al.,* 2004). Solidification

methods include ceramic setting, thermally or photochemically triggered systems, and thermal gelation (Ritter-Jones and Messersmith, 2004; Hou *et al.*, 2004). Matrigel® is an example of a thermally responsive biomatrix which is liquid at 4°C and gels at 37°C. It is a soluble basement membrane extract of the Engelbreth-Holm-Swarm tumour that gels rapidly to form a genuine reconstituted basement membrane (Kleinman *et al.*, 1986). Matrigel® matrix is also available as a growth factor-reduced product in which the level of a variety of growth factors, except TGF-β, has been effectively reduced (Catalogue number 354230, BD Biosciences). Vukicevic *et al.* (1990) demonstrated vigorous growth and differentiation of bone cells on a reconstituted gel of basement membrane. The cells formed clusters with interconnecting cytoplasmic projections similar to the canalicular network seen in bone. However, the authors cautioned that the growth factors in Matrigel® were active and results should therefore be interpreted accordingly (Vukicevic *et al.,* 1992). Maxian *et al.* (1998) examined the mitogenic behaviour of rat calvarial cells on various biomaterials coated with Matrigel®. Biomaterials used were high and low crystallinity hydroxyapaptite, rough titanium and tissue culture polystyrene. Alkaline phosphatase activity (APA) and cell growth were measured for Matrigel®-coated and uncoated surfaces. APA was enhanced on the titanium surfaces and even more so on both types of hydroxyapaptite-coated surfaces in the presence of Matrigel®. Ripamonti *et al.* (2002b) noted an increase in bone mineral density, as measured by dual photon x-ray absorptiometry, after injecting hOP-1 with Matrigel® as carrier into the lumbar vertebrae of oestrogen-deficient baboons.

The ensuing chapters will illustrate a method used for the regeneration of periodontal tissue by application of TGF-β3 alone, or in combination with skeletal muscle tissue, in an injectable, thermodynamic matrix. The regenerative capabilities of growth factor-induced, extra-oral autogenous bone graft material will also be examined.

3. AIM OF STUDY

The aims for this study were as follows:

1. To determine whether rhTGF-β3, or rhTGF-β3 plus muscle tissue from the *rectus abdominis,* delivered by Matrigel® as carrier, will induce periodontal tissue regeneration in bilateral, surgically created periodontal defects in the first and second molars of both the mandible and the maxilla of the adult baboon (*Papio ursinus).*

2. To determine whether induced autogenous bone, generated heterotopically in the *rectus abdominis* muscle, using TGF-β3 in Matrigel® carrier, or using a synergistic combination of TGF-β3 and osteogenic protein-1 (OP-1) in Matrigel® carrier, are viable devices for transplantation to induce healing in bilateral, surgically-created periodontal defects in the first and second molars of both the mandible and the maxilla of the adult baboon (*Papio ursinus).*

4. MATERIALS AND METHODS

4.1 Animals

Four clinically healthy adult baboons (*Papio ursinus*) with an average body mass of 21,5 kg were selected from the non-human primate colony of the University of the Witwatersrand, Johannesburg. The animals were caged individually in rooms kept under slight negative pressure (-25 kPa) with controlled ventilation (18 filtered air changes per hour), temperature (22 ± 2° C), humidity (40 ± 10%) and photoperiod (lights on 06h00 to 18h00). The animals were fed a diet of basic proteins, carbohydrates, dietary fibre, fats, calcium, iron, phosphates and vitamins (riboflavin, nicotinic acid and thiamine).

4.2 Implant Materials

The soluble molecular signals to induce heterotopic autogenous bone were transforming growth factor-beta 3 (TGF-β3) and osteogenic protein-1 (OP-1). TGF-β3 was used either alone or in combination with OP-1 in either Matrigel® matrix or insoluble collagenous bone matrix (ICBM) as carrier.

The periodontal implants consisted of TGF-β3 alone, TGF-β3 together with minced muscle tissue, and the heterotopically induced autogenous bone material harvested from the *rectus abdominis* muscle.

4.2.1 Growth Factors

4.2.1.1 *rhTGF-β3* (Novartis, Basel, Switzerland)

The dilutions for rhTGF-β3 were made as described in Appendix 1. Briefly, a stock solution was made by re-suspending 800 µg rhTGF-β3 in 2000 µl of 5 mM HCl. This solution was aliquotted into amounts of 125 µl stock solution for the 2.5 µg rhTGF-β3 and 1.5 µg rhTGF-β3 doses and 1875 µl stock solution for the 75 µg rhTGF-β3 dose. A constant volume of 200 µl per dose was used for both heterotopic and periodontal implants.

4.2.1.2 *rhOP-1* (Stryker Biotech, U.S.A.).

As shown in Appendix 2, the required dose of 25 µg rhOP-1 was made from an available stock solution.

4.2.2 Muscle Tissue

Freshly harvested muscle tissue taken from the *rectus abdominis* during the second surgical procedure (Phase 2) was used in this study. The muscle was minced with scalpel blades and added to rhTGF-β3 and Matrigel® at the time of surgical implantation (Phase 2).

4.2.3 Delivery System

4.2.3.1 Growth Factor-Reduced (GFR) Matrigel® Matrix (BD Biosciences, catalogue number 354230).

Matrigel® matrix is a soluble basement membrane extract of the Engelbreth-Holm-Swarm tumour that is liquid at 4°C and gels rapidly at 37°C to form a genuine reconstituted basement membrane (Kleinman *et al.*, 1986).

4.2.3.2 Insoluble Collagenous Bone Matrix (ICBM)

ICBM was prepared as shown in Appendix 3. Briefly, baboon cortical bone was dehydrated with alcohol, crushed and demineralized with hydrochloric acid after which it was neutralized and treated with guanidinium hydrochloric acid containing protease inhibitors (Sampath and Reddi, 1981; Ripamonti *et al.,* 1992b).

4.3 Preparation of Implants

4.3.1 Matrigel®-Based Implants

As per manufacturer's specifications, to maintain a gelled consistency, a Matrigel® dilution not exceeding 1:3 was used. Appendix 4 shows the method used for making the Matrigel®-based implants. In short, a volume of 200 µl growth factor solution was added to 400 µl Matrigel® delivery system resulting in a final volume

of 600 µl of implant device. Prepared devices were stored in the cold until implantation.

4.3.2 ICBM-Based Implants

As shown in Appendix 5, rhTGF-β3 and rhOP-1 were combined with ICBM to allow for protein precipitation into the ICBM. Chondroitin sulphate and baboon type I collagen were added followed by washing and centrifuging in pre-chilled ethanol. The pellets were drained by briefly inverting the tubes on paper towel after which they were lyophilized overnight.

4.4 Surgery on Baboons

Surgery was performed in three phases. During the first phase growth factors were implanted heterotopically in the *rectus abdominis* muscle of each animal and periodontal defects were prepared. After 40 days (Phase 2), autogenous bone in the form of ossicles was harvested from each animal and these were fragmented and implanted in periodontal defect sites. At the same time, selected periodontal defects were implanted with rhTGF-β3 and rhTGF-β3 plus muscle tissue in Matrigel® carrier. Control defects were filled with Matrigel® only. The defects were allowed to heal for 60 days after which the animals were euthanased (Phase 3).

4.4.1 Phase 1: Heterotopic Implantation of Molecular Soluble Signals for the Induction of Autogenous Bone and Preparation of Periodontal Defects.

4.4.1.1 Heterotopic Surgery

Day 0. The animals were fasted before surgery and immobilized with an intramuscular injection of ketamine hydrochloride (10 mg per kilogram of body weight) and anesthetized intravenously using thiopentone sodium (30 mg per kilogram of body weight). Anaesthesia was maintained with halothane vapour in 100 per cent oxygen following rhinotracheal intubation. The ventral aspect of the animal was exposed, shaved, rendered aseptic with Hibitane and the area of interest surrounded by sterile drapes. Five (for Animals 1 and 3) or four (for Animals 2 and 4) ventral intramuscular pouches (Figure 4.1) were made by sharp and blunt dissection as follows: Using sterile operative techniques, longitudinal incisions, measuring 15 - 20 mm, were made bilaterally in the *rectus abdominis* muscle of each of the four baboons. The following materials were implanted:

- Matrigel® carrier together with 75 μg rhTGF-β3 (Figure 4.2),
- Matrigel® carrier together with 2.5 μg rhTGF-β3 and 25 μg rhOP-1 (Figure 4.2),
- Matrigel® carrier together with 1.5 μg rhTGF-β3 and 25 μg rhOP-1 (Figure 4.2),
- ICBM carrier together with 2.5 μg rhTGF-β3 and 25 μg rhOP-1 (Figure 4.3),
- ICBM carrier with 1.5 μg rhTGF-β3 and 25 μg rhOP-1 (Figure 4.3).

Matrigel®-based implants were allowed to stand at room temperature for 15 – 30 minutes before use, and applied using sterile 1 ml syringes (Figure 4.2).

Figures 4.4 and 4.5 show the surgical implant design used for each animal. The design for Animals 1 and 3 were alike and the design for Animals 2 and 4 were alike. The incisions were closed in layers using resorbable sutures.

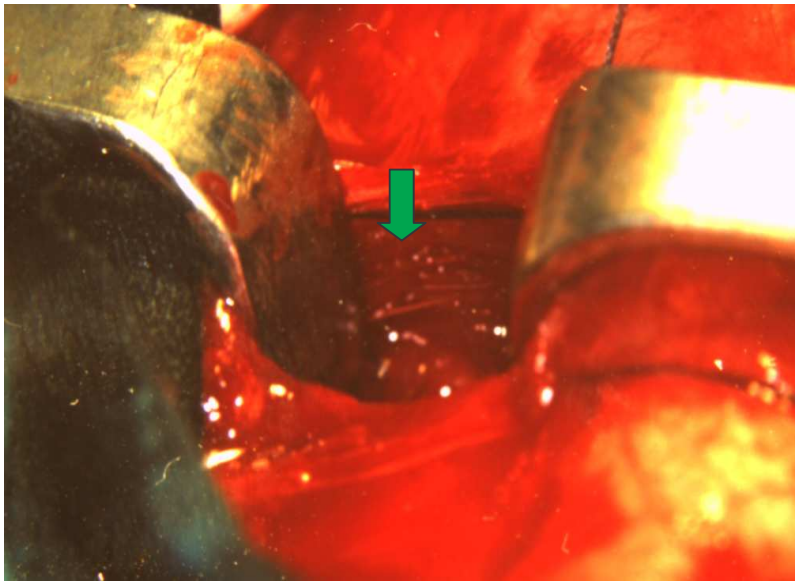

Figure 4.1. Heterotopic implant site in the *rectus abdominis* muscle. Green arrow indicates pouch made to receive implant.

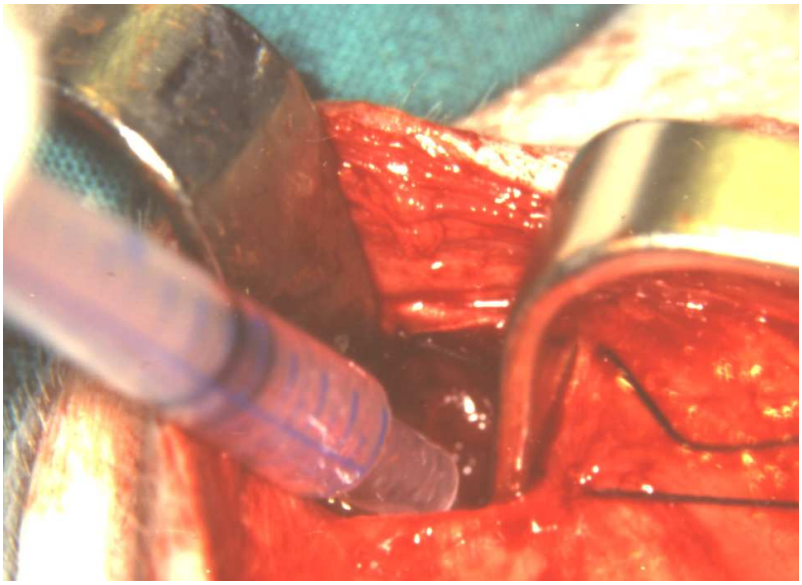

Figure 4.2. Application of Matrigel®-based implant in the *rectus abdominis* muscle.

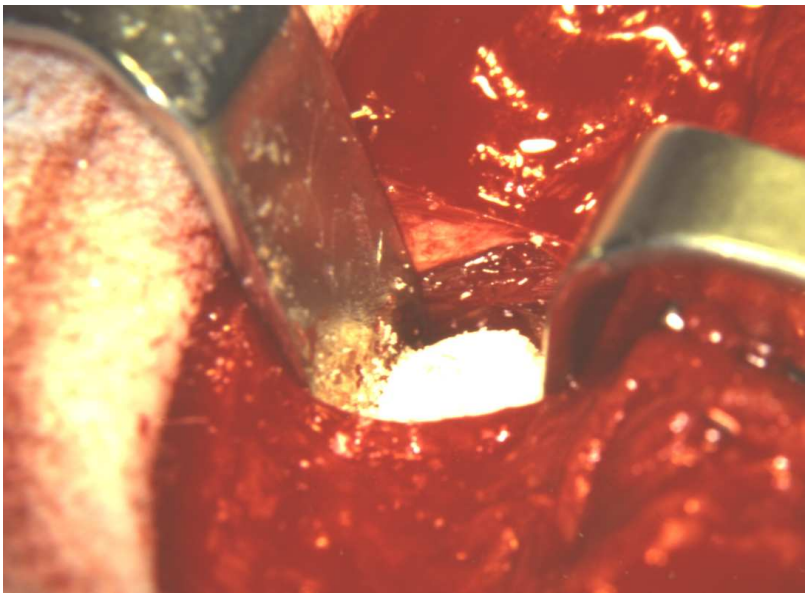

Figure 4.3 Application of ICBM-based implant in the *rectus abdominis* muscle.

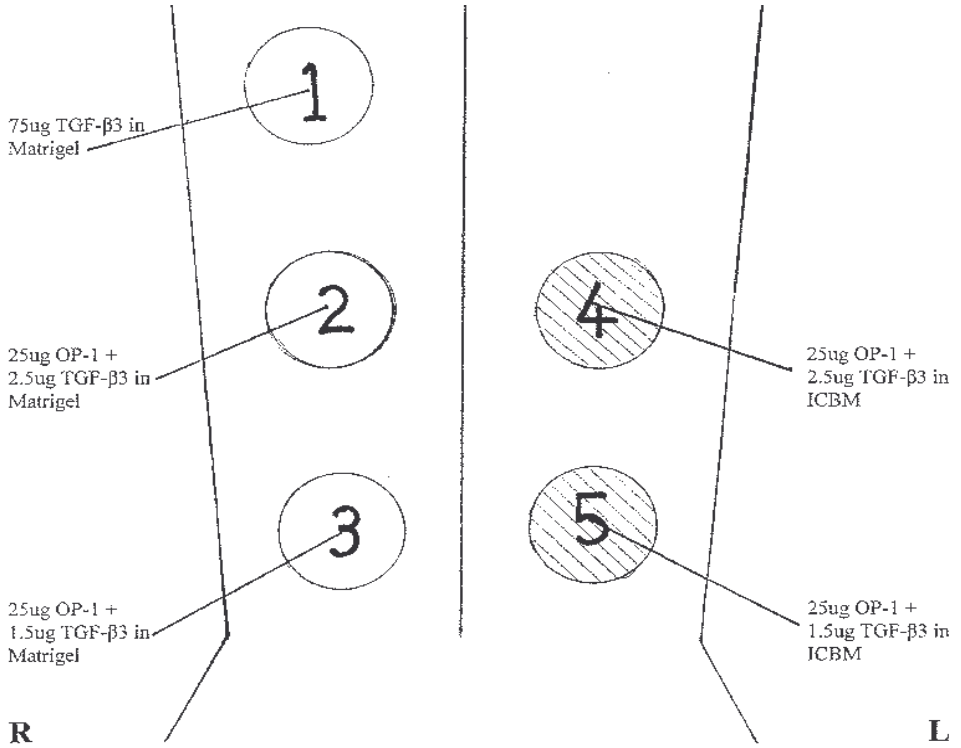

Figure 4.4 *Animals 1 and 3:* Surgical implant design for heterotopic implants.

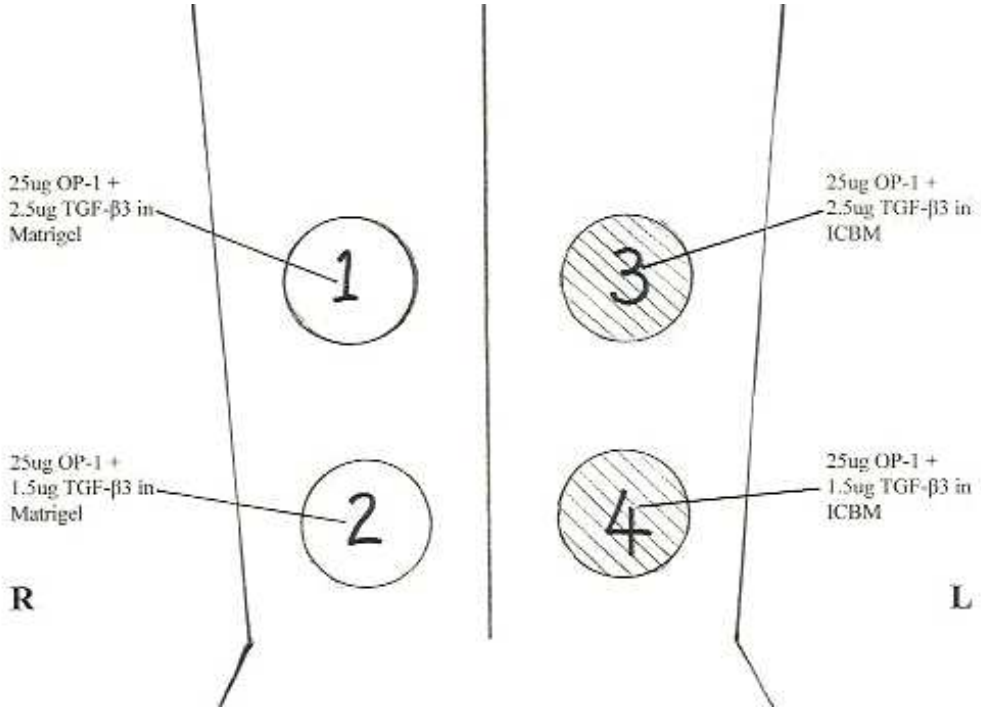

Figure 4.5 *Animals 2 and 4:* Surgical implant design for heterotopic implants.

4.4.1.2 Periodontal Surgery

Day 0. Full thickness mucoperiosteal flaps were raised to expose the alveolar bone. A total of eight Class II furcation defects, measuring 6-8 mm in height and with a buccolingual depth 10-12 mm, were made bilaterally in the first and second molars of both the mandible and maxilla of each animal (Ripamonti *et al.,* 1994; 1996a). Class II furcation defects exceed the horizontal periodontal tissue loss limit of 3 mm as seen in Class I, but do not exhibit the horizontal "through and through" destruction of periodontal tissue of Class III furcation defects (Hamp *et al.,* 1975.) The exposed root surfaces were denuded of periodontal ligament fibres and cementum. The flaps were realigned and sutured using resorbable sutures. Postoperative pain was controlled by buprenorphine hydrochloride administered by intramuscular injection.

4.4.2 Phase 2: Harvesting of Heterotopically Induced Autogenous Bone and Implantation of Periodontal Defects.

4.4.2.1 Heterotopic Surgery

Day 40. On day 40 it was noted that several of the ossicles had been resorbed. The presence of these ossicles had been previously determined by palpation of the abdomen. Of the eighteen implants only seven ossicles were harvested. Tables 4.1, 4.2, 4.3 and 4.4 show the fate of the heterotopic implants after 40 days. Table 4.5 gives a summary of the remaining ossicles as well as those which were lost to the resorption process. It should be noted at this point that only Matrigel®-based

implants were meant to be transplanted to periodontal sites and that the ICBM-based implants were for laboratory interest only. However, in light of the fact that none of the low-dose Matrigel®-based implants survived the 40 day implant period, an *ad hoc* decision was made to use two of the ICBM-based ossicles for transplantation to the periodontium (Animals 2 and 4). All surviving ossicles were surgically removed from the anaesthetized animals and those earmarked for transplantation were fragmented with a scalpel and placed on ice to await transplantation to periodontal defect sites (Figures 4.6 and 4.7). In an effort to retain a balanced study (i.e. Animals 1 and 3 alike and Animals 2 and 4 alike), it was decided that Animals 1 and 3 receive the 75 µg/Matrigel® ossicles and Animals 2 and 4 receive the 2.5 µg rhTGF-β3/25 µg rhOP-1/ICBM ossicles for transplantation to the periodontium. Ossicles were assessed only as having sufficient material for transplantation and were therefore not weighed, measured or radiographed during surgery. Any ossicle or portion thereof that was not used for transplantation to a periodontal defect site was placed in 10% phosphate buffered formalin in preparation for histological analysis.

Table 4.1 *Animal 1:* Heterotopic implant doses and fate of implants after forty days.

Implant Site No.	Type of implant	Fate of implant
1	75 µg rhTGF-β3 in Matrigel®	Transplanted to left and right maxillary defects
2	2.5 µg rhTGF-β3 plus 25 µg rhOP-1 in Matrigel®	Resorbed
3	1.5 µg rhTGF-β3 plus 25 µg rhOP-1 in Matrigel®	Resorbed
4	2.5 µg rhTGF-β3 plus 25 µg rhOP-1 in ICBM	Resorbed
5	1.5 µg rhTGF-β3 plus 25 µg rhOP-1 in ICBM	Harvested for histology

Table 4.2 *Animal 2:* Heterotopic implant doses and fate of implants after forty days.

Implant Site No.	Type of implant	Fate of implant
1	2.5 μg rhTGF-β3 plus 25 μg rhOP-1 in Matrigel®	Resorbed
2	1.5 μg rhTGF-β3 plus 25 μg rhOP-1 in Matrigel®	Resorbed
3	2.5 μg rhTGF-β3 plus 25 μg rhOP-1 in ICBM	Transplanted to left maxillary defects
4	1.5 μg rhTGF-β3 plus 25 μg rhOP-1 in ICBM	Resorbed

Table 4.3 *Animal 3:* Heterotopic implant doses and fate of implants after forty days.

Implant Site No.	Type of implant	Fate of implant
1	75 μg rhTGF-β3 in Matrigel®	Transplanted to left and right maxillary defects
2	2.5 μg rhTGF-β3 plus 25 μg rhOP-1 in Matrigel®	Resorbed
3	1.5 μg rhTGF-β3 plus 25 μg rhOP-1 in Matrigel®	Resorbed
4	2.5 μg rhTGF-β3 plus 25 μg rhOP-1 in ICBM	Harvested for histology
5	1.5 μg rhTGF-β3 plus 25 μg rhOP-1 in ICBM	Harvested for histology

Table 4.4 *Animal 4:* Heterotopic implant doses and fate of implants after forty days.

Implant Site No.	Type of implant	Fate of implant
1	2.5 μg rhTGF-β3 plus 25 μg rhOP-1 in Matrigel®	Resorbed
2	1.5 μg rhTGF-β3 plus 25 μg rhOP-1 in Matrigel®	Resorbed
3	2.5 μg rhTGF-β3 plus 25 μg rhOP-1 in ICBM	Transplanted to right maxillary defects
4	1.5 μg rhTGF-β3 plus 25 μg rhOP-1 in ICBM	Resorbed

Table 4.5 Summary of fate of heterotopic implants.

Both 75 µg rhTGF-β3 in Matrigel® implants (Animals 1 and 3) were harvested. All 2.5 µg rhTGF-β3/Matrigel® and 1.5 µg rhTGF-β3/Matrigel® implants were resorbed. Three 2.5 µg rhTGF-β3/25 µg rhOP-1/ICBM implants (Animals 2, 3 and 4) and two 1.5 µg rhTGF-β3/25 µg rhOP-1/ICBM implants (Animals 1 and 3) were harvested.

Animal	**Doses for Heterotopic Implants**				
	75µg rhTGF-β3/ Matrigel®	***2.5 µg rhTGF-β3/ 25 µg rhOP-1/ Matrigel®***	***1.5 µg rhTGF-β3/ 25 µg rhOP-1/ Matrigel®***	***2.5 µg rhTGF-β3/ 25 µg rhOP-1/ ICBM***	***1.5 µg rhTGF-β3/ 25 µg rhOP-1/ ICBM***
1	+	–	–	–	+
2	Not implanted	–	–	+	–
3	+	–	–	+	+
4	Not implanted	–	–	+	–
Key: (+) = harvested ossicle; (—) = resorbed ossicle.					

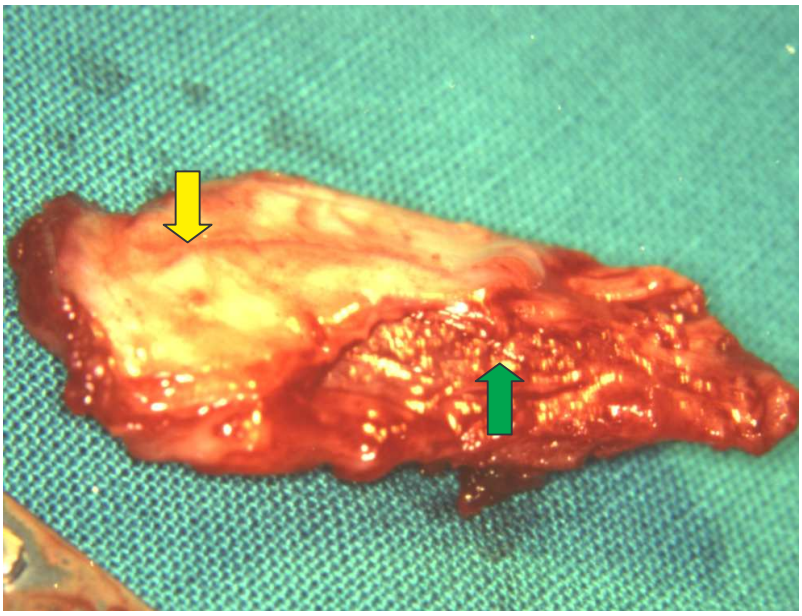

Figure 4.6. Harvested ossicle of autogenous bone from the *rectus abdominis* muscle. The yellow arrow indicates muscle fascia; the green arrow indicates underlying muscle tissue containing endochondral bone.

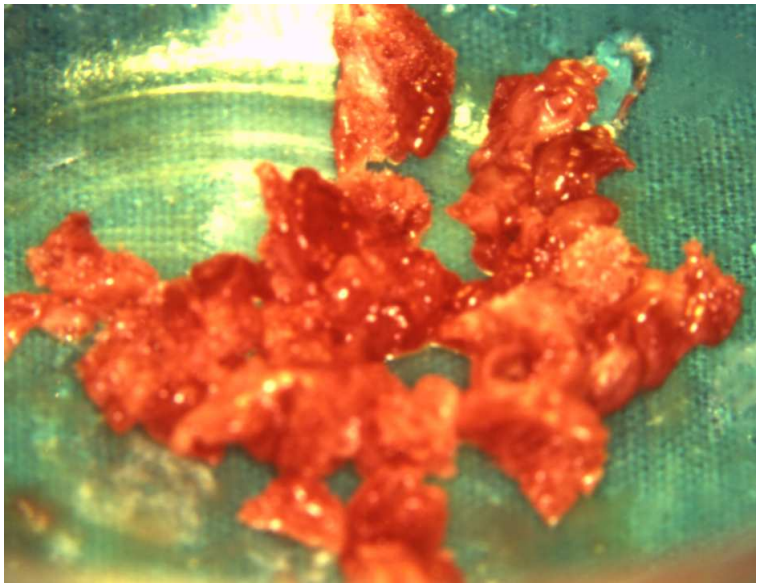

Figure 4.7. Fragmented ossicle of autogenous bone from the *rectus abdominis* muscle for transplantation.

4.4.2.2 Periodontal Surgery

Day 40. The mucoperiosteal flaps were raised and the granulation tissue resulting from the creation of the critical-sized defects was removed by curetting and planing the root surfaces (Figure 4.8). A small bur was used to make a horizontal groove on each root to indicate the base of the defect, that is, the residual bony housing. The furcation defects were 'packed' (Figure 4.9) with one of the following:

- Matrigel® carrier alone as control
- Matrigel® carrier and rhTGF-β3
- Matrigel® carrier, rhTGF-β3, and minced muscle tissue
- Heterotopically induced autogenous bone, harvested from the *rectus abdominis* muscle, minced with a scalpel

Figures 4.10, 4.11 and 4.12 and Tables 4.6, 4.7 and 4.8 show the implantation sites and types of implants that were implanted or transplanted for Animals 1 to 4.

The mucoperiosteal flaps were reattached using resorbable sutures.

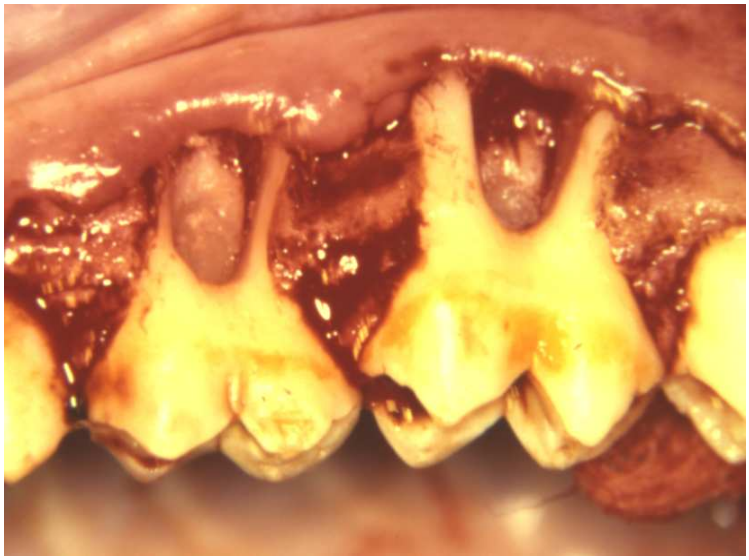

Figure 4.8 Class II furcation defects in first and second maxillary molars prior to implanting with autogenous bone.

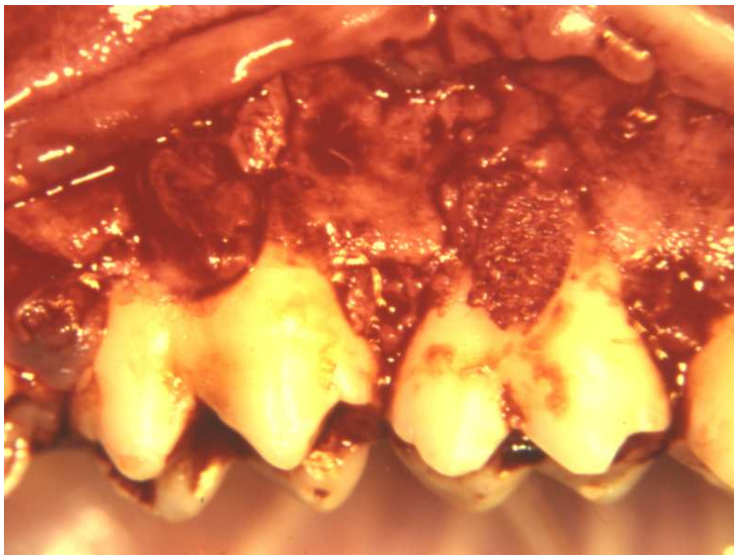

Figure 4.9 First and second maxillary molars after implanting with fragmented autogenous bone.

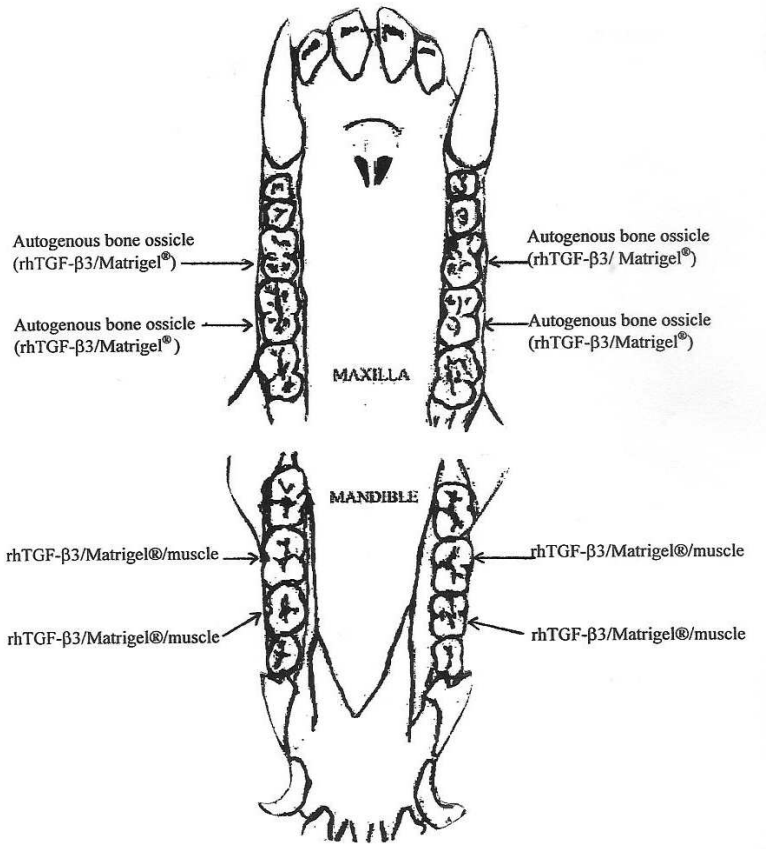

Figure 4.10 *Animals 1 and 3:* Surgical implant design for periodontal implants.

Table 4.6 *Animals 1 and 3:* Location of periodontal implants and doses of implants.

Location of implant	Type of implant
Left maxilla, 1st and 2nd molars	75 µg rhTGF-β3/Matrigel® ossicle
Right maxilla, 1st and 2nd molars	75 µg rhTGF-β3/Matrigel® ossicle
Left mandible, 1st and 2nd molars	75 µg rhTGF-β3, Matrigel® plus muscle tissue
Right mandible, 1st and 2nd molars	75 µg rhTGF-β3, Matrigel® plus muscle tissue

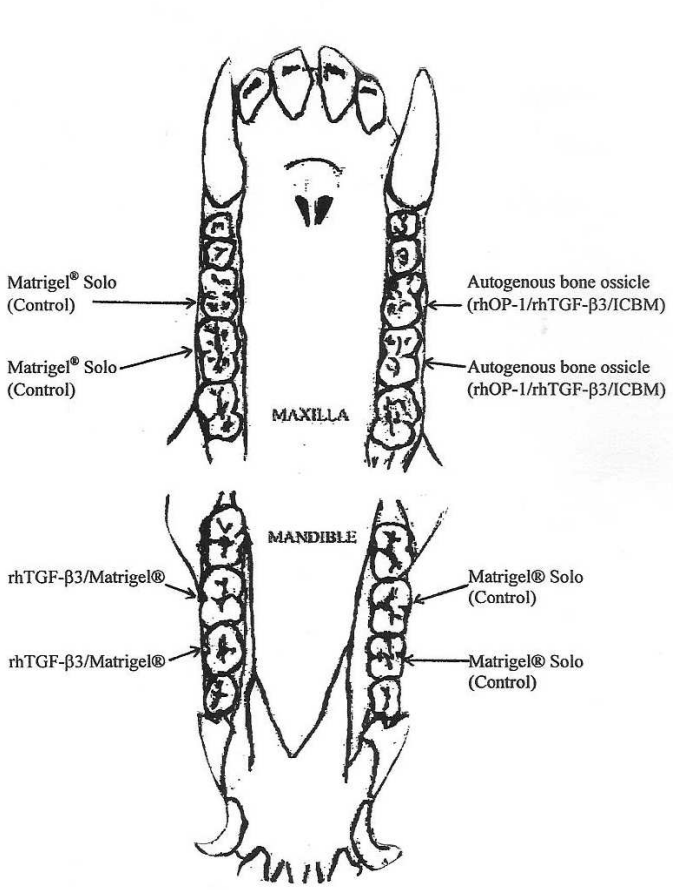

Figure 4.11 *Animal 2:* Surgical implant design for periodontal implants.

Table 4.7 *Animal 2:* Location of periodontal implants and doses of implants.

Location of implant	Type of implant
Left maxilla, 1st and 2nd molars	2.5 µg rhTGF-β3/25 µg rhOP-1/ICBM ossicle
Right maxilla, 1st and 2nd molars	Matrigel® solo (control)
Left mandible, 1st and 2nd molars	Matrigel® solo (control)
Right mandible, 1st and 2nd molars	75 µg rhTGF-β3 and Matrigel®

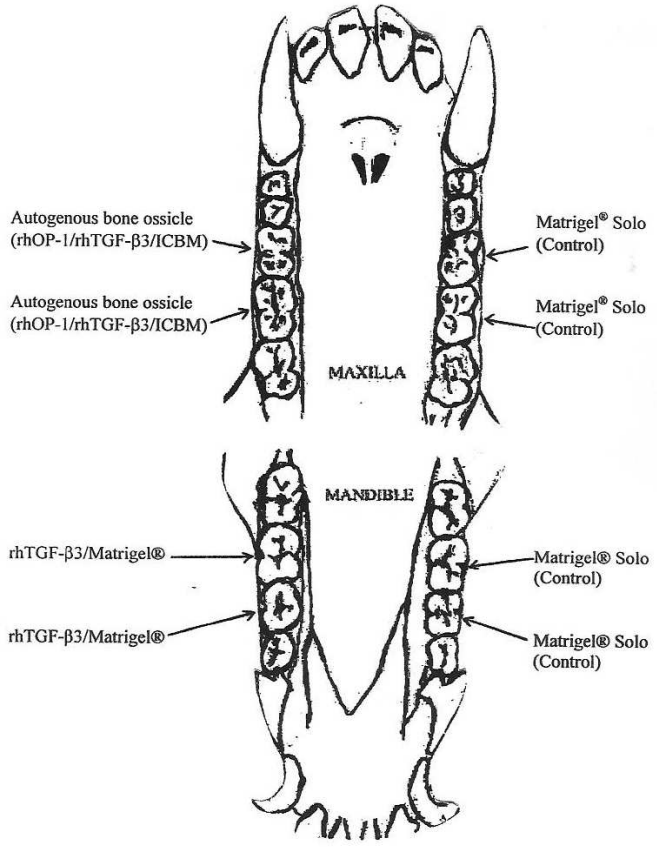

Figure 4.12 *Animal 4:* Surgical implant design for periodontal implants.

Table 4.8 *Animal 4:* Location of periodontal implants and doses of implants.

Location of implant	Type of implant
Left maxilla, 1st and 2nd molars	Matrigel® solo (control)
Right maxilla, 1st and 2nd molars	2.5 µg rhTGF-β3/25 µg rhOP-1/ICBM ossicle
Left mandible, 1st and 2nd molars	Matrigel® solo (control)
Right mandible, 1st and 2nd molars	75 µg rhTGF-β3 and Matrigel®

4.4.3 Phase 3: Euthanasia and Harvest of Periodontal Tissue

Day 100. Sixty days after implantation of periodontal defects, anaesthetized animals were euthanased using an overdose of sodium pentobarbitone. Bilateral carotid saline perfusion, using 0.9 % saline, followed by 10 % formaldehyde perfusion was performed. The first and second maxillary and the mandibular molars of each animal, together with surrounding bone and soft tissue, were harvested *en bloc* and fixed in 10 % phosphate buffered formalin. Each resected specimen block measured approximately 25 mm x 20 mm.

4.5 Photography and Radiography

Photographs were taken during all phases of surgery using a Nikon 35 mm camera using a 200 mm medical Nikkor focal lens.

Intra-oral periapical radiographs, with an exposure time of 0.4 minutes, were taken during Phases 2 and 3 of surgery using a Philips Oralix 50.

4.6 Tissue Processing of Specimens.

As described in Appendix 6, the periodontal and heterotopic specimens were processed by dehydrating through ascending grades of ethanol, cleared in toluene, and infiltrated and embedded in K-Plast resin (MEDIS-Weber) in preparation for the cutting of undecalcified sections. The polymerized blocks of periodontal tissue were trimmed on a Leica SM2500E heavy-duty microtome using 16 cm D-profile

tungsten carbide knives until the defect indication notches made during surgery became visible. After locating the notches, the sections cut at six microns were labelled level one through level one hundred. The polymerized blocks of heterotopic specimens were similarly trimmed on the Leica SM2500E heavy-duty microtome using 16 cm D-profile tungsten carbide knives until the entire surface area of the specimen was exposed, after which six micron sections were cut and labelled level one through level thirty. All sections were stained free-floating using a modified Goldner's trichrome staining method for undecalcified sections as described in Appendix 7. Briefly, the nuclei were stained with stable iron haematoxylin, followed by Ponceau Fuchsin with Orange G differentiation for osteoid. Mineralised bone was stained with methyl blue. Sections were examined microscopically, using an Olympus Provis AX70 Research Microscope, for evidence of periodontal tissue regeneration.

4.7 Histomorphometric analysis

4.7.1 Heterotopically Induced Autogenous Bone

Using the Olympus Provis AX70 microscope at 4x magnification and a 100 lattice point Zeiss Integration Platte II, the fractional volume of bone (*i.e.* mineralized bone plus osteoid), cartilage and carrier matrix was measured by means of the point counting technique (Parfitt, 1983). Histological sections of the Matrigel®-based and ICBM-based autogenous bone ossicles at levels 1 and 30 were selected for histometric analysis. By superimposing the graticule over two sources (Parfitt *et al.,* 1987), two hundred points per slide were measured i.e. four hundred points

per ossicle. The calculations were expressed in mean percentage values. Using GraphPad Prism computer software for statistical analyses, the mean values, standard deviation and standard error were calculated and bar graphs were plotted. P-value was calculated by one-way analysis of variance (ANOVA).

4.7.2 Periodontal Defects

Histological sections of the periodontal defects at levels 1, 50 and 100 were selected for histomorphometric analysis.

Area (%)

Using the Olympus Provis AX70 microscope at 2x magnification and analySIS® Imager imaging software system with CC12 digital camera (Wirsam Scientific and Precision Equipment, South Africa), the area of newly-formed bone was measured from the apical border of the notch to the coronal area of the furcation and compared to total defect size. Measurements were expressed as a percentage (%) of the total defect size.

Linear Measurements (mm)

The height of new alveolar bone in relation to total defect height at the medial and distal aspects of each furcation defect was also measured. Measurements of new cementum were also taken. Measurements were expressed in millimetres (mm).

Volume (%)

Using the Olympus Provis AX70 microscope at 4x magnification and a 100 lattice point Zeiss Integration Platte II, the fractional volume of mineralized bone and

osteoid was calculated by means of the point counting technique (Parfitt, 1983) on histological sections of periodontal defects at levels 1, 50 and 100. By superimposing the graticule over two sources, namely apical and coronal areas (Parfitt *et al.,* 1987), two hundred points per slide were measured i.e. six hundred points per furcation defect. The calculations were expressed percentage.

Using GraphPad Prism computer software for statistical analyses, mean value and standard error of the mean were calculated and bar graphs were plotted. P-value was calculated by one-way analysis of variance (ANOVA). The following criteria were assessed:

- Performance of all five variables in periodontal defect sites:

  Matrigel® solo (control),

  75 μg rhTGF-β3 and Matrigel®,

  75 μg rhTGF-β3, Matrigel® and muscle tissue,

  Matrigel®-based autogenous bone,

  ICBM-based autogenous bone.
- Area of newly regenerated alveolar bone compared to total defect area.
- Height of newly regenerated alveolar bone and cementum compared to defect height.
- Regeneration of alveolar bone by individual animals, with special emphasis on the regenerative capabilities of Animals 2 and 4.
- Regeneration of alveolar bone in mandibular defects compared to regeneration of alveolar bone in maxillary defects.
- Regeneration of alveolar bone in first molar compared to regeneration of alveolar bone in second molar.

5. RESULTS

Results of this study have been reported in two parts. The first section examines the portions of heterotopically induced autogenous bone that remained after transplantation to periodontal sites as well as the ossicles that were not used for transplantation. Photomicrographs of the histological findings are shown together with data tables and histograms to illustrate osteogenic viability. Part two of this chapter gives the results of the treated periodontal defects after the sixty day healing period and includes photomicrographs, data tables and histograms.

5.1 Heterotopic Implants for Autogenous Bone

5.1.1 Histological Observations

5.1.1.1 75 µg rhTGF-β3/Matrigel®-Induced Autogenous Bone

The remnants of two rhTGF-β3/Matrigel® autogenous bone ossicles were processed for histological analysis, the bulk of each ossicles having been transplanted to a periodontal defect site. The histological sections showed multiple areas of osteogenesis (Figures 5.1 and 5.2) and chondrogenesis (Figure 5.2). Residual Matrigel® carrier was not seen.

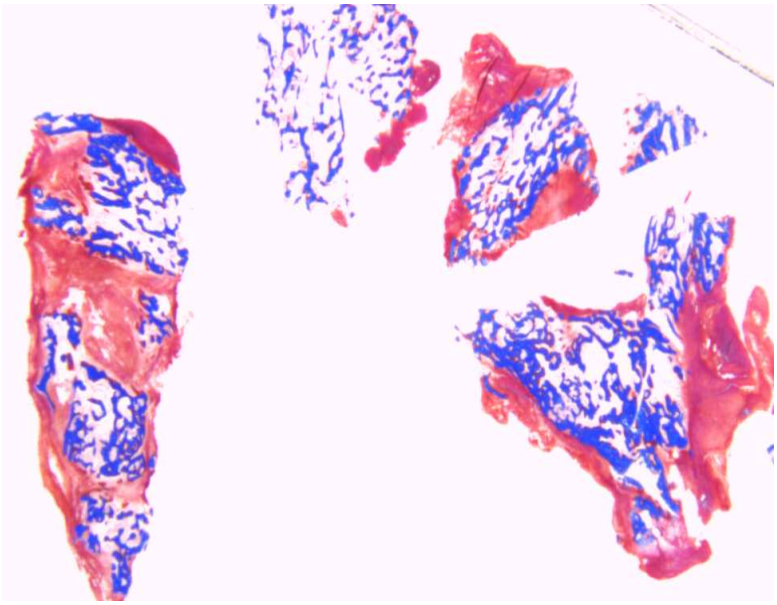

Figure 5.1 *Autogenous bone:* Photomicrograph of a 75 µg rhTGF-β3/Matrigel®-induced ossicle showing mineralized bone (blue areas), 1.25x magnification. Modified Goldner's stain.

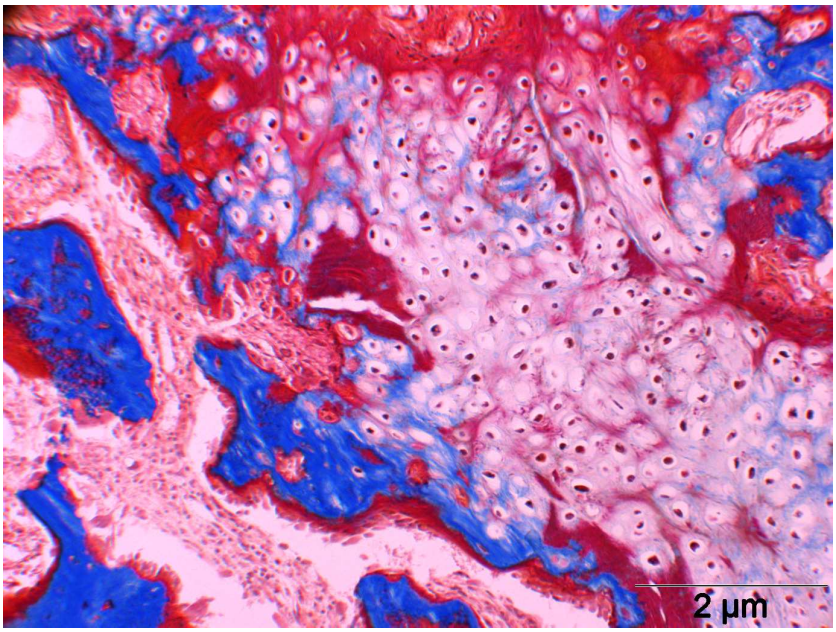

Figure 5.2 *Autogenous bone:* Photomicrograph of a 75 µg rhTGF-β3/Matrigel®-induced ossicle showing bone and cartilage within autogenous bone graft material, 20x magnification. Modified Goldner's stain.

5.1.1.2 2.5 µg rhTGF-β3/25 µg rhOP-1/ICBM-Induced Autogenous Bone

The transplant remnants of two 2.5µg rhTGF-β3/25 µg rhOP-1/ICBM autogenous bone ossicles, plus one ossicle that had not been transplanted were processed for histological assessment. The histology sections (Figure 5.3) showed multiple areas of osteogenesis with residual ICBM. The remnants of the two transplanted ossicles (from Animals 2 and 4) did not appear to have a cartilaginous component (Table 5.4) but the ossicle harvested from Animal 3 showed a healthy chondrogenic element (Table 5.5). The chondrogenic cells appeared to be restricted to the periphery of the ossicles. The ossicle harvested from Animal 4 had the least osteogenic material and the most residual carrier matrix (Figure 5.4 and Table 5.4)

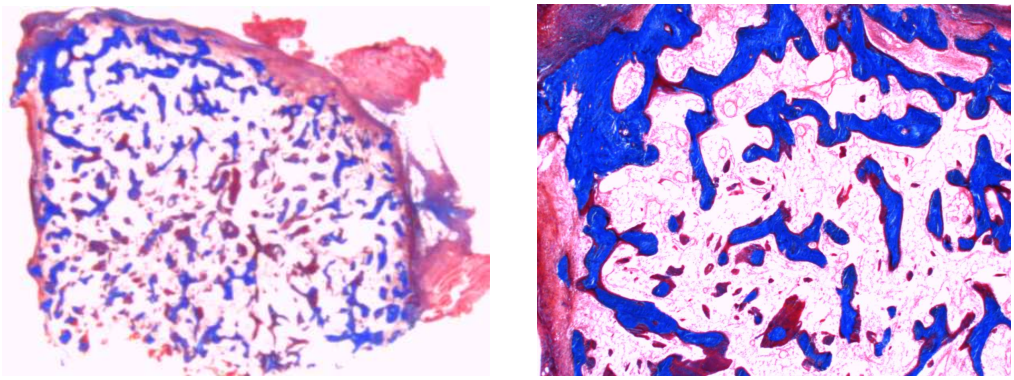

A **B**

Figure 5.3 *Autogenous bone:* Photomicrograph of a 2.5 µg rhTGF-β3/25 µg rhOP-1/ICMB-induced ossicle showing bone content (blue areas), (**A**) 1.25x magnification; (**B**) 4x magnification. Modified Goldner's stain.

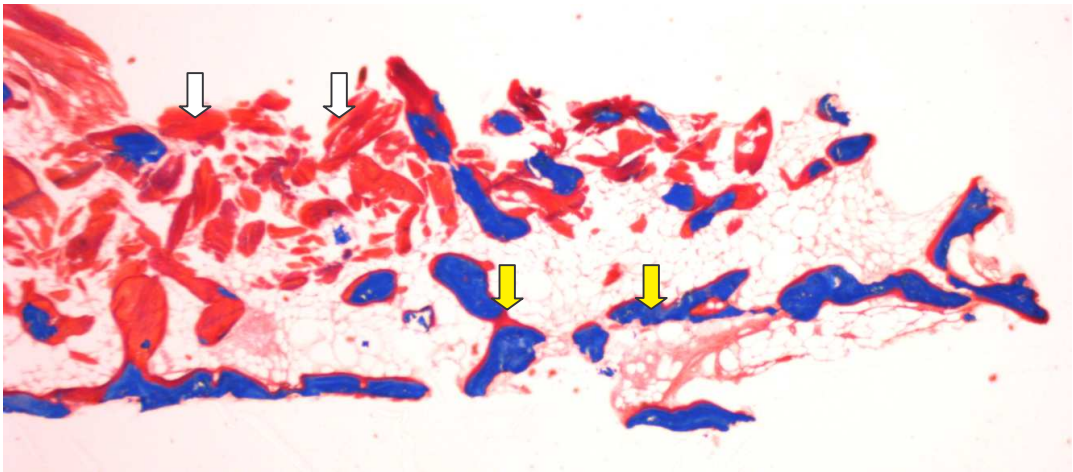

Figure 5.4 *Autogenous bone:* Photomicrograph of a 2.5 µg rhTGF-β3/25 µg rhOP-1/ICMB-induced ossicle harvested from Animal 4 showing sparse distribution of bone (yellow arrows) and abundant residual carrier (white arrows) within autogenous bone graft material, 4x magnification. Modified Goldner's stain.

5.1.1.3 1.5 µg rhTGF-β3/25 µg rhOP-1/ICBM-Induced Autogenous Bone

These ossicles were not used for transplantation to a periodontal site but were processed for histological analysis. Histology sections (not shown) revealed an abundance of osteogenic material, very similar to the rhTGF-β3/Matrigel® autogenous bone ossicles, but with less chondrogenesis (Figure 5.5, Table 5.1 and Table 5.5). A small amount of residual ICBM carrier was noted.

5.1.2 Histomorphometric Analysis

Figure 5.5 and Table 5.1 show the distribution of mineralized bone, osteoid, cartilage and carrier matrix within the harvested induced autogenous bone ossicles. Values, expressed as a percentage of the mean, show that the 75 µg rhTGF-β3/ Matrigel® and 1.5µg rhTGF-β3/25 µg rhOP-1/ICBM ossicles had similar bone volume (40.9% and 39.7%, respectively) (Table 5.1) with different cartilage content (8.8% and 2.7%, respectively). The 2.5µg rhTGF-β3/25 µg rhOP-1/ ICBM ossicles, although with similar bone volume (30.1%), had an amount of 12.8% residual carrier matrix when compared to the 75 µg rhTGF-β3/Matrigel® and 1.5µg rhTGF-β3/25µg rhOP-1/ICBM ossicles (0% and 2.6%, respectively) (Table 5.1). There were no significant differences between the three types of ossicles (p >0.05) as shown by Bonferroni's Multiple Comparison Test (Table 5.2).

Table 5.3 shows the bone volume of the 75µgTGF-β3/Matrigel® ossicles transplanted to periodontal defects. The ossicles were similar in bone volume (43.7% and 38.2%) and neither contained residual carrier matrix.

Table 5.4 shows the bone volume of the 2.5µgTGF-β3/25µg rhOP-1/ICBM ossicles transplanted to periodontal defects. The ossicle from Animal 4 consisted of less bone volume and contained more carrier matrix (Figure 5.4 and Table 5.4) than the ossicle harvest from Animal 2 (Figure 5.3 and Table 5.3).

Table 5.5 gives the bone volume of the three ossicles that were not transplanted to a periodontal site. It was noted that the ossicle with the highest bone content (46.7%) was that of a 1.5µgTGF-β3/25 µg rhOP-1/ICBM ossicle.

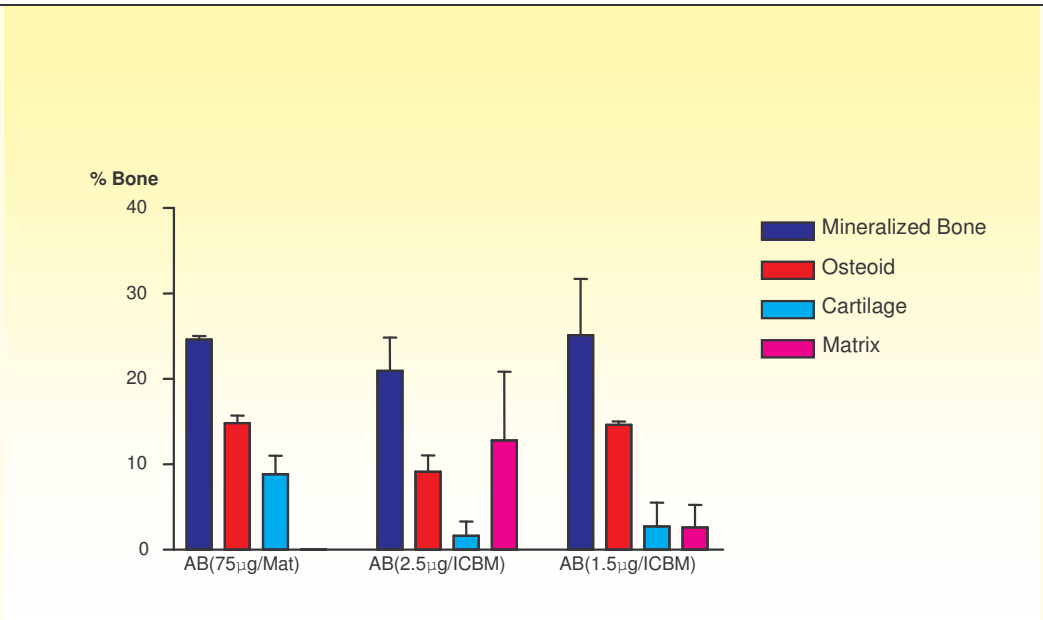

Induced Autogenous Bone Ossicles

Key	
AB(75µg/Mat)	Autogenous bone ossicles induced by 75 µg TGF β3/Matrigel®
AB(2.5µg/ICBM)	Autogenous bone ossicles induced by 2.5 µg rhTGF β3/25 µg rhOP-1/ ICBM
AB(1.5µg/ICBM)	Autogenous bone ossicles induced by 1.5 µg rhTGF β3/25 µg rhOP-1/ ICBM

Figure 5.5 Distribution of mineralized bone, osteoid, cartilage and carrier matrix within the harvested induced ossicles. Values are expressed in percentage.

Table 5.1 Volume fraction (%) of bone (mineralized bone plus osteoid), cartilage and residual matrix in the seven ossicles of induced bone harvested from the *rectus abdominis* of the baboons. Values are expressed as mean and standard error of the mean (SEM); n indicates the number of ossicles harvested for each implant variable.

	75µgTGF-β3/Matrigel Ossicle			**2.5µgTGF-β3/ 25µg rhOP-1/ICBM Ossicle**			**1.5µgTGF-β3/ 25µg rhOP-1/ICBM Ossicle**		
	Mean	SEM	n	Mean	SEM	n	Mean	SEM	n
Bone	40.9	± 2.7	2	30.1	± 4.5	3	39.7	± 7.0	2
Mineralized Bone	26.1	± 1.9	2	20.9	± 3.8	3	25.1	± 6.6	2
Osteoid	14.8	± 0.8	2	9.1	± 1.8	3	14.6	± 0.4	2
Cartilage	8.8	± 2.1	2	1.6	± 1.6	3	2.7	± 2.7	2
Matrix	0.0	0.0	2	12.8	± 8.0	3	2.6	± 2.6	2

Table 5.2 Bonferroni's Multiple Comparison Test comparing
75µgTGF-β3/Matrigel® ossicle (Column A),
2.5 µg TGF-β3/25 µg rhOP-1/ICBM ossicle (Column B) and
1.5 µg TGF-β3/25 µg rhOP-1/ICBM ossicle (Column C).
There is no significant difference between the three types of ossicles ($p > 0.05$).

Bonferroni's Multiple Comparison Test	**Mean Diff.**	**t**	***p* value**	**95% CI of diff**
Column A vs Column B	3.207	0.3522	$p > 0.05$	-22.10 to 28.51
Column A vs Column C	1.195	0.1313	$p > 0.05$	-24.11 to 26.50
Column B vs Column C	-2.012	0.2210	$p > 0.05$	-27.32 to 23.29

Table 5.3 Volume fraction (%) of bone (minerlaized bone plus osteoid) and cartilage in the ossicles induced with 75ugTGF-β3/Matrigel® and transplanted to periodontal defects. The ossicles are similar in bone volume and neither contain residual carrier matrix.

Volume Fraction (%) of Transplanted 75ugTGF-β3/Matrigel Ossicles				
	Animal 1	**Animal 2**	**Animal 3**	**Animal 4**
Bone	43.7	-	38.2	-
Mineralized Bone	28.0	-	24.2	-
Osteoid	15.7	-	14.0	-
Cartilage	6.7	-	11.0	-
Matrix	0.0	-	0.0	-

Table 5.4 Volume fraction (%) of bone (mineralized bone plus osteoid) and carrier matrix of 2.5 µg TGF-β3/25 µg rhOP-1/ICBM ossicles transplanted to periodontal defects. The ossicle from Animal 4 consists of less osteogenic material and more carrier matrix than the ossicle harvest from Animal 2.

Volume Fraction (%) of Transplanted 2.5ugTGF-β3/OP-1/ICBM Ossicles				
	Animal 1	**Animal 2**	**Animal 3**	**Animal 4**
Bone	-	31.2	-	21.7
Mineralized Bone	-	25.0	-	13.2
Osteoid	-	6.2	-	8.5
Cartilage	-	0.0	-	0.0
Matrix	-	8.0	-	28.5

Table 5.5 Volume fraction (%) of bone (mineralized bone plus osteoid), cartilage and residual carrier matrix of ossicles not transplanted to periodontal sites.

Volume fraction (%) of Non-Transplanted Ossicles					
	Animal 1	Animal 2	Animal 3		Animal 4
Type of Ossicle	1.5μg TGF-β3/ OP-1/ ICBM	-	2.5μg TGF-β3/ OP-1/ ICBM	1.5μg TGF-β3/ OP-1/ ICBM	-
Bone	32.7	-	37.5	46.7	-
Mineralized Bone	18.5	-	24.7	31.7	-
Osteoid	14.2	-	12.7	15.0	-
Cartilage	0	-	5.0	5.5	-
Matrix	5.2	-	2.0	0	-

5.2 Periodontal Implants

5.2.1 Post-operative Observations

Periodontal healing was uneventful in all four animals, but with mild inflammation in the immediate areas surrounding surgical sites (Figures 5.6 and 5.7).

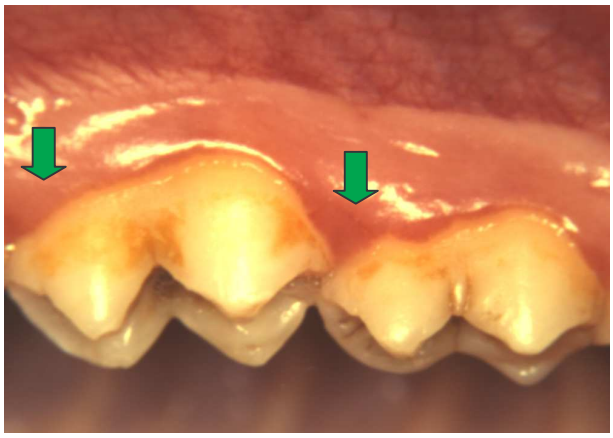

Figure 5.6 First and second maxillary molars, showing periodontal healing, sixty days post-implantation, exhibiting areas of mild inflammation (green arrows).

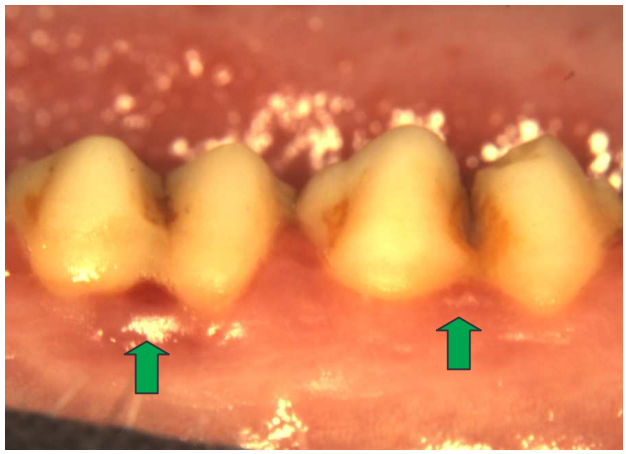

Figure 5.7 First and second mandibular molars, showing periodontal healing, sixty days post-implantation, exhibiting areas of mild inflammation (green arrows).

5.2.2 Radiographic Observations

Radiographs taken at the time of surgery (Figure 5.8A) and again at harvest showed regeneration of alveolar bone in experimental specimens (Figure 5.8B) compared with little or no regeneration within the control defects implanted with Matrigel® carrier (Figure 5.9).

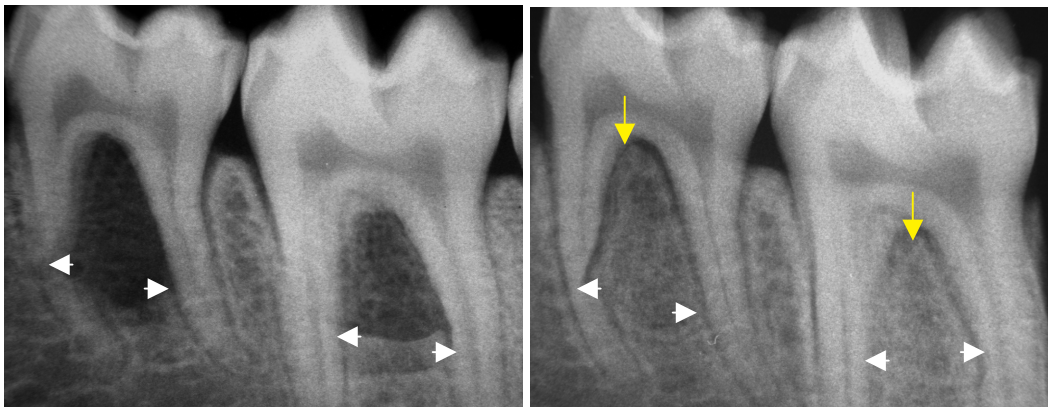

A **B**

Figure 5.8 Radiographs of mandibular defects implanted with rhTGF-β3 plus muscle in Matrigel® before (**A**) and after (**B**) healing. White arrows indicate notches at base of defects; yellow arrows (**B**) indicate height of bone after sixty day healing period.

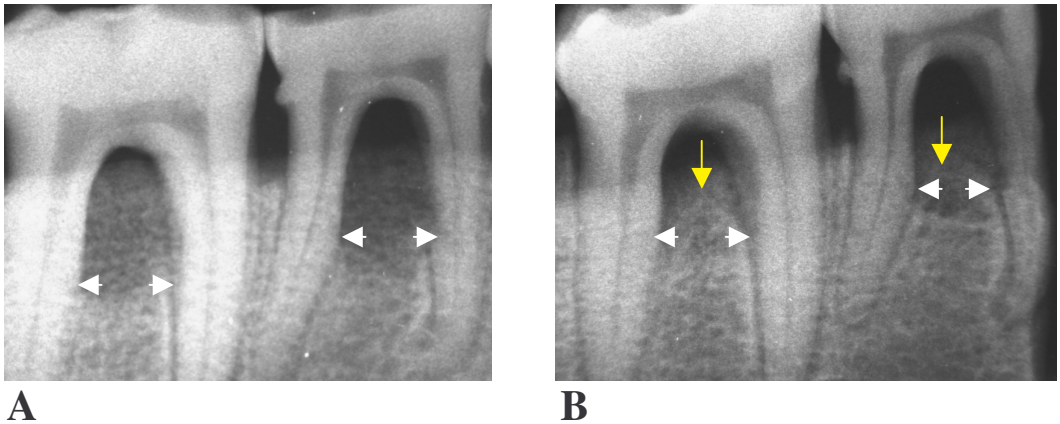

A **B**

Figure 5.9 Radiographs of mandibular defects implanted with Matrigel® alone, before (**A**) and after (**B**) healing, showing little or no regeneration within the defects. White arrows indicate notches at base of defects; yellow arrows (**B**) indicate height of bone after sixty day healing period.

5.2.3 Histological Observations

5.2.3.1 Matrigel® Control

Histological sections of Matrigel® as control demonstrated partial healing (Figure 5.10). There was an abundance of fibrous tissue which extended to the coronal area of the furcation defect, with limited insertion of collagenous fibres. The periodontal ligament consisted of areas sparsely populated with collagenous fibres, some of which were organized parallel to the cementum (Figure 5.11A). This was in sharp contrast to the well-developed periodontal ligament situated immediately apical to the notched area (Figure 5.11B).

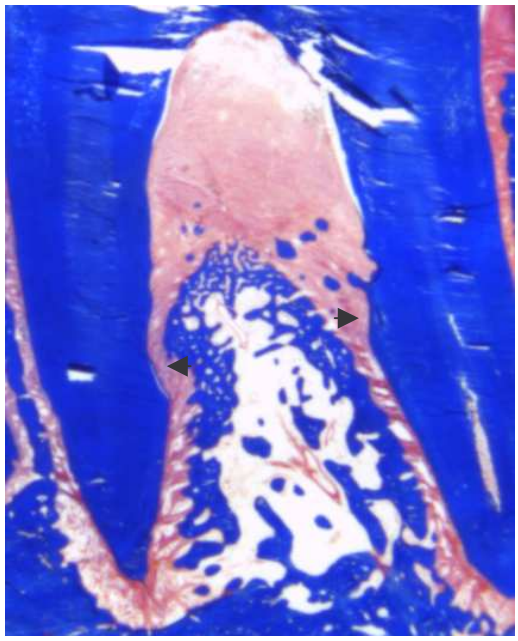

Figure 5.10 *Matrigel® control specimen:* Photomicrograph showing periodontal tissue regeneration in a control specimen, 1.25x magnification. Arrows indicate the notches made at time of implantation. Modified Goldner's stain.

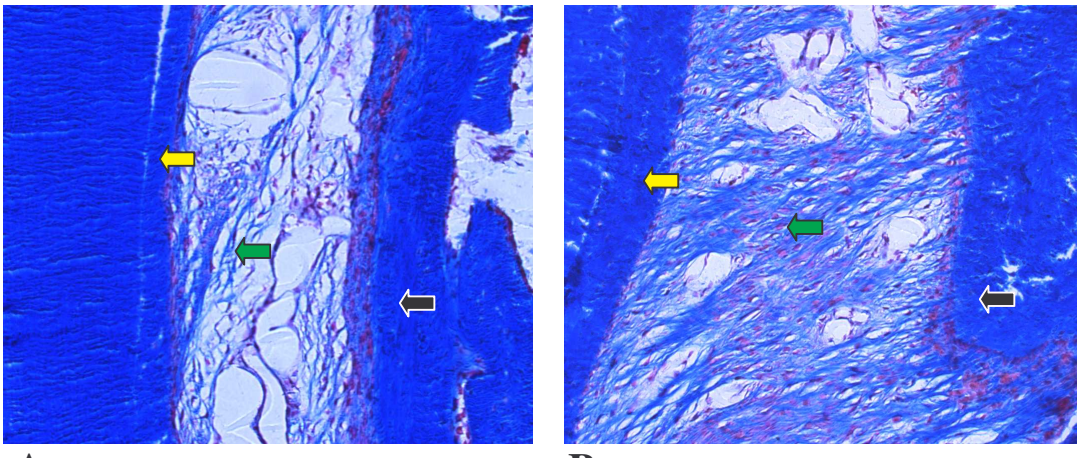

Figure 5.11 *Matrigel® control specimen:* Photomicrograph of new periodontal ligament in furcation defect area coronal to the notch (**A**) showing poorly organized periodontal ligament fibres arranged between cementum and alveolar bone, 20x magnification. In the same specimen, the area apical to the notch (**B**) shows Sharpey's fibres with good insertion, 20x magnification. Modified Goldner's stain. Yellow arrows indicate cementum, green arrows indicate periodontal ligament fibres and black arrows indicate alveolar bone.

5.2.3.2 rhTGF-β3 with Matrigel® carrier

Histological sections showed evidence of newly formed alveolar bone (Figure 5.12), new periodontal ligament and new cementum (Figure 5.13) within the defect areas. The new alveolar bone was arranged in a more compact manner than that of the apical residual alveolar bone (Figure 5.12). The new periodontal ligament was highly vascularized with well-demarcated Sharpey's fibres (Figure 5.13). High power examination of the sections showed a repetitive pattern of capillary sprouting in close contact with the periodontal ligament fibres originating from the newly formed alveolar bone (Figure 5.13). The arrangement of Sharpey's fibres appeared to be governed by the position of the capillaries demonstrating a 'buttonhole' effect along the edge of the newly formed alveolar bone. This feature was particularly prominent in histology tissue of periodontal regeneration by rhTGF-β3 in Matrigel®.

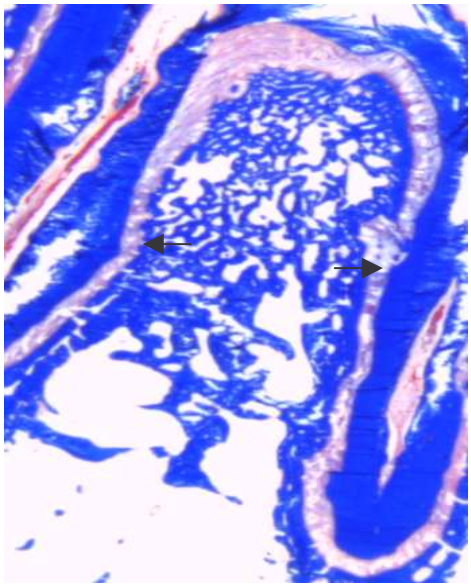

Figure 5.12 *Periodontal tissue regeneration by rhTGF-β3 with Matrigel® carrier*: Photomicrograph of periodontal healing within furcation defect using rhTGF-β3 in Matrigel® as carrier, 1.25x magnification. Arrows indicate the notches made at time of implantation. Modified Goldner's stain.

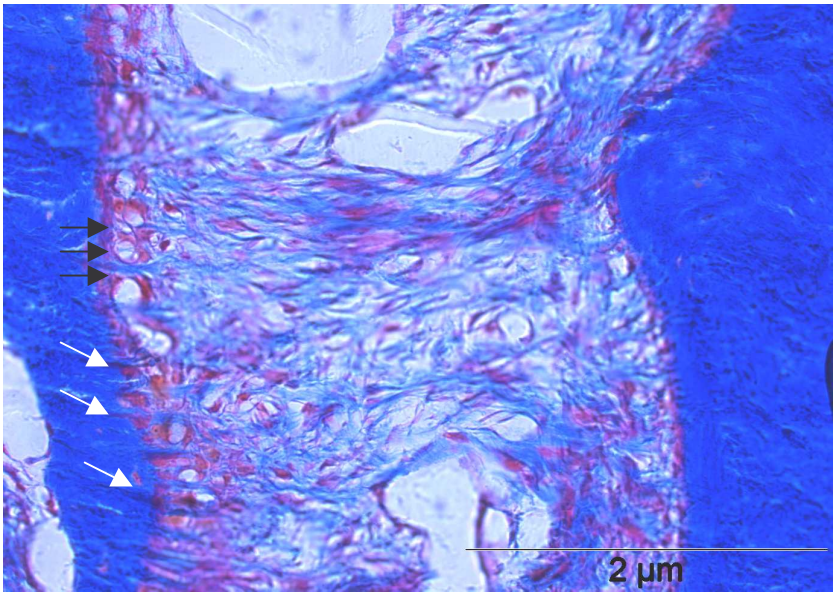

Figure 5.13 *Periodontal tissue regeneration by rhTGF-β3 with Matrigel® carrier*: Histological section showing new periodontal ligament with repetitive pattern of capillaries along edge of alveolar bone (black arrows) and well-defined insertion of Sharpey's fibres (white arrows), 40x magnification. Modified Goldner's stain.

5.2.3.3 rhTGF-β3 plus muscle tissue implants with Matrigel® carrier

Histological sections showed the presence of newly formed alveolar bone (Figure 5.14) with new cellular cementum (Figure 5.15) and new, well-vascularized, periodontal ligament with Sharpey's fibres (Figure 5.16). The new alveolar bone appeared to be well distributed within the notched areas, extending from the apical notches to the coronal area of the furcation defects (Figure 5.14). The new periodontal ligament exhibited highly organized collagenous fibres with functional insertion of Sharpey's fibres into both new alveolar bone (Figures 5.17) and new cementum (Figure 5.18).

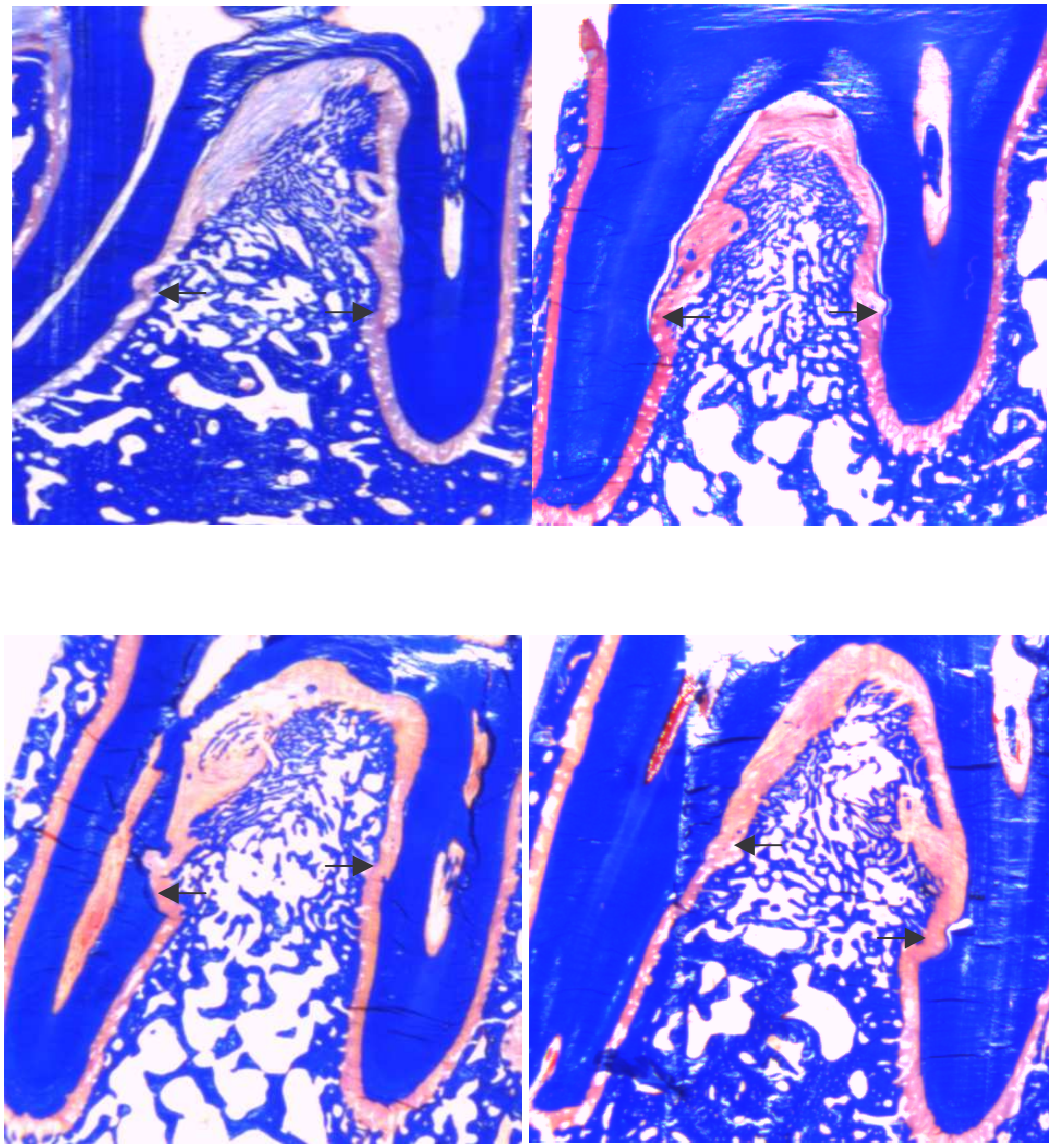

Figure 5.14 *Periodontal tissue regeneration by rhTGF-β3 plus muscle tissue with Matrigel® carrier*: Photomicrographs showing newly formed alveolar bone within notched areas of furcation defects, 1.25x magnification. Arrows indicate the notches made at time of implantation. Modified Goldner's stain.

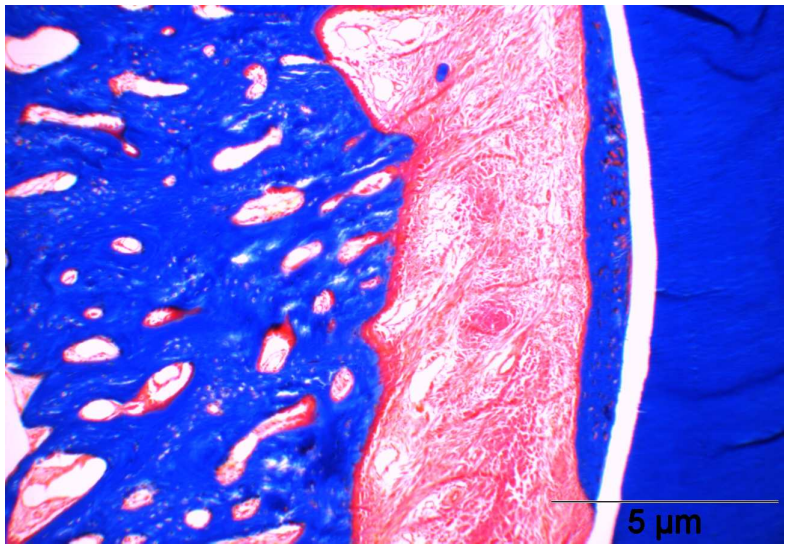

Figure 5.15 *Periodontal tissue regeneration by rhTGF-β3 plus muscle tissue with Matrigel® carrier:* Histological section showing new alveolar bone with osteoid, periodontal ligament, and cellular cementum, 10x magnification. Modified Goldner's stain.

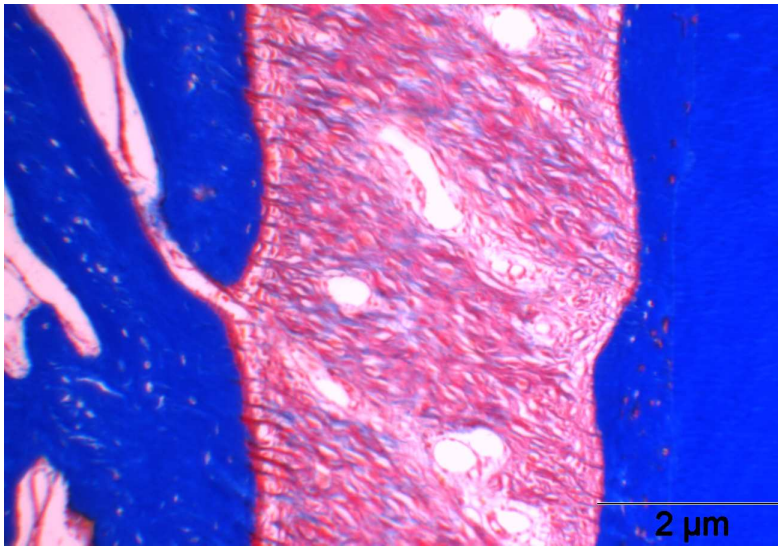

Figure 5.16 *Periodontal tissue regeneration by rhTGF-β3 plus muscle tissue with Matrigel® carrier:* Histological section showing new alveolar bone with osteoid, periodontal ligament with prominent insertion of Sharpey's fibres, and cellular cementum, 20x magnification. Modified Goldner's stain.

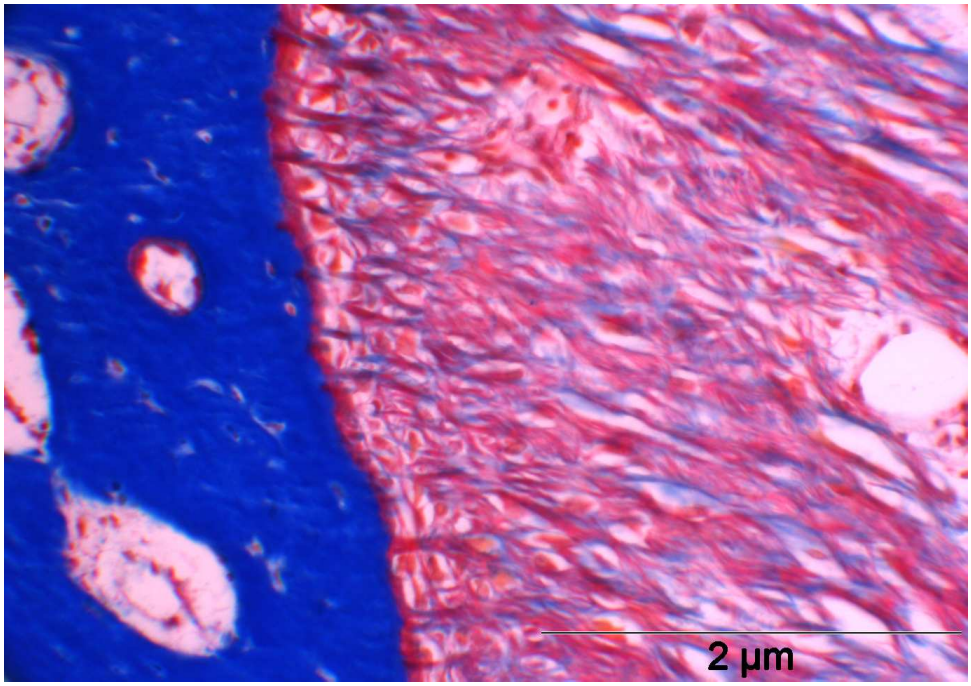

Figure 5.17 *Periodontal tissue regeneration by rhTGF-β3 plus muscle tissue with Matrigel® carrier:* Histological section showing new periodontal ligament with insertion of Sharpey's fibres into newly formed alveolar bone, 40x magnification. Modified Goldner's stain.

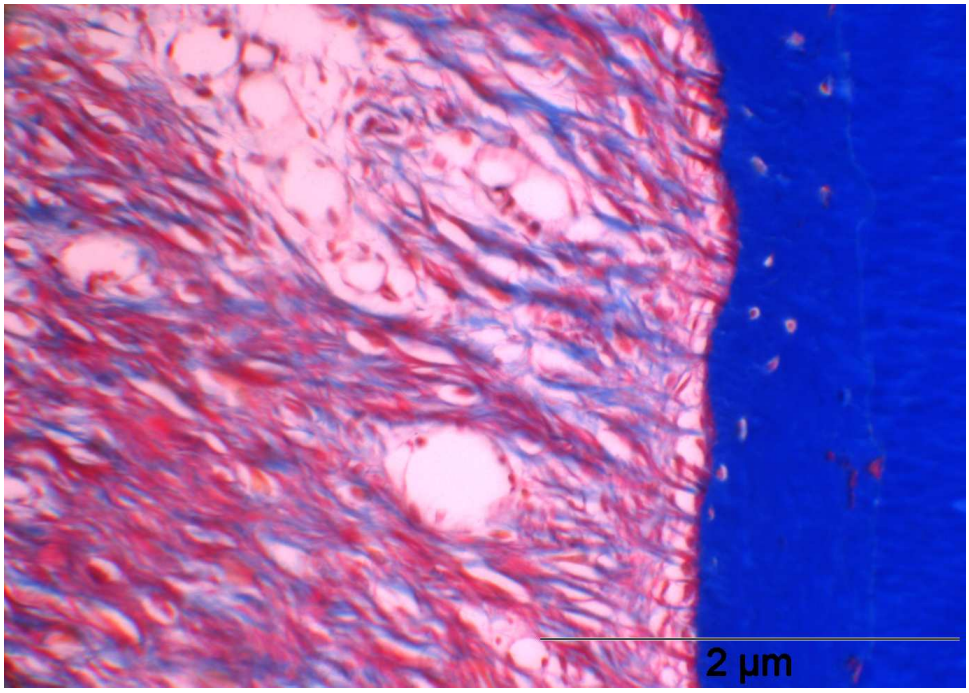

Figure 5.18 *Periodontal tissue regeneration by rhTGF-β3 plus muscle tissue with Matrigel® carrier:* Histological section showing new periodontal ligament with vascularization and insertion of Sharpey's fibres into new cellular cementum, 40x magnification. Modified Goldner's stain.

5.2.3.4 75μg rhTGF-β3/Matrigel®-Induced Autogenous Bone

Histological examination of the periodontal defects implanted with 75μg rhTGF-β3/Matrigel®-induced autogenous bone material showed new alveolar bone extending into the coronal area within the furcation defect with no separation between the residual alveolar bone and the newly generated bone. One furcation defect showed osteogenic invasion of the pulp cavity (Figure 5.19), possibly due to damage to the dentinal area during the surgical creation of the periodontal defects. The new cementum appeared to be cellular (Figure 5.20) with a newly formed collagenous matrix of cementoid into which the new collagenous fibres were inserted (Figure 5.21). The new periodontal ligament appeared to be well vascularized with an abundance of well-organized Sharpey's fibres. In one defect there was a small area of ankylosis situated at the coronal margin of the defect (Figure 5.22).

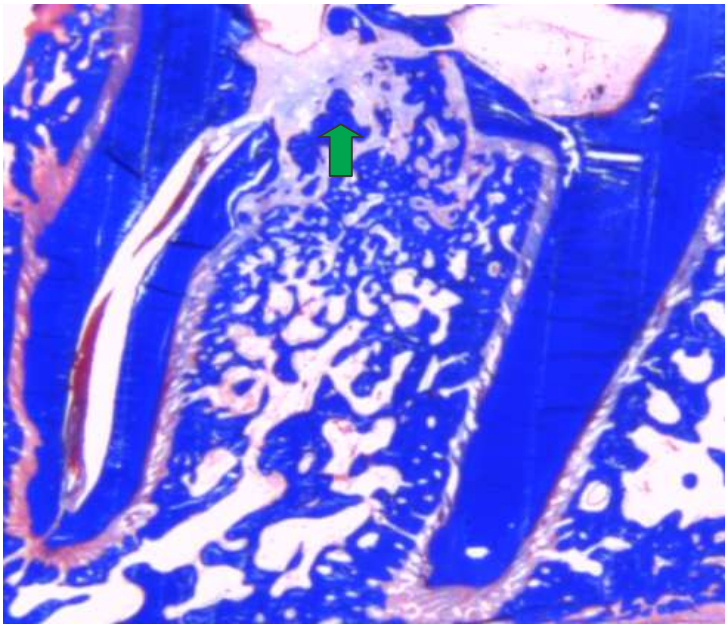

Figure 5.19 *Periodontal tissue regeneration by autogenous bone (75 µg rhTGF-β3/Matrigel® ossicle):* Photomicrograph, 1.25x magnification, showing newly formed alveolar bone within furcation defect by rhTGF-β3/Matrigel® ossicle. Arrow indicates osteogenic invasion of the pulp cavity.

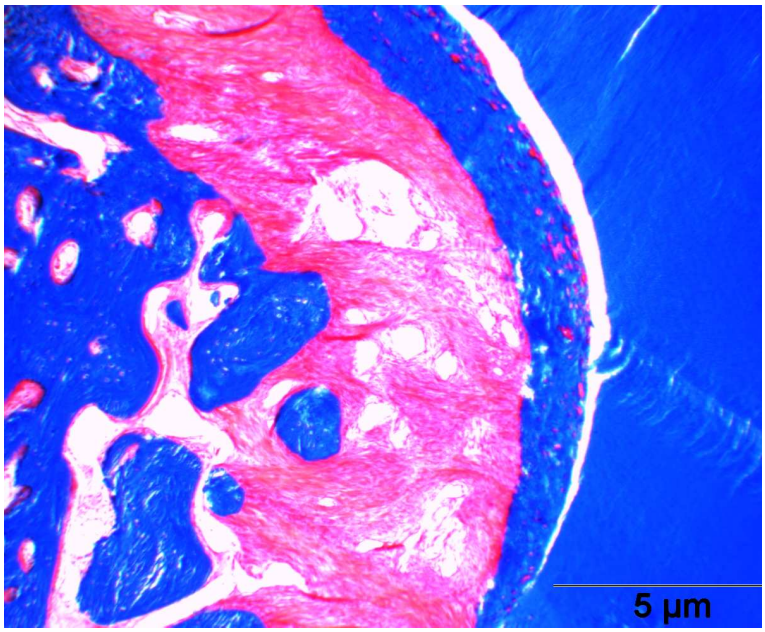

Figure 5.20 *Periodontal tissue regeneration by autogenous bone (75 µg rhTGF-β3/Matrigel® ossicle):* Histological section showing new alveolar bone, new periodontal ligament and new cellular cementum within the notched area of the defect, 10x magnification. Modified Goldner's stain.

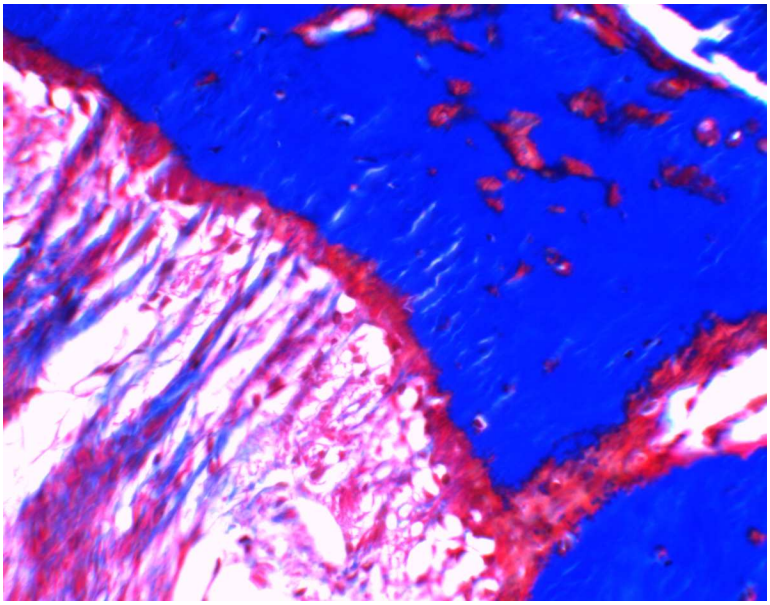

Figure 5.21 *Periodontal tissue regeneration by autogenous bone (75 μg rhTGF-β3/Matrigel® ossicle):* Histological section showing insertion of Sharpey's fibres into cementoid matrix of cementum, 40x magnification. Modified Goldner's stain.

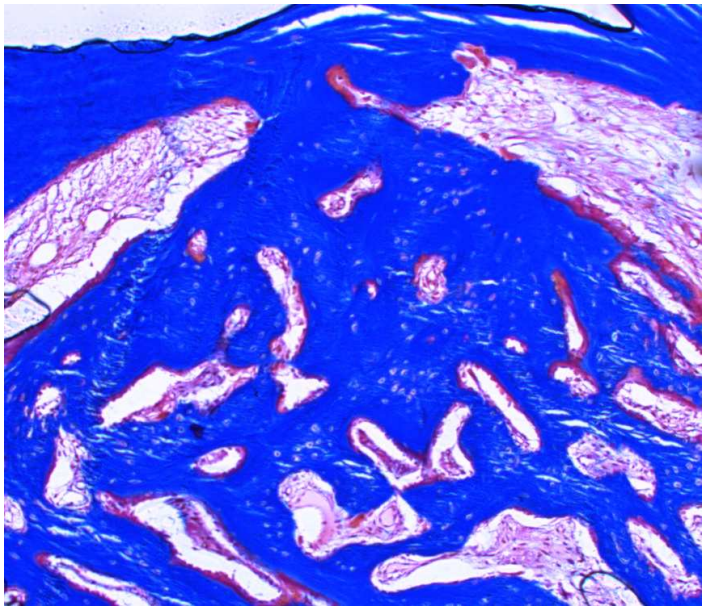

Figure 5.22 *Periodontal tissue regeneration by autogenous bone (75 μg rhTGF-β3/Matrigel® ossicle):* Histological section showing ankylosis within furcation defect at coronal margin, 10x magnification. Modified Goldner's stain.

5.2.3.5 2.5 μg rhTGF-β3/25 μg rhOP-1/ICBM-Induced Autogenous Bone

Histological examination of periodontal defects implanted with 2.5 μg rhTGF-β3/25 μg rhOP-1/ICBM-induced autogenous bone material showed incomplete regeneration of new alveolar bone (Figure 5.23), with new cementum and highly vascularized periodontal ligament with insertion of Sharpey's fibres (Figure 5.24).

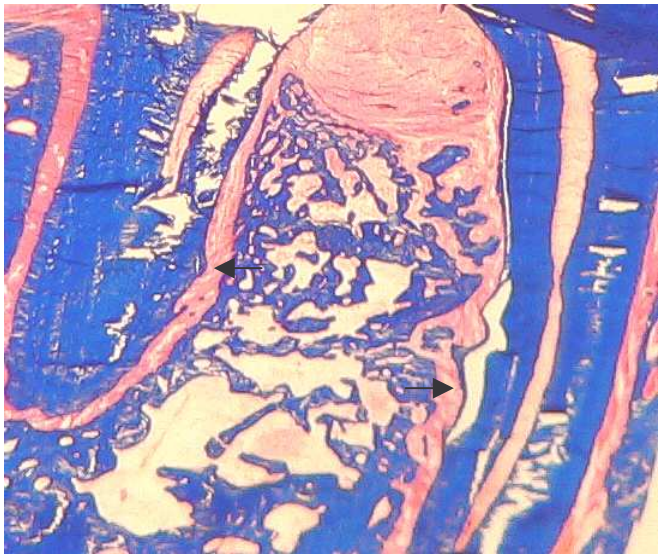

Figure 5.23 *Periodontal tissue regeneration by autogenous bone (2.5 µg rhTGF-β3/25µg rhOP-1/ICBM ossicle):* Photomicrograph, 1.25x magnification, showing newly formed alveolar bone within furcation defects by 2.5 µg rhTGF-β3/25 µg rhOP-1/ICBM ossicle. Arrows indicate notches made at time of surgery.

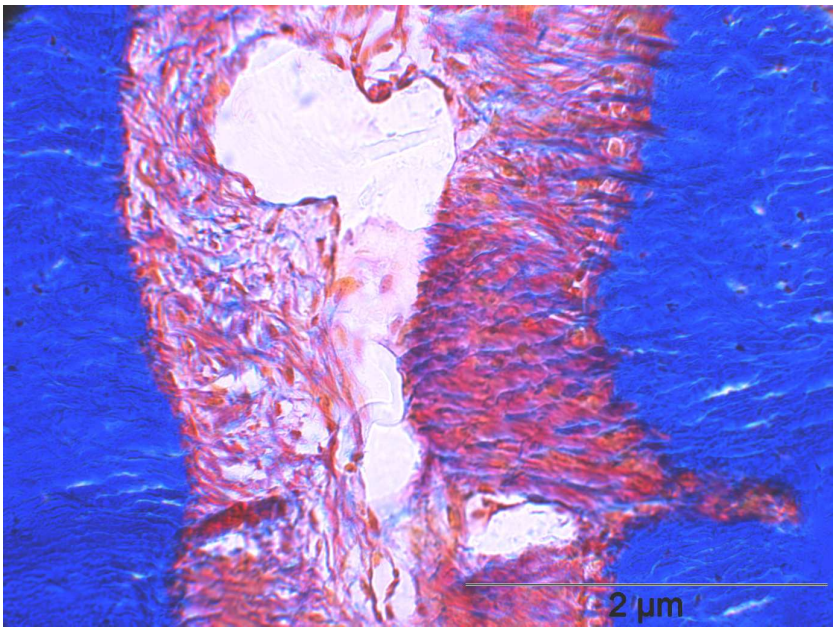

Figure 5.24 *Periodontal tissue regeneration by autogenous bone (2.5 µg TGF-β3/25 µg OP-1/ICBM ossicle)*: Histological section showing new periodontal ligament with insertion of Sharpey's fibres, 40x magnification. Modified Goldner's stain.

5.2.3 Histomorphometric Analysis

Area (%)

Figure 5.25 and Table 5.6 show the area of regenerated alveolar bone by the five implant variables. Values are expressed as a percentage of the total defect size. TGF-β3/muscle (58.9 ± 3.2%) and Matrigel®-based autogenous bone (64.9 ± 9.4%) implants regenerated the most alveolar bone compared to the control (31.3% ± 9.1).

Linear Measurements (mm)

Table 5.7 gives the linear measurements (mm) in mean values including SEM for the height of the defect from the notch to the fornix of the furcation (N-F), the height of the new cementum (N-C) and new alveolar bone (N-AB), as regenerated by each of the five implant types for both mesial and distal root surfaces. There were no significant differences ($p > 0.05$) between the defects (N-F), however significant differences were computed by Dunnett's Multiple Comparison Test for notch to cementum (N-C, distal) ($p < 0.05$) for control versus TGF-β3/muscle, as well as the notch to alveolar bone height (N-AB, mesial) for control versus TGF-β3/muscle ($p < 0.05$). N-AB distal values for control versus TGF-β3/muscle and control versus Matrigel®-based autogenous bone showed a significant difference ($p < 0.01$).

Volume (%)

Figure 5.26 and Table 5.8 show the results for histomorphometric analysis by the point counting technique (Parfitt, 1983) within the treated periodontal defects. The

mean values (%) of alveolar bone regenerated by the five implant variables are divided into bone, mineralized bone and osteoid (Table 5.8). Standard errors of the mean (SEM) have been included in the analysis. Alveolar bone regenerated by Matrigel®-based autogenous bone (53.1 ± 4.9%) showed a significant difference ($p < 0.05$) compared to the control (30.3 ± 5.4%). There was no significant difference ($p > 0.05$) between the other variables as shown by Dunnett's Multiple Comparison Test (Table 5.9), which compares control group to experimental groups.

An animal response comparison was performed by measuring the amount of alveolar bone regenerated within the periodontal defects by each animal, irrespective of implant type. Figure 5.27 and Table 5.10 show that there was very little variation between Animals 1, 2 and 3. However Animal 4 displayed a distinct lack of regenerative capabilities in comparison. Table 5.10 gives the mean and SEM values (%) of alveolar bone regenerated by each animal. The highest percentage of alveolar bone was regenerated by Animal 1 (51.6 ± 4.1%) and the lowest by Animal 4 (17.3 ± 2.2%); n represents the number of defects per animal. Bonferroni's Multiple Comparison Test (Table 5.11) compared the alveolar bone regenerated in each of the four animals. Animals 1, 2 and 3 were all significantly different from Animal 4 ($p < 0.001$).

The surgical implant designs for Animals 2 and 4 were alike (Figure 4.11, Table 4.7 and Figure 4.12, Table 4.8 respectively) and should therefore have shown similar bone regeneration values. Figure 5.28 and Table 5.12 compare the alveolar bone regenerated by TGF-β3 in Matrigel® implants in each animal and show that

Animals 2 and 4 are far from similar. The alveolar bone response by Animal 2 (52.1 ± 7.6%) is almost four times that of Animal 4 (14.1 ± 0.8%). Figure 5.29 and Table 5.13 compare the alveolar bone regenerated by the 2.5 μg TGF-β3/25 μg OP-1/ICBM ossicles. The alveolar bone response by Animal 2 is 59.7 ± 5.9% while Animal 4 responded with 19.8 ± 0.9%.

Data gathered by the point counting technique (Parfitt, 1983) was used to compare the total amount of alveolar bone regenerated in all mandibular defects (teeth 36, 37, 46 and 47) compared to all maxillary defects (teeth 16, 17, 26 and 27). Figure 5.30 and Table 5.14 showed that there was no statistical difference between maxillary (43.3 ± 3.9%) and mandibular (41.2% ± 4.9%) defects.

The same data was used to analyze the difference in bone regeneration between first molars (teeth 16, 26, 36 and 46) and second molars (teeth 17, 27, 37, and 47). Figure 5.31 and Table 5.15 demonstrate no significant difference in bone regeneration between first (38.3% ± 4.4%) and second (46.2% ± 4.2%) molars.

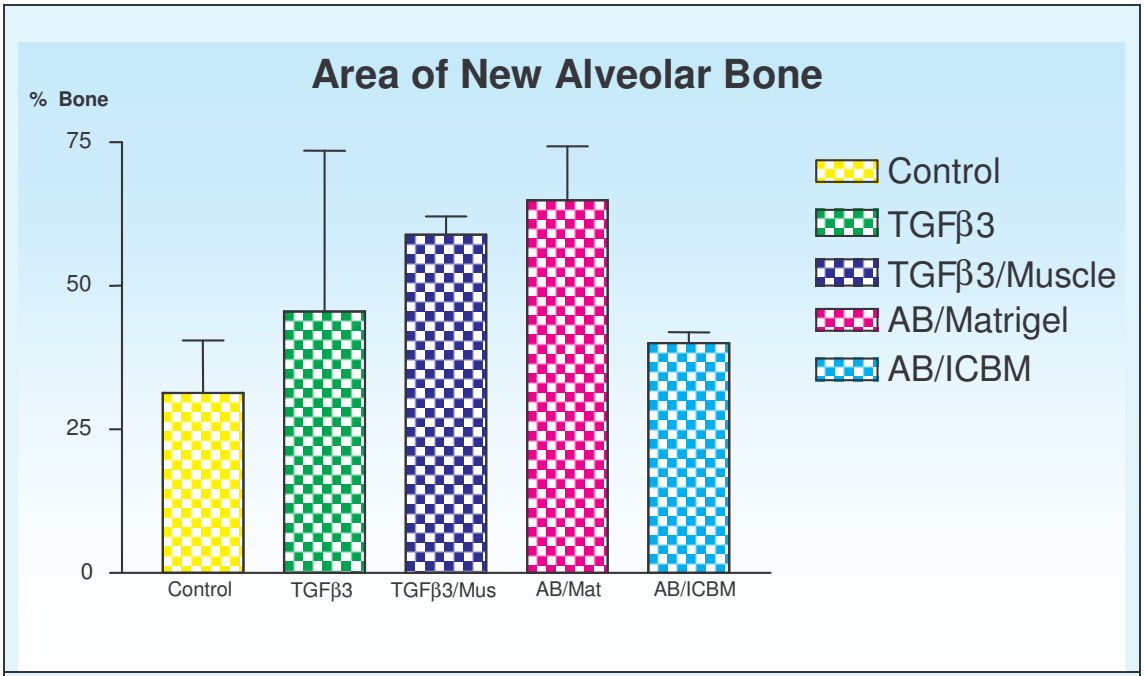

Key	
Control	Matrigel® alone
TGFβ3	rhTGF-β3 in Matrigel® carrier
TGFβ3/Mus	rhTGF-β3 and muscle tissue in Matrigel® carrier
AB/Mat	Matrigel®-based autogenous bone ossicle (75 µg rhTGF-β3 in Matrigel® carrier)
AB/ICBM	ICBM-based autogenous bone ossicle (2.5 µg rhTGF-β3/25 µg rhOP-1/ICBM)

Figure 5.25 Area of new alveolar bone compared to total defect as regenerated by the five implant variables. Values are expressed in percentage (%).

Table 5.6 Area of new alveolar bone compared to total defect size. Values are expressed in percentage (%); n indicates the number of defects per implant type.

Control	SEM	n	TGFβ3	SEM	n	TGFβ3/ Muscle	SEM	n	AB/ Matrigel	SEM	n	AB/ ICBM	SEM	n
31.3	± 9.1	8	45.5	± 28.0	4	58.9	± 3.2	8	64.9	± 9.4	8	40.0	± 1.9	4

Table 5.7 Histometric analysis of periodontal tissue regeneration in 32 furcation defects. Values (in mm) are given as mean ± SEM; n indicates the number of defects.

N: apical border of the notches on the mesial and distal roots surfaces; F: fornix of the furcation defect;

C: cementum; AB: alveolar bone.

There was no significant difference detected by Dunnett's Multiple Comparison Test ($p > 0.05$) for

N-F (mesial and distal values), or N-C (mesial).

Significant differences were noted for:

N-C (distal) control versus TGF-β3/Muscle implant ($p < 0.05$); N-AB (mesial) control versus TGF-β3/Muscle implant ($p < 0.05$),

N-AB (distal) control versus TGF-β3/Muscle implant ($p < 0.01$); N-AB (distal) control versus AB/Matrigel® ($p < 0.01$).

	Control	**SEM**	**n**	**TGF-β3**	**SEM**	**n**	**TGF-β3/ Muscle**	**SEM**	**n**	**AB/ Matrigel**	**SEM**	**n**	**AB/ ICBM**	**SEM**	**n**
Mesial															
N-F	6.0 mm	± 0.3	8	5.9 mm	± 0.1	4	6.2 mm	± 0.1	8	5.5 mm	± 0.4	8	5.2 mm	± 0.4	4
N-C	4.5 mm	± 0.7	8	3.8 mm	± 0.9	4	6.1 mm	± 0.2	8	5.3 mm	± 0.4	8	5.1 mm	± 0.4	4
N-AB	2.9 mm	± 0.6	8	2.8 mm	± 0.9	4	4.8 mm	± 0.3	8	4.6 mm	± 0.4	8	2.6 mm	± 0.9	4
Distal															
N-F	6.0 mm	± 0.2	8	5.9 mm	± 0.3	4	6.5 mm	± 0.1	8	5.8 mm	± 0.4	8	5.9 mm	± 0.4	4
N-C	3.7 mm	± 0.7	8	3.5 mm	± 0.6	4	6.1 mm	± 0.4	8	5.2 mm	± 0.5	8	4.8 mm	± 0.8	4
N-AB	2.3 mm	± 0.4	8	2.8 mm	± 0.8	4	4.7 mm	± 0.3	8	4.9 mm	± 0.5	8	2.8 mm	± 1.2	4

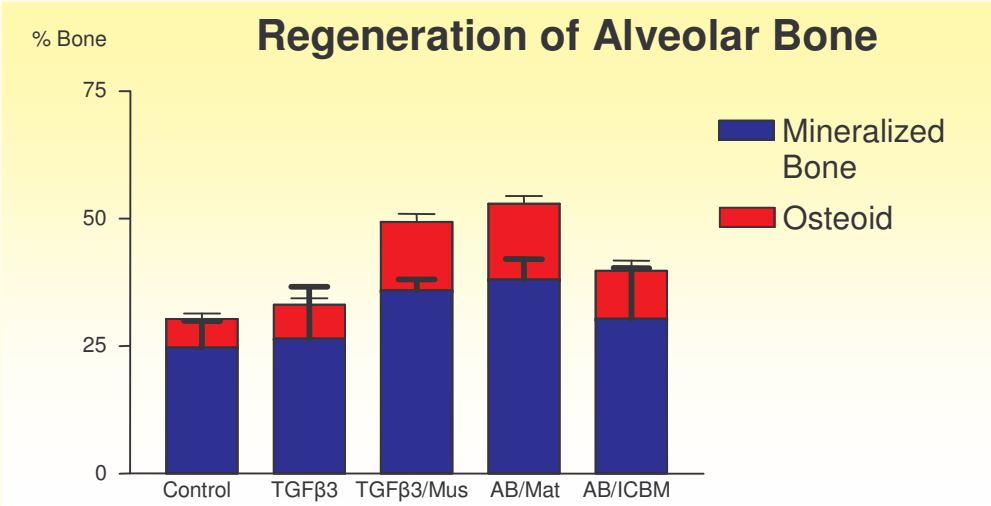

Key	
Control	Matrigel® alone
TGFβ3	rhTGF-β3 in Matrigel® carrier
TGFβ3/Mus	rhTGF-β3 and muscle tissue in Matrigel® carrier
AB/Mat	Matrigel®-based autogenous bone ossicle (75 µg rhTGF-β3 in Matrigel® carrier)
AB/ICBM	ICBM-based autogenous bone ossicle (2.5 µg rhTGF-β3/25 µg rhOP-1/ICBM)

Figure 5.26 Distribution of alveolar bone (mineralized bone plus osteoid) as regenerated by each of the five variables. Periodontal tissue regeneration by Matrigel®-based autogenous bone ossicle (75 µg rhTGF-β3/Matrigel® ossicle) yielded the most significant amount of alveolar bone (53.1 ± 4.9 %) when compared to the control (30.3 ± 5.4%) ($p < 0.05$).

Table 5.8 Volume fraction (%) of bone, *i.e.,* mineralized bone (Md bone) plus osteoid, as regenerated by the five variables implanted in periodontal furcation defects. Values are expressed as mean and standard error of the mean (SEM); n indicates the number of defects per implant variable.

	Control			TGF-β3			TGF-β3/Muscle			AB/Matrigel			AB/ICBM		
	Mean	SEM	n	Mean	SEM	n	Mean	SEM	n	Mean	SEM	n	Mean	SEM	n
Bone	30.3	± 5.4	8	33.1	± 11.4	4	49.3	± 3.1	8	53.1	± 4.9	8	39.7	± 11.8	4
Md Bone	24.7	± 5.1	8	26.5	± 10.1	4	35.9	± 2.1	8	38.1	± 3.9	8	30.4	± 9.9	4
Osteoid	5.5	± 1.1	8	6.6	± 1.2	4	13.3	± 1.5	8	14.8	± 1.5	8	9.3	± 2.0	4

Table 5.9 Dunnett's Multiple Comparison Test compares the control group (Column A) with the experimental groups:

rhTGF-β3/Matrigel® (Column B),

rhTGF-β3 and muscle tissue in Matrigel® carrier (Column C),

Matrigel®-based autogenous bone (Column D),

ICBM-based autogenous bone (Column E).

Control (Column A) compared to Matrigel®-based autogenous bone (Column D) showed a significant difference ($p < 0.05$).

Dunnett's Multiple Comparison Test	Mean Diff.	q	*p* value	95% CI of diff
Column A vs Column B	-2.800	0.2893	$p > 0.05$	-27.92 to 22.32
Column A vs Column C	-19.00	2.404	$p > 0.05$	-39.51 to 1.509
Column A vs Column D	-22.80	2.885	$p < 0.05$	-43.31 to -2.291
Column A vs Column E	-9.400	0.9711	$p > 0.05$	-34.52 to 15.72

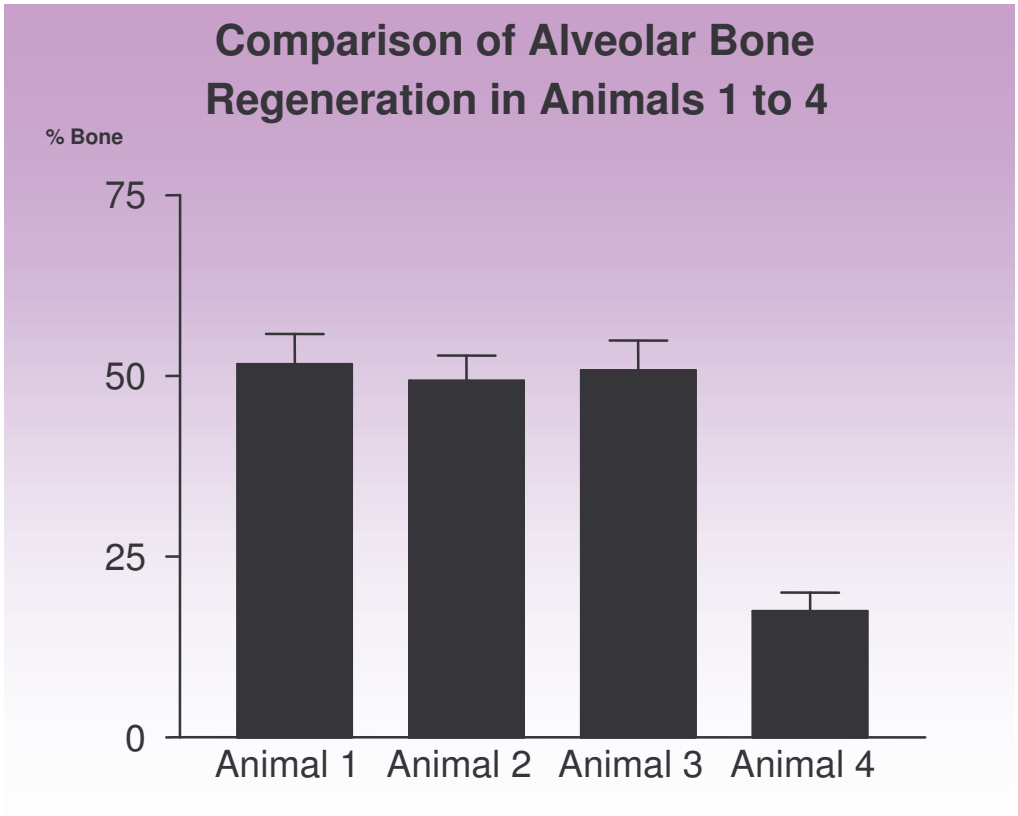

Figure 5.27 Volume (%) of alveolar bone regenerated by each animal. The amount of alveolar bone regenerated by Animals 1, 2 and 3 is much greater than that regenerated by Animal 4.

Table 5.10 Alveolar bone regenerated within the periodontal furcation defect of each animal irrespective of implant type used. Animal 4 shows a distinct lack of regenerative capabilities compared to Animals 1, 2 and 3. n is the number of defects per animal.

Animal	Total Alveolar Bone Regenerated (% mean)	SEM	n
Animal 1	51.6	± 4.1	8
Animal 2	49.3	± 3.5	8
Animal 3	50.7	± 4.1	8
Animal 4	17.4	± 2.6	8

Table 5.11 Bonferroni's Multiple Comparison Test compares the alveolar bone regenerated in each of the four animals. There is a significant difference between Animal 1 and Animal 4 ($p < 0.001$), Animal 2 and Animal 4 ($p < 0.001$), and Animal 3 and Animal 4 ($p < 0.001$).

Bonferroni's Multiple Comparison Test		**Mean Diff.**	**t**	***p* value**
Animal 1 vs Animal 2	Column A vs Column B	2.337	0.4493	$p > 0.05$
Animal 1 vs Animal 3	Column A vs Column C	0.9000	0.1730	$p > 0.05$
Animal 1 vs Animal 4	Column A vs Column D	34.24	6.580	$p< 0.001$
Animal 2 vs Animal 3	Column B vs Column C	-1.438	0.2763	$p > 0.05$
Animal 2 vs Animal 4	Column B vs Column D	31.90	6.131	$p < 0.001$
Animal 3 vs Animal 4	Column C vs Column D	33.34	6.408	$p < 0.001$

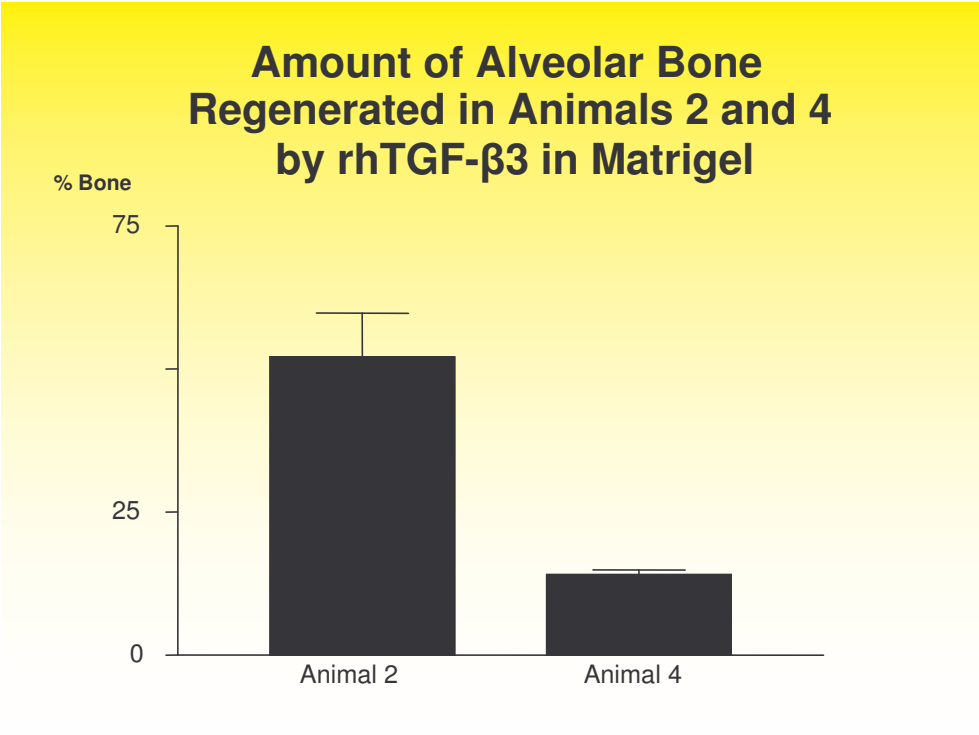

Figure 5.28 Comparison of the amount of alveolar bone regenerated in Animals 2 and 4 by rhTGF-β3/Matrigel® implants in periodontal defects.

Table 5.12 Comparison of amount of alveolar bone regenerated in periodontal defects in Animals 2 and 4 by rhTGF-β3 in Matrigel®.

Alveolar Bone Regenerated in Animals 2 and 4 by rhTGF-β3 in Matrigel®			
	Bone (% mean)	**SEM**	**n**
Animal 2	52.1	± 7.6	2
Animal 4	14.1	± 0.8	2

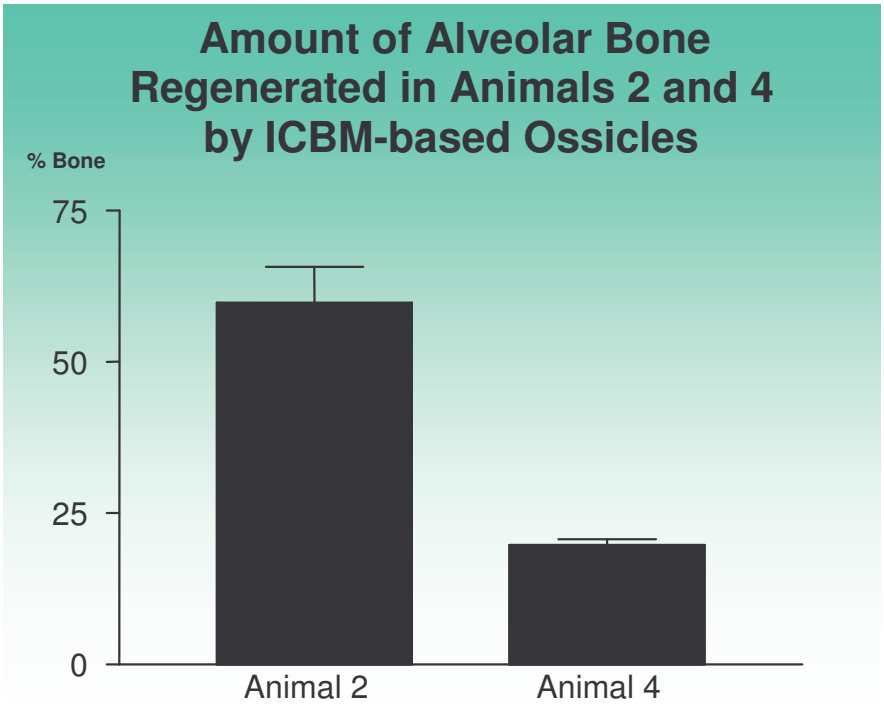

Figure 5.29 Comparison of amount of alveolar bone regenerated in periodontal defects in Animals 2 and 4 by 2.5 µg TGF-β3/25 µg rhOP-1/ICBM ossicles.

Table 5.13 Comparison of amount of alveolar bone regenerated in periodontal defects in Animals 2 and 4 by 2.5 µg TGF-β3/25 µg rhOP-1/ICBM ossicles.

Alveolar Bone Regenerated in Animals 2 and 4 by 2.5 µg rhTGF-β3/25µg rhOP-1/ICBM Ossicles			
	Bone (% mean)	**SEM**	**n**
Animal 2	59.7	5.9	2
Animal 4	19.8	0.9	2

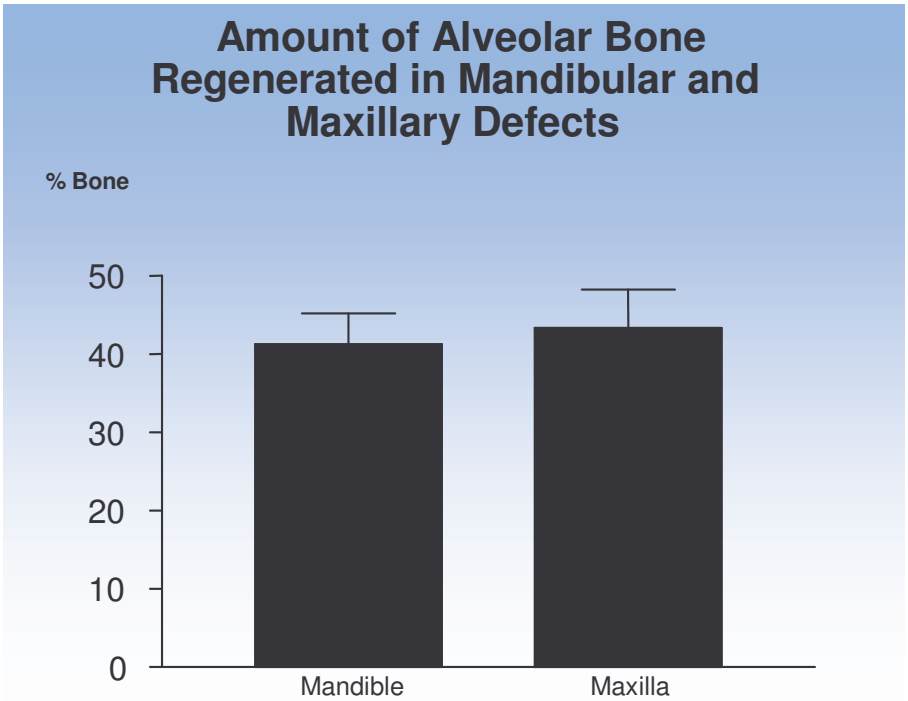

Figure 5.30 Comparison of alveolar bone regenerated in mandibular and maxillary defects.

Table 5.14 Comparison of total amount of alveolar bone regenerated in mandibular implants compared to maxillary implants. There is no significant difference between mandibular (41.2 ± 3.9%) and maxillary (43.3 ± 4.9%) defects; n indicates the number of defects.

Site	Total Alveolar Bone Regenerated (% mean)	SEM	n
Mandibular Implants	41.2	± 3.9	16
Maxillary Implants	43.3	± 4.9	16

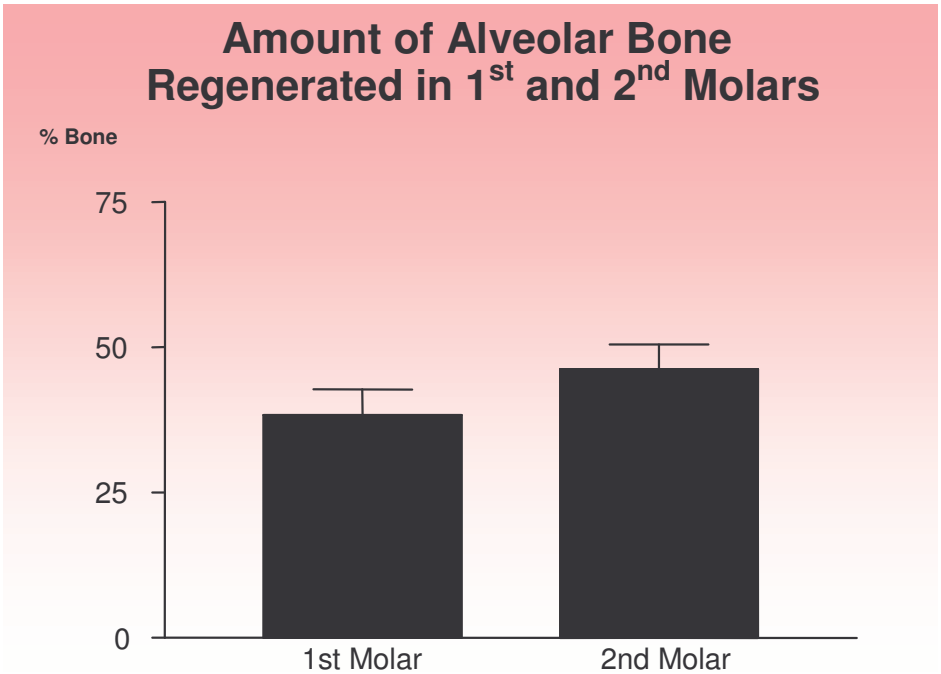

Figure 5.31 Volume (%) of alveolar bone regenerated in the first and second molars of the animals showing that the difference was not statistically significant.

Table 5.15 Comparison of total amount of alveolar bone regenerated in first and second molars. There is no statistical difference between first (38.3 ± 4.4%) and second (46.2 ± 4.2%) molars; n indicates the number of molars.

Site	Total Alveolar Bone Regenerated (% mean)	SEM	n
1st Molar	38.3	± 4.4	16
2nd Molar	46.2	± 4.2	16

6. DISCUSSION

The present study evaluated the healing potential of rhTGF-β3 when implanted in Class II furcation defects of *Papio ursinus,* either by direct application of the morphogen to the defects, or by transplantation of TGF-β3-induced autogenous bone. Both methods have shown remarkable potential for the regeneration of alveolar bone, periodontal ligament and cementum within the exposed furcations.

It was noted that in one animal (Animal 4) all treated furcation defects showed only a limited amount of tissue regeneration (Figure 5.27 and Table 5.10). At the time of surgery it became apparent to the surgical team that the animal was somewhat older than the others. The gingivae appeared to be friable, making suturing difficult. However, post-operative healing was uneventful with evidence of only mild inflammation. Induced autogenous bone harvested from the heterotopic implants appeared to be adequate, but upon histological examination it was noted that the trabecular bone was sparsely distributed with an abundance of residual carrier matrix (Figure 5.4 and Table 5.4). Differences in the induction of both heterotopic bone and periodontal tissue regeneration may be ascribed to animal-to-animal variation and, to date, are neither quantifiable nor mechanistically explained. However, *in vitro* studies on rodent bone marrow stem cells by Quarto *et al.* (1995) showed that age is related to a deficit of osteoprogenitor cells. Fleet *et al.* (1996) demonstrated that the activity of an osteoinductive protein is significantly compromised by advancing age but that this could be partially reversed by increasing the amount of growth factor at the

implant site. With these observations in mind, it would appear that enthusiastic response to TGF-β3 might be regulated by age.

The delivery system of choice for this study was Matrigel® matrix as it has several attractive qualities for use in a periodontal study. It is a user-friendly, injectable, thermodynamic material, which gels at body temperature, forming a three-dimensional scaffold. At 4°C, Matrigel® is liquid which allows for the incorporation and even distribution of growth factors. By means of a syringe, the Matrigel® matrix together with the soluble molecular signal can be placed accurately within the defect during surgery. The gelled consistency of the material conforms to the shape of the defect giving better integration with the surrounding tissue. Matrigel® matrix contains several growth factors including TGF-β. However, a more purified product is available in the form of Growth factor reduced (GFR) Matrigel® matrix, in which the quantities of the growth factors are reduced, with TGF-β content at a minimal value of 1.7ng/ml. GFR Matrigel® was used for this study so as to allow for fair assessment of the added TGF-β isoform performance.

Furcation defects implanted with GFR Matrigel® showed partial bony regeneration (Figure 5.10) with minimal cementogenesis. The collagenous fibres within the periodontal ligament were arranged parallel to the cementum (Figure 5.11A) and this lack of orientation of one of the pivotal tissues of periodontal healing, together with the reduced amount of alveolar bone regenerated, was a clear indication that GFR Matrigel® on its own is not capable of inducing acceptable periodontal tissue regeneration.

Experimental studies in dogs using TGF-β1 (Wikesjö *et al.,* 1998; Tatakis *et al.,* 2000) demonstrated little or no alveolar bone and cementum regeneration. To date, no studies have been conducted using TGF-β3 in periodontal regeneration, let alone the incorporation of this morphogen in periodontal defects of the non-human primate *Papio ursinus*. Coelho *et al.* (2003; 2004) maintained that TGF-β3, as the main isoform in intramembranous bone such as the mandible, should be of significant benefit when employed in the repair of mandibular defects as it demonstrated a high capacity for mesenchymal cell stimulation of angiogenesis and/or osteogenesis. The angiogenic potency of TGF-β3 was described more than a decade ago by Merwin *et al.* (1991) and Cox *et al.* (1994; 1995) and the osteogenic capabilities of TGF-β3, within soft tissue implants, was noted more recently by Ripamonti *et al.* (2004b), highlighting the evidence that angiogenesis is a prerequisite for bone formation (Trueta, 1963).

The most prominent feature of periodontal tissue regeneration within the defects implanted with rhTGF-β3 in Matrigel® matrix was the striking vascularization seen in the periodontal ligament (Figure 5.13). The formation of multiple capillaries along the edge of the alveolar bone appeared to preside over the arrangement and insertion of the Sharpey's fibres emphasizing Trueta's hypothesis that vascularization is the forerunner of osteogenesis. In this study, periodontal defects implanted with rhTGF-β3 in Matrigel® showed virtually complete healing (Figure 5.12) in two of the four implant sites. However, the amount of alveolar bone regenerated by rhTGF-β3 on its own was less significant (Figure 5.26) when compared to that of rhTGF-β3/muscle and Matrigel®-based autogenous bone transplant (75 μg rhTGF-β3/Matrigel® ossicle). This may not be a true reflection

of the regenerative capabilities of TGF-β3 as two of the four furcation defects implanted with rhTGF-β3 performed well with an average of 52.1 ± 7.6% alveolar bone regenerated (Figure 5.28 and Table 5.12). The remaining two defects implanted with rhTGF-β3 were those of Animal 4, which was a particularly poor respondent (Figure 5.28 and Table 5.12), and showed an average of 14.1 ± 0.8% alveolar bone regeneration. Hypothetically, if Animal 4 had been as competent a respondent as Animal 2, it is possible that a different outcome for this study may have been reported with superlative periodontal regeneration induced by rhTGF-β3 in Matrigel®.

Zacks and Sheff (1982) reported that nodules of cartilage and bone were induced in mouse limbs when implanted with minced skeletal muscle tissue. The structures resembled bony outgrowths of cartilage-capped bone. The TGF-beta isoform is site and tissue specific (Ripamonti *et al.,* 1997; Duneas *et al.,* 1998; Ripamonti *et al.,* 2000), possibly due to the presence or absence of the required responding cells in various anatomical locations or the presence of inhibitory binding proteins (Nakao *et al.,* 1997). This phenomenon was initially noted in studies by Ripamonti *et al.,* (1996b) when TGF-β1 showed only limited chondro-osteogenesis in calvarial sites but induced large heterotopic ossicles of endochondral bone within the *rectus abdominis* of non-human primates (Ripamonti *et al.,* 1997; Duneas *et al.,* 1998). Subsequent studies carried out by Ripamonti *et al.* (2000), using high doses of rhTGF-β2 in calvarial defects, demonstrated bone formation which was restricted to the pericranial region of the specimen, that is, new bone formed only along the muscle-lined periphery of the implant. It is therefore possible that muscle contains the responding cells required for the initiation of

osteogenesis within certain bony sites. Further studies by Ripamonti *et al.* (unpublished data) have demonstrated that muscle tissue, added to a bony defect site where TGF-beta isoforms are being employed, is beneficial in encouraging healing. Studies performed by other researchers have shown that skeletal muscle tissue contains inducible osteoprogenitor cells which, when stimulated by morphogens, are capable of differentiating into osteoblasts (Lee *et al.,* 2001; Turgeman *et al.,* 2002; Lu *et al.,* 2003; Corsi *et al.,* 2004; Sun *et al.,* 2005). In this study, this concept was exploited by transplanting harvested muscle tissue (from the *rectus abdominis* muscle of the baboons), combined with rhTGF-β3, to a periodontal site where superior regeneration of alveolar bone, cementum and periodontal ligament was elicited together with prominent vascularisation and the insertion of functionally oriented collagenous fibres (Figures 5.14 through 5.18). The formation of new cementum was particularly enhanced in defects implanted with rhTGF-β3 and muscle (Table 5.7). The quantity of new alveolar bone was significantly greater ($p < 0.05$) in defects implanted with rhTGF-β3 and muscle than in control defects (Figures 5.25 and 5.26; Tables 5.6 and 5.8).

Autogenous bone graft has for some time been the method of choice for enhancing biological repair within bony sites. Experimental methods using growth factor-induced prefabricated muscular flaps have been utilized for the manufacture of autogenous bone for the treatment of bony defects (Khouri *et al.,* 1991; Alam *et al.,* 2001; 2003; Abdelaal *et al.,* 2004). The graft material is harvested at an optimal time of growth and transplanted to a bony defect site. The time period allowed for growth of autogenous bone is of critical importance. If harvested too early, there may be no evidence of bony transformation and if harvested too late,

resorption may have taken place or the bone may be difficult to excise due to fusion with the surrounding tissue. In addition, induced autogenous bone material that has been left for too long may be too hard to fragment prior to transplantation. Attempting to transplant larger fragments to an irregularly shaped defect site may be problematic. In the present study, the original time period decided upon for heterotopic bone initiation was 30 days. However, due to the unavailability of theatre facilities and the surgical team, the harvesting was postponed by ten days. Those ossicles which survived this prolonged period, contained an abundance of osteogenic material, consisting of trabecular bone covered by osteoid seams, which were populated by osteoblasts (Figures 5.2, 5.3 and 5.5; Table 5.1). However, the loss of a large number of ossicles (Table 4.5), which had been detected earlier by palpation but not located during surgery on day 40, indicates that there are more factors than time period alone that need to be considered. The fact that *all* low TGF-β3 dose implants in Matrigel® carrier were resorbed (Table 4.5) may indicate that Matrigel® has a higher rate of resorption than ICBM and that for a time period exceeding 30 days (or possibly less), large doses of TGF-β3 are indicated if a Matrigel® carrier is to be used. The incorporation of the ICBM-based implants was originally meant for laboratory interest only but due to the failure of so many Matrigel®-based implants and in an effort to salvage this study, it became necessary to make use of the ICBM-based implants. The addition of 25 µg rhOP-1 to the implants appeared to have little influence on the time factor as some ossicles survived the 40-day implantation period while others did not. An equal number of 2.5 µg rhTGF-β3/25 µg rhOP-1/ICBM ossicles and 1.5 µg rhTGF-β3/25 µg rhOP-1/ICBM ossicles survived (Table 4.5), possibly indicating that the OP-1 : TGF-β3

ratio was within the optimal range for synergistic interaction when using ICBM as carrier but not so for Matrigel®.

The Matrigel®-based endochondral ossicles which were transplanted to periodontal defects showed bony proliferation within furcation defects after the 60 day healing period resulting in dense areas of alveolar bone regeneration (Figure 5.19). New cellular cementum (Figure 5.20) and new periodontal ligament with insertion of Sharpey's fibres into a cementoid matrix (Figures 5.21) were noted within the defects. A small area of ankylosis was seen in the coronal region of the furcation defect (Figure 5.22). In this study, transplanted Matrigel®-based endochondral ossicles yielded the best results for periodontal tissue regeneration with a total bone volume of 53.1 ± 4.9% (Figure 5.26; Table 5.8) compared to control (30.3 ± 5.4%).

The heterotopic ossicles induced by the binary application of 2.5 µg rhTGF-β3 and 25 µg rhOP-1 with ICBM as carrier yielded the least bone volume (Figure 5.5 and Table 5.1). This trend was perpetuated after transplantation to the periodontal furcation defects where incomplete alveolar bone regeneration was noted (Figure 5.23). The alveolar bone regenerated by the ICBM-based transplants (39.7 ± 11.8%) showed no statistical difference compared to the control (30.3 ± 5.4%). Ironically, the two low-dose ossicles (1.5 µg rhTGF-β3/25 µg rhOP-1/ICBM) that survived but were not transplanted, were the more viable of the two types of ICBM-based ossicles (Figure 5.5 and Table 5.1) with bone volumes of 39.7 ± 7.0% and 30.1 ± 4.5% for 1.5 µg rhTGF-β3/25 µg rhOP-1/ICBM and 2.5 µg rhTGF-β3/25 µg rhOP-1/ICBM ossicles, respectively. In fact, the low-dose ICBM

ossicles were more comparable with the Matrigel®-based ossicles than with each other (Figure 5.5 and Table 5.1).

Measurements carried out by the point counting technique (Parfitt, 1983) revealed that there was no significant difference in periodontal tissue regeneration between mandibular and maxillary defects (Figure 5.30 and Table 5.14). There was also no significant difference in periodontal tissue regeneration between defects of the first and second molars (Figure 5.31 and Table 5.15).

There are limitations that need to be acknowledged regarding the present study. The negative impact of a poor respondent has far-reaching consequences, even more so when a study consists of too few animals and too many implant variables. Ideally, an experiment of this nature should have no more than four variables, including the control, implanted in each animal. This would circumvent problems related to animal performance in that each animal would be host to the entire repertoire of implants to be used. The second limitation of this study is the rapidity of bone formation and subsequent resorption of the heterotopically induced ossicle. Further studies are needed to pinpoint the correct time period for bone induction in the *rectus abdominis* by the various growth factors or combinations thereof.

7. CONCLUSION

This study, with a short-term observation period and only histological analysis as an evaluation parameter, indicates by morphology and histomorphometry, that rhTGF-β3, delivered by Matrigel® as carrier, induces the key elements of periodontal tissue regeneration, namely, alveolar bone, periodontal ligament and cementum. The addition of skeletal muscle from the *rectus abdominis* enhanced the periodontal tissue regeneration with increased cementum formation indicating that the harvested muscle tissue retained responding mesenchymal cells capable of transformation into the essential components of periodontal tissue regeneration upon application of exogenous rhTGF-β3. The innovative strategy of engineering heterotopic ossicles by the application of rhTGF-β3 singly, or in combination with rhOP-1, was implemented, which allowed fragmented, induced heterotopic bone to be transplanted to surgically created periodontal defects and resulted in the induction periodontal tissue regeneration. Within a clinical context, the rapid production of mineralized ossicles in the *rectus abdominis* by rhTGF-β3 is a novel source of induced autogenous bone for transplantation, which may augment or eventually usurp bone graft material harvested from the iliac crest.

This study in non-human primates is the first step in investigating the regenerative capabilities of rhTGF-β3 in a periodontal application and the results achieved indicate that rhTGF-β3 may be on the brink of therapeutic application.

8. REFERENCES

Abdelaal, M.M., Tholpady, S.S., Kessler, J.D., Morgan, R.F., Ogle, R.C. (2004) BMP-9-transduced prefabricated muscular flaps for the treatment of bony defects. *J Craniofac Surg.* **15**:736-741.

Åberg, T., Wozney, J., Thesleff, T. (1997) Expression patterns of bone morphogenetic proteins (BMPs) in the developing mouse tooth suggest roles of morphogenesis and cell differentiation. *Dev Dyn.* **210**:383-396.

Alam, M.I., Asahina, I., Seto, I., Oda, M., Enomoto, S. (2001) Prefabricated vascularized bone flap: a tissue transformation technique for bone reconstruction. *Plast Reconstr Surg.* **108**:952-958.

Alam, M.I., Asahina, I., Seto, I., Oda, M., Enomoto, S. (2003) Prefabrication of vascularized bone flap induced by recombinant human bone morphogenetic protein 2 (rhBMP-2). *Int J Oral Maxillofac Surg.* **32**:508-514.

Anderson, T.J., Billman, C.A., Schuster, G.S. (1998) Effects of transforming growth factor-β. *J Clin Periodontol.* **25**:48-55.

Anusaksathien, O., Giannobile, W.V. (2002) Growth factor delivery to re-engineer periodontal tissues. *Curr Pharm Biotechnol.* **3**:129-139.

Armitage, G.C. (1999) Development of a classification system for periodontal diseases and conditions. *Ann Periodontol.* **4**:1-6

Bancroft, J.D., Stevens, A. (1996) Goldner's Method. *Theory and practice of histological techniques,* **4th Edition**:332-333.

Bartold, P.M., McCulloch, C.A.G., Narayanan, A.S., Pitaru, S. (2000) Tissue engineering: A new paradigm for periodontal regeneration based on molecular and cell biology. *Periodontol 2000.* **24**:253-269.

Beertsen, W., McCulloch, C.A.G., Sodek, J. (1997) The periodontal ligament: A unique, multifunctional connective tissue. *Periodont 2000.* **13**:20-40.

Bennet, N.T., Schultz, G.S. (1993) Growth factors and wound healing: part II. Role in normal and chronic wound healing. *Am J Surg.* **166**:74-81.

Bergue-Kirn, C., Smith, A.J., Ruch, J.V., Wozney, J.M., Purchio, A., Hartmann, D., Lesot, H. (1992) Effects of dentin proteins, transforming growth factor beta 1 (TGF beta 1) and bone morphogenetic protein 2 (BMP2) on differentiation of odontoblasts in vitro. *Int J Dev Biol.* **36**:491-503.

Berkovitz, B.K.B., Holland, G.R., Moxham, B.L. (2002) Oral anatomy, histology and embryology, 3rd edition.

Birkedal-Hansen, H., Butler, W.T., Taylor, R.E. (1997) Proteins of the periodontium. Characterization of the insoluble collagens of bovine dental cementum. *Calcif Tissue Res.* **23**:39-44.

Blank B.S., Levy A.R. (1999) Combined treatment of a large periodontal defect using GTR and DFDBA. *Int J Periodontics Restorative Dent.* **19**:481-487.

Bliss, C.I. (1939) The toxicity of poisons applied jointly. *Ann Appl Biol.* **26**:585-615.

Bowers, G., Felton, F., Middleton, C., Glynn, D., Sharp, S., Mellonig, J., Corio, R., Emerson, J., Park, S., Suzuki, J. (1991) Histologic comparison of regeneration in human intrabony defects when osteogenin is combined with demineralized freeze-dried bone allograft and with purified bovine collagen. *J Periodontol.* **62**:690-702.

Cassidy, N., Fahey, M., Prime, S.S., Smith, A.J. (1997) Comparative analysis of transforming growth factor-β isoforms 1-3 in human and rabbit dentine matrices. *Arch Oral Biol.* **42**:219-223.

Celeste, A.J., Iannazzi, J.A., Taylor, R.C., Hewick, R.M., Rosen, V., Wang, E.A., Wozney, J.M. (1990) Identification of transforming growth factor β family members present in bone-inductive protein purified from bovine bone. *Proc Natl Acad Sci., USA.* **87**:9843-9847.

Chai, Y., Mah, A., Crohin, C., Groff, S., Bringas, P., Jr., Le, T., Santos, V., Slavkin, H. (1994) Specific Transforming growth factor-β subtypes regulate embryonic mouse Meckel's cartilage and tooth development. *Dev Biol.* **162**:85-103.

Chai, Y., Sasano, Y., Bringas, P., Jr., Mayo, M., Kaartinen, V., Heisterkamp, N., Groffen, J., Slavkin, H., Chuler, C. (1997) Characterization of the fate of midline epithelial cells during the fusion of mandibular prominences *in vivo*. *Dev Dyn.* **208**:526-535.

Chien, H-H., Lin, W-L., Cho, M-I. (1999) Expression of TGF-β isoforms and their receptors during mineralized nodule formation by rat periodontal ligament cells *in vitro*. *J Periodont Res.* **34**:301-309.

Cho, M.I., Garant, P.R. (1989) Radiographic study of [3H] mannose utilization during cementoblast differentiation, formation of acellular cementum, and development of periodontal ligament principal fibres. *Anat Rec.* **223**:209-222.

Cho, T-J., Gerstenfeld, L.C., Einhorn, T.A. (2002) Differential temporal expression of members of the transforming growth factor-β superfamily during murine fracture healing. *JBMR* **17**:513-520.

Choi, S-H., Kim, C-K., Cho, K-S., Huh, J-S., Sorenson, R.G., Wozney. J.M., Wikesjö, U.M.E. (2002) Effect of recombinant human bone morphogenetic

protein-2/absorbable collagen sponge (rhBMP-2.ACS) on healing in 3-wall intrabony defects in dogs. *J Periodontol.* **73**:63-72.

Cochran, D.L., Wozney, J.M. (1999) Biological mediators for periodontal regeneration. *Periodontol 2000.* **19**:40-58.

Cochran, D.L., Jones, A.A., Lilly, L.C., Fiorellini, J.P., Howell, H. (2000) Evaluation of recombinant human bone morphogenetic protein-2 in oral applications including the use of endosseous implants: 3-year results of a pilot study in humans. *J Periodontol.* **71**:1241-1257.

Coin, R., Kieffer, S., Lesot, H., Vonesch, J-L., Ruch, J-V. (2000) Inhibition of apoptosis in the primary enamel knot does not affect specific tooth crown morphogenesis in the mouse. *Int J Dev Biol.* **44**:389-396

Coelho, P.V., Santos, C.T., Leitão, J., Mascarenhas, R., Glatt, M., Arvinte, T., Rahn, B. (2003) Tissue engineering in critical size mandibular bone defects. An animal study in Beagle dogs. BIOENG 2003, 7th Portuguese Conference on Biomedical Engineering, Lisbon. Portugal.

Coelho, P., Leitão, J., Santos, C., Mascarenhas, R., Arvinte, T., Glatt, M., Rahn, B. (2004) Transforming growth factor beta-3 (TGF-β3) activity is relevantly dependant on carriers differences when used for a critical mandibular bone defect repair in a Beagle dog model. *Eur Cell Mater.* **7**(Suppl 1):Pg 50. .

Cooper, D.M., Yu, E.Z., Hennessey, P., Ko, F., Robson, M.C. (1994) Determination of endogenous cytokines in chronic wounds. *Ann Surg.* **219**:688-691; discussion 691-692.

Corsi, K., Li, G.H., Peng, H., Huard, J. (2004) Muscle-based gene therapy and tissue engineering for cartilage and bone healing. *Curr Genomics.* **5**:7-17.

Coventry, J. (2000) Periodontal disease – ABC of oral health. *BMJ* **329**:36-39.

Cox, D.A, McMaster, G.K., Bürgi, R., Kunz, S., Vaxelaire, J., O'Reilly, T., Schupp, J.P.H. (1994) Experimental wound healing studies with TGF-β3. *Wound Repair and Regeneration* **2**:S208.

Cox, D.A. (1995) Transforming growth factor-beta 3. *Cell Biol Int.* **19**:357-371.

Czarnetzki, A., Jakob, T., Pusch, C.M. (2003) Palaeopathological and variant conditions of the *Homo heidelbergensis* type specimen (Mauer, Germany). *J Hum Evol.* **44**:479-495.

D'errico, J.A., MacNeil, R.L., Takata, T., Berry, J., Strayhorn, C., Somerman, M.J. (1997) Expression of bone associated markers by tooth root lining cells, in situ and in vitro. *Bone* **20**:117-126.

Duncan, M.J., Emory, S.A., Almira, E.C. (1996) *Porphyromonas gingivalis* genes isolated by screening for epithelial call attachment. *Infect Immun.* **64**:3624-3631.

Duncan, M.J. (2003) Genomics of oral bacteria. *Crit Rev Oral Biol Med.* **14**:175-187.

Duneas, N., Crooks, J., Ripamonti, U. (1998) Transforming growth factor-β1: induction of bone morphogenetic protein genes expression in the baboon and synergistic interaction with osteogenic protein-1 (BMP-7). *Growth Factors* **15**:259-277.

Fleet, J.C., Cashman, K., Cox, K., Rosen, V. (1996) The effects of aging on the bone inductive activity of recombinant human bone morphogenetic protein-2. *Endocrinology.* **137**:4605-4610.

Galetti, R., Benelli, A., Bruzzeai, G., Concolo, U., Filaferro, M., Genedani, S., Palazzini, S., Rasio, G., De Pol, A. (2000) *In vitro* study of periodontal ligament cells. *Minerva Stomatol.* **49**:149-154.

Gao, J., Symons, A.L., Bartold, P.M., (1998) Expression of transforming growth factor-beta 1 (TGF-beta 1) in the developing periodontium of rats. *J Dent Res.* **77**:1708-1716.

Giannobile, W.V. (1996) Periodontal tissue engineering by growth factors. *Bone* **19**(1 Suppl):23S-37S.

Giannobile, W.V., Ryan, S., Shih, M-S., Su, D.L., Kaplan, P.L., Chan, T.C.K. (1998) Recombinant human osteogenic protein-1 (OP-1) stimulates periodontal wound healing in class III furcation defects. *J Periodontol.* **69**:129-137.

Gottlow, J., Nyman, S., Karring, T., Lindhe, J. (1984) New attachment formation as the result of controlled tissue regeneration. *J Clin Periodontol.* **11**:494-503.

Gottlow, J., Nyman, S., Lindhe, J., Karring, T., Wennstrom, J. (1986) New attachment formation in the human periodontium by guided tissue regeneration. Case reports. *J Clin Periodontol.* **13**:604-616.

Gottlow, J., Laurell, L., Lundgren, D., Mathisen, T., Nyman, S., Rylander, H., Bogentoft, C. (1994) Periodontal tissue response to a new bioresorbable guided tissue regeneration device: a longitudinal study in monkeys. *Int J Periodontics Restorative Dent.* **14**:436-449.

Graves, D.T., Cochran, D.L. (1994) Periodontal regeneration with polypeptide growth factors. *Curr Opin Periodontics.* 178-186.

Greco, W.R., Bravo, G., Parsons, J.C. (1995) The search for synergy: A critical review from a response surface perspective. *Pharmacol Rev*. **47**:331-385.

Greco, W.R., Faessel, H., Levasseur, L. (1996) The search for cytotoxic synergy between anticancer agents: A case of Dorothy and the ruby slippers? *J National Cancer Institute* **88**:699-700.

Greenhalgh, D.G. (1996) The role of growth factors in wound healing. *J Trauma* **41**:159-167.

Haffajee, A.D., Socransky, S.S. (1994) Microbial etiological agents of destructive periodontal diseases. *Periodontol 2000.* **5**:78-111.

Häkkinen, L., Uitto, V-J., Larjava, H. (2000) Cell biology of gingival wound healing. *Periodontol 2000.* **24**:127-152.

Hammarstrom, L. (1997) Enamel matrix, cementum development and regeneration. *J Clin Periodontol.* **23**:658-668.

Hamp, S-E., Nyman, S., Lindhe, J. (1975) Periodontal treatment of multirooted teeth. Results after 5 years. *J Clin Periodontol.* **2**:126-135.

Heikinheimo, K., Happonen, R-P., Miettinen, P.J., Ritvos, O. (1993) Transforming Growth Factor β2 in epithelial differentiation of developing teeth and odontogenic tumours. *J Clin Invest.* **91**:1019-1027.

Helder, M.N., Karg, H., Bervoets, T.J., Vukicevic, S., Burger, E.H., D'Souza, R.N., Woltgens, J.H., Karsenty, G., Bronckers, A.L. (1998) Bone morphogenetic protein-7 (osteogenic protein-1, OP-1) and tooth development. *J Dent Res.* **77**:545-554.

Holmes, T.C. (2002) Novel peptide-based biomaterial scaffolds for tissue engineering. *Trends Biotechnol.* **20**:16-21.

Holt, S.C., Bramanti, T.E. (1991) Factors in virulence expression and their role in periodontal disease pathogenesis. *Crit Rev Oral Biol Med.* **2**:177-281.

Hou, Q., De Bank, P.A., Shakesheff, K.M. (2004) Injectable scaffolds for tissue regeneration. *J Mater Chem.* **14**:1915-1923.

Howell, T.H., Martuscelli, G., Oringer, J. (1996) Polypeptide growth factors for periodontal regeneration. *Curr Opin Periodontol.* **3**:149-156.

Howell, T.H., Fiorellini, J., Jones, A., Alder, M., Nummikoski, P., Lazaro, M., Lilly, L., Cochran, D. (1997) A feasibility study evaluating rhBMP-2/absorbable collagen sponge device for local alveolar ridge preservation or augmentation. *Int J Periodontics Restorative Dent.* **17**:124-139.

Huang, K-K., Shen, C., Chiang, C-Y., Hsieh, Y-D., Fu, E. (2005) Effects of bone morphogenetic protein-6 on periodontal wound healing in a fenestration defect of rats. *J Periodont Res.* **40**:1-10.

Hubbell, J.A. (1995) Biomaterials in tissue engineering. *Biotechnology* **13**:565-575.

Ioannidou, E., Makris, G.P. (2003) Twelve-year follow-up of an autogenous mandibular canine transplant. *Oral Surg Oral Med Oral Pathol Oral Radiol Endod.* **96**:582-590.

Jernvall, J., Kettunen, P., Karavanova, I., Martin, L.B., Thesleff, I. (1994) Evidence for the role of the enamel knot as a control centre in mammalian tooth cusp formation: non-dividing cells express growth stimulating Fgf-4 gene. *Int J Dev Biol.* **38**:463-469.

Jin, Q-M., Takita, H., Kohgo, T., Atsumi, K., Itoh, H., Kuboki, Y. (2000) Effects of geometry of hydroxyapatite as a cell substratum in BMP-induced ectopic bone formation. *J Biomed Mater Res.* **52**:491-499.

Jin, Q-M., Anusaksathien, O., Webb, S.A., Rutherford, R.B., Giannobile, W.V. (2003) Gene therapy of bone morphogenetic protein for periodontal tissue engineering. *J Periodontol* **74**:202-213.

Karring, T., Nyman, S., Gottlow, J., Laurell, L. (1993) Development of the biological concept of guided tissue regeneration – animal and human studies. *Periodontol 2000.* **1**:26-35.

Keys, D., Bartold P..M. (2000) Periodontal conditions of relevance to the Australian Defence Force. *ADP Health* **1**:114-118.

Khouri, R.K., Koudsi, B., Reddi, H. (1991) Tissue transformation into bone in vivo. A potential practical application. *JAMA* **266**:1953-1955.

Kinoshita, A., Oda, S., Takahashi, K., Yokota, S., Ishikawa, I. (1997) Periodontal regeneration by application of recombinant human bone morphogenetic protein-2 to horizontal circumferential defects created by experimental periodontitis in beagle dogs. *J Periodontol.* **68**:103-109.

Kleinman, H.K., McGarvey, M.L., Hassell, J.R., Star, V.L., Cannon, F.B., Laurie, G.W., Martin, G.R. (1986) Basement membrane complexes with biological activity. *Biochem.* **25**:312-318.

Knox, B., Aukhil, I. (1988) Ultrastructural study of experimental cementum regeneration in rats. *J Periodont Res.* **23**:60-67.

Kojović, D., Kesić, L. (2003) Diseases of the periodontium: The therapeutic aspects. *Acta Stomatol Naissi* **19**:351-359.

Kuboki, Y., Sasaki, M., Takita, H., Kato, H. (1998a) Regeneration of periodontal ligament and cementum by BMP-applied tissue engineering. *Eur J Oral Sci.* **106**(Suppl 1):197-203.

Kuboki, Y., Takita, H., Kobayashi, D., Tsuruga, E., Inoue, M., Murata, M., Nagai, N., Dohi, Y., Ohgushi, H. (1998b) BMP-induced osteogenesis on the surface of

hydroxyapaptite with geometrically feasible and nonfeasible structures: topology of osteogenesis. *J Biomed Mater Res.* **39**:190-199.

Langer, R., Vancanti, J.P. (1993) Tissue engineering. *Science* **260**:930-932.

Laurencin, C.T., Ambrosio, A.M., Borden, M.D., Cooper, J. A., Jr. (1999) Tissue engineering: orthopedic applications. *Annu Rev Biomed Eng.* **1**:19-46.

Lee, J.Y., Musgrave, D., Pelinkovic, D., Fukushima, K., Cummins, J., Usas, A., Robbins, P., Fu, F.H., Huard, J. (2001) Effect of bone morphogenetic protein-2-expressing muscle-derived cells on healing of critical-sized bone defects in mice. *J Bone Joint Surg Am.* **83**:1032-1039.

Li, R.H., Wozney, J.M. (2001) Delivering on the promise of bone morphogenetic proteins. *Trends Biotechnol.* **19**:255-265.

Lin, W.L., McCulloch, C.A., Cho, M.I. (1994) Differentiation of periodontal ligament fibroblasts into osteoblasts during socket healing after tooth extraction in the rat. *Anat Rec.* **240**:492-506.

Lindhe, J., Pontoriero, R., Berglundh, T., Araujo, M. (1995) The effect of flap management and bioresorbable occlusive devices in GTR treatment of degree III furcation defects. An experimental study in dogs. *J Clin Periodontol.* **22**:276-283.

Listgarten, M.A., Rosenberg, M.M. (1979) Histological study of repair following new attachment procedures in human periodontal lesions. *J Periodontol.* **50**:333-344.

Listgarten, M.A., Schifter, C.C., Laster, L. (1985) 3-year longitudinal study of the periodontal status of an adult population with gingivitis. *J Clin Periodontol.* **12**:225-238.

Löe, H., Waerhaug, J. (1961) Experimental replantation of teeth in dogs and monkeys. *Arch Oral Biol.* **3**:176-184.

Lu, H.H., Kofron, M.D., El-Amin, S.F., Attawia M.A., Laurencin C.T. (2003) *In vitro* bone formation using muscle-derived cells: a new paradigm for bone tissue engineering using polymer-bone morphogenetic protein matrices. *Biochem Biophys Res Commun.* **305**:882-889.

Luyten, F.P., Cunningham, N.S., Ma, S., Muthukumaran, N., Hammonds, R.G., Nevins, W.B., Woods, W. I., Reddi, A.H. (1989) Purification and partial amino acid sequence of osteogenin, a protein initiating bone differentiation. *J Biol Chem.* **264**:13377-13380.

Lynch, S.E. (1992) Methods for evaluation of regenerative procedures. *J Periodontol.* **63**:1085-1092.

Magan, A., Ripamonti, U. (1996) Geometry of porous hydroxyapaptite implants influences osteogenesis in baboons ((*Papio ursinus). J Craniofac Surg.* **7**:71-78.

Marcopoulou, C.E., Vavouraki, H.N., Dereka, X.E., Vrotsos, I.A. (2003) Proliferative effect of growth factors TGF-β1, PDGF-BB and rhBMP-2 on human gingival fibroblasts and periodontal ligament cells. *J Int Acad Periodontol.* **5**:63-70.

Mastrogiacomo, M., Derubeis A.R., Cancedda R. (2005) Bone and cartilage formation by skeletal muscle derived cells. *J Cell Phys.* **204**:594-603.

Matthews, D.C. (2000) Periodontal medicine: A new paradigm. *J Can Dent Assoc.* **66**:488-491.

Maxian, S.H., Di Stefano, T., Melican, M.C., Tiku, M.L., Zawadsy, J.P. (1998) Bone cell behavior on Matrigel®-coated Ca/P coatings of varying crystallinities. *J Biomed Mater Res.* **40**:171-179.

McAllister, B., Narayanan, A.S., Miki, Y., Page, R.C. (1990) Isolation of a fibroblast attachment protein from cementum. *J Periodont Res.* **25**:99-105.

McCauley, L.K., Somerman, M.J. (1998) Biologic modifiers in periodontal regeneration. *Dent Clin North Am.* **42**:361-387.

McCulloch C.A. (1985) Progenitor cell populations in the periodontal ligament of mice. *Anat Rec.* **211**:258-262.

McCulloch, C.A., Bordin, S. (1991) Role of fibroblast subpopulations in periodontal physiology and pathology. *J Peridontol Res.* **26**:144-154.

McCulloch, C.A. (1995) Origins and functions of cells essential for periodontal repair: the role of fibroblasts in tissue homeostasis. *Oral Dis.* **1**:271-278.

Melcher, A.H. ((1976) On the repair potential of periodontal tissues. *J Periodontol.* **47**:256-260.

Mellonig, J.T., Bowers, G.M., Bailey, R.C. (1981) Comparison of bone graft materials. Part I. New bone formation with autografts and allografts determined by Strontium-85. *J Periodontol.* **52**:291-296.

Merwin, J.R., Roberts, A., Kondaiah, P., Tucker, A., Madri, J. (1991) Vascular cell responses to TGF-beta 3 mimic those of TGF-beta 1 in vitro. *Growth Factors* **5**:149-158.

Michalowicz, B.S., Ronderos, M., Camara-Silva, R., Contreras, A., Slots, J. (2000) Human herpes viruses and *Porphyromonas gingivalis* are associated with juvenile periodontitis. *J Periodontol.* **71**:981-988.

Miguel, S.M-S., Rupf, S., Frenzel, J., Eschrich, K. (2003) The effects of extracts from periodontopathic bacteria on human periodontal fibroblasts stimulated with mineralization supplements. *J Oral Sci.* **45**:127-137.

Miki, Y., Narayanan, A.S., Page, R.C. (1987) Mitogenic activity of cementum components to gingival fibroblasts. *J Dent Res.* **66**:1399-1403.

Mohammed, S., Pack, A.R.C., Kardos, T.B. (1998) The effect of transforming growth factor beta one (TGF-β1) on wound healing, with or without barrier membranes, in a Class II furcation defect in sheep. *J Periodont Res.* **33**:335-344.

Nakao, A., Afrakhte, M., Morèn, A., Nakayama, T., Heldin, N-E., Heldin C-H., ten Dijke, P. (1997) Identification of Smad7, a TGFβ-inducible antagonist of TGF-β signalling. *Nature.* **389**:631-635.

Nakashima, M., Reddi, A.H. (2003) The application of bone morphogenetic proteins to dental tissue engineering. *Nature Biotech.* **21**:1025-1032.

Nevins, M., Kirker-Head, C., Nevins, M., Wozney, J.A., Palmer, R., Graham, D. (1996) Bone formation in goat maxillary sinus induced by absorbable collagen sponge implants impregnated with recombinant human bone morphogenetic protein-2. *Int J Periodontics Restorative Dent.* **16**:8-19.

Nevins, M., Camelo, M., Nevins, M.L., Schenk, R.K., Lynch, S.E. (2003) Periodontal regeneration in humans using recombinant human platelet-derived growth factor-BB (rhPDGF-BB) and allogenic bone. *J Peridontol.* **74**:1282-1292.

Nimni, M.E. (1997) Polypeptide growth factors: targeted delivery systems. *Biomaterials* **18**:1201-1225.

Nishimura, K., Hayashi, M., Matsuda, K., Shigeyama, Y., Yamasaki, A., Yamaoka, A. (1989) The chemo attractive potency of periodontal ligament, cementum and dentin for human gingival fibroblasts. *J Periodont Res.* **24**:146-148.

Nyman, S., Gottlow, J., Karring, T., Lindhe, J. (1982a) The regenerative potential of the periodontal ligament. An experimental study in the monkey. *J Clin Periodontol.* **9**:257-265.

Nyman S., Lindhe J., Karring T., Rylander H. (1982b) New attachment following surgical treatment of human periodontal disease. *J Clin Periodontol.* **9**:290-296.

Oates, T.W., Rouse, C.A., Cochran, D.L. (1993) Mitogenic effects of growth factors on human periodontal ligament cells in vitro. *J Periodontol.* **64**:142-148.

Page, R.C. (1986) Gingivitis. *J Clin Periodontol.* **13**:345-355.

Parfitt, A.M. (1983) Stereologic basis of bone histomorphometry: theory of quantitative microscopy and reconstruction of third dimension. In Recker HR, ed. *Bone Histomorphometry: Techniques and interpretation.* Boca Raton: CRC Press: 53-87.

Parfitt, A.M., Drezner, M.K., Glorieux, F.H. (1987) Bone histomorphometry: standardization of nomenclature, symbols and units. *J Bone Miner Res.* **2**:595-610.

Pelton, R.W., Saxena, B., Jones, M., Moses, H.L., Gold, L.I. (1991) Immunohistochemical localization of TGF-β1, TGF-β2, and TGF-β3 in the mouse embryo: expression patterns suggest multiple roles during embryonic development. *J Cell Biol.* **115**:1091-1105.

Pitaru, S., Aubin, J.E., Gray, A., Metzger, Z., Melcher, A.H. (1984) Cell migration attachment and orientation in vitro are enhanced by partial demineralisation of dentine and cementum and inhibited by bacterial endotoxin. *J Periodont Res.* **19**:661-665.

Pitaru, S., Narayanan, A.S., Olson, S., Savion, N., Hekmati, H., Alt, I., Metzger, Z. (1994) Cellular origins and differentiation control mechanisms during periodontal development and wound healing. *J Periodont Res.* **29**:81-94

Pussinen, P.J., Laatikainen, T., Alfthan, G., Asikainen, S., Jousilahti, P. (2003) Periodontitis is associated with a low concentration of vitamin C in plasma. *Clin Diagn Lab Immunol.* **10**:897-902.

Quarto, R., Thomas, D., Liang, C.T. (1995) Bone progenitor cell deficits and the age-associated decline in bone repair capacity. *Calcif Tissue Int.* **56**:123-129.

Quattlebaum, J.B., Mellonig, J.T., Hensel, N.F. (1988) Antigenicity of freeze-dried cortical bone allograft in human periodontal osseous defects. *J Periodontol.* **59**:394-397.

Ramoshebi, L.N., Matsaba, T.N., Teare, J., Renton, L., Patton, J., Ripamonti, U. (2002) Tissue engineering: TGF-β3 superfamily members and delivery systems in bone regeneration. *Expert Rev Mol Med.* **4**:1-11.

Reddi, A.H. (1994) Symbiosis of biotechnology and biomaterials: applications in tissue engineering of bone and cartilage. *J Cell Biochem.* **56**:192-195.

Reddi, A.H. (1997) Bone morphogenetic proteins: An unconventional approach to isolation of first mammalian morphogens. *Cytokine Growth Factor Rev.* **8**:11-20.

Register, A.A., Burdick, F. A. (1975) Accelerated reattachment with cementogenesis to dentin, demineralized in situ. I. Optimum range. *J Periodontol.* **46**:646-655.

Register, A.A., Burdick, F. A. (1976) Accelerated reattachment with cementogenesis to dentin, demineralized in situ. II. Defect repair. *J Periodontol.* **47**:497-505.

Ripamonti, U., Petit, J-C., Lemmer, J., Austin, J.C. (1987) Regeneration of the connective tissue attachment on surgically exposed roots using a fibrin-fibronectin adhesive system. An experimental study on the baboon *(Papio ursinus). J Periodont Res.* **22**:320-326.

Ripamonti, U. (1988) Paleopathology in *Australopithecus africanus:* A suggested case of a 3-million-year-old prepubertal periodontitis. *Am J Phys Anthropol.* **76**:197-210.

Ripamonti, U., Ma, S., Reddi, A.H. (1992a) The critical role of geometry of porous hydroxyapaptite delivery system in induction of bone by osteogenin, a bone morphogenetic protein. *Matrix* **12**:202-212.

Ripamonti, U., Ma, S., Cunningham, N.S., Yeates, L., Reddi, A.H. (1992b) Initiation of bone regeneration in adult baboons by osteogenin, a bone morphogenetic protein. *Matrix* **12**:369-380.

Ripamonti, U., Reddi, H. (1994) Periodontal regeneration: potential role of bone morphogenetic proteins. *J Periodont Res.* **29**:225-235.

Ripamonti, U., Heliotis, M., van den Heever,B., Reddi A.H. (1994) Bone morphogenetic proteins induce periodontal regeneration in the baboon *(Papio ursinus). J Periodont Res.* **29**:439-445.

Ripamonti, U., Heliotis, M., Rueger, D.C., Sampath, T.K. (1996a) Induction of cementogenesis by recombinant human osteogenic protein-1 (hOP-1/BMP-7) in the baboon *(Papio ursinus). Archs Oral Biol.* **41**:121-126.

Ripamonti, U., Bosch, C., van den Heever, B., Duneas, N., Melsen, B., Ebner, R. (1996b) Limited chondro-osteogenesis by recombinant human transforming growth factor--β1 in calvarial defects of adult baboons (*Papio ursinus*). *JBMR* **11**: 938-945.

Ripamonti, U., Duneas, N., van den Heever, B., Bosch, C., Crooks, J. (1997) Recombinant transforming growth factor-β1 induces endochondral bone in the baboon and synergizes with recombinant osteogenic protein-1 (bone morphogenetic protein-7) to initiate rapid bone formation. *JBMR* **12**:1584-1595.

Ripamonti, U., Reddi, H. (1997) Tissue engineering, morphogenesis and regeneration of periodontal tissues by bone morphogenetic proteins. *Crit Rev Oral Biol Med.* **8**:154-163.

Ripamonti, U., Crooks, J., Kirkbride, A.N. (1999) Sintered porous hydroxyapatites with intrinsic osteoinductive activity: geometric induction of bone formation. *SAJS* **95**:335-343.

Ripamonti, U., Crooks, J., Matsaba, T., Tasker, J. (2000) Induction of endochondral bone formation by recombinant human transforming growth factor-beta 2 in the baboon *(Papio ursinus). Growth Factors* **17**:269-285.

Ripamonti, U., Crooks, J., Petit, J-C., Rueger, D.C. (2001) Periodontal tissue regeneration by combined applications of recombinant human osteogenic protein-1 and bone morphogenetic protein-2. A pilot study in chacma baboons (*Papio ursinus*). *Eur J Oral Sci.* **109**:241-248.

Ripamonti, U., Crooks, J., Teare, J., Petit, J-C., Rueger, D.C. (2002a) Periodontal tissue regeneration by recombinant human osteogenic protein-1 in periodontally-induced furcation defects of the primate *Papio ursinus. SAJS* **98**:361-368.

Ripamonti, U., van den Heever, B., Heliotis M., Dal Mas, I., Hahnle, U.R., Biscardi, A. (2002b) Local delivery of bone morphogenetic proteins in with Matrigel®. *SAJS* **98**:429-433.

Ripamonti, U. (2004a) Soluble, insoluble and geometric signals sculpt the architecture of mineralized tissues. *J Cell Mol Med.* **8**:169-180.

Ripamonti, U. (2004b) Invited Speaker, Keynote Lecture. The 5th International Conference on Bone Morphogenetic Proteins, Nagoya, Japan September 2004.

Ripamonti, U., Teare, J.A., Petit, J-C. (2006) Pleiotropism of bone morphogenetic proteins: From bone induction to cementogenesis and periodontal ligament regeneration. *J Int Acad Periodontol.* **8**:23-32.

Ritter-Jones, M., Messersmith, P.B. (2002) In situ forming biomaterials. *Oral Maxillofacial Surg Clin N Am.* **14**:29-38.

Roberts, W.E., Chase, D.C. (1981) Kinetics of cell proliferation and migration associated with orthodontically-induced osteogenesis. *J Dent Res.* **60**:174-181.

Rose, F.R.A.J., Oreffo, R.O.C. (2002) Bone tissue engineering: Hope vs. hype. *Biochem Biophys Res Com.* **292**:1-7.

Rose, F.R.A.J., Hou, Q., Oreffo, R.O.C. (2004) Delivery systems for bone growth factors – the new players in skeletal regeneration. *J Pharm Pharmacol.* **56**:415-427.

Ruch, J.V., Lesot, H., Bergue-Kirn, C. (1995) Odontoblast differentiation. *Int J Dev Biol.* **39**:51-68.

Rummelhart, J.M., Mellonig, J.T., Gray, J.L., Towle H.J. (1989) A comparison of freeze-dried bone allograft and demineralized freeze-dried bone allograft in human periodontal osseous defects. *J Periodontol.* **60**:655-663

Salgado, A.J., Coutinho, O.P., Reis. R.L. (2004) Bone tissue engineering: State of the art and future trends. *Macromol Biosci.* **4**:743-765.

Sampath, T.K., Reddi, A.H. (1981) Dissociative extraction and reconstitution of extracellular matrix components involved in local bone differentiation. *Proc Natl Acad Sci USA.* **78**:7599-7603.

Sampath, T.K., Nathanson, M.A., Reddi, A.H. (1984) *In vitro* transformation of mesenchymal cells derived from embryonic muscle into cartilage in response to extracellular matrix components of bone. *Proc Natl Acad Sci USA.* **81**:3419-3423.

Scott, M.R., Will, R., Ironside, J., Nguyen, H-O.B., Tremblay, P., DeArmond, S.J., Prusiner, S.B. (1999) Compelling transgenic evidence for transmission of bovine spongiform encephalopathy prions to humans. *Proc Natl Acad Sci USA.* **96**:15137-15142.

Sculean, A., Chiantella, G.C., Windisch, P., Donos, N. (2000) Clinical and histologic evaluation of human intrabony defects treated with an enamel matrix protein derivative (Emdogain). *Int J Periodontics Restorative Dent.* **20**:374-381.

Sigurdsson, T.J., Lee, M.B., Kubota, K., Turek, T.J., Wozney, J.M., Wikesjö, U.M.E. (1995) Periodontal repair in dogs: Recombinant human bone morphogenetic protein-2 significantly enhances periodontal regeneration. *J Periodontol.* **66**:131-138.

Simion, M., Fontana, F. (2004) Autogenous and xenogeneic bone grafts for bone regeneration. *Minerva Stomatol.* **53**:191-206.

Slayton, R.L., Williams, L., Murray, J.C., Wheeler, J.J., Lidral, A.C., Nishimura, C.J. (2003) Genetic association studies of cleft lip and/or palate with hypodontia outside the cleft region. *Cleft Palate Craniofac J.* **40**:274-279.

Somerman, M.J., Archer, S.Y., Shteyer, A., Foster, R.A. (1987) Protein production by human gingival fibroblasts is enhanced by guanidine EDTA extracts of cementum. *J Periodont Res.* **22**:75-77.

Somerman, M.J., Sauk, J.J., Foster, R.A., Dickerson, K., Norris, K., Argraves W.S. (1991) Cell attachment activity of cementum: bone sialoprotein II identified in cementum. *J Periodont Res.* **26**:10-16.

Somerman, M.J., Ouyang, H.J., Berry, J.E., Saygin, N.E., Strayhorn, C.L., D'errico, J.A., Hullinger, T., Giannobile, W.V. (1999) Evolution of periodontal regeneration: from the roots' point of view. *J Periodont Res.* **34**:420-424.

Sorensen, R.G., Polimeni, G., Kinoshita, A., Wozney, J.M., Wikesjö, U.M.E. (2004) Effect of recombinant human bone morphogenetic protein-12 (rhBMP-12) on regeneration of periodontal attachment following tooth replantation in dogs. *J Clin Periodontol.* **31**:654-661.

Stadelman, W.K., Digenis, A.G., Tobin, G.R. (1998) Physiology and healing dynamics of chronic cutaneous wounds. *Am J Surg.* **176**(2A Suppl):26S-38S.

Sun, J-S., Wu, S.Y-H., Lin, F-H. (2005) The role of muscle-derived stem cells in bone tissue engineering. *Biomaterials* **24**:3953-3960.

Sykaras, N., Opperman, L.A. (2003) Bone morphogenetic proteins (BMPs): How do they function and what can they offer the clinician? *J Oral Sci.* **45**:57-73.

Talwar, R., Di Silvio, L., Hughes, F.J., King, G.N. (2001) Effects of carrier release kinetics on bone morphogenetic protein-2-induced periodontal regeneration *in vivo.* *J Clin Periodontol.* **28**:340-347.

Tanner, A.C., Haffer, C., Bratthall, G.T., Visconti, R.A., Socransky, S.S. (1979) A study of the bacteria associated with advancing periodontitis in man. *J Clin Periodontol.* **6**:278-307.

Tatakis, D.N., Wikesjö, U.M.E., Razi, S.S., Sigurdsson, T.J., Lee, M.B., Nguyen, T., Ongpipattanakul, B., Hardwick, R. (2000) Periodontal repair in dogs: effect of transforming growth factor-β1 on alveolar bone cementum regeneration. *J Clin Periodontol.* **27**:698-704.

Thesleff, I., Vaahtokari, A., Partanen, A.M. (1995) Regulation of organogenesis. Common molecular mechanisms regulating the development of teeth and other organs. *Int J Dev Biol.* **39**:35-50.

Thomadakis, G., Ramoshebi, L.N., Crooks, J., Rueger, D.C., Ripamonti, U. (1999) Immunolocalization of bone morphogenetic protein-2 and -3 and osteogenic protein-1 during murine tooth root morphogenesis and in other craniofacial structures. *Eur J Oral Sci.* **107**:368-377.

Toriumi, D.M., Kotler, H.S., Luxenberg, D.P., Holtrop, M.E., Wang, E.A. (1991) Mandibular reconstruction with a recombinant bone-inducing factor. Functional,

histologic, and biomechanical evaluation. *Arch Otolaryngol Head Neck Surg.* **117**:1101-1112.

Trueta, J. (1963) The role of vessels in osteogenesis. *JBJS* **45B**:402-418.

Turgeman, G., Aslan, H., Gazit, Z., Gazit, D. (2002) Cell-mediated gene therapy for bone formation and regeneration. *Curr Opin Mol Therap.* **4**:390-394.

Uludag, H., Gao, T., Porter, T.J., Friess, W., Wozney, J.M. (2001) Delivery systems for BMPs: Factors contributing to protein retention at an application site. *JBJS* **83**:S128-S135.

Urist, M.R. (1965) Bone: Formation by autoinduction. *Science* **150**:893-899.

Urist, M.R., Strates, B.S. (1971) Bone Morphogenetic Protein. *J Dent Res.* **50**:1392-1406.

Vaahtokari, A., Åberg, T., Jernvall, J., Keränen, S., Thesleff, I. (1996) The enamel knot as a signaling center in the developing mouse tooth. *Mech Dev.* **54**:39-43.

Van Eeden, S.P., Ripamonti, U. (1994) Bone differentiation in porous hydroxyapaptite in baboons is regulated by the geometry of the substratum: implications for reconstructive craniofacial surgery. *Past Reconstr Surg.* **93**:959-966.

Vukicevic, S., Luyten, F.P., Kleinman, H.K., Reddi, A.H. (1990) Differentiation of canalicular cell processes in bone cells by basement membrane matrix components: regulation by discreet domains of laminin. *Cell* **63**:437-445.

Vukicevic. S., Kleinman. H.K., Luyten. F.P., Roberts. A.B., Roche. N.S., Reddi. A.H. (1992) Identification of multiple active growth factors in basement membrane Matrigel® suggests caution in interpretation of cellular activity related to extracellular matrix components. *Exp Cell Res.* **202**:1-8.

Wang, E.A., Rosen, V., D'Alessandro, J.S., Bauduy, M., Cordes, P., Harada, T., Israel, D.I. Hewick, R.M., Kerns, K.M., LaPan, P., Luxenberg, D.P., McQuaid, D., Moutsatsos, I.K., Nove, J., Wozney, J.M. (1990) Recombinant human bone morphogenetic protein induces bone formation. *Proc Natl Acad Sci., USA.* **87**:2220-2224.

Wiebe, C.B., Putnins, E.E. (2000) The periodontal disease classification system of the American Academy of Periodontology – an update. *J Can Dent Assoc.* **66**:594-597.

Wikesjö, U.M.E., Nilveus, R.E., Selvig, K.A. (1992) Significance of early healing events on periodontal repair: a review. *J Periodontol.* **63**:158-165.

Wikesjö, U.M., Sigurdsson, T.J., Lee, M.B., Tatakis, D.N., Selvig, K.A. (1995) Dynamics of wound healing in periodontal regenerative therapy. *J Calif Dent Assoc.* **23**:30-35.

Wikesjö, U.M.E., Razi, S.S., Sigurdsson, T.J., Tatakis, D.N., Lee, M.B., Ongpipattanakul, B., Nguyen, T., Hardwick, R. (1998) Periodontal repair in dogs: effect of recombinant human transforming growth factor-β1 on guided tissue regeneration. *J Clin Periodontol.* **25**:475-481.

Wikesjö, U.M.E., Sorenson, R.G., Kinoshita, A., Li, J., Wozney, J.M. (2004) Periodontal repair in dogs: Effect of recombinant human bone morphogenetic protein-12 (rhBMP-12) on regeneration of alveolar bone and periodontal attachment. *J Clin Periodontol.* **31**:662-670.

Younger, W. (1893) Some of the latest phases in implantation and other operations. *Dent Cosmos.* **35**:102-108.

Zernik, J.H., Nowroozi, N., Liu, Y.H., Maxson, R. (1997) Development, maturation, and aging of the alveolar bone. *Dent Clin North Am.* **41**:1-15.

Zacks, S.I., Sheff, M.E. (1982) Periosteal and metaplastic bone formation in mouse minced muscle regeneration. *Lab Invest.* **46**:405-412.

Zhao, M., Jin, Q., Berry, J.E., Nociti Jr., F.H., Giannobile, W.V., Somerman, M.J. (2004) Cementoblast delivery of periodontal tissue engineering. *J Periodontol.***75**: 54-161.

9. APPENDICES

Appendix 1

Dilutions for rhTGF-β3 Doses

Stock solution: 800 µg TGF-β3 in 2000 µl 5 mM HCl (0.4 µg TGF-β3 / µl HCl)		
Dilutions for doses:		
125 µl stock solution used for:		1875 µl stock solution used for:
2.5 µg TGF-β3	**1.5 µg TGF-β3**	**75 µg TGF-β3**
50 µl HCl = 20 µg TGF-β3 plus 1550 µl HCl 1600 µl = 20 µg TGF-β3	30 µl HCl = 12 µg TGF-β3 plus 1570 µl HCl 1600 µl = 12 µg TGF-β3	1875 µl HCl = 750 µg TGF-β3 plus 125 µl HCl 2000 µl = 750 µg TGF-β3
For an amount of 200 µl per dose:		
200 µl = 2.5 µg TGF-β3	200 µl = 1.5 µg TGF-β3	200 µl = 75 µg TGF-β3

Appendix 2

Preparation of OP-1 Solutions

Preparation of rhOP-1 doses:

A 600 µl stock solution of rhOP-1 in 5 mM HCl, containing 960 µg of rhOP-1 was available for use. An amount of 0.625 µl of stock solution therefore contained 1 µg rhOP-1. For the required dose of 25 µg rhOP-1, an amount of 15.625 µl of stock solution was be used. Accurate measurement was achieved by using a 2 – 20 µl Nichipet autoclavable micropipette.

Appendix 3

Preparation of Insoluble Collagenous Bone Matrix (ICBM)

1. Diaphyseal segments of baboon tibia and femur were dehydrated using absolute alcohol and treated with diethyl ether to remove fat.
2. The dehydrated bone segments were then pulverized under liquid nitrogen by means of an industrial crusher from the Geology Department, University of the Witwatersrand, sieved through 74 – 420 micron meshes and only particles within this range collected.
3. The powder was demineralized overnight under cold conditions using 0.5 N hydrochloric acid (pH 2.0), neutralized with 50 mM Tris-hydrochloric acid (pH 7.4) and extracted with a solution of 4 M guanidinium hydrochloric acid in 50 mM Tris (pH 7.4) containing protease inhibitors (100 mM α-amino-*n*-caproic acid, 5 mM benzamidine HCl, 0.5 mM phenyl methasulphonyl fluoride and 5 mM N-ethyl maleimide).
4. The resultant ICBM was washed with 0.5 M Tris (pH 7.4) and lyophilized overnight.

Appendix 4

Matrigel®-based Implants

A constant volume of 200 µl was used throughout the experiment for the Matrigel® doses. As per manufacturer's specifications, in order to maintain a gelled consistency, a dilution not exceeding 1:3 was used. Therefore, 200 µl containing the relevant rhTGF-β3 dose was added to 400 µl Matrigel® carrier, resulting in an implant device of 600 µl to be placed in the predetermined heterotopic or periodontal site.

Appendix 5

ICBM-based Implants

Pellets designed for heterotopic sites were impregnated with rhOP-1 and rhTGF-β3 proteins and were made as follows:

1. Using sterile 15 ml polypropylene centrifuge tubes, add the desired protein combination to 100 mg ICBM.
2. Leave to stand for a few minutes to allow precipitation of proteins into the ICBM.
3. Add 2mg chondroitin sulphate and 2mg baboon Type 1 collagen and vortex.
4. Wash with 2 to 3 volumes of pre-chilled absolute ethanol, centrifuge at 2500 rpm for 15 minutes (*i.e.* 3 x 5 minutes with chilling at -70°C at 10 to 15 minute intervals).
5. Decant the absolute ethanol supernatant.
6. Invert the tubes briefly on absorbent paper towel to drain.
7. Lyophilize the pellets overnight.

Appendix 6

Processing Schedule for K-Plast Resin Embedding

70%	Alcohol	24 hours
80%	Alcohol	24 hours
96%	Alcohol	24 hours
96%	Alcohol	24 hours
100%	Alcohol	24 hours
100%	Alcohol	24 hours
100%	Alcohol	24 hours
100%	Alcohol	24 hours
Toluene		48 hours
Toluene		48 hours
Infiltrate under vacuum in K-Plast resin		4 weeks
Embed in K-Plast resin		

Infiltration Solution:

K-Plast Infiltration solution A	90 ml
K-Plast Infiltration solution B	10 ml

Embedding Solution:

K-Plast Infiltration solution A	90 ml
K-Plast Infiltration solution B	10 ml
K-Plast Initiator	1.0 g

Supplier:

Medis Weber, Floesser Weg 10, D-35418 Buseck, Germany

Appendix 7

Modified Goldner's Trichrome Staining Method

(Modified from Bancroft and Stevens, 1996)

1. Stain sections in Stable Iron Haematoxylin for 20 minutes. Wash in running tap water.
2. Differentiate in acid alcohol for 1 – 2 minutes. Wash and blue in running tap water for10 minutes.
3. Stain sections in Ponceau Fuchsin for 45 minutes. Wash briefly in water and rinse in 1% acetic acid
4. Differentiate sections in Orange G for 13 minutes (time may vary with age of solution). Wash briefly in water and rinse in 1% acetic acid.
5. Stain in 2% Methyl Blue for 10 minutes. Wash well in tap water and rinse in 1% acetic acid. Drain well on paper towel.
6. Rinse sections in 2 changes of 96% alcohol and 2 changes of absolute alcohol.
7. Dehydrate sections in 2 more changes of absolute alcohol of 30 minutes each.
8. Place sections on slide and trim away excess resin with a scalpel blade.
9. Coverslip using Entellan mounting medium.
10. Place weight on top of mounted slides and leave for 48 hours to flatten sections.

Results:

Mineralized bone – blue

Osteoid – orange/red

Nuclei – blue/black