https://dspace.org/

Primordial cysts

Shear, M

1960-07
http://hdl.handle.net/10539/19445
Shear, M. 1960. Primordial cysts. Journal of the Dental Association of South Africa;15(7):211-217

Downloaded from a DSpace repository. https://dspace.org/

lation to these interdigitations could enable the intervening soft tissue to convert any form of pressure through a suture into a tension force on the adjacent bones. Each individual interdigitation in a suture with its connective tissue bridge to the opposing bone may be compared with the root of a tooth and its periodontal membrane attached to the socket. The periodontal membrane converts the direct pressures exerted on the tooth into mild pressure and marked tension forces on the surrounding bone. This alteration of the direction of the force on the bone enables greater forces to be transmitted from bone to bone or as in the case of the periodontal membrane from tooth to bone while still not damaging the intervening soft tissue.

The metabolism of the osteogenic layer of cells surrounding bone will be affected if a constant pressure is applied directly to the endosteum, or periosteum. The mechanism whereby these cells are protected from such direct pressure varies throughout the body. Most periosteal surfaces are protected by varying thicknesses of superimposed muscle, connective tissue and skin. Cartilage which can withstand lengthy periods of pressure, due to its low metabolic rate, is utilized to transmit pressure through joints and growing bones. In the sutures, where a great deal of the growth of the skull occurs, the osteogenic layer of cells is protected by the denticulation of the bones and the arrangement of the connective tissue which consists mostly of the direct pressure into tension on this surface of the bone.

REFERENCES

WHITEHEAD, R. G., and WEIDMANN, S. M. (1959). The Biochem. Journal. Vol. 72, page 667-672.
WEINMANN, J. P., and SICHER, H. (1955). Bone and Bones. 2nd Edition C. V. Mosby Company.

PRIMORDIAL CYSTS

M. SHEAR, B.D.S., H.DIP.DENT. (RAND)

Department of Dentistry, University of the Witwatersrand

ALTHOUGH the primordial cyst is a well recognised entity, not a great deal has been written about it. It is given brief mention by Kronfeld (1949) and Stones (1951). Thoma (1954) states that they are found most frequently in the mandibular third molar region and occur in the young although they may not be discovered for years. Bernier (1955), who refers to them either as primordial or as simple follicular cysts, considers them rare. He found only three cases out of 400 follicular cysts of all types in the files of the Armed Forces Institute of Pathology. Rushton and Cooke (1959) illustrate a specimen by means of a photo-micrograph, but do not describe it in their text.

HISTOGENESIS

The primordial cyst is a developmental abnormality. It is generally believed to arise from the enamel organ prior to the commencement of tooth formation. (Fig. 1). It is thought that the stellate reticulum breaks down to form the cyst cavity; that the internal and external enamel epithelia form the epithelial cyst lining; and that the fibrous cyst wall is formed from the dental follicle. Primordial cysts develop either from an enamel organ of the normal dentition or from a supernumerary bud.

The observations made in this report are based on the study of 22 cysts considered to be primordial in nature.

CLINICAL FINDINGS

The ages of the patients varied from 14 to 67 years, but the cysts occurred most frequently in the second and third decades. Ten cysts of this series of 22 came from patients between the ages of 14 and 27 years (Table 1). Males and females were almost equally affected (Table 2).

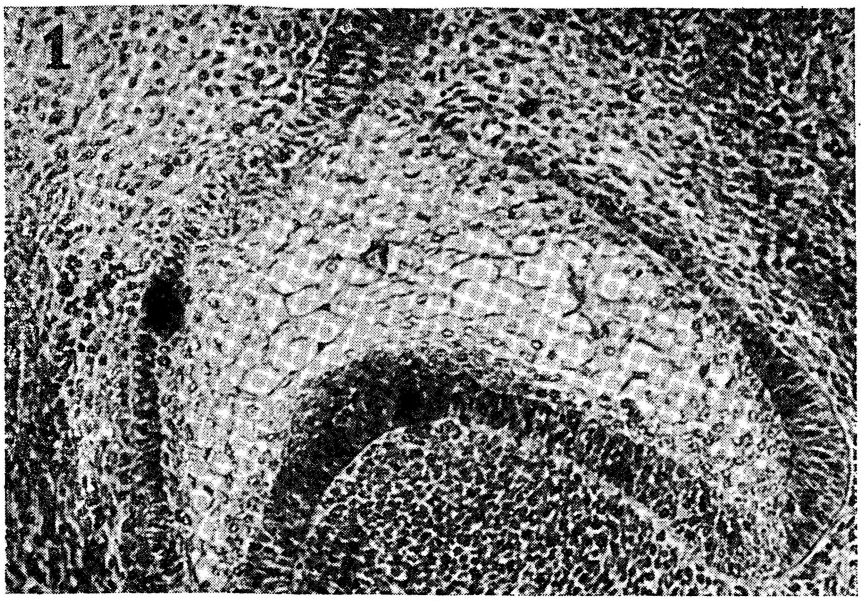

FIG. 1.—The enamel organ at the cap phase of development. Primordial cysts are believed to arise at this stage by breakdown of the stellate reticulum. The epithelial cyst lining is formed by the internal and external enamel epithelia, and the cyst wall by the dental follicle. Mallory x 250.

TABLE 1.—Age distribution of patients with primordial cysts

Age Group	*No.*
0—10	0
11—20	4
21—30	6
31—40	2
41—50	2
51—60	4
61—70	3
Not recorded	1
TOTAL	22

TABLE 2.—Sex distribution of patients with primordial cysts

Sex	*No.*
Male	12
Female	10
TOTAL	22

Nine of the cysts were from the mandibular third molar region, three from the mandibular premolar region, and two extended throughout the whole body of the mandible. Three cysts were from the maxillary third molar region, three from the maxillary premolar region and one from the maxillary canine region. The position of one cyst was not mentioned in the clinical notes (Table 3).

Primordial cysts tend to be symptomless and unless discovered by routine radio-

TABLE 3.—Location of primordial cysts

Position	*No.*
Mandibular — 3rd Molar	9
Mandibular — Premolar	3
Mandibular — Whole body	2
Maxillary — 3rd Molar	3
Maxillary — Premolar	3
Maxillary — Canine	1
Not recorded	1
TOTAL	22



FIG. 2.—The typical epithelial lining of a primordial cyst. H. & E. x 250.

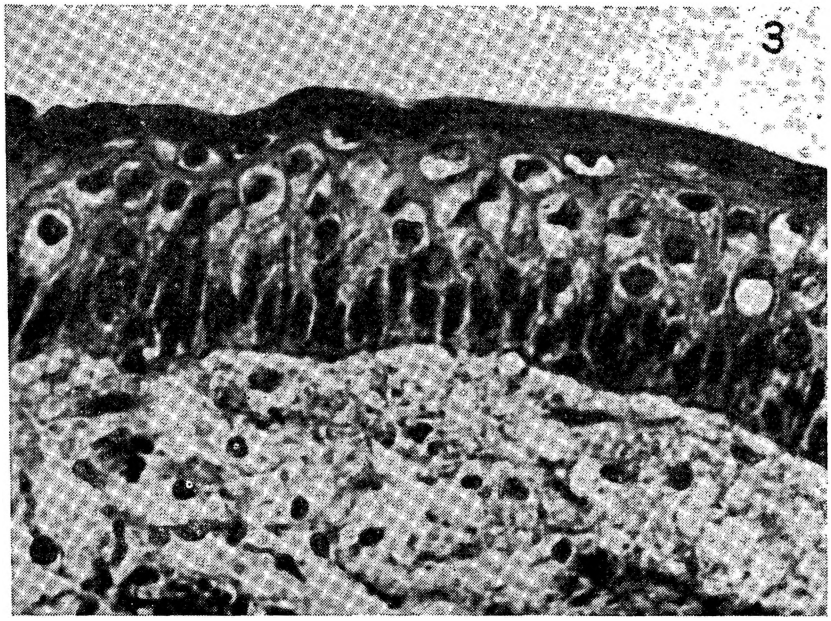

FIG. 3.—Same case as Fig. 2. The typical histological features of a primordial cyst are illustrated. There is a thin, regular parakeratinised stratified squamous epithelial lining with no rete pegs. The basal cells are columnar with pyknotic nuclei, and there is no inflammatory cell infiltration. H. & E. x 650.

FIG. 4.—Another primordial cyst. This photomicrograph illustrates the marked folding of the cyst wall that may occur. Keratin has been formed in this case and may be seen within the cyst cavity. H. & E. x 40.

graphy may grow to an extremely large size. In the mandibular third molar region they may extend to involve the whole of the ramus before bone expansion occurs.

Radiologically, they may be seen at an early stage as small, round radiolucent areas, either in the position of a tooth germ of the normal dentition or in a supernumerary position. When they grow to a large size, they may appear as round or ovoid radiolucent areas producing extensive bone destruction. In the ascending ramus they frequently give a false appearance of multilocularity and may be mistaken for adamantinoma.

HISTOPATHOLOGY

The clinical and radiological appearances are not sufficiently specific to enable a definite diagnosis of primordial cyst to be made. Particularly where teeth are missing, it becomes extremely difficult to differentiate between primordial cyst and residual dental cyst. However, the primordial cysts show a number of histological features which, when considered together, render the diagnosis fairly certain.

The main histological features are:

1. A regular, thin lining of stratified squamous epithelium, with no rete pegs.
2. The presence of a keratinised or parakeratinised layer on the surface of the epithelium. Keratin is frequently present within the cyst cavity.
3. A relative absence of inflammatory cell infiltration.
4. The presence of columnar basal cells with either pyknotic or vesicular nuclei. (Figs. 2 and 3).

In addition, those cysts which grow to a large size are extremely thin-walled, and when removed at operation collapse and become folded. Such specimens appear to be multilocular on histological section. (Fig. 4).

Of the 22 cases included in this report, all were lined by a stratified squamous epithelium on the surface of which was either a layer of keratin, or parakeratin, or both. Keratin was present on the surface of 12 of these linings and parakeratosis was evident in 19. Keratin was found within nine of the cyst cavities.

The epithelium was of regular thickness in 21 cases. In the other, the cyst com-

municated with the nose and was partially lined by respiratory epithelium. In 15 cases there was a straight junction between epithelium and corium. In the remaining seven cases, although there were irregular projections of connective tissue into epithelium in parts, there was no suggestion of any regular rete peg arrangement.

There was complete absence of any inflammatory cell infiltration in the epithelial linings of 16 cysts. In five cases there was a mild infiltration of polymorphonuclear leucocytes and in one case there was a mild lymphocytic infiltration. In four of the six cysts showing inflammatory change, this was confined to areas in which the

TABLE 4.—Histological features in 22 primordial cysts

Case No.	*Keratin*	*Para-keratin*	*Regu-larity*	*Rete Pegs*	*Inflam-mation*	*Basal*	*Cells*	*Keratin in Cavity*
1.	Yes	No	R	No	Nil	Cu	V	Yes
2.	Yes	No	R	No	Nil	C	P	No
3.	Yes	Yes	R	No	Nil	C	P	Yes
4.	Yes	Yes	Varies	Yes	Nil	C	V	No
5.	No	Yes	R	Yes	Nil	C	V	No
6.	No	Yes	R	No	P +	C	P	No
7.	No	Yes	R	No	Nil	C	P	No
8.	Yes	Yes	R	Yes	Nil	C	P	No
9.	No	Yes	R	No	Nil	Cu	V	No
10.	No	Yes	R	Yes	L +	C	V	No
11.	Yes	No	R	No	Nil	C	V	No
12.	No	Yes	R	No	Nil	C	P	No
13.	No	Yes	R	No	P +	C	V	Yes
14.	Yes	Yes	R	No	Nil	C	V	Yes
15.	Yes	Yes	R	No	Nil	C	P	Yes
16.	Yes	Yes	R	Yes	Nil	C	P	Yes
17.	No	Yes	R	No	Nil	C	P	No
18.	Yes	Yes	R	No	Nil	C	P	Yes
19.	Yes	Yes	R	No	Nil	C	V	No
20.	No	Yes	R	Yes	P +	C	V	Yes
21.	Yes	Yes	R	Yes	P +	C	V	No
22.	No	Yes	R	No	P +	Cu	V	Yes
TOTALS:	12	19	21	Absent in 15	Absent in 16	Cu 3 C 19	P 10 V 12	9
	22							

Key: R — Regular.
P — Polymorphonuclear leucocytes.
L — Lymphocytes.
Cu — Cuboidal.
V — Vesicular.
P — Pyknotic.
C — Columnar.

keratin or parakeratin layer was absent. Within the fibrous cyst wall there was usually a mild to moderate chronic inflammatory cell infiltration, but in three cases the chronic inflammation was intense and in one there was a marked acute inflammatory reaction.

There were columnar basal cells in 19 cases. Of these 10 had pyknotic and nine had vesicular nuclei. The basal layers of the remaining three cysts comprised cuboidal cells with vesicular nuclei.

A stratum granulosum was present in four of the cases in which a keratinised layer was present.

TREATMENT

Primordial cysts are simple lesions and their treatment is as for other simple cysts of the jaws. They will not recur after enucleation.

DISCUSSION

In most respects the diagnosis of primordial cysts is of academic importance only. They are of developmental origin and are entirely simple in behaviour. They may grow to a large size, as can other cysts, and can result in extensive bone destruction. However, they are not infiltrative and will not recur if enucleated.

In one respect, nevertheless, it becomes important that the primordial cyst be readily diagnosed. The radiological appearances, particularly of those cases involving the ascending ramus of the mandible, may be confused with those of the adamantinoma. Four of the cases in this series were considered to be adamantinomata prior to histological examination. In view of the fact that the treatment of an adamantinoma differs radically from that of a primordial cyst it is necessary that the two lesions be differentiated.

The histological criteria described above appear to be sufficiently constant to make the diagnosis of primordial cyst fairly certain. The most consistent features are the presence of a thin, well-differentiated stratified squamous epithelium with no rete pegs, having a surface layer of keratin or parakeratin. Dowsett (1933) has reported that a keratin layer on the surface of the epithelial lining of a dental cyst, and Shear (1960) has observed four dental cysts lined by stratified squamous epithelium showing parakeratosis. The histological features of Dowsett's case were not fully described, and this might, in fact, have been a primordial cyst. The fact that the epithelium of dental cysts may occasionally exhibit parakeratosis renders this feature on its own insufficient evidence on which to base the diagnosis of primordial cyst. However, the identification becomes more certain when associated with the other criteria described.

In the great majority of cases there is no inflammatory cell infiltration of the epithelium. Where it is present, it is mild and restricted to those areas in which the surface layer is absent. This indicates that inflammation, when it occurs, is of a secondary nature, and tends to confirm that these lesions are of developmental origin.

The presence of columnar basal cells is a frequent finding within the epithelia of primordial cysts. Particularly when associated with pyknotic nuclei, this is suggestive of greater cellular activity. However, there is no clinical evidence that primordial cysts behave in any way differently from other cysts with flat or cuboidal basal cells. In fact, the high degree of differentiation of the epithelial linings and the thin cyst walls in many cases, indicate that differentiation is keeping apace with cell multiplication and that increase in cyst size is entirely the result of increased tension within the cyst cavity.

It is interesting that the epithelial linings of primordial cysts may keratinise so frequently, whereas this occurs so infrequently in dental cysts. The reason for this probably lies in the respective histogeneses of the two lesions. The dental cyst arises from epithelial cell rests which have previously differentiated, performed their function, and lain impotent until stimulated to proliferation by an inflammatory process. However, the epithelial cells which form the lining of a primordial cyst have not differentiated and apparently retain the potential which they have inherited from their parent tissue, the oral epithelium. They are thus able to differentiate to form keratin.

Case 22 of this series, from 8| region, was diagnosed provisionally as a denti-

gerous cyst, but has been shown on histological grounds to be a primordial cyst. This cyst developed from the dental lamina distal to 8|, and by its growth enveloped this tooth. As a result, it appeared radiographically to be a dentigerous cyst. Other apparent dentigerous cysts may have had similar natural histories and this may account for some of the so-called "extra-follicular dentigerous cysts".

Primordial cysts may occur anywhere in the mouth by extension or additional offshoots of the dental lamina, although they are most frequently found in the mandibular third molar region. It is here, owing to the great bulk in this area, that these cysts are least likely to be discovered until they have reached a large size.

They are most commonly found in the young and probably form early in life. The reason for their being found in older patients is that they may remain symptomless until they reach a large size.

They are not as rare as suggested by Bernier, and probably form about 10 per cent of all epithelial-lined cysts of the jaws.

SUMMARY

1. Primordial cysts develop from the enamel organ prior to tooth formation, by a breakdown of the stellate reticulum. They may replace a tooth of the normal series or form from a supernumerary bud.

2. They form early in life, but may not manifest clinically till much later. Hence they may appear at any age. They affect both sexes equally.

3. They may occur anywhere in the mouth, but are most common in the mandibular third molar region.

4. When they grow to a large size they frequently give a false appearance of multilocularity on X-ray and may be mistaken for adamantinoma.

5. They present certain constant histological features which are diagnostic.

6. They are simple lesions which will not recur after enucleation.

ACKNOWLEDGMENTS

These cases were taken from the files of the Department of Oral Pathology, Institute of Dental Surgery, London. I am most grateful to Mr. Ivor Kramer, head of the Department, for indicating this work to me and for his advice, guidance and encouragement at all times.

I should also like to thank Mrs. A. Vorster, of the University of the Witwatersrand/C.S.I.R. Dental Research Unit, and Mrs. J. Malan, of the Witwatersrand University Dental Hospital, for photographic assistance.

BIBLIOGRAPHY

BERNIER, J. L. (1955). The Management of Oral Disease, 1st ed. The C. V. Mosby Co., St. Louis, p. 472.

DOWSETT, E. B. (1933). "Unique Dental Cyst". Proc. Roy. Soc. Med., **26,** 1562.

KRONFELD, R. (1949). Histopathology of the Teeth and their Surrounding Structures. Henry Kimpton, London.

RUSHTON, M. A., and COOKE, B. E. D. (1959). Oral Histopathology. 1st ed. E. and S. Livingstone Ltd, Edinburgh and London, p. 29.

SHEAR, M. (1960). Unpublished data.

STONES, H. H. (1951). Oral and Dental Diseases. 2nd ed., E. and S. Livingstone Ltd, Edinburgh, p. 796.

THOMA, K. (1954). Oral Pathology. 4th ed., Henry Kimpton, London, p. 806.