

https://dspace.org/

The ultrasonographic determination of the position of the mental foramen in relation to hard and soft tissue landmarks in a selected South African black and Caucasian adult population

Laher, Abdullah

2013

http://hdl.handle.net10539/13716

Downloaded from a DSpace repository. https://dspace.org/

The Ultrasonographic Determination of the Position of the Mental Foramen in Relation to Hard and Soft Tissue Landmarks in a Selected South African Black and Caucasian Adult Population

Abdullah Laher

9902884f

A research report submitted to the Faculty of Health Sciences, University of the Witwatersrand, Johannesburg in partial fulfillment of the requirements for the degree of Master of Medicine (Emergency Medicine)

Johannesburg, 2013

DECLARATION

I, Abdullah Laher, hereby declare that this research report is my own work. It is being submitted in partial fulfillment of the requirements for the degree of Master of Medicine (Emergency Medicine) to the University of the Witwatersrand, Johannesburg. It has not been submitted or presented for any other degree, diploma or professional qualification at this or any other University.

The work presented in this research report was undertaken in the Division of Emergency Medicine, University of the Witwatersrand, Johannesburg.

_____ _____

Abdullah Laher Date

Johannesburg

DEDICATION

This research report is dedicated to:

My Creator, the Greatest, the All Knowing, the Mighty, the Wise, …

ACKNOWLEDGEMENTS

My gratitude is sincerely expressed to the following people:

My parents and my wife Rookeya, for their ongoing support and immense patience.

Dr MD Wells, my supervisor for all his assistance, bright ideas and guidance.

Professor EB Kramer, Head of the Division of Emergency Medicine, University of the Witwatersrand, who was always available for invaluable advice, and whose ethical standards are an example to all.

Dr F Motara, Head of Emergency Department (ED), Charlotte Maxeke Johannesburg Academic Hospital (CMJAH), *Dr Z Mahomed and Dr M Moolla*, specialist Emergency Physicians at CMJAH ED. They were a source of continual support, advice, encouragement, leadership and motivation especially at times when proceedings were at a halt and the going was tough.

Dr T Chirwa, Mr D Garetha and Miss T Gitau, of the Department of Bioethics, University of the Witwatersrand, for their invaluable assistance with the statistical analysis.

Professor WG Evans, Dr M Kaka and Dr E Pitout from the Division of Orthodontics, School of Dentistry, University of the Witwatersrand for their kind assistance and permission for the photographs used in figures1 - 4 & 9 - 10.

Last and not least, to all the participants of the study who, without hesitation, volunteered to be a part of the progress and development of medical science.

ABSTRACT

Background: Ultrasound can accurately locate the mental foramen and may facilitate local anaesthesia to the mental nerve under direct visualization.

Methods: 100 subjects were included. An ultrasound transducer was used to locate the mental foramina. Distances to various landmarks were measured and compared.

Results: All mental foramina were visualised. Overall the most frequent position of the mental foramen in relation to vertical hard tissue landmarks was in line with the long axis of the 2nd premolar tooth on the right and between 1st and 2nd premolar teeth on the left. There were no statistically significant differences between race groups, gender and age categories. The mean hard tissue distances from the mental foramen on the right and left sides respectively were as follows: a) 22.8 mm (SD 2.1 mm) and 22.8 mm (SD 2.0 mm) to the cusp of the related tooth. b) 13.2 mm (SD 1.6 mm) and 13.2 mm (SD 1.6 mm) to the inferior border of the mandible. The mean soft tissue distances from the mental foramen on the right and left sides respectively were as follows: a) 3.4 mm (SD 1.7 mm) and 3.4 mm (SD 1.5 mm) lateral to a vertical line passing through the chelion. b) 20.1 mm (SD 2.6 mm) and 20.1 mm (SD 2.6 mm) distal to a horizontal line bisecting the chelions. c) 15.1 mm (SD 3.4 mm) and 15.0 mm (SD 2.4 mm) to the inferior border of the mandible.

Conclusion: Ultrasound is an effective modality to locate the mental foramen. There is insignificant variation in the position of the mental foramen in relation to

the mandibular premolar teeth between races. Statistically significant differences, for the distance of the mental foramen to various landmarks, were minimal and are not regarded clinically significant.

TABLE OF CONTENTS

DECLARATION ..... **i**

DEDICATION ..... **ii**

ACKNOWLEDGEMENTS ..... **iii**

ABSTRACT ..... **iv**

LIST OF FIGURES ..... **x**

LIST OF TABLES ..... **xii**

GLOSSARY OF TERMS USED ..... **xiv**

LIST OF ABBREVIATIONS ..... **xv**

INTRODUCTION **1**

1.1 Background **1**

1.2 The aim of the study **2**

1.3 Objectives **2**

1.4 The type of study **3**

1.5 Significance of this study **3**

LITERATURE REVIEW **5**

2.1 Anatomy of the mental nerve and foramen **5**

2.2 The significance of the mental foramen **6**

2.3 Population groups previously studied **7**

2.4 Position and relations of the mental foramen **9**

2.4.1 Vertical hard tissue relations 9

2.4.2 Horizontal hard tissue relations 12

2.4.3 Soft tissue relations 13

2.4.4 Other variations with regard to the mental foramen 14

2.5 Modalities used to determine the position of the mental foramen 16

2.5.1 Modalities discussed in the literature 16

2.5.2 Ultrasound 17

2.6 Conclusion 18

MATERIALS AND METHODS 20

3.1 Site of the study 20

3.2 The study population 20

3.3 Inclusion criteria 20

3.4 Exclusion criteria 21

3.5 Sampling 21

3.6 Measuring instruments 22

3.7 Data collection 22

3.8 Illustration of some of the measurements carried out in the study ... 25

3.9 Data analysis 26

3.10 Ethical considerations 27

3.11 Study limitations 28

3.12 Source of Bias 28

RESULTS 29

4.1 Description of sample 29

4.2 Age distribution of cases per race 29

4.3 Overall results of entire study population 30

4.3.1 Vertical hard tissue relations 30

4.3.2 Horizontal hard tissue relations..... 33

4.3.3 Soft tissue relations..... 34

4.4 The impact of race on the position of the mental foramen 37

4.4.1 Vertical hard tissue relations..... 37

4.4.2 Horizontal hard tissue relations..... 39

4.4.3 Soft tissue relations..... 41

4.5 The impact of sex on the position of the mental foramen..... 44

4.5.1 Vertical hard tissue relations..... 44

4.5.2 Horizontal hard tissue relations..... 46

4.5.3 Soft tissue relations..... 48

4.6 The impact of age on the position of the mental foramen..... 50

4.6.1 Vertical hard tissue relations..... 51

4.6.2 Horizontal hard tissue relations..... 53

4.6.3 Soft tissue relations..... 54

4.7 Symmetry 56

4.8 The proportion of patients in whom the mental foramen could not be identified ultrasonographically 56

4.9 Accessory mental foramina..... 56

4.10 The effects of facial hair 57

4.11 Time taken to locate the first mental foramen in each patient..... 57

DISCUSSION..... 59

5.1 Vertical hard tissue relations 59

5.2 Horizontal hard tissue relations..... 62

5.3 Soft tissue relations 64

5.4 Symmetry 66

5.5 The proportion of patients in whom the mental foramen could not be identified ultrasonographically 67

5.6 Accessory mental foramina..... 67

5.7 The effects of facial hair 68

5.8 Time taken to locate the first mental foramen in each patient..... 68

5.9 Clinical and practical implications of study findings..... 68

5.9.1 Vertical hard tissue relations..... 68

5.9.2 Horizontal hard tissue relations..... 69

5.9.3 Soft tissue relations..... 70

5.9.4 Accessory mental foramina..... 71

5.9.5 Does ultrasonography have a role in mental nerve blocks? 71

CONCLUSION 73

REFERENCES..... 75

APPENDICES..... 85

Appendix 1 85

Ethics clearance certificate 85

Appendix 2 86

Patient Data Collection Sheet..... 86

Appendix 3 87

Tables and graph not included under the chapter entitled results 87

LIST OF FIGURES

Figure 1: The extra-oral sensory innervations of the mental nerve (shaded area) *(courtesy: Division of Orthodontics, School of Dentistry, University of the Witwatersrand)* 1

Figure 2: The various possible positions of the mental foramen (black circles) and its (vertical) relationship to the long axis of the mandibular teeth (yellow lines) *(courtesy: Division of Orthodontics, School of Dentistry, University of the Witwatersrand)* 10

Figure 3: Frontal view of the mandible showing horizontal hard tissue measurements *(courtesy: Division of Orthodontics, School of Dentistry, University of the Witwatersrand)* 25

Figure 4: Frontal view of the lower face showing the various soft tissue measurements *(courtesy: Division of Orthodontics, School of Dentistry, University of the Witwatersrand)* 26

Figure 5: Frequencies of the position of the mental foramen in the entire group of subjects in relation to the mandibular premolar teeth on the right side 31

Figure 6: Frequencies of the position of the mental foramen in the entire group of subjects in relation to the mandibular premolar teeth on the left side 32

Figure 7: Means and Standard deviations of horizontal hard tissue relations for the entire group of subjects 33

Figure 8: Means and Standard deviations of soft tissue relations for the entire group of subject 35

Figure 9: Frontal view of the mandible showing the various mean horizontal hard tissue measurements for the entire group of participants *(courtesy: School of Dentistry, University of the Witwatersrand)* 36

Figure 10: Frontal view of the lower face showing the various mean soft tissue measurements for the entire group of participants *(courtesy: School of Dentistry, University of the Witwatersrand)* 36

Figure 11: The impact of race on the position of the mental foramen with regard to vertical hard tissue relations on the right (HVR) side 37

Figure 12: The impact of race on the position of the mental foramen with regard to vertical hard tissue relations on left (HVL) side 38

Figure 13: The impact of sex on the position of the mental foramen with regard to vertical hard tissue relations on the right (HVR) side 44

Figure 14: The impact of sex on the position of the mental foramen with regard to vertical hard tissue relations on the left (HVL) side 45

Figure 15: Two-way scatter plot of the time taken (seconds) to locate the first mental foramen in each of the 100 subjects 58

Figure 16: The impact of age on the position of the mental foramen with regard to vertical hard tissue relations on the right side (HVR) 91

Figure 17: The impact of age on the position of the mental foramen with regard to vertical hard tissue relations on the left side (HVL) 92

LIST OF TABLES

Table 1: Age group frequencies for the various race groups studied 30

Table 2: The impact of race on the position of the mental foramen with regard to horizontal hard tissue relations 40

Table 3: The impact of race on the position of the mental foramen with regard to soft tissue relations 43

Table 4: The impact of sex on the position of the mental foramen with regard to horizontal hard tissue relations 47

Table 5: The impact of sex on the position of the mental foramen with regard to soft tissue relations 49

Table 6: The impact of age on the position of the mental foramen with regard to vertical hard tissue relations on the right side (HVR) 51

Table 7: The impact of age on the position of the mental foramen with regard to vertical hard tissue relations on the left side (HVL) 52

Table 8: The impact of age on the position of the mental foramen with regard to horizontal hard tissue relations 53

Table 9: The impact of age on the position of the mental foramen with regard to soft tissue relations 55

Table 10: The impact of race on the position of the mental foramen with regard to vertical hard tissue relations on the right (HVR) side 87

Table 11: The impact of race on the position of the mental foramen with regard to vertical hard tissue relations on the left (HVL) side 88

Table 12: The impact of sex on the position of the mental foramen with regard to vertical hard tissue relations on the right (HVR) side 89
Table 13: The impact of sex on the position of the mental foramen with regard to vertical hard tissue relations on the left (HVL) side 90

GLOSSARY OF TERMS USED

Caucasian	Refers to Asian and White race groups.
Chelion	Corner of the mouth, where the upper lip meets with the lower lip.
Foramen	An opening, hole or orifice, usually through bone.
Hard tissue relations	Description of structures and measurements with regards to its relationship to the bony mandible and teeth.
Mesial	Term used in dentistry to describe a position in relation to a structure (e.g. a tooth) closer to the midline. Synonymous to the term medial and opposite to the term lateral.
Position 1	Mesial to the 1st premolar.
Position 2	In line with the long axis of the 1st premolar.
Position 3	Between the 1st and 2nd premolars.
Position 4	In line with the long axis of the 2nd premolar.
Position 5	Lateral to the 2nd premolar.
Soft tissue relations	Description of structures and measurements with regards to its relationship to soft tissue structures such as the corner of the mouth and the skin overlying the inferior border of the mandible.

LIST OF ABBREVIATIONS

%L	The proportion of the distance (in percentage) of the position of the mental foramen from the cusp of the related tooth to inferior border of the mandible on the left side i.e. HHCR / HHCR + HHIR).
%R	The proportion of the distance (in percentage) of the position of the mental foramen from the cusp of the related tooth to inferior border of the mandible on the right side (i.e. HHCL / HHCL + HHIL).
CBCT	Conebeam computed tomography.
CMJAH	Charlotte Maxeke Johannesburg Academic Hospital.
ED	Emergency Department.
HHCL	Horizontal hard tissue relation measuring the vertical distance between the cusp of the related tooth and the mental foramen on the left side.
HHCR	Horizontal hard tissue relation measuring the vertical distance between the cusp of the related tooth and the mental foramen on the right side.
HHIL	Horizontal hard tissue relation measuring the vertical distance between the inferior border of the mandible and the mental foramen on the left side.

HHIR	Horizontal hard tissue relation measuring the vertical distance between the inferior border of the mandible and the mental foramen on the right side
HVL	Vertical hard tissue relation on the left side.
HVR	Vertical hard tissue relation on the right side.
MRI	Magnetic resonance imaging.
MSCT	Multi slice computed tomography.
SHChL	Horizontal soft tissue distance from a vertical line passing through the chelion to the mental foramen on the left.
SHChR	Horizontal soft tissue distance from a vertical line passing through the chelion to the mental foramen on the right.
SVChL	Vertical soft tissue distance from a horizontal line bisecting the chelions to the mental foramen on the left.
SVChR	Vertical soft tissue distance from a horizontal line bisecting the chelions to the mental foramen on the right.
SVIL	Vertical soft tissue distance from the inferior border of the mandible to the mental foramen on the left.
SVIR	Vertical soft tissue distance from the inferior border of the mandible to the mental foramen on the right

CHAPTER 1

INTRODUCTION

1.1 Background

The mental foramen is located on either side of the mandible just below the corners of the lips around the region of the root of the second premolar tooth. The mental nerve emerges from the mental foramen and provides sensation to the lower central portion of the face (Haghanifar & Rokouei 2009; Al-Khateeb, Al-Hadi Hamasha & Ababneh 2007).

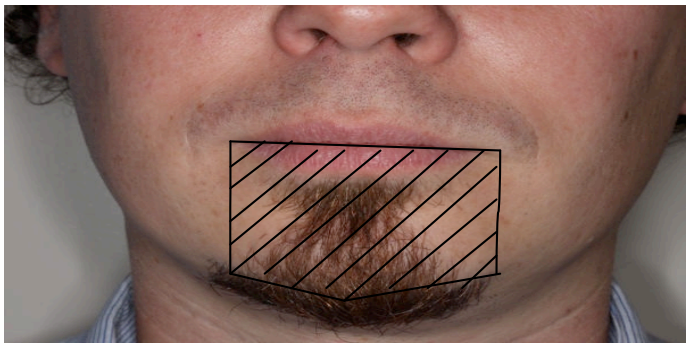

Figure 1: The extra-oral sensory innervations of the mental nerve (shaded area) *(courtesy: Division of Orthodontics, School of Dentistry, University of the Witwatersrand)*

Many patients presenting to the Emergency Department (ED) may require procedures that require anaesthesia to the area supplied by the mental nerve. If the ED practitioner is not familiar with the exact position of the mental nerve, it

may result in higher doses of local anaesthetic agent being used to achieve a mental nerve block, or it may result in a failed block. This may increase the risk of local anaesthetic toxicity. Other potential complications of a mental nerve block include inadvertent intravascular administration of the local anaesthetic agent, haematoma formation and mental nerve injury (Smith & Lung 2006). Therefore, accurately determining the position of the mental foramen would allow for the safer administration of the appropriate dose of local anaesthetic at the correct place. This would decrease complication rates and improve first time success rates.

The use of ultrasonography in the ED for regional nerve block anaesthesia has been shown to be safe, effective, accurate and time saving (Wells 2010).

1.2 The aim of the study

The aim of this study is to ultrasonographically determine the position of the mental foramen in relation to hard and soft tissue landmarks in a selected South African Black and Caucasian adult population. It has not been reported in this population previously.

1.3 Objectives

The objectives of the study were as follows:

1. To determine the range of positions of the mental foramen in the study group, using ultrasound as a modality.
2. To compare the differences in position of the mental foramen between Blacks and Caucasians (Asians and Whites) in the selected group.
3. To compare symmetry of the mental foramen between both sides of the face.
4. To determine the proportion of patients in whom the mental foramen cannot be identified ultrasonographically.

1.4 The type of study

Prospective, Cross-sectional study that included 100 patients

1.5 Significance of this study

With the progress and development of the Specialty of Emergency Medicine in South Africa and around the world, trained ED doctors are able to perform a variety of procedures, thus decreasing the rate of referral to other specialists. This decreases the amount of time that patients need to spend in hospitals, decreases hospital costs and increases patient satisfaction. This may potentially also decrease the rate of patient litigation (Jeanmonod et al. 2012). Amongst the procedures that trained emergency physicians can perform in the emergency department include procedures within the field of supply of the mental nerve.

Therefore it is important for Emergency Medicine practitioners to be knowledgeable regarding the anatomy of the mental nerve and foramen.

No published studies thus far have made use of ultrasound as a modality to determine the position of the mental foramen in a study group, although ultrasound guided mental nerve blocks for local anaesthesia have been well described.

CHAPTER 2

LITERATURE REVIEW

2.1 Anatomy of the mental nerve and foramen

The mandibular canal runs anteriorly along the internal surface of the mandible. It splits into the mental and incisive canals. The incisive canal continues anteriorly to the incisive teeth and the mental canal runs superolaterally to the mental foramen (Chrcanovic, Abreu & Custodio 2011).

The inferior alveolar nerve runs along the mandibular canal. The mental nerve is a terminal branch of the inferior alveoli nerve and emerges from the mental foramen together with the mental vessels. The mental nerve divides into four branches as it emerges from the mental foramen: a) angular branch which innervates the area around the angle of the mouth, b) medial and c) lateral inferior labial branches which innervate the skin of the lower lip, oral mucosa, and gingiva as far posterior as the 1st molar and d) mental branch which innervates the skin of the mental region (Neves et al. 2010).

The mental foramen is situated on the buccal cortex of the mandibular bone and is in close relation to the root of the 2nd mandibular premolar tooth. It moves in a posterior direction during the development of the mandible (Balcioglu et al. 2011). Variation in the position and location of the mental foramen has been

reported within and between various adult population groups (Haghanifar & Rokouei 2009; Al-Khateeb et al. 2007).

2.2 The significance of the mental foramen

A mental nerve block, which is performed in the region of the mental foramen, is a very useful means of achieving local anaesthesia for the purposes of carrying out painful procedures in its field of supply. Mental nerve blocks are frequently carried out by emergency physicians, dentists, oral maxillofacial surgeons and plastic and reconstructive surgeons (Song et al. 2007).

Dentists carry out mental nerve blocks to facilitate the management of periodontal pathology such as tooth extractions, root canal treatments, scaling and polishing and the treatment of gingival disease. Oral maxillofacial surgeons extend the use of mental nerve blocks to more complex intra-oral procedures such as implant surgery, periapical surgery, orthognathic procedures and trauma. Plastic and reconstructive surgeons perform mental nerve blocks for the repair of lower lip and chin lacerations and reconstructive procedures involving the area of supply of the mental nerve (Al-Khateeb et al. 2007; Song et al. 2007; Guo et al. 2009).

With an effective mental nerve block, trained emergency physicians may carry out various procedures in the field of supply of the mental nerve in the ED. These

include suturing of simple and complex lacerations, debridement of wounds, removal of foreign bodies and analgesia for dental pathology (e.g. periodontal abscesses, severe toothache, and tooth avulsions). The knowledge of the accurate determination of the mental nerve is thus paramount to the practice of Emergency Medicine and to doctors working in the ED (Rocco 2010).

Local anaesthesia infiltration and procedures in the vicinity of the mental nerve may cause temporary or permanent sensory dysfunction and paraesthesia due to injury to the mental nerve (Loudon 2011; Smith & Lung 2006). The mental nerve may be injured by direct trauma from the injection needle, nerve compression as a result of inadvertent infiltration into the mental foramen or from a haematoma secondary to vascular injury and from neurotoxicity as a result of chemical damage from the local anaesthetic itself (Meechan 2011). Therefore the accurate determination of the position of the mental foramen is important for all concerned clinicians.

2.3 Population groups previously studied

The position of the mental foramen has been well determined in various population groups by researchers from various disciplines both radiologically (Haghanifar & Rokouei 2009; Al-Khateeb et al. 2007; al Jasser & Nwoku 1998; Kim et al. 2006; Neo 1989; Ngeow & Yuzawati 2003; Olasoji et al. 2004; Pria et al. 2011; Smajilagic & Dilberovic 2004) and on cadaver specimens (Song et al. 2007; al Jasser & Nwoku 1998; Olasoji et al. 2004; Smajilagic & Dilberovic 2004;

Aktekin et al. 2003; Fabian 2007; Gupta 2008; Igbigbi & Lebona 2005; Kqiku et al. 2011; Mbajiorgu et al. 1998; Moiseiwitsch 1998; Mwaniki & Hassanali 1992; Oguz & Bozkir 2002; Phillips, Weller & Kulild 1992; Sankar, Bhanu & Susan 2011; Santini & Alayan 2012; Smith, Surek & Cortez 2010; Yesilyurt et al. 2008).

Population groups studied thus far include Chinese (Guo et al. 2009; Santini & Alayan 2012; Green 1987), Korean (Song et al. 2007; Kim et al. 2006), Indian (Gupta 2008; Sankar et al. 2011; Santini & Alayan 2012; Shankland 1994), Turkish (Aktekin et al. 2003; Oguz & Bozkir 2002; Yesilyurt et al. 2008), North American (Pria et al. 2011; Phillips et al. 1992; Smith et al. 2010; Phillips et al. 1990), Zimbabwean (Mbajiorgu et al. 1998), Malawian (Igbigbi & Lebona 2005), Tanzanian (Fabian 2007), English (Santini & Alayan 2012), Brazilian (Chrcanovic et al. 2011), Saudi Arabian (al Jasser & Nwoku 1998), Jordanian (Al-Khateeb et al. 2007), Iranian (Haghanifar & Rokouei 2009), Austrian (Kqiku et al. 2011), Kenyan (Mwaniki & Hassanali 1992), Nigerian (Olasoji et al. 2004), Malay (Neo 1989) and Bosnian (Smajilagic & Dilberovic 2004).

Most published studies were carried out by oral maxillofacial and dental surgeons (Al-Khateeb et al. 2007; Chrcanovic et al. 2011, al Jasser & Nwoku 1998; Neo 1989; Ngeow & Yuzawati 2003; Olasoji et al. 2004; Pria et al. 2011; Smajilagic & Dilberovic 2004; Moiseiwitsch 1998; Mwaniki & Hassanali 1992; Phillips et al. 1992; Santini & Alayan 2012). Other studies were conducted by anatomists (Song et al. 2007; Aktekin et al. 2003; Fabian 2007; Gupta 2008; Igbigbi &

Lebona 2005; Mbajiorgu et al. 1998; Oguz, Bozkir 2002; Smith et al. 2010; Yesilyurt et al. 2008), plastic surgeons (Song et al. 2007; Guo et al. 2009) and radiologists (Haghanifar & Rokouei 2009; Kim et al. 2006; Olasoji et al. 2004).

2.4 Position and relations of the mental foramen

The position of the mental foramen has been determined in relation to hard tissue landmarks (Al-Khateeb et al. 2007; Kim et al. 2006; Ngeow & Yuzawati 2003; Olasoji et al. 2004; Fabian 2007; Igbigbi & Lebona 2005; Kqiku et al. 2011; Mbajiorgu et al. 1998; Oguz, Bozkir 2002; Yesilyurt et al. 2008) and soft tissue landmarks (Song et al. 2007; Guo et al. 2009) or both (Guo et al. 2009).

2.4.1 Vertical hard tissue relations

When using vertical hard tissue landmarks, the position of the mental foramen has been described in relation to the long axis of the mandibular premolars. That is mesial to the 1st premolar (position 1), in line with the long axis of the 1st premolar (position 2), between the 1st and 2nd premolars (position 3), in line with the long axis of the 2nd premolar (position 4) and lateral to the 2nd premolar (position 5) (Haghanifar & Rokouei 2009; Al-Khateeb et al. 2007; Olasoji et al. 2004; Fabian 2007; Igbigbi & Lebona 2005; Kqiku et al. 2011; Mbajiorgu et al. 1998; Yesilyurt et al. 2008).

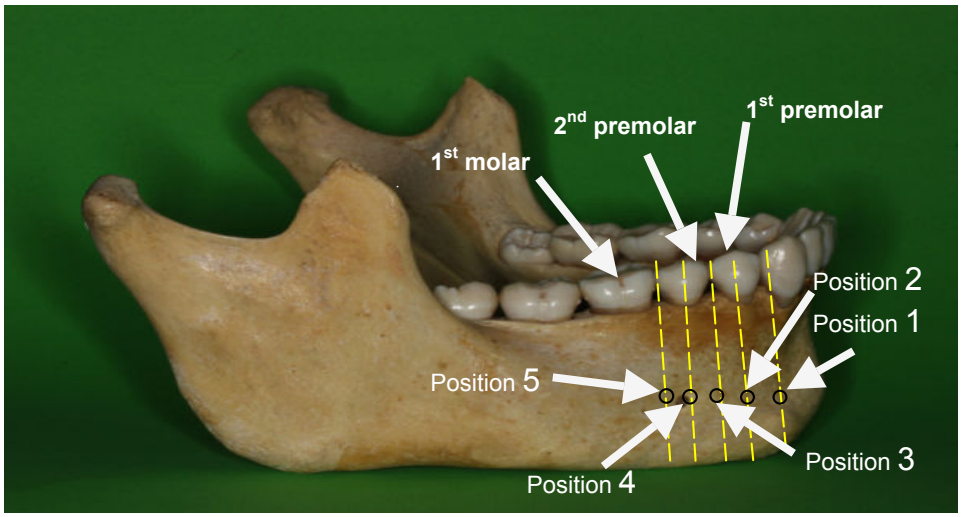

Position 1 - mesial to 1st premolar. **Position 2** - in line with the long axis of the 1st premolar. **Position 3** - between 1st and 2nd premolars. **Position 4** - in line with the long axis of the 2nd premolar. **Position 5** - lateral to 2nd premolar.

Figure 2: The various possible positions of the mental foramen (black circles) and its (vertical) relationship to the long axis of the mandibular teeth (yellow lines) *(courtesy: Division of Orthodontics, School of Dentistry, University of the Witwatersrand)*

In the above mandible, the mental foramen is situated at position 4.

There is variation in the position of the mental foramen reported in the literature amongst different population groups. The most common position of the mental foramen in relation to hard tissue landmarks was found to be either in line with the long axis of the 2nd premolar tooth or between the 1st and 2nd premolar teeth. It is commonly reported that in Caucasian and Middle Eastern populations, the most common position of the mental foramen is between the 1st and 2nd premolars, whereas in Black and Mongoloid populations the mental foramen is positioned more posteriorly (Al-Khateeb et al. 2007; Kim et al. 2006; Sankar et al.

2011; Santini & Alayan 2012). In Saudi Arabian, Tanzanian, Chinese, Malawian, Korean, Zimbabwean, Kenyan, Malay, and Bosnian populations the most common position was recorded as below the 2nd mandibular premolar tooth with frequencies of between 45% and 75.3% at that position (Guo et al. 2009; al Jasser & Nwoku 1998; Kim et al. 2006; Neo 1989; Smajilagic & Dilberovic 2004; Fabian 2007; Igbigbi & Lebona 2005; Mbajiorgu et al. 1998; Mwaniki & Hassanali 1992). In Jordanian, Brazilian, Iranian, Austrian, North American, Indian and European populations, the most common position was recorded as between the 1st and 2ndmandibular premolar teeth with frequencies of between 33% and 73.2% in that position (Haghanifar & Rokouei 2009; Al-Khateeb et al. 2007; Chrcanovic et al. 2011; Kqiku et al. 2011; Moiseiwitsch 1998; Sankar et al. 2011). Studies conducted in two Turkish (Oguz & Bozkir 2002; Yesilyurt et al. 2008) and two Indian (Neo 1989; Santini & Alayan 2012) population groups found the most common position to be in line with the long axis of the 2nd madibular premolar tooth, whereas another Turkish study (Aktekin et al. 2003) and an Indian study (Sankar et al. 2011) found that the most common position to be between the 1st and 2nd premolars. The mental foramen lies either mesial to the first premolar or lateral to the first molar in only 1–2% of cases (Shah, Vaze & Kinhal 2010).

Some researchers measured the distance from the symphysis menti to the mental foramen (Smajilagic & Dilberovic 2004; Gupta 2008; Santini & Alayan 2012) and from the mental foramen to the posterior border of the ramus of the mandible (Smajilagic & Dilberovic 2004; Sankar et al. 2011; Smith et al. 2010) and compared it to studies carried out on other population groups. This was not

considered in this study as it is technically challenging to accurately locate the symphysis menti on ultrasound, and also the distance from the mental foramen to the posterior border of the ramus of mandible cannot be included onto a single ultrasound field due to the short length of standard linear ultrasound probes.

2.4.2 Horizontal hard tissue relations

Some researchers measured the vertical distance between the buccal cusp tip of the concerned tooth and the mental foramen. Mean distances of 23.34 mm and 25.69 mm have been recorded in Chinese and Korean populations respectively (Guo et al. 2009; Kim et al. 2006). Other researchers measured the vertical distance between the alveolar margin and mental foramen. Average distances of between 13.7 mm and 16.4 mm have been reported in various population groups (Smajilagic & Dilberovic 2004; Igbigbi & Lebona 2005; Mbajiorgu et al. 1998; Sankar et al. 2011). The mean vertical distance between the inferior border of the mandible and the mental foramen has been reported as between 12.9 mm and 16.5 mm in various studies (Guo et al. 2009; Kim et al. 2006; Smajilagic & Dilberovic 2004; Gupta 2008; Igbigbi & Lebona 2005; Mbajiorgu et al. 1998; Oguz & Bozkir 2002; Sankar et al. 2011; Santini & Alayan 2012; Smith et al. 2010).

Igbigbi et al and Mbajiorgu et al found the mean position of the mental foramen in Malawian and Zimbabwean populations to be just below the midpoint of the vertical distance between the alveolar margin and the inferior border of the

mandible (Igbigbi & Lebona 2005; Mbajiorgu et al. 1998). Smajilagic and Diberovic investigated the relationship between the mental foramen, the alveolar crest and the inferior border of the mandible in cadavers and on panoramic X rays. They found the mental foramen to be at 50% of the distance between the alveolar crest and the inferior border of the mandible on cadavers and slightly below this point on panoramic X rays (Smajilagic & Dilberovic 2004).

An American study located the mental foramen an average of approximately 60% of the distance between the buccal cusp tip and the inferior border of the mandible (Phillips et al. 1990). A Korean study compared dry skulls with panoramic radiographs and concluded that the average distance ratio from the buccal cusp tip to the inferior border of the mandible to be 60.6% on dry skulls and 63.6% on panoramic radiographs (Kim et al. 2006).

2.4.3 Soft tissue relations

The chelion (corner of the mouth) has been used as a soft tissue landmark to determine the vertical and horizontal distance from the mental foramen (Song et al. 2007; Guo et al. 2009). Guo et al indirectly measured the horizontal and vertical distances from the chelion to the mental foramen on digitalized photographic images. Mean distances recorded were 23.38 mm (SD, 2.00 mm) inferior and 3.55 mm (SD, 1.70 mm) medial to the chelion in the front view, and 23.59 mm (SD, 2.11 mm) inferior and 7.19 mm (SD, 3.03 mm) lateral to the chelion on the lateral view (Guo et al. 2009). Song et al also conducted their

measurements indirectly on digitalized photographs and located the average measurement of the mental foramen as 20.4 mm (SD, 3.9 mm) inferior and 3.3 mm (SD 2.9 mm) medial to the chelions on frontal views (Song et al. 2007). Facial expressions and other conditions at the time of death (before rigor mortis) may have affected these measurements (e.g. facial soft tissues may assume different positions at time of death which may become fixed). This has not been mentioned or commented on in the literature.

2.4.4 Other variations with regard to the mental foramen

The position of the mental foramen has also been compared bilaterally for symmetry. Most studies looked at anterior-posterior asymmetry and reported frequencies of asymmetry of 14.3%, 20%, 32% and 33% (Haghanifar & Rokouei 2009; Al-Khateeb et al. 2007; al Jasser & Nwoku 1998; Ngeow & Yuzawati 2003; Fabian 2007). A Tanzanian study involving 100 cadavers reported that 78% of mental foramina were asymmetrical (Fabian 2007). Al-Khateeb also looked at superior-inferior asymmetry and found an incidence of 14% (Al-Khateeb et al. 2007).

The incidence of accessory mental foramina has been variously reported as 3%, 4.5%, 5%, 6.5%, 6.6%, 7% 8.9% and 10% (Al-Khateeb et al. 2007; Guo et al. 2009; Fabian 2007; Mwaniki & Hassanali 1992; Santini & Alayan 2012; Kalender, Orhan & Aksoy 2011; Naitoh et al. 2009; Ritter et al. 2009; Kulkarni et al. 2011). Naitoh et al concluded that the mean distance between the mental and accessory mental foramina was 6.3 mm (SD, 1.5 mm) (Naitoh et al. 2009). The

incidence of triple mental foramina has been reported as 1.2% (Ramadhan, Messo & Hirsch 2010). Awareness of the presence of accessory mental foramina is important to avoid mental nerve damage during surgical procedures and local anaesthetic infiltration (Kalender et al. 2011).

Chrcanovic et al reported a change in the position of the mental foramen with age and loss of teeth. With loss of teeth and resultant bone resorption, the alveolar crest shifts downwards and closer to the mental foramen (Chrcanovic et al. 2011). Soikkonen et al reported that the mental foramen was situated on average of 3.8 mm lower in edentulous jaws than in dentulous jaws (Soikkonen et al. 1995) with respect to a superior reference point (the alveolar crest). A study in Hong Kong found there to be a significant correlation between tooth wear and position of the mental foramen (Green & Darvell 1988).

A study conducted in Jordan (Al-Khateeb et al. 2007) discovered that the position of the mental foramen was found to be more posterior and inferior with advancement in age. This is probably due to a combination of bone resorption and dental degeneration as a consequence of aging.

2.5 Modalities used to determine the position of the mental foramen

2.5.1 Modalities discussed in the literature

Thus far panoramic radiographs, periapical radiographs, magnetic resonance imaging (MRI), conebeam computed tomography (CBCT) and multi slice computed tomography (MSCT) has been used for clinical purposes to determine the position of the mental foramina (Ritter et al. 2009; Chau 2012; da Silva Ramos Fernandes, Capelozza & Rubira-Bullen 2011; Greenstein & Tarnow 2006; Jalili et al. 2011; Liang et al. 2010; Parnia et al. 2011; Shibli et al. 2012; Yasar, Yesilova & Apaydin 2011).

Periapical and panoramic radiographic techniques have their limitations. The determination of the mental foramen with these modalities is not always possible and linear measurements need to be corrected as a result of radiographic distortions. Jacobs et al (Jacobs et al. 2004) reported detection of the mental foramen in 94% of panoramic radiographs, but only 49% were clearly visible, while the mental foramen was only visualized in 84.2% of cases in an Iranian study (Jalili et al. 2011). Shibli et al found there to be good to moderate inter-examiner agreement for the detection of the mental foramen on panoramic radiographs (Shibli et al. 2012). The effects of compression on image quality of digital panoramic radiographs were recently assessed. Size reduction of digital radiographic images through compression has been shown to have definite effects on image quality and the detection of the mental foramen and other

important anatomical structures (Yasar et al. 2011). A study compared the position of the mental foramen in patients intra-operatively with the position as determined radiologically by panoramic X-rays. A discrepancy in positioning was found. This is due to the fact that panoramic X-rays do not take the curvatures and angles of the mandible into account (Kim et al. 2006; Phillips et al. 1992, Phillips et al. 1990). Phillips et al found there to be a 23% increase in size and a distal shift of the mental foramen on panoramic radiographs (Phillips et al. 1992).

With periapical views, the yield is even lower. A study conducted in 1976 by Fishel et al, using periapical films reported that the mental foramen was detected in only 46.8% of cases (Fishel et al. 1976).

CBCT image detection of the mental foramen was found to be superior and also used lower radiation doses when compared with MSCT imaging (Liang et al. 2010). In a study conducted in Germany, advancing age and dental restorative surgery had a negative impact on CBCT determination of the mental foramen and other related anatomic structures (Ritter et al. 2009). Chau et al compared MRI images with CBCT images and found MRI imaging to be more accurate in determining the position of the mental foramen and nerve (Chau 2012).

2.5.2 Ultrasound

Ultrasonography, regarded as the 21st century stethoscope of the ED (Coskun 2011), is a cost effective, time saving, non-invasive, safe modality with no risk of

radiation exposure. It can be used as a diagnostic and interventional tool. It has many uses in the ED including regional nerve block anaesthesia (Wells 2010). Traxler et al in 1992 used ultrasound to determine the alveolar ridge width for purposes of dental implants. He also commented that ultrasound provided accurate information about the position of the mental foramen, as a secondary finding (Traxler et al. 1992).

Another potential benefit of the use of ultrasonography is that the mental nerve may be blocked under direct vision, using real time ultrasound guidance as a tool. This would increase first time success rates, decrease failure rates and decrease the chances of neurological injury in trained and experienced hands. One pitfall with the use of ultrasonography is that it is operator dependant. Therefore operator training and experience would have an impact on accuracy, interpretation and reliability (Wells 2010).

2.6 Conclusion

Most studies have been carried out on specific population groups in various countries. South Africa has a multiracial population with diverse backgrounds. The position of the mental foramen has not been studied in the South African population thus far.

The purpose of this study is to ultrasonographically determine the position of the mental foramen in relation to hard and soft tissue landmarks in a selected South African Black and Caucasian adult population. It has not been previously reported in this population.

CHAPTER 3

MATERIALS AND METHODS

3.1 Site of the study

The study was conducted in the non-urgent, stable patient, waiting area of the Charlotte Maxeke Johannesburg Academic Hospital's (CMJAH) ED, Area 167.

3.2 The study population

The study population consisted of Adult Black and Caucasian (White and Asian) patients presenting to the CMJAH ED. These patients had passed through the hospital's triage system and did not require urgent or emergent treatment. Patients did not necessarily present with conditions requiring a mental nerve block.

3.3 Inclusion criteria

1. Adult Black and Caucasian patients older than 18 years that presented to the ED.
2. The above patients had to have been triaged as non-urgent.
3. All patients had to have given written consent prior to participating in the study.

3.4 Exclusion criteria

1. Patients who had undergone previous mandibular surgery.
2. Patients who had mandibular teeth missing between the right and left lower 1st molars.
3. Facial distortion (congenital or acquired).
4. Patients who spoke a language for which no translator was available.

3.5 Sampling

This convenience sample made use of 100 patients. The following parameters were used in determining the sample size:

Significance level: 5%

Power: 80%

Difference in population means: 2.5 mm

Estimated standard deviation: 3.5 mm

(For vertical and horizontal measurements)

The data was entered into the Stata statistical package and a subject number of 42, for each group, was generated. 100 subjects were enrolled in the study (50 Black subjects and 50 Caucasian subjects).

3.6 Measuring instruments

A Toshiba diagnostic ultrasound system (model SSA-510A, serial no. P3C06X5875), belonging to the emergency department was used. The mental foramina of both sides of the face were located using a high frequency (8MHz) transducer (PLF.805ST) with the machine set on a “small parts” preset mode. A non-permanent body marker was then used to mark the position of the mental foramen in order to measure soft tissue relations. The ultrasound machine measured hard tissue measurements. Soft tissue measurements were gently measured using calipers and a ruler. All measurements were rounded off to one decimal place.

The measurements obtained were entered into a data collection sheet (see appendix 2, p. 86). Asymmetry, the presence of facial hair, the time taken to find the 1st mental foramen in each patient and any difficulties encountered were documented on the data collection sheet. Other information documented included age, gender, race, presence of primary teeth and previous mandibular surgery.

3.7 Data collection

Data was collected by the researcher who is level 1 emergency ultrasound accredited.

The following procedures were followed:

- Patients were selected randomly and in no particular order, at a time convenient to the researcher.
- The last patient waiting in the queue was approached first and so on, so as not to increase patient waiting times.
- Potential participants were given an information leaflet.
- Bearded patients were told that they would not be required to shave or trim their beard. They would follow the same procedure as the other subjects.
- Individuals who volunteered to participate in the study were asked to follow the researcher to a private cubicle.
- Participants were then questioned regarding exclusion criteria.
- Individuals that were not eligible to participate were thanked and taken back to their place in the queue.
- Eligible volunteers, who agreed to participate, were requested to sign informed consent.
- They were then allocated a participant number to maintain anonymity.
- Demographic details were thereafter entered on the data collection sheets.
- The volunteer was then requested to lie supine.
- Sonar gel was applied to the ultrasound transducer once the machine was in running mode.

- The transducer, with the marker pointing to the participant's right, was gently applied above the inferior border of the mandible and just lateral to the mentum.
- Once the mental foramen was localized the image was frozen on the monitor screen. The position in relation to vertical hard tissue landmarks was determined and documented in the data collection sheet.
- The probe was then rotated 90 degrees with the marker facing cranially and the monitor in unfreeze mode.
- The appropriate image was once again frozen and a) the cusp to mental foramen and b) the inferior border of the mandible to mental foramen distances were measured and documented.
- The mental foramen was once again found under ultrasound guidance and its position marked off on the skin with a body marker. A caliper and ruler was used to measure horizontal and vertical distances to the chelion and the vertical distance to the inferior border of the mandible. Participants were asked to maintain a neutral facial expression during measurements.
- The above procedure was repeated on the opposite side of the face.
- Once the measurements were documented, any gel and marks on the volunteer was gently cleaned off and the volunteer thanked.
- All volunteers, as far as possible, maintained their position in the queue waiting to see their clinician.
- Any difficulties experienced during the investigation were documented.

3.8 Illustration of some of the measurements carried out in the study

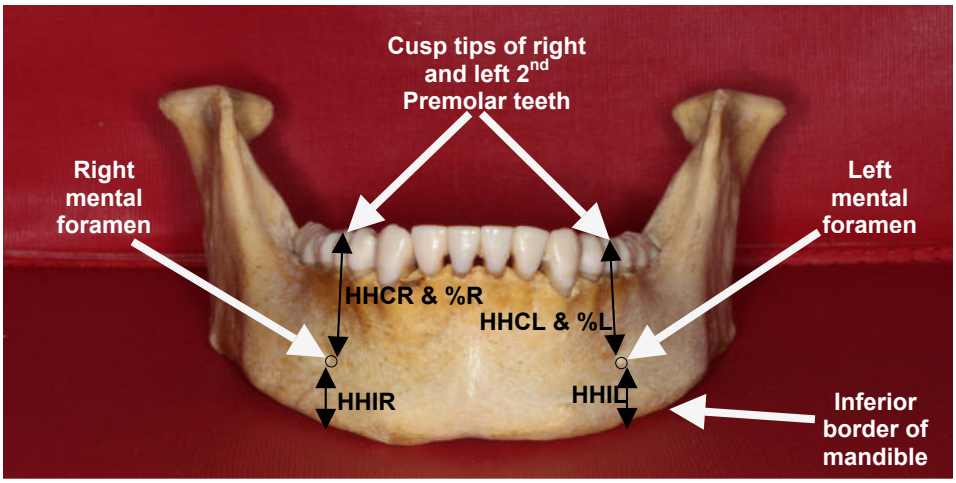

HHCR - horizontal hard tissue relation measuring the vertical distance between the cusp of the concerned tooth and the mental foramen on the right side
HHIR - horizontal hard tissue relation measuring the vertical distance between the inferior border of the mandible and the mental foramen on the right side
%R - the proportion of the distance (in percentage) of the position of the mental foramen from the cusp of the related tooth to the inferior border of the mandible on the right side (i.e. HHCR / HHCR + HHIR).
HHCL - horizontal hard tissue relation measuring the vertical distance between the cusp of the concerned tooth and the mental foramen on the left side.
HHIL - horizontal hard tissue relation measuring the vertical distance between the inferior border of the mandible and the mental foramen on the left side.
%L - the proportion of the distance (in percentage) of the position of the mental foramen from the cusp of the related tooth to the inferior border of the mandible on the left side (i.e. HHCL / HHCL + HHIL).

Figure 3: Frontal view of the mandible showing horizontal hard tissue measurements *(courtesy: Division of Orthodontics, School of Dentistry, University of the Witwatersrand)*

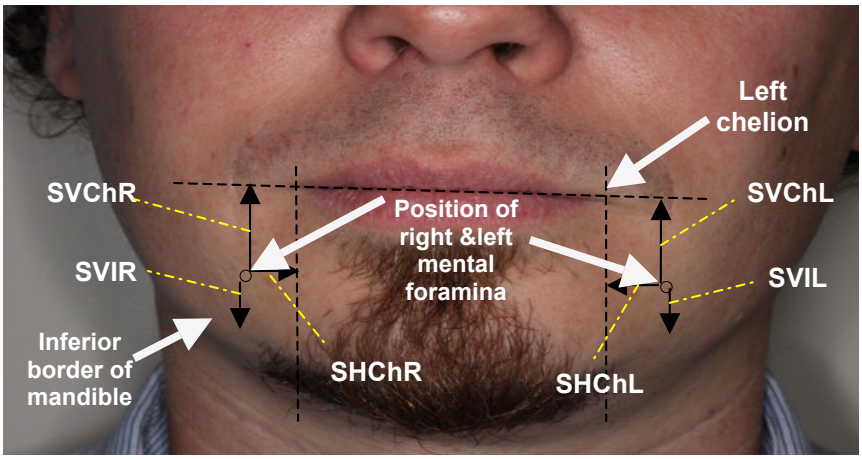

Chelion – corner of the mouth where the upper and lower lips meet
SHChR - horizontal soft tissue distance from a vertical line passing through the chelion to the mental foramen on the right
SHChL - horizontal soft tissue distance from a vertical line passing through the chelion to the mental foramen on the left
SVChR - vertical soft tissue distance from a horizontal line bisecting the chelions to the mental foramen on the right
SVChL- vertical soft tissue distance from a horizontal line bisecting the chelions to the mental foramen on the left
SVIR - vertical soft tissue distance from the inferior border of the mandible to the mental foramen on the right
SVIL - vertical soft tissue distance from the inferior border of the mandible to the mental foramen on the left

Figure 4: Frontal view of the lower face showing the various soft tissue measurements *(courtesy: Division of Orthodontics, School of Dentistry, University of the Witwatersrand)*

3.9 Data analysis

All data was captured from the data collection forms and entered into an electronic spreadsheet (Microsoft Excel, Microsoft Office 2007, Microsoft Corporation). Data was analyzed using Stata 12. Statisticians employed at the

University of the Witwatersrand were approached for assistance. Each volunteer was placed in to an age category: a) 18-30 yrs, b) 31-40 yrs, c) 41-50 yrs, d) 51-60 yrs, e) 61-70 yrs. Means and standard deviations were calculated for continuous variables (measurements obtained). Categorical variables such as sex, race, age category (above) and position (i.e. positions 1 – 5) were described by the use of percentage frequency distribution tables.

Variations in position (vertical and horizontal) were plotted on distribution graphs. Cross tabulation and graphs were used to compare age, gender, race and symmetry with the position of the mental foramen.

The means of measurements obtained (continuous variable) were compared for age group, sex and race (categorical variables) using Analysis of Variance (ANOVA). The Fisher's exact test was used to assess for relationships between two categorical variables (positions 1 – 5 versus age group, gender, and race). The chi-squared test was not used, as there were less than 5 observations in certain cells.

3.10 Ethical considerations

Patients were enrolled in the study only once written informed consent was obtained. Patient confidentiality was respected at all times. Data collection sheets did not include personal data. Only relevant demographic data was included. The

information gathered was protected by a coded numbering system, which was stored in a password-protected computer that was only accessible by the researcher. Permission to conduct the study was obtained from the head of department (H.O.D) of the CMJAH ED and the hospital management. Clearance was obtained from the Human Research Ethics Committee of the University of the Witwatersrand; certificate M110920 (Appendix 1, p. 85).

3.11 Study limitations

Some patients had difficulty communicating in English. A member of staff who was able to understand that particular language was kindly requested to translate. If a translator was not available for a particular language, those patients were excluded from the study. Ultrasonography is operator dependant and a single investigator conducted all measurements. However the investigator was level 1 emergency ultrasound accredited.

3.12 Source of Bias

South Africa has a multiracial population with marked genetic variation and many interracial marriages. It was on occasion difficult to accurately classify subject race group on the data collection sheet.

CHAPTER 4

RESULTS

4.1 Description of sample

A total of 100 patients were selected to participate in the study. This included 50 Black (27 males and 23 females) and 50 Caucasian (23 males and 27 females) subjects. The Caucasians were further subdivided into 25 Asian (13 males and 12 females) and 25 White (10 males and 15 females) subjects. The overall sex distribution was equal and comprised 50 males and 50 females.

4.2 Age distribution of cases per race

The analysis of each race group according to age is shown in table 1. The overall mean age of the study population was 35.7 years. Most of the subjects were aged between 18 and 30 years (40 subjects). The 31-40 year age group formed the second largest overall group (29 subjects). Thirty-one subjects were older than 40 years of age and only two subjects were older than 60 years. The reason being that, with advancement in age, the incidences of missing teeth between the right and left mandibular 1st molars are higher. Therefore many potential subjects that were approached to participate in the study were excluded as they had missing teeth between the right and left 1st mandibular molars.

Table 1: Age group frequencies for the various race groups studied

Race	Age Group					
	(18-30yrs)	(31-40 yrs)	(41-50 yrs)	(51-60 yrs)	(61-70 yrs)	Total
Black	18	20	8	3	1	50
Asian	13	6	3	3	0	25
White	9	3	5	7	1	25
Total	40	29	16	13	2	100
Mean age	24.3 yrs	36.7 yrs	46.7 yrs	56.2 yrs	63.0 yrs	35.7 yrs

4.3 Overall results of entire study population

4.3.1 Vertical hard tissue relations (Figure 5 & 6)

Overall the most frequent position of the mental foramen in relation to vertical hard tissue landmarks was at position 4 on the right (44%) and position 3 on the left (44%). They were closely followed by position 3 on the right (41%) and position 4 on the left (43%). In 4% or less of subjects, the mental foramen was located at position 1 (mesial to the 1st premolar) and position 5 (lateral to the 2nd premolar) on either side.

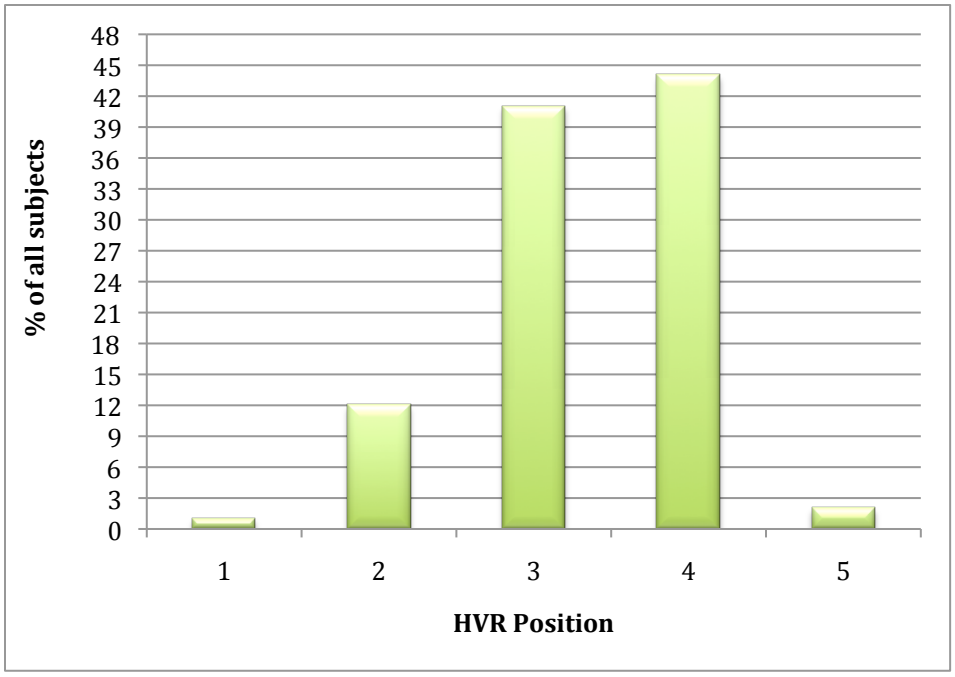

HVR - vertical hard tissue relation on the right side. **Position 1** - mesial to 1st premolar. **Position 2** - in line with the long axis of the 1st premolar. **Position 3** - between 1st and 2nd premolars. **Position 4** - in line with the long axis of the 2nd premolar. **Position 5** - lateral to 2nd premolar.

Figure 5: Frequencies of the position of the mental foramen in the entire group of subjects in relation to the mandibular premolar teeth on the right side

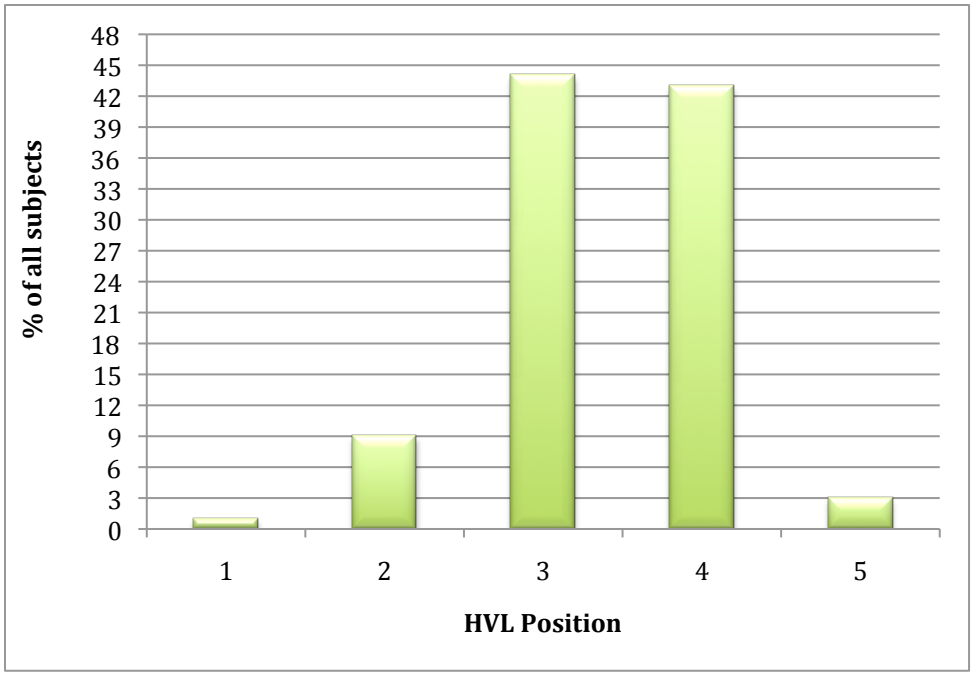

HVL - vertical hard tissue relation on the left side. **Position 1** - mesial to 1st premolar. **Position 2** - in line with the long axis of the 1st premolar. **Position 3** - between 1st and 2nd premolars. **Position 4** - in line with the long axis of the 2nd premolar. **Position 5** - lateral to 2nd premolar.

Figure 6: Frequencies of the position of the mental foramen in the entire group of subjects in relation to the mandibular premolar teeth on the left side

4.3.2 Horizontal hard tissue relations (Figure 7)

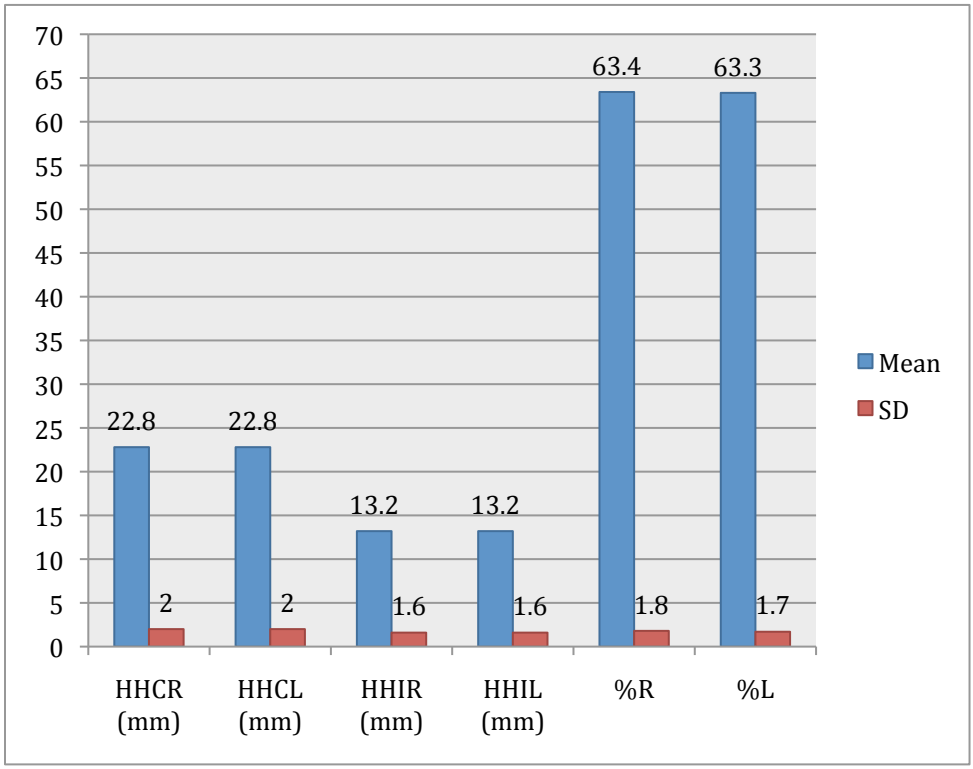

HHCR - horizontal hard tissue relation measuring the vertical distance between the cusp of the related tooth and the mental foramen on the right side. **HHCL** - horizontal hard tissue relation measuring the vertical distance between the cusp of the related tooth and the mental foramen on the left side. **HHIR** - horizontal hard tissue relation measuring the vertical distance between the inferior border of the mandible and the mental foramen on the right side. **HHIL** - horizontal hard tissue relation measuring the vertical distance between the inferior border of the mandible and the mental foramen on the left side. **%R** - the proportion of the distance (in percentage) of the position of the mental foramen from the cusp of the related tooth to the inferior border of the mandible on the right side (i.e. HHCR / HHCR + HHIR). **%L** - the proportion of the distance (in percentage) of the position of the mental foramen from the cusp of the related tooth to the inferior border of the mandible on the left side (i.e. HHCL / HHCL + HHIL).

Figure 7: Means and Standard deviations of horizontal hard tissue relations for the entire group of subjects

Mean measurements of the entire group were as follows: The mean distance from the cusp of the related tooth to the mental foramen was 22.8 mm (SD 2.04 mm) on the right (HHCR) and 22.8 mm (SD 2.0 mm) on the left (HHCL). The

mean distance from the inferior border of the mandible to the mental foramen was 13.2 mm (SD 1.6 mm) on the right (HHIR) and 13.2 mm (SD 1.6 mm) on the left (HHIL). The mean position of the mental foramen was found to be 63.4% (SD 1.8%) of the distance from the cusp of the related tooth to the inferior border of the mandible on the right (%R) and 63.34% (SD 1.7%) on the left (%L).

4.3.3 Soft tissue relations (Figure 8)

Mean measurements for the entire group were as follows: The mean horizontal distance from a vertical line passing through the chelion to the mental foramen was 3.4 mm (SD 1.7 mm) lateral to the line on the right (SHChR) and 3.4 mm (SD 1.5 mm) lateral to the line on the left (SHChL). The mean vertical distance from a horizontal line bisecting the chelions to the mental foramen was 20.1 mm (SD 2.6 mm) below the line on the right (SVChR) and 20.1mm (SD 2.7 mm) below the line on the left (SVChL). The mean vertical distance from the mental foramen to the inferior border of the mandible was 15.1 mm (SD 2.4 mm) on the right (SVIR) and 15.0 mm (SD 2.4 mm) on the left (SVIL). The mean distances were longer with the soft tissue measurements (SVIR & SVIL) when compared to the hard tissue measurements (HHIR & HHIL). This is due to the fact that the soft tissue measurements include the skin thickness below the inferior border of the mandible.

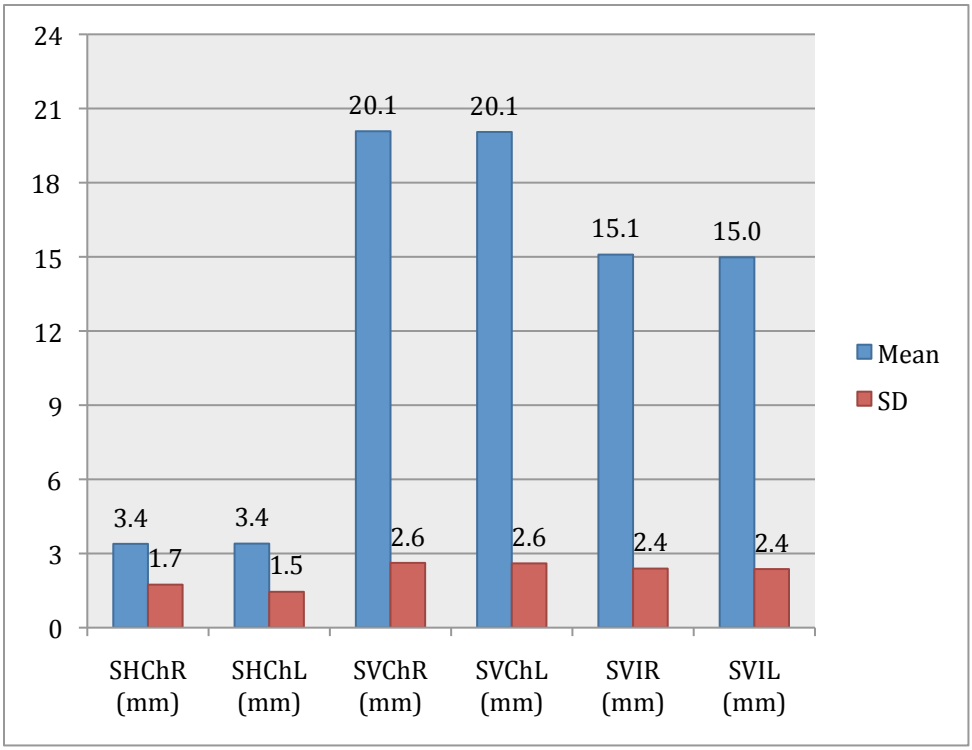

SHChR – horizontal soft tissue distance from a vertical line passing through the chelion to the mental foramen on the right. **SHChL** – horizontal soft tissue distance from a vertical line passing through the chelion to the mental foramen on the left. **SVChR** - vertical soft tissue distance from a horizontal line bisecting the chelions to the mental foramen on the right. **SVChL**- vertical soft tissue distance from a horizontal line bisecting the chelions to the mental foramen on the left. **SVIR** - vertical soft tissue distance from the inferior border of the mandible to the mental foramen on the right. **SVIL** - vertical soft tissue distance from the inferior border of the mandible to the mental foramen on the left.

Figure 8: Means and Standard deviations of soft tissue relations for the entire group of subject

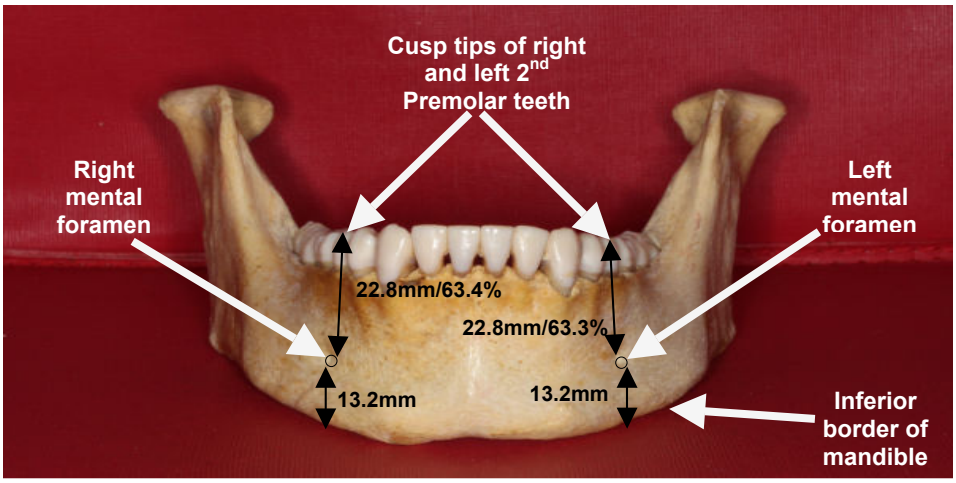

Figure 9: Frontal view of the mandible showing the various mean horizontal hard tissue measurements for the entire group of participants *(courtesy: School of Dentistry, University of the Witwatersrand)*

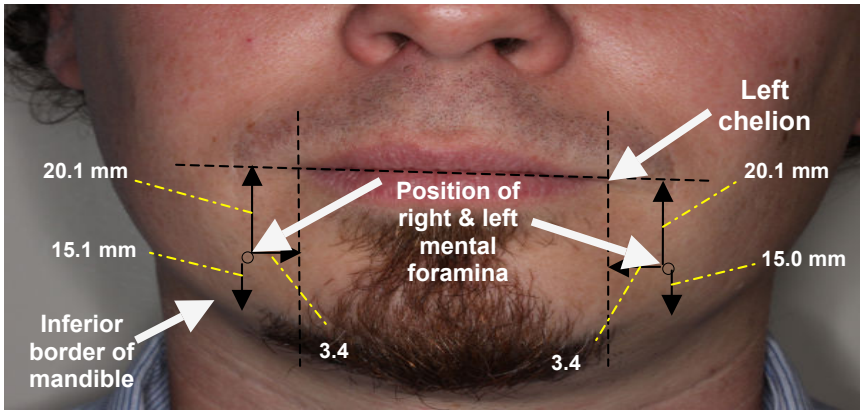

Figure 10: Frontal view of the lower face showing the various mean soft tissue measurements for the entire group of participants *(courtesy: School of Dentistry, University of the Witwatersrand)*

4.4 The impact of race on the position of the mental foramen

4.4.1 Vertical hard tissue relations (Figure 11, 12 (below) & Table 10, 11 (appendix))

Fisher's exact test was used instead of Chi^2 analysis to assess for statistical significance, as there were less than 5 observations for some positions. There were no statistical differences ($P > 0.05$) between the various race groups with regard to the position of the mental foramen in relation to the mandibular premolars on both the right and left sides.

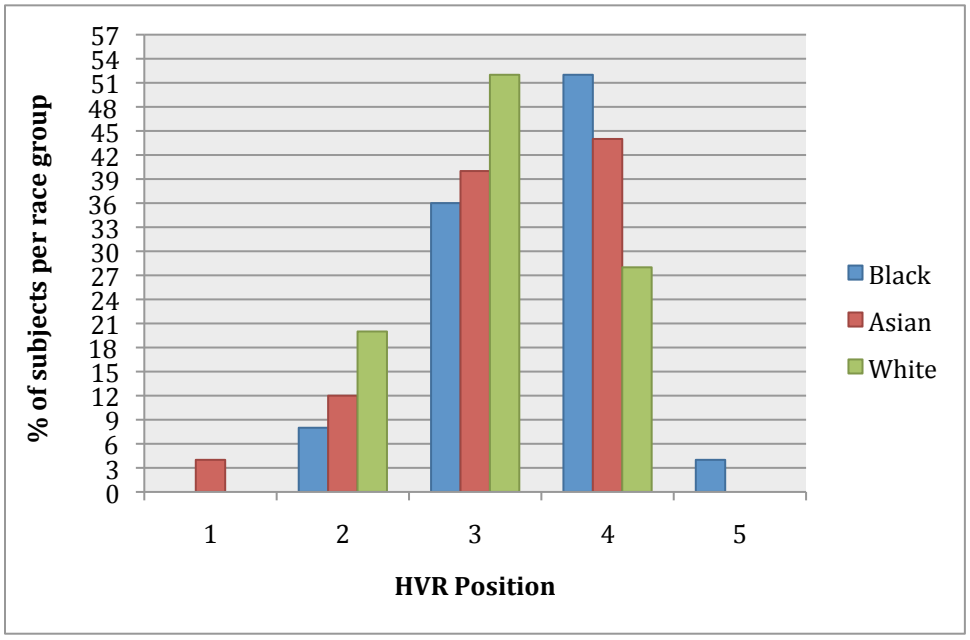

Fisher's exact test (P=0.264)

HVR - vertical hard tissue relation on the right side. **Position 1** - mesial to 1st premolar. **Position 2** - in line with the long axis of the 1st premolar. **Position 3** - between 1st and 2nd premolars. **Position 4** - in line with the long axis of the 2nd premolar. **Position 5** - lateral to 2nd premolar.

Figure 11: The impact of race on the position of the mental foramen with regard to vertical hard tissue relations on the right (HVR) side

In Blacks, the most frequent position of the mental foramen in relation to vertical hard tissue landmarks was at position 4 on the right (52%) and left (50%) side. The second most common position was at position 3 with a frequency of 36% on the right and 38% on the left side.

In Asians, the most frequent position of the mental foramen in relation to vertical hard tissue landmarks was found to be slightly more frequently at position 4 on the right (44%) and left (48%) sides, then at position 3 with a frequency of 40% on both the right and left sides.

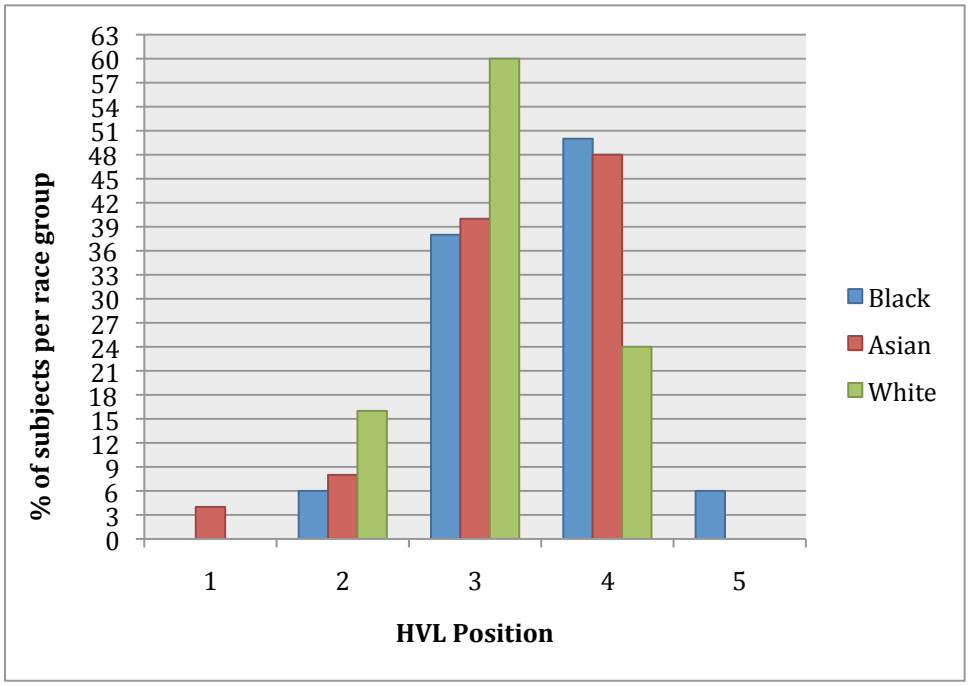

Fisher's exact test (P=0.121)

HVL - vertical hard tissue relation on the left side. **Position 1** - mesial to 1st premolar. **Position 2** - in line with the long axis of the 1st premolar. **Position 3** - between 1st and 2nd premolars. **Position 4** - in line with the long axis of the 2nd premolar. **Position 5** - lateral to 2nd premolar.

Figure 12: The impact of race on the position of the mental foramen with regard to vertical hard tissue relations on left (HVL) side

In Whites, the most frequent position of the mental foramen in relation to vertical hard tissue landmarks was at position 3, on the right (52%) and left (60%) sides. The second most common position was at position 4 with a frequency of 28% on the right and 24% on the left.

4.4.2 Horizontal hard tissue relations (Table 2)

The Analysis of Variance (ANOVA) statistical test revealed that there were significant differences between race groups for the distances from the mental foramen to the various horizontal hard tissue relations. Bartlett's test for equal variance showed no significance. Post hoc analysis using the Bonferroni method showed differences between race groups as follows:

HHCR – There were significant statistical differences between Blacks and Asians (P =0.011) and Blacks and Whites (P=0.015). There was no statistically significant difference between Asians and Whites (P=1.000). The differences were minimal (slightly more than 1 mm), with the blacks having the longest mean distances.

HHCL - There were significant statistical differences between Blacks and Asians (P=0.012) and Blacks and Whites (P=0.003). There was no statistically significant difference between Asians and Whites (P=1.000). The differences were minimal (slightly more than 1 mm), with the blacks having the longest mean distances.

Table 2: The impact of race on the position of the mental foramen with regard to horizontal hard tissue relations

Measurement (mm)		Race		
		Black	**Asian**	**White**
HHCR	**Mean**	23.5	22.1	21.9
	SD	2.0	1.8	1.7
	ANOVA (P=0.0009)			
HHCL	**Mean**	23.5	22.1	22.1
	SD	1.9	1.7	2.0
	ANOVA (P=0.0023)			
HHIR	**Mean**	13.9	12.2	12.8
	SD	1.4	1.5	1.6
	ANOVA (P=0.0000)			
HHIL	**Mean**	13.9	12.2	12.7
	SD	1.4	1.4	1.6
	ANOVA (P=0.0000)			
%R	**Mean**	62.9	64.5	63.4
	SD	1.3	2.0	2.0
	ANOVA (P=0.0007)			
%L	**Mean**	62.8	64.3	63.4
	SD	1.5	1.8	1.9
	ANOVA (P=0.0020)			

HHCR - horizontal hard tissue relation measuring the vertical distance between the cusp of the related tooth and the mental foramen on the right side. **HHCL** - horizontal hard tissue relation measuring the vertical distance between the cusp of the related tooth and the mental foramen on the left side. **HHIR** - horizontal hard tissue relation measuring the vertical distance between the inferior border of the mandible and the mental foramen on the right side. **HHIL** - horizontal hard tissue relation measuring the vertical distance between the inferior border of the mandible and the mental foramen on the left side. **%R** - the proportion of the distance (in percentage) of the position of the mental foramen from the cusp of the related tooth to the inferior border of the mandible on the right side (i.e. HHCR / HHCR + HHIR). **%L** - the proportion of the distance (in percentage) of the position of the mental foramen from the cusp of the related tooth to the inferior border of the mandible on the left side (i.e. HHCL / HHCL + HHIL).

HHIR - There were statistically significant differences between Blacks and Asians (P =0.000) and Blacks and Whites (P =0.010). There was no statistically significant difference between Asians and Whites (P =0.542). The differences were minimal (slightly more than 1 mm), with the blacks having the longest mean distances.

HHIL - There were significant statistical differences between Blacks and Asians (P=0.000) and Blacks and Whites (P=0.002). There was no statistically significant difference between Asians and Whites (P=0.890). The differences were minimal (slightly more than 1 mm), with the blacks having the longest mean distances.

%R - There was a significant statistical difference between Blacks and Asians (P=0.000). There were no statistically significant differences between Blacks and Whites (P=0.708) and Asians and Whites (P=0.054). The differences were minimal (<2%), with the Asians having the higher percentages.

%L - There was a significant statistical difference between Blacks and Asians (P=0.001). There were no statistically significant differences between Blacks and Whites (P=0.555) and Asians and Whites (P=0.147). The differences were minimal (<2%), with the Asians having the higher percentages.

4.4.3 Soft tissue relations (Table 3)

The Analysis of Variance (ANOVA) statistical test found that there were significant differences between race groups for some of the distances from the mental foramen to the various horizontal hard tissue relations. Bartlett's test for

equal variance showed no significance. Post hoc analysis using the Bonferroni method showed differences between race groups as follows:

SHChR & SHChL - There were no statistically significant differences between the groups (P=0.2868 and P=0.2766 respectively). There were minimal differences of about half a millimeters between race groups, with the blacks having the longest mean distances.

SVChR - There were statistically significant differences between Blacks and Asians (P=0.000) and Blacks and Whites (P=0.000). There was no statistically significant difference between Asians and Whites (P=1.000). The differences were minimal (slightly more than one and a half millimeters), with the blacks having the longest mean distances.

SVChL - There were statistically significant differences between Blacks and Asians (P=0.001) and Blacks and Whites (P=0.002). There was no statistically significant difference between Asians and Whites (P=1.000). The differences were minimal (slightly more than one and a half millimeters), with the blacks having the longest mean distances.

SVIR -There were statistically significant differences between Blacks and Asians (P =0.002) and Blacks and Whites (P =0.039). There was no statistically significant difference between Asians and Whites (P =1.000). The differences were minimal (about half a millimeter), with the blacks having the longest mean distances.

Table 3: The impact of race on the position of the mental foramen with regard to soft tissue relations

Measurement (mm)		Race		
		Black	**Asian**	**White**
SHChR	**Mean**	3.6	3.0	3.5
	SD	1.5	1.4	1.4
	ANOVA (P=0.2868)			
SHChL	**Mean**	3.6	3.0	3.5
	SD	1.5	1.5	1.3
	ANOVA (P=0.2766)			
SVChR	**Mean**	21.3	19.0	18.7
	SD	2.5	2.3	2.1
	ANOVA (P=0.0000)			
SVChL	**Mean**	21.2	19.2	18.6
	SD	2.5	2.3	1.9
	ANOVA (P=0.0000)			
SVIR	**Mean**	15.9	14.0	14.5
	SD	2.3	2.1	2.4
	ANOVA (P=0.0013)			
SVIL	**Mean**	15.8	14.0	14.4
	SD	2.2	2.3	2.2
	ANOVA (P=0.0022)			

SHChR – horizontal soft tissue distance from a vertical line passing through the chelion to the mental foramen on the right. **SHChL** – horizontal soft tissue distance from a vertical line passing through the chelion to the mental foramen on the left. **SVChR** - vertical soft tissue distance from a horizontal line bisecting the chelions to the mental foramen on the right. **SVChL**- vertical soft tissue distance from a horizontal line bisecting the chelions to the mental foramen on the left. **SVIR** - vertical soft tissue distance from the inferior border of the mandible to the mental foramen on the right. **SVIL** - vertical soft tissue distance from the inferior border of the mandible to the mental foramen on the left.

SVIL - There were statistically significant differences between Blacks and Asians (P =0.005) and Blacks and Whites (P =0.034). There was no statistically

significant difference between Asians and Whites (P =1.000). The differences were minimal (about half a millimeter), with the blacks having the longest mean distances.

4.5 The impact of sex on the position of the mental foramen

4.5.1 Vertical hard tissue relations (Figure 13, 14 (below) & Table 12, 13 (appendix))

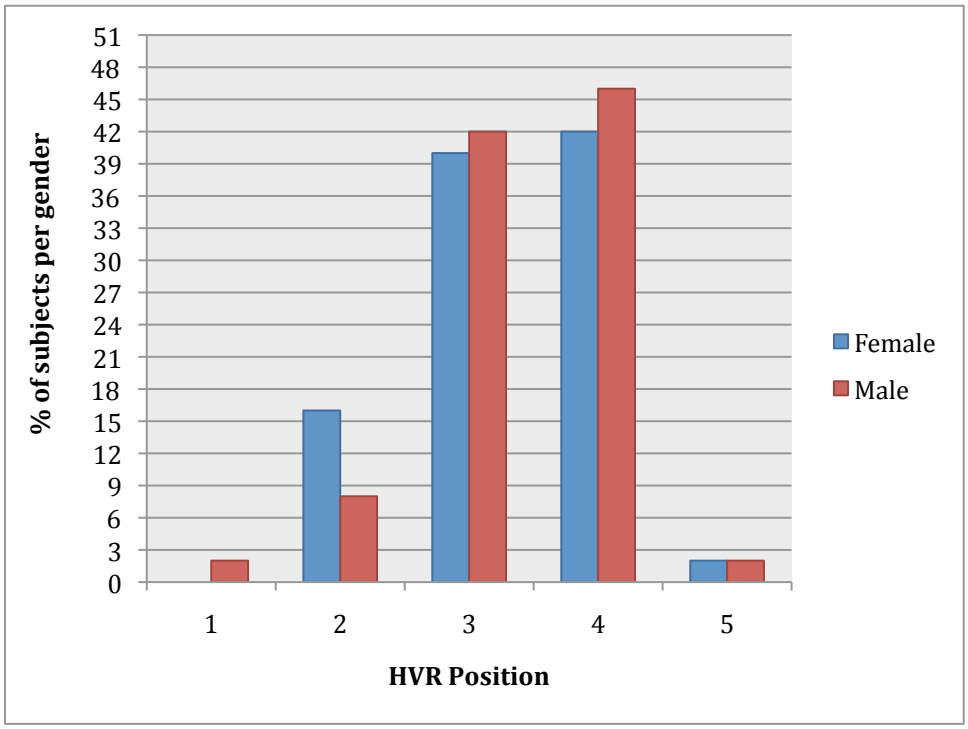

Fisher's exact test (P=0.766)

HVR - vertical hard tissue relation on the right side. **Position 1** - mesial to 1st premolar. **Position 2** - in line with the long axis of the 1st premolar. **Position 3** - between 1st and 2nd premolars. **Position 4** - in line with the long axis of the 2nd premolar. **Position 5** - lateral to 2nd premolar.

Figure 13: The impact of sex on the position of the mental foramen with regard to vertical hard tissue relations on the right (HVR) side

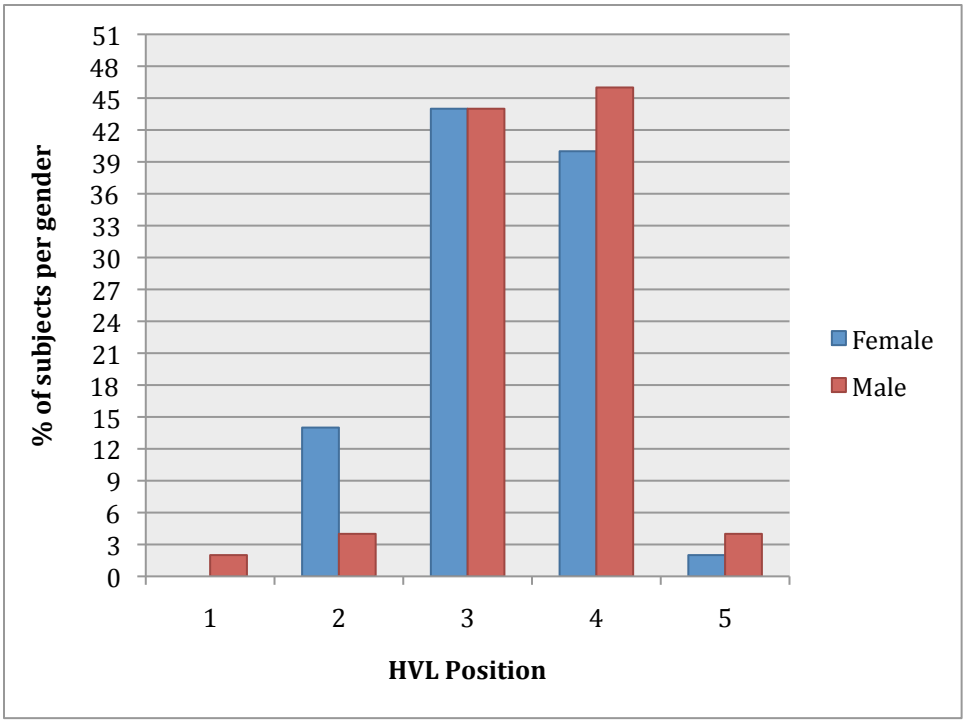

Fisher's exact test (P=0.387)

HVL - vertical hard tissue relation on the left side. **Position 1** - mesial to 1st premolar. **Position 2** - in line with the long axis of the 1st premolar. **Position 3** - between 1st and 2nd premolars. **Position 4** - in line with the long axis of the 2nd premolar. **Position 5** - lateral to 2nd premolar.

Figure 14: The impact of sex on the position of the mental foramen with regard to vertical hard tissue relations on the left (HVL) side

Fisher's exact test was used to assess for statistical significance. There were no statistically significant differences between females and males with regard to the position of the mental foramen and its relation to the mandibular premolars on both the right and left sides (P=0.766 and P=0.387 respectively).

The most frequent position of the mental foramen in relation to vertical hard tissue landmarks in females was at position 4 on the right (42%) and position 3

on the left (44%) side. The second most common position was at position 3 on the right with a frequency of 40% and position 4 on the left with a frequency of 40%.

The most frequent position of the mental foramen in relation to vertical hard tissue landmarks in males on the right was at position 4 (46%) and then position 3 at 42%. On the left it was found most frequently found at position 4 (46%) and then position 3 at 44%.

4.5.2 Horizontal hard tissue relations (Table 4)

The two-sample t-test found that there were statistically significant differences between females and males with regard to the position of the mental foramen in relation to the various horizontal hard tissue relations. $P < 0.05$ for all measurements (see table below).

The mean distance from the cusp of the related tooth to the mental foramen was 21.5 mm (SD 1.5 mm) on the right (HHCR) and 21.6 mm (SD 1.4 mm) on the left (HHCL) in females, whereas in males it was 24.0 mm (SD 1.7mm) on the right and 24.0 mm (SD 1.7 mm) on the left. The mean distances were approximately two and a half millimeters longer in males when compared to females, on either side.

Table 4: The impact of sex on the position of the mental foramen with regard to horizontal hard tissue relations

Measurement (mm)		Gender	
		F	M
HHCR	Mean	21.5	24.0
	SD	1.5	1.7
	T-TEST (P=0.0000)		
HHCL	Mean	21.6	24.0
	SD	1.4	1.7
	T-TEST (P=0.0000)		
HHIR	Mean	12.1	14.2
	SD	1.2	1.3
	T-TEST (P=0.0000)		
HHIL	Mean	12.1	14.2
	SD	1.2	1.3
	T-TEST (P=0.0000)		
%R	Mean	63.9	62.9
	SD	1.9	1.5
	T-TEST (P=0.0037)		
%L	Mean	63.9	62.8
	SD	1.8	1.6
	T-TEST (P=0.0019)		

HHCR - horizontal hard tissue relation measuring the vertical distance between the cusp of the related tooth and the mental foramen on the right side. **HHCL** - horizontal hard tissue relation measuring the vertical distance between the cusp of the related tooth and the mental foramen on the left side. **HHIR** - horizontal hard tissue relation measuring the vertical distance between the inferior border of the mandible and the mental foramen on the right side. **HHIL** - horizontal hard tissue relation measuring the vertical distance between the inferior border of the mandible and the mental foramen on the left side. **%R** - the proportion of the distance (in percentage) of the position of the mental foramen from the cusp of the related tooth to the inferior border of the mandible on the right side (i.e. HHCR / HHCR + HHIR). **%L** - the proportion of the distance (in percentage) of the position of the mental foramen from the cusp of the related tooth to the inferior border of the mandible on the left side (i.e. HHCL / HHCL + HHIL).

The mean distance from the inferior border of the mandible to the mental foramen on the right side (HHIR) was 12.1 mm (SD 1.2 mm) in females and 14.3 mm (SD 1.3 mm) in males. On the left side (HHIL) it was 12.1 mm (SD 1.2 mm) in females and 14.2 mm (SD 1.3 mm) in males. The mean distances were approximately two millimeters longer in males when compared to females, on either side.

The mean position of the mental foramen was found to be 63.9% (SD 1.9%) of the distance from the cusp of the tooth to the inferior border of the mandible on the right side (%R) and 63.9% (SD 1.8%) on the left side (%L) in females and 62.9% (SD 1.5%) on the right side and 62.8% (SD 1.6%) on the left side in males. The mean position of the mental foramen was located approximately 1 % lower in females when compared to males, on either side.

4.5.3 Soft tissue relations (Table 5)

The mean horizontal distance from a vertical line passing through the chelion to the mental foramen was 3.4 mm (SD 1.8 mm) lateral to the line on the right (SHChR) and 3.4 mm (SD 1.4 mm) lateral to the line on the left (SHChL) in females. In males it was 3.4 mm (SD 1.6 mm) lateral to the line on the right and 3.4 mm (SD 1.5 mm) lateral to the line on the left. The two-sample t-test found no statistically significant differences (P =0.835 on the right and P = 1.000 on the left).

Table 5: The impact of sex on the position of the mental foramen with regard to soft tissue relations

Measurement (mm)		Gender	
		F	M
SHChR	Mean	3.4	3.4
	SD	1.8	1.6
	T-TEST (P=0.8348)		
SHChL	Mean	3.4	3.4
	SD	1.4	1.5
	T-TEST (P=1.0000)		
SVChR	Mean	18.6	21.6
	SD	1.8	1.4
	T-TEST (P=0.0000)		
SVChL	Mean	18.5	21.6
	SD	1.8	2.3
	T-TEST (P=0.0000)		
SVIR	Mean	13.6	16.5
	SD	2.0	1.8
	T-TEST (P=0.0000)		
SVIL	Mean	13.6	16.4
	SD	2.0	1.9
	T-TEST (P=0.0000)		

SHChR – horizontal soft tissue distance from a vertical line passing through the chelion to the mental foramen on the right. **SHChL** – horizontal soft tissue distance from a vertical line passing through the chelion to the mental foramen on the left. **SVChR** - vertical soft tissue distance from a horizontal line bisecting the chelions to the mental foramen on the right. **SVChL**- vertical soft tissue distance from a horizontal line bisecting the chelions to the mental foramen on the left. **SVIR** - vertical soft tissue distance from the inferior border of the mandible to the mental foramen on the right. **SVIL** - vertical soft tissue distance from the inferior border of the mandible to the mental foramen on the left.

The mean vertical distance from the horizontal line bisecting the chelions to the mental foramen was 18.6 mm (SD 1.8 mm) below the line on the right (SVChR) and 18.5 mm (SD 1.8 mm) below the line on the left (SVChL) in females. In males it was 21.6 mm (SD 1.4 mm) below the line on the right and 21.6 mm (SD 2.3 mm) below the line on the left. The two-sample t test found the difference to be statistically significant (P =0.000 on the right and left sides). In males the mean distances were approximately three millimeters longer.

The mean vertical distance from the mental foramen to the inferior border of the mandible was 13.6 mm (SD 2.0 mm) on the right (SVIR) and 13.6 mm (SD 2.0 mm) on the left (SVIL) in females. In males it was 16.5 mm (SD 1.8 mm) on the right and 16.4 mm (SD 1.9 mm) on the left. The two-sample t-test found the difference to be statistically significant (P =0.000 on the right and left sides). In males the mean distances were approximately three millimeters longer. The mean distances were longer with the soft tissue measurements when compared to the hard tissue measurements. This is due to the fact that the soft tissue measurements include skin thickness below the inferior border of the mandible.

4.6 The impact of age on the position of the mental foramen

Age groups a; b; c and d (18 – 60 years) were analysed as only 2 percent of subjects were in category e (i.e. older than 60 years)

4.6.1 Vertical hard tissue relations (Table 6, 7 (below) & Figure 16, 17 (appendix))

Fisher's exact test was used to assess for statistical significance. There were no statistically significant differences (P > 0.05) between the various age categories with regard to the position of the mental foramen in relation to the mandibular premolars on both the right and left sides.

Table 6: The impact of age on the position of the mental foramen with regard to vertical hard tissue relations on the right side (HVR)

HVR position	**Age Group**				
	18-30 yrs	**31-40 yrs**	**41-50 yrs**	**51-60 yrs**	**61-70 yrs**
1	1 2.5%	0 0%	0 0%	0 0%	0 0%
2	5 12.5%	2 6.9%	3 18.75%	1 7.69%	1 50%
3	19 47.5%	13 44.83%	4 25%	4 30.77%	1 50%
4	14 35%	14 48.28%	8 50%	8 61.54%	0 0%
5	1 2.5%	0 0%	1 6.25%	0 0%	0 0%
Fisher's exact test (P=0.522)					

HVR - vertical hard tissue relation on the right side. **Position 1** - mesial to 1st premolar. **Position 2** - in line with the long axis of the 1st premolar. **Position 3** - between 1st and 2nd premolars. **Position 4** - in line with the long axis of the 2nd premolar. **Position 5** - lateral to 2nd premolar.

Table 7: The impact of age on the position of the mental foramen with regard to vertical hard tissue relations on the left side (HVL)

HVL position	Age Group				
	18-30 yrs	**31-40 yrs**	**41-50 yrs**	**51-60 yrs**	**61-70 yrs**
1	1 2.5%	0 0%	0 0%	0 0%	0 0%
2	4 10%	1 3.45%	3 18.75%	0 0%	1 50%
3	20 50%	14 48.28%	3 18.75%	6 46.15%	1 50%
4	14 35%	14 48.28%	8 50%	7 53.85%	0 0%
5	1 2.5%	0 0%	2 12.5%	0 0%	0 0%
Fisher's exact test (P=0.135)					

HVL - vertical hard tissue relation on the left side. **Position 1** - mesial to 1st premolar. **Position 2** - in line with the long axis of the 1st premolar. **Position 3** - between 1st and 2nd premolars. **Position 4** - in line with the long axis of the 2nd premolar. **Position 5** - lateral to 2nd premolar.

The most common position of the mental foramen in subjects in the age group category a (18 - 30 years) was at position 3 on the right and left sides. In age group categories b; c and d (31 – 60 years) position 4 was the most common position, with higher frequencies of subjects at position 4 with advancement of age. In 4% or less of patients, the mental foramen was positioned at position 1 or 5 on both the right and left sides.

4.6.2 Horizontal hard tissue relations (Table 8)

Table 8: The impact of age on the position of the mental foramen with regard to horizontal hard tissue relations

Measurement (mm)		Age Group				
		a	b	c	d	e
HHCR	Mean	22.3	23.4	23.3	22.2	20.9
	SD	1.7	1.9	2.4	2.4	0.6
	ANOVA (P=0.0671)					
HHCL	Mean	22.4	22.4	23.4	22.3	20.8
	SD	1.7	1.9	2.3	2.4	0.6
	ANOVA (P=0.0842)					
HHIR	Mean	12.6	13.7	13.4	12.9	12.4
	SD	1.6	1.6	1.7	1.9	0.4
	ANOVA (P=0.2487)					
HHIL	Mean	12.8	13.7	13.3	12.9	12.5
	SD	1.5	1.5	1.8	1.8	0.8
	ANOVA (P=0.2263)					
%R	Mean	63.6	63.2	63.6	63.2	62.8
	SD	2.0	1.4	1.8	1.9	0.0
	ANOVA (P=0.8039)					
%L	Mean	63.6	63.1	63.5	63.1	62.4
	SD	1.9	1.6	1.8	1.6	1.0
	ANOVA (P=0.6668)					

HHCR - horizontal hard tissue relation measuring the vertical distance between the cusp of the related tooth and the mental foramen on the right side. **HHCL** - horizontal hard tissue relation measuring the vertical distance between the cusp of the related tooth and the mental foramen on the left side. **HHIR** - horizontal hard tissue relation measuring the vertical distance between the inferior border of the mandible and the mental foramen on the right side. **HHIL** - horizontal hard tissue relation measuring the vertical distance between the inferior border of the mandible and the mental foramen on the left side. **%R** - the proportion of the distance (in percentage) of the position of the mental foramen from the cusp of the related tooth to the inferior border of the mandible on the right side (i.e. HHCR / HHCR + HHIR). **%L** - the proportion of the distance (in percentage) of the position of the mental foramen from the cusp of the related tooth to the inferior border of the mandible on the left side (i.e. HHCL / HHCL + HHIL).

The Analysis of Variance (ANOVA) statistical test did not detect any statistically significant differences between age categories for the distances from the mental foramen to the various horizontal hard tissue relations. Bartlett's test for equal variance showed no significance.

4.6.3 Soft tissue relations (Table 9)

The Analysis of Variance (ANOVA) statistical test did not detect any statistically significant differences between age categories for the distances from the mental foramen to the various soft tissue relations. Bartlett's test for equal variance showed no significance.

Table 9: The impact of age on the position of the mental foramen with regard to soft tissue relations

Measurement (mm)		Age Group				
		a	b	c	d	e
SHChR	Mean	3.3	3.8	2.8	3.5	3.0
	SD	1.3	1.6	1.2	1.4	2.8
	ANOVA (P=0.1710)					
SHChL	Mean	3.3	3.8	2.8	3.5	3.0
	SD	1.3	1.6	1.4	1.3	2.8
	ANOVA (P=0.2308)					
SVChR	Mean	19.9	21.0	20.1	19.0	18.5
	SD	2.6	2.6	3.0	2.0	2.1
	ANOVA (P=0.1626)					
SVChL	Mean	19.9	20.8	20.0	19.1	18.5
	SD	2.6	2.5	3.1	2.1	0.7
	ANOVA (P=0.2880)					
SVIR	Mean	14.7	15.9	15.2	14.7	14.0
	SD	2.5	1.2	2.4	2.9	1.4
	ANOVA (P=0.2869)					
SVIL	Mean	14.5	15.8	15.3	14.6	14.0
	SD	2.5	2.1	2.3	2.4	1.4
	ANOVA (P=0.2129)					

SHChR – horizontal soft tissue distance from a vertical line passing through the chelion to the mental foramen on the right. **SHChL** – horizontal soft tissue distance from a vertical line passing through the chelion to the mental foramen on the left. **SVChR** - vertical soft tissue distance from a horizontal line bisecting the chelions to the mental foramen on the right. **SVChL**- vertical soft tissue distance from a horizontal line bisecting the chelions to the mental foramen on the left. **SVIR** - vertical soft tissue distance from the inferior border of the mandible to the mental foramen on the right. **SVIL** - vertical soft tissue distance from the inferior border of the mandible to the mental foramen on the left.

4.7 Symmetry

The position of the mental foramen with regard to its relationship to the mandibular premolar teeth (vertical hard tissue relations (positions 1 – 5)), was assessed for asymmetry. If the mental foramina were found to be at different positions on the right and left sides, they were classified as asymmetrical. In 9 out of 100 subjects the mental foramina were found to be asymmetrical. The race and gender distributions were as follows: 3 Black males, 2 Black females, 2 Asian males, 2 White females.

There was no asymmetry observed between the right and left sides for all other distances measured when rounded off to the nearest millimeter.

4.8 The proportion of patients in whom the mental foramen could not be identified ultrasonographically

The mental foramina were identified ultrasonographically in all of the subjects in the study group.

4.9 Accessory mental foramina

3 out of the 100 subjects were noted to have accessory mental foramina. They were each located 5.9 mm; 6.4 mm and 6.1 mm medial to the non-accessory

mental foramen (mean 6.1 mm). They were all located in the same horizontal plane as the non-accessory mental foramen. The mental foramen that was symmetrical to the opposite side was regarded as the non accessory mental foramen. The race and gender distributions were as follows: 2 black males and 1 white female.

4.10 The effects of facial hair

12 out of 100 subjects were noted to have facial hair in the vicinity of the mental foramen. In all of these subjects the mental foramen was easily visualized on ultrasonography. However a more generous amount of sonar gel was required in order to achieve an improved picture on the screen. The quantity of gel required per case was not documented.

4.11 Time taken to locate the first mental foramen in each patient (figure 15)

The overall mean time taken to locate the first mental foramen studied in each patient was 16.1 seconds (SD 12.9 seconds). The quickest time was noted as 6 seconds and the longest time was noted as 58 seconds. For the first 25 subjects studied, the mean time was 34.7 seconds (SD 13.4 seconds), whereas for the next 75 subjects studied, the mean time taken was 9.9 seconds (SD 3.0 seconds). It is noted from the figure below that the more subjects that were assessed, the shorter the time taken to find the mental foramen.

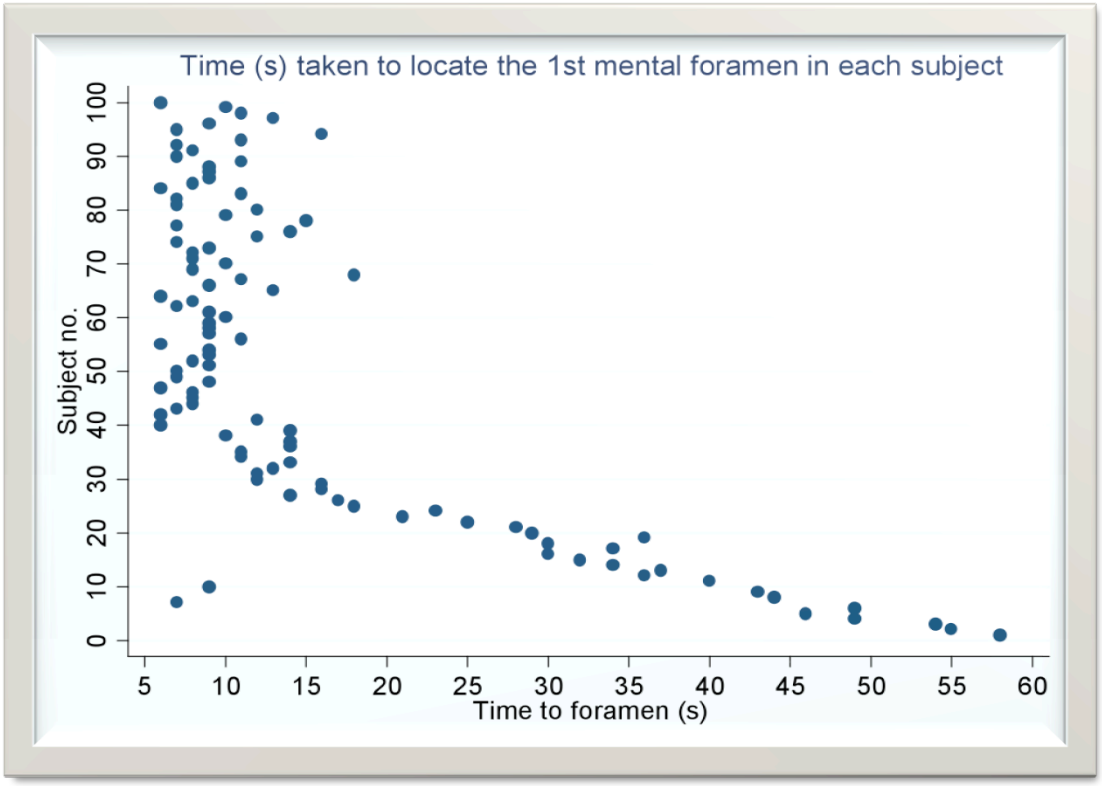

Figure 15: Two-way scatter plot of the time taken (seconds) to locate the first mental foramen in each of the 100 subjects

CHAPTER 5

DISCUSSION

5.1 Vertical hard tissue relations

There were no statistically significant differences between race groups, gender and age categories with regard to the position of the mental foramen in relation to the mandibular premolars on both the right (HVR) and left (HVL) sides ($P > 0.05$ for all categories).

However, in Blacks the most common position was in line with the long axis of the second mandibular premolar (52% on the right and 50% on the left). This is in keeping with studies conducted on Black population groups in Tanzania, Malawi, Zimbabwe and Kenya (Fabian 2007; Igbigbi & Lebona 2005; Mbajiorgu et al. 1998; Mwaniki & Hassanali 1992). This was also the most common position in Mongoloid populations such as Chinese, Korean and Malay (Guo et al. 2009, Kim et al. 2006, Neo 1989). al Jasser et al and Smajilagic et al also found the same in Saudi Arabian and Bosnian populations (al Jasser & Nwoku 1998; Smajilagic & Dilberovic 2004). Frequencies of between 45% and 75.3% have been reported in the studies above when the most common position was in line with the long axis of the 2nd mandibular premolar.

In Asians, the most frequent position of the mental foramen was found slightly more frequently in line with the long axis of the 2nd mandibular premolar (44% on the right and 48% on the left) followed closely by position 3, which is between the 1st and 2nd mandibular premolars (40% on either side). Four different studies in Asian population groups found the most common position at different locations. Two studies found the most common position to be in line with the long axis of the 2nd mandibular premolar (frequencies of 75.3% & 47%) (Neves et al. 2010, Shankland 1994). One study each found the most common position to be between the first and 2nd mandibular premolars (73.2%) and lateral to the 2nd mandibular premolar (51.5%) respectively (Sankar et al. 2011; Santini & Alayan 2012).

In Whites, the most frequent position of the mental foramen was between the 1st and 2nd mandibular premolars on the right (52%) and left (60%) sides. Studies in white population groups of Austria (Kqiku et al. 2011), North America (Moiseiwitsch 1998), USA (Pria et al. 2011), and Britain (Santini & Alayan 2012) also found the same. Frequencies of between 50% and 62.5% have been reported. Another study conducted in USA found the most frequent position to be in line with the long axis of the 2nd mandibular premolar (Phillips et al. 1992). Studies in Jordanian, Brazilian and Iranian and Turkish populations also found the most common position to be between the 1st and 2nd mandibular premolars (Al-Khateeb et al. 2007; Chrcanovic et al. 2011; Haghanifar & Rokouei 2009; Aktekin et al. 2003).

Overall, in only 3% of cases on the right and 4% of cases on the left, the mental foramen was found to be mesial to the 1st premolar or lateral to the 2nd premolar. In Blacks the mental foramen was lateral to the 2nd premolar in 4% of subjects on the right and 6% on the left and in Asians, 4% of subjects had their mental foramina mesial to the 1st premolars on either side. In Blacks and Whites the mental foramen was not found mesial to the 1st premolar and in Asians and Whites it was not found lateral to the 2nd premolar. When the mental foramen was found mesial to the 1st premolar, frequencies of between 1% and 5% have been reported in the literature (Al-Khateeb et al. 2007; Neo 1989; Santini & Alayan 2012: Ngeow & Yuzawati 2003). Frequencies of between 4% and 51.5% have been reported for the position lateral to the 2nd premolar (Al-Khateeb et al. 2007; Fabian 2007; Kqiku et al. 2011; Oguz & Bozkir 2002; Santini & Alayan 2012). Shah et al commented that the mental foramen lies either mesial to the first premolar or lateral to the first molar in only 1–2% of cases (Shah et al. 2010).

Only 2 percent of subjects were in category e (i.e. older than 60 years). Therefore to avoid sampling bias, this category will not be commented on further. For age group categories b, c and d (31 – 60 years) position 4 (in line with the long axis of the 2nd premolar) was the most frequent position, with higher frequencies of subjects at position 4 with advancement in age. A study done in Jordan (Al-Khateeb et al. 2007) discovered that the position of the mental foramen was found to be more posterior and inferior with advancement in age.

5.2 Horizontal hard tissue relations

There were statistically significant differences between the various race groups and between the gender groups with regard to the distances from the mental foramen to the various horizontal hard tissue relations. Post hoc analysis using the Bonferroni method detected significant differences between Blacks and Asians and Blacks and Whites, but not between Asians and Whites (except for %R and %L, where there were no statistically significant differences between Blacks and Whites and Asians and Whites). There were no statistically significant differences between age categories with regard to the distances from the mental foramen to the various horizontal hard tissue relations.

The mean vertical distance of the entire group of subjects from the buccal cusp tip of the concerned tooth to the mental foramen was 22.8mm (SD 2.0 mm) on the right and 22.8 mm (SD 2.0 mm) on the left side. Differences between the various race groups were minimal at around 1 mm. In males the mean distances were about 2.5 mm longer than females ($p < 0.05$). Average distances of 23.34mm and 25.69mm have been recorded in Chinese and Korean populations respectively (Guo et al. 2009, Kim et al. 2006). There has been no comparison between gender groups or age groups in the literature.

The mean vertical distance of the entire group of subjects from the inferior border of the mandible to the mental foramen was 13.2 mm (SD 1.6 mm) on the right and 13.2 mm (SD 1.6 mm) on the left side. The mean difference between race

groups was approximately 1 mm ($p < 0.05$). In males the mean distances were about 2 mm longer than females. In studies on American and Indian subjects the mean distance has been reported as 12.9 mm and 16.5mm respectively (Smith et al. 2010; Sankar et al. 2011). Other studies documented distances between the above (Guo et al. 2009; Kim et al. 2006; Smajilagic & Dilberovic 2004; Gupta 2008; Igbigbi & Lebona 2005; Mbajiorgu et al. 1998; Oguz & Bozkir 2002; Santini & Alayan 2012). There has been no comparison between gender groups or between age groups in the literature.

The mean position of the mental foramen for the entire group of subjects in this study was 63.4% (SD 1.8%) of the distance from the cusp of the related tooth to the inferior border of the mandible on the right (%R) and 63.3% (SD 1.7%) on the left (%L) side. The mean position of the mental foramen was the lowest in Asians, then Whites and then Blacks. They were all however within 2% of each other. The mental foramen was located about 1 mm lower in females compared to males ($P<0.05$). An American study located the mental foramen an average of approximately 60% of the distance between the buccal cusp tip and the inferior border of the mandible (Phillips et al. 1990). A Korean study compared dry skulls with panoramic radiographs and concluded that the average distance ratio from the buccal cusp tip to the inferior border of the mandible to be 60.6% on dry skulls and 63.6% on panoramic radiographs (Kim et al. 2006). Ultrasonographic techniques make use of direct measurement and do not have the negative effect of radiographs, where angles and curves are not taken into account.

5.3 Soft tissue relations

There were no statistically significant differences between race groups, between gender group and between age categories with regard to the horizontal soft tissue distance from a vertical line passing through the chelion to the mental foramen on the right or left sides (SVChR & SVChL). The overall mean distances were 3.4 mm (SD 1.7 mm) on the right and 3.4 mm (SD 1.5 mm) on the left side. Both distances were found lateral to the chelions. Guo et al indirectly measured the horizontal distance from the chelion to the mental foramen on digitalized photographs. A mean distance of 3.55 mm (SD, 1.70 mm) mesial to the chelion in the frontal view, and 7.19 mm (SD, 3.03 mm) lateral to the chelion on the lateral view was recorded (Guo et al. 2009). Song et al also conducted their measurements indirectly on digitalized photographs and documented the mean position of the mental foramen as 3.3 mm (SD 2.9 mm) mesial to the chelions on frontal views (Song et al. 2007). Digitalized photography does not take angles and curves of the mandible into account. This would account for the differences when compared to this study, as ultrasound is a direct measurement.

There were statistically significant differences between race groups (between Blacks and Asians and between Blacks and Whites but not between Asians and Whites) and between gender groups but not between age groups with regard to the vertical soft tissue distance from a horizontal line bisecting the chelions to the mental foramen on the right and left sides. The overall mean distances were 20.1

mm (SD 2.6 mm) on the right and 20.1 mm (SD 2.60 mm) on the left side. The distances were longer in Blacks then Asians. Whites had the shortest mean distances. Overall the differences between race groups were minimal (around 2.5 mm) and is not regarded clinically significant. The mean distances were approximately 3 mm longer in males when compared to females. Guo et al indirectly measured the vertical distance from the chelion to the mental foramen on digitalized photographs. Mean distances recorded were 23.38 mm (SD, 2.00 mm) inferior to the chelion in the frontal view, and 23.59 mm (SD, 2.11 mm) inferior to the chelion on the lateral view (Guo et al. 2009). Song et al also conducted their measurements indirectly on digitalized photographs and located the mean distance of the mental foramen as 20.40 mm (SD, 3.9 mm) inferior to the chelion on frontal views (Song et al. 2007).

There were statistically significant differences between race groups (between Blacks and Asians and between Blacks and Whites but not between Asians and Whites) and between gender groups but not between age groups with regard to the vertical soft tissue distance from the inferior border of the mandible to the mental foramen on the right and left sides. The overall mean distances were 15.1mm (SD 3.4 mm) on the right and 15.0 mm (SD 2.4 mm) on the left side. The distances were longer in Blacks than Whites. Asians had the shortest mean distances. Overall the differences between race groups were minimal (around 1 mm) and is not regarded clinically significant. The mean distances were approximately 3 mm longer in males when compared to females. The measured

distances were longer with the soft tissue measurements (SVIR & SVIL) when compared to the hard tissue measurements (HHIR & HHIL). This is due to the fact that the soft tissue measurements include the skin thickness below the inferior border of the mandible. No report regarding this measurement has been found in the literature.

5.4 Symmetry

In 9 out of 100 subjects (9%), the mental foramina were assessed as asymmetrical with regard to its relationship to the mandibular premolar teeth. Frequencies of 14.3%, 20%, 32% and 33% have been variously reported in the literature (Haghanifar & Rokouei 2009; Al-Khateeb et al. 2007; al Jasser & Nwoku 1998; Ngeow & Yuzawati 2003; Fabian 2007). A Tanzanian study involving 100 cadavers reported that 78% of mental foramina were asymmetrical (Fabian 2007).

There was no asymmetry observed between the right and left sides for all other distances measured when rounded off to the nearest millimeter. This is in contrast to Al-Khateeb, who looked at superior-inferior asymmetry and found an incidence of 14% (Al-Khateeb et al. 2007).

5.5 The proportion of patients in whom the mental foramen could not be identified ultrasonographically

All mental foramina (100%) in the study group were clearly identified with ultrasound. Jacobs et al (Jacobs et al. 2004) reported detection of the mental foramen in 94% of panoramic radiographs, and only 49% were clearly visible, whilst the mental foramen was only visualized in 84.2% of cases in an Iranian study (Jalili et al. 2011). A study conducted in 1976 by Fishel et al, using periapical films reported that the mental foramen was detected in 46.8% of cases (Fishel et al. 1976). Therefore ultrasound determination of the mental foramen should be regarded as superior to panoramic and periapical films. It is also a safer option with no side effects or risk of radiation exposure.

5.6 Accessory mental foramina

Three percent of subjects were noted to have accessory mental foramina. This is in keeping with previous literature reports. The incidence of accessory mental foramina has been reported as between 3% and 10% (Al-Khateeb et al. 2007; Guo et al. 2009; Fabian 2007; Mwaniki & Hassanali 1992; Santini & Alayan 2012; Kalender et al. 2011; Naitoh et al. 2009; Ritter et al. 2009; Kulkarni et al. 2011). The mean distance between the mental foramen and accessory mental foramen was 6.1 mm. Naitoh et al in his study found the mean distance as 6.3 mm (Naitoh et al. 2009).

5.7 The effects of facial hair

With the aid of more generous amounts of sonar gel, the mental foramen was detected in all 12% of subjects who had facial hair present in the vicinity of the mental foramen. This proves that the presence of hair should not be regarded as a contraindication to the use of ultrasound.

5.8 Time taken to locate the first mental foramen in each patient

For the first 25 subjects studied, the mean time was 34.7 seconds (SD 13.4 seconds), whereas for the next 75 subjects studied, the mean time taken was 9.9 seconds (SD 3.0 seconds). Therefore, with more experience, the time taken to find the mental foramen with ultrasonography was markedly quicker. It can be concluded that the saying “practice makes perfect” is true.

5.9 Clinical and practical implications of study findings

5.9.1 Vertical hard tissue relations

In 85% of participants on the right side and 87% of participants on the left side, the mental foramina was found to be in line with the long axis of the 2nd mandibular premolar or between the 1st and second mandibular premolars. Therefore in the absence of an ultrasound device, a mental block should be attempted in this region if one chooses to make use of the mandibular premolars

as the landmark. Although not statistically significant, in Blacks the mental foramen was more frequently located in line with the 2nd mandibular premolar whereas in Whites it was more frequently located between the first and 2nd mandibular premolars. In Asians the most frequent position was almost equal in line with the 2nd premolar or between the 1st and 2nd premolars. Therefore blind (non-ultrasound guided) mental nerve blocks should initially be attempted in the most common positions of the mental foramen based on patient race. If the attempted block fails, a block at the 2nd most common position should be attempted and then at other positions. Although also not statistically significant, the mental foramen was found to be more frequently below the 2nd mandibular premolar than between the 1st and 2nd premolars with advancement in age (31-60 years). This should also be taken into consideration.

5.9.2 Horizontal hard tissue relations

The differences between race groups for the distances between the various horizontal hard tissue landmarks to the mental foramen were statistically significant. Mean distances between the various race groups when compared to the overall mean distances were minimal and as follows: HHCR = 0.9mm, HHCL = 0.7 mm, HHIR = 1.0 mm, HHIL = 1.0 mm, %R = 1.1%, %L = 1.0%. In males versus females the differences were significantly statistically different and as follows when compared to the overall mean distances for the entire group: HHCR = 1.3 mm, HHCL = 1.2 mm, HHIR = 1.1 mm, HHIL = 1.1 mm, %R = 0.5%, %L = 0.5%. The differences between age groups were not statistically significant. The

above differences between distances are minimal and not regarded as significant in clinical practice and can be ignored. Therefore based on this study, when using horizontal hard tissue landmarks to locate the mental foramen, the overall mean distances can be used as a guide when trying to blindly locate and anaesthetise the mental nerve in all individuals.

5.9.3 Soft tissue relations

The differences between the various race groups for the distances between the various soft tissue landmarks to the mental foramen were statistically significant for SVChR, SVChL, SVIR and SVIL but not for SHChR and SHChL. Mean distances between race groups when compared to the overall mean distances for the entire group were minimal and as follows: SVChR = 1.4 mm, SVChL = 1.5 mm, SVIR = 1.1 mm, SVIL = 1.0 mm. In males versus females the differences were also significantly statistically different for SVChR, SVChL, SVIR and SVIL but not for SHChR and SHChL and were as follows when compared to the overall mean distances for the entire group: SVCHR = 1.5 mm, SVCHL = 1.6 mm, SVIR = 1.5 mm, SVIL = 1.4 mm. The differences between age groups were not statistically significant. The above differences between distances are minimal and not regarded as significant in clinical practice and can be ignored. Therefore based on this study, when using soft tissue landmarks to locate the mental foramen, the overall mean distances can be used as a guide when trying to blindly locate and anaesthetize the mental nerve in all individuals.

5.9.4 Accessory mental foramina

When ultrasound is used, one must assess for the presence of accessory mental foramina. If one does not assess for the presence of accessory mental foramina, the area around the foramen that is not transmitting the mental nerve may be anaesthetised. This may result in inadequate anaesthesia.

5.9.5 Does ultrasonography have a role in mental nerve blocks?

Theoretically the use of ultrasonography for mental nerve blocks should decrease the amount of local anaesthetic requirements, increase first time success rates and decrease complication rates. This study has shown that with practice the time needed to ultrsonographically locate the mental foramen becomes markedly quicker (figure 17). It can be recommended that post graduation specialty and other higher degree courses where mental nerve blocks are commonly carried out, must include the teaching of mental foramen detection and mental nerve anaesthesia under ultrasound guidance. Accreditation procedures should include at least 20 – 25 procedures. Further studies need to be carried out to compare the time taken to anaesthetise the mental nerve, complication rates, amount of local anaesthetic agent used and success rates between ultrasound guided mental nerve blocks and blind mental nerve blocks.

Ultrasound guided nerve blocks are regarded as an advanced as opposed to a basic/core emergency ultrasound skill (Bhoi et al. 2012). Studies of other nerves that are commonly blocked under ultrasound guidance need to be conducted. If the ease of locating those nerves, as was the case in this study, can be

reproduced, relevant international consensus committees should consider classifying ultrasound guided nerve blocks as a core/basic emergency ultrasound skill.

CHAPTER 6

CONCLUSION

There were no statistically significant differences between race groups, between gender groups and between age categories with regard to the position of the mental foramen in relation to the mandibular premolars on both the right and left sides. However, in Blacks, the most common position was found in line with the long axis of the second mandibular premolar. This is in keeping with studies conducted in other black population groups internationally. In Asians, the most frequent position of the mental foramen was found slightly more frequently in line with the long axis of the second mandibular premolar followed very closely by the position between the 1st and 2nd mandibular premolars. There has been variation as to the most common position in other Asian population groups studied. In Whites, the most frequent position of the mental foramen was between the 1st and 2nd mandibular premolars. The same was found in previous studies that were reported in the literature.

Overall in only 3% of cases on the right and 4% of cases on the left the mental foramen was found to be mesial to the 1st premolar or lateral to the 2nd premolar. With advancement in age, there were higher frequencies of subjects who had their mental foramina positioned at more posterior locations.

There were statistically significant differences between race groups and between gender groups with regard to the distances from the mental foramen to the various horizontal hard tissue relations. Distances were however minimal and are not regarded significant from a practical and clinical point of view.

Some of the soft tissue measurements were statistically significant with regard to race groups and gender, whilst others were not. However, differences were minimal and are also not regarded as significant from a practical and clinical point of view.

9% of subjects had asymmetrical mental foramina with regard to its relationship to the mandibular premolar teeth. This was less than in previous studies in other population groups. 3% of subjects had accessory mental foramina. This is in keeping with previous reports of between 3% and 10%.

Ultrasound has emerged as an effective means to detect the position of the mental foramen for clinical purposes. When compared to other modalities used to detect the mental foramen, it is safer, quicker, cheaper and less time consuming. It has also proven to be more sensitive then panoramic and apical radiographs. The presence of facial hair did not prevent the detection of the mental foramen, although more generous amounts of sonar gel were required. Ultrasonography, however, is operator dependant. Therefore with more experience, the time taken to find the mental foramen with ultrasound was shown to be quicker.

REFERENCES

Aktekin, M., Celik, H.M., Celik, H.H., Aldur, M.M. & Aksit, M.D. 2003, "Studies on the location of the mental foramen in Turkish mandibles", *Morphologie : Bulletin de Association des Anatomistes,* vol. 87, no. 277, pp. 17-19.

al Jasser, N.M. & Nwoku, A.L. 1998, "Radiographic study of the mental foramen in a selected Saudi population", *Dentomaxillo Facial Radiology,* vol. 27, no. 6, pp. 341-343.

Al-Khateeb, T., Al-HadiHamasha, A. & Ababneh, K.T. 2007, "Position of the mental foramen in a northern regional Jordanian population", *Surgical and Radiologic Anatomy : SRA,* vol. 29, no. 3, pp. 231-237.

Balcioglu, H.A., Kilic, C., Akyol, M. & Ulusoy, A.T. 2011, "Horizontal migration of pre- and postnatal mental foramen: an anatomic study", *International journal of Pediatric Otorhinolaryngology,* vol. 75, no. 11, pp. 1436-1441.

Bhoi, S., Sinha, T.P., Rodha, M., Bhasin, A., Ramchandani, R. & Galwankar, S. 2012, "Feasibility and safety of ultrasound-guided nerve block for management of limb injuries by emergency care physicians", *Journal of Emergencies, Trauma, and Shock,* vol. 5, no. 1, pp. 28-32.

Chau, A. 2012, "Comparison between the use of magnetic resonance imaging and conebeam computed tomography for mandibular nerve identification", *Clinical Oral Implants Research,* vol. 23, no. 2, pp. 253-256.

Coskun, F., Akinci, E., Ceyhan, M.A. & Sahin Kavakli, H. 2011, "Our new stethoscope in the emergency department: handheld ultrasound", *Ulusal Travma ve Acil Cerrahi Dergisi = Turkish Journal of Trauma & Emergency surgery : TJTES,* vol. 17, no. 6, pp. 488-492.

Chrcanovic, B.R., Abreu, M.H. & Custodio, A.L. 2011, "Morphological variation in dentate and edentulous human mandibles", *Surgical and Radiologic Anatomy : SRA,* vol. 33, no. 3, pp. 203-213.

da Silva Ramos Fernandes, L.M., Capelozza, A.L. & Rubira-Bullen, I.R. 2011, "Absence and hypoplasia of the mental foramen detected in CBCT images: a case report", *Surgical and Radiologic Anatomy : SRA,* vol. 33, no. 8, pp. 731-734.

Fabian, F.M. 2007, "Position, shape and direction of opening of the mental foramen in dry mandibles of Tanzanian adult black males", *Italian Journal of Anatomy and Embryology = Archivio Italiano Dianatomia Edembriologia,* vol. 112, no. 3, pp. 169-177.

Fishel, D., Buchner, A., Hershkowith, A. & Kaffe, I. 1976, "Roentgenologic study of the mental foramen", *Oral Surgery, Oral Medicine, and Oral Pathology,* vol. 41, no. 5, pp. 682-686.

Green, R.M. 1987, "The position of the mental foramen: a comparison between the southern (Hong Kong) Chinese and other ethnic and racial groups", *Oral Surgery, Oral Medicine, and Oral Pathology,* vol. 63, no. 3, pp. 287-290.

Green, R.M. & Darvell, B.W. 1988, "Tooth wear and the position of the mental foramen", *American Journal of Physical Anthropology,* vol. 77, no. 1, pp. 69-75.

Greenstein, G. & Tarnow, D. 2006, "The mental foramen and nerve: clinical and anatomical factors related to dental implant placement: a literature review", *Journal of Periodontology,* vol. 77, no. 12, pp. 1933-1943.

Guo, J.L., Su, L., Zhao, J.L., Yang, L., Lv, D.L., Li, Y.Q. & Cheng, F.B. 2009, "Location of mental foramen based on soft and hard-tissue landmarks in a Chinese population", *The Journal of Craniofacial Surgery,* vol. 20, no. 6, pp. 2235-2237.

Gupta, T. 2008, "Localization of important facial foramina encountered in maxillo-facial surgery", *Clinical Anatomy (New York, N.Y.),* vol. 21, no. 7, pp. 633-640.

Haghanifar, S. & Rokouei, M. 2009, "Radiographic evaluation of the mental foramen in a selected Iranian population", *Indian Journal of Dental Research : official publication of Indian Society for Dental Research,* vol. 20, no. 2, pp. 150-152.

Igbigbi, P.S. & Lebona, S. 2005, "The position and dimensions of the mental foramen in adult Malawian mandibles", *West African Journal of Medicine,* vol. 24, no. 3, pp. 184-189.

Jacobs, R., Mraiwa, N., Van Steenberghe, D., Sanderink, G. & Quirynen, M. 2004, "Appearance of the mandibular incisive canal on panoramic radiographs", *Surgical and Radiologic Anatomy : SRA,* vol. 26, no. 4, pp. 329-333.

Jalili, M.R., Esmaeelinejad, M., Bayat, M. & Aghdasi, M.M. 2012, "Appearance of anatomical structures of mandible on panoramic radiographs in Iranian population", *Acta Odontologica Scandinavica,* vol. 70, no. 5, pp. 384-389.

Jeanmonod, R., Delcollo, J., Jeanmonod, D., Dombchewsky, O. & Reiter, M. 2012, "Comparison of resident and mid-level provider productivity and patient satisfaction in an emergency department fast track", *Emergency Medicine Journal : EMJ,* .

Kalender, A., Orhan, K. & Aksoy, U. 2012, "Evaluation of the mental foramen and accessory mental foramen in Turkish patients using cone-beam computed tomography images reconstructed from a volumetric rendering program", *Clinical Anatomy (New York, N.Y.),* vol. 25, no. 5, pp. 584-592.

Kim, I.S., Kim, S.G., Kim, Y.K. & Kim, J.D. 2006, "Position of the mental foramen in a Korean population: a clinical and radiographic study", *Implant Dentistry,* vol. 15, no. 4, pp. 404-411.

Kqiku, L., Sivic, E., Weiglein, A. & Stadtler, P. 2011, "Position of the mental foramen: an anatomical study", *Wiener Medizinische Wochenschrift (1946),* vol. 161, no. 9-10, pp. 272-273.

Kulkarni, S., Kumar, S., Kamath, S. & Thakur, S. 2011, "Accidental identification of accessory mental nerve and foramen during implant surgery", *Journal of Indian Society of Periodontology,* vol. 15, no. 1, pp. 70-73.

Liang, X., Jacobs, R., Hassan, B., Li, L., Pauwels, R., Corpas, L., Souza, P.C., Martens, W., Shahbazian, M., Alonso, A. & Lambrichts, I. 2010, "A comparative evaluation of Cone Beam Computed Tomography (CBCT) and Multi-Slice CT (MSCT) Part I. On subjective image quality", *European Journal of Radiology,* vol. 75, no. 2, pp. 265-269.

Loudon, J. 2011, "Beware the mental foramen", *British Dental Journal,* vol. 210, no. 7, pp. 293.

Mbajiorgu, E.F., Mawera, G., Asala, S.A. & Zivanovic, S. 1998, "Position of the mental foramen in adult black Zimbabwean mandibles: a clinical anatomical study", *The Central African Journal of Medicine,* vol. 44, no. 2, pp. 24-30.

Meechan, J.G. 2011, "The use of the mandibular infiltration anesthetic technique in adults", *Journal of the American Dental Association (1939),* vol. 142 Suppl 3, pp. 19S-24S.

Moiseiwitsch, J.R. 1998, "Position of the mental foramen in a North American, white population", *Oral Surgery, Oral Medicine, Oral Pathology, Oral Radiology, and Endodontics,* vol. 85, no. 4, pp. 457-460.

Mwaniki, D.L. & Hassanali, J. 1992, "The position of mandibular and mental foramina in Kenyan African mandibles", *East African Medical Journal,* vol. 69, no. 4, pp. 210-213.

Naitoh, M., Hiraiwa, Y., Aimiya, H., Gotoh, K. & Ariji, E. 2009, "Accessory mental foramen assessment using cone-beam computed tomography", *Oral Surgery, Oral Medicine, Oral Pathology, Oral Radiology, and Endodontics,* vol. 107, no. 2, pp. 289-294.

Neo, J. 1989, "Position of the mental foramen in Singaporean Malays and Indians", *Anesthesia Progress,* vol. 36, no. 6, pp. 276-278.

Neves, F.S., Torres, M.G., Oliveira, C., Campos, P.S. & Crusoe-Rebello, I. 2010, "Lingual accessory mental foramen: a report of an extremely rare anatomical variation", *Journal of Oral Science,* vol. 52, no. 3, pp. 501-503.

Ngeow, W.C. & Yuzawati, Y. 2003, "The location of the mental foramen in a selected Malay population", *Journal of Oral Science,* vol. 45, no. 3, pp. 171-175.

Oguz, O. & Bozkir, M.G. 2002, "Evaluation of location of mandibular and mental foramina in dry, young, adult human male, dentulous mandibles", *The West Indian Medical Journal,* vol. 51, no. 1, pp. 14-16.

Olasoji, H.O., Tahir, A., Ekanem, A.U. & Abubakar, A.A. 2004, "Radiographic and anatomic locations of mental foramen in northern Nigerian adults", *The Nigerian Postgraduate Medical Journal,* vol. 11, no. 3, pp. 230-233.

Parnia, F., Moslehifard, E., Hafezeqoran, A., Mahboub, F. & Mojaver-Kahnamoui, H. 2012, "Characteristics of anatomical landmarks in the mandibular interforaminal region: a cone-beam computed tomography study", *Medicina Oral, Patologia Oral y Cirugia Bucal,* vol. 17, no. 3, pp. e420-5.

Phillips, J.L., Weller, R.N. & Kulild, J.C. 1992, "The mental foramen: 3. Size and position on panoramic radiographs", *Journal of Endodontics,* vol. 18, no. 8, pp. 383-386.

Phillips, J.L., Weller, R.N. & Kulild, J.C. 1990, "The mental foramen: 1. Size, orientation, and positional relationship to the mandibular second premolar", *Journal of Endodontics,* vol. 16, no. 5, pp. 221-223.

Pria, C.M., Masood, F., Beckerley, J.M. & Carson, R.E. 2011, "Study of the inferior alveolar canal and mental foramen on digital panoramic images", *The Journal of Contemporary Dental Practice,* vol. 12, no. 4, pp. 265-271.

Ramadhan, A., Messo, E. & Hirsch, J.M. 2010, "Anatomical variation of the mental foramen. A case report", *Stomatologija / issued by public institution "Odontologijosstudija" ...[et al.],* vol. 12, no. 3, pp. 93-96.

Ritter, L., Mischkowski, R.A., Neugebauer, J., Dreiseidler, T., Scheer, M., Keeve, E. & Zoller, J.E. 2009, "The influence of body mass index, age, implants, and dental restorations on image quality of cone beam computed tomography", *Oral Surgery, Oral Medicine, Oral Pathology, Oral Radiology, and Endodontics,* vol. 108, no. 3, pp. e108-16.

Rocco, V.J. 2010, 28 June 2010-last update*, Mental Nerve Block* [Homepage of Medscape], [Online]. Available:http://emedicine.medscape.com/article/82603-overview#showall [2012, July 31].

Sankar, D.K., Bhanu, S.P. & Susan, P.J. 2011, "Morphometrical and morphological study of mental foramen in dry dentulous mandibles of South Andhra population of India", *Indian Journal of Dental Research : official publication of Indian Society for Dental Research,* vol. 22, no. 4, pp. 542-546.

Santini, A. & Alayan, I. 2012, "A comparative anthropometric study of the position of the mental foramen in three populations", *British Dental Journal,* vol. 212, no. 4, pp. E7.

Shah, S., Vaze, S. & Kinhal, K. 2010, "A variation in the position of the mental foramen: a case report", *Journal of Maxillofacial and Oral Surgery,* vol. 9, no. 3, pp. 307-309.

Shankland, W.E. 1994, "The position of the mental foramen in Asian Indians", *The Journal of Oral Implantology,* vol. 20, no. 2, pp. 118-123.

Shibli, J.A., Martins, M.C., Loffredo, L.C. & Scaf, G. 2012, "Detection of the mandibular canal and the mental foramen in panoramic radiographs: intraexaminer agreement", *The Journal of Oral Implantology,* vol. 38, no. 1, pp. 27-31.

Smajilagic, A. & Dilberovic, F. 2004, "Clinical and anatomy study of the human mental foramen", *Bosnian Journal of Basic Medical Sciences / Udruzenje Basicnih Medicine Skihz Nanosti = Association of Basic Medical Sciences,* vol. 4, no. 3, pp. 15-23.

Smith, J.D., Surek, C.C. & Cortez, E.A. 2010, "Localization of the supraorbital, infraorbital, and mental foramina using palpable, bony landmarks", *Clinical Anatomy (New York, N.Y.),* vol. 23, no. 4, pp. 495-499.

Smith, M.H. & Lung, K.E. 2006, "Nerve injuries after dental injection: a review of the literature", *Journal (Canadian Dental Association),* vol. 72, no. 6, pp. 559-564.

Soikkonen, K., Wolf, J., Ainamo, A. & Xie, Q. 1995, "Changes in the position of the mental foramen as a result of alveolar atrophy", *Journal of Oral Rehabilitation,* vol. 22, no. 11, pp. 831-833.

Song, W.C., Kim, S.H., Paik, D.J., Han, S.H., Hu, K.S., Kim, H.J. & Koh, K.S. 2007, "Location of the infraorbital and mental foramen with reference to the soft-tissue landmarks", *Plastic and Reconstructive Surgery,* vol. 120, no. 5, pp. 1343-1347.

Traxler, M., Ulm, C., Solar, P. & Lill, W. 1992, "Sonographic measurement versus mapping for determination of residual ridge width", *The Journal of Prosthetic Dentistry,* vol. 67, no. 3, pp. 358-361.

Wells, M. 2010, *Local and Regional Anaesthesia in the Emergency Department Made Easy,* Churchill Livingstone Elsivier, London.

Yasar, F., Yesilova, E. & Apaydin, B. 2011. “The effects of compression on the image quality of digital panoramic radiographs”, *Clinical Oral Investigations,* vol. 16, no. 3, pp. 719-726.

Yesilyurt, H., Aydinlioglu, A., Kavakli, A., Ekinci, N., Eroglu, C., Hacialiogullari, M. & Diyarbakirli, S. 2008, "Local differences in the position of the mental foramen", *Folia Morphologica,* vol. 67, no. 1, pp. 32-35.

APPENDICES

Appendix 1

Ethics clearance certificate

UNIVERSITY OF THE WITWATERSRAND, JOHANNESBURG
Division of the Deputy Registrar (Research)

HUMAN RESEARCH ETHICS COMMITTEE (MEDICAL)
R14/49 Dr Abdullah E Laher

CLEARANCE CERTIFICATE	M110920
PROJECT	The Ultrasonographic Determination of the Position of the Mental Foramen in Relation to Hard to hard and Soft Tissue Landmarks in a Selected South African Black and Caucasian Adult Population
INVESTIGATORS	Dr Abdullah E Laher.
DEPARTMENT	Department of Emergency Medicine
DATE CONSIDERED	30/09/2011
M1109200DECISION OF THE COMMITTEE*	Approved unconditionally

Unless otherwise specified this ethical clearance is valid for 5 years and may be renewed upon application.

DATE 25/11/2011 **CHAIRPERSON** .....
(Professor PE Cleaton-Jones)

*Guidelines for written 'informed consent' attached where applicable
cc: Supervisor : Dr Mike Wells

DECLARATION OF INVESTIGATOR(S)

To be completed in duplicate and **ONE COPY** returned to the Secretary at Room 10004, 10th Floor, Senate House, University.
I/We fully understand the conditions under which I am/we are authorized to carry out the abovementioned research and I/we guarantee to ensure compliance with these conditions. Should any departure to be contemplated from the research procedure as approved I/we undertake to resubmit the protocol to the Committee. **I agree to a completion of a yearly progress report.**

PLEASE QUOTE THE PROTOCOL NUMBER IN ALL ENQUIRIES...

Appendix 2

Patient Data Collection Sheet

Subject number: _____

1) Exclusion criteria

	Yes	No
Missing mandibular teeth between the right and left lower 1st molars		
Previous mandibular surgery		
Presence of any facial abnormalities (congenital/acquired)		
Age < 18 yrs		

2) Demographic Data

Age: yrs	
18 – 30	
31 – 40	
41 – 50	
51 – 60	
61 – 70	
> 70	

Sex:

Male	**Female**

Race:

Black	***Caucasian***

3) Position of mental foramina:

Position:	**Right**	**Left**
	Hard tissue relations	
Vertical	*1 / 2 / 3 / 4 / 5	*1 / 2 / 3 / 4 / 5
Horizontal	Distance from cusp: _____mm (a) Distance from lower mandibular border: _____mm (b) (a) / (a) + (b) : _____%	Distance from cusp: _____mm (a) Distance from lower mandibular border: _____mm (b) (a) / (a) + (b) : _____%
	Soft tissue relations	
	Distance from chelion	
Horizontal	_____mm	_____mm
Vertical	_____mm	_____mm
	Distance from inferior border of mandible	
Vertical	_____mm	_____mm

*1- mesial to 1st premolar, 2- in line with the long axis of the 1st premolar, 3 - between 1st and 2nd premolars, 4 - in line with the long axis of the 2nd premolar, 5 - lateral to 2nd premolar

4) Remarks / Incidental findings: _____

_____

Appendix 3

Tables and graph not included under the chapter entitled results

Table 10: The impact of race on the position of the mental foramen with regard to vertical hard tissue relations on the right (HVR) side

HVR position	Race		
	Black (n/%)	**Asian (n/%)**	**White (n/%)**
1	0 0%	1 4%	0 0%
2	4 8%	3 12%	5 20%
3	18 36%	10 40%	13 52%
4	26 52%	11 44%	7 28%
5	2 4%	0 0%	0 0%
Fisher's exact test (P=0.264)			

HVR - vertical hard tissue relation on the right side. **Position 1** - mesial to 1st premolar. **Position 2** - in line with the long axis of the 1st premolar. **Position 3** - between 1st and 2nd premolars. **Position 4** - in line with the long axis of the 2nd premolar. **Position 5** - lateral to 2nd premolar.

Table 11: The impact of race on the position of the mental foramen with regard to vertical hard tissue relations on the left (HVL) side

HVL position	Race		
	Black (n/%)	**Asian (n/%)**	**White (n/%)**
1	0 0%	1 4%	0 0%
2	3 6%	2 8%	4 16%
3	19 38%	10 40%	15 60%
4	25 50%	12 48%	6 24%
5	3 6%	0 0%	0 0%
Fisher's exact test (P=0.121)			

HVL - vertical hard tissue relation on the left side. **Position 1** - mesial to 1st premolar. **Position 2** - in line with the long axis of the 1st premolar. **Position 3** - between 1st and 2nd premolars. **Position 4** - in line with the long axis of the 2nd premolar. **Position 5** - lateral to 2nd premolar.

Table 12: The impact of sex on the position of the mental foramen with regard to vertical hard tissue relations on the right (HVR) side

HVR position	Gender	
	F	M
1	0 0.0	1 2.0
2	8 16.0	4 8.0
3	20 40.0	21 42.0
4	21 42.0	23 46.0
5	1 2.0	1 2.0
Fisher's exact test (P=0.766)		

HVR - vertical hard tissue relation on the right side. **Position 1** - mesial to 1st premolar. **Position 2** - in line with the long axis of the 1st premolar. **Position 3** - between 1st and 2nd premolars. **Position 4** - in line with the long axis of the 2nd premolar. **Position 5** - lateral to 2nd premolar.

Table 13: The impact of sex on the position of the mental foramen with regard to vertical hard tissue relations on the left (HVL) side

HVL position	Gender	
	F	M
1	0 0.0	1 2.0
2	7 14.0	2 4.0
3	22 44.0	22 44.0
4	20 40.0	23 46.0
5	1 2.0	2 4.0
Fisher's exact test (P=0.387)		

HVL - vertical hard tissue relation on the left side. **Position 1** - mesial to 1st premolar. **Position 2** - in line with the long axis of the 1st premolar. **Position 3** - between 1st and 2nd premolars. **Position 4** - in line with the long axis of the 2nd premolar. **Position 5** - lateral to 2nd premolar.

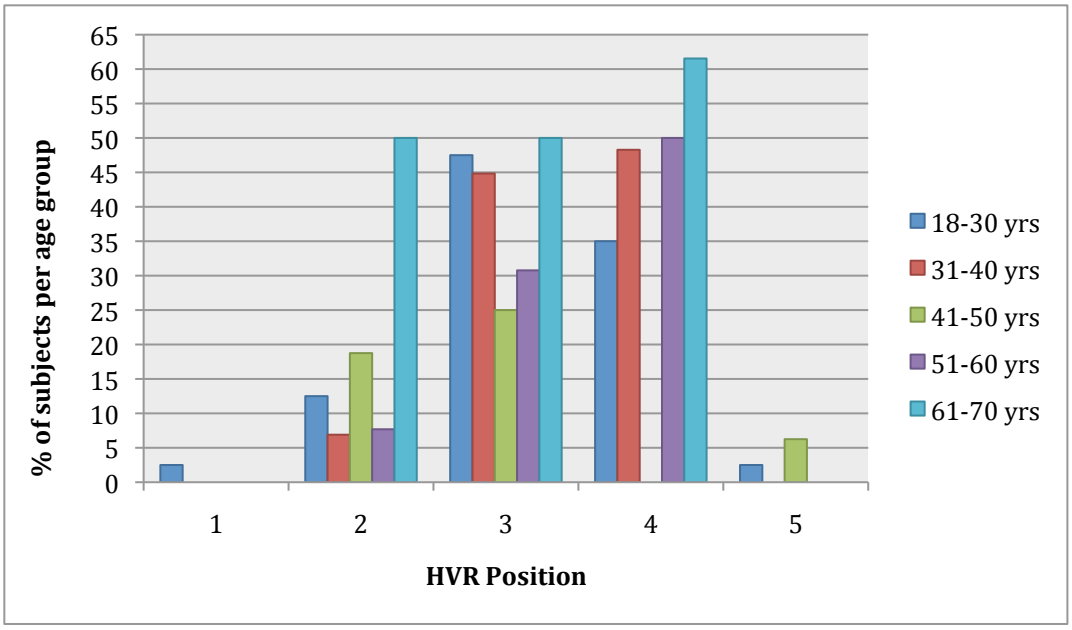

HVR - vertical hard tissue relation on the right side. **Position 1** - mesial to 1st premolar. **Position 2** - in line with the long axis of the 1st premolar. **Position 3** - between 1st and 2nd premolars. **Position 4** - in line with the long axis of the 2nd premolar. **Position 5** - lateral to 2nd premolar.

Figure 16: The impact of age on the position of the mental foramen with regard to vertical hard tissue relations on the right side (HVR)

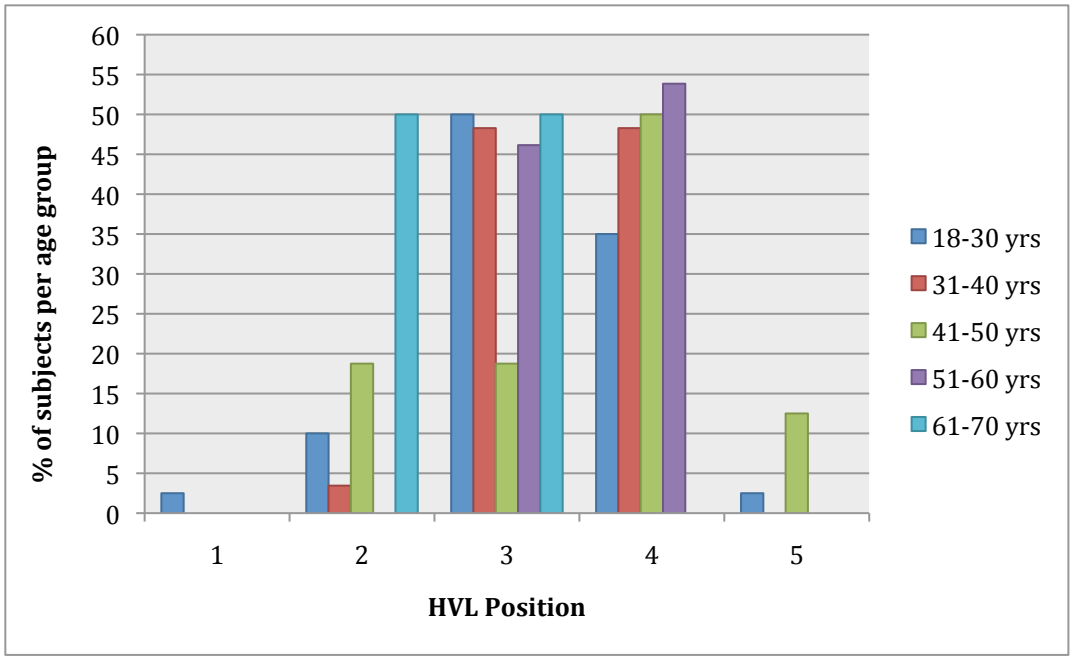

HVL - vertical hard tissue relation on the left side. **Position 1** - mesial to 1st premolar. **Position 2** - in line with the long axis of the 1st premolar. **Position 3** - between 1st and 2nd premolars. **Position 4** - in line with the long axis of the 2nd premolar. **Position 5** - lateral to 2nd premolar.

Figure 17: The impact of age on the position of the mental foramen with regard to vertical hard tissue relations on the left side (HVL)