

https://dspace.org/

The types and prevalence of patholgies related to impacted mandibular third molars based on panoramic radiographs

Hari, Anisha Anil

2024

University of the Witwatersrand, Johannesburg

https://hdl.handle.net/10539/42759

Hari, Anisha Anil. (2024). The types and prevalence of patholgies related to impacted mandibular third molars based on panoramic radiographs [Master's dissertation, University of the Witwatersrand, Johannesburg]. WireDSpace. https://hdl.handle.net/10539/42759

Downloaded from a DSpace repository. https://dspace.org/



UNIVERSITY OF THE
WITWATERSRAND,
JOHANNESBURG

THE TYPES AND PREVALENCE OF PATHOLGIES RELATED TO IMPACTED MANDIBULAR THIRD MOLARS BASED ON PANORAMIC RADIOGRAPHS

Anisha Anil Hari

"A Research Report submitted to the Faculty of Health Science, University of Witwatersrand, Johannesburg, in partial fulfilment of the requirements for the degree of Master of Science in Dentistry, in the Department of Maxillofacial and Oral Surgery."

School of Oral Health Sciences, Faculty of Health Sciences
University of the Witwatersrand,
Johannesburg
20 May 2024

DECLARATION

I, Anisha Anil Hari (student number: **835 676**), hereby declare that this research report and the work herein is my own, original work. It is being submitted for the degree of Master of Science in Dentistry, in the Department of Maxillofacial and Oral Surgery at the University of the Witwatersrand, Johannesburg.

Neither the whole work nor any part of it has been, is being, or is to be submitted for another degree or examination in this or any other University.

Signature : 

Date: 20 May 2024

DEDICATION

I dedicate this work to:

My dear parents, Anil and Chandani Hari for believing in me, supporting me and encouraging me to fiercely pursue my dreams.

ABSTRACT

Introduction

An impacted tooth may be defined as a pathological situation where the tooth is prevented from attaining a typical functional position. Impacted mandibular third molars are a frequent dental concern worldwide that may lead to a variety of other pathologies. This study aims to determine the prevalence and types of pathologies related to impacted mandibular third molars based on panoramic radiographs within a South African setting.

Methods

Panoramic radiographs were utilized to analyse pathologies related to impacted mandibular third molars through a cross sectional retrospective study. 600 radiographs were assessed. Patients of any age who were referred from the Maxillofacial and Oral Surgery department to the Radiology department for a panoramic radiograph relating to impacted mandibular third molars at Wits Oral Health Centre during a 5-year period from (2016 to 2020) were included in this study. Data was extracted by a single examiner to ensure diagnostic reproducibility.

Results

A total of 271 (45,0%) patients were female, and 329 (55,0%) patients were male.

The patients' ages varied from 15 to 79 years old, with a mean age of 29,55 years.

The age group between 20 and 29 years old (n = 288, 48,0%) had the highest frequency of pathology, followed by the 30-39-year-old age group (n = 219, 36,5%). Among all age groups, those over 50 represented the lowest percentage of pathology, with 8 individuals (1,3%).

In terms of pathologies found, caries on the impacted third molar was the most prevalent (n=169, 28,1%) followed by caries on the adjacent second molar (n=136, 22,6%) while 72 patients presented with both caries on the impacted mandibular third molar as well as the adjacent second molar. 128 radiographs presented with peri-coronal radiolucent lesions. Periodontal bone loss accounted for 40 patients. Root resorption was the least prevalent pathology detected with a total of 4 patients.

Conclusion

The findings of this study along with parallels from the literature, indicates that caries is the most frequent pathology associated with impacted mandibular third molars. Caries may be seen on both the impacted third molar itself as well as the adjacent second molar and may be seen mostly between the ages of 30-49 years, with a higher predilection for males.

Seeing that caries is so prevalent within the South African population, treatment or intervention of impacted mandibular third molars would be advisable.

Keywords

Impactions

Mandibular third molars

Pathologies

Panoramic radiographs

ACKNOWLEDGEMENTS

In completion of this work, I would like to sincerely thank:

Firstly, my supervisor, Dr. E.T. Mabaso for his patience, guidance and encouragement throughout the research process. I would like to express my heartfelt gratitude for all I have learnt and for opening my eyes to the world of research and academics.

To the staff of the WOHC Radiology department for allowing me the time in the department to collect my data and for the encouragement during the process.

To Dr. Zvifadzo Matsena- Zingoni and Anthony O' Donnell for their help with the statistical aspect of the study.

To my siblings, Reshma, Seema and Rindhir for always checking in on me and encouraging me to move forward.

Lastly, to my husband, Vishant, for your support, motivation and encouragement throughout this process.

TABLE OF CONTENTS

DECLARATION ii

DEDICATION iii

ABSTRACT iv

ACKNOWLEDGEMENTS vi

TABLE OF CONTENTS vii

CHAPTER 1: INTRODUCTION 1

CHAPTER 2: LITERATURE REVIEW 4

AIM AND OBJECTIVES OF THE STUDY 14

AIM 14

HYPOTHESIS 14

OBJECTIVES 14

CHAPTER 3: METHODOLOGY 15

3.1 Study Design 15

3.2 Data Collection 15

3.3 Sample size 16

3.4 Inclusion Criteria 16

3.5 Sample size 16

3.6 Data Analysis 16

3.7 Ethical Considerations 17

3.8 Data collection Limitations 17

CHAPTER 4: RESULTS 18

CHAPTER 5: DISCUSSION AND CONCLUSION 23

5.1 Discussion 28

5.2 Study limitations 29

5.3 Conclusion 30

5.4 Future recommendations 31

REFERENCES 32

APPENDICES 39

APPENDIX A: Plagiarism Declaration 39
APPENDIX B: Turnitin Report 40
APPENDIX C: Ethics Clearance 41
APPENDIX D: Permission Letter from CEO of CMJAH 42
APPENDIX E: Permission from HOD of Maxillofacial and Oral Surgery 43
APPENDIX F: Data Collection Sheet 44

LIST OF FIGURES

Figure 1: Pie chart representing age categories and their corresponding percentages…… 19

Figure 2: Histogram and box-and-whisker plots for age distribution……..20

Figure 3: Pie chart depicting distribution of pathologies……21

LIST OF TABLES

Table 1: Distribution of age group of patients presenting with pathologies related to an impacted lower third molar……..20

Table 2: Distribution of associated pathology with gender of patients……22

Table 3: Distribution of associated pathology with age group of patients……23

Table 4: Various studies being compared with regard to the prevalence of pathologies related to impacted mandibular third molars……25

Table 5: Various studies being compared with regard to the gender predilection in terms prevalence of pathologies related to impacted mandibular third molars……28

Table 6: Various studies being compared with regard to the mean age of patients in terms prevalence of pathologies related to impacted mandibular third molar……30

CHAPTER 1: INTRODUCTION

An impacted tooth may be defined as a pathological situation where the tooth is prevented from attaining a typical functional position (Santosh, 2015). Various teeth may present as impacted, however, the mandibular third molar is by far the most commonly affected tooth followed closely by maxillary third molars (Altan and Akbulut, 2019; Nazir *et al.*, 2014). Third molars, commonly referred to as wisdom teeth (Ishwarkumar *et al.*, 2019)., are generally the very last teeth to erupt in an individual's dentition and eruption normally occurs between the ages of 17 and 23 years (Indira *et al*., 2013).

There are various reasons put forth to explain why teeth become impacted.
Some explanations include dense overlying bone, deficiency of space between the second and third molar, soft tissue covering, abnormal positioning of the tooth bud or other pathological conditions (Nazir *et al.*, 2014).

Impacted teeth can either remain asymptomatic or may be associated with a number of pathologies such as caries of both the impacted third molar as well as the adjacent second molar, pericoronitis, cysts, tumours, as well as root resorption of the neighbouring tooth (Bouloux *et al.,* 2007). Pathologies associated with third molars may present as clinically recognizable or may be asymptomatic, however; the lack of symptoms does not equate to the lack of disease (Braimah *et al.*, 2018).

Several pathologies that are related to impacted mandibular third molars may cause substantial amounts of pain and discomfort to the patient.
There are various published articles that have put forward recommendations for the management of impacted mandibular third molars (Krishnan *et al.*, 2009) . It was shown that pathology such as pericoronitis , untreatable caries, root resorption of either the impacted tooth itself or the adjacent tooth, cysts and tumours are all well-defined standards for third molar removal.

The management of impacted third molars should aim to re-establish the patient's oral health and general well-being by relieving symptoms such as pain, infection or inflammation.

Depending on the type of pathology associated with the impacted molar, treatment options may include extraction of the impacted third molar itself, extraction of the adjacent tooth, enucleation of a cyst or operculectomy of gingival tissue supplemented with pharmaceuticals such as antibiotics to treat infection, as well as analgesics and anti-inflammatory drugs where indicated to mitigate pain and inflammation.

While extraction of impacted mandibular third molars are one of the most common oral surgical procedures performed in dental practices, numerous researchers have probed the need of extraction in asymptomatic or pathology free patients (Chu *et al.,* 2003).
Literature surrounding the potential for development of pathologies associated with impacted third molars has found conflicting results. For example, (Sewerin and von Wowern, 1998), demonstrated no pathologic changes in the vicinity of asymptomatic impacted third molars, while a similar study conducted by (Girod *et al.*, 1993) reported the potential of cyst formation in purposefully retained impacted mandibular third molars. The researchers emphasized that dentigerous cysts were the most frequent type of cyst to develop.

Impacted third molars are very frequently seen in general dental practice in South Africa (Ishwarkumar *et al.*, 2019). Dentists and oral surgeons have an obligation to prioritise the interests of the patient during the assessment of disadvantages and benefits of third molar removal thus it is essential for them to know the pathologic conditions associated with impacted mandibular third molars.

As individuals age, the morbidity associated with surgery ,infection or general anaesthesia increases. Hence, it is imperative to factor in these considerations when patients are informed about the benefits and risks of third molar extraction (Girod *et al.*, 1993).

Knowledge regarding the prevalence of pathologies gives clinicians an idea of how frequently they may come across a particular pathology as well as the type of pathology to be on the lookout for in routine oral examinations.

Several studies have been carried out in European, Middle Eastern (Al-Wusaybie *et al.*, 2023), Asian (Tai *et al.,* 2023) and other African populations (Braimah *et al.*, 2018) regarding pathologies related to impacted mandibular third molars, however data in South Africa is limited.

This indicates a need for research and literature on the prevalence and types of pathologic conditions that can develop in association with impacted third molars within a South African setting.

CHAPTER 2: LITERATURE REVIEW

Impacted mandibular third molars are a frequent dental concern that may lead to a variety of other pathologies. This literature review provides a complete assessment of current research on the prevalence, types, and detection techniques of pathologies that are associated with impacted mandibular third molars.

Pathologies Associated with Impacted Mandibular Third Molars

Impacted mandibular third molars are not merely an occurrence of interest in dental healthcare; rather, they are a substantial source of potential oral pathologies. Impacted molars may cause a variety of oral health problems. The failure of these teeth to erupt correctly inside the oral cavity may lead to a range of complications, some of which include pericoronitis, dental caries, periodontal abnormalities, root resorption, cystic alterations, and, in very rare instances, neoplasms (Venta et al., 2019; Tai et al., 2021).

Caries associated with the impacted third molar is a frequent issue that is linked to impacted teeth. Caries may occur in both the impacted third molars and the neighbouring second molars. Al-Wusaybie *et al.* (2023) found that dental caries were associated with 23,1% of impacted third molars and 11,5% of neighbouring second molars' distal surfaces in a Saudi Arabian population.

Similarly, research conducted in China by (Tai *et al.,* 2023) revealed that the incidence of dental lesions in impacted third molars was 6,98%, whereas the incidence of periodontal lesions was 37,81%. The sequential effect of impactions was highlighted in a study that was conducted in China (Tai *et al.,* 2023). The study indicated that 24,63 percent of dental lesions and 35,3 percent of periodontal lesions were discovered on the distal aspect of neighbouring second molars.

However, a pathology that cannot be diagnosed on radiographs is pericoronitis. Literature suggests that it is seemingly the most widespread pathology related to impacted mandibular third molars (Ye *et al.*, 2021). It is an inflammatory lesion of the tissues that surround the crown of a tooth that is only partly erupted or that is impacted. In a study conducted in Al Ahsa, Saudi Arabia, pericoronitis was linked to 61,5% of impacted third molars (Al-Wusaybie et al., 2023).

However, not all impacted third molars lead to complications, despite the high prevalence of these conditions. The observation of a considerable proportion of symptom-free impacted third molars in a Finnish population by (Venta *et al.,* 2019) highlights the relevance of patient-specific variables and unique clinical presentations in the pathogenesis of impacted third molar-related complications.

In general, the presence of an impacted third molar might be considered to be a potential risk for a number of oral pathologies. On the other hand, the development of these pathologies is not a given and may be contingent on patient-specific variables such as oral hygiene, age, immunological condition, and genetic predisposition. As a result, it is essential to conduct routine monitoring on patients who have impacted third molars in order to recognise early indicators of potential pathologies and to provide therapy in a timely manner so as to avoid future complications. In order to properly treat impacted third molars, it is crucial to strike a careful balance between the two management strategies of cautious waiting and intervention.

Prevalence of Impacted Mandibular Third Molars Worldwide

Understanding the prevalence, pathogenesis, and potential complications of impacted mandibular third molars, frequently known as wisdom teeth, is a significant concern in dental treatment worldwide. These findings are important since there is a considerable prevalence of this dental condition in a variety of groups. However, the prevalence of impacted third molars seems to be influenced by a number of variables, including genetic predisposition, environmental factors, and dietary habits (Passi *et al*., 2019; Bamdadianf, 2018). The

incidence rates of impacted third molars vary substantially across various locations and ethnic groups.

For example, according to the conclusions of a study that was conducted out in Al Ahsa, Saudi Arabia, 27,1% of Saudi patients presented with a minimum of one impacted tooth, with mandibular third molars being the most prevalent form of impacted tooth (Al-Wusaybie *et al*., 2023). This research was carried out in a retrospective manner. Rauf *et al.* (2023) conducted research that was based on a Pakistani population found that impacted mandibular third molars were substantially associated with gender. This indicates that gender-specific genetic variables may play a potentially major role in the pathogenesis of impacted teeth.

Similarly, a research conducted on the population of North Cyprus found that 60% of the third molars that were examined had been impacted, and there were no significant variations between the genders in this regard. According to the findings of the same research (Genc *et al.*, 2023), the incidence of impacted third molars appeared to be greatest in individuals between the ages of 20 and 29.
This pattern highlights the need for suitable treatment options for impacted teeth in individuals of this age range, as well as the need of early detection.

It is interesting to see that not only does the prevalence of impaction varies amongst groups, but also the patterns of impaction differ from one population to the next. The direction and location of the impacted mandibular third molars, often known as the impaction pattern, may vary quite a bit from one group to the next. For instance, the most frequent kind of impaction in Pakistani and North Cyprus populations was mesioangular, whereas the most common type of impaction in a Jordanian population was vertical (Rauf *et al.,* 2023; Genc *et al.,* 2023; Baiteneh *et al.*, 2002).

Because of the great variety of impaction patterns and the varying prevalence of this condition, it is necessary to develop care techniques for impacted third molars that are tailored to either the population or the location. In addition, it highlights how important it is to take into consideration demographic factors like age and gender, in addition to the

patient's clinical presentation, when making judgements on diagnostic and therapeutic approaches.

Prevalence and types of pathologies related to impacted third molars within an African setting

Several studies related to the prevalence and types of pathologies associated with impacted third molars have been carried out in various parts of the world (Al-Wusaybie *et al.*, 2023; Tai *et al.,* 2023) however data in Africa is still limited.

Saisha *et al.,* (2023) studied the clinical presentation of impacted teeth and its influence on the adjacent tooth in Lusaka, Zambia. This study was conducted in a prospective manner and hence soft tissue pathology was included in the findings.
The researchers found that clinical presentations in this study were 76% pain and swelling while 69% were dental caries. The most prevalent pathology seen on the adjacent tooth was dental caries, gingival pathology and periodontal pockets.
The diagnostic modality was intraoral radiographs in contrast to several other studies including the current one where panoramic radiographs were used in diagnosis.
This may imply that even in 2023, access to panoramic radiography in Africa is still limited. We also see this in South Africa as many primary healthcare centres do not have access to panoramic radiographs which should be a gold standard when extracting impacted third molars.
While supportive care was used to treat the adjacent second molar, surgical extraction was the course of treatment for the affected third molar.

Two studies were done in Nigeria. Osunde and Bassey, (2016) focussed on the pattern of impacted third molars in Nigeria. They authors found a low prevalence rate of impacted third molars (4,7%). They have hypothesised that this is due to the diet of the population in area which is mainly vegetables, sea foods and dairy products rich in calcium. They have attributed bone development to this. They have also indicated that chewing these natural foods may act as a stimulus for bone growth via functional adaptation and hence the mandible has enough space to accommodate the third molar.

Braimah *et al.,* (2018) focussed on evaluating the types of associated pathologies with impacted third molars in Sub-Saharan Africans.
The authors discovered that the mesioangular impaction pattern was the most prevalent, which is consistent with several other studies. They also found that the majority of related pathologies (27,4%) were caused by pathological pockets and caries on both the lower second molar and impacted third molar teeth.

In contrast to Osunde and Bassey (2016), (Braimah *et al.,* 2018) focussed solely on patients who had been referred for extractions as opposed to the general population. This bias increases the prevalence of pathologies found.

Two studies have also been conducted in South Africa. Skyes *et al.,* (2022) investigated the classification and prevalence of mandibular third molar impactions and associated second molar pathology within a population group in Gauteng.

This study indicated that there is no gender predilection with regards to impacted mandibular third molars, with the majority of patients who had symptoms being between the ages of 24 and 33. Mesially angulated impactions were the most prevalent type of impaction. These were also linked to inferior alveolar nerve involvement and a greater degree of tooth destruction on neighbouring second molars. The authors suggest that this implies that CBCT scans should routinely be taken in addition to panoramic radiographs in order to facilitate clinical decision making and evaluating the risk of inferior alveolar nerve injury. Although this would be ideal, access to even routine panoramic radiographs is limited in South Africa.

Ishwarkumar *et al.,* (2019) investigated the prevalence of impacted third molars in the eThekwini Metropolitan Region within a South African Indian population. At least one impacted third molar was seen in 81% of individuals with mandibular occurrence being considerably higher in both genders. However, impactions in general were more prevalent in females. The authors also found that mesially angulated impactions are the most prevalent which is in keeping with the findings of (Skyes *et al.,* 2022).

Panoramic Radiography and Emerging Diagnostic Tools

Panoramic radiographs, which have been used for a long time in the field of dental diagnostics, provide a view that is all-encompassing of the patient's whole dental arch (Jaro & Trybek, 2021). These imaging methods are very helpful in determining the existence and location of impacted mandibular third molars, as well as in detecting any pathologies that may be associated with this condition (Kuhnisch *et al*., 2022). (Akarslan and Kocabay, 2019) This kind of radiographic imaging provides a comprehensive view of the oral cavity, allowing for the detection of any abnormalities that could go missed during a typical clinical examination.

Even though it has a wide range of applications, panoramic radiography still has certain inherent restrictions. The two-dimensional nature of this imaging modality makes it difficult to conduct a comprehensive analysis of the spatial interaction between impacted teeth and neighbouring anatomical structures (Ravikumar *et al*., 2018; Nascimento *et al.,* 2022). This might possibly have an effect on the accuracy of diagnoses and risk assessments, which can then lead to management measures that are less than optimum (Choi *et al.,* 2022). In addition, this approach may sometimes generate distortion, enlargement, or superimposition of structures, all of which may make the interpretation of the picture more difficult (Murakami *et al.,* 2021).

In view of these obstacles, current technological breakthroughs provide potential opportunities for the further development of dental diagnostics. For example, prior to the surgical extraction of impacted lower third molars, three-dimensional imaging can be used to estimate the likelihood of postoperative inferior alveolar nerve impairment. Eyrich *et al.,* (2011) reported a low inferior alveolar nerve injury rate when compared to similar study groups in the literature from the pre-3D imaging era suggesting that the availability of 3D information is actually lowering the risk of nerve injury following lower third molar removal

However, in contrast with what was found by (Eyrich *et al.,* 2011), a study conducted by Mabongo and Tekiso in 2019 concluded that the additional information that may be identified

on a cone beam computed tomography scan did not necessarily reduce the incidence of injury to the inferior alveolar nerve.

The introduction of artificial intelligence (AI) and machine learning (ML) marks the beginning of a revolution in the field of dentistry, including the diagnosis and treatment of impacted third molars (Celik, 2022; Ongkosuwito *et al.*, 2022).

Pathologic changes related to impacted mandibular third molars found in routine dental examinations

In order to understand the need for routine surveillance and radiography at a primary healthcare level within South Africa, it is essential to appreciate what the literature says about the pathological changes which can be detected early by these methods.

Cystic alterations, with dentigerous cysts being the most prevalent kind of developmental cysts, are also frequently associated with impacted mandibular third molars. These cysts, if left untreated, have the potential to develop into very large cysts, which may result in the loss of bone and the displacement of structures in the surrounding area (Shear and Singh, 2022; Zhou *et al.*, 2023).

Impacted third molars have been associated with the development of both benign and malignant tumours, such as ameloblastomas and squamous cell carcinomas (Johnson *et al.*, 2021; Guimaraes *et al.*, 2023). However, this association is only shown in very rare instances. In their early stages, these pathologies may not present any symptoms, highlighting the need of maintaining regular dental check-ups and imaging for the sake of early detection and treatment (Borgonovo *et al.*, 2023).

Guven *et al.,* (1999) studied the incidence of cysts and tumours associated with impacted third molars in a Turkish population. Their study sample included 9994 impacted third molars in 7582 patients which were extracted. A normal dental examination that included radiography was used to diagnose the impacted molars and related pathology in 3621 of these individuals, who did not exhibit any symptoms.

In relation to the impacted third molars, the researchers discovered 231 cysts (2,31%) and 79 tumours (0,79%), two of which were malignant (0,02%). Of the 231 cysts, 16 (7%) of the cysts were odontogenic keratocysts, while 215 (93%) were confirmed to be dentigerous. 41 ameloblastomas (52%), 15 odontogenic myxomas (19%), 11 odontogenic fibromas (14%), 10 odontomas (13%), one squamous cell carcinoma (S.C.C.) and one fibrosarcoma which constituted the 0,02% of malignant tumours described above were among the 79 patients who had a tumour when they first appeared.. The above data emphasises the need for routine radiography and screening in patients between the ages of 17-23 years old as this is the period where third molars usually erupt.

Another article which highlights pathology found on routine dental radiographs was done in Sweden by Bondemark *et al.,* (2006). Examining the prevalence and location of accidental observations of pathology and anomalies in preoperative orthodontic panoramic radiographs was the aim of this investigation.
The most frequent findings were periapical inflammatory lesions (2,0%), thickening of the mucosal lining of the maxillary sinus (3,0%), and radiopacities in the alveolar bone (4,4%), which were primarily classified as idiopathic sclerosis. Dentigerous cysts were found in 0,6% of patients , whereas odontomas and cysts found in alveolar bone were found to be 0,4% of patients. Although the prevalence of cysts and odontomas were low in this study, it highlights the need for routine dental examinations and radiographs. The mean age of the patients in this study was 11,2 years of age and hence the prevalence of pathology related to impacted third molars is not significant.

A similar study was done within a South African setting at an academic hospital in Pretoria. Hlongwa *et al.,* (2023) investigated the prevalence of incidental pathologic findings using orthodontic pre-treatment panoramic radiographs. Pre-treatment panoramic radiographs were the subject of a retrospective cross-sectional review. The majority of pathologic findings were most commonly found in the age range of 7 to 20 years, highlighting the importance of radiographic analysis and screening in this group. After reviewing 100 panoramic radiographs, the authors discovered incidental pathological abnormalities in 38 (38%). Two incidental pathological abnormalities were identified in eight panoramic radiographs which included

thickening of the mucosal lining of the sinus, idiopathic osteosclerosis, dentigerous cyst, periapical inflammatory lesion, marginal bone loss, and cyst in the alveolar bone.

The results of the investigation by (Hlongwa *et al.*, 2023) were not the same as those of (Bondemark *et al*., 2006) , which found a prevalence of 8,7%. The observed variations might be related to the sample's geographic and ethnic makeup highlighting the prevalence of pathology within a South African setting.

Conclusions and Future Perspectives

Impacted mandibular third molars have a notable place in the arena of oral health disorders, chiefly owing to the high prevalence of the condition and the associated potential for complications. They provide a broad variety of therapeutic issues, ranging from diagnostic ambiguity to difficult treatment choices, which may be particularly difficult. However, they also present a rich area for study, which helps to create a better understanding of oral health and illness (Bamgbose *et al.,* 2021; Mokhtari e*t al.,* 2022).

The problem of diagnosing impacted third molars is essential to resolving the problem. (Kugelberg *et al.,* 2019; Peker *et al.,* 2021) In the past, panoramic radiography has been considered to be the most important part of the diagnostic process when it comes to determining the existence, orientation, and potential pathology associated with these teeth. It is a non-invasive imaging technology that delivers a full overview of the whole dental arch, which facilitates a wide perspective on oral health (Ravikumar *et al*., 2018; Swanson *et al.,* 2023)

However, the introduction of newer technology is gradually changing the face of dental diagnostics, despite the fact that panoramic radiography remains a very important diagnostic tool.

Technologies such as 3D imaging, machine learning and artificial intelligence have the potential to significantly improve the diagnostic accuracy of identifying impacted mandibular third molars, as well as the prediction of potential pathologies, hence contributing to the design of individualised treatment programmes (Celik *et al.,* 2022).

However, despite the fact that these technical improvements hold a great deal of promise, they are not a silver bullet. It is possible that the evaluation of the exact spatial connections between impacted teeth and the surrounding anatomical structures might be hindered by the fact that panoramic radiography and other comparable imaging modalities are only two-dimensional (Jaro and Trybek, 2021; Scutariu *et al.,* 2022).

As a consequence of this, there is still a continuing need for additional advancements in imaging technologies, in addition to research to test the usefulness and accuracy of developing tools such as AI-based systems (Smith *et al.,* 2023; Becker *et al.,* 2023).

Additionally, due to the intricacy of the etiological causes that might lead to the impaction of third molars, a more in-depth understanding is required. Although a number of variables, including genetic predisposition, environmental effects, and dietary habits, have been implicated, there is still a great deal that is unknown (Passi *et al.,* 2019; Bamdadianf *et al.,* 2018; Bahadure *et al.,* 2023).

The morbidity that is associated with third molar impactions can be reduced (Santos *et al.,* 2022; Zhang *et al.,* 2023) by having a full understanding of the factors that contribute to them. This might pave the way for improved prevention efforts and early intervention. The treatment of impacted third molars has its own unique set of obstacles and opportunities for further investigation, in addition to the concerns surrounding detection and prevention of the condition. When deciding whether to remove or keep an impacted third molar, the decision-making process requires a delicate balancing act between the patient-specific considerations, potential dangers, and potential benefits. It is still a topic of dispute, and the recommendations are always changing, which highlights the need of doing high-quality research that is focused on the patient (Kim *et al.,* 2023; Saldanha and Kostakis, 2023).

Additionally, the potential complications associated with the surgical extraction of impacted third molars, such as nerve damage, infection, and disorders of the temporomandibular joint, warrant the continuation of research into refining surgical techniques and improving post-operative care (Renton and Smeeton, 2021; Salinas-Torres *et al.,* 2023).

AIM AND OBJECTIVES

AIM

The aim of this is study is to determine the prevalence and types of pathologies related to impacted mandibular third molars based on panoramic radiographs.

OBJECTIVES

1. To measure the prevalence of pathologies discovered.
2. To determine the types of pathologies related to impacted mandibular third molars based on panoramic radiographs over a 5-year period.
3. To determine the association between pathology and gender of the patient
4. To determine the association between pathology and age group

CHAPTER 3: METHODOLOGY

3.1 Study design

This study is a cross-sectional retrospective study using panoramic radiographs to analyse pathologies related to impacted mandibular third molars.
Panoramic radiographs were utilized in the study as more anatomic structures can be viewed on a panoramic image as opposed to intraoral radiographs.

Study population: Patients of any age who were referred from the Maxillofacial and Oral Surgery department to the Wits Oral Health Centre Radiology department for a panoramic radiograph relating to impacted mandibular third molars at Wits Oral Health Centre during a 5-year period from (2016 to 2020) were included in this study. The time period was selected due to the Covid-19 pandemic limiting patient numbers at Wits Oral Health Centre during 2020 and thereafter.

3.2 Data collection

Data was extracted by a single examiner who is familiar with the health system of the Wits Maxillo-facial and Oral Surgery and Radiology departments. Files of patients who have been referred for mandibular third molar panoramic radiographs were collected from the department and radiographs were analysed in the Radiology department.
A data collection form was used in order to record information (Appendix A).

Data was extracted by a single examiner to ensure diagnostic reproducibility.

3.3 Sample size

600 radiographs were assessed. The sample size was planned using Yamane's sample size formula in conjunction with a biostatistician. This was to ensure a confidence level of 95%. The factor used to determine sample size was the average number of radiographs taken in a specific time period (2016-2020) that were referred by the Maxillo-facial and Oral Surgery department at Wits Oral Health Centre. Recording of data was done using a data collection form (Appendix F).

3.4 Inclusion criteria

- The presence of one or more impacted mandibular third molars. By definition, for this study, an impacted third molar is either fully or partly covered by bone and is not at the level of the occlusal plane.
- A clear panoramic radiograph as well as complete records that indicate the patient's age and gender.

3.5 Exclusion criteria

- Mandibular third molars that have erupted to the level of the occlusal plane.
- Any record that lacks a clear panoramic radiograph or records with incomplete information.
- Any impaction due to soft tissue alone.

3.6 Data analysis

The age, gender, and number of impacted third molars associated with pathologies are shown by percentage and frequency. Descriptive statistics of the tendencies were captured and then presented in data tables, charts and graphs.

The age ranges for the different pathologies were additionally analysed in order to determine which age group has the most prevalent pathologies.
The median and mean were also analysed in terms of prevalence, age and gender. The statistical significance level was set at $p<0.05$

The data was tested for normal distribution using the Kolmogorov–Smirnov test.
STATA version 17 was the software used for data analysis.

3.7 Ethical considerations

- Ethics clearance was applied for and granted by the University of the Witwatersrand Human Research Ethics Committee (HREC) (Appendix B).

- Permission was requested and granted from the CEO of Charlotte Maxeke Johannesburg Academic Hospital (Appendix D) and the Head of Department of Maxillo-facial and Oral Surgery (Appendix E).

- The confidentiality of patients was maintained throughout the study, as no identifying information was disclosed in the study. The researcher utilized a numerical system to record all information retrieved.

3.8 Limitations

- Files with Incomplete or illegible information had to be excluded.

- Lack of clear radiographs (Poor quality)

- There is a level of bias as all patients in the study have been referred for extractions inferring some pathology. However, we have not excluded any patients in terms of age or gender which offers a well-rounded demographic of patients.

CHAPTER 4: RESULTS

The sample size of this study comprised of 600 patients (radiographs and files) who presented to the WOHC with at least one impacted mandibular third molar within the years 2016-2020.

GENDER

Male patients represented a figure of 229 patients (54,83%), while 271 (45,17%) patients were female (Figure 1).

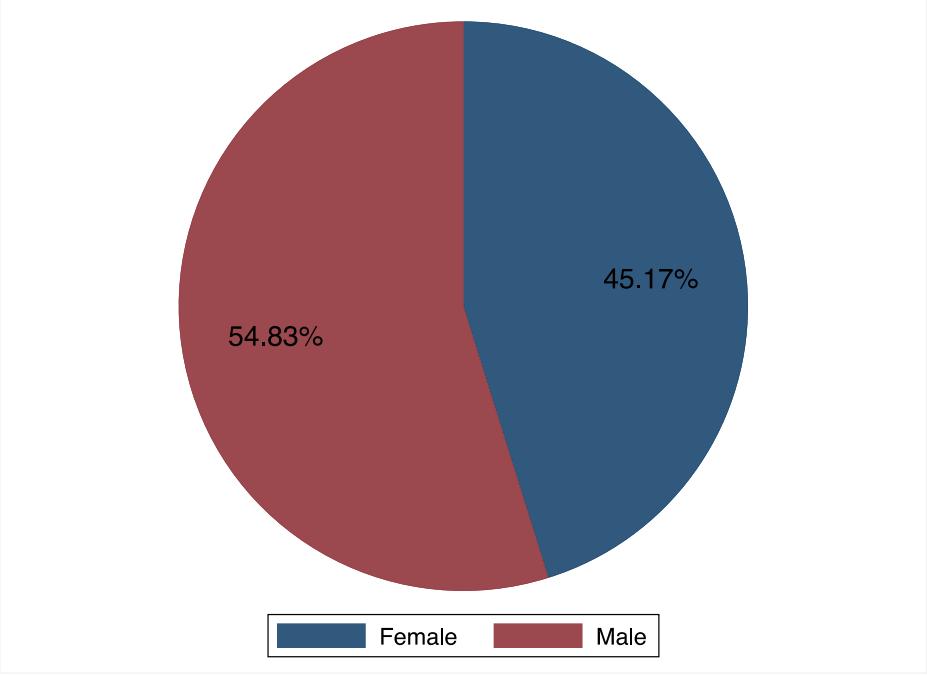

Figure 1: Gender distribution

AGE

The age ranged from 15 to 79 years. However, the data was right skewed (Figure 2).

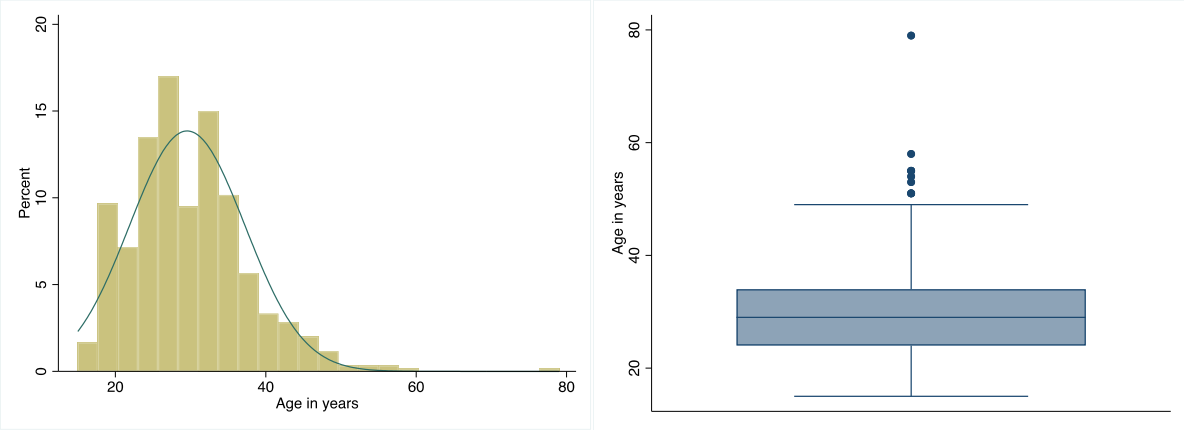

Figure 2: Histogram (left) and box-and-whisker (right) plots for age distribution

The mean ± SD was 29.6± 7.7 years while the median (IQR) was 29 (24-34) years. The mode in terms of age was 28 years old.

Table 1 shows the age group distribution of participants. Most of the participants (48,0%) were in the age group of 20-29 years

Table 1: Distribution of age group of patients presenting with an impacted lower third molar.

Age Range in years	Frequency	Percent
15-19	37	6.17
20-29	288	48
30-39	219	36.5
40-49	48	8
50 and older	8	1.33

PATHOLOGY

In terms of pathologies found, caries on the impacted third molar itself accounted for the highest number of associated pathologies 169 (28,2%) followed closely by pathological caries on the adjacent second molar 136 (22,7%) while 72 patients presented with both caries on the impacted mandibular third molar as well as the adjacent second molar (12%).

128 radiographs (21,3%) presented with peri-coronal radiolucent lesions while periodontal bone loss accounted for 40 patients (7,0%) . External root resorption accounted for the least prevalent pathology (0,67%).

49 records fell into the “other” category of which 25 radiographs displayed no radiographic pathology, 12 radiographs presented with cysts like lesions and 5 radiographs depicting a periapical radiolucency on the impacted third molar itself.

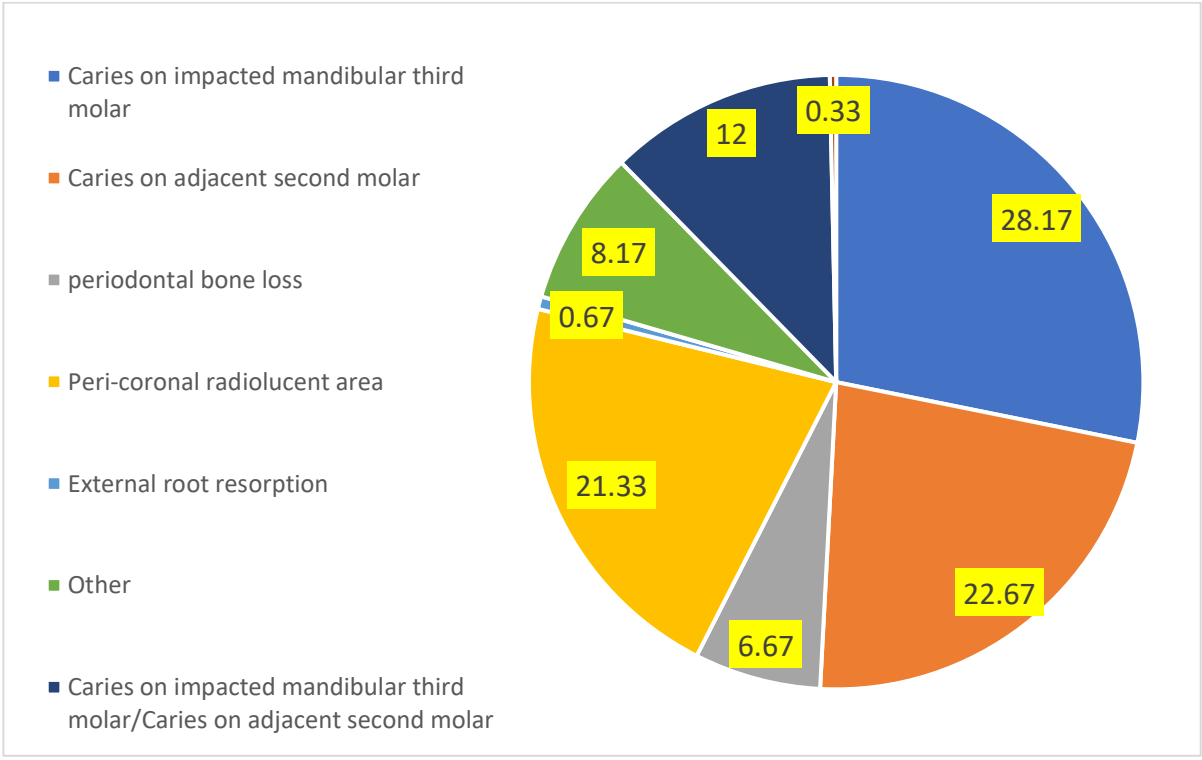

Figure 3: Pathological distribution

Table 2 shows the association between pathology and the gender of patients. With the use of a Pearson Chi-Square test, the following was found : Chi-square value=18,2, df=7, p=0,011. The Pearson Chi-Square test was used as the association between categorical variables were being tested.

This implies that there was a significance when the associated pathology was compared with gender of the patient $\chi 2 = 18,2$, df= 7, P = 0,011 (Table 2).

Caries on the impacted third molar and peri-coronal radiolucent lesions were associated with females whereas caries on adjacent second molar, periodontal bone loss and external root resorption were more common in males.

Table 2: Distribution of associated pathology with gender of patients

	Female n (%)	**Male n (%)**	**Total**
Caries on impacted mandibular third molar	82(30.26)	87(26.44)	169(28.17)
Caries on adjacent second molar	49(18.08)	87(26.44)	136(22.67)
Periodontal bone loss	13(4.8)	27(8.21)	40(6.67)
Peri-coronal radiolucent area	72(26.57)	56(17.02)	128(21.33)
External root resorption	1(0.37)	3(0.91)	4(0.67)
Other	19(7.01)	30(9.12)	49(8.17)
Caries on impacted mandibular third molar and caries on adjacent second molar	33(12.18)	39(11.85)	72(12)

Table 3 shows the association between pathology and the age group of the patients. There was a significant association between pathology and age groups. Peri-coronal radiolucent area was mostly common in the 15-19 years (59%), 20-29 years (27%) and 50 years and above (38%) age groups.

Caries on impacted mandibular third molar was most common in the 30-39 years (35%) while caries on adjacent second molar was most common in the 40-49 years (44%).

There was a significant difference when the associated pathology was compared with age groups of the patient $\chi 2 = 109, 6$, df= 28, P < 0, 011. This implies significance between age and types of pathology.

Table 3: Distribution of associated pathology with age group of patients

Pathology	**15-19 n (%)**	**20-29 n (%)**	**30-39 n (%)**	**40-49 n (%)**	**50 and above n (%)**
Caries on impacted mandibular third molar	1(2.7)	78(27.08)	76(34.7)	12(25.0)	2(25.0)
Caries on adjacent second molar	6(16.22)	54(18.75)	55(25.11)	21(43.75)	0
Periodontal bone loss	3(8.11)	19(6.6)	14(6.39)	2(4.17)	2(25.0)
Peri-coronal radiolucent area	22(59.46)	79(27.43)	22(10.05)	2(4.17)	3(37.5)
External root resorption	1(2.7)	1(0.35)	2(0.91)	0	0
Other	3(8.11)	31(10.76)	8(3.65)	6(12.5)	1(12.5)
Caries on impacted mandibular third molar/Caries on adjacent second molar	1(2.7)	25(8.68)	41(18.72)	5(10.42)	0

CHAPTER 5: DISCUSSION AND CONCLUSION

5.1 Discussion

Historically, mandibular third molars are the most frequent teeth in the dental arch to present with impaction (Chu *et al.*, 2003 and Aitasalo *et al.*, 1972).
There are various definitions of what an "impacted tooth" is and according to (Aitasalo *et al*., 1972) a tooth is considered impacted when it is significantly late in erupting, and when there is clinical or radiographic evidence of future hindrance to its eruption.
It may also be defined as a pathological situation where the tooth is prevented from attaining it's typical functional position (Santosh, 2015).
For the purpose of this study, an impacted third molar is either fully or partially covered by bone and is not at the level of the occlusal plane implying that is both not functional and there is an obstruction to its eruption.

There are several pathologies that may be associated with impacted mandibular third molars. Various studies have proposed that the most common pathologies associated with impacted mandibular third molars are: caries on the impacted third molar itself, caries on the adjacent molar, periodontal bone loss, root resorption of the adjacent tooth and pericoronitis (Akarslan and Kocabay, 2009; Al-Khateeb and Baitaneh, 2006; Sharma *et al.*, 2019). Conflicting results have been found relating to the prevalence of pathologies in different areas around the world.
Pathologies may present in diverse ways however widespread signs and symptoms which may be experienced include; pain, swelling, restricted jaw opening and halitosis (Langlais and Miller, 2009) .

Age, gender and classification of type of impaction are several variables which were common in the literature. In this study six hundred files and radiographs were examined with the purpose of investigating the types and prevalence of pathologies related to impacted mandibular third molars based on panoramic radiographs.

Our findings show that caries on the impacted mandibular third molar itself is the most common pathology related to impacted mandibular third molars based on panoramic radiographs. Similar studies have been done in other parts of the world and results of those studies are depicted in the table below.

Table 4: Various studies being compared with regard to the prevalence of pathologies related to impacted mandibular third molars

Author	**Year**	**Sample size**	**Most prevalent pathology**	**Country in which research was conducted**
Sejfijia *et al.*	2019	5515	Root resorption of adjacent tooth	Kosovo
Al-Khateeb and Baitaneh	2006	1398	Caries on impacted mandibular third molar	Jordan
Akarslan and Kocaby	2009	342	Caries on impacted mandibular third molar	Turkey
Chu *et al.*	2003	3853	Periodontal bone loss on the distal surface of mandibular second molars adjacent to impacted third molars	Hong-Kong
Polat *et al.*	2008	1914	Caries and periodontal damage on the adjacent second molar	Turkey
Knutsson *et al.*	1992	1996	Pericoronitis	Sweden
Breimah *et al.*	2018	135	Pathological pockets and caries on both impacted lower third molar and the adjacent lower second molar tooth	Nigeria
This study	2023	600	Caries on impacted mandibular third molar	South Africa

The results found in this study are similar to what was seen in Nigeria by (Breimah *et al*., 2018), in Jordan by (Al-Khateeb and Baitaneh, 2006) and in Turkey by (Akarslan and Kocaby, 2009) which noted that the most prevalent pathology is caries on the impacted mandibular third molar.

The study by (Breimah *et al*., 2018) looked at both hard and soft tissue pathologies which gives a broader overview of what to be aware of when dealing with impacted mandibular third molars however the study participants had an narrow age range which excluded findings that would be seen in older individuals. The limitation of our current study is that it is based solely on panoramic radiographs and hence clinical diagnosis such as pericoronitis and pathological pockets cannot be assessed.

Polat *et al.,* (2008) reported that the most common pathology discovered was caries and periodontal damage on the adjacent second molar. This contradicts what was found in the study by (Al-Khateeb and Bataineb, 2006) as well as the current study where it was found that caries was more commonly found on the third molar itself instead of the adjacent molar tooth.

It is likely that this study has found a high prevalence of caries on both the impacted third molar and the adjacent second molar as these pathologies usually result in pain or discomfort encouraging the patient to seek dental treatment .

This is in contrast to periodontal bone loss and root resorption which were the most common pathologies discovered by (Chu *et al.,*2003) and (Sejfijia *et al.,* 2019) respectively, which are usually asymptomatic pathologies. This may be attributed to more routine dental screenings and higher rate of panoramic radiographs taken in developed countries. Access to standard panoramic radiography is still limited within a South African setting with many patients presenting only when symptoms begin.

It is interesting to note that pericoronal radiolucent areas account for 21,3% of pathologies in this study. In unerupted teeth, it usually represents the dental follicle which is a soft tissue remnant (Farah and Savage, 2002). However, a radiolucent lesion on a radiograph also represents a structure that has density deficits or indicates bone destruction (Yamaoka *et al.*, 2009).

It is plausible that the acute inflammatory process associated with pericoronitis could account for the pericoronal radiolucent areas seen in the results of this study. This is also in keeping with other studies who have reported a high prevalence of pericoronitis (Knuttson *et al.*, 1992).

Root resorption is reported to be a common pathology associated with impacted mandibular third molars. It is usually caused by increased osteoclastic activity triggered by increasing pressure from the impacted tooth (Smailene *et al.*, 2019). However, there is debate as to whether impacted teeth can cause root resorption of the adjacent teeth.

Smailene *et al.,* (2019) found the prevalence of external root resorption to be 40,2%. It was put forward that the justification for the high prevalence of root resorption in the study may be that the study sample included many deeply-impacted impacted third molars which poses the highest risk of root resorption. The prevalence in this study was much higher than that found by (Nitzan *et al.,* 1981) who reported that 8% of adjacent second molars presented with root resorption.

Chu *et al.,* (2003) reported, only 13 (0,4%) cases of root resorption among more than 3000 impacted third molars. Chu *et al*., (2003) believe that intact tooth cementum should normally be able to withstand 'pressure' from neighbouring impacted teeth, but differentiating radiolucency as resorption or caries is challenging, whether on panoramic or periapical radiographs.

Findings of this study indicate that only 4 cases out 600 presented with root resorption. This represents 0,67% of the study sample which is similar to what was reported by both (Chu *et al.*, 2003 and Nitzan *et al.,* 1981).

Although no histopathological data was gathered in this study, we found cystic changes in 12 radiographs (2%). This is in keeping with other studies done such as the one by (Guven *et al.*, 2000) who found the prevalence of cysts to be 2,31% within a Turkish population. The low prevalence reported in our study could be attributed to the idea that most of our patients present when there is pain or discomfort. In an ideal situation, routine panoramic radiographs should be taken on the general population in order to get a true reflection of the prevalence.

In this study, we found a male predilection in terms of gender. Male patients represented a figure of 229 patients (54,83%), while 271 (45,17%) patients were female. This is in keeping with studies such as the one conducted by Al-Khateeb and Bainteneh (2006) who found that 57, 4% of impactions were found in males while 42,5% were found in females, with a definite male gender predominance in almost all age groups. It is worthy to note that various other studies show no gender predilection (Osunde and Bassey, 2016; Ishwarkumar *et al.,* 2019 and Aitasalo *et al.,* 1972) . The table below summarizes gender predilection in various studies.

Table 5: Various studies being compared with regard to the gender predilection in terms prevalence of pathologies related to impacted mandibular third molars

Author	**Year**	**Gender predilection**	**Country in which research was conducted**
Al-Khateeb and Baitaneh	2006	Male	Jordan
Osunde and Bassey	2016	None	Nigeria
Ishwarkumar *et al.*	2019	None	South Africa
Aitasalo *et al.*	1972	None	Finland
Breimah *et al.*	2018	Female	Nigeria
This study	2023	Male	South Africa

According to Hellman's theory, "the jaws of a female stop growing when third molar teeth begin to erupt, as opposed to the jaws of a male continue to grow even after third molar eruption resulting in decreased impactions amongst males" (Reddy and Prasad, 2011), however this theory could not be validated in this study. The study by Reddy and Prasad in 2011 also noted a male predominance.

There was a significant association between pathology and gender when Chi-square tests were applied (P< 0,05). The male predilection in this study could suggest the population group that visits WOHC. An alternative explanation is that females are more likely to seek medical attention for preventative measures and hence do not present as frequently for extractions.

Third molars are generally the very last teeth to erupt in an individual's dentition and eruption normally occurs between 17 and 23 years of age (Indira *et al*., 2013). Mandibular third molars in particular have a high rate of impaction due to a lack of space in the dental arches.
In this study the age of the patients ranged from 15-79 years with the mean age being 29,6 , SD was 29,6± 7,7 years while the median (IQR) was 29 (24-34) years. The mode in terms of age was 28 years old. The prevalence of pathologies differed in terms of age groups. There was a significant difference when the associated pathology was compared with age groups of the patient P < 0.011. This implies significance between age and types of pathology.

Peri-coronal radiolucent area was mostly common in the 15-19 years (59%), 20-29 years (27%) and 50 years and above (38%) age groups. Yamoaka et al., (2009) reported that the greatest number of impacted mandibular third molars extractions in the elderly are owing to pericoronitis, and should be a reminder of its association with coronal radiolucency. It can be noted that pericoronal radiolucent areas are the most prevalent pathology found in the 15-19 year and 20-29 year age groups which can be attributed to younger patients having a better dental IQ and more access to information regarding their health and hence seek treatment earlier than those in the older age groups.

Caries on the impacted mandibular third molar was most common in the 30-39 years (35%) while caries on adjacent second molar was most common in the 40-49 years (44%). Caries being the most prevalent pathology in the older age groups could be attributed to how long the tooth has been in oral cavity exposed to known causes of caries combined with poor oral hygiene practices.

The table below summarizes the mean ages of populations presenting with pathology related to impacted mandibular third molars.

Table 6: Various studies being compared with regard to the mean age of patients in terms prevalence of pathologies related to impacted mandibular third molars

Author	**Year**	**Mean age**	**Country in which research was conducted**
Genc *et al.*	2022	29	North Cyprus
Rauf *et al.*	2020	32,90	Pakistan
Osunde and Bassey	2016	27,5	Nigeria
Breimah *et al.*	2018	24,8	Nigeria
This study	2023	29,6	South Africa

It can be seen that the findings of this study are in keeping with various others as described above.

5.2 Study limitations

It is challenging to obtain an unbiased selection of a population sample for the investigation of impacted third molars to determine the types and prevalence of pathologies associated with impacted third molars.

In an ideal situation , a random sample of adults from the general population is required. It is however difficult to do this as exposing the general population to radiation from a panoramic radiograph without justification is an ethical dilemma.

This study is subject to some bias as it only included teeth that were for referred for removal and with a preoperative panoramic radiograph showing at least one impacted mandibular third molar.

5.3 Conclusion

The findings of this study along with parallels from the literature, indicates that caries is the most frequent pathology associated with impacted mandibular third molars. Caries may be seen on both the impacted third molar itself as well as the adjacent second molar and may be seen mostly between the ages of 30-49 years, with a higher predilection for males. We have also discovered that pericoronal radiolucent areas, followed by periodontal bone loss are also common pathologies which may be associated with impacted mandibular third molars hence clinicians should be conscious of their prevalence when analysing radiographs. Seeing that caries is so prevalent within the South African population, treatment or intervention of impacted mandibular third molars would be advisable.

The treatment plan should ideally be customised and based on the individual taking into account both clinical and radiographic findings. NICE guidelines should be followed in terms of surgical management, or regular maintenance follow up visits may also be considered when looking at asymptomatic impacted mandibular third molars.

5.4 Future perspectives

It would be recommended that future studies should be conducted as a prospective study rather than retrospective. This may reduce the limitations of poor record keeping and poor radiograph quality as only those who meet the inclusion criteria would be recorded.

This would also allow the researcher to include the study of soft tissue pathologies such as pericoronitis which is prevalent within the South African population.

If a larger sample size is to be used in related studies (larger than the current study), this may be helpful in determining the possible indications for prophylactic extraction of impacted mandibular third molars.

Ideally, the type of impaction (mesioangular, vertical etc.) would provide further insight into whether angulation plays a role in pathology and should be included in future studies.

The researchers have suggested that companies be approached to consider donation of panoramic radiograph machines to primary healthcare centres in Gauteng in order to facilitate early detection of pathologies such as cysts and tumours.

REFERENCES

Aitasalo, K., Lehtinen, R. and Oksala, E. (1972). An orthopantomography study of prevalence of impacted teeth. *International Journal of oral surgery*. *1*(3), pp.117-120.

Akarslan, Z.Z. and Kocabay, C. (2009). Assessment of the associated symptoms, pathologies, positions and angulations of bilateral occurring mandibular third molars: is there any similarity? *Oral Surgery, Oral Medicine, Oral Pathology, Oral Radiology, and Endodontology*, *108*(3), pp. e26-e32.

Al-Khateeb, T.H. and Bataineh, A.B. (2006). Pathology associated with impacted mandibular third molars in a group of Jordanians. *Journal of oral and maxillofacial surgery*, *64*(11), pp.1598-1602.

Al-wusaybie, M.M., Al-Ramil, A.M., Al-Wosaibi, A.M. *et al*. (2018). Prevalence of impacted teeth and associated pathologies–A radiographic study, Al Ahsa, Saudi Arabia Population. *The Egyptian Journal of Hospital Medicine*, *70*(12), pp.2130-2136.

Altan A., and Akbulut N. (2019).Does the Angulation of an Impacted Mandibular third Molar Affect the Prevalence of Preoperative Pathoses? *Journal of Dentistry. (Shiraz, Iran),* 20(1) 48-52. doi:10.30476/DENTJODS.2019.44563

Bamdadianf, T. (2018). Evaluation of impact teeth prevalence and related pathologic lesions in patients in Northern part of Iran (2014-2016). *Journal of Contemporary Medical Science*, *4*(1), pp.30-32.

Bataineh, A.B., Albashaireh, Z.S. and Hazza'a, A.M. (2002). The surgical removal of mandibular third molars: a study in decision making. *Quintessence international*, *33*(8).

Bondemark, L., Jeppsson, M., Lindh-Ingildsen, L., *et al*. (2006). Incidental findings of pathology and abnormality in pretreatment orthodontic panoramic radiographs. *The Angle Orthodontist*, *76*(1), pp.98-102

Bouloux, G.F., Steed, M.B., and Perciaccante V.J., (2007). Complications of third molar surgery. *Oral and Maxillofacial Surgery Clinics*, *19*(1), pp.117-128.

Braimah, R.O., Ibikunle, A.A., Taiwo, A.O. *et al.* (2018). Pathologies associated with impacted mandibular third molars in Sub-Saharan Africans. *Dentistry and Medical Research*, *6*(1), pp.2-6.

Celik, M.E. (2022). Deep learning based detection tool for impacted mandibular third molar teeth. *Diagnostics*, *12*(4), p.942.

Chu, F.C.S., Li, T.K.L., Lui, V.K.B. *et al.* (2003). Prevalence of impacted teeth and associated pathologies-a radiographic study of the Hong Kong Chinese population. *Hong Kong Medical Journal*.

Farah, C.S. and Savage, N.W. (2002). Pericoronal radiolucencies and the significance of early detection. *Australian dental journal*, *47*(3), pp.262-265.

Genç, B.G.Ç., Orhan, K. and Hincal, E. (2022). Maxillary and Mandibular Third Molars Impaction with Associated Pathologies in a North Cyprus Population: A Retrospective Study. *Applied Sciences*, *12*(11), p.5756.

Girod, S.C., Gerlach, K.L. and Krueger, G. (1993). Cysts associated with longstanding impacted third molars. *International journal of oral and maxillofacial surgery*, *22*(2), pp.110-112.

Güven, O., Keskln, A. and Akal, Ü.K. (2000). The incidence of cysts and tumors around impacted third molars. *International journal of oral and maxillofacial surgery*, *29*(2), pp.131-135.

Hlongwa, P., Moshaoa, M.A.L., Musemwa, C. *et al.* (2023). Incidental Pathologic Findings from orthodontic pretreatment panoramic radiographs. *International Journal of Environmental Research and Public Health*, *20*(4), p.3479.

Indira, A.P., Kumar, M., David, M.P. *et al.* (2013). Correlation of pericoronitis and the status of eruption of mandibular third molar: A clinico radiographic study. *Journal of Indian Academy of Oral Medicine and Radiology*, *25*(2), p.7.

Ishwarkumar, S., Pillay, P., Haffajee, M.R. *et al.* (2019). Prevalence of impacted third molars in the South African Indian population of the eThekwini Metropolitan Region. *South African Dental Journal*, *74*(6), pp.302-309.

Jaroń, A. and Trybek, G.(2021). The pattern of mandibular third molar impaction and assessment of surgery difficulty: A Retrospective study of radiographs in east Baltic population. *International journal of environmental research and public health*, *18*(11), p.6016.

Knutsson, K., Brehmer, B., Lysell, L. *et al.* (1992). Asymptomatic mandibular third molars: oral surgeons' judgment of the need for extraction. *Journal of oral and maxillofacial surgery*, *50*(4), pp.329-333.

Krishnan B., Sheikh M.H., Rafa el-G. *et al.* (2009) "Indications for removal of impacted mandibular third molars: a single institutional experience in Libya." *Journal of maxillofacial and oral surgery* 8 (3) pp. 246-248.

Mabongo, M. and Thekiso, M. (2019). Does additional information provided by cone beam computed tomography (CBCT) and a consequent modification of surgical technique reduce the possibility of inferior alveolar nerve injury? A pilot study. *South African Dental Journal*, 74(2). doi:https://doi.org/10.17159/2519-0105/2019/v74no2a2.

Nazir, A., Muhammad A.K. and Shahid A. (2014) "Assessment of different patterns of impacted mandibular third molars and their associated pathologies." *Journal of Advance Medical and Dental Science Research* 2 (2) pp 14-22.

Nitzan, D., Keren, T. and Marmary, Y., (1981). Does an impacted tooth cause root resorption of the adjacent one?. *Oral Surgery, Oral Medicine, Oral Pathology*, *51*(3), pp.221-224.

Osunde, O. and Bassey, G. (2016). Pattern of impacted mandibular third molars in Calabar, Nigeria. *African Journal of Medical and Health Sciences*, *15*(1), pp.14-14.

Passi, D., Singh, G., Dutta, S. *et al.* (2019). Study of pattern and prevalence of mandibular impacted third molar among Delhi-National Capital Region population with newer proposed classification of mandibular impacted third molar: A retrospective study. *National journal of maxillofacial surgery*, *10*(1), p.59.

Polat, H.B., Özan, F., Kara, I. *et al.* (2008). Prevalence of commonly found pathoses associated with mandibular impacted third molars based on panoramic radiographs in Turkish population. *Oral Surgery, Oral Medicine, Oral Pathology, Oral Radiology, and Endodontology*, *105*(6), pp.e41-e47.

Rauf, S., Ali, W., Tariq, Q. *et al.* (2019). Pattern of mandibular third molar impaction: a radiographic study. *Pakistan Oral & Dental Journal*, *39*(3), pp.238-242.

Ravikumar, K.K., Jamal, B.T., Ageel, R., *et al.* (2018). Prevalence of impacted teeth and their associated pathologies on panoramic films in the Saudi Population. *International Journal of Social Rehabilitation*, *3*(2), p.40.

Reddy, K.V.G. and Prasad, K.V.V. (2011). Prevalence of third molar impactions in urban population of age 22-30 years in South India: An epidemological study. *Journal of Indian Dental Association*, *5*(5), pp.609-11.

Saisha, J., Kapeshi, C., Siame, A. *et al.* (2023). Clinical presentation of impacted third molar tooth and its effect on the adjacent tooth, in Lusaka, Zambia. *Anatomy Journal of Africa*, *12*(1), pp.2296-2302.

Santos, K.K., Lages, F.S., Maciel, C.A.B. *et al.* (2022). Prevalence of mandibular third molars according to the Pell & Gregory and Winter classifications. *Journal of maxillofacial and oral surgery*, pp.1-7.

Santosh, P. (2015). Impacted mandibular third molars: Review of literature and a proposal of a combined clinical and radiological classification. *Annals of medical and health sciences research*, *5*(4), pp.229-234.

Sewerin I. and von Wowern N. (1990). A radiographic four-year follow up study of asymptomatic mandibular third molars. *International Dental Journal* , 40(24)

Sharma, V., Yadav, A., Dubey, S. *et al*. (2019). Angulation of impacted Mandibular third molar and prevalence of pathology. *Journal of Advanced Medical and Dental Sciences Research*, *7*(9), pp.148-152.

Smailienė, D., Trakinienė, G., Beinorienė, A. *et al.* (2019). Relationship between the position of impacted third molars and external root resorption of adjacent second molars: a retrospective CBCT study. *Medicina*, *55*(6), p.305.

Subedi, S., Koirala, U. and Shrestha, B. (2020). Indications for removal of impacted mandibular third molars and associated pathologies. *Journal of Gandaki Medical College-Nepal*, *13*(2), pp.134-139.

Sykes, L.M., Postma, T.C. and Dawson, L. (2022). The prevalence and classification of mandibular third molar impactions and associated second molar pathology in a Gauteng population group. A retrospective study. *South African Dental Journal*, *77*(4), pp.200-205.

Tai, S., Zhou, Y., Pathak, J.L. *et al.* (2021). The association of mandibular third molar impaction with the dental and periodontal lesions in the adjacent second molars. *Journal of periodontology*, *92*(10), pp.1392-1401.

Ventä, I., Vehkalahti, M.M. and Suominen, A.L. (2019). What kind of third molars are disease-free in a population aged 30 to 93 years?. *Clinical oral investigations*, *23*, pp.1015-1022.

Yamaoka, M., Ono, Y., Takahashi, M. *et al.* (2009). Acute inflammation in horizontal incompletely impacted third molar with radiolucency in the elderly. *Clinical Interventions in Aging*, pp.337-342.

Ye, Z.-X., Qian, W.H., Wu, Y.B. *et al.* (2021). Pathologies associated with the mandibular third molar impaction. *Science Progress*, 104(2), p.003685042110132. doi:https://doi.org/10.1177/00368504211013247.

APPENDIX A: PLAGIARISM DECLARATION



PLAGIARISM DECLARATION TO BE SIGNED BY ALL HIGHER DEGREE STUDENTS

SENATE PLAGIARISM POLICY: APPENDIX ONE

I _____Anisha Anil Hari_____ (Student number: __835 676_____) am a student registered for the degree of ____Master's of Science in Dentistry_____ in the academic year 2024

I hereby declare the following:

- I am aware that plagiarism (the use of someone else's work without their permission and/or without acknowledging the original source) is wrong.
- I confirm that the work submitted for assessment for the above degree is my own unaided work except where I have explicitly indicated otherwise.
- I have followed the required conventions in referencing the thoughts and ideas of others.
- I understand that the University of the Witwatersrand may take disciplinary action against me if there is a belief that this is not my own unaided work or that I have failed to acknowledge the source of the ideas or words in my writing.
- I have included as an appendix a report from "Turnitin" (or other approved plagiarism detection) software indicating the level of plagiarism in my research document.

Signature: _____ Date: 20 May 2024

1

APPENDIX B: TURNITIN REPORT

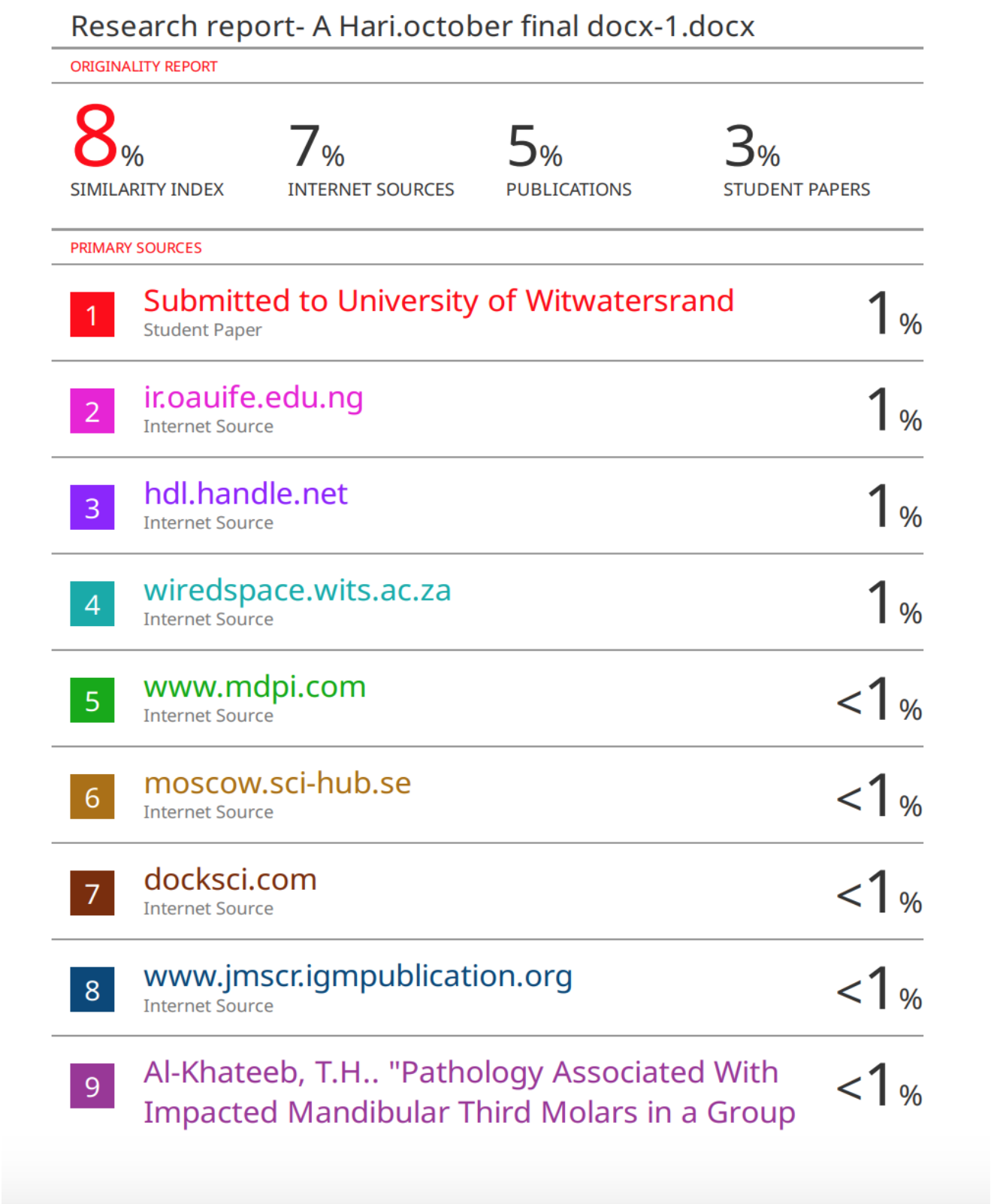

Research report- A Hari.october final docx-1.docx

ORIGINALITY REPORT

8%	7%	5%	3%
SIMILARITY INDEX	INTERNET SOURCES	PUBLICATIONS	STUDENT PAPERS

PRIMARY SOURCES

1	Submitted to University of Witwatersrand Student Paper	1%
2	ir.oauife.edu.ng Internet Source	1%
3	hdl.handle.net Internet Source	1%
4	wiredspace.wits.ac.za Internet Source	1%
5	www.mdpi.com Internet Source	<1%
6	moscow.sci-hub.se Internet Source	<1%
7	docksci.com Internet Source	<1%
8	www.jmscr.igmpublication.org Internet Source	<1%
9	Al-Khateeb, T.H.. "Pathology Associated With Impacted Mandibular Third Molars in a Group	<1%

APPENDIX C: HREC APPROVAL

UNIVERSITY OF THE WITWATERSRAND, JOHANNESBURG

R14/49 Dr A Hari

HUMAN RESEARCH ETHICS COMMITTEE (MEDICAL)

CLEARANCE CERTIFICATE NO. M221057

NAME: (Principal Investigator)	Dr A Hari
DEPARTMENT:	School of Oral Health Sciences Department of Maxillo-facial and Oral Surgery
PROJECT TITLE:	*The prevalence and types of pathologies related to impacted mandibular third molars, based on panoramic radiographs*
DATE CONSIDERED:	28/10/2022
DECISION:	Approved unconditionally
CONDITIONS:	Previous condition (CMJAH CEO approval) satisfied on 2023/04/25
SUPERVISOR:	Drs E Mabaso and M Turton
APPROVED BY:	CB Penny Dr CB Penny, Chairperson, HREC (Medical)
DATE OF APPROVAL:	2023/02/14

This clearance certificate is valid for 5 years from date of approval. Extension may be applied for.

DECLARATION OF INVESTIGATORS

To be completed in duplicate and **ONE COPY** returned to the Research Office Secretary on the Third Floor, Faculty of Health Sciences, Phillip Tobias Building, 29 Princess of Wales Terrace, Parktown, 2193, University of the Witwatersrand. I/we fully understand the conditions under which I am/we are authorized to carry out the above-mentioned research and I/we undertake to ensure compliance with these conditions.Should any departure be contemplated, from the research protocol as approved, I/we undertake to resubmit the application to the Committee. **I agree to submit a yearly progress report.** The date for annual re-certification will be one year after the date of convened meeting where the study was initially reviewed. In this case, the study was initially reviewed in **October** and will therefore be due in the month of **October** each year. Unreported changes to the application may invalidate the clearance given by the HREC (Medical).

Principal Investigator Signature _____ Date _____

PLEASE QUOTE THE PROTOCOL NUMBER IN ALL ENQUIRIES

APPENDIX D: APPROVAL FROM CEO OF CMJAH

GAUTENG PROVINCE
HEALTH
REPUBLIC OF SOUTH AFRICA

CHARLOTTE MAXEKE JOHANNESBURG ACADEMIC HOSPITAL

Enquiries: *Ms N. Mzila*
Email: Nolwazi.Mzila@gauteng.gov.za
Tel: *011 488 3365*
Ref: *1/7/2*
Date: 26 May 2023

GP_202302_048

Dear Dr. Anisha Anil Hari

RE: FINAL APPROVAL OF STUDY

TITLE: THE PREVALENCE AND TYPES OF PATHOLOGIES RELATED TO IMPACTED MANDIBULAR THIRD MOLARS BASED ON PANORAMIC RADIOGRAPHS

Permission is granted for you to conduct the above-mentioned study as described in your request provided:

1. Charlotte Maxeke Johannesburg Academic Hospital will not in any way incur or inherit costs as a result of the said study.
2. Your study shall not disrupt services at the study sites.
3. Strict confidentiality shall always be observed.
4. Informed consent shall be solicited from patients participating in your study.

Please liaise with the HOD and Unit Manager or Sister in charge to agree on the dates and time that would suit all parties.

Kindly forward this office with the results of your study on completion of the research.

Supported / ~~Not Supported~~

Signed by:Jayshina Punwasi
Signed at:2023-05-27 12:03:08 +02:00
Reason:Witnessing Jayshina Punwasi

Dr J. Punwasi
Clinical Director

Approved / ~~Not Approved~~

Signed by:Gladys Magugudi Bogoshi
Signed at:2023-05-28 06:11:50 +02:00
Reason:Witnessing Gladys Magugudi Bo

Ms G. Bogoshi
Chief Executive Officer: CMJAH

APPENDIX E: APPROVAL FROM HOD OF MAXILLOFACIAL AND ORAL SURGERY

UNIVERSITY OF THE WITWATERSRAND, JOHANNESBURG

FACULTY OF HEALTH SCIENCES

Department of Maxillo-Facial and Oral Surgery
011 717 2130
Liza.huygen@wits.ac.za

28 September 2022

To Whom It May Concern:

I, Dr MG Sehume (Acting HOD) hereby grant Anisha Hari (Student number: 835 676) permission to conduct research in the below mentioned department in partial fulfilment of a Master of Science in Dentistry (Maxillo-facial and Oral Surgery).

Patient anonymity will be maintained at all times and access to radiographs and patient records will be granted.

The approved title of research being:

" The types and prevalence of pathologies related to impacted mandibular third molars based on panoramic radiographs"

Department: Maxillo-Facial and Oral Surgery

Name and signature of Acting Head of Department : Dr MG Sehume

Date:

APPENDIX F: Data collection form

PREVALENCE AND TYPES OF PATHOLGIES RELATED TO IMPACTED MANDIBULAR THIRD MOLARS

A RETROSPECTIVE STUDY

Study number: _____

Examiner: _____

Patient's age: ___

Gender: ___

The data collection form is adapted and

modified from Al-Khateeb and Bataineh(2006)

Diagnosis	**Criteria**
Caries on impacted mandibular third molar	A radiographically clear carious lesion on the impacted mandibular third molar.
Caries on adjacent second molar	A radiographically clear carious lesion on adjacent second molar.
Periodontal bone loss	A clear loss of bone from the physiologic bone level (at the cemento-enamel junction)
Peri-coronal radiolucent area	A radiolucent area on the distal aspect of the impacted mandibular third molar
External root resorption	A clear loss of substance of the root of the adjacent mandibular second molar.
Other (Please elaborate)	Cyst-like lesions, radiopaque masses.