

https://dspace.org/

Outcome of Retinoblastoma After Implementation of National Retinoblastoma Treatment Guidelines in South Africa

M Kruger; S L van Elsland; A Davidson; D Stones; E et al ...

https://hdl.handle.net/10539/42676
SCOPUS

Downloaded from a DSpace repository. https://dspace.org/

Check for updates

Outcome of Retinoblastoma After Implementation of National Retinoblastoma Treatment Guidelines in South Africa

Mariana Kruger, MMed Paed, MPhil, PhD, FCPaed (SA)[1,2]; Sabine L. van Elsland, PhD[1,2,3]; Alan Davidson, MBChB (UCT), DCH (SA), FCPaed (SA), CertMed Onc (Paed)[4]; David Stones, FCPaed (SA)[5,6]; Jan du Plessis, FCPaed (SA)[5,6]; Gita Naidu, FCPaed (SA)[7,8]; Jennifer Geel, FCPaed (SA)[9,10]; Janet Poole, FCPaed (SA)[9,10]; Judy Schoeman, PhD[1,2]; Clare Stannard, FF Rad (T) (SA)[11,12]; Hamzah Mustak, FC Ophth(SA)[12,13]; Anel van Zyl, MMed Paed, PhD, FCPaed (SA)[1,2]; Julie Wetter, FC Rad Onc (SA)[11,12]; and Karin Lecuona, FC Ophth (SA)[12,13]

DOI https://doi.org/10.1200/GO.24.00034

ABSTRACT

PURPOSE Retinoblastoma, a curable childhood cancer, has been identified as a tracer cancer in the WHO Global Initiative for Childhood Cancer. To document the outcomes of children with retinoblastoma in South Africa, treated as per the first prospective standard national treatment guidelines for childhood cancer in South Africa.

PATIENTS AND METHODS All children diagnosed with retinoblastoma between 2012 and 2016 in five South African pediatric oncology units were treated with a standard treatment on the basis of the International Society of Pediatric Oncology-Pediatric Oncology in Developing Countries guidelines for high-income settings. Treatment included focal therapy with/without chemotherapy, or enucleation with/without chemotherapy, and orbital radiotherapy, depending on enucleated eye histology. The end point was survival at 24 months, using Kaplan-Meier curves with log-rank (Mantel-Cox) and chi-square ($\chi 2$) tests with respective P values reported.

RESULTS A total of 178 children were included in the study; 68% presented with unilateral disease. The median age was 27 months (range 0-118 months) with a male: female ratio of 1:0.75. The overall survival was 79% at 24 months with significant association with stage at diagnosis ($P < .001$) and older age over 2 years as opposed to younger than 2 years ($P < .001$). Causes of death were disease progression/relapses in 90% (34 of 38) and unknown in 2% (1 of 38), whereas treatment abandonment was 1.7% (3 of 178).

CONCLUSION Efficacy with national treatment guidelines was confirmed, and feasibility of implementing standard national childhood cancer treatment guidelines was documented, involving multidisciplinary teams in South Africa. Outcome was significantly associated with stage at diagnosis and age.

ACCOMPANYING CONTENT

Data Supplement

Protocol

Accepted July 24, 2024
Published August 29, 2024

JCO Global Oncol 10:e2400034

© 2024 by American Society of Clinical Oncology

Licensed under the Creative Commons Attribution 4.0 License

Downloaded from ascopubs.org by University of Witwatersrand (WITS) on October 11, 2024 from 146.141.224.025
Copyright © 2024 American Society of Clinical Oncology. All rights reserved.

INTRODUCTION

Retinoblastoma usually presents in the first 5 years of life.[1] The South African Children's Cancer Study Group Tumour Registry (SACCSG-TR), established in 1987, reported the age-specific standardized rate for retinoblastoma as 3.3 per million for the period 1987 to 2007[2] or as one per 21,641 live births with no difference between the sexes.[3] Survival is excellent in well-resourced settings, reaching nearly 100%.[4,5] Survival is varied in studies reported from Africa, with good survival documented for limited disease but poor outcome for metastatic disease.[6-8]

The standard practice for childhood cancer until 2012 in South African pediatric oncology units (POUs) was to use international childhood cancer treatment guidelines or research guidelines from high-income countries according to their preference or links with international POUs. In 2010-2011, members of the SACCSG embarked on the development of the first standard national treatment guidelines, with ethics approval, for retinoblastoma. The goal of this study is to document the outcome of children with retinoblastoma, after implementation of the national retinoblastoma treatment guidelines in five of the then existing nine POUs in South Africa. To our knowledge, it is therefore the first report of national collaborative retinoblastoma treatment guidelines in South Africa.

PATIENTS AND METHODS

This prospective study included all children diagnosed with retinoblastoma between January 2012 and December 2016 in

CONTEXT

Key Objective

The key objective was to implement national treatment guidelines for retinoblastoma, a rare childhood cancer, with the aim of improving outcome, involving the multidisciplinary treatment team.

Knowledge Generated

The study demonstrated the successful implementation of management guidelines, involving the multidisciplinary team in the management of retinoblastoma in South Africa. To our knowledge, this was the first successful management guideline implemented for a rare childhood cancer in South Africa with improved health care access and equity for all patients with retinoblastoma.

Relevance

South Africa is in the process of introducing universal health care for the population. During this process, it will be necessary to implement feasible management guidelines for rare diseases that will improve both equity access and outcome of such patients. These management guidelines should use the existing health care resources, as demonstrated in this study.

Downloaded from ascopubs.org by University of Witwatersrand (WITS) on October 11, 2024 from 146.141.224.025
Copyright © 2024 American Society of Clinical Oncology. All rights reserved.

five of the nine existing POUs in South Africa with parental informed consent (and assent if age appropriate). Data were extracted from the South African Children's Cancer Study Group Tumor Registry and from patient files. The International Retinoblastoma Staging System was used to document stage (Data Supplement, Tables S1 and S2).[9] Bilateral retinoblastoma was staged according to the most affected eye. Bone marrow and cerebrospinal fluid examinations were performed for stages II to IV.[10]

Intraocular disease (Group A-D, Data Supplement, Table S3) was treated with focal therapy (laser or cryotherapy or transpupillary thermotherapy [TTT] or I-125 plaque radiotherapy) or intra-arterial melphalan according to available resources and the preference of the POU (Table 1; Data Supplement, Tables S2 and S4).[11] Brachytherapy was only available in Groote Schuur hospital in Cape Town with referral of patients from the rest of South Africa to this center (Data Supplement, Table S4). For those eyes not amenable to focal therapy, enucleation was performed, and chemotherapy and/or orbital radiotherapy were given according to the histologic extent of tumor and the likelihood of further spread as per the Society of Pediatric Oncology-Pediatric Oncology in Developing Countries guidelines for middle- to high-income settings with adequate resources (Table 1; Data Supplement, Table S4).[12] The chemotherapy regimen was vincristine, etoposide, and carboplatin given every three to 4 weeks, depending on the neutrophil count.[12] Chemotherapy was delayed if the neutrophil count was <1,000/μL. Orbital radiotherapy was given in the form of I-125 brachytherapy where available or as external beam radiotherapy. Intrathecal chemotherapy (hydrocortisone, cytarabine, and methotrexate for stages II to IV once a week for 6 weeks) was given at the discretion of the individual POU and was included as there was reluctance to exclude this treatment modality in the new national treatment guidelines. Clinical assessments were performed at follow-up visits. Further investigations were only performed if progression of disease or relapses were suspected.

Overall survival (OS) at 12 and 24 months was documented with the end point defined as 24 months postdiagnosis. Log-rank (Mantel-Cox), chi-square (χ^2), and Kaplan-Meier survival curves were calculated. Patients who abandoned treatment were censored at the date last seen. Cox proportional hazards regression analysis compared the survival probabilities among various age groups. A P value of <.05 was considered statistically significant.

The ethics review committees of Stellenbosch University, the University of the Witwatersrand, the University of the Free State, and the University of Cape Town gave ethics approval for the study to be conducted in the five participating POUs. Parental consent was obtained before enrollment in the

TABLE 1. Treatment According to the International Retinoblastoma Staging System Stage

Stage	Treatment Modality
Stage 0	Local therapy: TTT/cryotherapy/I-125 plaque/IACT with or without systemic chemotherapy
Stage I	Enucleation with or without chemotherapy (for C2 with or without S1) with or without orbital brachytherapy/EBRT (for S1 with or without N2 with margin <4 mm)
Stage II	Enucleation + chemotherapy + orbital brachytherapy/EBRT
Stage III	Enucleation with or without preoperative chemotherapy, postoperative chemotherapy + orbital brachytherapy (if no apex/bony involvement)/EBRT (orbit with or without involved nodes)
Stage IV	Enucleation with or without preoperative chemotherapy, postoperative chemotherapy, with or without palliative radiotherapy (EBRT) for metastases

Abbreviations: EBRT, external beam radiation therapy; IACT, intra-arterial chemotherapy; TTT, transpupillary thermotherapy.

study, and custodian consent was obtained to access the patient files.

RESULTS

A total of 178 children were treated from 2012 to 2016 in five POUs in South Africa. There was a slight male preponderance (57%) with a median age of 27 months at diagnosis (age range 0-118 months, standard deviation [SD], 21.5; Table 2). The majority were African children (83%), reflecting the demographics of South Africa,[13] and 68% presented with unilateral disease. There were 15% with stage 0, 44% with stage I, 15% with stage II disease, 7% with stage III, and 12% with stage IV disease (bone marrow involvement). Stage was unknown in 7%. The majority (83%) of the 57 children with bilateral disease (32% of the study population) presented with stages 0-II, whereas 10 had metastatic disease (18%; bone marrow involvement). Two patients were initially diagnosed with stage I unilateral disease but, because of initial treatment refusal, later presented at another POU with stage IV disease where they were included in the study and were treated for metastatic disease. One patient presented with trilateral retinoblastoma with distant metastasis (stage IV).

Thirty-four (19%) patients received focal therapy to the affected eye. Six children with unilateral stage 0 disease received only focal therapy to the affected eye, whereas four children with bilateral disease received focal therapy to only one affected eye. Enucleation was performed for 124 (70%) patients, including two patients with bilateral disease. Only 25 (14%) had enucleation as monotherapy. The majority, namely, 129 (73%), received six cycles of chemotherapy. There were 24 (41%) who received orbital brachytherapy and 35 (59%) who received orbital external beam radiotherapy (Table 2).

The OS was 83% (148 of 178) at 12 months postdiagnosis and 79% (140 of 178) with an estimated cumulative survival of 0.786 (SE, 0.031) at 24 months (study end point; Fig 1). Children with an unknown stage had a 69.2% (9 of 13) OS at 24 months. Stage and age at diagnosis (2 years and older as opposed to younger than 2 years) were significantly associated with OS at 24 months ($P < .001$ and $P < .00,1$ respectively; Fig 2). There was no significant difference in OS between unilateral versus bilateral disease ($P = .707$) or sex ($P = .444$). Survival was 96% for stage 0, 91% for stage I, 89% for stage II, 58% for stage III, and 14% for stage IV. The cumulative proportion surviving was 0.963 for stage 0 (SE, 0.0369), 0.910 for stage I (SE, 0.032), 0.889 for stage II (SE, 0.060), 0.583 for stage III (SE, 0.142), and 0.143 for stage IV (SE, 0.076). For stages 0-II, the OS was 91.7% (121 of 132) with a cumulative proportion surviving of 0.917 (SE, 0.024), and for metastatic bilateral disease, the OS was 30.3%% (10 of 33) with a cumulative proportion surviving of 0.222 (SE, 0.303).

TABLE 2. Overview Demographics and Clinical Characteristics

Characteristic	N = 178	No. (%)
Sex	Male	102 (57.3)
	Female	76 (42.7)
Age (months)	Mean (min-max, SD)	30.1 (0-118, 21.5)
	Median (IQR)	27.0 (15.0-39.3)
	<24 months	75 (42.1)
	=/>24 months	103 (57.9)
Laterality	Unilateral	121 (68.0)
	Bilateral	57 (32.0)
IRSS staging	0	27 (15.2)
	I	78 (43.8)
	II	27 (15.2)
	III	12 (6.7)
	IV	21 (11.8)
	Unknown	13 (7.3)
Focal therapy	TTT, cryo, I-125 plaque	34 (19.1)
Enucleation		124 (69.7)
Chemotherapy		129 (72.5)
Orbital radiotherapy		59 (33.1)
	Brachytherapy	24 (13.4)
	External beam	35 (19.7)
Outcome	Survived (at the 12-month follow-up)	148 (83.1)
	Survived (at the 24-month follow-up)	140 (78.7)

Abbreviations: cryo, cryotherapy; IRSS, International Retinoblastoma Staging System; SD, standard deviation; TTT, transpupillary thermotherapy.

Downloaded from ascopubs.org by University of Witwatersrand (WITS) on October 11, 2024 from 146.141.224.025
Copyright © 2024 American Society of Clinical Oncology. All rights reserved.

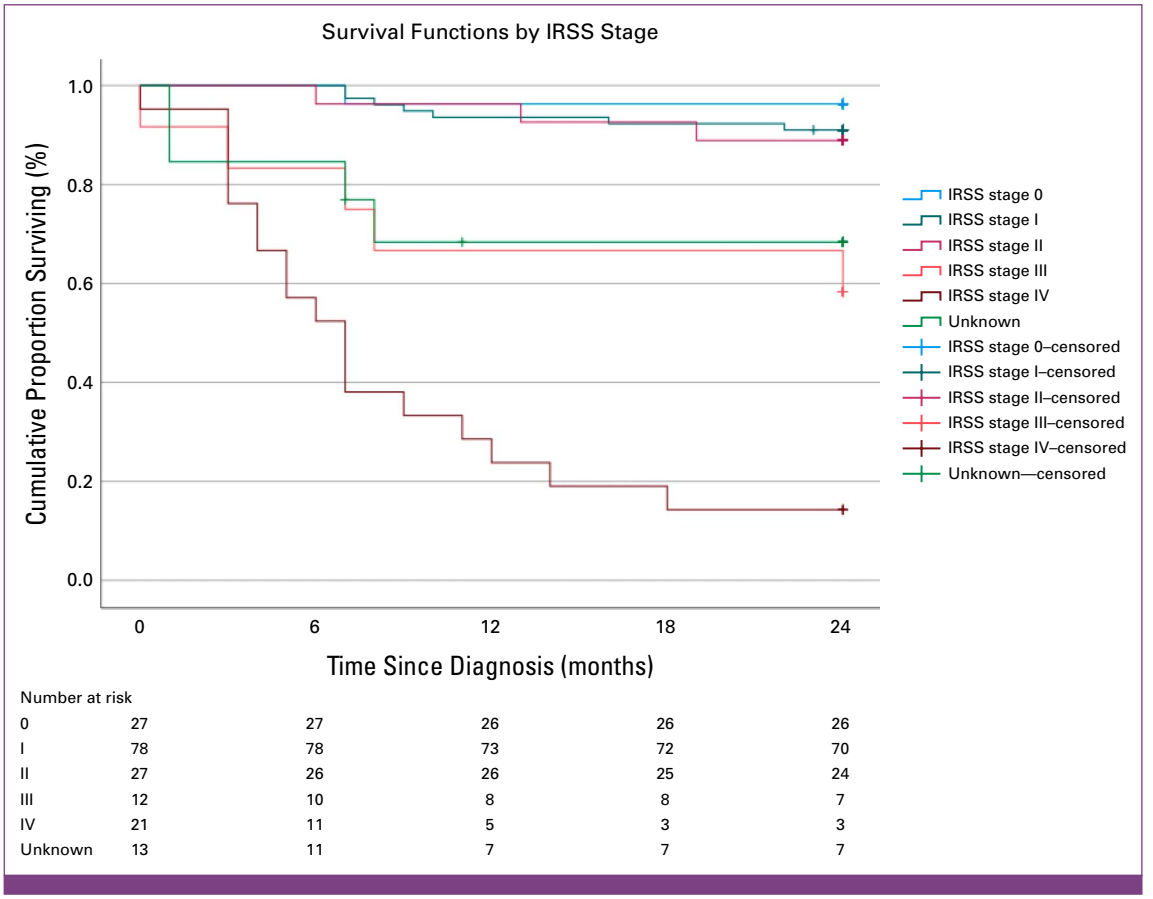

FIG 1. Kaplan-Meier overall survival at 24 months of unilateral eye or most affected eye of bilateral disease for the full cohort by clinical stage (IRSS stage[9]). IRSS, International Retinoblastoma Staging System.

Occurred events were deaths in 20% (35 of 178) and treatment abandonment in 1.7% (3 of 178). Causes of death were progression or relapse (90%, 34 of 35) or unknown (2%, 1 of 35; Data Supplement, Table S4). Two of the three children, who absconded, had unilateral disease with unknown stage. They absconded within 1 month of diagnosis and could be presumed dead. One child had stage one disease and absconded 4 months after enucleation only. Both the reason and their outcome at data analysis were unknown.

The Kaplan-Meier median survival time for those who died because of disease progression was 7.0 months (SE, 0.410; 95% CI [6.196 to 7.804]). One child with limited bilateral disease had an unknown cause of death.

DISCUSSION

Kivelä et al[14] reported in 2009 that retinoblastoma seemed to be more common in Asia, Africa, and Latin America than in Europe and North America, with the mortality rate the greatest in Africa, i.e. 70%. Fabian et al[15] reported in 2020 that the majority (85%) of children diagnosed with retinoblastoma between June 2017 and December 2018 were from low- and middle-income countries. As retinoblastoma is eminently curable, this disease was chosen as the first childhood cancer for the development of a standard national childhood cancer management study in South Africa. Children were treated according to standardized treatment guidelines, including focal therapy, adjuvant chemotherapy, and radiotherapy when indicated. Five of the then existing POUs in South Africa participated. Four POUs did not participate for various reasons related to resource limitations (personal communication). This study demonstrated the feasibility of treating a childhood cancer with national standardized treatment guidelines, involving a multidisciplinary team in South Africa.

The median age at diagnosis in this population was 27 months, which was older than the median age of patients diagnosed in high-income countries (median age of 14 months).[15] However, the ratio between those with unilateral disease versus bilateral disease was similar to previously reported ratios.[16]

Staging of retinoblastoma, both clinical and histologic, is crucial for both the necessary assignment to appropriate management strategies and prediction of prognosis. The study used the International Retinoblastoma Staging System, which has been proven to be effective in grouping patients with an increased risk of relapse or progression of

Downloaded from ascopubs.org by University of Witwatersrand (WITS) on October 11, 2024 from 146.141.224.025
Copyright © 2024 American Society of Clinical Oncology. All rights reserved.

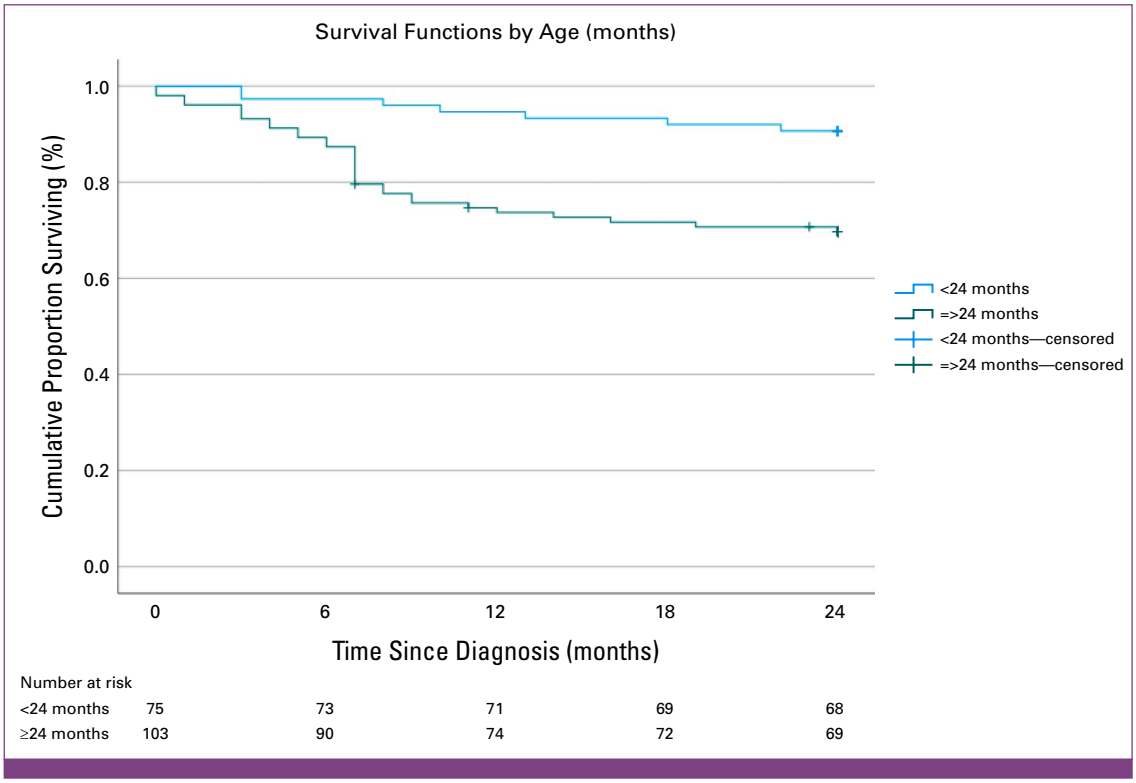

FIG 2. Kaplan-Meier overall survival at 24 months of unilateral eye or most affected eye of bilateral disease for the full cohort by age (younger than 24 months and 24 months and older).

disease.[10] Both Stannard et al and Tomar et al reported that the presence of extraocular disease was significantly associated with poor outcome.[16,17] Our study demonstrated that prognosis worsened when retinoblastoma breached the ocular borders. Stage and age were the only statistically significant predictors of poor outcome, which is in accordance with the findings of a prospective global retinoblastoma outcome study. The presence of bilateral disease had no significant effect on OS, as reported previously.[14]

Nearly a fifth of patients had stage III to IV disease, necessitating therapeutic chemotherapy with enucleation. This finding correlates with reports that there is an increased risk of extraocular retinoblastoma at presentation in sub-Saharan African countries.[14,15] The reasons for delayed diagnosis in South Africa may be the lack of awareness among both the public and health care workers and distance from treatment facilities.[15] Treatment abandonment was documented in three children (1.7% of study population), which was lower than the 3.8% reported in the prospective global retinoblastoma study[18] or the 7% reported by the CANCare-Africa group of childhood cancer treatment abandonment in sub-Saharan Africa.[19] Abandonment in both studies was due to parental financial constraints and was most likely the cause for the three children with abandonment in this study, as 18.2 million South Africans lived in extreme poverty, namely on $1.90 US dollars per day.[20]

A limitation of the study was that the data entry per site was only collated at the end of the study, and so potentially, important information regarding treatment delays and late diagnosis was not captured, especially the timing of enucleation. Another limitation was the fact that not all South African POUs participated and, as they serviced different regions, did not assist in highlighting potential resource constraints that could assist with future improvement in the management of the treatment of retinoblastoma. Moreover, staging was performed by the primary treating physician and was not reviewed by a centralized panel of experts, which could have ensured that staging was uniformly assigned. At the initiation of this study, most South African treatment centers did not have the capacity to administer intra-arterial or intravitreal chemotherapy, whereas the ability to administer TTT was also severely constrained.

In conclusion, this study demonstrates the feasibility of harmonized management guidelines for retinoblastoma, a challenging but curable childhood cancer. Efforts should be made to ensure early diagnosis through education of health care workers and the public regarding the early signs of retinoblastoma to allow for vision preservation and reduce late presentation. Further standardized management guidelines would be revised and expanded to include intra-arterial chemotherapy as the standard of care for eyes amenable to targeted therapy. The overarching aim should be to preserve vision and improve outcome.

Downloaded from ascopubs.org by University of Witwatersrand (WITS) on October 11, 2024 from 146.141.224.025
Copyright © 2024 American Society of Clinical Oncology. All rights reserved.

AFFILIATIONS

[1]Department of Pediatrics and Child Health, Faculty of Medicine and Health Sciences, Stellenbosch University, Cape Town, South Africa
[2]Tygerberg Hospital, Cape Town, South Africa
[3]MRC Centre for Global Infectious Disease Analysis, School of Public Health, Imperial College London, London, United Kingdom
[4]Haematology-Oncology Service, Department of Pediatrics and Child Health, Red Cross Children's Hospital, University of Cape Town, Cape Town, South Africa
[5]Department of Pediatrics, University of the Free State, Bloemfontein, South Africa
[6]Universitas Hospital, Bloemfontein, South Africa
[7]Department of Pediatrics and Child Health, University of the Witwatersrand, Johannesburg, South Africa
[8]Chris Hani Baragwanath Academic Hospital, Johannesburg, South Africa
[9]Division of Pediatric Hematology Oncology, Department of Pediatrics and Child Health, Faculty of Health Sciences, School of Clinical Medicine, University of the Witwatersrand, Johannesburg, South Africa
[10]Charlotte Maxeke Johannesburg Academic Hospital, Johannesburg, South Africa
[11]Department Radiation Oncology, Groote Schuur Hospital, Cape Town, South Africa
[12]Faculty of Health Sciences, University of Cape Town, Cape Town, South Africa
[13]Department of Ophthalmology, Groote Schuur Hospital, Cape Town, South Africa

CORRESPONDING AUTHOR

Mariana Kruger, MMed Paed, MPhil, PhD, FCPaed (SA); e-mail: marianakruger@sun.ac.za.

AUTHOR CONTRIBUTIONS

Conception and design: Mariana Kruger, Clare Stannard, Karin Lecuona
Provision of study materials or patients: All authors
Collection and assembly of data: All authors
Data analysis and interpretation: Mariana Kruger, Sabine L. van Elsland
Manuscript writing: All authors
Final approval of manuscript: All authors
Accountable for all aspects of the work: All authors

AUTHORS' DISCLOSURES OF POTENTIAL CONFLICTS OF INTEREST

The following represents disclosure information provided by authors of this manuscript. All relationships are considered compensated unless otherwise noted. Relationships are self-held unless noted. I = Immediate Family Member, Inst = My Institution. Relationships may not relate to the subject matter of this manuscript. For more information about ASCO's conflict of interest policy, please refer to www.asco.org/rwc or ascopubs.org/go/authors/author-center.
Open Payments is a public database containing information reported by companies about payments made to US-licensed physicians (Open Payments).

Mariana Kruger
Expert Testimony: Advisory Clinical Committee of the South African Health Products Regulatory Authority (SAHPRA), Mediclinic Southern Africa

Alan Davidson
Consulting or Advisory Role: Sanofi, MediClinic Dubai
Speakers' Bureau: Key Oncologics, Roche, Novartis

Anel van Zyl
Consulting or Advisory Role: Roche, Novo Nordisk

Julie Wetter
Travel, Accommodations, Expenses: Roche/Genentech, Regeneron

No other potential conflicts of interest were reported.

ACKNOWLEDGMENT

We acknowledge Linda Wainwright for her contribution in the development of the national retinoblastoma guideline and the recruitment of patients into this prospective national study.

REFERENCES

1. Fabian ID, Sagoo MS: Understanding retinoblastoma: Epidemiology and genetics. Community Eye Health 31:7, 2018
2. Stefan DC, Stones DK, Wainwright RD, et al: Childhood cancer incidence in South Africa, 1987-2007. S Afr Med J 105:939-947, 2015
3. Stuart KV, Shepherd DJ, Kruger M, et al: The incidence of retinoblastoma in South Africa: Findings from the South African national cancer Registry (2004-2018). Ophthalmic Epidemiol 29:681-687, 2021
4. Johnston WT, Lightfoot TJ, Simpson J, et al: Childhood cancer survival: A report from the United Kingdom childhood cancer study. Cancer Epidemiol 34:659-666, 2010
5. Broaddus E, Topham A, Singh AD: Survival with retinoblastoma in the USA: 1975-2004. Br J Ophthalmol 93:24-27, 2009
6. Waddell K, Matua M, Bidwell C, et al: A ten-year study of retinoblastoma in Uganda: An approach to improving outcome with limited resources. Cancer Epidemiol 71:101777, 2021
7. Kruger M, Reynders D, Omar F, et al: Retinoblastoma outcome at a single institution in South Africa. S Afr Med J 104:859-863, 2014
8. Cole C: Registering childhood cancers. Lancet. 364:2074-2076, 2004
9. Chantada G, Doz F, Antoneli CB, et al: A proposal for an international retinoblastoma staging system. Pediatr Blood Cancer 47:801-805, 2006
10. Chantada GL, Sampor C, Bosaleh A, et al: Comparison of staging systems for extraocular retinoblastoma: Analysis of 533 patients. JAMA Ophthalmol 131:1127-1134, 2013
11. Linn Murphree A: Intraocular retinoblastoma: The case for a new group classification. Ophthalmol Clin North Am 18:41-53, 2005
12. Chantada G, Luna-Fineman S, Sitorus RS, et al: SIOP-PODC recommendations for graduated-intensity treatment of retinoblastoma in developing countries. Pediatr Blood Cancer 60: 719-727, 2013
13. Department of Statistics South Africa: Statistical Release P0302. Mid-year Population Estimates 2021. http://www.statssa.gov.za/publications/P0302/P03022021.pdf
14. Kivelä T: The epidemiological challenge of the most frequent eye cancer: Retinoblastoma, an issue of birth and death. Br J Ophthalmol 93:1129-1131, 2009
15. Global Retinoblastoma Study Group, Fabian ID, Abdallah E, Abdullahi SU, et al: Global retinoblastoma presentation and analysis by national income level. JAMA Oncol 6:685-695, 2020
16. Stannard C, Lipper S, Sealy R, et al: Retinoblastoma: Correlation of invasion of the optic nerve and choroid with prognosis and metastases. Br J Ophthalmol 63:560-570, 1979
17. Tomar AS, Finger PT, Gallie B, et al; American Joint Committee on Cancer Ophthalmic Oncology Task Force: Global retinoblastoma treatment outcomes: Association with national income level. Ophthalmology 128:740-753, 2021

Downloaded from ascopubs.org by University of Witwatersrand (WITS) on October 11, 2024 from 146.141.224.025
Copyright © 2024 American Society of Clinical Oncology. All rights reserved.

18. Global Retinoblastoma Study Group, Abdallah E, Abdullahi SU, Abdulqader RA, et al: The global retinoblastoma outcome study: A prospective, cluster-based analysis of 4064 patients from 149 countries. Lancet Glob Health 10:e1128-e1140, 2022
19. Chagaluka G, Afungchwi GM, Landman L, et al: Treatment abandonment: A report from the collaborative African network for childhood cancer care and research—CANCaRe Africa. Pediatr Blood Cancer 68:e29367, 2021
20. Number of people living in extreme poverty in South Africa from 2016 to 2030. https://www.statista.com/statistics/1263290/number-of-people-living-in-extreme-poverty-in-south-africa/

Downloaded from ascopubs.org by University of Witwatersrand (WITS) on October 11, 2024 from 146.141.224.025
Copyright © 2024 American Society of Clinical Oncology. All rights reserved.