

https://dspace.org/

The histological appearance of the epithelium and related structures of the buccal cavity of the gold fish

King, Rodney Edwin

2015-05-15
http://hdl.handle.net/10539/17766

Downloaded from a DSpace repository. https://dspace.org/

THE HISTOLOGICAL APPEARANCE OF THE EPITHELIUM AND RELATED STRUCTURES OF THE BUCCAL CAVITY OF THE GOLDFISH

by

RODNEY EDWIN KING

Dissertation submitted to the Faculty of Science, University of the Witwatersrand, Johannesburg, in fulfilment of the requirements for the degree of Master of Science.

Johannesburg,
September, 1973.

I hereby declare that this dissertation is my own work, and has not been submitted or incorporated in another dissertation or thesis for any other degree.

.....

R. E. KING

PROLOGUE

A story told in the Shu I Chi (Record of Stories of Marvels) -

'In Shensi there was a Goldfish God. In the second year of the reign of the Emperor P'ing (769 B.C.) of the Chou Dynasty, no rain fell for one hundred days, and while sacrifices were being made to appease the Gods, suddenly a bubbling well appeared, a goldfish leaped out, and the rain fell'.

This story is not intended by the Chinese to account for the origin of the goldfish. However, the same Shu I Chi says that 'Huan Ch'ung (328 - 384) of the Chin Dynasty (265 - 420) visiting Mount Lu saw that in the lake were fish with red scales'.

In the Pao P'o Tzu, written by Ko Hung in the fourth century, it says, 'The Red River rises in the Chung-ling Hills in the Shang-lo District of the Metropolis (Shensi) and flows into the Cho River. Redfish are produced in it'.

These red-scaled fish first observed by the Chinese in natural waters about sixteen hundred years ago were wild fish, and not until many years later do we find records of them being domesticated under the name of Chin Chi-yu or GOLDFISH (Hervey and Hems - The Goldfish).

ACKNOWLEDGEMENTS

My most grateful thanks are due to Professor R. Trevor-Jones, not only for the facilities in his Department and the sacrifice of his valuable time, but for making the possibility of this dissertation become a reality.

My wife and daughter have provided me with much encouragement and have been extremely patient when the many extra hours required have taken me from home.

Professor D. H. Retief and Dr. P. E. Cleaton-Jones have offered a lot of worthy criticism. By giving so freely of their valuable time, they provided a source of assistance for which I am deeply indebted.

Mrs. J. McInnes has been a constant source of help in many ways and my thanks are due to her for helping me through a difficult time.

Last, but by no means the least, Mrs. J. G. Grant has earned a special vote of thanks for patiently typing and re-typing the manuscript. Her invaluable aid made it possible for an organised layout to emerge from the chaos, clarifying my thoughts in the process and encouraging me with her interest.

ABSTRACT

A considerable amount of literature is available regarding various aspects of fish behaviour, anatomy, histology, dentition and feeding habits. Authoritative sources describe certain features and behavioural responses under experimental conditions of varying species of fish and frequently lead one to assume that stated facts generally apply to all species. Detailed information regarding any one species is scanty and a book of general teleost anatomy appears to be unavailable.

Further, much evidence is presented to support the belief of many ichthyologists that fish are devoid of a sense of taste. Many contradictory arguments are presented concerning the sense of smell and the common chemical sense and many statements are made regarding the fish's inability to taste, often without any supporting evidence.

It was decided, therefore, to confine the present study to one species of fish that was readily available and easy to maintain in the laboratory, the goldfish, Carassius auratus.

Feeding behaviour has been observed in order to determine whether or not this fish masticates its food or, as in the opinion of many authors, simply gulps food directly into its stomach.

The buccal cavity has been selected for detailed examination because many past investigators have begun their descriptions at the posterior pharynx, providing only scanty information with regard to the buccal cavity. It is of special interest that certain regions of the buccal cavity of the goldfish possess a vast number of taste organs, a feature that is either absent in other species, or has not been considered worthy of particular emphasis by other investigators. Emphasis has been placed upon the taste-bud system in the goldfish in an attempt to present evidence for a sense of taste in this particular species, because no other function can be

attributed to this highly specialised mechanism.

An anatomical description has been made, supported by illustrations of the ventral floor, lateral walls and dorsal roof. This was done by cutting heads in a sagittal and longitudinal plane and observing the distribution of the oral mucosa. Further information was obtained by decalcifying a whole head and producing transverse sections too thick for histological detail but adequate for additional micro-anatomical observations.

Histological studies were carried out on the various regions which make up the buccal cavity by using the paraffin-wax embedding procedure, followed by a series of routine histological staining methods. Special metal impregnation techniques have been applied in an attempt to demonstrate nerve endings in the taste-bud system. The presence of large numbers of mucous goblet cells in the epithelium indicated the necessity for some basic carbohydrate histochemistry and it is postulated that these cells in certain locations compersate to some extent for the absence of salivary glands.

Scanning electron microscopy was included to substantiate the previous findings and surface-view details have been used to confirm the functions of the various regions.

The information obtained has been used in an attempt to consolidate a series of observations relevant to one species and to determine whether or not the goldfish is a discriminating feeder, masticates its food and is sensible to taste.

CONTENTS

	PAGE
Declaration	i
Prologue	ii
Acknowledgements	iii
Abstract	iv - v
Contents	vi - viii

CHAPTER I

INTRODUCTION	1
1.1. Aim of investigation	1
1.2. General	2
1.3. The common goldfish	6
1.4. Variations from the common goldfish	6
1.5. Classification	8

CHAPTER II

MATERIALS AND METHODS	9
2.1. General information	9
2.2. Plan of investigation	9
2.3. Age and sex determination	10
2.4. Fate of specimens	10
2.5. Fixation of tissue	11
2.6. Processing of tissue	11
2.7. Histochemistry	12
2.8. Histological methods	12
2.9. Microphotography and illustrations	13

CHAPTER III

PAGE

MORPHOLOGY OF THE BUCCAL CAVITY 14

3.1. General notes on the buccal cavity and variations in the dentition 14

3.2. The buccal cavity of some cyprinids 15

3.3. The buccal cavity of the goldfish 17

3.4. The floor 17

3.5. The roof 19

3.6. The lateral walls 22

3.7. Nerve supply 22

3.8. The protrusible mechanism of the mouth 25

3.9. The branchial apparatus 26

3.10. Gills and gill rakers 26

CHAPTER IV

THE BUCCAL CAVITY AS REVEALED BY THICK TRANSVERSE SECTIONS 29

4.1. General 29

4.2. Shape and contents of the buccal cavity 30

CHAPTER V

HISTOLOGY AND HISTOCHEMISTRY OF THE BUCCAL CAVITY OF THE GOLDFISH 41

5.1. General 41

5.2. Ventral floor 41

5.3. Lateral walls 47

5.4. Dorsal roof 48

5.5. Taste-buds in the goldfish 54

5.6. Histochemistry 60

CHAPTER VI

THE BUCCAL MUCOSA AS REVEALED BY THE SCANNING ELECTRON MICROSCOPE 71

6.1. General 71

6.2. Ventral floor 75

PAGE

6.3. Lateral walls 77
6.4. Dorsal roof 78

CHAPTER VII

OBSERVATIONS ON FEEDING BEHAVIOUR 83

CHAPTER VIII

DISCUSSION 87
8.1. General 87
8.2. Mucous glands 88
8.3. The alimentary tract 89
8.4. Feeding habits 90
8.5. Mastication 91
8.6. The taste-bud system, chemoreceptors and smell 92
8.7. Nerve supply 98
8.8. Unidentified gland 99

CHAPTER IX

CONCLUSIONS 100

LIST OF REFERENCES 103

CHAPTER 1

INTRODUCTION

1.1. Aim of Investigation

A considerable amount of literature is available regarding the feeding habits, mouth form and dentition of fishes, both bony and cartilaginous. However, much of it is contradictory and inadequate in its coverage. For instance, Parker (1912) claimed that, 'in addition to smell and taste vertebrates possess a third sense' which he called 'a common chemical sense', but quoted Nagel as saying that 'the nose of water inhabiting vertebrates is an organ of taste rather than smell'. Route (1935) stated that 'in fish, taste is from an external source, and the sense of taste behaves like a sense of smell. The creature tastes at a distance'. Barrington (1942) described the Cyclostomata (lampreys and hagfish) and said that 'the absence of a stomach in these jawless vertebrates was regarded as a primitive feature'. However, when referring to certain species in a later report he said that 'the absence of a stomach was a secondary feature and not a primitive one'. The Life Nature Library volume (1964), 'The Fishes', stated that 'the sense of taste is probably not an important one in any fish's life and that they do not have taste organs in their mouths'. Smith (1961) simply said that 'little is known about the sense of taste, but it probably functions to some extent'. The broad generalisations made by various authors lead one to assume that these facts or descriptions may be applied to many species of fish.

Because so many authors are at variance with one another, it was decided to confine the present study to one species of fish only and provide a detailed description of the buccal cavity and its related structures. The main emphasis is on the histological appearances, with supporting anatomical details and observations on the feeding behaviour.

The goldfish was chosen because of on interest which was stimulated by its many variations, its ready availability and ease of maintenance.

1.2. General

The goldfish (Carassius auratus), like the carp, is a cyprinid fish. It is indigenous to Eastern Asia but has been introduced by man into many other parts of the world.

It is closely related to the Crucian carp of Europe and Northern Asia. Both species resemble the common carp, having a long dorsal fin, but differ from it in having no barbels. The goldfish flourishes in ponds and feeds on reeds and small invertebrates. In the wild state the coloration is generally greenish-brown but specimens do occur with brown or black patches, with the rest being bright orange in colour.

These golden fish have been bred by the Chinese for centuries and many strange and monstrous types, varying in colour and shape, have been produced. As a result, fish with silvery patches or even pure white are not uncommon.

Goldfish were introduced from China into Japan. For hundreds of years the Japanese have cultivated them in ponds and, by cross breeding, produced many varieties.

From this long-finned, single-tailed fish (Figure 1), veiltails, fringetails and fantails have been developed. The telescope has large, protruding eyes, equally spaced and developed. This is a feature which can appear in either the veiltail or fantail. It is, however, a special characteristic of the black moor which, ideally, is an even, deep black colour. Orandas have a fleshy, warty growth on the head, varying in size from a slight protuberance on the dorsal aspect to a complete hood over all the head and surrounding the eyes. This, in turn, is taken a step further in the lionhead, the most prized of double-tailed fish without dorsal fins. Taking longer to develop and perfect, the Japanese consider the lionhead to be the most prized goldfish and, consequently, specialised lionhead ('Ranchu') societies have been formed. This fish alone has many variations depending on the degree to which the fleshy hoods cover the head, the ideal being an extensive hood covering the whole head, surrounding the eyes and extending over the gill covers.

Other variants include the celestial with telescope eyes which point directly upwards, the bubble-eye, with large, fluid-filled sacs hanging beneath each eye and the pom-pon which has a waving, frilly appendage over each nostril (Figure 2).

When the goldfish escapes from artificial pools into rivers, it reverts to the original greenish-brown colour and attains a length of from six to twelve inches (Encyclopaedia Britannica).

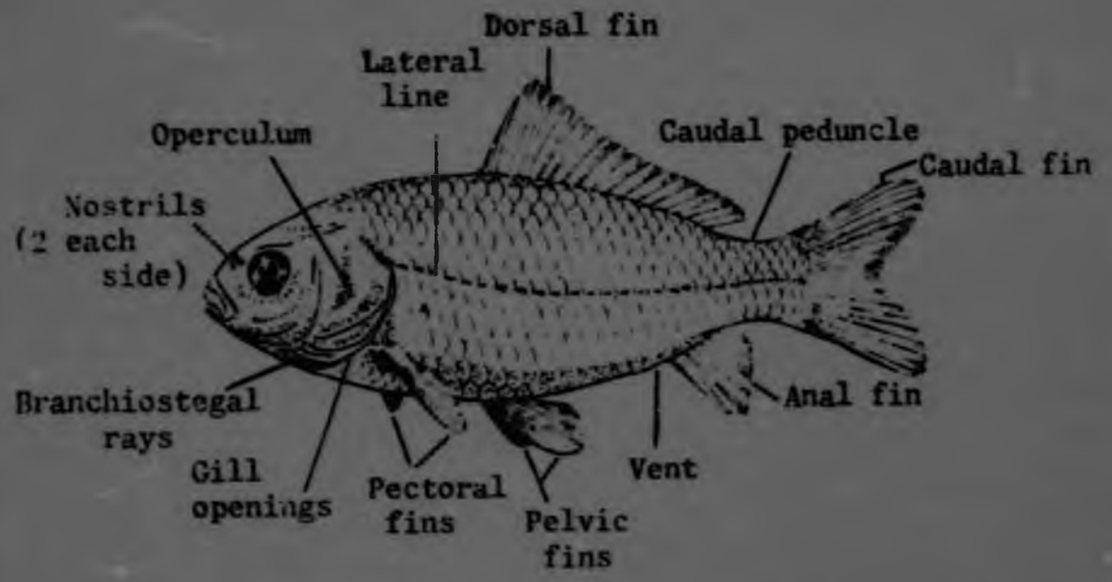

Figure 1.

THE COMMON GOLDFISH (Carassius auratus).



Figure 2. Some variations of the common goldfish.

1.3. The common goldfish

Harvey and Hems (1948) established that the common goldfish is a distinct species and not a variation of the Crucian carp or the common carp.

Externally, the common carp (Cyprinus carpio communis), found throughout the Old World, can be distinguished from both members of the genus Carassius by the presence of a pair of barbels at each corner of the mouth.

Internally, the most striking difference is the arrangements of the pharyngeal teeth. In Cyprinus they form three rows, whereas in Carassius there is only a single row.

It is not so easy to distinguish the wild form of goldfish from the Crucian carp, since they are closely related. The most obvious difference is the shape of the dorsal fin and the body. A more exact method is by counting the scales. The Crucian carp has twenty-eight to thirty-five scales along the lateral line and from seven to nine between the dorsal spine and lateral line. The wild goldfish has proportionately larger scales, numbering from twenty-eight to thirty-one along the lateral line and six between the dorsal spine and lateral line. In domestication, the two species will seldom be confused, since only the highly coloured mutants of goldfish are encouraged by breeders. A source of difficulty which has led to confusion in the past, lies in the fact that the two species are so closely related that they hybridise readily.

The wild stock of eastern Asiatic waters show a strong tendency to xanthochroism (loss of black pigment and consequent golden colour). It was postulated by Hervey and Hems (1948) that this might be due to the mineral content of the local waters, for one has to remember that much of China and the whole of Japan are of recent (geologically speaking) volcanic origin, so that the water of these countries contains a considerable amount of dissolved minerals. It was from these xanthochroous fish that the Chinese were able to develop the many fancy breeds.

The common goldfish is known as Chin-yu in China and Kingyo in Japan.

1.4. Variations from the common goldfish

Among fishes, the goldfish is unique, for Chen (1925) has estimated that from this common ancestor, about 126 breeds of fancy goldfish have been developed. This number is, of course, largely academic, since nearly every breed has a number

of sub-breeds and, today, approximately thirteen varieties are commercially available. It should be appreciated that these fishes are distinguished one from another by characteristics obvious to fish breeders which are not necessarily acceptable to a taxonomist.

Thus, goldfishes are placed into the following categories:-

Group I. SINGLE-TAILED FISH

(a) Common goldfish
(b) Comet
(c) Shubunkin.

Group II. DOUBLE-TAILED FISH WITH DORSAL FIN

(a) Veiltail (Fringetail, Broadtail)
(b) Fantail
(c) Telescope
(d) Oranda
(e) Moor
(f) Pearlscale.

Group III. DOUBLE-TAILED FISH WITHOUT DORSAL FIN

(a) Lionhead
(b) Celestial
(c) Bubble-eye
(d) Pom-pon.

In South Africa, the varieties of goldfish most readily available are:-

(1) SINGLE-TAILED; the common goldfish Carassius auratus, and the Comet, also Carassius auratus.

The common goldfish is not a frequent inhabitant of the small aquaria, although it is a most popular fish in ponds.

(2) VARIANTS; with the double tail and dorsal fin. Of these, the fantail is most common, although the Moor and the Telescope are available, all three being varieties of Carassius auratus.

1.5. Classification

The bony fishes of the world belong to the order Ostariophysi (Young, 1962). This order may be further sub-divided into freshwater and marine bony fishes. Those from a freshwater environment also vary as to whether they belong to the Old World or the New World.

The Old World fishes are sub-divided into two large sub-orders:-

A. The carp family (Cyprinidae);
B. The catfishes (Siluroidea).

To the carp sub-order belong:-

The Characins (Characinidae);
The Suckers (Catastomidae);
The Loaches (Cobitidae).

The Cyprinidae is the largest of all fish families and contains about two thousand species. It is characterised by its members having toothless jaws, the only dentition being a set of toothlike processes on certain highly modified gill-bones known as pharyngeals. These pharyngeal teeth are important in classifying the family, since this huge family shows many further lines of divergence. It is divided into a large number of genera, each of which includes several families.

One genera is Carassius, containing two species, Carassius carassius (the Crucian carp) and Carassius auratus (the common goldfish), classified as follows:-

Class - Pisces
Order - Ostariophysi
Sub-Order - Cyprinoidea
Family - Cyprinidae
Genera - Carassius
Species - Carassius auratus.

CHAPTER II

MATERIALS AND METHODS

2.1. General information

Goldfish of the fantail and comet varieties were maintained in a tank measuring 61,00 centimetres x 30,50 centimetres x 30,50 centimetres. The tank was kept at room temperature and was constantly aerated by means of a motorised pump. The fish were obtained from a variety of sources and no specimen records were available. Four common goldfish were obtained from a garden pond. Eleven specimens were studied. Of these, three were of the common type and the remainder were fantails and comets.

2.2. Plan of investigation

Eleven goldfish of three varieties were obtained. The three common goldfish were immersed in 10 per cent formol saline which both killed and fixed them. The comets and fantails were maintained in the tank for observation and subsequent study.

The largest of the common goldfish was used for the study of the buccal cavity as a whole. For this, a dissecting microscope with a drawing tube attachment was used. A more detailed study of the buccal cavity was made by examining thick, twenty micron transverse sections of the decalcified head of a small fish, using magnifications of x40 or less.

The mucosal lining of the roof, floor and walls of the buccal cavity was stripped from the mouth to the pharynx. The lining of the roof included the so-called palatine organ of Valatour. These tissues were divided longitudinally and sectioned serially for histological examination.

Tissues from two specimens were examined by scanning electron microscopy. It was hoped that this method would assist in interpreting the macroscopic and microscopic appearances.

2.3. Age and sex determination

It was not possible to estimate the exact age of the fishes used since their source of origin was unknown. Size was not a reliable indication of age because size was inversely proportional to the size of the tank Specimens were therefore classified as simply being small, medium or large. In these categories specimens measuring up to six centimetres were considered as being small, those between six to eight and a half centimetres as medium and from eight and a half to ten centimetres as being large.

Sex determination was not considered to be relevant to this study.

2.4. Fate of specimens

The three largest common goldfish were reserved for macroscopical observations. These were:-

(1) dissected for examination of the brain and nerve supply to the palatine organ;

(2) decapitated and cut in a sagittal plane for examination of the lateral walls and protrusible mechanism of the mouth;

(3) decapitated and cut in coronal plane for examination of the dorsal roof and ventral floor.

Six specimens were reserved for the study of the palatine organ, sub-divided as follows:-

(1) the palatine organ of Valatour was removed from a common goldfish for histological examination and divided longitudinally through the median groove. The calcified spicules were removed from one half and the specimen sectioned transversely throughout its entire length. The second half was decalcified and sectioned longitudinally;

(2) the palatine organ was removed from one fantail;

(3) the palatine organ was removed from one comet for comparison with that of the fantail.

The palatine organs were removed from three fantails and fixed according to:-

(4) Bodian (1937);

(5) Fitzgerald (1964);

(6) Ranvier-Loewitt (cited by Drury and Wallington, 1967).

Two specimens were reserved for scanning electron microscopy:-

(1) contents of buccal cavity removed from one fantail and prepared for examination with the scanning electron microscope:

(2) contents of buccal cavity removed from one comet and prepared for examination with the scanning electron microscope.

2.5. Fixation of tissue

All tissues were fixed in 10 per cent formol saline, except for two which were reserved for metal impregnation techniques. These were fixed in picric acid and lemon juice respectively.

2.6. Processing of tissue

Dehydration was carried out in ascending grades of alcohol, clearing in chloroform and tissues were embedded in histological wax* with a melting point of 56° C. Sections were cut on a Jung sliding microtome** with a plane wedge knife. The thickness of sections varied between six to eight microns, except in the case of the one specimen required for some orientation to the buccal cavity. In this case,

---

* Histological Paraffin Wax, M.P. 56-60° C., E. Merck, D.61 Darmstadt, Germany.

** F Jung A.G., Heidelburg, West Germany.

the whole head was cut transversely in twenty microns thick sections. Ten per cent formic acid* was used for decalcifying tissues where necessary. All chemicals and reagents were of Merck standard.

2.7. Histochemistry

Histochemical techniques were confined to two basic methods, these being:-

(1) P.A.S. reaction for carbohydrates according to Bancroft (1967);

(2) Alcian blue method for acid mucopolysaccharides according to Steedman (1950).

2.8. Histological methods

Sections cut at twenty microns thickness were arranged with five sections on each slide. The slides were stained alternately with Mayer's haematoxylin and eosin and Masson's trichrome.

Serial sections were prepared from the remaining specimens and the slides were stained in the following series for routine histological examination:-

(1) Mayer's haematoxylin and eosin;

(2) Masson's trichrome;

(3) Haematoxylin and Van Gieson;

(4) Verhoef's method;

all according to Clayden (1962).

For reticulin:-

(5) Gordon and Sweet's (1936) modification;

For histochemistry:-

(6) P.A.S. reaction;

(7) Alcian blue.

---

* E. Merck, D.61 Darmstadt, Germany.

For metal impregnation techniques:-

(8) Bodian (1937);

(9) Palmgren (1948);

(10) Fitzgerald (1964);

(11) Ranvier-Loewitt (Drury and Wallington, 1967).

The last four methods are covered in greater detail in the relevant section on taste-buds.

2.9. Microphotography and illustrations

Specimens described anatomically, were drawn with the aid of a Wild M5 stereoscopic microscope and its accessory drawing tube.*

Kodacolour X (CX 135-136)** was used in a Zeiss Photomicroscope II*** with a blue daylight conversion filter included to produce photomicrographs of the histological specimens.

Scanning electron photomicrographs were produced with a Cambridge Stereoscan S4 microscope, using Ilford Pan-F extra fine grain film.****

---

* Wild Heerbrugg Ltd., Heerbrugg/Switzerland.

** Eastman Kodak Company, Rochester, N.Y., U.S.A.

*** Carl Zeiss, Oberkochen/Wuertt., West Germany.

**** Ilford Co., Sales region 4, Ilford, Essex.

CHAPTER III

MORPHOLOGY OF THE BUCCAL CAVITY

3.1. General notes on the buccal cavity and variations in the dentition

The Buccal Cavity

The anatomy of the buccal cavity of fishes varies to a remarkable extent.

These variations are related to the fishes' feeding habits. The parrot fish has developed a proper beak for snipping off plants and coral animals. Others have a hard, sharp projection on the lower jaw with which they root around in the sand for crustaceans, fish fry and worms. Surface feeding fish usually have upturned mouths, often with lengthened lower jaws like a half-beak. Similarly, bottom dwellers, like the angler, feed upon prey swimming above them and also have mouths which are turned upwards. On the other hand, bottom feeders, like skate, rays, haddock and suckers, have mouths on the underside of their heads.

Dentition

The dentition is variable but there is a clear correlation with diet (Al-Hussaini, 1949b). Sharks are predators, having sharp teeth variable in form but usually having cusps or serrations, while bottom living rays have blunt or flattened teeth with a large surface area for grinding molluscs and crustacea. The basking shark feeds on plankton which is filtered by taking water into the mouth and straining it through very long gill rakers. During winter, when plankton is insufficient to provide the necessary energy requirements, the rakers are lost and the fish enters a resting stage (Parker and Boesman, 1954). The Holocephali possess three pairs of grinding plates formed by the fusion of separate denticles, and this form is claimed to be associated with

the ability to supplement an animal diet with plant material. A group of stomachless fish, the Dipnoi (lungfish), also possess grinding toothplates and are said to be carnivorous. However, according to Bridge (1922) they crop plants extensively in search of associated animal life.

Teleost dentition is usually comprised of oral teeth, situated at the margins of the mouth and on the palate, and pharyngeal teeth which are especially associated with the branchial arches (Goodrich, 1930). In some predatory fish, the mouth and pharynx have an arrangement of villiform teeth, some of which are enlarged into canine-like tusks. The prey is swallowed whole, without mastication, and the teeth, sometimes aided by tooth-like gill rakers, serve to prevent the escape of the prey. An additional aid in some fishes is a movable hinge arrangement of the teeth which allows them to be folded back during the entry of food, and a primitive tongue which probably contributes to the control of the prey (Al-Hussaini, 1947b; Kapoor, 1953; Suyehiro, 1941).

The other extreme is the total absence of teeth and this edentate condition is usually associated with plankton feeding. In contrast, the sublittoral plankton feeder retains a weak villiform dentition on the jaws, palate and pharynx. This is thought to be related to the winter decline in zooplankton and the necessity to consume small fish (Al-Hussaini, 1946a).

Suyehiro (1941) suggests that there is a tendency for the development of pharyngeal and oral teeth to be inversely proportional to each other. However, Al-Hussaini (1946) describes three herbivorous fish, the first of which comminutes the plant food with oral teeth, the second with pharyngeal teeth and the third with a pyloric gizzard.

The Cyprinidae have no teeth on the edge of the jaw, hence the name 'leather mouths'. There are, however, teeth on the pharyngeal floor, biting against a horny pad on the floor of the skull (Young, 1962).

3.2. The buccal cavity of some cyprinids

The development of pharyngeal teeth in addition to this 'dorsal callous pad' constitutes the specialised buccal organs in the carp and the common goldfish.

In the past, numerous workers have described different parts of the buccal cavity of various cyprinoid fishes, the goldfish included.

According to Cole (1944), 'Aristotle saw the palatal organ of the carp, which he says is so fleshy that it might be mistaken for a tongue'. Cole (1944) also states that, 'It was later re-described by Rondelet (1554) and Swammerdam (1667)'.

The earliest studies on the common carp were of a morphological nature. In addition to other fishes, Valatour (1861) studied the carp, particularly the mucosa and muscularis of the oesophagous and the large arm of the intestine. He described only the macroscopic appearance of the thick, soft palatal organ.

According to Valatour (1861), this organ had previously been described by Cuvier and Duvernoy but they thought the whole organ was a gland and Weber observed taste-buds in this region. Pictet (1909) worked on five cyprinids, among them Cyprinus carpio and gave a general description of the mucosa of the palate, oesophagous and intestine, emphasising the differences which he observed in the five species.

His work did not include the floor of the mouth, buccal cavity, nor the floor or roof of the posterior pharynx. The anatomical description was brief, making it difficult to understand which part he was describing histologically. The work dealt mainly with the mucosa. Curry (1939), in an effort to give more detail, described the entire digestive tract of the common carp, covering the buccal cavity, pharynx, oesophagous and intestine. Girgis (1952) in his description of the herbivorous bottom feeding cyprinoid, Labeo horie (Cuvier) also reported the presence of the pharyngeal pad. He stated that:-

> the diversity of the alimentary systems is such that there would appear to be a correlation between structure of gut and feeding habits in teleost fish.
>
> The anterior part of the roof mucosa of the buccal cavity is thrown into slight transverse foldings.
>
> A 'lamellar organ of the palate' hangs from the median part of the roof. It is composed of a number of lamellae arranged in two rows, which extend backwards almost to the end of the roof.
>
> The floor of the cavity is practically flat, except for some trans-

verse foldings which are deeper and more apparent at the posterior end.

There is no true tongue.

An anterior gustatory and respiratory part of the pharynx is followed by a posterior masticatory one.

The roof of the anterior pharynx is formed entirely of a thick, prominent pharyngeal pad. This is the so-called 'palatal organ' described by Valatour (1861) who considered it to be a tongue, and thereafter it became known as the 'palatal organ of Valatour', or Valatour's tongue.

McKay and Kaan (1940), in their work on the digestive tube of Carassius auratus, included a description of the anatomy and histology of the posterior pharynx, which they described as a more or less rigid structure consisting of bony ventral and lateral walls and a horny dorsal pad. They did not describe the rest of the buccal cavity in detail.

3.3. The buccal cavity of the goldfish

The buccal cavity extends from the lips to the first gill slit. A broadly rounded snout occupies the cranial forward position of the head, leaving the lower jaw in a slightly ventral position. The mouth is extremely protractile and permits the buccal cavity to vary from a conical shape when closed, to a tubular shape when open. It commences as a small, narrow cavity and widens rapidly, reaching its maximum width at the point where the branchial clefts begin. This is considered to be the caudal limit of the buccal cavity. Both lips have a smooth, featureless surface.

For descriptive purposes, the buccal cavity may be divided into a dorsal roof, a ventral floor, and two lateral walls.

3.4. The Floor

The floor (Figure 3) represents the ventral aspect of the cone or tube. Immediately inside the lower lip, a small area occupying a space of approximately one square millimetre is raised into a number of horseshoe-shaped folds. It contains a rudimentary tongue which is completely immobile and is convex cranio-caudally as well as transversely. The floor of the cavity is lined with a white mucosa which is thrown into slight transverse foldings which become deeper and



Figure 3. Floor of mouth showing (a) 'horseshoe configuration' caudal to lip; (b) rudimentary tongue; and (c) gills radiating from (d) ventral pharyngeal floor.

more apparent at the caudal end. At the caudal limit of the rudimentary tongue, a more pronounced transverse ridge of mucosa indicates the boundary of a large, triangular-shaped region, the apex of the triangle situated caudally. This area is raised into very slight transverse foldings and is densely studded with knob-like papillae. These papillae have very little order initially but, posteriorly, they form longitudinal rows that converge at the last gill arch. The sides of the triangle are made up of fine, cartilaginous bars, from which the gill arches, supporting the gill rakers, radiate.

3.5. The roof

The roof (Figures 4 and 5) represents the dorsal aspect of the cone or tube. The upper lip is smooth and featureless and no corresponding area of horseshoe-shaped folds is apparent. However, immediately behind the lip and attached to its base, is a flap of tissue that is free at the caudal border. This crescent-shaped flap, following the contour of the lip, moves forward with it telescopically on hinged membrane bones, the premaxillae. A slightly bi-lobed and thickened area is present dorsal to, and hidden by, the flap.

Like the floor, the roof is lined with a white mucosa, raised into folds or ridges. The rows follow the contour of the roof cranially, extending diagonally down the sides and longitudinally down the arched roof, which is concave cranio-caudally as well as transversely.

The greater part of the caudal pharyngeal roof is taken up by a prominent, thick, pharyngeal pad. This is the 'palatine organ of Valatour', which projects markedly ventrally, and therefore occupies a lower level than the roof of the buccal cavity. The convexity of the cranial part corresponds very closely with the concavity of the floor in the same region. The pharyngeal cavity therefore becomes very narrow and food particles have to touch the mucosa of the roof when being ingested.

The pad consists of two reniform lobes, divided symmetrically by a shallow median groove. It is a fairly rigid muscular organ, covered with mucosa, and is attached caudally to the basi-occipital bone, and cranially to the head musculature. Triangular in shape, it is wider at the cranial end and narrows gradually towards the oesophagous. Laterally, a series of shallow depressions accommodate the gills.



Figure 4. The roof, showing (a) tissue flap caudal to (b) lip, (c) direction of mucosal folds and partial extent of (d) palatal organ with its attachment to the (e) basi-occipital bone.



Figure 5. Oblique view of the roof with the gills removed to show the great bulk of (a) the palatal organ in relation to the size of (b) the buccal cavity. Note (c) the median groove dividing the palatal organ into reniform lobes.

A small, cornified area, again triangular in shape with the base directed cranially, appears at the front of the pad, with a wedge-shaped strip of mucosa thrown into pronounced folds on each side.

The whole of this palatine organ is studded with knob-like papillae also without any particular order, except for the last one to two millimetres, where they seem to be arranged in parallel rows similar to the floor of the mouth.

3.6. The lateral walls

As an aid to description, the buccal cavity has been likened to a tube or cone. In view of this, it is difficult to determine definite boundaries for the lateral walls (Figure 6). The most positive feature is a very thin, transparent mucosal lining, which is raised into fairly pronounced folds.

Cranially, for a distance of about two to three millimetres, the folds are continuous with those of the roof, running down the side of the tube and doubling back upon themselves in the direction of the lips. From this point they run parallel in a cranio-caudal direction, curving down slightly towards the floor and terminating at the first gill arch.

The curve of the lower lip forms an S-shaped fold and this, in turn, creates a small, raised elevation of mucosal foldings laterally, immediately inside the mouth. When the highly protrusible upper lip is thrust forward, carrying the lower jaw with it and straightening out the S, the buccal region becomes a very spacious cavity. This action has the effect of pulling the lateral folds into almost straight, longitudinal rows and making the lateral elevation disappear (Figure 7).

3.7. Nerve supply

According to Young (1962),

> the trigeminal nerve in fishes, like that of man, has ophthalmic, maxillary and mandibular branches.
>
> The ophthalmic branch is a sensory nerve carrying fibres for skin sensation from the snout. The maxillary branch supplies sensory fibres to the upper jaw, whereas the mandibular is a mixed nerve to the skin and muscles of the lower jaw.



Figure 6. The lateral wall illustrating the distribution of (a) the mucosal folds when (b) the mouth is in a retracted position. (c) Brain, (d) Palatine organ, (e) Rudimentary tongue.



Figure 7. Lateral views of (a) protruding lips. Note (b) mucosal folds of buccal cavity straightened into longitudinal rows. (c) Palatine organ, (d) Gills.

The facial is a large, mixed nerve, with the ophthalmic branch running to the snout carrying mainly fibres for the organs of the lateral line system that lie there. A large, buccal branch supplies sensory fibres to the mouth, and a palatine branch joins the trigeminal.

The series of dorsal roots in the more posterior region of the head is uninterrupted. The ninth (glossopharyngeal) nerve is the dorsal root of the fourth segment of the series and runs out through the auditory capsule. The dorsal roots of the succeeding segments are then fused to form the vagus nerve and the branches it sends to the gills are typical branchial nerves. The vagus is compounded of the dorsal roots of several segments and is a mixed nerve containing both receptor and motor fibres.

The ventral roots of this post-otic region have become much reduced. Several myotomes are always missing completely, so there are no ventral roots corresponding to the glossopharyngeal and first three or four vagal segments. The ninth cranial nerve supplies the first bronchial arch and the taste-buds in the oral cavity.

Attempts to confirm the above observations were unsuccessful but it is probable that there is a similar nerve supply in the goldfish.

3.8. The protrusible mechanism of the mouth

Supporting structures:

The maxillae support the cranial and lateral parts of the snout.

The premaxillae support the dorsal lip.

The palatines, together with the vomer, support the cranial roof of the buccal cavity. The cranio-dorsal ends of the palatines support the snout, and short protruding cranial processes prevent lateral dislocation of the maxillae.

The pterygoids support the anterior lateral walls of the buccal cavity.

A description of the protractile apparatus of the mouth of catastomids was published by Edwards (1926). Gregory (1933) gave a generalised account of the mechanism based on papers available to that date, but gave particular emphasis to specimens of cyprinids and catastomids.

Girgis (1952) in his work on the bottom-feeding cyprinoid, Labeo horie, found that he agreed, in principle, with Gregory's (1933) study of natural mech-

anisms, which placed special emphasis on fish skulls.

In the goldfish, protrusion of the upper lip is brought about by depression of the mandible or by pulling on the geniohyoid muscle, during which the ventral border of the snout is raised slightly and the dorsal lip slides out of it and extends cranio-ventrally (Figure 8). In this movement the premaxillae, supporting the dorsal lip, are thrust cranio-ventrally, since their ends are attached by ligaments to the caudal ends of the maxillae which are attached by ligaments to the ascending processes of the dentaries.

3.9. The branchial apparatus (Smith, 1961).

The operculum or gill cover is made up of four main bones, more or less embedded in a single membrane.

These are the opercle, preopercle, subopercle and interopercle. In most fishes the operculum is free from the body but, in some, the ventral portion of the gill-membrane is joined to the isthmus which is the tapering front of the thorax. The gill-membrane is then said to be adnate and the gill opening restricted. In a few fishes the gill-membrane may be almost entirely adnate, leaving only a very small opening on each side. This description has been confirmed by personal observations.

3.10. Gills and gill rakers (Smith, 1961).

The gill arches are five in number, though only four support gills. The first is the hyoid arch, consisting of large, flat bones forming a strong frame for the gill-cavities. The gill arches also bear a series of sabre-shaped bones, known as branchiostegal rays, which open like a fan below the gill-covers to protect the gills even when expanded.

Each gill arch consists of several slender bones, suspended in a chain ventral to the cranium, all linked together ventrally. In the last arch the lower pharyngeals are greatly enlarged, almost sickle-shaped, and bear rows of four strong, flattened, tooth-like processes, which can be brought together for the purpose of mastication.



Figure 8. Dorsal aspect of the goldfish head showing (a) retraction and (b) protrusion of the mouth.

Hervey and Hems (1948) in their description of the goldfish say that food is taken into the mouth and passed immediately backwards. The mouth is toothless, and there are no salivary glands present. At the entrance to the oesophagus, food is masticated by eight pharyngeal teeth (four on each side in a single row) which bite against a horny pad on the base of the skull. The food then passes into the oesophagus where the first processes of digestion begin. To lessen the danger of food particles or abrasives passing through the pharyngeal slits and injuring the gills, double rows of stiff fibres are affixed to the inner margins of the gill arches (Figure 9). These are known as gill-rakers and although they do not actually rake the gills, they serve as a sieve, before water reaches the delicate gill structure. The gill-rakers function only as long as the fish keeps its gill arches close together.

The number of gill-rakers does not vary widely in any one species of fish and is considered to be helpful in identification.

Study of the gills and gill-rakers in the goldfish confirmed this description.



Figure 9. A modified diagram from a standard illustration of a typical gill arch. This arrangement is identical in the goldfish.

CHAPTER IV

THE BUCCAL CAVITY AS REVEALED BY THICK TRANSVERSE SECTIONS

4.1. General

Cranial sections revealed a triple layered arrangement comprising the ventral lip, the protrusible mechanism and the snout.

All these layers contained a large amount of loose connective tissue with a preponderance of collagen fibres. The core of bone (premaxillae) in the protrusible mechanism had a distinct symphysis. Sparsely scattered in the dorsal surface of the dorsal lip and the ventral surface of the ventral lip were some fairly large, clear cells which resembled taste-buds. However, the thickness of the sections made it impossible to resolve any detail.

One of the most striking features demonstrated by these sections was the variation in shape of the buccal cavity as one moved in a cranio-caudal direction.

Transverse sections were studied cranio-caudally at intervals of 400 microns (Figures 10a - 10k). Each figure consists of a diagram of the buccal cavity and a photo-micrograph of a transverse section of the head.

4.2. Shape and contents of the buccal cavity

Cranially, the cavity is narrow and wide, with a convex floor and an almost flat roof (Figure 10a).

The buccal epithelium descends from the roof to form two lateral knobs with cores of connective tissue. These are the folds that result from the inferior position of the lower jaw. The epithelium of the rudimentary tongue is thick and has three or four raised papillae on each side of the central elevation. Cores of collagenic connective tissue invade these papillae.

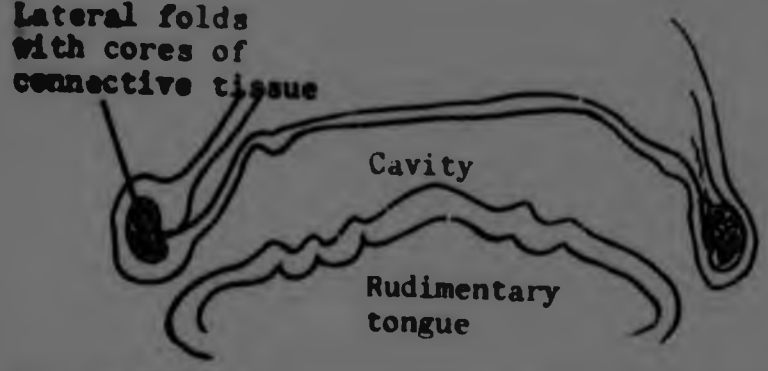



Figure 10a. Masson's Trichrome x 10

The height of the cavity increases caudally because the roof and the floor both become concave. The width remains the same (Figure 10b).

The epithelium is thinner and of an even thickness in the roof and the floor. At the extreme limits of the concavity of the roof, two lateral strips of epithelium project into the cavity. These are the wedges of mucosa that precede the palatine organ. The roof epithelium has a serrated appearance. Immediately below each epithelial layer in the roof and floor, is a clearly demarcated fibrous layer of collagen. The deepest part of the lower concavity has a small area of desquamating cells.

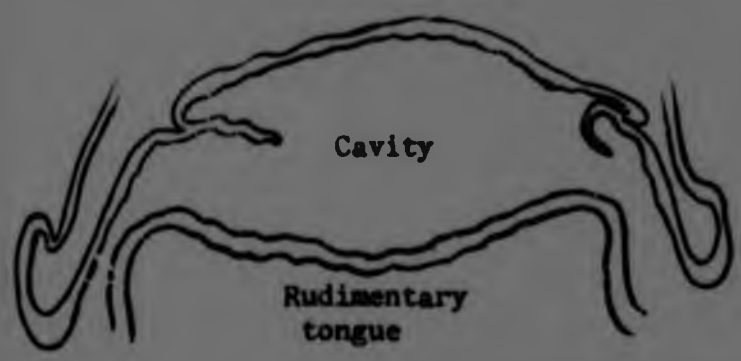



Figure 10b. Masson's Trichrome x 10

The rudimentary tongue raises the floor into a convexity and the roof becomes more concave, making the cavity very high and narrow (Figure 10c).

The epithelium around the whole cavity is uniformly thin and fairly regular. The collagenic layer in the floor and roof is very pronounced.

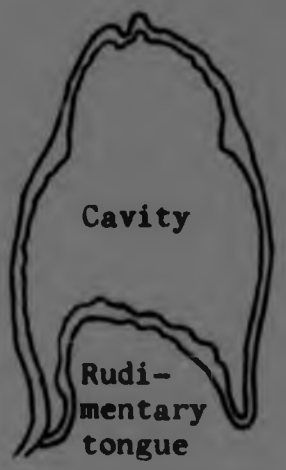



Figure 10c. Masson's Trichrome x 10

The shape remains similar, but becomes wider with the roof still relatively high (Figure 10d).

The epithelium is still uniformly thin but becomes more irregular on the rudimentary tongue. Post-orbitally, and situated at the point where the gills converge on the sides of the palatine organ in the roof, is a very small, bean-shaped structure (a) that appears to be a gland of the endocrine type. It is surrounded by a very thin connective tissue capsule, has a hilus and is extremely convoluted in appearance. Cells within the gland are large, very acidophilic with light staining nuclei, and are arranged in cords. Between the cords are fine strands of collagenic fibres and scattered lymphocytes. The whole structure is highly vascular.

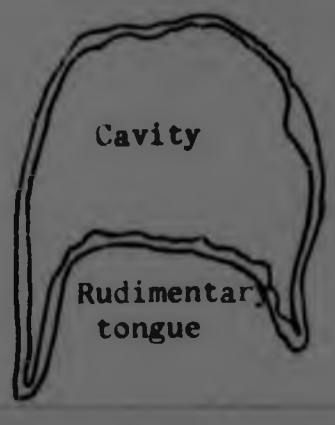



Figure 10d. Masson's Trichrome x 10

The cavity now assumes a semicircular shape, wider than it is high. The convexity of the floor corresponds with the concavity of the roof and the whole is of a uniform height. At this stage the gills radiating from the floor are apparent (Figure 10e).

The epithelium is slightly thicker on the rudimentary tongue and a few raised papillae are visible. The epithelium of the roof has a slightly undulating appearance. The collagenic layer is not as thick but is still clearly demarcated. Above the buccal roof mucosa is a triangular-shaped region of fatty connective tissue (a) which precedes the commencement of the palatine organ.





Figure 10e. Masson's Trichrome x 10

As the gills begin to occupy more space in the floor, the rudimentary tongue becomes narrower and takes on a triangular shape with the apex situated ventrally. The roof is broadly concave and the whole cavity is wide and narrow (Figure 10f).

The gills now occupy much of the floor space and follow the contours of the cavity laterally, radiating from the base of the tongue. The palatine organ, containing much adipose connective tissue and scattered muscle fibres, can be seen dorsally (a). Above the organ and situated on each side of the midline, the convoluted post-orbital glands are prominent (b). The epithelium of the organ is thin and fairly flat except for a small central area where there are several indentations. That of the tongue is thick with three to four broad, raised papillae. The fibrous layer below the epithelium is thinner but is still clearly visible.



Figure 10f. Masson's Trichrome x 10

At the point where the palatine organ becomes prominent and occupies most of the roof, the cavity remains wide and narrow (Figure 10g).

The rudimentary tongue is very small and most of the floor and lateral walls are occupied by the gills, which radiate from the base of the tongue, follow the contours of the cavity and join with the sides of the palatine organ in the roof. The organ at this stage is divided into lobes by a wide, shallow depression. The tongue is covered with a very thick epithelium, with two to three flat-topped papillae on each side of the midline (a). The fibrous area is thick and cores of connective tissues invade those elevations. A layer of desquamating cells is visible.

The palatine organ is covered with a thinner epithelium, which is fairly regular. Shallow crypts extend for a short distance on each side of the median groove. A desquamating layer is apparent in this region. The fibrous layer is visible but not pronounced and recedes laterally. The organ is predominantly muscular, with many scattered fat cells and has a vascular appearance.

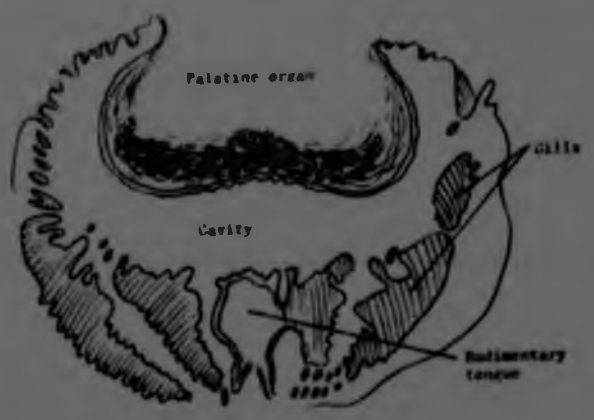



Figure 10g. Masson's Trichrome x 10

The palatine organ is more pronounced and the median groove deeper and narrower. The floor is taken up almost entirely by the gills, and the surface area of the tongue is very small (Figure 10h).

At this stage, the convoluted gland which is closely associated with the gills and their point of attachment with the palatine organ, is no longer visible. The epithelium of the palatine organ is thin, the fibrous layer barely discernible. The cleft (a) and a much larger area on each side of it show a layer of desquamating cells and, in addition, crypts increasing in depth are lined with goblet cells. The centre of the organ contains most of the adipose tissue (b), while the muscle fibres are concentrated laterally (c). The tongue, although smaller, has a very thick epithelium, a raised central elevation with a layer of desquamating cells and a faintly visible collagenic layer.

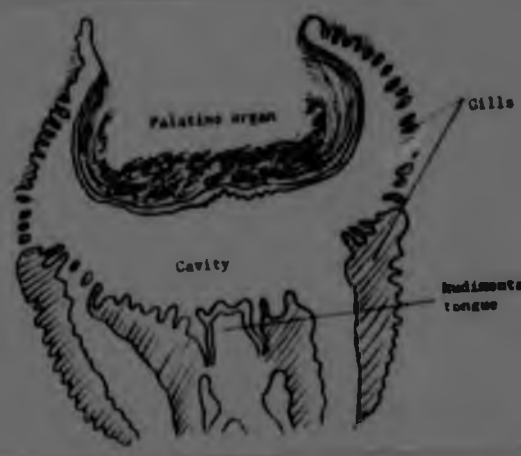

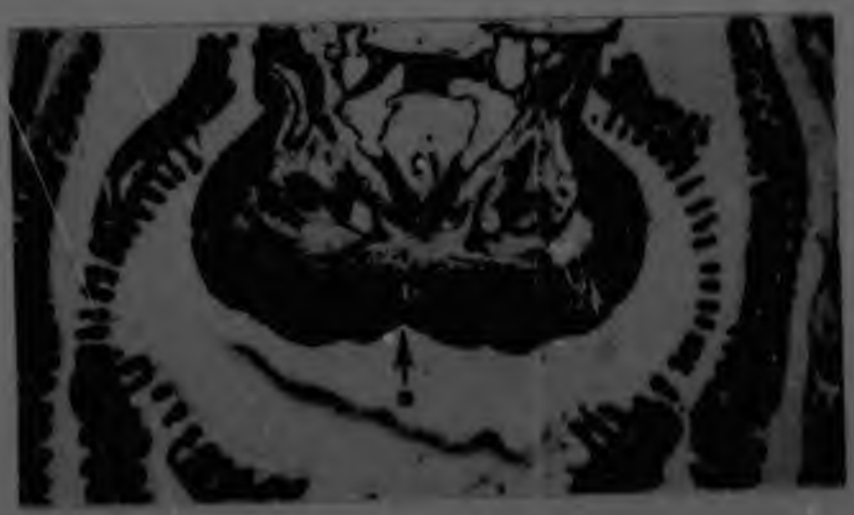

Figure 10h. Masson's Trichrome x 10

Towards the caudal extremity, the palatine organ changes shape and the cleft becomes a wide, shallow depression and the organ less bi-lobed in appearance. The tongue widens slightly and the gill surfaces lie on a level with the tongue surface (Figure 10i).

The epithelium of the organ is uniformly thin and the depression is covered with a desquamating layer that does not extend to the sides. The striated muscle (a) remains concentrated laterally, but some fibres extend towards the central region. The tongue has a very thick epithelium and the central elevation is also covered with a thick desquamating layer. Both show a visible fibrous layer.

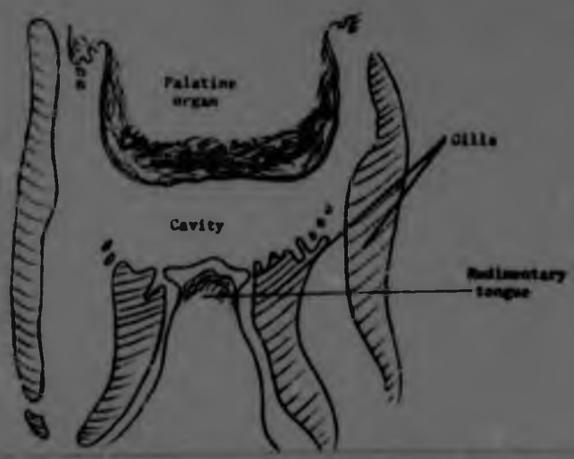



Figure 10i. Masson's Trichrome x 10

Close to its point of attachment with the basi-occipital bone, the shape of the palatine organ undergoes a complete change. There is no evidence of a groove and it projects low into the cavity. The floor is flat and wide and there is little space between the two (Figure 10j).

The organ is predominantly muscular and its epithelium contains a large number of low crypts, all of which are lined with goblet cells (a). The floor is raised into low, flat-topped papillae, also lined throughout with goblet cells (b). Beneath the epithelium is a thick, muscular layer (c). No collagenic layer is visible at this stage.





Figure 10j. Masson's Trichrome x 10

Immediately before the oesophagous, the cavity is very small and narrow. The palatine organ becomes nothing more than a hard, fibrous pad, triangular in shape (a). The apex of the triangle is directed into the cavity and the sides provide a grinding surface for the teeth which take up most of the floor (Figure 10k). At this level the ventral pharyngeal teeth are conspicuous.

Laterally, and between the teeth, are tall, foliaceous papillae lined with mucous cells (b).

The teeth are narrow and conical, similar in appearance to mammalian teeth. They are located laterally, slant in a slightly caudal direction, and their angle of insertion permits them to bite against the sides of the fibrous pad. At the base of each tooth is an unerupted tooth (c).





Figure 10k. Masson's Trichrome x 10

CHAPTER V

HISTOLOGY AND HISTOCHEMISTRY OF THE BUCCAL CAVITY OF THE GOLDFISH

5.1. General

The mucosa of the buccal cavity is made up of stratified squamous epithelium which is not completely keratinised and in some regions has a layer of desquamating cells.

Absence of a muscularis mucosae in the digestive tract of fishes has led to certain departures from the commonly accepted terminology. McVay and Kaan (1940) quote Bridge (1910) in the Cambridge Natural History, as designating the sub-epithelial tissue as submucosa, the mucosa accordingly comprised only the epithelium and basement membrane. Rogick (1931) followed this method in her description of the minnow. Blake (1930, 1936) and Scott and Kendall (1935) distinguished a tunica propria immediately below the epithelium which continued without interruption into the submucosa. Since this followed more closely the interpretation of similar tissues in higher vertebrates (Maximow and Bloom, 1938), the term 'tunica propria' was used throughout by McVay and Kaan (1940) to indicate the connective tissue lying directly beneath the epithelium and forming the core of the mucosal folds. To aid description of the histology of the buccal cavity, the division of the regions into ventral floor, dorsal roof and lateral walls will again be used.

5.2. Ventral floor

Cranially, the surface of the floor is raised into a series of low, round-topped papillae, covered with stratified squamous epithelium which is fairly thick and non-keratinised. It differs from the ordinary stratified epithelium in that vertical to the stratum compactum, and resting on the basement membrane, is a row of columnar

cells These cells, somewhat pointed at the top, follow the irregularities produced by the invaginations of the stratum com[illegible]n. They have large, oval nuclei containing distinct nucleoli and a chro[illegible] network which is very apparent. Above this layer, also vertical to the stratum c[illegible]actum, are three to four rows of fusiform cells that possess a similar type of oval nucleus. Lying on these are several layers of polygonal shaped cells and, more superficially, the cells become flattened with elongated nuclei and lie horizontal to the stratum compactum. This pattern of arrangement is repeated throughout most regi[illegible] of the cavity and changes only where a proliferation of goblet cells or taste-buds takes place.

The mucosa covering the floor and the tongue forms wide papillae with broad tops and shallow crypts, and occasionally secondary papillae are present. Taste-buds are rare but sometimes a single, small bud is present on top of an elevation of connective tissue (Figure 11).



Figure 11. The mucosa of the cranial floor. Connective tissue invaginations are high only where they support taste-buds (a). Masson"s Trichrome x 40

The surface contains small, scattered mucous cells on top of and sometimes between papillae. However, the majority of papillae, especially those in the cranial part of the tongue, are devoid of mucous cells. Instead, surface cells are arranged horizontally and desquamation is seen. Connective tissue elevations are

broad and do not invaginate extensively into the epithelium except where a taste-bud is present.

A basement membrane is present but barely discernible due to the dense layer of stratum compactum immediately below it. The basement membrane was, in fact, only clearly distinguishable in imperfect sections where the layers had become separated.

The thick collagen fibres of the stratum compactum stains an intense blue with Masson's Trichrome stain.

On the lateral surfaces of the tongue, the papillae have a similar appearance but the crypts are somewhat deeper and the elevations of connective tissue considerably higher. Small mucous cells increase in number but taste-buds are rare. Patches of desquamating cells are seen.

A fairly thin muscular layer is present consisting of longitudinally arranged, widely spaced strands of striated muscle (a). Interspersed between the fibres is much loose connective tissue. Below the muscular coat is a broad region of adipose tissue (b). Both are richly vascular and nerve bundles are scattered throughout (Figure 12).



Figure 12. Lateral surface of rudimentary tongue. Taste-buds (c) are rare, but when present as many as four may appear on one papilla. Masson's Trichrome x 40

Curry (1939) drew a definite line of distinction between the buccal cavity and the pharynx and further sub-divided the pharynx into anterior and posterior parts. However, this sub-division into anterior and posterior parts is relevant only to the pharyngeal roof. As a result, it made her description very difficult to understand and orientation to the exact region to which she was referring became somewhat of a problem.

It is simplified by considering the floor of the pharynx as being a continuation of the floor of the mouth.

There appears to be no distinct dividing line between the mucosa of the mouth and that of the pharynx, similar histological elements being apparent in both.

The cranial part of the pharyngeal floor is taken up by gill slits, and caudally, where the mucosa covers the lower pharyngeal bone, is a region described by Curry (1939) as, '...a triangular plateau of tissue whose mucosa forms knob-like papillae in longitudinal rows...'. The last one to two millimetres of this region is occupied by foliaceous papillae extending down between the pharyngeal teeth which are of an equal height to the papillae surrounding them (Figure 13).



Figure 13. Thick section showing foliaceous papillae (a) occupying sides of cavity and extending down between pharyngeal teeth (b). Masson's Trichrome x 25

The dentine of the teeth is widest at the top and tapers down their length to a narrow line. The dentine consists of a collagenous mesh with a calcified ground substance and definite radial striations are visible.

As with mammalian teeth, there are no nerves, vessels or complete cells in the dentine. On the outside of the dentine there appears to be only a single layer of enamel cells. The pulp cavity is large and filled with a soft gelatinous core. The cells of the pulp are fusiform and stellate, much like mesenchyme in appearance. A few macrophages and lymphocytes are present, with reticular fibres interspersed in the ground substance. At the periphery, a layer of columnar cells, the odontoblasts, send processes into the adjacent dentinal tubules. Blood vessels and nerves are apparent. At the base of each mature tooth is an unerupted tooth (Figure 14). A wedge of foliaceous mucosa (a) extends from between the teeth to the sides of the cavity and terminates at the opening of the oesophagous.



Figure 14. Pharyngeal teeth (b) with an unerupted tooth (c) present at the base of each mature tooth.
Masson's Trichrome x 25

The papillae covering this triangular plateau are flat-topped and similar in appearance to those of the buccal cavity. They increase in number as the plateau increases in width, and caudally, crypts become deeper, goblet cells in the crypts proliferate and the papillae become narrower until the foliaceous papillae begin to

become apparent. Taste-buds are rare in this region. Where goblet cells are numerous at the base of the crypts, the stratified epithelium is reduced to two to three layers of cuboidal cells. However, on the sides of the crypts, columnar and fusiform cells gradually reappear. The lateral areas of the plateau are devoid of taste-buds and goblet cells but desquamating cells are plentiful. The foliaceous papillae are tall and slender with many secondary foldings. Epithelial cells in the dorsal part of the deep crypts are reduced to one to two rows of cuboidal cells with very distinct nuclei. Very large, sac-shaped goblet cells are extremely numerous in the crypts. Frequently, goblet cells continue over the tops of the papillae. Occasionally, some folds have a few layers of stratified, fusiform cells which spread out fan-wise on top of a fold with some goblet cells squeezed between them (Figure 15).



Figure 15. Fan-shaped papilla with some goblet cells (a) interspersed between fusiform cells. Alcian blue x 40

A basement membrane is present throughout and the stratum compactum, which is apparent in the region of the plateau, disappears before the formation of the foliaceous papillae.

The muscular layer of the plateau is very dense, consisting of longitudinally arranged striated muscle fibres, with much loose connective tissue interspersed between them. Fat cells and blood vessels are present. Staining for elastic fibres

produced a negative result.

5.3. Lateral walls

At the point where the mucosa of the lateral parts of the tongue meets and joins with the sides of the cavity, the crypts become much deeper, goblet cells more prolific and the heavy collagenic fibres disappear, leaving only a thin stratum compactum. Taste-buds are absent. The sides of the cavity have a very thin mucosa which permits a great deal of stretching. A few flat, broad papillae are present, with cores of equally thin stratum compactum invading them. Desquamating areas are apparent, taste-buds and small mucous cells are rare.

A fine, indefinite sub-mucosa attaches the mucosa to the underlying bone, enabling the folds to be extended to some considerable degree. It was expected that the amount of movement in the lateral walls would indicate the presence of some elastic tissue. However, selective stains for elastic fibres gave a negative result. No muscle layer is present (Figure 16).



Figure 16. Side of cavity. The mucosa is uniformly thin with a fine stratum compactum. Taste-buds are rare but one is visible (a) in the illustration. Masson's Trichrome x 40

At the most caudal limit of the floor, immediately before the oesophagus, the mucosa changes to contain extremely foliaceous papillae with many secondary foldings and extends down between the pharyngeal teeth to the opening of the oesophagus. The epithelium is of a specialised columnar type containing unbroken rows of large mucous cells, in which the large-meshed reticulum is clearly visible (Figure 17).

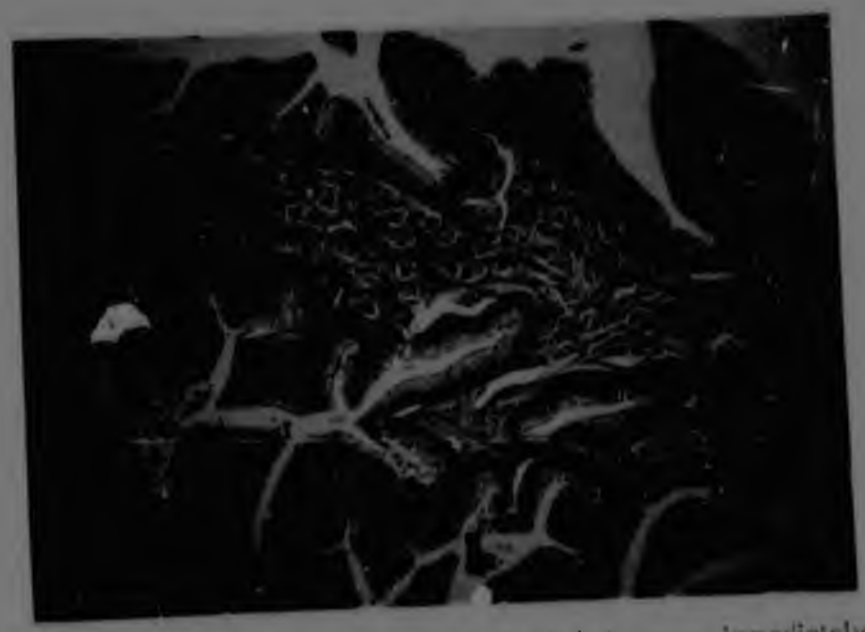

Figure 17. Foliaceous papillae of the type that appears immediately before the oesophagus. The unbroken rows of large mucous cells are clearly visible.
Masson's Trichrome x 40

5.4. Dorsal roof

The cranial roof mucosa is similar to that in the floor. Immediately inside the cavity, dorsal to the flap, papillae are less broad but have deeper crypts and the goblet cells are more numerous in the crypts. There appear to be far more goblet cells in the roof than there are in the floor. Taste-buds are present on the flap but rare elsewhere in the roof. Desquamating cells do not appear in this region. The stratum compactum is present, but decreases towards the sides and the caudal part of the cavity.

A muscular layer does not appear in all the sections of the roof but it is present in the cranial portion where transverse strands are abundant, interspersed with loose connective tissue. The muscle fibres are absent from the middle portion of the roof but reappear longitudinally at the beginning of the palatine organ. Below the muscle is a network of loose connective tissue containing capillaries and larger vessels, although they are not numerous (Figure 18).



Figure 18. Cranial portion of buccal roof, where the muscular layer is present. Scattered taste-buds (a) are visible.
Masson's Trichrome x 40

At the caudal limit of the buccal roof, the dorsal pharynx begins. At this point the thick, soft white palatal organ of Valatour occupies the bulk of the roof and fills most of the cavity. The mucosa of the cavity with its knob-like papillae continues uninterrupted over the surface of the organ and, as Curry (1939) observed, '...the microscopic structure of the anterior pharynx differs so much from the posterior that it is necessary to consider the two separately ...'.

Cranially, the mucosa of the palatine organ is similar to that of the buccal roof, the same histological components being present in both. The roof epithelium tends to lose its differentiation as it passes over the organ and the basal layer of columnar cells give way to crowded cells with boundaries that are difficult to dis-

tinguish. The to, ho ever, have prominent, dark-staining nuclei. Where epithelial cells are apparent on the surface, they are large and flattened. A basement membrane is present but very difficult to distinguish and is backed by a thin stratum compactum.

It is necessary to differentiate the palatine organ into central and lateral regions on the basis of histological differences. The mucosa of the median cleft that divides the organ into lobes has a distinctly different structure to that of the peaks of the lobes. The papillae in the cleft differ in their shape, a stratum compactum is present, taste-buds are rare and the crypts are lined with a great number of goblet cells. Cranially, the papillae are low, flat-topped and the goblet cells line only the sides of the crypts, seldom appearing on tops of the papillae. Cranio-caudally, the crypts in the cleft gradually become narrower and deeper and the layers of epithelial cells in the crypts lessen. At the most caudal limit, the papillae form short, longitudinal rows, having narrow, flat tops and dee pts with parallel sides (Figure 19).



Figure 19 Caudal region of median cleft of palatine organ, where crypts form short, longitudinal rows with parallel sides. Goblet cells line crypts and cover the tops of many papillae Masson's Trichrome x 40

This description corresponds closely to that of Curry's (1939) work on the common carp. However, she said, '...goblet cells are found in the crypts; occasionally a few are found on top of a papilla...'. The crypts in this region of the goldfish are lined entirely with large goblet cells and these invariably cover the tops of the papillae. In fact, to find a papilla without them is the exception rather than the rule and they are so numerous that they have crowded the epithelial cells to such an extent that only one or two rows are left in the bottom of the crypts. Taste-buds are seldom seen but in areas where no taste-buds or goblet cells are found, flattened epithelial cells are present, sloughing off from the surface.

The stratum compactum is present in the cranial portion of the cleft but recedes caudally and finally disappears.

The mucosa of the lateral areas in the goldfish undergoes a dramatic change. Curry (1939) describing the carp stated,

> ...the papillae of the lateral areas are low, wide and flat-topped, with shallow crypts. A gradual increase in the depth of the crypts is noticed in the posterior part but this is not nearly so pronounced as in the middle region. The taste-buds are numerous here, so much so that they are found opening on the sides of the crypts. Goblet cells are found in the crypts and sometimes on top of papillae...

No region in this area of the goldfish palatine organ can be described as possessing crypts. The mucosa is certainly irregular in appearance but its thickness is little more than that required to accommodate the row upon row of taste-buds that occupy it (Figure 20).

These appear, following the contours of the organ for at least two-thirds of its length. More often than not, they project beyond the surface and where they stop just below it, small goblet cells are occasionally seen.

No stratum compactum is present in the lateral area.

A submucosa that is very indistinct forms slight undulations on which the taste-buds are supported. It contains a considerable amount of connective tissue carrying capillaries. There is not a distinct demarcation between the mucosa and the muscle layer. Strands of muscle frequently invade the areas of connective tissue.

The muscle layer makes up the greatest part of the organ providing its soft, cushiony texture. It is thickest in the centre and recedes laterally. It consists

mainly of longitudinal striated muscle of a type that demonstrates its striations particularly well even when stained with haematoxylin and eosin, and exceptionally well with special stains (Figure 21).



Figure 20. Median sagittal section of lateral regions of palatine organ, lined with taste-buds. Masson's Trichrome x 40



Figure 21. Striated muscle typical of the type that makes up the bulk of the palatine organ. Gold Chloride x 240

Definite tunics do not exist but scattered transverse bundles are also present. The fibres are well spaced apart and are interspersed with connective tissue. Many fat cells, capillaries and larger blood vessels are scattered throughout the muscular layer. The muscle fibres are particularly concentrated close to the mucosa, become more scattered further away and are finally replaced by an extensive mesh-work of fat cells. The great extent of fat cells is limited to a very thin layer in immature fishes.

The region that Curry (1939) called the posterior pharynx, and is in fact the most caudal region of the dorsal pharyngeal roof, is histologically quite different from the rest of the palatine organ. The mucosa covering the inferior pharyngeal bone again forms knob-like, flat-topped papillae similar to those of the buccal cavity. They increase in number with the increase in width of the mucosa. Caudally, crypts become deeper, goblet cells proliferate and the papillae become narrower until, just before the oesophagous, foliaceous papillae are formed. These are long and slender with secondary foldings. Taste-buds are not present but goblet cells that are numerous in the bottom of the crypts reduce the stratified epithelium to one or two layers of cuboidal cells. Deep crypts appear and large sac-shaped goblet cells are plentiful. The tops of the folds are covered with squamous epithelium and frequently the goblet cells continue over the tops of the papillae (Figure 22).



Figure 22. Transitional region (a) where the mucosa covering the caudal extreme of the dorsal pharyngeal roof, changes to the foliaceous type preceding the oesophagus.
Masson's Trichrome x 40

A basement membrane is present throughout but the stratum compactum disappears just before the formation of the foliaceous papillae.

The muscular layer in this region remains thick and is composed of numerous longitudinal striated muscle fibres. They are loosely arranged in connective tissue containing fat cells and many blood vessels.

The final region that appears in the dorsal roof, immediately before the oesophagus, consists of a small, cornified, triangular structure which is extremely hard and is situated dorsal to the pharyngeal teeth. This is what Curry (1939) called the 'dorsal cornified pad' and is, in fact, the area that provides a grinding surface for the pharyngeal teeth. Again, it is histologically different from the other regions of the roof. It rests on a layer of very dense connective tissue, extensions of which invade the pad. Between the extensions are large, polygonal cells with distinct, dark-staining nuclei. They stain less intensely as they reach the surface level of the connective tissue invaginations. Above this level the cells become thinner and the polygonal cells are replaced by an eosinophilic stratum, five or six layers deep, of flattened, horizontal cells with disintegrating nuclei. Beyond this are several layers of dead cells and desquamation takes place over the whole surface.

Below the connective tissue layer are spicules of bone and scattered longitudinal striated muscle fibres.

The mucosa around the sides of the pad is of a similar foliaceous type to that in the region of the pharyngeal teeth, and occasional taste-buds are seen (Figure 23).

5.5. Taste-buds in the goldfish

Curry (1939) described the digestive tube of the common carp and divided the layers of the mouth into mucous, muscular and fibrous coats. She said that,

> The mucosa of the buccal cavity is made up of stratified epithelium showing some desquamating cells and contains goblet cells and some taste-buds. The taste-buds are flask-shaped structures usually resting on an evagination of stratum compactum and connective tissue, in which capillaries are sometimes present. Spindle-shaped central taste cells are enlarged near their middle to contain the oval nuclei. They end in a refractive process which can be seen pro-

jecting beyond the surface.



Figure 23. 'Dorsal cornified pad' (a). Although the section is thick, invaginations from the dense connective tissue layer (b) can be seen. Angulation of teeth in relation to the pad is clearly demonstrated. Masson's Trichrome x 25

McVay and Kaan (1940) investigated the digestive trace of Carassius auratus and had even less to say, '...taste-buds were present in the epithelium of the posterior pharynx. They were elongated and rather narrow. The cells extended from the basement membrane to a point just below the surface of the epithelium...'. Neither of these workers gave a detailed account of the distribution of taste-buds in the carp or the common goldfish, even though they are widely scattered throughout the roof, walls and floor of the mouth. It is sufficient to say that they are present in the epithelium of the buccal cavity of Carassius auratus (Figure 24) since the arrangement in this region is not particularly startling. They are widely scattered, more spherical in appearance and rest on an elevation of the stratum compactum and connective tissue, which raises the mucosa into low, broad-topped papillae.



Figure 24. Mucosa of cranial roof, showing four small, round taste-buds (a) situated on top of a papilla.
Haematoxylin and Eosin x 40

The greatest profusion of taste-buds occur on the palatal organ of Valatour. The taste-bud distribution in this region undergoes a dramatic change and the epithelium covering the cranial two-thirds of the organ is so crowded with densely packed taste-buds that one can almost describe it as a 'taste-bud epithelium' Figures 25 and 26).

These taste organs bear a marked similarity to those found in higher mammals, the main difference being one of shape. The mammalian taste-bud extends vertically from the basement membrane almost to the surface of the stratified squamous epithelium and its shape is somewhat like a barrel, often narrower at the top. In the goldfish taste-buds do extend to the free surface (Figure 27) but this difference in appearance may be related to the 'in vivo' method of fixation. They usually end in a refractive process that projects beyond the surface. They are elongated and distinctly flask-shaped with very dark staining nuclei.



Figure 25. Densely packed taste-buds in the epithelium covering the palatine organ. Haematoxylin and Eosin x 40



Figure 26. Detail of epithelium showing the close proximity of taste-buds to each other. Verhoeff's method x 250



Figure 27. Taste-bud projecting beyond surface of epithelium (a). The refractive process is not present. Nucleated oval red blood cells can be seen above the mucosa (b).
Verhoeff's method x 250

Since taste-buds are only stable when their innervation is intact (Arey, 1968), it was assumed that this particular region must have a very rich nerve supply. In an attempt to demonstrate this, Palmgren's (1948) silver impregnation technique was applied, this being one of the most reliable methods for paraffin sections. The results demonstrated that the palatine organ is well supplied with nerves as shown by the large distribution of nerve bundles (Figures 28 and 29).

The gold chloride toning bath provided a beautiful specimen of striated muscle in the underlying tissue of the organ (see Figure 21) but, although the taste-buds could be seen with great clarity, no nervous elements were visible in them.

The technique of Bodian (1937) gave similar results.

The double impregnation technique of Fitzgerald (1964) is recommended for nervous elements in mammalian tissue. The method requires fixation in a saturated solution of picric acid in alcohol, formalin and glacial acetic acid. Tissue is then impregnated with silver nitrate followed by protargol. Once again the nerve bundles were well demonstrated but no taste-bud nerve elements were visible.



Figure 28. Silver impregnation showing presence of nerve fibres (a) and bundles (b) in the palatine organ.
Palmgren's silver impregnation x 40



Figure 29. Typical nerve bundles found scattered throughout the underlying tissues of the palatine organ.
Palmgren's silver impregnation x 250

Finally, the Ranvier-Loewitt method cited by Drury and Wallington (1967) was applied. This technique requires fixation in fresh lemon juice, immersion in one per cent gold chloride, development in formic acid and the use of small pieces of tissue in preference to sections. When the processing is complete, the tissue is teased or crushed under a cover slip.

The presence of the nerve fibres was demonstrated very clearly, but the acid maceration of the tissue caused the epithelium to disintegrate completely.

It is apparent that further investigation of the nerve supply to the palatine organ of Valatour is indicated since it obviously functions as a highly specialised chemo-receptor and very probably acts as an efficient taste mechanism.

5.6. Histochemistry

Many workers who investigated the pharyngeal epithelium of fish reported the presence of closely packed, elongated mucous cells, a feature which was emphasised by McVay and Kaan (1940) in their study of Carassius auratus. These goblet-shaped cells are scattered throughout the buccal cavity but proliferate on the caudal extreme of the palatine organ, the caudal extreme of the ventral floor and the lateral regions of the cavity that precede the oesophagus. Those located in the buccal cavity are noticeably smaller, more rounded in shape and react less positively with histochemical stains. McVay and Kaan (1940) applied only routine histological dyes before classifying the structures which they observed as mucous cells. Copeland (1948) presented evidence for a cell type responsible for the active excretion of salt from the gills of marine fish, and which he called a 'chloride cell'. A subsequent report by Pettengill and Copeland (1948) suggested that on the basis of phosphatase activity the cell might also fulfil the role of actively absorbing salt in freshwater situations. In their summary they stated that, '...the chloride cell adapts more rapidly to freshwater than it does to sea water and the various lines of evidence indicate that the cell is very labile and sensitive to blood salt levels...'.

A further report by Burns and Copeland (1950) confirmed that, ...chloride excreting cells are not limited to gill epithelium, being found in other regions of the head, especially the inner surface of the operculum. In the operculum the population density of these cells is in positive ratio to the vascularity of the tissue. Such a topographical positioning of cells is significant to its function of removing

chlorides from the circulatory system...'.

It is probable that these goblet-shaped cells which are present in such large numbers in the buccal cavity, compensate to some extent for the absence of salivary glands. It is also conceivable that those of a different size and shape, located at the caudal extreme of the pharynx in close proximity to the gills, might serve a different function. Many of them do, in fact, bear a marked resemblance to the 'chloride cell' described by Copeland (1948) and, in view of this, it is probably insufficient to describe them as 'mucous cells'.

Mucins form a very large group of varying compounds, usually found as mixtures. In the past, 'mucin' has been used as a term of convenience and not one of specificity. According to Drury and Wallington (1967) it was formerly used to describe substances in tissues, or secretions from glands which were slimy, were precipitated with alcohol and acetic acid and stained with mucicarmine. It is now customary to include mucins within the mucoid carbohydrates, which can be divided into three main groups:-

(1) mucopolysaccharides: polysaccharide-protein complexes which are predominantly carbohydrate;

(2) mucoproteins: polysaccharide-protein complexes which are predominantly protein;

(3) mucolipids: polysaccharide-fat compounds.

It must be pointed out that these three groups contain a large number of substances, widely distributed throughout the tissues. They are invariably mixed and have staining reactions which are given by substances previously classified generally as 'mucins'. With the increased amount of histochemical work and improvements in histochemical techniques in recent years, a better understanding of the composition of 'mucin' has arisen. As a result, it is becoming common practice to identify the type of mucoid carbohydrate which is present and the indefinite term 'mucin' is falling into disuse.

Mucopolysaccharides can be neutral or acid. A neutral mucopolysaccharide contains carbohydrate made up of hexose units, usually acetylated, such as glucosamine.

Acid mucopolysaccharides contain carboxylated glucose units (glucuronic acid) and hyaluronic acid which is a simple acid mucopolysaccharide made up of chains of glucosamine and glucuronic acid. Complex acid mucopolysaccharides contain, in addition to glucuronic acid, sulphated glucosamine units.

Mucoproteins, predominantly protein, are usually considered to contain more than 4 per cent of a hexosamine-containing polysaccharide. When the polysaccharide content is higher, that is, over 20 per cent, sialic acid is usually present and the sialic acid-containing mucins are then known as sialo-mucins.

The third group, mucolipids, are made up of fatty acids combined with carbohydrates, usually galactose.

Spicer et al. (1965) have proposed the word 'muco-substance' as a general term for tissue entities rich in carbohydrate. Shackleford and Wilborn (1968) devised a histochemical classification for their work on mammalian salivary glands based on carbohydrate content and use only four terms to describe the different secretory cells. These are:-

(1) mucous cells possessing abundant mucosubstance;

(2) serous cells which are poor in mucosubstance;

(3) seromucous cells which are neither rich nor poor in mucosubstance but exhibit characteristics which are intermediate between those of mucous and serous cells,

(4) special serous cells which have little or no detectable mucosubstance, yet differ structurally from other serous cells.

All normally occurring carbohydrates except acid mucopolysaccharides will give a positive P.A.S. reaction. This reaction is based upon the fact that periodic acid will oxidise 1,2-glycol groups in the carbohydrate to produce aldehydes which are then coloured red by Schiff's reagent.

The P.A.S. reaction is histochemically specific but as many different tissue components will give a positive reaction it is not valid in diagnosing any one tissue entity or single group of substances. To improve the specificity it is necessary to use enzymic or chemical controls or to apply a blocking technique.

Acid mucopolysaccharides may be demonstrated by the use of alcian blue, which has a strong affinity for mucin at a pH of 1,0 to 3,0. This method depends on the presence of acidic groups and strongly sulphated compounds give the most intense colour reactions. As with the P.A.S. reaction, this technique is not specific but stains a wide group of substances, among them the acidic mucins. Specificity may also be improved by the use of blocking techniques.

However, in terms of Shackleford and Wilborn's (1965) classification, the P.A.S. and alcian blue reactions can be applied to determine whether the cells are muco-substance rich or poor.

Many past investigators have reported the presence of glandular epithelium in fish gills but, again, there is a diversity of opinion in regard to their occurrence, structure and function. Leydig (1850) described glandular tissue in fish and credited it with the function of a sixth sense. Dahlgren and Kepner (1908) postulated a possible respiratory function to some gland-like cells related to the gill lamellae. Others, such as Riess (1881), Dröscher (1882) and Faussek (1902), described cells and their locations but simply called them mucous cells and attributed no specific function to them.

Bevelander (1936), in a comparative study of the branchial epithelium of fish, classified three distinct types and seven sub-types of intraepithelial glands. These glands were classified according to their morphological patterns, cytoplasmic content and other features dealing with structural complexity. The conclusion reached from the characteristic arrangement, relationships and specific staining reactions was that these structures were intraepithelial mucous glands.

Single, specific secretory cells may be scattered throughout an epithelial sheet, the commonest type being the goblet mucous cell of the respiratory and intestinal tracts which, in its resting condition, is an ordinary-looking columnar cell. Sometimes gradual discharge from, and replacement in, the cell goes on simultaneously and, under these circumstances, the goblet shape is retained. Arey (1968) stated that,

> ...the goblet cell shape occurs only when mucous cells are interspersed in an epithelium and is gained by crowding and distorting neighbouring, ordinary cells. The goblet cell occurs in either a simple columnar or pseudostratified epithelium. Intermediate between unicellular and multicellular glands are the pit-like, intraepithelial glands that lie wholly within a generalised epithelial layer...

These cells in the goldfish appear to contain much mucigen since only a little basal cytoplasm remains and the nucleus is more or less flattened against the cell base. Using the P.A.S. technique, dense localisation of red, P.A.S.-positive substances is found uniformly distributed within the cell. The alcian blue reaction was equally strongly positive.

The classification of intraepithelial glands by Bevelander (1936) appears to be correct and it is apparent that, since the glands contain such large quantities of P.A.S. and alcian blue positive material, they must be described as being muco-substance rich.

Further selective histochemistry seems to be indicated as an aid to determining their function since it appears probable that the function differs in varying localities of the buccal cavity.

According to Drury and Wallington (1967), routine histological tissue processing is not an ideal method for demonstrating substances histochemically. This is because the reagents involved remove many of the constituents and the hot wax impregnation destroys even more. In view of this, tissues processed in this way are not considered to be accurate for diagnostic purposes and results obtained must be presumed to be less positive than those obtained from tissues processed in the prescribed manner.

The following twelve illustrations have been produced from tissues subjected to the routine method of processing.

Although it is probable that much of the P.A.S. and alcian blue positive material has been destroyed, it is possible to gain an indication of the richness of the muco-substances present in the various regions of the buccal cavity (Figures 30 - 41).

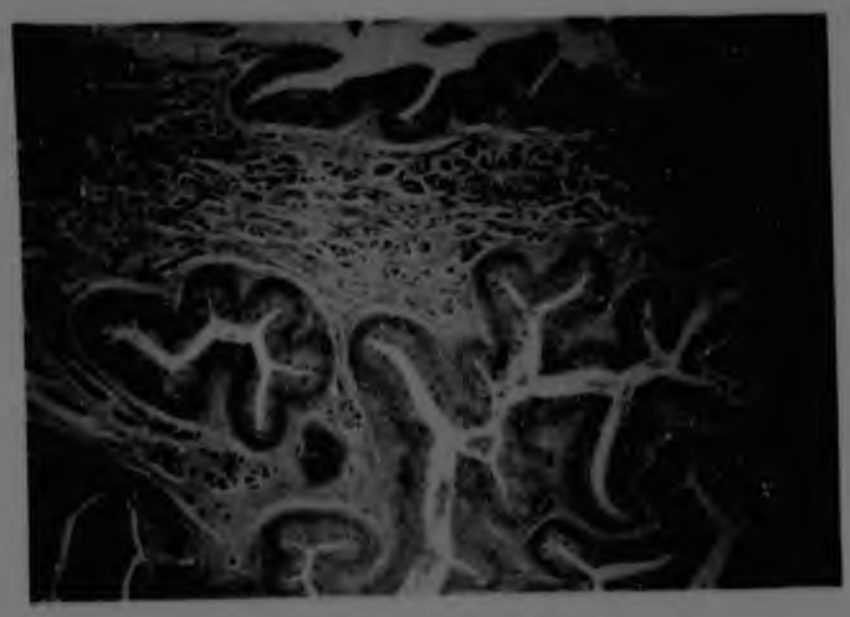

Figure 30. Dense localisation of P.A.S. positive substances in the pharyngeal foliaceous papillae. P.A.S. x 40



Figure 31. Dense localisation of alcian blue positive substances in the pharyngeal foliaceous papillae. Alcian blue x 40



Figure 32. Goblet cells in the cranial region of the buccal floor. P.A.S. positive substances present in cells that do not form unbroken rows over the tops of the papilla. P.A.S. x 40



Figure 33. Cranial region of the buccal floor. P.A.S. positive substances in cells concentrated in the base and on the sides of the crypts. The goblet cells in the floor are smaller than those in the palatine organ. P.A.S. x 250



Figure 34. Localisation of P.A.S. positive substances in the cells of the caudal pharyngeal floor. P.A.S. x 40



Figure 35. Localisation of alcian blue positive substances in the cells of the caudal pharyngeal floor. A few scattered taste-buds are present. Alcian blue x 40



Figure 36. P.A.S. positive substances in the cells of the lateral walls. Where a taste-bud (a) is present, mucous cells are absent. P.A.S. x 40



Figure 37. P.A.S. positive substances in cells of the lateral walls. They are slightly larger and more numerous than those of the floor. P.A.S. x 250



Figure 38. P.A.S. positive goblet cells in cranial buccal roof mucosa. P.A.S. x 40



Figure 39. Cleft of palatine organ. Alcian blue positive goblet cells lining crypts. Alcian blue x 40



Figure 40. Localisation of P.A.S. positive substances in goblet cells of caudal extremity of the palatine organ.
P.A.S. × 250



Figure 41. Localisation of alcian blue positive substances in goblet cells of caudal extremity of the palatine organ.
Alcian blue × 250

CHAPTER VI

THE BUCCAL MUCOSA AS REVEALED BY THE SCANNING ELECTRON MICROSCOPE

6.1. General

Diagrams of the ventral floor and dorsal roof have been numbered to indicate the exact regions which have been illustrated in greater detail with the aid of the scanning electron microscope (Figures 42 and 43). Figures 44, 48 and 48a are areas that do not appear on the diagrams, these being the ventral lip and the lateral walls. This method of labelling has been used to enable the division of the buccal cavity into ventral floor, dorsal roof and lateral walls to be continued.

A study of this nature ideally requires a comparison of preparation techniques and examination of a fairly large number of specimens. However, the details revealed by these superficial observations seem to be in accord with the histological appearances.

The tip of the ventral lip has been included because of the 'horseshoe-shaped' arrangement of raised epithelial ridges revealed by the anatomical study. These appear in the photomicrograph as small, irregularly shaped craters with sides that are raised above the general surface of the epithelium (Figures 44 and 44a). It is possible that this is a calloused area which provides a better gripping surface in the absence of buccal teeth.

The lateral walls reveal very little and it is probable that specimen damage occurred during removal, since the mucosa adheres very closely to the walls. A photomicrograph of the striated muscle in this region shows that the striations are not merely a question of periodic spacing, but the fibre does, in fact, possess very definite corrugations (Figures 48 and 48a).



Figure 42. Diagram of rudimentary tongue, ventral pharyngeal floor and radiating gills, produced from a scanning electron photomicrograph.



Figure 43. Diagram of the buccal roof mucosa and the surface of the palatine organ, produced from a scanning electron photomicrograph.



Figure 44. Horseshoe-shaped arrangement of 'pits' caudal to the ventral lip.
S.E.M. x 500



Figure 44a. Sides of 'pits' raised above general level of the epithelial surface. This arrangement probably provides a strong gripping surface for the ventral lip.
S.E.M. x 2 000

6.2. Ventral Floor

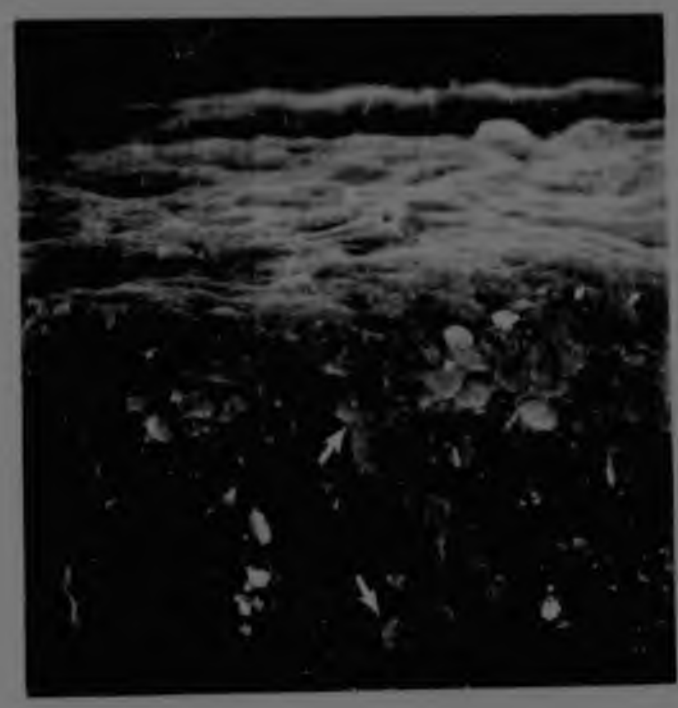

Figure 45. Surface and lateral view of rudimentary tongue; cranial portion. Raised spherical structures are probably taste-buds.
S.E.M. x 1 000



Figure 45a. Lateral surface of tongue. Mucosa is raised into low, flat-topped elevations.
S.E.M. x 1 000



Figure 46. Foliaceous papillae with secondary foldings raised into 'knob' like elevations, in the region of the pharyngeal teeth.
S.E.M. x 200

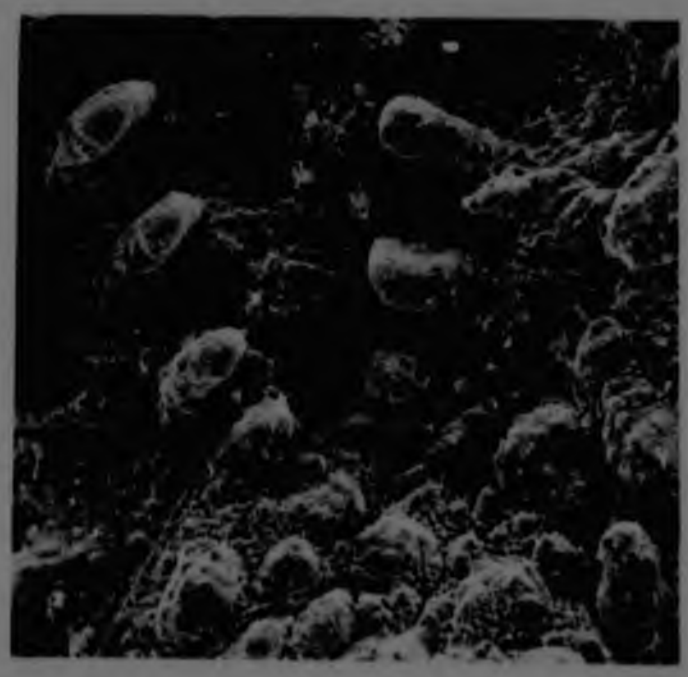

Figure 47. Bases of two gills radiating from ventral pharyngeal floor. Papillae (a) are high and rough surfaced, probably indicating that this region is subjected to considerable wear. S.E.M. x 100

6.3. Lateral walls



Figure 48. Papillae are very low, debris is present. Striated muscle fibres can be seen.
S.E.M. x 1 000



Figure 49a. Papillae of lateral walls. (a) Striated muscle in foreground shows definite corrugations (b). S.E.M. x 5 000

6.4. Dorsal roof



Figure 49. Cranial region of dorsal roof. Papillae (a) are seen to have shallow depressions, and those raised above general surface level, are thought to be taste-buds (b). S.E.M. x 1 000



Figure 49a. Detail of Figure 49. Taste-bud (a), in close proximity to a deep depression with a clearly demarcated boundary which is probably an empty goblet cell (b). S.E.M. x 5 000



Figure 50. Cranial part of palatine organ, where papillae are fairly high and taste-buds numerous. Each elevation is thought to support a taste-bud.
S.E.M. x 500



Figure 50a. Detail of Figure 50. Taste bud (a) and apical aperture (b). S.E.M. x 5 500

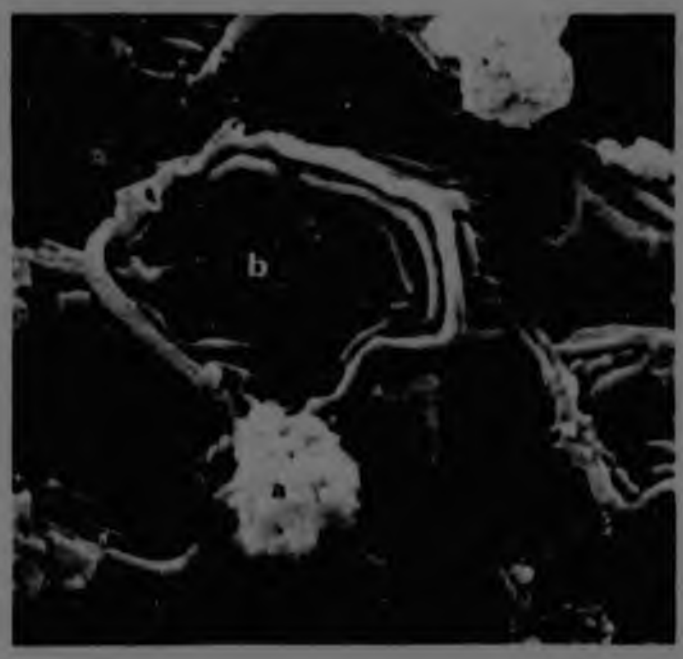

Figure 51. Caudal region of palatine organ where goblet cells are numerous and taste-buds scattered (a). Deep 'pits' with clearly demarcated boundaries are thought to be goblet cells (b).
S.E.M. x 4 500



Figure 52. Centre of median cleft where papillae are low and broad. Very little detail is resolvable.
S.E.M. x 5 500



Figure 52a. Higher magnification of the cleft reveals little except that the mucosa seems to be made up of finger-like projections.
S.E.M. x 10 000

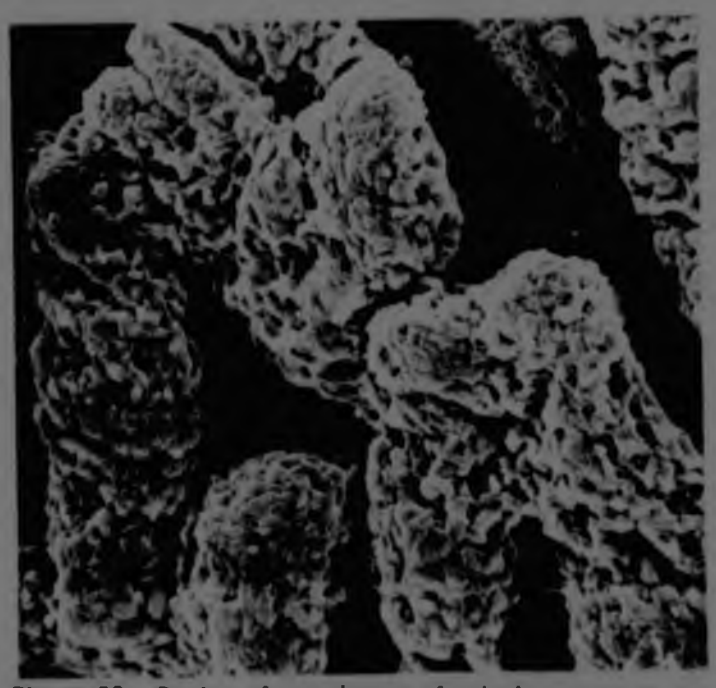

Figure 53. Region of attachment of palatine organ to the basi-occipital bone. The mucosa has many secondary foldings in this area.
S.E.M. x 500



Figure 53a. Higher magnification of Figure 53 illustrates the secondary foldings more clearly. However, the depth of the crypts with their lining of mucous cells cannot be seen.

S.E.M. x 2 000

CHAPTER VII

OBSERVATIONS ON FEEDING BEHAVIOUR

This mosaic of anatomy and histology suggests that the goldfish has a sophisticated and highly specialised buccal cavity. The postulation that various regions of the buccal cavity have specific functions is partially supported when the feeding habits are considered.

It clearly emerges from personal observations, that within certain ranges of acceptability, fish maintained in an aquarium can be conditioned to consuming certain foods, even after becoming accustomed to food of a different type. There is, however, no strictly regular feeding pattern.

Two simple observation experiments were conducted to substantiate these statements.

(1) Six goldfish, two comets and four fantails, were maintained in a communal tank for more than three months, and fed daily on a commercial processed flake food.

A live tadpole was introduced into the tank and was swallowed by one fish who ejected the tadpole almost immediately, unharmed.

This action led to the question of whether it was the taste or the texture that the fish disliked. It was assumed that if smell was an influencing factor, the fish would not have ingested the tadpole in the first instance.

It was decided, therefore, that in addition to the processed food, three other substances, dehydrated and reduced to the same texture, would be fed to the fish over a period of sixteen days.

The following were used as food:-

A - Commercial flaked food.
B - Tadpoles.
C - Minced L
D - Mosquito larvae.

The processed flakes were used exactly as they were purchased. The remaining three foodstuffs were cut into very small pieces and placed into petri-dishes in an oven at 60°C. until partially dry. They were then ground with a pestle and mortar and returned to the oven. This process was repeated until all the water content had been removed and the texture was similar to that of the commercial flaked food.

The four foods were labelled A, B, C and D, and the feeding pattern was arranged according to a form of the Latin square. The first day commenced with food A, the fifth day with food B, the ninth day with food C and the thirteenth day with food D. In this manner the various foods were utilised four times each over a period of sixteen days at irregular intervals. The feeding reactions were then recorded (Figure 54).

A++	B+	C+	D-
B-	C+	D++	A++
C+	D++	A+	B++
D+	A++	B++	C+

Figure 54. Table indicating degree of acceptance of four different types of food.

The varying daily reactions were as follows:-

A - Processed commercial food:

1. Immediate consumption with no apparent 'tasting'.
2. Immediate surface feeding and complete consumption.
3. Ignored for some time, small quantity eaten with reluctance.
4. Immediate surface feeding with no preliminary investigation.

B - Tadpoles:

1. Taken reluctantly, lengthy preliminary 'sucking'.
2. Voracious 'attack' on food, lengthy preliminary 'sucking', no rejection.
3. Voracious feeding with lengthy 'sucking' after investigation.
4. Immediate feeding accompanied by lengthy 'sucking' motions.

C - Minced beef:

1. Complete disinterest for some time. No surface feeding at all. When particles sank, small quantities were taken up at mid-level. Lengthy 'sucking', majority of food ignored and left on surface.
2. Sporadic surface feeding, most of the food ignored.
3. The mince had a pungent smell and when sprinkled on the surface of the water it created a lot of excited activity from the fish on the bottom. After rising to the surface, a small quantity was consumed but after 'tasting', most was ignored.
4. Bottom activity, reluctant feeding. Mainly ignored.

D - Mosquito larvae:

1. Total disinterest, no feeding at all.
2. When sprinkled on the surface, much bottom activity ensued, but a long time lapse occurred before surface feeding. Preliminary 'sucking', then rapid consumption.
3. Immediate surface feeding and rapid consumption.
4. When sprinkled on the surface, much bottom activity ensued and after a time lapse, reluctant surface feeding took place.

Although no regular pattern emerged, it can be seen from these observations that unfamiliar foods may be accepted after preliminary investigation in the mouth.

The minced beef was the least acceptable of the four foods and had a very pungent smell. Even so, the fish, to a certain extent, were prepared to eat it. However, ingestion was accompanied by lengthy 'mouthing' movements which can only be described as mastication. This appeared to be a reasonable assumption since the fatty content of the meat was not removed during dehydration and, consequently, it was not as dry and crisp as the others. The particles were considerably larger and probably required some chewing to render them down to a size that could be swallowed. The commercial flake food which was normally accepted without any preliminaries, now became viewed with some hesitation and, on one occasion, was eaten with some reluctance. It was also noted that after being conditioned to a variety of foods, anything thereafter was carefully masticated.

(2) A proprietary brand of fish food, "Tetra Menu 4 in 1"* is available. It can be obtained in four different colours; brown, green, red and yellow. The manufacturers recommend one for an all-purpose diet, one to promote spawning conditions, one for growing and conditioning small fry, and one to provide a green vegetable diet.

For this observation, the value of these foods was due only to the fact that four distinct colours were obtainable. A community tank with a population of thirteen fishes was established. The fish were accustomed over a period of several months to being fed on the green, all-purpose food. A mixture was then made containing all four colours, and this was fed to the fish in the usual quantity. The fish ingested the flakes indiscriminately, but expelled all those except the green ones. Yet again, everything was taken into the mouth, 'tasted', and then rejected if found unacceptable. The various colours made it possible to observe this behaviour with great accuracy. If the flakes were large, lengthy 'chewing' motions would ensue before further feeding.

---

* Tetra Dr. Ger. nat. Baensch, Melle, Western Germany.

CHAPTER VIII

DISCUSSION

8.1. General

'Like any vertebrate, the fish is a bilaterally symmetrical animal, the right and left sides being mirror images. It has a simple basic anatomical plan, that of a hollow cylinder, open at both ends, with a food canal running inside from front to back. The front end represents the mouth and the back end the vent'. (Life Nature volume, 'The Fishes').

The simplicity of this arrangement, however, is in no way indicative of a similar simplicity in the way in which the animal functions. The fish has adapted [illegible] multiplicity of ways to suit his aqueous environment, and conditioning to a [illegible] water has, in itself, required an adaptation to that of fresh or salt water.

A life of submersion immediately introduces the problem of breathing. The fish [illegible]ercame this by the development of a specialised mechanism that enables it to ex[illegible]t oxygen from the water. The water is taken into the mouth, passed through the gill chambers and expelled through the gill openings on the sides of the head. The gills are lined by blood vessels close to the surface and are covered by a thin skin. This skin forms folds and plates in order to increase the surface area, the so-called gill filaments. The whole gill mechanism is contained in a chamber and is protected by a bony shield, the operculum. The gill mechanism is highly adaptable, so much so, that some fish are able to make use of atmospheric air, as well as oxygen obtained from the water.

This mechanism, combined with the question of how a fish breathes, has provided physiologists with much stimulating experimental work. However, there are other aspects in the head region of the fish that are equally worthy of interest.

For example, Life Nature volume, 'The Fishes', has this to say:-

> ...a special problem that fishes have, is combating the chemical barriers. A fish requires to maintain a balance between the salts in its body fluids and those that are present or absent in the water environment. The freshwater fish has a higher salt content in its body fluids than the surrounding water, and as the water is constantly diluting these salts by entering the body through the skin, gill membranes, mouth and other exposed body surfaces, it is in constant danger of water invasion. To maintain the correct balance, it constantly excretes water. The marine fish has the opposite problem and is constantly gulping water to maintain the balance. To enable it to cope with the high salinity of the engulfed water, marine fish possess cells in the gill filaments whose special function is to excrete certain of these salts...

8.2. Mucous glands

Once again, evidence supporting the above statements is provided mainly by physiologists, aided by their carefully controlled experiments. Comparatively few supporting facts have been contributed by histological observations. Histological examination of structures is an important confirmatory link in any study of this nature. The kidney is considered to be an inadequate excretory unit for the problems that exist in a fish's normal functions. Copeland (1948), therefore made an important contribution when his histochemical studies revealed the presence of what he called 'chloride cells' and a further report confirmed that these chloride-excreting cells were not limited to the gill epithelium but were also found in other regions of the head. The precise distribution, however, is still to be ascertained and the importance of their function still to be determined. The classification of three distinct types and seven sub-types of intra-epithelial mucous glands by Bevelander (1936) is of equal value, but detailed evaluation of the glandular distribution and its function in individual species of fish is still required. A variation exists in shape, size and staining reaction among these epithelial mucous glands, depending upon their location in the cavity. It is possible that some of the largest, situated in the most caudal regions, are additional chloride-excreting units because many of them are situated in close proximity to the gills, in areas which are highly vascular. It is also probable that some situated in the buccal cavity and in the cleft of the palatine organ compensate to some degree for the absence of salivary glands. Personal observations indicate that, in spite of many views to the contrary, regarding fishes in general, the goldfish is one species that does, in fact, masticate

food. If this is the case, it is to be expected that a secretion of some sort is required as an aid to mastication in the fish, as much as it is in higher animals.

8.3. The alimentary tract

Many descriptions are available, both anatomical and histological, on the digestive tract of various species of fish. Most of these attempt to relate the anatomy or histology to the feeding habits and much of the work has been stimulated by the fact that certain fish have no true stomach.

Barrington (1936, 1942, 1945) stated that the simplest form of vertebrate alimentary tract is seen in the Cyclostomata (lampreys and hagfish). The larval and adult lamprey have clearly differentiated buccal cavities, pharynges, oesophagi and mid-guts. They also have livers, but there is a complete absence of a stomach. The pancreas is present in an early stage of its evolution, a caecum containing zymogen-secreting cells, and closely associated follicles which develop from the intestinal epithelium and from a bile duct, which are postulated to represent the islets of Langerhans.

The absence of a stomach in these jawless vertebrates is regarded as a primitive feature and it is suggested that its appearance in fish may be correlated with the development of macrophagous feeding, which was made possible by the evolution of jaws.

However, Barrington (1942) referring to certain species in another report said:-

> ...as far as histological structure is concerned a stomach is absent from the Dipnoi, the Holocephali and certain Teleostei. Cyprinus carpio, which typifies this condition, has a short muscular oesophagus with ten to twelve longitudinal folds continuous with those of the intestine and lined by stratified epithelium with goblet cells passing into the columnar intestinal epithelium.
>
> The anterior end of the intestine widens from three millimetres to ten millimetres and this forms a food receptacle, often mistaken for a stomach. There are no gastric glands present and bile pancreatic ducts enter approximately six millimetres from the oesophagus. No valve exists between oesophagus and intestine. There is a complete absence of peptic digestion. The absence of a stomach is a secondary feature and not a primitive one...

It is not clear whether the absence of a stomach is regarded as a primitive feature only in the jawless vertebrates, or whether, in fact, the latter observation regarding Cyprinus carpio is a contradictory statement.

Banki (1936) regarded the alimentary tract of the fish as being divided into two main regions, the 'kopfdarm', comprising the buccal cavity and pharynx and the 'rumpfdarm', comprising the fore-gut (oesophagus and stomach), mid-gut (intestine) and hind-gut (rectum). However, more recent descriptions which have emerged as a result of the interest in the presence or absence of a stomach, seem to have persuaded investigators to lose sight of the fact that the digestive tract begins at the buccal cavity and not at the pharynx or oesophagus. The result has been that either the buccal cavity is not mentioned at all, or else it has been considered worthy of only a brief reference.

It appears that the buccal cavity has simply been considered as nothing more than the 'mouth', possessing similar appearances in all fishes and, as such, has not warranted close examination. Detailed work has then been carried out on the alimentary tract, from and including the oesophagus to the vent. Descriptions are often misleading, and as many authors frequently use the terms 'anterior and ventral', 'caudal and dorsal' with equal abandon, orientation is something of a problem. However, the common aim of most investigators appears to be their determined attempts to relate appearances to specific feeding habits.

8.4. Feeding habits

The question arises then of how specific are these feeding habits? Fish are categorised by some authors as being 'omnivorous', 'carnivorous' or 'herbivorous' but others say that they will eat what is available. There appears to be no doubt that a plant-eater will unhesitatingly consume small crustaceans associated with plants. Does this mean that this particular fish is not a discriminating feeder, or does it perhaps lend weight to the belief that a fish is not sensible to taste? The leerfish (Hypacanthus amia (Linn.)), a fighting game-fish, prefers live or moving bait, always seizing the fish across the middle and working it about in the jaws until head-on for ease of swallowing. This is described by anglers as 'scaling the bait'. An immature leerfish will frequently try to consume a prey that is too large, and choke to death in the process. This fish is obviously carnivorous, but

is not necessarily discriminating enough to select prey that it can handle with ease.

Fish are generally described as being 'voracious' feeders. A personal communication from a skindiver indicated that this is also an inaccurate observation. He described certain fish as selecting their prey, and 'mouthing' it before swallowing. Once again, some sort of investigation is applied to the potential food source before the decision to reject or accept is made.

Personal observations made on fish in general maintained in aquaria indicate that they can be attributed with omnivorous, carnivorous, or herbivorous habits as a convenient means of categorisation. However, by inclination they are clearly seen to be selective feeders. For instance, goldfish will readily accept the proprietary brands of dry, flaked fish food. If this food source is terminated, they will happily crop the plants in the tank, and if the plants are removed they will be content with turning over the gravel at the bottom and eating the smaller snails. Once the whole environment is re-established, they will unhesitatingly select the processed flakes as the food of choice.

A mixed community of tropical fish provides a source of varied observations because they will also readily consume the processed flaked food. It is of interest, however, to note that, in between feeding, some will prey on smaller fish, some will crop plants and others will browse around the bottom picking up small snails.

There seems to be some substance in the statement that fish will eat anything that is obtainable but, at the same time, it is apparent that the fish is a discriminating feeder if a choice is available. This is borne out by the fact that, when presented with a mixture of foods, all of the same texture but differing in colour, the fish will investigate them all but consume only one. The various colours made it possible to observe this selection with a great deal of accuracy and was further confirmed by the fishes' habit of always taking the food into the mouth before accepting or rejecting it.

8.5. Mastication

The question of mastication has given rise to definite contradictory statements. Some authors flatly state that the fish swallows its food without any preliminaries, whereas others claim that all the Cyprinidae carefully masticate their food. If this question was simply related to the presence or absence of teeth, the answer might be more obvious. However, as with most aspects of the

fish, the dentition is variable. Some species have teeth situated on the jaws and it is postulated by the workers concerned that the main function of these is to aid in the control of the prey (Al-Hussaini, 1947b; Kapoor, 1953; Suyehiro, 1941).

The Cyprinidae have no teeth on the jaws, but do possess two rows of pharyngeal teeth situated at the caudal extreme of the ventral pharynx. Although these teeth in the goldfish are small and embedded in the mucosa, it is apparent that they are fully functional. The teeth are similar in histological appearance to mammalian teeth and situated at the base of each is an unerupted replacement tooth. There is no corresponding pharyngeal-roof dentition but, instead, a very hard, cornified pad provides a biting surface for the lower teeth. The histological appearance of this pad indicates that it is subject to a considerable amount of wear and the teeth are angled in such a way that they are permitted to make maximum contact with the sides of this triangular-shaped pad.

Observations show that the goldfish will devote a considerable amount of time over food of an unaccustomed type and give every indication that it is 'chewing' before swallowing. The combination of structural appearance and behaviour lead one to conclude that the goldfish is one species that masticates its food thoroughly before taking it into the stomach.

8.6. The taste-bud system, chemoreceptors and smell

It is apparent that, in the past, no special emphasis was placed upon the buccal cavity as a whole or the palatine organ in particular. Although brief mentions are made in a number of publications of the existence of the organ and the presence of taste-buds in certain locations, the detailed histology and distribution of taste-buds is ignored and heavy emphasis is placed on the anatomical and histological appearances of the alimentary tract. The common aim of most investigators seems to have been their determined attempts to relate the anatomy and histology of the alimentary tract to specific feeding habits.

Although it is recognised that some species of fish are associated predominantly with particular categories of food, it is clear that many species will make use of a wide variety of foods and, under aquarium conditions, will eat what is available. In spite of this, reference is often made to 'herbivorous', 'carnivorous' and 'omnivorous' habits. Of course, diet is partly determined by

the foraging methods of the fish concerned. For instance, a fish that never leaves the bottom will not consume larval forms swarming on the surface, whereas others have highly developed tactile senses or acute vision and will seek their food accordingly.

The fact that a fish bolts its food, has no salivary glands and has either no tongue or, if present, is not protrusible, leads ichthyologists to believe that a sense of taste is unknown in the fish. There is, however, some evidence to show that goldfish may be sensible of taste for, like all Cyprinidae, they masticate their food with considerable care and it is suggested that the peculiar organ, richly supplied with nerves found on the palate, is perhaps an organ adapted for the perception of this sense.

Moreover, personal observations show that the majority of aquarium fishes must, to some extent, be sensible of taste, for in no other way can the fact that they will readily take some foods but reject others even when hungry be accounted for. Sight or smell cannot account for it, since the food is taken into the mouth and then rejected. This observation is important in supporting these statements and it is to be re-emphasised that the fish does not necessarily ignore a source of food on sight. Only after it has been tested in the oral cavity is it accepted or discarded.

Since the digestive process and the alimentary tract obviously begin in the buccal cavity, one feels that the importance of the buccal cavity and the palatine organ have been overlooked by previous workers. This is particularly important in view of the fact that close observation reveals that the palatine organ is densely studded with taste-buds. The impressive extent of these taste-buds is such that one can consider this organ to be a highly specialised mechanism in its own right. The generally accepted views on taste and smell among fishes should also be reviewed, since there is very much controversy regarding this subject. Can a fish taste? This question, in the light of this research, is unsatisfactorily answered by the following statement in the Life Nature Library volume (1964) entitled, 'The Fishes'.

> As for the sense of taste, it is probably not an important one in any fish's life. To begin with, none of them except lung-fishes have taste organs in their mouths. They do have taste-buds, but these may be positioned on the head, body, tail, modified fins or chin barbels, so that if they do taste food, they do so before taking it

into their mouths. Most fish simply gulp their food directly into the stomach where it is digested.

The sense of smell, however, is believed to be very highly developed, this sense being so acute that it is used more than sight in seeking food (Life Nature volume, 'The Fishes').

Smith (1961) said,

> Little is known about the sense of taste but that it functions probably to some extent. Some fishes, for instance the Kabeljou (Johnius hololepidotus (Lacepede)), will take in food, eject it, and then return to swallow it. Some fish will not take stale bait, while others prefer it. However, it is not known whether this depends on taste or not. It is believed that smell is poorly developed in bony fishes, but is the main food detector in cartilaginous fishes, the shark, in fact, being described as the 'swimming nose'.

Young (1962) elaborated on this theme to a greater extent and, in a brief section of his book, had the following to say:-

> As in all vertebrates, there are two separate chemical senses, taste and smell. The former serves mainly to produce appropriate reactions to food near the body, such as snapping, swallowing, or movements of rejection. Smell, on the other hand, is a 'distance sense', by which the whole animal is steered. The fact that taste-buds occur all over the body obscures the distinction between the two types of receptor. They are innervated by branches of the seventh, ninth and tenth cranial nerves, which may reach far backwards. In some species it has been shown that the fish is able to turn and snap at a piece of food placed near the tail, this power being lost if the branches from the cranial nerves are cut. In mammals, taste-buds serve to discriminate only four qualities (salt, sour, bitter and sweet), most of the so-called 'tasting' being in reality the smelling of the food in the mouth. In fishes, also, the four qualities are discriminated by the taste-bud system, and it has been shown that the minnow (Phoxinus) continues to make such discriminations after the forebrain has been removed. Other chemical discriminations are made by the nose, however, and can only be performed with an intact forebrain. Thus, Phoxinus tastes and smells the same class of substances as man does. The taste-buds are exceedingly sensitive, the threshold for sweet substances being five hundred times and for salt two hundred times lower than in man. On the other hand, some substances that are very bitter for us produce little reaction in Phoxinus.
>
> In many fishes the nose is the chief receptor (macrosomatic). The nose does not communicate with the mouth, except for a few fishes that live buried in the sand (Astroscopus). The sense of smell is used to find food.

It is apparent that there is a great divergence of opinion among these authorities, and the question of whether or not the fish can taste his food remains inadequately answered. Young (1962) offered some positive facts regarding the minnow but gave no indication as to whether the same facts applied to other types of fish. Nor do these sources proffer a description of the buccal cavity or its contents.

Parker (1912) claimed that in addition to smell and taste (chemical senses), vertebrates possess a third sense, which he called a 'common chemical sense'. Nagel (cited by Parker, 1912) contended that the nose of water-inhabiting vertebrates is an organ of taste rather than smell. Parker (1912) refuted this, but stated that the 'common chemical sense' was more closely related to the sense of taste than the sense of smell which was the most primitive sense. A central migration of the cell body [illegible]itive olfactory receptors from the general surface gave rise to the organ[illegible]mmon chemical sense', these in turn taking over groups of epidermal cells w[illegible]volved into taste-buds and, as a result, the organs of taste developed.

[illegible]alatine organ has been observed in a number of Cyprinoid fish, and is part[illegible]y well-developed in the common goldfish (Carassius auratus) and its variations. Close examination reveals several interesting features, not the least being the enormous distribution of structures revealed by the light microscope, which bear a very strong similarity to the recognised taste organs in higher vertebrates.

What then are these structures in the mouth of an animal, that simply gulps food directly into the stomach, has a poor sense of taste, or does not taste at all? Perhaps by classifying them as [illegible]ceptors rather than taste-buds, the answer becomes more apparent.

How does one distinguish between chemoreceptors and taste-buds? Grove and Newell (1961) offered the following definition:-

> Chemoreceptors - organs of chemical sense.
>
> > These comprise a system of taste-buds, not necessarily confined to the oral cavity, and the olfactory organs.
> >
> > Both kinds of organ are stimulated by substances in solution in an aqueous medium. This is provided by the surrounding water in the case of aquatic animals, but in land-dwellers by a solution of watery mucus over the sensory epithelium in the mouth or olfactory organs.

The sense of taste and smell are always closely associated, but a distinction can usually be drawn between the two. The olfactory organs respond to a much lower concentration of chemical substances in the surrounding medium. Also, stimulation of the olfactory organs usually leads to a somatic response, i.e., movement of the whole body towards or away from the stimulus.

During the movement the animal appreciates a gradient of concentration in the stimulating substance and is therefore able to detect the direction from which it is diffusing.

On the other hand, taste-buds respond only to higher concentrations of chemical substances and their stimulation leads to visceral responses, buccal gland secretion, swallowing, etc.

Thus, the olfactory senses give an awareness of substances at a distance, whereas taste is chiefly concerned with testing substances entering the alimentary canal, and can be considered as a later stage in the chemical discrimination.

The taste-bud system

The structure is more or less uniform in all vertebrates. They consist of groups of sensory cells ensheathed in supporting cells and are embedded in the stratified epithelium of the epidermis or that lining the buccal cavity. The sensory cells are long and narrow and their free surfaces carry short, hair-like processes, and around their basal part are nerve fibres. These fibres contributed to 7th, 9th or 10th cranial nerves, according to the position of the taste-buds. In most animals taste-buds lie in the epithelium lining the oral cavity, but in many fishes they occur also on the skin, especially lips and barbels.

Not all taste-buds are concerned with the sensation of taste. Those on the epiglottis of man or around the opening of the swim bladder of fishes, function as a tester of substances in these regions, promoting reflexes that guard against solid particles entering the air passages.

Smell and taste are closely allied senses and certain animals possess an organ of chemical sense, Jacobson's organ, lodged in the diverticulum from the dorsal boundary of the buccal cavity. Its function may be described as 'smelling the food in the mouth'.

This, then, clarifies to a certain extent the differences between taste buds and chemoreceptors. However, it does not aid in the identification of the structures found in the buccal cavity of the goldfish, which for want of evidence to the contrary must be considered as being taste-buds.

The problem of determining whether or not the fish possesses a sense of taste opens up a large sphere of experimentation that requires considerable aid

from the physiologists. This is not, however, an unexplored field since a considerable amount of literature is available regarding this subject. However, when reports vary from statements such as, 'most fish do not possess taste organs in their mouths', to, 'taste functions probably to some extent', it is apparent that there is a wide diversity of opinions.

Taste may be briefly defined as the sensation produced in the mouth by contact with certain substances and the definition applies equally to terrestrial or aquatic animals. Roule (1935) said:-

> ...the fish need not receive substances that taste in its mouth, on its tongue. They are disseminated in the surrounding water as odours are in the air around us. Taste in the fish, is from an external, not an internal source. In aquatic animals the sense of taste behaves like a sense of smell. The creature tastes at a distance...

It has already been stressed that goldfish will reject a piece of food which presumably it finds distasteful only after it has been taken into the mouth and, further, it will investigate the same piece of food, taking it into its mouth and rejecting it, time after time. It would seem reasonable, therefore, to conclude that a fish does not taste substances disseminated in surrounding water any more than a terrestrial vertebrate tastes substances disseminated in the surrounding air. Whether or not a fish can taste is a question that still remains inadequately answered. It appears, however, that Roule (1935) and the authors of 'The Fishes' (1964), subscribe to the same school of thought, both believing that taste in the fish is from on external source. It is easier to present evidence that refutes the observation regarding the absence of taste organs in the mouth. One must assume that this statement has been made on the basis of inadequate histological examination, or possibly it holds good only for fish of certain species.

Kyle (1926) said:-

> ...the composition of the fish is completely different to that of its environment, particularly with respect to its blood. It only takes in what it wants to take in, as is the case with other animals... In this way we can understand why a fish does not taste salt although it lives in salt water...

In actual fact, this statement does not provide a better understanding at all of why fishes do not taste salt; it is not even certain that the statement is an

accurate one. Perhaps marine fishes are devoid of a sense of taste but, more probably, they have a better adapted mechanism than the freshwater fish to enable them to excrete unwanted chlorides. Few observers have chosen to attribute any significance to the presence of taste-buds and, more particularly, to their distribution in the buccal cavity of fishes. McVay and Kaan (1940), working on the goldfish digestive tract, merely observed the presence of taste-buds. Curry (1939), describing the alimentary tract of the carp, gave a far more detailed histological description which corresponded closely to that of the goldfish. However, taste-buds in the buccal cavity were given only a passing reference. In this study of the goldfish, emphasis has been placed upon the presence of the taste-buds. These are sufficient in number in the buccal cavity alone to negate the belief that taste organs in the fish are only located exteriorly. In addition the mucosa of the palatine organ has an accumulation of taste organs that makes it worthy of special attention. The epithelium of this organ is studded with rows of taste-buds that bear a close similarity in appearance to those of other vertebrates but the number is far greater than one would expect to find in any higher vertebrate. The object of this investigation was not to determine whether the goldfish was sensible to taste or not, but the structures revealed histologically, made it impossible to ignore the question completely. It does seem, however, that on the basis of appearances alone, this fish must possess an awareness of taste to some considerable degree, because in no other way can the presence of such a vast taste-bud distribution be explained. If this was so, it would support the observation of careful mastication and discriminating feeding because discrimination is valueless without the ability to taste.

Young (1950) said that, 'it is to be re-emphasised that fish have followed their own lines of specialisation, often with a confusing amount of parallel evolution, and therefore may have evolved features which are unknown in higher forms or, if known, have appeared quite independently.'

8.7. Nerve supply

The nervous system of the goldfish represents a similar basic plan to that from which the higher vertebrate has been elaborated, namely, a number of separate centres, one concerned with each of the main receptor systems. The

main nerve centre is the brain which appears rather elongated, with its lobes widely separated. The XI (accessory cranial nerve) supplies the first branchial arch and the taste-buds in the oral cavity. Young (1962) said that, 'it is generally accepted that the ventral root of cranial nerve XI has disappeared', but it does seem likely that it has survived in the goldfish to supply the striated muscle of the palatine organ. It has already been pointed out that taste-buds are only stable when their innervation is intact and, for this reason, one expected to demonstrate the presence of a very rich nerve supply. The application of various recommended metal impregnation techniques failed to show the nerve endings in the taste-buds but demonstrated the presence of numerous nerve bundles in the palatine organ.

8.8. Unidentified gland

The presence of a small, encapsulated gland with a hilus and a highly convoluted appearance, has been noted. Situated outside the cavity, bi-laterally, above the palatine organ and post-orbitally, this gland appears to be closely associated with the gills. On the basis of its location and relations, it is postulated that the gland, which seems to be of the endocrine type, is associated with an osmoregulatory function. According to Romer and Grove (1935), the quantity and variety of salts in both fresh and sea waters is different from that in the body fluids of fish. The functions of excretion and osmoregulation are performed in fish by the gills and the kidneys.

It is possible, therefore, that this gland functions in some way as an aid in maintaining the correct chloride balance.

CHAPTER IX

CONCLUSIONS

The tremendous number of variations of Carassius auratus that have been derived from one common root stock is an indication of the hardiness and adaptability of the goldfish. It is of interest that some of the established varieties bear very little resemblance to the original common goldfish and many of the gross features influenced and developed by man must surely have reduced the chances of survival. It appears, however, that in spite of the many changes in external appearance, the features of the buccal cavity remain the same. This is certainly true of the varieties of Carassius auratus that were studied for this investigation. The buccal cavity as a whole appears to be a highly specialised feature in this species of fish, and further study of the buccal cavity in other species seems to be indicated.

Due to the wide coverage of this investigation many of the observations that have been produced are fairly superficial. One feels that the buccal cavity, albeit a comparatively small region in relation to the total body size of the fish, can be divided into regions with specialised functions in their own right. In view of the size of the cavity, the variation in shape at different levels is most striking. When the mouth is closed it remains small and compact, but when the protrusible mechanism is operated and the jaws are thrust forward, the cavity is converted into a very capacious receptacle.

In the region of the pharynx the cavity is very small and narrow, and remains unchanged during the process of opening and closing of the mouth. Certain restrictions are imposed by the immobility of the palatal organ which occupies the bulk of the pharyngeal roof. Its convexity corresponds very closely

to the concavity of the floor, ensuring that the highly specialised mucosa covering the palatal organ is brought into contact with any ingested foodstuffs.

Although there is an absence of dentition in the roof, it is obvious from the appearance of the 'dorsal cornified pad' that it serves a very similar function to teeth. The ventral pharyngeal teeth are histologically similar to mammalian teeth but are angulated in such a way that maximum contact can be made with the 'dorsal cornified pad'. It appears that these teeth are eventually worn away since an unerupted tooth is present at the base of each mature tooth. The term 'chewing', as applied to higher mammals is inapplicable to the goldfish, but although biting is impossible, a very efficient grinding mechanism is present.

The distribution of taste-buds and muco-substance rich goblet cells is such that special functions must be attributed to them. The goldfish has no salivary glands, but if active mastication takes place, then it is highly probable that these mucous glands compensate in part, if not wholly, for their absence.

Physiological experimentation would certainly reveal more functional information regarding the taste-buds. However, it is unlikely that such large numbers of taste-buds would be present if a sense of taste was entirely absent.

The bulk of the palatine organ is made up of striated muscle, and apart from reducing the size of the cavity in the pharyngeal region, the organ obviously possesses some other function. It possibly acts as a sphincter, preventing substances taken into the buccal cavity from reaching the oesophagous until they have been 'tested' by the specialised mucosa that covers the organ. Alternatively, or in addition to this, it might function as an expulsion mechanism, since fishes possess the ability to eject unwanted substances from the buccal cavity with considerable force.

Personal observations on a variety of fishes indicate that food substances taken into the mouth are subjected to preliminary investigation before swallowing. For want of different terminology this must be called 'chewing', since this is precisely what it would be in higher vertebrates.

In summary, therefore, it is apparent that the goldfish possesses a very sophisticated buccal cavity, with a highly specialised chemo-receptor mechanism

that functions as part of the palatal organ of Valatour. Provided with the opportunity, the goldfish is a selective feeder, masticates its food and is probably sensible to taste to some great extent.

It must be emphasised, however, that these conclusions are based purely on observations, and it is appreciated that controlled experimentation might well reveal that entirely different functions can be attributed to the structures described.

LIST OF REFERENCES

Al-Hussaini, A.H. (1946). The anatomy and histology of the alimentary tract of the bottom-feeder, Mulloides auriflamma (Forsk). J. Morphol. 78: 121-154.

Al-Hussaini, A.H. (1947a). The anatomy and histology of the plankton-feeder Atherina forskali (Rüpp). J. Morphol. 80: 251-286.

Al-Hussaini, A.H. (1947b). The feeding habits and the morphology of the alimentary tract of some teleosts. Publ. Marine Biol. Sta. Ghardaqua, No.5.

Al-Hussaini, A.H. (1949b). On the functional morphology of the alimentary tract of some fish in relation to differences in their feeding habits. Cytology and Physiology. Quart. J. Microscop. Sci. 90: 323-354.

Arey, L.B. (1968). Human Histology. 3rd ed. Philadelphia: W.B. Saunders Co.

Bancroft, J.D. (1967). An introduction to histochemical technique. England: Butterworth and Co. Ltd.

Banki, Ö. (1936). In 'Handbuch der vergleichenden Anatomie der Wirbeltiere'. Berlin: Urban and Schwarzenberg, 17. 3v. (Bolk et al. Eds.)

Barrington, E.J.W. (1936). Proteolytic digestion and the problem of the pancreas in the Ammocoete larva of Lampetra planeri. Proc. Roy. Soc. (B). 121: 221-232.

Barrington, E.J.W. (1942). Gastric digestion in the lower vertebrates. Biol. Revs. 17: 1-27.

Barrington. E.J.W. (1945). The supposed pancreatic organs of Petromyzon fluviatilis and Myxine glutinosa. Quart. J. Microscop. Sci. 85: 391-497.

Bevelander, G. (1930). Branchial glands in fishes. J. Morphol. 49: 215-221.

Blake, I.J. (1930). Studies on the comparative histology of the digestive tube of certain teleost fishes. I. A predaceous fish, the sea-bass (Centropristes striatus). J. Morphol. 50: 39-70.

Blake, I.J. (1936). Studies on the comparative histology of the digestive tube of certain teleost fishes. III. A bottom feeding fish, the sea-robin (Prionotus carolinus). J. Morphol. 60: 77-102.

Bodian, D. (1935). New methods for staining nerve fibres and nerve endings in mounted paraffin blocks. Anat. Rec. 65: 89.

Bridge, T.W. (1910). The Cambridge Natural History. London: Macmillan, 7v. (Harmer and Shipley (eds.)).

Chen, Shisan C. (1925). Variations in the external characters of the goldfish, Carassius auratus. Con. Bio. Lab. Sci. Soc., China: 1v. Nanking.

Clayden, E.C. (1962). Practical section cutting and staining. 4th ed. London: Churchill.

Cole, F.J. (1944). A History of Comparative Anatomy. London: Macmillan.

Copeland, D.E. (1948). The cytological basis of chloride transfer in the gills of Fundulus heteroclitus. J. Morph. 82: 201-227.

Curry, E. (1939). The histology of the digestive tube of the carp (Cyprinus carpio communis). J. Morphol. 65: 53-78.

Dahlgren, U. and Kepner, W. (1908). Textbook of the Principles of Animal Histology. London: Macmillan.

Dröscher, W. (1882). Beiträge zur Kenntius der histologischen structur der Kieman der Plagiostomen. Arch. f. Naturgesch. 48 Jahr., Bd.1 S.120-177.

Drury, R.A B. and Wallington, E.A. (1967). Carleton's Histological Technique. 4th ed. London: Oxford University Press, 255-290.

Eawards, L.F. (1926). The protractile apparatus of the mouth of the Catastomid fishes. Anat. Rec. 33: 257-270.

Encyclopaedia Britannica (1956). 'GAME to GUNM': 10v. pp. 491-492.

Faussek, V. (1902). Beiträge zur Histologie der Kiemen bei Fischen und Amphibien. Arch. f. mikr. Anat., Bd. 60, S.157-174.

Fitzgerald, M.J.T. (1964). The double-impregnation silver technique for nerve fibres in paraffin sections. Quart. J. Micr. Sci. 105: Pt. 3, 359-361.

Girgis, S. (1952). The bucco-pharyngeal feeding mechanism in an herbivorous bottom-feeding cyprinoid, Labeo horie (Cuvier). J. Morphol. 90: 281-315.

Goodrich, E.S. (1930). Studies on the Structure and Development of Vertebrates. London: Macmillan.

Gregory, W.K. (1933). Fish skulls. A study of the evolution of natural mechanisms. Trans. Amer. Philos. Soc. Phila. No. 23.

Grove, A.J. and Newell. G.E. (1961). Animal Biology, 6th ed. London: Univer. Tutorial Press, 545-548.

Hervey, G.F. and Hems, J. (1948). The Goldfish. London: Butterworth Press.

Kapoor, B.G. (1953). The anatomy and histology of the alimentary canal in relation to its feeding habits of a siluroid fish, Wallago attu (Bl. and Schn.). J. Zool. Soc. (India). 5: 191-210.

Kyle, H.M. (1926). The Biology of Fishes. London: Sidgwick and Jackson.

Leydig, F. (1850). Über die Knochen Schleimkanale fische. Arch. f. Anat. u. Physiol. Jahrg 1850, S. 170-182.

Maximow, A.A. and Bloom, W. (1938). A textbook of histology, 3rd ed. Philadelphia: W.B. Saunders Co.

McVay, J.A. and Kaan, H.W. (1940). The digestive tract of Carassius auratus. Biol. Bull. 78: 53-67.

Parker, G.H. (1912). Sensory appropriation, as illustrated by the organs of taste in vertebrates. Proc. Acad. Nat. Sci. Phila. 64: 147.

Parker, H.W. and Boesman, M. (1954). The basking shark, Cetorhinus maximus, in winter. Proc. Zool. Soc. (London). 124: 185-194.

Pictet, A. (1909). Contribution a l'étude histologique du tube digestif des poisson cyprinoides. Rev. Swisse de Zool. v.17.

Pettengill, O. and Copeland, D.E. (1948). Alkaline phosphatase activity in the chloride cell of Fundulus heteroclitus and its relation to osmotic work. J. Exp. Zool. 108: 235-241.

Riess, A.J. (1881). Der Ban der Kiemenblätter bei den Knochen Fischen. Arch. f. Naturgesch. Bd. 47, S. 518-550.

Rogick, M.D. (1931). Studies on the comparative histology of the digestive tube of certain teleost fishes. 2. A minnow (Campostoma anomalum). J. Morphol. 52: 1-25.

Romer, A.S. and Grove, B. H. (1935). Environment of the early vertebrates. Am. Midland Naturalist, 16: 805-856.

Roule, L. (1935). Fishes: their ways of life. London: Routledge.

Scott, G.G. and Kendall, J.i. (1935). The microscopic anatomy of vertebrates. Philadelphia: Lea and Febiger.

Shackleford, J.M. and Wilborn, W.H. (1968). Structural and histochemical diversity in mammalian salivary glands. Ala. J. Med. Sci. 2: 180-203.

Smith, J.L.B. (1961). The Sea Fishes of Southern Africa. 4th ed. South Africa: Central News Agency, 29, 83-84.

Spicer, S.S., Leppi, T.J. and Stoward, P.J. (1965). Suggestions for a histochemical terminology of carbohydrate rich tissue components. J. Histochem. Cytochem. 13: 599-603.

Suyehiro, Y. (1941). A study on the digestive system and feeding habits of fish. Japan. J. Zool. 10: 1-303.

Ommanney F.D. and the Editors of Life (1964). The Fishes. Life Nature Library. N.V.: Time-Life International (Nederland).

Valatour, M. (1861). Recherches sur les glandes gastriques les tuniques musculaires du tube digestif dans les poissons osseux et les Batraciens. Ann. Sci. Nat. Zool. 16: 219.

Young, J.Z. (1950). The Life of Vertebrates. Oxford: Clarendon Press.

Young, J.Z. (1962). The Life of Vertebrates. Oxford: Clarendon Press, pp. 152-154, 220-221, 252.

Author King R E
Name of thesis The Histological appearance of the epithelium and related structures of the Buccal Cavity of the goldfish 1973

PUBLISHER:
University of the Witwatersrand, Johannesburg
©2013

LEGAL NOTICES:

Copyright Notice: All materials on the University of the Witwatersrand, Johannesburg Library website are protected by South African copyright law and may not be distributed, transmitted, displayed, or otherwise published in any format, without the prior written permission of the copyright owner.

Disclaimer and Terms of Use: Provided that you maintain all copyright and other notices contained therein, you may download material (one machine readable copy and one print copy per page) for your personal and/or educational non-commercial use only.

The University of the Witwatersrand, Johannesburg, is not responsible for any errors or omissions and excludes any and all liability for any errors in or omissions from the information on the Library website.