

https://dspace.org/

Jaws cysts: a correction of the accuracy of a provisional radiological diagnosis with the definitive histological diagnosis

Enahoro, Catherine Olajumoke

2018
https://hdl.handle.net/10539/25246

Downloaded from a DSpace repository. https://dspace.org/

JAW CYSTS: A CORRELATION OF THE ACCURACY OF A PROVISIONAL RADIOLOGICAL DIAGNOSIS WITH THE DEFINITIVE HISTOLOGICAL DIAGNOSIS



Catherine Olajumoke Enahoro

Supervised by: Professor Brian Buch and Dr Sizakele Ngwenya

A research report submitted to the Faculty of Health Sciences, University of the Witwatersrand, Johannesburg, in partial fulfilment of the requirements for the degree of Master of Science.

Johannesburg, 2017

DECLARATION

I, Catherine Olajumoke Enahoro, declare that this research report has been composed solely by myself, and unaided. It is being submitted for the degree of Master of Science in Dentistry (Maxillofacial and Oral Radiology) at the University of the Witwatersrand, Johannesburg. It has not been submitted before for any degree or examination at any other university.

O. C. Enahoro

(Signature of candidate)

19th day of September 2017 in Lagos, Nigeria.

DEDICATION

To Almighty God, who made this possible.

ABSTRACT

This study evaluated the diagnostic accuracy of panoramic and cone-beam CT (CBCT) techniques by correlating the provisional radiological diagnoses of various suspected jaw cysts with their corresponding histological diagnoses. The possible added diagnostic value of CBCT over panoramic radiography was also investigated.

Thirty-five CBCT scans and panoramic radiographs of patients with suspected jaw cysts were analysed at the Wits Oral Health Centre, Johannesburg. Provisional radiological diagnoses were made by two observers using set criteria. Histological records, along with relevant clinical information of these patients were then collected from the Department of Oral Pathology. The histological diagnoses were correlated with the provisional panoramic and CBCT diagnoses using the Cohen kappa statistical method. Sensitivity and specificity tests of the radiological techniques were done.

Although CBCT displayed superior overall sensitivity and specificity compared to panoramic radiography, most diagnoses correlated only moderately with the histological diagnoses (greatest with nasopalatine duct cyst k=0.82, and least with odontogenic keratocyst k=0.64; overall p value=0.00). The value of CBCT was however confirmed in its provision of additional detail useful for both diagnosis and surgical planning in most cases.

Radiographic techniques alone without clinical information are insufficient in the provision of an accurate diagnosis of jaw cysts. Although CBCT shows an overall moderate agreement with the histological diagnoses of most cysts, it is invaluable in the management of jaw cysts, as it often provides important additional details not visible on panoramic radiographs. CBCT may therefore be undervalued as a highly diagnostic tool.

ACKNOWLEDGEMENTS

I would like to thank my sister/aunt, Opeoluwa Adejoro for her immense emotional and financial support throughout the duration of this project.

My profound gratitude goes to my supervisor and mentor, Professor Brian Buch, for his fatherly support, and for reawakening my interest in this subject. My supervisor Dr Sizakele Ngwenya, for showing me the ropes and making this experience pleasurable.
I could not have prayed for a better team.

Special thanks to all members of my family in Lagos, who in no small measure, contributed to making my dreams come true. The Oyetundes, for being my family in Johannesburg. Dr Tunde Ajidahun, for his time, advice and assistance during the project. Dr Rukayat Salami, for the phone calls that kept me going. All my friends who lent their support in different ways.

TABLE OF CONTENTS

DECLARATION II
DEDICATION iii
ABSTRACT iv
ACKNOWLEDGEMENTS v
TABLE OF CONTENTS vi
LIST OF FIGURES viii
LIST OF TABLES ix
CHAPTER 1 1
1. INTRODUCTION 1
1.1. Odontogenic cysts of inflammatory origin 3
1.1.1. Radicular (periapical) cyst and residual cyst 3
1.1.2. Inflammatory collateral cyst, (paradental, mandibular buccal bifurcation cyst) 5
1.2. Odontogenic cysts of developmental origin 6
1.2.1. Dentigerous (follicular) cyst and eruption cyst 6
1.2.2. Odontogenic keratocyst (OKC) 8
1.2.3. Lateral periodontal cyst and botryoid odontogenic cyst 10
1.2.4. Gingival cyst 12
1.2.5. Glandular odontogenic cyst (GOC) 13
1.2.6. Calcifying odontogenic cyst (COC) 14
1.2.7. Orthokeratinised odontogenic cyst (OOC) 15
1.3.1. Nasopalatine duct cyst (NPDC) 15
1.4. Bony cysts 16
1.4.1. Simple bone cyst 16
1.4.2. Aneurysmal bone cyst 17
1.5. Radiological differential diagnoses of jaw cysts 18
1.6. Diagnosis of jaw cysts 18
1.6.1. Use of advanced imaging techniques in the evaluation of jaw cysts 19
1.6.2. Value of CBCT in the diagnosis of jaw cysts 20
1.6.3. Comparative literature analysis 22
1.7. Rationale for the study 27
1.9. Objectives of the study 27

CHAPTER 2 29
2. MATERIALS AND METHODOLOGY 29
2.1. Study Design 29
2.2. Study Site 29
2.3. Sampling and Sample Size 29
2.4. Inclusion and Exclusion Criteria 29
2.5. Data Collection 30
2.6. Ethics 34
2.7. Data analysis 34
CHAPTER 3 36
3. RESULTS 36
3.1. Definition and characterisation of the jaw cysts 36
3.1.1. Patient demographics 36
3.1.2. Radiological features of the cysts 36
3.1.3. Clinical features of the cysts 43
3.2. Sensitivity and specificity of the radiological techniques 46
3.3. Measure of agreement 47
CHAPTER 4 60
4. DISCUSSION 60
CHAPTER 5 65
5. CONCLUSION 65
REFERENCES 66
APPENDIX ONE: PLAGIARISM DECLARATION 78
APPENDIX TWO: PATIENT DATA FORM 79
APPENDIX THREE: ETHICAL APPROVAL 80
APPENDIX FOUR: APPROVAL OF TITLE 81
TURNITIN DOCUMENT 82

LIST OF FIGURES

Chapter 3

Figure 3.1. Schematic representation of the prevalence of jaw cysts based on panoramic radiographic diagnoses 41
Figure 3.2.Schematic representation of the prevalence of jaw cysts based on CBCT radiographic diagnoses 42
Figure 3.3.Schematic representation of the prevalence of jaw cysts based on histological diagnoses 45
Figure 3.4. Panoramic radiograph of a lesion suspected to be an odontogenic keratocyst but confirmed histologically as a glandular odontogenic cyst……..49
Figure 3.5. CBCT scan of a cyst suspected to be an aneurysmal bone cyst but confirmed histologically as a glandular odontogenic cyst……50
Figure 3.6. Photomicrograph of a glandular odontogenic cyst (I) ……..51
Figure 3.7. Photomicrograph of a glandular odontogenic cyst (II)……..52
Figure 3.8. Panoramic radiograph of a maxillary cyst suspected to be a dentigerous cyst but confirmed on CBCT and histology as an OKC……56
Figure 3.9. CBCT scan of an OKC with the appearance of daughter cysts……..56
Figure 3.10. Photomicrograph of an odontogenic keratocyst (I)……57
Figure 3.11. Photomicrograph of an odontogenic keratocyst (II)……58
Figure 3.12. CBCT scan of a NPDC with posterior extension into the nasal fossa…….59

LIST OF TABLES

Chapter 2

Table 2.1. Summary of typical radiological features of various cysts……32
Table 2.2. Summary of typical clinical features of various cysts……33

Chapter 3

Table 3.1. Patient demographics……36
Table 3.2. Site/distribution of the jaw cysts per patient and per cyst……37
Table 3.3. General radiological features of the analysed jaw cysts……...38
Table 3.4. Specific features of the most prevalent CBCT-diagnosed jaw cysts……..39
Table 3.5. Specific features of the least prevalent CBCT-diagnosed jaw cysts……..40
Table 3.6. Average sizes of the CBCT-diagnosed jaw cysts……..42
Table 3.7. Clinical features of the most prevalent histologically-diagnosed jaw cysts…43
Table 3.8. Clinical features of the least prevalent histologically-diagnosed jaw cysts…44
Table 3.9. Panoramic, CBCT and histological diagnoses of the analysed jaw cysts…..45
Table 3.10. Results of sensitivity and specificity tests of panoramic and CBCT radiography……..46
Table 3.11. Measure of agreement (kappa score and p-value)……..47

CHAPTER 1

1. INTRODUCTION

A cyst is a pathological epithelium-lined cavity, which contains fluids, semi-solids or gases (Weber et al, 2003)), but is not formed by the accumulation of pus (Kramer, 1974). The jaw bones are most commonly affected (White and Pharoah, 2009). Although many jaw cysts are discovered incidentally during dental examinations, some may exert pressure on the bony cortices causing slow-growing bony expansions or functional disturbances due to structural weakening and remodeling of the bone (Devenney-Cakir et al, 2011). They typically are painless, unless secondarily infected, and may occur in relation with missing, unerupted or impacted teeth (White and Pharoah, 2009).

Radiologically, cysts in the maxilla or mandible commonly appear as round or oval, well-defined radiolucencies with a thin radiopaque border. A secondary infection may however, erode the border to some extent causing it to become fuzzy or slightly ill-defined. Some cysts display a scalloped periphery around the roots of involved teeth. They are mostly unilocular, but may be multilocular, due to internal bony septae. They may extend into the maxillary antrum, or displace the inferior alveolar canal inferiorly. There may be resorption of roots of associated teeth, or displacement of teeth. Long-standing cysts may present with diffuse opacities due to dystrophic calcification (White and Pharoah, 2009).

Several classifications of jaw cysts by different authors exist. These have been modified and reviewed over the years. The most recent World Health Organisation (WHO) classification of head and neck tumours and cysts (El-Naggar et al, 2017) classifies jaw cysts based on their tissues of origin and pathogenesis.

WHO classification of jaw cysts (2017)

a. Odontogenic cysts of inflammatory origin
    i. Radicular cyst, Residual cyst
    ii. Inflammatory collateral cyst, Paradental cyst, Mandibular buccal bifurcation cyst
b. Odontogenic developmental cysts
    i. Dentigerous cyst, Eruption cyst
    ii. Odontogenic keratocyst
    iii. Lateral periodontal cyst, Botryoid odontogenic cyst
    iv. Gingival cyst: Gingival cyst of adults, Gingival cyst of infants
    v. Glandular odontogenic cyst
    vi. Calcifying odontogenic cyst
    vii. Orthokeratinised odontogenic cyst
c. Non-odontogenic cysts
    i. Nasopalatine duct cyst
d. Bone cysts (pseudocysts)
    i. Solitary bone cyst
    ii. Aneurysmal bone cyst

All true cysts have an epithelial lining. Odontogenic cysts arise from the proliferation and cystic degeneration of epithelial residues of the tooth-forming tissues, and may be of inflammatory (acquired) or developmental origin. Three types of epithelial residues have been described.

1. *Epithelial rests of Malassez* found in the periodontal ligament are remnants of the epithelial root sheath of Hertwig after the initiation of dentinogenesis. These cells are stimulated to proliferate by bacterial endotoxins and necrotic debris released at a focus of inflammation. This results in renewed mitotic activity, leading to the formation of an inflammatory odontogenic cyst (Browne, 1975).
2. *Reduced enamel epithelium* is a remnant of the enamel organ after crown formation, through which a tooth erupts into the oral cavity.

Obstruction of follicular veins by an impacted unerupted tooth results in transudation across the vessel walls. Accumulation of the resultant fluid between the reduced enamel epithelium and the unerupted tooth, leads to the formation of a dentigerous cyst (Browne, 1975).

3. *Epithelial rests of Serres* are remnants of the dental lamina. These cells have the ability to proliferate, keratinise and form microcysts from as early a stage as 10 weeks in-utero (Shear and Speight, 2007).

   Odontogenic keratocysts are formed by the proliferation of these cell rests (Browne, 1975).

Non-odontogenic cysts, on the other hand, do not develop from the remnants of tooth-forming tissues (Shear and Speight, 2007).

1.1. Odontogenic cysts of inflammatory origin

1.1.1. Radicular (periapical) cyst and residual cyst

Radicular cyst

This is the most frequently-occurring odontogenic cyst of the jaw. It is found most commonly in persons between the ages of 30-60 years (White and Pharoah, 2009) and occurs as a sequel to pulpal necrosis due to caries or trauma (Lin et al, 2007). Pulpal inflammation spreads to the apex of the tooth root resulting in a periapical periodontitis. An acute apical abscess or a chronic granuloma may follow. Persistence of the chronic lesion may lead to the formation of a cyst (Weber et al, 2003). The maxillary anterior teeth, which tend to be most frequently affected by trauma, are most often affected but any tooth may be involved. Although dental caries is common in children, the radicular cyst is not usually associated with deciduous teeth, in which pulpal and periapical infections tend to drain more easily. Most radicular cysts are asymptomatic and discovered incidentally, or during investigation of non-vital (e.g. discoloured) teeth, but others may present with pain, infection, or a bony hard swelling, which may become fluctuant when expanded. A discharging sinus may be associated with the involved tooth (Shear and Speight, 2007).

The typical radiological feature is a well-defined unilocular radiolucency with a narrow radiopaque rim extending from the lamina dura at the apex of a non-vital tooth. It may also occur lateral to the tooth root if the lateral accessory canal is involved (Shear and Speight, 2007). There are situations, however, where a radiopaque rim is not present, or where present may not infer the presence of a cyst, but of a granuloma or abscess (Ricucci et al, 2006). There may be associated root resorption, tooth displacement, displacement of the inferior alveolar canal, and cortical expansion in large lesions (Weber et al, 2003).

Histologically, the epithelium is usually a stratified squamous epithelial lining of variable thickness, with inflammatory cell infiltrates. The fibrous capsule is made up of collagenous fibrous connective tissue which, during active growth, is vascular, and infiltrated by chronic inflammatory cells adjacent to the epithelium. In early, proliferative linings, there is an abundance of polymorphonuclear leucocytes and a considerable degree of spongiosis. Inflammation reduces as the cyst enlarges and thus becomes quiescent, this is most evident at the part of the epithelium most distant from the apex of the tooth. Often, cholesterol crystals are found, alongside haemosiderin-containing macrophages, and pigmented lipofuscin-containing macrophages. Hyaline bodies may occasionally be found in the epithelium, and rarely in the fibrous capsule. The epithelium may undergo metaplasia, whereby mucous cells and ciliated cells may be found (Shear and Speight, 2007).

Residual cyst

Proliferation of the epithelial remnants from a radicular cyst of an extracted tooth may result in a residual cyst. This cyst may remain asymptomatic and static, regress, or increase in size over the years. A case of a residual cyst causing a swelling so large it involved half of the mandible with associated mental nerve paraesthesia has been reported (Dimitroulis and Curtin, 1998).

Histologically, the epithelial lining is non-specific, thin and regular, similar to a developmental cyst, as there has been progressive loss of inflammation (Martin and Speight, 2017).

1.1.2. Inflammatory collateral cyst, (paradental, mandibular buccal bifurcation cyst)

This is an odontogenic inflammatory cyst which occurs on the lateral surface of a vital tooth. There are different variants of this cyst, with the same pathogenesis and histological features, but occurring in different locations within the jaws.

Several authors believe that they are derived from the reduced enamel epithelium secondary to inflammatory destruction of the periodontium due to pericoronitis or an inflamed periodontal pocket. This has been suggested by the continuity of the cyst linings with the reduced enamel epithelium or periodontal pocket of the associated tooth, and may be sequential to the downward extension of the reduced enamel epithelium at the site of an enamel spur, leading to stagnation in that area. A few authors believe they may be derived from the epithelial rests of Malassez (Shear and Speight, 2007).

The “paradental cyst” is the most common variant, located lateral to the roots of a partially erupted mandibular third molar, with the patient presenting with a history of recurrent or persistent pericoronitis. It typically presents around the 3rd decade of life, with a recorded male predilection in most cases. Occasionally they may occur bilaterally. Radiologically they appear as well-demarcated unilocular radiolucencies with the location of the cyst being dependent on the angle of impaction of the tooth. The cyst is often superimposed on the buccal surface of the tooth, usually with an additional distal radiolucency distinct from the distal follicular space. The lamina dura and periodontal space are often intact (Shear and Speight, 2007).

The mandibular buccal bifurcation cyst (or mandibular infected buccal cyst) is a rare inflammatory cyst specifically located at the bifurcation of the roots of vital 1st, or less commonly, 2nd molars, unilaterally. It originates from the buccal periodontium, and is found most commonly in the 6-11year-old age group (David et al, 1998). It may present with more severe clinical signs and symptoms than paradental cysts such as facial swelling or abscess, due to the difference in anatomical features of the mandible in this younger age group (Shear and Speight, 2007). It presents as a u-shaped unilocular radiolucency which appears superimposed over the associated roots. Typically, there is tilting of the buccal cusp of the involved tooth, with its root apex wedged into the lingual

cortex (David et al, 1998). This feature is best observed on an occlusal radiograph. Buccal cortical expansion may be associated (Shear and Speight, 2007).

Rarely, inflammatory collateral cysts may be found in the globulomaxillary region due to an erupting canine or the mandibular premolar region (Shear and Speight, 2007).

Histologically, the cyst lining typically shows hyperplastic, non-keratinising squamous epithelium, with haemosiderin or cholesterol crystal deposits and is indistinct from that of radicular cysts (Shear and Speight, 2007).

1.2. Odontogenic cysts of developmental origin

1.2.1. Dentigerous (follicular) cyst and eruption cyst

Dentigerous cyst

This is the second most commonly-occurring odontogenic cyst. Typically found in the 3rd molar region of the mandible and the maxillary canine region, it occurs most frequently in the 3rd and 4th decades of life (Dunfee et al, 2006). Other less frequent sites are the mandibular premolar and maxillary third molar regions. The maxillary mesiodens is the most commonly associated supernumerary tooth. They may also be associated with odontomes (Shear and Speight, 2007).

Differentiating between a small dentigerous cyst and an expanded follicular space may be difficult. The criterion normally used is the pericoronal width at the tooth neck, which when at least 3-4mm may be considered a cyst (Shear and Speight, 2007).

Often discovered incidentally during routine radiological investigations, dentigerous cysts are slow-growing and may grow to a large size before being clinically obvious (Shear and Speight, 2007). The typical radiological presentation is that of a well-defined, unilocular radiolucency with a sclerotic border, adjacent to the crown of an unerupted tooth (usually an impacted 3rd molar), attached to the neck of the tooth (Freitas et al, 2006). Resorption of roots is frequent (Shear and Speight, 2007).

There are three radiological varieties of dentigerous cysts:

- Central variety: The cyst envelopes the crown of the tooth symmetrically, applying pressure to it, such that the tooth is often pushed away from its path of eruption. Hence, mandibular 3rd molars may be pushed to the lower border of the

mandible, and maxillary canines to the maxillary sinus, even as far as the orbital floor.

- Lateral variety: There is a dilatation of the follicle on one side of the crown, such as is mostly seen in a partially erupted tooth with a lateral orientation.
- Circumferential variety: Envelopes the entire tooth, as it appears to be falling under its own weight.

  (Shear and Speight, 2007).

Lesions which mimic dentigerous cysts radiologically include radicular cysts developing from deciduous teeth, envelopmental and follicular variants of odontogenic keratocyst, and unilocular ameloblastomas associated with an adjacent unerupted tooth. In such cases, a histological diagnosis provides confirmation (Shear and Speight, 2007).
Histologically, the epithelial lining is thin and non-keratinised with 2-4 cell layers of flat or cuboidal cells characteristic of reduced enamel epithelium. Sometimes mucous cells, ciliated cells, or rarely sebaceous glands may be found, suggestive of metaplasia. The superficial layer may contain low columnar ameloblast-like cells. The cyst wall is thin and fibrous, consisting of young fibroblasts separated by stroma and ground substance rich in acid mucopolysaccharide. Hyaline bodies may be seen. When inflamed the cyst wall is thick, although occasional epithelial bud-like thickenings extending into the fibrous capsule may be seen in the absence of inflammation (Shear and Speight, 2007).
Rarely, paraesthesia of the inferior alveolar nerve occurs and malignant change is a possibility. The occurrence of bilateral dentigerous cysts has been noted in patients with syndromes such as cleidocranial dysplasia or mucopolysaccharidosis (type VI), but very rarely, isolated cases have been reported (Freitas et al, 2006).

Eruption cyst

Believed to be a form of dentigerous cyst, an eruption cyst occurs within the thick fibrous mucosa overlying an erupting tooth (Bodner et al, 2005). They occur most frequently in young patients, and occasionally in adults when there is delayed eruption of teeth. They may be associated with deciduous or permanent teeth, and multiple lesions may occur concurrently. They appear as soft, fluctuant, smooth swellings, which

are either bluish or the normal colour of the gingivae, and are often painless unless secondarily infected (Shear and Speight, 2007).

Recorded causal links have been made between the development of eruption cysts and the administration of cyclosporine A, an immunosuppressant. In a study of a young boy who developed the cysts when administered the drug, withdrawal of the drug resulted in their resolution and no further development of cysts (Kuczek et al, 2003).

Radiologically, a soft tissue shadow instead of bone may appear above the crown of an unerupted tooth (Shear and Speight, 2007).

1.2.2. Odontogenic keratocyst (OKC)

In the 3rd edition of the classification of head and neck tumours, the WHO re-classified this lesion, which had hitherto been regarded as a developmental cyst, as a benign odontogenic tumour. This was due to its then reported neoplastic nature. The lesion was re-named “keratocystic odontogenic tumour” (Barnes et al, 2005). However, due to controversies about its neoplastic nature, the classification has been revised, and it is now regarded yet again as an odontogenic cyst (El-Naggar et al, 2017). It typically involves the angle of the mandible, though other regions of the mandible, and even the maxilla may be affected. A rare extra-osseous variety has also been found, involving the alveolar mucosa or gingiva of the canine-premolar region (Chi et al, 2005). It typically presents in the 2nd and 3rd decades of life (Minami et al, 1996). Though often discovered incidentally on routine radiographs, it may present with pain, swelling and drainage if infected. It tends to grow to a large size, sometimes causing pathological fractures, before manifesting clinically (Shear and Speight, 2007). There have been reported occurrences of maxillary odontogenic keratocysts so extensive as to encroach on the maxillary sinus and destroy the floor of the orbit, leading to proptosis of the eyeballs (Voorsmit, 1985; Lund, 1985). Chuong et al (1982) and Jackson et al (1993), reported lesions which extended to the infratemporal fossa and the base of the skull.

OKCs have distinctive clinical and histological features, which include a high recurrence rate and a locally aggressive character. The possible reasons for recurrence include the thin and fragile cystic lining and the presence of daughter cysts which are often difficult to remove entirely during enucleation. They may be part of a syndrome known as Gorlin-Goltz syndrome (basal cell nevus syndrome). Other signs of this syndrome

include multiple naevoid basal cell carcinomas of the skin, ectopic calcifications, frontal bossing, hypertelorism, bifid ribs, central nervous system defects, and ocular lesions (Shear and Speight, 2007). There are, however, incidents where patients present with multiple keratocysts involving both jaws, but not as part of a syndrome (Chow, 1998).

Radiologically, they appear as well-defined unilocular radiolucencies with smooth borders, or multilocular radiolucencies, some with scalloped borders suggestive of unequal growth patterns in different parts of the cyst lining. There is often an associated impacted tooth and perhaps displaced teeth, but root resorption is rare (Grasmuck and Nelson, 2010). They extend through the medullary cavity and therefore do not tend to cause significant expansion in the body of the mandible. However, once they extend to the ramus and coronoid process, they may cause extensive expansion (White and Pharoah, 2009). Considerable cortical expansion is more common in children. They may also cause displacement of the inferior alveolar canal (Shear and Speight, 2007).

Often an OKC may involve an unerupted tooth, which seems to have ‘grown into’ the cyst, forming a ‘dentigerous’ relationship, with an attachment to the cemento-enamel junction of the tooth. This “follicular” presentation may lead to a radiological misdiagnosis of a dentigerous cyst. A variety of OKC which completely encircles an unerupted tooth, on the other hand, is an “envelopmental OKC”. Other radiological forms are the “replacement OKC” which replaces a normal tooth in the arch; the “collateral OKC” which occurs lateral to the roots of a tooth (usually a mandibular premolar) and the “extraneous OKC” which occurs in the ascending ramus of the mandible.

Thus, a number of cysts may present with similar radiological features. These include dentigerous cysts, radicular cysts, residual cysts, lateral periodontal cysts, and even nasopalatine duct cysts should they occur in the anterior midline. Multilocular cysts may also present as ameloblastomas (Shear and Speight, 2007).

Histologically, the stratified squamous epithelial lining is parakeratinised with a corrugated surface, 6-8 cells thick, lacking rete ridges, with the lumen of the lesion filled with keratin-like material or clear fluid (Grasmuck and Nelson, 2010). There are palisaded columnar/cuboidal basal cells with hyperchromatic nuclei, displaying reversal of polarity. There is an increase in mitotic figures in the suprabasal layers. The thin

fibrous capsule which is usually rich in mucopolysaccharides may occasionally contain mild lymphocytes and monocytes, which when intense cause a loss of keratinization of the epithelial lining, development of rete ridges or ulceration. Satellite cysts or epithelial rests may be present, especially in patients with multiple cysts. Melanin pigments, hyaline bodies, mast cells and cholesterol crystals may also be present. Mucous metaplasia may occur (Shear and Speight, 2007). Occasionally, the epithelial linings may exhibit dysplasia, and a few cases of carcinomatous change have been documented (Van der Waal, 1985; Makowski et al, 2001).

1.2.3. Lateral periodontal cyst and botryoid odontogenic cyst

Lateral periodontal cyst

This is a rare intra-osseous developmental cyst, which arises in close proximity to the roots of vital teeth (Shear and Speight, 2007). It is most frequently found in the premolar region of the mandible, followed by the anterior maxilla. It typically occurs in individuals between the ages of 40-70 years old, but may also be found in older or younger individuals (Wysocki et al, 1980). It has no definite gender predilection. When clinically symptomatic it may present with pain, tenderness on palpation, a bony swelling, or even a fluctuant gingival swelling similar to a gingival cyst of adults (Shear and Speight, 2007).

The epithelial origin of this cyst is controversial. Some authors propose that they originate from remnants of the dental lamina. Wysocki and colleagues (1980) proposed that they originate from post-functional rest cells of the dental lamina with limited proliferative capacity, unlike odontogenic keratocysts of the same epithelial origin, which develop from highly proliferative cells of the dental lamina. They supported their hypothesis by the occasional presence of glycogen-rich clear cells, characteristic of cells of the dental lamina. Other authors propose its origin from lateral parts of the reduced enamel epithelium, before the eruption of a tooth into the oral cavity (Friedrich et al, 2014). Moreover, epithelial plaques seen in the lining of lateral periodontal cysts are also occasionally seen in the lining of dentigerous cysts, supporting this theory (Shear and Speight, 2007). A few authors propose its origin from the cell rests of

Malassez, but evidence of this is not really available. A genetic basis has also been postulated (Shear and Speight, 2007).

The cyst displays several variants, and in rare cases may remain after loss of a tooth, similar to residual radicular cysts (Mendes and van der Waal, 2006). It must also be differentiated from other cysts which may occur in the same site, such as a lateral radicular cyst and a collateral OKC (Shear and Speight, 2007).

It shares similar morphological features with gingival cysts of adults. These, however, arise post-eruption. Furthermore, gingival cysts of adults are not intra-osseous (Friedrich et al, 2014).

Often found incidentally on radiographs, these cysts present as well-defined, often sclerotic, unilocular radiolucencies. They may also resemble lateral outgrowths of dentigerous cysts (Rasmussen et al, 1991). They usually lie somewhere between the apex and the cervical margin of the tooth. They are mostly less than 1cm in diameter. There is usually no associated root resorption. Cortical expansion may occur (Shear and Speight, 2007).

Histologically, the cyst lining is a thin, non-keratinising, squamous or cuboidal epithelium, often with the presence of epithelial thickenings (plaques) which may extend into the cyst lumen or wall. There are also epithelial nests and follicles, and sometimes microcysts in the fibrous wall. The nuclei are small and pyknotic, and there is sometimes presence of glycogen-rich clear cells. The presence of melanin granules has also been reported (Shear and Speight, 2007).

Botryoid odontogenic cyst

The multicystic variant of the lateral periodontal cyst is regarded as a separate entity due to its more expansile nature and tendency to recur if improperly enucleated (Ramer and Valauri, 2005). It occurs most frequently in patients in their 5th, 6th or 7th decades of life. It is typically found in the mandible and may occur bilaterally. Patients may be asymptomatic and the cysts are discovered incidentally, or may present with swelling, pain, paraesthesia or discharge (Ramer and Valauri, 2005).

Radiologically, the BOC presents as a unilocular or multilocular radiolucency.

Weathers and Waldron first described the cyst in 1973 as having a 'grape-like' (botryoid) macroscopic presentation, possibly caused by epithelial plaques forming new locules within the lumen. The cyst is histologically similar to the lateral periodontal cyst except for its multicystic nature, with the cysts separated by thin fibrous connective tissue septae. Clear cells are however unusual (Shear and Speight, 2007).

1.2.4. Gingival cyst

Gingival cyst of adults

Wysocki and colleagues (1980) postulated that this cyst is the extra-osseous variant of the lateral periodontal cyst, as it originates from the breakdown of epithelial rests of the dental lamina, and shares similar clinical and morphological properties with the lateral periodontal cyst. Nxumalo and Shear (1992), believe that the gingival cyst of adults (GCA) originates from reduced enamel epithelium, citing similarities of the epithelial linings with that found in dentigerous cysts. GCA occurs most often in the mandibular premolar-canine region. Although it presents in a wide age range, the GCA typically occurs in an older age group with a peak incidence in the 6th decade of life. GCA may have a slight female predilection (Shear and Speight, 2007).

Clinically, GCA often remain unnoticed and is discovered incidentally in gingival biopsies. In exceptional cases, GCA may be large enough to result in gingival swelling and erosion of the underlying bone (Moskow, 1966). The usual presentation is that of a soft, fluctuant, painless, slow-growing mass on the interdental papilla of the buccal gingivae or the attached gingivae. The swelling is usually less than 1cm in greatest diameter, round, well-circumscribed and smooth surfaced (Shear and Speight, 2007). The cysts may be bilateral (Shade et al, 1987), or present synchronously with a lateral periodontal cyst (Tolson et al, 1996).

Radiologically, GCA may show no change, or a vague shadow indicating shallow bone erosion (Shear and Speight, 2007).

Histologically, the epithelial lining is of variable thickness, often with pyknotic nuclei and cytoplasmic vacuolation. The cyst is usually unicystic, but may occasionally be multicystic (Shear and Speight, 2007).

Gingival cyst of infants

The gingival cyst of infants presents as a small, relatively common white or cream-coloured lesion on the alveolar ridge that develops from cystic formation in the epithelial rests of the dental lamina in newborn infants. The cyst rarely persists beyond the age of 3 months and usually disappears by involution or rupture through the surface epithelium (Shear and Speight, 2007).

1.2.5. Glandular odontogenic cyst (GOC)

The GOC is a rare aggressive developmental odontogenic cyst with a tendency to recur and no significant gender predilection (Shear and Speight, 2007). The cyst, initially believed to be of salivary gland origin, occurs over a wide age range. The anterior mandible is the site of predilection, although the maxilla may be involved.

Histologically, the cyst is similar to the central mucoepidermoid carcinoma of the jaw and shares features with the lateral periodontal and botryoid odontogenic cysts. It contains plaques and mucous cells in its non-keratinised epithelial lining of variable thickness, with eosinophilic cuboidal or columnar ("hobnail") cells and occasional goblet cells in the superficial layer (Padayachee and van Wyk, 1987). The hobnail cells may exhibit 'pinching-off' of the surface, similar to cells that line apocrine gland ducts or be ciliated. Clear cells may be present subjacent to the hobnail cells (Fowler et al, 2011). The occasional presence of microcysts opening onto the surface through crypts may give the epithelium a corrugated appearance (Padayachee and van Wyk, 1987).

The connective tissue wall may contain islands of odontogenic epithelium, microcysts or irregular calcifications

It often contains multiple cystic spaces which may either be empty or contain mucinous materials (Padayachee and van Wyk, 1987).

Radiological presentation is non-specific. The cyst may present as a unilocular or more frequently a multilocular, well-demarcated radiolucency, with smooth or scalloped margins. Cortical plate expansion is common, and cysts larger than 6cm tend to display perforated margins, with some maxillary cysts encroaching on the maxillary sinus (Noffke and Raubenheimer, 2002). Associated tooth displacement and root resorption may be noted (Shear and Speight, 2007).

The infiltrative nature of this cyst makes it difficult to distinguish the GOC from ameloblastomas and OKCs radiologically. In 1994, Takeda reported a variant which had a similar presentation to that of a LPC.

1.2.6. Calcifying odontogenic cyst (COC)

Like the OKC, classification of this lesion has been in contention. In 2005, due to its tumour-like characteristics, the lesion was re-classified by the WHO as a benign odontogenic tumour, and was renamed “calcifying cystic odontogenic tumour” (Barnes et al, 2005). It has recently been re-categorised by the same body, as an odontogenic cyst and retains its original name and status, as there has been insufficient evidence for neoplastic behaviour (El-Naggar et al, 2017). COC is believed to originate de novo either from remnants of the reduced enamel epithelium, gingival tissue, or bone (Takeda et al, 1990; Praetorius et al, 1981).

The characteristic presence of “ghost cells” and the histological resemblance of COC to the cutaneous calcifying epithelioma of Malherbe was first observed by Gorlin and colleagues (1962,1964), who called it a “Gorlin cyst”. Dentinogenic ghost cell tumour, the solid variant of this ghost cell lesion, has been described as a true neoplasm and not a cyst. However, the majority of ghost cell lesions present as simple cysts which may be associated with odontomes. True tumours constitute about 5% (Ledesma-Montes et al, 2008). The term COC thus specifically describes the cystic non-neoplastic lesion.

The rare cystic lesion occurs over a wide age range and has little tendency to recur (Shear and Speight, 2007). Although Daniels, in 2004 reported a recurrent lesion encroaching the maxillary sinus and involving the orbital floor of the orbit and zygomatic bone. The COC occurs in the maxilla or the mandible with relatively equal frequency. It often presents as an extensive bony hard swelling, and may perforate bony cortices (Shear and Speight, 2007).

Radiologically, it presents as a unilocular or occasionally multilocular radiolucency, with a well- or poorly-demarcated margin. Within the cyst there may be calcifications of variable size and opacity. Unerupted teeth and complex odontomes are often associated. Adjacent root resorption and tooth displacement is frequently seen. Cortical expansion may occur (Shear and Speight, 2007).

Histologically distinct, a thick stellate reticulum-like layer overlies an epithelial lining, 6-8 cells thick, with a well-defined basal layer of columnar/ cuboidal cells, with hyperchromatic nuclei displaying reversal of polarity. The presence of 'ghost' cells in the lining and fibrous capsule is characteristic. Islands of epithelium, satellite cysts, dentinoid, or odontoma may be seen in the wall (Shear and Speight, 2007). Odontoameloblastoma, ameloblastic fibroma and ameloblastic fibro-odontoma may be associated (Praetorius, 1975).

1.2.7. Orthokeratinised odontogenic cyst (OOC)

In 2017, the WHO added this lesion as a distinct developmental odontogenic cyst (El-Naggar et al, 2017). Prior to this period, it had always been regarded as a relatively rare variant of the OKC (Wright, 1981). It typically occurs in young male adults, in the body or ramus of the mandible (Swain et al, 2012).

Its clinical presentation is similar to a typical OKC, but it is histologically distinct. It presents with an orthokeratinised epithelial lining with a flattened cuboidal basal cell layer without palisading or reversal of nuclear polarity. Unlike the OKC, it rarely recurs, as there are no daughter cysts and no epithelial proliferation (Wright, 1981).

Radiologically, it presents as a well-defined unilocular or multilocular radiolucency. Unlike the OKC, it tends to display extensive cortical expansion, with the lingual cortex extending inferiorly below the inferior border of the mandible, similar to an ameloblastoma. OOC does not cause root resorption (MacDonald-Jankowski, 2010)

1.3. Non-odontogenic cysts

1.3.1. Nasopalatine duct cyst (NPDC)

The NPDC is an epithelium-lined non-odontogenic cyst of the maxilla, presenting apical to the roots of the central incisors. It originates from cystic degeneration of the embryonic remnant of the nasopalatine duct and most frequently occurs in the 3rd to 6th decades of life. NPDC has a predilection for black males, in whom the lesion tends to be larger and more aggressive (Shear and Speight, 2007).

Often diagnosed incidentally, it is usually asymptomatic, except in instances where there is secondary infection with resultant pain, fluctuant swelling and/or drainage. The NPDC rarely recurs (Nelson and Linfesty, 2010).

Radiologically, they appear as well-defined, round or heart-shaped unilocular radiolucencies, depending on the specific view and due to either the superimposition of the anterior nasal spine or the occurrence of bilateral cysts in both fossae. Divergence of the roots, root resorption and tooth displacement may be associated. Posterior extension of the cyst may occur, leading to the former diagnosis of these variants as median palatine cysts (Shear and Speight, 2007). The distinction between a large incisive fossa and a cystic cavity may be difficult. In a South African study, Chamda and Shear (1980) concluded that radiographic shadows with anteroposterior dimensions of up to 10mm were within normal limits of incisive fossae, and recommended that patients presenting in this manner, especially in the absence of symptoms, should be periodically monitored. Bodin and colleagues (1986) concluded in their findings that any similar radiolucency exceeding 14mm in diameter should be regarded as a cyst.

Histologically the epithelial lining is variable and majority of nasopalatine duct cysts have a varied combination of epithelial lining including stratified squamous epithelium, pseudostratified columnar or cuboidal epithelium, or primitive flat epithelium. Occasionally, melanin and lipofuscin granules are found in the lining. The fibrous capsule often contains nerves and blood vessels, and occasional mucous glands. Rarely, small islands of hyaline cartilage may be seen in the cystic wall (Shear and Speight, 2007).

1.4. Bony cysts

These are cyst-like cavities within the bone and are not true cysts as they lack an epithelial lining. They are hence termed “pseudocysts”.

1.4.1. Simple bone cyst

This is a general term for certain rare cystic lesions which present with fluid-filled or empty cavities within the bone (Shear and Speight, 2007). These lesions may also be referred to as solitary bone cyst, haemorrhagic bone cyst, traumatic bone cyst,

idiopathic bone cavity and unicameral bone cyst (Suomalainen et al, 2009). They occur most often in young individuals, with a peak frequency in the second decade of life. There is no significant gender predilection. They typically occur in the mandible, with very few cases recorded in the maxilla (Shear and Speight, 2007).

Although the cause is unknown, they are postulated to occur following trauma to the bone marrow with subsequent intramedullary haemorrhage. Cystic formation may result from failure of organization of the primary haematoma and subsequent breakdown of the clot. Osteoclastic activity is then stimulated by the resultant increased intracystic pressure, resulting in resorption of intact cortical bone. Subperiosteal new bone formation, clinically presenting as a swelling, may be seen. Reduction of intracystic pressure due to transudation into the cyst will result in spontaneous regression of the lesion (Shear and Speight, 2007).

Histologically, these lesions lack an epithelial lining, but have a fibrous connective tissue wall of variable thickness. They may be empty, or may contain blood or serosanguineous fluid. Haemosiderin pigments and multinucleated giant cells may be present (Shear and Speight, 2007).

Often discovered incidentally during routine radiographs, simple bone cysts typically present as well-defined, non-corticated unilocular radiolucencies, with scalloping between the roots of teeth (Suomalainen et al, 2009). Occasionally, cysts may be multilocular. There is usually no cortical expansion, and only occasional root resorption. The lamina dura may or may not be intact (Shear and Speight, 2007).

1.4.2. Aneurysmal bone cyst

This is a rare pseudocyst typically located in the mandible in children. It may present as a locally-aggressive facial swelling, which though painless, may be very unaesthetic (Capote-Moreno et al, 2009). It may also result in malocclusion of the jaws, or limitation of mouth opening if the lesion affects the capsule of the temporomandibular joint. Perforation of the bony cortices may lead to egg-shell crackling of the resultant thin periosteum (Shear and Speight, 2007).

While some authors propose its origin as secondary to erosion of the cortical bone of a preexisting asymptomatic bony lesion, others believe it may be congenital due to

primary trauma such as a dental extraction or a result of vascular alteration within a latent lesion (Capote-Moreno et al, 2009).

Histologically, aneurysmal bone cysts are very similar to, and may be indistinguishable from central giant cell granulomas and other giant cell lesions, giving weight to the theory that they may result from these preexisting lesions. The cysts contain many capillaries and blood-filled spaces of various sizes lined by flat spindle-shaped cells, loose fibrous tissue, multinucleated giant cells and trabeculae of osteoid and woven bone scattered within. Occasionally, there may be solid areas, resembling central giant cell granuloma (Shear and Speight, 2007).

Radiologically, a characteristic “blown-out” contour of the bone is seen; a feature first described by Jaffe and Lichtenstein (1942), hence the name “aneurysmal bone cyst”. ABCs appear as unilocular or multilocular (soap-bubble) radiolucencies with destruction of the bony cortices. Formation of subperiosteal new bone may be noticeable using advanced computerized tomography (CT) imaging. Associated root resorption and tooth displacement may occur (Shear and Speight, 2007).

1.5. Radiological differential diagnoses of jaw cysts

Certain lesions may mimic unilocular or multilocular jaw cysts radiologically, sometimes causing a diagnostic dilemma. Examples include ameloblastoma (unilocular or multilocular), odontogenic myxoma, ameloblastic fibroma, odontogenic fibroma and multiple myeloma (Devenney-Cakir et al, 2011).

Stafne cysts are lingual bony depressions of the mandible which may also mimic jaw cysts. They usually present in the 3rd molar region as well defined unilocular radiolucencies below the inferior alveolar canal. Rarely some variants may occur more anteriorly, in the premolar region of the jaws. No surgical intervention is usually needed (Sisman et al, 2010).

1.6. Diagnosis of jaw cysts

Diagnosis of jaw cysts is typically made by evaluation of the clinical features, histological investigation of the epithelial lining if present, and accurate radiological assessment (Weber et al, 2003). There are situations, however, whereby histological

misdiagnoses may occur. As in the case reported by White and Pharoah in 2009, where a large radicular cyst infiltrating the maxillary antrum began filling in with new bone and was as a result diagnosed as a benign fibro-osseous lesion. However, radiographic evaluation demonstrated a peripheral, rather than central bone-forming pattern, and was able to exclude a fibro-osseous lesion.

A residual cyst may be confused histologically as a developmental cyst, since its epithelial lining becomes thin and regular once their source of inflammation has been removed. Clinical and radiological correlation will confirm a previous tooth extraction and will aid the diagnostic process (Martin and Speight, 2017).

The lack of an accurate clinical picture of an inflammatory collateral cyst may lead to a histological misdiagnosis as an inflamed dentigerous cyst, pericoronitis, or an inflamed expanded follicle (Shear and Speight, 2007).

Histological evaluation of the epithelial lining of dentigerous cysts may be non-specific (White and Pharoah, 2009), or have undergone mucous metaplasia further in which case the definitive diagnosis is mainly reliant on the radiological and surgical presentations of the lesion (Fowler et al, 2011).

1.6.1. Use of advanced imaging techniques in the evaluation of jaw cysts

Radiological investigation is primarily carried out by the use of intraoral and panoramic radiography.

Panoramic radiography has been in use since the 1950s, as a preliminary screening dental tool (Shah et al, 2014). It may also be used to estimate bone mineral density. It produces a flat representation of the curved surfaces of the jaws. It is, however, due to this 2-dimensional representation, subject to a considerable degree of geometric distortion and low spatial resolution of the complex cranio-facial structures. Hence, the use of advanced imaging techniques, which are 3-dimensional, may be advocated (Shah et al, 2014).

There have been several jaw cysts discovered to mimic other lesions clinically, only to be confirmed with advanced imaging (Sisman et al, 2010, Takeda, 1994). Advanced imaging techniques have been used to exclude ameloblastoma and simple bone cysts for a Stafne cyst displaying atypical features. Furthermore, these techniques have been

used to determine the presence of daughter cysts, and possible malignant transformation in OKCs (Devenney-Cakir et al, 2011).

Computerised tomography (CT) is the advanced radiological technique of choice for the investigation of most maxillofacial pathological lesions. A CT scan will show the extent of many lesions, particularly large ones, and therefore aids in treatment planning. A CT scan will also display fluid levels better than conventional radiography in the investigation of aneurysmal bone cysts (Devenney-Cakir et al, 2011). It is often difficult to distinguish between a periapical cyst and a granuloma on periapical radiographs, as superimposing structures, such as the cortical plates of bone complicate the diagnostic process (McCullough and Coulam, 1976). Moreover, the size of a periapical lesion, except when at least 2cm in diameter (and is then most likely a cyst), cannot be reliably used to determine whether the lesion is a granuloma or a cyst (Natkin et al, 1984). However, due to the different grey levels displayed by cystic content and granulomatous tissue a CT scan shows marked difference in density between these lesions (Trope et al, 1989).

The value of magnetic resonance (MR) imaging has also been affirmed, as conventional radiography, CT and histopathology may be insufficient for diagnosis in some cases; for example, in the differentiation of some ameloblastomas and OKCs from other cysts (Minami et al, 1996). MR imaging is also useful in the differentiation of an aneurysmal bone cyst from similar lesions such as the central giant cell granuloma, odontogenic myxoma, OKC and ameloblastoma.

A study by van Rensburg and colleagues (2003) reviewing twenty-one cases of OKCs using CT and MR imaging confirmed improved analysis of the actual locularity of lesions that appeared unilocular on conventional views but were, in fact, multilocular. Moreover, by adjusting the bony window settings of a CT, the authors demonstrated the perforation of bony cortices, extension to the ascending ramus, coronoid process, ethmoid sinuses, palate, and floor of the orbit.

1.6.2. Value of CBCT in the diagnosis of jaw cysts

Recently, cone-beam CT (CBCT), a modification of the conventional CT, has been used in the evaluation of several bony lesions, outlining intraosseous lesions with high

resolution (Araki et al, 2007). It allows cross-sectional imaging of lesions prior to biopsy. It similarly allows imaging of maxillary lesions, especially those extending to the sinus. Conventional radiographs are inadequate for the complex anatomy of this region (MacDonald, 2016).

A CBCT machine confers a lower radiation dose on a patient than the conventional CT, due to its use of a cone-shaped, rather than a fan-shaped beam. In fact, in a study by Li (2013), the absorbed radiation dose from a multi-slice CT is several to 100 times higher than from a CBCT. Furthermore, CBCT units are cheaper, compact, and produce a higher spatial resolution than conventional CT. Some units are capable of acquiring panoramic tomograms directly and constructing undistorted 3-dimensional (3D) images (Boeddinghaus and Whyte, 2008).

Occasionally, lesions that may not be easily detected with conventional radiography are easily diagnosed on CBCT scans. A case of a seemingly typical representation of a simple bone cyst associated with a mandibular molar on a panoramic radiograph showed destruction and perforation of the lingual and buccal cortices, and well as encroachment on the inferior alveolar canal, on the CBCT (Nikneshan and Hadian, 2015).

The surgical planning of bony lesions using CBCT to measure the lesion at different angles is valuable, as measurements in CBCT are accurate with less than 1% error, using the dry skull as gold standard. Panoramic radiographs, on the other hand, result in magnification errors, and are thus not reliable for size measurement (Ahmad et al, 2012).

The absorption of significantly higher doses of radiation, relatively higher cost of purchase of the machine and thus cost to the patient and certain limitations of the technique, are some of the factors contributing to the selective usage of advanced techniques, limited to patients who would truly benefit from them (MacKenzie et al, 1985). Different radiation doses are conferred by CBCT units available in the market. On average a CBCT machine confers 10-100 times more radiation on the patient than a standard periapical radiograph (Wenzel, 2014). Li's study (2013) compared the effective radiation doses from panoramic, lateral cephalometric and CBCT radiological techniques. The effective dose from a panoramic radiograph, lateral cephalometric and

CBCT examination was 22.0μSv, 4.5μSv, and 61-134μSv respectively. A wide range of effective radiation doses was also noted by Ludlow and colleagues (2006) and Pauwels and colleagues (2012) when evaluating 8 and 14 different units respectively. A wide range of 19μSv-1073μSv was for different examinations, or different techniques in the same units. The use of a thyroid collar and leaded glasses has thus been advocated for radiation protection (Li, 2013).

Another drawback to using CBCT is the appearance of artefacts due to mechanical errors in the reconstruction of lesions. These may lead to errors in interpretation, for instance when an acceptable root filling appears inadequate in a CBCT scan (Schulze et al, 2011). Beam-hardening artefacts such as high-density structures like enamel, as well as scatter radiation, may affect image accuracy and hence limit imaging of soft tissues. CBCT is thus not of much value in the investigation of soft tissues. CBCT, unlike panoramic radiography, may also not be used for estimation of bone density (Shah et al, 2014).

1.6.3. Comparative literature analysis

The value of panoramic radiography and CBCT have been compared in several studies. In the investigation of pain in the lower right molar region of a 27-year-old patient, panoramic radiography indicated the fusion of a supernumerary tooth with a permanent 3rd molar, associated with a dilated follicular space. The panoramic view, however, only provided information in the mesio-distal plane, and was insufficient in making a proper diagnosis. CBCT, on the other hand, indicated the presence of a fused supernumerary tooth on the lingual aspect of the wisdom tooth, as well as a cystic lesion present in the peri-radicular region. An axial view of the CBCT also revealed perforations of the cystic lesion on the buccal and lingual borders of the compact bone. An additional incidental finding noted on the sagittal CBCT view was the presence of the retromolar canal, an anatomic variation, which is significant for surgical management. This cyst was confirmed histologically as a paradental cyst. Fusion of teeth is rare in mandibular molars, and this case, including the association with the retromolar canal, is likely the first of such to be reported in literature (Ozcan et al, 2016).

In the case of a patient with a dentigerous cyst of expressive dimensions in the body of the mandible, Deana and Alves (2017) concluded that CBCT provides greater accuracy

than panoramic radiography in surgical treatment planning, as panoramic radiographs, although routinely used, often produce image overlaps. The 28-year-old patient presented with a complaint of increased volume in the vestibular region and slight discomfort in the mandibular left region while eating. Data from a CBCT scan revealed an extensive hypodense image in the region of the missing second molar, and resorption of the adjacent root. Surgical management of the lesion was based on this data.

An earlier study by Liao et al (2012) concluded that CBCT is of greater benefit than panoramic and periapical radiography in the diagnosis and surgical management of jaw cysts. Twenty-five patients with jaw cysts were examined using both panoramic radiography and CBCT. Information revealing the 3-dimensional location, cystic wall, and relationship of the cyst to adjacent teeth and other important anatomical structures, relevant in the surgical operation of the cyst, were provided by CBCT. Small calcifications in cysts are also more easily identified on CBCT than panoramic radiography (Kumar et al, 2015).

Sekerci et al, in 2013, reported two cases, whereby panoramic misdiagnoses had been made, when in fact, these were simply anatomical variations of the maxillary sinus. The roots of maxillary first molars often lie in close proximity to, and may project into the floor of the sinus. Thin folds of cortical bone, which appear as radiopaque lines, often traverse the image of the sinus. The sinus may also extend into the alveolar process, in variable degrees. This may therefore, occasionally cause a confusing diagnostic picture. In the first case, a 25-year-old man had presented for a routine dental examination. A periapical radiolucency related to an upper right first molar with a poor root filling had been noted by his general practitioner on a panoramic radiograph. The well-circumscribed radiopaque border, coupled with the fact that this was the only non-vital tooth in the region, resulted in a provisional diagnosis of a periapical cyst. After several months' follow-up of a retreated root canal, and no resolution of the "lesion", a CBCT scan was done to ascertain the exact position of the pathology. On the scan, the border of the maxillary sinus was found to extend, but not involve the roots of the suspected tooth. A final diagnosis of an anatomical variation of the sinus was thus made. In the second case, a unilocular radiolucency with sclerotic borders associated with a

maxillary second premolar and first molar also appeared on panoramic radiography to be a radicular cyst. All the teeth in the region, in this case, were vital following vitality tests. CBCT also confirmed this “lesion” as an anatomical variation of the maxillary sinus.

In a retrospective study to evaluate whether CBCT imaging revealed any additional surgically relevant detail or had any significant impact in surgical planning of lesions, records of patients with panoramic radiographs and CBCT scans over 4 years, were examined. Although CBCT revealed significantly more surgically-relevant information, surgical strategies had not been influenced to any major extent by 3-dimensional imaging. The authors decided that further studies were necessary to define these surgical indications in detail (Wolff et al, 2016).

The effective doses from two different CBCT machines, under child and adult exposure conditions were, however, calculated to be 67 and 21 times greater than from panoramic radiography from a study evaluating the effective doses of both techniques, using dose area product (Shin et al, 2014). The authors therefore suggested that the use of CBCT be limited to cases for which its use is justified.

Hisatomi et al (2000) correlated the radiological and histological features of a glandular odontogenic cyst associated with an ameloblastoma. The authors found that plain radiography and axial CT views could not differentiate between the solid and cystic areas of the lesion. Although unable to characterize the cystic lesion, the CT scan and true occlusal views revealed more detail than the periapical and panoramic radiographs. MR imaging was useful in delineating the cystic from the solid areas of the lesion. Histological results were confirmatory.

In a study by Rosenberg et al (2010) evaluating the radiological and histological diagnosis of periapical cysts and granulomas, it was concluded that CBCT scans are not a reliable method of differentiating between these two lesions. Forty-five patients who had been scheduled for apicoectomies had CBCT scans taken of the same dental arch. Two independent maxillofacial radiologists assessed the scans and made provisional diagnoses using set criteria. Diagnoses of cyst, likely cyst, likely granuloma, granuloma, or other, were made for each lesion. The biopsy specimens of these lesions were assessed by two independent oral pathologists, also using set histopathological

criteria. Diagnoses of radicular cyst, granuloma, or other, were made. Although the interrater agreement between the pathologists was strong (k=0.75), there was a weak interrater agreement between the two radiologists. The accuracy of the radiologists' assessments, compared with the biopsy results, was 51% for the first radiologist, and 63% for the second. The conclusion concerning the inaccuracy of CBCT was thus made due to the inconsistency of the radiologists' report.

In a study comparing the radiographic (2- and 3- dimensional) and histologic diagnoses of periapical lesions treated with apical surgery, of which cysts were included, radiographic techniques resulted in an over-estimation of the number of cysts by 28.4% (CBCT) and 20.7% (periapical). CBCT provided only minimum agreement when correlated with the histological diagnoses. An almost perfect inter-observer agreement (94.8%) of the histological diagnoses was recorded. The authors concluded that histology be used as the gold standard (Bornstein, et al. 2015).

There are, however, recorded situations confirming the value of CBCT in determining the extent of atypical expansile cysts, such as of that of an infected dentigerous cyst associated with an impacted third molar in the maxillary sinus of a 17-year-old patient (Mamatha et al, 2014). A CBCT scan showed the extent of the cyst to involve the lateral wall of the nasal cavity, alveolar process and the orbit and was invaluable in surgical planning. The provisional radiological diagnosis was confirmed on histopathology.

In the evaluation of the accuracy, sensitivity and specificity of CBCT and histopathological diagnoses of thirty-six periapical lesions assessed by Guo and colleagues (2013), CBCT showed good to excellent accuracy in differentiating between granulomas and cysts. Three independent evaluators defined cysts based on the presence of 4 or more out of 6 radiological characteristics (location, periphery, shape, internal structure, effects on surrounding structures and perforation of the cortical plate) and a minimum of 5mm diameter for each lesion. The histopathological diagnoses of the lesions were made following root end resections, whereby biopsy specimens were taken and interpreted by a board-certified oral pathologist, without any previous knowledge of the clinical features of the lesions. Intrarater agreement was excellent for the pathologists, while intrarater agreement was good to excellent for the evaluators. Interrater agreement between the evaluators was excellent (and not caused by chance

agreement). There was a high mean overall agreement (0.77), with evaluator 1 obtaining 30/36 diagnoses (0.83), evaluator 2, 27/36 (0.75), and evaluator 3, 26/36 (0.72). Sensitivity was 0.60 for all 3 evaluators, while specificity was 0.92 for evaluator 1, 0.81 for evaluator 2, and 0.77 for evaluator 3.

In a previous similar previous study of 17 periapical lesions by Simon et al (2006), 13 out of the 17 CBCT diagnoses correlated with the histological diagnoses. The remaining 4 lesions were suspected to be inaccurately diagnosed histologically, citing that the tissue specimens may not have been fully representative of the lesions. This group of authors concluded that CBCT results may be more accurate than histological results with the added benefit of being a nonsurgical diagnostic approach.

A diagnostic challenge may arise in a situation whereby a radicular cyst may not be easily differentiated from a dentigerous cyst, usually in patients at the mixed dentition stage of life (Narang et al, 2012). At least two types of dentigerous cysts arise- those of developmental origin which occur in mature teeth, and those of inflammatory origin, which are postulated to progress from the root apex of non-vital primary teeth to the follicle of an unerupted mature tooth, usually in patients with mixed dentition (Benn and Altini, 1996). Narang et al, in 2012, investigated four cases of patients with such suspected cysts. They analysed their clinical, radiological and histological features. While two of the cysts were partly lined with reduced enamel-epithelium-like epithelium which merged with hyperplastic, non-keratinising stratified squamous epithelium and were thus confirmed as dentigerous cysts, the other two cases presented with just hyperplastic non-keratinising stratified squamous epithelium with anastomosing rete ridges and were thus indistinguishable from radicular cysts. Radiologically, these cysts were associated with non-vital deciduous teeth with discontinuous lamina dura, but the underlying impacted teeth also showed a dilated follicular space attached at the cemento-enamel junction. They were thus also indistinguishable radiologically. As dentigerous cysts may progress later to ameloblastoma, various radiological views will therefore need to be taken to ascertain the proper diagnosis of the cyst. Radicular cysts from primary teeth are rare, but may arise. The clinical history will, in such cases, also be of paramount importance, A history of a carious or root-treated deciduous tooth, and

radiological discontinuation of the lamina dura or a large radiolucency in a patient at a tender age, will favour the diagnosis of a radicular cyst.

1.7. Rationale for the study

The importance of accurate radiological assessment of lesions cannot be overemphasized in the diagnosis and treatment planning of jaw cysts. The possibility of occasionally arriving at a misleading histological conclusion has also been considered. Several studies on the correlation of the radiological and histological diagnoses of individual lesions have led to conflicting conclusions on the actual value, especially of advanced radiological investigations, in the diagnosis of cysts (Hisatomi et al, 2000; Rosenberg et al, 2010; Bornstein et al, 2015; Mamatha et al, 2014; Guo et al, 2013; Simon et al, 2006). The outcome of this study in determining the predictive accuracy of diagnosis of jaw cysts using both plain and advanced imaging techniques, puts forward another opinion from the perspective of the typical dentist faced with this ongoing diagnostic challenge in a South African setting.

CBCT scans may therefore be sufficiently predictive diagnostic tools. If so, adequate education of general dentists and surgeons on the correct interpretation of scans and observation of significant additional features is essential. This will invariably improve treatment outcomes.

1.8. Aim of the study

The aim of the study is to assess the radiological features of histologically proven cases of jaw cysts in order to determine whether radiological features seen on panoramic and/or CBCT imaging are accurately predictive of the type of cyst diagnosed histologically.

1.9. Objectives of the study

The following objectives will be defined, in order to achieve this aim:

- Identification of the radiological features of jaw cysts as seen on panoramic radiographs and CBCT scans, and the provision of a radiological diagnosis based on the findings.

- Assessment of whether CBCT scans provide more diagnostic detail than panoramic radiographs.
- Correlation of the accuracy of the provisional radiological diagnosis with the definitive histological diagnosis.

Chapter 1 explained the rationale, aim and specific objectives of this study. The following chapter deals with the methodology and data collection procedures.

CHAPTER 2

2. MATERIALS AND METHODOLOGY

2.1. Study Design

A retrospective quantitative design was used for this study.

2.2. Study Site

Radiology records of patients used for this study were extracted from the radiology section of the Wits Oral Health Centre, Johannesburg. Histological records of the same patients were obtained from the Department of Oral Pathology at the University of the Witwatersrand, Johannesburg, South Africa.

2.3. Sampling and Sample Size

The starting date of the research was March 2011, coinciding with the period when CBCT was introduced as a diagnostic tool at the hospital. The end date of the search was April 2017 in an attempt to acquire sufficient cases for study.

A total number of 64 patients referred to the radiology section for CBCT investigations had radiologically-suspected jaw cysts, and also had both CBCT and panoramic radiographs available.

Only 35 out of these 64 patients had histological diagnoses recorded from tissue samples investigated by the Oral Pathology department, as well as both panoramic and CBCT radiographs of good diagnostic quality. These 35 samples were used for analysis in this study.

2.4. Inclusion and Exclusion Criteria

Included in the study were

- Patients of all ages and both sexes
- Patients with available panoramic radiographs, CBCT scans and histological investigations

Excluded from the study were

- Patients with inconclusive histological diagnoses, possibly due to insufficient tissue samples
- Lesions diagnosed radiologically as cystic lesions (for example unicystic ameloblastoma), and not categorized as jaw cysts under the latest WHO classification (2017)

2.5. Data Collection

Radiology

Records of all patients referred to the radiology section of the Wits Oral Health Centre within the study period were examined, and details of patients initially suspected of having jaw cysts were extracted. Differential diagnoses searched for included diagnoses of specific cysts, patients vaguely diagnosed with “jaw cysts”, “swellings”, “pathologies”, “lesions” or other non-specific diagnoses.

A patient data form (Appendix two) was used to record radiological features noted first on the panoramic radiograph followed by careful manipulation of the tangential, cross-sectional and axial views of the CBCT scan of each patient. The Sirona dental systems GmbH CBCT unit, made in Germany, was used for this study (Model no: 6308923 D3437. Manufactured in December 2010).

Radiological criteria assessed for each patient included locularity of the lesion, nature of margins, site/distribution of the lesion, size of the lesion in three dimensions (mesio-distal, supero-inferior, and bucco-lingual), presence or absence of root resorption or tooth displacement, presence or absence of cortical plate expansion, involvement of adjacent structures such as the maxillary antrum and inferior alveolar canal, and presence of any other features such as calcifications.

The assessments were made by two observers: the principal investigator, a general dentist with 14 years’ experience in clinical dentistry, and a professor with 30 years’ experience in oral and maxillofacial radiology. Diagnoses were made by correlating the observed radiographic features with the typical radiological features of jaw cysts as supported by literature.

For each patient, both panoramic and CBCT diagnoses were made individually by each observer and thereafter both together.

Histology

All histological records of patients reported by the Department of Oral Pathology at the University of the Witwatersrand from March 2011 till April 2017 were searched for and examined. Data for all patients diagnosed with jaw cysts were extracted.

Data could be compiled only for patients who had all of panoramic, CBCT and histological records. All available clinical information for such patients were recorded, including age, gender, duration of the lesion, presence or absence of pain, extraoral or intraoral swellings, any history of trauma, recurrence and any other significant information such as mobility of teeth and history of a previous extraction.

The histological diagnoses and any significant comments made by the pathologists were then recorded. Tables 2.1 and 2.2 summarise the typical radiological and clinical features of various jaw cysts.

Table 2.1. Summary of typical radiological features of various cysts

Cyst	Site/ tooth region	Locularity: Uni/Multi.	Root Resorption	Tooth Displacement	Cortical Expansion	Specific features
RadC*	Max* ant*/ any site	Uni	Sometimes	Sometimes	Sometimes	Apex of carious / non-vital tooth.
ResC*	Any site	Uni	Sometimes	Sometimes	Sometimes	Missing/extracted tooth
PC*	Man* 38/48	Uni	No	No	Seldom	Fuzzy outline
MBBC*	Man37/46/47	Uni	Seldom	Sometimes	Buccal	Buccal cusp tilting
DC*	Man 38/48	Uni	Frequent	Seldom	Frequent	CEJ attachment. Impacted tooth.
EC*	Primary teeth, permanent molars	Uni	x*	x	X	Soft tissue shadow
OKC*	Man post*/ramus	Uni/Multi	Seldom	Sometimes	Seldom/ Slight	M-D growth. Root Scalloping.
LPC*	Man premolars	Uni	Seldom	Seldom	Sometimes	Between apex and cervical margin. <1cm
BOC*	Man post	Uni/Multi	Sometimes	Sometimes	Sometimes	Extensive
GOC*	Man ant	Uni/Multi	Sometimes	Sometimes	Frequent	Extensive
COC*	Max/Man	Uni/Multi	Frequent	Frequent	Frequent	Opacities. Unerupted tooth. Odontome
OOC*	Man post	Uni/Multi	Seldom	Seldom	Frequent	Lingual expansion
NPDC*	Max ant	Uni	Sometimes	Frequent	Sometimes	Heart-shaped on pan*. Splayed roots
SBC*	Man post	Uni/Multi	Sometimes	Seldom	Seldom	Root scalloping
ABC*	Man post	Uni/Multi	Sometime	Sometimes	Frequent	Soap bubble. Extensive.

Key *: Max=Maxilla. Man=Mandible. Ant=Anterior. Post=Posterior. Pan=Panoramic radiographs. X= non-specific. RadC= Radicular Cyst. ResC= Residual Cyst. PC=Paradental Cyst. MBBC= Mandibular Buccal Bifurcation Cyst. DC= Dentigerous Cyst. EC= Eruption Cyst. LPC= Lateral Periodontal Cyst. BOC= Botryoid Odontogenic Cyst. SBC= Solitary bone Cyst. ABC= Aneurysmal Bone Cyst. M-D= Mesio-Distal

Table 2.2. Summary of typical clinical features of various cysts

Cyst	Age range	Gender	Specific clinical features
RadC	3rd-5th decade	x	Non-vital, necrotic tooth due to caries or trauma. Maybe discoloured tooth. Usually permanent tooth. Discharging sinus may be present. Swelling, if present, may be fluctuant.
ResC	Any age	x	History of extraction of non-vital tooth or enucleation of cyst.
PC	3rd decade	Male	Lateral to partially-erupted mandibular wisdom tooth. History of recurrent or persistent pericoronitis. May be bilateral
MBBC	6-11 years old	x	Rare. More severe symptoms than paradental cyst, such as facial abscess, Buccal periodontium. Buccal cusp tilting with root apex wedged in lingual cortex.
DC	3rd-4th decade	x	Impacted, unerupted tooth, especially wisdom teeth and maxillary canines. May be a supernumerary tooth. Sometimes delayed eruption. Slow-growing. May be bilateral as part of a syndrome or isolated cases. Rarely, paraesthesia.
EC	Young patients	x	Soft, fluctuant, smooth swelling; bluish or normal colour. Often painless. May be multiple. Often delayed eruption of teeth.
OKC	2nd-3rd decade		Locally aggressive. May grow very large, even causing pathologic fractures before being noticed clinically. High recurrence rate. May be part of Gorlin-Goltz syndrome.
LPC	4th-7th decade	x	Rare. Vital teeth. Usually <1cm.
BOC	5th-7th decade	x	Maybe expansile. Tendency to recur if improperly treated
GC*-adult	Any decade	F*>M*	Soft. Painless. Slow-growing. Buccal/attached gingivae. <1cm
GC-infant	<3 months	x	Small. White/ cream coloured lesion on alveolar ridge.
GOC	Wide	x	Rare. Aggressive. Extensive swelling. Tendency to recur.
COC	Wide	x	Rare. Extensive swelling.
OOC	Young adults	M	Extensive lingual expansion, and no tendency to recur, unlike OKC.
NPDC	3rd-6th decade	M	Black individuals. Displacement of teeth often apparent
SBC	2nd decade	x	Non-distinct
ABC	Children	x	Aggressive, localized swelling. Sometimes malocclusion

Key: M=Male. F= Female. GC= Gingival Cyst.

These features were all considered in making a final diagnosis.

2.6. Ethics

Ethical clearance to proceed with this study was approved unconditionally by the Human Research Ethics Committee (Medical) of the University of the Witwatersrand with a clearance certificate number: M170630 (Appendix three).

Permission for the collection and use of patients' data was granted by the Chief Executive Officer of the Wits Oral Health Centre, Johannesburg.

Permission was also granted by the heads of the Departments of General Dental Practice and Oral Pathology, for the use of radiology and histology records, respectively.

Patients' names, dates of birth and other identifiable factors were not included in this study.

2.7. Data analysis

Measures of central tendencies (averages and percentages) of the radiological features were calculated in order to correctly define and characterise these cysts. Inter-rater agreement of radiological observers was calculated using the Cohen kappa statistical method.

Sensitivity (ability to correctly diagnose cases) and specificity (ability to correctly rule out a disease) tests of both radiological techniques were done. This was in order to determine if CBCT scans provide more diagnostic detail than panoramic radiographs.

Sensitivity (true-positive) and specificity (true-negative) values were calculated as (Maxim et al, 2014):

$$\text{Sensitivity} = \frac{\text{number of true-positives}}{\text{number of true positives + number of false negatives}}$$

$$\text{Specificity} = \frac{\text{number of true-negatives}}{\text{number of true negatives + number of false positives}}$$

A measure of agreement to correlate the accuracy of the provisional radiological diagnoses with the definitive histological diagnoses was calculated, using the histological diagnoses as the gold standard.

The Cohen kappa (k) statistical method was employed to measure the level of agreement (McHugh, 2012).

The formula used was: $$k = \frac{Pr(a) - Pr(e)}{1 - Pr(e)}$$

where Pr(a)= actual observed agreement. Pr(e)= Chance agreement

The Pr(e) was calculated as:

$$Pr(e) = \frac{\left(\frac{cm1 \; x \; rm1}{n}\right) + \left(\frac{cm2 \; x \; rm2}{n}\right)}{n}$$

where cm1= column 1 marginal

cm2= column 2 marginal

rm1= row 1 marginal

rm2= row 2 marginal

n= number of diagnoses made

The level of significance of the techniques was set at p-value <0.05.

Chapter 2 described the data collection and collation procedure, outcome measures and the statistical tests undertaken for this study. The following chapter presents the results obtained from this study.

CHAPTER 3

3. RESULTS

3.1. Definition and characterisation of the jaw cysts

3.1.1. Patient demographics

Out of 64 patients with radiologically-suspected jaw cysts using both panoramic and CBCT radiography records from the radiology division of the Wits Oral Health Centre, only 35 patients (55%) had histological diagnoses documented at the Department of Oral Pathology of the University of the Witwatersrand.

Table 3.1 is a summary of the patient demographics recorded in the study.

Table 3.1. Patient demographics

Patient demographics		
Age	**Mean**	**Standard Deviation**
All cysts	38.7	17.0
Gender	**n***	**%**
Male	22	62.9
Female	13	37.1

n= number of patients

The mean age of patients included in the study was 38.7yrs. The youngest patient was 11yrs old and the oldest patient 73yrs old. There was a significant male predilection with 62.9% of patients being male, while 37.1% of patients were female.

3.1.2. Radiological features of the cysts

Table 3.2 is a summary of the site/distribution of the cysts recorded in the study.

Table 3.2. Site/distribution of the jaw cysts per patient and per cyst

Radiological feature	Description	N	%
Patients with single cysts Patients with multiple cysts (no of cysts in brackets). Total number of patients: 35 Total number of cysts: 38.	Maxilla or Mandible	31	88.6
	Maxilla only (2)	1	2.9
	Mandible only (2)	2	5.7
	Maxilla and Mandible (2)	1	2.9
Site (per patient) Number of patients=35	Maxilla only	19	54.3
	Mandible only	15	42.9
	Maxilla and Mandible	1	2.9
Site and exact location (per cyst) Number of cysts = 38	Maxilla: Anterior	18	47.4
	Maxilla: Posterior	3	7.9
	Mandible: Anterior	1	2.6
	Mandible: Middle	1	2.6
	Mandible: Posterior	10	26.3
	Mandible Ramus	5	13.2

Slightly more patients (54.3%) presented with maxillary cysts, while 42.9% presented with mandibular cysts. While most patients presented with a single cyst each, four presented with multiple cysts; two patients presenting with bilateral mandibular cysts, one with multiple maxillary cysts and one patient with cysts in both the mandible and the maxilla. This resulted in a total of 38 cysts in these 35 patients. Although these patients presented with multiple cysts, one diagnosis was made for each panoramic and CBCT view per patient, as these patients all presented with multiples of the same cyst type.

Eighty-six percent of maxillary cysts occurred in the anterior region (mesial to the 1st premolars), while 14.3% occurred in the posterior region (distal to the 2nd premolars). In contrast, 58.8% of mandibular cysts occurred in the posterior region (distal to the 2nd premolars), 29.4% involved the ramus, 5.9% occurred in the anterior region (mesial to the 1st premolars), and 5.9% in the middle of the body of the mandible (premolar region).

Table 3.3 is a summary of the general radiological features of the cysts in the study.

Table 3.3. General radiological features of the analysed jaw cysts (N=38)

Radiological feature	Description	N	%
Locularity	Unilocular	27	71.0
	Multilocular	11	29.0
Cyst margins	Well-defined	32	84.2
	Partly defined	1	2.6
	Fuzzy	1	2.6
	Unclear	4	10.5
Root resorption	Present	2	5.3
	Absent	33	86.8
	Unclear	3	7.9
Tooth displacement	Present	12	31.6
	Absent	25	65.8
	Unclear	1	2.6
Cortical expansion	Present	20	52.6
	Absent	18	47.4
Specific plate expansion (n=20)	Bucco-lingual	12	60.0
	Buccal only	2	10.0
	Lingual only	5	25.0
	Nasal floor	1	5.0
Involvement of IDN/antrum	Present	4	10.5
	Absent	33	86.8
	Unclear	1	2.6

Seventy-one percent of the cysts appeared unilocular, while 29% appeared multilocular. Of these cysts, 84.2% presented with well-defined margins, 2.6% with a fuzzy outline, 10.5% had unclear margins, while 1 cyst was well-defined in parts and seemed to lose cortication in other regions.

No root resorption was recorded in 86.8% of the cysts. Some degree of root resorption was observed in 5.3% of the cysts, and while in 7.9% of patients, root resorption was inconclusive. Tooth displacement was recorded in 31.6% of patients. Of these, half were diagnosed radiologically as nasopalatine duct cysts. Maxillary antrum involvement was seen in 9.5% of maxillary cysts, while 11.8% of mandibular cysts encroached on the inferior alveolar canal. Calcifications were not noted on any of the images analysed.

Some degree of cortical expansion was displayed in 52.6% of the cysts. Majority of the cysts displayed bucco-lingual expansion, 25% and 10% displayed lingual and buccal expansion, respectively. expansion. One cyst displaced the nasal floor.

Tables 3.4 and 3.5 describe the specific features of the most prevalent and least prevalent CBCT-diagnosed cysts in the study.

Table 3.4. Specific features of the most prevalent CBCT-diagnosed jaw cysts

		Odontogenic keratocyst (N=16)		Dentigerous cyst (N=8)		Nasopalatine duct cyst (N=6)	
		N	%	N	%	N	%
Locularity	Unilocular	6	37.5	8	100	6	100
	Multilocular	10	62.5	-	-	-	-
Root resorption	Absent	16	100	7	87.5		
	Present	-	-	1	12.5	5	83.3
	Unclear	-	-	-	-	1	16.7
Tooth displacement	Present	3	18.8	-	-	6	100
	Absent	12	75	8	100	-	-
	Unclear	1	6.3	-	-	-	-
Cortical expansion	Present	8	50	3	37.5	5	83.3
	Absent	8	50	5	62.5	1	16.7
Specific plate expansion	Bucco-lingual	7	43.8	1	12.5	2	33.3
	Buccal only	1	6.3	1	12.5	-	-
	Lingual only	-	-	1	12.5	3	50
	Nasal floor	-	-	-	-	-	-
	Not reported	8	50	-	-	1	16.7
Involvement of IDN/antrum	Present	2	12.5	-	-	1	16.7
	Absent	14	87.5	8	100	5	83.3

OKCs were the most frequently diagnosed jaw cysts (45.7%), half of them presenting as multilocular radiolucencies.

Table 3.5. Specific features of the least prevalent CBCT-diagnosed jaw cysts

Feature		Radicular cyst (N=3)		Paradental cyst (N=1)		Aneurysmal bone cyst (N=1)	
		N	%	N	%	N	%
Locularity	Unilocular	3	100	1	100	-	
	Multilocular	-	-	-	-	1	100
Root resorption	Absent	3	100	1	100	-	-
	Present	-	-	-	-	1	100
	Unclear	-	-	-	-	-	-
Tooth displacement	Present	1	33.3	-	-	1	100
	Absent	2	66.7	1	100	-	-
	Unclear	-	-	-	-	-	
Cortical expansion	Present	1	33.3	-	-	1	100
	Absent	2	66.7	1	100	-	-
Specific plate expansion	Bucco-lingual	-	-	-	-	1	100
	Buccal only	-	-	-	-	-	-
	Lingual only	1	100	-	-	-	-
	Nasal floor	-	-	-	-	-	-
	Not reported	-	-	-	-	-	-
Involvement of IDN/antrum	Present	1	33.3	-	-	-	-
	Absent	2	66.7	1	100	1	100

Radicular cyst, although documented as the most frequently-occurring jaw cyst (Shear and Speight, 2007), was only diagnosed in 8.6% of the CBCT scans.

Figures 3.1 and 3.2 illustrate the prevalence of jaw cysts in the study based on panoramic and CBCT techniques respectively. The most prevalent jaw cyst by radiological diagnosis, using both panoramic and CBCT techniques was OKC (48.6% on panoramic radiographs; 45.7% on CBCT), followed by dentigerous (25.7%; 22.9%), and nasopalatine duct cysts (17.1%; 17.1%).

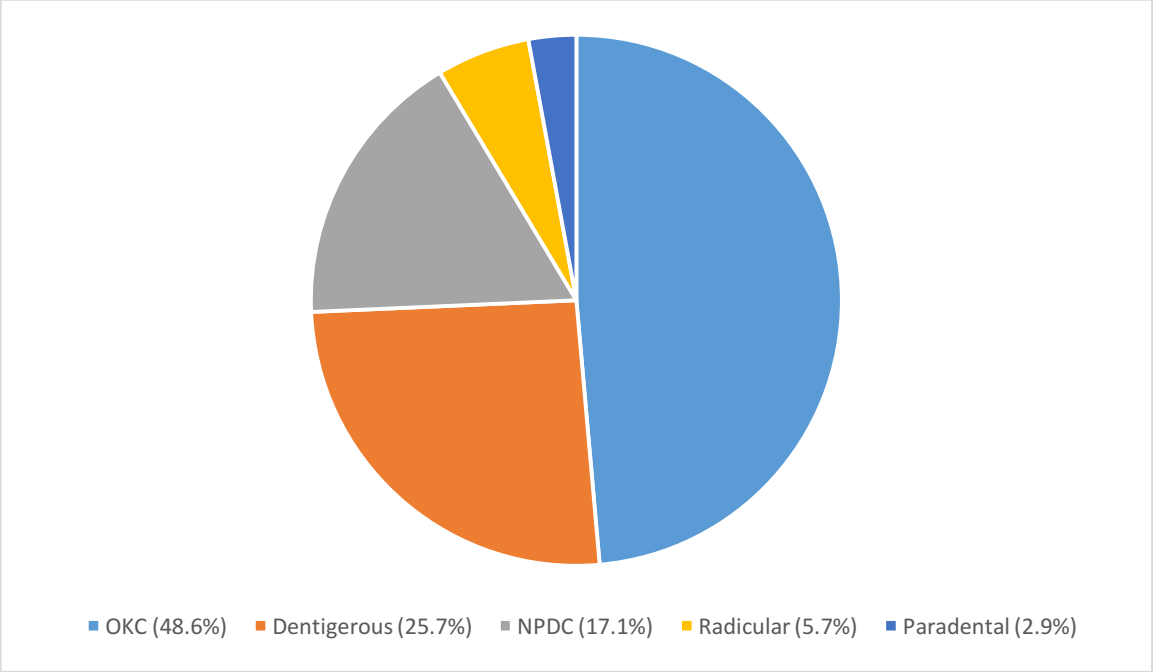

Figure 3.1. Schematic representation of the prevalence of jaw cysts based on panoramic radiographic diagnoses

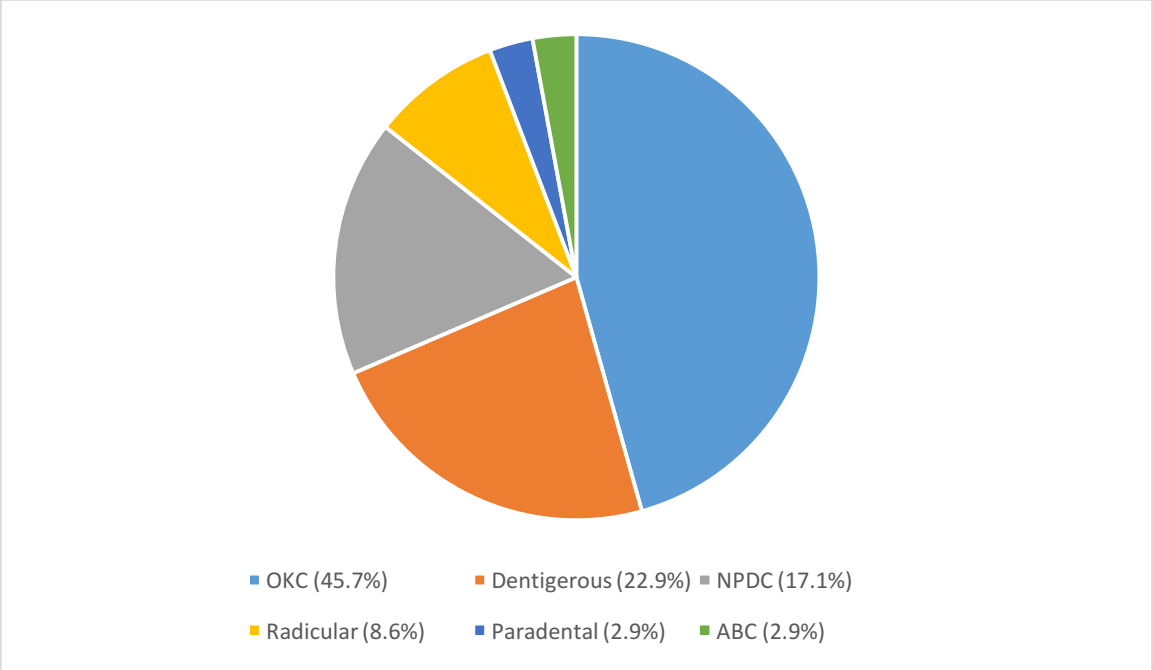

Figure 3.2.Schematic representation of the prevalence of jaw cysts based on CBCT radiographic diagnoses

Table 3.6 is a summary of the average sizes of the cysts diagnosed on CBCT.

Table 3.6. Average sizes of the CBCT-diagnosed jaw cysts

CBCT diagnosis	Mesio-Distal (mm)	Supero-Inferior (mm)	Bucco-lingual (mm)
Odontogenic keratocyst	38.86	24.26	16.68
Dentigerous cyst	26.31	20.25	16.84
Nasopalatine duct cyst	31.11	27.30	25.83
Radicular cyst	22.76	20.69	19.75
Paradental cyst	17.44	18.90	12.09
Aneurysmal bone cyst	28.40	16.92	15.31

The average size of maxillary cysts was 29.21mm in the mesio-distal dimension, 30.14mm in the supero-inferior dimension and 24.38mm in the bucco-lingual dimension. The average size of mandibular cysts on the other hand was 36.12mm in the mesio-distal dimension, 18.9mm in the supero-inferior dimension and 12.33mm in the bucco-lingual dimension.

3.1.3. Clinical features of the cysts

Clinical data available together with the histological diagnoses of the patients used in the study were compiled to reflect the total picture of the diagnosed cysts.

The histological diagnoses were made on both clinical and radiological information available. Tables 3.7 and 3.8 summarise the clinical features associated with the most prevalent and least prevalent cysts in the study.

Table 3.7.Clinical features of the most prevalent histologically-diagnosed jaw cysts

Feature		Odontogenic keratocyst (28.6%). n=10 Average age: 35.9 Gender ratio (M: F): 1:1		Dentigerous cyst (25.7%). n=9 Average age: 40.3 Gender ratio (M: F): 7:2		Nasopalatine duct cyst (22.9%). n=8 Average age: 44 Gender ratio (M: F): 3:1	
		N	**%**	**N**	**%**	**N**	**%**
Pain	Present	4	40	6	66.7	-	-
	Absent	2	20	2	22.2	6	75
	Not recorded	4	40	1	11.1	2	25
EO swelling	Present	-	-	2	22.2	6	75
	Absent	5	50	2	22.2	-	-
	Not recorded	5	50	5	55.6	2	25
IO swelling	Present	-		3	33.3	6	75
	Absent	4	40	3	33.3	-	-
	Not recorded	6	60	3	33.3	2	25
History of trauma	Present	-	-	-	-		
	Absent	10	100	9	100	8	100
	Not recorded	-	-	-	-	-	-

Key: EO swelling= Extra-oral swelling. IO swelling= Intraoral swelling

The most prevalent jaw cyst histologically was also OKC (28.6%). Clinically, majority of the diagnosed cysts presented with their typical features as supported by literature. There was a significant male predilection for dentigerous cysts with a male: female ratio of 7:2.

Table 3.8. Clinical features of the least prevalent histologically-diagnosed jaw cysts

Feature		Radicular cyst (N=5) **Age:** 29.4 years **Gender M: F-** 4:1		Residual cyst (N=2) **Average age:** 47.5 years **Gender ratio (M: F):** 0:2		Glandular odontogenic cyst (N=1)	
		N	**%**	**N**	**%**	**N**	**%**
Pain	Present	3	60	-	-	1	100
	Absent	1	20	-	-	-	-
	Not recorded	1	20	2	100	-	-
EO swelling	Present	4	80	-	-	1	100
	Absent	-	-	-	-	-	-
	Not recorded	1	20	2	100	-	-
IO swelling	Present	4	80	-	-	1	100
	Absent	-	-	-	-	-	-
	Not recorded	1	20	2	100	-	-
History of trauma	Present	1	20	-	-	-	-
	Absent	1	20	2	100	-	-
	Not recorded	3	60	-	-	1	100

Key: EO swelling= Extra-oral swelling. IO swelling= Intraoral swelling. M= male. F= female.

Forty percent of patients reported the presence of pain while 31.4% reported no pain. The presence or absence of pain was not recorded for the remaining 28.6%. In 37.1%, there was an obvious clinical extra-oral swelling, whereas there was no apparent extra-oral swelling in 20% of patients. However, this information was not recorded in the remaining 42.9%. Similarly, intraoral swelling was noted in 40% of patients, and absent in 17.1%. No information was recorded for the remaining 42.9% of patients. Association of the cyst with trauma was reported in 2.9% of patients. There was no recorded history of recurrence in any of the cysts.

Figure 3.3 illustrates the prevalence of the cysts based on histological diagnoses.

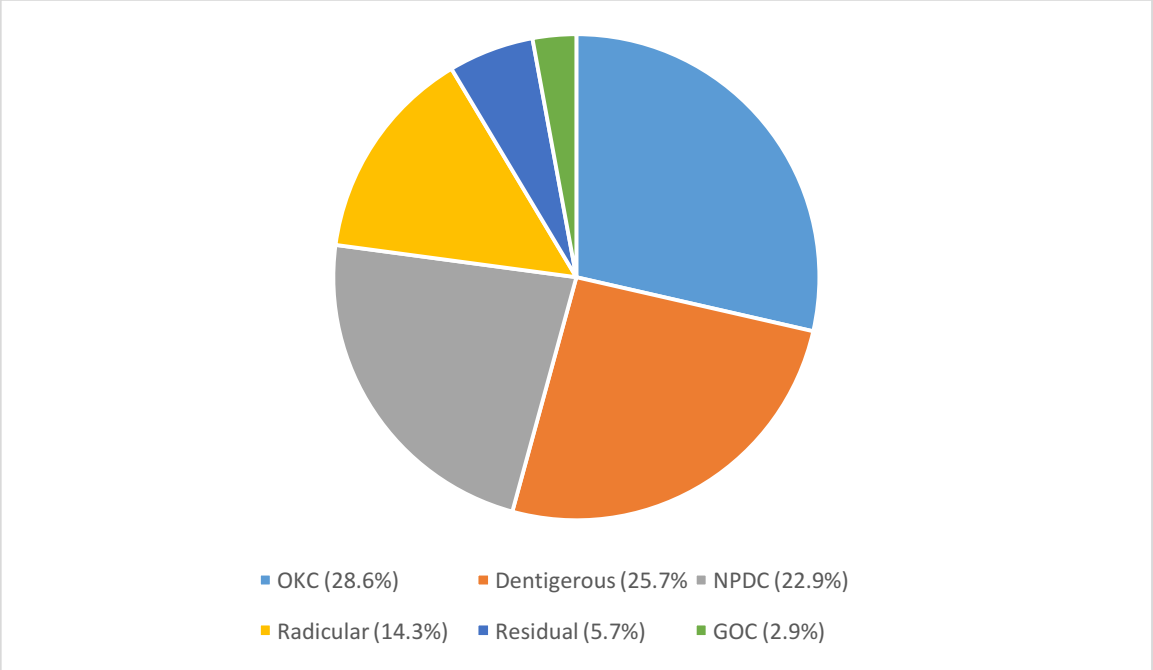

Figure 3.3.Schematic representation of the prevalence of jaw cysts based on histological diagnoses

Table 3.9 is a summary of the panoramic, CBCT and histological diagnoses of all the jaw cysts analysed.

Table 3.9.Panoramic, CBCT and histological diagnoses of the analysed jaw cysts

	Panoramic		CBCT		Histology	
Cyst	**n**	**%**	**n**	**%**	**n**	**%**
OKC	17	48.6	16	45.7	10	28.6
Dentigerous	9	25.7	8	22.9	9	25.7
NPDC	6	17.1	6	17.1	8	22.9
Radicular	2	5.7	3	8.6	5	14.3
Residual	-	-	-	-	2	5.7
Paradental	1	2.9	1	2.9	-	-
ABC	-	-	1	2.9	-	-
GOC	-	-	-	-	1	2.9

The prevalence of OKC was much lower on histology than was radiologically diagnosed. The prevalence of radicular cysts was also discovered to be higher than was seen on x-ray. Dentigerous cyst was the most accurately diagnosed cyst. NPDC was

under-diagnosed radiologically, whereas residual cyst was only diagnosed histologically. This lesion was diagnosed as an OKC on both panoramic radiography and CBCT. For the histological diagnosis of GOC, ABC had been diagnosed on CBCT, and a diagnosis of multilocular OKC on panoramic radiography.

3.2. Sensitivity and specificity of the radiological techniques

Table 3.10 is a summary of the sensitivity and specificity of the radiological techniques. The histological diagnosis was the gold standard.

Table 3.10. Results of sensitivity and specificity tests of panoramic and CBCT radiography

	Panoramic radiography		**CBCT technique**	
Diagnosis	Sensitivity	Specificity	Sensitivity	Specificity
Odontogenic keratocyst	50%	89.5%	62.5%	100%
Dentigerous cyst	77.8%	92.3%	87.5%	92.6%
Nasopalatine duct cyst	100%	93.1%	100%	93.1%
Radicular cyst	50%	87.9%	100%	93.8%
Residual cyst	-	94.3%	-	94.3%
Paradental cyst	-	100%	-	100%
Aneurysmal bone cyst	-	100%	-	100%
Glandular odontogenic cyst	-	97.1%	-	97.1%

Overall, CBCT scans displayed considerably superior sensitivity to jaw cysts, and also relatively greater specificity. Sensitivity analysis of CBCT to NPDC and radicular cysts was 100%, emphasising the superiority of CBCT in diagnosing these cysts. Sensitivity of CBCT in the diagnosis of OKC however, was 62.5%, therefore raising suspicions in the accuracy of diagnosis of these cysts. In comparison, however, while panoramic radiography also displayed superior sensitivity in the diagnosis of NPDC and a relatively high sensitivity in the diagnosis of dentigerous cysts, the resultant 50% sensitivity in the diagnosis of OKCs and radicular cysts suggests a hit-or-miss scenario when using panoramic radiography only to investigate these cysts.

While the specificity of CBCT for OKC, paradental cyst and aneurysmal bone cyst was 100%, specificity for all the other cysts was also high. For a general diagnosis of cysts, specificity of panoramic radiography was high.

3.3. Measure of agreement

The following kappa scores and p-values outlined in Table 3.11 were obtained by correlating the panoramic and CBCT diagnoses with histological diagnoses of the same cysts.

Table 3.11. Measure of agreement (kappa score and p-value)

	Panoramic radiography		**CBCT technique**	
Diagnosis	k	p-value	k	p-value
Odontogenic keratocyst	0.41	0.01	0.64	0.00
Dentigerous cyst	0.70	0.00	0.77	0.00
Nasopalatine duct cyst	0.82	0.00	0.82	0.00
Radicular cyst	0.22	0.14	0.72	0.00
Residual cyst	-	-	-	-
Paradental cyst	-	-	-	-
Aneurysmal bone cyst	-	-	-	-
Glandular odontogenic cyst	-	-	-	-

Key values used for this study (McHugh, 2012):

Value	Agreement	% of reliable data
0.00-0.20	None	0-4%
0.21-0.39	Minimal	4-15%
0.40-0.59	Weak	15-35%
0.60-0.79	Moderate	35-63%
0.80-0.90	Strong	64-81%
≥ 0.90	Almost perfect	82-100%

Overall, CBCT showed greater accuracy than panoramic radiography when correlated with the histological diagnoses. Both techniques displayed strong, significant accuracy in the diagnosis of nasopalatine duct cysts. CBCT (p-value=0.00) however, only resulted in a moderate agreement with the histological diagnoses in the diagnoses of all other types of cysts.

Panoramic radiography on the other hand displayed moderate significant agreement in the diagnosis of dentigerous cyst. A weak significant agreement in the diagnosis of OKC was reported. In the diagnosis of radicular cysts, however, it showed a minimal agreement which was not significant.

The interrater agreement for the radiological assessment was high at 0.93 for panoramic radiography and 0.86 for CBCT (McHugh 2012).

In the case of a mandibular cyst in the premolar region diagnosed as an aneurysmal bone cyst on CBCT but confirmed as a glandular odontogenic cyst histologically, the radiological features conformed to either type of cyst. The patient was a 37year-old female patient, and although an aneurysmal bone cyst is more common in children (Capote-Moreno et al, 2009), it could not be ruled out due to the rarity of this type of cyst and the possibility that much is yet to be known about this cyst. The cyst presented as a multilocular radiolucency with considerable cortical expansion, associated root resorption, and splaying of the roots. On CBCT, the cyst exhibited even more locularity the deeper it was examined (quasi soap-bubble appearance), suggestive of a giant cell lesion. This feature, observed during CBCT examination, led to a diagnosis different from the odontogenic keratocyst initially suspected on the panoramic radiograph, since the mesio-distal dimension of the cyst (28.41mm) was almost twice the size of the bucco-lingual dimension (15.31mm). In the histological record the patient had reported a 3-month history of a mildly-tender bony hard swelling with no other significant medical history. The reported duration was suggestive of an aggressive cyst, a characteristic which may be seen in aneurysmal bone cysts and glandular odontogenic cysts. Most importantly, as both cysts tend to recur if inappropriately managed, they are managed in a similar manner, with complete excision, possible reconstruction of the defect and periodic monitoring. Although the histological diagnosis differed from the CBCT

diagnosis, the CBCT scan nevertheless provided the most vital information about the aggressive nature of the cyst which would have informed decisions on the appropriate treatment choice, reliant on clinical behavior rather than on the definitive diagnosis. Figures 3.4, 3.5, 3.6 and 3.7 represent the panoramic, CBCT and histological representations of the cyst. On panoramic radiography, an OKC had been initially suspected. The multiple loculation seen on CBCT informed the provisional diagnosis of aneurysmal bone cyst.



Figure 3.4. Panoramic radiograph of a lesion suspected to be an odontogenic keratocyst but confirmed histologically as a glandular odontogenic cyst

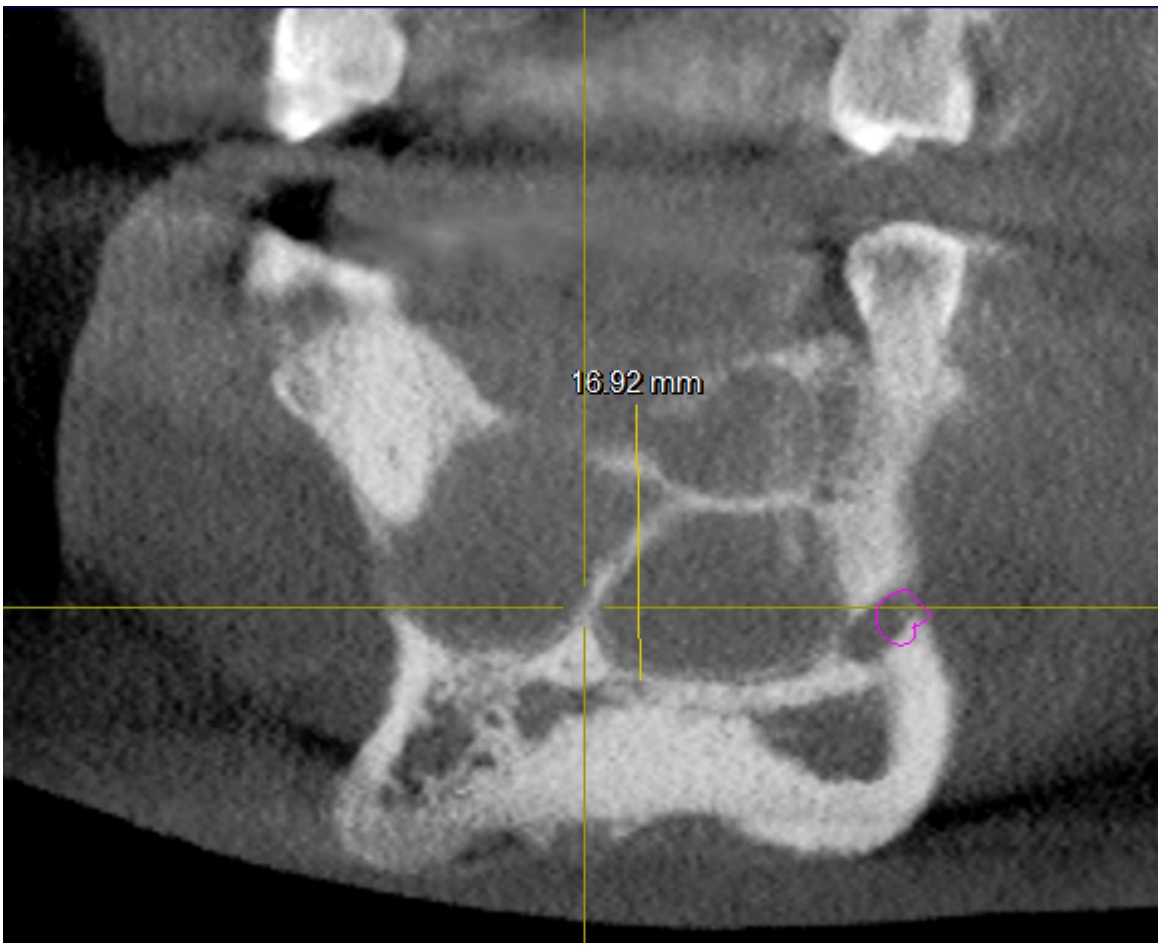

Figure 3.5. CBCT scan of a cyst suspected to be an aneurysmal bone cyst but confirmed histologically as a glandular odontogenic cyst

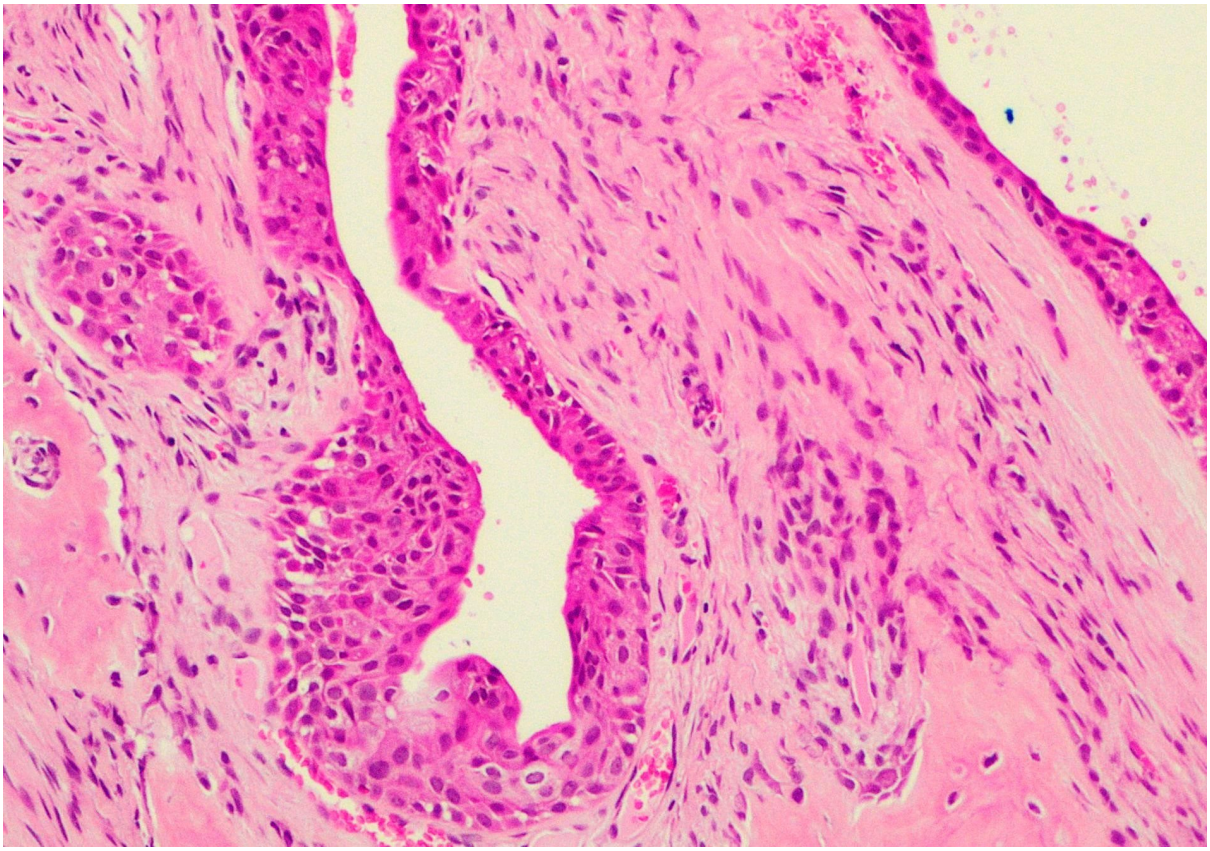

Figure 3.6. Photomicrograph of glandular odontogenic cyst (I). Showing non-keratinised stratified squamous epithelium of variable thickness. Epithelial plaques, superficial cuboidal cells and microcystic spaces are seen. (Haematoxylin-eosin stain, original magnification x 200)

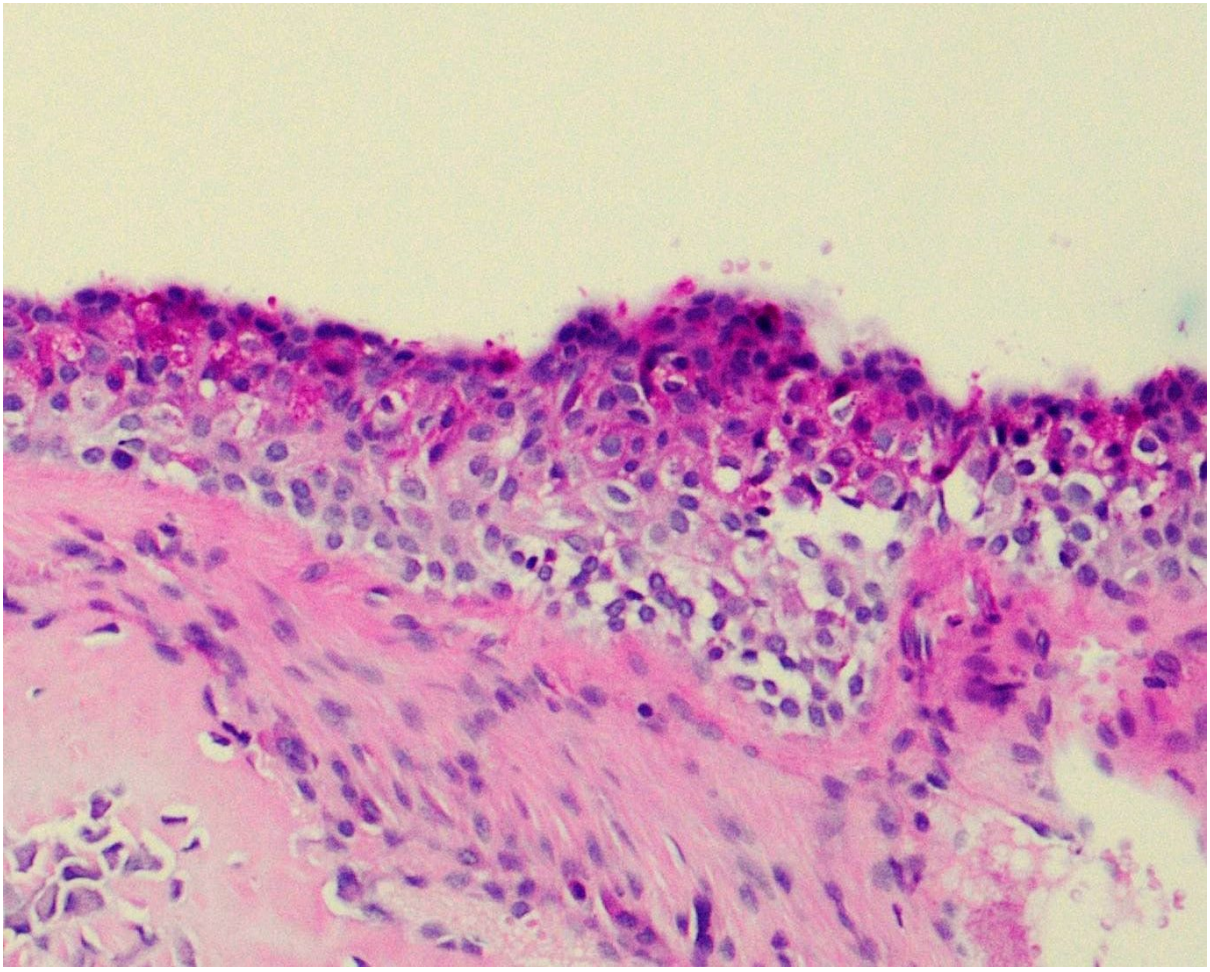

Fig 3.7. Photomicrograph of glandular odontogenic cyst (II). Periodic Acid-Schiff (PAS) with diastase (PAS-D) staining confirming mucin production in the glandular odontogenic cyst depicted in Fig 3.6. (Original magnification x 400)

The CBCT (and panoramic) diagnosis of a paradental cyst was based on the appearance of the cyst lying seemingly lateral to or enveloping an impacted, partially erupted mandibular 3rd molar but not convincingly coronal to the tooth. The fuzzy outline implied an infection suggestive of pericoronitis, which is commonly precedent to a paradental cyst, but may also be involved in an inflamed dentigerous cyst. The lack of an obvious attachment of the cystic lining to the cemento-enamel junction of the tooth favoured the provisional radiological diagnosis. The lesion was however, histologically confirmed as an inflamed dentigerous cyst.

In the radiological investigation of a cyst occurring in the anterior maxilla, a provisional diagnosis of odontogenic keratocyst was made on both panoramic and CBCT views.

The lesion was unilocular, well-corticated, though losing its cortication at some points, and did not show any obvious cortical expansion, root resorption or tooth displacement. Although there was a missing tooth around the region of the cyst, teeth in other regions of the oral cavity were also missing and the patient did not appear to have a significantly high rate of caries. The mesio-distal dimension (48.83mm) was relatively larger than that of the bucco-lingual dimension (34.28mm), and although a diagnosis of a residual cyst was considered, this cyst, in the opinion of the observers, seemed rather too large for a typical residual cyst, and was, according to set criteria, more likely to be an odontogenic keratocyst. The cyst was histologically confirmed as a residual cyst. Another cyst diagnosed as a residual cyst histologically, which was radiologically diagnosed as an odontogenic keratocyst occurred in a 28year old female who presented with a cyst in the anterior maxilla. This cyst was unilocular, with well-defined margins and minimal cortical expansion. A diagnosis of residual cyst had also been considered, but the scalloping around associated roots seemed more typical of an odontogenic keratocyst. A histological confirmation of a residual cyst was made, but on the other hand useful clinical information had also been made available, especially a history of pain and a previous extraction of a tooth at the same site.

A histological diagnosis of radicular cyst was made after an anterior maxillary cyst in a 42year old male had been radiologically diagnosed both on panoramic and CBCT as an odontogenic keratocyst. On CBCT a deeper locule had been observed, both observers having described the lesion as bilocular. This feature influenced the diagnosis. Clinical information, including a history of fluid discharge and carious teeth was available together with the biopsy specimen which, had this information been available to the radiological observers, may have led to the correct diagnosis.

A well-defined unilocular cyst in the anterior maxilla in a 27year old female was radiologically diagnosed on both panoramic and CBCT views as an odontogenic keratocyst. There was an impacted canine in the maxillary antrum, the root of which was not seen on the panoramic radiograph. The dilemma of diagnosing the cyst as either a dentigerous cyst or an odontogenic keratocyst lay mainly in determining

whether there was an attachment of the cyst lining to the cemento-enamel junction of the tooth, and the degree of root development. Although, the mesio-distal (22.97mm) and bucco-lingual (22.56mm) dimensions of the cyst were almost equal, and there was obvious buccal expansion seen on CBCT, which was more suggestive of a dentigerous cyst, the fact that no convincing attachment of the lining could be seen on CBCT and its location apical to the lateral incisor and canine, resulted in a diagnosis of odontogenic keratocyst. The cyst was histologically diagnosed as a dentigerous cyst.

A case diagnosed as an odontogenic keratocyst was a well-defined cyst with a unilocular radiolucency in the anterior region of the left maxilla, involving the central and lateral incisors and canine in a 65-year old male patient. No obvious cortical expansion was seen, and based on the location of the cyst a radiological diagnosis of odontogenic keratocyst was made both on panoramic and CBCT views. A histological diagnosis of nasopalatine duct cyst was made, with a clinical history of a root canal treatment of the associated canine with fluid discharge. Radiologically there was no suggestion that this was a nasopalatine duct cyst. The lesion did not seem to involve the contralateral central incisor and displacement of the roots of the lateral incisors and canine was observed on CBCT. In addition, the typical heart-shaped radiolucency characteristic of these cysts was absent. The clinical history, on the other hand, would rather have suggested a radicular cyst. This might, therefore have been an interesting case of an atypical nasopalatine duct cyst.

Another case diagnosed as an odontogenic keratocyst on both panoramic and CBCT views was diagnosed histologically as a nasopalatine duct cyst. The cyst was discovered in a 28year old male patient. The anterior maxillary cyst was unilocular with unclear margins and very large and extensive, extending from the left 1st premolar to the right 1st premolar. The lack of attachment of the cyst lining to an unerupted ectopic canine seen on CBCT ruled out the diagnosis of a dentigerous cyst. Encroachment into the nasal cavity was also evident on CBCT. There was no displacement or splaying of the roots of the incisors, which would normally suggest possibly a really large nasopalatine duct cyst. However, while being very extensive, there was minimal cortical

expansion and evidence of scalloping around the involved root. The observers concluded that this was most likely a large odontogenic keratocyst, the features not being characteristic of a nasopalatine duct cyst. Histology proved otherwise.

A histologically-diagnosed radicular cyst in a 31year old female was diagnosed radiologically as a dentigerous cyst both on panoramic and CBCT views. It presented as a unilocular radiolucency around an unerupted maxillary impacted canine. CBCT confirmed attachment of the cyst lining to the cemento-enamel junction of the tooth, and a diagnosis of dentigerous cyst seemed the most likely. A clinical history of recurrent lip swelling, suggestive of an infection, was provided. No other clinical history was included, e.g. a carious tooth or trauma, which might have suggested a radicular cyst. It is suggested, therefore, that this case be re-investigated.

The superiority of a CBCT scan over a panoramic radiograph was evident in several cases where additional detail seen on the CBCT scans provided a diagnosis which was confirmed histologically. A 17year old female patient with a posterior maxillary cyst associated with an impacted ectopic 3rd molar in the maxillary antrum, which was unilocular on panoramic radiograph, was diagnosed as a dentigerous cyst. On the CBCT scan however, the cyst was seen to be multilocular, with daughter cysts present within. Moreover, no attachment of the lining to the cemento-enamel junction of the tooth was observed. The root development was not advanced, a feature better represented on the CBCT. These findings led to the diagnosis of an odontogenic keratocyst, which was subsequently confirmed histologically, along with the confirmation of the presence of prominent daughter cysts.
Figures 3.8, 3.9, 3.10 and 3.11 represent the panoramic, CBCT and histological representations of this cyst. It was initially suspected to be a dentigerous cyst on panoramic radiography, but a provisional diagnosis of OKC was made on CBCT due to the appearance of daughter cysts. This was further confirmed histologically.



Figure 3.8. Panoramic radiograph of a maxillary cyst suspected to be a dentigerous cyst but confirmed on CBCT and histologically as an OKC

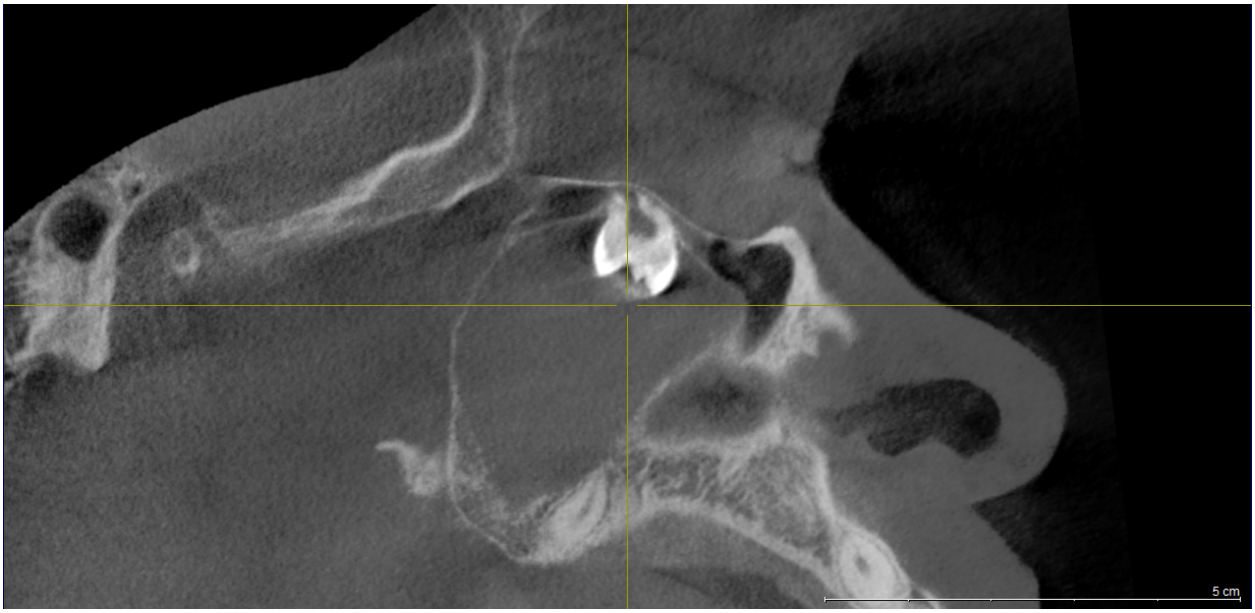

Figure 3.9. CBCT scan of an OKC with the appearance of daughter cysts

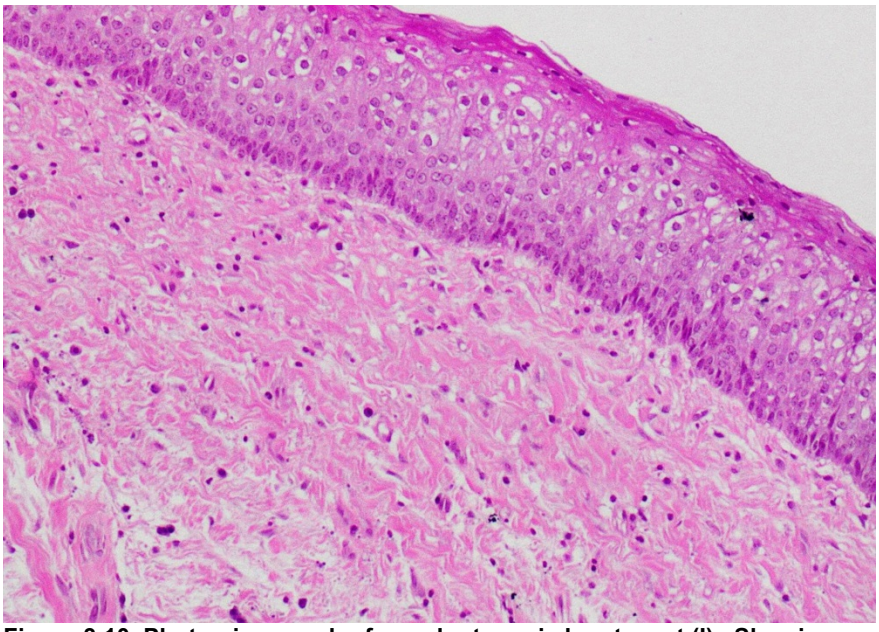

Figure 3.10. Photomicrograph of an odontogenic keratocyst (I). Showing parakeratinised stratified squamous epithelium. A prominent palisaded basal cell layer with hyperchromatic nuclei and reverse polarity is seen (Haematoxylin-eosin stain, original magnification x 100)

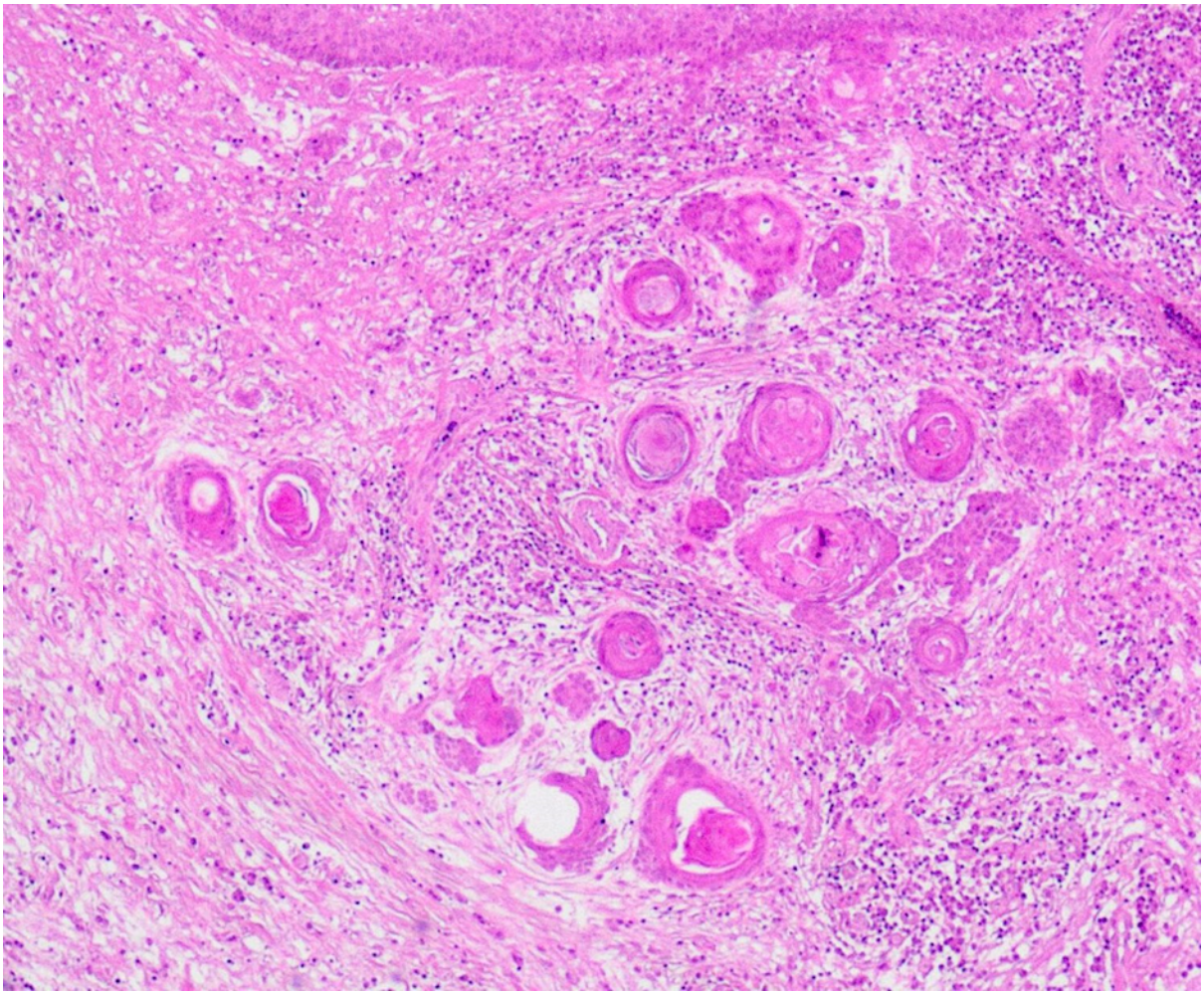

Figure 3.11. Photomicrograph of an odontogenic keratocyst (II). Numerous microcysts and islands of odontogenic epithelium extending deep into the wall of the odontogenic keratocyst depicted in Fig. 3.10. (Haematoxylin-eosin stain, original magnification x 40)

In the diagnosis of a nasopalatine duct cyst in a 16year old male patient with a large anterior maxillary radiolucency, the CBCT scan showed a backward extension of the cyst into the nasal fossa (figure 3.10), information which would have been vital in the surgical management of the cyst. Encroachment of the lesion into the nasopalatine canal, displacing the nasal floor, was also evident on the CBCT scan of yet another patient with a histologically confirmed diagnosis of a nasopalatine duct cyst. It would appear that CBCT is especially useful in the investigation of nasopalatine duct cysts. In the provision of a possible diagnosis both panoramic and CBCT radiographs appear to be equally sensitive and specific for the diagnosis of these cysts (100% sensitivity and

93.1% specificity for both techniques). Also, the location of the cyst is often very specific. CBCT scans, however, are especially useful in the provision of additional detail which is not easily seen on a panoramic radiograph due to the superimposition of structures in the maxilla.

Figure 3.12 is a CBCT scan of the NPDC with a backward extension of the cyst into the nasal cavity.

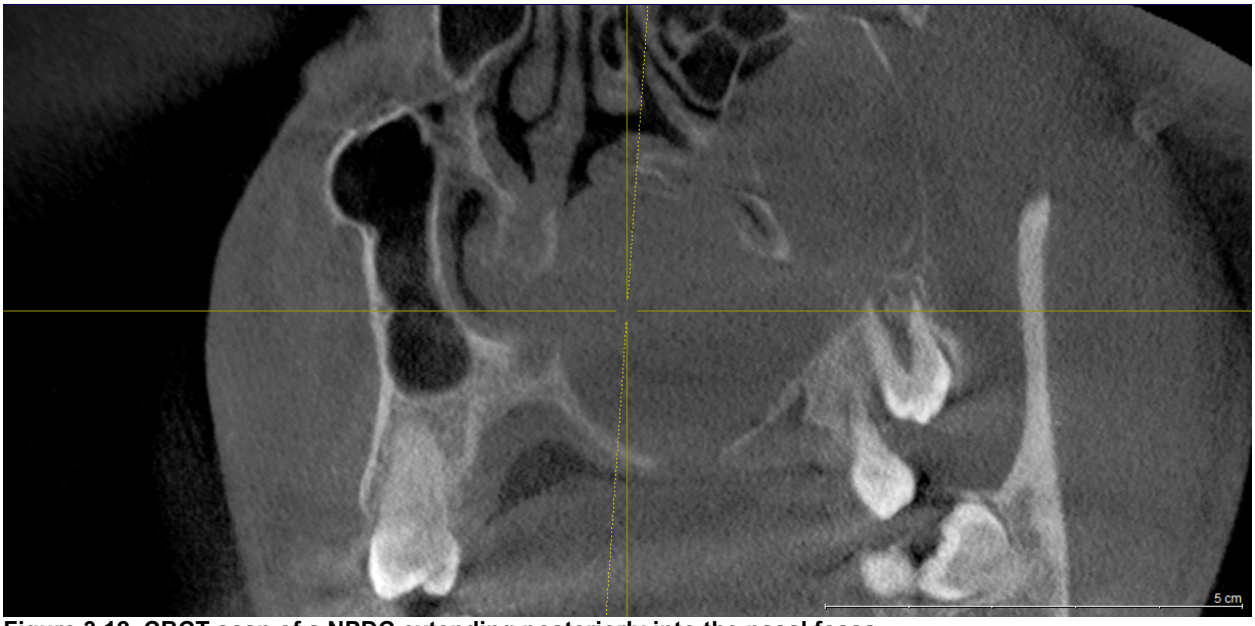

Figure 3.12. CBCT scan of a NPDC extending posteriorly into the nasal fossa

The following chapter explains and translates the results of this study.

CHAPTER 4

4. DISCUSSION

The aim of the study was to correlate the provisional panoramic and CBCT diagnoses of various jaw cysts with the final histological diagnoses. A comparison of the diagnostic accuracy of both radiological techniques was also done to assess the superiority of one technique over the other, and to determine whether CBCT provides significant additional detail relevant to the management of cysts.

Many of the cysts diagnosed radiologically presented with typical features. Features related to site/distribution, such as the posterior mandibular location of dentigerous cysts (dunfee et al, 2006) seen in 62.5% of the CBCT-diagnosed dentigerous cysts, and the maxillary anterior location of NPDCs (Shear and Speight, 2007) seen in 100% of the diagnosed cases, were valuable in making a diagnosis. Many cysts also presented in the typically expected age groups; however, 44% of CBCT-diagnosed cases of OKC were not in the 2nd-3rd decade age bracket, as commonly found (Minami et al, 1996). Two of the patients were much older than expected: 67- and 73year old, and the youngest patient was 11years old. The lesion in the 67year old patient however, was confirmed histologically as a residual cyst. None of the dentigerous cysts occurred in patients in their 3rd-4th decades, as expected in the study by Dunfee et al (2006). The patients were of a wide age range, with the youngest being 11 and the oldest patient being 70-years-old. Most of the OKCs occurred in the mandibular body/angle/ramus of the mandible region and the anterior maxillary region. However, a 17-year-old female patient presented with a posterior maxillary OKC, with the presence of daughter cysts noted on CBCT. Nasopalatine duct cysts, which are commonly seen in black male patients (Shear and Speight, 2007) occurred in 4 male patients out of the 6 patients diagnosed on CBCT. These cases were confirmed histologically as NPDCs. Only one of the patients was not in the 3rd-6th decade age range (Shear and Speight, 2007), and was 16 years old. The histologically-confirmed glandular odontogenic cyst diagnosed radiologically on CBCT as an aneurysmal bone cyst, occurred in the anterior mandibular region, as commonly found (Shear and Speight, 2007).

Most of the radiological diagnoses made on the panoramic radiographs tallied with the CBCT diagnoses. Out of the 35 cases investigated, only 3 panoramic diagnoses differed from the CBCT diagnoses. One of such is the case of a histologically-confirmed radicular cyst which was initially diagnosed as an OKC on panoramic radiography but proposed as a radicular cyst on CBCT. The three-dimensional view of the lesion on CBCT showing significant lingual expansion, an unlikely (but not impossible) feature of an OKC (White and Pharoah, 2009), raised the suspicion of a radicular cyst. This further highlights the limitations of conventional two-dimensional radiographs in reaching a correct diagnosis, as stressed by Deana and Alves (2017), Ozcan et al (2016), and Liao et al (2012). The other two cases were of the glandular odontogenic cyst diagnosed as an OKC on panoramic radiography and ABC on CBCT, and an OKC which had been initially suspected as a dentigerous cyst on panoramic radiography but confirmed as an OKC on CBCT and histologically, due to the presence of daughter cysts.

In several cases, additional detail was provided by CBCT, which would be relevant during surgical management of the cysts. In the radiological and histological diagnosis of a NPDC, though correctly diagnosed on the panoramic radiograph, a backward extension of the cyst into the nasal fossae seen on CBCT showed the full extent of the lesion. This would be vital information for a surgeon. In another case of NPDC, cortical expansion in the nasopalatine canal was also evident on the CBCT scan. Involvement of the IDN which was not very obvious on the panoramic radiograph as well as cortical plate expansion, was revealed in the CBCT scan of a confirmed OKC. Attachment of the cyst to the cemento-enamel junction of an unerupted 3rd molar with complete roots but minimal cortical expansion on the cross-sectional view was noted on the CBCT scan of a confirmed OKC. Most of this information was not available on the panoramic radiograph. The presence of daughter cysts was another apparent feature in yet another CBCT-diagnosed OKC. This feature would alert a surgeon to the possibility of recurrence of a cyst (Shear and Speight, 2007) and caution by the surgeon in its management. A dentigerous cyst in the anterior maxilla associated with an impacted canine was found on CBCT to encroach on the nasal cavity. The information on the CBCT scan of another cyst being more locular in the deeper sections was suggestive of

a giant cell lesion. This feature was not seen on the panoramic radiograph, and would be of interest to the surgeon. The histological diagnosis, however, was that of a GOC. In general, apart from aiding in the diagnoses of the cysts, the additional details provided by CBCT in many of these cases are relevant for surgical management of these cysts, as concluded by Mamatha et al (2014) in a case of an infected dentigerous cyst associated with an ameloblastoma in the maxillary sinus.

The result of the study suggests that although CBCT scans are superior to panoramic radiographs in the diagnosis of jaw cysts, they are perhaps not definitively diagnostic as the diagnoses obtained from them do not strongly correlate with the histological diagnoses, except in the diagnosis of nasopalatine duct cysts. Out of the 35 patients included in the study, only 26 of the CBCT diagnoses correlated with the histological diagnoses. The result of the study is thus similar to the conclusion from similar studies by Rosenberg et al (2010), and Hisatomi et al (2000). In these studies, it was concluded that CBCT is not a reliable method of differentiating between lesions, and histology remains confirmatory. In order to record highly accurate findings, and to keep the intra- and inter-rater reliability high, the set radiological criteria were strictly adhered to in this study. Radiological features such as attachment of a cyst lining to the cemento-enamel junction of an impacted tooth and increased mesio-distal expansion (in relation to bucco-lingual expansion) typically inferring the probability of a dentigerous cyst and an odontogenic keratocyst, respectively, were adhered to. This did not always necessarily take into consideration the occasional presence of atypical features found in many cysts. As a result, there was a radiological overestimation of OKCs, similar to the study done by Bornstein et al (2015), and an underestimation of radicular cysts.

The results of this study reveal that CBCT scans (and radiological techniques generally) are more sensitive and specific to certain types of jaw cysts than to others. This may be due to factors such as predictable/typical locations of cysts such as the nasopalatine duct cyst and dentigerous cysts (77.8% sensitivity and 92.3% specificity on panoramic radiographs; 87.5% sensitivity and 92.6% specificity on CBCT scans). CBCT scans have however, displayed an overall superiority to panoramic radiographs in the

diagnosis of jaw cysts. From this study panoramic radiographs have, on occasion, even displayed a minimal/weak correlation with the histological diagnoses. The inclusion of CBCT as standard protocol in the investigation and management of jaw cysts should be encouraged, but only in cases where its use is justified (Shin et al, 2014). In the long run this could be less time-consuming than taking a panoramic radiograph, referring the patient for a histological analysis (which is standard protocol), and then referring the patient back for further radiological investigations to assist the surgeon in treatment planning when an aggressive cyst is suspected. This will also reduce the cumulative radiation dose in a patient referred for multiple radiological investigations. Although more expensive than a panoramic machine, there are several brands of CBCT machines available to choose from and proper maintenance should also keep costs down.

As CBCT opens a new vista in dental imaging, it is suggested that all clinicians who wish to utilize this modality should undergo a period of extensive training. It is essential to be totally familiar with all software features provided by a specific machine and to utilise this to the best advantage. Clinicians must be taught to recognize radiographic features seen at various depths within a structure and in different planes as provided by this modality. Should a practitioner not have the necessary skills to make a provisional diagnosis based on the patient's history, clinical examination and conventional radiographs, he/she may become disorientated when confronted with a cone-beam scan.

The records kept at the Radiology Division contained limited clinical and demographic data as only names, dates of birth and initial diagnoses of patients were available. Potential study cases may have been excluded from the study due to initial misdiagnoses by inexperienced referring clinicians. For example, some cysts may have been entirely missed and therefore not documented.

The sample size was small mainly due to unsatisfactory diagnosis of several panoramic or CBCT views taken, which could not be included in the study. In addition, many

patients did not have available histological investigations. Some of these patients may never have reported back to the hospital, and some may not have been referred for histology at all. A larger sample size may possibly have produced a different outcome. Histological reports were dependent on often lacking clinical and demographic data provided by clinicians on request forms for microscopic examination.

Although the CBCT diagnoses were statistically proven to correlate moderately with the histological diagnoses, relevant information which would ideally have been available for a more comprehensive radiological diagnosis was not always available for this study.

CHAPTER 5

5. CONCLUSION

From this study, although CBCT displayed greater diagnostic accuracy than panoramic radiographs, it is only moderately, and not strongly predictive of jaw cysts when correlated with the histological diagnoses.

CBCT is a vital and useful imaging modality in the diagnosis of jaw cysts. In this study, it has consistently provided additional detail relevant to the diagnosis and management of jaw cysts. This was displayed, for example, in the case of a maxillary cyst that was diagnosed both radiologically and histologically as an OKC. The presence of daughter cysts, which was only displayed by CBCT and not panoramic radiography, is a feature of great importance in the management of this cyst. Its superiority over panoramic radiography was thus confirmed. The most important features of a cyst necessary for its management, such as its extent, have also, often been provided by the technique in this study.

This study highlights the importance of comprehensive clinical and radiological reports in assisting the pathologist in the histological assessment of clinicopathological entities. Ultimately, clinicoradiopathological correlation is central to improving diagnostic accuracy. Histology, however, remains the gold standard of diagnosis of jaw cysts.

Recommendations from the study

A similar study, prospective in nature, where proper detailed clinical history is recorded, conventional radiographs and CBCT scans of good diagnostic value are available and adequate referral of patients for biopsy specimens and follow-up are conducted. Important information should be included in request forms for both CBCT and microscopic examination, to improve diagnostic accuracy.

REFERENCES

Ahmad, M., Jenny, J. and Downie, M (2012). Application of cone beam computed tomography in oral and maxillofacial surgery. *Australian Dental Journal*. 57 (s1), 82-94.

Araki, M., Iameoha, S., Mastumoto, N. and Komiyama, K. (2007). Usefulness of cone-beam CT for odontogenic myxoma. *Dentomaxillofacial Radiology.* 36 (7), 423-427.

Barnes, L., Eveson, J.W., Reichart, P. and Sidransky, D. (2005). *WHO classification of tumours: pathology and genetics of head and neck tumours*. 9th series. Lyon, France: IARC Press.

Benn, A. and Altini, M. (1996). Dentigerous cysts of inflammatory origin: a clinicopathologic study. *Oral Surgery, Oral Medicine, Oral Pathology, Oral Radiology and Endodontology*. 81 (2), 202-209.

Bodin, I., Isacsson, G. and Julin, P. (1986). Cysts of the nasopalatine duct. *International Journal of Oral and Maxillofacial Surgery.* 15 (6), 696-706.

Bodner, L., Goldstein, J. and Samat, H. (2005). Eruption cysts: a clinical report of 24 cases. *Journal of Clinical Paediatric Dentistry.* 28 (2), 183-186.

Boeddinghaus, R. and Whyte, A. (2008). Current concepts in maxillofacial imaging. *European Journal of Radiology.* 66 (3), 396-418.

Bornstein, M.M., Bingisser, A.C., Reichart, P.A., Sandi, P., Bosshardt, D.D. and von Arx, T. (2015). Comparison between radiographic (2-dimensional and 3-dimensional) and histologic findings of periapical lesions treated with apical surgery. *Journal of Endodontics*. 41 (6), 804-811.

Browne, K.M. (1975). The pathogenesis of odontogenic cysts: a review. *Journal of Oral Pathology and Medicine.* 4 (1), 31-46.

Capote-Moreno, A., Acero, J., Garcia-Recuero, I., Ruiz, J., Serrano, R. and de Paz, V. (2009). Giant aneurysmal bone cyst of the mandible with unusual presentation. *Medicina Oral Patologia Oral y Cirugia Bucal.* 14 (3), E137-140.

Chamda, R.A. and Shear, M. (1980). Dimensions of incisive fossae on dry skulls and radiographs. *International Journal of Oral Surgery.* 9 (6), 452-457.

Chi, A., Owings, J. and Muller, S. (2005). Peripheral odontogenic keratocyst: report of two cases and review of the literature. *Oral Surgery, Oral Medicine, Oral Pathology, Oral Radiology, and Endodontology.* 99 (1), 71-78.

Chow, Hsun-Tau. (1998). Odontogenic keratocyst. A clinical experience in Singapore. *Oral Surgery, Oral Medicine, Oral Pathology, Oral Radiology and Endodontology.* 86 (5), 573-577.

Chuong, R., Donoff, R.B. and Guralnick, W. (1982). The odontogenic keratocyst. *Journal of Oral and Maxillofacial Surgery.* 40 (12), 797-802.

Daniels, J.S.M. (2004). Recurrent calcifying odontogenic cyst involving the maxillary sinus. *Oral Surgery, Oral Medicine, Oral Pathology, Oral Radiology, and Endodontology*. 98 (6), 660-664.

David, L.A., Sandor, G.K.B. and Stoneman, D.W. (1998). The buccal bifurcation cyst: is non-surgical treatment an option? *Journal (Canadian Dental Association).* 64: 712-716.

Deana, N.F. and Alves, N. (2017). Cone beam CT in diagnosis and surgical planning of dentigerous cyst. *Case reports in Dentistry*. Article ID 7956041. 6 pages.

Devenney-Cakir, B., Subramaniam, R.M., Reddy, S.M., Imsande, H., Gohel, A. and Sakai, O. (2011). Cystic and cystic-appearing lesions of the mandible: review*. American Journal of Roentgenology.* 196 (6) _ supplement.

Dimitroulis, G. and Curtin, J. (1998). Massive residual dental cyst: case report. *Australian Dental Journal.* 43 (4), 2-4.

Dunfee, B.L., Sakai, O., Pistey, R. and Gohel, A. (2006). Radiologic and pathologic characteristics of benign and malignant lesions of the mandible*. Radiographics.* 26 (6), 1751-1768.

El-Naggar, A.K., Chan, J.K.C., Grandis, J.R., Takata, T. and Slootweg, P.J. (2017). *World Health Organisation classification of head and neck tumours* (4th edn), IARC Press, Lyon. Ch8; 232-242.

Fowler, C.B., Brannon, R.B., Kessler, H.P., Castle, J.T. and Kahn, M.A. (2011). Glandular odontogenic cyst: analysis of 46 cases with special emphasis on microscopic criteria for diagnosis*. Head and Neck Pathology.* 5 (4), 364-375.

Freitas, D.Q., Tempest, L.M., Sicoli, E. and Lopes-Neto, F.C. (2006). Bilateral dentigerous cysts: review of the literature and report of an unusual case. *Dentomaxillofacial Radiology.* 35 (6), 464-468.

Friedrich, R.E., Scheuer, H.A. and Zustin, J. (2014). Lateral periodontal cyst. *In Vivo.* 28 (4), 595-598.

Gorlin, R.J., Pindborg, J.J., Clausen, F.P. and Vickers, R.A. (1962). The calcifying odontogenic cyst- a possible analogue of the cutaneous calcifying epithelioma of Malherbe. *Oral Surgery, Oral Medicine, Oral Pathology.* 15 (10), 1235-1243.

Gorlin, R.J., Pindborg, J.J., Redman, R.S., Williamson, J.J. and Hansen, L.S. (1964). The calcifying odontogenic cyst. A new entity and possible analogue of the cutaneous calcifying epithelioma of Malherbe. *Cancer.* 17 (6), 723-729.

Grasmuck, E.A. and Nelson, B.L. (2010). Keratocystic odontogenic tumour. *Head and Neck Pathology.* 4 (1), 94-96.

Guo, J., Simon, J.H., Sedghizadeh, P., Soliman, O.N., Chapman, T. and Enciso, R. (2013). Evaluation of the reliability and accuracy of using cone-beam computed tomography for diagnosing periapical cysts from granulomas. *Journal of Endodontics.* 39 (12), 1485-1490.

Hisatomi, M., Asaumi, J., Konouchi, H., Yanagi, Y. and Kishi, K. (2000). A case report of glandular odontogenic cyst associated with ameloblastoma: correlation of diagnostic imaging with histopathological features. *Dentomaxillofacial Radiology.* 29 (4), 249-253.

Jackson, I.T., Potparic, Z., Fasching, M., Schievink, W.I., Tidstrom, K. and Hussain, K. (1993). Penetration of the skull base by dissecting keratocyst. *Journal of Craniomaxillofacial Surgery.* 21 (8), 319-325.

Jaffe, H.L. and Lichtenstein, L. (1942). Solitary unicameral bone cyst with emphasis on the roentgen picture, the pathologic appearance, and the pathogenesis. *Archives of Surgery.* 44 (6), 1004-1025.

Kramer, I.R. (1974). Changing views on oral disease. *Proceedings of the Royal Society of Medicine.* 67 (4), 271-276.

Kuczek, A., Beikler, T., Herbst, H. and Flemmig, T.F. (2003). Eruption cyst formation associated with ciclosporin A. *Journal of Clinical Periodontology.* 30 (5), 462-466.

Kumar, M., Shanavas, M., Sidappa, A. and Kiran, M. (2015). Cone beam computed tomography – know its secrets (2015). *Journal of International Oral Health*. 7(2), 64-68.

Ledesma-Montes, C., Gorlin, R.J., Shear, M., Praetorius, F., Mosqueda-Taylor, A., Altini, M., Unni, M., Paes de Almeida, O., Carlos-Bregni, R., Romero de Leon, E., Phillips, V., Delgado-Azanero, W. and Meneses-Garcia, A. (2008). International collaborative study on ghost cell odontogenic tumours: calcifying cystic odontogenic tumour, dentinogenic ghost cell tumour and ghost cell odontogenic carcinoma. *Journal of Oral Pathology and Medicine.* 37 (5), 302-308.

Li, G. (2013). Patient radiation dose and protection from cone-beam computed tomography. *Imaging Science in Dentistry.* 43 (2), 63-69.

Liao, R., Sun, M., Gu, Y., Wang, R. and Liu, M. (2012). Clinical application of cone beam CT in the treatment of jaw bone cysts. *West China Journal of Stomatology*. 30 (3), 262-266.

Lin, L.M., Huang, GT-J. and Rosenberg, P.A. (2007). Proliferation of epithelial cell rests, formation of apical cysts, and regression of apical cysts after periapical wound healing. *Journal of Endodontics.* 33 (8), 908-916.

Ludlow, J.B. and Ivanovic, M. (2006). Comparative dosimetry of dental CBCT devices and 64-slice CT for oral and maxillofacial radiology. *Oral Surgery, Oral Medicine, Oral Pathology, Oral Radiology and Endodontology.* 106 (1), 106-114.

Lund, V.J. (1985). Odontogenic keratocyst of the maxilla: a case report. *British Journal of Oral and Maxillofacial Surgery.* 23 (3), 210-215.

MacDonald, D. (2016). Lesions of the jaws presenting as radiolucencies on cone-beam CT. *Clinical Radiology.* 71 (10), 972-985.

MacDonald-Jankowski, D.S. (2010). Orthokeratinised odontogenic cyst: a systematic review. *Dentomaxillofacial Radiology.* 39 (8), 455-467.

MacKenzie, G.D., Oatis, G.W., Mullen, M.P. and Grisius, R.J. (1985). Computed tomography in the diagnosis of an odontogenic keratocyst. *Oral Surgery, Oral Medicine, Oral Pathology.* 59 (3), 302-305.

Makowski, G.J., McGuff, S., and Van Sickels, J.E. (2001). Squamous cell carcinoma in a maxillary odontogenic keratocyst. *Journal of Oral and Maxillofacial Surgery.* 59 (1), 76-80.

Mamatha, N.S., Bhuvana, K., Savitha, J.K. and Pankaja, B. (2014). Diagnostic CBCT in dentigerous cysts with ectopic third molar in the maxillary sinus- a case report. *Journal of Clinical and Diagnostic Research.* 8 (6), ZD07-ZD09.

Martin, L.H.C. and Speight, P.M. (2017). Odontogenic cysts: an update. *Diagnostic Histopathology.* 23 (6), 260-265.

Maxim, L.D., Niebo, R. and Utell, M.J. (2014). Screening tests: a review with examples. *Inhalation Toxicology*. 26 (13), 811-828.

McCullough, E.C. and Coulam, C.M. (1976). Physical and dosimetric aspects of diagnostic, geometrical and computer-assisted tomographic procedures. *Radiologic Clinics of North America.* 14 (1), 3-14.

McHugh, M.L. (2012). Lessons in biostatistics. Interrater reliability: the kappa statistic. *Biochemia Medica*. 22 (3), 276-282.

Mendes, R.A. and van der Waal, I. (2006). An unusual clinicoradiographic presentation of a lateral periodontal cyst- report of two cases. *Medicina Oral, Patologia Oral y Cirugia Bucal.* 11 (2), mar/abr. ISSN 1698-6946.

Minami, M., Kaneda, T., Ozawa, K., Yamamoto, H., Itai, Y., Ozawa, M., Yoshikawa, K. and Sasaki, Y. (1996). Cystic lesions of the maxillomandibular region: MR imaging distinction of odontogenic keratocysts and ameloblastomas from other cysts. *American Journal of Roentgenology.* 166 (4), 943-949.

Moskow, B.S. (1966). The pathogenesis of the gingival cyst. *Periodontics.* 4 (1), 23-28.

Narang, R.S., Manchanda, A.S., Arora, P., and Randhawa, K. (2012). Dentigerous cysts of inflammatory origin- a diagnostic dilemma. *Annals of Diagnostic Pathology*. 16 (2), 119-123.

Natkin, E., Oswald, R.J., and Carnes, L.I. (1984). The relationship of lesion size to diagnosis, incidence, and treatment of periapical cysts and granulomas. *Oral Surgery, Oral Medicine, Oral Pathology.* 57 (1), 82-94.

Nelson, B.L. and Linfesty, R.L. (2010). Nasopalatine duct cyst. *Head and Neck Pathology.* 4 (2), 121-122.

Nikneshan, S. and Hadian, H. (2015). Unusual aggressive radiographic appearance of simple bone cyst (a case report and review of literature). *British Journal of Medicine and Medical Research.* 6 (8), 833-840.

Noffke, C. and Raubenheimer, E.J. (2002). The glandular odontogenic cyst: clinical and radiological features; review of the literature and report of nine cases. *Dentomaxillofacial Radiology.* 31 (6), 333-338.

Nxumalo, T.N. and Shear, M. (1992). The gingival cyst of adults. *Journal of Oral Pathology and Medicine.* 21 (7), 309-313.

Ozcan, G., Sekerci, A.E., Soylu, E., Nazlim, S., Amuk, M. and Avci, F. (2016). Role of cone-beam CT in the evaluation of a paradental cyst related to the fusion of a wisdom tooth with a paramolar: A rare case report. *Imaging Science in Dentistry*. 46 (1), 57-62.

Padayachee, A. and Van Wyk, C.W. (1987). Two cystic lesions with features of both the botryoid odontogenic cyst and the central mucoepidermoid tumour: sialo-odontogenic cyst? *Journal of Oral Pathology and Medicine.* 16 (10), 499-504.

Pauwels, R., Beinsberger, J., Collaert, B., Theodorakou, C., Rogers, J., Walker, A., Cockmartin, L., Bosmans, H., Jacobs, R., Bogaerts, R. and Horner, K. (2012). Effective dose range for dental cone beam computed tomography scanners. *European Journal of Radiology.* 81 (2), 267-271.

Praetorius, F. (1975). Calcifying odontogenic cyst: range, variations and neoplastic potential. Paper delivered at a Symposium on Maxillofacial Bone Pathology, Brussels, 30-31 March 1974, organized by Committee on Maxillofacial Bone Pathology. *International Journal of Oral Surgery*. 4, 89 (Abstract).

Praetorius, F., Hjorting-Hansen, E., Gorlin, R.J. and Vickers, R.A. (1981). Calcifying odontogenic cyst. Range, Variations and Neoplastic Potential. *Acta Odontologica Scandinavica.* 39 (4), 227-240.

Ramer, M. and Valauri, D. (2005). Multicystic lateral periodontal cyst and botryoid odontogenic cyst. Multifactorial analysis of previously unreported series and review of the literature. *New York State Dental Journal.* 71 (4), 47-51.

Rasmussen, L.G., Magnusson, B.C. and Bosman, H. (1991). The lateral periodontal cyst. A histopathologic and radiographic study of 32 cases. *British Journal of Oral and Maxillofacial Surgery.* 29 (1), 54-57.

Ricucci, D., Mannocci, F. and Pitt Ford, T.R. (2006). A study of periapical lesions correlating the presence of a radiopaque lamina with histological findings. *Oral Surgery, Oral Medicine, Oral Pathology, Oral Radiology and Endodontology.* 101 (3), 389-394.

Rosenberg, P.A., Frisbie, J., Lee, J., Lee, K., Frommer, H., Kottal, S., Phelan, J., Lin, L. and Fisch, G. (2010). Evaluation of pathologists (histopathology) and radiologists (cone beam computed tomography) differentiating radicular cysts from granulomas. *Journal of Endodontics.* 36 (3), 413-428.

Schulze, R., Hell, U., Groß, D., Bruellmann, D.D., Dranischnikow, E., Schwanecke, U. and Schoemer, E. (2011). Artefacts in CBCT: a review*. Dentomaxillofacial Radiology.* 40 (5), 265-273.

Sekerci, A.E., Sisman, Y., Etoz, M., and Bulut, D.G. (2013). Aberrant anatomical variation of maxillary sinus mimicking periapical cyst: a report of 2 cases and role of CBCT in diagnosis. *Case Reports in Dentistry*. Vol 2013. Article ID 757645, 4 pages.

Shade, N.L., Carpenter, W.M., and Delzer, D.D. (1987). Gingival cyst of the adult. Case report of a bilateral presentation. *Journal of Periodontology.* 58 (11), 796-799.

Shah, N., Bansal, N., and Logani, A. (2014). Recent advances in imaging technologies in dentistry. *World Journal of Radiology*. 6 (10), 794-807.

Shear, M. and Speight, P.M. (2007). *Cysts of the oral and maxillofacial regions*. 4th edition. Oxford, Blackwell Munksgaard.

Shin, H.S., Nam, K.C., Park, H., Choi, H.U., Kim, H.Y. and Park, C.S. (2014). Effective doses from panoramic radiography and CBCT (cone beam CT) using dose area product (DAP) in dentistry. *Dentomaxillofacial Radiology*. 43 (5), 20130439.

Simon, J.H., Enciso, R., Malfaz, J.M., Roges, R., Bailey-Perry, M. and Patel, A. (2006). Differential diagnosis of large periapical lesions using cone-beam computed tomography measurements and biopsy. *Journal of Endodontics.* 32 (9), 833-837.

Sisman, Y., Etoz, O.A., Mavili, E., Sahman, H. and Tarim Ertas, E. (2010). Anterior stafne bone defect mimicking a residual cyst: a case report. *Dentomaxillofacial Radiology.* 39 (2), 124-126.

Suomalainen, A., Apajalahti, S., Kuhlefelt, M. and Hagstrom, J. (2009). Simple bone cyst: a radiological dilemma. *Dentomaxillofacial Radiology.* 38 (3), 174-177.

Swain, N., Patel, S., Poonja, L.S., Pathak, J. and Dekate, K. (2012). Orthokeratinised odontogenic cyst. *Journal of Contemporary Dentistry*. 2 (2), 31-33.

Takeda, Y., Suzuki, A. and Yamamoto, H. (1990). Histopathologic study of epithelial components in the connective tissue wall of unilocular type of calcifying odontogenic cyst. *Journal of Oral Pathology and Medicine.* 19 (3), 108-113.

Takeda, Y. (1994). Glandular odontogenic cyst mimicking a lateral periodontal cyst: a case report. *International Journal of Oral and Maxillofacial Surgery.* 23 (2), 96-97.

Tolson, G.E., Czuszak, C.A., Billman, M.A. and Lewis, D.M. (1996). Report of a lateral periodontal cyst and gingival cyst occurring in the same patient. *Journal of Periodontology.* 67 (5), 541-544.

Trope, M., Pettigrew, T., Petras, J., Barnett, F. and Tronstad, L. (1989). Differentiation of radicular cysts and granulomas using computerized tomography. *Dental Traumatology.* 5 (2), 69-72.

Van der Waal, I., Rauhamaa, R., van der Kwast, W.A.M. and Snow, G.B. (1985). Squamous cell carcinoma arising in the lining of odontogenic cysts. Report of 5 cases. *International Journal of Oral Surgery.* 14 (2), 146-152.

van Rensburg, L.J., Paquette, M., Morkel, J.A. and Nortje, C.J. (2003). Correlative MRI and CT imaging of the odontogenic keratocyst: a review of twenty-one cases. *Oral and Maxillofacial Surgery Clinics of North America.* 15 (3), 363-382.

Voorsmit, R.A. (1985). The incredible keratocyst. Deutsche Zahnarztliche Zeitschrift. 40 (6), 641-644.

Weathers, D.R. and Waldron, C.A. (1973). Unusual multilocular cysts of the jaws (botryoid odontogenic cysts). *Oral Surgery, Oral Medicine, Oral Pathology.* 36 (2), 235-241.

Weber, A.L., Kaneda, T., Scrivani, S.J. et al (2003). Cysts, tumours and non-tumorous lesions of the jaw. In: Som, P.M., Curtin, H.D., eds. *Head and neck imaging*, 4th ed. St Louis, Mo: Mosby. pp. 930-994.

Wenzel, A. (2014). Radiographic display of carious lesions and cavitation in approximal surfaces: advantages and drawbacks of conventional and advanced modalities. *Acta Odontologica Scandinavica.* 72 (4), 251-264.

White, S.C. and Pharoah, M.J. (2009). Cysts and cyst-like lesions of the jaws. In: White, S.C., Pharoah, M.J., eds. *Oral radiology: principles and interpretation*, 6th ed. St. Louis, Mo: Mosby Elsevier. pp. 343-365.

Wolff, C., Mucke, T., Wafenpfeil, S., Kanatas, A., Bissinger, O. and Deppe, H. (2016). *Journal of Cranio-Maxillo-Facial Surgery*. 44 (10), 1700-1705.

Wright, J.M. (1981). The odontogenic keratocyst: orthokeratinised variant. *Oral Surgery*, *Oral Medicine and Oral Pathology.* 51 (6), 609-618.

Wysocki, G.P., Brannon, R.B., Gardner, D.G. and Sapp, P. (1980). Histogenesis of the lateral periodontal cyst and the gingival cyst of the adult. *Oral Surgery, Oral Medicine, Oral Pathology.* 50 (4), 327-334.

APPENDIX ONE: PLAGIARISM DECLARATION

UNIVERSITY OF THE WITWATERSRAND, JOHANNESBURG

FACULTY OF HEALTH SCIENCES

PLAGIARISM DECLARATION TO BE SIGNED BY ALL HIGHER DEGREE STUDENTS

SENATE PLAGIARISM POLICY: APPENDIX ONE

I CATHERINE O. ENAHORO (Student number: 1154858) am a student registered for the degree of MSc (Dentistry) in the academic year 2017

I hereby declare the following:

- I am aware that plagiarism (the use of someone else's work without their permission and/or without acknowledging the original source) is wrong.
- I confirm that the work submitted for assessment for the above degree is my own unaided work except where I have explicitly indicated otherwise.
- I have followed the required conventions in referencing the thoughts and ideas of others.
- I understand that the University of the Witwatersrand may take disciplinary action against me if there is a belief that this is not my own unaided work or that I have failed to acknowledge the source of the ideas or words in my writing.
- I have included as an appendix a report from "Turnitin" (or other approved plagiarism detection) software indicating the level of plagiarism in my research document.

Signature: O.C Enahoro Date: 8/09/2017

1

APPENDIX TWO: PATIENT DATA FORM

Study number	
Age	
Sex	
Site/ Distribution of lesion	
Duration of lesion	
Presence of pain (yes/no)	
Extra-oral swelling (y/n)	
Intra-oral swelling (y/n)	
Tooth displacement (y/n)	
History of recurrence (y/n)	
History of trauma (y/n)	
Any other symptoms?	

Radiological features

Criteria	Panoramic features	CBCT features
Unilocular/Multilocular?		
Margins		
Root resorption (y/n)		
Tooth displacement (y/n)		
Cortical expansion (y/n)		
Site/Distribution of lesion		
Involvement of antrum/ IDN		
Presence of calcifications		
Size of the lesion		
Any other features?		

Radiological diagnosis:

Histological diagnosis:

APPENDIX THREE: ETHICAL APPROVAL

R14/49 Dr Catherine Enahoro

HUMAN RESEARCH ETHICS COMMITTEE (MEDICAL)

CLEARANCE CERTIFICATE NO. M170630

NAME: (Principal Investigator)	Dr Catherine Enahoro
DEPARTMENT: Division	General Dental Practice/Maxillofacial and Oral Radiation
	University of the Witwatersrand
PROJECT TITLE:	Jaw Cysts: A Correlation of the Accuracy of a Provisional Radiological Diagnosis with the Definitive Histological Diagnosis
DATE CONSIDERED:	30/06/2017
DECISION:	Approved unconditionally
CONDITIONS:	
SUPERVISOR:	Prof B. Buch and Dr S.P. Ngwenya
APPROVED BY:	Professor P. Cleaton-Jones Chairperson, HREC (Medical)
DATE OF APPROVAL:	07/07/2017

This clearance certificate is valid for 5 years from date of approval. Extension may be applied for.

DECLARATION OF INVESTIGATORS

To be completed in duplicate and **ONE COPY** returned to the Research Office Secretary in Room 10004,10th floor, Senate House/3rd floor, Phillip Tobias Building, Parktown, University of the Witwatersrand. I/We fully understand the conditions under which I am/we are authorised to carry out the above-mentioned research and I/we undertake to ensure compliance with these conditions. Should any departure be contemplated, from the research protocol as approved, I/we undertake to resubmit to the Committee. **I agree to submit a yearly progress report**. The date for annual re-certification will be one year after the date of convened meeting where the study was initially reviewed. in this case, the study was initially review June and will therefore be due in the month of June each year. Unreported changes to the application may invalidate the clearance given by the HREC (Medical).

Principal Investigator Signature

Date 11/07/2017

PLEASE QUOTE THE PROTOCOL NUMBER IN ALL ENQUIRIES

APPENDIX FOUR: APPROVAL OF TITLE

UNIVERSITY OF THE
WITWATERSRAND,
JOHANNESBURG

Private Bag 3 Wits, 2050
Fax: 027117172119
Tel: 02711 7172076

Reference: Mrs Sandra Benn
E-mail: sandra.benn@wits.ac.za

14 August 2017
Person No: 1154858
PAG

Dr CO Enahoro
No. 9,
Oduduwa Way
G.r.a Ikeja. Pmb 21184 Ikeja
21184
Nigeria

Dear Dr Enahoro

Master of Science in Dentistry: Approval of Title

We have pleasure in advising that your proposal entitled *Jaw cysts: A correlation of the accuracy of a provisional radiological diagnosis with the definitive histological diagnosis* has been approved. Please note that any amendments to this title have to be endorsed by the Faculty's higher degrees committee and formally approved.

Yours sincerely

Mrs Sandra Benn
Faculty Registrar
Faculty of Health Sciences

l154858:turnitin.docx

ORIGINALITY REPORT

3%	0%	3%	0%
SIMILARITY INDEX	INTERNET SOURCES	PUBLICATIONS	STUDENT PAPERS

PRIMARY SOURCES

1	Encyclopedia of Pathology, 2016. Publication	1%
2	Shear. "Dentigerous Cyst", Cysts of the Oral and Maxillofacial Regions, 06/06/2007 Publication	1%
3	Shear. "Calcifying Odontogenic Cyst (Calcifying Cystic Odontogenic Tumour)", Cysts of the Oral and Maxillofacial Regions, 06/06/2007 Publication	1%
4	R. M. Browne. "The pathogenesis of odontogenic cysts: a review", Journal of Oral Pathology and Medicine, 1/1975 Publication	1%

Exclude quotes	On	Exclude matches	< 1%
Exclude bibliography	On		