Silicotuberculosis: a critical narrative review

Rodney Ehrlich[1], Jill Murray[2], Qonita Said-Hartley[3] and David Rees[2,4]

[1]Division of Occupational Medicine, School of Public Health, University of Cape Town, Cape Town, South Africa. [2]School of Public Health, University of the Witwatersrand, Johannesburg, South Africa. [3]Division of Radiology, University of Cape Town and Groote Schuur Hospital, Cape Town, South Africa. [4]National Institute for Occupational Health, National Health Laboratory Service, Johannesburg, South Africa.

Corresponding author: David Rees (David.rees@wits.ac.za)

Shareable abstract (@ERSpublications)
Silicotuberculosis is a common but neglected disease in high TB burden countries with many silica-exposed workers. Despite its long history, fundamental questions about the diagnosis, treatment and prevention of combined disease remain to be answered. https://bit.ly/3XQw6Bq

Cite this article as: Ehrlich R, Murray J, Said-Hartley Q, *et al*. Silicotuberculosis: a critical narrative review. *Eur Respir Rev* 2024; 33: 240168 [DOI: 10.1183/16000617.0168-2024].

Copyright ©The authors 2024

This version is distributed under the terms of the Creative Commons Attribution Non-Commercial Licence 4.0. For commercial reproduction rights and permissions contact permissions@ersnet.org

Received: 24 July 2024
Accepted: 30 Sept 2024

Abstract

Silicotuberculosis, the combination of silicosis and pulmonary tuberculosis (TB), remains a substantial clinical and public health problem in high TB burden countries with silica-exposed workforces. The objectives of this narrative review are to propose a definition of silicotuberculosis which includes post-tuberculous lung disease, to emphasise the importance of understanding how the two diseases modify each other, and to identify as yet unanswered questions relevant to clinical practice and disease control and mitigation. The unique aetiological relationship between silica exposure and TB is now firmly established, as is the accelerated impairment and mortality imposed by TB on individuals with silicosis. However, the rich clinical, pathology and laboratory literature on combined disease from the pre-TB treatment era appears to have been largely forgotten. The close clinical and pathological appearance of the two diseases continues to pose a challenge to imaging, diagnosis and pathological description, while inconsistent evidence regarding TB treatment and TB preventive treatment prevails. Many other topics raise questions to be answered, *inter alia*: the range of phenotypes of combined disease; the rates and determinants of disease progression; the role of computed tomography in identifying and characterising combined disease; appropriate screening practice; acceptable policies of management of workers that combine risk reduction with social security; and the workplace respirable silica concentration that protects against the excess TB attributable to inhaled silica.

Introduction

The persistence in high tuberculosis (TB) burden countries of hazardous occupational exposure to silica involving large numbers of workers and of silicosis as an occupational disease underlies the continuing importance of combined disease in the modern world [1–7]. The strong epidemiological association between silicosis and active TB has recently been quantified in a systematic review [8], although the unique association between silica dust, silicosis and pulmonary TB was well established during the first two-thirds of the 20th century [9–13].

The pathogenesis and radiological and pathological character of combined disease were the subject of frequent publication and debate until the 1960s [12, 13–15]. So closely associated were the effects of silica dust and tuberculous infection that the existence of silicosis as a fatal occupational disease in the absence of TB was for a period the subject of contention [9, 16, 17]. Political as much as scientific consensus was achieved only at the 1930 International Labour Office Conference in Johannesburg [14, 18]. Even as separate diseases, difficulty in distinguishing them clinically has been a constant theme in the literature, including the pathology and radiology of the nodular and massive fibrotic forms of the two diseases [10, 15, 19–28].

Interest in combined disease appears to have faded with the advent of effective TB treatment and the decrease in high-exposure silica occupations in affluent countries [29]. Although case reports and series

Downloaded from https://publications.ersnet.org on December 18, 2024 by guest. Please see licensing information on first page for reuse rights.

appear regularly from across the globe [5, 30–39], dedicated reviews are few [40–42] and many questions persist [43–45].

In contrast to the literature of recent decades, this article is an attempt at a critical assessment. Its objectives are threefold: 1) to propose a broad definition which takes into account the phenotype of chronic silicotuberculosis in addition to that of silicosis with active TB; 2) to consider how the two diseases may modify each other, posing diagnostic and treatment difficulty; and 3) to identify gaps in our epidemiological and clinical knowledge of the combined disease in the current era.

Our overall aim is to encourage a more nuanced clinical view of the pulmonary effects of serial or simultaneous exposures of workers to silica and to *Mycobacterium tuberculosis*.

Definitions, scope and methods

The terminology applied to combined disease has varied considerably over the past 130 years. Besides silicotuberculosis, historical usage includes miners' phthisis, infective silicosis, tuberculo-silicosis and "tuberculosis with silicosis" [9, 11, 15, 19, 22, 25]. The variation in nomenclature reflects the attempt to distinguish different pathogenetic pathways or clinical phenotypes in the pre-TB treatment era. These were based, *inter alia*, on 1) whether silica exposure or silicosis occurred before or after tuberculous infection [15]; 2) which disease predominated in determining prognosis and mortality [12, 15, 22, 25]; and 3) the difference between a bacteriologically negative "indolent" form of TB accompanying silicosis and associated with an excessive fibroid reaction and a clinically typical "frank open TB" [21, 22, 25, 46].

TB in this article means thoracic disease due to *M. tuberculosis*, and excludes latent TB infection (LTBI). Silicotuberculosis is defined as the combination of silicosis and active TB and/or post-tuberculous lung disease (PTLD) [47, 48], and covers all temporal sequences of occurrence. This extends our interest from a focus on the diagnosis and management of active TB in individuals with silicosis to include the diagnosis, prognosis and workers' compensation of silicosis combined with PTLD. TB in silica-exposed individuals without radiological silicosis is dealt with in later sections on screening and prevention because of its relevance to TB control. The review does not cover coal workers' pneumoconiosis (CWP), although the occurrence of silicosis as a component of CWP [49] makes the review relevant to populations exposed to coal dust [50].

This narrative review was based on the literature collections of the authors, including reviews and article references, and augmented by a literature search limited to human subjects and articles in the English language. A search of PubMed and Embase was undertaken using combinations of the terms "silica or silicosis (or both) and tuberculosis", for the period 1973–2020. This was supplemented for the period 2021–2023 inclusive using PubMed. Publications for potential citation were identified by one author and agreed by consensus.

Epidemiology

Aetiology

The meta-analysis cited earlier concluded that silicosis increases the risk of TB fourfold, with a strong disease severity-response gradient [8]. Silica exposure after controlling for radiological silicosis doubles the risk of TB, an inference of less precision owing to the scarcity of reliable long-term measurements of cumulative respirable silica exposure [51, 52]. Among established relative risks for TB, silicosis has been placed second with malnutrition after HIV infection [53]. Little is known about interaction of the various risk factors for TB, with the marked exception of HIV: the risk of TB in a gold miner with both silicosis and HIV has been estimated at approximately 15 times that of a miner with neither condition, demonstrating multiplicative interaction [54].

A close association between complicated silicosis in the form of progressive massive fibrosis (PMF) and fibrosis due to TB has long been noted [12, 15, 24, 55, 56]. It may be difficult to distinguish them when confronted with fibrotic masses on chest radiography [12, 19, 25, 28, 56]. To the extent that PMF is a marker of the severity of silicosis, it would be expected to be a risk factor for subsequent TB, demonstrated as such in one study [57]. Conversely, TB has been shown to be a risk factor for PMF as identified on chest radiography and computed tomography (CT) [56, 58].

A role for TB in the aetiology or progression of nodular silicosis has also been proposed [11, 15, 59–61]. The overall implication is that silicotuberculosis should be considered a phenotype in which clear distinction between the presentation and effects of the two diseases may not always be possible.

Downloaded from https://publications.ersnet.org on December 18, 2024 by guest. Please see licensing information on first page for reuse rights.

While there are studies showing an elevated LTBI prevalence in silica-exposed workers or in individuals with silicosis [62–64], there is a deficit of well-controlled longitudinal studies. There are a number of confounding factors, notably age, country of birth, childhood/adolescent exposure to TB, socioeconomic status, living environment and congregate work setting, which need to be controlled before it can be inferred that silica or silicosis is the aetiological factor [65].

Prevalence

Reported prevalences of silicotuberculosis from affected settings, although not based on a standard definition or comparable work status or period, illustrate the existence of a substantial burden. For example, combined disease has been found in 11–25% of Basotho former workers from the South African gold mines [4, 66] and in 42% among haematite miners in China [2]. Similar figures have been reported in non-mining occupations, *e.g.* 24% among former stone grinders in India [67] and 35% in a multi-occupational cohort of silicotic patients in Hong Kong [57]. A double burden of silicosis and TB is emerging among the growing number of artisanal and small-scale miners [68, 69].

Silica-exposed individuals are at risk of silicotuberculosis irrespective of the setting. While silicotuberculosis has declined in incidence in low TB burden countries [29], it continues to be diagnosed in such settings [30, 32, 39], including in a number of trades in the UK [70] and accompanying accelerated silicosis in stonemasons in Australia [71] and denim sandblasters in Turkey [72]. Non-occupational silicotuberculosis has been identified in community members exposed to dust from agate and slate pencil operations in India [73].

Impairment and mortality

Historically, clinical accounts of combined disease were shaped by the high exposures to silica and by the absence of effective treatment for pulmonary TB. The poorer prognosis of combined disease compared with silicosis alone was common cause [22, 74], a view which persisted into the pre-rifampicin TB treatment era [12, 75]. However, even in the recent era of lower silica exposures in high- and upper-middle-income countries and rifampicin-containing TB regimens, studies have confirmed the poorer prognosis of silicosis when complicated by TB, whether active disease or as PTLD, in respect of lung function impairment and mortality. More specifically, a history of TB has been shown to be associated with elevated rates of radiological progression of silicosis [76, 77]. While silicosis can progress with variable effects on lung function, superimposition of TB adds significant clinical impairment [78, 79], accelerated by recurrent TB [80]. Effects on response to TB treatment are discussed in a later section.

Estimates of TB mortality ratios associated with silicosis, whether relative to individuals without silicosis in silica-exposed populations or to the general population, are available from countries able to record cause of death in identifiable cohorts [81–86]. Estimates of relative mortality risk vary with country, calendar period and sex, but consistently exceed 2.5 with some reaching very high levels, *e.g.* 22 in Italy [83] and 39 in the USA [84]. A number of pathways may be involved. These include accelerated TB and increased severity due to impairment of the normal lung defences by silica exposure (described in the next section on co-pathogenesis), TB treatment delay [87], and lower effectiveness of current TB regimens in silicotuberculosis (described in the later section on treatment). Comorbidity in the form of pulmonary hypertension, a complication of TB [88] and silicosis [89], and of emphysema related to silicotic fibrosis or directly to dust exposure [90], may contribute to the aggravated course of combined disease. End-stage conditions include respiratory failure and cor pulmonale [31, 36, 91].

Co-pathogenesis

In contrast to laboratory research on silicosis and TB as individual diseases, that on co-pathogenesis remains scarce. Almost all such investigations in recent decades have focused on the effect of silica particles rather than silicosis in reducing host resistance and promoting *M. tuberculosis* disease. Immunomodulatory pathways remain speculative and in some cases contradictory regarding the potential effect on host resistance to *M. tuberculosis* [44, 92, 93]. However, the centrality of damage by silica particles to the macrophage, in the frontline of innate defence against silica and *M. tuberculosis*, has been established *in vitro* [92–94] and *in vivo* [95, 96]. Primary damage to the macrophage by silica particles arises from the promotion of pro-inflammatory pathways disturbing the balance between apoptosis and necrosis, promoting the release of viable *M. tuberculosis* from dying cells [97]. Even without rapid cell death, intergenerational impairment of macrophage defences against *M. tuberculosis* has been demonstrated in silica-exposed macrophages transferred from dusted to undusted mice [95]. Recent work has demonstrated a role for the cGAS–STING (cyclic GMP-AMP synthase–stimulator of interferon genes) nucleic acid sensing pathway [94]. In this system, silica pre-exposure and resultant release of host and *M. tuberculosis* DNA stimulates the cGAS–STING pathway which promotes upregulation of type 1

Downloaded from https://publications.ersnet.org on December 18, 2024 by guest. Please see licensing information on first page for reuse rights.

interferon and type 2 immune responses to *M. tuberculosis* DNA. This environment impairs the host's innate and acquired immunity to *M. tuberculosis*, promoting its survival and proliferation. This mechanism has been characterised as "the cross-roads of sterile inflammation and infection" [94]. Enhanced fibrogenesis following exposure to silica and *M. tuberculosis*, relative to that arising from either disease on its own, has also been demonstrated [98], but has otherwise received little mechanistic attention.

Diagnosis

Diagnosis of TB in the presence of silicosis

While there are comprehensive guides for TB diagnosis [99–101], none to our knowledge deal specifically with TB diagnosis in the presence of silicosis.

Where they do occur, symptoms and radiological abnormalities typically associated with TB may be due to silicosis and/or PTLD, consequently reducing the specificity of these clinical features for active TB. This is the case particularly in high TB burden countries with large silica-exposed populations such as South Africa, India and China.

The effect of these coexisting conditions on the accuracy of microbiological tests for TB needs to be considered. In one study of gold miners, silicosis did not reduce the sensitivity of sputum microscopy and culture for active TB, nor the specificity of smear [102]. However, as HIV infection has been shown to lower the sensitivity of Xpert MTB/RIF [103], of relevance to Southern Africa where gold miners have a high HIV prevalence [76], the performance of Xpert MTB/RIF in the presence of HIV and silicosis combined requires investigation. The same applies to the sensitivity of Xpert MTB/RIF for the indolent smear-negative form of TB accompanying silicosis described historically earlier [21, 22] and re-identified in the 1980s [27, 61, 104].

The concurrence of silicosis and PTLD in a population at high risk of active TB and HIV and concern about community transmission of TB are likely to result in high rates of empirical treatment of silicotuberculosis [28]. This may follow either from lack of access to confirmatory tests or the clinical presentation of symptoms and an abnormal chest radiograph with a negative sputum smear or Xpert MTB/RIF test [105, 106]. Empirical treatment remains an important part of the management of TB [107], but is not without adverse consequences [108]. Overtreatment has been shown to be common in some settings [106, 108], of which silica-exposed populations are an important example [28]. Overtreatment entails an unnecessary risk of side-effects, overuse of anti-tuberculous drugs, and concomitant failure to diagnose other medical conditions, including silicosis, and those requiring other forms of treatment. The latter includes non-tuberculous mycobacterial (NTM) pulmonary disease, for which silicosis is a risk factor [109]. Diagnostic criteria for NTM disease have been published [110], but evidence-based guides for initiating empirical TB treatment in individuals with silicosis are needed.

Imaging

Plain chest radiography

The range of plain chest radiography features of combined disease (with PTLD, active TB or both) is wide and variable. Table 1 lists chest radiography features regarded as suggestive of lone occurrence or co-occurrence of silicosis and TB [27, 28, 42, 61, 104, 111–114]. Figure 1 provides example chest radiography.

Chest radiography features of chronic silicosis are readily recognisable as bilateral small, rounded opacities uniformly distributed with predominance in the upper and mid-zones of the lungs [42]. When diffusely filling the lungs, they may resemble the small opacities of miliary TB. Localised nodulation is more suggestive of either active TB or PTLD [111]. However, it has been suggested that silica exposure may result in a more profuse tuberculous nodulation than seen in non-occupational settings [27, 104]. In silica exposure settings, the chest radiograph reader is faced with the task of distinguishing whether nodular opacities, particularly when bilateral and in the upper to mid-zones, are due to silicosis, TB or to both.

In silica-exposed individuals, early nodular changes of TB may be difficult to identify, especially if silicosis is evident [27, 61]. Conversely, silicosis may be missed in the presence of tuberculous abnormalities, whether small nodular opacities or fibrotic masses, particularly with volume loss and anatomical distortion. An occupational history is needed, and if there is a history of significant silica exposure, the modification by TB of the typical "angel wing" symmetrical distribution of silicotic nodules needs to be considered. In the case of presumptive active TB, the reading of the presence and/or extent of silicosis in this setting should be delayed until a repeat chest radiograph is examined after treatment completion, to determine whether tuberculous lesions mimicking or obscuring silicosis may have cleared.

Downloaded from https://publications.ersnet.org on December 18, 2024 by guest. Please see licensing information on first page for reuse rights.

TABLE 1 Typical plain chest radiography features suggestive of chronic silicosis, tuberculosis (TB) (active or post-tuberculous lung disease (PTLD)) and combined disease

	Silicosis [27, 42, 61, 104, 112]	TB# [111, 113]	Silicotuberculosis [28]
Small nodules/rounded opacities			
Morphology	Multiple, 1–10 mm diameter opacities (typically 2–6 mm)	Localised: sparse to multiple, varying sizes, typically >5–10 mm; miliary: uniform nodules 1–3 mm	Silicosis pattern may be evident in one or both lungs, but may be difficult to distinguish where post-TB distorts lung anatomy
Location, distribution	Bilateral symmetrical, upper and mid-zones, sparing apices and bases (“angel wing”) unless advanced	Localised: asymmetrical, upper and mid-zones including apices, with regional aggregation around other tuberculous changes; miliary: fills both lung fields	
Large opacities/fibrotic masses			
Morphology	PMF: range 10 mm to large masses; rounded, ovoid	Linear strands, focal or massive irregular opacities; may show cystic changes	Difficult to distinguish features of individual diseases; nodulation of silicosis may be asymmetrical
Location, distribution	Unilateral or bilateral, upper zones and mid-zones, sparing apices	Unilateral or bilateral, often upper zones involving apices, and mid-zones, with frequent tracheal deviation towards the more fibrotic lung	
Other features			
Active TB		Localised consolidation or infiltrates, cavities, adenopathy, pleural effusion; may be difficult to distinguish from PTLD; rapid changes over serial chest radiographs suggest activity; miliary TB as described above	Active TB complicating pre-existing silicotuberculosis may be particularly difficult to distinguish; in silica exposed, TB may present along broncho-vascular bundles (“hilar flare”) [61]
Adenopathy (mediastinal, hilar or lung) [114]	Bilateral, may have rim calcification but if uncalcified difficult to see on plain chest radiography	Unilateral, may also be calcified	Variable combination of both diseases
Pleural abnormalities	Uncommon on plain chest radiography	Common; unilateral effusion if active; in PTLD, unilateral or bilateral pleural fibrosis, as apical cap or basal	
Hyperinflation	Associated with PMF, may reflect coexistent dust-related COPD	Common with massive fibrosis or anatomical distortion of lung	

PMF: progressive massive fibrosis. #: features described are of post-primary TB.

https://doi.org/10.1183/16000617.0168-2024

Downloaded from https://publications.ersnet.org on December 18, 2024 by guest. Please see licensing information on first page for reuse rights.

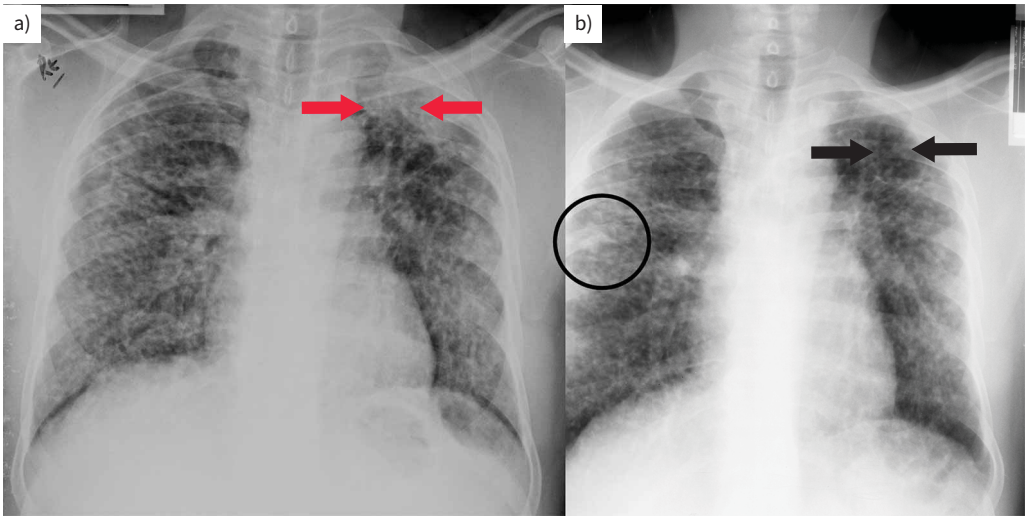

FIGURE 1 Serial chest radiographs demonstrating co-occurring silicosis and tuberculosis (TB) in a silica-exposed miner. History: former gold miner, diagnosed silicosis in 2000, culture-positive *Mycobacterium tuberculosis* and *M. kansasii* in 2005. a) Chest radiograph dated 16 October 2012, on repeat TB treatment (empirical). b) Chest radiograph dated 26 February 2013, post-TB treatment. The left upper zone opacification seen in a) (red arrows) is attributed to active TB infection with adjacent left apical pleural reaction. Following completion of treatment, this has resolved in b), leaving a residual thin-walled cavity (black arrows) as evidenced by a lucent region which has replaced the region of opacification. The dense nodular infiltrate noted in a) is unchanged in b) and mainly composed of small nodules (<10 mm; International Labour Organization (ILO) classification: r/q 3/2). Some large opacities (>10 mm) are noted in the periphery of the right upper zone (black circle) in b). These are consistent with silicosis (ILO classification: A) but post-TB fibrosis cannot be excluded.

Large fibrotic lesions (>10 mm in longest dimension) may occur due to silicosis, TB or combined disease. Previous chest radiographs may be helpful in identifying PMF by showing early coalescence of small opacities, with sequential chest radiographs showing medial migration over time. However, chest radiography differentiation between PMF and a large TB mass may be difficult, especially when there is a unilateral mass with surrounding fibronodular opacities.

In summary, even experienced readers may find it difficult to distinguish confidently between silicosis, PTLD, active TB and combined disease on plain chest radiography. Active TB can be confirmed bacteriologically, but the presence of active TB or PTLD does not eliminate silicosis as a co-diagnosis. Computer-aided detection tested against expert readers has shown promise in identifying silicotuberculosis but needs further validation in populations with high prevalences of both diseases [115]. In practice, the decision on whether silicotuberculosis is reported on the chest radiograph may depend on the level of certainty demanded of the reader. For example, the evidence threshold or workers' compensation eligibility is generally a balance of probabilities, *i.e.* a >50% likelihood that combined disease is present. In high TB settings, co-occurrence of silicosis with TB should always be considered in silica-exposed individuals presenting with suggestive chest radiography abnormalities.

CT of the chest

We could find no studies on the value of CT relative to plain chest radiography in the evaluation of individuals who may have both silicosis and TB (active or inactive). This may be due to the absence of a gold standard against which to compare the two techniques other than the pathology of large lung sections obtained near the time of imaging.

However, CT has been shown to be more sensitive than chest radiography in detecting silicosis [116, 117], and accompanying features such as PMF, pleural thickening and adenopathy, with greater inter-observer agreement on silicosis [118]. CT is also superior to chest radiography in distinguishing active and inactive TB [113]. Since the CT features of both conditions are well established [42, 111, 113, 119, 120], it is reasonable to assume that CT is valuable in distinguishing between individual and combined disease based

Downloaded from https://publications.ersnet.org on December 18, 2024 by guest. Please see licensing information on first page for reuse rights.

on the differing appearance and distribution of nodules, massive fibrosis and ancillary features. However, it is possible that the features of one or both diseases may be altered by the presence of the other.

Silicosis on CT is a predominantly posterior upper lobe disease with a perilymphatic distribution of nodular opacities (figure 2) [119]. Typically the silicotic nodules are discrete, solid and well defined. Active tuberculous nodules have a softer (lower attenuation/density) appearance, are irregular and centrilobular in distribution, with associated tree-in-bud opacities as a manifestation of the small airway spread of disease [119]. There may be coalescence, resulting in larger nodules or consolidation, and/or cavitation. Against a background of silicosis, features suggestive of supervening active disease are asymmetrical nodules or consolidation, cavitation or rapid progression [120]. Uncommonly, cavitation may occur within PMF due to ischaemic necrosis [121].

The lymph nodes in active TB on CT show peripheral rim enhancement with intravenous contrast and lower density centrally due to necrosis, with calcification being uncommon [114]. Nodes with inactive TB show calcification more frequently, and may be indistinguishable from silicotic nodes with calcification, either rim or of the central amorphous type [114]. While the presence of emphysema can complicate the detection of silicotic nodules on chest radiography, nodules can be easily distinguished from emphysema and related architectural changes on CT. Finally, although positron emission tomography/CT has been used in this context [39], on current data this imaging modality does not appear to be of value in distinguishing between PMF, TB and malignancy [122, 123]. Specifically, PMF has been shown to be hypermetabolic even without associated malignancy or TB [122].

Research is needed on the ability of chest CT to distinguish active and PTLD from silicosis and to identify concurrent disease. Such research may also help refine the reading of chest radiography images for underappreciated features.

Pathology

Lung biopsy is not a routine investigation for suspected silicotuberculosis. However, where tissue is available from biopsy, lung resection or autopsy, and particularly in settings with a high prevalence of silicosis and TB, the pathologist is still faced with the task of distinguishing silicosis, active TB, PTLD and silicotuberculosis, whether as discrete nodular disease or massive fibrosis or both. This task requires a detailed understanding of their similarity and differences.

When lung tissue is examined histologically, the term granuloma is occasionally used to describe the silicotic nodule [124]. This is not correct and careful attention to distinguishing features will prevent misinterpretation. The silicotic nodule exhibits a unique appearance (figure 3a): a central acellular zone of concentric whorled collagen fibres and a narrow peripheral margin of dust-laden macrophages [42, 125].

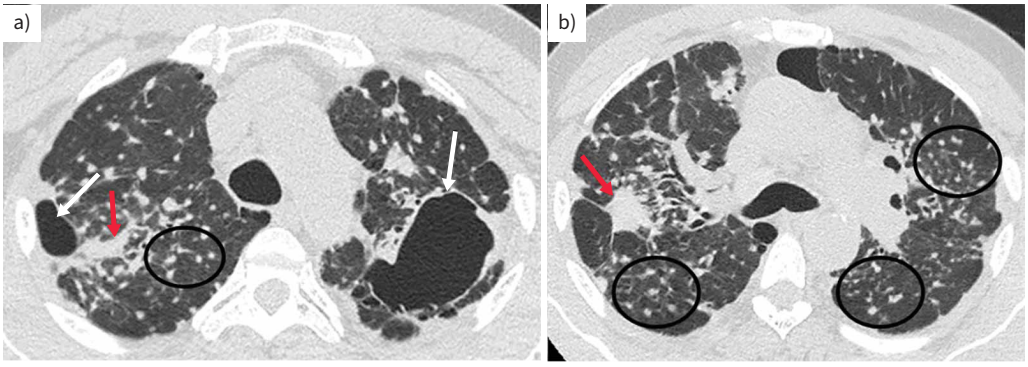

FIGURE 2 Chest computed tomography post-tuberculosis treatment dated 15 October 2013 (same patient as in figure 1). Selected axial images at the a) mid-thoracic tracheal level and b) tracheal carina show residual thin-walled cavities bilaterally, the left larger and visible on the chest radiographs. The background numerous small (<10 mm) nodular opacities are clustered and predominantly posterior (black ovals) and typical in location for silicotic nodules. Additionally there are multiple nodules studded along the pleural surface, also a typical location for silicotic nodules which are mainly perilymphatic in contrast to TB nodules which are bronchocentric. The larger (>10 mm) opacities are indicated by red arrows, image b) showing the peripheral para-cicatricial emphysema indicated by white arrows in image a) which is also a typical finding in patients with progressive massive fibrosis. b) Reproduced from [33] with permission.

Downloaded from https://publications.ersnet.org on December 18, 2024 by guest. Please see licensing information on first page for reuse rights.

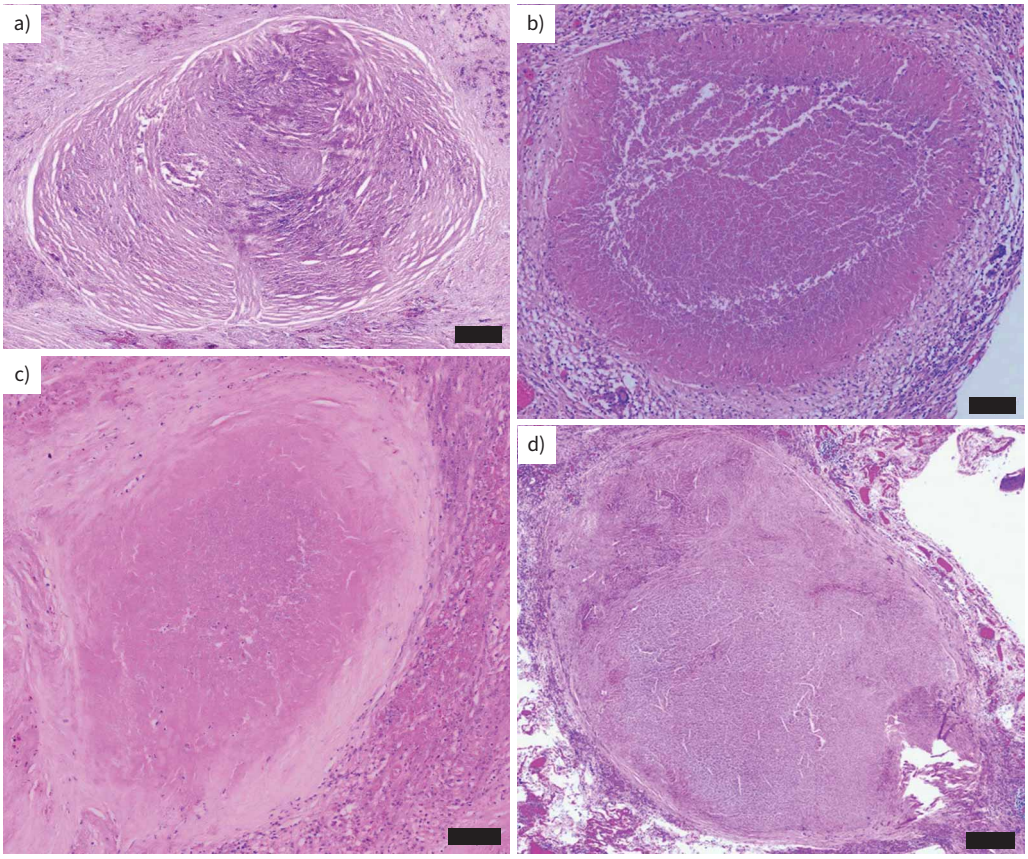

FIGURE 3 Histology images of silicosis and/or tuberculosis (TB) in lung tissue from silica-exposed ex-miners. Array of pulmonary lesions from two former gold miners who had autopsy examination of their lungs to determine the presence of occupational disease for compensation purposes: a, d) 60 years of age, 15 years of gold mining, with multiple nodules in both upper lobes; and b, c) 68 years of age, 17 years of gold mining, with bilateral upper lobe lesions. a) Classical rounded, well-circumscribed silicotic nodule, 5 mm in diameter, characterised by acellular collagen fibres. b) Active tuberculous granuloma with central necrosis and a marginal zone of inflammatory cells including multinucleate Langhans giant cells; Ziehl–Neelsen stain positive for numerous acid-fast bacteria (not shown). c) Inactive TB in which the necrotic zone is surrounded by an acellular rim of collagen; Ziehl–Neelsen stain negative. d) Nodule randomly sampled from the upper lobe; central necrosis with a margin of collagenous fibrosis; acid-fast bacilli absent; consistent with silicosis with ischaemic necrosis or with inactive TB. Haematoxylin/eosin stain. Scale bars: 400 μm. Courtesy of the National Institute for Occupational Health, National Health Laboratory Service, Johannesburg, South Africa.

Under polarised light, silica particles, which are weakly birefringent, may be seen but their absence does not exclude silicosis. Strong birefringence is more accurately attributed to accompanying silicates such as mica and talc [125]. There is wide agreement among pathologists that granulomatous inflammation is not a feature of the silicotic nodule on its own, and when present another process (alone or concurrent with silicosis), in particular TB, should be excluded [125–127].

In contrast to silicosis, active TB is a granulomatous disease in which the characteristic lesion displays central necrosis surrounded by elongated epithelioid macrophages, some of which fuse to form multinucleate Langhans giant cells, admixed with lymphocytes (figure 3b) [128]. On occasion granulomas may be non-necrotising, or both lesions may be found. While mycobacterial infection is the commonest cause of pulmonary necrotising granulomatous inflammation, the differential diagnosis is wide [129, 130]. It includes infections, typically fungi such as *Histoplasma* and *Coccidioides*, and less commonly non-infectious disorders such as granulomatosis with polyangiitis. Sarcoid is the commonest non-necrotising granulomatous disease [131].

Culture of *M. tuberculosis* within the lesion, where fresh tissue is available, remains the gold standard for tissue diagnosis [132]. The Ziehl–Neelsen stain is still frequently used in formalin-fixed paraffinised tissue,

Downloaded from https://publications.ersnet.org on December 18, 2024 by guest. Please see licensing information on first page for reuse rights.

but it is only positive if there is a sufficient bacterial load [133]. More recently, molecular techniques utilising nucleic acid amplification have been utilised for tissue diagnosis. However, their use in tissue is typically restricted to pathology reference centres and they have not yet replaced culture in tissue analysis in the TB laboratory [134, 135].

Regarding its natural evolution, the TB granuloma may resolve completely, leave a residual small irregular scar or progress to frank cavitation. However, a frequent host response is for fibrous tissue to wall off the active inflammatory focus (figure 3c). This ensuing inactive lesion comprises central necrosis, an absence of inflammatory cells and a surrounding rim of fibrosis comprising concentric acellular collagen fibres [128]. Silicotic nodules rarely show central ischaemic necrosis [125, 136] but should this occur, a silicotic nodule would be indistinguishable from that of PTLD (figure 3d).

PMF is characterised by the conglomeration of silicotic nodules to form a mass ranging from 1 cm to many centimetres within which ischaemic cavitation may occur [125, 126, 137]. TB on occasion progresses to result in large masses comprising admixtures of active or inactive disease, with varying proportions of necrosis and cavitation. Masses may also be the result of combined disease, whereby the tuberculous inflammatory process, together with necrosis, cavitation and fibrosis, contributes to conglomeration of discrete silicotic nodules [56, 126, 138].

In summary, while silicosis and TB may occur on their own, in settings where these conditions are common it is not unusual to encounter combined disease. The histological appearance in such cases is variable. Interspersed with silicotic nodules, there may be signs of active and/or inactive TB or an admixture of both. Given the importance and difficulty of distinguishing between silicosis and TB, both active and inactive, there is a need for research into practical nucleic acid amplification tests for the tissue diagnosis of TB in both fresh and formalin-fixed tissue which can be reliably utilised in low-resource settings.

Other investigations

Other potentially useful investigative techniques for silicotuberculosis are endobronchial ultrasound-guided transbronchial needle aspiration (EBUS-TBNA) and EBUS mediastinal cryobiopsy. These are minimally invasive procedures used to sample tissue, especially mediastinal and hilar lymph nodes [139, 140]. However, research on their diagnostic utility for silicotuberculosis is scant [141].

Lung function testing provides assessment of impairment in silicotuberculosis but is not diagnostic. Any combination of obstructive and restrictive dysfunction may be expected on spirometry, depending on the degree of co-occurrence of nodular silicosis, PMF, active TB and/or PTLD [79], as well as of emphysema, chronic bronchitis and/or small airways disease [142]. Diffusing capacity of the lung for carbon monoxide (D_{LCO}) is correlated with the extent of radiological disease in silicosis as determined on CT [143] and is a common sequela of treated TB [144, 145]. D_{LCO} testing therefore has a role in the assessment of impairment in silicotuberculosis, particularly where spirometric findings are discordantly normal or mild in relation to the extent of chest radiograph abnormality and/or symptoms.

Screening

Screening of silica-exposed populations for silicosis is well established in many jurisdictions [146]. Populations exposed to silica (currently or in the past) have been identified by the World Health Organization (WHO) for priority TB screening [7]. The most recent guidance recommends rapid tools for TB screening, namely symptom screening, chest radiography, computer-aided detection software and molecular WHO-approved rapid diagnostic tests (predominantly Xpert MTB/RIF and Xpert MTB/RIF Ultra) [7, 101]. The WHO guidelines, or any others to our knowledge, do not identify tools specifically for TB screening in individuals with silicosis. This may change with the recent demonstration of the ability of chest radiography computer-aided detection to identify silicosis and TB in a population with a high prevalence of both diseases [115].

While the last decade has seen a renewed emphasis on chest radiography screening for TB [100], the occupational context needs to be taken into account. For example, among gold miners subject to regular screening in the pre-HIV treatment era in South Africa, sensitivity of chest radiography was very low [102]. More recently, in former gold miners not subject to regular screening, chest radiography has been shown to have high sensitivity but low specificity for Xpert MTB/RIF as the reference standard, particularly in the presence of silicosis or PTLD [147]. However, in regions where migrant ex-miners live or where there are large numbers of artisanal or small-scale miners or other silica-exposed workers far from established services, mobile chest radiography with computer-aided detection followed by rapid molecular testing in those with abnormal chest radiography are screening options [101].

Downloaded from https://publications.ersnet.org on December 18, 2024 by guest. Please see licensing information on first page for reuse rights.

The evidence base for the frequency of screening for TB in silica-exposed individuals is scant. The WHO guidelines on screening [7] recommend a screening interval of no longer than 12 months where possible. However, this frequency is impractical for those currently unemployed or working in sectors not subject to medical surveillance. Local jurisdictions may have guides or tools to inform screening silica-exposed individuals for TB [148].

Treatment

Prior to the rifampicin era several studies documented poorer TB treatment outcomes in patients with silicosis [112]. Subsequent trials and observational studies of short-course therapy have yielded conflicting evidence. A South African clinical trial of 5 months of chemotherapy published in 1984 found no difference in relapse between gold miners with silicotuberculosis and two groups with TB only [149]. A similar finding was made in a related observational study with longer follow-up and a larger number of controls (relapse proportions 8.5% *versus* 5.9% in silicotuberculosis and TB, respectively; p=0.35) [150]. More frequent relapse with a significant difference between groups was, however, recorded in a further follow-up (silicotuberculosis 17% *versus* TB 11%; rate ratio 1.55 (95% CI 0.97–2.48)) [151]. Interpretation of these studies is complicated by substantial loss to follow-up of miners who left service during TB treatment or for other reasons before study completion, a feature of the migratory nature of mine labour, and by statutory exclusion requirements for fitness for dusty work.

A second clinical trial involving only individuals with silicosis, published from Hong Kong in 1991, found a higher TB relapse proportion among those treated for 6 months than those treated for 8 months (22% *versus* 7%; p<0.025) [152]. In a recent TB patient follow-up in India, patients with silicosis (mostly drug sensitive and treated for 6 months) suffered a much higher proportion of poor treatment outcomes (39% *versus* 18%) and relapses (59% *versus* 20%) than controls with TB only [86]. The Hong Kong trial finding was the basis of a subsequent recommendation for 8 months of TB treatment in 2012 [153]. Surprisingly, no subsequent clinical trials have been published, and the recommendation for prolongation of treatment is absent from recent expert consensus statements [154, 155].

Studies of treatment outcomes and recurrence rates following standard TB treatment regimens, and if indicated longer regimens, in individuals with silicosis are needed. It has been speculated that a set of mechanistic factors, notably oxidative and nitrosamine stress, similar to those found in TB co-occurring with diabetes and HIV infection might contribute to treatment failure in silicosis [43]. Accordingly, treatment of TB in silicosis may be a priority target for adjunct treatment with antioxidants or other host-directed therapies.

While comprehensive frameworks for the management of PTLD have recently been published [48, 156], co-occurrence of silicosis and TB is likely to complicate management options for PTLD. Silicosis may exacerbate the degree and progression of lung fibrosis and of functional impairment associated with PTLD, aggravating prognosis and mortality risk relative to TB on its own, as described in an earlier section. It is important that clinicians take an occupational history in relevant settings and are aware of the implications of both subradiological silicosis [157] and frank silicosis in managing these patients.

Prevention

Primary prevention of silicotuberculosis requires control or limitation of respirable silica exposure and reduction of risks for TB transmission such as congregate living settings, untreated HIV infection and delayed TB treatment initiation. Since there is no currently accepted means of clinically reversing fibrosis in those with silicosis, secondary prevention involves mainly medically lowering the risk of TB through TB preventive treatment (TPT) and limiting further silica exposure, both discussed in the following sections. Smoking cessation may also contribute to reduction in TB infection and disease risk [158] and TB mortality in individuals with silicosis [159].

TB preventive treatment

Starting with long-term isoniazid treatment in the late 1950s [160], TPT has been shown to reduce the risk of active TB disease in silicosis [161,162], although not universally so [163]. In the case of silica exposure without reference to silicosis, long-term effectiveness of short-course TPT in high TB burden occupational settings is questionable. A mass trial of 9 months of isoniazid in silica-exposed gold miners without reference to silicosis status found that the substantial reduction in mine TB incidence due to isoniazid was not sustained during the 12-month post-treatment period [164, 165]. A subanalysis of miners with silicosis found a similar effect of isoniazid on TB risk, but lacked the statistical power to draw robust conclusions [166].

Downloaded from https://publications.ersnet.org on December 18, 2024 by guest. Please see licensing information on first page for reuse rights.

Guides for TPT in silicosis have been published [40, 167–169]. The WHO consolidated guideline [170] recommends that individuals with silicosis should be tested and treated for LTBI, and describes several treatment options depending on the level of community TB transmission and HIV status. Testing for LTBI with interferon-γ release assay or tuberculin skin test before starting TPT is generally recommended but local guides should be consulted as recommendations vary, as do the regimens [40, 168–170]. Logistical demands on patients and health services providing TPT, *e.g.* monthly clinic attendance, and treatment-related adverse events [171] may be disincentives for such programmes, especially in resource-poor settings and for workers not covered by occupational health services. Recently recommended shorter rifampicin-based regimens could lower some of the implementation barriers [172] and reduce adverse events.

Silica exposure limitation or cessation

Limitation of silica exposure can be achieved by reduction of airborne respirable concentrations [173], work re-organisation to limit dusty tasks, use of effective respiratory protective equipment and deployment of the individual to low-exposure jobs or removal from continued silica dust exposure. In formal workplaces, these are employer responsibilities requiring the application of the hierarchy of occupational hygiene controls [174]. These require enforcement through regulatory control and inspection. In unregulated, small-scale settings, educational and resource support programmes involving state agencies, worker organisations and workers are needed [175].

However, since the concentration of silica exposure below which there is no materially increased risk of TB is unknown [8] and silicosis may not be visible on chest radiography in almost 60% of cases of autopsy-positive silicosis [157], it cannot be assumed that preventing radiological silicosis will eliminate the excess TB risk due to dust exposure. It is probable that lungs sufficiently silicised to result in subradiological silicosis are at lifelong increased risk of TB irrespective of additional exposure [176].

While total cessation of silica exposure in individuals diagnosed has been recommended [177–179], there is limited evidence to support a blanket approach [180]. More considered, stepwise recommendations are now available [180]. With regard to modification of TB risk following cessation of silica exposure, we could find only one study: a retrospective analysis of claimants with silicosis in a legal action showed an increased odds of TB (OR 4.61 (95% CI 1.14–18.71)) in those who had continued exposure relative those who had stopped [181]. This question is relevant to management of affected employees, post-employment surveillance and compensation. Long-term cohort studies able to control for selection factors such as disease status at time of diagnosis, differential mortality and loss to observation are needed. With regard to compensation, although the International Labour Organization recommended list of occupational diseases has long included silicotuberculosis [182], the ability of affected workers to secure compensation for this condition is unknown.

Discussion and conclusion

Despite advances in dust control in developed countries and worldwide programmes to provide effective TB treatment, silicotuberculosis remains a global problem. We have proposed a broader definition of silicotuberculosis than frequently used, to include PTLD and not only active TB. While there is a large literature on silicosis from recent decades, clinical and epidemiological interest in silicotuberculosis has failed to match the size of the problem, such that fundamental questions about the diagnosis, treatment and prevention of combined disease persist. Understanding the interaction of the two disease processes is central to answering these questions. In this regard, potentially important questions and insights can be found in literature from the pre-TB treatment era. Increased funding and the building of research groups able to sustain the long-term effort required for mechanistic and cohort studies and clinical trials are needed.

Questions for future research

- Cohort studies to characterise the prevalence and severity of PTLD in individuals with silicosis, the rates and determinants of progression of combined disease, and the effects of different temporal sequences of TB infection, TB disease and silicosis.
- Cohort studies of LTBI able to control for confounding factors in the hypothesised causal association between silicosis and LTBI.
- Validation of the use of nucleic acid amplification tests for the tissue diagnosis of TB in fresh and formalin-fixed tissue.
- Characterisation of how features of combined disease on plain chest radiography and CT modify each other.

Downloaded from https://publications.ersnet.org on December 18, 2024 by guest. Please see licensing information on first page for reuse rights.

- Trials of effectiveness of different treatment regimens for TB in silicosis.
- Trials of effectiveness of different TPT regimens in silicosis, and operational studies of feasibility and uptake.
- Effect of cessation of silica exposure on silicosis progression, TB risk, employment and quality of life, including adequacy of social security.
- The workplace respirable silica concentration that does not result in excess TB attributable to silica dust.

Provenance: Submitted article, peer reviewed.

Acknowledgements: We thank Naomi Walker (Department of Clinical Sciences and Centre for TB Research, Liverpool School of Tropical Medicine, Liverpool, UK), for comments on a draft of the article, and Joy Oliver (Health Systems Research Unit, South African Medical Research Council, Cape Town, South Africa), for conducting the literature search.

Author contributions: All authors participated in the conception and preparation of the article, and reviewed and approved the final version.

Conflict of interest: R. Ehrlich and D. Rees have written expert reports for plaintiff attorneys in silicosis legislation. The other authors declare no conflicts of interest.

References

1 Hoy RF, Jeebhay MF, Cavalin C, *et al.* Current global perspectives on silicosis – convergence of old and newly emergent hazards. *Respirology* 2022; 27: 387–398.
2 Chen S-Y, Hayes RB, Wang JM, *et al.* Nonmalignant respiratory disease among hematite mine workers in China. *Scand J Work Environ Health* 1989; 15: 319–322.
3 Cheepsattayakorn A, Cheepsattayakorn R. Silicosis-associated tuberculosis: management and control. *Am J Public Health Res* 2018; 6: 125–129.
4 Maboso BM, Moyo DM, Muteba KM, *et al.* Burden of disease among Basotho ex-miners in a large out-reach medical assessment programme. *Occup Health South Afr* 2020; 26: 145–152.
5 Nandi SS, Dhatrak SV, Sarkar K. Silicosis, progressive massive fibrosis and silico-tuberculosis among workers with occupational exposure to silica dusts in sandstone mines of Rajasthan state: an urgent need for initiating national silicosis control programme in India. *J Family Med Prim Care* 2021; 10: 686–691.
6 Carneiro APS, Teixeira VDSP, Silveira AM, *et al.* Non-malignant silica-related diseases in a specialized outpatient clinic. *Occup Med* 2022; 72: 394–402.
7 World Health Organization. Consolidated guidelines on tuberculosis. Module 2: Screening – systematic screening for tuberculosis disease. 2021. https://iris.who.int/bitstream/handle/10665/340255/9789240022676-eng.pdf Date last accessed: 11 October 2024.
8 Ehrlich R, Akugizibwe P, Siegfried N, *et al.* Silica exposure, silicosis and tuberculosis – a systematic review. *BMC Public Health* 2021; 21: 953.
9 Watt AH, Irvine LG, Johnson JP, *et al.* Silicosis ("miners' phthisis") on the Witwatersrand. *South Afr Med Rec* 1916; 14: 276–283.
10 Collis EL. Industrial pneumoconiosis with special reference to dust-phthisis. *Public Health* 1915; 28: 292–305.
11 Benson L. Silicotuberculosisis. *N Engl J Med* 1940; 223: 398–407.
12 O'Neill RP, Robin ED. Relations of pneumoconiosis and pulmonary tuberculosis. *Arch Environ Health* 1964; 8: 873–871.
13 Meikeljohn A. The clinical and epidemiological aspects of the role of tuberculosis in pneumoconiosis. *In:* Orenstein AJ, ed. Proceedings of the Pneumoconiosis Conference, Johannesburg, 1959. London, Churchill, 1960; pp. 325–337.
14 International Labour Office. Silicosis. Records of the International Conference held at Johannesburg, 13–27 August 1930. 1930. www.ilo.org/public/libdoc/ilo/ILO-SR/ILO-SR_F13_engl.pdf Date last accessed: 13 March 2024.
15 Schepers GWH. Silicosis and tuberculosis. *Ind Med Surg* 1964; 33: 381–399.
16 Rosner D, Markowitz G. Consumption, silicosis, and the social construction of industrial disease. *Yale J Biol Med* 1991; 64: 481–498.
17 Baldasseroni A, Carnevale F. The genesis and development of the scientific concept of pulmonary silicosis during the nineteenth century. *In:* Rosental PA, ed. Silicosis: A World History. Baltimore, Johns Hopkins University Press, 2016; pp. 30–63.
18 Rosental PA. Truncating a disease. The reduction of silica hazards to silicosis at the 1930 International Labor Office Conference on Silicosis in Johannesburg. *Am J Ind Med* 2015; 58: S6–S14.

Downloaded from https://publications.ersnet.org on December 18, 2024 by guest. Please see licensing information on first page for reuse rights.

19 Kettle EH, Archer HE. The differential diagnosis of tuberculo-silicosis. *Proc Royal Soc Med* 1933; 26: 811–824.
20 Pancoast, K, Pendergrass EP, Riddell AR, *et al.* Roentgenological appearances in silicosis and the underlying pathological lesions. *Public Health Rep* 1935; 50: 989–996.
21 Howlett KR Jr, Warring FC Jr. Response to treatment in silicotuberculosis; a ten-year survey. *Arch Environ Health* 1964; 9: 343–354.
22 Irvine LG. Control of silicosis in industry in South Africa. *Br Med J* 1932; 1: 693–698.
23 Taylor H, Alexander H. Silicosis and silicotuberculosis. *JAMA* 1938; 111: 400–408.
24 Gardner LU. The similarity of the lesions produced by silica and by the tubercle bacillus. *Am J Pathol* 1939; XIII: 13–22.
25 Du Toit FS. Tuberculo-silicosis. *S Afr Med J* 1954; 28: 845–850.
26 Cherniack MG. Pancoast and the image of silicosis. *Am J Ind Med* 1990; 18: 599–612.
27 Solomon A. Silicosis and tuberculosis: part 2 – a radiographic presentation of nodular tuberculosis and silicosis. *Int J Occup Environ Health* 2001; 7: 54–57.
28 Maboso B, Rees D, te Water Naude J, *et al.* Difficulties in distinguishing silicosis and pulmonary tuberculosis in silica exposed gold miners – a report of four cases. *Am J Ind Med* 2023; 66: 339–348.
29 Nasrullah M, Mazurek JM, Wood JM, *et al.* Silicosis mortality with respiratory tuberculosis in the United States, 1968–2006. *Am J Epidemiol* 2011; 174: 839–848.
30 Martins P, Marchiori E, Zanetti G, *et al.* Cavitated conglomerate mass in silicosis indicating associated tuberculosis. *Case Rep Med* 2010; 2010: 293730.
31 Dennis E, Mussa H, Sanga MP, *et al.* Silicosis and silicotuberculosis among respiratory hospital admissions: a cross-sectional survey in northern Tanzania. *Afr J Thorac Crit Care Med* 2023; 29: e269.
32 Constandina C, Raşcu A, Trăilescu AM, *et al.* Pulmonary silicotuberculosis in an electrician male – case report and literature review. *Ars Med Tomitana* 2012; 3: 140–145.
33 Oni, T, Ehrlich R. Complicated silicotuberculosis in a South African gold miner: a case report. *Am J Ind Med* 2015; 58: 697–701.
34 Farazi A, Jabbariasl M. Silico-tuberculosis and associated risk factors in central province of Iran. *Pan Afr Med J* 2015; 20: 333.
35 Moyo D, Kgalamono S. Diagnostic challenges of silico-tuberculosis in a case with progressive massive fibrosis – a Zimbabwe case report. *Occup Health South Afr* 2017; 23: 11–13.
36 Skowroński M, Halicka A, Barinow-Wojewódzki A, *et al.* Pulmonary tuberculosis in a male with silicosis. *Adv Respir Med* 2018; 86: 121–125.
37 Khemakhem R, Moussa N, Kotti A, *et al.* Accelerated silicosis and silico-tuberculosis: a difficult diagnosis. *Clin Case Rep* 2022; 10: e05482.
38 Djatioetomo YCED, Marhana IA. Deadly dust: silicotuberculosis as a downplayed and overlooked fatal disease in Indonesia. *Ann Med Surg* 2022; 78: 103794.
39 D'Sa L, Pezzuto F, Lunardi F, *et al.* Complex case of pulmonary silico-tuberculosis and review of literature. *Diagnostics* 2023; 13: 2728.
40 Barboza CEG, Winter DH, Seiscento M, *et al.* Tuberculosis and silicosis: epidemiology, diagnosis and chemoprophylaxis. *J Bras Pneumol* 2008; 34: 961–968.
41 Lanzafarme M, Vento S. Mini-review: silico-tuberculosis. *Clin Tuberc Other Mycobact Dis* 2021; 23: 100218.
42 Rees D, Murray J. Silica. *In:* Taylor AN, Cullinan P, Blanc P, *et al.*, eds. Parkes' Occupational Lung Disorders. 4th Edn. Boca Raton, CRC Press, 2017; pp. 187–205.
43 Yew WW, Leung CC, Chang KC, *et al.* Can treatment outcomes of latent TB infection and TB in silicosis be improved? *J Thorac Dis* 2019; 11: E8–E10.
44 Konecny P, Ehrlich R, Gulumian M, *et al.* Immunity to the dual threat of silica and *Mycobacterium tuberculosis*. *Front Immunol* 2019; 9: 3069.
45 Balmes J. Commentary for JOEM Forum – Silicosis: then and now. *J Occup Environ Med* 2017; 59: 222–223.
46 Gloyne R. Indolent tuberculosis. *Tubercle* 1946; 27: 106–109.
47 Meghji J, Simpson H, Squire SB, *et al.* A systematic review of the prevalence and pattern of imaging defined post-TB lung disease. *PLoS One* 2016; 11: e0161176.
48 Rachow A, Walker NF, Allwood B, *et al.* The challenge of post-tuberculosis lung disease. *In:* García-Basteiro AL, Öner Eyüboğlu F, Rangaka MX, eds. The Challenge of Tuberculosis in the 21st Century (ERS Monograph). Sheffield, European Respiratory Society, 2023; pp. 191–209.
49 Cool CD, Murray J, Vorajee NI, *et al.* Pathologic findings in severe coal workers' pneumoconiosis in contemporary US coal miners. *Arch Pathol Lab Med* 2023; 148: 805–817.
50 Jin Y, Fan JG, Pang J, *et al.* Risk of active pulmonary tuberculosis among patients with coal workers' pneumoconiosis: a case-control study in China. *Biomed Environ Sci* 2018; 31: 448–453.
51 Brouwer DH, Rees D. Can the South African milestones for reducing exposure to respirable crystalline silica and silicosis be achieved and reliably monitored? *Front Public Health* 2020; 8: 107.
52 Kromhout H. Hygiene without numbers. *Ann Occup Hyg* 2016; 60: 403–404.
53 Narasimhan P, Wood J, MacIntyre CR, *et al.* Risk factors for tuberculosis. *Pulm Med* 2013; 2013: 828939.

Downloaded from https://publications.ersnet.org on December 18, 2024 by guest. Please see licensing information on first page for reuse rights.

54 Corbett EL, Churchyard GJ, Clayton TC, *et al.* HIV infection and silicosis: the impact of two potent risk factors on the incidence of mycobacterial disease in South African miners. *AIDS* 2000; 14: 2759–2768.
55 Morgan K. The relationship between silicosis and tuberculosis. *Am Rev Respir Med* 1979; 110: 319–320.
56 Ng TP, Chan SL. Factors associated with massive fibrosis in silicosis. *Thorax* 1991; 46: 229–232.
57 Chang KC, Leung CC, Tam CM. Tuberculosis risk factors in a silicotic cohort in Hong Kong. *Int J Tuberc Lung Dis* 2001; 5: 177–184.
58 Ferreira AS, Moreira VB, Ricardo HMV, *et al.* Progressive massive fibrosis in silica-exposed workers. High-resolution computed tomography findings. *J Bras Pneumol* 2006; 32: 523–528.
59 Mavrogordato A. The mode of action of dust in relation to respiratory disease. *South Afr Med Rec* 1922; 24: 226–228.
60 Charalambous S, Churchyard GJ, Murray J, *et al.* Persistent radiological changes following miliary tuberculosis in miners exposed to silica dust. *Int J Tuberc Lung Dis* 2001; 5: 1044–1050.
61 Solomon A, Rees D, Felix M, *et al.* Silicosis and tuberculosis: a proposed radiographic classification of tuberculosis to accompany the ILO international classification of radiographs of pneumoconiosis. *Int J Occup Environ Health* 2000; 6: 215–219.
62 Hanifa Y, Grant AD, Lewis J, *et al.* Prevalence of latent tuberculosis infection among gold miners in South Africa. *Int J Tuberc Lung Dis* 2009; 13: 39–46.
63 Yang Q, Lin M, He Z, *et al. Mycobacterium tuberculosis* infection among 1,659 silicosis patients in Zhejiang Province, China. *Microbiol Spectr* 2022; 10: e0145122.
64 Rupani MP, Balachandar R, Kharkwal G, *et al.* Mixed methods study on latent tuberculosis among agate stone workers and advocacy for testing silica dust exposed individuals in India. *Sci Rep* 2024; 14: 13830.
65 Ringshausen FC, Nienhaus A, Schablon A, *et al.* Frequent detection of latent tuberculosis infection among aged underground hard coal miners in the absence of recent tuberculosis exposure. *PLoS One* 2013; 8: e82005.
66 Girdler-Brown, B, Ehrlich RI, White NW, *et al.* The burden of silicosis, tuberculosis and COPD among former Basotho gold miners. *Am J Ind Med* 2008; 51: 640–647.
67 Tiwari R, Narain R, Sharma Y, *et al.* Comparison of respiratory morbidity between present and ex-workers of quartz crushing units: healthy workers' effect. *Indian J Occup Environ Med* 2010; 14: 87–90.
68 Moyo D, Ncube R, Kavenga F, *et al.* The triple burden of tuberculosis, human immunodeficiency virus and silicosis among artisanal and small-scale miners in Zimbabwe. *J Environ Res Public Health* 2022; 19: 13822.
69 Howlett P, Mousa H, Said B, *et al.* Silicosis, tuberculosis and silica exposure among artisanal and small-scale miners: a systematic review and modelling paper. *PLoS Glob Public Health* 2023; 3: e0002085.
70 Hayton C, Hoyle J. Silicosis and mycobacterium disease: is it a problem in the UK? *Thorax* 2017; 72: Suppl. 3, A203–A205.
71 Cronin KM, Rees MA, Tay EL, *et al.* TB in stonemasons in Australia. *Int J Tuberc Lung Dis* 2020; 24: 966–968.
72 Bakan ND, Özkan G, Çamsari G, *et al.* Silicosis in denim sandblasters. *Chest* 2011; 140: 1300–1304.
73 Bhagia LJ. Non-occupational exposure to silica dust. *Indian J Occup Environ Med* 2012; 16: 95–100.
74 Turner MH, Martin WJ. Mortality and survival rates in males with silicosis or silico-tuberculosis. *Br Med J* 1949; 2: 1148–1150.
75 Morgan EJ. Silicosis and tuberculosis. *Chest* 1979; 75: 202–203.
76 Park HH, Girdler-Brown BV, Ehrlich RI, *et al.* Incidence of tuberculosis and HIV and progression of silicosis and lung function impairment among former Basotho gold miners. *Am J Ind Med* 2009; 52: 901–908.
77 Lee S, Phoon WH, Ng TP. Radiological progression and its predictive risk factors in silicosis. *Occup Environ Med* 2011; 58: 467–471.
78 Ehrlich RI, Myers JE, te Water Naude J, *et al.* Lung function loss in relation to silica exposure among South African gold miners. *Occup Environ Med* 2011; 68: 96–101.
79 Ivanova O, Hoffmann VS, Lange C, *et al.* Post-tuberculosis lung impairment: systematic review and meta-analysis of spirometry data from 14 621 people. *Eur Respir Rev* 2023; 32: 220221.
80 Hnizdo E, Singh T, Churchyard G. Chronic pulmonary function impairment caused by initial and recurrent pulmonary tuberculosis following treatment. *Thorax* 2000; 55: 32–38.
81 Goldsmith DF, Beaumont JJ, Morrin LA, *et al.* Respiratory cancer and other chronic disease mortality among silicotics in California. *Am J Ind Med* 1995; 28: 459–467.
82 Churchyard GJ, Kleinschmidt I, Corbett EL, *et al.* Factors associated with an increased case-fatality rate in HIV-infected and non-infected South African gold miners with pulmonary tuberculosis. *Int J Tuberc Lung Dis* 2000; 4: 705–712.
83 Carta P, Aru G, Manca P. Mortality from lung cancer among silicotic patients in Sardinia: an update study with 10 more years of follow up. *Occup Environ Med* 2001; 58: 786–793.
84 Calvert GM, Rice FL, Boiano JM, *et al.* Occupational silica exposure and risk of various diseases: an analysis using death certificates from 27 states of the United States. *Occup Environ Med* 2003; 60: 122–129.
85 Hatman EA, Karagül DA, Oyman EK, *et al.* Premature deaths due to silicosis in Turkey, 2006–2017: a twelve-year longitudinal study. *Balkan Med J* 2021; 38: 374–381.

Downloaded from https://publications.ersnet.org on December 18, 2024 by guest. Please see licensing information on first page for reuse rights.

86 Rupani MP. A mixed-methods study on impact of silicosis on tuberculosis treatment outcomes and need for TB-silicosis collaborative activities in India. *Sci Rep* 2023; 13: 2785.

87 Diez M, Bleda MJ, Alcaide J, *et al.* Determinants of health system delay among confirmed tuberculosis cases in Spain. *Eur J Public Health* 2005; 15: 343–349.

88 van Heerden JK, Louw EH, Thienemann F. The prevalence of pulmonary hypertension in post-tuberculosis and active tuberculosis populations: a systematic review and meta-analysis. *Eur Respir Rev* 2024; 33: 230154.

89 Kumari J, Advani M, Purohit G. Prevalence of pulmonary hypertension in chronic simple silicosis patients and its correlation with smoking history, occupation type, age and duration of silica exposure. *Monaldi Arch Chest Dis* 2023; in press [https://doi.org/10.4081/monaldi.2023.2719].

90 Cowie RL, Hay M, Glyn Thomas R. Association of silicosis, lung dysfunction, and emphysema in gold miners. *Thorax* 1993; 48: 746–749.

91 Murray J, Reid G, Kielkowski D, *et al.* Cor pulmonale and silicosis: a necropsy based case-control study. *Br J Ind Med* 1993; 50: 544–548.

92 Gulumian M, Khoali LM, Vetten M. An Investigation of the Mechanisms Involved in Increased Susceptibility to Mycobacterial Infection of Silica Exposed Individuals. Final Report: SIM 05 06 02. Pretoria, Mine Health and Safety Council, 2009.

93 Allison AC, Hart PD. Potentiation by silica of the growth of *Mycobacterium tuberculosis* in macrophage cultures. *Br J Exp Pathol* 1968; 49: 465–476.

94 Benmerzoug S, Bounab B, Rose S, *et al.* Sterile lung inflammation induced by silica exacerbates *Mycobacterium tuberculosis* infection via STING-dependent type 2 immunity. *Cell Rep* 2019; 27: 2649–2664.

95 Pasula R, Britigan BE, Turner J, *et al.* Airway delivery of silica increases susceptibility to mycobacterial infection in mice: potential role of repopulating macrophages. *J Immunol* 2009; 182: 7102–7109.

96 Dong H, Jing W, Yabo Y. Establishment of rat model of silicotuberculosis and its pathological characteristic. *Pathog Glob Health* 2014; 108: 312–316.

97 Chávez-Galán L, Ramon-Luing LA, Torre-Bouscoulet L, *et al.* Pre-exposure of *Mycobacterium tuberculosis*-infected macrophages to crystalline silica impairs control of bacterial growth by deregulating the balance between apoptosis and necrosis. *PLoS One* 2013; 8: e80971.

98 Karpov MA, Skurupiy VA, Nadeev AP. Analysis of fibrotic depositions in granulomas in chronic silicotuberculosis in mice. *Bull Exp Biol Med* 2010; 149: 659–662.

99 Lewinsohn DM, Leonard MK, LoBue PA, *et al.* Official American Thoracic Society/Infectious Diseases Society of America/Centers for Disease Control and Prevention clinical practice guidelines: diagnosis of tuberculosis in adults and children. *Clin Infect Dis* 2017; 64: 111–115.

100 World Health Organization. Chest radiography in tuberculosis detection – summary of current WHO recommendations and guidance on programmatic approaches. 2016. https://iris.who.int/bitstream/handle/10665/252424/9789241511506-eng.pdf Date last accessed: 11 October 2024.

101 World Health Organization. Consolidated guidelines on tuberculosis. Rapid diagnostics for tuberculosis detection. Module 3: Diagnosis. 2021 update. 2021. https://iris.who.int/bitstream/handle/10665/376221/9789240089488-eng.pdf Date last accessed: 11 October 2024.

102 Lewis J, Charalambous S, Day J, *et al.* HIV infection does not affect active case finding of tuberculosis in South African gold miners. *Am J Respir Crit Care Med* 2009; 180: 1271–1278.

103 Horne DJ, Kohli M, Zifodya JS, *et al.* Xpert MTB/RIF and Xpert MTB/RIF Ultra for pulmonary tuberculosis and rifampicin resistance in adults. *Cochrane Database Syst Rev* 2019; 6: CD009593.

104 Solomon A, Rees D. Back to basics – the chest radiograph in silica associated tuberculosis. *Occup Health South Afr* 2010; 16: 25–27.

105 McCarthy K, Fielding K, Churchyard GJ, *et al.* Empiric tuberculosis treatment in South African primary health care facilities – for whom, where, when and why: implications for the development of tuberculosis diagnostic tests. *PLoS One* 2018; 13: e0191608.

106 Kendall EA, Kamoga C, Kitonsa PJ, *et al.* Empiric treatment of pulmonary TB in the Xpert era: correspondence of sputum culture, Xpert MTB/RIF, and clinical diagnoses. *PLoS One* 2019; 14: e0220251.

107 World Health Organization. Improving the diagnosis and treatment of smear-negative pulmonary and extrapulmonary tuberculosis among adults and adolescents. Recommendations for HIV-prevalent and resource-constrained settings. 2007. https://iris.who.int/bitstream/handle/10665/69463/WHO_HTM_TB_2007.379_eng.pdf Date last accessed: 11 October 2024.

108 Houben RMGJ, Lalli M, Kranzer, K, *et al.* What if they don't have tuberculosis? The consequences and trade-offs involved in false-positive diagnoses of tuberculosis. *Clin Infect Dis* 2019; 68: 150–156.

109 Corbett EL, Churchyard GJ, Clayton T, *et al.* Risk factors for pulmonary mycobacterial disease in South African gold miners. A case-control study. *Am J Respir Crit Care Med* 1999; 159: 94–99.

110 Griffith DE, Aksamit T, Brown-Elliott BA, *et al.* An official ATS/IDSA statement: diagnosis, treatment, and prevention of nontuberculous mycobacterial diseases. *Am J Respir Crit Care Med* 2007; 175: 367–416.

111 Leung AN. Pulmonary tuberculosis – the essentials. *Radiology* 1999; 210: 307–322

112 Snider DE Jr. The relationship between tuberculosis and silicosis. *Am Rev Respir Dis* 1978; 118: 455–460.

Downloaded from https://publications.ersnet.org on December 18, 2024 by guest. Please see licensing information on first page for reuse rights.

113 Skoura E, Zumla A, Bomanji J. Imaging in tuberculosis. *Int J Infect Dis* 2015; 32: 87–93.
114 Nin CS, de Souza VV, do Amaral RH, *et al.* Thoracic lymphadenopathy in benign diseases: a state of the art review. *Respir Med* 2016; 12: 10–17.
115 Ehrlich R, Barker S, te Water Naude J, *et al.* Accuracy of computer-aided detection of occupational lung disease: silicosis and pulmonary tuberculosis in ex-miners from the South African gold mines. *Int J Environ Res Public Health* 2022; 19: 12402.
116 Sun J, Weng D, Changshan J, *et al.* The value of high resolution computed tomography in the diagnostics of small opacities and complications of silicosis in mine machinery manufacturing workers, compared to radiography. *J Occup Health* 2008; 50: 400–405.
117 Carneiro APS, da Silva LL, Silva FDCL, *et al.* Volume-based tomography for the diagnosis of incipient silicosis in former gold miners. *Occup Environ Med* 2022; 79: 427–432.
118 Bégin R, Ostiguy G, Fillion F, *et al.* Computed tomography scan in the early detection of silicosis. *Am Rev Respir Dis* 1991; 144: 697–705.
119 Verschakelen JA, De Wever W. Nodular pattern. *In:* Computed Tomography of the Lung (Medical Radiology/Diagnostic Imaging Series). Heidelberg, Springer, 2018; pp. 81–101.
120 Chong S, Lee KS, Chung MJ, *et al.* Pneumoconiosis: comparison of imaging and pathologic findings. *Radiographics* 2006; 26: 59–77.
121 Moon WK, Im JG, Yeon KM, *et al.* Mediastinal tuberculous lymphadenitis: CT findings of active and inactive disease. *Am J Roentgenol* 1998; 170: 715–718.
122 Chung SY, Lee JH, Kim TH, *et al.* ^{18}F-FDG PET imaging of progressive massive fibrosis. *Ann Nucl Med* 2010; 24: 21–27.
123 O'Connell M, Kennedy M. Progressive massive fibrosis secondary to pulmonary silicosis appearance on F-18 fluorodeoxyglucose PET/CT. *Clin Nucl Med* 2004; 29: 754–755.
124 Pagan AJ, Ramakrishnan L. The formation and function of granulomas. *Annu Rev Immunol* 2018; 36: 639–665.
125 Craighead J, Kleinerman J, Abraham JL, *et al.* Diseases associated with exposure to silica and nonfibrous silicate minerals. Silicosis and Silicate Disease Committee. *Arch Pathol Lab Med* 1988; 112: 673–720.
126 Gibbs AR, Wagner JC. Diseases due to silica. *In:* Churg A, Green FHY, eds. Pathology of Occupational Lung Disease. 2nd Edn. Baltimore, Williams & Wilkins, 1998; pp. 209–234.
127 Katzenstein AL. Pneumoconiosis. *In:* Katzenstein and Askin's Surgical Pathology of Non-neoplastic Lung Disease. 4th Edn. Philadelphia, Saunders, 2006; p. 130.
128 Corrin B, Nicholson AG. Infectious diseases. *In:* Pathology of the Lungs. 2nd Edn. London, Churchill Livingston, 2006; pp. 193–207.
129 Mukhopadhyay S, Gal AA. Granulomatous lung disease: an approach to the differential diagnosis. *Arch Pathol Lab Med* 2010; 134: 667–690.
130 Rosen Y. Pathology of granulomatous pulmonary diseases. *Arch Pathol Lab Med* 2022; 146: 233–251.
131 Mukhopadhyay S, Farver CF, Vaszar LT, *et al.* Causes of pulmonary granulomas: a retrospective study of 500 cases from seven countries. *J Clin Pathol* 2012; 65: 51–57.
132 Zijenah LS. The World Health Organization recommended TB diagnostic tools. *In:* Kayembe JMN, ed. Tuberculosis. London, InTechOpen, 2018; pp. 71–90.
133 Jain D, Ghosh S, Teixeira L, *et al.* Pathology of pulmonary tuberculosis and non-tuberculous mycobacterial lung disease: facts, misconceptions, and practical tips for pathologists. *Semin Diagn Pathol* 2017; 34: 518–529.
134 Antel K, Oosthuizen J, Malherbe F, *et al.* Diagnostic accuracy of the Xpert MTB/Rif Ultra for tuberculosis adenitis. *BMC Infect Dis* 2020; 20: 33.
135 Yu G, Zhong F, Ye B, *et al.* Diagnostic accuracy of the Xpert MTB/RIF assay for lymph node tuberculosis: a systematic review and meta-analysis. *Biomed Res Int* 2019; 2019: 4878240.
136 Webster I. Some aspects of the pathology of silicosis found in miners from the South African Gold Mines. *In:* Orenstein AJ, ed. Proceedings of the Pneumoconiosis Conference, Johannesburg, 1959. London, Churchill, 1960; pp. 158–171.
137 Weissman DN. Progressive massive fibrosis: an overview of the recent literature. *Pharmacol Ther* 2022; 240: 108232.
138 Leibowitz MC, Goldstein B. Some investigations into the nature and cause of massive fibrosis (MF) in the lungs of South African gold, coal, and asbestos mine workers. *Am J Ind Med* 1987; 12: 129–143.
139 Shitrit D, Adir Y, Avriel A, *et al.* EBUS-TBNA is sufficient for successful diagnosis of silicosis with mediastinal lymphadenopathy. *Lung* 2018; 196: 441–445.
140 Ariza-Prota M, Pérez-Pallarés J, Fernández-Fernández A, *et al.* Endobronchial ultrasound-guided transbronchial mediastinal cryobiopsy in the diagnosis of mediastinal lesions: safety, feasibility and diagnostic yield – experience in 50 cases. *ERJ Open Res* 2023; 9: 00448-2022.
141 Tung AHM, Ngai JCL, Ko FWS, *et al.* Diagnosis of silicotuberculosis by endobronchial ultrasound-guided transbronchial needle aspiration (EBUS-TBNA). *Respirology* 2013; 18: 383–384.

Downloaded from https://publications.ersnet.org on December 18, 2024 by guest. Please see licensing information on first page for reuse rights.

142 Hnizdo E, Vallyathan V. Chronic obstructive pulmonary disease due to occupational exposure to silica dust: a review of epidemiological and pathological evidence. *Occup Environ Med* 2003; 60: 237–243.

143 Dixit R, Jalutharia J, Gupta A, *et al.* Measurement of diffusion lung capacity (DLCO) in silicosis patients: correlation with radiographic abnormalities on high-resolution CT scan chest. *Lung India* 2022; 39: 352–356.

144 Allwood BW, Maasdorp E, Kim GJ, *et al.* Transition from restrictive to obstructive lung function impairment during treatment and follow-up of active tuberculosis. *Int J Chron Obstruct Pulmon Dis* 2020; 15: 1039–1047.

145 Gupta MB, Bagri S, Garg A, *et al.* Pulmonary function in cured pulmonary tuberculosis cases. *Indian J Tuberc* 2022; 69: 535–538.

146 Health and Safety Executive. Health surveillance in silica exposed workers. Research Report RR827. 2010. www.hse.gov.uk/Research/rrpdf/rr827.pdf Date last accessed: 30 September, 2023.

147 Maboso B, Ehrlich RI. Accuracy of chest x-ray screening of silica-exposed miners for tuberculosis. *Occup Med* 2024; 74: 386–391.

148 Reu, NK, Gray Z, Burchill BB, *et al.* Tuberculosis screening in silica-exposed workers: developing a tool for health care providers. *Public Health Rep* 2022; 137: 244–254.

149 Escreet BC, Langton ME, Cowie RL. Short-course chemotherapy for silicotuberculosis. *S Afr Med J* 1984; 66: 327–330.

150 Cowie RL, Langton ME, Becklake MR. Pulmonary tuberculosis in South African gold miners. *Am Rev Respir Dis* 1989; 139: 1086–1089.

151 Cowie RL. Silicotuberculosis: long-term outcome after short-course chemotherapy. *Tuber Lung Dis* 1995; 76: 39–42.

152 Hong Kong Chest Service/Tuberculosis Research Centre, Madras/British Medical Research Council. A controlled clinical comparison of 6 and 8 months of antituberculosis chemotherapy in the treatment of patients with silicotuberculosis in Hong Kong. *Am Rev Respir Dis* 1991; 143: 262–267.

153 Leung CC, Yu ITS, Chen W. Silicosis. *Lancet* 2012; 379: 2008–2018.

154 Nahid P, Mase SR, Migliori GB, *et al.* Treatment of drug-resistant tuberculosis. An official ATS/CDC/ERS/IDSA clinical practice guideline. *Am J Respir Crit Care Med* 2016; 200: e93–e142.

155 World Health Organization. WHO consolidated guidelines on tuberculosis. Module 4: Treatment. Drug-susceptible tuberculosis treatment. 2022. https://iris.who.int/bitstream/handle/10665/353829/9789240048126-eng.pdf Date last accessed: 11 October 2024.

156 Migliori GB, Marx FN, Ambrosino N, *et al.* Clinical standards for the assessment, management and rehabilitation of post-TB lung disease. *Int J Tuberc Lung Dis* 2021; 25: 797–813.

157 Ehrlich R, Murray J, Rees D. Subradiological silicosis. *Am J Ind Med* 2018; 61: 877–885.

158 Leung CC, Yew WW, Law WS, *et al.* Smoking and tuberculosis among silicotic patients. *Eur Respir J* 2007; 29: 745–750.

159 Tse LA, Yu ITS, Qiu H, *et al.* Joint effects of smoking and silicosis on diseases to the lungs. *PLoS One* 2014; 9: e104494.

160 Monaco A. Antituberculosis chemoprophylaxis in silicosis. *Bull Int Union Tuberc* 1964; 35: 51–56.

161 Hong Kong Chest Service/Tuberculosis Research Centre, Madras/British Medical Research Council. A double-blind placebo-controlled clinical trial of three antituberculosis chemoprophylaxis regimens in patients with silicosis in Hong Kong. *Am Rev Respir Dis* 1992; 145: 36–41.

162 Ruan Q-L, Huang X-T, Yang Q-L, *et al.* Efficacy and safety of weekly rifapentine and isoniazid for tuberculosis prevention in Chinese silicosis patients: a randomized controlled trial. *Clin Microbiol Infect* 2021; 27: 576–582.

163 Cowie RL. Short course chemoprophylaxis with rifampicin, isoniazid and pyrazinamide for tuberculosis evaluated in gold miners with chronic silicosis: a double-blind placebo controlled trial. *Tubercle Lung Dis* 1996; 77: 239–243.

164 Churchyard GJ, Katherine L, Fielding KL, *et al.* A trial of mass isoniazid preventive therapy for tuberculosis control. *N Engl J Med* 2014; 370: 301–310.

165 Vynnycky E, Sumner T, Fielding KL, *et al.* Tuberculosis control in South African gold mines: mathematical modeling of a trial of community-wide isoniazid preventive therapy. *Am J Epidemiol* 2015; 181: 619–632.

166 Escombe R. An Investigation into the Effect of Silicosis on the Efficacy of Isoniazid Preventive Therapy for the Prevention of Tuberculosis Disease in South African Gold Miners. London, London School of Hygiene and Tropical Medicine, 2012.

167 De Jager P, Churchyard GJ, Ismail N, *et al.* Clinical guidelines on isoniazid preventive therapy for patients with silicosis in South Africa. *Occup Health South Afr* 2014; 20: 6–11.

168 Au K, Chau C, Mok YT, *et al.* Management of latent tuberculosis infection in patients with silicosis. 2020. www.info.gov.hk/tb_chest/doc/4_Guidelines_management%20of%20LTBI_%20silicosis_Dec%202020_Final.pdf Date last accessed: 30 September 2023.

169 Department of Health, Republic of South Africa. National guidelines on the treatment for tuberculosis infection. 2023. https://knowledgehub.health.gov.za/elibrary/national-guidelines-treatment-tuberculosis-infection Date last accessed: 23 September 2023.

Downloaded from https://publications.ersnet.org on December 18, 2024 by guest. Please see licensing information on first page for reuse rights.

170 World Health Organization. Consolidated guidelines on tuberculosis. Module 1: Prevention – tuberculosis preventive treatment. 2020. https://iris.who.int/bitstream/handle/10665/378536/9789240096196-eng.pdf Date last accessed: 11 October 2024.

171 Melnychuk L, Perlman-Arrow S, Bastos L, *et al.* A systematic review and meta-analysis of tuberculous preventative therapy adverse events. *Clin Infect Dis* 2023; 77: 287–294.

172 Sterling TR, Njie G, Zenner D, *et al.* Guidelines for the treatment of latent tuberculosis infection: recommendations from the National Tuberculosis Controllers Association and CDC, 2020. *MMWR Recomm Rep* 2020; 69: 1–11.

173 Gottesfeld P, Murray J, Chadha SS, *et al.* Preventing tuberculosis with silica dust controls. *Int J Tuberc Lung Dis* 2011; 15: 713–714.

174 Worksafe BC. Developing a silica exposure control plan. 2014. www.worksafebc.com/en/resources/health-safety/exposure-control-plans/exposure-control-plan-developing-a-silica Date last accessed: 14 July 2024.

175 Nota MM, Mbuligwe SE, Kassenga GR, *et al.* Feasibility of respirable crystalline silica exposure reduction in small-scale tanzanite mining in Tanzania. *Ann Work Expo Health* 2024; 68: 804–810.

176 Hnizdo E, Murray J. Risk of pulmonary tuberculosis relative to silicosis and exposure to silica dust in South African gold miners. *Occup Environ Med* 1998; 55: 496–502.

177 Dhooria S, Sehgal IS, Agarwal R. Silica-associated lung disease in developing countries. *Curr Opin Pulm Med* 2023; 29: 65–75.

178 Handra CM, Gurzu IL, Chirila M, *et al.* Silicosis: new challenges from an old inflammatory and fibrotic disease. *Front Biosci* 2023; 28: 96.

179 Álvarez RF, González CM, Martínez AQ, *et al.* Guidelines for the diagnosis and monitoring of silicosis. *Arch Bronconeumol* 2015; 51: 86–93.

180 Workers' Compensation Regulatory Services. Returning workers with mine dust lung diseases to the workplace. 2021. www.worksafe.qld.gov.au/__data/assets/pdf_file/0029/88913/mine-dust-lung-disease-guidelines.pdf Date last accessed: 15 July 2024.

181 Carneiro APS, Barreto SM, Siqueira AL, *et al.* Continued exposure to silica after diagnosis of silicosis in Brazilian gold miners. *Am J Ind Med* 2006; 49: 811–818.

182 Kim EA, Kang SK. Historical review of the List of Occupational Diseases recommended by the International Labour Organization (ILO). *Ann Occup Environ Med* 2013; 25: 14.

Downloaded from https://publications.ersnet.org on December 18, 2024 by guest. Please see licensing information on first page for reuse rights.