

https://dspace.org/

A 6 year review of the histopathology of nasopharyngeal tumours in adult patients at the Carlotte Maxeke Johannesburg Academic Hospital

Naidoo, Lalenthra

2011-03-08
http://hdl.handle.net/10539/9112

Downloaded from a DSpace repository. https://dspace.org/

A 6 YEAR REVIEW OF THE HISTOPATHOLOGY OF NASOPHARYNGEAL TUMOURS IN ADULT PATIENTS AT THE CHARLOTTE MAXEKE JOHANNESBURG ACADEMIC HOSPITAL

By

Dr Lalenthra Naidoo

A research report submitted to the

Faculty of Health Sciences, University of Witwatersrand,

In partial fulfilment of the requirements for the degree of

Master of Medicine

In

Otorhinolaryngology.

Johannesburg

2010

This dissertation is dedicated

To

My husband,

Indran Govender,

And my children,

Kaelin Govender

And

Revanya Govender.

DECLARATION BY STUDENT

I, Lalenthra Naidoo declare that this dissertation is my own work. It is being submitted for the degree of Master of Medicine (Otorhinolaryngology) in the University of Witwatersrand, Johannesburg. It has not been submitted before for any degree or examination at this or any other University.

Dr Lalenthra Naidoo
MBBCH(WITS), DCH(SA)

DECLARATION BY SUPERVISORS

This dissertation is submitted for examination with my approval as University Supervisor/ Co-supervisor.

Professor Pradip C Modi (Supervisor)
MBBCH(WITS), DCH(SA), FCS(SA), MMED(WITS)

Dr Shahed Omar (Co-supervisor)
MBCHB(MEDUNSA), DA(SA), FCPath(Chem), Crit Care(SA)

_____Day of _____, 2010.

ACKNOWLEDGEMENTS

I wish to express my gratitude to all the following:

To **PROFESSOR PC MODI**, my supervisor, for his patience, guidance, support and encouragement throughout the study process.

To Dr SHAHED OMAR, my co-supervisor, for his invaluable assistance in supervising the data analysis and results of this study.

To Dr Waasila Jassat, Dr Alison Bentley and Dr Shahpar Motakef and for their guidance and valuable criticism.

To the staff of the following departments at Charlotte Maxeke Johannesburg Academic Hospital for their help in sourcing all the relevant data and material for this study.

- Records
- National Health Laboratory Services
- ENT Operating Theatre and Ward
- Radiology –Mrs H Oates
- Radio nuclear medicine – Prof W Vangu and Dr NS Perumal

To the staff of Wits Health Science Library, especially Ms C. Ford, for advice and assistance with accessing references.

To all my colleagues in the ENT department who have contributed to this study.

To my family, for the encouragement, support and sacrifice during the study process.

TABLE OF CONTENTS

Page No

DECLARATION BY STUDENT iii

ACKNOWLEDGEMENTS iv

TABLE OF CONTENTS v

LIST OF FIGURES: vii

LIST OF TABLES: viii

LIST OF ABBREVIATIONS: ix

SUMMARY xi

CHAPTER 1 1

1. INTRODUCTION 1

1.1 MOTIVATION FOR THE STUDY 1

1.2 OBJECTIVES 2

CHAPTER 2 3

2. LITERATURE REVIEW 3

2.1 ANATOMY 3

2.2 CLASSIFICATION OF NASOPHARYNGEAL TUMOURS 6

2.3 SYMPTOMATOLOGY OF NASOPHARYNGEAL DISEASE 9

2.4 NASOPHARYNGEAL CARCINOMA (NPC) 11

2.6 RADIOLOGICAL EVALUATION OF THE NASOPHARYNX 19

2.7 THE BURDEN OF HIV IN SOUTH AFRICA 25

2.8 HIV AND THE OTORHINOLARYNGOLOGIST 27

2.9 HIV AND THE NASOPHARYNX 29

CHAPTER 3 32
3. MATERIALS AND METHODS 32
3.1 STUDY LOCATION 32
3.2 STUDY DESIGN 32
3.3 STUDY PERIOD 32
3.4 STUDY POPULATION 32
3.5 INCLUSION CRITERIA 33
3.6 EXCLUSION CRITERIA 33
3.7 DATA COLLECTION 33
3.8 DATA ANAYLSIS 34
3.9 ETHICAL CONSIDERATIONS 35

CHAPTER 4 36
4. RESULTS 36

CHAPTER 5 47
5. DISCUSSION 47
5.1 LIMITATIONS 55

CHAPTER 6 57
6. CONCLUSIONS AND RECOMMENDATIONS 57

REFERENCES: 59
APPENDIX A 64
APPENDIX B 67

LIST OF FIGURES:

Figure 1: Sagittal section of the nasopharynx and nasal cavity (Encyclopaedia Britannica, 2003)... 5

Figure 2: Patient with NHL of the nasopharynx with significant lymphadenopathy. 10

Figure 3: View of the nasopharynx through a rigid scope (McClay, 2008) 18

Figure 4: Lateral X-ray view of the nasopharynx. 19

Figure 5: CT- Axial cut through a normal nasopharynx. 20

Figure 6: CT- Axial cut showing a malignant nasopharyngeal tumour. 21

Figure 7: CT- Axial cut through the nasopharynx showing a benign tumour. 21

Figure 8: MRI sagittal section showing a mass in the nasopharynx 22

Figure 9: PET-CT of the nasopharynx 24

Figure 10: Box and whisker plot of age (yrs) vs. gender, 1=Male and 2=Female 37

Figure 11: Distribution of age groups (yrs) in the study population (n=81) 37

Figure 12: Distribution of benign and malignant disease (n=81) 38

Figure 13: Frequency of all nasopharyngeal pathology (n=81) 39

Figure 14: Frequency of benign disease (n=52) 39

Figure 15: Frequency of malignant disease (n=29) 40

Figure 16: Frequency of pathology in the HIV positive group (n=28) 45

Figure 17: Frequency of pathology in the HIV negative group (n=13) 45

LIST OF TABLES:

Table 1: WHO Histological Classification of Tumours of the Nasopharynx-1991. 7

Table 2: The WHO 1991 Classification of NPC 12

Table 3: UICC/AJCC 1997 TNM Classification of NPC 13

Table 4: UICC/AJCC 1997 Staging of NPC 14

Table 5: Head and Neck Manifestations of HIV 28

Table 6: Age distribution of study patients (n=81) 36

Table 7: Distribution of males and females with benign and malignant disease 40

Table 8: Gender distribution among patients with HIV status known and those with unknown HIV status 41

Table 9: HIV frequency among male and female study patients (n=41) 41

Table 10: Record of symptoms among the study patients 42

Table 11: Differences between malignant and benign disease with reference to common symptoms using a multiple regression model 43

Table 12: The frequencies of HIV positive status and HIV negative status among patients with benign and malignant disease 44

Table 13: Table of risk for malignant disease 46

LIST OF ABBREVIATIONS:

AIDS – Acquired Immunodeficiency Syndrome

AJCC – American Joint Cancer Committee

ARC – AIDS Related Complex

ARV – Anti-retroviral

CMJAH – Charlotte Maxeke Johannesburg Academic Hospital

CT – Computerised Tomography

EBV – Epstein Barr Virus

FDG – 2-[fluorine-18] fluoro-2-deoxy-d-glucose

FDG-PET – 2-[fluorine-18] fluoro-2-deoxy-d-glucose – Positron emission tomography

HAART – Highly active anti-retroviral treatment

HLA – Human Leukocyte antigens

HIV – Human Immunodeficiency Virus

HPV – Human Papilloma Virus

IMRT – Immune modulated radiotherapy

KS- Kaposi sarcoma

MRI – Magnetic resonance imaging

NHL- Non Hodgkin's lymphoma

NLTH – Nasopharyngeal lymphoid tissue hypertrophy

NPC – Nasopharyngeal carcinoma

OPD – Outpatients department

PET – Positron Emission Tomography

PGL – Progressive glandular lymphadenopathy

PNS – Post nasal space

UICC – International Union Against Cancer

WHO – World Health Organisation

3DRT – 3-Dimensional Radiotherapy

SUMMARY

This study is a six year retrospective review of the histopathology of nasopharyngeal masses in adult patients who underwent a biopsy in theatre at the Charlotte Maxeke Johannesburg Academic Hospital (CMJAH) from 1st January 2003 to 31st December 2008.

Eighty one patients were included in this study. They comprised of 54 males (67%) and 27 females (33%) aged between 18 and 82 years. There was no statistical difference between the two genders in terms of their ages (p= 0.39).

Fifty two patients (64%) had benign disease and 29 patients (36%) had malignant disease (ratio 1.8:1). Thirty four males (65%) and 18 females (35%) had benign disease. Twenty males and 9 females had malignant disease. There was no significant correlation between gender and malignancy (r= -0.04, p=0.75).

The independent predictors of the nature of the tumour were: nasal congestion, epistaxis, hearing loss, otalgia and Human Immunodeficiency Virus (HIV) status. The statistically significant positive predictors of malignancy were the presence of nasal congestion, epistaxis and otalgia. The presence of at least one or more of these symptoms was associated with an odds ratio of 3.06 for malignant disease. (CI= 1.17-8.01). The presence of hearing loss was independently associated with benign disease (p=0.031).

The HIV status was known in 41 of the 81 patients. Of the 41 patients whose HIV status was known, 25 were male and 16 were female. The HIV positive patients comprised of 19 males (76% of all males) and 9 females (56% of all females).

The presence of HIV infection was independently associated with benign disease. The absence of HIV infection was in fact associated with malignant disease, with an odds ratio of 4.00 and 95% confidence intervals of 1.04 to 15.43.

CHAPTER 1

1. INTRODUCTION

Analyses of tumour types of the nasopharynx are poorly researched across the globe and this scenario is also applicable to South Africa. Majority of the research pertaining to tumours of the nasopharynx focuses specifically on the nasopharyngeal carcinoma (NPC), which is endemic to certain parts of the world. In most Western countries and also in South Africa, nasopharyngeal carcinoma accounts for less than two percent of all head and neck tumours (Larson, Clifford & Einhorn, et al., 1976; Glynn, Keogh & Ali, et al., 2006). There has not been any historical study in South Africa describing the prevalence or incidence of the various nasopharyngeal pathologies in adults.

South Africa has one of the highest prevalence rates of Human Immunodeficiency Virus (HIV) infection in the world (10.6%), with 5.21 million people known to be living with this infection (Statistics South Africa, 2009). Since the onset of the HIV epidemic, Otorhinolaryngologists have been recognising at a clinical level, a changing spectrum of diseases occurring in the nasopharynx.

1.1 MOTIVATION FOR THE STUDY

The decision to conduct this study was prompted by the need to identify the prevalence of benign nasopharyngeal pathology in a South African setting in comparison to their malignant counterparts. The potential influence of HIV infection on these tumours would also be determined.

If the results of this study prove significant, it could potentially influence the future management of these tumours by specifying whether all nasopharyngeal tumours need to be biopsied.

1.2 OBJECTIVES

The objectives of this study were:

1. To determine the frequency of the various nasopharyngeal tumours presenting to the Otorhinolaryngology department at the Charlotte Maxeke Johannesburg Academic Hospital (CMJAH), formerly known as Johannesburg General Hospital.

2. To determine if there was an association between the presenting symptoms of nasopharyngeal disease and a tumour type (i.e. benign or malignant).

3. To determine if there was an association between nasopharyngeal neoplasms and the presence of a superimposed HIV infection.

CHAPTER 2

2. LITERATURE REVIEW

This chapter gives a brief description of the anatomy of the nasopharynx, discussion on the symptoms related to nasopharyngeal disease, classification of nasopharyngeal tumours and summary of the well documented NPC. A discussion on the clinical and radiological evaluation of the nasopharynx is provided along with a superficial overview of the burden of HIV in South Africa and pathology in the head and neck. Focus has been placed on nasopharyngeal pathology related to HIV infection. This chapter concludes with the observations and hypothesis of this study.

2.1 ANATOMY

2.1.1 Embryology

The nasopharynx is mainly derived from the primitive foregut (endoderm) and is separated from the primitive buccal cavity (ectoderm) by the buccopharyngeal membrane. The buccopharyngeal membrane eventually disappears and leaves the primitive pharynx and buccal cavity in communication with each other. The two main outpouchings from this developing nasopharynx is Rathke's pouch (ectoderm) and the Eustachian tube and middle ear (endoderm). Different tissue types exist in the nasopharynx and it is important to know where the tissues originate. These tissues migrate and nests of tissue can be left behind in their migration path and present with varying pathology of endoderm, ectoderm and mesoderm (Godtfredson, 1944).

2.1.2 Surgical Anatomy

The nasopharynx is a complex anatomical area, bounded by various bony, muscular, vascular and neural structures. It is the uppermost part of the pharynx, lying behind the soft palate and communicates anteriorly with the nasal cavity through two large apertures called the posterior choanae. It extends superiorly, from the base of the skull, forming a continuous surface that lies inferior to the body of the sphenoid and the basilar part of the occipital bone. The floor of the nasopharynx is formed by the superior surface of the soft palate.

The lateral aspect of the nasopharynx is defined by the temporal bones. The pharyngeal orifice of the Eustachian tubes lies in the lateral wall of the nasopharynx, where it is bound by a tubal elevation or torus, produced by the medial end of the cartilaginous part of the Eustachian tube. Extending inferiorly from the torus is the salpingo-pharyngeal fold, which houses the salpingo-pharyngeus muscle responsible for the opening of the Eustachian tube during swallowing. Posterior to the torus and the salpingo-pharyngeal fold is a slit like lateral projection called the pharyngeal recess or the fossa of Rosenmuller.

2.1.3 Micro-anatomy

The mucosa of the nasopharynx is predominantly a non-keratinizing squamous epithelium. The anterior wall of the roof of the nasopharynx is, however, lined by moist ciliated respiratory epithelium. The transition area of the mucosa varies from respiratory to squamous type and can be gradual or abrupt with islands of tissue mixed with each other. This is especially prevalent in the area of the pharyngeal recess, making this transitional zone an ‘unstable’ one and thus an area favourable for the development of tumours or malignancies.

The submucosa of the nasopharynx has a very rich supply of blood vessels, lymphatic channels, sero-mucinous glands, minor salivary glands, nerve plexuses and a variety of connective tissues. This diversity of tissues allows for a multitude of neoplastic diseases that do arise in the nasopharynx (Cummings, Flint & Harker, et al., 2005).

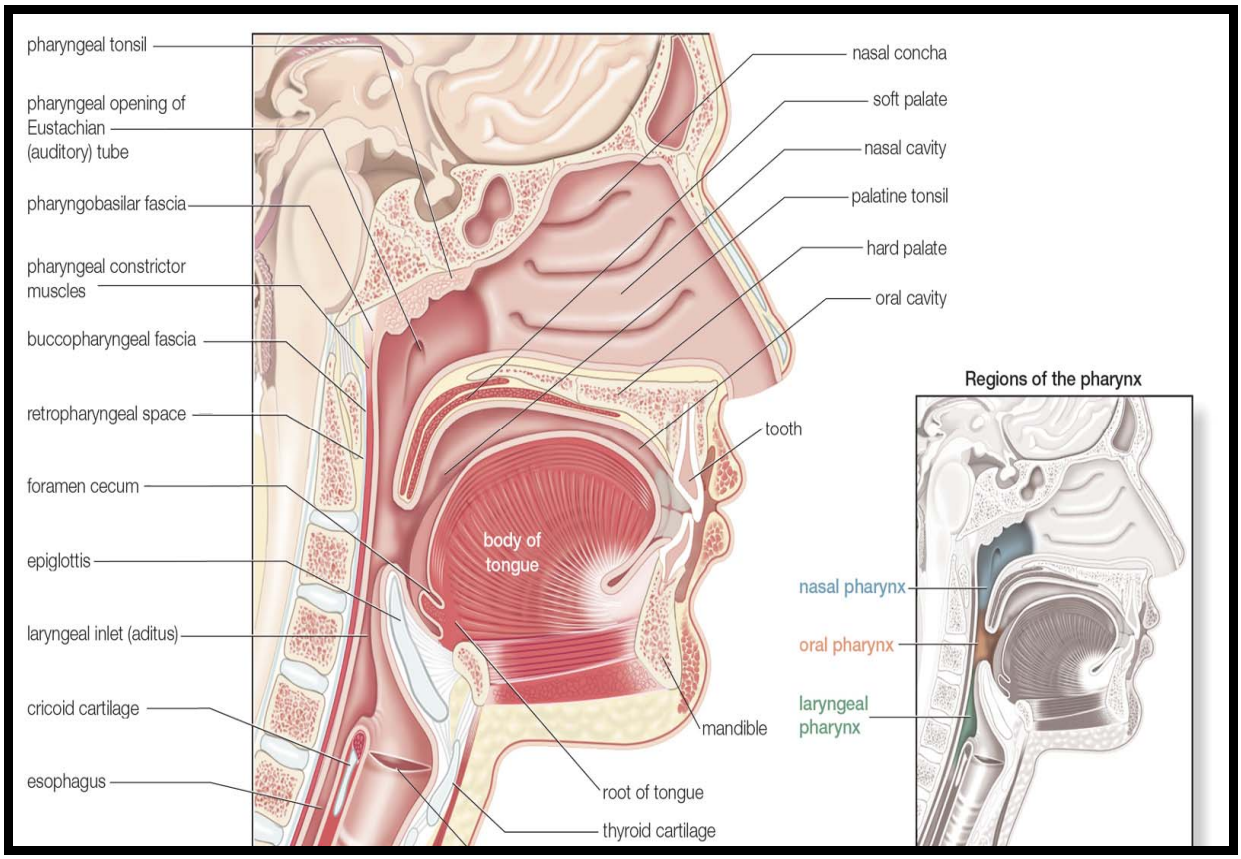

Figure 1: Sagittal section of the nasopharynx and nasal cavity (Encyclopaedia Britannica, 2003)

By courtesy of Encyclopaedia Britannica, Inc., copyright 2003; used with permission. Image available at: http://www.britannica.com/EBchecked/topic-art/22980/68641/Sagittal-section-of-the-pharynx.

2.2 CLASSIFICATION OF NASOPHARYNGEAL TUMOURS

Neoplastic growths of the nasopharynx include benign and malignant pathologies and these are classified into the epithelial and the non-epithelial groups.

Common benign conditions include angiofibroma, allergic-type polyps, squamous papillomata, pleomorphic adenomas, schwannoma and teratomas.

Malignant lesions of the nasopharynx include nasopharyngeal carcinoma, adenocarcinoma, adenoid cystic carcinoma, lymphomas, sarcomas, malignant melanoma, plasmacytoma, chondrosarcoma and rhabdomyosarcoma.

Tumours of the nasopharynx needs to be differentiated from tumours in the nasal cavity due to the diverse pathology in this area and thus needs its own classification (Heffner, 1990). The histological classification of nasopharyngeal tumours was developed by the World Health Organization (WHO) in 1978, and revised in 1991 (Shanmugaratnam & Sobin, 1993) (see table 1).

Table 1: WHO Histological Classification of Tumours of the Nasopharynx-1991.

	Benign	Malignant
1. Epithelial Tumours	Papillomata	Nasopharyngeal carcinoma
	Pleomorphic adenoma	Squamous cell carcinoma (keratinizing carcinoma)
	Oncocytoma	Non-keratinizing carcinoma
	Basal cell adenoma	1. Differentiated non-keratinizing carcinoma
	Ectopic pituitary adenoma	2. Undifferentiated carcinoma (of nasopharyngeal type)
		Adenocarcinoma
		Papillary adenocarcinoma
		Mucoepidermoid carcinoma
		Adenoid cystic carcinoma
		Polymorphous low grade adenocarcinoma
2. Soft Tissue Tumours	Juvenile angiofibroma	Fibrosarcoma
	Haemangioma	Rhabdomyosarcoma
	Haemangiopericytoma	Angiosarcoma
	Neurilemmoma (Schwannoma)	Kaposi sarcoma
	Neurofibroma	Malignant haemangiopericytoma
		Malignant nerve sheath tumour
		Synovial sarcoma
3. Tumours of Bone and Cartilage		
4. Malignant lymphomas		Non Hodgkin's lymphoma
		Extramedullary Plasmacytoma
		Midline malignant reticulosis
		Histiocytic lymphoma

	Benign	Malignant
		Hodgkin’s disease
5. Miscellaneous Tumours	Meningioma	Malignant melanoma
	Craniopharyngioma	Chordoma
	Mature teratoma	Malignant germ cell tumour
6. Secondary Tumours		
7. Unclassified Tumours		
8. Tumour like Lesions	Cysts	
	Heterotopic pituitary tissue	
	Meningocele, Meningo-encephalocele	
	Fibro-inflammatory pseudotumour	
	Infective granulomas	
	Wegener's granulomatosis	
	Pseudoepitheliomatous hyperplasia	
	Oncocytic metaplasia and hyperplasia	
	Pyogenic granuloma	
	Lymphoid hyperplasia	
	Malakoplakia	
	Amyloid deposits	

2.3 SYMPTOMATOLOGY OF NASOPHARYNGEAL DISEASE

The general symptoms of nasopharyngeal mass lesions include nasal obstruction, epistaxis, hearing loss, otalgia and Eustachian tube obstruction (Hopping, Keller & Goodman et al., 1983; van Hasselt & Gibb, 1991). It must however be noted that infiltrative diseases may present with neurological deficits and cervical lymphadenopathy (Godtfredson, 1944; Glynn, et al., 2006).

Mass lesions arising in the nasopharynx generally cause obstruction to the passage of nasal air flow, usually in the posterior choanae, thus resulting in the nasal obstructive symptoms. With further growth, nasopharyngeal tumours can also extend anteriorly into the nasal cavity and present as a mass protruding through the nostrils. Commonly associated symptoms include nasal blockage, anosmia, nasal discharge and intermittent epistaxis. If the mass extends inferiorly, it can present as a mass in the oropharynx which pushes the soft palate forward. Typical presentation thereof would include snoring or stertor and a hypo nasal quality of speech.

Masses in the nasopharynx can obstruct the pharyngeal opening of the Eustachian tube. This results in accumulation of secretions produced by the respiratory mucosa in the middle ear and ultimately middle ear effusions. Patients can experience otalgia from distension of the tympanic membrane. Chronic middle ear effusions can be associated with a temporary or permanent hearing loss and this is usually conductive in nature.

The nasopharynx has a rich network of lymphoid tissue and lymphatic channels. The main drainage site of the nasopharyngeal lymphatics is to the retropharyngeal lymph nodes, and

subsequently, the upper posterior triangle and the deep cervical lymph nodes. Lesions that extend out of the nasopharynx can result in lymphadenopathy in the drainage areas of the surrounding structures. Metastatic disease involving lymph nodes in the upper deep cervical area and the posterior triangle can thus be an early presentation of nasopharyngeal pathology.

The nasopharynx is in close proximity to the sphenoid and orbital bones, the cavernous sinus and brain. Tumour spreading and infiltrating into these adjacent areas cause neurological deficits and cranial nerve fallout, especially the lower cranial nerves, and cavernous sinus thrombophlebitis. The common cranial nerve deficits include: ophthalmoplegia or diplopia, headaches, trigeminal neuralgia, hoarseness and tongue and pharyngeal paralysis (Godtfredson, 1944).

The nasopharynx thus provides easy access to its adjacent anatomical structures, thus clinical presentation of neoplasia will vary according to the sites of involvement.



Figure 2: Patient with NHL of the nasopharynx with significant lymphadenopathy.

2.4 NASOPHARYNGEAL CARCINOMA (NPC)

The most widely researched malignant nasopharyngeal lesion is NPC. In Western countries, NPC accounts for less than one percent of all malignant tumours (Stein, Ruff & Weaving, et al., 1996; Johannsson, Sveinsson & Agnarsson, et al.,1997; Her, 2001; Glynn, et al., 2006) but in countries in the East especially those with a high Chinese population, the incidence ranges from 13-21% (Glynn, et al 2006). In certain areas such as North East Africa, Southern China and Southeast Asia, NPC is regarded as being endemic.

Genetic, environmental and dietary factors and Epstein Barr virus (EBV) infection are implicated as the causative factors of NPC (van Hasselt, et al., 1991; Her, 2001; Chan, Teo & Johnson, 2002). Human leukocyte antigens (HLA) haplotypes are genetic factors that pose a risk for malignancy and some of these are well associated with NPC (van Hasselt, et al., 1991; Her, 2001; Chan, et al., 2002). This could account for the continued higher prevalence of NPC in people of Chinese origin that have emigrated to Western countries than their Eastern counterparts (Tse,Yu & Mang, et al., 2006).

The consumption of salted fish and other foods containing high levels of nitrosamines, which is thought to be carcinogenic, together with vitamin deficiencies, poses a substantial risk for development of NPC (Her, 2001). Tobacco smoking, formaldehyde, hydrocarbons, incense burning and dust exposure are also considered as significant environmental risk factors for the development of NPC.

Nasopharyngeal carcinoma seems to develop with gradual changes in the histology of the mucosa (Chan, et al., 2002). The tumour begins as patchy dysplasia and it is suggested that

environmental carcinogens may be responsible (Chan, et al., 2002). These changes affect the chromosomes and results in inactivation of tumour suppressor genes. EBV infection seems to be the crucial factor that leads to severe dysplasia. It is thought to contain genes that are capable of transforming human epithelial cells. In areas that are endemic for NPC, EBV antibody titres are particularly high. Monitoring EBV-DNA levels in plasma is a valuable tool for prognosticating the cancer, assessing responses during treatment and monitoring for recurrence (Her, 2001; Chan, et al., 2002; Cummings, et al., 2005).

There are many classifications of NPC based on the histological findings but the most recent and widely accepted classification is the WHO 1991 histological classification (Shanmugaratnam, et al., 1993) (see table 2). Categorising NPC according to histological types may prognosticate response to treatment (Chan, et al., 2002; Goh & Lim, 2009).

Table 2: The WHO 1991 Classification of NPC

I – Keratinising squamous cell carcinoma	II- Non-keratinising carcinoma
	A) Undifferentiated
	B) Differentiated

In 1997, a new International Union Against Cancer (UICC) / American Joint Cancer Committee (AJCC) stage classification was formulated (see tables 3 &4). This new staging considered whether the tumour extended to areas associated with a higher metastatic rate (e.g. the parapharyngeal space), intracranial extension and nodal involvement and taking these factors into consideration, seems to prognosticate NPC more accurately (Chan, et al., 2002).

Table 3: UICC/AJCC 1997 TNM Classification of NPC

T (Tumour)	N (Regional nodal involvement)	M (Metastasis)
T1 - Nasopharynx	**N1**- Unilateral nodal involvement of < 6cm in the greatest dimension, above the supraclavicular fossae	**M0** - No distant metastasis
T2 - Soft tissue of oropharynx and/or nasal fossa	**N2**- Bilateral nodal involvement of < 6cm in the greatest dimension, above the supraclavicular fossae	**M1** - With distant metastasis
T2a-Without Parapharyngeal extension	**N3**- Metastasis in the lymph nodes > 6cm, in the supraclavicular fossa	
T2b- With Parapharyngeal extension		
T3 - Invades bony structures and/or paranasal sinuses		
T4 - Intracranial extension, involvement of cranial nerves, infratemporal fossa, hypopharynx or orbit		

Table 4: UICC/AJCC 1997 Staging of NPC

Stages	
Stage 0	T in situ N0 M0
Stage 1	T1 N0 M0
Stage 2a	T2a N0 M0
Stage 2b	T2b N0 M0
	T1 N1 M0 or T2 N1 M0
Stage 3	T3 N0, N1 M0
	T1, 2, 3 N2 M0
Stage 4a	T4 N0, N1, N2 M0
Stage 4b	Any T, N3 M0
Stage 4c	Any T, Any N, M1

Nasopharyngeal carcinoma, even in advanced stages, has good cure rates. Initial treatment in the 1990's, involved radical radiotherapy (60-70Gy) being delivered in two dimensions, however subsequent technological advances allowed radiation to be delivered in three dimension conformal (3DCRT) or intensity-modulated (IMRT) techniques. The 3DRT and IMRT methods proved to be superior to the older treatment, improving local cure rates from 90% compared to the 80% achieved by two dimensional radiotherapy technique (Chan, et al., 2002; Goh, et al., 2009). These new modalities combined with images from CT scans and MRI, help determine the gross tumour volume to be treated, allowing radiation to be delivered to the tumour-filled areas whilst sparing vital structures in the vicinity. It is now also possible to use altered fractionation and dose escalation techniques by intracavity brachytherapy, and this could lead to better results associated with local control of the disease (Chan, et al., 2002).

Combined chemo-radiation was proven in 1998 to have a significant advantage over radiotherapy alone (Her, 2001; Chan, et al., 2002) and this resulted in the change of treatment protocol for these tumours. Concurrent chemo-radiation is beneficial for advanced, local or regional tumours as well as for treatment of recurrent disease.

Nasopharyngeal carcinoma is a very chemo sensitive tumour and the use of platinum based cytotoxic agents such as Cisplatin or Carboplatin, and combined with 5-fluorouracil, bleomycin, gemcitabine, paclitaxel or ifosfamide allows the tumour to be more radiosensitive, thus producing good response rates (Stein, et al., 1996; Chan, et al., 2002).

2.5 CLINICAL EVALUATION OF THE NASOPHARYNX

Examination of the nasopharynx can either be performed in an outpatient department (OPD) or clinic setting, or in a theatre utilising the following examination methods, viz.: mirror examination, rigid endoscopy or flexible endoscopy.

Mirror examinations can be easily performed on a conscious patient with the patient seated in front of the examiner who is equipped with a head lamp and a nasopharyngeal mirror. The mirror is warmed to prevent misting and the oropharynx can be anaesthetised with topical agents to reduce the gag effect. The mirror is placed just behind the soft palate facing upwards to view the nasopharynx. The disadvantage of this procedure however, is that it may only give a limited view of the fossa of Rosenmuller and may also induce the gag effect. In theatre, examination of the nasopharynx using the mirror is aided by using a mouth gag to keep the oral cavity opened and the soft palate is retracted using the Jacques rubber catheters. Biopsies can then be taken transorally.

Rigid endoscopy refers to using zero or thirty degree Hopkins rod endoscopes (telescopes) to visualise the nasopharynx. In a similar method as described above, the patient is seated in front of the examiner. The nasal cavity can be anaesthetised with a topical agent and the scope is advanced into and through the nasal passage until it reaches the nasopharynx. Visualisation of the nasopharynx with this method is of a better quality than mirror examination but anatomical variations especially of the nasal septum can make it difficult to manoeuvre these scopes to reach the nasopharynx. If a biopsy is to be taken, the biopsy forceps is passed through the nostril (on the side of the pathology) and the scope is passed through the nostril on the unaffected side and the biopsy can be performed under direct

vision. An alternative technique described by van Hasselt (1991) makes use of a ninety degree Hopkins rod passed transorally and may be used with palatal retractors. This provides excellent views of the nasopharynx picking up even the smallest of tumours.

The introduction of the fibre optic flexible nasopharyngoscope has simplified the examination of patients in the OPD or clinic setting. Built with a biopsy port, this scope allows for the convenient examination of the nasopharynx and concurrent biopsy without needing to take a patient to theatre for the procedure. The risks of the biopsy include patient discomfort hence poor co-operation, and associated bleeding. Flexible endoscopy provides a panoramic view of the nasopharynx and even tiny lesions can be identified.

Outpatient based biopsy of the nasopharynx is not generally recommended although this procedure may be particularly appropriate for patients that are too ill to undergo a general anaesthesia (Glynn, et al., 2006).

The clinical appearance of a nasopharyngeal mass may be a vital clue to predict if a tumour is benign or malignant. Smooth, symmetric, non-ulcerated masses that do not involve the fossa of Rosenmuller, are most likely to be benign (Barzan, Carbone & Tirelli, et al., 1990; Glynn, et al., 2006). Ulcerated and irregular looking masses however, are most likely to be malignant. Some tumours may also extend submucosally and the nasopharynx may appear normal on flexible endoscopy, so malignancy can be missed. If it is decided that a biopsy of a normal looking nasopharynx in patients with nasopharyngeal symptomatology is not warranted, close outpatient follow up is strongly recommended.

As tumours in the nasopharynx grow, they may extend into the nasal passages and present as a mass in the anterior nasal passages. Hence, biopsies of nasal lesions may in fact be masses originating from the nasopharynx.

In patients with occult primary tumours, a panendoscopy is performed, taking random biopsies from areas that are highly probable to harbour malignancies. Panendoscopy refers to endoscopic examination of the nasopharynx (especially in the region of the fossa of Rosenmuller), oral cavity, oropharynx, hypopharynx, larynx, trachea, bronchi and upper oesophagus.

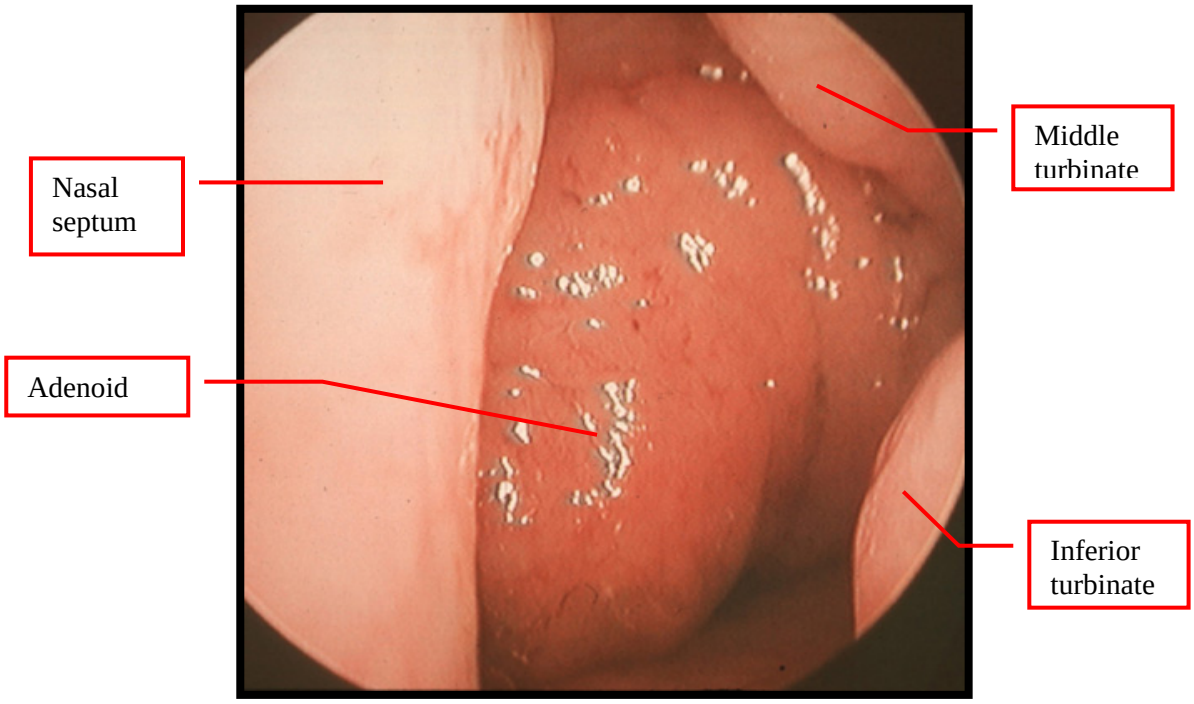

Figure 3: View of the nasopharynx through a rigid scope (McClay, 2008).

Image reprinted with permission from eMedicine.com, 2010. Available at: http://emedicine.medscape.com/article/872216-overview.

2.6 RADIOLOGICAL EVALUATION OF THE NASOPHARYNX

The radiological evaluation of the nasopharynx is done using plain X-rays, Computerised tomography (CT) scans and Magnetic resonance imaging (MRI), with or without the use of contrast and angiography.

The nasopharynx can be easily seen on a lateral X-ray view and the presence of increased soft tissue in the area behind the nasal cavity is suggestive of mass lesions in the nasopharynx. The X-ray may also demonstrate surrounding bony erosion.

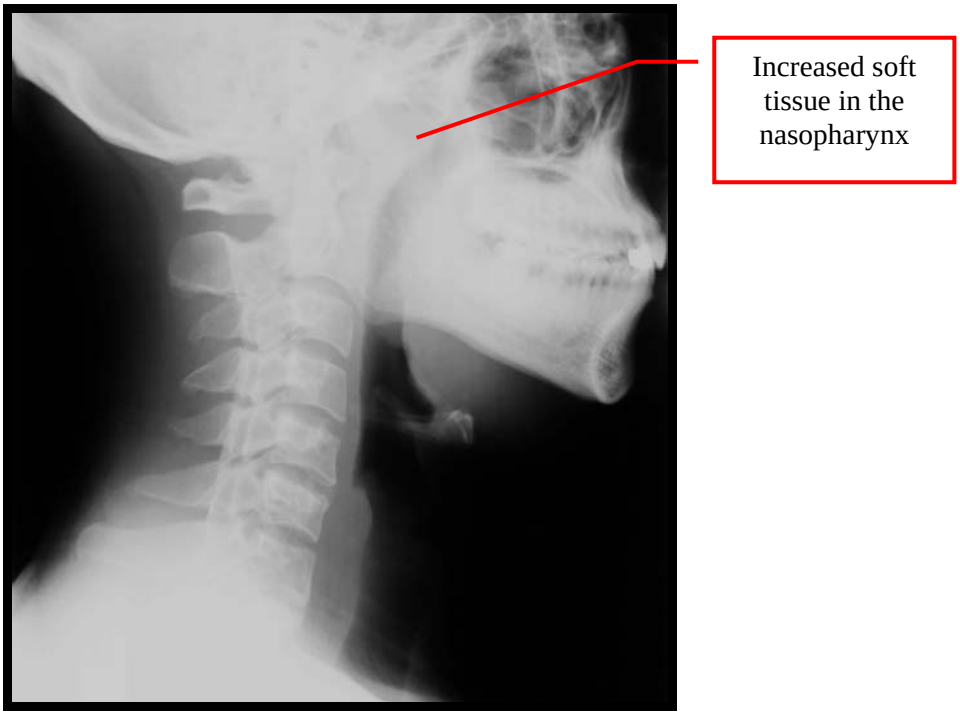

Figure 4: Lateral X-ray view of the nasopharynx.

CT scans are especially useful for evaluation of the bony framework of the nasopharynx. Erosion of this bony framework warns the surgeon of mass extension and infiltration into the surrounding structures and possibly into the brain. Other useful sites to assess on CT

scans are extension of tumour into the parapharyngeal space and the pterygoid muscles (Sievers, Grees & Baum, et al., 2000).

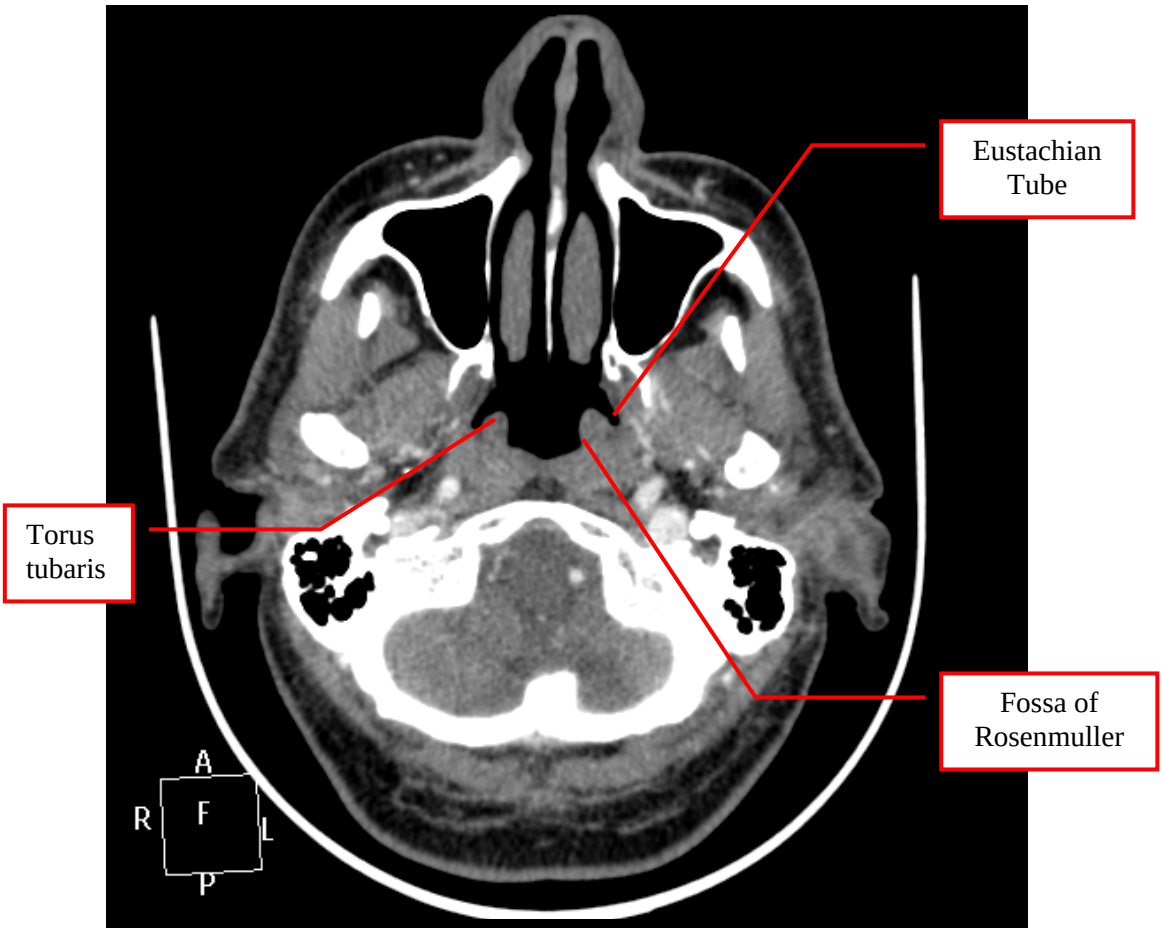

Figure 5: CT- Axial cut through a normal nasopharynx.

There are four important fascial sheaths in the nasopharynx, viz. pharyngobasilar, buccopharyngeal, carotid and prevertebral sheaths. These fascial planes can be identified on CT scans and the associated pattern of tumour spread within or across the planes, can assist with the prediction on whether a lesion of the nasopharynx is benign or malignant (Bohman, Mancuso & Thompson, et al., 1981). Benign mucosal lesions will generally not cross the dense pharyngobasilar layer, and the loose buccopharyngeal layer allows benign tumours to assume a spherical configuration. Malignant lesions, on the other hand, easily

invade the pharyngobasilar fascia and do not stay confined to the fascial planes (Bohman, et al, 1981).

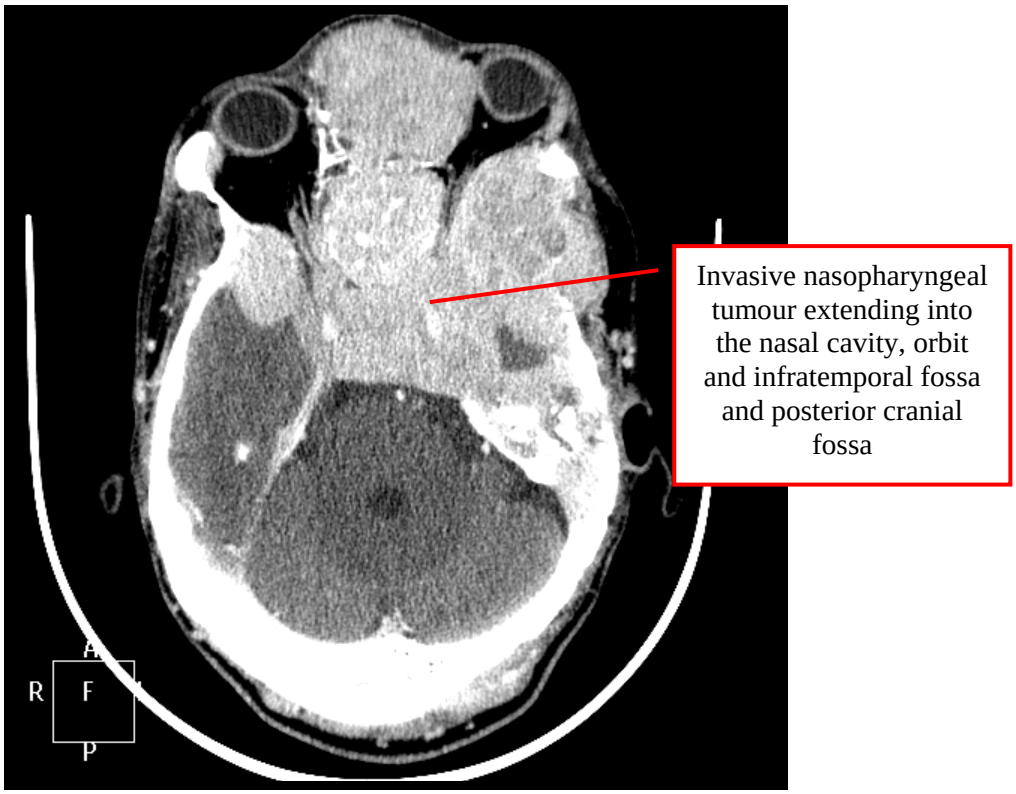

Figure 6: CT- Axial cut showing a malignant nasopharyngeal tumour.

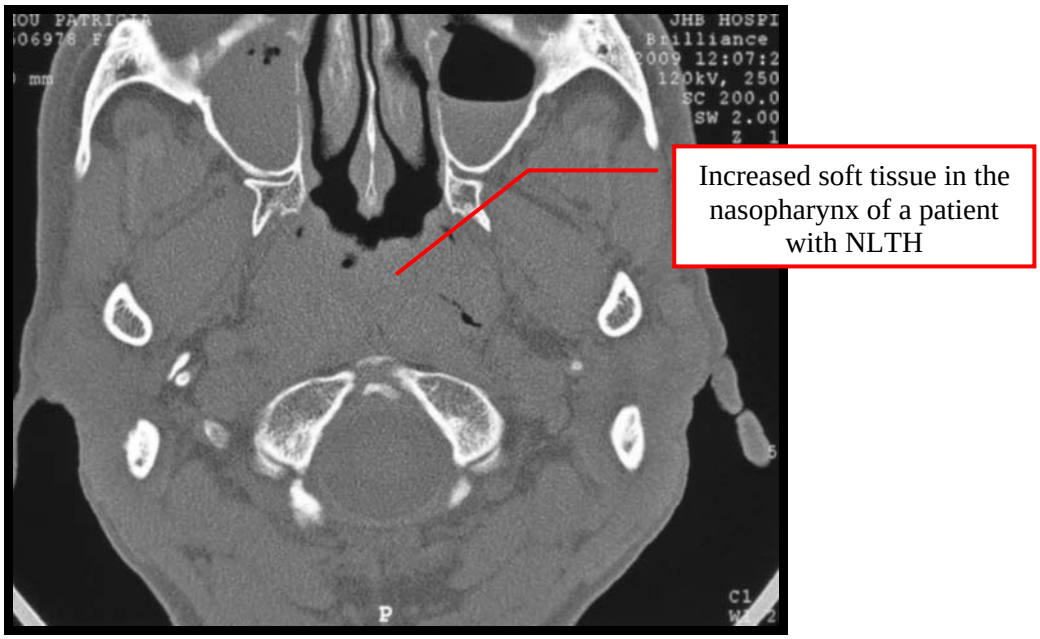

Figure 7: CT- Axial cut through the nasopharynx showing a benign tumour.

Magnetic resonance imaging is the radiological investigation of choice for the nasopharynx (Sievers, et al., 2000; Goh, et al., 2009). It has a vastly superior soft tissue contrast and resolution making it the investigation of choice to assess perineural spread, involvement of the parapharyngeal space and other surrounding areas of the nasopharynx such as the orbits, sinuses and infratemporal fossa. T1 weighted images, although it does not delineate tumour from muscle well, is very useful for the assessment of the parapharyngeal space. When used with gadolinium, the tumour becomes distinguishable from muscle and fat (Sievers, et al., 2000). Magnetic resonance imaging is essential if there is any suspicion of intracranial extension. The combination of T1 weighted imaging, T2 weighted imaging with gadolinium and fat saturation sequences makes delineation of tissues easy and reliable (Sievers, et al., 2000).

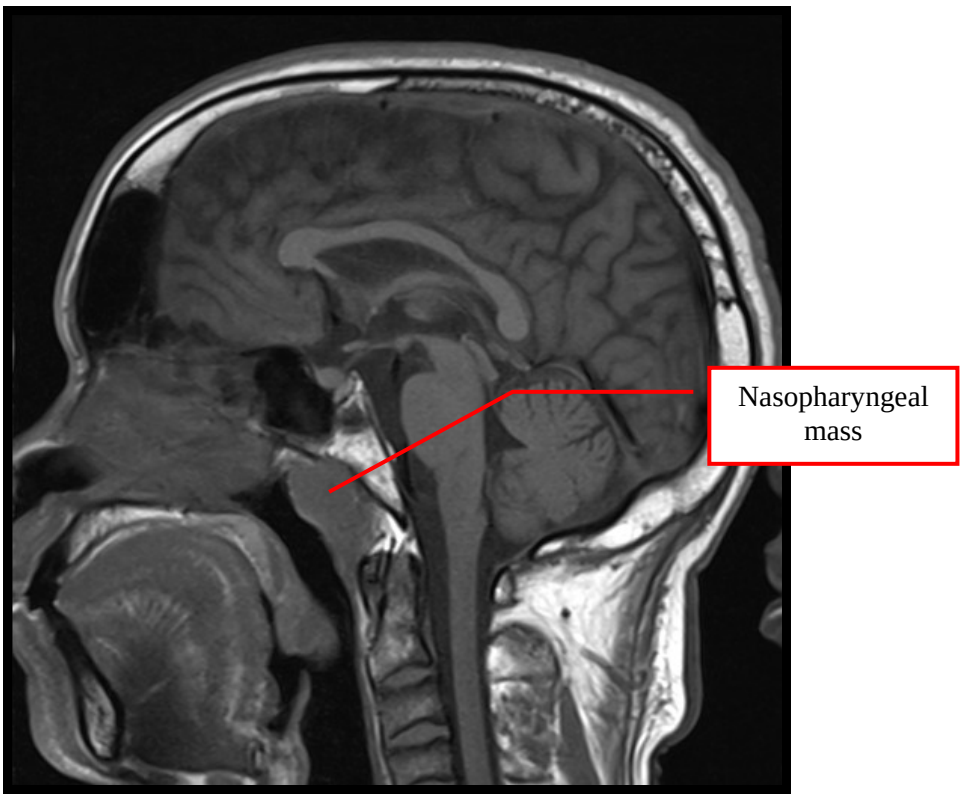

Figure 8: MRI sagittal section showing a mass in the nasopharynx.

A Positron emission tomography (PET) scan utilising 2-[fluorine-18] fluoro-2-deoxy-d-glucose (FDG) is a useful diagnostic tool for identifying malignancies, staging of the disease and detecting any recurrence of malignancy (Blodgett, Fukui & Snyderman, et al., 2005). Used alone, PET scans have a low specificity of tumour detection due to lack of anatomical landmarks and variable uptake of FDG. Positron emission tomography combined with CT scanning allows better localization of FGD uptake and can more accurately identify areas of malignancy and recurrence of tumour (Fukui, Blodgett & Snyderman, et al., 2005; Goh, et al., 2009). Of all of the above radiological modalities, FDG-PET is the most accurate for local residual or recurrent NPC (Lui, Xu & Yang, et al., 2007).

The combination of all the above-mentioned radiological investigations of the nasopharynx and its' surrounding areas is essential for accurate staging of the disease and based on these investigations, appropriate management decisions can be made.

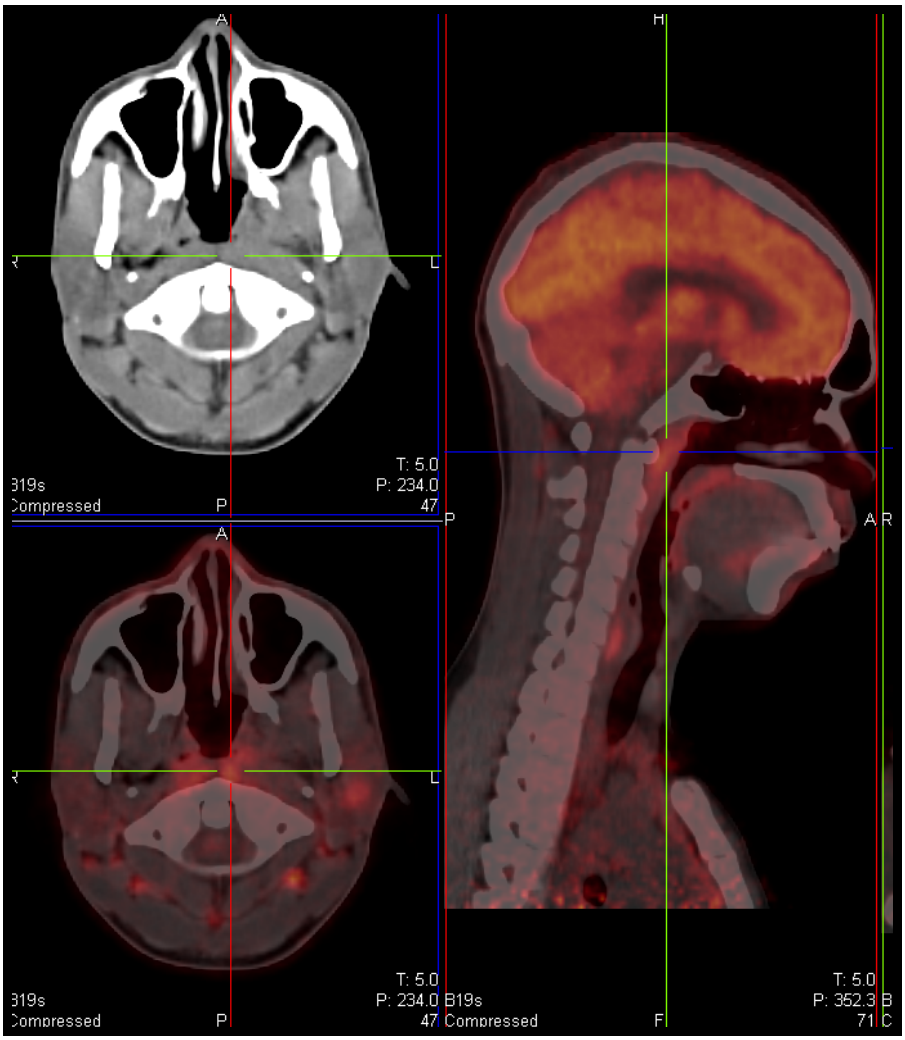

Figure 9: PET-CT of the nasopharynx .

The pictures above show asymmetry in the left side of the nasopharynx and there is increased uptake of FDG in this area which indicates residual disease in this patient.

2.7 THE BURDEN OF HIV IN SOUTH AFRICA

Global statistics in 2007 showed that there were 33.2 million people living with HIV. Of these, 30.8 million were adults and 2.5 million were children under fifteen years of age. Two and a half million people were newly infected with HIV in 2007, comprising of 2.1 million adults and 420000 children less than 15 years. Approximately 1.7 million adult deaths in 2007 were attributed to AIDS. In 2007, Southern Africa accounted for 32% of all people living with HIV and almost one third of all new HIV infections and AIDS deaths globally. South Africa was reported to have the highest number of HIV infection in the world. (UNAIDS, 2007).

The South African population was estimated to be around 49 million people in July 2009. The prevalence of HIV infection was estimated to be 10.6% and the number of people living with HIV was 5.21 million. Adults between 15 to 49 years of age accounted for 17% of this number. Over the years HIV prevalence rates have slowly risen from 9.3% in 2001 to 10.6% in 2009 and there are over 1 million more people living with HIV in 2009 as compared to 2001(4.1 million). (Statistics South Africa, 2009).

South Africa has the biggest anti-retroviral (ARV) programme in the world, but having the highest prevalence of HIV in the world, the access to treatment is still far too low (Leake, 2009). The international recommendations for starting ARV's, is at a CD4 level of below 350 cells/mm2, however in South Africa, the starting level is a CD4 level of below 200cells/mm2. By the time these patients receive their treatment, the disease has usually progressed further (Leake, 2009). It is estimated that there were 568 000 people receiving ARV's in the public sector by mid 2008 (Adam & Johnson, 2009). The number of people

in need of ARV's is over 1.5 million and the estimated costs of full scale ARV programme for 2008/9 was 996 million US dollars (Palitza, 2006).

A successful ARV programme needs support and commitment. The South African government has acknowledged that ARV treatment is a priority and has committed to supporting and expanding the current ARV programme (Kilfe, 2009). Also, with the US providing a further 900 million US dollars for ARV treatment over the next two years over and above the 4.2 billion dollars that was budgeted for ARV's in 2010, access to ARV's will be easier and the South African government's estimated target coverage of ARV treatment is a possibility (US to commit R900mil for ARVs in South Africa, 2009).

2.8 HIV AND THE OTORHINOLARYNGOLOGIST

In light of the current HIV epidemic, the Otorhinolaryngologist is faced with the challenge of diagnosing diseases associated with HIV infection. This is due to the fact that it is estimated that approximately 40% to 60% (Barzan, et al., 1990) of all patients with HIV will at some point present with head and neck manifestations of HIV infection (Gurney & Murr, 2003). More recent studies (Moazzez & Alvi, 1998) suggest that nearly 100 % of patients with AIDS will have head and neck manifestations of this disease.

Pathology in the head and neck related to HIV includes oropharyngeal, laryngeal, nasal cavity, otological, cutaneous, parotid and lymphatic lesions (Moazzez, et al., 1998) (see table 5). The nasopharynx is of critical importance to this study in that it may harbour growths such as Kaposi sarcoma (KS) or Non- Hodgkin's lymphoma (NHL) both of which are AIDS defining or stage four of the HIV infection (Mohammed, 2007). The most common benign lesion in the nasopharynx in the presence of HIV infection is benign lymphoid hyperplasia.

Table 5: Head and Neck Manifestations of HIV

Oral	Nasal	Cutaneous	Otological	Neck
Oral ulceration	Sinusitis	Kaposi sarcoma	Otitis externa	Lymphadenopathy
Candidiasis	Allergic rhinitis	Bacillary angiomatosis	Serous otitis media	Parotidomegaly
Hairy leukoplakia	Nasopharyngeal lymphoid hyperplasia	Seborrheic dermatitis	Eustachian tube dysfunction	Neck space infections
Herpes simplex	Kaposi sarcoma	Herpes zoster	Hearing loss	
Kaposi sarcoma	Non-Hodgkins lymphoma	Skin infections		
Non-Hodgkin's lymphoma		Cutaneous carcinomas		
Squamous carcinoma				

2.9 HIV AND THE NASOPHARYNX

A variety of diseases are present in the nasopharynx of the HIV positive population. Bacterial and protozoal infections as well as tuberculosis have been identified. Mass lesions of the nasopharynx include both benign and malignant disease.

The most common benign nasopharyngeal lesion in HIV positive patients is benign lymphoid hyperplasia (Barzan, et al., 1990). Benign lymphoid hyperplasia is also referred to as nasopharyngeal lymphatic tissue hypertrophy (NLTH). In a case series involving seven patients (Stern, Lin & Lucente, 1990) none with noticeable features of HIV infection, all presented with nasal obstruction and hearing loss. Only six of these patients had otitis media effusions. Examination of the nasopharynx revealed large nasopharyngeal masses which on biopsy, revealed histological diagnoses of benign lymphoid hyperplasia. Serological testing for HIV infection found that all of these patients were HIV infected.

A prospective study (Barzan, et al., 1990) was conducted on 218 HIV negative patients and 59 HIV positive patients comparing the nasopharyngeal lymphatic tissue of both groups. It was noticed that the macroscopic appearance of nasopharyngeal lymphatic tissue hyperplasia (NLTH) was always smooth, symmetrical and never ulcerated. It was however observed that NLTH was far more common in the HIV positive group. Based on these findings, the authors suggested that NLTH be recognised as one of the most common head and neck manifestations of HIV.

Nasopharyngeal lymphatic tissue hyperplasia is commonly seen in the persistent generalized lymphadenopathy (PGL) and AIDS related complex (ARC) stages of HIV

infection (Barzan, et al., 1990). In a study by Shahab, Osborne & Butler (1994), a review of the histology of lymphoid tissue from either the nasopharynx or tonsil in HIV positive patients showed that all the tissue had some degree of reactive follicular hyperplasia. It has been believed that NLTH is a benign process however one case report showed that NLTH can transform into malignant lymphoma but predictors of this type of transformation are unknown (Kieserman & Stern, 1995).

Malignant lesions of the nasopharynx include NHL, Hodgkin's lymphoma, Burkitts lymphoma and KS. Kaposi sarcoma is by far the most common malignancy in the head and neck in patients with HIV infection (Mohammed, 2007). Its existence in the nasopharynx is uncommon and not well documented but one study indicated that 4.3% of KS was found in the nasopharynx (Yang, Hsu & Liu, et al., 2009).

Kaposi sarcoma and NHL are both AIDS defining malignancies. Incidence rates of these cancers have decreased and success in treatment of these malignancies in the HIV population has improved over the years, and the biggest contributor seems to be the effects of highly active antiretroviral therapy (HAART) (Bower, Palmieri & Dhillon, 2006). HAART has also increased the life span of AIDS sufferers, and this has increased the number of non-AIDS defining malignancies and Human Papilloma Virus (HPV) associated tumours (Bower, et al., 2006; Mohammed, 2007). Clinicians are thus observing a changing spectrum of malignancies in HIV infection.

2.10 OBSERVATIONS AND HYPOTHESIS

There is no study to date in South Africa documenting the prevalence of nasopharyngeal neoplasms. Hence, the purpose of this study is to determine the tumour types that do occur more frequently in the South African setting and to try to determine those factors that may be influencing the pathologies. Anecdotally, the impressions gained by clinicians in Otorhinolaryngology over the past 10 years is that the majority of the patients seen with mass lesions in the nasopharynx are being diagnosed with benign conditions, especially that of lymphoid hyperplasia.

The hypothesis of this study is thus based on the experienced clinicians' observation that the incidence of benign tumours of the nasopharynx is far more prevalent then those that are malignant.

CHAPTER 3

3. MATERIALS AND METHODS

This chapter describes the study process, lists the inclusion and exclusion criteria of this study and concludes with the ethical considerations.

3.1 STUDY LOCATION

This study was conducted at the Charlotte Maxeke Johannesburg Academic Hospital.

3.2 STUDY DESIGN

This study is a retrospective clinical audit.

3.3 STUDY PERIOD

This retrospective study identified patients diagnosed with nasopharyngeal pathology from 01/01/2003 to 31/12/2008.

3.4 STUDY POPULATION

All adult patients who may have underwent a biopsy of the nasopharynx in theatre, under general anaesthetic, were considered for this study.

3.5 INCLUSION CRITERIA

- Patients over 18yrs of age
- All patients that underwent a biopsy of the post nasal space or nasopharynx.

3.6 EXCLUSION CRITERIA

- Patients under 18yrs of age. Children were excluded from this study to prevent lymphoid hyperplasia, a very common pathology in this age group from confounding the results.
- Patients previously diagnosed and treated for pathology of the nasopharynx that require a re-biopsy following treatment. This will avoid duplication of patients and identify only newly diagnosed patients.

3.7 DATA COLLECTION

Patients for this study, clinical information & pathology reports were identified from three main data sources, which included the operating theatre surgical register, patients' hospital files, and National Health Laboratory Service (NHLS) database.

The Otorhinolaryngology operating theatre surgical register was used as the primary reference to identify patients. Names, hospital numbers, age and date of biopsy of any patient who may have had a post nasal space biopsy were recorded. The main key words used to identify possible subject were: Post nasal space (PNS) biopsy, evaluation under anaesthesia (EUA) of PNS, adenoidectomy, nasopharyngeal biopsy, panendoscopy, intranasal biopsy, biopsy of nasal mass, EUA nasal cavity, nose or nostril and polypectomy.

The hospital numbers and patient names were used to search the NHLS database to identify all patients that had a biopsy of the nasopharynx. The hospital files for these patients were requested from the records department and viewed to obtain the history of the presenting complaints, clinical findings, histology reports, HIV status, age and gender. In a few cases, the histology results and HIV results were not found in patients files, and these were traced using the patients hospital number and the NHLS data base.

Data that was retrieved from patients' files included the following:

1. Patients age
2. Gender
3. Presenting complaints
4. Clinical findings
5. Histopathology result
6. HIV result

3.8 DATA ANAYLSIS

Data from record reviews were coded and captured onto an Excel spreadsheet and transferred to a Statistica version 6 (STATA-6) programme for analysis by computer. Non parametric statistical methods were used as the data was predominantly non-normal with unequal variance. Values are reported as median and range (minimum and maximum). Mann-Whitney U test was used to determine differences between independent variables. Spearman's rank correlation coefficient (rho) was used to determine the associations. Chi square test was used for comparison of 2 proportions, counts etc. A multiple regression model was used to find independent predictors of malignancy.

3.9 ETHICAL CONSIDERATIONS

Permission to conduct this study was obtained from the Acting Chief Executive Officer of CMJAH, Dr S Mfenyana and the Head of the School of Pathology of NHLS, Professor M Hale.

Ethics clearance was granted by the University of Witwatersrand Human Research Ethics Committee to conduct this study.

Informed consent from patients used in this study was not required since this is a retrospective clinical audit. The HIV testing that was carried out on some of these patients was done at the discretion of the doctor evaluating the patient and not for the purposes of this study. Routinely informed consent and pre-test counselling is required prior to testing for HIV. Patients are also adequately informed about the risks of surgical procedures prior to signing of a consent form.

Confidentiality was maintained by keeping patients details anonymous, but traceable by using a coded number.

CHAPTER 4

4. RESULTS

This chapter highlights the major findings of this study. Following the descriptive data of the study group, the data is then described in relation to the aims of this study.

There were a total of 81 patients included in the study. This included 54 males (67%) and 27 females (33%).

The median age for the entire study group was 42 years. The male group had median age of 43.5 years while the female median age was lower at 39 years (see table 6). There was no statistical difference between the 2 genders in terms of their ages (Mann Whitney U test, p= 0.39- see Figure 10).

Table 6: Age distribution of study patients (n=81)

	Median Age	Minimum	Maximum
Entire group	42years	18 years	82 years
Males	43.5 years	18 years	76 years
Females	39 years	19 years	82 years

Patients were categorized into age groups (see figure 11) to determine if there was a trend for benign and malignant disease. There was no statistical difference between age and benign and malignant disease (p=0.14) or age groups and benign and malignant disease (p= 0.1) using Spearmans rank order correlations.

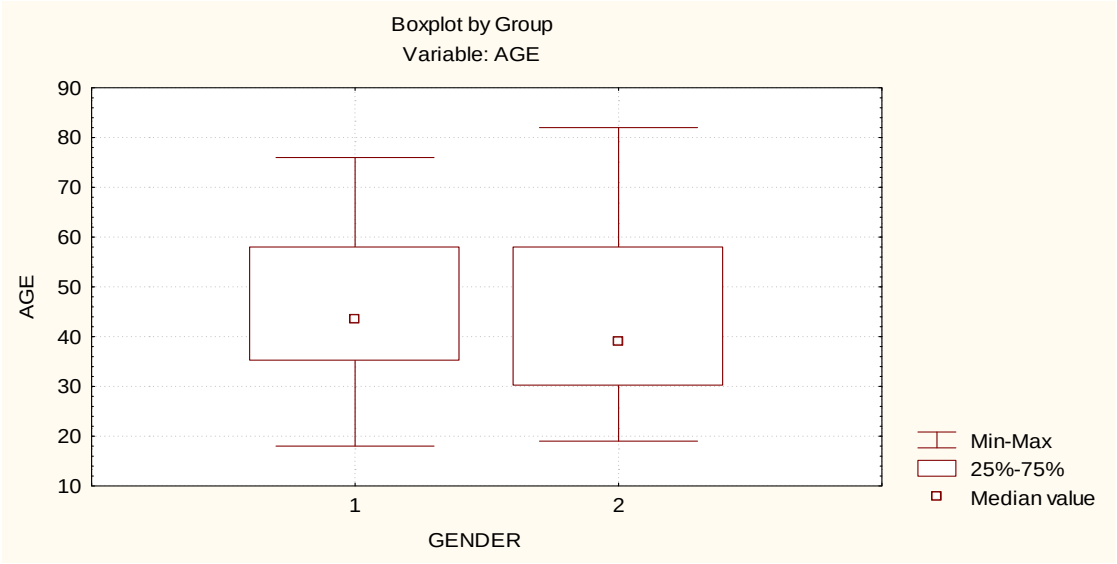

Figure 10: Box and whisker plot of age (yrs) vs. gender, 1=Male and 2=Female

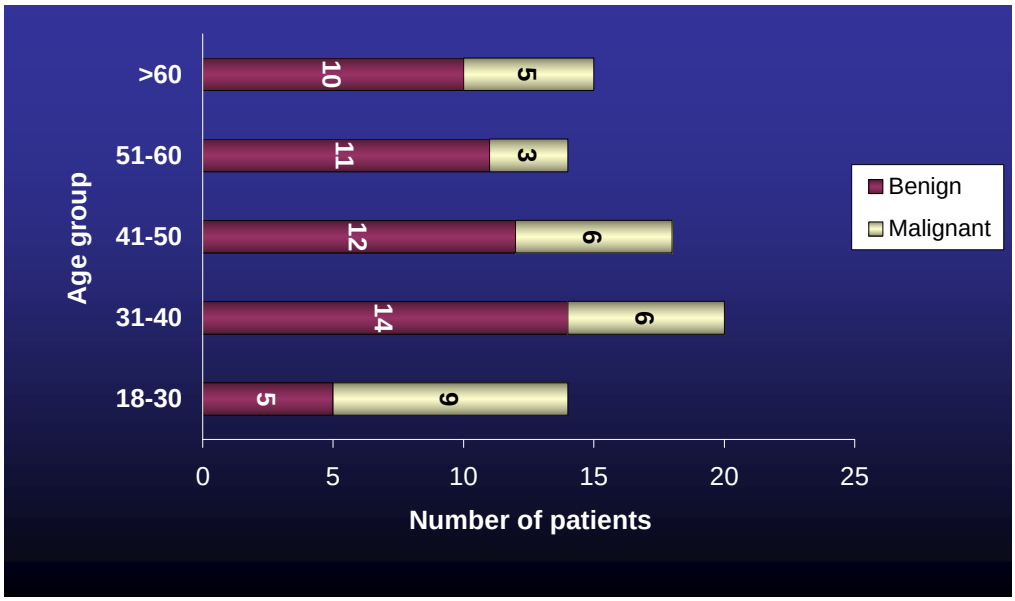

Figure 11: Distribution of age groups (yrs) in the study population (n=81)

The main aim of this study was to determine the frequency of the various nasopharyngeal tumours. Fifty two patients (64%) had benign disease and 29 patients (36%) had malignant disease (see figure 12). Of the benign conditions, reactive lymphoid hyperplasia was found to be the most common, followed by inflamed respiratory mucosa. (See figure 13 for distribution all pathology and figure 14 for distribution and percentages of benign disease.)

In the malignant group, NPC and NHL predominated. (See figure 15 for distribution and percentages of malignant disease.)

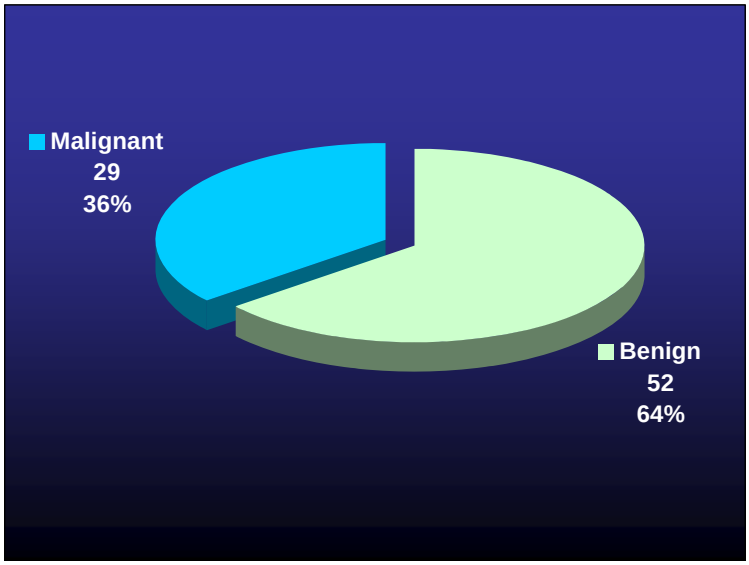

Figure 12: Distribution of benign and malignant disease (n=81)

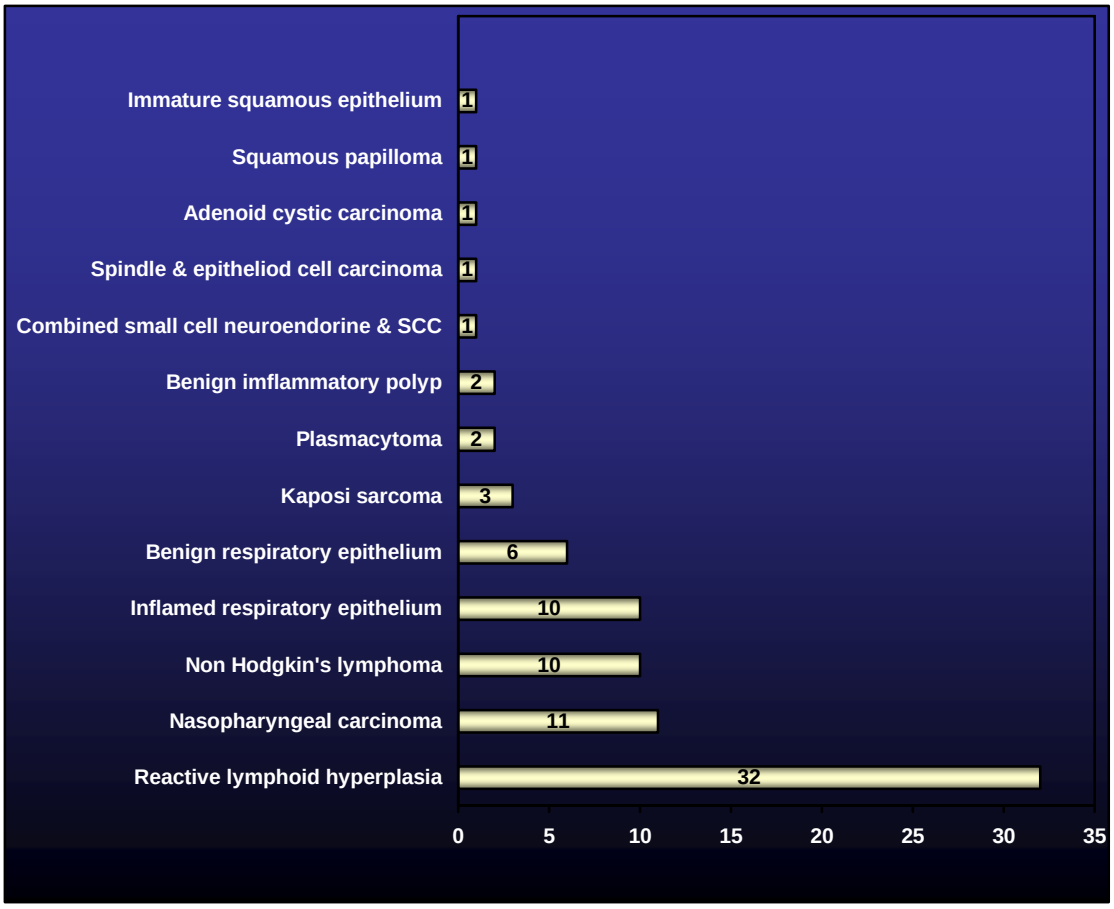

Figure 13: Frequency of all nasopharyngeal pathology (n=81)

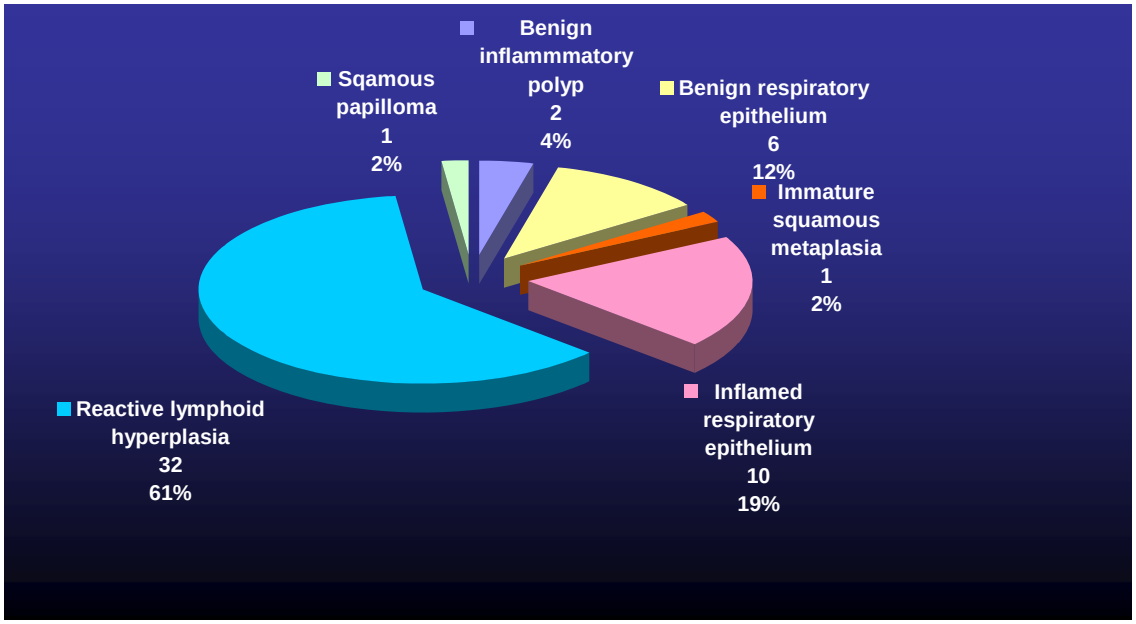

Figure 14: Frequency of benign disease (n=52)

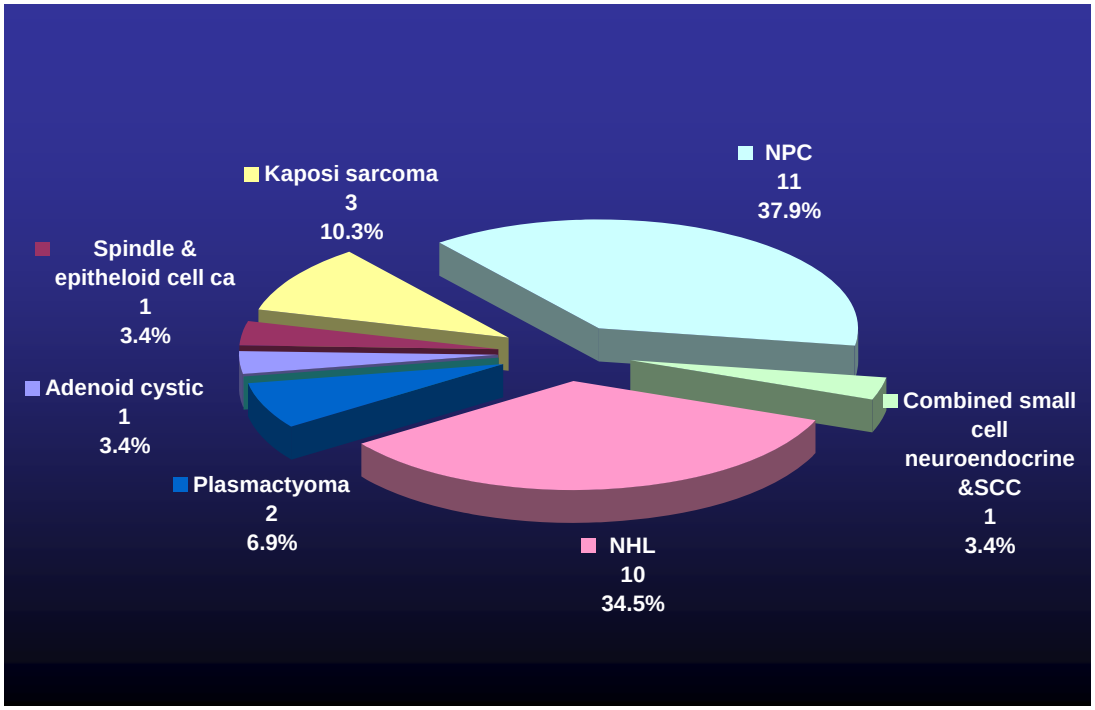

Figure 15: Frequency of malignant disease (n=29)

Thirty four males (65%) had benign disease compared to 18 females (35%) who had benign disease. Twenty males had malignant disease compared to 9 females (see table 7). There was no significant correlation between gender and malignancy (r= -0.04, p=0.75).

Table 7: Distribution of males and females with benign and malignant disease

	Males	%Male	Female	%Female	Total
Benign	34	*65%*	18	*35%*	52
Malignant	20	*69%*	9	*31%*	29

Human immune deficiency virus (HIV) status was known in 41 of the 81 patients. The remaining 40 patients did not have a documented HIV result at the time of the study. Twenty eight patients were HIV positive and 13 patients were HIV negative. Of the 41 patients whose HIV status was known, 25 were male and 16 were female. There was no

significant difference between the number of males with an unknown HIV status compared to the number of females with an unknown HIV status ($X^2 = 1.21$, $p = 0.27$). (See table 8.)

Table 8: Gender distribution among patients with HIV status known and those with unknown HIV status

	HIV status known	HIV status unknown
Male	25(71%)	29 (73%)
Female	16 (29%)	11 (27%)
Total	41	40

Nineteen (19) males (76% of all males) were HIV positive compared to 9 females (56% of all females) (see table 9). There was no significant difference between the number male HIV positive patients and female HIV positive patients ($X^2 = 1.98$, $p = 0.16$)

Table 9: HIV frequency among male and female study patients (n=41)

Gender	HIV positive	%HIV positive	HIV negative	% HIV negative	Total number
Male	19 patients	76%	6 patients	24%	25 patients
Female	9 patients	56%	7 patients	44%	16 patients

The secondary aim of this study was to determine if there was an association between the presenting symptoms of nasopharyngeal disease and a tumour type (i.e. benign or malignant). Symptoms that were looked at specifically as symptoms of nasopharyngeal disease included: persistent nasal obstruction, epistaxis, hearing loss, otalgia, a neck mass and neurological fallout. Symptoms that made up the group labeled as “other” were non-

specific for nasopharyngeal disease and were grouped together because of the low numbers. These symptoms included tinnitus, throat pain, trismus, dysphagia, odynophagia, snoring, anosmia, rhinitis, headache, parotid swelling, eye mass and hoarseness. Symptoms were recorded as present if the patient reported it as one of their presenting complaints or if the physician asked for or examined for that symptom. Symptoms were recorded as being absent if the information was not reported by the patient, never evaluated by the physician or not present. (See table 10).

Table 10: Record of symptoms among the study patients

Symptoms	Present
Nasal congestion	42 *(52%)*
"Other" symptoms	27 *(33%)*
Hearing loss	26 *(32%)*
Neck mass	26 *(32%)*
Epistaxis	12 *(15%)*
Neurological	11 *(14%)*
Otalgia	7 *(9%)*

Using multiple regressions, a model was developed to predict tumour nature. Included in the model were age, gender, HIV status and the presence or absence of relevant symptoms listed in table 11 below. The independent predictors of tumour nature were: nasal congestion, epistaxis, hearing loss, otalgia and HIV status. The statistically significant positive predictors of malignancy were the presence of nasal congestion, epistaxis and otalgia.

The presence of hearing loss and a positive HIV status was independently associated with benign disease (see table 12).

Table 11: Differences between malignant and benign disease with reference to common symptoms using a multiple regression model

Number	Symptoms	Benign	Malignant	p value*
1a	Nasal congestion	24 *(46%)*	18 *(62%)*	
1b	No Nasal congestion	28 *(54%)*	11 *(38%)*	**0.045***
2a	Epistaxis	5 *(10%)*	7 *(24%)*	
2b	No Epistaxis	47 *(90%)*	22 *(75%)*	**0.005***
3a	Hearing loss	19 *(37%)*	7 *(24%)*	
3b	No Hearing loss	33 *(63%)*	22 *(76%)*	**0.031***
4a	Otalgia	3 *(6%)*	4 *(14%)*	
4b	No Otalgia	49 *(94%)*	25 *(86)*	**0.036***
5a	Neck mass	15 *(29%)*	11 *(38%)*	
5b	No Neck mass	37 *(71%)*	18 *(62%)*	0.33
6a	Neurological	3 *(6%)*	*8 (27%)*	
6b	No Neurological	49 *(94%)*	21 *(72%)*	0.27
7a	“Other” symptoms	15 *(29%)*	12 *(41%)*	
7b	No” Other” symptoms	37 *(71%)*	*17 (59)*	0.28

* Indicates a statistically significant difference. Actual number of patients with complaints indicated in columns. Percentages indicated in parenthesis

Table 12: The frequencies of HIV positive status and HIV negative status among patients with benign and malignant disease

	Benign disease	Malignant disease	P value
HIV positive status	20 (80%)	8 (50%)	
HIV negative status	5 (20%)	8 (50%)	**0.000***
Total	25	16	

* P value determined from multiple regression model.

The third aim of this study was to determine if there was an association between a tumour type and the presence of HIV infection. As mentioned above, the presence of HIV infection was associated with benign disease. In the subgroup of this study where HIV status was known, further analyses were carried out. There were a total of 41 patients in the group where the HIV status was known. Twenty eight patients (68.3%) were known positive. Spearman's rank order correlations showed that there was no statistically significant correlation between age (p=0.53) or age groups (p=0.42) and HIV.

The most common pathology in the HIV positive group was reactive lymphoid hyperplasia (57.2%), followed by NHL and KS. (See figure 16).

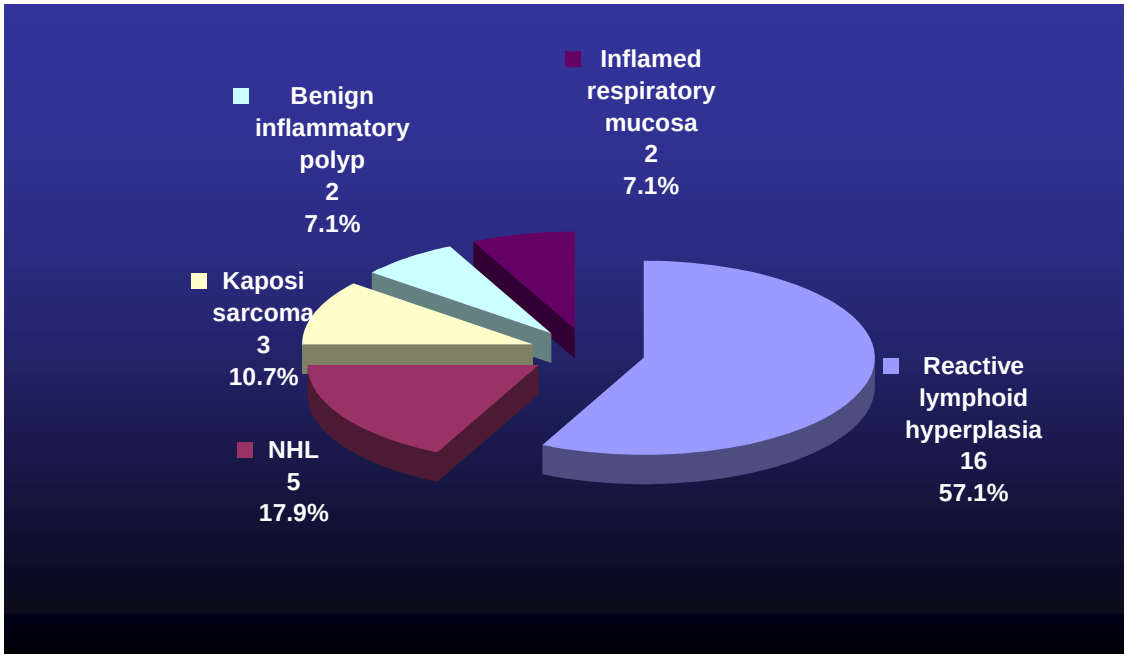

Figure 16: Frequency of pathology in the HIV positive group (n=28)

There were 13 patients in the known HIV negative group. Malignant disease was found to be frequent in the HIV negative patient group with 38.5% having NPC. (See figure 17 for frequencies of pathology in HIV negative subset).

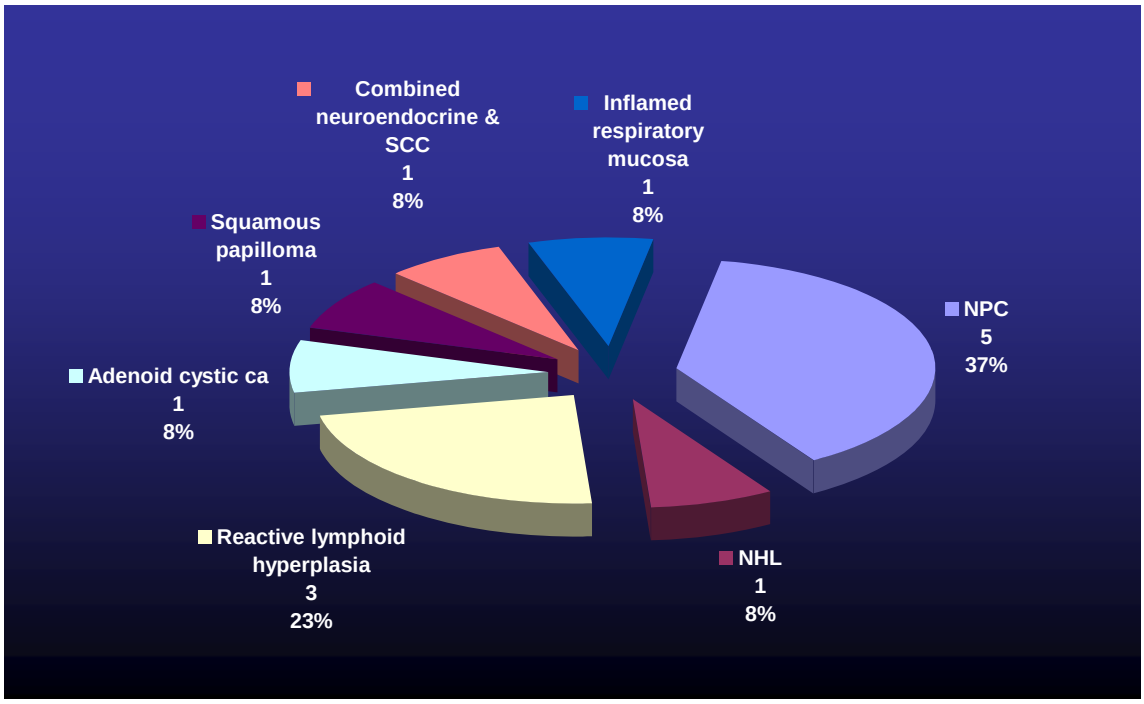

Figure 17: Frequency of pathology in the HIV negative group (n=13)

As previously mentioned the presence of persistent nasal blockage, epistaxis and otalgia were independent predictors of malignant disease. The presence of at least one or more of these symptoms was associated with an odds ratio of 3.06 for malignant disease. The 95% confidence intervals are 1.17 to 8.01. The risk attributable to these symptoms is 52%. (See table 13).

The absence of HIV infection was in fact associated with malignant disease, with an odds ratio of 4.00 and 95% confidence intervals of 1.04 to 15.43. Alternatively it can be stated that the presence of HIV infection was in fact associated with benign disease with an odds ratio of 0.25 for malignant disease (i.e. protective) and 95% confidence intervals of 0.06 to 0.96. (See table 13.)

Table 13: Table of risk for malignant disease

Risk of Malignant disease	**Presence of symptoms***	**HIV negative status (absence of HIV infection)**
Absolute risk	62%	47%
Relative risk	2.15	2.1
Risk difference	33%	24%
Attributable risk	52%	54%
Odds ratio	3.06 (1.17 – 8.01)#	4.0 (1.04 - 15.4)#

* Symptoms include persistent nasal blockage, epistaxis, otalgia or more than 1 of them.

Ninety five percent (95%) confidence intervals in parenthesis.

CHAPTER 5

5. DISCUSSION

This chapter discusses the study findings and compares it to the findings in other relevant studies. The limitations of this study are also discussed at the end of this chapter.

In this study, the nasopharyngeal biopsies of 81 adult patients presenting to CMJAH between 2003 and 2008, were analysed.

The hypothesis of this study stated that benign tumours of the nasopharynx were more common than their malignant counterpart and the main aim was to identify the most common types of tumours. The results confirms this study's hypothesis that benign conditions are more common (ratio of 1.8:1) with 64% of this study group having benign disease and 36% having malignant disease. It was unfortunately not possible to calculate the incidence or prevalence rates for the various pathologies because the total number of patients seen at the OPD during 2003 and 2008 were not recorded.

A similar study was conducted over a seven year period in Uttar Pradesh in India, with the main aim being to determine the incidence rates of non-neoplastic and neoplastic polypoid lesions of the nasal cavity, paranasal sinuses and the nasopharynx. Although the overall observation showed that benign lesions in the three abovementioned sites outnumbered malignant lesions by a ratio of 1.5:1, no non-neoplastic lesions were found in the nasopharynx (Zafar, Khan & Afroz, et al., 2008). The histopathologies of the masses found in the nasopharynx were not covered in the article, thus a comparison to this study could

not be undertaken. The study by Zafar et al. (2008) also included biopsies of both adult and children (mean age of 22.5 years) whereas this study excluded patients under the age of 18 years.

In Biswas, Ghosh & Mukhopadhyay, et al. (2002), 30 cases of nasopharyngeal masses were reported in one year at their institution and this number accounted for 0.08% of all patients seen at their clinic in the same year. In their study, benign tumours were also more common than malignant disease with a ratio of 1.5:1 (as compared to 1.8:1 in this study). Antro-choanal polyp was found to be the most common pathology in their study, followed by angiofibroma and adenoids (or lymphoid hyperplasia). Nasopharyngeal Carcinoma accounted for 13% of the masses. The study by Biswas et al (2002), like the study by Zafar et al. (2008) included children with nasopharyngeal masses

Adenoidal hypertrophy is very common in children and it usually regresses as they enter adulthood. In both of the abovementioned studies one would have expected the results to show a higher percentage of adenoids and a higher ratio of benign to malignant disease. The primary reason for excluding patients under the age of 18 years from this study was to avoid this common benign disease from confounding the results.

In Johannsson, et al. (1997), malignant nasopharyngeal pathologies were evaluated in Iceland over a 26 year period. Nasopharyngeal Carcinoma was found to be the most common malignant disease (82%), followed by plasmacytoma (4%), lymphoma (3%) and rhabdomyosarcoma (1%). This study also found that nasopharyngeal carcinoma to be the most common malignant disease (38% of all malignant disease and 13.6% of all nasopharyngeal disease), followed by NHL and KS (34.5% and 10.3% of all malignant

disease respectively). South Africa has poor record of the incidence of NPC and most studies assume its incidence to be similar to that of the Western world but this may not actually be true. An evaluation of true incidence rates of NPC in this country should rectify any discrepancies.

In Hopping, et al. (1983), NPC was also found to be the most common malignancy followed by lymphoma which is in keeping with the findings of this study. The common benign conditions included chronic inflammation, lymphoid hyperplasia, Thornwaldt cyst, mucus retention cyst, choanal polyp and normal mucosa. Of note in this study, is that reactive lymphoid hyperplasia accounted for 62% of all benign disease and 39.5% of all nasopharyngeal masses.

The secondary aim of this study was to determine if there was an association between symptoms and benign or malignant disease. This study found a statistically significant association between the symptoms of nasal obstruction, otalgia and epistaxis with malignancy. HIV positive disease and hearing loss was associated with benign disease. The presence of neck mass or neurological fallout was not found to be statistically significant.

A study looking at nasopharyngeal masses and serous otitis media (Glynn, et al., 2006), found that all their patients with malignancy presented with hearing loss as their presenting complaint and were also found to have a suspicious looking mass in the nasopharynx. Masses were considered as being suspicious if they looked irregular, granular or exophytic. Three of their four patients demonstrating malignant lesions had unilateral otitis media effusions and one had bilateral effusions. This study being a retrospective record review did not record the clinicians' assessment of the middle ear and the appearance of the

nasopharyngeal mass prior to biopsy, so correlation with other studies comparing the abovementioned findings was not possible. Contrary to their study results, hearing loss in this study was predictive for benign disease.

In Stern, et al. (1990), a small series of 7 patients who presented with hearing loss and nasal obstruction were studied. They found all of the biopsies of the PNS to be that of benign lymphoid proliferation or hyperplasia and all patients in this group were HIV positive. Similar to this study, hearing loss was associated with benign disease. However this study found nasal obstruction to be associated with malignant disease ($p=0.045$).

Hearing loss can be conductive, sensorineural or a mixed pattern. None of the studies, including this study, concentrated on the type of hearing loss that was present. A prospective study with larger numbers of patients may help determine exactly how hearing loss relates to nasopharyngeal pathology.

In this study benign disease predominated and the major contributor of benign pathology was reactive lymphoid hyperplasia which was far more common in the HIV positive subset. Patients with HIV infection have a weaker immune system as compared to the general population and prolonged ear infections, presence of ototoxins released by the pathogens, systemic illnesses and ototoxic drugs (anti tuberculosis drugs and ARV's) can contribute to hearing loss. This could possibly be the reason why this study found an association between hearing loss and benign disease rather than malignant disease.

In Hopping, et al. (1983), the symptomatology of nasopharyngeal masses in adults was reviewed and it was determined that symptoms were more common in the malignant

group. Serous otitis media was the most common presenting symptom in both groups. Epistaxis and trismus was exclusive to the malignant group and malignant lesions presented with serous otitis media effusions as the earliest sign, followed by nasal obstruction, pain and bleeding. Although in this study, epistaxis, nasal obstruction and otalgia were associated with malignant disease, these symptoms were not exclusive to the malignant group.

Cervical lymphadenopathy in the study by Hopping, et al. (1983) was present in both groups, but more commonly in the malignant group. Masses in the neck in the benign group were mostly from a malignant process not related to the nasopharynx.

The lack of statistical significance in the presence of a neck mass and malignant disease in this study may be explained by a two main possibilities. Firstly, like Hopping, et al. (1983) neck masses were from malignancy not related to the nasopharynx. A few of the subjects in this study with malignant neck masses had a biopsy of their nasopharynx as part of a panendoscopy, which was aimed to find the primary site of malignancy, and none of these patients were found to have malignancy in the nasopharynx, thus skewing the results.

Secondly, 34.6% of the study group had confirmed HIV positive results. In the HIV positive group, 71.4% had benign disease of the nasopharynx. In the presence of HIV infection, generalized lymphadenopathy is very common, especially in the PGL phase, and neck lymphadenopathy in this group is most likely to be associated with the HIV infection rather than nasopharyngeal disease.

Neurological fallout is generally associated with a malignant process. However, in this study the correlation of neurology with malignant disease was unsuccessful. Similarly as discussed above, looking for the primary site of malignancy in the nasopharynx for occult primary tumours, may during a panendoscopy reveal a benign process in the nasopharynx. Three of the 11 patients that had neurological symptoms in this study, had facial weakness. Nasopharyngeal malignancy needs to be very advanced to cause facial weakness and other cranial nerve palsies precede that of the facial nerve. These patients could possibly have had a Bell's palsy. Also only 11 patients in the entire study group had neurological fallout and possibly larger numbers are needed to prove statistical significance.

The third aim of this study was to determine if there was a relationship between nasopharyngeal neoplasms and a superimposed HIV infection. This study found that HIV infection was associated with benign disease and protective of malignant disease with an odds ratio of 0.25 (CI 0.06-0.96) for malignancy. Reactive lymphoid hyperplasia was predominant in the HIV positive group accounting for 57% of all the pathology. AIDS defining NHL and Kaposi sarcoma accounted for 17.9% and 10.7% of nasopharyngeal pathology respectively.

Reports of nasopharyngeal lymphoid tissue hypertrophy are becoming more common in the literature. Probably one of the earliest is that of Stern, et al. (1990), who found all of their HIV positive patients having benign lymphoid proliferation accounting for their nasopharyngeal masses. All patients in their study group also complained of hearing loss. Based on these observations, it is suggested that nasal obstruction secondary to nasopharyngeal lymphoid proliferation together with hearing loss can be the first clues that a patient may have HIV infection.

A comparative study involving a much larger group compared nasopharyngeal biopsies of 59 HIV positive patients to a control group of 218 HIV negative patients. It demonstrated, like this study, a significantly higher incidence of nasopharyngeal lymphoid hyperplasia in the HIV positive group. NLTH was also found to be more common in PGL and ARC stages of HIV infection. All of these masses morphologically were symmetrical and non-ulcerated. (Barzan, et al., 1990).

Evaluation of HIV infected patients with nasopharyngeal or tonsillar masses by Shahab, et al. (1994) revealed reactive follicular hyperplasia in all cases. All of these patients had nasal stuffiness as their presenting complaint. Cervical lymphadenopathy was present in 6 of the 9 patients and hearing loss in 5 of the 9 patients.

Non Hodgkin's lymphoma is 60-200 times more common in HIV positive population (Bower, et al., 2006; Mohammed, 2007) and is an AIDS defining illness. Hodgkin's lymphoma, on the other hand, is considered as non-AIDS defining but occurs 8-10 times more frequently in HIV positive population (Grogg, Miller & Dogan, 2007; Mohammed, 2007). In this study, there were no cases of Hodgkin's lymphoma but NHL accounted for 17.9% of disease in the HIV positive subset and 7.7% in the known HIV negative group (2.3 times more common in the HIV positive group).

Kaposi sarcoma is the most common HIV associated malignancy occurring between 1000-77000 times more than the general population (Mohammed, 2007). The incidence rates of KS have gradually declined even in the pre- HAART era and this intensified with the introduction of HAART (Bower, et al., 2006; Mohammed, 2007). Kaposi sarcoma in the

nasopharynx is rare and incidence rates of KS in the nasopharynx are not well documented in the literature however one study quotes a rate of 4.3% (Yang, et al., 2009). In this study KS was present in 3 out of 81 patients, comprising of 10.3% of all malignant nasopharyngeal pathology and was also found to exist exclusively in HIV positive patients.

5.1 LIMITATIONS

Although this study was very informative, there were a few limitations that are discussed below.

The adequacy of the records, particularly the clinical information captured on the admission notes, was sub-standard. Clinicians were all not fully aware of all the symptomatology of nasopharyngeal pathology so history taking and examination in most instances were not complete and consistent but were adequate to complete this study. The best way to overcome such a problem is to conduct a prospective study, thus ensuring all subjects undergo a standardized evaluation.

Clinic records prior to 2006 were poor. The total number of patients attending the OPD during the study period could not be determined thus incidence and prevalence rates could not be determined.

A small number of archived hospital records were also misfiled and some clinical information was misplaced. The number in this instance was negligible and clinical notes were carefully scrutinized to ensure that the recorded data was actually that of the subject in question.

The theatre log book which was the first source of screening for patients for this study had a negligible amount of patients' details that were incorrectly captured. This made clinical records difficult to trace and a few patients were thus not considered for this study.

Charlotte Maxeke Johannesburg Academic Hospital is a tertiary-quaternary centre for referral of patients to specialised units such as radiation oncology and medical oncology. The actual numbers of malignant nasopharyngeal tumours may be much higher than that determined in this study as patients may have had a direct referral to these units rather than being evaluated or biopsied by the Otorhinolaryngology unit at CMJAH.

Although this study is a six year review it only produced 81 patients that met inclusion criteria. Perhaps a longer study period is needed to get better results but a prospective study will give a more accurate and detailed account of the tumours.

CHAPTER 6

6. CONCLUSIONS AND RECOMMENDATIONS

Benign disease of the nasopharynx is much more common than malignant pathology. Symptoms of otalgia, nasal obstruction and epistaxis appear to be associated with malignant disease. Hearing loss and HIV infection were found to be predictors of benign disease.

Although a prevalence rate of NPC could not be determined in this study, NPC is still the most common malignant disease of the nasopharynx. Reactive lymphoid hyperplasia was shown to be the most common benign disease. Most of the patients that had reactive lymphoid hyperplasia had concurrent HIV infection.

Symptoms and macroscopic appearance of masses in the nasopharynx could guide one as to whether or not a nasopharyngeal mass is benign or malignant and whether it warrants a biopsy. However, if one opts not to biopsy a benign looking nasopharyngeal lesion, close and regular follow up is recommended. The follow up examination should include nasal endoscopy in the OPD setting and regular CT scanning of the nasopharynx to look for progression of the lesion and to look for asymmetry especially in the pharyngeal recess.

This conservative approach to nasopharyngeal masses should be reserved for institutions that have very limited financial and surgical resources. This “watch and see” approach may also be of value in institutions that have a very high incidence of HIV infection, where one

can predict that most patients will have a nasopharyngeal mass, and it is most likely to be a benign process. Biopsy should then be performed for all suspicious looking lesions.

With emerging case reports of malignant transformation of NLTH, one perhaps should have a higher threshold for biopsying even benign looking lesions.

Nasal obstruction is one of the most common presentations of nasopharyngeal disease; hence it would be both beneficial to the patient and the physician to surgically relieve the obstruction by way of adenoidectomy if it is safe to do so and if there is no progression of disease intracranially. This way the patient would benefit by having a good airway to breathe through and the surgeon can have the specimen evaluated histologically for malignancies.

REFERENCES:

Adam, M. A. & Johnson, L.F. 2009. Estimation of adult antiretroviral coverage in South Africa. *South African Medical Journal*. 99(9):661-667.

Barzan, L.; Carbone, A. & Tirelli, U.; et al. 1990. Nasopharyngeal lymphatic tissue in patients infected with human immunodeficiency virus. A prospective clinicopathologic study. *The Archives of Otolaryngology - Head & Neck Surgery*. 116:928-31.

Biswas, G.; Ghosh, S. K. & Mukhophadyay, S.; et al. 2002. A clinical study of nasopharyngeal masses. *Indian Journal of Otolaryngology Head and Neck Surgery.* 54(3):193-195.

Blodgett, T. M.; Fukui, M. B. & Snyderman, C. H.; et al. 2005. Combined PET-CT in the head and neck: Part 1. Physiological, altered physiological and artefactual FDG uptake. *RadioGraphics.* 25:897-912.

Bohman, L.; Mancuso, A. & Thompson, J.; et al. 1981. CT Approach to benign nasopharyngeal masses. *American Journal of Roentgenology*. 136:173-180.

Bower, M.; Palmieri, C. & Dhillon, T. 2006. AIDS- related malignancies: changing epidemiology and the impact of highly active antiretroviral therapy. *Current Opinion in Infectious Disease.* 19:14-19.

Chan, A.T.C.; Teo, P.M.L. & Johnson, P.J. 2002. Nasopharyngeal carcinoma. *Annals of Oncology.* 13:1007-1015.

Cummings, C.W.; Flint, P.W. & Harker L.A.; et al. 2005. *Cummings Otolaryngology Head & Neck Surgery*. Fourth Edition. Volume 2, Philadelphia: Mosby, 1669-1684.

Fukui, M.B.; Blodgett, T.M. & Snyderman, C.H.; et al. 2005. Combined PET-CT in the head and neck: Part 2. Diagnostic uses and pitfalls in oncological imaging. *RadioGraphics*. 25:913-930.

Glynn, F.; Keogh, I.J. & Ali, T.A.; et al. 2006. Routine nasopharyngeal biopsy in adults presenting with isolated serous otitis media: is it justified? *The Journal of Laryngology & Otology*. 120(6):439-41.

Godtfredson, E. 1944. Chapter VI: Symptomatology of Malignant Nasopharyngeal tumours Illustrated from Topographic Anatomical orientation. *Acta Otolaryngologica*. 32:81-95.

Goh, J. & Lim, K. 2009. Imaging of the Nasopharyngeal Carcinoma. *Annals Academy of Medicine*. 38(9):809-816.

Grogg, K.L.; Miller, R.F. & Dogan, A. 2007. HIV infection and lymphoma. *Journal of Clinical Pathology*. 60(12):1365-1372.

Gurney, T.A. & Murr, A.H. 2003. Otolaryngological manifestations of human immunodeficiency virus infection. *Otolaryngological Clinics of North America*. 36:607-624.

Heffner, K. 1990. Classification of human upper respiratory tract tumors. Environmental Health Perspectives. 85:219–229.

Her, C. 2001. Nasopharyngeal carcinoma and the Southeast Asian patient. *American Family Physician*. 63(9):1776-82.

Hopping, S.B.; Keller, J.D. & Goodman, M.L.; et al. 1983. Nasopharyngeal masses in adults. *The Annals of Otology, Rhinology & Laryngology*. 92(2 Pt 1):137-40.

Johannsson, J.; Sveinsson, T. & Agnarsson, B.A.; et al. 1997. Malignant Nasopharyngeal Tumours in Iceland. *Acta Oncologica.* 36(3):291-294.

Keiserman, S. P. & Stern, J. 1995. Malignant transformation of nasopharyngeal lymphoid hyperplasia. *Otolaryngology Head and Neck surgery.* 113:474-476.

Kilfe, E. 2009. South Africa expands access to antiretrovirals. Available from: http://www.ethiopianreview.com/36535. [Accessed 22/01/2010].

Larson, L.G.; Clifford, P. & Einhorn, J.; et al. 1976. Radiation therapy of Nasopharyngeal carcinoma in East Africa. *Acta Ragiologica Therapy Physics Biology.* 15:305-314.

Leake, M. 2009. HIV & AIDS in South Africa. Available from: http://www.avert.org/aidssouthafrica.htm. [Accessed 27/10/2009].

Lui, T.; Xu, W. & Yan, W.; et al. 2007. FDG-PET, CT, MRI for diagnosis of local residual or recurrent Nasopharyngeal carcinoma, which one is the best? A systemic review. *Radiotherapy and Oncology.* 85:327-335.

McClay, J.E. Updated: Oct 30, 2008. Adenoidectomy. Available from: http://emedicine.medscape.com/article/872216-media. [Accessed 12/01/2010].

Moazzez, A.H. & Alvi, A. 1998. Head and Neck Manifestations of Aids in Adults. *American Family Physician.* 57(8):1813-1822.

Mohammed, Z. 2007. HIV Associated Malignancies. *CME.* 25(22):70-74.

Palitza, K. 2006. HEALTH-SOUTH AFRICA: A Burden That Will Only Become Heavier. Available from: http://ipsnews.net/africa/nota.asp?idnews=33396. [Accessed 27/10/2009].

Sagittal section of the pharynx. 2003. [Online image]. *Encyclopaedia Britannica, Inc.* Available from: http://www.britannica.com/EBchecked/topic-art/22980/68641/Sagittal-section-of-the-pharynx. [Accessed 28/02/2010].

Shahab, I.; Osborne, B.M. & Butler, J.J. 1994. Nasopharyngeal lymphoid tissue masses in patients with human immunodeficiency virus-1. Histologic findings and clinical correlation. *Cancer.* 74(12):3083-3088.

Shanmugaratnam, K. & Sobin, L.H. 1993. The World Health Organisation Histological Classification of tumours of the Upper Respiratory Tract and Ear. *Cancer.* 71(8):2189-2697.

Sievers, K.W.; Grees, H. & Baum, U.; et al. 2000. Paranasal sinuses & Nasopharynx CT & MRI. *European Journal of Radiology.* 33:185-202.

Statistics South Africa. 2009. Mid-year Population estimates 2009. Available from: http://www.statssa.gov.za/Publications/P0302/P03022009.pdf. [Accessed 27 October 2009].

Stein, M.; Ruff, P. & Weaving, A.; et al. 1996. A Phase II study of Cisplatin/Ifosfamide in Recurrent/Metastatic Nasopharyngeal Carcinoma among young Blacks in Southern Africa. *American Journal of Clinical Oncology*. 19(4):386-388.

Stern, J.C.; Lin, P.T. & Lucente, F.E. 1990. Benign nasopharyngeal masses and human immunodeficiency virus infection. *The Archives of Otolaryngology - Head & Neck Surgery.* 116(2):206-8.

Tse, L.A.; Yu. I.T-S. & Mang, O.W-K.; et al. 2006. Incidence rate trends of histological subtypes of nasopharyngeal carcinoma in Hong Kong. *British Journal of Cancer*. 95(9):1269-1273.

UNAIDS. 2007. AIDS Epidemic Update: December 2007. Available from: http://data.unaids.org/pub/EPISlides/2007/2007_epiupdate_en.pdf [Accessed 21 May 2009].

US to commit R900mil for ARVs in South Africa. 2009. *BuaNews online*. 01 Dec. Available from: http://www.buanews.gov.za/news/09/09120109351001. [Accessed 22/01/2010].

Van Hasselt, C.A. & Gibb, A.G. 1991. *Nasopharyngeal carcinoma*. The Chinese University of Hong Kong.

Yang, M-C.; Hsu, H-Y. & Liu, D-W. et al. 2009. AIDS related Kaposi's Sarcoma of the Nasopharynx. *Tzu Chi Medical Journal*. 21(4):342-344.

Zafar, U.; Khan, N. & Afroz, N.; et al. 2008 Clinicopathological study of non-neoplastic lesions of nasal cavity and paranasal sinuses. *Indian Journal of Pathology & Microbiology*. 51(1):26-29.

APPENDIX A

Filtered data of study patients (n=81)

	A	E	F	G	H	I	J	K	L	M	N	O	P	S	T	U	V
1	**No**	**Gender**	**Age**	**Age Group**	**Persistent nasal blockage**	**Epistaxis**	**Hearing loss**	**Otalgia**	**Neck mass**	**Neurological fallout**	**Other**	**HIV**	**Presenting Symptoms**	**Benign or Malignant**	**Histo group**	**Key**	
2	1	1	42	3	1	1	2	1	1	1			Hearing loss	1	Inflamed respiratory mucosa	**Gender**	
3	2	1	52	4	2	2	1	2	1	1			Epistaxis, Nasal obstruction & otalgia	1	Reactive lymphoid hyperplasia	Male	**1**
4	3	2	30	1	1	1	2	2	1	1	2		Hearing loss, otalgia &throat pain	2	Nasopharyngeal carcinoma	Female	**2**
5	4	1	76	5	1	1	2	1	2	1	2		Neck Mass, hearing loss & tinnitus	2	Non Hodgkins Lymphoma		
6	5	2	37	2	2	1	1	2	2	1		2	Nasal obstruction, Otalgia, neck mass	2	Non Hodgkins Lymphoma	**HIV Status**	
7	6	1	60	4	1	1	1	1	2	1			Neck Mass	1	Benign respiratory epithelium	HIV Negative	**1**
8	7	1	34	2	2	2	1	1	1	1	2		Nasal obstruction, epistaxis & throat pain	1	Inflamed respiratory mucosa	HIV Positive	**2**
9	8	1	47	3	2	2	1	1	1	1			Nasal mass, nasal obstruction, epistaxis	2	Nasopharyngeal carcinoma		
10	9	1	36	2	2	1	1	1	2	1			Nasal obstruction, nasal discharge & neck mass	2	Nasopharyngeal carcinoma	**Tumour Group**	
11	10	1	41	3	2	1	2	1	1	1		2	Nasal obstruction & Hearing loss	1	Reactive lymphoid hyperplasia	Benign	**1**
12	13	1	46	3	2	2	2	1	1	1			Hearing loss, nasal obstruction & epistaxis	1	Reactive lymphoid hyperplasia	Malignant	**2**
13	14	1	75	5	1	1	2	1	1	1	2		Hearing loss & Rt Tinnitus	1	Reactive lymphoid hyperplasia		
14	15	2	35	2	2	1	1	1	1	1		2	Nasal obstruction	1	Reactive lymphoid hyperplasia	**Symptom**	
15	17	1	28	1	1	1	1	1	2	1		2	Neck Mass	1	Inflamed respiratory mucosa	Negative or not asked for on history	**1**
16	18	1	43	3	1	1	2	1	1	1	2		Hearing loss, tinnitus & snoring	1	Reactive lymphoid hyperplasia	Symptom present	**2**
17	19	2	33	2	1	1	1	1	1	1	2		Trismus & TMJ pain	1	Reactive lymphoid hyperplasia		
18	21	2	32	2	2	1	1	1	1	1		2	Nasal obstruction	1	Reactive lymphoid hyperplasia	**Age group**	
19	25	2	39	2	1	1	1	1	1	1	2	1	Chronic throat pain	1	Reactive lymphoid hyperplasia	18-30	**1**
20	26	1	18	1	2	2	1	1	1	1			Epistaxis,Nasal mass with obstruction	1	Reactive lymphoid hyperplasia	31-40	**2**
21	27	1	35	2	2	1	2	2	1	2	2	2	Nasal obstruction, otalgia, hearing loss & anosmia	2	Kaposi Sarcoma	41-50	**3**
22	28	1	25	1	2	2	1	1	2	1			Nasal obstruction,Epistaxis, Neck mass	2	Nasopharyngeal carcinoma	51-60	**4**
23	29	2	41	3	2	1	1	1	1	2			Nasal obstruction, facial pain	2	Non Hodgkins Lymphoma	>60	**5**
24	30	2	28	1	2	2	1	1	1	1		2	Epistaxis & nasal obstruction	2	Kaposi Sarcoma		
25	31	1	31	2	2	1	1	1	1	1			Nasal obstruction	1	Reactive lymphoid hyperplasia		
26	32	1	58	4	2	1	2	1	1	1		1	Nasal obstruction & Hearing loss	1	Squamous papilloma		
27	33	1	55	4	2	1	1	1	1	1	2	2	Nasal obstruction & dysphagia	2	Non Hodgkins Lymphoma		
28	34	1	41	3	2	1	1	1	1	1		2	Nasal obstruction	2	Plasmablastic lymphoma		
29	35	2	51	4	2	1	1	1	1	1		2	Nasal obstruction	1	Reactive lymphoid hyperplasia		
30	36	1	40	2	2	1	2	1	1	1		2	Nasal obstruction & Hearing loss	1	Reactive lymphoid hyperplasia		
31	37	1	52	4	2	1	2	1	1	1			Nasal obstruction & Hearing loss	1	Benign respiratory epithelium		
32	40	1	41	3	2	2	1	1	1	1	2	2	Nasal mass, epistaxis & dysphagia	2	Kaposi Sarcoma		
33	41	1	48	3	1	1	2	1	2	1			Neck Mass & blocked ear	2	Nasopharyngeal carcinoma		
34	42	2	44	3	2	1	1	1	1	1		1	Nasal obstruction	1	Reactive lymphoid hyperplasia		
35	43	2	35	2	2	1	1	1	1	1		2	Nasal obstruction	1	Reactive lymphoid hyperplasia		
36	44	1	69	5	1	1	2	1	1	1			Hearing loss	1	Inflamed respiratory mucosa		
37	45	2	52	4	2	2	1	1	1	1		2	Nasal obstruction &epistaxis	1	Reactive lymphoid hyperplasia		
38	46	2	59	4	1	1	2	1	1	1		1	Hearing loss	1	Reactive lymphoid hyperplasia		
39	47	1	25	1	1	1	1	1	1	2	2	1	Blindness & other CN fallout & dysphagia	2	Adenoid cystic carcinoma		
40	48	2	30	1	2	1	1	1	2	1			Nasal obstruction & neck mass	1	Reactive lymphoid hyperplasia		
41	49	1	76	5	2	2	1	1	1	1			Nasal obstruction &epistaxis	2	Plasmacytoma		
42	50	1	32	2	2	1	2	1	1	1		2	Nasal obstruction & hearing loss	1	Reactive lymphoid hyperplasia		

	A	E	F	G	H	I	J	K	L	M	N	O	P	S	T	U	V
1	**No**	**Gender**	**Age**	**Age Group**	**Persistent nasal blockage**	**Epistaxis**	**Hearing loss**	**Otalgia**	**Neck mass**	**Neurological fallout**	**Other**	**HIV**	**Presenting Symptoms**	**Benign or Malignant**	**Histo group**	**Key**	
43	51	1	34	2	2	1	2	1	1	1	2	2	Nasal obstruction, hearing loss & tinnitus	1	Reactive lymphoid hyperplasia	**Gender**	
44	54	2	67	5	1	1	1	1	1	1	2		Rhinitis	1	Inflamed respiratory mucosa	Male	**1**
45	55	1	37	2	1	1	1	1	1	2		1	Cranial nerve palsies & headaches	2	Combined small cell neuroendocrine carcinoma & SCC	Female	**2**
46	56	1	65	5	2	1	1	1	1	2			Nasal obstruction & neurological fallout	2	Nasopharyngeal carcinoma		
47	57	2	19	1	1	1	1	1	2	1		1	Neck Mass	2	Nasopharyngeal carcinoma	**HIV Status**	
48	58	2	21	1	1	2	2	1	2	1		1	Neck mass, epistaxsis & hearing loss	2	Nasopharyngeal carcinoma	HIV Negative	**1**
49	60	2	26	1	2	1	2	1	1	1	2		Nasal obstruction, anosmia & hearing loss	1	Reactive lymphoid hyperplasia	HIV Positive	**2**
50	61	1	56	4	2	1	2	1	2	1			Neck mass, nasal obstruction & hearing loss	2	Spindled & epithelioid cell neoplasm		
51	62	1	45	3	2	1	1	1	1	1	2	2	Nasal obstruction, dysphagia & odynophagia	2	Non Hodgkins Lymphoma	**Tumour Group**	
52	63	1	50	3	2	1	2	1	1	1	2	2	Nasal obstruction,hearing loss & tinnitus	1	Reactive lymphoid hyperplasia	Benign	**1**
53	64	1	35	2	1	1	2	1	1	2	2	1	Facial pain, headache, hearing loss & ophthalmoplegia	2	Nasopharyngeal carcinoma	Malignant	**2**
54	65	1	42	3	2	1	2	2	1	1		2	Nasal obstruction, Hearing loss & otalgia	1	Reactive lymphoid hyperplasia		
55	66	1	67	5	1	1	2	1	1	1		2	Hearing loss	1	Reactive lymphoid hyperplasia	**Symptom**	
56	67	2	41	3	2	1	1	1	1	1		2	Nasal obstruction	1	Reactive lymphoid hyperplasia	Negative or not asked for on history	**1**
57	69	1	51	4	2	1	1	1	2	1		1	Nasal obstruction & neck nodes	2	Non Hodgkins Lymphoma	Symptom present	**2**
58	70	1	39	2	1	1	1	1	2	1	2	2	Parotid swelling & neck nodes	1	Inflamed respiratory mucosa		
59	71	1	61	5	1	1	1	1	2	1			Neck Mass	1	Benign respiratory epithelium	**Age group**	
60	72	1	44	3	1	1	1	1	1	1	2	2	Hoarseness- sq ca of vc	1	Reactive lymphoid hyperplasia	18-30	**1**
61	73	2	67	5	1	1	1	1	1	2	2		Eye mass, blindness & anosmia	2	Plasmacytoma	31-40	**2**
62	74	2	55	4	1	1	2	1	1	2		1	Hearing loss & facial palsy	1	Inflamed respiratory mucosa	41-50	**3**
63	77	1	20	1	2	1	1	1	2	1		1	Neck Mass & nasal blockage	2	Nasopharyngeal carcinoma	51-60	**4**
64	78	1	43	3	1	1	1	1	1	2	2	2	Headache , facial weakness & diplopia	1	Benign Inflammatory polyp	>60	**5**
65	79	2	28	1	1	1	1	2	1	1	2	1	Neck pain & otalgia	2	Nasopharyngeal carcinoma		
66	80	1	35	2	2	1	1	1	1	1			Nasal obstruction	1	Inflamed respiratory mucosa		
67	81	1	38	2	2	2	1	1	1	2		2	Diplopia, nasal obstruction & epistaxis	2	Non Hodgkins Lymphoma		
68	82	1	25	1	1	1	1	1	1	2		2	Facial weakness & diplopia	1	Reactive lymphoid hyperplasia		
69	83	1	28	1	2	1	1	1	2	1	2		Neck Mass, blocked nose &dysphagia	2	Non Hodgkins Lymphoma		
70	84	2	82	5	1	1	1	1	1	1	2		Sore throat	1	Reactive lymphoid hyperplasia		
71	85	1	58	4	1	1	1	1	2	1			Neck mass	1	Benign respiratory epithelium		
72	86	1	63	5	1	1	1	1	2	1			Neck mass	1	Inflamed respiratory mucosa		
73	87	1	35	2	1	1	2	1	2	1			Neck mass & hearing loss	1	Reactive lymphoid hyperplasia		
74	88	2	74	5	1	1	1	1	1	1	2		Sore throat	2	Non Hodgkins Lymphoma		
75	89	1	63	5	1	1	1	1	2	1			Neck mass	1	Benign respiratory epithelium		
76	91	1	71	5	1	1	1	1	2	1			Neck Mass	1	Inflamed respiratory mucosa		
77	92	1	47	3	1	1	1	1	2	1	2	2	Neck Mass, dysphagia & difficulty breathing	1	Benign Inflammatory polyp		
78	93	2	78	5	1	1	1	1	2	1			Neck Mass	1	Reactive lymphoid hyperplasia		
79	94	1	60	4	1	1	1	1	2	1			Immature squamous metaplasia	1	Immature squamous metaplasia		
80	95	2	33	2	2	1	2	2	1	1		2	Nasal obstruction, Hearing loss & otalgia	1	Reactive lymphoid hyperplasia		
81	96	2	58	4	1	1	1	1	2	1	2		Neck mass & dysphagia	1	Benign respiratory epithelium		
82	97	1	47	3	1	1	1	1	2	1			Neck mass	1	Reactive lymphoid hyperplasia		
83																	

APPENDIX B

UNIVERSITY OF THE WITWATERSRAND, JOHANNESBURG
Division of the Deputy Registrar (Research)

HUMAN RESEARCH ETHICS COMMITTEE (MEDICAL)
R14/49 Dr Lalenthra Naidoo

CLEARANCE CERTIFICATE	**M090419**
PROJECT	A 6 Year Review of the Histopathology of Nasopharyngeal Tumours in Adult Patients at the CM Johannesburg Academic Hospital
INVESTIGATORS	Dr Lalenthra Naidoo.
DEPARTMENT	Department of Otorhinolaryngology
DATE CONSIDERED	09.04.29
DECISION OF THE COMMITTEE*	Approved unconditionally

Unless otherwise specified this ethical clearance is valid for 5 years and may be renewed upon application.

DATE 09.04.29 **CHAIRPERSON** .....
(Professor PE Cleaton-Jones)

*Guidelines for written 'informed consent' attached where applicable
cc: Supervisor : Prof PC Modi

DECLARATION OF INVESTIGATOR(S)

To be completed in duplicate and **ONE COPY** returned to the Secretary at Room 10004, 10th Floor, Senate House, University.
I/We fully understand the conditions under which I am/we are authorized to carry out the abovementioned research and I/we guarantee to ensure compliance with these conditions. Should any departure to be contemplated from the research procedure as approved I/we undertake to resubmit the protocol to the Committee. **I agree to a completion of a yearly progress report.**

PLEASE QUOTE THE PROTOCOL NUMBER IN ALL ENQUIRIES...