

https://dspace.org/

Intracranial aneurysms: biographical variables and multiplicity in a consecutive unselected series of patients

Ghookal, Dharmendra Manibhai

2014-03-12
http://hdl.handle.net10539/14115

Downloaded from a DSpace repository. https://dspace.org/

Intracranial Aneurysms:

Biographical Variables and Multiplicity in a Consecutive Unselected Series of Patients

INTRACRANIAL ANEURYSMS: BIOGRAPHICAL VARIABLES AND MULTIPLICITY IN A CONSECUTIVE UNSELECTED SERIES OF PATIENTS

DHARMENDRA MANIBHAI GHOOKAL

A dissertation submitted to the Faculty of Health Sciences, University of the Witwatersrand, Gauteng in fulfillment of the requirements for the degree of Master of Medicine in the branch of Diagnostic Radiology.

Gauteng 2000

DECLARATION

I declare that this dissertation is my own work. It is being submitted for the degree of Master of Medicine in the University of the Witwatersrand, Gauteng. It has not been submitted for any degree or examination in any other university.



Dr D M Ghookal

30th day of April 2000

This work is dedicated to my parents,
my brother and his family and my sisters.

ACKNOWLEDGEMENTS

I would like to thank the following people:

Dr E. Joseph and my two supervisors (Dr V Goolab and Dr G Modi) for their unfailing support, and helpful criticism and advice during the preparation of this dissertation.

Dr P Becker and Mrs S Moti of the Centre for Epidemiological Research in Southern Africa for their prompt assistance in initial data analysis.

The Medical Research Endowment Fund for a small grant that helped defray costs incurred in this study.

I would be remiss not to mention my sincere and grateful thanks to Mrs N. Morar and Mrs S. Valla for their diligent painstaking and superb assistance in the preparation of this manuscript.

I am grateful to my colleagues who have entrusted their patients to our X-ray department's care, the experience of which provided the basis for this dissertation.

My greatest debt of gratitude is reserved for my parents whose tireless enthusiasm and encouragement were always available.

ETHICAL CONSIDERATIONS

The Committee for Research on Human Subjects (medical) approved this research project unconditionally.

Ref: R14/49 Ghookal

Clearance # M980109

ABSTRACT

Morgagni, the Professor of Anatomy at Padua in 1761 was the first person to imply that the existence of such an entity as an aneurysm was probable. In 1765, Bianchi of Milan described the first case of an unruptured cavernous sinus aneurysm seen at post mortem in a 52 year old woman. In 1813, J Blackwell observed clinically what probably represented the first account of a ruptured intracranial (basilar artery) aneurysm.

Review of the literature shows a paucity of information about cerebral aneurysms in Africa. To this end, a study of the biographical variables and characteristics of cerebral aneurysms was performed. Analysis of 126 cerebral angiograms for suspected intracranial aneurysms was performed. Seventy-five patients (60%) with a total of 93 aneurysms were identified. The most important aspect of this study is that patients in South Africa are presenting one decade earlier (10 years) compared to patients in other continents. The other interesting feature was that aneurysms in childhood and adolescence had a striking propensity to be situated on the right terminal internal carotid artery.

This dissertation will hopefully be a comprehensive reference work for those engaged in the field of cerebral aneurysms.

TABLE OF CONTENTS

PART 1
Literature Review

1. **DEFINITION** 1

2. **CLASSIFICATION** 1

2.1 Atherosclerotic aneurysms 2

2.2 Mycotic aneurysms 2

2.3 Traumatic aneurysms 3

2.4 Dissecting aneurysms 3

2.5 Miliary aneurysms of Charcot and Bouchard 3

2.6 Oncotic aneurysms 4

2.7 Saccular aneurysms 5

3. **SACCULAR ANEURYSMS** 6

3.1 Pathogenesis 6

3.2 Incidence 9

3.3 Biographical variables of intracranial aneurysms 9

- Age 9
- Sex 10
- Geographic and racial factors 10

3.4 Anatomic sites of intracranial aneurysms 10

- Internal carotid artery 11
  - Intracavernous 11
  - Ophthalmic 11
  - PCoA 11
  - Anterior choroidal 12
  - Internal carotid bifurcation/trifurcation 12
- Middle cerebral artery 12

- Anterior cerebral artery 13
  - Classification 13
  - Pathological anatomy of the ACoA complex 13
  - Pericallosal artery 13
- Vertebrobasilar artery 14
  - Classification 14

3.5 Size of aneurysms 15

3.6 Giant aneurysms 15
- Incidence and location 16
- Clinical presentation and Natural History 16

3.7 Natural History of Intracranial Aneurysms 17
- Rebleeding 18
- Multiple Aneurysms 19

3.8 Multiple Aneurysms 21

4. FAMILIAL OCCURRENCE OF ANEURYSMS 23

5. ANEURYSMS OF INFANCY AND CHILDHOOD 24

6. ANEURYSMS IN PREGNANCY 25

6.1 Diagnosis 25

6.2 Time of gestation at which hemorrhage occurs 26

6.3 Treatment 26

7. CLINICAL FEATURES 27

7.1 Clinical presentation of aneurysmal rupture 27

7.2 Clinical presentation not due to aneurysm rupture 27
- Distal embolization from partially thrombosed aneurysms 27
- Neurological signs from giant aneurysms 28
- Symptoms and signs from non-giant aneurysms 28

8. DIAGNOSIS OF ANEURYSMS AND ANEURYSM RUPTURE 30

8.1 Physical Examination 30

8.2 Lumbar Puncture 31

8.3 Computed Tomography 33

8.4 Magnetic Resonance Imaging 35

9. COMPLICATIONS OF ANEURYSMS AND ANEURYSM RUPTURE

9.1 Intracranial 36
- Rebleeding 36
- Cerebral Ischemia 36
- Hydrocephalus 36
- Expanding intracerebral hematoma 37
- Seizures 37
- Intellectual impairment and depression 37

9.2 Extracranial 37
- Cardiovascular 37
- Pulmonary 37
- Gastric hemorrhage 38
- Fluid and Electrolyte Disturbance 38

10. SCREENING FOR ANEURYSMS 39

11. IMAGING OF INTRACRANIAL ANEURYSMS 40

11.1 Plain Films 40

11.2 High Resolution Computed Tomography 40
- Unenhanced CT Scanning 40
- Enhanced CT Scanning 41
- CT and aneurysm localization from SAH Distribution 42
- CT and Intracerebral hematoma 43
- Hypodense Areas 44
- Relation of Cerebral Vasospasm to SAH visualized by CT Scanning 44
- CT in Multiple Aneurysms 45
- Hydrocephalus 45
- CT scan findings and Prognosis 45
- CT scan findings and SAH of Unknown Origin 45
- CT and Giant Aneurysms 46
- CT and Patient Deterioration 46

11.3 CT Angiography 47
- Advantages of CTA 48
- Disadvantages of CTA 49

11.4 Intra-arterial Cerebral Angiography 50

- Procedure 51
- Aims of Angiography 51
- Timing of angiography 52
- Type of Angiography 53
- Extent of Angiography 53
- Angiographic projections and Specific Aneurysm Sites 55
  - Intracavernous aneurysms.....55
  - Internal carotid artery 56
  - Middle cerebral artery 56
  - ACoA 56
  - Pericallosal artery 57
  - Ophthalmic artery 58
  - Basilar artery.....59
  - PICA 60
- Angiographic signs of rupture 60
  - Irregularity or loculation of aneurysmal sac 60
  - Vasospasm.....60
  - Focal Mass Effect 62
  - Aneurysmal Nipples 61
  - Changes in aneurysm shape on repeat angiograms 62
  - Size of aneurysm 62
- Cross Compression.....62
- Accuracy of Angiography.....63
- Which vessel angiogram should be done first ? 64

12. INTRAOPERATIVE DSA.....65

13. DIGITAL SUBTRACTION ROTATIONAL ANGIOGRAPHY FOR ANEURYSMS OF THE ANTERIOR CIRCULATION 65

14. MAGNETIC RESONANCE IMAGING AND MAGNETIC RESONANCE ANGIOGRAPHY 66

14.1 What is MRA ? 67

14.2 MRA Applications.....68

14.3 Limitations of PCA 69

14.4 Limitations of TOF 69

14.5 Advantages of MRA compared to DSA 69

PART 2

Intracranial Aneurysms: Biographical Variables and Multiplicity in an Unselected Consecutive Series of Patients

1. MATERIALS AND METHODS 70

2. RESULTS 73

Age
Gender
Multiplicity
Aneurysms of Childhood and Adolescence
Sites of Aneurysms
Vasospasm
Vessel Catherizations

3. GDCs AND ANEURYSMS 91

4. CASES 92

5. DISCUSSION 105

6. CONCLUSIONS 115

7. REFERENCES 116

8. APPENDIX (DATA SHEET) 122

9. ABBREVIATIONS 123

List of Images

1 Left Internal Carotid Artery 93

2 PICA Aneurysm 94

3 MCA Aneurysm 96

4 M1 segment and Pericallosal Aneurysm 98

5 Vasculopathy 100

6 Infundibulum 102

7 PCoA Aneurysm 103

8. AVM 104

List of Tables

A1 Frequency distribution of sample population 74

A2 Cross tabulation of Age by Angiogram Outcome 75

A3 Overall Descriptive Statistics 76

M1 Cross tabulation of Aneurysm Number with Age categories 82

M2 Multiplicity and Side of Aneurysms 83

M3 Cross tabulation of Race by Gender controlling for Single and Multiple aneurysms 83

L1 Location of Aneurysms in Childhood and Adolescence 84

S1 Site Distribution and Sex Ratio of patients with aneurysms 86

S2 Frequency distribution of Right:Left:Midline Aneurysms 87

V1 Cross tabulation of Vasospasm by Aneurysm Outcome 88

V2 Cross tabulation of Race by Gender controlling for aneurysm positive angiograms and focal spasm 89

VC Cross tabulation of Age by Vessel Sequence controlling for gender.....90

1. DEFINITIONS

An aneurysm is an abnormal localized dilatation of an artery.

A true aneurysm is formed by dilatation of the constituents of the vessel wall, which then exhibits structural alterations.

A false aneurysm results from partial or complete rupture of the wall. The hematoma, formed from the extravasation of blood, becomes walled off by perivascular tissue and the organization of the fibrinous coagulum.

Ectasia is defined as a diffuse increase in calibre of the vessel wall that occurs in the cerebral arteries with age. It occurs more often in larger vessels and often is accompanied by variable tortuosity.

2. CLASSIFICATION

Central nervous system aneurysms may be classified according to morphologic or etiologic features.

Morphologically aneurysms may be categorized by their shape, i.e. saccular or fusiform. The saccular type consists of a pouchlike dilatation of the artery, and is also referred to as congenital or berry aneurysms. The fusiform type is a spindle-shaped dilatation of the artery (1).

The etiological classification includes congenital, atherosclerotic, mycotic, traumatic, dissecting, microaneurysms of Charcot and Bouchard and oncotic aneurysms (1, 2).

2.1 Atherosclerotic fusiform aneurysms

True arteriosclerotic aneurysms (atherosclerotic aneurysms) of intracranial vessels are most common in the basilar and than the terminal end of the internal carotid artery (1). The shape of the aneurysm may be fairly uniform or irregular.

Associated tortuosity of the vertebral and basilar arteries may result in obstructive hydrocephalus due to compression of the third ventricle.

Spontaneous thrombosis of fusiform aneurysms in the vertebrobasilar system may occur producing acute brainstem or cerebellar infarction.

Aneurysms of the internal carotid artery usually involve the intracavernous portion, where expansion in all direction produces pressure symptoms. Subarachnoid hemorrhages (SAH) from the aneurysms is rare because they rarely rupture.

Histologically there is fibrosis of the elastic membrane, with hyaline degeneration, deposition of cholesterol, occasional inflammatory cells and intimal hemorrhage.

2.2 Mycotic aneurysms

True mycotic aneurysms are rare but must be considered a possibility in patients with diabetes, acquired immunodeficiency syndrome (AIDS), in patients on cytotoxic drug therapy, following cardiac valve surgery and in drug abusers. The incidence of these aneurysms has been reported as being 2,6% of all intracranial aneurysms (1). Spontaneous SAH in patients with a cardiac murmur or other evidence of endocarditis should suggest a diagnosis of mycotic aneurysms to be made. Common pathogens involved are streptococcus viridans, staphylococcus aureus and staphylococcus albus. Mycotic aneurysms have occurred with moniliasis, syphilis and aspergillosis. These aneurysms are commoner in younger

patients, are rarely associated with warning signs, may increase rapidly in size and are situated on the peripheral branches of the cerebral arteries. Because of the lack of specific symptoms during their development the diagnosis is usually made after the hemorrhage.

Inflammatory changes are seen in the wall of the aneurysm and in the surrounding brain. Adhesions may form between the arachnoid and brain in the region of the aneurysm. When the aneurysm ruptures, these adhesions may prevent free escape of the blood into the subarachnoid space. Patients therefore may present with an intracerebral hematoma or a subdural collection.

2.3 Traumatic aneurysms

These account for 0,5% of all cerebral aneurysms, and can be classified into (a) true, when the arterial wall is partially disrupted; (b) false, when the aneurysm cavity is encapsulated in a hematoma; and (c) mixed, where rupture of a true aneurysm gives rise to a secondary false aneurysm. These aneurysms are more commonly found on the branches of the external carotid artery than branches of internal carotid artery.

2.4 Dissecting aneurysms

A dissecting aneurysm is defined as an arterial lesion in which as a result of weakening, the vessel wall becomes split longitudinally into two layers, by leakage of blood beneath the weakened inner portion. The new channel is not lined by endothelium but by the tissues dissected and thus it is a false aneurysm. Aneurysmal dilatation of the dissected wall can occur. Dissection takes place usually between the tunica intima and the media. Dissecting aneurysms of the intracranial arteries are rare, occur mostly in the second, third, and fourth decades and although 27 years is the mean age, there is a wide range (6 months – 70 years) (3). Dissecting aneurysms are more frequent in males and are usually seen in normotensive rather than hypertensive patients.

Dissection may complicate arteritis or necrotizing arteritis associated with intravenous drug use. Other etiologies include trauma, syphilis and electrocution. The most common cause being blunt nonpenetrating injuries. It is not definitely known how blunt trauma induces these lesions.

The commonest intracranial vessel involved is the middle cerebral artery (MCA) (3). Dissecting aneurysms usually present as acute cerebral or brainstem infarction in young adults.

2.5 Miliary aneurysms of Charcot and Bouchard

The miliary aneurysm is a small, saccular, fusiform or irregular lesion often measuring less than 1mm in diameter and frequently observed in small arterioles of the deep structures of the cerebral tissues (basal ganglia, thalamus, corpora striatum, claustrum, pons), cerebellum and superficial cerebral cortex (3). It was Charcot and Bouchard (in 1868) who brought intracerebral miliary aneurysms into prominence – hence the name Charcot Bouchard aneurysms. Many authorities now recognize these as the cause of primary parenchymal hemorrhages associated with hypertension. This definition does not include the lobar and subcortical hemorrhages occurring predominantly in patients older than 70 years in association with cerebral amyloid angiopathy.

Miliary aneurysms rarely occur in elderly normotensive patients, but usually are found in subjects with longstanding hypertension and they correlate strongly with primary intracerebral hemorrhages. Once they have leaked, they are likely to thrombose, resulting in small lacunar infarcts.

2.6 Oncotic aneurysms

Tumor emboli from cardiac myxoma and choriocarcinoma are known to produce peripheral aneurysms. Aneurysms form following neoplastic invasion of the arterial wall following tumor embolism. Myxomas develop mostly in the left atrium, and embolism to the intracranial circulation occurs in approximately 50%

of all patients demonstrating systemic embolism (1, 3). Middle cerebral arteries are affected most often and the vertebrobasilar system least often. These aneurysms are irregularly fusiform or lobulated, grey-white swellings, usually not more than 5mm wide and usually located along the terminal leptomeningeal vessels. Nonfamilial myxoma is predominantly a left atrial solitary lesion occurring in middle-aged woman with a mean age of 51 years. Familial cardiac myxoma is, for the most part a disorder of young men (mean age 24 years), more often multicentric than solitary in the left atrium and is associated with multiple skin lesions (pigmentation, myxoma, nevi) oral and other tumors (testes, adrenal, pituitary).

2.7 Saccular Aneurysms (see below)

3. SACCULAR ANEURYSMS

Spontaneous non-inflammatory saccular aneurysms are of two types

- The aneurysm not specifically associated with a branching site

  Saccular aneurysms unrelated to forking vessels are associated in general with very severe atherosclerosis, usually of the vertebral, basilar, and internal carotid arteries (cavernous and intracranial parts). Therefore most patients are middle-aged or older and often hypertensive with the aneurysms being frequently multiple along a severely atherosclerotic vessel. These aneurysms rarely bleed but can produce serious local pressure symptoms or generalized intracranial pressure effects.

- Aneurysms associated with a branching site

  These aneurysms are referred to as congenital, developmental or berry aneurysms and are seen at branching points of vessels. They present as a saccular dilatation of the artery and are connected to the parent vessel by a variable area of attachment, usually arising at or very close to a branch or division of an artery. The aneurysms are by convention classified with reference to the closest take-off vessel.

3.1 Pathogenesis

The pathogenesis of saccular aneurysms is controversial, and currently two opposing views are held. One proposes congenital and the other proposes acquired factors in the development of aneurysms.

Congenital factors

- The medial defect

Cerebral arterial walls have defects in the muscular layer at points of bifurcation. Such defects are also found in the coronary and mesenteric arteries. Some authors have drawn attention to the fact that there is an increased incidence of defects with age and therefore have said that the defect is acquired. Irrespective of whether congenital or acquired the muscular gap is an essential element in aneurysm formation (4).

- Failure of involution of primitive vessels

The location of aneurysms coincides with the site of the primitive vessels, and incomplete involution or atrophy of these arteries has been postulated as a cause of aneurysm formation (1).

- Genetic factors and familial aneurysms

Familial aneurysms occur twice as frequently in the same site in siblings as a simple dominant inheritance. The association of hereditary disorders such as Ehlers-Danlos syndrome and an increased incidence of cerebral aneurysms in these patients also suggest the importance of genetic factors.

At the molecular level the different types of collagen and their variations in different sites may be associated with aneurysm formation. The proportion of type 3 collagen varies from 70% in the arteries to 10-20% in the skin, and 0-1% in the bones. Type 3 collagen deficient patients have abnormal collagen fibrils and this may influence the properties of arterial walls, and encourage aneurysm formation at points of known arterial weakness (5).

Acquired factors

- Degeneration of the Internal Elastic Lamina

The elastic lamina gives significant strength to the vessel wall. A combination of congenital muscular defect and acquired degeneration of elastic membrane results in aneurysm development (4).

- Pre-aneurysmal lesions of the arterial walls (infundibula)

Infundibula are funnel shaped (pyramidal), under 3mm in maximum diameter, and located at arterial origins with small arteries coming off the apex. Infundibula are more likely to occur in older patients and in patients with large arteriovenous malformations (AVMs). These infundibular dilatations lead to the formation of aneurysms and are seen commonly at the junction of the internal carotid artery and posterior communicating arteries (2). Histological examinations of the infundibula reveal medial atrophy.

- Atherosclerosis

Although aneurysms are most common in adults with prevalent atherosclerosis, the exact role of this factor in the pathogenesis is difficult to assess. Both the age distribution and the frequency of atherosclerosis in the cerebral arteries are consistent with a degenerative rather than a developmental disorder.

- Hypertension

Hypertension is an important factor in producing hemodynamic stress and intimal lesions, and acts against a background of elastic layer degeneration and the medial defect (2, 4).

In summary, there is still controversy regarding the origin of aneurysms, with both congenital and acquired mechanisms having their advocates. Defects in the muscular coat at the point of sacculation of the aneurysms has been proven histologically. The age distribution of aneurysm formation (50-70 years) favors an acquired rather than a congenital basis for the etiology of aneurysms. In old age it is suggested that atherosclerosis and hypertension play a significant role whereas in childhood and adolescence the medial defect is of greater importance. In early adult life it is the medial defect and blood pressure which are significant while atherosclerosis plays a minor role. Currently the most plausible explanation for the etiology of intracranial aneurysms is that they are acquired, degenerative, hemodynamically induced lesions (3).

3.2 Incidence

The incidence of congenital aneurysms at necropsy varies in different series, depending on the assiduity of the search as well as on the age and sex mix of any particular institution's cases. In general, less than 2 percent of the entire population will have an aneurysm; an intracranial aneurysm will rupture in less than 1 percent and will be the cause of death in 0.5 percent. The commonest presentation is a subarachnoid hemorrhage (SAH).

3.3 Biographical variables of intracranial aneurysms

- **Age**

Berry aneurysms occur predominantly in patients between 40 and 70 years of age, with a peak incidence at approximately 50-60 years, which is more consistent with an acquired degenerative disease rather than a congenital or developmental disorder (2, 3, 6, 7). Compared to the frequency of aneurysms in adults, the frequency of aneurysms in the pediatric population is small, and they tend to differ from the usual adult aneurysm with regards to site and sex-mix data. Overall, patients under 18 account for 1-2% of cases of aneurysmal SAH.

- **Sex**

  There is a clear female preponderance overall (single and multiple aneurysms). Sixty percent of aneurysms of infancy and childhood however occur in boys (1, 2, 3, 8, 9). Adult female to male ratio is reported to range from 1,5:1 to 2:1 depending on which previous studies are looked at. Before age 40, males and females are either equally affected or with a slight male predominance. Above age 40 there is an increasingly strong predominance of females. Kongable (10) demonstrated the gender-related differences in aneurysmal SAH in a recent article.

- **Geographic and racial factors**

  All races share a propensity to develop intracranial aneurysms. The rates of aneurysm formation and SAH in a given geographic area depend on the age distribution, the availability of medical care, smoking, alcohol intake, atherosclerosis, hypertension, diet composition and possibly on racial factors. The incidence of SAH has been reported to be higher in Japan and Finland than in the United States (2, 11). Blacks in the Greater Cincinnati area had a 2.1 times the risk of SAH as whites (95% confidence interval, 1.3 to 3.6) (2, 12).

3.4 Anatomic sites of intracranial aneurysms

Ninety to ninety-five percent of aneurysms occur close to the circle of Willis in relation to the anterior and posterior communicating arteries and the bifurcation's of the internal carotid, middle cerebral and basilar arteries (2, 6, 9, 13, 14, 15, 16, 17). Aneurysms usually arise from the distal carina of a bifurcation (2, 4) and are usually on the convexity of a curve and point in the direction that the proximal axial bloodstream would have taken if the curve were not there. The three most common sites are anterior communicating artery (ACoA) (35%), posterior communicating artery (PCoA) (30%), and at the middle cerebral artery bifurcation / trifurcation (25%) (13, 18).

- **Internal carotid artery**

  - *Intracavernous aneurysms*

    Aneurysms arising from the intracavernous portion of the internal carotid artery usually do not give rise to SAH. Unruptured aneurysms may be asymptomatic (34%) or give rise to pressure dysfunction of the cranial nerves in the cavernous sinus. Rupture of these aneurysms into the cavernous sinus may cause a carotid-cavernous sinus fistula (CCF). Being intracavernous these aneurysms cannot be treated directly by the intracranial approach and the only methods of treatment available are carotid ligation in the neck combined with an external carotid-internal carotid artery anastomosis or an embolization technique using detachable balloons (1, 3).

  - *Ophthalmic artery aneurysms (OAA)*

    These aneurysms arising from the anterior surface of the internal carotid artery at the origin of the ophthalmic artery (OA), are also called carotid ophthalmic aneurysms. The female:male ratio of patients with OAA is higher than the female:male ratio of patients with aneurysms at other sites. In addition, although most patients present with SAH a relatively large percentage of these aneurysms are found during evaluation of another aneurysm that has ruptured or as incidental findings (3).

  - *Posterior communicating artery (PCoA) aneurysms*

    These aneurysms are among the most common accounting for approximately 25 – 30% of all intracranial aneurysms. Small dilatations (less than 3mm) known as infundibula are frequently seen at angiography at the origin of PCoA from the internal carotid artery. Infundibula are regarded as aneurysms if their size exceed 3mm and some authors consider them pre-aneurysmal if less than 3mm in size. Waga and Morikawa (19) have

suggested that these infundibula occur in about 7% of normal angiograms and that their frequency increases with age.

- *Anterior choroidal artery aneurysms*

The uncommon anterior choroidal aneurysm arises at the superior angle between the anterior choroidal artery and the internal carotid artery. They may be misdiagnosed as PCoA aneurysms especially when the PCoA is not opacified. In most cases they are defined by the fact that they arise from the internal carotid artery distal to the origin of the PCoA but proximal to the bifurcation of the internal carotid artery.

- *Internal carotid artery bifurcation/trifurcation aneurysms*

Aneurysms of the internal carotid artery bifurcation or trifurcation account for approximately 5% of all intracranial aneurysms (3).

- **Middle cerebral artery (MCA) aneurysms**

MCA aneurysms comprise approximately 20-25% of all intracranial aneurysms. In general it is the second or third most common site of aneurysms (18, 20, 21). In a recent large series (1314 patients) by Rinnai et al (22) in Eastern Finland it was shown that the Finnish patients had a higher frequency of aneurysms at the MCA (43%) than reported in other papers. As in other Finnish series of intracranial aneurysms the study by Rinnai et al demonstrated a preponderance of male patients in both the singular aneurysm and multiple aneurysm group of patients.

Nearly 80% of MCA aneurysms occur at the bifurcation/trifurcation of the main trunk, 10% on the proximal trunk (M1 segment), and the remainder more peripherally usually at a point of first branching of one of the main MCA divisions (3, 23). A distal branch of the MCA is the most frequent location of infectious aneurysms (1).

- **Anterior cerebral artery (ACA) aneurysms**

  - *ACA aneurysms are conveniently classified into three groups:*

    - Anterior communicating artery (ACoA) aneurysms (90%)

    - Pericallosal artery aneurysms (distal ACA aneurysms) (9%)

    - A1 segment aneurysms (proximal trunk aneurysms) (1.3%)

  - *Pathological anatomy of the anterior communicating artery complex*

    ACoA aneurysms develop in an area of extensive variability. Duplications of the ACoA are especially common in patients with ACoA aneurysms. Often, one of the A1 segments of the ACA is dominant and occasionally one A1 segment is atretic, hypoplastic or even absent. The pericallosal and callosomarginal arteries can arise as separate vessels directly from the ACoA complex, and clipping of such a "third A2 segment" can result in catastrophic frontal lobe infarction. Perforating arteries to the hypothalamus, numbering from 3-13, arise from the ACoA (3). Heubner's recurrent arteries originate from either the A1 or A2 segments and course along the A1 segment into the internal capsule territory (16). Yasargil (24) emphasized that ACoA aneurysms typically arise at the bifurcation of the ACoA and the A2 segment of the ACA on the side of the dominant A1 segment, as if generated by a jet of blood from the dominant A1 segment. When the A1 segments are approximately equivalent, the aneurysm can arise from the entire wall of the ACoA from one A2 segment to the other.

  - *Pericallosal artery aneurysms*

    Distal ACA aneurysms comprise 2 to 4,5% of all intracranial aneurysms. The most common site of pericallosal artery aneurysm is the junction between the pericallosal artery and the callosomarginal artery at the level of

the genu of the corpus callosum, but rarely at the origin of the frontopolar artery (3). Anatomic variations are not uncommon in this area. A single anterior cerebral (azygous) artery may be present, which can be the origin of a distal ACA aneurysm.

- **Vertebrobasilar aneurysms**

Use of routine three or four vessel angiography has increased detection of posterior circulation aneurysms from 5,4 percent to more than 8 percent, which is more in keeping with autopsy findings (2). In general, vertebrobasilar aneurysms constitute between 5 and 15 percent of all aneurysms.

Classification

- Basilar bifurcation aneurysms (commonest in this group)
- Basilar trunk aneurysms
  - Basilar and anterior inferior cerebellar artery (AICA) junction aneurysms
  - Basilar and superior cerebellar junction aneurysms
  - Posterior cerebral aneurysms which may arise either at the junction with the posterior communicating artery (P1 segment) or at the first major branching on the side of the midbrain (P2 segment)
- Aneurysms at the junction of the vertebral arteries

Although aneurysms of the posterior circulation account for only 5 –15% of all intracranial aneurysms, they may represent the most challenging aspect of cerebrovascular surgery. They are usually situated close to the brainstem, which makes the surgery extremely troublesome and risky (25). However, recent advances in aneurysm microsurgery and perioperative management of aneurysm patients have dramatically improved the outcome of these patients. The major challenges of treating vertebrobasilar aneurysms

include achieving adequate exposure, avoiding cranial nerve injury, and maintaining vascular integrity (3). Treatment becomes even more difficult in cases of fusiform and giant posterior circulation aneurysms.

3.5 Size of aneurysms

Ruptured aneurysms tend to be larger than unruptured aneurysms, and symptomatic aneurysms are larger than asymptomatic aneurysms. The size at which aneurysms begin to rupture is about 3mm maximum in diameter, and the size at which they begin to produce symptoms by means other than rupture is around 7mm (2). In Chason's article of 1958 in Neurology it was stated that the mean size of ruptured aneurysms was 8,6 mm, almost twice the mean size of the unruptured aneurysms, which was 4,7 mm. Size is important with regards to the image modality used. With contrast enhanced axial computerized tomography (CT) scanning, aneurysms greater than 5mm can be seen. For prospective detection using either time-of-flight magnetic resonance angiography (TOF MRA), or phase-contrast MRA (PC-MRA) 5mm is the critical size (26). Retrospectively, aneurysms 3mm or larger can be identified by MRA (13, 21, 26, 27).

3.6 Giant Aneurysms

Giant aneurysms are defined as aneurysms measuring more than 25mm (2,5cm) in diameter (8, 14, 28), and comprise one of the most therapeutically challenging groups of lesions in contemporary surgery (3). Most are saccular; however, they may also be infectious, dissecting, dolichoectatic, fusiform or serpentine, and they may occur at any location on the intracranial arterial tree.

- **Incidence and location**

Giant aneurysms occur in all age groups but are most commonly seen in patients 30-60 years of age. They account for 5-25% of all intracranial aneurysms. The higher percentage in some series is probably because of referral bias. The rate of anterior circulation aneurysms to posterior circulation aneurysms closely approximate the distribution of aneurysms seen in large series of patients with all sizes of intracranial aneurysms (3). Patients harboring multiple giant intracranial aneurysms are rare.

- **Clinical Presentation and Natural history**

Patients often have symptoms related to mass effect or ischemic events secondary to emboli originating from an intraluminal thrombus. They also present with a subarachnoid hemorrhage. The symptomatology is strongly linked to the giant aneurysm location. Intracavernous giant aneurysms typically produce diplopia, optic atrophy, retro-orbital headaches and or facial numbness. Rupture results in a carotid-cavernous fistula. The patient with a carotid-ophthalmic giant aneurysm presents with optic atrophy, diminished visual activity, asymmetrical visual field deficits and third nerve palsies. Giant aneurysms of the ACA may result in loss of visual field or acuity, gait disturbance, change in mentation and or hydrocephalus.

The MCA is a common location for giant aneurysms and patients present with transient ischemic attacks, aphasia, seizures, hemiparesis or visual field defects. Posterior circulation giant aneurysms produce ataxia, dementia, oculomotor palsy, Weber's syndrome and bulbar palsy. A foramen magnum lesion usually causes mass effect symptoms, neuropathies of cranial nerves IX, X, XI and XII, progressive quadriparesis, ocular bobbing or Brown-Sequard's syndrome. Compared with smaller aneurysms, giant aneurysms more often produce symptoms of mass effect, but they hemorrhage at the same rate as that

of their smaller counterparts; that is, the natural history for hemorrhage in patients with giant aneurysms is the same as that in patients with smaller intracranial aneurysms (3). Contrary to earlier reports, giant size confers no protection against aneurysmal hemorrhage.

When SAH does occur in patients with giant aneurysms, neurological deterioration is precipitous. Because of the added risk of embolic stroke, progressive aneurysmal enlargement, and hydrocephalus, the overall natural history of patients with giant aneurysms may be worse than that of patients with smaller aneurysms. Partial thrombosis of giant aneurysms is very common, occurring in 48-76% of cases (29), does not confer protection against hemorrhage, and in fact, increases the risk of embolic stroke.

3.7 Natural History of Intracranial aneurysms

The natural history of ruptured and unruptured aneurysms must be clearly understood to evaluate rationally the surgical management of ruptured intracranial aneurysms. The best available data suggest that asymptomatic aneurysms either discovered incidentally or existing in patients with multiple aneurysms, bleed at a rate of 1 to 2% per year (30). Fifty to 60 percent of patients die after rebleeding, and 20 to 25 percent are left disabled. Because the risk of surgery for unruptured aneurysms is low (mortality close to 0 percent, morbidity about 4 percent), it is recommended that asymptomatic aneurysms (irrespective of size criteria) be clipped in most patients. (30, 31). Other factors entering into the decision about surgery include the general condition of the patient, the accessibility of the aneurysms to surgery, and the availability of a neurosurgeon who is experienced in aneurysmal surgery.

The incidence of ruptured aneurysms in two careful studies in the United States and Europe was 10,5 and 10,3 per 100 000 population per year respectively (2). About 15% of patients die before reaching a hospital. Spontaneous rupture of an intracranial aneurysm results in a death rate exceeding 50 percent in the first month (32, 33). Of all the aneurysmal SAH treated conservatively, 25% of the patients would be alive at 2 years (16).

- **Rebleeding**

SAH due to rupture of an intracranial aneurysm is both an acute illness and a chronic disease, as the risk of rebleeding is both short and long term. Rebleeding is a major problem following aneurysmal SAH. In the first 28 days (in untreated patients), approximately 30% of patients will rebleed; of these 70% die. In the following few months the risk gradually falls off but it never drops below 3-3,5% per year in the first decade (16, 33).

The rate of rebleeding was reported to increase to a peak at 7 days after the ictus but studies in the last decade have suggested that rebleeding is maximum on the day of the initial hemorrhage. However, it is difficult to diagnose a recurrent bleed within 24hrs after a major hemorrhage (33). With small unruptured aneurysms (3mm or less) the risk of bleeding is probably close to zero (8). The risk of rebleed in the acute stage increases, especially if aneurysm size is 9mm or more. The incidence of rebleed in posterior communicating artery aneurysms is greater than in ACoA aneurysms. The incidence of rebleed is least frequent following MCA aneurysm rupture (33).

- **Multiple Aneurysms (MA)**

MA are associated with a higher mortality than single aneurysms, but recurrent hemorrhage usually occurs from the original lesion. Rebleeding in these patients is more frequent and earlier than in patients with a single aneurysm.

The clinical picture of rebleeding is that of SAH, but usually the effects are more severe than the initial bleed. Most patients lose consciousness; the risk of death from a rebleed is more than twice than that from the initial bleed (16). Thus, even if patients survive the "high-risk" period in the first six months, there is a considerable chance of rebleeding and death in the subsequent ten years (16).

Algorithm of the Natural History of Ruptured Aneurysms (16)

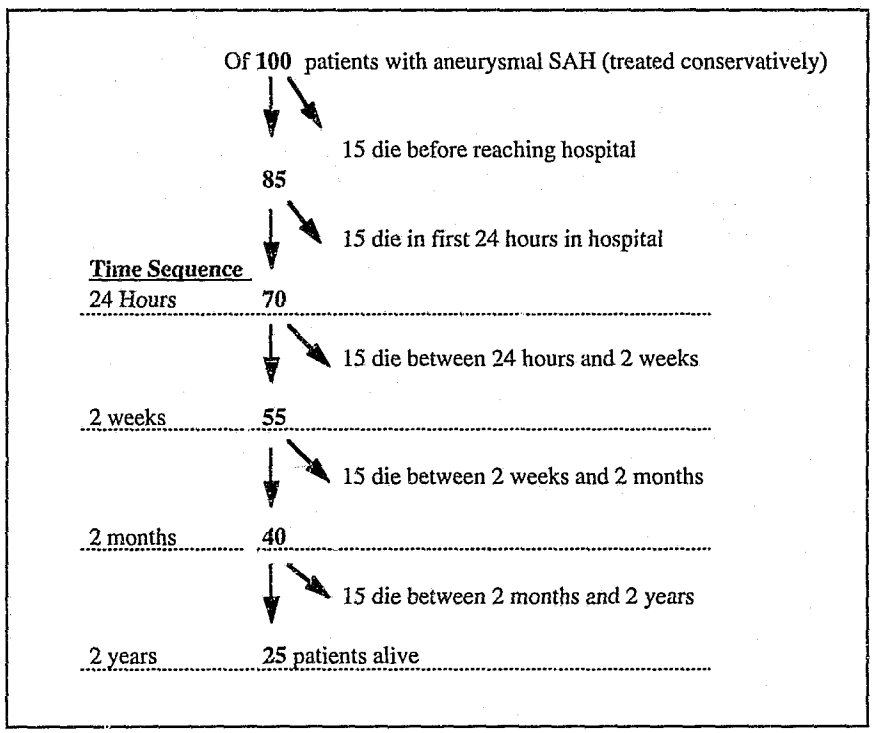

Kassel and Drake's algorithm for patients with SAH in United States

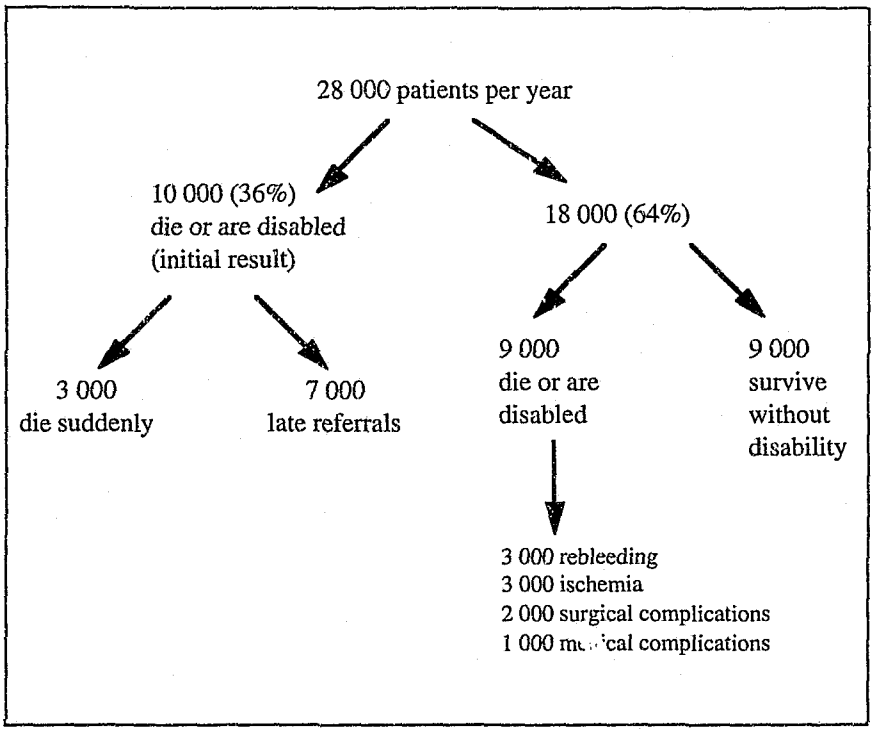

From the algorithm, it is clear that of the 64% of patients who survive to reach a neurosurgical service centre, approximately half of these will die or be severely disabled as a result of rebleeding, cerebral infarction and surgical and medical complications.

3.8 Multiple aneurysms (MA)

MA occur in 15-30% of cases (1, 7, 20, 22, 33) and are relatively more common in females. MA occur more frequently in patients with fibromuscular dysplasia, Ehlers-Danlos syndrome, and coarctation of the aorta. Suzuki's personal series of 1 080 cases published in 1979, showed that 47% of MA are on opposite sides, 21% are on the same side, 29% have one in the midline and one on the side, and 3% have both in the midline (2). When two internal carotid aneurysms coexist, the chance of their being "mirror" aneurysms is three times greater than that of their both being on the same side. Similarly, with two middle cerebral aneurysms the chance is four times greater, when an aneurysm on the anterior circulation is found, the chance of a second aneurysm existing on the posterior circulation is between 3 and 5 percent (1, 2). Posterior communicating aneurysms are least likely to be associated with another sac elsewhere; a second aneurysm in this instance is usually on the MCA. In Eastern Finland, singleton and multiple aneurysms are reported to be preponderant in males (22). If an aneurysm of ACoA is one of the ones present, statistically it is more likely to have bled.

The pathogenesis of multiple intracranial aneurysms is unclear. Recently (1998), Qureshi et al showed that both smoking and female gender remained independently associated with the presence of MA (34). Hormonal factors have been implicated in the association with MA especially since MA are more frequent in females. Smoking has antiestrogenic properties, which may potentiate aneurysm formation in postmenopausal females (34).

How do you tell then which aneurysm has ruptured? Clinically you cannot predict with certainty which aneurysm has bled. The only absolute proof of the site of the rupture is extravasation of contrast medium during angiography, the so-called "smoking gun" (20). However, this is an infrequent occurrence that carries a grave prognosis. Other highly reliable angiographic signs of rupture include

focal spasm, focal mass effect or changes in aneurysm shape on repeat angiograms.

Although these signs have a high diagnostic value, they are relatively uncommon (20, 33, 35). Further signs include irregular aneurysm shape, intra-aneurysmal clot (suggested by poor opacification of the periphery of the aneurysm), an irregular rough dome (umbilication or notch) and an aneurysm nipple. As a general rule when two aneurysms are on the same vessel, unless the proximal aneurysm is thrombosed the proximal aneurysm has ruptured. Clinical signs are helpful in less than a third of cases; although a third nerve palsy or unilateral retro-orbital pain would suggest that an aneurysm had ruptured at the origin of the posterior communicating artery.

Localized collections of subarachnoid blood on CT scan may point to the offending lesion. An algorithm for identifying the ruptured aneurysm, proposed by Nehls et al, was as follows: exclude extradural aneurysms, look for focal blood on the CT scan, check for focal mass or vasospasm on angiogram, observe size and shape (the larger aneurysm is more likely to bleed; if they are of similar size, look for irregularity of the sac or daughter loculus), use clinical signs, consider an EEG, repeat the angiogram later and look for changes in the aneurysms, and finally choose the aneurysm site with the highest probability of rupture (20).

4 FAMILIAL OCCURRENCE OF ANEURYSMS

The familial occurrence of intracranial aneurysms is usually defined by aneurysms occurring in two or more first-to-third degree relatives. Because aneurysms are relatively common, about 5,6 percent of patients can be expected to have a first-to-third degree relative affected with an aneurysm by chance alone. In contrast to sporadic aneurysm cases, familial aneurysms rupture at a smaller size and when the patient is younger (40 to 49 years). The sex distribution and incidence of MA is the same as in reported series of sporadic aneurysms.

In an even smaller percentage of cases, there are familial aggregations with aneurysms due to the effects of known hereditary syndromes or suspected hereditary syndromes. Ehlers-Danlos syndrome is a heterogeneous group of inherited metabolic disorders of which type IV manifests a deficiency of type III collagen, arterial fragility and aneurysm formation (3, 5). Angiography and surgery are extremely hazardous. The berry aneurysm must be regarded as a complication of connective tissue disorders that enhance the development of naturally occurring degenerative vascular changes.

Patients with coarctation of the aorta also have a greatly increased chance of having intracranial aneurysms, which tend to rupture when the patients are in their twenties (3, 14, 15, 36). It is uncertain whether there is a vascular intracranial anomaly associated with the aortic vascular lesion or whether the aneurysms result from the arterial hypertension secondary to the coarctation.

A similar problem exists in determining the relationship of autosomal dominant polycystic kidney disease (PCKD) to intracranial aneurysms. Previous studies found aneurysms in 0 to 40% of patients with polycystic kidney disease (2). The true incidence of aneurysms in the PCKD population remains unknown. Estimates of the prevalence of cerebral aneurysms in the PCKD population based on postmortem findings can be unreliable because the samples are small and not representative of the living population. The finding of petrous carotid aneurysms may be more common in PCKD (31). The role of screening magnetic resonance angiography in these patients is still controversial.

Intracranial aneurysms or pre-aneurysmal changes also have been reported in association with pseudoxanthoma elasticum, Marfan's syndrome (3) and Moyamoya syndrome (37, 38, 39).

5. ANEURYSMS OF INFANCY, CHILDHOOD AND ADOLESCENCE

Aneurysms of infancy, childhood and adolescence are rare and they tend to differ from the usual adult aneurysms. Overall, patients under age 18 account for less than 2% of cases of aneurysmal SAH.

The male female ratio is reversed. Sixty percent of pediatric aneurysms occur in boys (2, 40). This contrasts strikingly with the adult population, where there is a female preponderance of 3 to 2 (7, 10, 33). Between 40 and 45% occur in the posterior circulation, and perhaps 30% are giant. The sites do not differ greatly from those in adults, except that in the anterior circulation, one finds a striking tendency for aneurysms to be located at the internal carotid bifurcation (40).

Traumatic and bacterial aneurysms are more common. Incidence of multiple aneurysms is low. A 6 to 8% incidence has been reported (40). This contrasts with a 15-30% incidence in adults. Co-existence of cerebral aneurysms with a variety of congenital lesions has been reported, but this association is not significant, except with PCKD and coarctation of the aorta. The natural history of ruptured aneurysms in childhood is not well documented. Children are more resilient to the effects of SAH, and there is general agreement that the morbidity and mortality of ruptured aneurysms are more favorable than in the adult population. Vasospasm and associated brain infarction is also seen less frequently in the pediatric population (40). This compares strikingly with a high necropsy incidence (75%) of cerebral infarction in adults with ruptured intracranial aneurysms (33).

6. ANEURYSMS IN PREGNANCY

With decreasing maternal mortality over the last two decades, an increasing number of pregnant women with primary nonobstetrical diseases are being seen. The Department of Health and Social Security (1982) reported that 5,6% of maternal deaths between 1976 and 1978 in England and Wales were attributable to spontaneous intracranial hemorrhage, excluding those from cerebral hemorrhage associated with hypertensive diseases of pregnancy. SAH is an unusual event during pregnancy, labor or the puerperium. Secondary SAH associated with pre-eclampsia and eclampsia is well known. SAH in pregnancy is equally likely to be due to an aneurysm or AVM. Other rare causes of SAH in pregnancy include hematological disorders, metastatic choriocarcinoma, subacute bacterial endocarditis (SBE) and cerebral venous thrombosis.

6.1 Diagnosis

Obviously the outcome of SAH depends on the appropriate management of the source of the hemorrhage. Hence, it is essential to confirm the diagnosis and the underlying cause. Symptoms of SAH due to aneurysmal rupture are similar to those in non-pregnant patients. Pre-eclampsia is a triad of edema, hypertension and proteinuria ocurring primarily in nulliparas after the 20th gestational week. The American College of Obstetricians and Gynecologists have defined pre-eclamsia as the development of hypertension (>140/90 mmHg taken on 2 occasions 6 hours apart or a rise in systole by 30 or diastole by 15mmHg) together with proteinuria (>0,3g/l in a 24 hour urine sample or >1g/l in a random sample)

Premonitory signs and symptoms of eclampsia include hyperreflexia (due to cerebral edema), restlessness and agitation, generalized headache, epigastric discomfort and visual disturbances.

Pregnant cardiac patients may have signs to suggest a mycotic aneurysm rather than a primary berry aneurysm. Pointers towards subacute bacterial endocarditis as being the source of the anurysms include changing murmurs, Roth spots, absent pulses, splenomegaly, fever, clubbing of the digits, Janeway lesions, Osler's nodes, splinter hemorrhages and nephritis.

Cerebral venous thrombosis may present like an SAH. It commonly occurs during the puerperium, when it may present as an unexplained puerperal pyrexia. It may also occur in early pregnancy.

6.2 Time of gestation at which hemorrhage occurs

An arteriovenous anomaly may bleed at any time during pregnancy, with two periods of greatest incidence, one at 16 to 20 weeks and one at 30 to 40 weeks. With aneurysms, the incidence of hemorrhage rises steadily during pregnancy, and this increasing incidence roughly parallels the increase of up to 50% that occurs in the blood volume during pregnancy.

6.3 Treatment

The natural history of spontaneous SAH in pregnancy suggests that the appropriate management be dictated by the underlying source of the hemorrhage. Since rupture of an intracranial aneurysm in pregnancy leads to fatal recurrent bleeding, prompt diagnosis and surgical treatment should be carried out as for the non-pregnant patient (33). In aneurysm patients who bleed before the 36th week of pregnancy, if treated surgically, full-term normal delivery can be anticipated. If imperfectly treated by carotid ligation or if untreated, full-term delivery with the use of second-stage forceps and lumber epidural anesthesia is recommended (41).

7. CLINICAL FEATURES

7.1 Clinical presentations of aneurysmal rupture

About 89% of patients with aneurysms present with SAH, and 7% with tumor symptoms with or without hemorrhage. Aneurysms are incidental findings in 4% (2). Sarnor and Rose studied 962 patients with ruptured aneurysms. Symptoms and signs occurred with decreasing frequency as follows: meningism, 64%; coma, 52 %; nausea and vomiting, 45%; generalized headaches, 21%; reflex changes, 19%; motor deficit, 17%; dysphasia, 13%; confusion, 12%; intraocular hemorrhage, 12%; anisocoria, 11%; papilledema, 9%; homonomous hemianopia, 9%; lateralized headache, 8%; third nerve palsy, 7%; and sensory disturbances, 5%. Thirty nine percent had no localizing signs (2). The cardinal diagnostic feature remains an acute headache that is unusually severe, typically described by the patient as "the worst headache of my life" (8, 15, 42).

The classical clinical features of SAH include the meningitic presentation (fever, neck stiffness, photophobia and delirium) and coma. Because of this meningitic presentation, cases of aneurysmal SAH have been known to be treated erroneously as meningitis.

7.2 Clinical Presentation not due to aneurysm rupture

- **Distal Embolization from partially thrombosed aneurysms**

Transient ischemic attacks or stroke may be considered to be secondary to an aneurysm if no other lesion or predisposing risk factor is present, if the aneurysm is located proximal to the territory involved in the symptomatology, if there is thrombosis in the sac, if the attacks cease when the aneurysm is excluded from the circulation, and if there is no evidence of SAH or vasospasm. Focal neurological deficits depend on the site (anterior versus posterior circulation) and size of vessel (large versus small vessel) involved during the embolic episode.

- **Neurological signs from giant aneurysms**

Symptoms and signs relate to the location of the giant aneurysm and include seizures, focal neurological deficits due to mass effect, pain or embolization from the aneurysm. Giant cavernous aneurysms are extradural and manifest differently, most commonly with cranial nerve deficits (58%) followed by SAH (19%), and as an incidental finding (12%). They may produce carotid-cavernous fistulae and massive epistaxis. Giant ACoA aneurysms can present with autonomic and endocrine abnormalities related to hypothalamic compression, visual deficits related to chiasmal compression or hydrocephalus with associated signs (3).

- **Symptoms and signs from non-giant aneurysms**

The clinical characteristics of ophthalmic artery aneurysms differ from those of the other aneurysms. The lower incidence of SAH is related to the fact that the aneurysm is covered on its superomedial aspect by the optic nerve and similarly is covered superolaterally by the anterior clinoid process, which afford a measure of reinforcement that prevents rupture. Visual symptoms are responsible for about 40-50% of the presenting findings of ophthalmic artery aneurysms (42).

Initially the patient typically presents with an inferior nasal field defect due to pressure on the optic nerve from the superiorly located falciform ligament, a fold in the dura covering the optic foramen and anterior clinoid process (3).

Clinically, the PCoA aneurysm is a unique entity because it probably is the only aneurysm that has a nearly pathognomonic sign associated with its rupture or enlargement – oculomotor nerve paresis. The patient may exhibit anisocoria, ptosis and any degree of limitation in eye movement from the muscles controlled by the oculomotor nerve. An isolated third nerve palsy, in the

absence of SAH should suggest a PCoA aneurysm until further diagnosis proves otherwise. The anatomic basis for this characteristic is the fact that the third cranial nerve is inferior and medial to the PCoA aneurysm, the direction in which a PCoA aneurysm typically projects. Other causes of oculomotor nerve palsy include syphilis, ophthalmoplegic migraine, diabetes mellitus and idiopathic (6, 16, 43). The differentiation between cerebral aneurysms and these other etiologies of third nerve palsy on a clinical basis alone is extremely difficult and non-definitive (43).

ACoA aneurysm and internal carotid artery bifurcation aneurysm usually present with SAH.

SAH is the commonest presentation of MCA aneurysms. Other common symptoms are from mass effect such as focal neurological deficits, headache, papilledema, and temporal lobe epilepsy from compression of the medial temporal lobe. Posterior circulation aneurysms cause lower cranial nerve palsies and brainstem compression. In short, this diversity of clinical presentation mandates a high index of suspicion if timely diagnosis and treatment are to be instituted.

SAH is the hallmark presentation of cerebral aneurysms (18, 35, 44). It usually occurs in patients 40 to 60 years old. Seventy five percent of adults with non-traumatic SAH have a demonstrable aneurysm on angiography. Ten percent have a primary intracerebral hemorrhage as the cause without a demonstrable aneurysm, presumably an occult (non-imaged) aneurysm or AVM, and only 3-5% have an AVM.

8. DIAGNOSIS OF ANEURYSMS AND ANEURYSM RUPTURE

As with most other neurological illnesses, SAH is diagnosed from the nature and temporal profile of the symptoms expressed in the patient's medical history rather than by physical examination. Aneurysmal rupture manifests clinically as a sudden onset of a severe headache. The acute onset of an excruciating headache, with or without loss of consciousness should be considered the result of SAH until proved otherwise.

For as many as one quarter of all SAH patients, symptoms are attributed to other causes. Some of these include influenza, migraine, brain tumors, cervical spondylosis, meningitis, gastroenteritis, alcohol intoxication, head injury, malingering, delirium, myocardial infarction and cerebral infarction. Because of this multitude of conditions, the correct diagnosis is sometimes delayed (3).

8.1 Physical examination

The physical examination may or may not reveal global or focal neurological abnormalities, depending upon the location and extent of intracranial hemorrhage. Neck stiffness is a well-recognized sign of SAH but may take hours to develop and may never appear in some patients. Neck stiffness does not develop until blood starts to break down in the subarachnoid space. Therefore the absence of neck stiffness, especially in the acute phase does not exclude a recent hemorrhage, and this fact adds to the difficulties of diagnosing patients with severe headaches or loss of consciousness.

Oculomotor nerve palsy is seen with PCoA aneurysms and upper basilar artery aneurysms. Abducens nerve palsies are often bilateral in the acute stage and usually result from transient or prolonged elevations of intracranial pressure (3, 16). Fundal hemorrhages develop in about 20% of SAH patients. Linear streaks or round, flame-shaped hemorrhages may occur into the preretinal or

subhyaloid layer and into the vitreous body. Fundal hemorrhages are caused by an acute increase in intracranial pressure and are virtually pathognomic of aneurysmal rupture. These hemorrhages are the result of retinal venous congestion caused by obstruction of the central retinal vein as it traverses the optic nerve sheath.

Fever is unusual immediately after SAH. In most cases there is a rise in temperature (up to 38-39 degrees Celsius), generally on the second or third day (33). However, fevers up to 39 degrees are common after the fourth day (3). Fever is related to the accumulation of blood breakdown products in the subarachnoid space.

About 50% of all patients presenting with SAH have elevated blood pressure (BP). In most cases, hypertension is reactive in response to the hemorrhage, and the BP returns to normal in a few days. Efforts directed at reducing the BP may reduce rebleeding but carry a risk of increasing cerebral ischemia (3). The reactive transitory rise in BP is a physiological response to raised intracranial pressure in order to maintain cerebral perfusion. Excessive hypertension with a systolic BP above 250mmHg in critically ill patients often denotes a fatal outcome (33).

8.2 Lumbar Puncture (LP)

LP can also be used to establish the diagnosis of SAH. If the patient is in a coma or has focal neurological signs a lumbar puncture is contraindicated. Lumbar puncture may precipitate herniation syndromes in patients harboring intracerebral hematomas. Parenchymal hematomas secondary to SAH produce focal neurologic deficits in approximately half of the patients presenting with acutely ruptured aneurysms. The site of the hematoma determines the pattern of focal neurologic deficit. Because such a significant number of SAH patients may

be at risk a lumbar puncture should not be performed unless the results of a CT scan have excluded the possibility of a hematoma (3, 16, 45).

Subarachnoid blood may not reach the lumbar subarachnoid space for several hours following the ictus and xanthochromia may take even longer to develop. Therefore, if possible, it is best to wait 6 hours or preferably 12 hours, after the onset of headache before performing a lumbar puncture (3).

Distinguishing between blood-stained cerebrospinal fluid (CSF) resulting from SAH and that resulting from a traumatic LP is often difficult. Collecting the CSF in three consecutive tubes and comparing blood cell counts in each tube makes such differentiation possible. A decrease in red blood cell (rbc) count in successive tubes would indicate a traumatic puncture (2,16). However, decreasing blood cell counts may also occur after intracranial hemorrhage and distinctions cannot be made with certainty. Subjectively looking at the three tubes can also help in differentiating a traumatic tap from a SAH. If all three tubes are uniformly stained, a SAH is the more likely diagnosis. If the blood-stained CSF appears to be clearing from the first to the third tube, a traumatic tap is more likely.

The most reliable method for distinguishing a traumatic LP from SAH is to spin down the CSF and examine the supernatant fluid for the presence of xanthochromia. Xanthochromia is absent in traumatic taps but present in SAH. Spectrophotometric examination is more sensitive than direct visual inspection. All patients with SAH have xanthochromic CSF 12 hours to 2 weeks after the bleed. Measurable xanthochromia occurs in 70% of patients at 3 weeks and in 40% at 4 weeks. The first pigment to appear in the CSF after SAH is oxyhemoglobin, which can be detected as early as 2 hours after the bleed. Oxyhemoglobin is then converted to bilirubin. One alternative to examining the CSF for xanthochromia may be measurement of fibrin degradation products (3).

Table 8.1 CSF features of a traumatic tap and a SAH.

	Traumatic tap	SAH
Xanthochromia	absent	present after centrifugation
Clotting	may occur	absent
Blood staining	varies from tube to tube	usually uniform in all tubes
Pressure	usually normal	elevated
Repeat puncture at higher interspace	often clear	similar to initial tap

Other causes of xanthochromia include spinal block, Guillian-Barre syndrome, acoustic neuroma, subdural hematoma and purulent meningitis.

8.3 Computed Tomography (CT)

The technique of CT was developed by Godfrey Hounsfield (1973) (46). This major achievement earned him a knighthood and the award of the Nobel Prize for Medicine in 1979. The radiodensity of iron in recently extravasated, non-moving blood is much higher than that of CSF or brain tissue; therefore, CT scans can clearly show SAH. On unenhanced CT the hemorrhage (subarachnoid blood) shows as an area of increased attenuation ranging from 50-90 Hounsfield units (HU).

The presence and distribution of subarachnoid blood from a ruptured aneurysm can be inferred from the radiodense (white) regions in the subarachnoid space. Currently, CT is the imaging modality of choice used to confirm the diagnosis of SAH (15).

CT scan demonstrates the presence of blood in more than 90% of patients scanned within 24 hours of the ictus. Failure to detect blood with early scanning is particularly likely with posterior inferior cerebellar artery (PICA) aneurysms.

The accuracy of detection using non-contrast CT is 60-90% depending on the time of the scan. In fact, the proportion of positive scans decreases to 88% at 3 days, 50% at 7 days, 20% at 9 days and almost 0% at 10 days (3, 14). Factors that may account for this variation include rate of blood clearance and anemia. In addition, as blood decomposes with time, it becomes isodense to brain and is more difficult to detect on CT scans.

If SAH is suspected from the patient's medical history but the CT scan is normal, the patient should be further evaluated with a lumbar puncture, because all patients with SAH have xanthochromic CSF 12 hours to 2 weeks after the bleed.

A noncontrast CT scan (NCCT) typically shows hyperdense blood in the basal cisterns, superior cerebellar cistern, Sylvian and interhemispheric fissures and within the subarachnoid spaces over the convexities (6, 8, 14, 15 ,47). The presence of intraventricular blood or intracerebral blood may imply rupture of an aneurysm in a specific location. It is the tightly packed hemoglobin molecules, which are responsible for the high attenuation values. A NCCT scan should be done first because arterial enhancement in the basal cisterns may be mistaken for clotted blood. A contrast CT is rarely indicated in most subarachnoid hemorrhages but is of vital importance if the SAH is suspected to be due to an AVM or oncotic, mycotic, or giant aneurysm.

CT is the investigation of choice for locating the primary affected area, as a preliminary to "dedicated" angiography, which is required as a neurosurgical road map prior to surgery. Besides confirming the clinical diagnosis of SAH, CT scanning identifies other associated lesions such as hydrocephalus, intracerebral

hematoma, tumor, areas of ischemia or infarction and arteriovenous malformations (AVM). It also helps in identifying the site of aneurysmal rupture when the SAH is focal e.g. blood in the Sylvian fissure suggest MCA aneurysm rupture.

4 Magnetic Resonance Imaging (MRI)

MRI is less sensitive than CT in detecting SAH within the first few days. In the acute stages of SAH, subarachnoid blood can be detected as increased signal intensity on T2-weighted MRIs. Detection of subarachnoid blood clot depends on it yielding a relatively higher signal than the low signal of CSF on T2-weighted images; blood dispersed throughout the mobile cisternal CSF is unlikely to be detected. MRI becomes increasingly reliable at detecting subarachnoid or intracerebral clot over several days.

T1-weighted images best detect extravasated blood after 4 days, owing to the paramagnetic effect of hemoglobin breakdown products. Because of this paramagnetic effect, MRIs may be able to reveal the site of hemorrhage in patients whose referrals are delayed. In recurrent SAH, the hemosiderin deposited on the brain surface is detected as low-signal intensity (called delayed pial hemosiderosis) on T1 –weighted images. MRI rather than CT best shows complications of SAH (hydrocephalus, interstitial edema of hydrocephalus, and cerebral ischemia).

9. COMPLICATIONS OF ANEURYSMS AND ANEURSMAL RUPTURE

9.1 Intracranial

- **Rebleeding** (see page 18)

- **Cerebral ischemia** (see also vasospasm page 60)

A blood clot in the subarachnoid space in the vicinity of major cerebral vessels may result in development of cerebral arterial spasm. The greater the amount of blood in the cisterns (as shown by the CT scan), the higher the incidence of vasospasm and associated ischemic deficits. The distribution of blood clot at aneurysm rupture determines the distribution of vasospasm. Lillequist's membrane may block the spread of blood clot into the cisterns of the posterior fossa on rupture of an aneurysm in the carotid system. Vasospasm of the vertebrobasilar system is rare, and not severe when it does occur (48). The incidence of vasospasm following aneurysmal SAH varies in different series from 20-40% and is maximum between the 5th and 10th day (3, 33, 47, 48). About 25% of these patients develop clinical evidence of ischemia/infarction; of these 50% die as a result, and permanent neurological deficit persists in 50% of survivors (16). Hence, cerebral ischemia/infarction is an important contributory factor to morbidity and mortality.

- **Hydrocephalus**

Acute obstructive hydrocephalus (within a week) secondary to intraventricular hemorrhage or ependymitis obstructing the acqueduct of Sylvius or the outlet of the 4th ventricle should be treated with external ventricular drainage as an emergency. Delayed communicating hydrocephalus (after 1 week) is usually secondary to fibroblastic proliferation in the subarachnoid space and arachnoid villi. This more insidious chronic hydrocephalus, if it is delaying full recovery or is associated with regression and neurological signs, should be treated with a ventriculoperitoneal shunt (VP shunt) (2).

- **Expanding intracerebral hematoma**

Brain swelling around the hematoma may cause progressive deterioration in the level of consciousness or progression of focal signs.

- **Seizures**

Generalized or focal seizures may occur at any stage after SAH, especially if cortical damage from a hematoma has occurred. Most young patients with middle cerebral hematomas should be treated with anticonvulsants for at least 2 years following their aneurysmal rupture. Decisions about other patients should probably be individualized (2).

- **Intellectual impairment and depression**

These are the two most common psychiatric problems after aneurysmal rupture.

9.2 Extracranial

- **Cardiovascular**

Myocardial infarction and arrhythmias occurs secondarily to catecholamine release following ischemic damage to the hypothalamus. The electrocardiographic abnormalities that occur include T-wave abnormalities (47%), Q-T prolongation (37%), ST segment changes (30%) and prominent U-waves (25%).

- **Pulmonary**

Among the most dramatic and dangerous acute complications of aneurysmal rupture is pulmonary edema. This is probably as a result of massive sympathetic discharge.

- **Gastric hemorrhage**

  This occurs secondary to stress erosions and ulcers.

- **Fluid and Electrolyte Disturbances**

  Sodium abnormalities (hyponatremia and/or hypernatremia) occur with aneurysms of the anterior communicating artery more commonly than with aneurysms at all other sites combined. In a review of Suzuki's 1000 surgically treated aneurysms, the abnormalities reached a peak (20%) between the 3rd and 7th day after the last hemorrhage. In this series hyponatremia occurred in 4% of cases, hypernatremia in 2,1%, both disorders in 1%, and polyuria in 0,7% (49). The death rate associated with hypernatremia was 43%; with diabetes insipidus 25%; and with hyponatremia 15%, compared with the overall death rate of 6%.

  Hyponatremia after SAH has usually been attributed to SIADH. It is now believed that hyponatremia after SAH is not always due to SIADH.

10. SCREENING FOR ANEURYSMS

Noninvasive screening for aneurysms may be desired for the patient with a predisposing condition eg. fibromuscular dysplasia, Ehlers-Danlos syndrome, coarctation of the aorta, intracranial AVMs, systemic lupus erythematosus (SLE), polycystic kidney disease (adult PCKD), Moyamoya disease, Marfan's disease, pseudoxanthoma elasticum or persistent embryonic vessels.

Magnetic resonance angiography (MRA) is a technique that highlights flowing blood against featureless stationary tissue. The two methods to highlight blood flow include time of flight (TOF) and phase contrast (PC). The reported MRA sensitivity is 86 to 95% (26, 27). It is still difficult, however, to reliably detect intracranial aneurysms of less than 3mm by means of MRA (21, 26). MRA may fail to image an aneurysm, resulting in a false negative study. Subacute thrombus, with its short T1, may not be saturated and may be mistaken for blood flow in an aneurysm, giving a false positive result.

Another imaging modality that is used for screening for asymptomatic aneurysms is CT angiography (CTA). CTA is performed by thin-section, rapid, dynamic CT scanning during rapid (2mls/sec) intravenous injection of an iodinated contrast agent. Three-dimensional reconstructions of the enhanced vessels are then obtained using the software applications. The limited field of view and the overlying skull base limits the usefulness of this modality in screening for intracranial aneurysms. CTA is less sensitive than MRA in detecting asymptomatic aneurysms.

11. IMAGING OF INTRACRANIAL ANEURYSMS

11.1 Plain films

In the past, plain skull radiography was the first imaging modality undertaken in a patient suspected of having an intracranial aneurysm. These roentgenograms were reviewed for displacement of the pineal body or choroid plexus secondary to an intracerebral or subdural hematoma. Other features on x-ray include enlargement of the superior orbital fissure, rarefaction of the optic canal, destruction of the anterior clinoid process, the dorsum sellae, and the floor of the sella turcica. Rarely, calcification (curvilinear) can be seen in the walls of giant aneurysms.

11.2. High-Resolution Computed Tomography

CT is currently the investigation of choice for the detection of SAH. In cases of focal SAH it also helps in localization of intracranial aneurysms.

- **Unenhanced CT Scanning**

The blood in the subarachnoid spaces in acute SAH shows as high attenuation. The contribution of the various constituents of blood to this high attenuation at CT has been shown to be mainly due to its hemoglobin content. As clotted blood retracts, serum is extruded, the hemoglobin concentration increases, and with it the attenuation of the blood.

The length of time that the high attenuation (60-80 HU) persists at CT is dependent on the amount of blood in a given part of the subarachnoid space, but usually it lasts for about a week, although rarely it may be seen for up to 13 days. After about a week, blood becomes isodense with respect to brain, so that the involved cisterns are no longer visualized at CT. The cisterns then resume their previous low density after about 14 days, as the CSF replaces blood (33).

In patients with severe anemia, subarachnoid, intracerebral and intraventricular hemorrhages may be only slightly more dense then the surrounding brain tissue and therefore a SAH can be missed.

Aneurysmal SAH will be detected in more than 90% of the patients in the first 24 hours and over 50% within the first week. These percentages drop off dramatically following the seventh day. If the unenhanced CT scan does not demonstrate a SAH, an LP should be done in the absence of raised intracranial pressure.

The hemorrhage from a ruptured aneurysm is usually subarachnoid. It can also be subdural (up to 8%), intraparenchymal (21%), intraventricular (21%) or a combination (3, 28). The location of subarachnoid blood may frequently suggest the site of the bleeding aneurysm.

- **Enhanced CT Scanning**

After evaluating the unenhanced CT scans, intravenous iodinated contrast media may be given and the routine sections repeated. Sequential high-resolution thin slices through the circle of Willis following a second intravenous bolus may also be performed. These maneuvers are especially helpful in very sick patients where immediate cerebral angiography or surgery is not contemplated or where the unenhanced CT has not localized the site of the aneurysm (2). Contrast enhancement may also demonstrate the aneurysm itself, although only large aneurysms (more than 0,5 – 1 cm) are routinely seen.

Enhanced studies have several purposes. Firstly, they may identify the cause of SAH in some patients. Secondly, the size, shape, and relationship of an aneurysm to the parent vessel can sometimes be determined with high-resolution techniques. In patients, the localization of a SAH and its cause can

therefore be made on a relatively noninvasive, low-morbidity study, and angiography can be deferred until the patient is more stable, angiography team better prepared, and the angiographer better informed. Lastly, even rarer lesions such as hemorrhagic metastasis to the brain, which occasionally causes SAH, can be detected on enhanced studies. Magnification can help to delineate fine detail. The use of sagittal and coronal reformatting or direct coronal scanning provide additional information concerning the aneurysm's relationship to other vital structures at the base of the brain. (28). Contrast enhancement is unnecessary in the majority of cases when angiography will in any case be carried out. It is indicated in suspected arteriovenous malformations.

- **CT and aneurysm localization from SAH distribution**

The location of subarachnoid blood may frequently suggest the site of the bleeding aneurysm.

Table 11.1 Aneurysm localization from SAH distribution

Possible aneurysm site	Pattern of subarachnoid blood
Middle cerebral artery (M1- M2 junction)	Sylvian cistern
Anterior communicating artery	Anterior interhemispheric cistern ± both sylvian fissures
Pericallosal artery	Interhemispheric fissure
Basilar tip	Pontine ± ambient ± suprasellar cistern
Posterior communicating artery	Generalized

The location of the SAH associated with bleeding PCoA aneurysms varies depending on the direction to which the aneurysm points. Hemorrhage into the Sylvian fissure is seen with aneurysms whose tip points laterally. On the other hand, a tip pointing posteriorly may be associated with hemorrhage into the interpeduncular cistern. Specific patterns of bleeding frequently make it possible to locate the aneurysm that has bled. This ability may be of great importance when multiple aneurysms are found by subsequent angiography.

- **CT and intracerebral hematoma**

Cerebral hematoma is often an indication of aneurysm location.

Table 11.2 Aneurysm localization from hematoma site

Possible aneurysm site	Intracerebral hematoma
Terminal internal carotid artery	Basal ganglia
Middle cerebral artery	Insula and temporal lobe
Anterior communicating artery	Medial frontal lobes, septum pellucidum or corpus callosum
Pericallosal	Frontal lobe, septum pellucidum corpus callosum
Posterior circulation arteries	Infrequent cerebral hematomas

The pattern of SAH with intraventricular hemorrhage and without parenchymal hematoma is highly suggestive of a posterior fossa aneurysm, especially if the blood is in the fourth ventricle (3). Hematomas are frequently found in association with anterior communicating and middle cerebral artery aneurysms. Posterior communicating and posterior circulation aneurysms produce hematomas relatively infrequently. The pattern of distribution of intracerebral hematomas is more specific than that of subarachnoid cistern hemorrhage for aneurysm location (33).

- **Hypodense areas**

Cerebral vasospasm is defined as a prolonged but temporal narrowing of intradural, subarachnoid arteries, occurring days after SAH and lasting for approximately two weeks. Radiographic or angiographic vasospasm refers to the demonstration of arterial vasospasm on an angiogram after SAH. Neurological deterioration secondary to cerebral vasospasm usually presents at least 3 days after SAH and therefore is referred to as delayed cerebral ischemia or ischemic neurological deficit. Cerebral vasospasm was described initially by Ecker and Riemenschneider in 1951 (3).

Hypodense areas representing either ischemic edema or infarction are frequently seen on CT scan following aneurysmal SAH. In most cases, the infarct is in the territory of the artery from which the aneurysm arose. The rate of infarction may be related to the thickness of subarachnoid blood shown on the admission CT scan. The thicker the layer of subarachnoid blood, the more likely that infarction will be seen on CT scanning.

- **Relation of Cerebral Vasospasm to SAH visualized by CT scanning**

Fisher et al. (50), divided the CT findings within 5 days post ictus as follows:

group 1 - no blood detected;

group 2 – thin (<1mm thick) layer of blood in the interhemispheric fissure, insular cistern, or ambient cistern, or diffuse deposition;

group 3 – localized clots and/or layer of blood 1mm or greater in thickness;

group 4 – intracerebral or intraventricular clots with diffuse or no subarachnoid blood.

The group 3 findings were predictive of severe vasospasm.

- **CT in Multiple Aneurysms**

Although angiographic criteria, such as localized spasm, vessel displacement, size and lobulation of the aneurysm indicate which aneurysm has ruptured, CT scanning can be extremely helpful in patients with multiple aneurysms to decide which has bled. The CT scan may show an area of increased density indicative of a bleed in the vicinity of one of the aneurysms, thereby indicating the site of hemorrhage (7, 33).

- **Hydrocephalus**

The CT scan also gives information about the possible complications of aneurysm rupture. Both acute obstructive and chronic communicating hydrocephalus can be demonstrated. The reported CT incidence of hydrocephalus has been very variable, ranging from 12,4% to 58%.

- **CT scan findings and Prognosis**

Turnbull (1980) noted that the size of the intracerebral hematoma in patients with aneurysmal SAH could help to predict patient outcome (51). In his series over 80% of patients with a hematoma smaller than 2,5cm made a full recovery, while only 20% of patients recovered fully if the hematoma was greater than 2,5cm.

- **CT scan findings and SAH of Unknown Origin**

About 10% of patients with SAH have no demonstrable cause. This type of SAH with an initial negative cerebral angiogram has a more benign prognosis than untreated aneurysmal SAH (53, 54). It has been suggested that in these patients, the risk of both morbidity and rehemorrhage may be predicted by the distribution of subarachnoid blood as seen on CT scans obtained at the time of the SAH. In particular, a recognizable perimesencephalic pattern of hemorrhage appears to indicate a more favorable prognosis and a lower rehemorrhage rate than do other distributions of subarachnoid blood (3, 52).

Thus the findings on early CT scans can help identify patients with either a low or high risk of rehemorrhage and of further complications. Hemorrhage from a vein or capillary is especially implicated in those cases in which a perimesencephalic pattern of blood is seen on imaging studies. Other proposed possible causes include rupture and subsequent thrombosis of a small artery that arises directly from the basilar artery or circle of Willis and leakage from the lenticulostriate or thalamoperforate vessels.

- **CT and Giant Aneurysms**

Giant aneurysms are defined as those over 2,5cm at their maximum diameter. They can present as a space-occupying lesion or as an SAH. These aneurysms are round or globular, moderately hyperdense on noncontrast CT and may have rim like calcification in the walls. A peripheral ring of increased attenuation is present when there is intraluminal thrombosis.

Non-thrombosed aneurysms enhance uniformly (mimicking hypervascular tumors) but partially thrombosed aneurysms may show a central area of enhancement (target sign).

- **CT and Patient deterioration**

CT is the fastest imaging modality available for evaluating the cause of a patient's deterioration. Acute hydrocephalus, vasospasm and rebleeding are the three most common causes for patient deterioration.

Unenhanced CT is an ideal non-invasive modality for identifying hydrocephalus and recurrent SAH. If CT excludes these two causes then a strong presumptive diagnosis of ischemia from vasospasm can be made to be the cause of declining Glasgow Coma Scale.

11.3 CT Angiography (CTA)

CT angiography is a technique in which contrast-enhanced helical CT scans are used to create a computer-generated 3-dimensional (3-D) depiction of blood vessels. For helical CT of the intracerebral vessels a standard protocol dependent on the type of scanner is used. An intravenous catheter is placed into an antecubital vein and a topogram of the head is then obtained for localization of the skull base. The gantry is tilted to the orbitomeatal line, and a starting point is selected at the base of the sella turcica.

A non-contrast scan is usually not needed. Imaging is started 20 seconds after an intravenous injection of 75ml of iodinated contrast (low osmolar) medium using a power injector at 2,5mls/s. The CT table is withdrawn through the gantry at a velocity of 2mm/s while scanning is performed. This results in a 3-D volume acquisition of 6,4cm. The 2mm sections are reconstructed at 1mm increments. The bony structures at the skull base are excluded from the axial images and the resulting data reformatted using either surface shaded display (SSD) or maximum intensity projection (MIP). Post processing is then done and the 3-D CT angiogram can be rotated freely in space on a computer workstation for viewing vascular anatomy from any projection. A minimum density threshold of 90-100 HU can be used. This minimum density level is selected to exclude fresh hemorrhage in the basal cisterns while at the same time including intravascular contrast.

Helical CT and MRA generally are equivalent in their ability to delineate the location, contour, and neck of aneurysms greater than 3mm in size. Confusion with vessel tortuosity and multiple branching vessels in close proximity to the aneurysm are two causes of missed aneurysms (56).

Introduction of helical CT technology in early 1990s revolutionized CT and has allowed new CT applications to be created. The development of CTA may be the single area in which helical CT imaging has had its greatest impact, spawning a tremendous amount of research and development. Current documented applications for CTA include noninvasive neurovascular, thoracic and abdominal vascular application.

One reason for the integration of CTA into clinical radiology practice is the promotion of noninvasive imaging techniques over their invasive counterparts. Noninvasive techniques being advocated for patient safety and for economic reasons. Noninvasive examinations frequently can be performed at a lower cost compared with their invasive counterparts. Another distinct advantage of CTA which is driving the clinical integration of this technique, compared with other vascular imaging modalities include a faster examination that can be performed as an outpatient procedure without postprocedural monitoring and with less radiation to radiology personnel (57).

- **Advantages of CTA**

  - Most helical CT acquisitions take between 30 and 40 seconds to perform, so that aneurysms can be imaged without motion artifact.

  - The helical CT image reflects the volume of contrast media within a vessel and appears to be independent of the flow rate; thus flow related artifacts are not encountered. This results in better visualization of large aneurysms at CTA than at MRA.

  - Helical CT is sensitive in detecting calcium. Calcium in the neck of the aneurysm may cause difficulty during clipping. This information may be important to the neurosurgeon for surgical planning (55).

- CTA can be used particularly in patients who cannot tolerate an MR examination owing to anxiety, body size, or the presence of MR-incompatible implanted devices.

- The information reconstructed from the helical CT acquisition can be viewed from virtually any perspective in order to display vascular anatomy to maximum advantage (21).

• **Disadvantages of CTA**

- The use of intravenous iodinated contrast is associated with the usual risks of contrast media side effects and anaphylactic reactions.

- The relatively small volume of image acquisition of 6,4cm. This volume includes the most frequent sites of intracranial aneurysms, but small distal aneurysms of the ACA in the interhemispheric fissure or PICA can be missed.

- CTA delivers a radiation dose to the patient. Helical CT delivers a smaller radiation dose to the patient per section than does standard head CT. (21).

- The SAH has the potential to obscure an aneurysm, due to the similarity in attenuation of blood and contrast media.

- Aneurysms measuring 2mm can be overlooked on spiral CT (55).

- Postprocessing and reconstruction of the helical CT images generally takes 45-60 minutes in the hands on an experienced technologist and longer if done by a person who is unfamiliar with postprocessing.

11.4 Intra-arterial Cerebral Angiography.

Selective intra-arterial angiography is the gold standard for defining the location, orientation, and neck of an aneurysm. A transfemoral or, less commonly a brachial or an axillary approach allows for multiple arterial injections.

Egaz Moniz and his colleague Almeida Lima introduced the technique of cerebral angiography in 1927. Their first successful case involved surgical exposure of the carotid artery and the direct injection of a 25% solution of sodium iodide. Myerson and Loman in 1936 and Shimadzu in 1937 subsequently developed percutaneous cerebral angiography (33). In 1953, Seldinger introduced the technique of femoral artery catheterization. This approach provided the advantage that one could carry out a four vessel cerebral angiogram at one study with one arterial puncture. The subtraction technique aids in locating aneurysms, particularly in the vertebrobasilar system. The dense bone is subtracted so that the vascular anatomy is seen better.

Traditionally, film-screen technique has been recommended to look for aneurysms; it gives submillimeter resolution for distinguishing aneurysms from vessel loops. Digital subtraction angiography (DSA), with computer aided subtraction, is now the most popular method. No studies to date have compared intra-arterial DSA with intra-arterial film-screen techniques. Perhaps the new DSA technology is as good as the traditional film-screen method. The benefits of DSA are that every image is subtracted and the examination is faster with the instantaneous computer images.

Recent improvements in angiographic technique, including better equipment, catheter and guide wire design as well as increased safety of the current iodinated contrast media, mean that angiography now has an acceptably low complication rate.

- **Procedure**

Catheter cerebral angiography is the gold standard for identifying cerebral aneurysms. Four vessel or a technically adequate 3-vessel cerebral angiogram in which there is reflux of contrast medium from the one vertebral artery down to the contralateral posterior inferior cerebellar artery remains the most reliable means of identifying cerebrovascular aneurysms and is the final step in the radiological evaluation of patients with suspected aneurysmal SAH.

Selective injections of small amounts of low osmolar contrast medium (6-10ml) into each common carotid artery (CCA) or each internal carotid artery (ICA) and vertebral arteries will usually suffice to demonstrate the circle of Willis in great detail. Angiography is performed with selective CCA or ICA and vertebral injections, using a very high-resolution mask digital subtraction angiography technique (DSA) together with magnification rapid serial filming.

- **Aims of angiography**

  - To define the cause of the SAH (aneurysm, AVM, Moyamoya disease etc.)
  - To characterize the aneurysm with respect to size, its relationship to adjacent vessels, shape and the configuration of its neck.
  - To identify complications of aneurysm rupture e.g. vasospasm, and vessel displacement by hematoma.
  - To study the collateral circulation and identify any vascular anomalies of the circle of Willis as this may influence surgical approach.
  - To detect whether multiple aneurysms are present and if so, help indicate which has bled.
  - To check the effectiveness of neurosurgical treatment of aneurysms postoperatively (58).

- **Timing of angiography**

Aneurysmal SAH occurs in approximately 28000 individuals per year in North America. Estimates based upon "The International Cooperative Study on the Timing of Aneurysmal Surgery" and others suggest that between 15 and 46% of patients suffering aneurysmal SAH die prior to reaching the hospital (9). Of these patients who are admitted to the hospital following SAH, between 70 and 75% are in "good" neurological condition with respect to consciousness, motor responses and speech (9). Disappointingly, however, only about 60% of these patients return to their premorbid state and many in this group have subtle deficits on neuropsychological testing (59).

Although the best medical and hemodynamic therapies of aneurysmal SAH in the perioperative periods continue to evolve, surgical intervention is currently the only proven means by which to cure the patient with a ruptured intracranial aneurysm. Because of the devastating effects of aneurysmal SAH to the patient and to society, most neurosurgical units nowadays prefer angiography to be done within 24hours of admission so that aneurysmal clipping can be carried out on the next theatre list.

Limited angiography may be required as an emergency measure in seriously ill patients requiring lifesaving evacuation of a hematoma demonstrated on CT. Because vasospasm is maximum between the 5th and 10th day and rebleeding can occur in the first five days some neurosurgeons advocate that the first angiogram should be done after 2 weeks of the initial SAH.

- **Type of angiography**

The recent trend has been to use the transfemoral catheter angiography technique. The femoral approach is especially suited in younger patients and particularly if there is no clinical or CT clue of the site of the hemorrhage. This is simple to perform under local anesthesia and allows rapid demonstration of both the anterior and posterior circulations in the course of one examination.

In older patients (over age 55), atheromatous disease and vessel tortuosity may make this technique more difficult or impossible. Direct puncture is used in older patients where the site of the bleed has been localized at CT. With improvements being made to MRA, direct puncture is now seldom indicated. In places where MR imaging is still not available or easily accessible direct puncture is still being used.

- **Extent of angiography**

In the general population the maximum prevalence of unruptured intracranial aneurysms is 0.5%. Of these approximately 95% are first diagnosed after rupture. An aneurysmal SAH is a very serious cerebrovascular disease with a morbidity and mortality of at least 20-25% and 50-60% respectively (35).

One of the main problems in the treatment of intracranial aneurysms is how to diagnose more aneurysms before rupture. Patients with ruptured aneurysms have a much higher prevalence of unruptured aneurysms (multiple aneurysms) compared to the rest of the population. All four major intracranial vessels, both internal carotids and both vertebral arteries should be studied because of the 10-35% incidence of multiple intracranial aneurysms (3).

Typically, one vertebral injection with contrast reflux to the contralateral PICA is adequate. When the reflux is inadequate, a separate injection should be made into the contralateral vertebral artery.

The extent of angiography does depend to some extent on the age of the patient, the clinical grade of SAH and the attitude and local expertise of one's neurosurgical colleagues. Generally, a four-vessel angiogram is carried out. In elderly or sick patients in whom CT scan has definitely localized the site of the hemorrhage, the neurosurgeon may limit the extent of angiography to the relevant artery or arteries.

If a unilateral carotid angiogram (UCA) is extended to a bilateral carotid angiogram (BCA), the number of unruptured aneurysms (UA) is increased with 185% i.e., the disclosed frequency of UA is approximately three times greater if at least BCA is performed compared to only UCA. In patients with ruptured aneurysms located on the MCA the diagnostic gain of UA is nearly 10 times greater if BCA is performed instead of UCA. The frequency of additional UA in patients with ruptured aneurysms on the ICA is approximately doubled if BCA is performed compared to only UCA (35).

Assuming a 2% bleeding rate per year for UA a theoretical study has shown that UA diagnosis reduces the expected survival with 19%, 34%, 40%, 56%, 64% and 72%, 10, 20, 30, 40, 50 and 60 years after the UA-presenting age. An UA, therefore is much more serious the younger the presenting age. It is therefore recommended to perform at least BCA and one vertebral angiogram in patients with ruptured aneurysms (35).

- **Angiographic projections and specific aneurysm sites**

Four standard projections are carried out for anterior circulation aneurysms at our institution: (a) Towne's, (b) lateral, (c) per-orbital (AP oblique projection through the orbit), and (d) reverse per-orbital oblique through the orbit. For the per-orbital view, the Frankfurter baseline (lower border of the orbit to external auditory meatus) is used. The tube is angled 5-10 degrees cranially and 20 degrees oblique to the right or left for the right internal carotid artery and left internal carotid artery AP oblique projections respectively.

For posterior circulation aneurysms two standard projections are carried out (a) Towne's and (b) lateral.

These standard views are supplemented by additional projections, which may be required to show anatomical details more clearly or to distinguish between a vessel loop and an aneurysm. Magnification studies with subtraction in the projections, which optimaliy show the aneurysm, can be carried out.

Some neuroradiologists perform a third routine projection, the vertebral oblique, to show more clearly the origin of PICA. For this projection the Frankfurter baseline is used. The tube is angled 10 degrees caudally and 40 degrees oblique to either side from the vertical. Centering is 2.5cm in front of and 3.75cm above the external auditory meatus.

- *Intracavernous aneurysms*

Two disadvantages of angiography are, first, its inability to allow full evaluation of a thrombosed aneurysm and, second, the incorrect localization of it as extracavernous if it arises at or slightly distal to an ophthalmic artery with an intracavernous origin.

The following angiographic features suggest an intracavernous location of the aneurysm:

- The ophthalmic artery arises more proximally on the carotid trunk than on the most proximal part of the aneurysm.
- The aneurysm lies partly above and below the anterior clinoid process; this argues for a partly intradural and partly intracavernous location.
- The fundus of an intracavernous aneurysm (on the lateral view) is superimposed on the intracavernous carotid artery (33).

• *Internal carotid artery bifurcation (ICAB aneurysms)*

The most common projection of ICAB aneurysms is superior although occasionally they project in an anterior or posterior direction. Most are seen in the routine projections. A straight AP view through the orbit may be valuable.

• *Middle cerebral artery aneurysms*

The angiogram should define the size, shape, location and direction of the aneurysm; the length of M1 segment (first part of MCA) and the relationship of M2 (2nd part of the MCA) branches to the aneurysm and aneurysmal neck. The neck of the aneurysm may be difficult to visualize. The per-orbital view or submentovertical view may be of value in defining the aneurysm neck and indicating whether the aneurysm projects anteriorly or posteriorly (60).

• *Anterior communication artery (ACoA) aneurysms*

Oblique views usually show the aneurysmal neck in profile. Both A2 segments, and thus the ACoA itself must be visualized. Compression of the contralateral internal carotid artery during ipsilateral carotid injection may

be needed to depict the entire ACoA complex. Besides the projection of the aneurysm, the height of the aneurysm above the tuberculum sellae is important, in that the higher the lesion, the deeper the required retraction and the more likely the need for a ventriculostomy. It is therefore important that a hardcopy image of the aneurysm on an anatomical background (unsubtracted image) in the lateral projection always be taken.

Aneurysms projecting backward are approached from below through the longitudinal fissure, and those projecting forward from above by removing a small area of gyrus rectus. In the majority of the cases this information is provided by the lateral projection but occasionally a modified basal view will be found valuable, especially if the aneurysm is small (3, 33, 60).

- *Pericallosal artery aneurysms*

The lateral projection is the optimal view for such aneurysms, which are often small and project in cranial or craniodorsal direction.

- *Ophthalmic artery (OA) aneurysms*

The OA commonly arises from the superomedial aspect of the internal carotid artery. At angiography OA aneurysms can be classified into four types:

- Those arising from the superior wall of the internal carotid artery and projecting upwards and above the anterior clinoid process.
- Those projecting horizontally and medially from the superomedial internal carotid artery, and if sufficiently large passing under the optic nerve and chiasm.
- Those projecting upwards and medially from the superomedial aspect of the internal carotid artery above the optic tract toward the circle of Willis. This type may produce a suprasellar space-occupying effect, with elevation of the A1 segment of the anterior cerebral artery.
- Those arising from the inferomedial or lateral aspect of the ICA. Aneurysms of this group may be mistaken for a PICA aneurysm.

- *Basilar bifurcation aneurysms*

It is important to assess (in the lateral projection) whether the aneurysm projects anteriorly with the dome of the aneurysm above the dorsum sellae, posteriorly into the interpeduncular cistern or upwards in line with the basilar artery. Anteriorly projecting aneurysms will lie free of any perforating vessels and can be surgically obliterated. Posteriorly projecting aneurysms will be intimately related to small perforating vessels so that direct clipping will be hazardous. Assessment of the height of the basilar bifurcation (in relationship to the dorsum sellae) is important. A high bifurcation may necessitate greater retraction on the temporal lobe, while low bifurcation (base of dorsum sellae or lower down on the clivus) may mean that the tentorial edge hides the base of the aneurysm sac (33).

The standard Towne's projection simplifies the anatomy of the aneurysmal neck. Regardless of the operative approach undertaken, the surgeon cannot see the degree of space between the neck and the P1 segments that the Towne's projection affords. An anteroposterior transfacial view has been extremely helpful in giving a broader perspective of the anterior face of the basilar artery and a somewhat more reliable recognition of the anatomy to be encountered at surgery (3, 60).

Specific details of the aneurysmal neck are not particularly important, but the presence and size of the P1 segments, the presence of multiple superior cerebellar arteries and the configuration of the posterior communicating artery segments are of paramount importance to the neurosurgeon. A dominant PCoA can be a hindrance from an ipsilateral approach. The knowledge that a fetal posterior cerebral artery is present is extremely important because if one is present, division of the PCoA to expand the exposure is impossible.

Allcock's maneuver is accomplished by performing vertebral artery contrast injections during carotid artery compression in the neck. This maneuver can clarify whether posterior communicating vessels are present and is performed when carotid contrast injections fail to opacify the posterior communicating vessels. Having this information at hand preoperatively provides flexibility in dealing with intraoperative difficulties in which a clip placement below the P1 segment may become a life-saving maneuver (3).

- *Posterior inferior cerebellar artery (PICA) aneurysms*

  These aneurysms are often obscured on the lateral projection because of the dense petrous bone. Vertebral oblique projections with use of DSA are ideal to show the relationship of the neck of the aneurysm to the origin of the PICA (60).

- **Angiographic signs of rupture**

  - *Irregularity or loculation of aneurysmal sac*

    Aneurysms nearly always rupture at or near the dome of the sac. Irregularity or loculation of the aneurysmal sac suggests recent rupture. Nehls et al. (20) believe that irregularity of shape is the most important radiographic sign.

  - *Vasospasm*

    Vasospasm is related directly to the presence of blood in the subarachnoid space. It occurs when blood comes into contact with the adventitia of an artery. The subarachnoid clot contains vasospasmogenic substances, which cause arterial narrowing demonstrated at angiography. Spasmogens potentially responsible for cerebral vasospasm include oxyhemoglobin, eicosanoids, bilirubin, endothelin, lipid peroxides, potassium, serotonin and catecholamines. Angiographic vasospasm is seen in 62% of all patients of ruptured aneurysms when angiography is carried out between four and

twelve days after SAH (3). There is no known sex predilection and the incidence does not vary with age. Although angiographic vasospasm is equally common in children, there is evidence that delayed cerebral ischemia develops less frequently.

Diabetes mellitus, atherosclerosis, pre-existing hypertension, or the size and location of the aneurysm do not affect the development of cerebral vasospasm; however, vasospasm does tend to occur near ruptured aneurysms, where the thickes subarachnoid clots are most likely. Vasospasm is an independent, adverse prognostic factor for outcome after aneurysmal SAH.

Vasospasm causing arterial narrowing results in increased vascular resistance, which, if of a sufficient degree, decreases perfusion pressure below the limits of autoregulation and results in reduced cerebral blood flow. This may cause ischemia and, if severe, infarction. In patients with infarction the degree of vessel constriction is usually more than 60%.

Vessel narrowing due to vasospasm must be differentiated from that due to atherosclerosis or an arteritis. Differentiation between vasospasm and a hypoplastic A1 segment is important but is not difficult in most cases. In hypoplasia there is usually a characteristic curvature of the internal carotid artery, and the contralateral A1 segment artery tends to be large.

Spasm involving anterior circulation vessels is much more common than in the vertebrobasilar system. Vasospasm that is localized unilaterally in the internal carotid artery, M1 or A1 segments produce minimal and temporary neurological system deficit unless the vessel diameter is significantly reduced. In contrast, vasospasm involving the M3 segments consistently produce permanent neurological deficits and infarction, probably because the blood flow in the perforating arteries, branching from the spastic arteries, is directly affected and decreased.

- *Focal mass effect*
- *Aneurysm nipples*
- *Changes in aneurysm shape on repeat angiograms suggests rupture*
- *Size of aneurysms*

  In cases of multiple aneurysms it is usually the largest aneurysm that has ruptured (7, 20).

- **Cross compression**

Cross compression has been used during angiography in the following situations:

- *When ligation of the carotid artery is planned*

  The earliest form of therapy for intracavernous aneurysms was carotid ligation. Occasionally in some patients no cross-filling will be seen during this maneuver but carotid ligation is tolerated. This finding may be explained by blood entering the carotid system on the side of compression from the basilar artery via a large PCoA. For this reason many radiologists no longer perform carotid angiography with cross-compression to determine whether a patient will tolerate carotid ligation.

- *When ligation or clipping of the proximal ACA is planned as treatment for an ACoA aneurysm*

  The carotid artery is compressed on the side to be occluded while the opposite carotid is injected. Both ACAs may fill during this maneuver. The filling may include the proximal ACA from the PCoA to the point of planned ligation or clipping. This filling indicates that these vessels will receive blood and that surgery will probably be tolerated.

- *During vertebral angiography*

  If carotid compression is applied on the side to be demonstrated, the entire PCoA artery usually can be opacified.

- **Accuracy of angiography**

The accuracy of the initial angiogram in detecting a bleeding aneurysm varies from investigator to investigator (28, 52, 53, 54), depending on observer error, the use of magnification and subtraction techniques, and whether all four vessels are examined. With modern techniques, one should expect to identify more than 75% of the aneurysms on the first study. Causes of non-visualization of an aneurysm on the first study may be due to vasospasm, a change in the blood flow, narrowing of the neck of the aneurysm, thrombosis of the aneurysm or intracerebral thrombosis (54). The false negative angiography rate of initial angiography is quite variable (1,7 – 17,8%) and this may be explained by variation in imaging standards (53, 61).

A second (repeat) high-quality angiogram will usually discover 5-10% more aneurysms. If spasm was present on the initial negative angiogram then the second repeat angiogram should be performed after the 14th day of bleeding.

Patients with perimesencephalic SAH (seen on CT) are more likely to have a negative pancerebral angiogram. The source of bleeding in these patients is said to be from rupture of fine arterial vessels or microaneurysms or venous or capillary bleeding. Some authors have suggested that repeat angiography need not be performed in these patients. Considering the very low risk (0,1%) of a severe complication with permanent neurological deficit after cerebral angiography and the high risk (30-40%) of rehemorrhage of an aneurysm in the first 6 months after the initial rupture, many authors recommend (52, 61) a repeat angiogram in all other cases of negative initial angiography with

spontaneous SAH. Therefore the only situation, that does not require a repeat angiogram, is the perimesencephalic hemorrhage where the centre of bleeding is clearly defined immediately anterior to the midbrain (61).

- **Which vessel angiogram should be done first?**

If CT identifies a generalized or non-specific type pattern of SAH, then the first angiographic run performed should be on the non-dominant side of the patient. This is because should the patient have a severe complication with permanent neurological deficit due to the angiography, the patient's morbidity would be less compared with the deficits occurring in his or her dominant side.

If clinical examination or CT scanning can localize the probable site of the aneurysm then these should dictate which artery should be catheterized first. There are several advantages to performing the angiogram first in the artery "closest to the aneurysm".

- If there is severe spasm of the cerebral vessels on the first angiographic run, at least a "peek" at the aneurysm will have been obtained prior to terminating the study.
- If there is technical malfunction of the equipment during or after the first run, again a peek will have been obtained.
- Similarly, if the patient has an allergic reaction and the procedure needs to be abandoned, then at least a peek at the aneurysm will have been obtained.

12. INTRAOPERATIVE DSA

The goal of aneurysm surgery is to obliterate the lumen of the aneurysm without occluding the parent or branch vessels. The incidence of incomplete obliteration is not known. Residual aneurysms have been shown to enlarge and hemorrhage. Branch vessel occlusion by an aneurysm clip also may complicate aneurysm surgery. Intraoperative angiography has shown residual aneurysms, branch vessel occlusion and unsuspected aneurysms. Despite limitations inherent in the technique, information gained through an intraoperative study can lead to modifications at the time of initial operation that prevent complications or obviate the need for a second operation (58).

13. DIGITAL SUBTRACTION ROTATIONAL ANGIOGRAPHY FOR ANEURYSMS OF THE ANTERIOR CIRCULATION

Conventional intra-arterial DSA of aneurysms of the internal carotid artery circulation is inherently limited by the representation of complex three-dimensional anatomy in a two-dimensional medium. Digital subtraction rotational angiography (DSRA) provides a close approximation of the three-dimensional relationship surrounding vascular anatomy in a single injection.

The rotational technique was proposed in 1972 by Cornelius et al. (63), and Thron and Voigt reported its clinical use in 1983. DSRA enables vascular images to be acquired in a continuous arc. Each vascular territory requires 2 rotational runs; first a rotational mask without injection, followed by a second rotational run with contrast material.

X-ray delays are important in rotational angiography. To achieve arterial delay at the initiation of gantry movement and maximum arterial opacification throughout a 6-second exposure, the arrival of contrast material should be synchronous with initial gantry movement. A lengthy x-ray delay results in early termination of the injection with concomitant superimposition of venous obscuration (62).

Technical problems may result from incorrect ch e of x-ray delay time, insufficient memory space, or a small field of view (FOV) of the rotational angiography run. A large FOV decreases resolution. Subject problems include motion and overlying tubes and lines that may collide with the rotating C-arm. Patient motion causes loss of subtraction and small vascular detail. Rotational angiography can provide better definition of the aneurysmal neck and greater clarity of the aneurysm than conventional DSA.

14. MAGNETIC RESONANCE IMAGING (MRI) AND MAGNETIC RESONANCE ANGIOGRAPHY (MRA)

While CT scan remain the radiologic procedure of choice for detecting SAH and transfemoral catheter cerebral angiography is still the gold standard for identifying cerebral aneurysms, MRI and MRA have become very useful in diagnosing and treating intracranial aneurysms. MRI scans do not consistently identify fresh SAH due to the relatively high PO_2 in the CSF which prevents the formation of paramagnetic deoxyhemoglobin (3, 14, 28). Further, it is difficult to manage acutely sick patients within the environment of the MRI suite. MRI and MRA are excellent screening procedures to detect and characterize unruptured aneurysms.

Retrospectively aneurysms as small as 3mm have been identified in high-quality MRA studies (26, 27, 31, 64), and prospectively 5mm aneurysms have been identified. The sensitivities of MRA studies have varied from 73 to 95% depending on the sequences performed and computer programs used.

MRI studies are extremely helpful in quantifying the extent of the cerebral ischemia that accompanies arterial vasospasm due to SAH. In the postoperative period, MRI studies clearly demonstrate postoperative complications such as small areas of ischemia or extra-axial fluid collections, as well as demonstrating the effectiveness of balloon occlusion techniques.

With the emergence of commercially available software and hardware, the field of MRA is the subject of increasingly widespread interest in the radiologic community. Unfortunately, MRA is a complex subject both from a fundamental physics and a clinical application point of view.

14.1 What is MR Angiography?

MRA is a term used to describe a class of MR imaging techniques designed to create angiographic images without the use of ionizing radiation, contrast media or invasive techniques.

The two fundamental MR acquisition techniques expressly used in MRA is time of flight (TOF) (also known as inflow and flow related enhancement) and phase contrast angiography (PCA). These two methods are fundamentally different. TOF is based on the difference in signal intensity between static tissue and flowing blood. PCA is based on the fact that flowing blood will interact with a special type of magnetic gradient. In most clinical practices TOF is used rather than PCA because PCA is dependent on the radiologist selecting the correct flow velocity of the blood in a particular artery. The problem associated with using an incorrect velocity encoding value is that aneurysms can be missed (65). Because the physics behind the implementation of PCA is more complex than TOF and the demands on system performance are much greater, the PCA method is not offered by as many MR imaging manufacturers.

Helical CT and MRA (using 3-D TOF or PCA) generally are equivalent in their ability to delineate the location, contour and neck of intracranial aneurysms greater than 3mm in size (66, 67).

14.2 MRA Applications

- General screening for aneurysms
- Screening selective patients such as those with autosomal dominant polycystic kidney disease, fibromuscular dysplasia, coarctation of the aorta, Ehlers-Danlos syndrome etc.
- Evaluating aneurysm hemodynamics and flow characteristics
- Evaluating cerebral vasculature following aneurysms treated with endovascular techniques
- Monitoring mycotic aneurysms during antibiotic therapy
- Detecting aneurysms not seen on conventional angiograms in patient with non-traumatic SAH (68)

It takes nearly 12-20 minutes of examination time to perform conventional MRA. Therefore high quality MRA for the proper evaluation of the entire brain requires not only a short scan time but also submillimeter resolution. An important criticism of MRA is the inability of the technique to replicate the temporal resolution of conventional angiography during the arterial, venous and capillary phases. MRA may outperform helical CT in demonstrating aneurysms from the intracavernous or supraclinoid carotid artery (21), and is also better suited for evaluation of aneurysms at the skull base. MRA shares with helical CT the advantage of multiplanar imaging.

14.3 Limitations of PCA (65)

- Image reconstruction time of PCA sequences is much longer than TOF
- The choice of a reliable velocity sensitivity for every MR angiography study can be problematic
- The phase-sensitive nature of the PCA sequence is subject to errors and artifacts from system eddy currents as well as magnetic susceptibility effects and gross patient motion

14.4 Limitations of TOF (65)

TOF images suffer from problems with saturation of tortuous and slow flow and sometimes poor background suppression, which degrades vessel conspicuity. Poor background suppression is especially apparent in the presence of short T1 species such as gadolinium-enhancing lesions, fat and methmoglobin.

14.5 Advantages of MRA compared to DSA

- The non-invasiveness of MRA makes it better suited as a screening modality
- MRA is a faster modality
- MRA has an infinite number of possible projections and with the aid of targeted MIP it may be possible to resolve the aneurysm and the adjacent vessels and to demonstrate its relationship to the parent vessel
- No contrast reactions as no contrast media is used

STUDY METHODS

STUDY METHODS

The initial (first) cerebral angiographic examination of 126 consecutive unselected patients suspected of having cerebral aneurysms were retrospectively reviewed. The suspicion of the patient harboring an aneurysm was based on clinical examination and/or LP findings and/or CT scan findings.

STUDY POPULATION

From January to November 1998, 126 patients underwent cerebral angiography for suspected cerebral aneurysms. The angiographic examinations were performed at the two hospitals that have a functioning neurosurgical service i.e. Johannesburg General and Chris Hani Baragwanath Hospitals (CHBH). Between the two hospitals the 126 angiograms were studied as a single group. The x-rays were obtained from the neurosurgical and /or the X-ray department records.

Patients admitted to either of these hospitals having had their angiographic examination done elsewhere were not included in this study.

Cerebral angiography was performed by using the transfemoral Seldinger technique. Standard Towne's, lateral and 2 oblique views were obtained for evaluation of the anterior circulation and a Towne's and lateral view was obtained to evaluate the posterior circulation. Additional projections were obtained when deemed necessary.

The angiograms were performed using the Siemens Angiostar Polytron 1000. This digital subtraction unit consists of a C-arm fluoroscope, a digital image processor and storage unit, and a video monitor (TV-imaging chain). Images were printed on film by means of a laser printer (Konica LI 10A). Angiograms in the arterial, capillary and venous phases were assessed.

Two consultants; one neurosurgeon and one diagnostic radiologist (the author of this dissertation) viewed the angiographic studies. This assessment of the angiograms was performed initially by the author with the assistance of Dr V Goolab (the neurosurgery consultant). After discussing the angiographic findings the results were recorded as one on the prepared patient data sheets. In two instances significantly different results were recorded by the 2 readers; in these cases the decision of the more experienced and more senior neurosurgery consultant was recorded. In a separate instance neither of the two consultants were sure, in this case the findings at surgery were recorded.

When reports of the angiograms were present these findings were compared to those of the 2 readers. Significant differences between the two reports were recorded in the "comments" section of the patient's data sheet.

DATA COLLECTION AND PROCESSING

The patient's biographical data (age, sex, and race) was obtained from the x-ray request form and when these request forms were incompletely filled out, the ward clerk furnished the remaining data.

The angiographic findings were recorded on the patient data sheet. Aneurysm site, number and sidedness (right or left) were recorded. The presence or absence of vasospasm was also documented. The sequence in which the cerebral vessels were catheterized was noted. Specific additional features of the study group was also tabulated, viz., anatomical anomalies. Other pathologies if present were documented in the comments section.

In this descriptive study survey, statistics consist of frequencies and percentages, both in the univariate as well as in the high order tables. These frequencies, percentages and higher order tables were derived from the observed data (patient data sheets) using the analytical software " Statistix for Windows".

RESULTS

RESULTS

AGE DISTRIBUTION

Of the 126 patients, 75 (60%) patients with a total of 93 aneurysms were identified. Thirty-three men (44%) and 42 women (56%) were found to harbor aneurysms. Of the 75 patients with aneurysms, 63 cases (84%) had a single aneurysm and 12 cases (16%) had multiple aneurysms.

Other pathologies identified were 3 AVMs (1 case had an AVM and an aneurysm), and 1 vertebrobasilar thrombosis. Due to perceptual errors by the various angiographers a total of 8 aneurysms in 7 patients were missed. One angiographer misinterpreted a vascular loop as an aneurysm (1 false positive result).

Table A1 Frequency distribution of sample population

Age (yrs)	Frequency	Percent
0-20	10	7.9
21-30	19	15.1
31-40	34	27
41-50	36	28.6
51-60	20	15.9
> 60	7	5.6
Total	**126**	**100**

Table A2 Cross tabulation of Age by Angiogram Outcome

Age (yrs)	No Aneurysm	One Aneurysm	≥ Two Aneurysm	Total
0-20	5	5	0	10
21-30	6	12	1	19
31-40	13	17	4	34
41-50	16	14	6	36
51-60	7	12	1	20
> 60	4	3	0	7
Total %	**51 (40.5%)**	**63 (50%)**	**12 (19.5%)**	**126 (100%)**

Table A3 Overall Descriptive Statistics

Variable	Number of cases (%)		Mean Age (yrs)
Study population	*126*	*(100%)*	*40.3*
Female cases	67	(53%)	42.4
Male cases	59	(47%)	38.2
Cases with aneurysms	*75*	*(100%)*	*39.9*
Females with aneurysms	42	(56%)	42.8
Males with aneurysms	33	(44%)	36.2
Cases with single aneurysms	*63*	*(100%)*	*39.4*
Females with single aneurysms	32	(51.8%)	42.7
Males with single aneurysms	31	(49.2%)	36.1
Cases with multiple aneurysms	*12*	*(100%)*	*42.1*
Females with multiple aneurysms	10	(83.3%)	43.3
Males with multiple aneurysms	2	(16.7%)	36

The sample population consisted of 126 patients. The mean age was 40,3 years (range 8-73). Patients with aneurysms in childhood and adolescence (defined in this study as patients less than 20 years of age) accounted for 6,7% of patients with aneurysms. The mean age in this group was 15 years (range 11-20).

HISTOGRAM OF THE 75 PATIENTS WITH ANEURYSMS

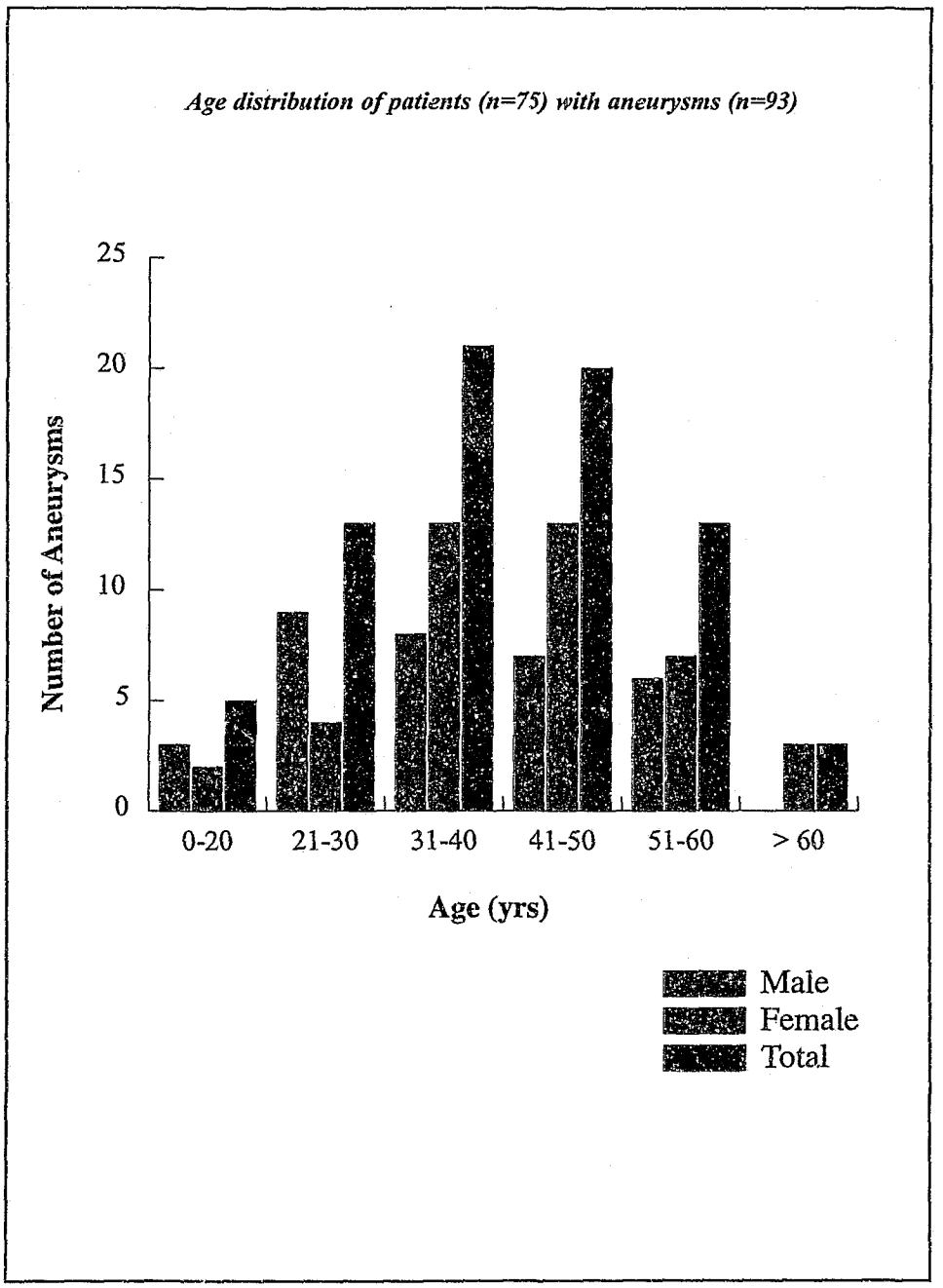

HISTOGRAM OF THE 63 PATIENTS WITH A SINGLE ANEURYSM

Approximately 60% of the study population had aneurysms (Group 1) and the remainder 40% had no aneurysms (Group 2). The mean age in Group 1 was 39,9 years. Group 1 males presented 6,6 years earlier than Group 1 females.

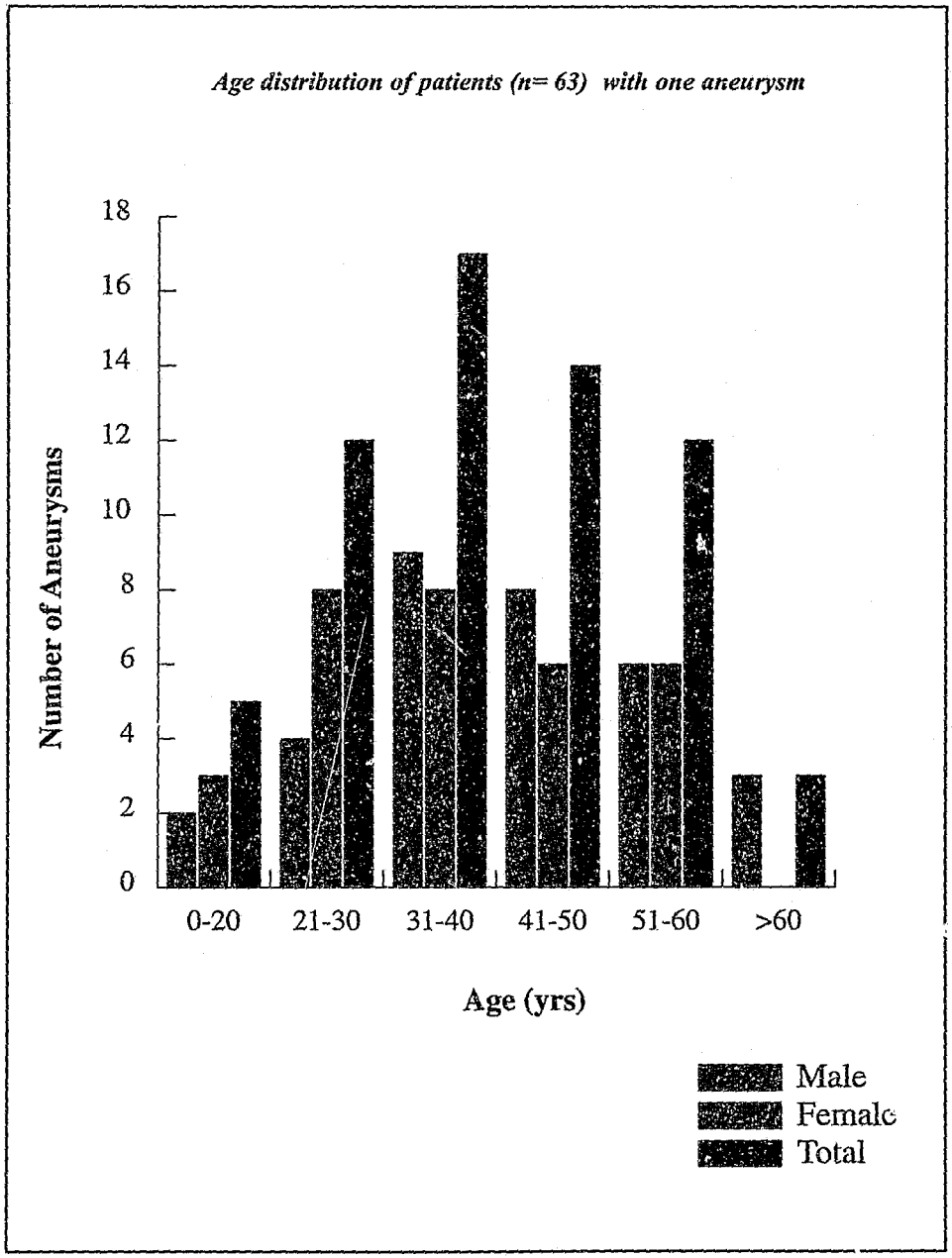

RACE

The study population comprised of 87% Black (n=109), 8% White (n=10), 4% Colored (n=5) and 1,5% Indian (n=2) of patients.

HISTOGRAM SHOWING THE RACE DISTRIBUTION OF PATIENTS WITH ANEURYSMS

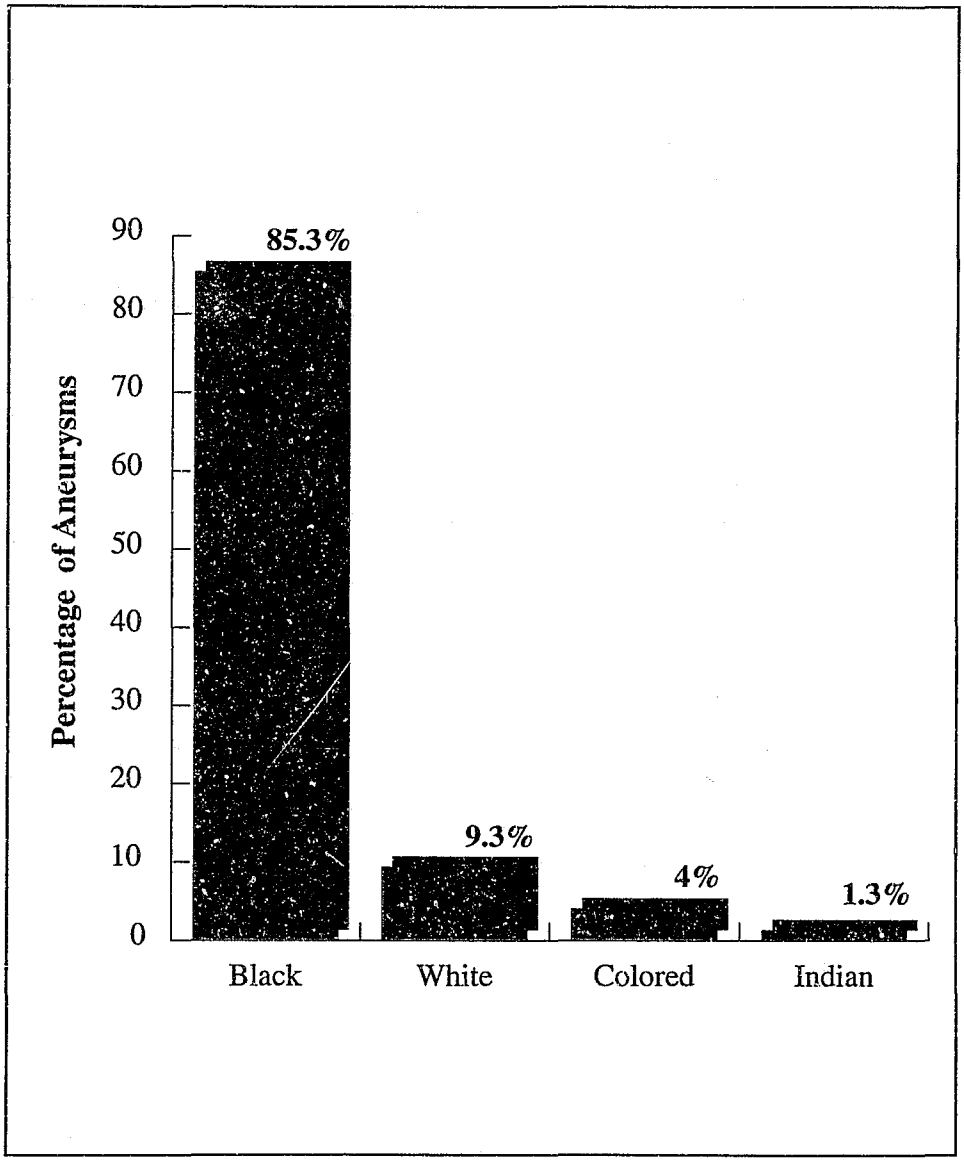

DOUGHNUT GRAPH SHOWING THE PERCENTAGES OF SINGLE ANEURYSMS (SUBDIVIDED BY RACE) AND MULTIPLE ANEURYSMS

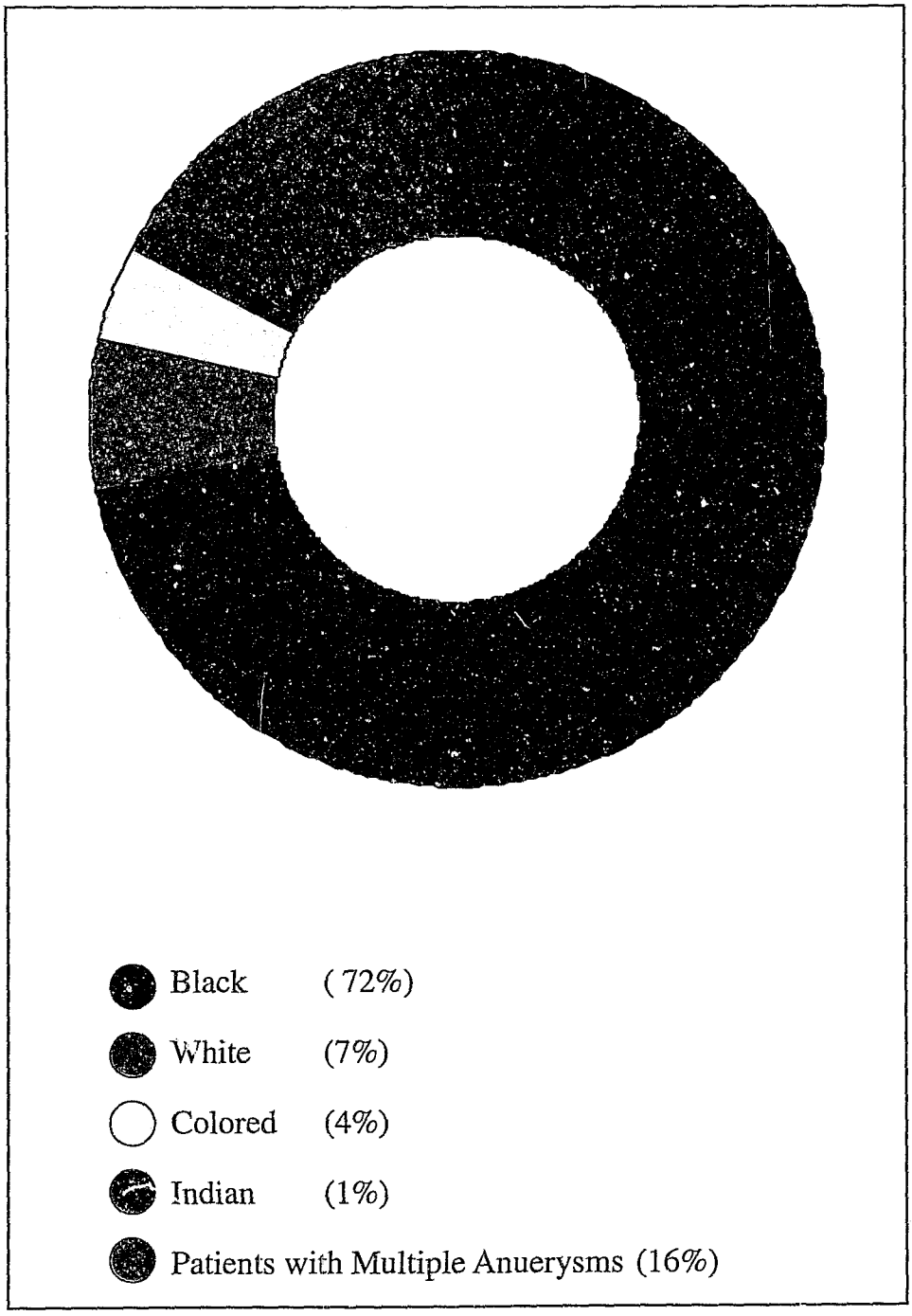

MULTIPLICITY

Of the Group 1 patients, 16% (n=12) had multiple aneurysms. Of these 12 cases, 10 (83.3%) were women and 2 (16,7%) were male.

HISTOGRAM OF THE 12 PATIENTS WITH MULTIPLE ANEURYSMS

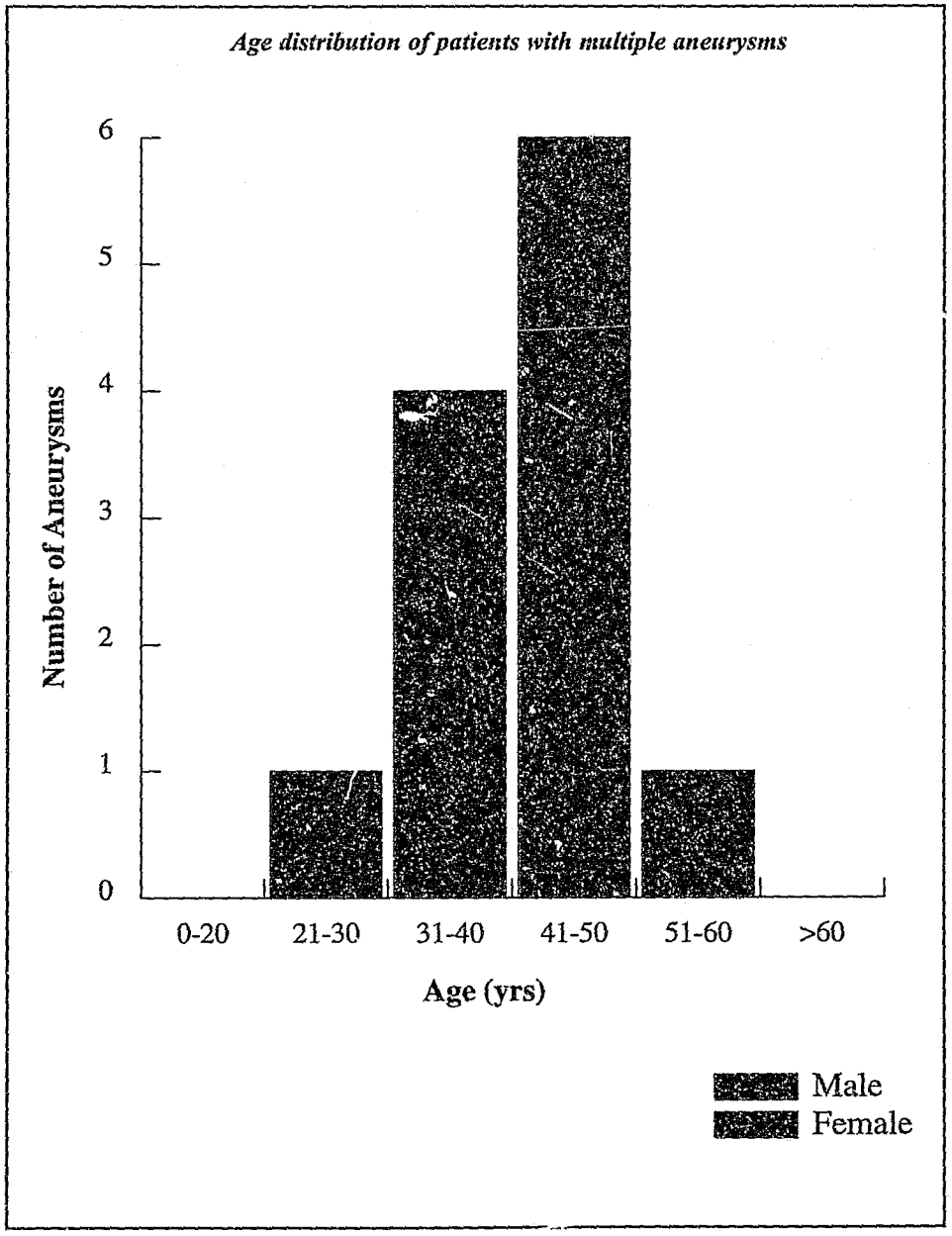

Eighty-three (10/12) percent of the multiple aneurysms occurred in patients in the age group 31-50 years. Eight patients had 2 aneurysms, 3 patients had 3 aneurysms and 1 patient had 5 aneurysms. The number of cases with one, two, and more than 2 aneurysms by sex and age is given in table M1 (below). Among the 75 patients, more than one aneurysm was present in 16% (n=12), 11% (n=8) had 2 aneurysms and 5% (n=4) had more than 2 aneurysms.

Of the 12 patients with multiple aneurysms, only 16,7% (n=2) had aneurysms in both the anterior and posterior circulations.

Table M1 Cross tabulation of aneurysm number with age categories

	One Aneurysm		Two Aneurysms		≥ Two Aneurysms	
	Male	Female	Male	Female	Male	Female
No. of cases	31	32	1	7	1	3
Age (yrs)						
<20	3	2	0	0	0	0
21-30	8	4	0	0	1	0
31-40	8	9	0	3	0	1
41-50	6	8	1	3	0	2
51-60	6	6	0	1	0	0
>60	0	3	0	0	0	0

Table M2 Multiplicity and side of aneurysms

Patients with aneurysms	Number (%)
Right and left side only	8 (66,7)
Right side only	1 (8,3)
Left side only	1 (8.3)
Right, left and midline	1 (8,3)
Right and midline only	1 (8,3)
Anterior circulation only	10 (83,3)
Anterior and Posterior circulation	2 (16.7%)

Table M3

Cross tabulation of race by gender controlling for single and multiple aneurysms

RACE	SINGLE ANEURYSM		MULTIPLE ANEURYSMS	
	Female	Male	Female	Male
Black	25	29	9	1
White	4	1	1	1
Indian	0	1	0	0
Colored	3	0	0	0
Total	32	31	10	2

Although single aneurysm cases were approximately equal in frequency in males and females (31 and 32 cases respectively), double aneurysm cases were more than 6 times as frequent in females (1 versus 7), and cases with more than 2 aneurysms 3 times as frequent in females (1 versus 3).

ANEURYSMS OF CHILDHOOD AND ADOLESCENCE

In this series this was defined as aneurysms occurring in patients less than and including 20 years of age. Ten patients (8%) underwent angiography for suspected aneurysms. Five cases were found to have aneurysms. This represented 6,7% of all patients (75 cases) with aneurysms. Among the 5 patients there was a preponderance of males in this series, the male-female ratio being 1,5:1. The mean age in this positive group of patients was 15 years (range 11-20 years). None of the 5 cases had multiple aneurysms. Anterior circulation aneurysms were 4 times as frequent than posterior circulation aneurysms.

Table L1 Location of Aneurysms (5 cases of single aneurysms)

Site	# of aneurysms
Right PICA	1
Right ICA	3
ACoA	1

All 5 aneurysms occurred in the second decade. Sixty percent (60%) of these were right ICA aneurysms. This contrasts strikingly with the adult population, where only 8% of ICA aneurysms were right sided.

HISTOGRAM SHOWING RIGHT ICA ANEURYSMS AS A PERCENTAGE OF THE TOTAL ANEURYSMS IN EACH GROUP

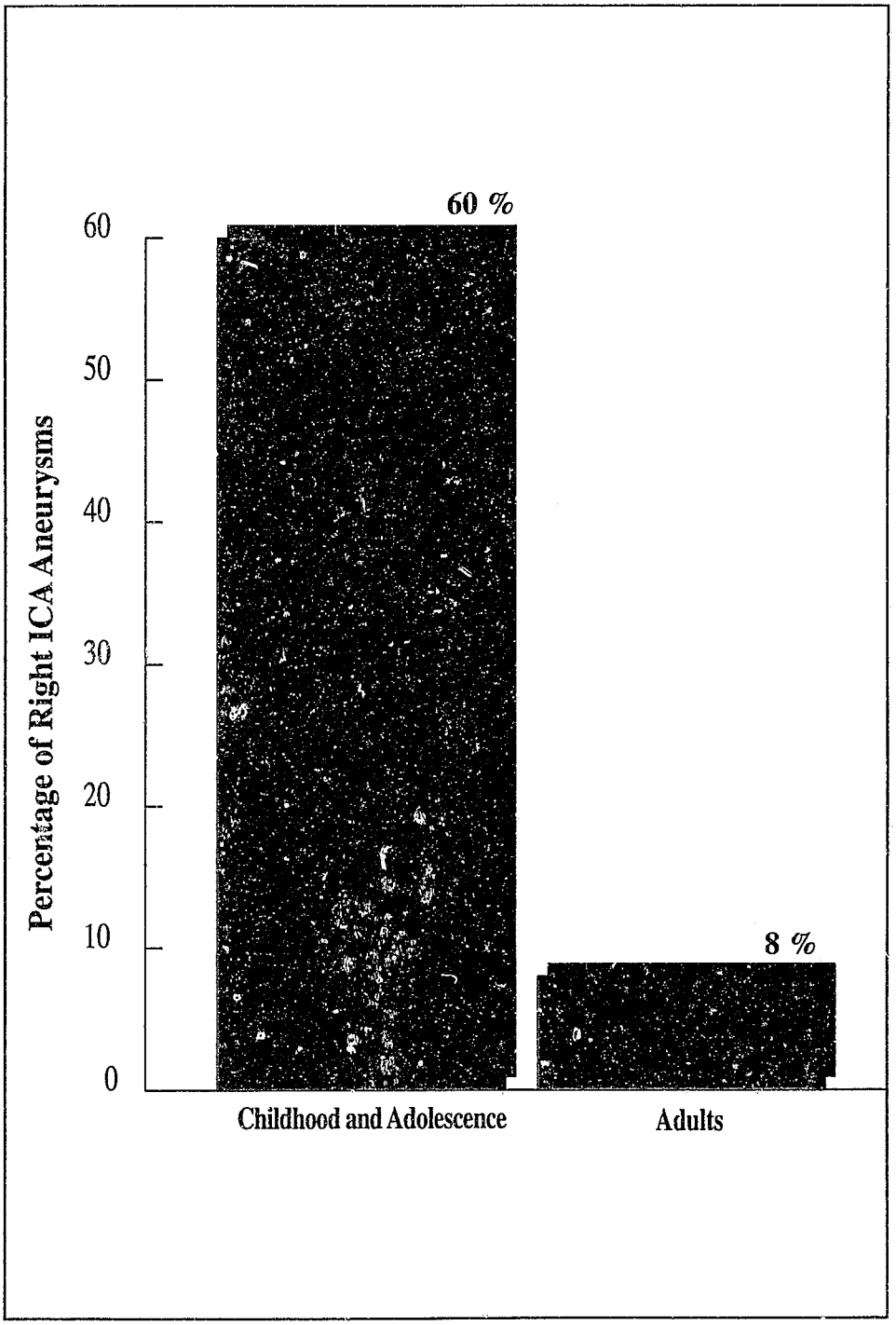

SITES OF ANEURYSMS

Table S1 Site distribution and sex ratio of patients with aneurysms

	Anterior Circulation						Posterior Circulation			
Factor	**Ophthalmic**	**MCA**	**ACoA**	**ICA**	**ACA**	**PCoA**	**Basilar**	**AICA**	**PICA**	**Superior Cerebellar**
93 aneurysms (%)	3 (3.2)	22 (23.6)	15 (16.1)	16 (17.2)	11 (11.8)	19 (20.4)	3 (3.2)	1 (1.1)	2 (2.1)	1 (1.1)
Sex ratio (M:F)	2:1	1:2	2:1	1:1.5	1:2.7	1:1.14	3 female	1 female	1:1	1 female
right: Left (# R: # L)	1:2 (1:2)	1.2:1(12:10)	midline	1.6: 1 (10:6)	1.28 (3:8)	1:1.38 (8:11)	midline	(0:1)	(2:0)	(0:1)
Age (yrs)										
0-20	0	0	1	3	0	0	0	0	1	0
21-30	1	5	2	1	0	6	0	0	0	0
31-40	2	4	0	5	5	7	1	0	1	1
41-50	0	11	5	4	3	5	1	1	0	0
51-60	0	1	6	2	3	1	1	0	0	0
>60	0	1	1	1	0	0	0	0	0	0

A total of 93 aneurysms were found in 75 patients. Overall 36 aneurysms were on the right, 39 on the left and 18 in the midline. In adults (age 21 and above) left sided aneurysms were 1,2 times as frequent than their right counterparts. In striking contrast to this no left-sided aneurysms were present in childhood and adolescence.

Table S2 Frequency distribution of right: left: midline aneurysms

	Number of Aneurysms		
	Right	**Left**	**Midline**
Childhood and Adolescence	4	0	1
Adults	32	39	17

Of the 93 aneurysms, 86 (92,5%) were located in the anterior circulation and 7 (7,5%) in the posterior circulation. In decreasing order of frequency the most common location of aneurysms was the MCA (23,6%), the PCoA (20,4%), the ICA (17,2 %), the ACoA (16,1%) and the ACA (11,8%). As a group the anterior cerebral artery complex (ACA and ACoA) was the most frequent site (27,9%).

MCA and ICA aneurysms were more frequent on the right side whereas ACA and PCoA aneurysms were common on the left side. Ophthalmic artery aneurysms were twice as frequent on the left side.

VASOSPASM

Angiographic vasospasm was divided into focal (2 or less vessels involved) or generalized (3 or more vessels involved). None of the patients had generalized spasm.

Table V1 Cross tabulation of Vasospasm by Aneurysm Outcome

	Present	Absent	Total Cases
Number of cases	52	74	126
Cases with aneurysms	32	43	75
Females	15	27	42
Males	17	16	33
Cases without aneurysms	20	31	51
Females	12	13	25
Males	8	18	26

Forty-one percent (n=52) of the sample population had angiographic focal spasm. Within this group of patients the highest frequency (54%) of vasospasm was found in the age group 31-50 years. Of the 75 patients that had aneurysms 43% (n=32) had vessel spasm. Here too the highest frequency of spasm (55%) was found in the age group 31-50 years. Of the 51 cases with aneurysm negative angiograms 39% (n=20) had focal vasospasm. An almost equal frequency of vasospasm was seen in male and female patients with aneurysms (15 and 17 cases respectively). However in aneurysm negative cases (n=51) females with vasospasm outnumbered males by 50%.

Table V2 Cross tabulation of Race by Gender, controlling for aneurysm positive angiograms and focal spasm.

Race	Gender	
	Female	Male
Black	10	15
White	2	1
Indian	0	1
Colored	3	0

Of the 20 patients that had focal spasm but no aneurysms 85% (17 cases) were black and 15% (3 cases) were white.

VESSEL CATHETERIZATIONS

A total of 389 vessels were catheterized. Sixty-four right verterbrals (RV), 87 left vertebrals (LV), 117 left internal carotid arteries (ICA) and 121 right ICAs. The LV was 1,36 times more frequently catheterized than the RV.

Five patients had no angiography of the vertebrobasilar system (4 patients with bilateral carotid and 1 patient with unilateral carotid angiography). Four patients had unilateral carotid and unilateral vertebral angiography. One patient had unilateral carotid and bilateral vertebral angiography.

ANATOMICAL ANOMALIES

Four patients had hypoplastic A1 segments. One patient had the rare normal variant in which the right subclavian, right common carotid, left common carotid, and left subclavian artery arose (in this sequential order) directly off the aortic arch.

GUGLIELMI DETACHABLE COILS (GDCs) AND ANEURYSMS

The endovascular treatment of intracranial aneurysms has evolved rapidly since the 1970s when latex balloon embolization was used. The focus of modern endovascular therapy has shifted to the use of retrievable platinum coils called Guglielmi Detachable Coils (GDCs).

The introduction of Guglielmi Detachable Coils has revolutionized the endovascular treatment of intracranial aneurysms and is rapidly gaining popularity as an alternate form of treatment compared to direct neurosurgical clipping of the aneurysm. GDCs have led to controversies with regards to the ideal first line management of the aneurysm. In North America many physicians consider surgical clipping to be the treatment of choice. Conversely in Europe, many physicians consider the endovascular approach with coil packing to be the ideal treatment of choice, reserving surgical clipping for when coiling has failed or those that are incompletely occluded after coiling.

The third approach (currently this method is favored), is using aneurysm location and geometry to help decide if surgical clipping or endovascular treatment would be the ideal management. Aneurysms ideal for endovascular treatment are those with a dome-to- neck ratio of at least 2 and with an absolute neck diameter of less that 5mm. These aneurysms correlate with higher complete occlusion rates and improved clinical outcome.

The geometry of wide neck aneurysms is less favorable for coil retention within the aneurysm lumen, resulting in greater risk of parent vessel flow compromise from coil herniation and difficulty in obtaining maximum coil packing. Aneurysm location unfavorable for endovascular coiling include MCA trifurcation (because branching vessels obscure the neck of the aneurysm) and ACoA (because the geometry is difficult to assess on the diagnostic angiogram).

Generally, anterior circulation aneurysms are more easily accessible by direct surgery and posterior circulation aneurysms more suited to endovascular coiling.

CASES

CASE # 4 IMAGE 1

LEFT ICA LATERAL VIEW



Fifty year old known hypertensive woman was admitted to the medical ward confused and drowsy. Her GCS was 10/15. Unenhanced CT of her brain revealed a diffuse subarachnoid hemorrhage. Two aneurysms were identified on the cerebral angiogram done on the second day of admission. Both these aneurysms were missed.

A right MCA aneurysm and the ruptured posterior communicating artery aneurysm (see above image) were present. Her medical treatment consisted of Nimotop, epanutin and moduretic. The posterior communicating artery aneurysm was clipped via a left frontotemporal craniotomy. Patient died 16 days after admission.

CASE # 12 IMAGE 2

PICA ANEURYSM



This 39 year old housewife was admitted to hospital complaining of a sudden severe headache followed by collapse and decreased level of consciousness. She was hypertensive with an admission blood pressure reading of 210/120. A grade 1 hypertensive retinopathy was present. Her GCS was 7/15. She had severe meningism and kernigism. CT scan showed extensive subarachnoid hemorrhage around the basal and chiasmatic cistern. Blood was also present in the 4th ventrical.

She was a Grade 4 Hunt and Hess SAH. On day 2 her GCS improved to 10/15. The angiogram showed a right PICA aneurysm pointing medially. No vasospasm was present and she was taken to theatre the same day (day 2). The posterior fossa was opened via a retromastoid approach. The cerebellar hemisphere was grossly swollen and it was impossible to approach the aneurysm. The lateral third of the cerebellar hemisphere was resected to permit closure.

Her clinical condition deteriorated postoperatively and she was declared brain dead 6 days after admission.

CASE # 16 IMAGE 3A

MCA ANEURYSM

Twenty-two year old male was referred from a peripheral hospital complaining of left-sided weakness for 3 months. CT scan showed a right frontoparietal bleed. Neurological examination revealed bilateral papilledema, a left upper motor neuron paresis of the facial nerve and he had a GCS of 15.



A right MCA aneurysm was identified on angiography. Image 3 shows a saccular MCA aneurysm with no vessel spasm. The anterior cerebral artery is not opacified. Both posterior cerebral arteries are opacified via the right posterior communicating artery. The patient wanted to discuss the neurosurgical intervention with his family prior to signing the consent form. He was discharged from hospital and lost to neurosurgical outpatient follow up.

CASE # 16 IMAGE 3B

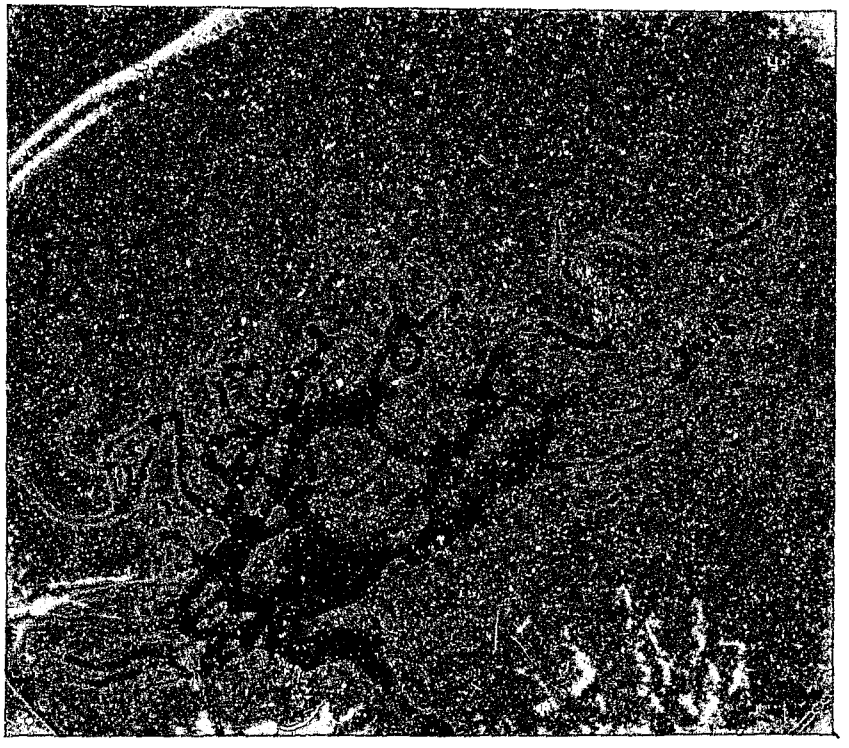

CASE # 20 IMAGE 4

PROXIMAL M1-SEGMENT ANEURYSM

The left CCA angiogram demonstrates a proximal M1 segment aneurysm and a pericallosal aneurysm. The pericallosal aneurysm is lobulated indicating rupture. This normotensive patient was admitted complaining of a severe headache. Her CT scan showed subarachnoid blood limited to the basal cisterns.



Via the transfemoral route the right CCA and left vertebral arteries were easily catheterized but the left CCA was difficult to catheterize due to tortuosity. This 2-vessel angiographic study demonstrated 3 aneurysms (right MCA, left AICA and basilar tip). After studying the CT scan and the 2-vessel angiogram, the neurosurgeons felt that the distribution of

subarachnoid blood was atypical for the site of the aneurysms demonstrated and they therefore requested a left carotid angiogram. Direct puncture of the left CCA was performed revealing a further 2 aneurysms. In total 5 aneurysms were identified.

The 43-year-old woman was a Grade 1 Hunt and Hess SAH. Her GCS was 15. She refused hospital treatment and left 38 days after admission with no neurological deficits.

CASE # 27 IMAGE 5

LEFT VERTEBRAL ANGIOGRAM

This 69-year-old patient presented to medical casualty complaining of headache, slurred speech and neck pain. Five days prior to her admission she gave a history of her legs suddenly giving way and subsequently falling on her forehead. On examination her GCS was 15 and she had a partial abducens nerve paresis on the left. Further neurological examination revealed left-sided dysmetria and disdiadochokinesia. Unenhanced axial CT scan of the brain demonstrated an acute left cerebellar hemisphere hematoma.



The 4-vessel angiogram was negative for aneurysms. The left vertebral run shown in the image demonstrates an irregular and narrowed artery. These features are those of a vasculopathy. The cerebellar hematoma was evacuated 16 days after admission. A biopsy of the hematoma wall was sent for histology. Patient made a good postoperative recovery and was without neurological deficit.

Highly atypical malignant cells were seen under microscopy. Immunohistochemistry staining with MNF116 was strongly positive within the tumor cells. S100 staining was negative within the tumor cells. The differential diagnosis considered was Glioblastoma multiforme and hemorrhagic metastasis. The patient was subsequently lost to outpatient follow up.

CASE # 51 IMAGE 6

RIGHT INFUNDIBULUM

Image of the late arterial phase of the right ICA showing an infundibulum at the junction of the ICA and PCoA. The infundibulum has a typical funnel shape and has an artery coming of the apex.

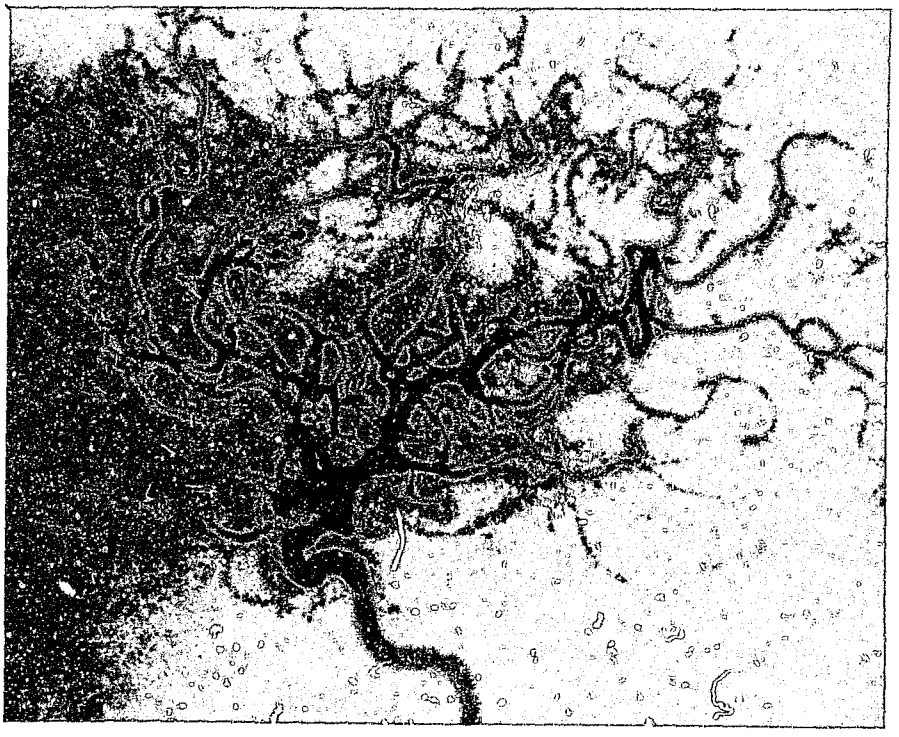

CASE # 59 IMAGE 7

PCoA ANEURYSM

A 43-year-old male was admitted to the medical ward complaining of a headache. He had a left ptosis and a third nerve palsy. Computed tomography showed a low density lesion in the left basal ganglia and a SAH. The clinical suspicion of the presence of a left PCoA was confirmed on angiography (see image below).



No vasospasm or vessel displacement is present. The aneurysm projects inferiorly and medially impinging on the oculomotor nerve causing third nerve paresis. The PCoA aneurysm was clipped following a craniotomy. Patient died 21 days after admission.

CASE # 110 IMAGE 8

RIGHT PCOA ANEURYSM AND AN AVM

Thirty-nine year old female was admitted to the hospital with a CT confirmed SAH.

The right ICA angiogram shows a lobulated (ruptured) PCoA aneurysm and a right posterior parietal AVM that is fed by the parietal branches of the MCA and the right posterior cerebral artery.

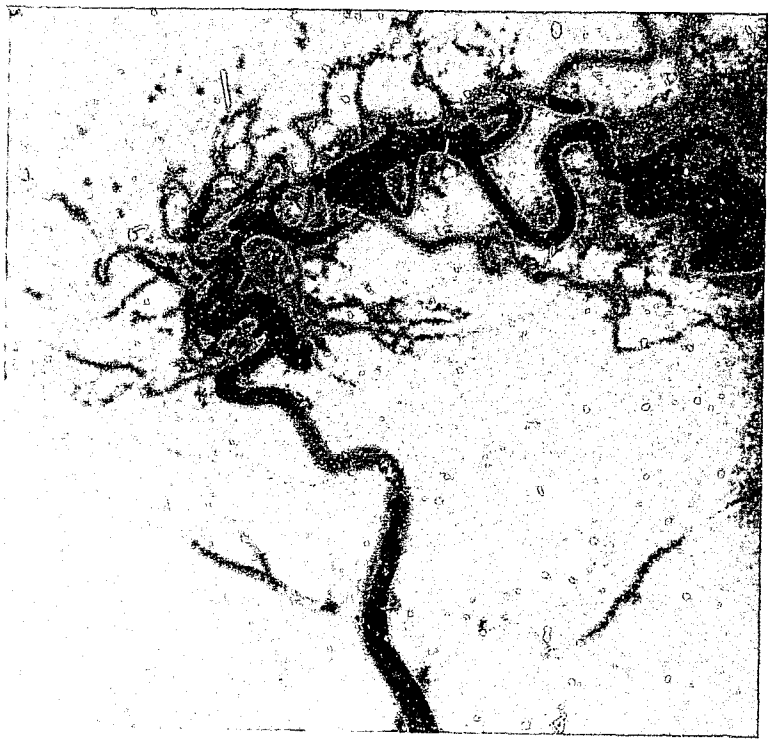

DISCUSSION

The initial cerebral angiographic studies of 126 consecutive unselected patients suspected of having cerebral aneurysms were retrospectively reviewed. The suspicion of the patient harboring an aneurysm was based on history and clinical examination and/or LP findings and/or CT scan findings. The study population was therefore a highly selective one and this is a bias of this study. Incidental aneurysms detected by angiography done for other indications (e.g. cerebral tumors) were not included in the sample population.

The major findings in our study were (a) earlier age presentation of both black and white patients with aneurysms; (b) higher frequency of aneurysms in males in the first three decades of life; (c) overall higher frequency of aneurysms in females; (d) females are more likely to have multiple aneurysms; (e) a probable propensity of aneurysms in childhood and adolescence to be located on the right ICA and (f) commonest site of aneurysm location was the MCA..

These major findings are elaborated on below under the following headings: age and race distribution, gender differences, multiple aneurysms, site and gender related site differences, aneurysms in the first two decades of life and aneurysm negative angiograms and importance of cerebral panangiography.

Age and race distribution

Various studies have reported that about 60% of aneurysms occur in patients in the fifth and sixth decades. Patients in our series were somewhat younger, with almost 79% of the patients less than 51 years of age. Most of the patients with aneurysms were in the age group 31-40 years (28%) and almost 55% of the aneurysms occurred in the age group 31-50 years i.e. third and fourth decades. These findings contrast with the observations of Andrews and Spiegel (7) whose peak incidence (51%) was shown between 40-60 years, and Kongable et al's whose peak incidence was between 46 and 60 years. Inagawa et al's study of aneurysmal SAH in Izumo City, Japan also showed a peak age distribution between 40-60 years (73).

In Kongable's recent paper (1996) (906 patients with aneurysmal SAH) the mean age for men was 47,3 years and women was 51,4 years (10). This contrasts sharply with the mean ages of men (36,2 years), women (42,8 years) and the overall mean of 39,9 years in our smaller series of patients with aneurysms. This earlier age presentation difference is again borne out by comparing the data in this dissertation with an even more recent American paper (1998) published by Qureshi et al. In Qureshi's paper (34) of 419 patients with aneurysms, the mean age of patients with single aneurysms was 51,3 years (compared to 39,4 years in our study) and the mean age of patients with multiple aneurysms was 53 years (compared to 42,1 years in our study). In Rinne et al's study (74) in Eastern Finland in which he attempted to study all of the patients with cerebral aneurysms, the overall mean age of patients with a single aneurysm was 52,5 years (male=48.9 and female =56 years), and multiple aneurysms was 49,4 years (male =48,4 and female =50,6 years). These Finnish baseline age characteristics are similar to the ones in Kongable's and Qureshi's paper but are different to the age characteristics in our study.

It is apparent from these comparisons that the patients admitted to the government hospitals (Johannesburg General and Chris Hani Baragwanath Hospitals) were presenting almost a decade earlier compared to North American and Finnish patients.

85,3% of the patients with aneurysms in our study were black. All of the patients in Qureshi's study were white and if we assume that the majority of patients in Kongable's North American study were Caucasian, than the 2nd important point that this study raises is: Is there an age-related racial bias in intracranial cerebral aneurysms? To help answer this important question a study of the biographical variables concerning aneurysms in North American Blacks needs to be undertaken.

In our study, 6 of the 10 white patients had aneurysms. The mean age of this group of patients with aneurysms was 44 years. A total of 7 aneurysms (6 patients) were identified. This was slightly higher than the mean age of all the patients with aneurysms, but was lower than the mean age of the white patients in Qureshi's North American study. It is difficult to say whether this earlier presentation of South African urban patients with aneurysms is an inherent phenomenon or forms part of a changing trend in the epidemiology of aneurysms. What is clearly apparent from these comparisons is that both South African urban black and white patients are presenting almost 10 years earlier compared to American patients. Certainly, if you compare the peak age distribution of patients with aneurysms in this study (31-40 years) to the peak age distribution of patients with aneurysms in the autopsy study (50-59 years) of the cerebral vasculature done by Anim (17) (published in mid 1985) in a Ghanaian adult population, it appears as if this earlier presentation is a changing trend.

I need to stress that this inference comparing the Ghanaian autopsy study to our study is biased because our sample population was highly selective and also

because approximately 12% of patients with aneurysms die before receiving medical attention (75). Obviously more comparative studies need to be undertaken in the future for a more scientific analysis.

There are large differences in the incidence of aneurysmal SAH among countries, with the lowest incidence reported in New Zealand. The highest incidence has been reported in Japan, the United States of America and Finland. The population in these countries is predominantly Caucasian. Low incidence of intracranial arterial aneurysms has been reported from India, Iran and many parts of Africa (70). These studies however were on a small sample population and the studies were done before the 1990s.

The findings in our study suggest that the claim about the rarity of such aneurysms in Africa deserve further evaluation.

An autopsy study of the cerebral vasculature in 310 Ghanaian adults showed an incidence of cerebral aneurysms of only 13,2% (41 cases). The highest incidence (41,4%) was in the age group 50-59 years, with a meager 7,3% incidence in the age group 30-39 years, and 9,7% in the 40-49 year age group (17). About 60% of the aneurysms occurred in patients in the 5th and 6th decades. This is in keeping with Kongable's and Andrews and Spiegel's findings but contrasts strikingly to our study.

Gender Differences

The greater incidence of aneurysms in females is generally accepted and this is also true of our study. Thirty-three men (44%) and 42 women (56%) were found to harbor aneurysms.

In our study we found a slight male preponderance under 20 years of age. The male:female ratio was 1,5:1. However when we considered cases less than 31 years of age, the males outnumbered the females by almost 3 to 1. Before age 40 the sex ratio of M:F with aneurysms was 1,35:1. After age 40 this ratio was 1:1,41. Overall however more women harbored aneurysms than men did.

Multiple aneurysms

In our study the frequency of multiple aneurysms in patients with aneurysms was 16%.

Double aneurysm cases were 2 times as frequent as those with more than 2 aneurysms; a marked predominance of females among both groups was noted. Multiple aneurysms were 5 times more common in women. When patients with three or more aneurysms were considered the female to male ratio dropped. to 3:1.

The 16% frequency of multiple aneurysms in our patients with aneurysms is within the reported range of frequencies by other authors. In Kassel et al's large series of 3521 patients, a frequency of 19% (669 patients) was reported (9).

In Nehl's study (20) of multiple intracranial aneurysms the peak incidence occurred in the 6th and 7th decades whilst in our study the peak incidence occurred in the 3rd and 4th decade.

McKissock et al reviewed 17 previous reports and found a range of 5% to 17% of multiple aneurysms in angiographic studies and 21% -33% in autopsy series (20). Multiplicity in the Cooperative Study was 19%; In Spiegel and Andrews' study (New Hampshire) of 350 patients, 212 had aneurysms. Sixty-two (29,2%) of these patients had multiple aneurysms (7). Nehls et al (Phoenix, Arizona) studied 69 patients with a total of 205 aneurysms. Amongst the patients with aneurysms, the incidence of multiple aneurysms was 33,5% (20). In Qureshi et al's (The Johns Hopkins Medical Institutions, Maryland) series of 419 patients with intracranial aneurysms, 127 (30%) had multiple intracranial aneurysms. In a recent review article written by Dr W Schievink for the New England Journal of Medicine it was stated that multiple intracranial aneurysms are found in 20-30% of patients (75). Our study as well as the studies mentioned above (7, 10, 20) found multiple aneurysms to be more frequent in females.

Adeloye et al studied spontaneous SAH in Nigerians. Of a total of 19 patients that underwent 3-vessel angiography, 9 patients (47%) had aneurysms, 3 patients (15,8%) had AVMs and 7 patients (38,9%) had negative findings. The reported frequency of multiple aneurysms in his paper was 22% (2/9 patients) which was in keeping with the reported range of 15-30%. It must be stressed that the sample population in Adeloye's paper was small.

Most series of multiple aneurysms have reported a female preponderance, with females outnumbering males by 2 or 3 to 1 (7, 20, 34, 43). In Finland multiple aneurysms are reported to be more frequent in males (22). The highest incidence of multiple aneurysms has been reported in Finland (73). In a one-year prospective study, Rinne et al (University Hospital of Kuopio, Finland) attempted to study all of the patients with cerebral aneurysms (with or without SAH) with panangiography. He detected a total of 170 intracranial aneurysms in 114 patients and of these 114 patients, 39 patients (34%) had multiple aneurysms for a total of 95 aneurysms.

Site and Gender related site differences

The commonest site of aneurysm location (in our study) in decreasing order of frequency was as follows: MCA (23,6%), PCoA (20,4%), ICA (17,2%), ACoA (16,1%) and ACA (11,8%). Our findings in this regard were similar to Nehls et al's and Raps et al's.

Raps et al's study (42) (New York and Philidelphia) of aneurysms had similar sites of predilection compared to our study. The 3 commonest sites in his series of 111 patients with 132 aneurysms were the ophthalmic artery (20%), MCA (20%), and PCoA (17%). When the ACA and its branches were collectively considered, this accounted for the main site of involvement (27%), as was in our study.

In Nehls' study (20), the common location of the 205 aneurysms were PCoA (22%), MCA (21,5%), and ICA (14,5%).

In Rinne's Finnish study (74) of 114 patients the frequency of aneurysms at the 3 commonest sites were MCA (43%), ICA (30%), and ACoA (16%).

The autopsy study in 310 Ghanaian adults showed that the site of predilection was the ACoA and the MCA was involved in only 7,3%. Just as in our study when the ACA and ACoA was considered as a single group (anterior communicating artery complex) this was the main site of involvement.

In our study female patients harbored 100% more middle cerebral artery aneurysms than males (14 and 7 respectively). Females also had 1,5 times more internal carotid artery aneurysms than male patients. Similar results have been reported by Kongable et al (10). On the other hand, male patients in our study had 100% more anterior communicating artery aneurysms than females (10 and 5 aneurysms respectively).

We found that women more frequently had MCA (33% vs. 21,2%), ICA (21,4% vs. 18%), ACA (19% vs. 9%) and PCoA (23,8% vs. 21,2%) aneurysms, and men harbored more ACoA (30,3% vs. 11,9%) and ACA complex (39,4% vs. 31%) aneurysms. These findings differed from Kongable's in that he showed no major differences in location between male and female with MCA aneurysms and he showed ACA aneurysms to be more common in males.

Aneurysms in the first two decades of life

In our study, of the 75 cases with aneurysms, aneurysms of childhood and adolescence accounted for 6,7% of cases (n=5). An interesting observation has been that of the 5 patients with aneurysms, 60% (n=3) had aneurysms of the right internal carotid artery bifurcation. Even though our sample size is small, this finding of ours collaborates Patel and Richardson's findings. In their paper published in 1971, an analysis of 3000 ruptured intracranial aneurysms revealed 58 cases under the age of 19 years. Twenty of the 58 patients had aneurysms of the terminal ICA. No reference however was made to the sidedness of the aneurysms.

According to the authors knowledge no series has been published regarding the sidedness and sites of the various aneurysms.

Aneurysm negative angiograms and Importance of Cerebral Panangiography

The frequency of aneurysm negative angiograms was higher in this series (40%) than in most studies, although a wide range exists (53,59). In Duong et al's recent (1996) article titled " The negative angiogram in subarachnoid haemorrhage" the overall incidence of negative cerebral panangiography was reported to be 31%.

Ninety-two percent (116 cases) of the sample population had technically adequate three or four-vessel angiograms. Pancerebral angiography was incomplete in 8% of cases. This is one of the contributory factors to this high incidence of aneurysm negative angiograms.

The high frequency (n=20, 39%) of vasospasm in the aneurysm negative group of patients (n=51) also contributed to the high aneurysm negative angiogram incidence. Of these 20 cases, 60% were female, 10 cases were black female and 7 cases were black males. On the otherhand vasospasm in black males with aneurysms was 1,5 times more frequent than in females with aneurysm positive angiograms.

Complete angiography (bilateral carotid and unilateral vertebral or bilateral carotid and bilateral vertebral angiograms) was performed in 116 (92%) patients. Eight percent of the sample population had incomplete cerebral angiographic studies.

Studies have shown that the extent of cerebral angiography in patients with ruptured aneurysms is highly correlated to the number of diagnosed unruptured aneurysms.

Marttila and Heiskanen found that 59% of the additional unruptured aneurysms were situated on the opposite side of the ruptured aneurysm while 33% were ipsilateral and the remaining 8% probably in the midline (72).

As stated earlier in this dissertation, the disclosed frequency of unruptured aneurysms is approximately 3 times greater if at least bilateral carotid angiography (BCA) is performed compared to at least unilateral carotid angiography (UCA). In patients with ruptured aneurysms located on the MCA the diagnostic gain of unruptured intracranial aneurysms is nearly ten times greater if BCA is performed instead of UCA.

It is probable that the reported frequency of aneurysms in the study (60%) would have been higher if the entire sample population had cerebral panangiography.

CONCLUSION

- The most important finding of this study is that South African urban patients with aneurysms are presenting one decade earlier compared to their overseas counterparts. Seventy-nine percent of patients presented before 51 years of age. Fifty-five percent of patients presented in the age group 31-50 years.

- In patients with suspected intracranial aneurysms investigated by angiography the incidence of cerebral aneurysms was 60%. Multiple aneurysms occured in 16% of those with positive angiographic findings.

- Right-sided aneurysms were more frequently seen in the MCA, ICA, and PICA.

- Left-sided aneurysms were more frequent in the PCoA and ACA.

- Females harbored more aneurysms in the ICA, MCA, PICA, PCoA, and basilar tip.

- Males harbored more aneurysms in the ACoA.

- Aneurysms in the first two decades of life had a propensity for the terminal right ICA and were more frequent in males.

- Black males as compared to black females with aneurysms had a higher frequency of vasospasm.

- Black males as compared to black females without aneurysms had a lower frequency of vasospasm.

- The incidence of aneurysm, negative angiograms was higher in our series when compared to Duong et al's recently published series. This was because of the high incidence(39%) of vasospasm in our group of patients and also because of 8% of the sample population had incomplete cerebral panangiography..

REFERENCES

1. Allcock JM. Aneurysms. In: Newton TH, Potts DG, editors. Radiology of the skull and brain. Angiography. C.V. Mosby Company. Volume 2, Book 4:2435-2489.

2. Weir B, Macdonald RL. Intracranial aneurysms and subarachnoid hemorrhage: An overview. In: Wilkins and Rengachary, authors. Neurosurgery. Mcgraw-Hills. 1996, 2nd edition, 2191-2212.

3. Tindall TG, Cooper PR, Barrow LE The Practice of Neurosurgery. Williams and Wilkins. Volume 2, 1996, 1941-2154.

4. Suzuki J, Ohara H. Clinicopathological study of cerebral aneurysms. Origin, rupture, repair and growth. J. Neurosurg 48:505-514,1978.

5. Pope FM, Narcisi P, Neil-Dwyer G, Nicholls AC, Bartlett S, Doshi B. Some patients with cerebral aneurysms are deficient in type III collagen. Lancet 1981 (I): 973-975.

6. Burrows EH, Leeds NE. Subarachnoid hemorrhage. In: Burrows EH, Leeds NE, editors. Neuroradiology. Churchill Livingtson. 1981. Volume 1. Chapter 3:119-155.

7. Andrews RJ, Spiegel PK. Intracranial aneurysms. Age, sex, blood pressure, and multiplicity in an unselected series of patients. J. Neurosurg 51: 27-32,1979.

8. Sutton D, Kendall B, Stevens J. Intracranial lesions. In: Sutton D. Textbook of Radiology and Imaging. Churchill Livingston. 1998, 6th edition, 1619-1633.

9. Hassel NF, Torner JC, Haley EC Jr. The International Cooperative Study on the Timing of Aneurysmal surgery. Part 1: Overall Management results. J Neurosurg 1990;73:18-36.

10. Kongable GL, Lanzino G, Germanson P, Truskowski LL, Alves WM, Torner JC et al. Gender related differences in aneurysmal subarachnoid hemorrhage. J. Neurosurg 84:43-48,1996.

11. Sarti C, Tuomilehto J, Salomon V, Sivenius J, Kaarsalo E, Narva VE et al. Epidemiology of Subarachnoid Hemorrhage in Finland from 1983 to 1985. Stroke Vol. 22, No 7, July 1991, 848-843.

12. Broderick JP, Brott T, Tomsick T, Huster G, Miller R. The risk of subarachnoid and intracerebral hemorrhages in blacks as compared with whites. N Engl J Med 1992:11:733-736.

13. Naidich TP , Righi AM. Neurovascular Imaging. Radiol Clin North Am. Vol 33, No.1 Jan 1995, 115-166.

14. Dahnert W. Radiology Review Manual. Williams and Wilkins. 1996, 3rd edition, 191-193.

15. Sutton D. Vascular Lesions. In: Sutton D, Young JWR, editors. A Concise Textbook of Clinical Imaging. Mosby. 1995, 2nd edition, 766-779.

16. Lindsay KW, Bone I, Callender R. Neurology and Neurosurgery Illustrated. Churchill Livingston. 1986. 261-278.

17. Anim JT. Cerebral Macroaneurysms in a Ghanian Adult Population. Atherosclerosis, 54 (1985) 37-42.

18. Chapman S, Nakielny. Aids to Radiological Differential Diagnosis. Saunders. 1995. Third edition. 442-443.

19. Waga S, Marikawa A. Aneurysms developing on the infundibular widening of the posterior communicating artery. Surg Neurol 1979:11:125-127.

20. Nehls DG, Flom RA, Carter LP, Spetzler RF. Multiple intracranial aneurysms: determining the site of rupture. J. Neurosurg 63:342-348,1985.

21. Schwartz RB, Tice HM, Hooten S, Hsu L, Stieg PE. Evaluation of Cerebral Aneurysms with Helical CT Correlation with Conventional Angiography and MR Angiography. Radiology 1994; 192:717-722.

22. Rinne J, Hernesniemi J, Niskanen M, Vapalahti M. Analysis of 561 Patients with 690 Middle Cerebral Artery Aneurysms: Anatomic and Clinical Features As Correlated to Management Outcome. Neurosurgery 38:2-11,1996.

23. Robinson RG. Ruptured aneurysms of the middle cerebral artery. J Neurosurg 1971;35: 25-33.

24. Yasargil RG, Fox JL. The microsurgical approach to intracranial aneurysms. Surg Neurol 1975;3:7-14.

25. Schwartz HG. Arterial aneurysms of the posterior fossa. J Neurosurg 1948;5:312-316.

26. Huston J, Nichols DA, Luetmer PH, Goodwin JT, Meyer FB, Wiebers DO et al. Blinded Prospective Evaluation of Sensitivity of MR Angiography to Known Intracranial Aneurysms: Importance of Aneurysms Size. Am J Neuroradiol 1994; 15:1607-1614.

27. Chung TS, Joo JY, Lee SK, Chien D, Laub G. Evaluation of Cerebral Aneurysms with High-Resolution MR Angiography Using a Section-Interpolation Technique: Correlation with digital subtraction angiography. Am J Neuroradiol 1999;20:225-235.

28. Binet EF, Angtuaio EJC. Imaging of Intracranial aneurysms. In: Wilkins and Rengachary, authors. Neurosurgery. Mcgraw-Hills. 1996, 2nd edition, 2229-2244.

29. Gerber S, Dormont D, Sahel M. Grob R, Foncin JF, Marsault C. Complete spontaneous thrombosis of a giant intracranial aneurysm. Neuroradiology (1994) 36:316-317.

30. Eskesen V, Rosenorn J, Sckmidt K. The influence of unruptured intracranial aneurysms on life expectancy in relation to their size at the time of detection and to age. Br J Neurosurg 1988;2:379-384.

31 Ruggieri PM, Poulos N, Masaryk TJ, Ross JS, Obuchowski NA, Lewin JS et al. Occult Intracranial aneurysms in Polycystic Kidney Disease: Screening with MR Angiography. Radiology 1994;191:33-39.

32 Wiebers OD, Whisnaut JP, O'Fallon WM. The Natural History of Unruptured Intracranial aneurysms. N Engl J Med March 1981: 304:696-698.

33 Sengupta RP, McAllister VL. Subarachnoid hemorrhage. Springer-Verlag. 1986.

34. Qureshi AI, Suarez JI, Parekh PD, Sung G, Geocadin R, Bhardwaj A et al. Risk factors for multiple Intracranial aneurysms. Neurosurgery 43:22-27,1998.

35. Rosenorn J, Eskesen V, Madsen F, Schmidt K. Importance of cerebral pan-angiography for detection of multiple aneurysms in patients with aneurysmal subarachnoid haemorrhage. Acta Neurol Scand 1993:87:215-218.

36. Baron MG. Plain film diagnosis of common cardiac anomalies in the adult. Radiol Clin North Am Vol. 37, No. 2 March 1999, 401-420.

37. Minelli C, Takayanagui OM, Santos dos AC, Fabio SC, Lima e JEP, Sato T et al. Moyamoya disease in Brazil. Acta Neurol Scand 1997:95:125-128.

38. Yamada I, Murata Y, Umehara I, Suzuki S, Matsushima Y. SPECT and MRI Evaluations of the Posterior Circulation in Moyamoya Disease. J Nucl Med 1996; 37:1613-1617.

39. Fodstad H, Bodosi M, Forssell A, Perricone D. Moyamoya disease in patients of Finno-Ugric origin. Br J Neurosurg 1996;10(2):179-186.

40. Patel AN, Richardson AE. Ruptured intracranial aneurysms in the first two decades of life. J. Neurosurg 35:571-576,1971.

41. Robinson JL, Chir B, Hall CJ, Sedzimir B. Subarachnoid hemorrhage in pregnancy. J. Neurosurg 36:27-33,1972.

42. Raps EC, Rogers JD, Galetta SL, Solomon RA, Lennihan L, Klebanoff M et al. The Clinical Spectrum of Unruptured Intracranial aneurysms. Arch Neuro. Vol 50, March 1993, 265-268.

43. Saffer D, Steingo B, Bill PLA. The diagnosis and significance of isolated third nerve palsy in the African. Trop. Geogr. Med. 29(1977)155-158.

44. Adeloye A, Osuntokun BO, Odeku EL. Spontaneous subarachnoid haemorrhage in Nigerians. Trop. Geogr. Med. 22(1970)20-29.

45. Hope RA, Longmore JM, Moss PAH, Warrens AN. Oxford Handbook of Clinical Medicine. Oxford University Press. 1989. 2nd edition. 412-413, 438-439.

46. Curry TS, Dowdey JE, Murry RC. Christensen's Physics of Diagnostic Radiology. Lea ND. Febiger. 1990. 4th edition. 289-322.

47. Wilson JD, Braunwald E, Isselbacher, Petersdorf RG, Martin JB, Fauci AS et al. Harrison's Principles of Internal Medicine. Mcgraw-Hill, Inc. 12th edition. 1991. 1998-2000.

48. Saito I, Shigeno T, Aritake K, Tanishima T, Sano K. Vasospasm assessed by angiography and computed tomography. J. Neurosurg 51:466-475,1979.

49. Takaku A, Stindo K, Tanaka S, Mori T, Suzuki J. Fluid and electrolyte disturbances in patients with intracranial aneurysms. Surg Neurol 1979:11:349-356.

50. Fisher CM, Kistler JP, Davis JM. Relation of cerebral vasospasm to subarachnoid hemorrhage visualized by computerized tomographic scanning. Neurosurgery 1980;6:1-9.

51. Turnbull IW. Computed tomography points to the prognosis of subarachnoid hemorrhage. Br. J. Radiol 53:416-420;1980.

52. Tatter SB, Crowell RM, Ogilvy CS. Aneurysmal and Microaneurysmal " Angiogram negative" subarachnoid hemorrhage. Neurosurgery 37:48-55,1995.

53. Duong H, Melanion D, Tampieri D, Ethier R. The negative angiogram in subarachnoid haemorrhage. Neuroradiology (1996) 38:15-19.

54. Ernestus RI et al. Nontraumatic Subarachnoid Hemorrhage: Value of repeat Angiography. Radiology 1997; 202:798-800.

55. Wilms G, Guffens M, Gryspeerdt S, Bosmans H, Maaly M, Boulanger T et al. Spiral CT of intracranial aneurysms: correlation with digital subtraction and magnetic resonance angiography. Neuroradiology(1996) 38:520-525.

56. Vieco PT, Shuman WP, Alsoform GF, Gross CE. Detection of Circle of Willis Aneurysms in patients with subarachnoid hemorrhage: A comparison of CT Angiography and Digital Subtraction Angiography. AJR 1995;165:425-430.

57. Angiography into Academic Radiology: Results of a focused Survey. AJR August 1999, 445-447.

58. Derdeyn CP, Moran J, Cross DT, Grubb L Jr, Dacey RG Jr. Intraoperative digital subtraction angiography: A Review of 112 consecutive examinations. Am J Neuroradiol 1995;16:302-318.

59. Hassel NF, Torner JC, Haley EC Jr. The International Cooperative Study on the Timing of Aneurysmal surgery. Part 2: Surgical results. J Neurosurg 1990;73:37-47.

60. Lin PJ, Kricheff II. Angiographic Investigation of cerebral aneurysms. Radiology 1972; 105:69-76.

61. Kaim A, Proske M, Kirsch E, Weymarn von A, Radu EW, Steinbrich W. Value of repeat angiography in cases of unexplained subarachnoid hemorrhage (SAH). Acta Neurol Scand 1996:93:366-373.

62. Tu RK, Cohen WA, Marnvilla KR, Bush WH, Patel NH, Eskridge J et al. Digital Subtraction rotational Angiography for aneurysms of the Intracranial Anterior Circulation: Injection Method and Optimization. Am J Neuroradiol 1996; 17:1127-1136.

63. Cornelius G, Bellet A, Van Eygen B, Raisin PH, Libon E. Rotational multiple sequence roentgenography of intracranial aneurysms. Acta Radiol 1972;13:74-76.

64. Huston J, Rufenacht DA, Ehman RL, Wiebers DO. Intracranial aneurysms and Vascular Malformations: Comparison of Time-of-Flight and Phase-Contrast MR Angiography. Radiology 1991;181:721-730.

65. Sheppard S. Basic Concepts in Magnetic Resonance Angiography. Radiol Clin North Am Vol. 33, No.1, Jan 1995, 91-113.

66. Schwartz RB, Helical (Spiral) CT in Neuroradiologic diagnosis. Radiol Clin North Am Vol. 33, No.5, Sept 1995, 981-995.

67. Bosmans H, Wilms G, Marchal G, Demaerel P, Baert AL. Characterisation of intracranial aneurysms with MR Angiography. Neuroradiology (1995) 37:262-266.

68. Curnes JT, Shogry MEC, Clark DC, Elsner HJ. MR Angiographic Demonstration of and intracranial aneurysm not seen on Conventional Angiography. Am J Neuroradiol 1993; 14:971-973.

69. Anzalone N, Triulzi F, Scotti G. Acute subarachnoid haemorrhage: 3D time-of-flight MR angiography versus intra-arterial digital angiography. Neuroradiology (1995) 37:257-261.

70. Ohaegbulum SC. Racial Bias in intracranial arterial aneurysms ? Trop. Geogr. Med. 30(1978)305-311.

71. Ohaegbulam SC. The value of angiography in the management of stroke. Afr. J. Med. med. Sci (1981)10,29-32.

72. Marttila I, Heiskanen O. Value of neurological and angiographic signs as indicators of the ruptured aneurysm in patients with multiple intracranial aneurysms. Acta Neurolchir 1970:23:95-102.

73. Inagawa T, Tokuda Y, Ohbayashi N, Takaya M, Moritake K. Study of Aneurysmal Subarachnoid Hemorrhage in Izumo City, Japan. Stroke. 1995;26:761-766.

74. Rinne J, Hernesniemi J, Puranen M, Saari T. Multiple Intracranial Aneurysms in a Defined Population: Prospective Angiographic and Clinical Study. Neurosurgery 35:803-808,1994

75. Schievink WI. Intracranial Aneurysms. N Engl J Med 1997:336:28-40.

ABBREVIATIONS

A1	-	first part of the ACA
ACA	-	anterior cerebral artery
ACoA	-	antertior communicating artery
AICA	-	anterior inferior cerebellar artery
AVM	-	arteriovenous malformation
BCA	-	bilateral carotid angiogram
CCA	-	common carotid artery
CSF	-	cerebro-spinal fluid
CT	-	computed tomography
CTA	-	computed tomography angiography
DSA	-	digital subtraction angiography
DSRA	-	digital subtraction rotational angiography
FOV	-	field of view
GCS	-	Glasgow Coma Scale
ICA	-	internal carotid artery
LP	-	lumbar puncture
M1	-	first part of the mca (sphenoidal segment)
M2	-	second part of the MCA (insular segment)
MA	-	mulitiple aneurysms
MCA	-	middle cerebral artery
MIP	-	minimum intensity projection
MRA	-	magnetic resonance angiography
MRI	-	magnetic resonance imaging
NCCT	-	non- contrast CT
OA	-	ophthalmic artery
PCA	-	phase contrast angiography
PCKD	-	polycystic kidney disease
PCoA	-	posterior communicating artery
PICA	-	posterior inferior cerebellar artery
SAH	-	subarachnoid hemorrhage
SLE	-	systemic lupus erythematosus
SSD	-	shaded surface display
TOF	-	time of flight
UA	-	unruptured aneurysms
UCA	-	unilateral carotid angiogram

Author Ghookal D M
Name of thesis Intranial Aneurysms: Biographical Variables Multiplicityin A Consecutive Unselected Series Of Patients Ghookal D M 2000

PUBLISHER:
University of the Witwatersrand, Johannesburg
©2013

LEGAL NOTICES:

Copyright Notice: All materials on the University of the Witwatersrand, Johannesburg Library website are protected by South African copyright law and may not be distributed, transmitted, displayed, or otherwise published in any format, without the prior written permission of the copyright owner.

Disclaimer and Terms of Use: Provided that you maintain all copyright and other notices contained therein, you may download material (one machine readable copy and one print copy per page) for your personal and/or educational non-commercial use only.

The University of the Witwatersrand, Johannesburg, is not responsible for any errors or omissions and excludes any and all liability for any errors in or omissions from the information on the Library website.