

https://dspace.org/

Radioautographic study of mesenchymal cell activity in the secondary palate of the rat

Cleaton-Jones, P.

1976

http://hdl.handle.net/10539/22264

Cleaton-Jones, P. 1976. Radioautographic study of mesenchymal cell activity in the secondary palate of the rat. Journal of dental research;55(3):437-440

Downloaded from a DSpace repository. https://dspace.org/

Radioautographic Study of Mesenchymal Cell Activity in the Secondary Palate of the Rat

P. CLEATON-JONES

Dental Research Unit of the South African Medical Research Council and the University of the Witwatersrand, Jan Smuts Avenue, Johannesburg, South Africa

Fifteen μCi of ^{3}H-thymidine was injected into the amniotic cavity of fetal rats from day 15 to 19 postinsemination. Analysis of radioautographs from these rats did not show increased mesenchymal cell activity to be responsible for medial rotation of the palatal shelves. Variations in cell activity in the older fetuses were mainly due to developing bone and glands.

During development of the secondary palate, the ventrally directed palatal shelves assume a horizontal position and then fuse one with the other. Peter[1] suggested that this change in position was due to a medial rotation of the palatal shelves, and Lazarro[2] postulated that the mechanism for this was an accumulation of intercellular substance within the ventral palatal shelves. Later studies have confirmed the accumulation of acid mucopolysaccharides in this region.[3–5]

Other mechanisms for palatal shelf rotation that have been suggested include an internal shelf force mediated by elastic fibers,[6] muscular activity in the tongue,[7] and a rapid proliferation of cells on the lateral side of the ventrally directed palatal process.[8,9] This latter mechanism does not appear to have been experimentally substantiated. The only relevant study is that of Mott, Toto, and Hilgers[10] which showed a greater radioautographic labeling index in normal mice as compared to those with a cleft palate. However, it was the activity in the shelves as a whole and not that in any particular area that was measured.

The present study was undertaken with the following objectives:

1. to see whether mitotic activity, as shown by a radioautographic labeling index, varies in different areas of the mesenchyme of the palatal shelves before and after shelf rotation;
2. to compare the mitotic activity in the mesenchyme of the hard and soft palates after palatal fusion.

Materials and Methods

Wistar strain albino rats were mated to produce fetuses of known age.[11] Eight pregnant rats were anesthetized with intramuscular droperidol and fentanyl,[a] their abdomens opened through a midline incision, and the right uterine horn located. The three most distal fetuses were then injected in their amniotic sacs with 15 μCi of tritiated thymidine.[b] All the viscera were then replaced into the mothers' abdomens which were sutured; after this, the mothers were roused by an intramuscular injection of nallorphine.[c] Exactly two hours later, the rats were once more anesthetized, their abdomens reopened, and the three experimental fetuses removed. These were placed in 10% buffered formol saline, dehydrated in ethanol, embedded in paraffin wax, and serially sectioned in the coronal plane at 7 micrometers. The age spread is shown in Table 1.

Radioautographs were produced using Ilford K5[d] nuclear emulsion and a specially constructed automatic dipping machine to ensure an even, thin emulsion layer.[11] The radioautographs were then assessed in the

Received for publication March 18, 1975.
Accepted for publication November 25, 1975.

[a] Thalamonal, Janssens Pharmaceutics, Belgium.
[b] Thymidine (methyl-^3H) TRA-120; specific activity 5,000 μCi/6 mmole, Radiochemical Centre, Amersham, Eng.
[c] Lethidrone, Burroughs Welcome, Johannesburg, South Africa.
[d] Ilford Ltd, Dagenham Essex, Eng.

TABLE 1

DISTRIBUTION OF MATERIAL FOR THE RADIOAUTOGRAPHIC STUDY OF SECONDARY PALATE DEVELOPMENT

Age of Fetus (day and hr, p.i.)	No. of Fetuses
15.9	3
16.9	6
16.16	3
17.9	6
18.9	3
19.9	3
Total	24

following way. Every tenth section was photographed and printed to a standard enlargement. The palatal shelves or fused palate were then subdivided as shown in the illustration to enable comparisons to be made between the various areas. The number of labeled cells (> 5 silver grains over the nucleus) per 1,000 cells was then determined using a transparent grid and a hand tally counter. Statistical analysis was performed on the results using the analysis of variance and student's *t* test.

Results

No rats died during the study; all sections showed radioactive labeling, and there was no demonstrable chemography or interfering background. Similarly, the counting technique proved successful.

When the labeling indexes in the nasal and oral areas of the secondary palate were compared, then no significant differences were seen up to 17 days postinsemination (p.i.), that is, up to and including the time of fusion (Table 2). On the 18th day p.i., there was a greater activity on the oral side

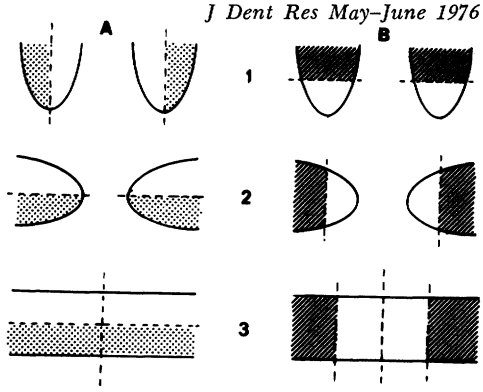

Diagrammatic representation of palatal shelf areas in which labeling activity was compared. *A*, oral vs nasal; *B*, lateral vs medial; *1*, ventrally directed shelves; *2*, horizontal shelves; and *3*, after fusion of shelves.

($P < 0.001$) which had disappeared by the 19th day p.i.

From the 17th day p.i., the hard and soft palates could be distinguished histologically from each other. When their labeling indexes were compared, the following results were seen (Table 3). On the 17th day p.i., the activity in the nasal and oral areas of the hard palate was similar, but on the 18th day p.i., the oral region was more active ($P < 0.001$), a pattern that was reversed on the 19th day p.i. ($P < 0.001$). In the soft palate, the number of labeled cells were similar in the oral and nasal regions on days 17 and 18 p.i., but on the 19th day p.i., activity was greater in the oral compared to the nasal area ($P < 0.001$). Osteogenesis was first seen at 18 days p.i. in the oral half of the developing hard palate. In the soft palate, by the 19th day p.i. mucous glands were seen to arise from the oral epithelium and to extend into the underlying mesenchyme.

When the labeling indexes in the lateral

TABLE 2

CELL ACTIVITY IN THE ORAL AND NASAL REGIONS OF THE SECONDARY PALATE MESENCHYME EXPRESSED IN LABELED CELLS PER 1,000 CELLS

Age of Fetus (day and hr)	Oral Region (mean ± SD)	Nasal Region (mean ± SD)	Significance (Student's *t* test)
15.9	226.4 ± 49.6	198.6 ± 52.4	*NS*
16.9	238.3 ± 89.3	204.7 ± 95.2	*NS*
16.16	214.6 ± 50.0	180.6 ± 57.2	*NS*
17.9	205.8 ± 57.4	191.7 ± 68.1	*NS*
18.9	278.1 ± 77.1	212.5 ± 43.0	$P < 0.001$
19.9	132.0 ± 66.1	106.6 ± 53.5	*NS*

Note: *NS*, not significant.

TABLE 3

CELL ACTIVITY IN THE ORAL AND NASAL REGIONS OF THE HARD AND SOFT PALATE MESENCHYME EXPRESSED IN LABELED CELLS PER 1,000 CELLS

Palatal Region	Age of Fetus (days)	Oral Region (mean ± SD)	Nasal Region (mean ± SD)	Significance (Student's *t* test)
Hard palate	17.9	220.7 ± 60.0	214.6 ± 79.3	*NS*
	18.9	298.2 ± 90.1	214.2 ± 48.5	$P < 0.001$
	19.9	97.4 ± 39.2	141.3 ± 57.0	$P < 0.01$
Soft palate	17.9	181.5 ± 51.6	164.3 ± 43.3	*NS*
	18.9	235.5 ± 43.4	208.8 ± 38.3	*NS*
	19.9	163.6 ± 68.9	75.0 ± 21.2	$P < 0.001$

Note: *NS,* not significant.

and medial regions of the developing secondary palate were analyzed, some variable results were seen. On days 15 to 18 p.i., there were more labeled cells in the medial region compared to the lateral which was statistically significant on days 15 ($P < 0.02$), 16.16 (days and hours) ($P < 0.02$), and 18 ($P < 0.02$) p.i. By the 19th day p.i., almost equal activity was found in the two regions (Table 4).

On analyzing the labeling indexes within the lateral and medial regions of the hard palate from days 17 to 19 p.i., no significant differences were seen. In the soft palate on the 18th day p.i., there was more activity in the medial than the lateral region ($P < 0.01$), but the activity on the other two days was similar in both areas.

Finally, an analysis of variance within each group did not show any significant change in the number of labeled cells within the various regions with increasing age.

Discussion

The theory that medial rotation of the palatal shelves is due to an increased mitotic activity in the lateral part of the ventrally directed palatal shelves[8,9] depends for its validity on the demonstration of this increased mitotic activity. No such increased mitotic activity, as shown by an increased labeling index, was seen in the present study, suggesting that this theory does not hold in the material examined. Thus, indirect support is given to the theory that the rotatory shelf force is an extracellular phenomenon.

A greater deoxyribonucleic acid (DNA) synthesis, as evidenced by the increased number of labeled cells, was seen in the oral half of the hard palate on days 18 and 19 p.i. It is probably due to the osteogenesis that begins about this time, gradually spreading throughout the area of the hard palate.

In the soft palate, on the 19th day p.i. there was more activity on the oral side compared to the nasal. This is due to the developing mucous glands arising from the oral epithelium.

Between the 15th and 18th day p.i., there was more activity in the medial region of the palatal shelves and fused palate than the lateral, although this was not always statistically significant (Table 4). The results suggest a number of spurts of increased ac-

TABLE 4

CELL ACTIVITY IN THE LATERAL AND MEDIAL REGIONS OF THE SECONDARY PALATE MESENCHYME EXPRESSED IN LABELED CELLS PER 1,000 CELLS

Age of Fetus (day and hr)	Lateral Region (mean ± SD)	Medial Region (mean ± SD)	Significance (Student's *t* test)
15.9	210.5 ± 58.6	242.0 ± 49.5	$P < 0.02$
16.9	211.4 ± 100.4	246.8 ± 92.0	*NS*
16.16	183.2 ± 43.5	217.7 ± 54.4	$P < 0.02$
17.9	183.4 ± 60.0	208.8 ± 62.5	*NS*
18.9	215.9 ± 52.7	244.2 ± 59.2	$P < 0.02$
19.9	122.4 ± 41.7	114.0 ± 34.8	*NS*

Note: *NS,* not significant.

tivity in the medial area. This occurred at day 15.9 p.i. before the palatal shelves became horizontal and again at 16.16 days p.i. when it was associated with contact between the palatal shelves. It was not seen on day 16.9 p.i., the reason for which is not clear. The third increase in activity at day 18.9 p.i. is probably due to development of the mucous glands which are more numerous in the medial region.

Comparison of the findings in this study with those in other studies is difficult. Mott, Toto, and Hilgers[10] did not investigate activity in the different regions of the mesenchyme of the secondary palate; instead, they investigated activity only in the palatal shelves as a whole. Nanda[11] remarked in passing that there was more activity in the medial than the lateral regions of the palatal shelves, but he gave no details. His findings do lend support to the present study.

Finally, although Enesco and Leblond[12] noted a steady decrease in DNA synthesis and cell diversion in many tissues of the fetal rat from 12 days p.i. onwards, this decrease was not seen in the palatal shelves and fused palate in the present study.

Conclusions

In this radioautographic study of the developing secondary palate of the rat, it has been shown that there was not the increased nuclear labeling indicative of increased mitotic activity in the mesenchyme said to be responsible for medial rotation of the palatal shelves.[8,9] Variations in labeling index in different regions of the developing palate appeared mainly because of developing bone and mucous glands.

The author acknowledges the technical assistance of Mrs. D. Banks, Mrs. B. Friedrich, Miss E. Vieira, and Mrs. H. Wilton-Cox; and the Department of Dental Research, University of Nijmegen, The Netherlands, for the radioautographic technique.

References

1. PETER, K.: Die Entwicklung des Säugetier Gaumens, *Ergeb Anat Entw Gesch* 25: 448-454, 1924.
2. LAZARRO, C.: Sul Meccanismo di Chiasma de Palato Secondario, *Monit Zool Ital* 51: 249-273, 1940.
3. LARSSON, K.S.; BOSTRÖM, H.; and CARLSÖÖ, S.: Studies on the Closure of Secondary Palate: I. Autoradiographic Study in the Normal Mouse Embryo, *Exp Cell Res* 16: 379-383, 1959.
4. WALKER, B.E.: Special Components of Embryonic Mesenchyme, *Anat Rec* 136: 298, 1960.
5. LARSSON, K.S.: Studies on the Closure of the Secondary Palate: III. Autoradiographic and Histochemical Studies in the Normal Mouse Embryo, *Acta Morph Neerl Scand* 4: 349-367, 1962.
6. WALKER, B.E., and FRASER, F.C.: Closure of the Secondary Palate in Three Strains of Mice, *J Embryol Exp Morphol* 4: 176-189, 1956.
7. WRAGG, L.E.; DIEWERT, V.M.; and KLEIN, M.: Spatial Relations in the Oral Cavity and the Mechanisms of Secondary Palate Closure in the Rat, *Arch Oral Biol* 17: 683-690, 1972.
8. ORBAN, B.J.: *Oral Histology and Embryology*, 4th ed, St. Louis: C. V. Mosby, 1957, pp 23-24.
9. SICHER, H., and BHASKAR, S.N.: *Orban's Oral Histology and Embryology*, 7th ed, St. Louis: C. V. Mosby, 1972, pp 6-12.
10. MOTT, W.J.; TOTO, P.D.; and HILGERS, D.C.: Labelling Index and Cellular Density in Palatine Shelves of Cleft Palate in Mice, *J Dent Res* 48: 263-265, 1969.
11. NANDA, R.: The Normal Palate and Induced Cleft Palate in Rat Embryos, MD thesis, University of Nijmegen, The Netherlands, 1969, pp 18-93.
12. ENESCO, M., and LEBLOND, C.P.: Increase in Cell Number as a Factor in the Growth of the Organs and Tissues of the Young Male Rat, *J Embryol Exp Morphol* 10: 530-562, 1962.