

https://dspace.org/

Morbidity and mortality associated with anomalous origin of the pulmonary artery from the aorta: a review of cases seen at a Southern African tertiary care institution

Dumani, Gcina

2016

http://hdl.handle.net/10539/23190

Downloaded from a DSpace repository. https://dspace.org/

MORBIDITY AND MORTALITY ASSOCIATED WITH ANOMALOUS ORIGIN OF THE PULMONARY ARTERY FROM THE AORTA: A REVIEW OF CASES SEEN AT A SOUTHERN AFRICAN TERTIARY CARE INSTITUTION

Gcina Dumani

This research report is submitted in fulfilment of the requirements for the degree of Master of Medicine in the Department of Paediatrics and Child Health, Faculty of Health Sciences, University of Witwatersrand, Johannesburg

Johannesburg, 27 January 2016

DECLARATION

I declare that this research report is my own unaided work. It is being submitted for the degree of Master of Medicine at the University of the Witwatersrand, Johannesburg. It has not been submitted before for any degree or examination at any other University.

_____
Gcina Dumani

__day of_____20_____in_____

DEDICATION

In loving memory of my mother,
Pindiwe Predience Dumani
1952 - 2016

In loving memory of my son,
Oyisile Mfuniselwa Dumani
2007 - 2012

In loving memory of my aunt,
Nontuthuzelo Alphine Binase
1942 - 2008

ABSTRACT

Objective: To describe the demographics, nutritional status, clinical features and assess the outcomes of patients diagnosed with AOPA (anomalous origin of the pulmonary artery from the aorta) in a developing country.

Methods: Retrospective cross-sectional review of all children and adults with AOPA seen between April 1990 and April 2015 at the Chris Hani Baragwanath Academic Hospital, a tertiary care institution. All available clinical, radiographic, electrocardiographic, echocardiographic, computed tomography scan, cardiac catheterization and angiography, operative and follow-up data was reviewed from the case files and database.

Results: Seventeen patients (infants, n = 15) were diagnosed with AOPA and ten (59%) were male. The median age was 81 days (2 days-36 years). Two thirds (77%,10/13) of the patients were malnourished and 46% (6/13) had severe malnutrition. The most common presentation was congestive cardiac failure and severe pulmonary hypertension was present in all the patients.The diagnosis was made on echocardiography in ten patients (59%) and on catheterization angiography in six patients (35%). Fourteen patients (82%) had anomalous origin of the right pulmonary artery (AORPA). The most common associated cardiac defect was patent ductus arteriosus (PDA). Surgery was undertaken in three patients and three patients were deemed inoperable. The overall mortality was 82% (14/17).

Conclusion: High morbidity and mortality is associated with AOPA if early diagnosis and surgery is not achieved. Mortality is related to early development of pulmonary hypertension and progressive congestive cardiac failure. Late presentation and lack of adequate resources may be contributing factors to the mortality in a developing country.

ACKNOWLEDGEMENTS

To my supervisor Professor Cilliers, a special thanks for the advice, encouragement and guidance throughout this report. Completion of this report would have not been possible without her.

I would like to thank you my whole family for their understanding, patience and support throughout my journey of completing this report.

TABLE OF CONTENTS

DECLARATION.....ii

DEDICATION.....iii

ABSTRACT.....iv

ACKNOWLEDGEMENTS.....v

TABLE OF CONTENTS.....vi-vii

LIST OF TABLES.....viii

LIST OF FIGURES……ix-x

LIST OF GRAPHS……xi

ABBREVIATIONS.....xii-xiv

PART 1: PROTOCOL.....1
- Introduction - Background Information.....1-3
- Motivation for the Study……..4
- Objectives.....4
- Definitions.....4
- Methods.....4
- Study design.....4
  - Study population.....4
  - Inclusion criteria.....5
  - Exclusion criteria.....5
- Data Collection.....5
- Sample size.....5
- Data Analysis.....5
- Ethical Considerations.....6
- Time lines.....6
- Funding/Cost.....6
- References.....7-9

PART 2: LITERATURE REVIEW.....10
- 2.1 Introduction.....10
- 2.2 Embryology and Morphology.....11
- 2.3 Pathophysiology, Presentation and Complications.....11-17
- 2.4 Pulmonary hypertension.....17-18
- 2.5 Diagnosis.....18-22
- 2.6 Associations……22-23
- 2.7 Treatment, Outcomes and Follow up…….....23-28

PART 3: MAIN REPORT/MANUSCRIPT.....29
- CHAPTER 1:……..29
  - 3.1.1 Study Design…….29
  - 3.1.2 Study Population……...29

3.1.3 Study Setting……29
3.1.4 Data collection/Procedures……29

CHAPTER 2:……..30
3.2.1 Patient Demographics……..30-33
3.2.2 Clinical Presentation……34
3.2.3 Diagnostic Modalities……..35-50
3.2.4 Mode of definitive diagnosis…….....51
3.2.5 Pulmonary Hypertension…….51-52
3.2.6 Pulmonary Vascular Resistance index…….52-53
3.2.7 Type of AOPA……..53
3.2.8 Associations…….53-54
3.2.9 Management: Medical and Surgical……..55
3.2.10 Outcomes and Follow up……...55-56

CHAPTER 3:……..57
3.1 Discussion……...57-66
3.2 Limitations……...67

CHAPTER 4:……..68
4.1 Conclusion……68
4.2 Recommendations……68
References…….69-80

APPENDIX:……...81
5.1 Appendix A - Ethics Clearance ……...81
5.2 Appendix B – Ethics Clearance……...82
5.2 Appendix C – Plagiarism Certificate ……..83

LIST OF TABLES

Table 1: Cardiac and non-Cardiac associations with AOPA

Table 2.1: AOPA literature review in Africa - Case series and reports

Table 2.2: Clinical characteristics and demographics of AOPA cases diagnosed in preterm infants

Table 2.3: WHO - Weight for age Z - scores in AOPA cases series (n = ≥ 5)

Table 2.4: Clinical characteristics and demographics of AOPA cases diagnosed at age ≥ 2 years and < 10 years

Table 2.5: Clinical characteristics and demographics of AOPA cases diagnosed at age ≥ 10 years and < 18 years

Table 2.6: Clinical characteristics and demographics of AOPA cases diagnosed in adults ≥ 18 years of age

Table 2.7: Pulmonary Hypertension, Associated Cardiac defects and Outcomes in AOPA cases series (n = ≥ 7)

Table 2.8: Associations - Cardiac defects or anomalies and Non-cardiac conditions

Table 2.9: AOPA surgical case series with ≥ 5 cases

Table 2.10: Summary of surgery and outcomes in Preterm infants, Children ≥ 2 years and < 18 years, Adults ≥ 18 years of age

Table 3.2.1: Demographics, Characteristics and Clinical presentation of patients diagnosed with AOPA

Table 3.2.2: Anthropometric and Growth parameters, World Health Organization (WHO) Z-scores and Growth problems

Table 3.2.3: Pulmonary Vascular Resistance index (PVRi) data in patients undergone cardiac catheterization with AOPA

Table 3.2.4: Cardiac catheterization and Echocardiographic data in patients with pulmonary hypertension (PHT) and AOPA

Table 3.2.5: Diagnosis, time to diagnosis, aortic arch sidedness and associations

Table 3.2.6: IPPV, hospital stay duration, surgery and outcomes

LIST OF FIGURES

Figure 2.1: Pathophysiology of AOPA
(with or without L to R shunts or RVOTO)

Figure 2.2: Clinical presentation in infants, children, adolescents and adults

Figure 3.2.1: Chest X-ray in the anterior-posterior view (AP view), patient no.15

Figure 3.2.2: Chest X-ray in the anterior-posterior view (AP view), patient no.17

Figure 3.2.3: Chest X-ray in the anterior-posterior view (AP view), patient no.10

Figure 3.2.4: Electrocardiogram, patient no. 15

Figure 3.2.5: Electrocardiogram, patient no. 17

Figure 3.2.6: Transthoracic echocardiography in the suprasternal long axis view, patient no. 16

Figure 3.2.7: Transthoracic echocardiography in the parasternal short axis view, patient no. 16

Figure 3.2.8: Transthoracic echocardiography in the parasternal long axis view, patient no. 4

Figure 3.2.9: Transthoracic echocardiography in the suprasternal long axis view, patient no. 4

Figure 3.2.10: Transthoracic echocardiography in the suprasternal long axis view, patient no. 17

Figure 3.2.11: Transthoracic echocardiography in the parasternal long axis view, patient no. 17

Figure 3.2.12: Transthoracic echocardiography in the suprasternal long axis view, patient no. 17

Figure 3.2.13: Computed tomograpgy angiogram (CT Angio) in the axial view, patient no. 12

Figure 3.2.14: Computed tomography angiogram (CT Angio) in the sagittal view, patient no. 12

Figure 3.2.15: Computed tomography angiogram (CT Angio) 3D reconstruction in the posterior view, patient no. 12

Figure 3.2.16: Computed tomography angiogram (CT Angio) in the sagittal view, patient no. 12

Figure 3.2.17: Computed tomography angiogram (CT Angio) 3D reconstruction in the left lateral view, patient no. 12

Figure 3.2.18: Computed tomography angiogram (CT Angio) in the axial view, patient no. 10

Figure 3.2.19: Computed tomography angiogram (CT Angio) 3D reconstruction in the anterio-lateral view, patient no. 10

Figure 3.2.20: Computed tomography angiogram (CT Angio) in the axial view, view, patient no. 9

Figure 3.2.21: Aortogram in the lateral view, patient no. 10

Figure 3.2.22: Aortogram in the anterio-posterior (AP) view, patient no. 11

Figure 3.2.23: Aortogram in the lateral view, patient no. 11

Figure 3.2.24: Aortogram in the anterio-posterior (AP) view, patient no. 12

Figure 3.2.25: Ascending aortogram in the lateral view, patient no. 12

Figure 3.2.26: Aortogram in the anterio-posterior view, patient no. 17

Figure 3.2.27: Aortogram in the lateral view, patient no. 17

Figure 3.2.28: Descending aortogram in the lateral view, patient no. 17

Figure 3.2.29: Aortogram in the anterio-posterior view, patient no. 15

Figure 3.2.30: Pulmonary angiogram in the anterio-posterior view, patient no. 15

Figure 3.2.31: Transthoracic echocardiography in the short axis view post surgical re-implantation of the right pulmonary artery, patient no. 9

Figure 3.2.32: Perfusion scan in the anterio-posterior (AP) view post surgical re-implantation of the right pulmonary artery, patient no. 9

LIST OF GRAPHS

Graph 3.2.1: AOPA – year of diagnosis

Graph 3.2.2: Patients age category – infants, a child and an adult

Graph 3.2.3: WHO Z-score, weight for age

Graph 3.2.4: WHO Z-score – Malnutrition < -2 vs < -3

Graph 3.2.4: WHO Z-score, length/height for age

Graph 3.2.6: Major mode of clinical presentation (excluding murmurs)

Graph 3.2.7: Imaging – mode of diagnosis

ABBREVIATIONS

AOPA: Anomalous Origin of the Pulmonary Artery from the ascending aorta

AORPA: Anomalous Origin of the Right Pulmonary Artery from the ascending aorta

AOLPA: Anomalous Origin of the Left Pulmonary Artery from the ascending aorta

ASD: Atrial Septal Defect

AS: Aortic stenosis

APVS: Absent Pulmonary Valve Syndrome

APV: Absent Pulmonary Valve

APW: Aorto-Pulmonary Window

BVH: Biventricular Hypetrophy

CATCH 22: Cardiac defects, Abnormal facies, Thymic hypoplasia, Cleft palate, Hypocalcaemia and chromosome 22

CCF: Congestive Cardiac Failure

CHD: Congenital Heart Disease

CM: Centimeters

CoA: Coarctation of the Aorta

CPB: Cardiopulmonary Bypass

CTR: Cardiothoracic Ratio

CT scan: Computerized Tomography scan

CT Angio/CTA: Computerized Tomography Angiography

CXR: Chest X-ray

DORV: Double Outlet Right Ventricle

ECG: Electrocardiography

ECHO: Echocardiography

F: Female

GA: Gestational Age

G: grams

Ht: Height

IPPV: Intermittent Positive Pressure Ventilation

iNO: inhaled Nitric Oxide

IQR: Interquantile Range

IAA: Interrupted Aortic Arch

Kg: kilograms

LPA: Left Pulmonary Artery

LV: Left Ventricle

LA: Left Atrium

LVOTO: Left Ventricular Outflow Tract Obstruction

LVH: Left Ventricular Hypertrophy

LRTIs: Lower Respiratory Tract Infections

M: Male

MPA: Main Pulmonary Artery

MAPCAs: Major AortoPulmonary Collaterals from the Aorta

MRI: Magnetic Resonance Imaging

MRA: Magnetic Resonance Angiography

PA/VSD: Pulmonary Atresia with Ventricular Septal Defect

PAB: Pulmonary Artery Band

PAp: Pulmonary Artery pressures

PDA: Patent Ductus Arteriosus

PFO: Patent Foramen Ovale

PGE1: Prostaglandin E1

PHT: Pulmonary Hypertension

PIG: Peak Instantaneous Gradient

Press.: Pressure

PVR: Pulmonary Vascular Resistance

PVRi: Pulmonary Vascular Resistance index

PS: Pulmonary Stenosis

PVOD: Pulmonary Vascular Obstructive Disease

RV: Right Ventricle

RA: Right Atrium

RVOTO: Right Ventricular Outflow Tract Obstruction

RPA: Right Pulmonary Artery

Resp. distress: Respiratory distress

RVH: Right Ventricular Hypertrophy

RSCA: Right subclavian artery

SCA: Subclavian artery

RICA: Right internal carotid artery

TTE: Transthoracic Echocardiography

TOF: Tetralogy of Fallot

TGV: Transposition of the Great Vessels

UAPA: Unilateral Absent Pulmonary Artery

V/Q scan: Ventilation-Perfusion scan

VSD: Ventricular Septal Defect

WHO: World Health Organization

WU/m^2: Wood Units per square metre

Wt: Weight

Yrs: Years

2D: Two-dimensional

PART 1: PROTOCOL

Background

Anomalous origin of the pulmonary artery from the aorta (AOPA) is a rare congenital anomaly, characterized by the anomalous origin of one of the branch pulmonary arteries from the ascending aorta and a normal origin of the other pulmonary artery from the right ventricular outflow tract in the presence of two semilunar valves.[1] It should be distinguished from discontinuous pulmonary arteries whereby pulmonary arteries receive blood supply to the lung from a patent ductus arteriosus-like structure or major aortopulmonary collaterals.[2]

AOPA was first described in 1868 at an autopsy of an adult 25 year old female with anomalous origin of the right pulmonary artery from the ascending aorta (AORPA) and aortopulmonary window (APW).[3] Surgical correction should be performed as early as possible once diagnosis is confirmed as without surgery, congestive cardiac failure and early onset pulmonary arterial hypertension are associated with a first year mortality of 70%.[4] The first successful surgical correction of AOPA by graft repair was reported in 1961 but the surgical procedure of choice whenever feasible is direct implantation of the anomalous pulmonary artery to the main pulmonary artery (MPA), which was first described by Kilpatrick et al in 1967.[5-6]

The incidence of AOPA is estimated at 0.12% of all congenital heart diseases.[7-8] Kutsche et al reported in the literature the largest case series of 108 cases with AOPA in 1988.[8] Anomalous origin of the right pulmonary artery (AORPA) occurs four to eight times more often than anomalous origin of the left pulmonary artery (AOLPA).[8] Single institutional surgical experiences of between 11 to 17 patients have been reported with an early mortality of between 0% and 21%.[1-2,9-12]

The development of AOPA is due to abnormal migration of the pleuripotent neural crest cells leading to the abnormal formation of the aortic arches. AORPA development is embryologically distinct from AOLPA.[2,13] AORPA occurs due to persistent presence of the right sixth aortic arch and failure of resorption of the right fifth aortic arch.[8,13] Incomplete migration of the right sixth aortic arch to the left side leads to the development of proximal AORPA.[8,13] The distal component of AORPA is due to the resorption of the proximal (close to the aortic valve) right pulmonary artery (RPA) and distal (close to the innominate artery) sixth aortic arch and failure of resorption of the fifth aortic arch.[8,13] The formation of AOLPA is different and follows failure of development of the left sixth aortic arch and left fifth aortic arch.[8,13] The persistence of the aortic sac from which the anomalous LPA arises and failure of fusion of the left pulmonary artery (LPA) to main pulmonary artery (MPA) occurs due to the absence of the left sixth aortic arch.[8,13]

AOPA should be distinguished from discontinuos pulmonary arteries where blood supply to the lungs is via patent ductus arterious (PDA) or patent ductus arteriosus-like structure from the aortic arch or other major aortopumonary

collaterals.[2] In AOPA, the origin of the anomalous pulmonary artery is either from the lateral, posterior or posteriolateral aspects of the ascending aorta while the other pulmonary artery arises from the right ventricle in the presence of two semilunar valves unlike truncus arteriosus which is associated with a single truncal valve.[1,8-9] Origin of the anomalous pulmonary artery may either be proximal close to the aortic valve or more distally close to the innominate artery or from the base of the innominate artery.[8] The proximal form of AOPA is more common than the distal type of AOPA which is associated with narrowing of the pulmonary arteries in about 50% of cases.[8] AOPA may occur in isolation or maybe associated with other cardiac defects and non-cardiac or extra-cardiac conditions. (Table 1) AORPA is reportedly more commonly associated with PDA and left aortic arch while AOLPA is commonly associated with Tetralogy of Fallot (TOF) and a right aortic arch.[1,8]

Table 1: Cardiac and non-Cardiac associations with AOPA

Cardiac				Extra-Cardiac
Left to Right shunts	**RVOTO**	**LVOTO**	**Other Cardiac**	**Syndromes**
PDA[2,5,7-8]	TOF[1,7-9,14]	CoA[9,22]	Ebstein's anomaly[23]	CATCH 22[25]
VSD[1-2,8-9]	PA/VSD with or without MAPCAs[15-16]	IAA[8]	DORV[24]	
APW[3,8]	TOF with APV syndrome[17-18]			
ASD[1]	Tricuspid atresia[19]			
	PS[20-21]			

AOPA has been divided into groups according to their clinical presentation, associated left to right cardiac lesions and the presence of right ventricular outflow tract obstruction (RVOTO) by various authors.[1,26] Peng et al[26] classifies AOPA into the following groups: Group 1 have simple associated cardiac lesions such as PDA, patent foramen ovale (PFO) and right aortic arch coupled with congestive cardiac failure. Group 2 have complex cardiac lesions associated with RVOTO and tend to be asymptomatic or present with cyanosis. Garg et al[1] classifies AOPA into the following groups: Group 1 are either isolated or associated with left to right shunt cardiac lesions but without RVOTO and tend to present with congestive cardiac failure (CCF), recurrent respiratory infections and failure to thrive within the first year of life. Group 2 are associated with RVOTO and tend to present late with cyanosis or failure to thrive.

AOPA with isolated or associated left to right cardiac lesions tend to present early within the first six months of life with CCF and may develop early pulmonary arterial hypertension.[1,4] One lung connected to the anomalous origin of the pulmonary artery from the aorta is exposed to systemic pressures and large left to right shunt while the other lung connected to the pulmonary artery arising from the right ventricle receives entire cardiac output from the right ventricle.[1-2]

Complex cardiac lesions associated with RVOTO have reduced pulmonary blood flow and tend to present with cyanosis and may survive late into childhood and adulthood.[1,27] Echocardiography is an important accurate diagnostic tool prenatally and postnatally. Careful imaging allows confirmation of the anomalous origin of the pulmonary artery and associated cardiac lesions.[14,28] Other imaging modalities that can be used when diagnosis is uncertain are computerized tomography scan, angiography or magnetic resonance angiography.[29-31]

Early surgical correction as soon as diagnosis is confirmed is the treatment of choice including in the neonatal period and also applies to premature babies to avoid development of irreversible pulmonary arterial hypertension.[2,4] Survival into adulthood in unoperated cases has been reported mostly in association with TOF or proximal pulmonary branch stenosis protecting the lungs or as isolated AOPA which in some cases are inoperable due to irreversible pulmonary hypertension.[27,32-33] The first successful correction of AOPA was accomplished by graft interposition.[5] However, direct implantation is the surgical procedure of choice and was first described in 1967.[1-2,6,9] Other surgical techniques that can be implemented for correction if direct implantation is not feasible include autologous pericardial grafts, synthetic grafts and homograft interposition with or without cardiopulmonary bypass.[9,34-35] Good outcomes have been reported even in adults with reversal of pulmonary hypertension in the lung exposed to right ventricular cardiac output.[36-38] The largest surgical series described after 2007 included 17 patients with a median follow up of 36.5 months and early mortality of 5.9%.[1] Reimplantation of the anomalous pulmonary artery may be complicated in the short and long term postoperatively by stenosis at the surgical anastomotic site which may need either balloon dilation or surgical reoperation.[9,39]

The survival of AOPA without surgery is 30% while with surgery it is reported as 84% at 1 year.[4] Early diagnosis and early surgery is important to avoid the inevitable high morbidity and mortality associated with AOPA. The majority of the literature around AOPA is focused on postoperative outcomes. Preoperative mortality is related to progressive or refractory CCF and early development of pulmonary hypertension leading to development of pulmonary vascular obstructive disease. Preoperative congestive cardiac failure, severe pulmonary hypertension (PHT) and associated cardiac defects are predictors of postoperative morbidity and mortality.[40] In a review of 50 cases, the preoperative mortality was 56% (28/50) and 18 of the patients that died were infants less than 6 months of age. Surgery was undertaken in 22 patients and the postoperative mortality was 40.9% (29/22).[7] In a review of 65 cases with AOPA, 35% of the patients died in the first month of life while 70% of the patients died by the age of 1 year.[4] In a case series of six patients with AOPA, two neonates died preoperatively and two other patients with associated Tetralogy of Fallot died postoperatively with overall mortality of 66.7%.[41] The overall postoperative hospital mortality in a review of 127 patients published in the literature is 10%.[40] The early mortality in a large surgical series of 11-17 patients post 1988 was reported as 0%-21%.[1-2,9-12,14]

In the literature there are two case reports, one case series of two patients and one surgical case series of five patients reported from Africa. Three patients with

pulmonary atresia and ventricular septal defect were deemed inoperable, one adult patient with AORPA and PDA underwent surgical correction and a surgical case series of five patients had a postoperative mortality of one patient (20%) due to extensive lung disease.[15-16,20,37]

Motivation for the study

There is a high morbidity and mortality associated with AOPA if an early diagnosis is not made in the fetus or immediately postnatally.[4,28] Early surgical correction has excellent outcomes.[1-2, 20] A literature search has revealed two case reports, one case series of two patients and one surgical series of five patients reported from the African continent.[15-16,20,37] The aim of the proposed study is to review the presentation, diagnosis and analyze the outcomes of patients with AOPA in a Southern African tertiary care centre in the modern era and to determine possible avoidable factors that may be related to increased morbidity and mortality in this setting.

Objectives

- To describe the cases diagnosed with AOPA at Chris Hani Baragwanath Academic Hospital.
- To describe demographics and nutritional status at presentation in patients with AOPA.
- To describe the clinical features of patients with AOPA at diagnosis.
- To describe imaging techniques used in diagnosis of AOPA.
- To assess and document outcomes including development of pulmonary hypertension, surgery and death of patients diagnosed with AOPA.
- To determine the possible unavoidable and avoidable factors that may be related to increased morbidity and mortality.

Definitions

- Children: birth to < 18 years
- Adult: ≥ 18 years

Methods

Study Design

This is a retrospective descriptive study of patients seen and diagnosed with AOPA at Chris Hani Baragwanath Academic Hospital.

Study Population

The sample population includes all children and adults diagnosed with AOPA at Chris Hani Baragwanath Academic Hospital.

Inclusion Criteria

- All patients with confirmed diagnosis of AOPA.
- Children from birth to age < 18 years and adults ≥ 18years

Exclusion Criteria

- AOPA connected via PDA or MAPCAs
- Anomalous origin of the pulmonary artery from the descending aorta.

Data Collection/Procedures

Review of records of all patients with diagnosis of AOPA from the hospital files and computerized database at Paediatric Cardiology division at Chris Hani Baragwanath Academic Hospital from April 1990 to April 2015.

The following clinical and diagnostic parameters e.g. chest X-ray (CXR), electrocardiography (ECG), echocardiography (ECHO), cardiac catheterization and cine-angiography, computerized tomography scan or angiography (CT scan or angiography) and magnetic resonance imaging (MRI) or angiography (MRA) will be analyzed to assess the following: clinical presentation (respiratory distress, congestive cardiac failure, failure to thrive, cyanosis, murmurs), CXR (pulmonary blood flow, lung fields- plethora or oligaemia, cardiomegaly by assessing cardiothoracic ratio - CTR, cardiac silhouette that may suggest associated cardiac lesions), ECG (evidence of P-pulmonale or P-mitrale, left ventricular hypertrophy- LVH or right ventricular hypertrophy - RVH or biventricular hypertrophy - BVH), ECHO (morphology, haemodynamics, associated cardiac lesions), cardiac catheterization and cine-angiography (define anatomy, haemodynamics), CT scan or angiography (anatomy), MRI/MRA(anatomy, haemodynamics), preoperative and postoperative care, surgery (corrective surgical techniques and complications - early or late) and outcomes (death or survival).

The following data will be recorded on a data collection sheet (Appendix A) and entered onto an excel computerized spread sheet: year seen, age at presentation, sex, nutritional status, diagnosis, time to diagnosis, associated cardiac lesions, level of care preoperative, time to surgery, surgical technique, complications post surgery, postoperative follow up, outcomes - death or survival.

Sample size

From our regular audit of the database we estimate that 13 cases with the diagnosis of AOPA have been identified from the Paediatric Cardiology computerized database over the last 20 years.

Statistical/Data analysis

Descriptive statistics will be used to analyze the data. Continuous variables will be presented as median and ranges for non-parametric data and mean $\pm$ standard deviation for parametric data. Categorical variables will be presented as frequencies and percentages.

Ethics

The ethics clearance will be obtained from Wits Human Research Ethics Committee (Medical) and permission to do the study will be obtained from the chief executive officer at Chris Hani Baragwanath Academic Hospital.
The division of Paediatric Cardiology has been granted ethics approval to the use of the database for retrospective studies (protocol number M130388).
All information obtained from the patients records will be treated with strict confidentiality and patient identification will be kept anonymous.

Timing/Time lines

The study will commence in August 2014 and the expected duration is 1 year including writing up the dissertation and the publication.

	Aug	Sept	Oct	Nov	Dec	Jan	Febr	Mar	Apr	May	Jun	Jul
Literature review												
Protocol preparation												
Protocol assessment												
Ethics application												
Collecting data												
Data analysis												
Writing up dissertation												
Writing paper												

Financial Support/Cost/Funding

No financial support or funding is expected for this study.

References

1. Garg P, Talwar S, Kothari SS, Saxena A, Juneja R, Choudhary SK et al. The anomalous origin of the branch pulmonary artery from the ascending aorta. *Interact Cardio Vasc Thorac Surg* 2012;15:86-92.
2. Nathan M, Rimmer D, Piercey G, Del Nido PJ, Mayer JE, Bacha EA et al. Early repair of hemitruncus: excellent early and late outcomes. *J Thorac Cardiovasc Surg* 2007;133:1329-35.
3. Fraentzel O. Ein fall von abnormer communication der aorta mit der arteria pulmonalis. *Virchows Arch Pathol Ana.*1868;43:420-6.
4. Fontana GP, Spach MS, Effman EL, Sabiston DC Jr. Origin of the right pulmonary artery from the ascending aorta. *Ann Surg* 1987;206:102-13.
5. Armer RM, Shumacker HB, Klatte EC. Origin of the right pulmonary artery from the ascending aorta. Report of a surgically corrected case. *Circulation* 1961;24:662-8.
6. Kirkpatrick SE, Girod DA, King H. Aortic origin of the right pulmonary artery. Surgical repair without a graft. *Circulation* 1967;36:777-82.
7. Keane JF, Maltz D, Bernhard WF, Corwin RD, Nadas AS. Anomalous origin of one pulmonary artery from the ascending aorta. Diagnostic, physiological and surgical considerations. *Circulation* 1974;50:588-94.
8. Kutsche LM, Van Mierop LH. Anomalous origin of a pulmonary artery from the ascending aorta: associated anomalies and pathogenesis. *Am J Cardiol* 1988;61:850-6.
9. Abu-Sulaiman RM, Hashmi A, McCrindle BW, Williams WG, Freedom RM. Anomalous origin of one pulmonary artery from the ascending aorta: 36 years experience from one centre. *Cardiol Young* 1998; 8:449-54.
10. Ruzmetov M, Rodefeld MD, Turrentine MW, Brown JW. Anomalous origin of one of the branch pulmonary arteries from the aorta (Hemitruncus): A single institution experience. *Chest* 2008;134: 4_Meeting abstracts.
11. Gan HL, Zhang JQ, Luo Y, Wang SX, Li WB, Zhou QW. Diagnosis and treatment of aortic origin of the right pulmonary artery: analysis of 14 cases. *Zhonghua Yi Xue Za Zhi* 2009;89:763-5.
12. Amir G, Frenkel G, Bruckheimer E, Dagan T, Katz J, Berant M et al. Anomalous origin of the pulmonary artery from the aorta: early diagnosis and repair leading to immediate physiological correction. *Cardiol Young* 2010;20:654-9.
13. Aru GM, English WP, Gaymes CH, Heath BJ. Origin of the left pulmonary artery from the aorta: Embryologic considerations. *Ann Thorac Surg* 2001;71:1008-10.
14. Talwar S, Meena A, Choudhary SK, Kothari SS, Gupta SK, Saxena A et al. Anomalous branch of pulmonary artery from the aorta and Tetralogy of Fallot: morphology, surgical techniques and results. *Euro J Cardio Thorac Surg* 2014; 46:291-6.
15. Pepeta L, Takawira FF, Adams PE, Ntsinjana NH, Mitchell BJ, Cilliers AM. Anomalous origin of the left pulmonary artery from the ascending aorta in two children with pulmonary atresia, subaortic ventricular septal defect and right-sided major aorto-pulmonary collateral arteries. *Cardiovasc J Afr* 2011;22:268-71.
16. Steyn FJS, Bellew N, Takawira F. Unusual case of pulmonary valve atresia.

S Afr J Rad 2008;12:8-9.
17. Saxena A, Shrivastava S, Sharma S. Anomalous origin of the left pulmonary artery from the ascending aorta in a patient with Tetralogy of Fallot and "absent pulmonary valve". *Int J Cardiol* 1991;33:315-7.
18. Aly AM, Reid DA, Jiwani AK, Desai PH. Absent pulmonary valve syndrome with left hemitruncus. *Am J Perinatal Rep* 2012;2:51-4.
19. Menzer LL, Takahashi M. Tricuspid atresia and aortic origin of right pulmonary artery in a nine-year-old girl. *West J Med* 1974;121:147-9.
20. Benatar A, Kinsley RH, Milner S, Dansky R, Hummel DA, Levin SE. Surgical correction for one pulmonary artery arising from ascending aorta-report of five cases. *Int J Cardiol* 1987;16:249-55.
21. Prifti E, Bonacchi M, Murzi B, Crucean A, Bernabei M, Luisi VS et al. Anomalous origin of the left pulmonary artery from the aorta. Our experience and literature review. *Heart Vessels* 2003;18:79-84.
22. Hu Y, Yang Y, Kan C. One-stage total repair of anomalous origin of right pulmonary artery from aorta by the double-flap technique, followed by coarctation repair using extended end-to-end arch reconstruction. *Ann Thorac Surg* 2013;6:71-3.
23. Marui A, Mochizuki T, Mitsui N, Koyama T, Horibe M. Anomalous origin of the right pulmonary artery from the ascending aorta - a report of three operative cases. *Nihon Kyobu Geka Gakkai Zasshi* 1997;45:1189-94.
24. Bockeria LA, Makhachev OA, Sobolev AV, Plakhova VV, Gorbachevsky SV, Zaets SB. Double outlet right ventricle with anomalous left pulmonary artery. *Asian Cardiovasc Thorac Ann* 2008;16:e18-20.
25. Saliba Z, Le Bidois J, Sidi D, Kachaner J, Bonnet D. Prenatal detection of a tetralogy of fallot with origin of the left pulmonary artery from the ascending aorta in a familial 22q11 microdeletion. *Prenat Diagn* 1999;19:260-2.
26. Peng EWK, Shanmugam G, Macarthur KJD, Pollock JCS. Ascending aortic origin of a branch pulmonary artery - surgical management and long-term outcome. *Euro J Cardio Thorac Surg* 2004;26:762-6.
27. Patel RJ, Zakir RM, Sethi V, Patel JN, Apovian J, Alexander JC et al. Unrepaired Tetralogy of Fallot with right hemitruncus in an adult. *Tex Heart Inst J* 2007;34:250-1.
28. Taskande A, Thomas E, Gautami V, Murthy KS. Diagnosis of aortic origin of a pulmonary artery by echocardiography. *Images Paediatr Cardiol* 2010;12:5-9.
29. Rosa U, Wade KC. CT findings in hemitruncus. *J Comput Assist Tomogr* 1987;11:698-700.
30. Lin MH, Shen CT, Wang NK, Lin YM, Jeng CM. Magnetic resonance imaging of the right pulmonary artery from the ascending aorta in association with ventricular septal defect. *Am Heart J* 1996;132:1073-4.
31. Koplay M, Erol C, Paksoy Y, Uysal E, Arslan D, Oran B. Hemitruncus arteriosus: cardiac magnetic resonance angiography findings. *Congenit Heart Dis* 2012;7:E66-69.
32. He J, Li H, Li Y, Gui L, Mao X. Anomalous origin of the right pulmonary artery from the ascending aorta. *Herz* 2015;40:311-3.
33. Nigam A, Trehan V. Left hemitruncus with normal right-sided pressures in an adult. *Cardiol Young* 2014;24:926-8.

34. Fucci C, di Carlo DC, Di Donato R, Marino B, Calcaterra G, Martelletti C. Anomalous origin of the right pulmonary artery from the ascending aorta: repair without cardiopulmonary bypass. *Int J Cardiol* 1989;23:309-13.
35. Van Son JA, Hanley FL. Use of autogenous aortic and main pulmonary artery flaps for repair of anomalous origin of the right pulmonary artery from the ascending aorta. *J Thorac Cardiovasc Surg* 1996;111:675-6.
36. Talwar S, Kothari SS, Sharma P, Chauhan S, Gulati GS, Choudhary SK et al. Successful surgical correction of anomalous origin of the right pulmonary artery from the aorta in an adult. *J Card Surg* 2011;26:201-16.
37. Long MA, Brown SC, de Vries WJ. Anomalous origin of the right pulmonary artery from the ascending aorta: a surgical case study in an adult patient with "irreversible" pulmonary vascular disease. *J Card Surg* 2009;24:212-5.
38. Agarwala B, Waldman JD, Sand M, Loe WA, Ruschhaup DG. Aortic origin of the RPA: immediate resolution of severe pulmonary artery hypertension by surgical repair. *Pediatr Cardiol* 1994;15:41-4.
39. Goldstein BH, Bergersen L, Powell AJ, Graham DA, Bacha EA, Lang P. Long-term outcome of surgically repaired unilateral anomalous pulmonary artery origin. *Pediatr Cardiol* 2010;31:944-51.
40. Prifti E, Crucean A, Bonacchi M, Bernabei M, Leacche M, Murzi B, et al. Postoperative outcome in patients with anomalous origin of one pulmonary artery branch from the aorta. *Eur J Cardiothorac Surg* 2003;24:21-7.
41. Fong LV, Anderson RH, Siewers RD, Trento A, Park SC. Anomalous origin of one pulmonary artery from the ascending aorta: a review of echocardiographic, catheter, and morphological features. *Br Heart J* 1989;62:389-95.

PART 2: LITERATURE REVIEW

2.1 Introduction

Anomalous origin of the pulmonary artery from the ascending aorta (AOPA) is a rare congenital cardiac anomaly with an estimated incidence of 0.12% of all congenital heart diseases.[1-5] Although AOPA is characterized by discontinuous pulmonary arteries, it is unique and therefore should be distinguished from other discontinuous pulmonary arteries to the lungs receiving blood supply from a patent ductus arteriosus or collaterals such as major aortopulmonary collaterals.[6] The diagnosis of AOPA in the first case report described by Frantzel et al in an adult in 1868 was made at autopsy.[7] There have been several case reports and case series since then with the most recent literature focused on surgery and postoperative outcomes. Mortality due to progressive congestive cardiac failure, early development of pulmonary hypertension (PHT) and pulmonary vascular obstructive disease (POVD) is high without early diagnosis and surgical correction. In a review of 65 cases with AOPA, 35% of the patients died in the first month of life while 70% of the patients died by the age of 1 year.[8] Surgery was undertaken in 22 patients and the postoperative mortality was 40.9% (9/22).[8] There is paucity of recent literature on preoperative mortality, the focus is mainly on postoperative outcomes. In a review of 50 cases, the preoperative mortality was 56% (28/50) and 18 of the patients that died were infants less than 6 months of age.[1] The diagnosis of AOPA was made at autopsy in almost half (46%) of the cases.[1] A more recent case series of 19 cases focused on the role of multi-detector computed tomography in making the diagnosis followed by the successful surgical correction of 14 patients.[9] Single institutional surgical experiences have reported a variable early mortality of between 0% and 21%.[4-6,10] Four publications from Africa include two surgical case series of four and five patients, one case series of two patients and one adult case report in which two patients were inoperable.[11-14] (Table 2.1) The postoperative mortality in the two surgical case series was between 0% and 20%.[11-12]

Table 2.1: AOPA literature review in Africa - Case series and reports

Year; Author	Presentation (Cases, n)	Age in months/yrs	Mode of Diagnosis	Diagnosis (Cardiac defects)	Surgery (Mortality/Outcome)
1987; Benatar et al[11]	CCF (n = 5)	7.2 months (mean)	Angiography, ECHO	AORPA = 4 AOLPA = 1 (PDA)	Yes (20%)
2015; Manuel et al[12]	No details (n = 4)	1.6 months (mean)	ECHO, CT Angio	AORPA = 4 (PDA, ASD)	Yes (0%)
2011; Pepeta et al[13]	Cyanosis (n = 2)	10 months; 6.5 yrs	Angiography	AOLPA = 2 (PA/VSD/MAPCAs)	No (survived)
2009; Long et al[14]	Dyspnoea, Cyanosis (n = 1)	23 yrs	ECHO, Angiography	AORPA (PDA)	Yes (survived)

2.2 Embryology and Morphology

The embryological development of AOPA is thought to be due to the abnormal migration of pleuripotent neural crest cells leading to the abnormal formation of the aortic arches.

Anomalous origin of the right pulmonary artery (AORPA) development is embryologically distinct from anomalous origin of the left pulmonary artery (AOLPA).[6,15] AORPA occurs due to persistent presence of the right sixth aortic arch and failure of resorption of the right fifth aortic arch.[2,15] The distal component of AORPA is due to the resorption of the proximal right pulmonary artery (RPA), close to the aortic valve and distal sixth aortic arch, close to the innominate artery and failure of resorption of the fifth aortic arch.[2,15] Incomplete leftward migration of the right sixth aortic arch to the left side leads to development of proximal AORPA.[2,15] The formation of AOLPA is different and follows failure of development of the left sixth aortic arch and left fifth aortic arch.[2,15] The persistence of the aortic sac from which the anomalous left pulmonary artery (LPA) arises and failure of fusion of the LPA to main pulmonary artery (MPA) occurs due to the absence of the left sixth aortic arch.[2,15]

In AOPA, the origin of the anomalous pulmonary artery is either from the posteriolateral, lateral or posterior aspects of the ascending aorta while the other pulmonary artery arises from the right ventricle in the presence of two semilunar valve unlike truncus arteriosus which is associated with a single truncal valve.[9-10,16]

Origin of the anomalous pulmonary artery may either be proximal close to the aortic valve or more distally close to the innominate artery or from the base of the innominate artery.[9,16-17] The proximal form of AOPA is more common than the distal type of AOPA which is associated with narrowing of the pulmonary arteries in about 50% of cases.[2,9,16] Other reported types of AOPA include AORPA arising from the left side of ascending aorta with fibrous connection to the MPA, AOPA not originating from the ascending aorta but arising directly from the descending aorta, innominate artery and RPA from the left coronary sinus.[18-24]

2.3 Pathophysiology, Presentation and Complications

One lung is connected to the anomalous origin of the pulmonary artery from the aorta which is exposed to systemic aortic pressures and a large left to right shunt while the other lung is connected to the pulmonary artery arising from the right ventricle and receives the entire cardiac output from the right ventricle.[6,8,10] The anomalous pulmonary artery exposes the ipsilateral lung to both pressure and volume overload while the contralateral lung is exposed to volume overload from the right ventricle. Associated cardiac defects with large left to right shunts such as ventricular septal defects (VSDs) and patent ductus arteriosus (PDAs) also markedly contribute to increased pulmonary blood flow predisposing to early development of PHT and pulmonary vascular obstructive disease (Figure 2.1).

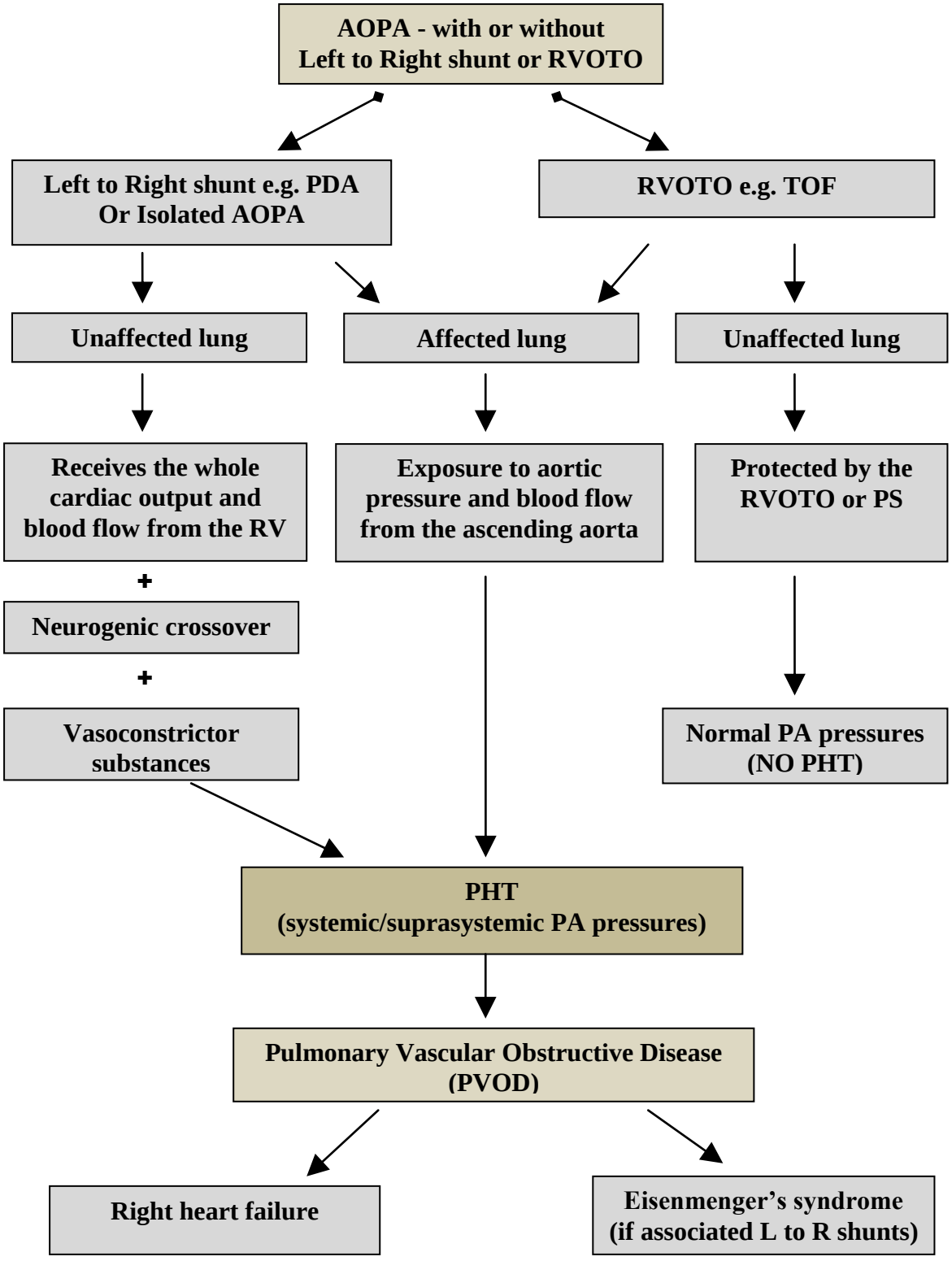

Figure 2.1: Pathophysiology of AOPA (with or without L to R shunts or RVOTO)

AOPA with isolated or associated left to right cardiac lesions tend to present early, within the first six months of life, with congestive cardiac failure and may develop early pulmonary arterial hypertension.[5,10,25] Complex cardiac lesions associated with right ventricular outflow tract obstruction (RVOTO) are associated with reduced pulmonary blood flow and tend to present with cyanosis and may survive late into childhood and adulthood.[10,28-30]

The clinical presentation varies according to the age of presentation. Infants including premature neonates (Table 2.2) and young children (> 1 year to < 2 years) often present with tachypnoea, progressive respiratory distress, congestive cardiac failure, recurrent respiratory infections, failure to thrive and may develop pulmonary hypertension as early as within few days of life especially if there are other associated cardiac defects with large left to right shunts such as VSDs, PDAs and aorto pulmonary window (APWs).[6,10,31-39] Early development of pulmonary hypertension with systemic to suprasytemic pulmonary artery or right ventricular pressures may progress to pulmonary vascular obstructive disease (PVOD) during infancy.[6,35]

Table 2.2: Clinical Characteristics and Demographics of AOPA cases diagnosed in preterm infants

Year; Author	Birth Wt; Sex	GA (weeks)	Presentation	Age at diagnosis; (diagnosis)	Mode of diagnosis	Cardiac defects associated
1974; Keane et al[1]	- ; M	36	CCF	18 years (AORPA)	Angiography	PDA
1995; Johnson et al[31]	1600 g; M	34	-	4 days (AORPA)	ECHO, Angiography	PDA, ASD
1997; Marui et al[32]	984 g; M	-	-	- (AORPA)	ECHO, Angiography	PDA
2000; Salaymeh et al[33]	1055 g; M	28	Resp. distress	5 days (AOLPA)	ECHO	PDA
2005; Vida et al[34]	950 g; F	30	Resp. distress, Cyanosis	62 days (AOLPA)	ECHO	PDA,TOF, ASD
2010; Amir et al[35]	780 g; F	< 37	-	< 2 weeks (AORPA)	ECHO	PDA
2011; Godown et al[36]	520 g; F	25,5	Resp. distress	3 months (AORPA)	ECHO	PDA
2013; Hu et al[37]	2100 g; -	-	Cyanosis	- (AORPA)	ECHO, CT Angio	PDA, CoA
2014; Guzoglu et al[23]	1890 g; F	33	Resp. distress	< 1 week (AORPA)	CT Angio	PDA
2014; Bi et al[38]	1550 g; M	35	Cyanosis	21 days (AORPA)	ECHO, CT Angio	PDA

Congestive cardiac failure may be progressive, refractory or unresponsive to medical and supportive treatment increasing the risk for surgery or death if there is no early surgical correction.[16,40-42] Malnutrition with World Health Organization (WHO) Z - score for weight for age < - 2 has been demonstrated in some of the case series with diagnosis of AOPA with or without asscociated cardiac defects (Table 2.3).

Table 2.3: WHO - Weight for age Z - scores in AOPA cases series (n = ≥ 5)

Author; Year	No. of cases (median age)	Wt for age < -2, n (%)	Growth problem	Wt for age < -3, n (%)	Growth problem
Nakamura et al[16]; 1991	5 (2 months)	4 (80%)	Malnourished (underweight)	2 (40%)	Severe malnutrition
Prifti et al[17]; 2003	8 (1.2 months)	1 (13%)	Malnourished (underweight)	-	-
Kajihara et al[25]; 2008	8 (8 days)	3 (38%)	Malnourished (underweight)	1 (13%)	Severe malnutrition
Amir et al[35]; 2010	12 (0.5 months)	4 (33%)	Malnourished (underweight)	2 (17%)	Severe malnutrition
Garg et al[10]; 2012	17 (7 months)	11 (65%)	Malnourished (underweight)	8 (47%)	Severe malnutrition
Talwar et al[30]; 2014	6 (60 months)	6 (55%)	Malnourished (underweight)	5 (45%)	Severe malnutrition
Liu et al[39]; 2015	11 (11 months)	1 (9%)	Malnourished (underweight)	1 (9%)	Severe malnutrition
Cho et al[57]; 2015	12 (1.8 months)	7 (58%)	Malnourished (underweight)	5 (43%)	Severe malnutrition
Xie et al[58]; 2015	6 (3.3 months)	5 (83%)	Malnourished (underweight)	3(50%)	Severe malnutrition

Neonates may rarely present with cyanosis due to right to left shunting across the shunts secondary to early development of PHT and cardiogenic shock associated with multiorgan failure which can be misinterpreted as transposition of great vessels (TGV), coarctation of the aorta (CoA) or a duct dependent systemic circulation.[37-38,40,42-43] In a literature review of fifty cases with median age at diagnosis of three months, 40% presented with cyanosis.[1] Other infants may present in the early neonatal period with markedly reduced right ventricular (RV) function or poor RV contractility associated with endocardial fibroelastosis, refractory cardiogenic shock associated with multiorgan failure secondary to severe pulmonary hypertension, pulmonary vascular disease, impaired filling of the left ventricle and aortic steal of blood away from vital organs due to preferential left to right shunting into the anomalous PA branch originating from the ascending aorta.[6,39,42,44-47] Right ventricular dysfunction is associated with increased morbidity and mortality and can be detected on echocardiography and angiography.[44-47]

A compromised coronary circulation resulting in myocardial ischemia and cardiogenic shock which causes end organ dysfunction and multiorgan failure has also been described in association with AORPA due to a steal away from the aorta into the anomalous aortic pulmonary artery (PA) branch which triggers a low diastolic pressure and consequently a reduction in coronary perfusion which normally takes place in diastole.[26,42]

Older children and adolescents (≥ 2 years and < 18 years) tend to present with cyanosis, dyspnoea and rarely congestive cardiac failure and recurrent lower respiratory tract infections (Table 2.4, Table 2.5 and Figure 2.2). The dyspnoea is due to the development of pulmonary hypertension. Survival into late childhood and adolescence may occur in patients with right ventricular outflow tract obstruction (RVOTO) and reduced pulmonary blood flow when associated with tetralogy of Fallot (TOF).[29-30,59-64] Patients with TOF develop unilateral pulmonary hypertension in the lung perfused from the aorta whereas the unaffected lung is protected by the pulmonary stenosis. Patients that are not protected by pulmonary stenosis and have other cardiac lesions with left to right shunts into the PA with a normal origin, have increased pulmonary blood flow and the possible development of severe bilateral pulmonary hypertension.

Adults (≥ 18 years) tend to present with progressive exertional dyspnoea, self-limited or recurrent haemoptysis, cyanosis and rarely congestive cardiac failure associated with right heart failure secondary to severe pulmonary hypertension (Table 2.6 and Figure 2.2). Differential cyanosis may be present in patients with severe PHT and secondary right to left shunting across shunts such as patent ductus arteriosus which may be coexistent.

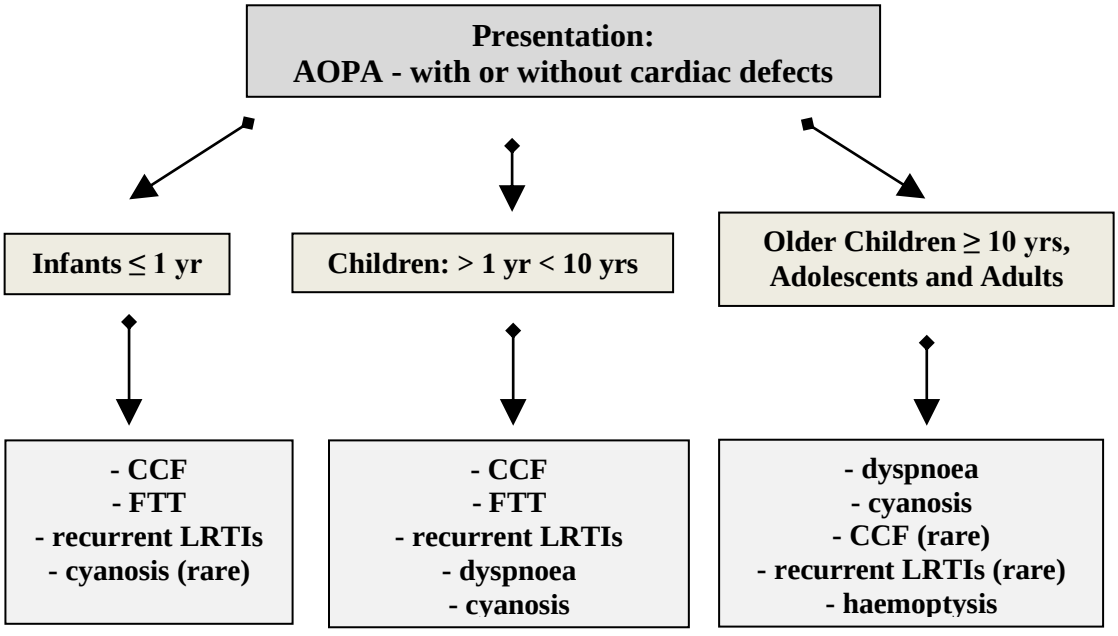

Figure 2.2: Clinical Presentation in infants, children, adolescents and adults

Table 2.4: Clinical Characteristics and Demographics of AOPA cases diagnosed at age ≥ 2 years and < 10 years					
Year; Author	**Age (yrs); Sex**	**Presentation**	**Diagnosis**	**Mode of diagnosis**	**Cardiac defects Associated**
1974; Menzer et al[48]	9 ; F	Cyanosis	AORPA	Angiography	Tricuspid atresia
1981; Duncan et al[49]	2 ; -	Cyanosis	AOLPA	Angiography	TOF
1987; Lo et al[50]	7 ; F 8 ; F	No details	AORPA AORPA	ECHO	PDA PDA
1988; Kutsche et al[2]	5 ; M 5 ; F	No details	AOLPA AOLPA	Surgery, Autopsy	TOF, Aberrant RSCA
1989; Fong et al[3]	2.2 ; - 2.1 ; -	Cyanosis	AOLPA AORPA	Angiography	TOF
1998; Abu-Sulaiman et al[4]	3.2 ; -	CCF	-	ECHO, Angiography	-
1990; Sasaki et al[51]	3 ; F	Cyanosis	AOLPA	Angiography	TOF
2007; Nathan et al[6]	2 ; -	CCF	AORPA	Angiography	PDA
2010; Pepeta et al[13]	6.5 ; M	Cyanosis	AOLPA	Angiography	TOF
2011; Jayan et al[52]	7 ; M	Cyanosis, Dyspnoea	AORPA	Angiography	PDA
2012; Sun et al[53]	2 ; M	Recurrent LRTIs	AOLPA	ECHO	TOF, APW
2012; Garg et al[10]	3 ; M 6 : F 7 ; M 8 ; F	Cyanosis	AORPA AOLPA AORPA AORPA	ECHO, Angiography	TOF
2013; Talwar et al[54]	6; F	Recurrent LRTIs, Fatigability	AORPA	Angiography	VSD
2013;Tantiwo-ngkosri et al[55]	9 ; M	Cyanosis	AOLPA	ECHO	VSD
2015; Vazquez et al[56]	6 ; M 7 ; F	- Dyspnoea	AORPA AORPA	ECHO ECHO	AS -
2014 Talwar et al[30]	2.8 ; F 3 ; M 3.5 ; M 5 ; M	Cyanosis	AOLPA AORPA AOLPA AORPA	ECHO, Angiography	TOF
2014; Liu et al[39]	2.9 ; M	Cyanosis, CCF	AORPA	ECHO	TOF
2015; Wang et al[24]	3 ; M 6 ; F 7 ; M	No details	AORPA	ECHO	APW, IAA, PDA PDA PDA
2015; Cho et al[57]	2 ; -	Cyanosis	AOLPA	ECHO, Angiography	TOF with APVS

Table 2.5: Clinical Characteristics and Demographics of AOPA cases diagnosed at age ≥ 10 years and < 18 years					
Year; Author	**Age; Sex**	**Presentation**	**Diagnosis**	**Mode of diagnosis**	**Cardiac defects associated**
1978; Gula et al[59]	13 yrs; F	Dyspnoea	AORPA	Angiography	APW
1993; Py et al[60]	12 yrs; -	Cyanosis, Dyspnoea	AOLPA	-	TOF
2000; Solyu et al[61]	14 yrs; F	Cyanosis, Dyspnoea	AOLPA	ECHO, Angiography	TOF
2008; Cheng et al[62]	10 yrs; M	Cyanosis, CCF	AOLPA	Angiography	TOF
2008; Kuinose et al[63]	16 yrs; F	-	AORPA	Angiography	PDA
2012; Garg et al[10]	13 yrs; F	Cyanosis	AOLPA	ECHO	TOF
2012; Dwivedi et al[64]	12 yrs; M	Dyspnoea, Cyanosis	AOLPA	Angiography	TOF
2014; Talwar et al[30]	13 yrs; M	Cyanosis	AORPA	ECHO	TOF
2015; Vazquez et al[56]	10 yrs; F	Cyanosis	AORPA	ECHO	PDA
2015 Mathur et al[29]	16 yrs; F	Dyspnoea	AOLPA	Angiography, CT Angio	TOF

2.4 Pulmonary hypertension

Severe pulmonary hypertension is present in the majority of the case series with almost 100% of the cases demonstrating systemic to suprasystemic pulmonary pressures (Table 2.7). The high pulmonary pressures occurs in both lungs due to exposure of both pulmonary arteries to a high aortic pressure in the case of the AOPA and increased pulmonary blood flow contributed to by a left to right shunt in the other PA. Other aetiologic mechanisms for the pulmonary hypertension include increased circulating vasoconstrictor substances, neurogenic crossover from the affected pulmonary artery and lung to the opposite side, and severe left ventricular failure.[17,80] Histological pulmonary vascular disease changes may develop as early as infancy and may vary from mild vascular changes to severe pulmonary vascular disease involving both lungs.[1,3-4,82-83]

Origin stenosis of the anomalous pulmonary artery restricts flow resulting in protection of the affected lung from developing severe pulmonary hypertension and pulmonary vascular obstructive disease.[10,29-30,39,74] There are only two cases of adult patients with AOLPA recorded that showed normal or only slightly raised

pressures in the unaffected lung.[68,77] One of the cases was a 19 year old male with an isolated AOLPA associated with a right aortic arch who presented with recurrent episodes of hemoptysis and exertional dyspnoea and on cardiac catheterization was found to have normal pressures in the RV and right atrium (RA) and systemic pressures in the left pulmonary artery.[77] Severe pulmonary hypertension will eventually result in right heart failure, congestive hepatopathy, liver cirrhosis and death if untreated.

2.5 Diagnosis

Early diagnosis and prompt surgery, good perioperative and postoperative care in infancy is crucial to prevent the high morbidity and mortality associated with AOPA.[5,8] Right ventricular (RV) dysfunction may be associated with AOPA and is associated with increased morbidity and mortality but can often resolve with surgical correction.[6,44,47]

Although diagnosis may be difficult, delayed or missed, there are several clues which can assist in making the diagnosis. These pointers towards the diagnosis include indicators within the medical history as well as various clinical signs and symptoms. Confirmation of AOPA can be made using specialized imaging modalities. The first diagnosis of TOF associated with AOLPA was made intraoperatively and unfortunately the attempt at surgical repair was unsuccessful.[84]

Historically many of the early reported cases were made post-mortem. Keane et al in 1974 reported that the diagnosis of 23 cases (46%) out of the 50 cases reviewed, including the first reported case of AOPA associated with APW, were made at autopsy.[1] On the whole, the diagnosis of AOPA is delayed because many of the clinical signs and symptoms and most of the immediately available diagnostic modalities such as chest X-ray (CXR) show features that are not specific to the diagnosis of AOPA. AOPA has been shown to masquerade as cyanotic congenital heart disease (CHD) such as TGV and coarctation of the aorta.[42-43]

The diagnosis should be strongly suspected if there is unexplained, persistent refractory PHT associated with congestive cardiac failure (CCF), absence of structural intracardiac defects and poor visualization of the normal main pulmonary artery bifurcation on echocardiography.[23,35-36,52]

Table 2.6: Clinical Characteristics and Demographics of AOPA cases diagnosed in adults > 18 years of age

Year; Author	Age; Sex	Presentation	Diagnosis	Mode of diagnosis	Cardiac defects
1868; Frantzel al et[7]	25 yrs; F	Dyspnoea, Edema	AORPA	Autopsy	APW
1957; Caro et al[65]	23 yrs; M	Hemoptysis, Dyspnoea	AORPA	Angiography	PDA
1974; Keane et al[1]	21 yrs; F	Hemoptysis, Dyspnoea CCF, Cyanosis	AORPA	Angiography	PDA
1978; Purcaro et al[17,46]	43 yrs; M	No details	AOLPA	No details	TOF
1987; Lo et al[50]	34 yrs	No details	AORPA	Angiography	TOF, PDA
1987; Rosa et al[66]	28 yrs; M	Hemoptysis, Dyspnoea	AORPA	CT scan, Angiography	PDA
1991; Sechtem et al[67]	32 yrs; F	Hemoptysis, Dyspnoea Chest pain	AOLPA	MRI, Angiography	PDA
1993; Prasad et al[68]	23 yrs; M	Hemoptysis	AOLPA	Angiography	-
1993; Mittal et al[69]	20 yrs; M	No details	AOLPA	No details	-
1994; Igarashi et al[70]	43 yrs; F	Cyanosis	AORPA	Angiography	PDA
1996; Edasery et al[71]	40 yrs; M	Dyspnoea, Cyanosis	AORPA	Angiography, MRI	PDA
2000; Rangel et al[72]	26 yrs; F	Dyspnoea	AORPA	ECHO, Angiography	PDA
2006; Wu et al[27]	25 yrs; M	Hemoptysis, Dyspnoea	AORPA	MRI, Angiography	PDA
2007; Patel et al[28]	36 yrs; M	Dyspnoea	AORPA	Angiography	TOF
2009; Long et al[14]	23 yrs; F	Dyspnoea, Cyanosis	AORPA	ECHO, Angiography	PDA
2010; Herren et al[73]	20 yrs; M	Hemoptysis	AOLPA	CT Angio, MRI, Angiography	-
2010; Nikolaidis et al[74]	41 yrs; F	Hemoptysis, Dyspnoea	AORPA	CT scan, Angiography	-
2011; Talwar et al[75]	25 yrs; F	Dyspnoea, Cyanosis	AORPA	CT Angio, Angiography	ASD
2013; He et al[76]	20 yrs; M	Hemoptysis	AORPA	ECHO, CT Angio	PDA
2014; Nigam et al[77]	19 yrs; M	Hemoptysis, Dyspnoea	AOLPA	ECHO, CT Angio, Angiography	-
2014; Talwar[30]	18 yrs; M	Cyanosis	AORPA	ECHO, CT Angio	TOF
2014; Khajali et al[78]	20 yrs; M	Cyanosis	AORPA	ECHO, CT Angio	APVS
2014; Haywood et al[79]	33 yrs; M	Hemoptysis, Dyspnoea	AORPA	CT Angio, Angiography	PDA
2015; Kim et al[80]	41 yrs; F	Dyspnoea	AORPA	CT scan	PDA
2015; Anathakrishna et al[81]	23 yrs; M	Dyspnoea, Cyanosis	AORPA	CT Angio, Angiography	TOF

Table 2.7: Pulmonary Hypertension, Associated Cardiac defects and Outcomes in AOPA cases series (n = ≥ 7)					
Year; Author	**Number of cases**	**PHT n (%)**	**Age < 1 yr n (%)**	**Cardiac defects**	**Mortality n (%)**
1998; Abu-Sulaiman et al[4]	16	10 (63%)	-	PDA, VSD, ASD, CoA, TOF, APVS	4 (25%)
2007; Nathan et al[6]	16	16 (100%)	15 (94%)	PDA, VSD, AS, PS	1 (6.3%)
2008; Kajihara et al[25]	8	8 (100%)	8 (100%)	PDA, ASD, CoA	0 (0%)
2010; Erdem et al[5]	7	7 (100%)	7 (100%)	PDA, APW, IAA	0 (0%)
2010; Amir et al[35]	12	12 (100%)	12 (100%)	PDA, VSD, CoA	0 (0%)
2012; Garg et al[10]	17	10 (59%)	9 (53%)	PDA, VSD, ASD, TOF	1 (5.9%)
2015; Liu et al[39]	11	11 (100%)	6 (55%)	PDA, VSD, APW, ASD, TOF, IAA	1 (9%)
2015; Cho et al[57]	12	12 (100%)	10 (83%)	PDA,TOF/APVS, VSD, ASD, CoA, PA/VSD/MAPCAs	1 (8.3%)

2.5.1 Electrocardiography (ECG)

Electrocardiographic (ECG) findings are often nonspecific and may be affected by associated cardiac defects and include P-pulmonale or P-mitrale, right ventricular hypertrophy (RVH), left ventricular hypertrophy (LVH) or biventricular hypertrophy (BVH).

2.5.2 Chest X-ray (CXR)

CXR as a non-invasive imaging tool may show specific features that could suggest the diagnosis of AOPA. These features include an increased cardiothoracic ratio (CTR) due to enlargement of the cardiac chambers and a prominent pulmonary artery segment suggestive of pulmonary hypertension. Features more suggestive of AOPA include an asymmetric pulmonary vascularity pattern with increased pulmonary blood flow to the affected lung and oligaemia in the opposite lung. This finding may be more evident in patients with associated right ventricular outflow tract obstruction such as TOF.[10,83] AOPA with associated significant left to right shunts show bilateral increased pulmonary vascularity greater in the affected lung supplied by the anomalous pulmonary artery.

2.5.3 Echocardiography (ECHO)

Echocardiography (ECHO) as the only non-invasive modality has proved to be very accurate in the diagnosis of AOPA both prenatally and postnatally. It is, however, operator-dependent and poor acoustic imaging windows in older patients may lead to a missed diagnosis. The use of echocardiography to diagnose AOPA in TOF is reliable in experienced hands, but cardiac catheterization and angiography may be needed to further define the anatomy.[10,30,57]

The most important diagnostic transthoracic echocardiographic (TTE) views include parasternal long and short axis, suprasternal long axis, subcostal and apical long axis views. AOPA can resemble other congenital heart defects on the intial echocardiographic screen and in particular should be differentiated from conotruncal anomalies such as truncus arteriosus, transposition of the great vessel (TGV), aortopulmonary window (APW), unilateral absent pulmonary artery (UAPA), interrupted aortic arch (IAA) and pulmonary atresia with ventricular septal defect (PA/VSD). AOPA may be recognized by the presence of two concordant ventricular outflow tracts and semilunar valves, an abnormal bifurcation of the main pulmonary artery with an apparent absence of one of the branch pulmonary arteries.[24,85-86] Further evaluation may show an anomalous pulmonary artery branch in continuity with the ascending aorta. Other suggestive TTE features include continuous Doppler flow into the anomalous pulmonary artery branch originating from the ascending aorta and reversal of flow in the descending aorta and aortic arch due to aortic run-off (back flow) into the anomalous branch pulmonary artery. In premature neonates, because of the high incidence of patent ductus arteriosus, the diagnosis may be delayed and missed if there is AORPA associated with a large patent ductus arteriosus (PDA). The PDA can easily be misinterpreted as the other pulmonary artery branch in the short axis view.[34,36] It has been suggested that echocardiography without additional cardiac catheterization can also be used to guide corrective surgery especially in infants who are unlikely to develop irreversible PHT with a very high pulmonary vascular resistance (PVR) > 8 Wood Units per square meter (WU/m^2).[44,50]

2.5.4 Fetal ECHO

Fetal echocardiography allows for early diagnosis and preparation immediately postnatally for early surgical correction, thus avoiding the early development of pulmonary hypertension. The first fetal echocardiographic diagnosis of AOPA was described at 21 weeks of gestation using the three vessel view.[88] The earliest reported fetal echocardiographic diagnosis of AOLPA associated with tetralogy of Fallot (TOF) and right aortic arch was made at 19 weeks of gestation and confirmed on postnatal echocardiography and cardiac computed tomography.[87] In another case report, the diagnosis of AOLPA and TOF with absent pulmonary valve syndrome (APVS) was made on prenatal echocardiography at 38 weeks of gestation allowing for early postnatal one-stage surgical correction within five weeks after birth.[89] Absence of the expected normal MPA bifurcation on fetal ECHO should warrant a careful and thorough search for the anomalous pulmonary artery.

2.5.5 Neonatal diagnosis

Diagnosis of AOPA in premature neonates has been achieved as early as 4 days in one patient and an extremely low birth weight of 780 grams resulting in surgical correction within 2 weeks (Table 2.2).[31,33,35] AOPA in neonates if associated with complex cardiac lesions such as IAA, CoA or hypoplastic aortic arch and APW can been accurately diagnosed on ECHO.[37,90]

2.5.6 Other diagnostic modalities

In the current era, when diagnosis is uncertain and there are suspected associated complex cardiac defects, other non-invasive and invasive imaging modalities such as computerized tomography scan (CT scan) or CT Angiography (CT Angio), MRI (magnetic resonance imaging) or magnetic resonance angiography (MRA), catheterization angiography or cine angiography can be utilized.[9,66-67,92-97] Although there is a risk of exposure to radiation, CT angiography is a noninvasive imaging tool which can provide additional information and clearer anatomy of the associated anomalies such as aortic arch and coronary anomalies for preoperative planning. Magnetic resonance imaging (MRI) and magnetic resonance angiography (MRA) are expensive imaging modalities but have the superior advantage of evaluating the anatomy and function of the vascular and cardiac structures but may not be readily available.[97] Although cardiac catheterization is invasive and requires hospitalization, it may be necessary to assess the pulmonary pressures, the reversibility of the pulmonary hypertension and to estimate the pulmonary vascular resistance index (PVRi) in each of the lungs.[30] In addition, angiography during catheterization may assist the diagnosis. An ascending aortogram will show the presence of the anomalous pulmonary artery arising from the ascending aorta and the main pulmonary angiogram will show the origin of only one branch pulmonary artery. In patients with severe pulmonary hypertension (PHT), an indexed pulmonary vascular resistance calculation (PVRi) and a pulmonary vascular reactivity test should be determined to assess the reversibility of pulmonary hypertension (PHT) and the risk for surgical correction.[30,44,98] Based on assumptions of oxygen consumption and the requirement for the separate calculations of the pulmonary blood flow and pressures in each lung, estimation of the PVRi may be inaccurate especially in the anomalous pulmonary artery. Cardiac MRI may be helpful to estimate the the pulmonary blood flow to each lung separately allowing for a more accurate calculation of PVR in each lung.[30] PVRi is usually expected to be high in both lungs unless there is significant unilateral origin stenosis of one of the branch pulmonary arteries or associated TOF.

2.6 Associations

AOPA may occur in isolation or associated with other common and rare congenital heart defects (Table 2.8). Congenital cardiac defects with increased pulmonary blood flow and left to right shunts that are most commonly associated with AOPA include PDA, VSD and APW, while TOF is the most common associated cardiac defect with decreased pulmonary blood flow. Coarctation of the aorta (CoA) and interrupted aortic arch (IAA) are the more common left ventricular outflow tract obstruction lesions associated with AOPA. Other commonly associated lesions include a PDA in 75% of patients with AORPA and TOF found in 74% of patients diagnosed with AOLPA.[2] Keane et al in a 1974 review of 50 cases of AOPA showed that 76% of the cases were associated with a PDA, while Fontana et al in their 1987 analysis of 65 cases with AORPA confirmed a 68% association with a PDA.[1,8] In general, AORPA is reportedly more commonly associated with a PDA and a left aortic arch while AOLPA is

more commonly associated with TOF and right aortic arch.[10,30] Cases of isolated AOPA without intracardiac defects in association with right aortic arch have been described more commonly in patients with AOLPA.[2,68-69,73-74] Of the 42 case reports describing patients with AOLPA up until 1999, two-thirds (75%) were associated with cardiac defects and 100% of those with isolated AOLPA were associated with right aortic arch.[15] The incidence of AOPA associated with TOF was reported in two large surgical case series of 2235 patients and 5241 patients as 0.21% and 0.4% respectively.[30,99] Age of presentation may provide clues to the type of AOPA and the associated cardiac defects. The most common associated cardiac defect found in premature neonates and adults (≥ 18 years) is patent ductus arteriosus (PDA), while TOF is more commonly described in older children and adolescents (≥ 10 years and < 18 years) (Table 2.2, 2.4 and 2.6).

The CATCH 22 syndrome (22q11 deletion) has been described frequently in patients with isolated AOPA or more frequently in combination with other conotruncal cardiac defects such as IAA, TOF, pulmonary atresia with VSD (PA/VSD). Consequently screening of patients with AOPA for the 22q11 deletion is recommended.[25-26,31,107-109] Berry syndrome which is an intricate aortopulmonary malformation which includes interrupted aortic arch, a distal aortopulmonary septal defect and intact interventricular septum has AORPA as part of the complex and has been described in several case reports and case series.[24,92,111-113]

Table 2.8: Associations - Cardiac defects or anomalies and Non-cardiac conditions

Cardiac defects				Non-cardiac
Left to Right shunts	**RVOTO**	**LVOTO**	**Others**	**Syndromes**
PDA[1-2,6,9,24]	TOF[1-4,9-10,19,28-30,51,60]	CoA[4,9,25,37]	Ebstein's anomaly[32]	CATCH 22[25-26,31,107-109]
VSD[2,4,6,9-10,54]	PA/VSD with or without MAPCAs[13,57]	IAA[5,9,39,101]	DORV[91,103]	Fetal valproate syndrome[110]
APW[4,7,9,53,90]	TOF with APV syndrome[4,78,85,89,100]	Mitral and aortic atresia[102]	ALCAPA[104]	Berry syndrome[24,92,111-113]
ASD[9-10,24,38]	Tricuspid atresia[48]	AS[6]	Cortriatriatum[105]	
	PS [11,17]		PAPVD[106]	
			Aberrant SCA[3,9,25-26,114]	
			Absent RICA[115]	

2.7 Treatment and Outcomes

2.7.1 Pharmacological treatment

The role of pharmacological treatment is temporary and involves treatment of the congestive cardiac failure (CCF), cardiogenic shock, and severe PHT while maintaining normal systemic pressures to reduce right to left shunting across the associated cardiac defects. Medical and supportive treatment targeting the cardiorespiratory system may include diuretics, digoxin/lanoxin or intravenous inotropes, non-invasive or invasive ventilation, selective and non-selective vasodilators such as inhaled nitric oxide (iNO) and sildenafil for severe symptomatic PHT. High concentrations of oxygen may need to be avoided because a dramatic reduction in pulmonary pressures may exacerbate the left to right shunting across intracardiac shunt lesions and increase flow within the anomalous pulmonary artery. There may be a role for left ventricular assist devices and extracorporeal membrane oxygenation preoperatively and postoperatively for severe refractory pulmonary hypertension (PHT), congestive cardiac failure (CCF) and cardiogenic shock.

2.7.2 Surgical treatment

Surgical re-implantation of the anomalous pulmonary artery at the time of diagnosis is the treatment of choice with or without cardiopulmonary bypass (CPB) depending on the presence of associated intracardiac cardiac defects that may also need repair. The first successful correction of AOPA was accomplished by graft interposition in a 12 month old male with AORPA associated with a PDA and severe pulmonary hypertension (PHT) diagnosed on angiography in 1961.[117] The current surgical procedure of choice is direct implantation of the anomalous pulmonary artery into the main pulmonary artery, which was first described in 1967.[118] Direct implantation has been used successfully as the preferred surgical technique in the majority of the surgical case series thus far (Table 2.9). Single institutional surgical experiences of large groups of 12 to 17 patients over a period of 17 to 36 years have reported an early mortality of between 0% to 25%.[4,6,10] The largest surgical single series using direct implantation over a period of 17 years reported a mortality of 5.9%.[10]

Neonates

Early successful surgical correction has even been reported in premature babies within 2 weeks of life. The smallest patient corrected was born with birth weight of 780 grams.[31,33,35] Very early surgical correction in neonates within the first week of life has been achieved resulting in complete resolution of the pulmonary hypertension.[25,35,41-43] The youngest neonate with successful surgical repair was described in a 2 day old neonate weighing 2.8 kg initially misdiagnosed clinically to have coarctation of the aorta (CoA).[42] Surgical correction of the AOPA most often results in an improvement of right ventricular dysfunction caused by pulmonary hypertension.[6,42,47]

Infants and young children

Surgical correction of the AOPA and associated cardiac defects has been reported to result in complete resolution of PHT in infants and young children (≥ 2 years and < 10 years). Nathan et al reported a single institutional surgical case series of 16 patients over a period of 24 years with an operative mortality of 6.3% and a 20 year survival of 93%.[6] There was no postoperative mortality in the two surgical case series of infants reported in 2010 by Erdem et al and Amir et al.[5,35] Recently, Liu et al described surgical correction of AOPA without artificial or homologous grafts in infants and the postoperative mortality was reported as 9%.[39] Surgical correction of AOPA and associated cardiac defects was accomplished in 81% of the young children with a postoperative mortality of 6.5% (Table 2.4).

Older children, adolescents and adults

Although surgical correction of AOPA in older children, adolescents and adults pose a high risk because of established severe PHT and risk of advanced pulmonary vascular disease, it is possible in carefully selected cases. Surgery was perfomed in cases of older children (≥ 10 years and < 18 years) shown in Tables 2.5 and 2.10, with a survival of 100%. Eight adult cases (32%) underwent surgery and 13 cases (52%) were deemed inoperable because of severe PHT and suspected advanced pulmonary vascular disease (Table 2.6 and 2.10).

Surgical techniques

Other surgical techniques that have been used if direct implantation is not feasible and include: interposition with an autologous pericardial graft, a synthetic graft, a homograft patch reconstruction and an endogenous aortic and/or main pulmonary artery flaps to increase the length of the anomalous pulmonary artery branch and reduce the risk of tension, kinking or stenosis at the anastomotic site.[4,16-17,39,119-121] The use of an autologous graft has an added advantage of allowing future growth compared to synthetic graft or a homograft which may need replacement in the future to relieve a stenosis at the anastomotic site.[37,39,122]

A two stage surgical approach surgery may be required in patients with complex associated cardiac defects either because of increased risk of morbidity and mortality associated with a one stage repair or a failed pulmonary reactivity test necessitating an initial pulmonary artery banding (PAB) of the anomalous pulmonary artery to restrict pulmonary blood flow.[30,98] A high surgical mortality has also been reported in patients with protected lungs. The mortality reported in two of the large case series of TOF associated with AOPA was 16.7% to 18.2%.[10,30]

Surgical complications

Reimplantation of the anomalous pulmonary artery may be complicated early post surgery or late, by stenosis at the surgical pulmonary artery anastomotic site. Supravalvar aortic stenosis related to the excision of the anomalous pulmonary vessel from the aorta has also been described. Any residual aortic or pulmonary stenotic lesion may be treated surgically or with balloon angioplasty with/or without stent placement.[9,25-26,121-123] The stenosis at the pulmonary artery anastomotic site may vary from mild to severe, or critical and can be detected on echocardiography (ECHO), computed tomography scan (CT scan), angiography or magnetic resonance imaging (MRI).[4,14,123] The incidence of pulmonary stenosis has been reported to be between 0% and 46%.[17,39] Other rare complications reported include torsion of the re-implanted anomalous right pulmonary artery, complete occlusion of the re-implanted pulmonary artery branch and thrombosis of the synthetic graft at the anastomotic site if the pulmonary artery branch is small in size prior to surgery.[6,122,124-125]

2.7.3 Follow up

Careful follow up should include reassessment of the pulmonary artery pressures in patients with pulmonary artery hypertension (PHT). Early or late surgical complications related to the anastomotic site can be detected using echocardiography, computerized tomography angiography and magnetic resonance imaging.[24,34,119-121] In a single-center retrospective review of long-term outcomes of surgically repaired AOPA and pulmonary atery slings reported the development of pulmonary stenosis in 74% of cases over 5 years post surgery and a median time from surgical repair to diagnosis of pulmonary artery stenosis of 0.4 years.[123] Cardiac catheterization, although invasive may be necessary to review post-operative pulmonary artery pressures or as a therapeutic tool for catheter interventions to treat surgical complications requiring balloon angioplasty or stenting.[5-6,10,57] Post-operative ventilation-perfusion (V/Q) scans although less effective than echocardiography in detecting the presence of pulmonary artery stenosis may be used as a screening tool to assess for differential perfusion of the lungs.[34,57,119,121]

Table 2.9: AOPA surgical case series with ≥ 5 cases					
Year; Author	**Cases; Study period**	**Age, mean/ median/range; ≤ 1yr (n,%)**	**Cardiac defects associated**	**Surgical technique**	**Mortality n (%)**
1987; Benatar et al[10]	5; 10 yrs	Mean, 7.2 months; (4; 80%)	PDA	Direct implantation	1 (20%)
1994; Nonoyama et al[114]	8; -	Mean, 19 months; (2; 3%)	PDA, ASD, TOF with APVS	Direct implantation, Graft	2 (25%)
1998; Abu-Sulaiman et al[4]	16; 36 yrs	Median, 1 month; -	PDA, ASD, VSD, TOF with APVS, CoA	Direct implantation, Graft (14 cases: surgery)	3 (21%)
2003; Prifti et al[16]	8; 11 yrs	Median, 1.2 months (8; 100%)	VSD, TOF, ASD	Direct implantation, Graft, Aortic flap	1 (12.5%)
2004; Peng et al[26]	9; 29 yrs	Median, 0.9 months (9; 100%)	PDA Aberrant RSCA	Direct implantation	0 (0%)
2005; Levy et al[119]	5; 5 yrs	Mean, 3 months (4; 80%)	IAA, APW, VSD TOF with APVS	Grafts	1 (20%)
2007; Nathan et al[6]	16; 24 yrs	Median, 0.4 months; (15; 94%)	PDA, TOF, ASD	Direct implantation, Graft	1 (6.3%)
2008; Kajihara et al[25]	8; 19 yrs	Mean, 1.2 months; (8; 100%)	PDA, ASD, CoA	Direct implantation, Graft	0 (0%)
2010; Erdem et al[5]	7; 6 yrs	Range, 4-84 days; (7; 100%)	PDA, IAA, APW	Direct implantation	0 (0%)
2010; Amir et al[35]	12; 20 yrs	Median, 0.5 months (12; 100%)	PDA, VSD, CoA	Direct implantation	0 (0%)
2012; Garg et al[10]	17; 17 yrs	Median, 7 months; (9; 53%)	PDA, TOF, VSD, ASD	Direct implantation, Graft	1 (5.9%)
2014; Vazquez et al[56]	5; 20 yrs	Median, 6 years (2; 40%)	PDA, AS	Direct implantation	1 (20%)
2014; Talwar et al[30]	11; 20 yrs	Mean, 73 months; (2; 18%)	TOF	Direct implantation, Graft	2 (18.2%)
2014; Liu et al[39]	11; 5 yrs	Mean, 12.7 months; (6; 55%)	PDA, TOF, VSD, ASD, IAA, APW	Direct implantation, Aortic flap Graft	1 (9%)
2015; Cho et al[57]	12; 23 yrs	Median, 1.8 months; (10; 83%)	PDA, TOF with APVS, VSD, ASD, CoA, PA/VSD/MAPCA	Direct implantation, Graft (pericardial)	1 (8.3%)
2015; Liu et al[9]	19; 6 yrs	Median, 3 months; (12; 63%)	PDA, ASD, VSD, APW, TOF, CoA	Direct implantation (14 cases: surgery)	0 (0%)
2015; Xie et al[58]	6; 2 yrs	Median, 3.3 months (6; 100%)	PDA, VSD, ASD	Direct implantation	0 (0%)

Table 2.10: Summary of Surgery and Outcomes in Preterm infants, Children ≥ 2 years and < 18 years, Adults ≥ 18 years with AOPA (Tables 2.2, 2.4, 2.5 and 2.6)	
Patient Characteristics	**Values, n (%)**
Surgery:	
Preterm	n = 10
Yes	10 (100%)
No	0
Children ≥ 2 yrs and < 10 yrs	n = 31
Yes	25 (81%)
No	4 (13%)
No details	2 (6%)
Children ≥ 10 yrs and < 18 yrs	n= 10
Yes	10 (100%)
No	0
Adults ≥ 18 yrs	n= 25
Yes	8 (32%)
No	13 (52%)
No details	4 (16%)
Outcomes:	
Preterm	n = 10
Survived	9 (90%)
Died	1 (10%)
Children ≥ 2 yrs and < 10 yrs	n = 31
Survived	27 (87%)
Died (postoperative)	2 (6.5%)
No details	2 (6.5%)
Children ≥ 10 yrs and < 18 yrs	n= 10
Survived	10 (100%)
Died	0
Adults ≥ 18 yrs	n= 25
Survived	24 (96%)
Died (postoperative)	1 (4%)

PART 3: MAJOR REPORT/MANUSCRIPT

CHAPTER 1: METHODS

3.1.1 Study Design:

This is a retrospective descriptive study of patients diagnosed with anomalous pulmonary artery from the ascending aorta (AOPA) at a tertiary care institution in a developing country.

3.1.2 Study Population:

Children (birth to < 18 years) and adults (≥ 18 years) diagnosed with AOPA between April 1990 to April 2015 were included.

3.1.3 Study Setting:

Chris Hani Baragwanath Academic Hospital, a public tertiary care institution. There are no on site cardiothoracic surgical services and limited paediatric intensive care facilities for ventilation. There were two full time Paediatric Cardiologists until 2012 and Paediatric Anaesthetic services in the catheterization laboratory were not available until 2014.

3.1.4 Data Collection/Procedures:

Records of all patients with diagnosis of AOPA from the hospital files and computerized database at Paediatric Cardiology division at Chris Hani Baragwanath Academic Hospital were reviewed from April 1990 to April 2015.

The following demographics, clinical and diagnostic parameters were collected and analysed: age at presentation, sex, year seen, clinical presentation, nutritional status, diagnosis and time to diagnosis, associated cardiac lesions, chest X-ray (CXR), electrocardiography (ECG), echocardiography (ECHO), cardiac catheterization and cine-angiography, computerized tomography scan or angiography (CT scan or angiography), magnetic resonance imaging (MRI), magnetic resonance angiography (MRA), preoperative and postoperative care, surgery and outcomes such as death or survival.

Descriptive statistics were used for analysis due to the small patient numbers. A median and ranges were used to depict continuous variables while frequencies and percentages were used to describe categorical variables. The study protocol was approved by the Wits Human Research Ethics Committee (Medical, M140739) and the hospital review committee.

CHAPTER 2: RESULTS

3.2.1 Patient Demographics

Year of diagnosis and Sex (Table 3.2.1 and Graph 3.2.1)

A total of 17 patients as shown in Table 3.2.1 were diagnosed over 25 years with an average of one patient every 1.5 years. The majority of the patients (9/17; 52.9%) were diagnosed in the second decade of the study (Graph 3.2.1). Ten patients (58.8%) were male.

Table 3.2.1: Demographics, Characteristics and Clinical Presentation

Patient Number; Year seen	Sex	Age (days)	CCF	Resp. distress	Cyanosis
1; 1990	M	50	+	+	+
2; 1991	M	216	+	+	-
3; 1998	F	77	+	+	+
4; 1999	M	14	+	+	+
5; 2002	F	84	+	+	-
6; 2003	F	2 (Preterm)	+	+	-
7; 2003	M	3	+	+	-
8; 2004	F	13	+	+	+
9; 2005	M	101	+	+	-
10; 2006	M	242	-	+	+
11; 2007	F	84	+	+	+
12; 2009	M	13140 (Adult)	+	+	-
13; 2009	F	69	+	+	-
14; 2011	M	81	+	+	-
15; 2011	F	238	+	+	-
16; 2012	M	16	+	+	+
17; 2015	M	913	+	+	+

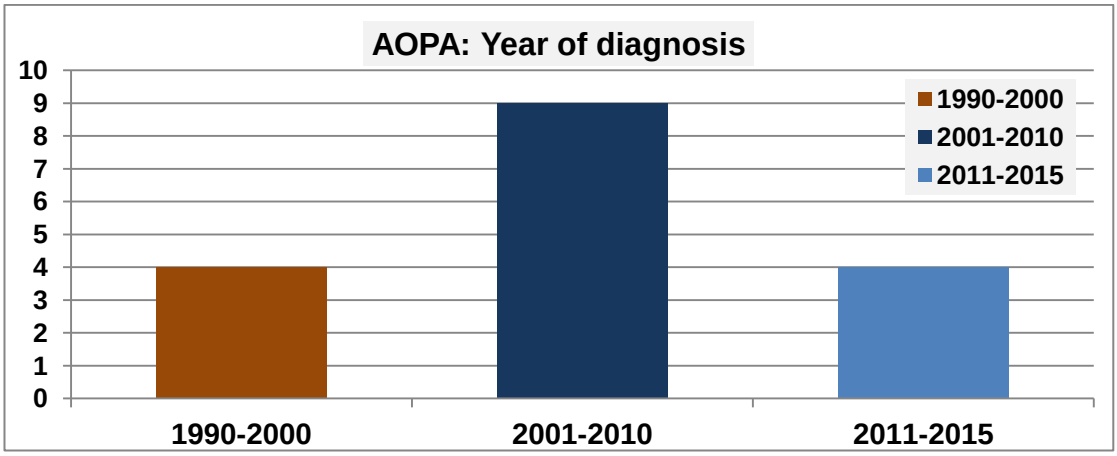

Graph 3.2.1: AOPA – Year of diagnosis

Age at presentation and study population (Table 3.2.1 and Graph 3.2.2)

The median age at presentation was 81 days (2 days - 36 years; interquantile range (IQR): 15 - 227). There were fifteen infants, one child and one adult (Graph 3.2.2). The two patients at the extreme ends of the age range were a premature neonate born at 34 weeks with birth weight of 1.8 kilograms (kg) who presented at the age of 2 days and an adult who presented at the age of 36 years. The remaining 15 patients included: four neonates (3-16 days), 10 infants (50-242 days) and one child at 2.5 years of age (Table 3.2.1).

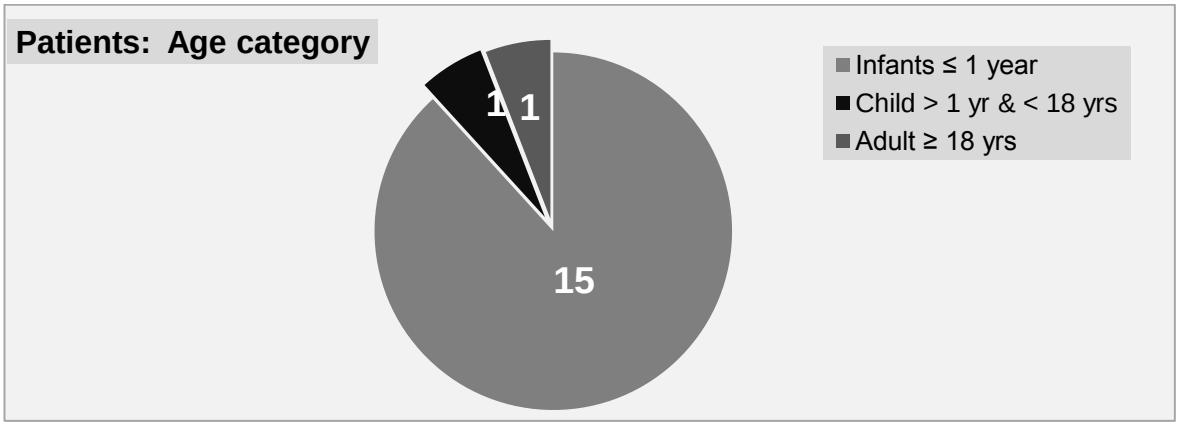

Graph 3.2.2: Patients age category - infants, a child and an adult

Nutritional Status and Growth Parameters (World Health Organization - WHO z - scores) (Table 3.2.2 and Graph 3.2.3)

The median weight at presentation (15/17, 88.2%) was 3.7 kg (1.8 - 62 kg; IQR: 3 - 6). Growth parameters were assessed in thirteen patients (n = 13) and six patients (6/13; 46.2%) had WHO weight-for-age z - score < -3 while ten patients (76.9%) had WHO weight-for-age z - score < -2. Seven patients (53.8%) had WHO length/height-for-age z - score < -2 and four of those patients had WHO

length/height-for-age z – score < -3. Five patients (38.5%) had WHO weight for length/height z - score < -2 and two of those patients had WHO weight for length/height z - score < -3. Growth parameters for two patients (no. 6 and 12), a premature neonate and an adult were not assessed as there were no appropriate growth standards or charts. In addition, no growth parameter data was available for patient no. 2 and 14 and these patients were also excluded from analysis.

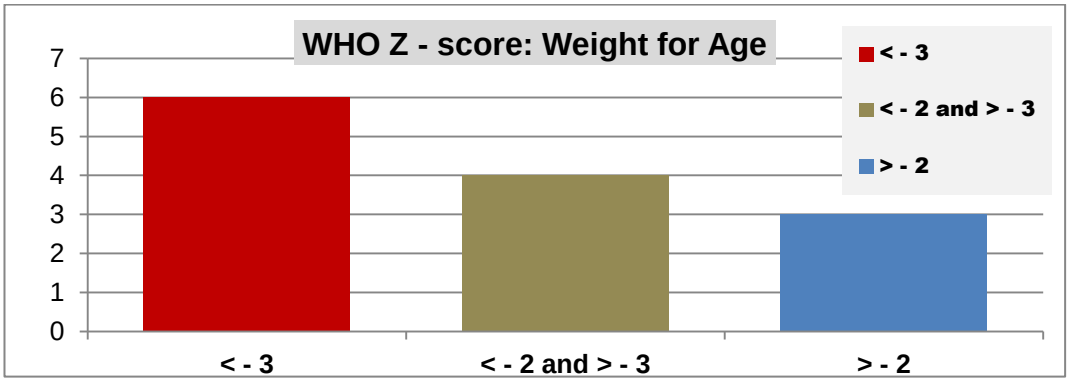

Graph 3.2.3: WHO Z- score, weight for age

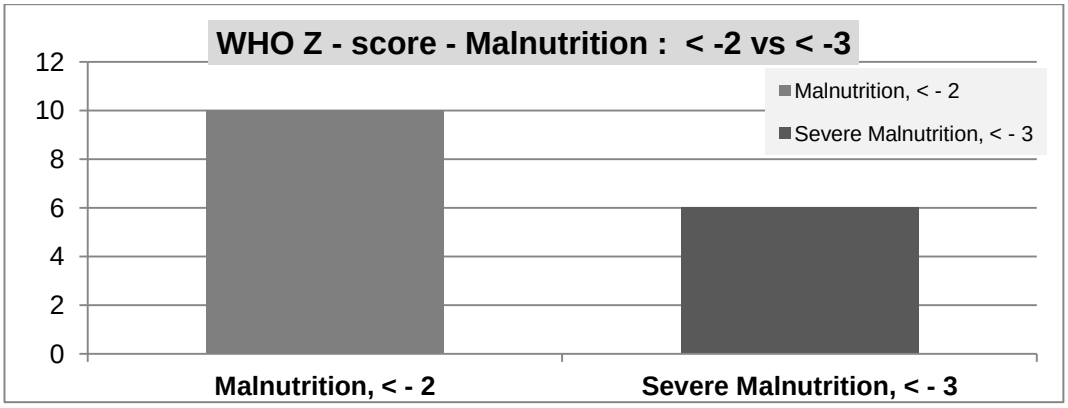

Graph 3.2.4: WHO Z- score - Malnutrition, < - 2 vs < - 3

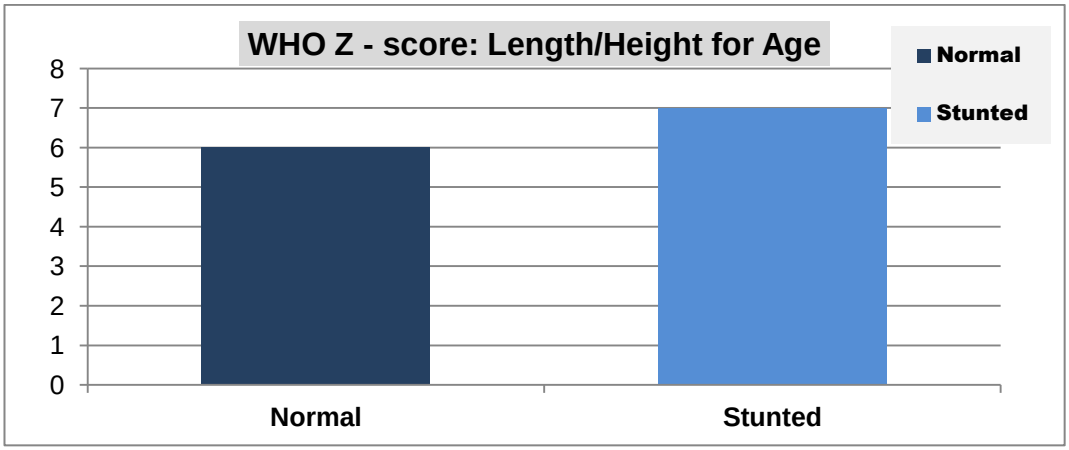

Graph 3.2.5: WHO Z- score, length/height for age

Table 3.2.2: Anthropometric and Growth parameters, World Health Organization (WHO) Z - scores					
Patient no.; Age (days)	**Weight (kg)**	**Height/Length (cm)**	**Wt for Age Z - score (actual)**	**Ht/Length for Age Z - score (actual)**	**Wt for Ht/Length Z - score (actual)**
1; 50	3	52	< -3 (-3.99)	-2 to -3 (-2.62)	-2 to -3 (-2.69)
2; 216	Data missing	Data missing	Data missing	Data missing	Data missing
3; 77	3.4	52	< -3 (-4.34)	< -3 (-4.00)	0 to -1 (-1.17)
4; 14	2.2	46	< -3 (-3.48)	< -3 (-3.32)	-1 to -2 (-1.92)
5; 84	3,7	57	< -3 (-3.06)	0 to -2 (-0.72)	< -3 (-3.64)
6; 2	1.8 (Prem)	-	-	-	-
7; 3	3.2	49	0 to -2 (-0.34)	0 to -2 (-0.74)	0 to -1 (-0.24)
8; 13	3.6	48	0 to -2 (-0.13)	0 to -2 (-1.76)	1 to 2 (2.03)
9; 101	4.4	58	< -3 (-3.35)	0 to -2 (-2.0)	-2 to -3 (-2.56)
10; 242	9	69	0 to 2 (0.43)	0 to -2 (-0.67)	1 to 2 (1.12)
11; 84	4	54	-2 to -3 (-2.36)	-2 to -3 (-2.04)	0 to -1 (-0.77)
12; 13140	62 (Adult)	-	-	-	-
13; 69	3.7	49	-2 to -3 (-2.80)	< -3 (-4.31)	1 to 2 (1.7)
14; 81	Data missing	Data missing	Data missing	Data missing	Data missing
15; 238	6	68	-2 to -3 (-2.28)	0 to -2 (-0.19)	-2 to -3 (-2.95)
16; 16	2.6	47	-2 to -3 (-2.28)	-2 to -3 (-2.51)	0 to -1 (-0.83)
17; 913	9	85	< -3 (-4.09)	< -3 (-3.72)	< -3 (-3.12)

3.2.2 Clinical presentation (Table 3.2.1 and Graph 3.2.4)

All patients (n = 17) presented with respiratory distress. As shown in graph 3.2.2, sixteen patients (94.1%) presented with congestive cardiac failure (CCF) and eight patients (47.1%) presented with cyanosis. Three patients (no. 12, 15 and 17) had a history of recurrent respiratory tract infections and murmurs were audible in fourteen patients (82.4%). Patient no. 5 presented with cardiogenic shock while patient no. 12 presented with a history of exertional dyspnoea, several episodes of self-limited haemoptysis, jaundice, anasarca and massive ascites.

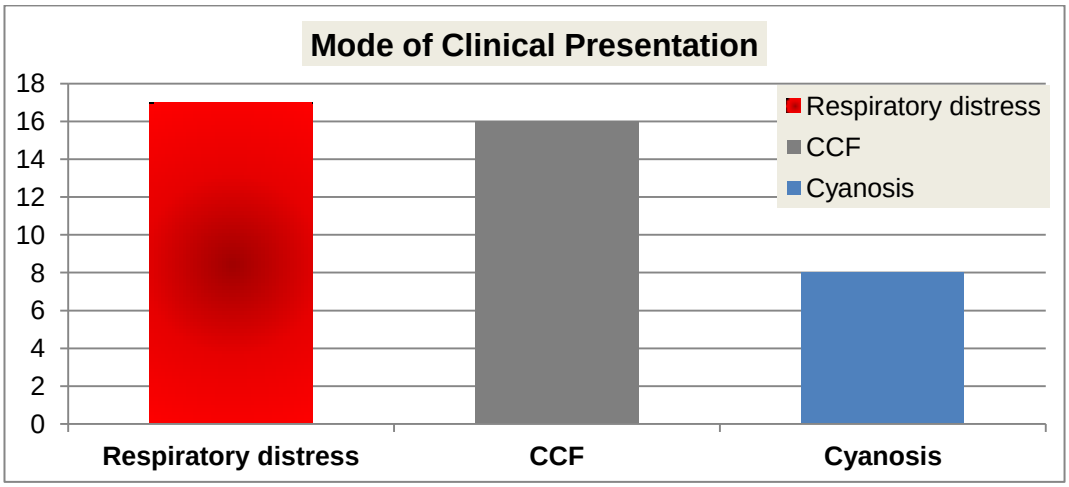

Graph 3.2.6: Major mode of clinical presentation (excluding murmurs)

3.2.3 Diagnostic Modalities

Chest Radiography (Chest X-ray, CXR): Figure 3.2.1, Figure 3.2.2 and Figure 3.2.3

Chest radiographs (n = 14) showed differential pulmonary vascularity with plethora in the affected lung perfused by the anomalous pulmonary artery and normal or relative oligaemia in the unaffected lung perfused by the normally connected pulmonary artery. The cardiothoracic ratio was increased in all representing cardiomegaly and the pulmonary artery segment was prominent, indicative of underlying pulmonary hypertension. One chest X-ray (patient no. 10) showed an absent pulmonary artery segment with boot-shaped heart (Figure 3.2.3).

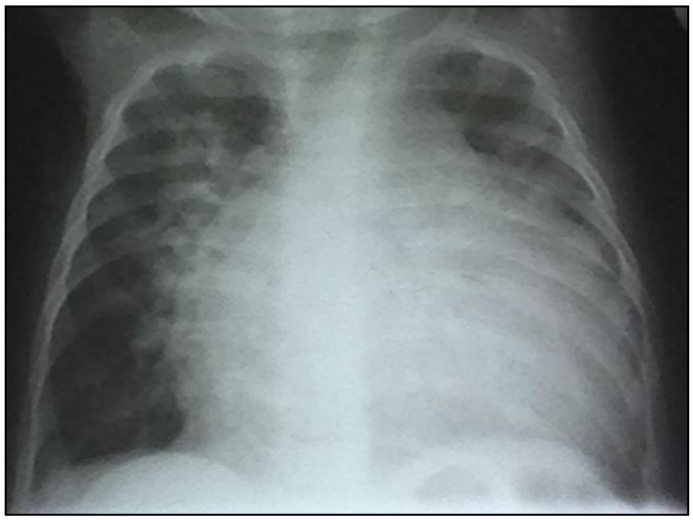

Figure 3.2.1: Chest X-ray in the anterior-posterior view (AP view), patient no.15 - shows differential pulmonary vascularity with plethora in the right lung and oligaemia in the left lung (left upper lobe). Cardiomegaly with cardiothoracic ratio (CTR) = 69% and left aortic arch.

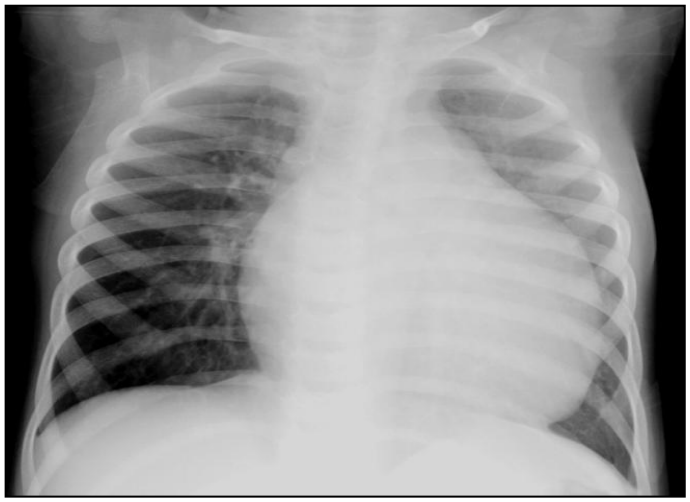

Figure 3.2.2: Chest X-ray in the anterior-posterior view (AP view), patient no.17 - shows differential pulmonary vascularity with prominent pulmonary vasculature in the right lung and paucity of the peripheral pulmonary vasculature suggestive of pruning. Cardiomegaly with cardiothoracic ratio (CTR) = 60% and left aortic arch.

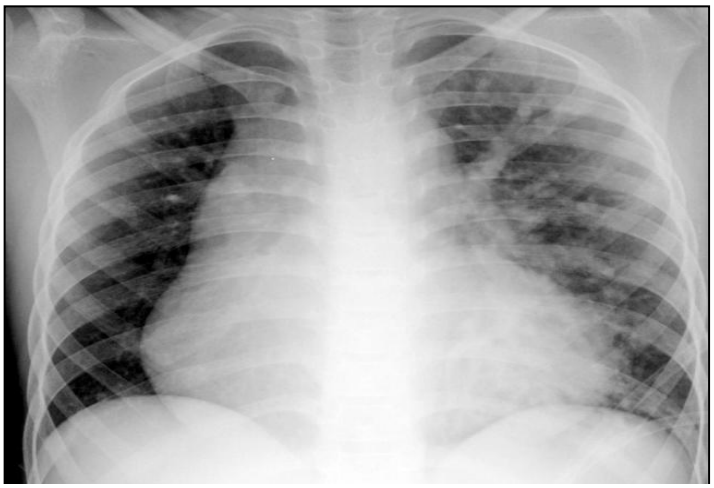

Figure 3.2.3: Chest X-ray in the anterior-posterior view (AP view), patient no.10 - shows differential pulmonary vascularity with oligaemia in the right lung and plethora in the left lung. Cardiomegaly with cardiothoracic ratio = 66% and left aortic arch.

Electrocardiography (ECG): Figure 3.2.4 and 3.2.5

Electrocardiographic changes (n = 15) included right axis deviation (RAD) with evidence of right atrial enlargement (P-pulmonale) and either right ventricular hypertrophy (RVH) or biventricular hypertrophy (BVH) in 12 patients (70.6%).

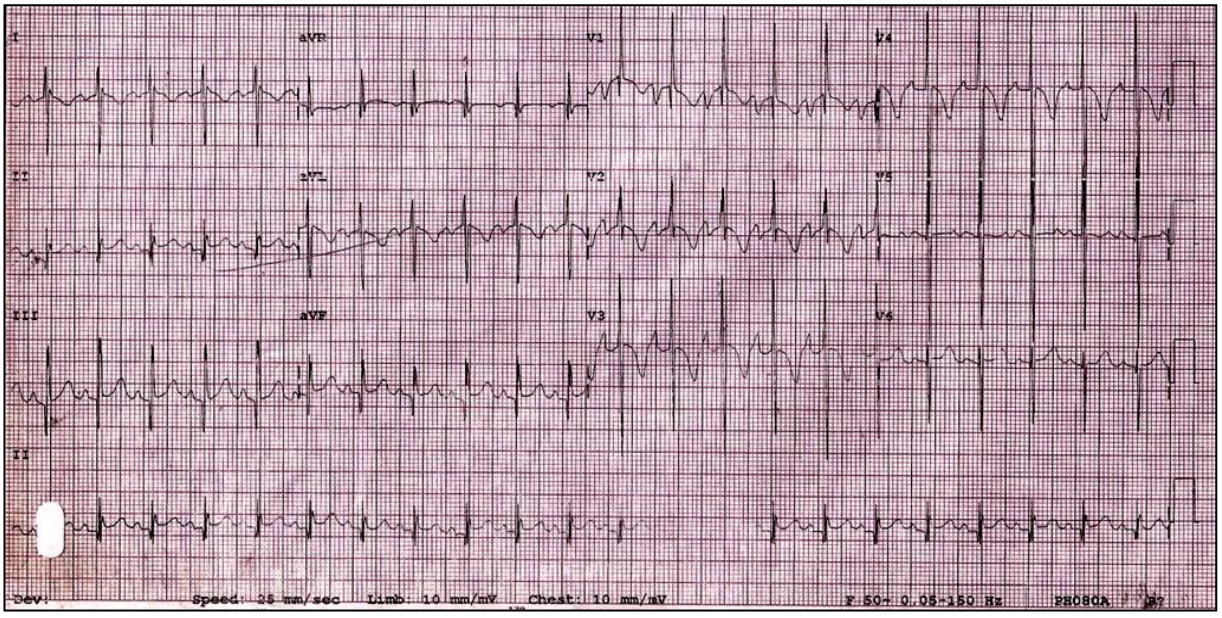

Figure 3.2.4: Electrocardiogram, patient no.15 - shows right axis deviation, right atrial enlargement (P-pulmonale) and right ventricular hypertrophy (RVH).

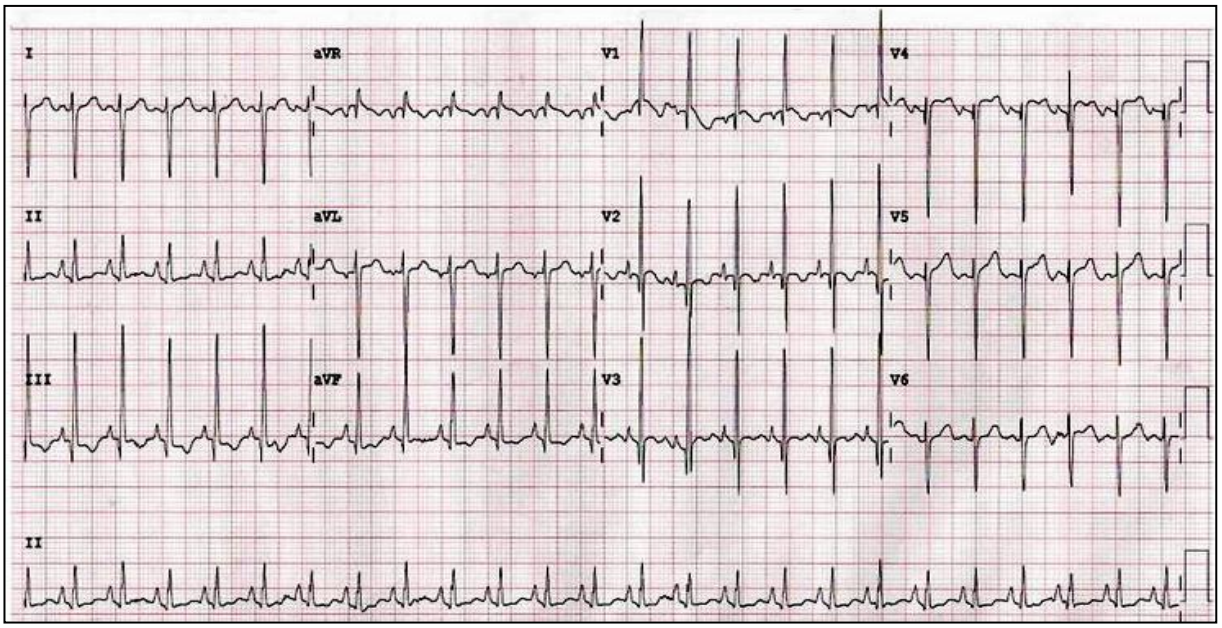

Figure 3.2.5: Electrocardiogram, patient no.17 - shows right axis deviation, right atrial enlargement (P-pulmonale) and right ventricular hypertrophy (RVH).

Transthoracic Echocardiography (TTE/ECHO): Figures 3.2.6 and 3.2.7; Figures 3.2.8 and 3.2.9; Figure 3.2.10, 3.2.11 and 3.2.12

The diagnosis was made using transthoracic echocardiography (TTE) in ten patients (59%). The suprasternal long axis, parasternal long axis and short axis views were the most useful echocardiaographic views in confirming the diagnosis.



Figure 3.3.6: Transthoracic echocardiography in the suprasternal long axis view, patient no.16 - shows anomalous right pulmonary artery **(asterisk)** from the proximal ascending aorta. There is a left aortic arch.

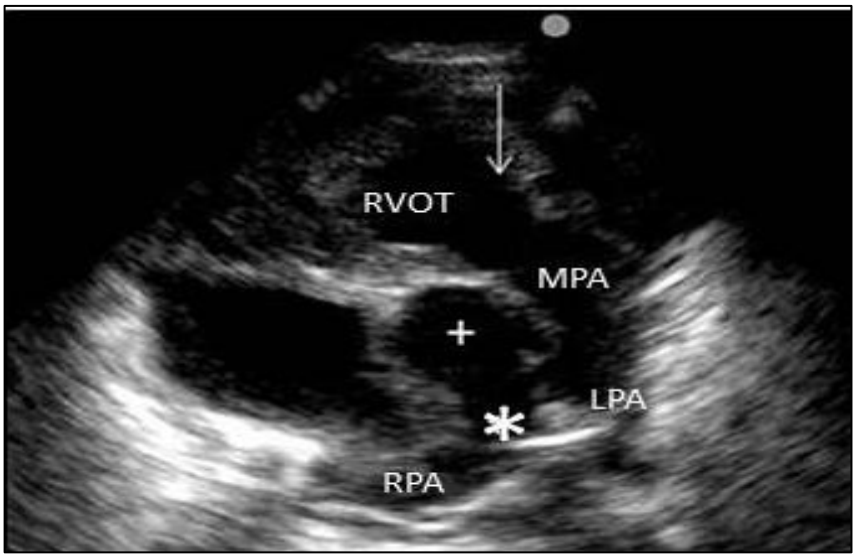

Figure 3.2.7: Transthoracic echocardiography in the parasternal short axis view, patient no.16 - shows anomalous right pulmonary artery **(asterisk)** from the posterior aspect of the ascending aorta **(cross)**. Normal relation of the great vessels without right ventricular outflow tract obstruction **(arrow)**.

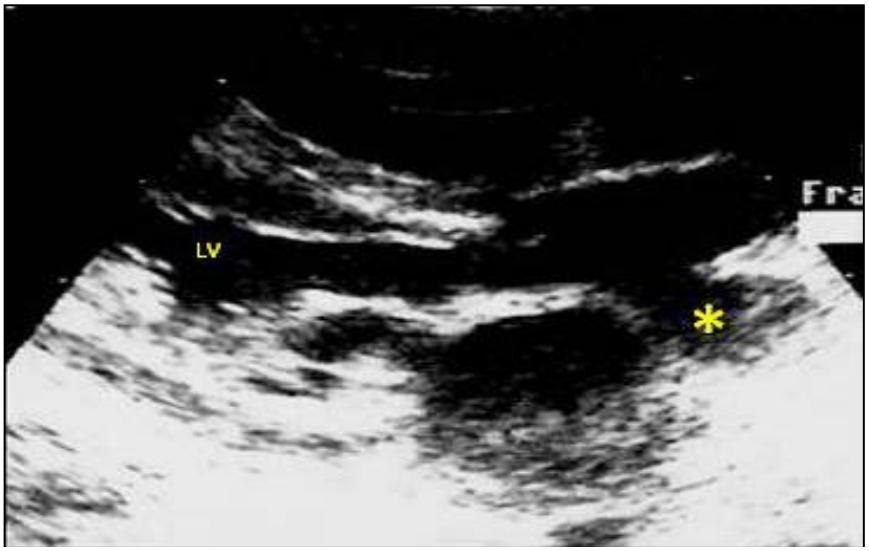

Figure 3.2.8: Transthoracic echocardiography in the parasternal long axis view, patient no.4 - shows anomalous left pulmonary artery **(asterisk)** from the proximal ascending aorta**.**

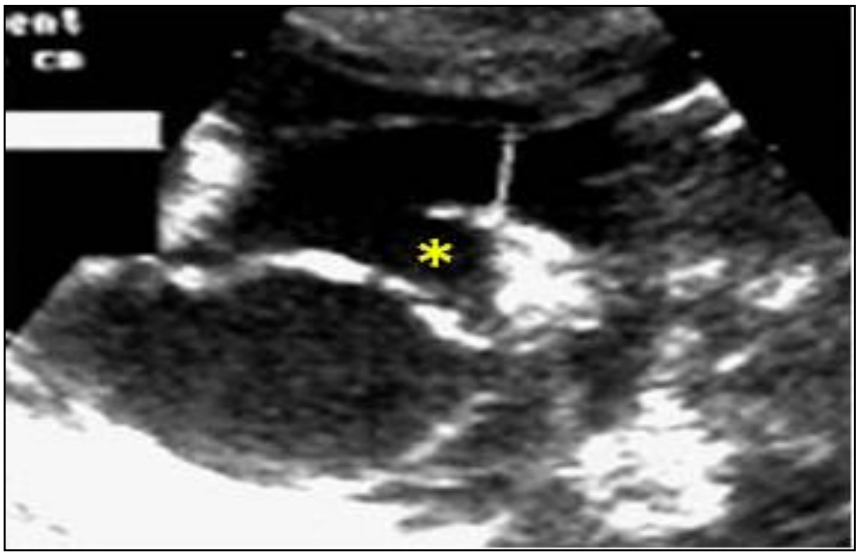

Figure 3.2.9: Transthoracic echocardiography in the suprasternal long axis view, patient no.4 - shows anomalous left pulmonary artery **(asterisk)** from the proximal ascending aorta and right aortic arch.

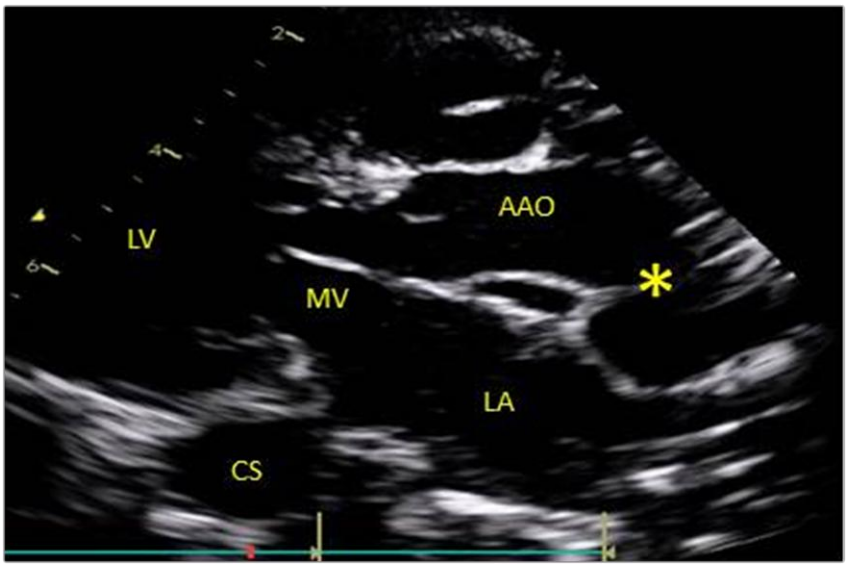

Figure 3.2.10: Transthoracic echocardiography in the suprasternal long axis view, patient no.17 - shows anomalous right pulmonary artery **(asterisk)** from the proximal ascending aorta**.**

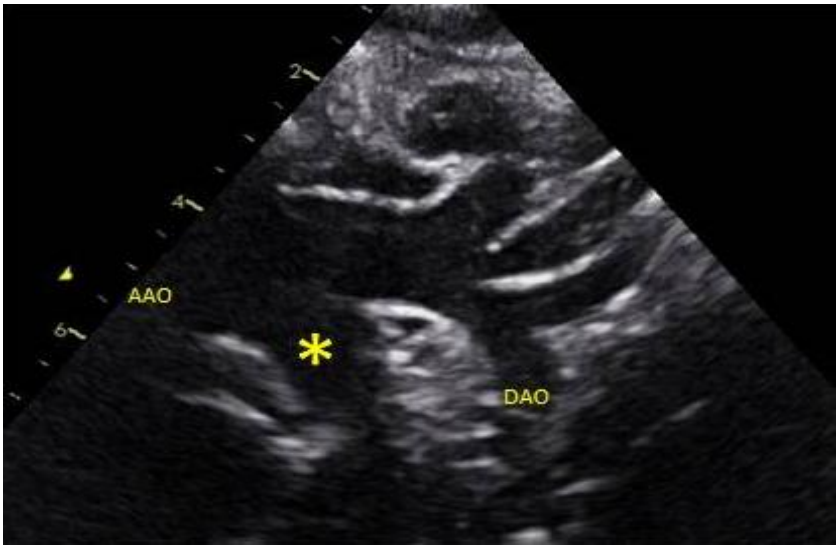

Figure 3.2.11: Transthoracic echocardiography in the parasternal long axis view, patient no.17 - shows anomalous right pulmonary artery **(asterisk)** from the proximal ascending aorta**.**

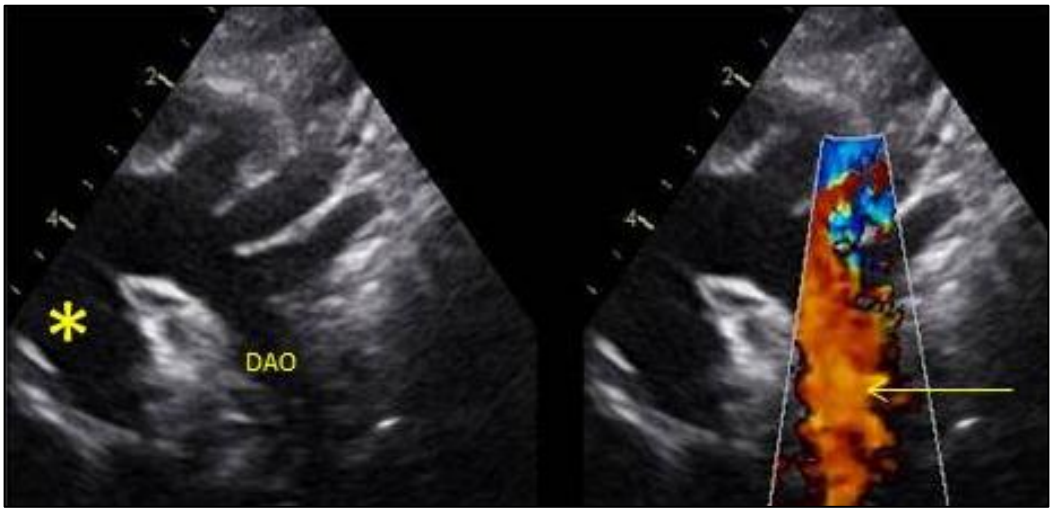

Figure 3.2.12: Transthoracic echocardiography in the suprasternal long axis view, patient no.17 - shows anomalous right pulmonary artery **(asterisk)** from the proximal ascending aorta**.** There is marked reversal or retrograde flow **(arrow)** in the descending aorta due to aortic run-off into the anomalous right pulmonary artery.

Computed Tomography scan or Angiography (CT scan/ CT Angio): Figures 3.2.13, 3.2.14, 3.2.15, 3.2.16, 3.2.17, 3.2.18 and 3.2.19

Computed tomography angiography (CT Angio) was done in four patients, diagnostic in patient no.12, confirmatory in patient no.10 and 15, and used as a postoperative follow up imaging tool in patient no.9.

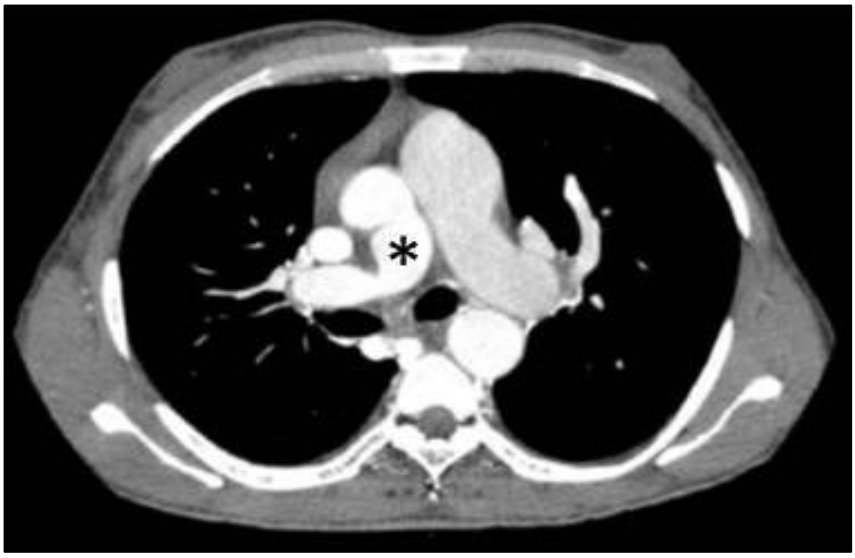

Figure 3.2.12: Computed tomography angiogram (CT Angio) in the axial view, patient no.12 - shows anomalous right pulmonary artery **(asterisk)** from the ascending aorta and normal connected left pulmonary artery from the main pulmonary artery. The main pulmonary artery and left pulmonary artery are dilated.



Figure 3.2.13: Computed tomography angiogram (CT Angio) in the sagittal view, patient no. 12 - shows the right pulmonary artery **(asterisk)** arising from the posterior aspect of the ascending aorta. No right pulmonary artery stenosis was visualized.

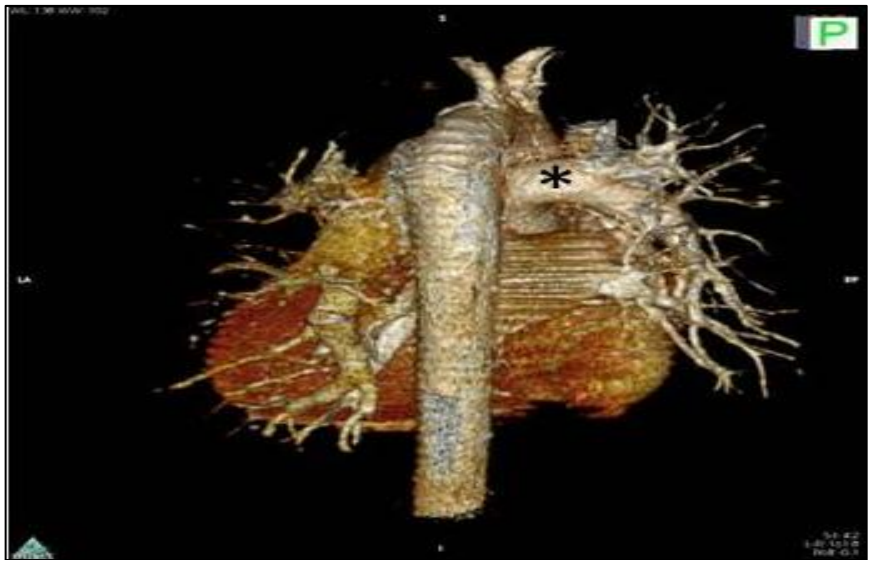

Figure 3.2.14: Computed tomography angiography (CT Angio) 3D reconstruction in the posterior view, patient no.12 - shows anomalous right pulmonary artery **(asterisk)** from the proximal, posterior aspect of the ascending aorta.

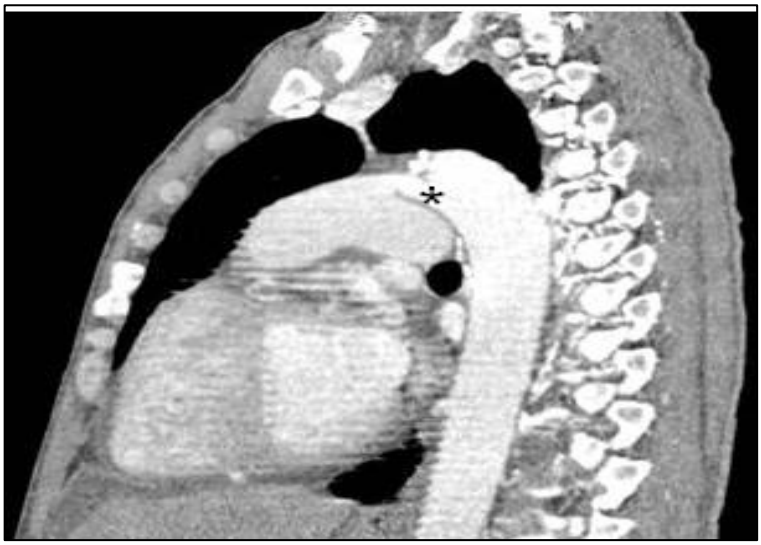

Figure 3.2.15: Computed tomography angiogram (CT Angio) in the sagittal view, patient no. 12 - shows large patent ductus arteriosus **(asterisk)** connecting the main pulmonary artery to the descending aorta.

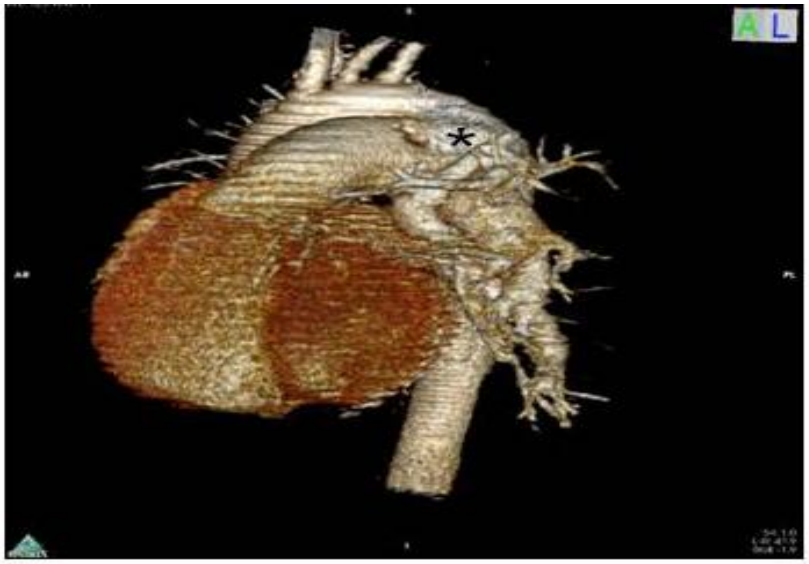

Figure 3.2.16: Computed tomography angiography (CT Angio) 3D reconstruction in the left lateral view, patient no. 12 - shows patent ductus arteriosus **(asterisk).**

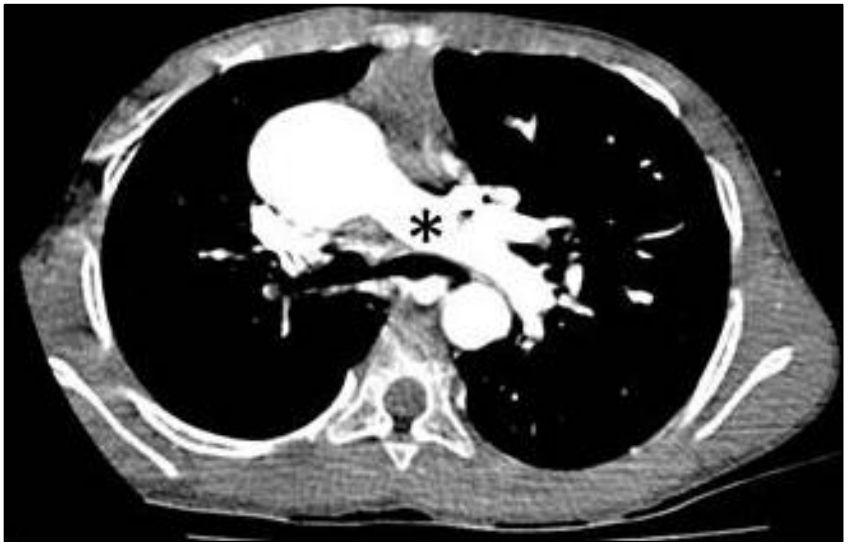

Figure 3.2.17: Computed tomography angiogram (CT Angio) in the axial view, patient no.10 - shows anomalous left pulmonary artery **(asterisk)** from a dilated ascending aorta. The main pulmonary and right pulmonary arteries are no depicted.

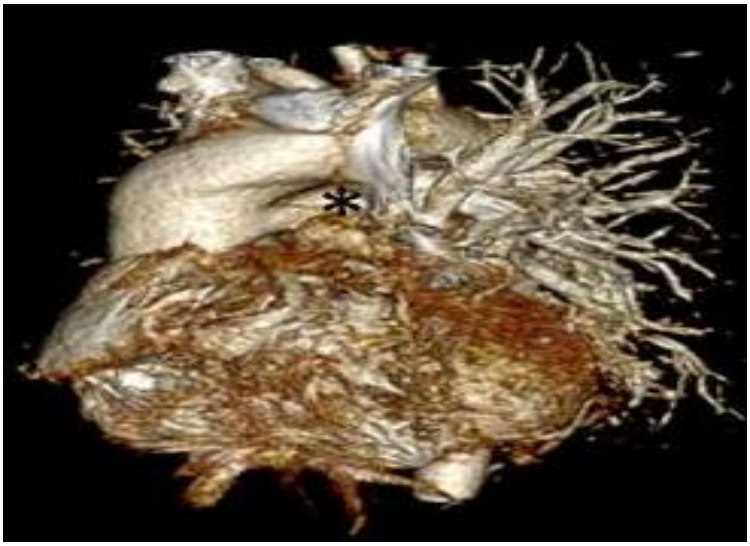

Figure 3.2.18: Computed tomography angiography (CT Angio) 3D reconstruction in the anterio-lateral left view, patient no.10 - shows anomalous left pulmonary artery **(asterisk)** from the posterior-lateral left aspect of the dilated ascending aorta. The main pulmonary and right pulmonary arteries are not depicted.



Figure 3.2.19: Computed tomography angiogram (CT Angio) in the axial view, patient no.9 - shows the re-implanted right pulmonary artery **(asterisk)** and no stenosis at the anastomotic site.

Cardiac Catheterization and Angiography: Figures 3.2.20, 3.2.21, 3.2.22, 3.2.23, 3.2.24, 3.2.25, 3.2.26, 3.2.27, 3.2.28, 3.2.29 and 3.2.30

Cardiac catheterization and angiography was done in nine patients (53%). It was diagnostic in six patients (35%) (patient no. 1, 2, 5, 10, 11 and 17) and confirmed the diagnosis of AOPA in three patients (patient no. 9, 12 and 15).

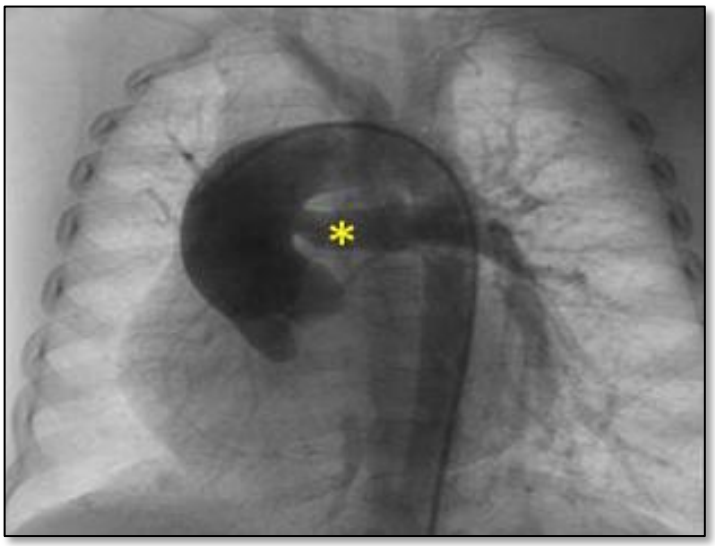

Figure 3.2.20: Aortogram in the lateral view, patient no.10 - shows anomalous left pulmonary artery **(asterisk)** arising from the posterior aspect of dilated ascending aorta**.**

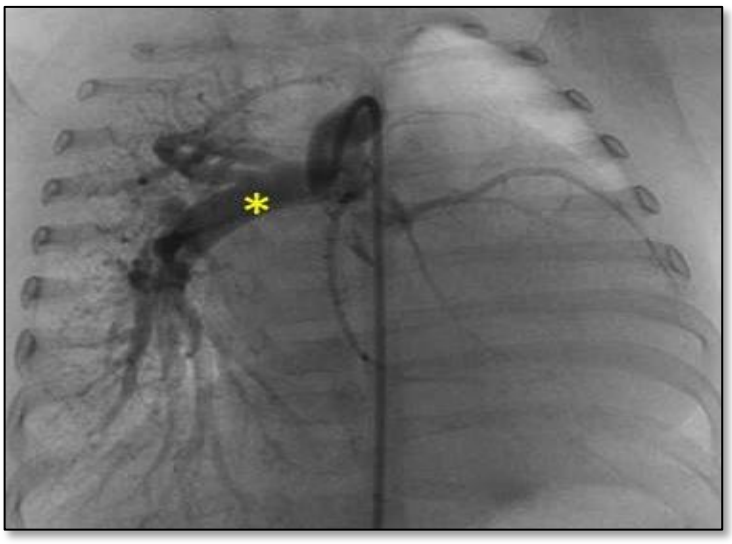

Figure 3.2.21: Aortogram in the anterio-posterior (AP) view, patient no.11 - shows anomalous right pulmonary artery **(asterisk)** originating from the ascending aorta**.**

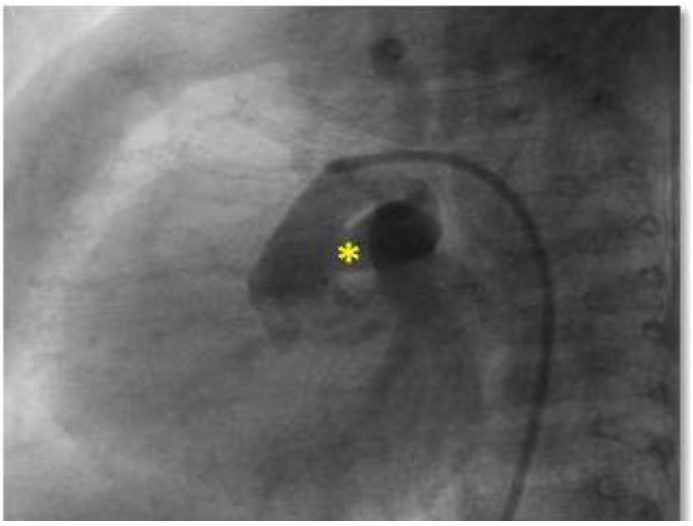

Figure 3.2.22: Aortogram in the lateral view, patient no.11 - shows anomalous right pulmonary artery **(asterisk)** arising from the ascending aorta**.**

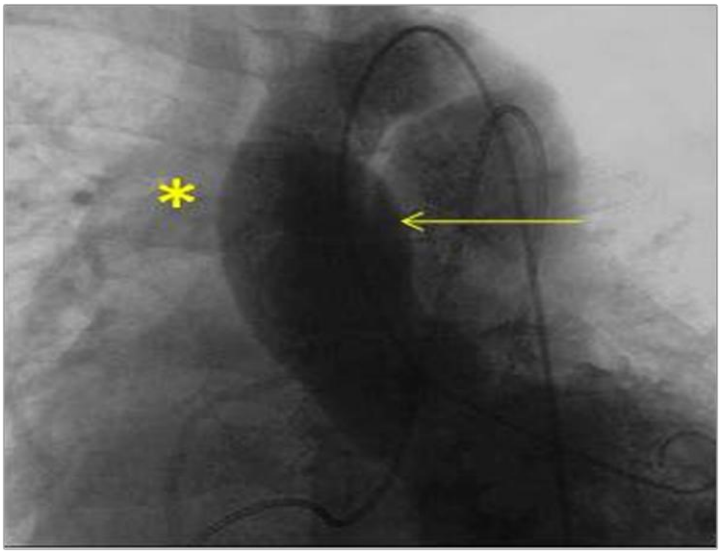

Figure 3.2.23: Ascending aortogram in the anterio-posterior (AP) view, patient no. 12 - shows right pulmonary artery from the ascending aorta **(asterisk and arrow).** No right pulmonary artery stenosis is visualized.

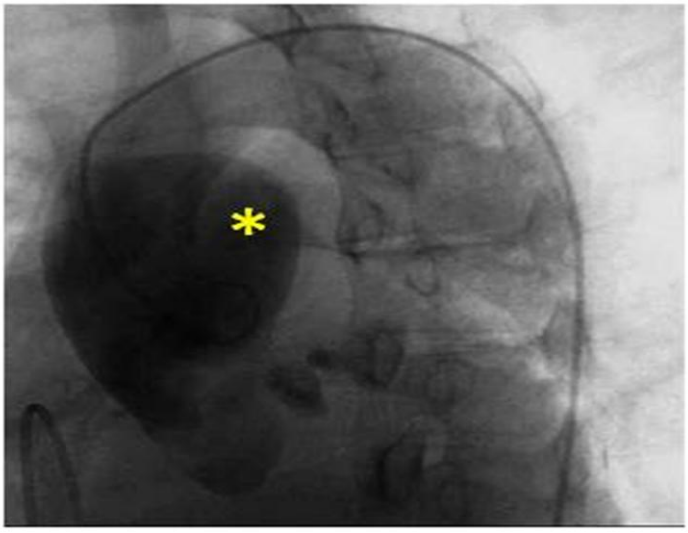

Figure 3.2.24: Ascending aortogram in the lateral view, patient no. 12 - shows the right pulmonary artery arising from the ascending aorta **(asterisk).** No right pulmonary artery stenosis is visualized.

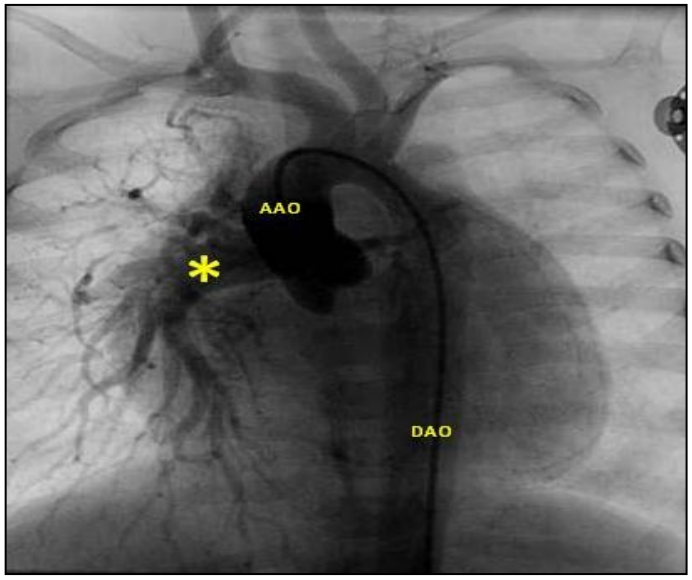

Figure 3.2.25: Aortogram in the anterio-posterior (AP) view, patient no.17 - shows the anomalous right pulmonary artery **(asterisk)** originating from the ascending aorta**.**

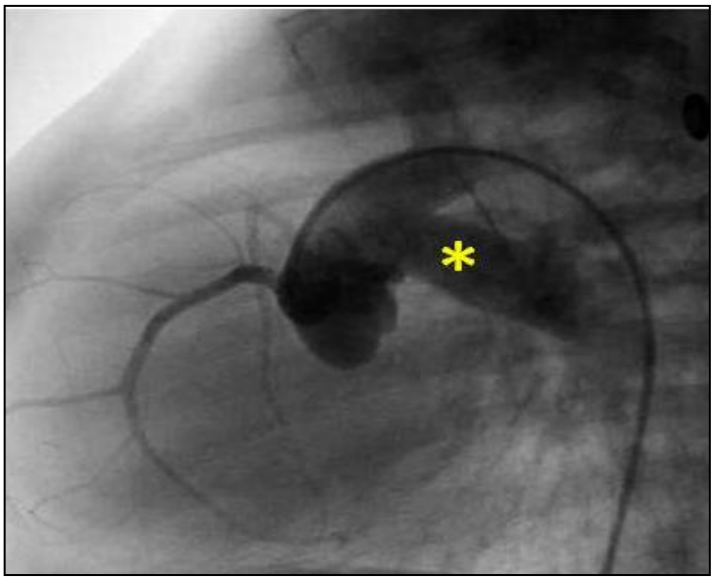

Figure 3.2.26: Aortogram in the lateral view, patient no.17 - shows the anomalous right pulmonary artery **(asterisk)** arising from the posterior aspect of the ascending aorta**.**

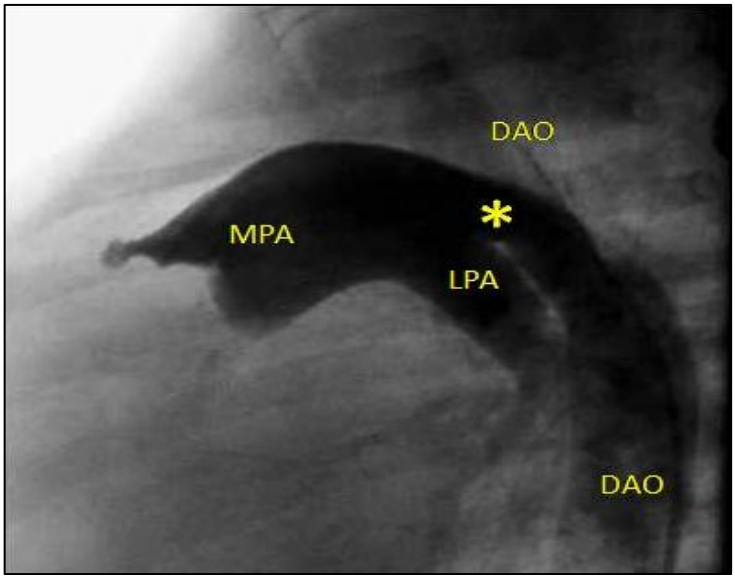

Figure 3.2.27: Descending aortogram in the lateral view, patient no.17 - shows large patent ductus arteriosus **(asterisk)** connecting the main pulmonary artery to the descending aorta.

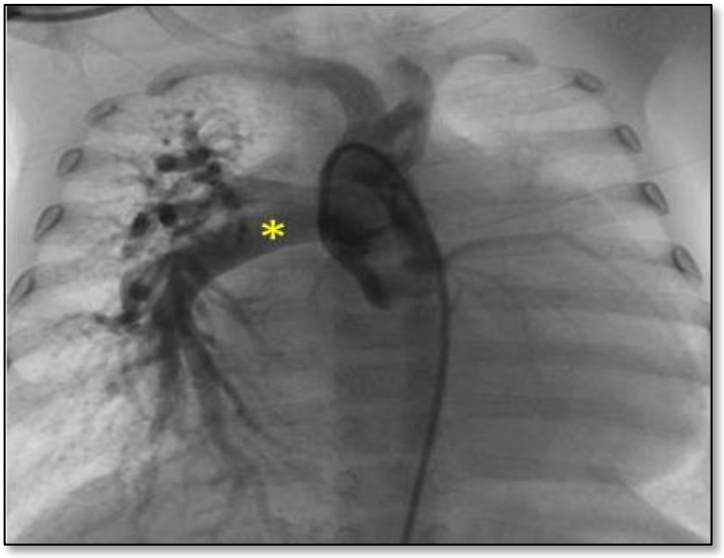

Figure 3.2.28: Aortogram in the anterio-posterior (AP) view, patient no.15 - shows anomalous right pulmonary artery **(asterisk)** arising from the ascending aorta**.**

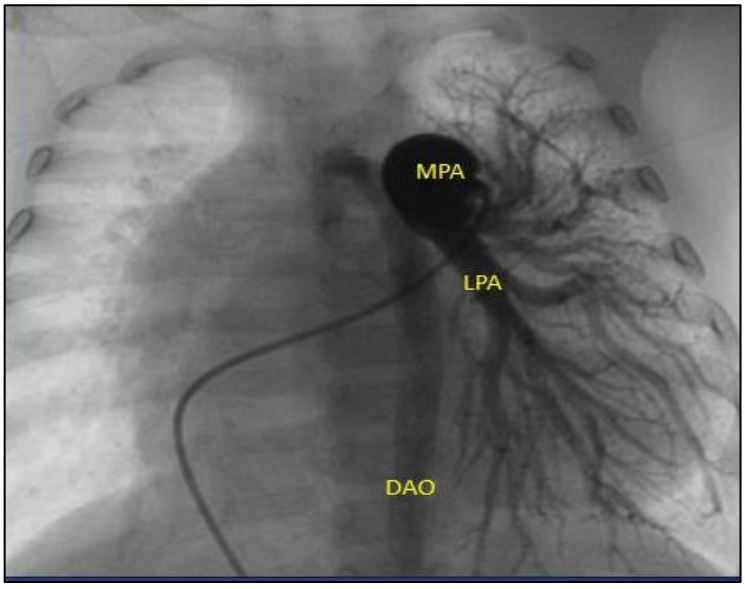

Figure 3.2.29: Pulmonary angiogram in the anterio-posterior (AP) view, patient no.15 - shows absent right pulmonary artery from the main pulmonary artery. Left pulmonary artery (LPA) is visualized coming off the main pulmonary artery (MPA). Contrast flow is visualized into the descending aorta (DAO) via the patent ductus arteriosus connecting the main pulmonary artery and the descending aorta.

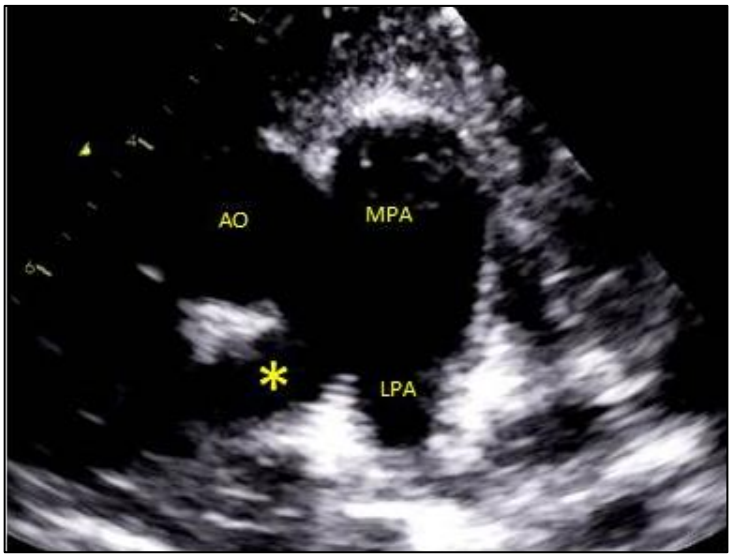

Figure 3.2.30: Transthoracic echocardiography in the short axis view post surgical re-implantation of the right pulmonary artery, patient no. 9 - shows patent right pulmonary artery **(asterisk)** with no stenosis or narrowing.

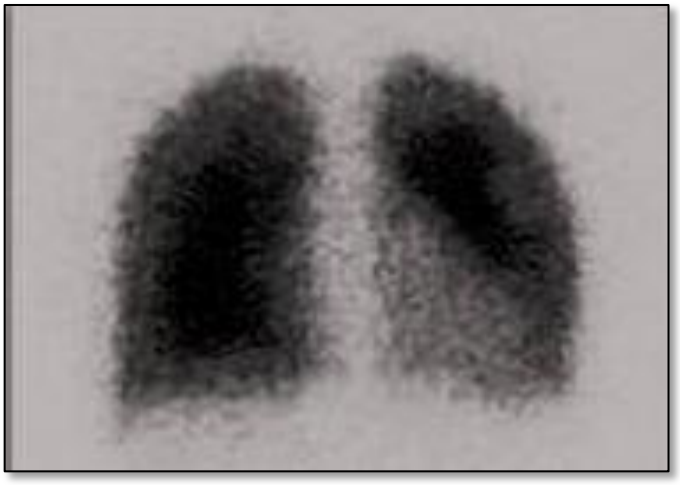

Figure 3.2.31: Perfusion scan in the anterio-posterior (AP) view post surgical re-implantation of the right pulmonary artery, patient no. 9 - shows equal perfusion to both lungs.

3.2.4 Mode of definitive diagnosis (imaging) - Summary (Graph 3.2.5)

The median time from presentation at the Chris Hani Baragwanath Academic hospital to definitive diagnosis was 4 days (1 - 83 days; IQR: 2 - 19). The diagnosis was made on transthoracic echocardiography (TTE) in the majority of the patients (10/17,58.8%), on catheterization (Cath) angiography in six patients (35.3%) and on computerized tomography (CT) angiography in one patient (5.9%).

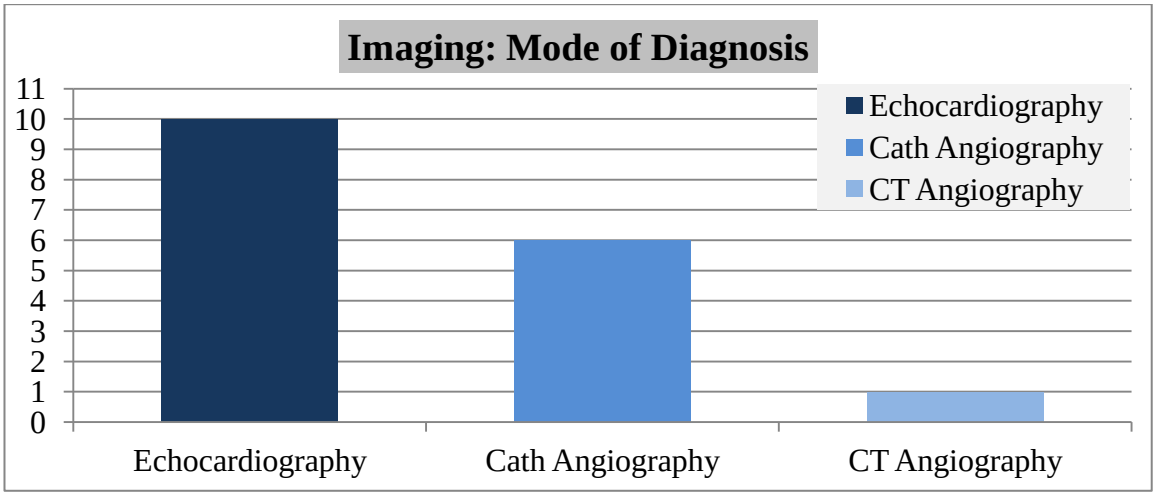

Graph 3.2.7: Imaging, mode of diagnosis

3.2.5 Pulmonary Hypertension (PHT) (Table 3.2.3)

All patients had pulmonary hypertension documented either at cardiac catheterization or estimated from the tricuspid regurgitation velocity gradient obtained at echocardiography (Table 3.2.3). The systolic pulmonary artery pressures (PAp) ranged between two-thirds of systemic pressures to suprasystemic pressures. The pulmonary pressures in the anomalous pulmonary artery (PA) arising from the ascending aorta was measured at cardiac catheterization directly in three patients (patient no. 10, 12 and 17) and estimated using the aortic pressures in five patients (patient no. 1, 5, 9, 11, and 15) provided there was no stenosis or narrowing of the anomalous pulmonary artery. Pulmonary pressures in the normally connected pulmonary artery was measured directly in six patients (patient no. 1, 5, 9 , 11, 15 and 17), not measured in patient no. 12 and impossible to measure in patient no. 10 because of an associated pulmonary atresia / ventricular septal defect with no direct access to the pulmonary artery. The catheterization data in patient no. 2 could not be found. Pulmonary pressures in the remaining eight patients was estimated from the tricuspid regurgitation using echocardiography provided there was no associated pulmonary stenosis or right ventricular outflow tract obstruction.

Table 3.2.3: Cardiac catheterization and Echocardiographic data in patients with Pulmonary hypertension (PHT) and AOPA				
Patient	**Anomalous PA systolic press.**	**Normal PA systolic press.**	**Ascending aorta systolic press.**	**Tricuspid Regurgitation(TR), PIG**
1	75 mmHg	110 mmHg	75 mmHg	Severe TR, not reported
2	Data missing	Data missing	Data missing	Moderate TR, 50 mmHg
3	-	-	-	Moderate TR, 63 mmHg
4	-	-	-	Moderate TR, 46 mmHg
5	84 mmHg	83 mmHg	84 mmHg	Severe TR, not reported
6	-	-	-	Moderate TR, 53 mmHg
7	-	-	-	Moderate TR, 40 mmHg
8	-	-	-	Moderate TR, 46 mmHg
9	63 mmHg	77 mmHg	63 mmHg	Severe TR, 76 mmHg
10	74 mmHg	-	82 mmHg	Moderate TR, 52 mmHg
11	95 mmHg	110 mmHg	95 mmHg	Severe TR, 90 mmHg
12	120 mmHg	-	120 mmHg	Severe TR, 70 mmHg
13	-	-	-	Severe TR, 103 mmHg
14	-	-	-	Severe TR, 80 mmHg
15	101 mmHg	112 mmHg	101 mmHg	Severe TR, 88 mmHg
16	-	-	-	Moderate TR, 61 mmHg
17	86 mmHg	105 mmHg	83 mmHg	Severe TR, 78 mmHg

3.2.6 Pulmonary Vascular Resistance index (PVRi) (Table 3.2.4)

Pulmonary vascular resistance was calculated using estimated oxygen consumption in five patients, in both the anomalous pulmonary artery from the ascending aorta in two patients and in the normally connected pulmonary artery to the main pulmonary artery in the other three patients. The median PVRi was 12.5 WU/m^2 (7.4 - 22 WU/m^2; IQR: 7.6 - 21).

Table 3.2.4: Pulmonary Vascular Resistance index (PVRi) data in patients undergone cardiac catheterization with AOPA		
Patient	**PVRi Anomalous PA (on 100% Oxygen)**	**PVRi Normal PA (on 100% Oxygen)**
1	Not calculated	Not calculated
2	Data missing	Data missing
5	Not entered	7.7 WU/m^2 (4 WU/m^2)
9	Not entered	9 WU/m^2 (6.6 WU/$m^{2)}$
10	7.4 WU/m^2	-
11	Not entered	Not calculated
12	Not calculated	Not calculated
15	Not entered	16 WU/m^2 (15 WU/m^2 on O2)
17	22 WU/m^2 (0 WU/m^2)	21 WU/m^2 (1.5 WU/m^2)

3.2.7 Type of AOPA (Table 3.2.5)

The majority of the patients (14/17; 82.4%) were diagnosed to have anomalous origin of the right pulmonary artery from the ascending aorta (AORPA) and three patients (17.6%) had anomalous origin of the left pulmonary artery from the ascending aorta (AOLPA).

3.2.8 Associations: Cardiac defects, Non- Cardiac and Aortic arch sidedness (Table 3.2.5)

AOPA was associated with cardiac defects in the majority of the patients (14/17; 82.4%) and included patent ductus arteriosus (PDA) in twelve patients, ventricular septal defect (VSD) in one patient, and pulmonary atresia and ventricular septal defect with major aorto-pulmonary collaterals from the aorta (PA/VSD/MAPCAs) in one patient. One of the patients with a PDA was found to have an ASD and two patients were found to have aberrant right subclavian artery. Three patients had isolated AOPA without associated intracardiac defects.
The aortic arch was opposite in all the patients with anomalous origin of the right pulmonary artery and one patient with anomalous origin of the left pulmonary artery from the ascending aorta. Extracardiac associations were found in three patients viz. CATCH 22, McKusick-Kauffman syndrome and an absent left kidney.

Table 3.2.5: Diagnosis, time to diagnosis, aortic arch sidedness and associations					
Patient number	**Diagnosis**	**Time to diagnosis (days)**	**Aortic arch side**	**Cardiac defects associations**	**Non-Cardiac associations**
1	AORPA	6	Left	-	-
2	AORPA	21	Left	PDA	-
3	AORPA	3	Left	PDA	-
4	AOLPA	17	Right	VSD	-
5	AOLPA	3	Left	PDA	-
6	AORPA	7	Left	PDA	McKusick - Kauffman syndrome
7	AORPA	4	Left	PDA	-
8	AORPA	3	Left	PDA	-
9	AORPA	1	Left	PDA	Absent left kidney
10	AOLPA	83	Left	PA/VSD,MAPCAs Aberrant RSCA	CATCH 22
11	AORPA	1	Left	PDA, Aberrant RSCA	-
12	AORPA	38	Left	PDA	-
13	AORPA	4	Left	-	-
14	AORPA	1	Left	-	-
15	AORPA	1	Left	PDA, ASD	-
16	AORPA	16	Left	PDA	-
17	AORPA	65	Left	PDA	-

Abbreviations: AORPA, anomalous origin of the right pulmonary artery; AOLPA, anomalous origin of the left pulmonary artery; PDA, patent ductus arteriosus; VSD, ventricular septal defect; PA/VSD, pulmonary atresia with ventricular septal defect; MAPCAs, major aorto-pulmonary collaterals; RSCA, right subclavian artery; ASD, atrial septal defect; CATCH 22, cardiac defects, abnormal facies, thymic hypoplasia, cleft palate, hypocalcaemia and chromosome 22.

3.2.9 Management: Medical and Surgical (Table 3.2.6)

The medical treatment prescribed included antifailure treatment (digoxin and diuretics) in sixteen patients (94.1%), intravenous inotropes in five patients (29.4%), and oxygen and antibiotics in fifteen patients (88.2%). A therapeutic and diagnostic ascitic tap was performed in the adult patient (patient no. 12) and diuretics including furosemide and spironolactone were commenced. Nine patients (52.9%) were ventilated with a median time of 5 days (2 - 55 days; IQR: 3 - 24). The median hospital stay (n = 17) preoperatively until death or surgical correction was 12 days (0 - 77 days; IQR: 4 - 19). Surgical correction was undertaken in three patients at a median age of 66 days (26 - 118 days) by direct implantation while three patients were deemed inoperable. The median time to surgery was 13 days (10 - 17 days).

3.2.10 Outcomes and Follow up (Table 3.2.6)

Twelve patients (71%; 12/17) including an adult who was deemed inoperable died preoperatively due to progressive congestive cardiac failure (16/17; 94%), early development of severe pulmonary hypertension and sepsis. Two patients died postoperatively (67%; 2/3) secondary to pulmonary hypertensive crises and multiorgan failure. There were three survivors including the two patients that were considered to be inoperable viz. - patient no. 10 who was diagnosed to have AOLPA and associated pulmonary atresia and ventricular septal defect with major aortopulmonary collaterals from the aorta (8.7 years of age) and patient no. 17 who had Eisenmenger's syndrome and suspected pulmonary vascular obstructive disease (3.8 years of age). The third survivor (patient no. 9) is post surgical correction who on follow up (9.8 years of age) shows no anastomotic site stenosis on both echocardiography and computed tomography angiography and the ventilation-perfusion scan showed no differential perfusion in the lungs. The overall mortality was 82%.

Table 3.2.6: IPPV, hospital stay duration, surgery and outcomes in patients with AOPA				
Patient	**IPPV (days)**	**Hospital stay (days)**	**Surgery (age in days)**	**Outcome**
1	5	15	Direct implantation (66)	Died
2	Data missing	20	-	Died
3	3	3	-	Died
4	13	17	-	Died
5	3	4	-	Died
6	55	77	-	Died
7	34	4	-	Died
8	-	16	Direct implantation (26)	Died
9	-	17	Direct implantation (118)	Alive
10	-	0	-	Alive, inoperable
11	3	3	-	Died
12	-	12	-	Died, inoperable
13	2	9	-	Died
14	-	1	-	Died
15	-	23	-	Died
16	7	21	-	Died
17	-	9	-	Alive, inoperable

CHAPTER 3: DISCUSSION AND LIMITATIONS

3.1 Discussion

Anomalous origin of the pulmonary artery from the ascending aorta (AOPA) is a rare anomaly with an incidence of 0.12% and is associated with a very high mortality without surgical correction.[1-4] This study was chosen to review the presentation, diagnosis and analyze the outcomes of patients with AOPA in a Southern African tertiary care centre. The mortality was high and similar to the other studies reported in the literature.[3,5-6]

3.1.1 Frequency

In our case series, one patient was diagnosed on average every 1.5 years with the majority of patients (9/17) diagnosed in the second decade of the study period (2001-2010). The largest review of 108 cases reported in literature over 120 years showed an average of one case report every 1.1 years.[4] A recent surgical case series of 11 cases was seen over 5 years with an average of one case diagnosed every 0.5 years.[5]

3.1.2 Mortality (Overall)

The overall study mortality was 82% with a preoperative and postoperative mortality of 71% and 67% respectively. The high mortality is in keeping with a previous study which also reported poor survival in patients without surgical treatment during infancy.[6] The majority of the preoperative mortality in this published study occurred in 92% infants (11/12) with a poor survival of 30% without surgery and 84% with surgery.[6] More recent literature pertaining to outcomes of AOPA has focused more on postoperative outcomes in contrast to more dated reviews by Keane et al and Fontana et al in 1974 and 1987 respectively who focused on preoperative outcomes.[3,6]

Other reports from developed countries such as the one by Abu-Sulaiman et al in 1998, show a better outcome with an overall mortality of 25%, a preoperative mortality of 6% and a postoperative mortality of 21%.[7] Another paper which described six patients with AOPA reported two neonates who died preoperatively and two patients with associated tetralogy of Fallot who died postoperatively with an overall mortality of 66.7%.[8] The diagnosis of AOPA in our study population was delayed due to the late presentation, which was an observation in another study from a developing country.[1] Despite the late presentation (beyond the neonatal period) the diagnosis was made rapidly soon after admission in our case series with a median time to diagnosis of 4 days.

3.1.3 Preoperative Mortality

A total of 12 patients (71%) including nine infants (< 1 year) died before surgical correction of the AOPA. The preoperative mortality in our study was related to late presentation and the pre-terminal diagnoses included progressive congestive

cardiac failure (CCF) and severe pulmonary hypertension (PHT). Preoperative mortality reported in the literature is similar and mostly related to progressive or refractory CCF and early development of PHT leading to development of pulmonary vascular obstructive lung disease (POVD).[9] In one review of 50 cases, the preoperative mortality was 56% (28/50) and the majority of the patients (18/50) that died were very young infants less than 6 months of age.[3]

Six of the study patients, including four neonates who were critically ill and were being ventilated in the neonatal intensive care unit (NICU), died while awaiting cardiac catheterization and angiography to define further the anatomy and hemodynamics. Other hospital related co-morbidities suffered by two of the four neonates that died in NICU included Klebsiella and Candida parapsilosis sepsis. One patient had a cardiac arrest in the catheterization theatre during catheterization under conscious sedationand required emergency intubation and ventilation in the paediatric intensive care unit (PICU), and eventually died of multiorgan failure. The adult patient (no. 12) with anomalous origin of the right pulmonary artery (AORPA) and a large patent ductus arteriosus (PDA) who was deemed inoperable eventually died from the severe pulmonary hypertension and progressive right heart failure. Two recent publications have detailed adult cases with AORPA and a PDA who were judged to be inoperable because of their advanced pulmonary vascular disease and who were labelled as having Eisenmenger's syndrome.[10-11]

Four of our patients including three infants died while awaiting surgery (4 days-6 weeks) from severe pulmonary hypertension and CCF. Three patients died while in hospital and one patient died at home. The cardiac surgery delay in our tertiary care hospitals has been highlighted by Hoosen et al, who documented long waiting lists secondary to insufficient time allocated for theatre, postoperative care facilities and personnel.[12-13]

3.1.4 Postoperative Mortality

Two (2/3) of our study patients that underwent surgical correction of the AOPA died. These data constituted a postoperative mortality of 67%. The patients died from PHT crisis unresponsive to conventional treatment which contributed to a low cardiac output state resulting in multiorgan failure. These pre-terminal scenarios are similar to those recorded in the literature.[5,14-16] A previously reported surgical case series of five patients from Africa documented one post operative death due to extensive lung disease.[17] Recently a surgical case series of four patients was published from Angola with a postoperative mortality of 0%.[18] Associated cardiac defects, progressive preoperative CCFand early development of severe pulmonary hypertension are predictors of postoperative morbidity and mortality.[1,5,9,14-16] In a study case series by Prifti et al of eight patients, one patient with AORPA associated with VSD and PS died postoperatively due to progressive CCF.[9] One death was reported postoperatively in a study of twelve case series by Cho et al in a patient with AORPA associated with VSD,PDA and ASD, severe pulmonary hypertension and suprasystemic pulmonary artery pressures.[16] Two of the patients that died postoperatively in our study case series

presented with CCF and developed severe pulmonary hypertension prior surgery. In the largest review of 108 cases, the overall postoperative hospital mortality was reported as 10%.[4]

3.1.5 Presentation

Congestive Cardiac Failure (CCF)

Congestive cardiac failure, signs of respiratory distress and cyanosis were the most common presentations in the study case series and the majority were infants. The infants that manifested with signs of respiratory distress and CCF in the study case series tended to present with failure to thrive and they were also sicker and showed a poor response to medical therapy especially if there was an associated cardiac defect with a left to right shunt.[1,5,16,19] These poor prognostic features have been described previously in another study.[20]

Cyanosis

Cyanosis as a presenting feature was frequently found in our patients (8/17, 47%) manifesting in the early infancy period (median age of 81 days). Similar findings were published in a review of 50 cases where 40% of the patients presenting with cyanosis had a median age of three months.[3]

Neonates

There were five neonates (29%) and three of those presented early within 3 days postnatally. They all presented with signs of respiratory distress and CCF associated with murmurs. In a surgical case series of 16 cases with AOPA, nine cases (56%) presented during the neonatal period.[14] One of the neonates in our study presented with cardiogenic shock and was suspected clinically to be a duct dependent systemic circulation cardiac lesion and on echocardiography was thought to have an interrupted aortic arch. Other reports have documented neonates presenting with cyanosis and cardiogenic shock associated with multiorgan failure which may be misdiagnosed as transposition of great vessels (TGV), coarctation of the aorta (CoA) or other conditions with a duct dependent systemic circulation.[19-22]

The majority of our cases who presented with signs of respiratory distress with or without cyanosis were managed as if they had a pneumonia. AOPA was diagnosed echocardiographically when there was normal intracardiac anatomy but were found to have abnormal pulmonary bifurcation with only one of the branch pulmonary arteries arising from the main pulmonary artery (MPA). Further systemic echocardiographical examination would reveal the other pulmonary artery arising from the ascending aorta.

Premature neonates

A preterm neonate with gestational age of 34 weeks and birth weight of 1.8 kilograms (kg) presented within the first week of life with respiratory distress, cyanosis and CCF, which is similar presentation to the other cases published in the literature.[21,23-30] The gestational age of these published cases varies between 25 and 36 weeks.[3,21,23-30] The lowest birth weight recorded was 520 grams (g).[24]

Infants

The majority of our patients presented in infancy which is similar to another study from India which reported 17 cases with the median age at presentation of 7 months.[1] Late presentation (beyond the neonatal period) often leads to late diagnosis and later surgery which is detrimental to the long term outcome of these patients. A case series of five patients published from South Africa, reported a mean age of 6.6 months at presentation.[17] In contrast, most case studies described from developed countries report early presentation (during the neonatal period) of patients, leading to early diagnosis and surgical correction of AOPA with better outcomes.[7,14,20-21]

Adults

The adult patient (patient no. 12) presented with several episodes of self-limited hemoptysis, progressive exertional dyspnoea, jaundice, anasarca and ascites secondary to congestive hepatopathy due to severe pulmonary hypertension and right heart failure. This presentation is similar to adults cases diagnosed to have AOPA reported in the literature, who tend to present with hemoptysis which may be self-limited or recurrent, and who have progressive exertional dyspnoea.[10-11] The presentation with congestive hepatopathy in our adult case has not been described before in association with AOPA. The very first case report of a patient with AOPA was a 25 year old adult female with AORPA associated with an aortopulmonary window (APW) made at autopsy and who died from CCF.[2]

Liver diseases such as congestive hepatopathy which was diagnosed in patient no. 12 and other pathologies such as ischaemic hepatitis, cardiac liver cirrhosis and Fontan liver disease have been described in association with various forms of circulatory failure secondary to either congenital or acquired heart disease.[31-33] Congestive hepatopathy is caused by increased venous congestion and hepatic venous pressure, diminished hepatic blood flow and reduced arterial oxygen saturation. It has been described in patients with severe acute and chronic structural heart disease usually causing right sided heart failure leading to chronic liver congestion and liver cirrhosis.[33-36]

3.1.6 Malnutrition

More than two thirds (77%) of our study patients were malnourished, which was higher than reported by Garg et al and Talwar et al, which showed a percentage frequency of malnutrition in their patients of 65% and 55% respectively.[1,15]

Severe malnutrition was observed in 46% of our study cases which is similar to studies reported from developing countries.[1,15] In contrast, the incidence of the malnutrition in patients from developed countries diagnosed with AOPA is much lower.[5,21] In one such study cases series of 12 cases, 4 cases (33%) were malnourished while 17% had severe malnutrition.[21]

3.1.7 Pulmonary hypertension

All the study patients had pulmonary hypertension (PHT) diagnosed using either cardiac catheterization or echocardiography. Every patient with AOPA reported in both early and the recent literature has been documented to have PHT.[5,14,20-21] The most recent report from 2015 of 12 patients, documented a 100% incidence of PHT.[16]

PHT was diagnosed in eight of the study patients using echocardiography exclusively, based on estimated values obtained from the tricuspid regurgitation velocity, which is a method common to other published studies.[14,21,37] Direct measurement of the pulmonary pressures in the anomalous pulmonary artery was possible in only two of the nine patients (patients no. 10 and 17) that underwent cardiac catheterization. The anomalous pulmonary artery is technically difficult to enter retrogradely to measure the pulmonary pressures because of the angle of origin, and as a result was entered only in four (46%) of the cases with Tetralogy of Fallot (TOF) reported by Talwar et al.[15]

PHT may present as early as the neonatal period which was the case in five of our cases. The PHT may be progressive and evolve into pulmonary vascular disease during infancy.[5,6,20-21] The cause of the PHT is due to the anomalous pulmonary artery and ipsilateral lung being exposed to systemic aortic pressures while the opposite lung and normally connected pulmonary artery receives the entire cardiac output from the right ventricle.[5] Other mechanisms postulated for the development of PHT include increased circulating vasoconstrictor substances and neurogenic crossover from the affected lung causing pulmonary hypertension in the normally connected pulmonary artery.[9]

3.1.8 Chest X-ray (CXR)

Careful evaluation of bedside imaging modalities such as a chest X-ray may show differential vascularity with plethora in the affected lung perfused by the anomalous pulmonary artery and normal or relative oligaemia in the unaffected lung such as was seen in more than two-thirds of our cases. Differential pulmonary vascularity on CXR may also be seen in patients with associated right ventricular outflow obstruction such as Tetralogy of Fallot, pulmonary atresia and AOPA, similar to the CXR of patient no. 10 who had AOPA associated with pulmonary atresia with ventricular septal defect and major aortopulmonary collaterals from the aorta (PA/VSD and MAPCAs).[1,15,38]

3.1.9 Echocardiography

Transthoracic echocardiography (TTE) was the major diagnostic tool in the majority of our case series (59%), similar to a study by Garg et al.[1] None of our study cases had a prenatal echocardiographic diagnosis, which if available may facilitate early prenatal diagnosis followed by surgery early in the neonatal period. The diagnosis of AOPA was made exclusively on TTE in eight cases without the addition of cardiac catheterization, which is a similar diagnostic approach in the majority of the cases of other studies.[5,14,21,37] The most useful echocardiographic views enabling the diagnosis of AOPA in our study included the parasternal suprasternal long axis, parasternal long axis and short axis views. The same diagnostic echocardiographic windows were employed in a recent publication discussing the role of TTE in the diagnosis of AORPA.[39] The use of echocardiography as a diagnostic modality has also resulted in the incorrect diagnosis with misinterpretation of the imaging as other congenital heart defects such as APW, TGV, truncus arteriosus, interrupted aortic arch (IAA), unilateral absent pulmonary artery (UAPA) and pulmonary atresia with ventricular septal defect and major aortopulmonary collateral arteries from the aorta (PA/VSD/MAPCAs).
Echocardiography (ECHO), however remains the most accurate noninvasive diagnostic tool for both the prenatal and postnatal diagnosis of AOPA and associated anomalies, with a diagnostic accuracy postnatally in a recent report of 88.9%.[39] Although the diagnosis of AOPA can be made in the majority of cases using ECHO, cardiac catheterization angiography may be required in some cases for confirmation and further delineation of the anatomy.[21,38] Right ventricular (RV) dysfunction which is a complication of pulmonary hypertension can also be accurately diagnosed using echocardiography. If present, RV dysfunction may be associated with increased morbidity and mortality but can be reversed and often resolves with surgical correction.[14,41-42] None of our patients were documented to have right ventricular dysfunction or decreased RV contractility.

3.1.10 Computed Tomography (CT) Scan/Angiography

The definitive diagnosis of AORPA and a large PDA was made using computed tomography angiography in the adult patient (no. 12) following a missed diagnosis using transthoracic echocardiography. A similar trend of failure to make the diagnosis of AOPA associated with PDA on echocardiography in adults patients has been documented in the literature.[10-11,43] The large PDA with a right to left shunt caused by the very high pressures within the pulmonary artery and also poor echocardiography windows often experienced in older patients may have resulted in the misinterpretation of the left pulmonary artery and the PDA as a normal main pulmonary bifurcation. Computed tomography angiography has been used in other centers to make the diagnosis of AOPA[16,44] and it was also used to confirm the diagnosis in two of our study patients (no. 10 and 15). Multidecter CT (MDCT) angiography has been found to be an important supplement to echocardiography in confirming the diagnosis and to further delineate the anatomy for preoperative planning.[44]

3.1.11 Cardiac Catheterization

The diagnosis of AOPA was made using catheterization angiography as the initial diagnostic modality in six patients (35%) and assisted in confirming the diagnosis in three patients in the study case series. It has been used in a similar way in other case studies and it has rarely been used to make the diagnosis after being missed on echocardiography.[1,14,21] Cardiac catheterization is not only an important diagnostic modality but essential, especially in older children to assess pulmonary pressures, reversibility of the pulmonary hypertension and to estimate the pulmonary vascular resistance index (PVRi) in each of the lungs. Cardiac catheterization and angiography is an essential diagnostic component in the subgroup of patients with Tetralogy of Fallot (TOF) and AOPA to further delineate the anatomy, to assess the haemodynamics and pulmonary vascular resistance index (PVRi).[15]

3.1.12 Other imaging modalities

Other imaging modalities such as magnetic resonance imaging (MRI) and magnetic resonance angiography (MRA) have been used to confirm the diagnosis at other institutions case studies but were not available at the study center.[45-47] MRI can also be used noninvasively to estimate the PVR and the pressures in some cases with AOPA.[15]

3.1.13 Pulmonary Vascular Resistance index (PVRi)

The PVRi was based on calculations in five patients (patient no. 5, 9, 10, 15 and 17) and was found to be very high, ranging between 7.4 WU/m^2 and 22 WU/m^2. The PVRi calculated in the anomalous pulmonary arteries (patient no.10 and 17) was 7.4 WU/m^2 and 22 WU/m^2 respectively while the PVRi in the normal connected pulmonary artery was 7.7 WU/m^2 (patient no. 5), 9 WU/m^2 (patient no. 9), 16 WU/m^2 (patient no. 15) and 21 WU/m^2 (patient no. 17). The PVRi has been reported in a study of 11 cases by Talwar et al, where the calculated PVRi in the anomalous connected pulmonary artery was documented in four patients to be between 7.7 WU/m^2 and 42.7 WU/m^2.[15] Garg et al reported the calculated PVRi in the normal connected pulmonary artery to be from 6.3 WU/m^2 to 22 WU/m^2 in three cases.[1]

PVRi is important to calculate in patients with severe PHT to assess the reversibility of PHT and therefore the risk for surgical correction. The estimation of PVRi based on assumptions may be inaccurate because one assumes equal blood flow to each lung which is incorrect. The use of cardiac MRI which can provide more accurate measurements of blood flow to each lung separately will result in more precise calculations of PVRi in each lung.[15,40]

3.1.14 Type of AOPA

The origin of the right pulmonary artery from the ascending aorta (AORPA) was diagnosed in the majority of the patients (14/17; 82%) which was, five times common than the anomalous origin of the left pulmonary artery from the ascending aorta (AOLPA). This finding was similar to other studies published in the literature, such as Nathan et al, Amir et al and Liu et al, who also found AORPA to be more common than AOLPA in 88%, 83% and 89%, of cases respectively.[14,21,44]

In the largest review case series published in 1988 of 108 cases with AOPA, AORPA was found to occur 4-5 times more common than AOLPA, similar to our study cases series.[4] AOLPA was diagnosed in three patients (18%) in our study case series which is similar to the finding of four cases (25%) in a study case series by Garg et al[1] and two cases (12%) out of 19 cases with AOPA in another case series by Liu et al.[44]

3.1.15 Associated Cardiac Defects

Associated cardiac defects were found in 82% of our study cases, comparable to a study by Garg et al which found associated cardiac defects in 88% of their cases.[1] A higher incidence of associated cardiac defects has been reported in other studies of between 95% and 100%.[5,21,44] The most common associated cardiac defect was a PDA in 71% of the patients, which is higher than a case series recently published which found PDAs in 63% of 19 cases with AOPA.[44] Nathan et al also reported similar high incidence of PDAs in 63% of their 16 study cases.[14] The highest number of PDA associated with AOPA was found in the studies by Amir at al and Kajihara et al, who reported a 92% and 88% frequency respectively.[20-21] The lowest rates of PDA associated with AOPA of 35% and 36% were found in the studies by Garg et al and Liu et al respectively.[1,5]

PDA is also the most common associated cardiac defect in paients with AORPA and the relationship was found in 10 (71%;10/14) of our study patients, which is in keeping with a recently published study where PDAs were reported in 71% of their 18 cases with AORPA.[44] In contrast, Amir et al found the PDA association in all their patients with AORPA.[21] The common association has also been reported in preterm neonates.[3,21,23-30]

None of our patients with AOLPA was associated with Tetralogy of Fallot (TOF), which is in contrast to other studies that show a 50% to 75% association.[1,4,15] Our three cases with AOLPA (3/17; 18%) were associated with pulmonary artery atresia, ventricular septal defect and major aorto-pulmonary collaterals (PA/VSD/MAPCAs), a PDA and a ventricular septal defect (VSD). Other studies have described the association of VSD with AOPA in 8% to 19% of cases and it is also usually associated with AOLPA.[1,5,44] The association of AOPA and PA/VSD with MAPCAs has been described in the literature.[16,48] The connection between ASDs and AOPA varies between 13% and 63%.[1,5,44]

All of our patients with AORPA had a left sided aortic arch, similar to a study by Garg et al who found that aortic arch was opposite in 92% cases with AORPA.[1] A similar association of an opposite aortic arch has been described in patients with AOLPA in whom the arch was right sided in the majority.[1,4,44] In contrast, the aortic arch was on the same side in all the three cases with AOLPA associated with TOF in a study of 11 cases by Liu et al.[5] The other aortic arch anomaly reported and found in one of our patients was aberrant right subclavian artery.[20,44,49]

3.1.16 Non-Cardiac associations

Non-cardiac associations were found in three patients in our study including Mckusick-Kaufman syndrome, CATCH 22 and an incidental finding of single right kidney in one of the patients. The association of AOPA with Mckusick-Kaufman syndrome has not been reported in the literature before. One of our study patients with AOLPA and PA/VSD and MAPCAs was found to be CATCH 22 positive. A recent publication showed CATCH 22 present in one out of 12 cases.[16] Non-cardiac associations may be found in patients with isolated AOPA or in association with other cardiac defects such as Tetralogy of Fallot, pulmonary atresia and IAA.[16,27,50]

3.1.17 Surgery

Three patients (18%) underwent early surgical correction using CPB during infancy, but the numbers were too small for a meaningful comparison with the other large surgical case series reported in the literature. The median age at surgery was 2.2 months (0.9-3.9 months), which is similar to a surgical case series recently published with median age of 1.8 months.[16] The two other surgical case series of five cases and four cases from Africa reported a median age at surgery of 8 months (2.5-19.5 months) and mean age of 1.6 months (3 weeks-3 months) respectively.[17,18] The published median age at surgery in other studies varies between 0.4 months and 3.5 years.[1,9,14-15,21,44] The youngest patient reported to undergo successful surgical correction of AOPA was a 2 days old neonate.[21] Patients from developed countries undergo surgical correction at the younger age compared to patients from developing coutries.[1,14-15,21] Patients with AOPA and associated TOF tend to present later than patients with associated left to right shunt lesions who develop PHT much earlier.

Direct implantation of the anomalous pulmonary was the surgical technique of choice in all three patients, which is a similar surgical approach in the majority of the studies reported from both developing and developed countries.[1,5,14-17,21,44] Early surgical correction to avoid the development of irreversible PHT, is the treatment of choice as soon as the diagnosis is confirmed with or without cardiopulmonary bypass (CPB) depending on the presence of associated cardiac defects.[1,14,18,21] Two patients were deemed inoperable. One patient was an adult patient and the other patient had a complex cardiac lesion which included PA/VSD and MAPCAs. Two other cases from Africa that were associated with

pulmonary atresia and ventricular septal defect were considered to be inoperable.[48] In contrast, a successful surgical correction of the AOPA associated with PA/VSD and MAPCAs was recently reported.[16] To the best of our knowledge, our adult patient at 36 years of age is the fourth longest survivor with AORPA and PDA, the longest survivor reported was 43 years old.[11,51-52] Adult patients with AOPA may pose a high risk during surgery because of advanced pulmonary vascular disease exposing the patients to pulmonary vascular crisis and deterioration if Eisenmenger's syndrome is present. Favourable outcomes have been reported in most patients, even adults, with reversal of pulmonary hypertension.[1,14-18,53-54]

3.1.18 Follow up

One of our study patients (patient no. 9) has been followed up for 10 years postoperatively without development of a stenosis at the anastomotic site using both echocardiography and CT angiography as screening imaging modalities. Reimplantation of the anomalous pulmonary artery may be complicated early or late by stenosis at the surgical anastomotic site and synthetic graft which may need either balloon dilation or surgical reoperation.[16,20-21,55-56] The pulmonary hypertension in our surviving patient has resolved completely postoperatively and monitored using echocardiography. The cardiac catheterization which is an invasive diagnostic modality is often not necessary for postoperative assessment of pulmonary artery pressures unless catheter intervention for stenosis is required. In a recent published study of 12 cases, both preoperative and postcardiac catheterizations were performed in five cases to assess the progress of pulmonary hypertension.[16] The much quoted other surgical case series from Africa, used postoperative cardiac catheterization to show a significant drop in pulmonary pressures.[17] The lung perfusion scan used for follow up in our case showed no differential lung perfusion. It is a nonivasive screening radiological modality used frequently in patients to assess the lung perfusion bilaterally postoperatively.[16] Several factors may have contributed to the high morbidity and mortality found in our patients. Many of the study patients presented late which is a trend prevalent in other developing countries, which then leads to a delay in diagnosis and surgery. Other delays in diagnosis of hospitalized patients who are critically ill are because they are not able to leave the intensive care unit for diagnostic cardiac catheterization or CT scan studies. Other factors contributing to less optimal management of patients with AOPA include the lack of onsite cardiothoracic surgical services, long waiting lists for surgery, limited preoperative and postoperative intensive care facilities. Critically ill patients also pose a high risk for adverse events including cardiac arrest and death during interhospital transfer and surgery. This is particularly relevant at our hospital where cardiac surgery facilities are not available within the hospital and patients have to be transferred several kilometres to another center to undergo surgery.

Lack of clinical suspicion and awareness of the condition and operator dependent echocardiographic diagnostic accuracy may have also contributed to the delayed diagnosis and surgery in some of the patients.

3.2 Limitations:

The study is a cross-sectional observational and retrospective review of patients with all the limitations pertaining to a retrospective study such as missing information. It is a single institutional audit and with a limited number of patients with AOPA which is a very rare congenital cardiac anomaly.

CHAPTER 4: CONCLUSIONS AND RECOMMENDATIONS

4.1 Conclusions

AOPA is a rare congenital cardiovascular anomaly associated with a very high morbidity and mortality. Early diagnosis using noninvasive diagnostic modalities such as echocardiography and timely surgery is mandatory to avoid the inevitable poor outcome if delayed. Any delay in presentation and diagnosis can result in the early development of pulmonary hypertension. The signs and symptoms of AOPA are non-specific and therefore a high index of suspicion is required to make diagnosis. The diagnosis should be suspected if there is unexplained severe pulmonary hypertension associated with congestive cardiac failure with or without other intracardiac defects. Other features of severe pulmonary hypertension such as haemoptysis which was present in the adult patient could suggest an underlying congenital heart defect such as AOPA. A high mortality and morbidity can be expected even if the patient is diagnosed early particularly if the patient presents beyond the neonatal period.

4.2 Recommendations

Future multi-institutional studies combining patients will allow for a more comprehensive review of preoperative outcomes and factors contributing to the increased morbidity and mortality of these patients especially in developing countries. New modalities of treating pulmonary hypertension such as oral sildenafil may contribute to a more favourable post operative outcome of patients presenting late with severe pulmonary hypertension especially those with very high PVRi > 8 WU/m^2 that show a positive vasoreactivity pulmonary test. These approaches are particularly relevant in our setting where the surgical infrastructure, including intensive care, is not optimal and pulmonary vasodilator therapy can be costly.

References: Part 2 - Literature Review

1. Keane JF, Maltz D, Bernhard WF, Corwin RD, Nadas AS. Anomalous origin of one pulmonary artery from the ascending aorta. Diagnostic, physiological and surgical considerations. *Circulation* 1974;50:588-94.
2. Kutsche LM, Van Mierop LH. Anomalous origin of a pulmonary artery from the ascending aorta: associated anomalies and pathogenesis. *Am J Cardiol* 1988;61:850-6.
3. Fong LV, Anderson RH, Siewers RD, Trento A, Park SC. Anomalous origin of one pulmonary artery from the ascending aorta: a review of echocardiographic, catheter, and morphological features. *Br Heart J* 1989;62:389-95.
4. Abu-Sulaiman RM, Hashmi A, McCrindle BW, Williams WG, Freedom RM. Anomalous origin of one pulmonary artery from the ascending aorta: 36 years experience from one centre. *Cardiol Young* 1998;8:449-54.
5. Erdem A, Aydemir NA, Demir H, Zeybek C, Saritas T, Akdeniz C et al. Anomalous origin of one pulmonary artery branch from the ascending aorta: experience of our center. *Arch Turk Soc Cardiol* 2010;38:411-15.
6. Nathan M, Rimmer D, Piercey G, Del Nido PJ, Mayer JE, Bacha EA et al. Early repair of hemitruncus: excellent early and late outcomes. *J Thorac Cardiovasc Surg* 2007;133:1329-35.
7. Fraentzel O. Ein fall von abnormer communication der aorta mit der arteria pulmonalis. *Virchows Arch Pathol Ana.* 1868;43:420-6.
8. Fontana GP, Spach MS, Effman EL, Sabiston DC Jr. Origin of the right pulmonary artery from the ascending aorta. *Ann Surg* 1987;206:102-13.
9. Liu H, Juan YH, Chen J, Xie Z, Wang Q, Zhang X et al. Anomalous origin of one pulmonary artery branch from the aorta: role of MDCT angiography. *Am J Roentgenol* 2015;204:979-87.
10. Garg P, Talwar S, Kothari SS, Saxena A, Juneja R, Choudhary SK et al. The anomalous origin of the branch pulmonary artery from the ascending aorta. *Interact Cardio Vasc Thorac Surg* 2012;15:86-92.
11. Benatar A, Kinsley RH, Milner S, Dansky R, Hummel DA, Levin SE. Surgical correction for one pulmonary artery arising from ascending aorta-report of five cases. *Int J Cardiol* 1987;16:249-55.
12. Manuel V, Sousa-Uva M, Morais H, Magalhaes MP, Pedro A, Miguel G et al . Anomalous origin of the pulmonary artery from the ascending aorta: from diagnosis to treatment in Angola. *World J Pediatr Congenit Heart Surg* 2015;6:521-5.
13. Pepeta L, Takawira FF, Adams PE, Ntsinjana NH, Mitchell BJ, Cilliers AM. Anomalous origin of the left pulmonary artery from the ascending aorta in two children with pulmonary atresia, subaortic ventricular septal defect and right-sided major aorto-pulmonary collateral arteries. *Cardiovasc J Afr* 2011;22:268-71.
14. Long MA, Brown SC, de Vries WJ. Anomalous origin of the right pulmonary artery from the ascending aorta: a surgical case study in an adult patient with "irreversible" pulmonary vascular disease. *J Card Surg* 2009;24:212-5.
15. Aru GM, English WP, Gaymes CH, Heath BJ. Origin of the left pulmonary artery from the aorta: Embryologic considerations. *Ann Thorac Surg* 2001;71:1008-10.

16. Nakamura Y, Yasui H, Kado H, Yonenaga K, Shiokawa Y, Tokunaga S. Anomalous origin of the right pulmonary artery from the ascending aorta. *Ann Thorac Surg* 1991;52:1285-91.
17. Prifti E, Bonacchi M, Murzi B, Crucean A, Bernabei M, Luisi VS et al. Anomalous origin of the left pulmonary artery from the aorta. Our experience and literature review. *Heart Vessels* 2003;18:79-84.
18. Kostolny M, Kocyildirim E, de Leval MR, Anderson RH. Anomalous origin of the right pulmonary artery from the ascending aorta with fibrous continuity to the pulmonary trunk. *Ann Thorac Surg* 2005;80:1917-8.
19. Miyazaki K, Murashita T, Kubota T, Matsuzaki K, Miyazaki YJ, Yasuda K. Neonatal repair of anomalous origin of the right pulmonary artery from the ascending aorta. A case report and review in the literature. *J Cardiovasc Surg* 2000;41:863-8.
20. Talaat A, Sayed HM, Terzaky AK, Sharaf M, Hamed MA. Anomalous origin of the right pulmonary artery from the descending thoracoabdominal aorta (report of three cases). *J Egypt Med Assoc* 1974;57:328-43.
21. Fu S, Xie C, Gong F, Zhu W. Anomalous Origin of the Right Pulmonary Artery from the Abdominal Aorta With Aberrant Right Subclavian Artery and Left Patent Ductus Arteriosus. *Pediatr Cardiol* 2011;32:674-7.
22. Tsutsumi Y, Ohnaka M, Ohashi H, Murakami A, Takahashi M, Tanaka T. A case report of anomalous origin of right pulmonary artery from innominate artery associated with left sided unilateral pulmonary hypertension. *Nippon Kyobu Geka Gakkai Zasshi* 1991;39:447-51.
23. Guzoglu N, Sari FN, Altug N. An unusual case of refractory persistent pulmonary hypertension of the newborn: anomalous origin of one pulmonary artery. *Cardiol Young* 2014;24:543-5.
24. Wang J, Song Y, Cheng TO, Xie M, Wang X, Yuan L et al. The value of transthoracic echocardiography in the diagnosis of anomalous origin of the right pulmonary artery from the ascending aorta: a single center experience from China. *Int J Cardiol* 2015;184:750-4.
25. Kajihara N, Imoto Y, Sakamoto M, Ochiai Y, Kano M, Joo K et al. Surgical results of anomalous origin of the right pulmonary artery from the ascending aorta including reoperation for infrequent complications. *Ann Thorac Surg* 2008;85:1407-11.
26. Peng EWK, Shanmugam G, Macarthur KJD, Pollock JCS. Ascending aortic origin of a branch pulmonary artery-surgical management and long-term outcome. *Euro J Cardio Thorac Surg* 2004;26:762-6.
27. Wu M, Yang G. Origin of the right pulmonary artery from the ascending aorta in a 25-year-old man. *Tex Heart Inst J* 2006;33:534-5.
28. Patel RJ, Zakir RM, Sethi V, Patel JN, Apovian J, Alexander JC et al. Unrepaired Tetralogy of Fallot with right hemitruncus in an adult. *Tex Heart Inst J* 2007;34:250-1.
29. Mathur A, Mathur A, Garg P, Sharma N, Mittal P. Anomalous origin of left pulmonary artery from aorta with tetralogy of Fallot in an adult: what is protecting the lung?. *Indian J Thorac Cardiovasc Surg* 2015;31:187-9.
30. Talwar S, Meena A, Choudhary SK, Kothari SS, Gupta SK, Saxena A et al. Anomalous branch of pulmonary artery from the aorta and Tetralogy of Fallot:

morphology, surgical techniques and results. *Euro J Cardio Thorac Surg* 2014; 46:291-6.
31. Johnson MC, Watson MS, Strauss AW, Spray TL. Anomalous origin of the right pulmonary artery from the aorta and CATCH 22 syndrome. *Ann Thorac Surg* 1995;60:681-3.
32. Marui A, Mochizuki T, Mitsui N, Koyama T, Horibe M. Anomalous origin of the right pulmonary artery from the ascending aorta - a report of three operative cases. *Nihon Kyobu Geka Gakkai Zasshi* 1997;45:1189-94.
33. Salaymeh KJ, Kimball TR, Manning PB. Anomalous pulmonary artery from the aorta via a patent ductus arteriosus: repair in a premature infant. *Ann Thorac Surg* 2000;69:1259-61.
34. Vida VL, Sanders SP, Bottio T, Maschietto N, Rubino M, Milanesi O et al. Anomalous origin of one pulmonary artery from the ascending aorta. *Cardiol Young* 2005;15:176-81.
35. Amir G, Frenkel G, Bruckheimer E, Dagan T, Katz J, Berant M et al. Anomalous origin of the pulmonary artery from the aorta: early diagnosis and repair leading to immediate physiological correction. *Cardiol Young* 2010;20:654-9.
36. Godown J, Baker C, Kuhn N, Brown K, Buck S, Mill M et al. Delayed repair of hemitruncus in an extremely low birth weight infant. *Congenit Heart Dis* 2013;8:E13-6.
37. Hu Y, Yang Y, Kan C. One-stage total repair of anomalous origin of right pulmonary artery from aorta by the double-flap technique, followed by coarctation repair using extended end-to-end arch reconstruction. *Ann Thorac Surg* 2013;6:71-3.
38. Bi W, Ren W, Song G, Shang C, Pan F, Xu M. Anomalous origin of one pulmonary artery from the ascending aorta (hemitruncus) in a premature infant: A case report and literature review. *J Clin Ultrasound* 2014;42:367-70.
39. Liu Y, Cheng L, Qian X, Zhu H, Duan W, Yu S et al. Surgical correction of anomalous origin of one pulmonary artery without grafts in infants. *J Card Surg* 2015;30:85-91.
40. Garg N, Moorthy N, Jain S, Neyaz Z, Kumar S. Hemitruncus with large patent ductus arteriosus simulating d-transposition of great arteries. *J Indian Coll Cardiol* 2014;5:29-31.
41. Santos MA, Azevedo VMP. Anomalous origin of one pulmonary artery from the ascending aorta. Surgical repair resolving pulmonary arterial hypertension. *Arq Bras Cardiol* 2004;83:503-7.
42. Chaudhuri M, Mahimarangaiah J, Chandra S, Shivanna DN. Catastrophic presentation of anomalous origin of right pulmonary artery in a neonate - an interesting differential. *Indian J Pediatr* 2014;81:1102-4.
43. Sibley YDL, Roberts KD, Silove ED. Surgical correction of anomalous origin of right pulmonary artery from aorta in a four day old neonate. *Br Heart J* 1986;56:98-100.
44. Agarwala B, Waldman JD, Sand M, Loe WA, Ruschhaup DG. Aortic origin of the RPA: immediate resolution of severe pulmonary artery hypertension by surgical repair. *Pediatr Cardiol* 1994;15:41-4.
45. Trapali CJ, Thanopoulos BD. Severe right ventricular dysfunction in a neonate with aortic origin of the RPA. *Pediatr Cardiol* 1998;19:425-7.

46. Tagliente MR, Troise D, Milella L. Isolated anomalous origin of left pulmonary artery from the ascending aorta. *Am Heart J* 1996;132:1289-92.
47. Wong JA, Cheng W. Preoperative management of right ventricular dysfunction in aortic origin of the right pulmonary artery. *Pediatr Cardiol* 2000;21:388.
48. Menzer LL, Takahashi M. Tricuspid atresia and aortic origin of right pulmonary artery in a nine-year-old girl. *West J Med* 1974;121:147-9.
49. Duncan WJ, Freedom RM, Olley PM, Rowe RD. Two-dimensional echocardiographic identification of hemitruncus: anomalous origin of one pulmonary artery from ascending aorta with the other pulmonary artery arising normally from the right ventricle. *Am Heart J* 1981;102:892-6.
50. Lo RNS, Mok CK, Leung MP, Lau KC, Cheung DLC. Cross sectional and pulsed doppler echocardiographic features of anomalous origin of right pulmonary artery from the ascending aorta. *Am J Cardiol* 1987;60:921-4.
51. Sasaki T, Shiina Y, Abe K, Kimura H, Hamada Y, Niitu K. Surgical correction of Tetralogy of Fallot with anomalous origin of left pulmonary artery from the ascending aorta. *Nippon Kyobu Geka Gakkai Zasshi* 1990;38:488-92.
52. Jayan JP, Vijayalakshmi IB, Narasimhan C. Images in cardiology: a rare anomaly: 'hemitruncus'. *Heart* 2011;97:12.
53. Sun HF, Qin C, Liang JL. One stage correction of Tetralogy of Fallot associated with anomalous origin of the left pulmonary artery from the aorta and aortopulmonary window. *J Card Surg* 2012;27:112-4.
54. Talwar S, Meena A, Ramakrishnan S, Choudhary SK, Airan B. Hemitruncus with ventricular septal defect in a 6 year old child. *Ann of Pediatr Card* 2013;6:194-6.
55. Tantiwongkosri K, Chanthong P, Sriyodcharti S. Hemitruncus arteriosus *JACC* 2013;61:1653.
56. Vazquez RM, Chavez IOM, Lopez MES, Bahena EJP, Zarate RC, Flores ACC et al. Anomalous origin of pulmonary branches from the ascending aorta. A report of five cases and review of the literature. *J Cardiol* 2015;11:1-6.
57. Cho S, Kim WH, Choi ES, Lee JR, Kim YJ. Surgical results of anomalous origin of one pulmonary artery branch from the ascending aorta. *Pediatr Cardiol* 2015;1-7. DOI 10.1007/s00246-015-1197-2.
58. Xie L, Gao L, Wu Q, Huang C, Yang JF, Zhao TL et al. Anomalous origin of the right pulmonary artery from the ascending aorta: results of direct implantation surgical repair in 6 infants. *J Cardiothorac Surg* 2015;10:97.
DOI 10.1186/s13019-015-0307-9.
59. Gula G, Chew C, Radley-Smith R, Yacoub M. Anomalous origin of the right pulmonary artery from the ascending aorta associated with aortopulmonary window. *Thorax* 1978;33:265-9.
60. Py A, Lazarus A, Spaulding C, Toussaint M, Planche C, Duboc D et al. Left pulmonary artery originating from the ascending aorta in Tetralogy of Fallot. Therapeutic strategy. *Archives des maladies du coeur et des vaisseaux* 1993;86:1069-72.
61. Soylu M, Demir AD, Tikiz H, Kisacik H, Korkmaz S. Left hemitruncus associated with Tetralogy of Fallot: a case report. *Catheter Cardiovasc Interv* 2000;51:58-60.

62. Cheng W, Xiao Y, Zhong Q, Wen R. Anomalous origin of left pulmonary artery branch from the aorta with Fallot's tetralogy. *Thorac Cardiovasc Surg* 2008;56:432-4.
63. Kuinose M, Tanemoto K, Murakami T, Kanaoka Y, Kobayashi G, Makabe, M et al. Surgical treatment for a 16-year-old girl with anomalous origin of the right pulmonary artery from ascending aorta. *Jpn J Thorac Surg* 1998; 46:380-4
64. Dwivedi SK, Vijay SK, Chandra S, Sran RK. Left hemitruncus with Tetralogy of Fallot and right aortic arch: rare survival beyond the first decade. *Pediatr Cardiol* 2012;33:863-5.
65. Caro C, Lermanda VC, Lyons HA. Aortic origin of the right pulmonary artery. *Br Heart J* 1957;19:345-52.
66. Rosa U, Wade KC. CT findings in hemitruncus. *J Comput Assist Tomogr* 1987;11:698-700.
67. Sechtem U, Jungehulsing M, de Vivie R, Mennicken U, Hopp HW. Left hemitruncus in adulthood: diagnostic role of magnetic resonance imaging. *Eur Heart J* 1992;13:1040-44.
68. Prasad K, Radhakrishnan S, Mittal PK. Anomalous origin of the left pulmonary artery from the aorta in an adult as an isolated anomaly: a case report. *Int J Cardiol* 1993;38:326-29.
69. Mittal PK, Agarwal SK, Ghosh PK. Isolated anomalous origin of left pulmonary artery from the ascending aorta in an adult. *J Thorac Cardiovasc Surg* 1993;106:1220-3.
70. Igarashi K, Masashi H. Origin of the right pulmonary artery from the ascending aorta. Longest survivor without receiving surgical repair. *Chest* 1994;105:1280-2.
71. Edasery B, Sharma M, Vaddigiri V, Santucci T. Hemitruncus presenting in an adult a case report. *Angiology* 1996;47:1023-6.
72. Rangel A, Arguero R, Albarran H, Ocampo H, Baleon R, Nandayapa O et al. Aortic origin of the right pulmonary artery associated with ductus arteriosus in an adult. A case report. *Arch Inst Cardiol Mex* 2000;70:596-602.
73. Herren T, Wustmann K, Ruder T, Nicod LP, Schwerzmann M. An unusual cause of hemoptysis - aberrant origin of the left pulmonary artery from the ascending aorta in the adult. *Congenit Heart Dis* 2010;5:638-40.
74. Nikolaidis N, Velissaris T, Haw MP. Pulmonary artery banding for hemi-truncus arteriosus in adulthood. *Thorac Cardiovasc Surg* 2010;58:181-3.
75. Talwar S, Kothari SS, Sharma P, Chauhan S, Gulati GS, Choudhary SK et al. Successful surgical correction of anomalous origin of the right pulmonary artery from the aorta in an adult. *J Card Surg* 2011;26:201-16.
76. He J, Li H, Li Y, Gui L, Mao X. Anomalous origin of the right pulmonary artery from the ascending aorta. *Herz* 2015;40:311-3.
77. Nigam A, Trehan V. Left hemitruncus with normal right-sided pressures in an adult. *Cardiol Young* 2014;24:926-8.
78. Khajali Z, Mohammadzadeh A, Khayatzadeh M. Anomalous origin of the right pulmonary artery from the ascending aorta accompanied by absent pulmonary valve syndrome and right-sided aortic arch: a rare case in adult congenital heart disease. *Cardiol Young* 2014:1-3.

79. Haywood LJ, Chakryan Y, Kim D, Boltzer T, Rivas G, Shavelle D. Abnormal origin of the right pulmonary artery from ascending aorta (hemitruncus arteriosus). *J Invest Med High Impact Case Rep* 2014;2:1-3.
80. Kim M, Woo JJ, An JK, Cho YK. Anomalous origin of the right pulmonary artery from the ascending aorta associated with patent ductus arteriosus: focusing on computed tomography findings. *Jpn J Radiol* 2015;33:164-8.
81. Ananthakrishna R, Moorthy N, Rao DP, Nanjappa MC. An adult with central cyanosis and differential pulmonary vascularity. *Ann Pediatr Card* 2015;8:253-4.
82. Penkoske PA, Castaneda AR, Fyler DC, Van Praagh R. Origin of pulmonary artery branch from the ascending aorta. Primary surgical repair in infancy. *J Thorac Cardiovasc Surg* 1983;85:537-45.
83. Yamaki S, Suzuki Y, Ishizawa S, Kagawa Y, Horiuchi T, Sato T. Isolated aortic origin of right pulmonary artery. Report of a case with special reference to pulmonary vascular disease in the left and right lung. *Chest* 1983;83:575-8.
84. Czarnecki SW, Hopeman AR, Child PL. Tetralogy of Fallot with aortic origin of the left pulmonary artery: Radiographic and angiocardiographic considerations: report of a case. *Chest* 1964;46:97-101.
85. Saxena A, Shrivastava S, Sharma S. Anomalous origin of the left pulmonary artery from the ascending aorta in a patient with tetralogy of Fallot and "absent pulmonary valve". *Int J Cardiol* 1991;33:315-7.
86. Taskande A, Thomas E, Gautami V, Murthy KS. Diagnosis of aortic origin of a pulmonary artery by echocardiography. *Images Paediatr Cardiol* 2010;12:5-9.
87. Diab K, Richardson R, Pophal S, Alboleros E. Left hemitruncus associated with Tetralogy of Fallot: fetal diagnosis and postnatal echocardiographic and cardiac computed tomographic confirmation. *Pediatr Cardiol* 2010;31:534-7.
88. Jung MJ, Yoo SJ. Prenatal diagnosis of anomalous origin of the right pulmonary artery from the ascending aorta. *Cardiol Young* 2002;12: 186-8.
89. Tsukimori K, Morihana E, Fusazaki N, Fujita Y. Prenatal images of left hemitruncus in Tetralogy of Fallot with an absent pulmonary valve. *Pediatr Cardiol* 2013;34:1285-7.
90. Sreeram N, Walsh K. Aortopulmonary window with aortic origin of the right pulmonary artery. *Int J Cardiol* 1991;31:249-51.
91. Bockeria LA, Makhachev OA, Sobolev AV, Plakhova VV, Gorbachevsky SV, Zaets SB. Double outlet right ventricle with anomalous left pulmonary artery. *Asian Cardiovasc Thorac Ann* 2008;16:e18-20.
92. Yoo SJ, Choi HY, Park IS, Hong CY, Song MG, Kim SH. Distal aortopulmonary window with aortic origin of the right pulmonary artery and interruption of the aortic arch (Berry syndrome): diagnosis by MR imaging. *Am J Roent* 1991;157:835-6.
93. Siy LL, Chen MR, Chiu IS, Lee BS, Chiu CB, Wu YL. Right pulmonary artery arising from ascending aorta: report of a successfully treated case. *J Formos Med Assoc* 1993;92:751-4.
94. Kim TK, Choe YH, Kim HS, Ko JK, Lee YT, Lee HJ et al. Anomalous origin of the right pulmonary artery from the ascending aorta: diagnosis by magnetic resonance imaging. *Cardiovasc Intervent Radiol* 1995;18:118-21.
95. Lin MH, Shen CT, Wang NK, Lin YM, Jeng CM. Magnetic resonance imaging of the right pulmonary artery from the ascending aorta in association with ventricular septal defect. *Am Heart J* 1996;132:1073-4.

96. Katayama H, Shimizu T, Tanaka Y, Narabayashi I, Tamai H. Three dimensional magnetic resonance angiography of vascular lesions in children. *Heart Vessels* 2000;15:1-6.
97. Koplay M, Erol C, Paksoy Y, Uysal E, Arslan D, Oran B. Hemitruncus arteriosus: cardiac magnetic resonance angiography findings. *Congenit Heart Dis* 2012;7:e66-69.
98. Ozyurt A, Ceyran H, Baykan A, Argun M, Pamukcu O, Uzum K et al. Staged surgical treatment in an infant with left hemitruncus. *Turk Gogus Kalp Dama* 2014;22:620-4.
99. Changela V, John C, Maheshwari S. Unusual cardiac associations with Tetralogy of Fallot- a descriptive study. *Pediatr Cardiol* 2010;31:785-91.
100. Aly AM, Reid DA, Jiwani AK, Desai PH. Absent pulmonary valve syndrome with left hemitruncus. *Am J Perinatal Rep* 2012;2:51-4.
101. Kumar TKS, Talwar S, Sinha P, Fan D, Slack M, Moulick A. Interrupted aortic arch with anomalous origin of left pulmonary artery from aorta. *Congenit Heart Dis* 2009;4:485-8.
102. Keutel J, Kampmann A, Kyrieleis C. Abnormal origin of the right pulmonary artery from the ascending aorta. Report of four cases, one of them with additional mitral and aortic atresia. *Zeitschrift far Kardiologie* 1973;62:567-85.
103. Gybels Y, Grapow MTR, Todorov A, Wagner G, Zerkowski HR. Aberrant right pulmonary artery and double outlet ventricle: One-stage repair. *Ann Thorac Surg* 2000;69:630-2.
104. Talwar S, Rajashekar P, Gupta SK, Gulati GS, Choudhary SK, Airan B. Hemitruncus, septal defect, and anomalous coronary artery from pulmonary artery. *Asian Cardiovasc Thorac Ann* 2013;21:338-41.
105. Sievers HH, Lange PE, Radtcke W, Hahne HJ, Heintzen P, Bernhard A. Repair of anomalous origin of the right pulmonary artery from the ascending aorta associated with subtotal left cortriatriatum. *Ann Thorac Surg 1985*;39:80-1.
106. Kobayashi D, Cook A, Williams D. Anomalous origin of left pulmonary artery from the aorta with partial anomalous pulmonary venous return. *Pediatr Cardiol* 2010;31:560-1.
107. Dodo H, Alejos JC, Perloff JK, Laks H, Drinkwater DC, Williams RG. Anomalous origin of the left main pulmonary artery from the ascending aorta associated with DiGeorge syndrome. *Am J Cardiol* 1995;75:1294-5.
108. Takahashi K, Kido S, Hoshino K, Oqawa K, Ohashi H, Fukushima Y. Frequency of a 22q11 deletion in patients with conotruncal cardiac malformations: a prospective study. *Eur J Pediatr* 1995;154:878-81.
109. Saliba Z, Le Bidois J, Sidi D, Kachaner J, Bonnet D. Prenatal detection of a tetralogy of fallot with origin of the left pulmonary artery from the ascending aorta in a familial 22q11 microdeletion. *Prenat Diagn* 1999;19:260-2.
110. Mo CN, Ladusans EJ. Anomalous right pulmonary artery origins in association with the fetal valproate syndrome. *J Med Genet* 1999;36:83-4.
111. Berry TE, Bharati 5, Muster AJ, et al. Distal aortopulmonary septal defect, aortic origin of the right pulmonary artery, intact ventricular septum, patent ductus arteriosus and hypoplasia of the aortic isthmus: a newly recognized syndrome. *Am J Cardiol* 1982:49:108-16.
112. Sharma J, Saleh M, Das BB. Berry syndrome with trisomy 13. *Pediatr Cardiol* 2002;23:205-9.

113. Mannelli L, Mosca R, Henry G, Srichai-Parsia MB. A case of berry syndrome type 2B. *Congenit Heart Dis* 2011;6:389-92.
114. Hamzeh G, Crespo A, Rey E, Blanco R, Luis M, Rodriguez MA et al. Right aortic arch with aberrant left subclavian artery and anomalous origin of right pulmonary artery from ascending aorta. *World J Pediatr Congenit Heart Surg* 2011;2:324-6.
115. Paredes AM, Caspi J, Lilje C. Tetralogy of Fallot and anomalous origin of the left pulmonary artery from the ascending aorta associated with absent right internal carotid artery. *World J Pediatr Congenit Heart Surg* 2015;6,324-7.
116. Nonoyama M, Imai Y, Sawatari K, Nagatsu M. Anomalous origin of the right pulmonary artery from the ascending aorta. A report of eight cases. *J Jpn Assoc Thorac Surg* 1994;42:83-9. [in Japanese]
117. Armer RM, Shumacker HB, Klatte EC. Origin of the right pulmonary artery from the ascending aorta. Report of a surgically corrected case. *Circulation* 1961;24:662-8.
118. Kirkpatrick SE, Girod DA, King H. Aortic origin of the right pulmonary artery. Surgical repair without a graft. *Circulation* 1967;36:777-82.
119. Van Son JA, Hanley FL. Use of autogenous aortic and main pulmonary artery flaps for repair of anomalous origin of the right pulmonary artery from the ascending aorta. *J Thorac Cardiovasc Surg* 1996;111:675-6.
120. Marcano SL, Gonzalez GA, Lambert MJ, Senra RLM. Repair of an anomalous origin of the left pulmonary artery from the ascending aorta. *Ann Thorac Surg* 2013;96:121-123.
121. Levy E, Milgalter E, Nir A, Rein AJ. Repair of anomalous pulmonary artery with interposition graft: Midterm Results. *Asian Cardiovasc Thorac Ann* 2005;13:217-21.
122. Sugimoto S, Kikuchi S, Oosawa H, Hachiro Y, Takagi N, Abe T. A reoperation for anomalous origin of right pulmonary artery: report of a case. *Surg Today* 2001;31:643-5.
123. Goldstein BH, Bergersen L, Powell AJ, Graham DA, Bacha EA, Lang P. Long-term outcome of surgically repaired unilateral anomalous pulmonary artery origin. *Pediatr Cardiol* 2010;31:944-51.
124. Arboleda M, Nino de Guzman I, Ticona E, Morales G, Gloria E, Obregon P et al. Surgical repair of the anomalous origin of the right pulmonary artery from the ascending aorta. *Arq Bras Cardiol* 2004;83:519-21.
125. Martinez PD, Dery J, Vobecky S, Bigras JL, Lapierre C. Right pulmonary artery torsion following surgical reimplantation. *Pediatric Radiology* 2012;42:1514-6.

References: Part 3 - Discussion

1. Garg P, Talwar S, Kothari SS, Saxena A, Juneja R, Choudhary SK et al. The anomalous origin of the branch pulmonary artery from the ascending aorta. *Interact Cardio Vasc Thorac Surg* 2012;15:86-92.
2. Fraentzel O. Ein fall von abnormer communication der aorta mit der arteria pulmonalis. *Virchows Arch Pathol Ana.*1868;43:420-6.
3. Keane JF, Maltz D, Bernhard WF, Corwin RD, Nadas AS. Anomalous origin of one pulmonary artery from the ascending aorta. Diagnostic, physiological and surgical considerations. *Circulation* 1974;50:588-94.
4. Kutsche LM, Van Mierop LH. Anomalous origin of a pulmonary artery from the ascending aorta: associated anomalies and pathogenesis. *Am J Cardiol* 1988;61:850-6.
5. Liu Y, Cheng L, Qian X, Zhu H, Duan W, Yu S et al. Surgical correction of anomalous origin of one pulmonary artery without grafts in infants. *J Card Surg* 2015;30:85-91.
6. Fontana GP, Spach MS, Effman EL, Sabiston DC Jr. Origin of the right pulmonary artery from the ascending aorta. *Ann Surg* 1987;206:102-13.
7. Abu-Sulaiman RM, Hashmi A, McCrindle BW, Williams WG, Freedom RM. Anomalous origin of one pulmonary artery from the ascending aorta: 36 years experience from one centre. *Cardiol Young* 1998; 8:449-54.
8. Fong LV, Anderson RH, Siewers RD, Trento A, Park SC. Anomalous origin of one pulmonary artery from the ascending aorta: a review of echocardiographic, catheter, and morphological features. *Br Heart J* 1989 62:389-95.
9. Prifti E, Crucean A, Bonacchi M, Bernabei M, Leacche M, Murzi B et al. Postoperative outcome in patients with anomalous origin of one pulmonary artery branch from the aorta. *Eur J Cardiothorac Surg* 2003;24:21-7.
10. Haywood LJ, Chakryan Y, Kim D, Boltzer T, Rivas G, Shavelle D. Abnormal origin of the right pulmonary artery from ascending aorta (hemitruncus arteriosus). *J Invest Med High Impact Case Rep* 2014;2:1-3 http://dx.doi.org/10.1177/ 2324709614536139 (2324709614536139).
11. Kim M, Woo JJ, An JK, Cho YK. Anomalous origin of the right pulmonary artery from the ascending aorta associated with patent ductus arteriosus: focusing on computed tomography findings. *Jpn J Radiol* 2015;33:164-8.
12. Hoosen EGM, Cilliers AM, Hugo-Hamman CT, Brown SC, Lawrenson JB, Zuhlke L et al. Paediatric cardiac services in South Africa. *S Afr Med J* 2011;101:106-7.
13. Hoosen EGM, Cilliers AM, Hugo-Hamman CT, Brown SC, Harrisberg JR, Takawira FF et al. Optimal paediatric cardiac services in South Africa - what do we need ? Statement of the Paediatric Cardiac Society of South Africa: paediatric cardiac services. *SA Heart* 2010;7:10-6.
14. Nathan M, Rimmer D, Piercey G, Del Nido PJ, Mayer JE, Bacha EA et al. Early repair of hemitruncus: excellent early and late outcomes. *J Thorac Cardiovasc Surg* 2007;133:1329-35.
15. Talwar S, Meena A, Choudhary SK, Kothari SS, Gupta SK, Saxena A et al. Anomalous branch of pulmonary artery from the aorta and Tetralogy of Fallot: morphology, surgical techniques and results. *Euro J Cardio Thorac Surg* 2014;46:291-6.

16. Cho S, Kim WH, Choi ES, Lee JR, Kim YJ. Surgical results of anomalous origin of one pulmonary artery branch from the ascending aorta. *Pediatr Cardiol* 2015;1-7. DOI 10.1007/s00246-015-1197-2.
17. Benatar A, Kinsley RH, Milner S, Dansky R, Hummel DA, Levin SE. Surgical correction for one pulmonary artery arising from ascending aorta - report of five cases. *Int J Cardiol* 1987;16:249-55.
18. Manuel V, Sousa-Uva M, Morais H, Magalhaes MP, Pedro A, Miguel G et al . Anomalous origin of the pulmonary artery from the ascending aorta: from diagnosis to treatment in Angola. *World J Pediatr Congenit Heart Surg* 2015;6:521-5.
19. Chaudhuri M, Mahimarangaiah J, Chandra S, Shivanna DN. Catastrophic presentation of anomalous origin of right pulmonary artery in a neonate - an interesting differential. *Indian J Pediatr* 2014;81:1102-4.
20. Kajihara N, Imoto Y, Sakamoto M, Ochiai Y, Kan-o M, Joo K et al. Surgical results of anomalous origin of the right pulmonary artery from the ascending aorta including reoperation for infrequent complications. *Ann Thorac Surg* 2008;85:1407-11.
21. Amir G, Frenkel G, Bruckheimer E, Dagan T, Katz J, Berant M et al. Anomalous origin of the pulmonary artery from the aorta: early diagnosis and repair leading to immediate physiological correction. *Cardiol Young* 2010;20:654-9.
22. Sibley YDL, Roberts KD, Silove ED. Surgical correction of anomalous origin of right pulmonary artery from aorta in a four day old neonate. *Br Heart J* 1986;56:98-100.
23. Bi W, Ren W, Song G, Shang C, Pan F, Xu M. Anomalous origin of one pulmonary artery from the ascending aorta (hemitruncus) in a premature infant: A case report and literature review. *J Clin Ultrasound* 2014;42:367-70.
24. Godown J, Baker C, Kuhn N, Brown K, Buck S, Mill M et al. Delayed repair of hemitruncus in an extremely low birth weight infant. *Congenit Heart Dis* 2013;8:E13-6.
25. Hu Y, Yang Y, Kan C. One-stage total repair of anomalous origin of right pulmonary artery from aorta by the double-flap technique, followed by coarctation repair using extended end-to-end arch reconstruction. *Ann Thorac Surg* 2013;6:71-3.
26. Marui A, Mochizuki T, Mitsui N, Koyama T, Horibe M. Anomalous origin of the right pulmonary artery from the ascending aorta - a report of three operative cases. *Nihon Kyobu Geka Gakkai Zasshi* 1997;45:1189-94.
27. Johnson MC, Watson MS, Strauss AW, Spray TL. Anomalous origin of the right pulmonary artery from the aorta and CATCH 22 syndrome. *Ann Thorac Surg* 1995;60:681-3.
28. Vida VL, Sanders SP, Bottio T, Maschietto N, Rubino M, Milanesi O et al. Anomalous origin of one pulmonary artery from the ascending aorta. *Cardiol Young* 2005;15:176-81.
29. Salaymeh KJ, Kimball TR, Manning PB. Anomalous pulmonary artery from the aorta via a patent ductus arteriosus: repair in a premature infant. *Ann Thorac Surg* 2000;69:1259-61.

30. Guzoglu N, Sari FN, Altug N. An unusual cause of refractory persistent pulmonary hypertension of the newborn: anomalous origin of one pulmonary artery. *Cardiol Young* 2014;24:543-5.
31. Weisberg JS, Jacobson IM. Cardiovascular diseases and the liver. *Clin Liver Dis* 2011;15:1-20.
32. Asrani SK, Asrani NS, Freese DK, Phillips SD, Warnes CA, Heimbach J et al. Congenital heart disease and the liver. *Hepatology* 2012;56:1160-9.
33. Ford RM, Book W, Spivey JR. Liver disease related to the heart. *Transplant Rev* 2015;29:33-7.
34. Giallourakis CC, Rosenberg PM, Friedman LS. The liver in heart failure. *Clin Liver Dis* 2002;6:947-67.
35. Samsky MD; Patel CB, DeWald TA, Smith AD, Felker GM, Rogers JG et al. Cardiohepatic interactions in heart failure: an overview and clinical implications. *J Am Coll Cardiol* 2013;61:2397-405.
36. Kavoliuniene A, Vaitiekiene A, Cesnaite G. Congestive hepatopathy and hypoxic hepatitis in heart failure: a cardiologist's point of view. *Int J Cardiol* 2013;166:554-8.
37. Erdem A, Aydemir NA, Demir H, Zeybek C, Saritas T, Akdeniz C et al. Anomalous origin of one pulmonary artery branch from the ascending aorta: experience of our center. *Arch Turk Soc Cardiol* 2010;38:411-15.
38. Saxena A, Shrivastava S, Sharma S. Anomalous origin of the left pulmonary artery from the ascending aorta in a patient with tetralogy of Fallot and "absent pulmonary valve". *Int J Cardiol* 1991;33:315-7.
39. Wang J, Song Y, Cheng TO, Xie M, Wang X, Yuan L et al. The value of transthoracic echocardiography in the diagnosis of anomalous origin of the right pulmonary artery from the ascending aorta: a single center experience from China. *Int J Cardiol* 2015;184:750-4.
40. Garg N, Moorthy N, Jain S, Neyaz Z, Kumar S. Hemitruncus with large patent ductus arteriosus simulating d-transposition of great arteries. *J Indian Coll Cardiol* 2014;5:29-31.
41. Agarwala B, Waldman JD, Sand M, Loe WA, Ruschhaup DG. Aortic origin of the RPA: immediate resolution of severe pulmonary artery hypertension by surgical repair. *Pediatr Cardiol* 1994;15:41-4.
42. Wong JA, Cheng W. Preoperative management of right ventricular dysfunction in aortic origin of the right pulmonary artery. *Pediatr Cardiol* 2000;21:388.
43. Talwar S, Kothari SS, Sharma P, Chauhan S, Gulati GS, Choudhary SK et al. Successful surgical correction of anomalous origin of the right pulmonary artery from the aorta in an adult. J Card Surg 2011;26:201-16.
44. Liu H, Juan YH, Chen J, Xie Z, Wang Q, Zhang X et al. Anomalous origin of one pulmonary artery branch from the aorta: role of MDCT angiography. *Am J Roentgenol* 2015;204:979-87.
45. Rosa U, Wade KC. CT findings in hemitruncus. *J Comput Assist Tomogr* 1987;11:698-700.
46. Sechtem U, Jungehulsing M, de Vivie R, Mennicken U, Hopp HW. Left hemitruncus in adulthood: diagnostic role of magnetic resonance imaging. *Eur Heart J* 1992;13:1040-4.

47. Koplay M, Erol C, Paksoy Y, Uysal E, Arslan D, Oran B. Hemitruncus arteriosus: cardiac magnetic resonance angiography findings. *Congenit Heart Dis* 2012;7:E66-9.
48. Pepeta L, Takawira FF, Adams PE, Ntsinjana NH, Mitchell BJ, Cilliers AM. Anomalous origin of the left pulmonary artery from the ascending aorta in two children with pulmonary atresia, subaortic ventricular septal defect and right-sided major aorto-pulmonary collateral arteries. *Cardiovasc J Afr* 2011;22:268-71.
49. Peng EWK, Shanmugam G, Macarthur KJD, Pollock JCS. Ascending aortic origin of a branch pulmonary artery - surgical management and long-term outcome. *Euro J Cardio Thorac Surg* 2004;26:762-6.
50. Takahashi K, Kido S, Hoshino K, Oqawa K, Ohashi H, Fukushima Y. Frequency of a 22q11 deletion in patients with conotruncal cardiac malformations: a prospective study. *Eur J Pediatr* 1995;154:878-81.
51. Igarashi K, Masashi H. Origin of the right pulmonary artery from the ascending aorta. Longest survivor without receiving surgical repair. *Chest* 1994;105:1280-2.
52. Edasery B, Sharma M, Vaddigiri V, Santucci T. Hemitruncus presenting in an adult a case report. *Angiology* 1996;47:1023-6.
53. Long MA, Brown SC, de Vries WJ. Anomalous origin of the right pulmonary artery from the ascending aorta: a surgical case study in an adult patient with "irreversible" pulmonary vascular disease. *J Card Surg* 2009;24:212-5.
54. He J, Li H, Li Y, Gui L, Mao X. Anomalous origin of the right pulmonary artery from the ascending aorta. *Herz* 2015;40:311-3.
55. Levy E, Milgalter E, Nir A, Rein AJ. Repair of anomalous pulmonary artery with interposition graft: Midterm Results. *Asian Cardiovasc Thorac Ann* 2005;13:217-21.
56. Goldstein BH, Bergersen L, Powell AJ, Graham DA, Bacha EA, Lang P. Long-term outcome of surgically repaired unilateral anomalous pulmonary artery origin. *Pediatr Cardiol* 2010;31:944-51.

5.1 **APPENDIX A:** Ethics Clearance

M140739

HUMAN RESEARCH ETHICS COMMITTEE (MEDICAL)

CLEARANCE CERTIFICATE NO. M140739

NAME: (Principal Investigator)	Dr Gcina Dumani
DEPARTMENT:	Division of Paediatric Cardiology Chris Hani Baragwanath Academic Hospital
PROJECT TITLE:	Morbidity and Mortality Associated with Anomalous Origin of the Pulmonary Artery from the Aorta: A Review of Cases as a Southern African Tertiary Care Institution
DATE CONSIDERED:	25/07/2014
DECISION:	Approved unconditionally
CONDITIONS:	
SUPERVISOR:	Prof AM Cilliers

APPROVED BY:

Professor PE Cleaton-Jones, Chairperson, HREC (Medical)

DATE OF APPROVAL: 25/07/2014

This clearance certificate is valid for 5 years from date of approval. Extension may be applied for.

DECLARATION OF INVESTIGATORS

To be completed in duplicate and **ONE COPY** returned to the Secretary in Room 10004, 10th floor, Senate House, University.

I/we fully understand the conditions under which I am/we are authorized to carry out the above-mentioned research and I/we undertake to ensure compliance with these conditions. Should any departure be contemplated, from the research protocol as approved, I/we undertake to resubmit the application to the Committee. **I agree to submit a yearly progress report.**

DR G. DUMANI — 06/03/2015

Principal Investigator Signature — M140739Date

PLEASE QUOTE THE PROTOCOL NUMBER IN ALL ENQUIRIES

5.2 **APPENDIX B:** Ethics Clearance

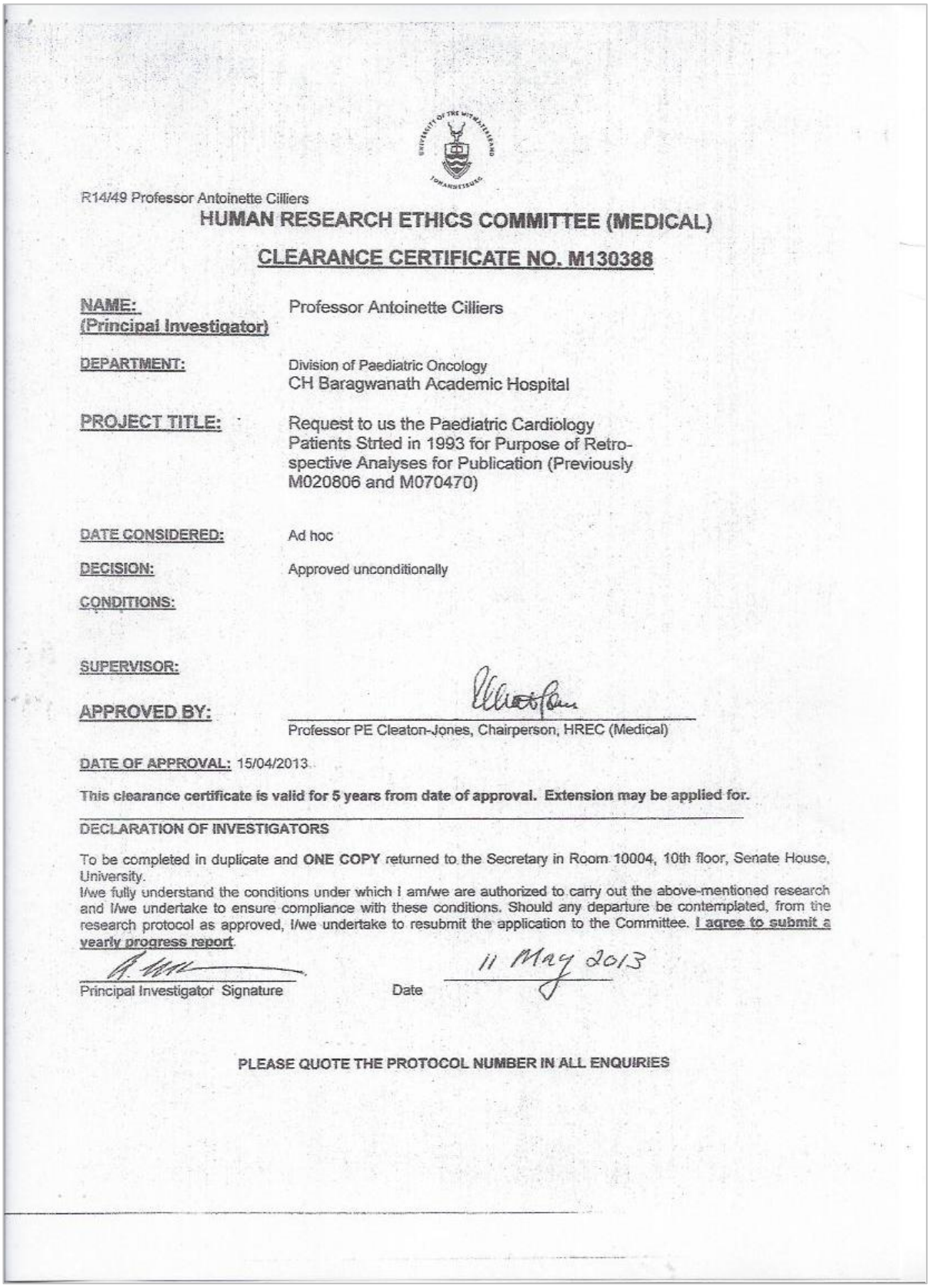

R14/49 Professor Antoinette Cilliers

HUMAN RESEARCH ETHICS COMMITTEE (MEDICAL)

CLEARANCE CERTIFICATE NO. M130388

NAME: (Principal Investigator)	Professor Antoinette Cilliers
DEPARTMENT:	Division of Paediatric Oncology CH Baragwanath Academic Hospital
PROJECT TITLE:	Request to us the Paediatric Cardiology Patients Strted in 1993 for Purpose of Retrospective Analyses for Publication (Previously M020806 and M070470)
DATE CONSIDERED:	Ad hoc
DECISION:	Approved unconditionally
CONDITIONS:	
SUPERVISOR:	
APPROVED BY:	Professor PE Cleaton-Jones, Chairperson, HREC (Medical)

DATE OF APPROVAL: 15/04/2013

This clearance certificate is valid for 5 years from date of approval. Extension may be applied for.

DECLARATION OF INVESTIGATORS

To be completed in duplicate and **ONE COPY** returned to the Secretary in Room 10004, 10th floor, Senate House, University.

I/we fully understand the conditions under which I am/we are authorized to carry out the above-mentioned research and I/we undertake to ensure compliance with these conditions. Should any departure be contemplated, from the research protocol as approved, I/we undertake to resubmit the application to the Committee. **I agree to submit a yearly progress report**.

Principal Investigator Signature

Date 11 May 2013

PLEASE QUOTE THE PROTOCOL NUMBER IN ALL ENQUIRIES

5.3 **APPENDIX C:** Plagiarism Certificate

Turnitin Originality Report

Dissert Correct AOPA Draft 5.pdf by Gcina Dumani

From MMed submission 2015 (8P1Gr6Q2at0C3dybh9vW36k1KFM27938QYKA20NjSvhDWoeS908jGcO1K9xykBzQ1d1fw7nzyHWnjLvlL4hs9fYkH6PQx8ht8og)

- Processed on 09-Nov-2015 5:24 PM SAST
- ID: 597580495
- Word Count: 26369

Similarity Index

20%

Similarity by Source
Internet Sources:
18%
Publications:
14%
Student Papers:
4%

sources:

1

2% match (publications)
Hoffman. "Anomalous Origin of One Pulmonary Artery from the Aorta (Hemitruncus)", The Natural and Unnatural History of Congenital Heart Disease, 08/28/2009

2

1% match (Internet from 16-Oct-2015)
http://www.revespcardiol.org/en/aortic-origin-of-the-left/articulo/13078861/

3

1% match (Internet from 10-Jul-2010)
http://ejcts.ctsnetjournals.org/cgi/content/full/24/1/21

4

1% match (publications)
Edvin Prifti. "Anomalous Origin of the Right Pulmonary Artery from the Ascending Aorta", Journal of Cardiac Surgery, 3/2004

5

1% match (publications)
Nathan, M.. "Early repair of hemitruncus: Excellent early and late outcomes", The Journal of Thoracic and Cardiovascular Surgery, 200705

6

1% match (Internet from 20-Oct-2015)
http://www.cardiothoracicsurgery.org/content/10/1/97

7

1% match (Internet from 12-Oct-2010)
http://asianannals.ctsnetjournals.org/cgi/content/full/13/3/217