

https://dspace.org/

Clinical and immuno-pathological study of cutaneous tuberculosis in the Johannesburg area

Moche, Mohlabe John

2010-09-23
http://hdl.handle.net/10539/8791

Downloaded from a DSpace repository. https://dspace.org/

CLINICAL AND IMMUNO-PATHOLOGICAL STUDY OF CUTANEOUS TUBERCULOSIS IN THE JOHANNESBURG AREA

MOHLABE JOHN MOCHE

Submitted to the Faculty of Health Sciences, University of the Witwatersrand, in partial fulfilment of the requirements for the degree of Master of Medicine in Dermatology.

Johannesburg 2009

DECLARATION

I, Mohlabe John Moche declare that this research report is my own work. It is being submitted for the degree of Master of Medicine to the University of the Witwatersrand, Johannesburg. It has not been submitted before for any degree or examination at this or any other University.

.....

M J MOCHE

26th ....November....2009

DEDICATION

This research report is dedicated to my parents John and Eunica, my wife Brenda and two children Masego and Bokang.

ABSTRACT

Introduction: Cutaneous tuberculosis (TB) accounts for about 2 - 3% of all cases of tuberculosis. It is as a result of direct infection of the skin or immune responses to antigenic components of *Mycobacterium tuberculosis*, known as tuberculids. In sub-Saharan Africa around 70% of patients with tuberculosis are co - infected with the human immunodeficiency virus (HIV). The prevalence of HIV in South Africa is approximately 11.4%. There are no studies in South Africa on the manifestations of cutaneous tuberculosis in the setting of HIV infection.

Aims: The objectives of this study were to determine the clinical and histopathological spectrum of cutaneous tuberculosis in the Johannesburg area and to assess the correlation of HIV infection and CD4 count, on the clinical and pathological presentation.

Patients and Methods: This was a prospective, hospital-based study conducted over a period of 3 ½ years from Oct 2004 - March 2008. A total of 74 patients diagnosed with cutaneous tuberculosis who were seen during the above mentioned period were enrolled for the study. Patients were enrolled from the three academic hospitals, Johannesburg, Chris Hani Baragwanath and Helen Joseph. Inclusion criteria included patients aged 10 years and older diagnosed with cutaneous tuberculosis. Patients from whom consent could not be obtained and those with lesions caused by non-tuberculous mycobacteria were excluded from the study.

The diagnosis was based on clinical and histopathological features as well as supportive diagnostic tests. Data was captured onto Epi-Info spreadsheet and then analyzed using STATA data software.

Results: The entire clinical spectrum of lesions of cutaneous TB was seen with the exception of the nodular and phlebetic tuberculids. Erythema induratum, a tuberculid was the most common form of cutaneous TB accounting for more than a third (36.5%) of all cases. Scrofuloderma was the most common true infection accounting for about 29.7% of all cases. HIV-TB co-infection rate was 61.4%. The histology ranged from a granulomatous inflammation with absence of bacilli to a diffuse inflammation with abundance of bacilli.

Conclusions: Despite the high prevalence of TB and high TB-HIV co-infection rate, cutaneous tuberculosis infection is still relatively uncommon. There is a however a relative increase in the frequency of true infections particularly scrofuloderma in comparison with the studies done previously here in South Africa. The association between HIV positive status and true infections was statistically significant with $p = 0.024$ and was not found to be statistically significant between HIV positive status and tuberculids with $p = 0.71$.

ACKNOWLEDGEMENTS

The assistance and guidance of my supervisor Prof Deepak Modi (Division of Dermatology), co-supervisor Prof Ahmed Wadee (School of Pathology, Division of Immunology and National health laboratory services), Prof Wayne Grayson (Division of Anatomical Pathology), Prof Mohamed Tikly (Division of Rheumatology) and Eustasius Musenge (Bio-Statistician, Epidemiology data center at Wits) is greatly appreciated. I would also like to thank Prof J Schulz, Dr S Glassman, Mr M Rammutla, Dr F Patel and registrars of the departments of Dermatology and Pathology. My sincere gratitude to Galderma SA and the Faculty research council of University of the Witwatersrand for their financial assistance.

TABLE OF CONTENTS Page

Declaration ii

Dedication iii

Abstract iv

Acknowledgements vi

Table of contents vii

Introduction viii

Present study ix

List of figures x

List of tables and diagrams xi

Preface xii

INTRODUCTION Page

1.1.1 Definition 1

1.1.2 Classification 1

1.1.3 History of cutaneous TB 5

1.1.4 Epidemiology of TB 6

1.1.5 Immunology of TB 7

1.1.6 HIV-TB co-infection 8

1.2 Clinical subtypes of cutaneous TB 9

1.3 Diagnosis and Treatment 17

1.4 Non-tuberculous mycobacteria (NTM) 21

PRESENT STUDY Page

2.1 Background 23

2.3 Patients and Methods 24

3.1 Results 29

3.2 Statistical Analysis 45

4.1 Discussion 47

4.3 Conclusions 56

Legends to figures 63

References 64

LIST OF FIGURES Page

1. Scrofuloderma 41

2. Lupus Vulgaris a. Clinical image 42

b. Histology (haematoxylin & eosin) 42

3. Miliary TB a. Clinical image 43

b. Histology (haematoxylin & eosin) 43

c. Ziehl-Nielsen Stain 43

4. TB Orificialis a. Clinical image 44

b. Histology (haematoxylin & eosin) 44

c. Clinical image post-treatment 44

5. Erythema Induratum a. Clinical image 52

b. Histology (haematoxylin & eosin) 52

c. Histology (haematoxylin & eosin) 53

d. Histology (haematoxylin & eosin) 53

6. Papulonecrotic tuberculid (a),(b) Clinical images 54

7. Papulonecrotic tuberculid (a), with associated dactylitis (b,c) 55

LIST OF TABLES

	Page
1a. Modified Beyt *et al* classification	3
b. Original Beyt *et al.* suggested classification	4
2. Tuberculosis treatment a. Regimen 1	22
b. Recommended dosages in mg/kg	22
3. Total subtypes of skin TB and frequency of occurrence	37
4. True skin infections and HIV status	38
5. Tuberculids and HIV status	39
6. Overlapping skin TB lesions (dual pathology)	40
7. True skin infections : Clinico-pathological findings	57
8. Tuberculids : Clinico-pathological findings	58
9. CD4 counts in HIV positive patients	61

DIAGRAMS

1. Pie chart : male to female ratios	59
2. Subtypes of cutaneous TB and HIV status	60
3. CD4 counts in HIV positive patients	61
4. Subtypes of cutaneous TB and gender	62

PREFACE

Cutaneous tuberculosis is an uncommon condition affecting mainly black patients in South Africa.[1-3] There are two main groups, the tuberculids and true infections. Tuberculids are hypersensitivity reactions due to haematogenous spread of antigenic components of *M. tuberculosis* in persons with a moderate or high degree of immunity against *M. tuberculosis*. Patients with tuberculids have an active focus of tuberculosis infection elsewhere in the body. True infections are due to direct inoculation or haematogenous spread of *M. tuberculosis* resulting in the characteristic skin lesions.

There are no reports of cutaneous tuberculosis in the setting of HIV infection in South Africa. The largest study on cutaneous tuberculosis in this country was done over a period of ten years from 1982 - 1993 at Ga-Rankuwa (now George Mukhari) hospital, north west of Pretoria.[1] It was a retrospective study in which data of 92 patients seen during that period was analyzed. The concluding remark of the author pertaining to HIV/AIDS was that its influence on the incidence and clinical pattern of cutaneous tuberculosis remained to be seen.

CHAPTER 1

1.1 Introduction

1.1.1 Definition

Tuberculosis of the skin is caused mainly by *M. tuberculosis* and very rarely by *M. bovis* and bacillus Calmette-Guerin (BCG). It can be due to true or direct infection of the skin or hypersensitivity reactions to the antigenic components of *M. tuberculosis.*[4,5]

1.1.2 Classification

There is no single satisfactory classification and Beyt *et al.* modified classification was used for the purposes of this study (table1a). It takes into account host cell mediated immunity and the route of infection. The initial classification of cutaneous tuberculosis was proposed by Eugene Beyt and his colleagues from the University of Washington, School of Medicine in 1978. The authors examined the records of 34 patients with cutaneous mycobacteriosis and subsequently defined a clinically oriented classification system.[6] The shortfall of that classification system was that tuberculids were not included (table 1b). The classification included inoculation TB, secondary and haematogenous TB subtypes only. Skin lesions of TB can be due to an exogenous source as a result of direct inoculation of *M. tuberculosis* as seen in tuberculous chancre, warty TB and lupus vulgaris.

Skin TB lesions can be from an endogenous source due to direct spread of infection from an underlying lymph node as in scrofuloderma, or auto inoculation as seen in TB orificialis. Haematogenous spread of *M. tuberculosis* may result in miliary TB of the skin, lupus vulgaris and tuberculous abscess (gumma). There are 3 recognised tuberculids namely erythema induratum, papulonecrotic tuberculid (PNT) and lichen scrofulosorum. Nodular tuberculid and granulomatous phlebitis have recently been described and are extremely rare.[7,8] Skin TB lesions e.g disseminated TB, lupus vulgaris and papular tuberculids can arise as complications of Bacillus Calmette-Guerin (BCG) vaccination.

Table 1a. Modified Beyt *et al.* classification

I. Inoculation tuberculosis (exogenous source)	Tuberculosis chancre Warty tuberculosis Lupus vulgaris
II. Secondary tuberculosis (endogenous source) a.Contiguous spread b. Auto-inoculation	 Scrofuloderma Orificial tuberculosis
III. Haematogenous tuberculosis	Miliary tuberculosis Lupus vulgaris (some) Tuberculous gumma
IV. Eruptive tuberculosis (the tuberculids) 1. Micropapular 2. Papular 3. Nodular 4. Phlebitic V. Other	 Lichen scrofulosorum Papulonecrotic tuberculid Erythema induratum of Bazin Nodular tuberculid Phlebitic tuberculid BCG - related complications

Table 1b. Original Beyt *et al.* suggested classification in 1978

Proposed classification of cutaneous mycobacteriosis	Terms previously used in the literature
I. Inoculation cutaneous mycobacteriosis from an exogenous source	Primary inoculation, tuberculous chancre, tuberculosis primary complex Tuberculosis verrucosa cutis, verruca necrogenica, prosector's wart, tuberculosis cutis verrucosa.
II. Cutaneous mycobacteriosis from an endogenous source	
A. Contiguous spread	Scrofuloderma, tuberculosis colliguativa cutis
B. Autoinoculation	Orificial tuberculosis, tuberculosis cutis orificialis, tuberculosis ulcerosa cutis et mucosae
III. Cutaneous mycobacteriosis from haematogenous spread	
A. Lupus vulgaris	Lupus vulgaris, tuberculosis luposa cutis
B. Acute haematogenous dissemination	Acute miliary tuberculosis of the skin, tuberculosis cutis miliaris disseminata, tuberculosis cutis acuta generalisata
C. Nodules or abscesses	Tuberculous gumma, metastatic tuberculous abscess

1.1.3 History of Cutaneous Tuberculosis

The *genus* mycobacterium contains more than 80 species, most of which are harmless environmental saprophytes. Disease-causing mycobacteria other than *M. tuberculosis* are referred to as non-tuberculous mycobacteria. The term mycobacterium was given in 1896 to a large group of bacteria producing mould-like pellicles when grown on liquid media. They are aerobic, acid-fast, non-sporing rods with a waxy coating. There is evidence that *M. tuberculosis* may have preceded recorded history because the changes of spinal tuberculosis have been demonstrated in a skeleton of a Neolithic man in ancient Egypt (3400 BC).

Hippocrates (460 - 575 BC) called tuberculosis, phthisis which meant to dry up. The history of cutaneous tuberculosis dates back to the Salerno school of medicine in the 10th century.[9] It was initially recognised only as lupus vulgaris. Lupus is derived from the latin word of wolf. The term lupus vulgaris was coined by Robert Willan, the founder of British Dermatology in 1808. He gave the name to a nodular eruption on the face associated with ulceration. It was however William Fox in 1887 who used the term lupus vulgaris specifically for skin tuberculosis.

Foster described the giant cells and epitheloid cells in lupus lesions in 1855 and the term tuberculoid for these histopathological changes was recommended by Volkman in 1875. Scrofuloderma initially called scrofulous gumma was first described by ancient French writers and Ernest Bernier wrote extensively on its

pathogenesis in 1883. Prosector's wart was first described by René Laennec in 1826. He described a lesion on his own hand and it turned out to be the first published case recognizing the association of cutaneous disease and mycobacterial infection. Tuberculous chancre, or primary inoculation TB, previously called verruca necrogenica was described by Samuel Wilks in 1862. The concept of tuberculids was first introduced by Jean Darier in 1896. Hara *et al.* described the fourth tuberculid, nodular granulomatous phlebitis in 1997. Nodular tuberculid was first described here in South Africa in the year 2000 by Jordaan *et al*. Robert Koch discovered the tubercle bacillus in 1882 and Demme in 1883 demonstrated tubercle bacillus in tissue sections for the first time. Tuberculin reaction was discovered by Clemens von Pirquet in 1907 and Charles Mantoux devised the intracutaneous test in 1908.

1.1.4 Epidemiology of Tuberculosis

A third of the world's population is infected with *M. tuberculosis.*[10-12] There are about nine million new cases of tuberculosis and three million deaths annually. It is estimated that 5 million people are co-infected with human immunodeficiency virus (HIV) and TB and that three-quarters of these live in sub-Saharan Africa. The main reasons for the global TB burden are poverty, overcrowding, poor case management and the impact of HIV pandemic. The incidence rate of TB in South Africa is estimated at 940 /100 000 population, a major increase from 338/100 000 population in 1998.[13] It is way over the world health organization (WHO) overall incidence of 200/100 000 and has been declared an epidemic.

In 2006, South Africa had nearly 453.929 new cases of tuberculosis and in 80% of these patients, the infection was confined to the lungs. Extrapulmonary TB constitute around 10 - 20% of cases of TB and cutaneous TB makes up a small proportion of about 2 - 3% of these cases.[13] There is paucity of large studies which have investigated the incidence of cutaneous TB and its relative frequency in patients with organ TB as well as its association with HIV infection.

1.1.5 Immunology of Tuberculosis

Following infection only 5 - 10% of individuals develop active disease. Cell mediated immunity with sensitized Th1 lymphocytes plays a critical role in controlling the infection.[14] The interaction of antigen-presenting cells with antigen-specific T and B lymphocytes with subsequent production and release of the cytokines, interleukins 2 and 12 (IL2, IL12), interferon gamma (IFN-γ), tumour necrosis alpha (TNF-α) is an intricate process with many facets still unaccounted for.[15] In TB infection, the inflammatory process typically gives rise to a characteristic tubercle which consists of a focus of epitheloid cells containing a variable number of Langhans giant cells.

Caseation necrosis is due to the death and degeneration of these epitheloid cells. Immunology of cutaneous tuberculosis is poorly understood. It is thought that the clinical variants of skin TB form an immunological spectrum with lupus vulgaris at one pole with good immunity and scrofuloderma at the other pole with poor immunity. Warty tuberculosis shows intermediate changes indicating a balanced immune response between Th1 and Th2 cytokines.[16]

1.1.6 HIV-TB Co-infection.

In South Africa the concurrent HIV-TB infection rate is approximately 70 - 80%.[12,13] In patients with AIDS, the risk of disseminated TB is high with a significant mortality rate. The clinical and radiographic appearance of pulmonary TB in these patients may be atypical. Cavitation and a more typical radiographic picture may become apparent as part of immune reconstitution inflammatory syndrome (IRIS) which occurs when the patients start taking the highly active antiretroviral treatment (HAART).

T-cell depletion is thought to be the primary immunopathogenic event predisposing HIV positive patients to TB. The TB granuloma in advanced HIV disease is unable to contain the bacillus resulting in disseminated or extrapulmonary disease. Regarding therapy, there has been no controlled trials of sufficient power to detect differences in response to anti-TB treatment between HIV positive and HIV negative patients. Studies have suggested that standard regimens are as effective in HIV-positive as in HIV-negative patients hence the recommendation of a 6 or 9 months regimen for both groups.[12] However, higher drug reactions resistance due to interruption of therapy and higher re-infection rates occur in HIV positive patients.[13]

1.2 Clinical subtypes of cutaneous (skin) TB

There are two main categories, the true skin TB infections and tuberculids.

A. True skin TB infections

1.2.1 Scrofuloderma

Scrofuloderma results from contiguous extension of an underlying tuberculous focus secondary to local tissue breakdown. The underlying focus may be a tuberculous lymph gland, bone, joint or epididymis.[17-19] It occurs most often after cervical, submandibular, parotid glands infection and less often with axillary, inguinal and bone infection. The tuberculin test is usually positive. Skin lesions first present as firm subcutaneous nodules or as an asymptomatic induration of the skin.

As it enlarges it softens followed by liquefaction with subsequent perforation. Ulcers and sinuses develop and discharge watery, purulent or caseous material. Histopathology shows an ulcerated dermal abscess with an ill-defined histiocytic component. The margins of the sinuses contain tuberculoid granulomas and true tubercles. The lesions may contain few or lots of bacilli. Diagnosis is made by skin biopsy, tissue culture, fine needle aspiration and a smear with demonstration of acid fast bacilli. Scrofuloderma may heal spontaneously with typical cord-like or criss-crossed scars, but the course is generally protracted.

1.2.2 Lupus Vulgaris

This is a post-primary and chronic progressive form of tuberculosis. It may appear at the site of inoculation from an underlying focus as in scrofuloderma or BCG scars and via haematogenous or lymphatic spread. Skin TB lesions resembling those of lupus vulgaris have been reported in patients receiving intravesical BCG therapy.[20] Lupus vulgaris occurs in patients with moderately high immunity to tuberculosis with a positive tuberculin test. It typically presents as a single plaque with almost a gelatinous consistency, composed of grouped red-brown papules which on diascopic pressure reveal yellow or apple-jelly colour. The lesions of lupus vulgaris may mimick lichen simplex chronicus.[21]

The majority of cases are on the head and neck particularly around the nose. The prominent histopathological feature is the formation of typical tubercles with scanty central caseation surrounded by epitheloid cells and multinucleate giant cells. Old lesions which consists mainly of epitheloid cells may be impossible to distinguish from sarcoidal granulomas. It is paucibacillary and successful culture is difficult, reported to be positive in about 6% of cases.[22] Diagnosis can also be confirmed using polymerase chain reaction (PCR) test. Lupus vulgaris is a chronic condition and may lead to considerable impairment of function and disfigurement. The most serious complication of chronic lupus vulgaris is the development of squamous cell carcinoma.[23]

1.2.3 Primary Inoculation TB (Tuberculous chancre)

It results from inoculation of mycobacteria into the skin of a host not previously infected with tuberculosis. Inoculation may be through abrasions or minor injury and has been reported following needle stick injury, ear piercing and tattooing. Tuberculous chancre and the affected regional lymph node which develop 3 - 8 weeks after infection constitute the primary complex of the skin equivalent to a Ghon focus in the lung.[24] It mostly affects children but may occur in adolescents and young adults. Common sites include hands, face and lower extremities.

It presents initially as a small papule, scab or wound which develops into a painless granulating ulcer. The lesions become indurated with thick adherent crusts. It may present on the finger as painless paronychia. Acute non-specific inflammatory reaction may be seen on histology. Acid fast bacilli may be seen using the Ziehl Neelsen stain. The infiltrate may later become more granulomatous with caseation, a phase which coincides with disappearance of the bacilli. PPD may be initially negative and later positive. Diagnosis is verified by mycobacterial culture or PCR.[25]

1.2.4 Warty Tuberculosis (Tuberculosis Verrucosa Cutis)

It is caused by exogenous infection in a previously sensitized person and presents as an indolent indurated warty plaque, on areas exposed to trauma and to infected sputum.[26] Common sites include the hands, knees, ankles and

buttocks. Previously, pathologists were liable to acquire warty TB from patients or autopsy material hence the name “prosector’s wart”. It was reported to be the most common form of skin TB in Hong Kong in 1995.[27] Histology shows pseudoepitheliomatous hyperplasia of the epidermis, hyperkeratosis as well as suppurative and granulomatous inflammation in the upper and mid dermis. Acid fast bacilli can occasionally be seen. The lesions progresses slowly and persist for years. Spontaneous remission may occur and usually results in atrophic scars.

1.2.5 Orificial Tuberculosis (Tuberculosis Periorificialis)

This rare subtype of skin tuberculosis occurs in patients with pulmonary, intestinal or anogenital tuberculosis. The patients are usually severely ill with advanced visceral tuberculosis and impaired cell-mediated immunity. It is a form of autoinoculation tuberculosis with large numbers of mycobacteria shed and inoculated into the mucous membranes of orifices. The lesions occur most commonly in the mouth and less often in the perineum. Small red papules break down to form painful ulcers which shows no tendency to spontaneous healing. It has been reported in association with Kaposi’s sarcoma in an HIV negative patient.[28] Histopathological changes are variable and mycobacteria are usually present. Diagnosis can be confirmed with culture of *M. tuberculosis* or PCR.[29] Patients with this condition tend to have an unfavourable prognosis.

1.2.6 Disseminated Cutaneous (Miliary) Tuberculosis

It is an extremely rare skin eruption which occurs in association with fulminating miliary tuberculosis and is due to haematogenous dissemination of mycobacteria into the skin. It affects young children and immunosuppressed patients such as those with HIV/AIDS.[30-34] Cutaneous miliary tuberculosis in a patient with AIDS was first reported by Stack *et al.* in 1990.[34] The lesions are variable and consists of erythematous or reddish-brown macules, papules, pustules, vesicles, subcutaneous nodules or purpuric vasculitic lesions particularly on the trunk. The initial focus of infection may be meningeal or pulmonary. The tuberculin skin test is negative. Skin biopsies show diffuse suppurative inflammation with predominantly polymorphonuclear leukocytes and abundance of acid fast bacilli. If the patient develops immunity, lymphocytic cuffing of vessels and tubercles may occur. The prognosis is generally poor.

1.2.7 Metastatic Tuberculous Abscess (Tuberculous Gumma)

Tuberculous gumma is caused by haematogenous spread of mycobacteria from a primary focus resulting in a single or multiple ulcers usually on the legs. Lesions are seen in children and severely immunosuppressed patients.[35] Lesions may start as subcutaneous nodules and progress to form abscesses, and ulcers.[36] Tuberculous gumma affects mainly the extremities and less often the trunk. The patient may have progressive organ or miliary TB.[37] The tuberculin test is usually weakly positive. Histology shows massive necrosis and abscess formation with copious amounts of acid-fast mycobacterial bacilli.

B. Tuberculids

Tuberculids are due to haematogenous spread of antigenic components of *M. tuberculosis* in persons with a moderate or high degree of immunity against *M. tuberculosis*. The diagnosis of tuberculids is based on the morphology of the lesions, positive PPD and prompt response to anti-TB therapy.

1.2.8 Erythema Induratum of Bazin

It is characterized by recurrent tender subcutaneous nodules and ulcerative lesions which are often localized to the posterior part of the lower legs. Erythema induratum and nodular vasculitis are clinically and histologically similar but the latter does not usually ulcerate and is not associated with TB. The main differential diagnosis is erythema nodosum which is very rarely associated with TB, does not usually ulcerate and shows septal panniculitis on histology. In erythema induratum the tuberculin test is positive and active foci of tuberculosis may be identified. Mycobacterial DNA has been found in the skin specimen using PCR in up to 70 % of cases.[38,39] The pathogenesis is not clear but venous stasis, type III antigen-antibody mediated immune (Arthus) reaction and IFN-γ as part of the delayed hypersensitivity reaction may play a role. Histology shows a lobular or septo-lobular granulomatous panniculitis, with or without vasculitis and coagulative necrosis. Acid fast bacilli are not identified and culture for *M. tuberculosis* is negative.

1.2.9 Papulonecrotic tuberculid (PNT)

PNT is characterized by recurrent asymptomatic dusky red and necrotic papules affecting mainly the extensor aspects of the extremities. The lesions are symmetrically distributed on the elbows, knees, hands, buttocks and ears. The tuberculin test is positive often with a severe or necrotic reaction. It affects mainly young adults with a female to male ratio of around 3:1. The lesions typically heal with varioliform scarring.

Development of lupus vulgaris from lesions of PNT has been described in a landmark paper from South Africa titled " From Arthus reaction to lupus vulgaris".[40] The histology reveals a typical ovoid or wedge shaped area of coagulative dermal necrosis surrounded by a palisaded collection of histiocytes. Well formed tubercles are not seen. Granulomatous and lymphocytic vasculitis as well as thrombotic occlusion of vessels may be seen. Acid fast bacilli are not identified in the skin lesions except in the chronic cases that are progressing to lupus vulgaris. *M. tuberculosis* DNA has been demonstrated in 50 - 70% of cases.[41]

1.2.10 Lichen Scrofulosorum

This condition was first described by Hebra in 1868. It is very rare and typically affects mainly children and adolescents. It tends to occur in association with tuberculosis in the lymph nodes and bones. Lichen scrofulosorum has been reported in a patient with AIDS.[42] The lesions consists of closely grouped small follicular or parafollicular papules which are skin coloured or reddish brown and

are located mainly on the abdomen, chest, back and proximal limbs.[43] The tuberculin test is positive. Histology consists of superficial tuberculoid granulomas comprised predominantly of epitheloid cells around hair follicles and sweat ducts. Mycobacteria are not seen in the tissue sections and cannot be cultured.

1.2.11 Nodular granulomatous phlebitis (Phlebitic tuberculid)

It has recently been described as a fourth type of tuberculid by Hara *et al.* in Japan in 1997. It is characterized by subcutaneous nodules along the course of a leg vein. A similar case was reported in Pretoria in 2006 by Motswaledi and Schulz.[44] Histology shows epitheloid granulomas with multinucleated Langhans type giant cells observed within the walls of cutaneous veins. *M. tuberculosis* has been detected using the polymerase chain reaction method.

1.2.12 Nodular tuberculid

It was first described in South Africa by Jordaan *et al*. in 2000. It has been proposed by the authors as the fifth type of tuberculid. Only five cases have so far been reported in the literature, the first four cases by Jordaan *et al.* in the original paper and the fifth by Friedman *et al.* in an HIV positive patient in 2005.[45] The lesions consist of red and bluish nodules without ulceration that occur mostly on the lower limbs. The Mantoux test is strongly positive. Associated organ TB may be present. Histology shows granulomatous inflammation with or without vasculitis as well as necrosis at the junction of the dermis (hypodermis) and subcutaneous fat.

1.3 Diagnosis and Treatment

The diagnosis of cutaneous TB is based on clinical and histopathological features along with supportive diagnostic tests and response to anti-TB therapy. Culture still remains the single most important test for definitive diagnosis but it takes up to 6 weeks to obtain results.

1.3.1 Tuberculin test

It is designed to detect a cell mediated immune response to *M. tuberculosis*. It is mediated by sensitized T-lymphocytes following an intradermal injection of purified protein derivative (PPD). The test becomes positive between 2 and 10 weeks following infection and is usually lifelong. The Mantoux test is the standard and offers the highest degree of consistency. The test is read at 48 - 72 hours and the diameter of the area of induration not the area of erythema is recorded. Induration of 15mm is considered positive in immunocompetent patients, 5mm in immunosuppressed or HIV positive patients and skin induration of 0 - 4 mm is negative.

Induration of 10mm is suggestive of present or past tuberculous infection in UK and USA in patients who never received BCG. Negative reactions occur in anergic patients who are usually ill for example those with severe TB, malnutrition, viral infections, sarcoidosis, malignancy or if there is no TB infection. BCG immunization leads to a positive tuberculin result in immunized children but this reaction does not usually persist beyond 10 years.

The Heaf test is performed with a spring-loaded instrument which causes six tiny punctures on the skin. The reaction is measured in grades from I - IV, with grades III - IV suggesting past or present TB infection.

1.3.2 Polymerase chain reaction (PCR)

In *vivo* amplification of specific DNA sequences using the PCR has become a valuable tool in the rapid detection of slow growing organisms like *M. tuberculosis*. Using this technique mycobacterial DNA has been demonstrated in different subtypes of cutaneous tuberculosis. It can be used in a variety of pathological specimens including fresh or snap frozen samples as well as formalin-fixed tissue sections. The generic sensitivity of this test is good with a high specificity. Degradation of DNA in archival material, difficulties in extracting mycobacterial DNA from the lipid rich cell wall and diminished amplification as a result of formalin fixation may decrease its sensitivity and lead to false negative results.[46] PCR is also useful in distinguishing multibacillary TB from infections with atypical mycobacteria and in situations where cultures are not performed. It has been used successfully to identify *M. tuberculosis* in most subtypes of skin TB including lupus vulgaris, scrofuloderma, orificial TB, papulonecrotic tuberculid, erythema induratum and nodular granulomatous phlebitis.[41,46,47]

1.3.3 New TB immunological assays

Targeted tuberculin testing for latent tuberculosis infection is a key component of tuberculosis control. Poor specificity of the tuberculin skin test in populations vaccinated with BCG and its low sensitivity in immunosuppressed persons has prompted research into new immunological assays.

Two blood tests (T-SPOT.TB and QuantiFERON -TB Gold) which are based on detection of interferon gamma (IFN-γ) released by T-cells in response to *M. tuberculosis* have recently been described.[48] These tests have operational advantages and are both significantly more specific and sensitive than the skin test. The tests are also reported to help reduce the false -positive and false-negative results inherent in the skin test. The major advantage of these assays is that they are not affected by the BCG vaccination because they utilise two proteins which are encoded by a unique genomic segment which is absent from all strains of *M. bovis* BCG and non-tuberculous mycobacteria. One of the problems with these assays is that they cannot be used to distinguish between latent and active TB. Quantiferon - TB Gold uses whole blood whilst T.SPOT.TB utilises peripheral blood mononuclear cells. The precise role and the use of these tests in the diagnosis of cutaneous TB has not been elucidated. These two tests are not available in the government (state) hospitals as yet and were not used in any patient in our study.

1.3.4 Treatment of Tuberculosis

Skin TB treatment was previously given five times a week in both intensive and continuation phases as in pulmonary tuberculosis (table 2a).[49] The National TB control programme now recommends seven times weekly regimens. All patients on three times weekly regimens were on clinic DOT (direct observed therapy). Recommended dosages: Rifampicin: 10mg/kg, pyrazinamide 20 - 25mg/kg, isoniazid : 5 -10mg/kg and ethambutol 15mg/kg (table 2b). Regimen 1: for new smear positive patients, new smear negative patients and extrapulmonary tuberculosis. Treatment is with Rifafour (rifampicin, isoniazid, ethambutol and pyrazinamide) and pyridoxine for two months then followed by Rifinah (rifampicin and isoniazid) for four months during the continuation phase.

Regimen 2 (retreatment): for previously treated patients after cure, after completion, interruption and failure. Regimen 3: Is given to children with tuberculosis up to the age of 8 years. This regimen is similar to regimen 1 without pyrazinamide. Single drug chemoprophylaxis with isoniazid is now being recommended in South Africa. The emergence of multidrug resistance is complicating TB treatment. Multidrug resistant (MDR) tuberculosis defined as *in vitro* resistance to both isoniazid and rifampicin with or without resistance to other-anti-TB drugs. The problem of MDR has been compounded by the emergence of extensively drug resistant (XDR) TB which is defined as MDR-TB in association with *in vitro* resistance to any of the fluoroquinolones plus one or more of the injectable second-line anti-TB drugs i.e kanamycin, amikacin or

capreomycin. In the study from Tugela Ferry in Kwa Zulu Natal[50] the mortality rate in patients with XDR-TB exceeded 90% but was found to be only 35% in the study from the United States.[51] It has been difficult to accurately determine clinical outcomes in patients with XDR-TB in some of the studies in which the majority of patients were co-infected with HIV and were immunosuppressed.

1.4 Non-tuberculous mycobacteria (NTM)

Non-tuberculous (previously called atypical) mycobacteria were first isolated by Pinner in 1935. These are facultative pathogens and saprophytes and do not cause tuberculosis. They produce pulmonary and extrapulmonary lesions and less commonly affect the skin. Non-tuberculous mycobacteria may be pathogenic in the setting of HIV/AIDS. They exist in soil, water and animals. Most human disease is acquired from the environment. Common examples include *M. ulcerans*, *M. kansasii, M. scrofuloceum* and *M. avium intracellulare*. PCR identification, culture in a special medium or using mycolic acid high perfomanic liquid chromatography (HPLL) are used to confirm the diagnosis. Clinically the skin lesions present as erosions, papules, nodules and plaques some in a sporotrichoid pattern.[52] Histopathology may reveal a mixed inflammatory infiltrate, epitheloid cell tubercles with or without acid fast bacilli. Treatment include surgical excision where feasible, antibiotics e.g tetracyclines, clarithromycin, quinolones, sulfamethoxazole plus trimethoprim as well as the anti-TB drugs i.e rifampicin, isoniazid and ethambutol.

Table 2 (a): Anti -TB Treatment (SA Department of Health 2003)

Pretreatment body weight	Two months initial phase (5 x week)	Four months continuation phase			
	RHZE (150,75.400,275)	RH(150,75) 5 x week	RH(300,150) 5x week	RH(150,150) 3 x week	RH(300,150) 3 x week
30-37 kg	2 tabs	2 tabs		2 tabs	
38-54 kg	3 tabs	3 tabs		3 tabs	
55-70 kg	4 tabs		2 tabs		3 tabs
71 kg and over	5 tabs		2 tabs		3 tabs

Table 2 b

Recommended dose range in mg/kg		
	5 x week	3 x week
Isoniazid (H)	5 mg/kg	10 mg/kg
Rifampicin (R)	10 mg/kg	10 mg/kg
Pyrazinamide (Z)	25 mg/kg	35 mg/kg
Ethambutol (E)	15 mg/kg	30 mg/kg
Streptomycin	15 mg/kg	15 mg/kg

CHAPTER 2

PRESENT STUDY

2.1 Background

The estimated incidence of tuberculosis in South Africa is 940/100 000. Cutaneous tuberculosis accounts for about 2 - 3% of all cases of tuberculosis. In sub-Saharan Africa approximately 70 - 80% of patients with TB are co-infected with HIV (human immunodeficiency virus). South Africa has a population of approximately 48 million people comprising mainly of four racial groups: blacks, whites, Indians and Coloureds (mixed race). Blacks are in the majority accounting for more than 70% of the population. Johannesburg is in the Gauteng province and has a population of around 7.1 million.

About 5.7 million people are infected with HIV in South Africa with the prevalence estimated at 11.4%.[11] Amongst blacks the prevalence of HIV is 13.4%. The HIV prevalence differs between males and females with 9.5% amongst males and 12.8% amongst females. Gauteng has the second highest HIV prevalence rate of 14.8%. There are about 1500 new HIV infections in South Africa everyday. The recent increase of skin diseases amongst our patients has been ascribed to the HIV/AIDS epidemic. [53,54] Skin disease affects more than 90% of patients with HIV at some stage during the course of their illness. Patients with typical and atypical skin lesions of TB are increasingly being seen in our dermatology clinics.

2.2 Aims

The objectives of this study were to determine the clinical spectrum of cutaneous tuberculosis in the Johannesburg area and to assess the correlation of HIV infection and CD4 count on the clinical and histopathological presentation.

2.3 Patients and Methods

2.3.1 Study Design: This was a prospective hospital-based clinical and immuno-pathological study. Ethics approval was granted by the Ethics committee of the University of the Witwatersrand in October 2004.

2.3.2: Patients: A total of 74 (seventy four) patients diagnosed with cutaneous tuberculosis that were seen during the period October 2004 to March 2008 at the three academic hospitals Johannesburg, Chris Hani Baragwanath and Helen Joseph were enrolled for the study. Patients were also referred from Sizwe TB hospital as well as Charles Hurwitz Santa TB centre which is situated next to the Chris Hani Baragwanath hospital. Consent and assent for minors were obtained in all cases. Patients from whom consent could not be obtained those less than 10 years of age were excluded from the study. A questionaire was used to record the demographic data as well as history of use of HAART and anti-TB therapy. Patients were provided with information leaflets on skin TB.

The diagnosis was based on clinical and histopathological findings supported by other diagnostic procedures which included tuberculin tests, X-rays, fine needle aspirates (FNA), culture of skin tissue and sputum and response to anti-TB

treatment. Patients were initially seen after I month of commencement of therapy and then 3 monthly until the completion of treatment. Thereafter the patients were seen at 3 and then 6 months post-treatment to assess response to treatment and for any relapse.

2.3.3: Multiple skin biopsies were done under local anaesthetic using a punch or an incision. One to two biopy specimens were fixed in 10% buffered formalin, processed and paraffin embedded for haematoxylin and eosin as well as Ziehl-Neelsen staining. The other biopsy specimens were submitted for culture in cases of true cutaneous TB infections only and not for tuberculids.

The histopathologic features were analyzed and recorded by an independent histopathologist in the department of Pathology and were subsequently reviewed in our department with the help of a dermatopathologist. The histopathologic features that were recorded included the presence of granulomatous or non-granulomatous infiltrate, acid fast bacilli with Ziehl-Neelsen stain, caseous necrosis and the presence or absence of vasculitis.

Culture specimens were submitted to the TB laboratory in a sterile specimen bottle. In the laboratory the skin specimens were crushed using sterile sand, decontaminated and then placed into a mycobacterial growth indicator tube (MGIT). The specimens were thereafter incubated in an MGIT machine for up to six weeks (42 days). Positive fluorescence in the tube was picked up by the MGIT machine if there was growth. Sensitivity tests were subsequently done for *M. tuberculosis*.

2.3.4: Blood tests: HIV testing was done with the patients consent followed by CD4 counts in the HIV positive group. The patients were stratified into three groups: HIV negative patients, HIV positive patients and the third group with an unknown HIV status. The other blood tests that were done included full blood count, urea and creatinine and erythrocyte sedimentation rate (ESR).

2.3.5 Mantoux test: 0.1 ml of 1:10 000 dilution of intradermal injection of purified protein derivative was injected 10cm below the antecubital fossa on the volar aspect of the left forearm using a 27-gauge insulin syringe. The reaction was read at 72 hours and the diameter of the induration and not the erythema was recorded. A reaction of 15mm or more was considered positive in immunocompetent patients and 5mm induration was considered positive in HIV positive or immunosuppressed patients.

2.3.6 X-rays: All patients had chest x-rays (antero-posterior and lateral) done prior to commencement of anti-TB therapy. X-rays were reported by the radiologist and reviewed by pulmonologists if necessary.

2.3.7 FNAC (fine needle aspirate cytology): FNA was done in 3 patients with scrofuloderma in which skin biopsies could not be done immediately. A sterile needle was used to aspirate the lesions and the aspirate was placed on a glass slide and stained with Ziehl Neelsen to detect acid fast bacilli. The aspirate was also submitted for TB culture.

2.3.8 Polymerase chain reaction (PCR) test was not done routinely in our study patients because of cost (± R500-00 per specimen) and the observed poor yield from paraffin-embedded tissues that was reported (not published) previously in our department. PCR test was done in tissue specimens from 9 patients in which culture was negative or was not done.

2.3.9 Photographs of the skin lesions were taken with the patient's consent. The distribution and morphology of the skin lesions were recorded. Anonymity of the photographs was guaranteed.

2.3.10 Notification: All patients with cutaneous TB were notified with the department of health through the Infectious disease TB units in the hospitals and were subsequently referred to their nearest TB clinics for further treatment.

2.3.11 Data collection: Clinical records were reviewed and the data was recorded. A questionnaire form was used to record demographic data. Data included age, gender, occupation, past and family history of TB and drug history of anti-TB therapy and HAART. Results of PPD, X-rays, sputum for acid fast bacilli and culture, tissue histopathology, FNA, PCR, ESR, HIV serology, CD4 count, full blood count were recorded. Other relevant supportive investigations which were done e.g lumbar punctures, abdominal sonars and X-rays of the spine, were also recorded. These data was recorded on the Epi-info data software spread sheet then transferred onto STATA software for statistical analysis.

2.4 Statistical Analysis

Descriptive statistics of categorical variables were done using frequency distribution tables. Numerical variables were described using mean and standard deviations. Associations between pairs of categorical variables was determined using Pearson's Chi-Square (where necessary Fisher's exact test). Odds ratios together with 95% confidence intervals, for selected associated categorical variables were computed. The student t-test (one tailed and two tailed) was used to test for differences between pairs of a numerical variables (such as ages of males vs females). Statistical significance was ascertained at the 5% level, thus a p-value of less than 0.05 was significant.

CHAPTER 3

RESULTS

3.1 Descriptive

A total of 74 (seventy four) patients diagnosed with cutaneous tuberculosis were enrolled. The group comprised of 93.2% (n = 69) black patients, 5.4% (n = 4) coloured patients and 1.4% (n = 1) white patient. No Indian patients were seen. Their ages ranged from 10 years to 66 years, with a mean age of 32.8 (SD = 12.1) and median of 36.2 years. The entire clinical spectrum was seen except nodular and phlebitic tuberculids as well as skin lesions related to BCG vaccination**.** The male to female ratio was 1:3 comprising of 25. 3% (n = 18) males and 74.7% (n = 56) females (diagram 1). Fourty five point nine percent (n = 34) of patients had true skin TB infections only, 48.7% (n = 36) with tuberculids only and 5.4% (n = 4) had two (overlap) TB skin lesions. The fourth patient with dual (overlap) pathology had two tuberculids and that brought the total number of patients with tuberculids only, to 50.0% (n = 37).

Amongst the 74 patients, a total of 78 TB skin lesions were seen due to the overlapping (dual) TB skin lesions in the 4 patients (table 3*).* The prevalence of HIV amongst the study patients was 61.4%. A total of 70 (94.6%) of the 74 patients were tested for HIV. Sixty one point four percent (n = 43/70) of the tested patients were HIV positive, 36.5% (n = 27/70) were HIV negative, 5.4% (n = 4/74) had an unknown HIV status. (table 4-6). Sixty seven point six percent

(67.6%) of patients with true infections (n = 23/ 34) were HIV positive compared to 45.9% with tuberculids (n = 17/37). This translated to true infections accounting for 53.5% (n = 23/43) and tuberculids 39.53% (n = 17/43) of all HIV positive patients respectively (table 4,5). Patients with overlapping or dual TB skin lesions were all HIV positive (table 6). The mean CD4 count of all HIV positive patients (n = 43) with skin TB was 168.61 (SD = 114.1) cells/µl. A total of 39.2% (n = 29) patients had associated pulmonary tuberculosis**.** In this group of patients with pulmonary tuberculosis, 58.6% (n = 17) had true cutaneous TB infections, 34.5% (n = 10) had tuberculids and 6.8% (n = 2) had overlap TB skin lesions.

A total of 22 patients (29.7% of all cases) were diagnosed with **scrofuloderma**. It was the second most common subtype of skin tuberculosis and the most common true cutaneous TB infection accounting for 29.7% (n = 22) of all cases. The male to female ratio 1: 2 comprising of 7 males and 15 females with a mean age of 29.1 (SD = 11.9) years. Nineteen patients were black and 3 were coloured. Seventy seven point three percent (77.3%, n = 17) patients were HIV positive, 18.2% (n = 4) HIV negative and 1 had an unknown HIV status. The seventeen HIV positive patients comprised of 15 patients with scrofuloderma only and 2 with dual (overlap) skin lesions. Their CD4 counts ranged from 38 to 270 cells/µl with a mean of 145.8 (SD = 74.3) cells/ µl. A total of 12 patients (70.6%) had CD4 count of less than 200 cells/µl and 5 patients (29.4%) had CD4 counts of more than 200 cells/µl. The common sites involved were the cervical (fig 1) and submandibular regions. Other sites included the groin, sternum and axilla.

Pulmonary tuberculosis was present in 41.0% (n = 9/22) of patients. Nineteen patients had skin biopsies done and in 3 patients the diagnosis was made using fine needle aspiration cytology (FNAC). A granulomatous histology with multinucleated giant cells was found in 73.7% (n = 14/19) of the biopsy specimens. Non-granulomatous histology was seen in 21.1% (n = 4) cases. Acid fast bacilli were seen in 31.8% (n = 7) of the 22 specimens and *M. tuberculosis* was cultured in 45.5% (n = 10) of the total specimens. Seven of the 10 patients with positive tissue cultures for *M. tuberculosis* were HIV positive.

A total of 6 patients had **lupus vulgaris.** 5 patients had lupus vulgaris only and the sixth had lupus vulgaris and PNT. Their ages ranged from 10 years to 66 years with a mean age was 29.1 (SD = 20.2) years. Two patients were HIV positive with CD4 counts of 95 and 301cells/µl respectively with a mean of 198 cell/µl. PPD was positive in all 6 cases. Pulmonary tuberculosis was present in 33.3% (n = 2) of patients. Skin lesions consisted mainly of nodules (fig 2) and plaques involving the face in 5 patients and the leg in 1 patient. A tuberculoid histology with epitheloid cells, histiocytes and Langhans giant cells with variable caseation necrosis was seen. The histology was less granulomatous in the two HIV positive patients. Acid fast bacilli were demonstrated in the skin biopsy of an HIV patient with lupus vulgaris and PNT. One patient had TB spine and systemic lupus erythematosus. Culture for *M. tuberculosis* was positive in 2 patients, one HIV positive patient with acid fast bacilli on histology and an HIV negative patient with no acid fast bacilli seen on skin biopsy specimen.

Four cases of **miliary tuberculosis** were seen and accounted for 5.4% of all cases. Their ages ranged from 22 to 60 yrs, with a mean of 44.5 years (SD = 10.3). All patients were terminally ill, HIV positive with CD4 counts ranging from 2 to 25 cells/µl and a mean of 9.5 (SD = 10.7) cells/µl. These patients had pulmonary and fulminant disseminated tuberculosis. Two patients had confirmed bone marrow involvement. Skin lesions consisted of crusted erythematous follicular papules, purpuric macules and targetoid lesions (fig 3). There was negative reaction to PPD in all 4 cases. The histology of the skin biopsies showed non-specific inflammation with abundance of acid fast bacilli. *M. tuberculosis* was confirmed on culture (both on sputum and skin tissue).

Two cases of **tuberculous ulcers** were seen in patients aged 26 and 28 years. Lesions were both on the lower legs. Both patients were HIV positive with CD4 counts of 24 and 272 cells/µl and a mean of 148.5 cells/µl (SD = 188.8). PPD was reactive and pulmonary TB was present in one patient. Histology was non-specific, acid fast bacilli were positive in both cases and culture confirmed *M. tuberculosis* in one patient.

Orificial tuberculosis was seen in an HIV negative 30 year old female. The lesions were in the perianal region and consisted of shallow ulcers with a necrotic base (fig 4). Patient had sputum smear positive pulmonary and hepatic TB with a positive culture for *M.tuberculosis*. PPD was weakly positive and histology showed ill-defined granulomas and scanty acid fast bacilli.

One case of **warty tuberculosis** was seen in an HIV positive patient with pulmonary tuberculosis. Her CD4 count was 280.0 cells/µl. The patient presented with a hyperkeratotic plaque on the right hand. Histology showed pseudo-epitheliomatous hyperplasia with a granulomatous infiltrate. Acid fast bacilli were seen on histology and *M. tuberculosis* was grown on culture.

A case of **primary inoculation tuberculosis** was seen on the forefinger of a laboratory health worker three weeks after needle stick injury whilst aspirating a tuberculous lymph node from a patient. The patient was initially treated with antibiotics. *M. tuberculosis* was subsequently cultured from the FNA aspirate from that lymph node. PPD reaction on the laboratory worker was positive. Histology showed a granulomatous infiltrate with central caseation necrosis and Langhans type giant cells. A solitary acid fast bacillus was seen on the skin biopsy specimen and the response to anti TB therapy was remarkable.

Erythema induratum was the most common presentation of skin TB and accounted for 36.5% (n = 27) of all cases. Twenty five patients presented with erythema induratum only and 2 with dual skin lesions of erythema induratum with PNT and erythema induratum with scrofuloderma. Ninety six point three percent (96.3%, n = 26) were females and 3.7% (n = 1) male. Pulmonary tuberculosis was present in 25.9% (n = 7) of the patients with erythema induratum. Their ages ranged from 24 years to 60 years with a mean age 37. 5 (SD =10.1) years. Of the total of 25 patients with erythema induratum only, 44.0% (n =11) of patients were HIV positive, 48.0% (n = 12) were HIV negative, and 8.0% (n = 2)

of patients had an unknown HIV status. The CD4 counts of these 11 HIV positive patients ranged from 150 to 450 cells/µl with a mean of 234.5 (SD = 116.6) cells/µl. Fourty five percent (n = 5) of patients had CD4 counts of less than 200 cells/µl and 55% (n=6) had CD4 counts of more than 200 cells/µl. The lesions were predominantly on the calves and shins (fig 5). Ulceration of the skin lesions was present in 44.4% (n = 12) of patients. Histopathology showed predominantly septo-lobular granulomatous panniculitis in 66.7% (n = 18) and lobular panniculitis in 33.3% (n = 9) of patients (fig 5).

The infiltrate associated with focal necrosis and vasculitis was confined mainly to the subcutis. In the HIV positive patients with low CD4 counts of less than100 cells/µl, the granulomas were poorly formed. Acid-fast bacilli were not seen in any of the skin biopsy specimens. Tissue specimens were not submitted for PCR and culture of *M. tuberculosis.*

Thirteen patients were diagnosed with **papulonecrotic tuberculid (PNT)**. It was the third commonest subtype of skin TB accounting for 17.6% (n = 13) of all cases. There were 8 females and 5 males ranging in age from 10 to 38 years with a mean of 25.5 (SD = 8.9). Ten patients had PNT only and 3 had dual pathology. A total of 23.1% (n = 3) of the 13 patients had pulmonary tuberculosis. Of the 10 patients with PNT only, 50.0% (n = 5) patients were HIV positive, 40.0% (n = 4) were HIV negative and 1 patient had an unknown HIV status. The CD4 count of the 5 HIV positive patients with PNT ranged from 140 to 420 cells/µl with a mean of 240.8 (SD = 113.1) cells/µl. Lesions were located mainly

on the extensors surfaces of extremities, ears, buttocks and healed with varioliform scars. HIV positive patients displayed extensive and atypical follicular necrotic skin lesions. A rare linear subtype was seen in an HIV positive patient (fig 6). Dactylitis of the fingers in association with lesions of PNT was seen in a teenager (fig 7). Reaction to PPD was positive in all cases.

The histology of the biopsy specimens showed epidermal necrosis with granulomas in the dermis. The typical wedge shaped area of necrosis was seen in only 38. 5% (n = 5) of patients. Folliculitis-like histology with necrosis and ill- formed granulomas was seen in 23.1% (n = 3), all HIV positive patients. Acid fast bacilli were seen in only one biopsy specimen in a patient with both PNT and lupus vulgaris (dual pathology)**.**

Lichen scrofulosorum occurred in an HIV negative 25 year old patient, initially misdiagnosed as lichen nitidus. Lesions consisted of skin coloured and lichenoid asymptomatic papules which were confined to the trunk and upper extremities. Histology showed superficial granulomas with multinucleated giant cells but no acid fast bacilli were seen. Her PPD was positive and the lesions responded promptly to antituberculous therapy.

Four patients had **dual pathology**. They were all HIV positive with a mean CD4 count of 210.5 cells/µl (table 6). Two cases had erythema induratum, one with scrofuloderma and the other with PNT. The other two patients had PNT with lupus vulgaris and scrofuloderma respectively. PNT was the most common overlap skin lesion, seen in 3 of the 4 cases (table 6).

Polymerase chain reaction was not done routinely in all the patients. Paraffin-embedded tissue specimens from 9/74 patients, 8 with true TB infections and 1 with PNT and lupus vulgaris (dual pathology) were subjected to PCR. Four tissue specimen (n = 4/9, 44.4%) had a positive PCR reaction, one with lupus vulgaris only, the second with dual pathology (PNT and lupus vulgaris), the third with warty TB and the fourth with scrofuloderma. Cases of orificial and primary inoculation TB were found to have a negative PCR but yielded positive growth of *M. tuberculosis* on culture. The low yield was attributed to poor tissue sampling or diminished amplification of mycobacterial DNA.

Three cases had confirmed multidrug resistance (MDR) to both rifampicin and isoniazid. These included two cases of miliary TB and one with scrofuloderma. A total of 6 patients died, four patients with miliary TB died within a month, and two patients with scrofuloderma during the 4 month treatment.

Patients were seen up to 6 months after therapy to assess for relapse. Eight patients were lost to follow-up post-treatment. These 8 patients had received anti- TB treatment from their local clinics. A total of 60 who completed their treatment were seen, each patient at least twice in 6 months during the post-treatment period. The lesions had healed well in all patients with no evidence of relapse. Patients with tuberculids responded well to a 6 months regimen therapy and those with true skin infections to a 9 months course. One patient with nodular lupus vulgaris received a 12 months anti-TB treatment after failure of resolution of the skin lesions at 9 months.

Table 3: Total subtypes of cutaneous (skin) TB lesions and frequency of occurence.

A total of 74 patients: 70 patients had one skin TB subtype only, 4 had dual pathology. A total of 78 (total skin TB lesions) seen is higher than actual number of patients because of the overlap of lesions in 4 patients.

Subtypes	One subtype only	Erythema Induratum	Scrofuloderma	PNT	Lupus Vulgaris	Total no skin TB lesions
Erythema Induratum	25	-	1	1	-	27
Scrofuloderma	20	1	-	1	-	22
PNT (Papulonecrotic tuberculid)	10	1	1	-	1	13
Lupus Vulgaris	5	-	-	1	-	6
Miliary TB	4	-	-	-	-	4
TB Abscess	2	-	-	-	-	2
TB Orificialis	1	-	-	-	-	1
Warty TB	1	-	-	-	-	1
TB Chancre	1	-	-	-	-	1
L.Scrofulosorum	1	-	-	-	-	1
Total	**70**	**2**	**2**	**3**	**1**	**78**

Table 4: True skin TB infections and HIV status

Subtypes	Total number of patients N = 74	HIV Negative N = 27	HIV Positive N = 43	Unknown N = 4	P - value
Scrofuloderma	20	4	15	1	0.005
Lupus Vulgaris	5	4	1	-	0.028
Miliary TB	4	-	4	-	0.002
TB Abscess	2	-	2	-	-
TB Orificialis	1	1	-	-	-
Warty TB	1	-	1	-	-
TB Chancre	1	1	-	-	-
True Infections	**34**	**10**	**23**	**1**	**P = 0.024**

Table 5: Tuberculids and HIV status

Subtypes	Patients	HIV Negative	HIV Positive	Unknown	P - Value
Erythema Induratum	25	12	11	2	P = 0.84
PNT	10	4	5	1	P = 0.74
Erthema Induratum + PNT (Both tuberculids)	[1]	-	1	-	-
L.Scrofulosorum	1	1	-		-
Total	**37**	**17**	**17**	**3**	**P = 0.71**

Total number of patients	74
True infections only	34
Tuberculids only (including 1 case of 2 overlaping tuberculids)	37
Overlap cases : 3 cases (tuberculids + true infections) and 1 case (two tuberculids)	4
Total number of HIV negative patients:	27
Total number of HIV positive patients:	43
Unknown HIV Status	4

Table 6: Overlapping skin TB lesions, HIV status and CD4 counts

Overlaps	Patients	HIV Negative	HIV Positive	CD4 counts cells/µl
Scrofuloderma and Erythema Induratum	1	-	1	101
Scrofuloderma and PNT	1	-	1	170
Lupus Vulgaris and PNT	1	-	1	301
Erythema Induratum and PNT (both tuberculids)	1 Also counted under tuberculids	-	1 Also counted under tuberculids	270
Total	**4**	**-**	**4**	Mean CD4 **210.5**



Figure 1(a): Scrofuloderma

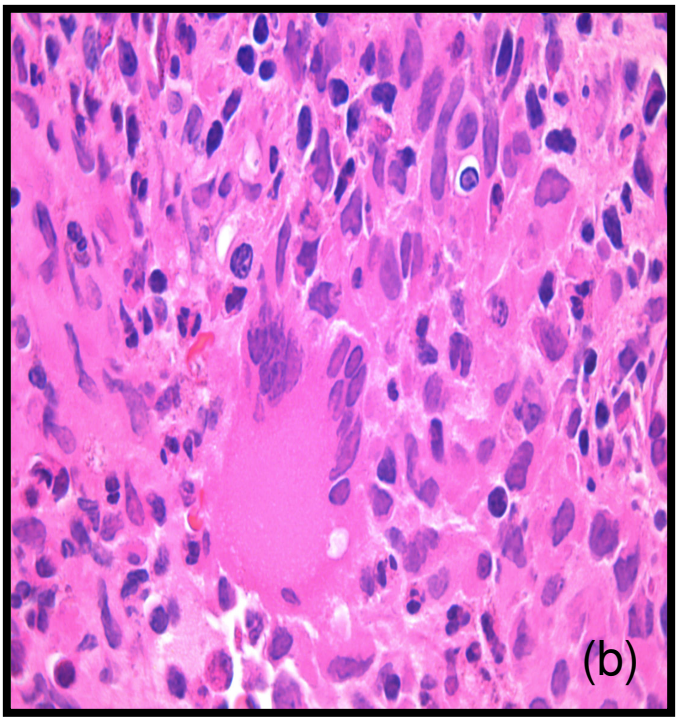

Figure 1(b): Granulomatous infiltrate with multinucleated giant cells

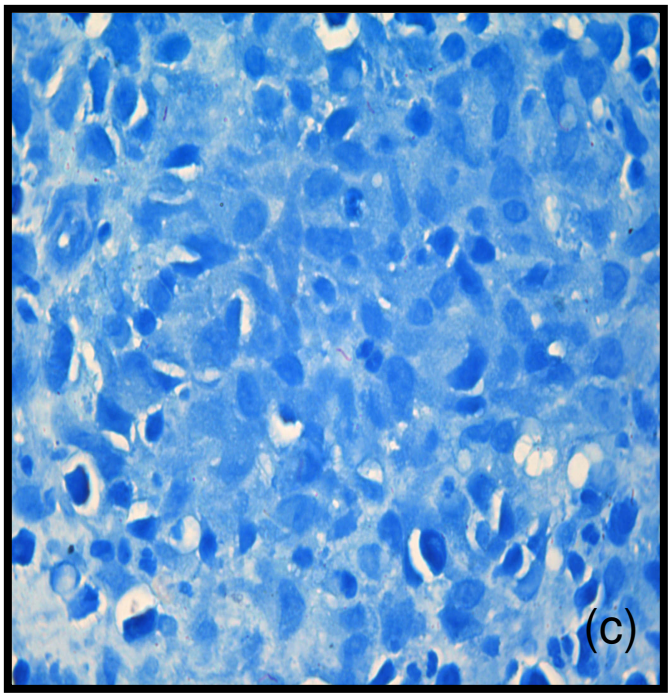

Figure 1(c): Positive acid fast bacilli

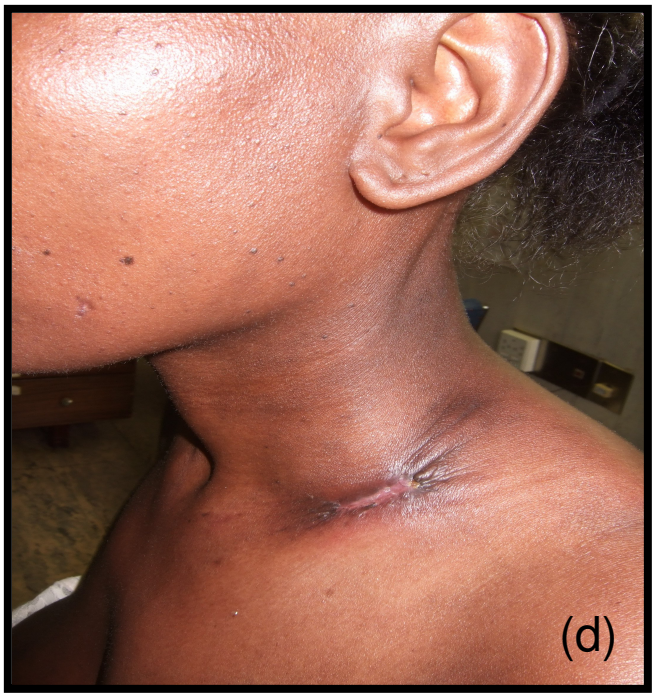

Figure 1(d): Resolving lesion after 2nd month of treatment



Figure 2(a): Nodular lupus vulgaris

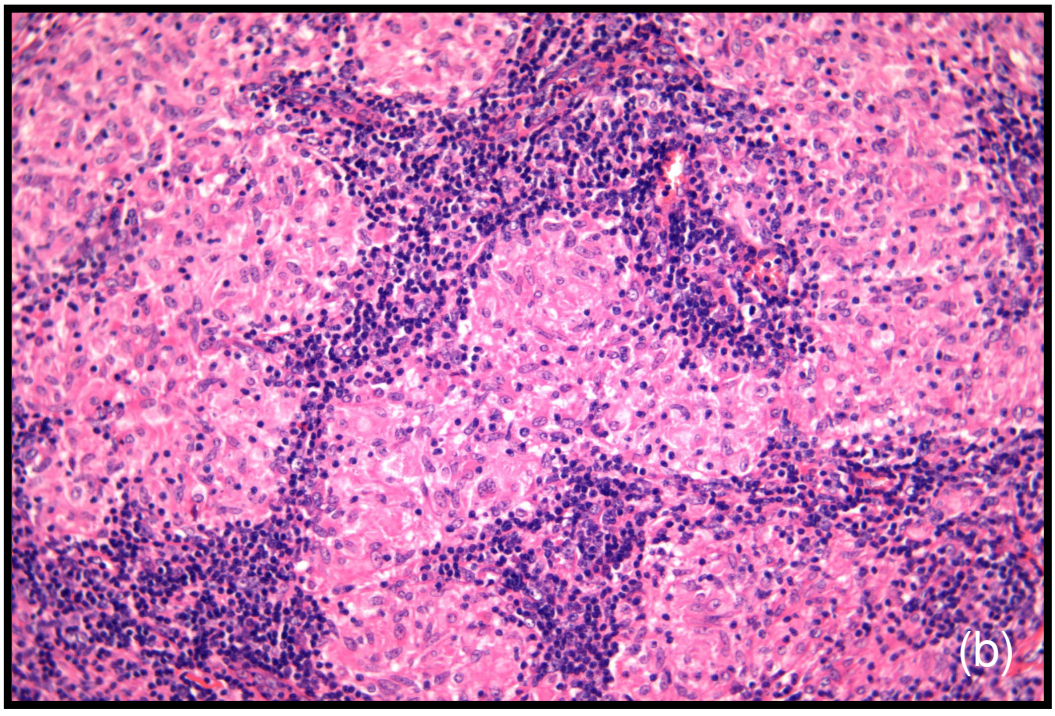

Figure 2(b): Well formed tuberculoid granulomas

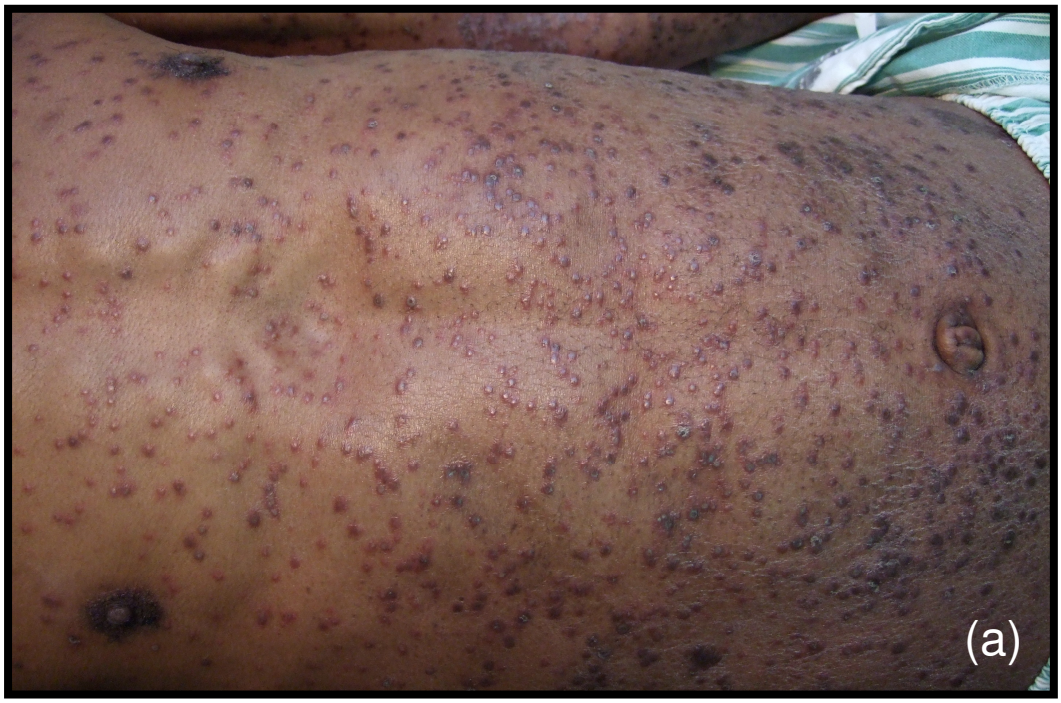

Figure 3(a): Disseminated cutaneous (miliary) TB

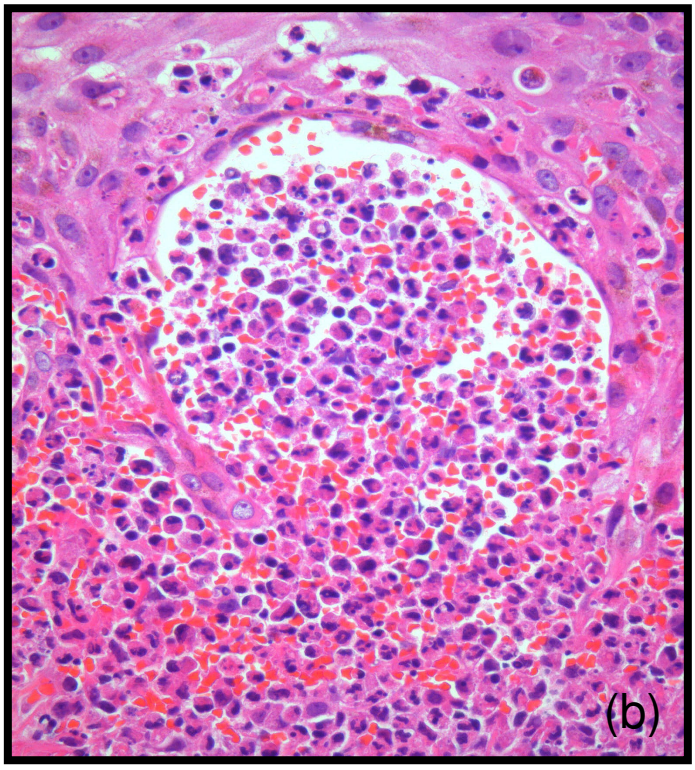

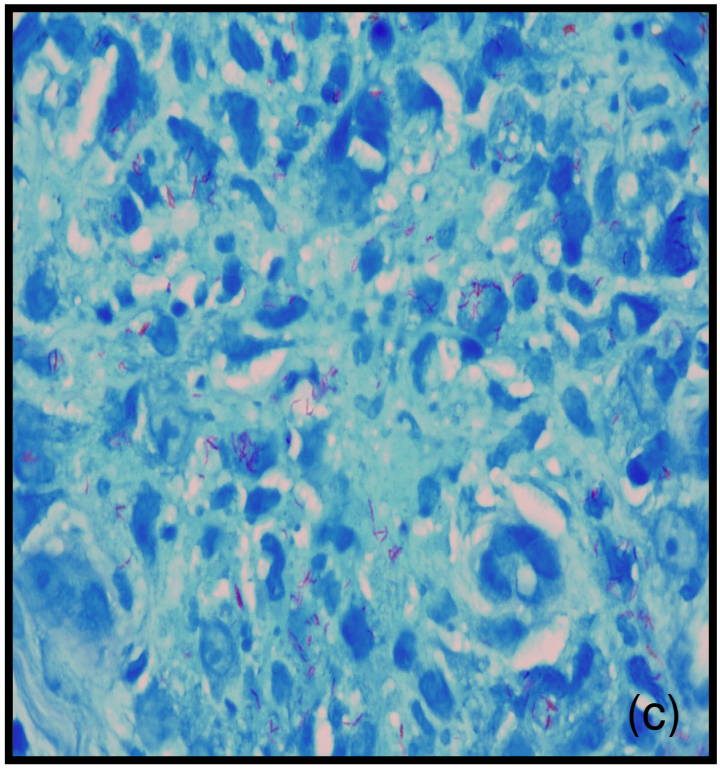

Figure 3(b): Histology of miliary TB showing a neutrophillic infiltrate (pustule)

Figure 3(c): Ziehl Nielsen staining showing abundance of acid fast bacilli

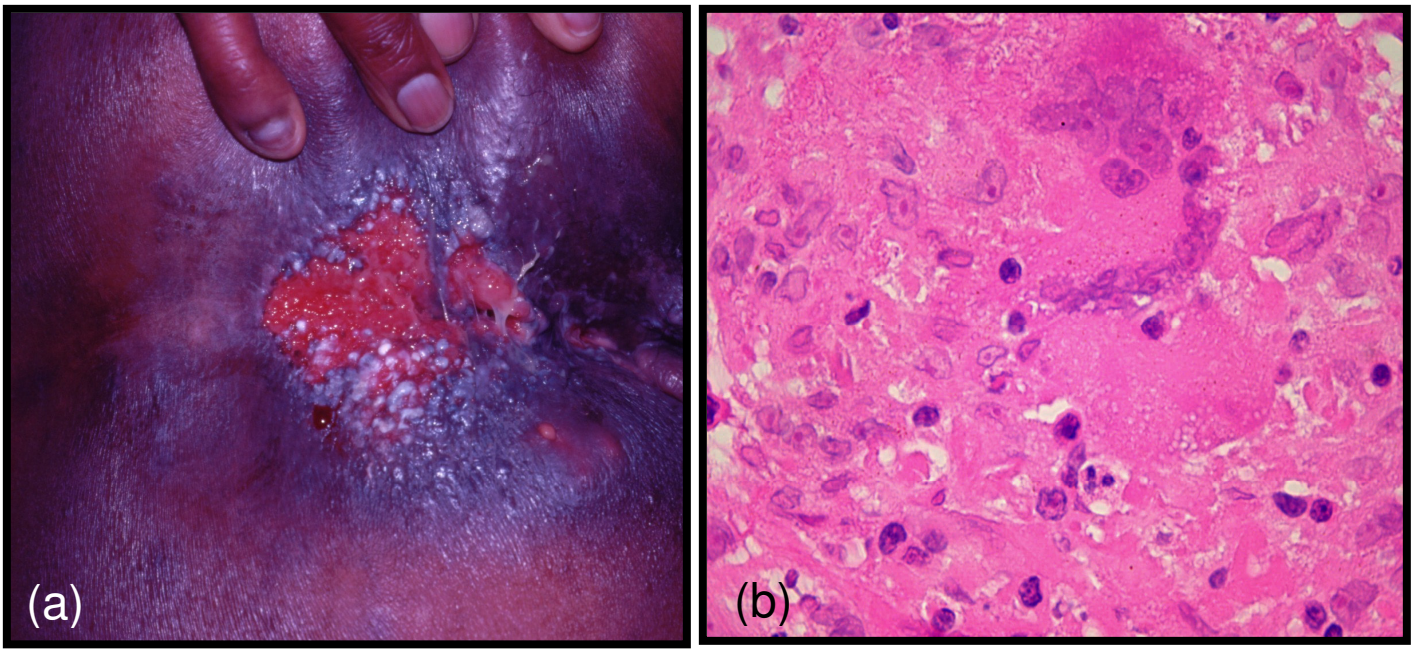



Figure 4(a,c): TB Orificialis (perianal), before and after treatment

Figure 4(b): Histology showing granulomatous infiltrate with Langhans giant cells and caseous necrosis

3.2 Statistical Analysis

Using the relevant bivariate methods, the spectrum of skin TB was analysed. The analysis of the HIV status, CD4 count and their clinical correlation was done using the Pearson's chi-square, Fisher's exact test and student t - test. The two common subtypes which accounted for more than 60% of all cases, erythema induratum and scrofuloderma were analysed in detail. Seventy five percent (15/20) of patients with scrofuloderma compared to 44.0% (11/ 25) of patients with erythema induratum were HIV positive. This translated to a statistically significant difference in the HIV positive status between the two subtypes with $p = 0.039$, odds ratio (OR) = 4.1 and 95% confidence interval (CI) = 0.8 - 21.6. HIV positive patients with scrofuloderma had a mean CD count of 145.8 cells/µl and erythema induratum a mean CD count of 234.5 cells/µl. The two-sample t - test showed a statistically significant CD4 count difference of 88.78 cells/µl (95% CI = 29.82 -147.73) with $p = 0.041$.

The non-parametric equivalent for the analysis of variance (Anova), namely the Kruskal-Wallis equality rank test showed a difference in the mean CD4 counts between various skin TB subtypes. A statistically significant difference was found between erythema induratum (CD4 count = 234.5 cells/µl) and PNT (CD4 count = 240.5 cells/µl) when plotted against miliary TB (CD4 count = 9.5 cells/µl) with p value = 0.005 and $p = 0.010$ respectively. There were 25.3% (n = 18) males and 74.7% (n = 56) females. Females accounted for 96.0% of all cases of erythema induratum and 68.2% of all cases of scrofuloderma.

The overall predominance of females resulted in a statistically significant difference in gender affected by skin TB with a p = 0.016. The difference in HIV status between true skin infections and tuberculids was recorded. Sixty seven point six percent (67.6%) of patients with true infections were found to be HIV positive (n = 23/34) compared to 45.9% of patients with tuberculids (n = 17/37). The difference was not statistically significant with p = 0.22, OR = 1.55, CI = 0.60 - 406, but showed a trend that patients were more likely to be HIV positive if suffering from a true infection rather than from a tuberculid. Pulmonary tuberculosis was found in 39.2% (n = 29) of patients and was significantly higher in patients with true skin infections than those with tuberculids. Analysis of these results showed a statistically significant difference with a p = 0.034, OR = 3.38, CI = 0.95 -11.16.

Chapter 4

4.1 DISCUSSION

A total of 74 patients were enrolled for our study over a period of 3 ½ years. The largest study on skin TB in South Africa was done almost 16 years ago at the then Ga-Rankuwa hospital, now George Mukhari hospital north west of Pretoria in Gauteng over a period of ten years from 1982 -1993. It was a retrospective study in which a total of 92 patients were analyzed. In that study only one patient had HIV infection and thus its impact on the clinical presentation of skin TB could not be assessed.

Our study was unique in that it was prospective, multi-centred (three academic hospitals) and patients could be followed up regularly to assess their clinical response to treatment. In the present study tuberculids were slightly more common than true infections accounting for 50.0% (n = 37) of all cases compared to 45.9% (n = 34) of true infections. The difference was however not statistically significant with p = 0.37. Four patients had dual pathology, i.e both tuberculids and true skin infections concurrently, and amongst these patients one had two overlapping tuberculids.

In the largest study in the world on cutaneous TB done in Japan in 2004, tuberculids were also reported to be more common than true infections.[55] In that study a total of 1324 patients seen between the years 1906 - 2002 (almost 100 years) with cutaneous TB were analyzed. Tuberculids accounted for 61% of all

cases with erythema induratum being seen in 40.5% of all cases. Similar results were reported in the Ga-Rankuwa study in which tuberculids predominated. Erythema induratum accounted for 36.5% of all cases in the present study. Scrofuloderma was the most common true skin TB infection that we encountered whilst lupus vulgaris was the most common true infection seen at Ga-Rankuwa. Factors responsible for the resurgence of tuberculosis include the HIV epidemic, adverse social conditions, multidrug-resistant tuberculosis and breakdown of tuberculosis control programmes. Some of these were prevalent amongst most of our patients, 95% of whom were black. A closer look at gender revealed that females were more commonly affected than males and accounted for 75.6% (n = 56) of all cases seen as compared to 24.3% (n = 18) of males. The difference was statistically significant with p = 0.016. The main reasons were unclear but could be partly related to the fact that erythema induratum being the most common subtype, affected primarily females.

The overall prevalence of HIV in the present study was 61.4%. This is comparable to the recorded rates in some of the studies on HIV-TB co-infection done in South Africa. In the study by Naidoo and Douglas from the School of Public Health at the University of Witwatersrand, the HIV-TB co-infection rate was found to be 46%.[56] In the same year in 2007 John *et al*. from the National health laboratory services reported a much higher HIV- TB coinfection rate of 95%. The report was based on patients who were admitted in the medical wards at the Helen Joseph hospital.[57] According to their report the data did not include HIV test results of 23.9% (89/373) of their patients.

In the HIV positive sub-group of patients with tuberculids, the mean CD4 counts were 234.5 cells/µl and 240.5 cells/µl for erythema induratum and PNT respectively. These results highlighted the fact that the majority of patients with HIV infection and tuberculids still had a relatively good cell mediated immunity with a moderate degree of hypersensitivity to *M. tuberculosis*. About 60% of HIV positive patients with tuberculids had CD4 count values of above 200 cells/ul. This is in contrast to only 30% of HIV positive patients with true skin TB infections having CD4 counts of above 200 cells/µl.

3.2.1 Clinical features (table 7)**:** Erythema induratum predominantly affected the calves of middle aged women. There was no significant clinical difference in the presentation of these skin lesions in HIV positive and HIV negative patients. PNT lesions in HIV positive patients tended to be atypical affecting mainly the ear helices, trunk, legs (linear subtype) and buttocks. Lesions often resembled papular follicular eruptions of HIV. Amongst patients with tuberculids only, 50.0% (n = 5/10) of patients with PNT were HIV positive compared to 44.0% (n = 11/25) of patients with erythema induratum. The number was less than that of scrofuloderma in which 75.0 % (n = 15/20) of patients were HIV positive. Using the Fischer exact test, a statistically significant association was found between HIV status and scrofuloderma with a p = 0.047**.** Of note is that the patients with scrofuloderma were predominantly females (n = 15, 68.2%).

The lesions of scrofuloderma were mainly found on the neck affecting the cervical glands in about 80% of cases. Miliary tuberculosis was seen only in

AIDS patients with atypical lesions consisting mainly of erythematous follicular and necrotic papules. The clinical presentation of cases of lupus vulgaris ranged from typical plaques to nodular type. The lesions affected the nose and cheeks on the face in 5 patients and the leg in the sixth patient.

3.2.2 Histopathological features (table 8) of the various subtypes of skin TB ranged from granulomatous to non-specific inflammation. Erythema induratum predominantly showed granulomatous inflammation with septolobular panniculitis. A non-granulomatous infiltrate in the HIV positive subgroup with CD4 counts of less than 100 cells/µl was seen. The histology of PNT was less striking with the typical wedge shaped area of necrosis demonstrated in 38.4% (n = 5/13) of patients. The histological appearance of scrofuloderma was characterized mainly by a granulomatous infiltrate and suppuration. This was less pronounced in the HIV positive group. *M. tuberculosis* was cultured in 45.5% (n = 10/22) of cases. The histology of lupus vulgaris was mainly tuberculoid. Acid fast bacilli were seen in only one biopsy specimen and culture was positive in 33. 3% (n= 2) of cases. The yield of TB culture in lupus vulgaris has been reported in previous studies to be around 6%.

The most striking findings were seen in milliary TB. All patients had AIDS, with a mean CD4 count of 9.5 cells/µl. The histology showed intradermal pustules with a neutrophilic infiltrate, conspicuous absence of a granulomatous reaction and abundance of acid fast bacilli on Ziehl Neelsen staining. A total of 7 patients, comprising of 3 with milliary TB, 1 with lupus vulgaris, 2 with scrofuloderma and

orificial TB were on anti-TB therapy for one week. The effect of this short course of therapy on the clinical and histological presentation could not be assessed objectively. Tuberculids responded well to a 6 months standard course of anti-TB therapy in both non-HIV and HIV infected subgroup of patients. Patients with true infections received a longer course of anti-TB therapy lasting 9 -12 months. There was essentially no difference in response to therapy in the two subgroups a finding that has previously been reported by Burman in 2005.[58] Three cases had confirmed MDR, which is resistance to both rifampicin and INH. These included two cases of miliary TB and one case of scrofuloderma. All three patients were HIV positive and consequently died of AIDS. No complications e.g bony deformities or 2^0 skin tumours were observed in any of our patients.

4.2 Limitations

Patients who were enrolled were seen primarily at the outpatient clinics as well as the in medical and general wards. A number of patients declined to participate in the study, consent not could be obtained and were therefore not enrolled. Patients less than 10 years of age were excluded primarily because of decreased level of co-operation and the reliability of PPD following BCG vaccination. Some patients with skin TB and organ TB (eg pulmonary or meningeal) could well have been treated by clinicians from other disciplines with clearance of the skin lesions and no further referral to the dermatology unit assessment.



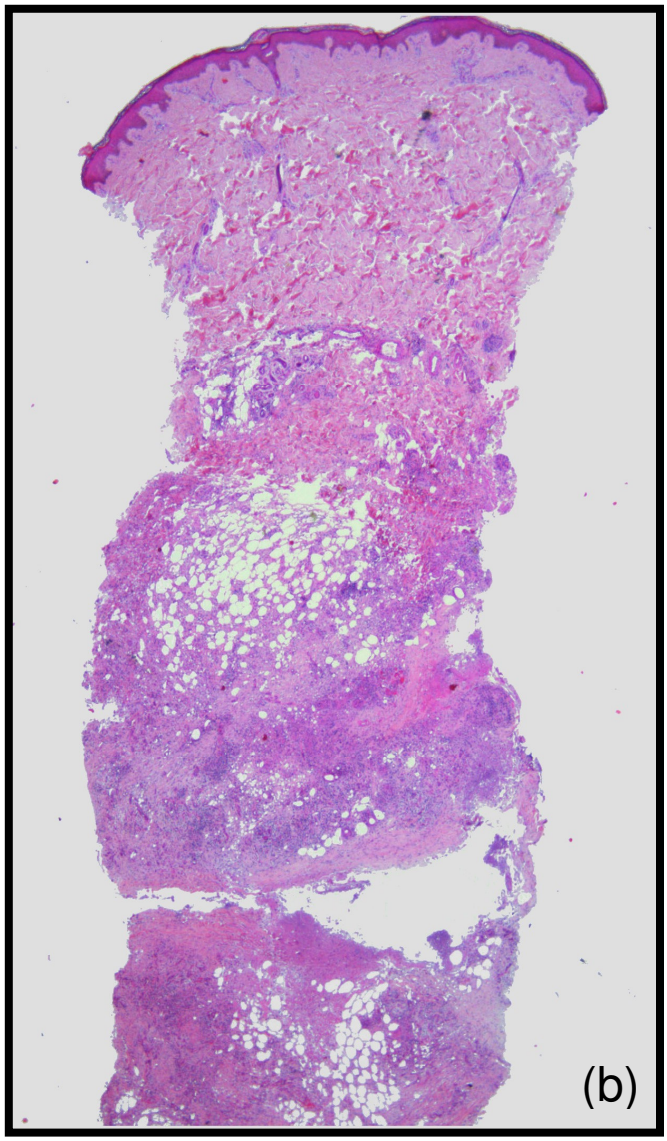

Figure 5 (a): Erythema induratum with ulcerated subcutaneous nodules affecting the calves

Figure 5 (b): Histology showing septo-lobular panniculitis

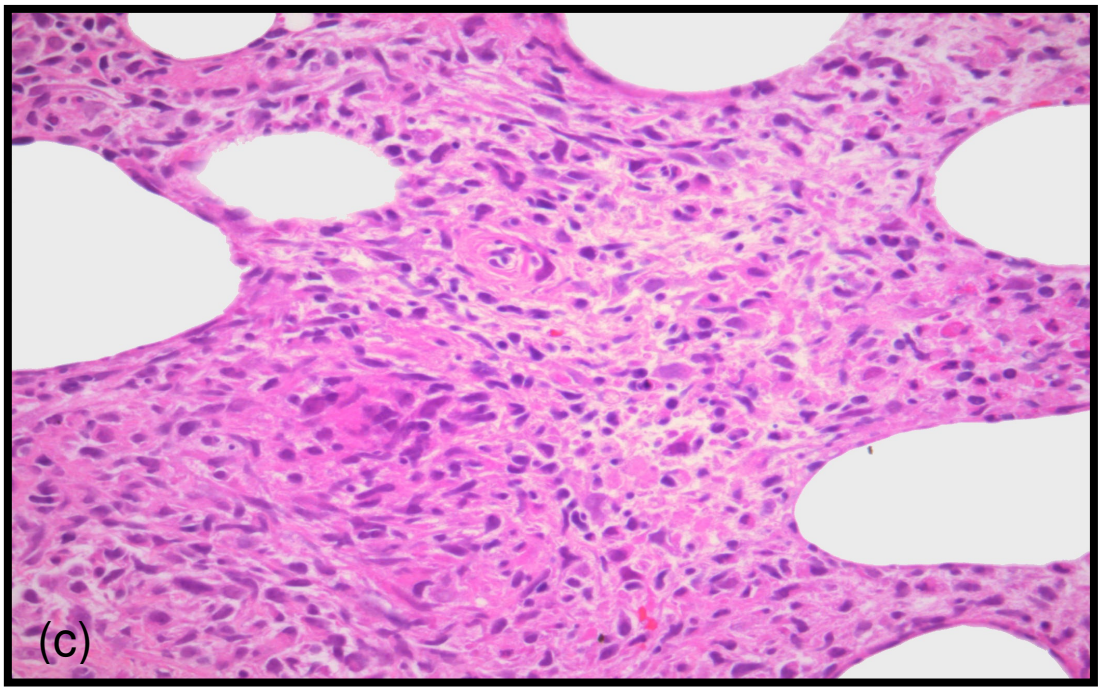

Figure 5 (c): Septo-lobular granulomatous panniculitis

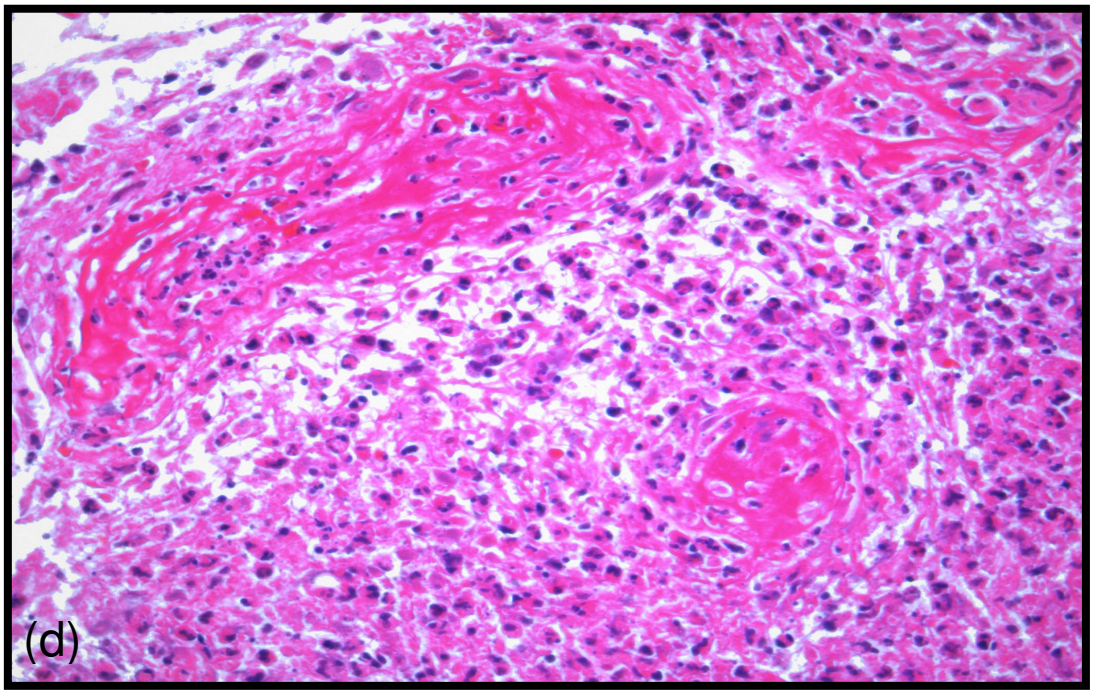

Figure 5 (d): Septo-lobular granulomatous panniculitis with coagulative necrosis and leukocytoclastic vasculitis



Figure 6 (a): Papulonecrotic tuberculid (PNT) affecting the ear helix



Figure 6 (b): Linear PNT on the legs of HIV positive patient



Figure 7 (a): Papulonecrotic tuberculid (PNT) affecting the buttocks

Figure 7 (b,c): Dactylitis associated with PNT

4.3 CONCLUSIONS

This was a prospective study which enrolled new patients and may not necessarily reflect the true spectrum of cutaneous TB in the general population in Johannesburg. It is evident from this study that the relative frequency of cutaneous TB is still low despite the high incidence of organ TB associated with HIV/AIDS. There however appears to be a trend in the pattern with a relative increase in true cutaneous TB infections particularly scrofuloderma. Tuberculids were marginally more common than true infections but the difference was not statistically significant with a $p = 0.37$. Erythema induratum was still the most common form of cutaneous TB seen, accounting for 36.5% of all the study patients, followed by scrofuloderma which accounted for 29.7% of all cases.

Cutaneous disseminated (miliary) TB continues to be rare and carries a high mortality. There was a significant statistical association between HIV infection and true cutaneous TB infections ($p = 0.024$) and not with tuberculids ($p = 0.71$). The difference between the clinical and histopathological patterns of the cutaneous TB lesions between the HIV positive and HIV negative patients depended largely on the subtype and immunological status. Further studies are necessary to look into the cytokine profile, cell adhesion molecules and T-lymphocytes sub-populations in lesional skin to elucidate the immunological mechanisms responsible for the paucity of cutaneous TB lesions despite the high prevalence of pulmonary and extrapulmonary TB especially in the setting of HIV/AIDS.

Table 7: True skin TB infections – Clinical and Pathological Features

Subtypes of skin TB	Patients	Clinical features	PPD	Culture	Histopathology
Scrofuloderma	22	Nodules, sinuses, ulcers, neck (80%), submandibular	+	45.5% +ve (10/22 pts)	Granulomas and mixed infilrate with necrosis & abscesses, AFB +ve in 7/22 pts (31.8%)
Lupus Vulgaris	6	Nodules, plaques - face (85%)	+	33,3% +ve (2/6 pts)	Tuberculoid granulomas. Mild caseation necrosis AFB +ve in 1 pt (16.5%)
Miliary TB	4	Erythematous, follicular and necrotic papules	-	100% +ve (4/4 pts)	Inflammatory infiltrate, microabscesses, AFB +ve in 4 pts (100%)
TB Abscess	2	Ulcers, abscesses on the legs	+	50% +ve 1 pt	Necrosis, abscesses, AFB +ve 2 pts
Orificial TB	1	Shallow ulcers perianally	+	+ ve	Granulomatous infiltrate, AFB +ve
Warty TB	1	Warty plaque on the hand	+	+ ve	Pseudo-epitheliomatous hyperplasia with granulomas, AFB +ve
TB Chancre	1	Indurated papulonodule on the finger	+	Not done	Mixed infiltrate with Granulomas, AFB +ve

Table 8: The Tuberculids – Clinical and Pathological features

Subtypes of skin TB	Patients	Clinical features	PPD	AFB	Histopathology
Erythema Induratum	27	Indurated ± ulcerated tender nodules – calves	+	-	Septolobular panniculitis. granulomas ± vasculitis
PNT	13	Dusky red necrotic papules legs, extensors, buttocks, ears	+	- 1 +ve	Granulomas. Wedge shaped areas of necrosis & folliculitis-like histology
Lichen scrofulosorum	1	Grouped perifollicular papules, trunk	+	-	Epitheloid granulomas with Langhans giant cells in the upper dermis
Nodular tuberculid	Not seen	-	-	-	-
Nodular granulomatous phlebitis	Not seen	-	-	-	-
+ indicates positive - indicates negative		AFB = Acid fast bacilli PPD = Purified protein derivative (Mantoux)			

Diagram 1: Pie chart. Male : Female Ratio = 1:3

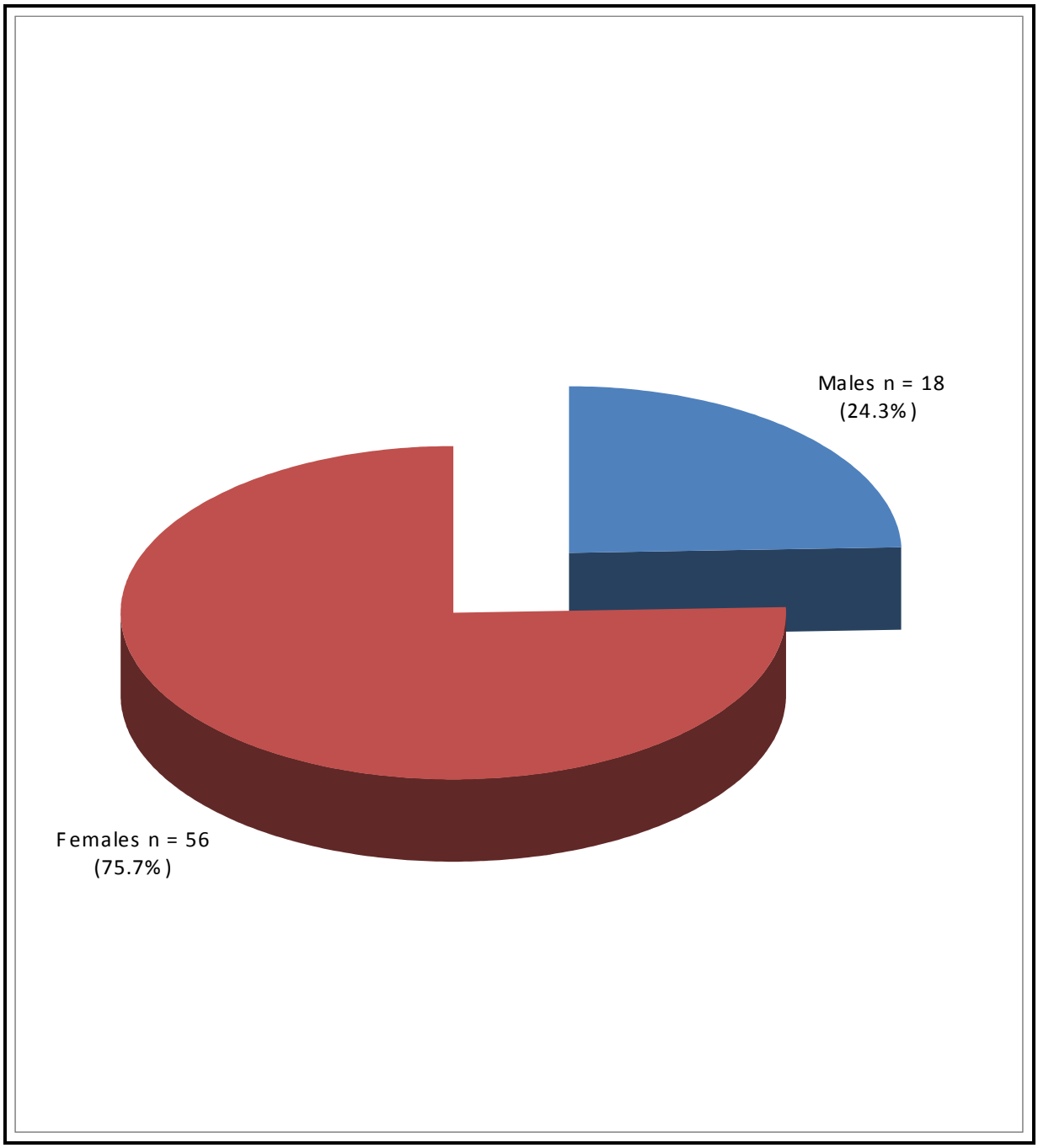

Diagram 2: Overall skin TB subtypes plotted against HIV status

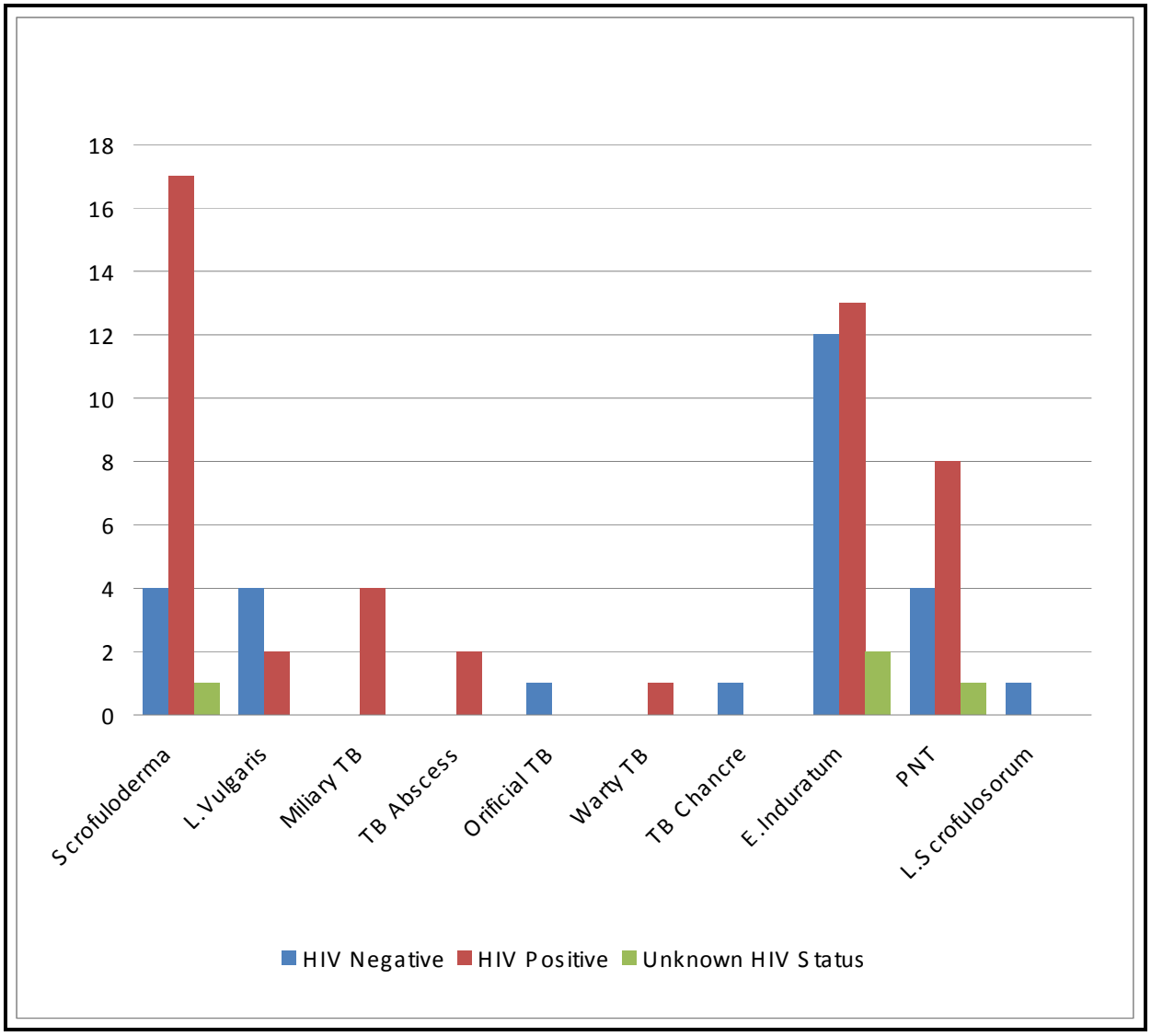

Diagram 3: CD4 counts in the HIV positive patients (Overlaps excluded)

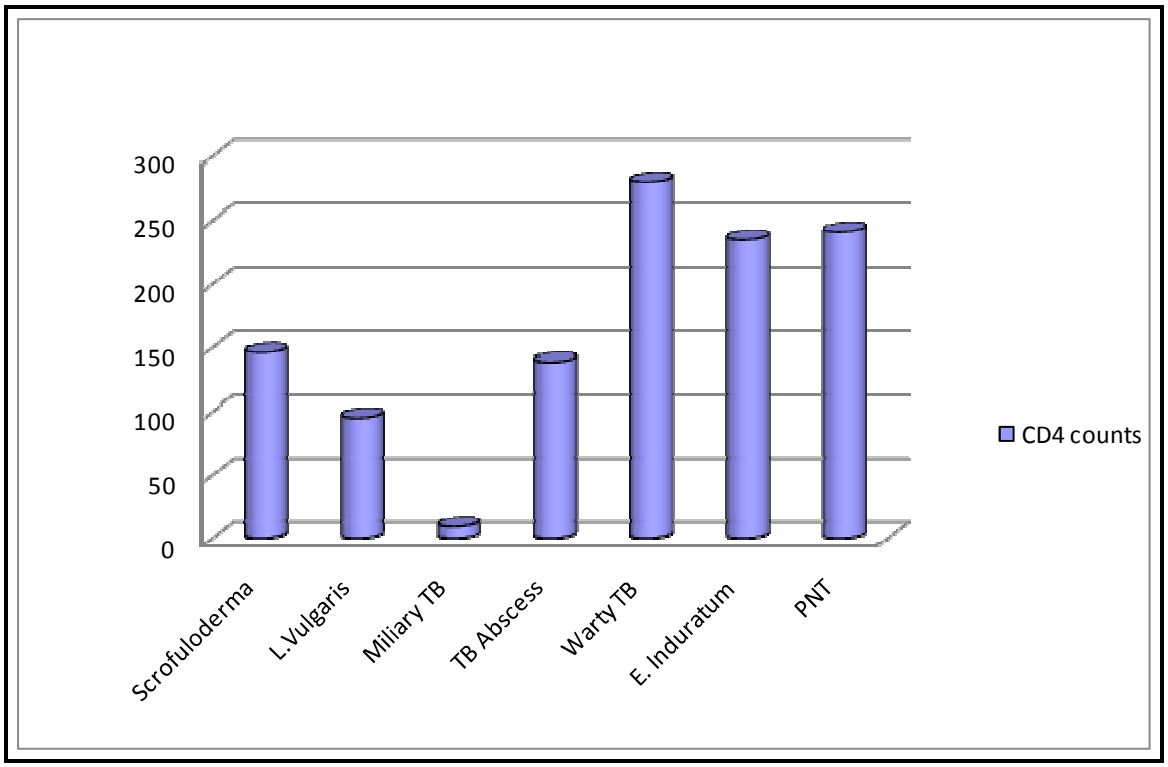

Table 9: CD4 counts in the HIV positive patients (Overlaps excluded)

Subtypes of skin TB	No. of HIV+ve patients	Mean CD4 count cells/µl
Scrofuloderma	15	145.8
L. Vulgaris	1	95
Miliary TB	4	9.5
TB Abscess	2	148.5
Warty TB	1	280
E. Induratum	11	234.5
PNT	5	240.8

Diagram 4: Skin TB subtypes plotted against gender

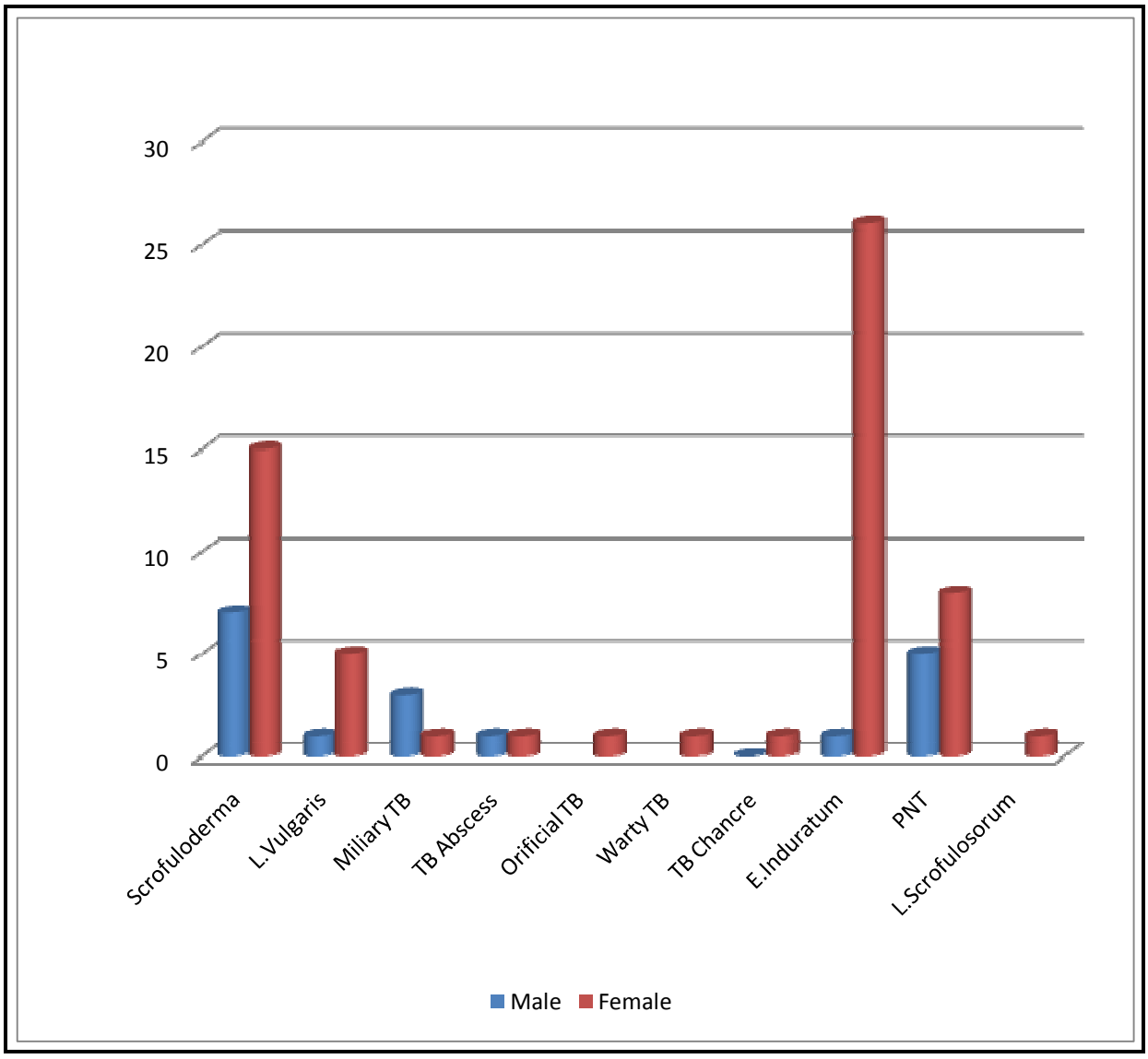

LEGENDS TO FIGURES

1. Figure 1 (a). Scrofuloderma presenting as an ulcer on the neck.
   (b). Histology showing granulomatous infiltrate with giant cells.
   (c). Positive acid fast bacilli on the tissue specimen.
   (d). Resolving lesions after 2 months of therapy.

2. Figure 2 (a). Nodular lupus vulgaris.
   (b). Well formed tuberculoid granulomas.

3. Figure 3 (a). Miliary TB presenting with erythematous follicular papules.
   (b). Histology showing an intradermal pustule.
   (c). Abundance of acid fast bacilli on Ziehl Neelsen staining.

4. Figure 4. TB orificialis perianally (a) before and (b) after treatment.

5. Figure 5 (a). Subcutaneous lesions of erythema induratum on the calves.
   (b). Histology of erythema induratum showing panniculitis.
   (c). Histology showing septo-lobular granulomatous panniculitis
   (d). Close-up showing coagulative necrosis with leukocytoclastic vasculitis.

6. Figure 6 (a). Papules on the ear in a patient with papulonecrotic tuberculid.
   (b). Linear papulonecrotic tuberculid affecting the both legs.

7. Figure7 (a). Lesions of papulonecrotic tuberculid affecting the buttocks.
   (b,c). Dactylitis associated with papulonecrotic tuberculid.

REFERENCES

1. Visser AJ, Heyl T. Skin tuberculosis as seen at Ga-Rankuwa Hospital, Pretoria. *Clin Exp Dermatol* 1993;18:507 - 15.

2. Schulz E.J. Leprosy and cutaneous tuberculosis: South African Perspectives. CME South Africa 1984; 2:39 - 51.

3. Schulz E.J. Skin disorders in Black South Africans. A survey of 5000 patients seen at Ga-Rankuwa Hospital, Pretoria. *S Afric Med J* 1982; 62: 864 - 67.

4. Yates VM, Rook GAW. *Rook's Textbook of Dermatology.*7th edition. Oxford: Blackwell Science Limited 2005. Mycobacterial Infections 28.27.

5 . Ilkunar Kivanc-Altanay, Baysal Z, Eckmeckci T.R, Koslu A. Incidence of cutaneous tuberculosis in patients with organ tuberculosis. *Int J Dermatol* 2003; 42:197 - 200.

6. Beyt BE, Ortbals DW, Santa Cruz DJ *et al.* Cutaneous mycobacteriosis: Analysis of 34 cases with a new classification of the disease. *Medicine* 1981;60:95 -109.

7. Jordaan HF, Schneider JW, Abdulla EAK. Nodular tuberculid : a report of four patients. *Pediatr Dermatol* 2000;17:183-188.

8. Hara K, Tsuzuki T, Takagi N, Shimokata K. Nodular granulomatous phlebitis of the skin. *Histopathology* 1997;30:129 - 134.

9. Seghal VN, Wagh A. The history of cutaneous tuberculosis. *Int J Dermatol* 1990;29:666 - 668.

10. *The SA Tuberculosis Control Programme*, Practical Guidelines 2001. Dept of Health.

11. Mandela N.HSRC study of HIV/AIDS 2002. Dept of Health South Africa.

12. The SA Tuberculosis Control Programme, Practical Guidelines 2006. Dept of Health.

13. WHO Global Report 2008 and WHO Anti-Tuberculosis Drug Resistance in the World Report, 2008.

14. Hanekom W. Abel B, Scriba TJ. Immunological protection against tuberculosis. *SAMJ* 2007;97:973 - 978.

15. Wadee AA, Kuschke RH. Expression of accessory molecules in the presence of *Mycobacterium tuberculosis extracts* on unstimulated and activated monocytes. *South Afric J Epidemiol Infect* 2003;18:89 - 95.

16. Sehgal N, Gupta R, Bose M, Saha K. Immunohistopathological spectrum in cutaneous tuberculosis. *Clin Exp Dermatol* 1993;18:309 - 313.

17. Seghal VN, Wagh SA. Cutaneous tuberculosis current concepts. *Int J Dermatol* 1990;29:237 - 249.

18. Bargallo J, Tager P, Ingleton R, *et al*. Cutaneous tuberculosis. *Am J Clin Dermatol* 2002;3:319 - 328.

19. Saxe N. Mycobacterial skin infections. *J Cut Pathol* 1985;12:300 - 312.

20. Ng YH, Bramwell SP, Palmer TJ. Cutaneous mycobacterial infection post intravesical BCG installation. Woo WK. *Surgeon* 2006;1:57- 58.

21. Pand D, Reddy S. Lupus vulgaris mimicking lichen simplex chronicus. *J Dermatol* 2001; 28:369 - 372.

22. Kilic A, Gul, Soylu S *et al*. Clinical and laboratory features of cutaneous tuberculosis. *EJD* 2009;19:527 - 528.

23. Motswaledi MH, Doman C. Lupus vulgaris with squamous cell carcinoma. *J Cutan Pathol* 2007;34:939 - 941.

24. Mataix J, Botella R, Herrero A, Lucas A. Tuberculous primary complex of the skin. *Int J Dermatol 2008*;47:479 - 481.

25. Margall N, Baselga E, Coll P, *et al*. Detection of Mycobacterium tuberculosis complex by polymerase chain reaction for rapid diagnosis of cutaneous tuberculosis. *Br J Dermatol* 1996;135:31 - 236.

26. Sehgal V, Sardana K, Bajaj P, Bhattacharya SN. Tuberculous verrucosa cutis: antitubercular therapy, a well-conceived diagnostic criterion. *Int J Dermatol 2005*; 44: 230 - 232.

27. Chong LY, Lo KK. Cutaneous tuberculosis in Hong-Kong: a 10-year retrospective study. *Int J Dermatol* 1995;34:26 - 29.

28. Chen YJ, Shieh PP, Shen JL. Orificial tuberculosis and Kaposi's sarcoma in an HIV-negative individual. *Clin Exp Dermatol* 2000;25:393 - 397.

29. Nachbar F, Classen V, Nachbar T, *et al*. Orificial tuberculosis: detection by polymerase chain reaction. *Br J Dermatol* 1996;135:106 - 109.

30. Daikos GI, Umtachandani R.B, Fischl M.A, Miller N, Cleary T, Saldana MJ. Disseminated miliary tuberculosis of the skin in patients with AIDS. *Clin Infect Dis* 1998; 27(1):205 - 208.

31. Libraty D, Byrd T. Cutaneous miliary tuberculosis in the AIDS era. *Clin Infec Dis* 1996 ;23 :706 - 710.

32. Chiewchanvit S, Mahanupab P, Walker P. Cutaneous tuberculosis in three HIV infected patients. *J Med Assoc Thai* 2000; 83:1550 - 1553.

33. Antorini S, Galimberti L, Tadini GL, *et al*. Tuberculosis cutis miliaris cutis disseminate due to multidrug-resistant *Mycobacterium tuberculosis* in AIDS patients. *Euro J Clin Microbiol Infect Dis* 1995;14:911 - 914.

34. Stack RJ, Bickley LK, Coppel IG. Miliary tuberculosis presenting as skin lesions in a patient with acquired immunodeficiency syndrome. *J Am Acad Dermatol* 1990;23:1031 - 5.

35. Inwald D, Nelson M, Cramp M, Francis N, Gazzard B. Cutaneous manifestations of mycobacterial infection in patients with AIDS. *Br J Dermatol* 1994;130:111 - 114.

36. Berg J, Leonard A. Clancy CJ, Nguyen MH. Subcutaneous abscesses due to *Mycobacterium tuberculosis* : paradoxical expansion of disease during therapy for miliary tuberculosis. *Clin Infect Dis* 1998; 26: 231 - 232.

37. Almagaro M, Pozo JD, Rodriquez-Lozano *et al*. Metastatic tuberculous abscesses in an immunocompetent patient. *Clin Exp Dermatol* 2005;30: 247 - 249.

38. Jacinto SS, Nograles KB. Erythema induratum of Bazin: role of polymerase chain reaction in diagnosis. *Int J Dermatol* 2003;42:380 - 381.

39. Schneider JW, Jordaan H.F, Geiger DH *et al*. Erythema Induratum of Bazin. A clinicopathological study of 20 cases and detection of *M. tuberculosis* DNA in skin lesions by polymerase chain reaction. *Am J Dermatopathol* 1995;17:350 - 356.

40. Morrison JG.L. Fourie E.D. From Arthus reaction to lupus vulgaris. *Br J Dermatol* 1974;91:263 - 269.

41. Victor T, Jordaan HF, van Niekerk DJT *et al*. Papulonecrotic tuberculid. Identification of *Mycobacterium tuberculosis* DNA by polymerase chain reaction. *Am J Dermatopathol* 1992;14:491 - 495.

42. Arianayagam AV, Ash S, Jones RR. Lichen scrofulosorum in a patient with AIDS. *Clin Exp Dermatol* 1994;19:74 -76.

43. Singal A, Sambit N, Bhattacharya. Lichen scrofulosorum: A prospective study of 39 patients. *Int J Dermatol* 2005;44:489 - 493.

44. Motswaledi HM, Schulz EJ. Superficial thrombophlebitic tuberculide. *Int J Dermatol* 2006;45:1337 - 1340.

45. Friedman PC, Husain S, Grossman M. Nodular tuberculid in a patient with HIV. *J Am Acad Dermatol* 2005;53:154 - 156.

46. Senturk N, Sahin S, Kocagoz T. Polymerase chain reaction in cutaneous tuberculosis, is it a reliable diagnostic method in paraffin-embedded tissues. *Int J Dermatol* 2002;41:863 - 866.

47. Hsiao P, Tzen C, Chen H, Su H. Polymerase chain reaction based detection of *Mycobacterium tuberculosis* in tissues showing granulomatous inflammation without demonstrable acid-fast bacilli. *Int J Dermatol* 2003;42:281 - 286.

48. Richeldi L. An update on the diagnosis of tuberculosis infection. *Am J Resp Crit Care Med* 2006; 174:736 - 742.

49. New Tuberculosis Control Programme Drug Regimens (2003). National Tuberculosis Control Programme of the National Dept of Health May 2003.

50. Ghandi NR, Moll A, Sturn AW *et al*. Extensively drug resistant tuberculosis as a cause of death in patients co-infected with tuberculosis and HIV in a rural area of South Africa. *Lancet* 2006; published on line Oct 26.

51. Shah N, Sarita. Extensively drug resistant tuberculosis in the United States,1993 - 2007. *JAMA* 2008; 300:2153 - 2160.

52. Kapur N, Schuster H, Parker N, Kesley MC *et al*. Severe sporotrichoid infection with Mycobacterium szulgai. *Clin Exp Dermatol* 2004;29:377 - 379.

53. Hartshorne ST. Dermatological disorders in Johannesburg, South Africa. *Clin Exp Dermatol* 2003;28:661 - 665.

54. Mosam A, Irusen ME, Kagoro H, *et al*. The impact of human immunodeficiency virus/ acquired immnunodeficiency syndrome (HIV/AIDS) on skin disease in KwaZulu - Natal, South Africa. *Int J Dermatol* 2004;43: 782 - 783.

55. Hamada M, Urabe K, Moroi Y*, et al*. Epidemiology of cutaneous tuberculosis in Japan: a retrospective study from 1906 to 2002. *Int J Dermatol* 2004;43: 727 - 731.

56. Naidoo S, Douglas DO. Admission trends of adult TB patients at one of the largest tuberculosis hospitals in South Africa: from 2001 to 2003. *South Afric J Epidemiology Infect* 2007;22(1):8 - 12.

57. John M, Menezes CN, Chita G *et al.* High tuberculosis and HIV coinfection rate in Johannesburg. *EID 2007*;13(5):795 - 796.

58. Burman WJ. Issues in the management of HIV-related tuberculosis. *Clin Chest Med* 2005;26(2):283 - 294.