

https://dspace.org/

Chloroquine retinal toxicity in Black African patients: comparing visual fields, spectral domain optical coherence tomography (SD-OCT) and fundus autofluorescence (FAF)

Moodley, Ashvira

2020
https://hdl.handle.net/10539/31993

Downloaded from a DSpace repository. https://dspace.org/

Chloroquine retinal toxicity in Black African patients: Comparing visual fields, spectral domain optical coherence tomography (SD-OCT) and fundus autofluorescence (FAF)

Ashvira Moodley

A research report submitted to the Faculty of Health Sciences, University of the Witwatersrand, Johannesburg, in partial fulfilment of the requirements for the degree of Master of Medicine.

Johannesburg, 2020

DECLARATION

I, Ashvira Moodley declare that this Research Report is my own, unaided work. It is being submitted for the Degree of Master of Medicine at the University of the Witwatersrand, Johannesburg. It has not been submitted before for any degree or examination at any other University.

Moodley
_____ (Signature of candidate)

23rd day of May 2020

in Johannesburg

CONTRIBUTION OF STUDENT TO SUBMISSABLE ARTICLE

Declaration: Student's contribution to article and agreement of co-author(s)

I, Ashvira Moodley, student number 0603375R, declare that this Research Report is my own work and that I contributed adequately towards research findings presented in the paper intended for publication below.

Signature of Student..... **Date**23/05/2020.....

Name of Primary Supervisor: Dr HD Alli

Signature of Primary Supervisor ..... **Date** 25/05/2020

Agreement by co-authors: By signing this declaration, the co-authors listed below agree to the use of the article by the student as part of the Research Report.

Article Title: Chloroquine retinal toxicity screening in Black African patients: Comparing Visual Fields, Spectral Domain Optical Coherence Tomography (SD-OCT) and Fundus Autofluorescence (FAF)

Authors	Name	Signature	Date
1st author	Dr Ashvira Moodley		23/05/2020
2nd author	Dr HD Alli		25/05/2020

Comments by primary supervisor:

_____

_____

_____

INTENDED JOURNAL FOR PUBLICATION

South African Ophthalmology Journal (SAOJ)

PRESENTATIONS ARISING FROM THIS STUDY

1. Department of Ophthalmology academic meeting
   University of the Witwatersrand
   Chloroquine & Hydroxychloroquine retinal toxicity - August 2017
2. Wits Ophthalmology Research Day
   Presented results of the study – August 2019

ACKNOWLEDGEMENTS

To my supervisor, Dr HD Alli for all his guidance, insight and support.

To Dr Fathima Mitha for her time and patience in assisting to independently analyse my investigations.

To Prof Tikly and Dr Naseer Ally for their time and advice in putting this project together.

To the Rheumatology department at Chris Hani Baragwanath Academic Hospital for all their assistance with referring patients to me.

To the nursing staff at St John Eye Hospital for assisting with patient education and information.

To my colleagues at St Johns Eye Hospital and Helen Joseph eye clinic for all their time and encouragement dedicated towards my project.

To my family for their patience and encouragement.

CONTENTS

DECLARATION	**i**
CONTRIBUTION OF STUDENT TO SUBMISSIBLE ARTICLE	**ii**
INTENDED JOURNAL FOR PUBLICATION	**iii**
PRESENTATIONS ARISING FROM THIS STUDY	**iv**
ACKNOWLEDGEMENTS	**v**
CONTENTS	**vi**
SUBMISSIBLE ARTICLE	**1**
Abstract	**1**
Introduction	**2**
Objectives	**4**
Materials & Method	**4**
Statistical Analysis	**6**
Results	**7**
Discussion	**13**
Conclusion	**15**
Acknowledgements	**15**
References	**16**
APPENDICES	**18**
Appendix A: Approved protocol	**18**
Appendix B: Ethics clearance certificate	**44**
Appendix C: Permission letters	**45**
Appendix D: Turnitin Report	**48**

SUBMISSABLE ARTICLE

Abstract

Background: The use of chloroquine is essential and lifesaving in many autoimmune diseases. Unfortunately with long term use, there is an increased risk of developing retinal toxicity. Multiple screening tests are available for recognition of toxicity but limited data on chloroquine retinal toxicity and use of the screening tests are available in South Africa.

Objective: To compare visual fields, spectral domain optical coherence tomography (SD-OCT) and fundus autofluorescence (FAF), to determine which of these screening tests best detects chloroquine retinopathy.

Method: A prospective, cross-sectional study of 54 patients on chloroquine >3 years. Each patient had a dilated fundus examination, visual fields, SD-OCT and FAF performed.

Results: 30-2 visual fields followed by fundus autofluorescence (FAF) showed the highest percentage of abnormal test results in chloroquine patients at 70% and 67% respectively. 30-2 and 10-2 visual fields best correlated with each other when performed in combination, with a percentage agreement of 69% followed by FAF and 10-2 visual fields with a percentage agreement of 61%. SD-OCT yielded few abnormal results (29.6%), with thinning of the outer nuclear layer without ellipsoid zone thinning. Visual field mean deviation (VFMD) was significantly lower in patients with abnormal visual field patterns than normal patients in both 10-2 ($p=0.0031$) and 30-2 ($p<0.0001$) visual fields.

Conclusion: A combination of tests should be performed when screening for chloroquine retinopathy. Our study revealed that although the 30-2 and 10-2 visual fields best correlated with each other, the 10-2 visual field and FAF yielded the best results when performing different screening tests.

Introduction

Chloroquine (CQ) and its analogue hydroxychloroquine (HCQ) have been used since the early 1960's.[1] Initially developed for use in malaria patients, it is now an integral part of management of a range of medical conditions, especially autoimmune conditions such as rheumatoid arthritis, systemic lupus erythematosus(SLE) and mixed connective tissue disorders; dermatologic conditions; and paediatric inflammatory conditions.[1]

The use of HCQ is increasing, due to the minimal systemic side effect profile; the increasing number of indications for its use; and data from the LUMINA study, which demonstrated a clear survival benefit of HCQ in patients with SLE.[1] However, long term use of HCQ and CQ has been associated with irreversible vision loss due to retinal toxicity requiring cessation of the drug.[1]

An overall prevalence of 7.5% of HCQ retinopathy was identified in patients taking HCQ for more than 5 years, rising to 20% after 20 years, which is three times higher than previously reported.[2] Based on these figures, HCQ retinopathy is a significant health and patient safety issue.

The most significant risk factors for developing HCQ and CQ retinal toxicity are the dose and duration of these drugs.[3] The recommended daily dose of HCQ is <5.0mg/kg of real weight and of CQ is <2.3mg/kg of real weight. At these recommended doses of HCQ, the risk of toxicity is 1% in 5 years, and up to 2% in 10 years.[3] Data on CQ retinopathy is limited but similar comparisons can be made.[3]

Retinopathy is irreversible and therefore recognition at an early stage is crucial to maintain central vision.[3] The mechanism of HCQ - and CQ - retinal toxicity is poorly understood, but primary damage appears to occur to the photoreceptor layer with secondary degeneration to the retinal pigment epithelium (RPE).[1] If retinopathy is recognised early, prior to RPE damage, there is only mild visual loss and minimal progression of damage after treatment is stopped, thus preserving central vision.[3] Recent evidence has shown that if the external limiting membrane is preserved, patients may have photoreceptor regeneration and good visual prognosis.[4]

There are various screening modalities, both objective and subjective available for HCQ and CQ retinopathy to effectively recognise retinal toxicity early before detected

clinically on fundus examination and prior to visual symptoms. Multifocal electroretinogram (Mf-ERG) is considered the gold standard for HCQ retinopathy detection, however it is not widely available in most practices and requires specialised training to perform and interpret the results.[5] Retinal macular thickness (especially the inner subfield) on optical coherence tomography (OCT) and visual field mean deviation (VFMD) correlated well with results from mf-ERG when looking at patients with HCQ/CQ retinopathy, and could be used as useful surrogate tests for mf-ERG testing results.[5]

The recommended screening tests for routine primary screening set out in the American Academy of Ophthalmology (AAO) guidelines in 2016 include both automated visual fields and SD-OCT, as these tests are widely available and easy to perform.[3] Mf-ERG and fundus autofluorescence, if available, are considered additional useful tests in the guidelines.[3]

HCQ or CQ retinopathy presents differently in each patient and some patients may be more sensitive to one screening test over another. In addition HCQ retinopathy does not always develop in a parafoveal (bulls eye) pattern, and some patients may present in a pericentral (typically near the arcades) pattern of damage.[6] This pericentral pattern was noted predominantly amongst Asian patients and therefore require wider test patterns; conclusions could not be drawn from African patients as the study number was too small. A study by Marmor comparing different screening modalities concluded that multiple screening tests may be necessary to detect retinal toxicity.[7]

HCQ is less toxic and more effective than CQ and largely replaced the use of CQ in developed countries.[1,3] This had led to a decrease in retinopathy in developed countries; however, in South Africa, HCQ is not available to patients in the public sector.[8] Limited data on CQ retinal toxicity and the use of screening tests are available in South Africa and specifically in the black African population.

The aim of the study was to compare results of screening tests in patients on CQ to determine which test or combination of tests are able to best recognise retinal toxicity.

Objectives

To compare Visual Field, Spectral Domain Optical Coherence Tomography (SD-OCT) and Fundus Autofluorescence (FAF) in black African patients on chloroquine in order to determine which of these screening tests best detected chloroquine retinopathy.

A secondary objective was to determine the patterns of retinal toxicity in black African patients.

Materials and Methods

A prospective, cross-sectional study was conducted on patients using chloroquine for more than 3 years. Patients were recruited from the Rheumatology Department of Chris Hani Baragwanath Academic Hospital from February 2018 until July 2019. Ocular history, examination and investigations were conducted at St John Eye Hospital (Ophthalmology Department at Chris Hani Baragwanath Academic Hospital). Ethics approval was obtained from the Human Research Ethics Committee (clearance number M 171161) of the University of Witwatersrand and the study adhered to the tenets of the Declaration of Helsinki. Written informed consent was obtained from all participants in the study.

Participants who met the following inclusion criteria were enrolled in the study:

- Patients on chloroquine for more than 3 years.
- 18 years or older.
- Normal intraocular pressure (10-21 mmHg).
- Clinically normal optic disc.
- Absence of other fundus pathologies.

Exclusion criteria included patients with:

- Neurological disease with optic disc abnormalities.
- Ocular conditions such as glaucoma; clinically significant retinal/macular or choroidal diseases; and history of eye trauma and uveitis.
- Poor visibility of the retina in whom screening tests could not be done.

Information obtained from patients included demographics; past medical history; body weight and height; dosage; duration and indication of chloroquine use; other drug history; and previous screening tests. Most recent renal function was obtained from hospital records. A slit lamp and dilated fundus examination was performed for each patient by the primary investigator. Screening tests were performed in both eyes of all patients.

Perimetric assessment included both a 10-2 and a 30-2 visual field by the Humphrey Visual Field Analyser (Carl Zeiss Meditec). Interpretation of visual field pattern was carried out independently by the primary investigator and a specialist ophthalmologist in our department. Criteria used for abnormal results included three or more non-edge contiguous points when looking at the 30-2 visual fields and three or more contiguous points when looking at the 10-2 visual fields. Visual field mean deviation values (VFMD) which represents the deviation from age matched eyes were obtained. The Spectral Domain Optical Coherence Tomography (Spectralis SD-OCT, Heidelberg eye explorer version 1.10.15.0, (Heidelberg Engineering, Germany)) images were obtained and analysed quantitatively by measuring the retinal thickness by looking at the macula subfield thickness maps. Qualitative analysis was done by manually assessing for the presence or absence of anatomic disruptions in the parafoveal, perifoveal and pericentric ellipsoid zone and outer retinal layers. Fundus autofluorescence (FAF) images were obtained using the Spectralis SD-OCT, Heidelberg eye explorer version 1.10.15.0, (Heidelberg Engineering, Germany). These were subjectively graded as normal or abnormal independently by both the principal investigator and a specialist ophthalmologist in our department. Disagreements in the grading of the images were resolved by a retinal specialist in our department. All data was electronically entered into a Redcap database, and then transferred to an excel spreadsheet.

Statistical Analysis

The sample size calculations was carried out in G*Power.[9] Assuming to find a large size effect, with 80% power at the 5% significance level, the sample size was calculated to be 52 patients.[9]

Descriptive analysis of the data was carried out as follows: categorical variables were summarised by frequency and percentage tabulation, and illustrated in bar charts. Continuous variables were summarised by the mean and standard deviation, median and interquartile range, and their distribution illustrated by histograms.

The abnormal and normal findings from the 30-2 and 10-2 visual fields, fundus autofluorescence (FAF) image and the SD-OCT images were cross-tabulated to determine which two tests performed together showed the highest correlation.

A t-test was used to compare the visual field mean deviation (VFMD) of patients with normal visual fields to patients with abnormal visual fields. The t-test was also used to compare the retinal macula thickness of patients with normal SD-OCT to patients with abnormal SD-OCT.

For each screening test, the median CQ daily dosage was compared between patients with abnormal and normal findings, using the Wilcoxon rank sum test (since the data did not meet the assumptions for the independent samples t-test).

Data analysis was carried out in conjunction with a statistician using STATISTICA v13.1. A 5% significance level was used.

Results

Fifty four patients on chloroquine (CQ) were included in the study (Table 1). The mean (SD) age was 46.9 (14.6) years (range 18-76 years) with a mean (SD) body mass index (BMI) of 29.4 (7.9) kg/m^2 (range 12.7-50.2 kg/m^2). Ninety eight percent of patients were female. Analysis of medical comorbidities, showed that 39% of patients had medical comorbidities; hypertension was the most common comorbidity. In terms of other drug history, 68.5% of patients had no other drug use. The most common drug used was steroids in 16.7%.

Fifty two percent of patients on CQ had systemic lupus erythematosus (SLE), forty six percent had rheumatoid arthritis (RA) with one patient (two percent) patient presenting with juvenile idiopathic arthritis (JIA) (Table 1). The median (IQR) duration of CQ use was six years (4-11). Figure 1 shows the distribution of duration of chloroquine use.

Table 1: Demographics, medical and screening history

Variable	Mean (SD)	Median (IQR)	Number (n)	Percentage (%)
Age (Years)	46.9 (14.6)			
BMI (kg/$m^{2)}$	29.4 (7.9)			
Gender				
Female			53	98
Male			1	2
Ethnicity				
African			54	100
Medical Comorbidities				
None			33	61
Hypertension			19	35
Thyroid			1	2
Asthma			1	2
Diabetes			0	0
Other drug history				
Steroids			9	16.7
NSAIDS			0	0
Methotrexate			8	14.8
None			37	68.5

Indication for CQ use SLE RA JIA			 28 25 1	 52 46 2
Duration of CQ use (years)		6 (4-11)		
Cumulative CQ dose (grams)		312 (208-468)		
Previous CQ screening Visual fields Fundus Autofluorescence SD-OCT None			 24 24 7 23	 44 44 13 43
Creatinine Level Normal High (Females >90µmol/L, Males > 104µmol/L)			 48 4	 92.3 7.7

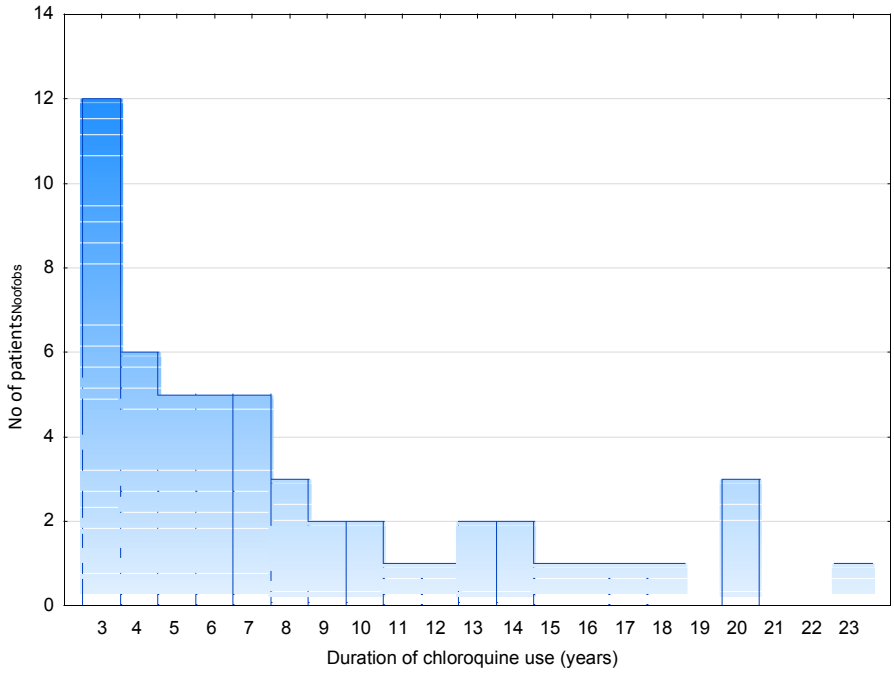

Figure 1: Distribution of duration of CQ use in study patients

The median (IQR) cumulative CQ dose was 312g (208-468). Figure 2 shows the CQ cumulative dose distribution.

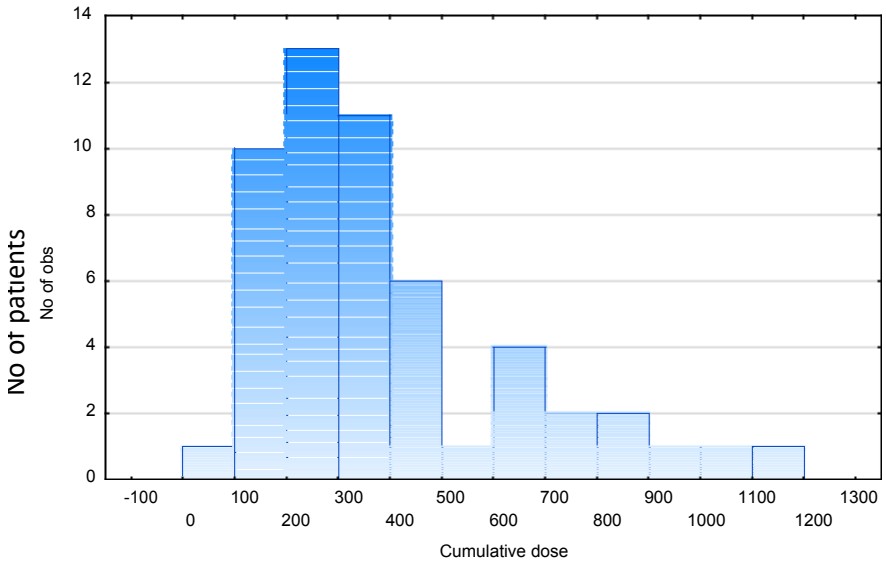

Figure 3: Distribution of cumulative dose of CQ in study patients

Forty three percent (23) of patients had no previous screening tests performed for CQ retinopathy. The most common screening tests performed previously included visual fields and FAF which was 44% (24 patients). Only 13 % (seven) of patients had a previous SD-OCT performed.

Creatinine levels, which is an indicator of kidney function, was obtained in 52 patients. It was normal in 92.3% of patients, while 7.7% had increased creatinine levels (females >90µmol/L and males > 104µmol/L).

The ocular examination of 54 patients (108 eyes) showed that most patients had good best corrected visual acuity (BCVA) in both eyes, with a mean (SD) LogMAR BCVA of 0.14(0.16) (Snellen equivalent = 6/7.5). Figure 3 shows the distribution of LogMAR BCVA.

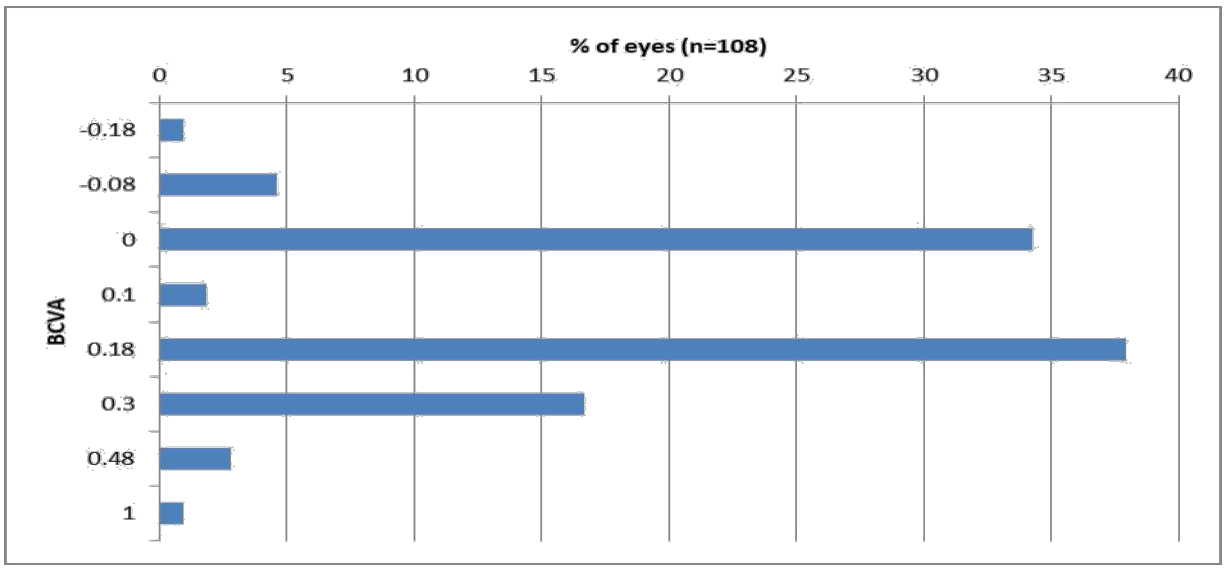

Figure 3: Distribution of BCVA (Log MAR) in study patients

Clinically, 40.7% of eyes had decreased foveal reflex and a mottled macula. No patients presented with a bulls eye maculopathy.

The number of patients with abnormal screening tests are shown in table 2 and depicted in figure 4. The 30-2 VF and the FAF yielded the highest number of abnormalities. (Table 2 and Figure 4).

Table 2: Results of CQ screening tests

Screening test	**Number of patients (n)**	**Percentage (%)**
30-2 Visual fields		
Abnormal	38	70
Normal	16	30
10-2 Visual fields		
Abnormal	31	57
Normal	23	43
SD-OCT ellipsoid zone		
Abnormal	16	30
Normal	38	70
FAF		
Abnormal	36	67
Normal	18	33

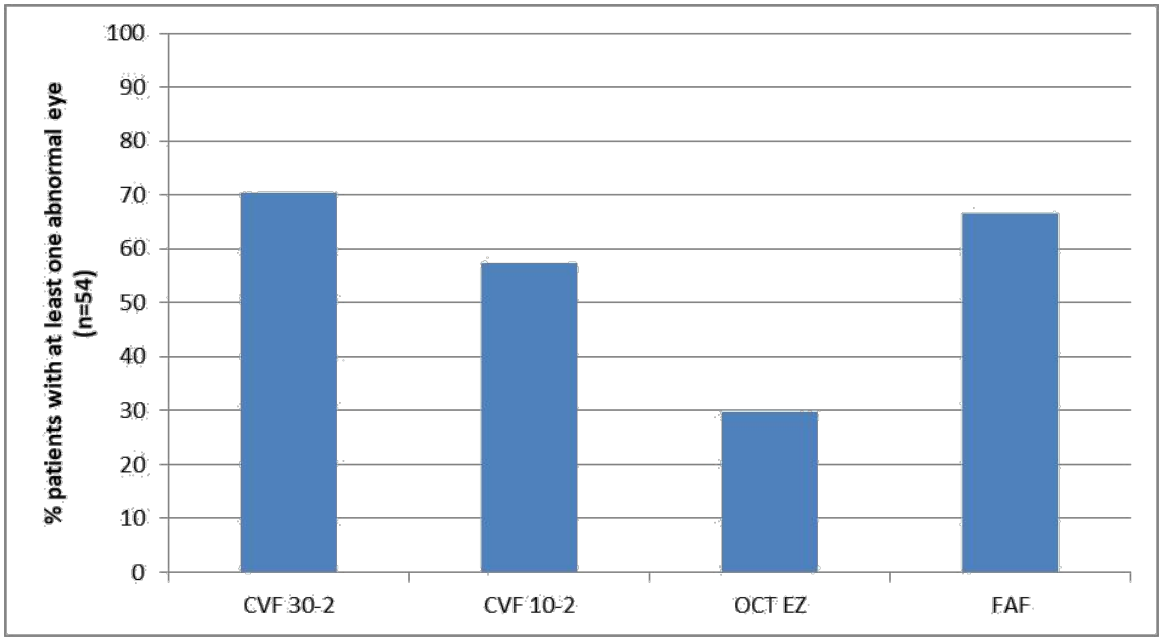

Figure 4: Outcomes of CQ screening tests in patients with at least one abnormal eye

The outcomes of the above tests were then cross tabulated in pairs to determine which two tests performed together showed the highest correlation / agreement. (Table 4)

Table 4: Pairing of screening tests to determine percentage agreement

Screening tests	**Outcomes**	**Number of patients (n)**	**Percentage (%)**	**% Agreement**
10-2 & 30-2 VF	Abnormal Normal	26 11	48.1 20.4	68.5
10-2 VF & FAF	Abnormal Normal	23 10	42.6 18.5	61.1
30-2 VF & FAF	Abnormal Normal	25 5	46.3 9.3	55.6
10-2 VF & SD-OCT ellipsoid zone (EZ)	Abnormal Normal	11 18	20.4 33.3	53.7
FAF & SD-OCT EZ	Abnormal Normal	10 12	18.5 22.2	40.7
30-2 VF & SD-OCT EZ	Abnormal Normal	11 11	20.4 20.4	40.7

The highest correlation / agreement occurred between the two types of visual fields, the 30-2 and the 10-2; the percentage agreement was 68.5%. The second best correlation was between the 10-2 visual fields and the FAF, which had a percentage agreement of 61.1%. The lowest correlation was between the OCT EZ with both the FAF and the 30-2 visual field, with a percentage agreement of 40.7%.

The mean 30-2 VFMD for patients with abnormal visual field patterns was significantly lower (-0.5) than that for normal patients (0.5) ($p<0.0001$). The effect size was large (Cohen's d =1.3). The mean 10-2 VFMD for abnormal patients was significantly lower (-3.1) than that for normal patients (0.1) ($p=0.0031$). The effect size was large (Cohen's d =0.87). Figure 5 illustrates the results, with the error bars denoting the 95% CI for the mean.

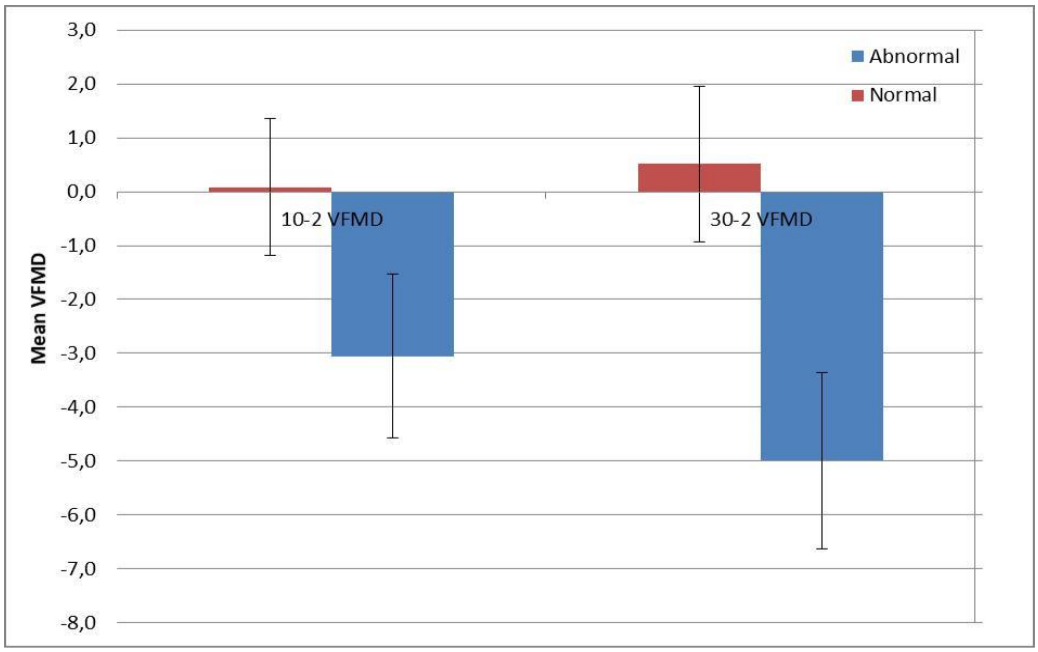

Figure 5: VFMD results of 10-2 and 30-2 visual fields

The association between each screening test outcome and median cumulative CQ dose were analysed. No significant difference in median cumulative CQ dose was found between abnormal and normal results. (Figure 6 [the error bars denote the IQR]).

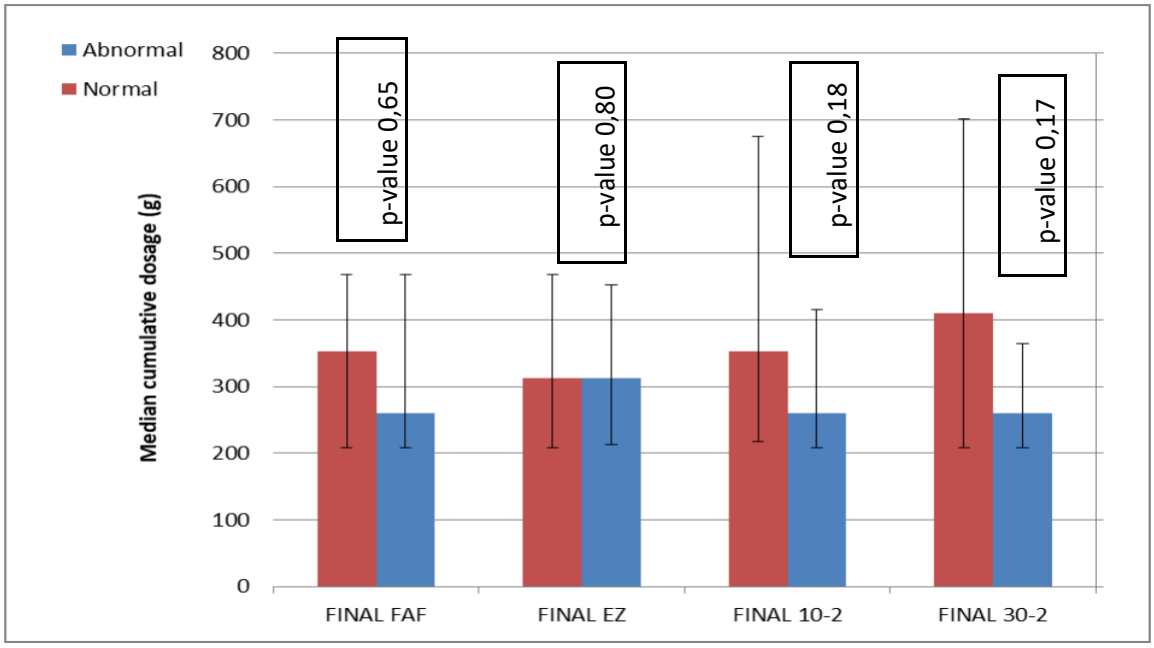

Figure 6: Association between screening test outcomes and median cumulative dose

Discussion

Marmor et al suggested that a combination of tests provided a more comprehensive and reliable method of detecting CQ retinopathy.[10] The American Academy of Ophthalmology (AAO) revised 2016 guidelines for CQ/HCQ screening suggest the use of both visual fields and SD-OCT for routine primary screening, because these tests are widely available.[3] However, in our study, in terms of performing different screening tests, the combination of the 10-2 visual field and FAF showed a better correlation, with 61.1% agreement between tests. The combination of 10-2 visual fields and SD-OCT had a percentage agreement of 53.7%. The lowest correlation was between the OCT EZ with both the FAF and the 30-2 visual field. The 30-2 and 10-2 visual fields yielded the highest agreement (68.5%) when performed together but constitutes the same test targeting different fields of view. Occasionally, it may be necessary to do both visual field tests. If a 10-2 shows any peripheral abnormalities a 30-2 should be performed thereafter, and likewise if a 30-2 shows any central defects, a 10-2 should be performed to confirm or exclude any central defects. The 2016 AAO guidelines suggest central (10-2) visual fields and to include wider test patterns (30-2/24-2) for Asian patients where toxicity manifests beyond the macula.[3]

CQ and HCQ retinopathy on FAF is depicted early as parafoveal or extramacular (pericentral) areas of increased autofluorescence, with late findings resulting in

decreased autofluorescence.[3] Patients with abnormal FAFs in our study presented with a central area of hyperfluorescence within the foveal area. However, our patients were on CQ and most of the literature reported on HCQ retinopathy. Larger studies need to be undertaken in the future to determine if this is the pattern of retinopathy in CQ patients. Our findings differ with the findings of a South African study by Goodman et al, who found a low incidence of CQ retinopathy on SD-OCT and FAF [8], and suggested that FAF may be difficult to detect early retinopathy. However, the patients in our study were on chloroquine for a minimum of three years.

Although the AAO 2016 guidelines for CQ screening recommended SD-OCT as a screening test, very few patients in our study showed abnormalities on SD-OCT.[3] Disruption and thinning of the photoreceptor ellipsoid zone develop in patients with HCQ/CQ retinopathy.[3] Outer retinal thickness remains normal until these focal signs develop. In our study, most of the patients with abnormal FAFs had a thinned outer nuclear layer without any ellipsoid zone thinning or damage on SD-OCT in 29.6% (n = 16) of patients. This outer nuclear layer thinning preceding ellipsoid zone damage in CQ patients' needs to be further investigated in a larger study.

In their study, Melles and Marmor highlighted that HCQ retinopathy does not always present in a parafoveal pattern of damage and that a pericentral pattern of damage, which is especially prevalent among Asian patients, can also be seen on FAF and SD-OCT.[6] In their study, black patients showed a predominantly parafoveal and foveal pattern of damage, but no conclusions could be made, as the percentage of black patients in their study was small. In our study on black African patients, none of our patients showed a pericentric pattern of damage on FAF and SD-OCT.

Visual field mean deviation (VFMD) is an important parameter to look at when screening for HCQ/CQ retinopathy. Cukras et al suggested that SD-OCT macula thickness and VFMD are sensitive and specific objective tests for HCQ retinopathy and may be a suitable surrogate test to Mf-ERG.[5] In our study, the VFMD was significantly lower in patients with abnormal visual fields than in those with normal visual fields. However, not all the visual fields included in the study for analysis were reliable (<20% fixation losses, <20% false negatives and positives) (22.2% 10-2 and 41.6% 30-2 unreliable visual fields). Tan et al suggested that labelling visual fields as reliable and unreliable can represent a false division in test results, as reliability and

its indices fall along a continuum.[11] Reliable visual fields itself may be misleading and unreliable fields can provide enough information to establish or exclude disease, and should not be disregarded. In a study by Browning et al, they looked at 10-2 visual fields in HCQ screening and no important differences were found between the analysis of reliable visual fields and all visual fields combined (reliable and unreliable).[12] On the basis of these two studies, we analysed all the visual fields (reliable and unreliable) in our study.

There are several limitations to this study including the use of both reliable and unreliable visual fields included in the analysis. Visual fields were carried out on two different machines due to technical related problems. A sample size of 54 patients is small and allows for detection of only large effect sizes.

Conclusion

Our study on CQ retinal toxicity showed that the combination of two different screening tests, the 10-2 visual field and FAF, showed the best correlation amongst the different tests. Because of the variability in abnormality between screening tests in patients, a combination of two tests is better than a single screening test. The pattern of CQ retinopathy on FAF and SD-OCT amongst black African patients in our study was parafoveal.

Unique to this study was outer nuclear layer thinning preceding ellipsoid zone disruption and thinning on SD-OCT. This study confirms that a lower VFMD is a useful objective indicator of CQ retinopathy.

Acknowledgements

The rheumatology department at CHBAH for providing patients on CQ, specialist ophthalmology consultants at SJEH for independent analysis of the investigations.

References

1. Yusuf IH, Sharma S, Luqmani R, Downes SM. Hydroxychloroquine retinopathy. *Eye*. 2017;doi:10.1038/eye.2016.298.
2. Melles RB, Marmor MF. The Risk of Toxic Retinopathy in Patients on Long-term Hydroxychloroquine Therapy. *JAMA Ophthalmol*.2014;132(12):1453-1460.
3. Marmor MF, Kellner U, Lai TY, Melles RB, Mieler WF. Recommendations on Screening for Chloroquine and Hydroxychloroquine Retinopathy (2016 Revision). *Ophthalmology*. 2016;123: 1386-1394.
4. Mititelu M, Wong B,Brenner M, Bryar PJ, Jampol LM, Fawzi AA. Progression of Hydroxychloroquine Toxic Effects After Drug Therapy Cessation. *JAMA Ophthalmol*.2013;131(9):1187-1197.
5. Cukras C, Huynh N, Vitale S, Wong WT, Ferris FL, Sieving PA. Subjective and Objective Screening Tests for Hydroxychloroquine Toxicity. *Ophthalmology.* 2015;122:356-366.
6. Melles RB, Marmor MF. Pericentral Retinopathy and Racial Differences in Hydroxychloroquine Toxicity. *Ophthalmology*.2015;122:110-116.
7. Marmor MF. Comparison of Screening Procedures in Hydroxychloroquine Toxicity. *Arch Opthalmol*.2012;130(4):461-469.
8. Goodman MB, Ziskind A. Fundus auto fluorescence and spectral domain ocular coherence tomography in the early detection of chloroquine retinopathy*. Afr Vision Eye Health*.2015;74(1):1-59.
9. Faul F, Erdfelder E, Lang A et al. G* Power 3: A flexible statistical power analysis program for the social, behavioural and biomedical sciences. *Behaviour Research Methods*. 2007;39:175-191
10. Marmor MF, Melles RB. Disparity between Visual Fields and Optical Coherence Tomography in Hydroxychloroquine Retinopathy.*Ophthalmology*.2014; 121:1257-1262
11. Tan N, Tham YC, Koh V et al. The effect of Testing Reliability on Visual Field Sensitivity in Normal eyes. *Ophthalmology*. 2018;125:15-21

12. Browning DJ, Lee C. Scotoma analysis of 10-2 visual field testing with a white target in screening for hydroxychloroquine retinopathy. *Clinical Ophthalmology*. 2015;9:943-952

Appendices

Appendix A: Approved protocol

RESEARCH PROTOCOL

Chloroquine retinal toxicity screening in black African patients: Comparing Central Visual Fields, Spectral Domain Optical Coherence Tomography (SD-OCT) and Fundus Autofluorescence (FAF)

Dr Ashvira Moodley
Registrar
MMED student
Student no: 0603375R
Department of Neurosciences
Division: Ophthalmology
University of Witwatersrand

Supervisor: Dr H.D. Alli

CONTENTS

			Page
1.	Introduction		2
2.	Literature Review		3
3.	Study aim		10
4.	Study objectives		10
5.	Study methods		10
	5.1	Study design and Study site	10
	5.2	Inclusion criteria	10
	5.3	Exclusion criteria	11
	5.4	Materials, equipment and facilities	11
	5.5	Data collection	11
	5.6	Study procedure	13
	5.7	Sample size	13
	5.8	Data analysis	13
	5.9	Predicted timeline	14
6.	Ethics		15
7.	Funding		15
8.	Possible limitations		15
9.	Reporting plans		16
10.	Authorship		16
11.	References		16
Appendix A-Information sheet			19
Appendix B-Informed consent form			21
Appendix C-Data capture sheet			22

Chloroquine retinal toxicity screening in black African patients: Comparing Central Visual Fields, Spectral Domain Optical Coherence Tomography (SD-OCT) and Fundus Autofluorescence (FAF)

1. Introduction

Chloroquine (CQ) was developed in 1939, its analogue hydroxychloroquine (HCQ) was introduced later and used since the 1960's.[1] Originally, CQ was used to treat malaria, however its use for malaria has declined due to increased drug resistance that developed. In developed countries HCQ has largely replaced the use of CQ as it is found to be more effective and less toxic than CQ. Currently it is widely used in a number of medical conditions, most commonly non-organ specific autoimmune diseases such as rheumatoid arthritis (RA), systemic lupus erythematosus (SLE) and mixed connective tissue disorders; dermatologic conditions and recently in paediatric inflammatory disorders and oncology.[1] Its use is increasing and there has been a proven survival benefit in patients with SLE.[1,2]

There are minimal systemic adverse effects which necessitate drug cessation but prolonged use of the drug has been shown to cause severe irreversible and potentially blinding retinal damage in susceptible patients.[3] If retinal toxicity is recognized early, central vision can be preserved. The main aim of screening for retinopathy is not to stop these valuable lifesaving drugs at the first borderline abnormality but rather to identify definitive signs of toxicity at an early stage to prevent progression and eventual vision loss. [4]

Screening for CQ/HCQ toxicity presents multiple challenges to ophthalmologists. There are various modalities both objective and subjective, which have been used for CQ/HCQ screening. It is important to remember that retinal toxicity can present differently in each patient and that any abnormalities on one test needs to be further investigated for possible retinal toxicity with other tests.[5] A study by Marmor comparing different screening procedures concluded that different patients are sensitive to different tests and that screening should involve multiple tests.[6] Algorithms for screening have constantly been changing throughout the years; debates on which

screening tests offer the best results are ongoing. Some challenges faced are that some tests may not be adequate to identify early retinal changes associated with toxicity, or require expert interpretation; thresholds for toxicity may not be well established and screening tests may not be widely available.[7] Currently there is no known treatment for retinal toxicity and recognition at an early stage is important, therefore understanding when and which tests to perform by ophthalmologists is crucial.

Advances and new information is constantly being made with regards to CQ and HCQ screening. Current practice in screening and management is heterogeneous amongst different institutions and it is still unclear what the best practice is. Considerations for screening recommendations include accessibility, reliability, ease of interpretation and cost of testing.[7]

This study aims to compare screening tests to determine which tests are more beneficial in terms of early recognisable retinal changes and prevention of loss of visual acuity. It will serve as a platform to guide ophthalmologists in our setting to have a uniform algorithm to follow when screening for CQ and HCQ toxicity thus allowing more efficacious, cost effective practices and a more responsible use of this valuable drug. It will avoid unnecessary stopping of treatment based on abnormal screening tests that are not appropriate for CQ and HCQ detection.

2. Literature review

The use of chloroquine (CQ) and hydroxychloroquine (HCQ) is increasing. [1] There are multiple indications for its use. It can be used as adjunctive treatment with other biologic drugs and disease modifying agents, and it has an important role in controlling disease activity. It has a reasonably favourable systemic safety profile during prolonged use. Based on these reasons, there is an expanding patient population on long term CQ and HCQ use. Unfortunately with this long term use there is an increased risk of irreversible vision loss due to retinal toxicity. In developed countries HCQ has largely replaced the use of CQ as it is found to be less toxic and more effective and with this the risk of retinopathy has also decreased but HCQ is not available to patients attending public clinics and hospitals in South Africa.[8]

HCQ retinal toxicity is much more apparent than previously documented. The prevalence in a recent study done on HCQ users in the United States which included 2361 patients using HCQ for a minimum of 5 years, showed that 177 (7.5%) patients developed retinal toxicity rising to almost 20% after 20 years.[1,3] Based on this data CQ/HCQ retinal toxicity is considered a significant health problem.[1]

In Nigeria, where the prevalence of malaria and malaria related deaths are high, CQ retinopathy is not uncommon. [9] This is escalated by the fact that many patients self-medicate with CQ as it is available as an over-the-counter drug. The mechanism of action of CQ and HCQ retinopathy is poorly understood. Most theories suggest that initial damage occurs to the photoreceptors in the retina and as the outer nuclear layer degenerates, this results in secondary disruption of the retinal pigment epithelium (RPE) .[4] This negatively impacts on the metabolism of the retinal cells and results in slow and toxic effects.[10] Presently there is uncertainty as to why the photoreceptors in the parafoveal area are most susceptible to the toxic effects of CQ/HCQ. [1]

In the initial stage of retinal toxicity most patients are asymptomatic and visual acuity is usually excellent until advanced stages of damage occur.[4, 10] With prolonged use of the drug, the area of functional damage increases to involve the retinal pigment epithelium and the retinopathy ultimately involves the foveal centre resulting in loss of vision.[4] Clinically, fundus findings may present late and is characterised by bilateral pigmentary macular changes, leading to the characteristic "bull's eye" maculopathy.[5]

Multiple screening techniques are available to diagnose early HCQ/CQ retinopathy. If toxicity is recognised early, prior to any RPE involvement, there is only mild and minimal progression after treatment is stopped allowing central vision to be preserved.[1] Some studies have shown that if the external limiting membrane is not affected when treatment is stopped, patients tend to have a good prognosis and it may be associated with regeneration of photoreceptor layer.[11,12,13] The optimal algorithm for HCQ and CQ toxicity screening using different methods is still being debated.[7] All available screening tests cannot be performed for every individual, as some screening tests may not be available and it will not be cost effective and practical to perform every test at every visit. It is important to mention that these drugs are highly beneficial in the treatment of certain diseases and that screening assists in helping patients continue use of this helpful drug for as long as possible.[4] A landmark clinical study, LUMINA, in the United States concluded that patients with SLE had an

increased survival rate when using HCQ.[1] Therefore effective screening is required which entails identifying risk factors for developing retinal toxicity and using appropriate screening tests to detect early retinal damage.

The American Academy of Ophthalmology (AAO) updated their recommendations for screening of HCQ and CQ in 2016 from the previous published guidelines in 2011.[4] These guidelines cover issues ranging from initial dosing methods, risk factors for developing retinopathy as well as the frequency and modalities of screening.[4]They show that the risk of retinal toxicity is dependent on multiple factors, the most important of which are daily dose by weight and duration of use. According to the new guidelines real weight is superior to ideal weight when calculating the appropriate dose. The recommended maximum daily dose of HCQ is <5.0mg/kg of real weight. Using these recommended doses, there is <1% risk of toxicity in the first 5 years of treatment, rising to 2% at 10 years and 4% after 20 years, which shows the impact that duration of use has on toxicity.[3,4] Other risk factors that have been identified include the presence of renal disease as well as pre-existing retinal and macular disease. [3, 4] Age and liver disease have been proposed as risk factors but no significant association has been made.[4] It is essential that ophthalmologists recognise patients who are more at risk of developing retinopathy and to ensure adequate screening tests are done at the appropriate times.

According to the new 2016 AAO guidelines a baseline examination should be done in the first year of starting treatment to identify pre-existing retinal/macula conditions and to obtain a baseline assessment of functional status and fundus appearance.[4] The previous 2011 guidelines included a slit lamp exam, 10-2 Humphrey visual field and a minimum of one of the following objective tests such as spectral domain optical coherence tomography(SD-OCT), fundus autofluorescence (FAF) or multifocal electroretinogram (mfERG) [11]; however in the updated 2016 guidelines it is not critical to obtain these additional tests such as visual fields and SD OCT at baseline unless abnormalities are present e.g. focal macular lesion, glaucoma.[4] Thereafter annual screening is conducted after the patient has had 5 years of drug exposure given the initial low risk of retinopathy; however if the patient has any risk factors such as a higher dose, renal disease or any underlying retinal pathology screening should begin sooner. The recommended screening tests at the annual visits include both automated visual fields and SD-OCT, as these tests are widely available.[4] According to the new

guidelines, unless the toxic changes are advanced and clinically obvious, at least 1 objective test should confirm subjective findings before toxicity is diagnosed.[4] The decision as to which tests to include in the 2016 guidelines were based on various studies previously conducted.

Multifocal ERG (mfERG) is considered the gold standard for detecting CQ and HCQ toxicity; however it is not widely available in most ophthalmology practices and hospitals and also requires specialised training to interpret and analyse the results.[7, 11] Multifocal ERG has characteristics of being both an objective test and a direct measure of retinal function. HCQ toxicity typically manifests on mfERG as a characteristic ring of depressed responses in the perifoveal regions of the macula.[7] Cukras et al in 2015 conducted a study to evaluate the findings of subjective and objective screening tests and to determine which tests were good alternatives to mfERG testing.[7] The SD-OCT retinal thickness, especially of the inner inferior subfield, and the visual field mean deviation (VFMD) obtained by Humphrey Visual Field testing correlated well with results from the mfERG. This study suggested that a combination of SD-OCT and Humphrey Visual Field 10-2 testing be used to screen patients with CQ toxicity.[7]

Visual field analysis is a good primary screening test and remains the most sensitive subjective screening test for CQ and HCQ retinal toxicity.[1] Central visual field testing using the 10-2 field pattern is very sensitive in reliable patients.[4] Marmor et al in 2013 looking at the value of red targets and pattern deviation plots concluded that red testing is more sensitive for early retinopathy but slightly less specific and consistent.[14] They concluded that either red or white fields should be acceptable for HCQ toxicity as long as the clinician is sensitive to the characteristic patterns of early parafoveal damage. The 2016 AAO guidelines recommend white SITA testing with pattern deviation plots.[4] The interpretation of visual fields may be challenging; defects can range from very subtle to prominent field loss.[1] Isolated points of reduction in sensitivity may be considered insignificant but they may also represent the earliest evidence of HCQ retinopathy. In these patients repeat visual field testing is necessary. Contiguous scotoma points identified in an annular zone between 2 and 8 degrees from fixation may more likely represent HCQ retinopathy. Parafoveal scotomata are typical of HCQ retinopathy.[1] According to Marmor et al, the site of earliest and most severe damage is the inferotemporal parafoveal region represented by superonasal field defects.[6] A

recent study has recommended the use of wider test patterns(30-2 or 24-2) in the Asian population as toxicity often presents beyond the macula in these patients.[15] Any central scotoma in the 24-2 or 30-2 field testing should signal a red flag and be further investigated with a 10-2 visual field which has a higher resolution within the macula.[1] It must be remembered that visual fields is a subjective test and results depend on the reliability of the patient and the interpretation of the examiner; the threshold for determining toxicity is not well established.[7] Having a very low threshold for determining retinal toxicity may allow for premature cessation of the drug whilst having a high threshold may allow for toxicity to be missed.[7] Therefore any uncertain or unclear visual field changes should be repeated (to demonstrate reliability) or evaluated with other objective tests such as an mfERG, SD-OCT and FAF.[4] The visual field mean deviation (VFMD) is also used to detect early retinal toxicity. Cukras et al found that VFMD correlated well with mfERG abnormalities in patients with HCQ toxicity.[7]

SD-OCT allows for both qualitative and quantitative measurement of retinal toxicity. It is a widely available objective screening test which looks at any structural damage that occurs in the macula in patients at risk of CQ/HCQ toxicity.[1]

Quantitatively one can look at retinal thickness in the macula by looking at macular subfields. Cukras et al found a significantly thinner mean OCT retinal thickness in patients with retinal toxicity.[7] The greatest difference in retinal thickness was observed in the inner subfield corresponding to the area 1mm from the foveal centre.[7] Marmor showed a consistent 360 ring of parafoveal thinning on the subfield thickness maps which occurred at a very early stage of toxicity, even when visual fields only showed small scotomatas.[6] This study also showed that the quadrant of earliest outer retinal damage generally involved the inferior retina (inner inferior subfield) which correlated well with the presence of toxicity.[6, 7]

Qualitative analysis of HCQ retinopathy on SD-OCT involves looking for parafoveal abnormalities of the outer segment, especially thinning or loss of the photoreceptor layer, outer nuclear layer and/or ellipsoid zone (inner segment/outer segment junction) and RPE.[1] Initial damage can be recognised as a marked localised interruption of the outer segment structures.[4] Chen et al described the perifoveal abnormalities seen on SD-OCT as a "flying saucer" sign.[5] These findings include preservation of the outer retinal structures in the central fovea, perifoveal loss of the photoreceptor IS/OS

junction and perifoveal outer retinal thinning, posterior or "sinkhole" displacement of the central foveal inner retinal structures toward the RPE and variable loss of the normal foveal depression.[5] Asian patients may manifest extramacular pattern of disease and therefore require wider field SD-OCT scans, possibly across the vascular arcade region.[1,4,15] In Cukras et al's study, 84% of affected patients had ellipsoid zone interruption which is highly specific for HCQ toxicity; however this abnormal sign lacked sensitivity.[7] A normal SD-OCT may also be helpful in excluding true HCQ toxicity especially when other imaging modalities are inconclusive.[5] If very early changes appear to be questionable, the test can be performed again or other tests can be done to confirm or rule out any abnormalities. SD-OCT may not be as sensitive as visual field or mfERG but it is definitive when regional thinning is present in a specific pattern and may play a complementary role to other screening modalities.[4,5]

A study done by Marmor et al in 2014 which looked at the disparity between SD-OCT and visual fields in CQ and HCQ toxicity showed that 10% of toxic cases had clear visual field loss with normal SD-OCT.[16] Ninety percent of toxic cases did not show any disparity with some cases having subtle visual field changes while SD-OCT was clearly abnormal; subfield thickness maps showed obvious parafoveal thinning even if visual fields had very subtle changes.[16] This emphasises that SD-OCT is a good objective screening tool and also highlights the importance of including visual fields in screening. The use of both these tests provides a more comprehensive and reliable method of detecting and confirming retinal toxicity. Any inconclusive findings seen on one screening test, should lower the examiners threshold for suspecting toxic retinopathy and allow for repeat testing or additional testing. The development of toxicity is slow enough to allow for repeat testing if suspicion is small. [4,16]

Another useful additional screening test that is included in the AAO 2016 guidelines is **fundus autofluorescence (FAF)**.[4] This is an objective structural test that reveals extramacular or parafoveal photoreceptor damage. This can be recognised as an area of increased autofluorescence which tends to occur before thinning is seen on SD-OCT.[4] As RPE loss or degeneration occurs, a dark (mottled) area of decreased parafoveal autofluorescence can be seen.[1,4] Currently there is no standardised grading system for the interpretation of FAF abnormalities; therefore it lacks sensitivity and requires subjective interpretation.[8] Wide field autofluorescence is required to detect extramacular disease in Asian patients with suspected HCQ retinopathy.[15] FAF

usually shows moderate to severe changes of retinal toxicity and can provide a sensitive indicator of RPE degeneration as toxicity progresses.[6] These changes are visible as spots or dark areas surrounding the fovea.[6]

A newer screening test which is non-invasive, sensitive and reproducible is **microperimetry**. This is a subjective functional test and may provide another option for assessing retinal sensitivity in patients on HCQ.[17] Exact correlation between retinal pathology and functional alteration can be obtained.[18] A study by Jivrajka et al, found that patients using HCQ therapy (>5years) with no evidence of toxicity on the recommended screening tests such as SD-OCT, 10-2 visual fields and FAF showed reduced retinal sensitivity in the central visual field as assessed by microperimetry.[17] Microperimetry is an accurate tool for detecting early and subtle macular damage and should be considered as part of screening algorithms in future guidelines.[18] Unfortunately, like mfERG, this test is not widely available in many ophthalmology departments, especially in the public sector.

Fundus photography and examination, amsler grid, fluorescein angiography and colour vision testing are not part of the 2016 AAO screening guidelines.[4]

Very limited data on CQ retinal toxicity and use of screening tests are available in South Africa; there is no data on HCQ retinal toxicity since HCQ is not available in South Africa. One study conducted in Tygerberg hospital in Cape Town looked at the sensitivity of SD-OCT and fundus autofluorescence as screening tests.[8] This study concluded that patients using CQ for greater than 5 years showed no abnormalities on SD-OCT and FAF that required treatment cessation. They concluded that perhaps the 5 year cut off to defer annual screening (according to the AAO guidelines) is premature.[8]

A study done by Melles et al in 2015 found that HCQ retinopathy does not always develop in a parafoveal (bull's eye) pattern and that some patients can present in a pericentral (typically near the arcades) pattern of damage. [15] This pericentral pattern of retinal toxicity in Asian patients raises awareness that mixed or pericentral patterns of damage may not be uncommon in a racially diverse population.[15] The parafoveal pattern of damage is a specific clinical finding, especially in a predominantly white population but this study emphasizes that screening should be altered to include detection of both parafoveal and pericentral damage in different racial groups.[15]

Therefore in addition to comparing the different screening tests, this study aims to determine the patterns of retinal toxicity in our population.

3. Study aim

The main aim of this study is to compare Central Visual Fields, Spectral Domain Optical Coherence Tomography (SD-OCT) and Fundus Autofluorescence (FAF) and to determine which of these screening tests best detects early chloroquine retinopathy. A secondary aim is to determine the patterns of retinal toxicity.

4. Study objectives

- PRIMARY objective
  To compare Central Visual Fields, Spectral Domain Optical Coherence Tomography (SD-OCT) and Fundus Autofluorescence (FAF) in black African patients on chloroquine (CQ) presenting to the Rheumatology Department at Chris Hani Baraghwanath Academic Hospital, to determine which of these tests can be best used for screening for early chloroquine retinopathy.
- SECONDARY objective
  To determine the patterns of chloroquine retinal toxicity in black African patients on chloroquine presenting to the Rheumatology Department at Chris Hani Baraghwanath Academic Hospital. Central Visual Fields (10-2 and 30-2), Spectral Domain Optical Coherence Tomography (SD-OCT) and Fundus Autofluorescence (FAF) will be performed to detect changes in the parafoveal and/or pericentral regions.

5. Study methods

5.1 Study Design and Study site

A prospective, cross sectional study of patients on chloroquine (CQ) presenting to the Rheumatology Department at Chris Hani Baragwanath Academic Hospital.

5.2 Inclusion criteria

- All patients taking chloroquine for > 3 years.

- Patients who have given informed consent.

5.3 Exclusion criteria

- Patients with any other retinal pathology that may affect interpretation of results.
- Patients in whom screening tests cannot be done because of poor visibility of the retina.

5.4 Materials, equipment and facilities

- Patients on chloroquine will be recruited from the Rheumatology department at Chris Hani Baraghwanath Academic Hospital.
- Screening using the Humphrey Visual Field, Spectral Domain OCT (SD-OCT) and fundus autofluorescence (FAF) and will be conducted at the Ophthalmology Department of Chris Hani Baraghwanath Academic Hospital (St John Eye Hospital).

5.5 Data collection

- Information collected from the patients will include the following :
  - Age
  - Gender
  - Race
  - Weight
  - Height
  - Indications for chloroquine use
  - Medical comorbidities
  - Other drug history
  - Chloroquine Dose
  - Duration of chloroquine use
  - Previous screening tests
  - Any visual symptoms
  - Past ocular history
- Examination including
  - Best corrected visual acuity
  - Basic slit lamp examination including dilated fundus examination
- Screening tests

- Perimetric assessments using the Humphrey Visual Field Analyser (10-2 and 30-2) including visual field mean deviation values (VFMD) will be performed (represents deviation from age matched normal eyes).
    - Abnormal results include:
        - Pattern deviation plots –
            - Parafoveal pattern: points of reduction in sensitivity usually between 2-8° from fixation, either isolated subtle points (may be insignificant or indicate early CQ/HCQ retinopathy) or contiguous scotoma points. Parafoveal scotomata are typical of CQ/HCQ toxicity especially in the superonasal field.
            - Pericentric pattern: points of reduction in sensitivity localised 8° or more from the centre of the fovea.
        - Visual field mean deviation – represents deviation from age matched normal eyes, normally between 0dB to -2dB. Optimal cut-point as determined by Cukras et al for toxicity of -3.30dB had 100% sensitivity and 88% specificity.[7]
- Fundus Autofluorescence Images using the Spectralis SD-OCT (Heidelberg engineering)
    - Abnormal results include: either areas of increased autofluorescence (early changes indicating RPE regions of anomalous metabolism and lipofuscin deposition) or areas of decreased autofluorescence (late changes which represent RPE atrophy)
- Retinal imaging using the Spectralis SD-OCT (Heidelberg engineering) looking at retinal thickness as well as abnormalities in the ellipsoid zone.
    - Abnormal results include:
        - Quantitatively looking at retinal thickness (macular subfields) - chloroquine toxicity showed a significantly thinner mean retinal thickness in the inner subfield (corresponding to 1mm from the fovea). The outer subfield corresponds to 3mm/10° from the fovea and can help in looking at a more pericentric pattern of toxicity. Optimal cut points determined by Cukras et al included [7]
            - Centre – 178.40µm

- Inner superior – 292.93µm
- Inner temporal – 269.80µm
- Inner inferior – 278.50µm (Most sensitive 100%, 88% specific)
- Inner nasal – 295.06µm
- Outer superior- 252.59µm
- Outer temporal- 205.82µm
- Outer inferior- 236.58µm
- Outer nasal- 261.69µm
- Distribution can be compared to normative data in relation to age to determine if there is a decrease in thickness

▪ Qualitatively looking for disruption in the photoreceptor ellipsoid zone

All the information gathered will be collected on a data capture sheet.

5.6 Study procedure

Patients on chloroquine treatment in the Rheumatology Department at Chris Hani Baraghwanath Academic Hospital will be asked to participate in the study. Patients will be informed about the study. An information sheet outlining the study will be given to patients. **(Appendix A).**Patients willing to participate in the study will be asked to fill in and sign a consent form. **(Appendix B)**

Patient information, baseline examination and results of screening tests (visual fields, SD-OCT and FAF) will be entered into a data capture sheet **(Appendix C).**

5.7 Sample size

45 patients on chloroquine attending the Rheumatology Department at Chris Hani Baraghwanath Academic Hospital.

Sample size estimation is based on the key research question, in this case the estimation of proportions (e.g. the proportion of patients with abnormal SD-OCT pattern). Based on worst-case (for sample size) estimates of 50% of abnormal results, 15% precision and the 95% confidence level, a sample size of 45 would be required.

Sample size for prevalence was determined using the formula [19]:

$$n = \frac{Z^2 P(1-P)}{d^2}$$

Where n = sample size,

Z = Z-statistic for the chosen level of confidence,

P = expected prevalence or proportion

d = precision

5.8 Data Analysis

All data collected will be entered onto an Excel spreadsheet.

VF, SD-OCT and FAF qualitative findings will each be categorised as 1=abnormal; 0=normal.

Descriptive analysis of the data will be carried out as follows: Categorical variables will be summarised by frequency and percentage tabulation, and illustrated by means of bar charts. Continuous variables will be summarised by the mean, standard deviation, median and interquartile range, and their distribution illustrated by means of histograms.

Interrater reliability will be assessed for categorical findings (presence/absence of abnormality for each of the three techniques) using Cohen's kappa, and for continuous measurements (VFMD from normal and SD-OCT retinal thickness) using the intraclass correlation coefficient (ICC).

The abnormal/normal findings from the three techniques will be cross-tabulated.

For each technique, the CQ daily dosage will be compared between patients with abnormal and normal findings, using the independent samples t-test.

The association between VF deviation from normal and the VF normal/abnormal grouping, as well as between the retinal thickness and the SD-OCT normal/abnormal grouping, will be determined by the independent samples t-test.

Finally, the association between CQ daily dosage and each of VF deviation from normal and retinal thickness will be determined by Pearson's correlation coefficient.

Data analysis will be carried out using STATISTICA version 13.2. The 5% significance level will be used.

5.9 Predicted Timeline

The study will commence after the protocol has been approved by the ethics committee and post graduate committee of the University of Witwatersrand

Timeline *pending approval of proposal and ethics committee permission*	
October 2016-July 2017	Literature review Writing of protocol Review and correction of protocol by supervisor
August 2017	Protocol and ethics submission
September 2017	Assessment Committee meeting
October 2017	Data collection
November 2017	Data collection
December 2017	Data collection
January 2018	Data collection
February 2018	Data analysis and write up
March-April 2018	Write up
May 2018	Submit for marking

6. Ethics

- Application for ethics approval from the Human Research Ethics Committee from the University of Witwatersrand will be submitted prior to any data collection being done.
- A written letter from the Head of Rheumatology at Chris Hani Baraghwanath Academic Hospital will be obtained to recruit patients from their department.
- A written letter from the CEO of Chris Hani Baraghwanath will be obtained to conduct the study at the hospital.
- A letter from the head of Ophthalmology will be obtained to allow permission to conduct the study at St Johns Eye Hospital.

7. Funding

- Chloroquine screening is routinely done at the Ophthalmology Department of Chris Hani Baraghwanath Hospital (St Johns Eye Hospital): therefore this study will utilise existing equipment in the department.
- The cost of paper, printer ink and the use of a statistician will be funded by the principal investigator.

8. Possible limitations

- Visual fields is a subjective test and depends on the reliability and good visual acuity of the patient.
- Interpretation of test results can also be subjective and depend on the examiners interpretation of the results
- The study is conducted on the assumption that patients are compliant with their treatment.

9. Reporting plans

- Write up as an MMED research report once data collection and analysis has been completed
- Publish an article in a scientific journal.
- Presentation of study findings at the Ophthalmological Society of South Africa (OSSA) congress.

10. Authorship

- The study will be conducted by the principal researcher Dr A. Moodley (Registrar at the Ophthalmology Department at Chris Hani Baraghwanath Academic Hospital (St Johns Eye Hospital)
- Supervisor : Dr H.D Alli (Consultant at the Ophthalmology Department at Chris Hani Baraghwanath Academic Hospital (St Johns Eye Hospital)

11. References

1. Yusuf IH, Sharma S, Luqmani R, Downes SM. Hydroxychloroquine retinopathy. *Eye*. 2017;doi:10.1038/eye.2016.298.
2. Shulman S, Wollman J, Brikman S, Padova H, Elkayam O, Paran D. Implementation of recommendations for the screening of hydroxychloroquine retinopathy: poor adherence of rheumatologists and ophthalmologists. *Lupus*. 2017;26:277-281.
3. Melles RB, Marmor MF. The Risk of Toxic Retinopathy in Patients on Long-term Hydroxychloroquine Therapy. *JAMA Ophthalmol*.2014;132(12):1453-1460.
4. Marmor MF, Kellner U, Lai TY, Melles RB, Mieler WF. Recommendations on Screening for Chloroquine and Hydroxychloroquine Retinopathy (2016 Revision). *Ophthalmology*. 2016;123: 1386-1394.
5. Chen E, Brown DM, Benz MS, Fish RH, Wong TP, Kim RY, et al. Spectral domain optical coherence tomography as an effective screening test for hydroxychloroquine retinopathy (the "flying saucer" sign). *Clin Ophthalmol*. 2010;4:1151-1158.
6. Marmor MF. Comparison of Screening Procedures in Hydroxychloroquine Toxicity. *Arch Opthalmol*.2012;130(4):461-469.
7. Cukras C, Huynh N, Vitale S, Wong WT, Ferris FL, Sieving PA. Subjective and Objective Screening Tests for Hydroxychloroquine Toxicity. *Ophthalmology*. 2015;122:356-366.
8. Goodman MB, Ziskind A. Fundus auto fluorescence and spectral domain ocular coherence tomography in the early detection of chloroquine retinopathy. *Afr Vision Eye Health*.2015;74(1):1-5.
9. Oluleye TS, Babalola Y, Ijaduola M. Chloroquine retinopathy: pattern of presentation in Ibadan, Sub-Sahara Africa. *Eye*. 2016;30:64-67.
10. Geamanu A, Popa-Cherecheanu A, Marinescu B, Geamanu CD, Voinea LM. Retinal Toxicity associated with chronic exposure to hydroxychloroquine and its ocular screening. Review. *Journal Of Medicine and Life*.2014;7:322-326
11. Weinlander E, Ringeisen AL, Mititelu M. Screening and Diagnosis of Hydroxychloroquine Toxicity:Advances and Controversies. *J Clin Exp Ophthalmol*.2016;7(1)
12. Mititelu M, Wong B,Brenner M, Bryar PJ, Jampol LM, Fawzi AA. Progression of Hydroxychloroquine Toxic Effects After Drug Therapy Cessation. *JAMA Ophthalmol*.2013;131(9):1187-1197.

13. Marmor MF, Hu J. Effect of Disease Stage on Progression of Hydroxychloroquine Retinopathy. *JAMA Opthalmol*.2014;132(9):1105-1112.
14. Marmor MF, Chien FY, Johnson MW. Value of Red Targets and Pattern Deviation Plots in Visual Field Screening for Hydroxychloroquine Retinopathy. *JAMA Ophthalmol*.2013;131(4):476-480.
15. Melles RB, Marmor MF. Pericentral Retinopathy and Racial Differences in Hydroxychloroquine Toxicity. *Ophthalmology*.2015;122:110-116.
16. Marmor MF, Melles RB. Disparity between Visual Fields and Optical Coherence Tomography in Hydroxychloroquine Retinopathy.*Ophthalmology*.2014; 121:1257-1262
17. Jivrajka RV, Genead MA, McAnany JJ, Chow CC, Mieler WF. Microperimetric sensitivity in patients on hydroxychloroquine (Plaquenil) therapy. *Eye (Lond)*.2013;27:1044-1052
18. Martínez-Costa L, Ibañez MV, Murcia-Bello C, Epifanio I, Verdejo-Gimeno C, Beltran-Catalan E, et al. Use of microperimetry to evaluate hydroxychloroquine and chloroquine retinal toxicity. *Can J Ophthalmol*.2013;48:400-405.
19. Daniel WW . Biostatistics: A Foundation for Analysis in the Health Sciences. 10th edition. New York: John Wiley & Sons, Chapter 6, p191 (2013)

Appendix A

Information sheet

Translation of information to your language of preference may be carried out by nursing staff at St. John Eye Hospital

Chloroquine retinal toxicity screening in black African patients: Comparing Central Visual Fields, Spectral Domain Optical Coherence Tomography (SD-OCT) and Fundus Autofluorescence (FAF).

Good day, my name is Dr Ashvira Moodley and I am specialising to become an eye doctor in the Department of Ophthalmology at the University of Witwatersrand / St John Eye Hospital-Chris Hani Baragwanath Hospital. As part of my training I am required to do research in this field. Research is a process where we try and learn more about a question we don't have an answer to.

Chloroquine is a drug that is widely used for many medical conditions. There are very few systemic adverse effects which require us to stop treatment but prolonged use of the drug has been shown to cause severe irreversible and potentially blinding retinal damage in eyes of certain patients. It has however been shown that central vision can be preserved if damage is recognised early. There are various screening tests which may be conducted to look at early retinal damage and determine when to stop treatment. In this study, I will screen patients on chloroquine using three screening tests to look for early retinal damage. The results of these tests will be compared to see which test or combination of tests will best be able to pick up early retinal damage. This study will also help to find out how soon after starting chloroquine should patients be screened and how often thereafter.

This is an invitation to participate in my study that will be carried out at St John Eye Hospital. Participation is voluntary i.e. you can choose to take part or not to take part in the study. Choosing not to take part will not have any consequence or impact on your future health care at St John Eye Hospital-Chris Hani Baragwanath Hospital i.e you will still be treated at this hospital.

The study will involve a brief questionnaire requiring some personal information about you such as why you are taking chloroquine including the dose and duration, any medical or ocular comorbidities and if you have had any screening tests done

previously. I will conduct a baseline vision and slit lamp examination. We will perform three of the screening tests we have available at our facility already. These non-invasive tests are routinely performed at St Johns Eye Hospital and do not cause any harm to patients. You will only be required to present for one hospital visit with no need for further follow up for the purposes of this study.

If you take part in the study, there is no direct benefit to you except being screened for early retinal damage. If early retinal damage is detected I will advise your clinician to stop treatment and consider an alternative drug. The results of the study will benefit patients in the future in terms of which screening test or tests is best; and how soon and how often should be screening be carried out.

During and after the study, your identity will remain confidential. This means that your personal information will not be shared. You will be allocated a study number under which all your demographics, examination findings and findings from the screening tests will be collected. This information, without your name, will be seen by me, my supervisor, the statistician and the medical fraternity. If at any point you choose to withdraw from this study, you may do so immediately and without reason. Your withdrawal will not have any consequence or impact on your future health care at St John Eye Hospital-Chris Hani Baragwanath Hospital i.e you will still be treated at this hospital.

Should you have any queries please feel free to contact me or any of the other people listed below.

Contact details of researcher:

Dr Ashvira Moodley : 0718963348

Contact details of supervisor:

Dr H. D. Alli : 0833078152

Contact details of HREC administrator and chair:

Thank you for taking the time to read this information sheet

Appendix B

Informed consent Form

I, _____, the undersigned hereby consent to voluntarily participate in this study. Dr Ashvira Moodley has clearly informed me and pointed out the purposes of the research she will be conducting. I have read and understand the information sheet provided to me, which clearly explains the information I am required to provide and the procedure.

- I am aware that I do have the right not to participate or to discontinue participation at any time without prejudicing any treatment that is required for existing or future medical conditions.
- Patient confidentiality will be maintained at all times meaning that information may be used from my file as long as my name is not mentioned.
- The documents completed by Dr Moodley are the only records that will be used for data collection.
- If I have any queries, they will be directed accordingly.

ENROLLED PATIENT

_____ _____ _____

Full name and Surname Date Signature

STUDY DOCTOR

I, Dr Ashvira Moodley hereby confirm that I have fully informed the participating patient of the nature and purposes of my study.

_____ _____ _____

Full name and Surname Date Signature

WITNESS

_____ _____ _____

Full name and Surname Date Signature

Appendix C

Data Capture Sheet

Study Nr: _____

Demographics ***Age:*** ***Gender:*** Male ☐ Female ☐ ***Ethnicity:*** African ☐ Asian ☐ Coloured ☐ Caucasian ☐
Weight: _____kg ***Height:***_____cm
Medical Comorbidities:
Other drug history:
Chloroquine use ***Indications for Chloroquine use:*** ***Chloroquine dose:*** ***Duration of chloroquine use:***
Previous Chloroquine screening tests:
Ocular history ***Visual symptoms:***

Past ocular history:

Ocular exam:

BCVA

Anterior segment

Pupil

Lens

GAT

Fundus

Screening Tests:

- ***Humphrey Visual Field*: 10-2** ☐ **30-2** ☐

10-2	Right Eye	Left eye
Fixation Losses		
False positive Error		
VF mean deviation		
Pattern deviation		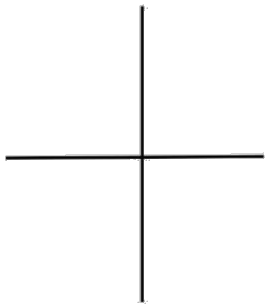

30-2	Right Eye	Left eye
Fixation Losses		
False positive Error		
VF mean deviation		
Pattern deviation (10-2)	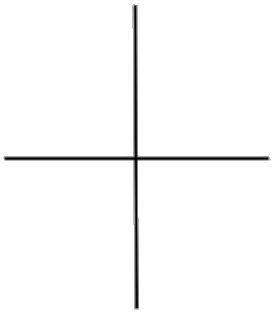	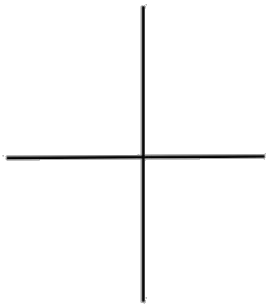

- ***SD-OCT:***

Macular Subfields (retinal thickness)	
Right eye	Left eye
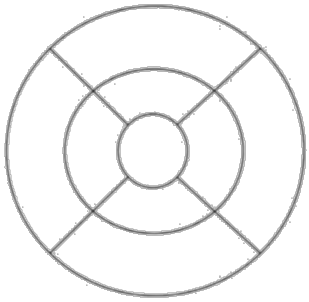	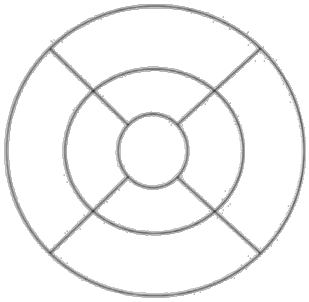

Disruption in ellipsoid zone (Inner segment-outer segment junction)	
Right Eye	**Left Eye**

- ***Fundus Autofluorescense (FAF)***

Right Eye	Left Eye

Appendix B: Ethics clearance certificate

UNIVERSITY OF THE WITWATERSRAND, JOHANNESBURG

R14/49 Dr Ashvira Moodley

HUMAN RESEARCH ETHICS COMMITTEE (MEDICAL)

CLEARANCE CERTIFICATE NO. M171161

NAME: (Principal Investigator)	Dr Ashvira Moodley
DEPARTMENT:	Ophthalmology - Department of Neurosciences Chris Hani Baragwanath Academic Hospital St Johns Eye Hospital
PROJECT TITLE:	Chloroquine Retinal Toxicity Screening in Black African Patients: Comparing Central Visual Fields, Spectral Domain Optical Coherence Tomography (SD-OCT) and Fundus Autofluorescence (FAF)
DATE CONSIDERED:	24/11/2017
DECISION:	Approved unconditionally
CONDITIONS:	
SUPERVISOR:	Dr Hassan Dawood Alli
APPROVED BY:	Professor CB Penny, Chairperson, HREC (Medical)
DATE OF APPROVAL:	15/02/2018

This clearance certificate is valid for 5 years from date of approval. Extension may be applied for.

DECLARATION OF INVESTIGATORS

To be completed in duplicate and **ONE COPY** returned to the Research Office Secretary in Room 301, Third Floor, Faculty of Health Sciences, Phillip Tobias Building, 29 Princess of Wales Terrace, Parktown, 2193, University of the Witwatersrand. I/we fully understand the conditions under which I am/we are authorized to carry out the above-mentioned research and I/we undertake to ensure compliance with these conditions. Should any departure be contemplated, from the research protocol as approved, I/we undertake to resubmit the application to the Committee. **I agree to submit a yearly progress report**. The date for annual re-certification will be one year after the date of convened meeting where the study was initially reviewed. In this case, the study was initially reviewed in November and will therefore be due in the month of November each year. Unreported changes to the application may invalidate the clearance given by the HREC (Medical).

Principal Investigator Signature Date

PLEASE QUOTE THE PROTOCOL NUMBER IN ALL ENQUIRIES

Appendix C: Permission letters

Consent to Allow for Collection of Data for the Purposes of Research

To whom it may concern,

This document hereby serves as permission for Dr. Ashvira Moodley, student number 0603375R, to collect the relevant data needed to complete the research intended under the title:

Chloroquine retinal toxicity screening in black African patients: Comparing Central Visual Fields, Spectral Domain Optical Coherence Tomography (SD-OCT) and Fundus Autofluorescence (FAF)

Data will be collected prospectively in both the Ophthalmology department as well as the Rheumatology department at Chris Hani Baragwanath Academic Hospital (CHBAH).

Collection methods will be as per the submitted protocol and information will remain strictly confidential to the author. All data collection will be performed after approval by the Human Research Ethics Committee of the University of Witwatersrand.

The intended research will not interfere with the daily running of the hospital.

Head of Department Ophthalmology CHBAH

Name I MAHE

Date 19/10/2017

Signature

Consent to Allow for Collection of Data for the Purposes of Research

To whom it may concern,

This document hereby serves as permission for Dr. Ashvira Moodley, student number 0603375R, to collect the relevant data needed to complete the research intended under the title:

Chloroquine retinal toxicity screening in black African patients: Comparing Central Visual Fields, Spectral Domain Optical Coherence Tomography (SD-OCT) and Fundus Autofluorescence (FAF)

Data will be collected prospectively in both the Ophthalmology department as well as the Rheumatology department at Chris Hani Baragwanath Academic Hospital (CHBAH).

Collection methods will be as per the submitted protocol and information will remain strictly confidential to the author. All data collection will be performed after approval by the Human Research Ethics Committee of the University of Witwatersrand.

The intended research will not interfere with the daily running of the hospital.

Head of Department Rheumatology CHBAH

Name ____Dr Govind____

Date __1/02/2018__

Signature_____

GAUTENG PROVINCE
HEALTH
REPUBLIC OF SOUTH AFRICA

MEDICAL ADVISORY COMMITTEE
CHRIS HANI BARAGWANATH ACADEMIC HOSPITAL

PERMISSION TO CONDUCT RESEARCH

Date: 20 October 2017

TITLE OF PROJECT: Chloroquine retinal toxicity screening in black African patients: comparing central visual fields, spectral domain optical coherence tomography (SD-OCT) and fundus autofluorescence (FAF)

UNIVERSITY: Witwatersrand

Principal Investigator: A Moodley

Department: Ophthalmology

Supervisor (If relevant): HD Alli

Permission Head Department (where research conducted): Yes

Date of start of proposed study: Oct 2017
Date of completion of data collection: Dec 2019

The Medical Advisory Committee recommends that the said research be conducted at Chris Hani Baragwanath Hospital. The CEO /management of Chris Hani Baragwanath Hospital is accordingly informed and the study is subject to:-

- Permission having been granted by the Human Research Ethics Committee of the University of the Witwatersrand.
- the Hospital will not incur extra costs as a result of the research being conducted on its patients within the hospital
- the MAC will be informed of any serious adverse events as soon as they occur
- permission is granted for the duration of the Ethics Committee approval.

.....
Recommended
(On behalf of the MAC)
Date: 20 October 2017

.....
Approved/Not Approved
Hospital Management
Date: 30/10/17

Scanned with CamScanner

Appendix D: Turnitin Report

DEPARTMENT OF NEUROSCIENCES

Neurology, Neurological Surgery, Ophthalmology, Otorhinolaryngology, Psychiatry

School of Clinical Medicine, Faculty of Health Sciences,
7 York Road, Johannesburg 2193, South Africa
Tel: +27 11 717-2774 · Fax: +27 11 717 2775

Plagiarism declaration for written work

I ….Ashvira Moodley…. as a postgraduate student registered for a MMed at the University of the Witwatersrand declare the following:

- I am aware that plagiarism is the use of someone else's work without their permission and or without acknowledging the original source.
- I am aware plagiarism is wrong.
- I confirm that this written work is my own work except where I have stated otherwise.
- I have followed the required conventions in referencing the thoughts and ideas of others.
- I understand that the University of the Witwatersrand may take disciplinary action against me if there is a belief that this is not my own unaided work or if I have failed to acknowledge the ideas or writing of others.

Signature of student ……Moodley……..

Signature of supervisor ……

Date 16 December 2019 ……

0603375r:mmed_turn_it_in_1.docx

ORIGINALITY REPORT

16%	6%	14%	%
SIMILARITY INDEX	INTERNET SOURCES	PUBLICATIONS	STUDENT PAPERS