

https://dspace.org/

A Retrospective Analysis of the Clinicopathological Features of Patients with Tuberculous Mastitis A Single Institutions Experience

Nine Olmesdahl; Carolina Nel; Aylwyn Mannell; L Fatman

https://hdl.handle.net/10539/39747
WOS

Downloaded from a DSpace repository. https://dspace.org/

Acta Cytologica

Fine Needle Aspiration

Acta Cytologica 2023;67:573–582
DOI: 10.1159/000534193

Received: August 11, 2023
Accepted: September 17, 2023
Published online: September 20, 2023

A Retrospective Analysis of the Clinicopathological Features of Patients with Tuberculous Mastitis: A Single Institution's Experience

Nine-Paula Olmesdahl[a] Carolina Nel[b] Aylwyn Mannell[c] Luvo Fatman[d]

[a]Registrar, Anatomical Pathology, Department of Anatomical Pathology, Faculty of Health Sciences, University of the Witwatersrand, and National Health Laboratory Services (NHLS), Johannesburg, South Africa; [b]Consultant Anatomical Pathologist, Department of Anatomical Pathology, Faculty of Health Sciences, University of the Witwatersrand, and National Health Laboratory Services (NHLS), Johannesburg, South Africa; [c]Consultant Surgeon, Department of Surgery, Faculty of Health Sciences, University of the Witwatersrand, Johannesburg, South Africa; [d]Medical Officer, Department of Cytology, National Health Laboratory Services (NHLS), Johannesburg, South Africa

Keywords
Tuberculous mastitis · Tuberculosis · South Africa

Abstract
Introduction: Tuberculosis remains a global health burden, especially in low- and middle-income countries. Breast tuberculosis is a rare disease with minimal research available. This disease produces a diagnostic challenge as the clinical presentation is variable, and diagnosis often requires additional investigations. This study was undertaken to determine the efficacy of cytology and histology, together with ancillary studies, in diagnosing tuberculous mastitis. ***Methods:*** This retrospective study was conducted in a Johannesburg Hospital over 5 years. Thirty-two patients with confirmed tuberculous mastitis were included. The patients were considered positive for tuberculous mastitis if histological or cytological findings were confirmed with either a positive tuberculosis culture, Ziehl-Neelsen stain, or polymerase chain reaction examination/GeneXpert. ***Results:*** This case series comprises 3 males and 29 females with a mean age of 35.66. A breast mass was the most common presentation. Over these 5 years, more biopsies were performed on inflammatory breast lesions than fine needle aspirations. There was a higher confirmation rate for cytology diagnoses compared to histology diagnoses. ***Conclusion:*** This study supports using fine needle aspiration combined with GeneXpert as the primary diagnostic modality in diagnosing tuberculous mastitis. This test combination is advantageous in resource- and financially constrained environments as it is relatively simple to perform, cost-effective, and has a rapid turnaround time. © 2023 S. Karger AG, Basel

Introduction

Tuberculosis (TB) is the 13th leading cause of global mortality [1]. The current rise in global population and increasing urbanisation further increase the risk of spreading TB and other communicable diseases [2]. Over 90% of TB cases are reported as occurring in developing countries [3]. According to the World Health Organisation's (WHO) Tuberculosis Report, the incidence of TB is higher than ever before in global history (10.4 million) [4].

Correspondence to:
Nine-Paula Olmesdahl, npolmesdahl@gmail.com

karger@karger.com
www.karger.com/acy

© 2023 S. Karger AG, Basel

Karger

Downloaded from http://karger.com/acy/article-pdf/67/6/573/4062920/000534193.pdf by Università Campus Bio-medico di Roma user on 06 February 2024

South Africa is a low- and middle-income country (LMIC) with one of the most significant burdens of TB in the world [5]. In 2019, 360,000 cases of TB were reported, with the highest mortality rates seen in vulnerable populations with poor socio-economic factors. Fifty-eight per cent of these individuals had human immunodeficiency virus (HIV). South Africa also has one of the largest HIV burdens in the world, especially among young women, further complicating the prevalence of TB [6].

Extrapulmonary tuberculosis (EPTB) accounts for 10–15% of TB cases globally, results which are at least paralleled in South Africa [4]. In 2019, 16% of newly reported TB cases were EPTB; in HIV-positive populations, this number was up to 50% [7]. In 2016, the prevalence of PTB in South Africa was estimated at 438/100,000 population. There were 244,053 TB cases notified, of which 135,000 (59%) were known to be HIV-co-infected. EPTB accounted for approximately 10% of the cases [8]. The varied and complex presentation of EPTB makes its diagnosis challenging for the clinician and the pathologist [8, 9]. Therefore, diagnosing EPTB is more time-consuming and costly than pulmonary tuberculosis, leading to delayed treatment [10]. Tuberculous mastitis (TBm) is no exception to this [3].

TBm is an uncommon diagnosis. The highest incidence of TBm occurs in developing countries, such as India, where the reported incidence of TBm varies between 0.64% and 3.59% of patients with TB [3, 11]. Conversely, the incidence of TBm in first-world countries is lower and only represents 0.1% of breast lesions examined histologically [12]. A literature review found no studies have documented the histopathological findings in the context of HIV co-infection in Sub-Saharan Africa, hence the rationale for this study.

Clinical and radiological examinations alone often fail to differentiate between breast carcinoma and TBm. The diagnosis of TBm is challenging and requires a high index of suspicion in conjunction with radiological, microbiological, and histopathological investigations [13]. Most patients presenting with TBm will either present with a mass or an abscess, with or without skin changes such as erythema, thickening, or a sinus tract [11].

Additional investigations are often required for the diagnosis of TBm. Ziehl-Neelsen (ZN) staining is widely used, but its sensitivity and specificity are relatively low compared to GeneXpert (GXP) and culture [14]. GXP offers a rapid and accurate diagnosis, particularly for drug-resistant TB, with high sensitivity and specificity. However, culture remains indispensable as the gold standard for TB diagnosis, offering the highest sensitivity and specificity despite its longer turnaround time [15]. Given the high prevalence of mycobacterial infection in South Africa and the challenges encountered in diagnosing TBm, this study was undertaken to highlight the cytologic and histologic features of TBm and thus improve diagnosis.

Materials and Methods

This was a retrospective, cross-sectional study analysing data over 5 years from January 2015 to December 2020. Thirty-two patients with TBm were identified from a single institution in an urban centre (Johannesburg) in South Africa. They all either underwent a breast core needle biopsy (CNB) for histopathological review at the NHLS laboratory at Charlotte Maxeke Johannesburg Academic Hospital and the University of the Witwatersrand or a fine needle aspiration (FNA) submitted to the cytology department of National Health Laboratory Service and the University of the Witwatersrand, Johannesburg. The patients were considered positive for TBm if histological or cytological findings were confirmed with either a positive TB culture, ZN stain, or polymerase chain reaction (PCR) examination/GXP. The radiological findings, where available, were also recorded. Ethics permission to undertake this study was obtained through the Health Research Ethics Committee (medical) of the University of the Witwatersrand.

Inclusion and Exclusion Criteria

All patients over 18 years of age with histological and cytological features diagnostic of TBm were included in the study. Reported cases of suspected TBm with no ancillary tests were excluded.

Data Collection

A SNOMED search of the NHLS Trakcare database was performed, and any diagnosis in keeping with TBm was selected for the study. Patient's medical records were accessed, and demographic data such as age, sex, and gender were reviewed along with retroviral disease status (Table 1). The clinical presentation, laterality of the lesion, and presence or absence of skin involvement were also documented. Cytologically and histologically, the presence of inflammation, well- or poorly formed granulomas, suppurative inflammation, and necrosis were recorded (Table 2).

Statistical Analysis

The data collected were analysed with SPSS version 28.0 (IBM Corp., Armonk, NY, USA) and Stata version 16.0 (StataCorp, College Station, TX, USA). Categorical data were presented as frequencies and percentages and compared using χ^2 tests (goodness-of-fit for single variables and test-of-independence for bivariate data). Odds ratios were used as a measure of association. Descriptive statistics (median and interquartile ranges) were used to describe the quantitative data collected. Continuous variable group means were compared using the Kruskal-Wallis test. A p value of 0.05 was regarded as statistically significant. All p values are χ^2 values unless otherwise specified.

Downloaded from http://karger.com/acy/article-pdf/67/6/573/4062920/000534193.pdf by Università Campus Bio-medico di Roma user on 06 February 2024

Table 1. Clinical information

No.	Age	Gender	HIV status	Presentation; mass/abscess	Left/right	Skin involvement	GXP	TB culture
Cytology								
1	32	Male	Negative	Abscess	Not stated	Not stated	Performed – positive	Performed – positive
2	32	Female	Positive	Mass	Right	Not stated	Not performed	Performed – positive
3	45	Male	Positive	Mass	Right	Not stated	Not performed	Performed – positive
4	45	Female	Negative	Mass	Left	Not stated	Performed – negative	Not performed
5	20	Female	Positive	Mass	Left	Not stated	Not performed	Not performed
6	31	Female	Positive	Mass	Left	Not stated	Performed – negative	Performed – positive
7	27	Female	Positive	Mass	Right	Not stated	Not performed	Performed – positive
8	25	Female	Negative	Mass	Right	Not stated	Performed – positive	Performed – negative
9	32	Female	Positive	Mass	Left	Not stated	Not performed	Not performed
10	21	Female	Positive	Mass	Left	Not stated	Not performed	Not performed
11	34	Female	Positive	Abscess	Left	Not stated	Performed – positive	Not performed
12	30	Female	Positive	Mass	Right	Not stated	Not performed	Not performed
13	32	Female	Positive	Mass	Right	Not stated	Performed – positive	Performed – positive
14	31	Female	Positive	Mass	Right	Not stated	Performed – positive	Performed – negative
15	45	Male	Positive	Abscess	Right	Not stated	Performed – positive	Not performed
16	42	Female	Unknown	Mass	Left	UOQ	Performed – positive	Performed – positive
17	23	Female	Unknown	Mass	Left	LIQ	Performed – positive	Performed – negative
18	27	Female	Unknown	Abscess	Right	Not stated	Performed – positive	Performed – negative
19	20	Female	Negative	Mass	Left	Not stated	Performed – positive	Not performed
Histology								
20	42	Female	Positive	Mass	Left	Not stated	Performed – positive	Performed – contaminated
21	41	Female	Unknown	Abscess	Left	Not stated	Not performed	Not performed
22	36	Female	Positive	Not stated	Right	Not stated	Performed – positive	Not performed
23	55	Female	Unknown	Mass	Left	Not stated	Not performed	Performed – positive
24	74	Female	Unknown	Mass	Left	Not stated	Performed – positive	Not performed
25	32	Female	Positive	Abscess	Left	Not stated	Not performed	Performed – positive
26	33	Female	Unknown	Mass	Right	Not stated	Performed – negative	Performed – positive
27	43	Female	Negative	Abscess	Left	Not stated	Performed – positive	Not performed
28	34	Female	Positive	Mass	Right	Not stated	Performed – negative	Performed – positive
29	58	Female	Positive	Mass	Left	Not stated	Not performed	Performed – positive
30	34	Female	Positive	Mass	Right	Not stated	Performed – positive	Performed – contaminated
31	26	Female	Positive	Abscess	Right	Not stated	Not performed	Not performed
32	39	Female	Positive	Mass	Right	Not stated	Not performed	Performed – positive

Results

Case Demographics

Of the 32 cases of confirmed TBm, 19 were cytology (59.38%) specimens, and 13 were histology (40.63%). The data were captured in Tables 1 and 2.

The median age for the cytology group was 31 years and the median age for the histology group was 39 years. The p value of 0.006 suggests a statistically significant difference in age between the cytology and histology groups. There was no significant difference in the ratio of females to males between the groups. However, in each group, there were significantly more females than males (p value: <0.050). In the cytology group, 4 individuals were HIV-negative (25.0%) and 12 were HIV-positive (75.0%). In the histology group, 1 individual was HIV-negative (11.1%) and 8 were HIV-positive (88.9%). The p value of 0.621 indicates that the difference in HIV status between the two groups is not statistically significant. The HIV status was unknown in 7 cases overall. In the cytology group, 9 individuals had the condition on the left side (50.0%) and 9 on the right side (50.0%). In the histology group, 7 individuals had the condition on the left side (53.8%) and 6 on the right side (46.2%). The p value of 1.000 suggests that there is no statistically significant difference in laterality between the two groups. Please see Table 3.

Downloaded from http://karger.com/acy/article-pdf/67/6/573/4062920/000534193.pdf by Università Campus Bio-medico di Roma user on 06 February 2024

Table 2. Cytological and histological features

	Inflammation/ non-specific	Granulomas – well-formed	Poorly formed granulomas	Suppurative inflammation	Necrosis	ZN (+)	ZN (–)	ZN not performed	Dual pathology, i.e., carcinoma
Cytology	19	7	1	10	12	5	2	12	0
(19 cases in total)	19	19	19	19	19	19	19	19	19
Percentage	100.00	36.84	5.26	52.63	63.16	26.32	10.53	63.16	0.00
Histology	13	10	2	7	12	3	9	1	0
(13 cases in total)	13	13	13	13	13	13	13	13	13
Percentage	100	76.92	15.38	53.85	92.31	23.08	69.23	7.69	0

ZN, Ziehl-Neelsen.

Cytology

A SNOMED search of the NHLS Trakcare database for inflammatory breast lesions within the study time frame delivered 177 patients on whom FNAs were performed. Twenty-four of these cases were cytologically suggestive of TB (13.56%). Nineteen cases were confirmed to have TB (10.73%), and five were cytologically suggestive of TB morphologically but lacked ancillary tests (2.82%). The remaining 153 cases were confirmed breast nontuberculous abscesses (86.44%).

Histology

A SNOMED search of the NHLS Trakcare database for inflammatory breast lesions within the study time frame delivered 734 patients on whom CNBs were performed. Forty-seven of these cases were histologically suggestive of TB (6.40%); however, the diagnosis of TB was confirmed in only 13 cases (1.77%). Thirty-four cases were histologically suggestive of TB but lacked ancillary tests to support the diagnosis (4.63%). The remaining 687 cases were signed out as nontuberculous breast abscesses (93.60%). In our study, 52 cases cytologically and histologically suggestive of TBm, lacked ancillary tests to confirm the diagnosis.

The χ^2 test was conducted to examine the association between the type of diagnosis (cytology vs. histology) and the ability to confirm the diagnosis. The analysis revealed a statistically significant association ($\chi^2 = 18.631$; df = 1; $p = < 0.05$) between the type of diagnosis and the ability to confirm the diagnosis. Of the 24 cytology diagnoses, 19 (79.2%) could be confirmed with other tests. On the other hand, only 13 out of 47 histological diagnoses (27.7%) could be confirmed. This indicates a higher confirmation rate for cytology compared to histology diagnoses. These findings suggest that cytology may be a more reliable diagnostic method than histology concerning the confirmation of TB.

Clinical Presentation

Of the 31 cases for which clinical presentation of the breast lesion was documented, 23 (74.2%) presented with a mass, and the remaining eight (25.8%) presented with a breast abscess. Please see Table 1.

Inflammatory Morphology in Confirmed TBm Cases

Histologically and cytologically, all 32 cases showed features of inflammation. Well-formed granulomas were more common in histological specimens (36.84% of cytology cases and 76.92% of histology cases,

Downloaded from http://karger.com/acy/article-pdf/67/6/573/4062920/000534193.pdf by Università Campus Bio-medico di Roma user on 06 February 2024

Table 3. TBm demographics and HIV status

	Cytology	Histology	*p* value	Test
Age, years, median (IQR)	31 (25.0–34.0)	39 (34.0–43.0)	0.006	Mann-Whitney
Gender, *n* (%)			0.253	Fisher's exact
Female	16 (84.2)	13 (100.0)		
Male	3 (15.8)	0 (0.0)		
HIV status, *n* (%)			0.621	Fisher's exact
Negative	4 (25.0)	1 (11.1)		
Positive	12 (75.0)	8 (88.9)		
Laterality, *n* (%)			1.000	Fisher's exact
Left	9 (50.0)	7 (53.8)		
Right	9 (50.0)	6 (46.2)		

respectively). Poorly formed granulomas were seen in 5.26% of cytology cases and 15.38% of histology cases. Please see Table 2. Suppurative inflammation was seen in 52.63% of cytology and 53.85% of histology cases. Necrosis was seen in 63.16% of cytology and 92.31% of histology cases. Please see Table 2.

Radiology Findings

A total of 22 out of 32 cases had radiological findings available. The recorded breast lesion sizes varied among the cases, spanning from 0.5 cm to 6.4 cm with a median size of 2.5 cm. Out of the 22 cases, most were in the left or right upper outer quadrants, with an equal distribution of five lesions in each. Three were retro areolar; one involved all four quadrants and there was one in each of the left and right lower inner quadrants.

A Breast Imaging Reporting and Data System (BIRADS) score was reported on eight of the cases only, ranging from BIRADS category 2 (benign) to BIRADs category 5 (highly suspicious for malignancy). The median BIRADS category is BIRADS 4A (suspicious for malignancy), which warrants tissue diagnosis. Although mammography findings were not available for all cases, these findings suggest that tissue diagnosis is indicated in many of these inflammatory breast lesions according to the BIRADS classification system. Please see Figure 1.

Confirmatory Diagnostic Tests

GXP® was performed on 63.16% of the TBm cytology cases and 53.85% of the TBm histology cases. TB culture was performed on 57.89% of cytology cases and 61.54% of histology cases. In our sample of 32, the overall positivity rate for TB culture was 76.5%, and the overall positivity rate for GXP was 78.9%. More positive results were observed in histology for TB culture (46.15%), and more positive cases were observed for cytology with GXP (52.63%). ZN staining was performed on 36.84% of cytology cases and 92.31% of histology cases. The overall positivity rate for ZN was lower at 42.10%.

The z-proportion column test indicates that there is a significant difference in the pathology between positive and negative results for ZN. More positive results for ZN were observed for cytology. Please see Table 4. There were no positive records showing a diagnosis of breast carcinoma. Please see Table 1.

Discussion

TBm is mainly seen in women of reproductive age [16]. Hormonal changes in the breast parenchyma and trauma related to breastfeeding contribute to the increased susceptibility of the breast to infection [16]. In our sample, CNB was performed on older patients, while FNA and submission for cytology were performed on younger patients. This may be explained by clinicians having a higher clinical suspicion of breast carcinoma in older patients [17].

Clinical preference and diagnostic algorithms have recently seen a shift in preference for CNB over FNA [18]. The choice of CNB or FNA depends on the prevailing practices of institutions and countries and the features of the breast lesion; for example, CNB is preferred in more diffuse lesions [17]. The sensitivity of breast FNA is 90–99%, with a positive predictive value approaching 100%. The false-positive rate is very low [19]. The preference for CNB over FNA was mirrored in our case review, with significantly more CNBs performed than FNAs (734 and 177, respectively). Our study showed, however, that GXP and culture for TB were more readily performed on the FNA specimens, with a higher number (10.3%) of FNAs showing confirmed TB than CNBs (1.7%). In our LMIC setting, where the prevalence of

Downloaded from http://karger.com/acy/article-pdf/67/6/573/4062920/000534193.pdf by Università Campus Bio-medico di Roma user on 06 February 2024

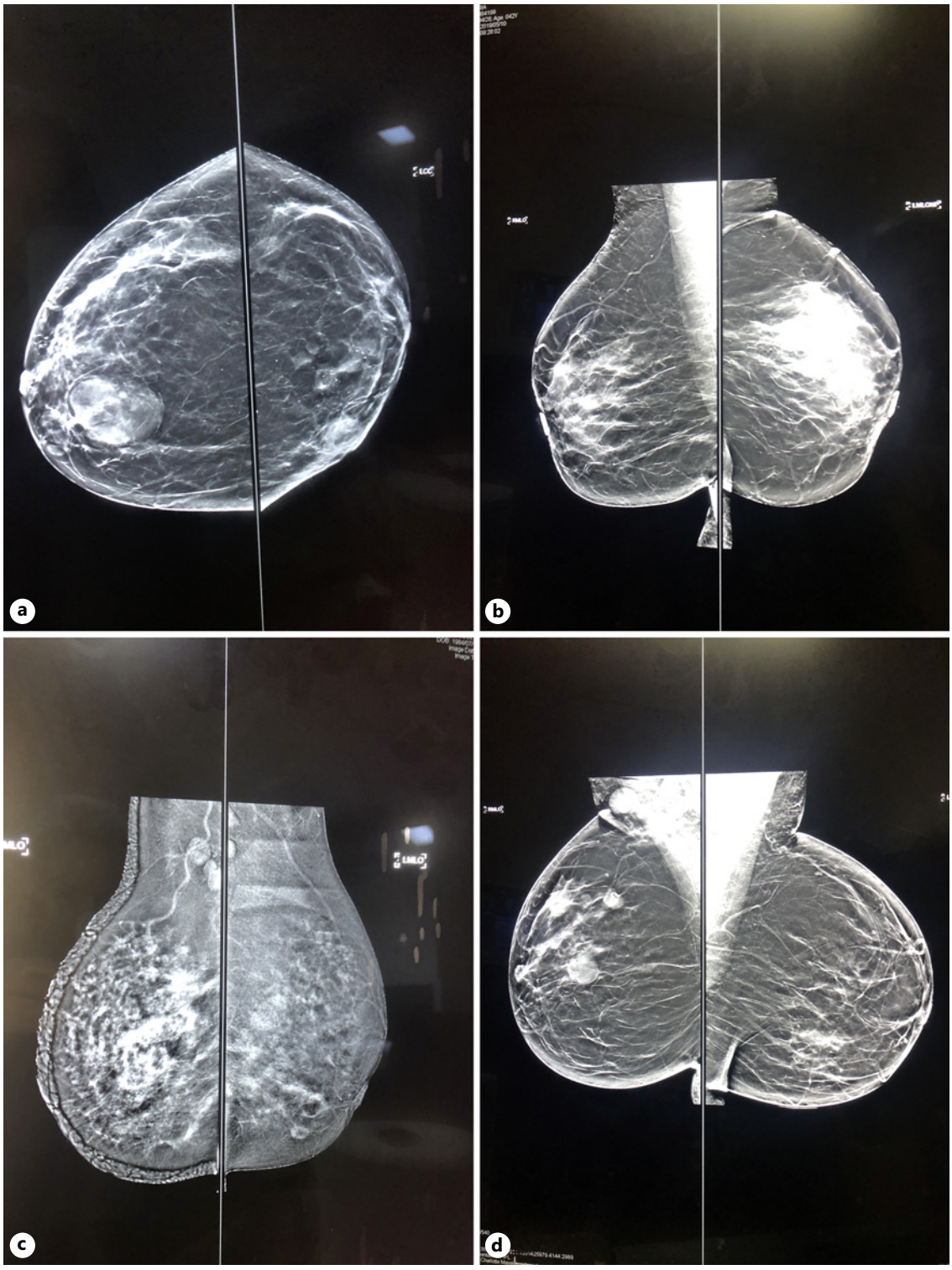

Fig. 1. a Multiple breast abscesses scattered throughout the breast (BIRADS 2). **b** Asymmetrical, ill-defined density in left upper outer quadrant (BIRADS 5). **c** Extensive segmental area in right mid-outer quadrant (RUOQ) with circumferential rim enhancement (BIRADS 4B). **d** Multiple segmental lesions in the right upper outer quadrant (BIRADS 4B).

Downloaded from http://karger.com/acy/article-pdf/67/6/573/4062920/000534193.pdf by Università Campus Bio-medico di Roma user on 06 February 2024

Table 4. ZN with pathology crosstabulation

ZN; +/− * pathology crosstabulation			
	pathology		total
	cytology	histology	
ZN; +/−			
Negative			
Count	2_a	9_b	11
% within pathology	28.6	75	57.9
Positive			
Count	5_a	3_b	8
% within pathology	71.4	25	42.1
Total			
Count	7	12	19
% within pathology	100.0	100.0	100.0

Each subscript letter denotes a subset of pathology categories whose column proportions do not differ significantly from each other at the 0.05 level.

EPTB is high, the possibility that FNA is underutilised in inflammatory breast lesions warrants consideration and re-evaluation.

FNA is more readily available in LMICs such as South Africa. Field et al. [20] discussed the benefits of FNA in LMICs, showing FNA to be reliable, cost-effective, non-intensive technologically, and more acceptable to patients. Philipo et al. conducted a prospective study at an intensive breast cancer screening event in Tanzania. They concluded that integrating a high-quality clinical breast examination with FNA and a rapid on-site evaluation was an effective screening method for breast cancer in a resource-limited setting [21].

It is highly recommended that ancillary tests for TB are undertaken to confirm the diagnosis. TBM can only be diagnosed with certainty if the clinicians, prompted by clinical suspicion of TB, or the pathologist perform ZN stain, GXP, or microbiological culture. FNA is more conducive to collecting material by clinicians for additional studies, aiding in rapid diagnosis and treatment of underlying TB [10]. This will prevent TB complications that burden an already under-resourced, overburdened healthcare system [22]. In addition, the implementation of rapid on-site evaluation may prompt the cytopathologist, based on the inflammatory morphology, to request further confirmatory diagnostic tests for TB, which will likely give an automated result before formal review by a cytopathologist [20, 21]. In LMICs such as South Africa, the index of suspicion for TBm should be higher, warranting the importance of adjusting screening and assessment guidelines for inflammatory breast lesions, particularly in women of childbearing age, to incorporate FNA and microbiological tests. Another consideration is the high prevalence of patients on treatment for HIV. Gynaecomastia is a side-effect of antiretroviral therapy. FNA and CNB will readily make this distinction as the management differs [23].

The microscopic presentation of TB varies and depends on the host's inflammatory response to the bacillus [24]. The morphological features range from granulomatous inflammation with Langhans type giant cells, Figure 2, necrotising granulomatous inflammation, Figure 3, in patients with a strong immune response to frank necrosis without granulomata in the severely immune-compromised, Figure 4 [24]. A spectrum exists between the two, ranging from poorly formed necrotic granulomata to suppurative inflammation with variable amounts of neutrophils, histiocytes, and lymphocytes.

Necrosis without granulomas and a suggestive inflammatory component should also be considered suspicious for TB in patients with a poor immune response [24]. Using ZN staining of formalin-fixed tissue aids in confidently diagnosing a mycobacterial infection by confirming the presence of acid-fast bacilli, Figure 4 [14].

The sensitivity of ZN staining is variable in formalin-fixed paraffin-embedded tissue due to processing with formalin and xylene [14]. Acid-fast bacilli staining has a specificity of 87%. However, it does not classify the species of the bacillus. Sensitivity is far more variable and ranges from 22 to 80% [15], adding another dimension of complexity to confirming a diagnosis of EPTB.

In TBm, the sensitivity and specificity of detecting bacilli by ZN are low, which was mirrored in our study [14]. Acid-fast bacilli are only identified in 12% of cases; therefore, a histological diagnosis of caseating granulomatous inflammation in the breast and lymph nodes is considered sufficient for diagnosis in some settings [25]. The sensitivity of ZN staining on FFPE tissue is extremely low, approximately 12% [10]. In South Africa, the sensitivity of ZN staining in TBm has not been evaluated.

GXP is currently the gold standard for diagnosing TB. GXP allows rapid diagnosis and has a high sensitivity making it more optimal than smear microscopy. However, GXP specificity is still suboptimal and non-respiratory specimens often have a low bacterial load, affecting rapid tests such as GXP and acid-fast microscopy [26]. One study showed a 100% diagnostic accuracy when FNA was combined with GXP PCR (10).

Despite advances in nucleic acid amplification technology, PCR for *Mycobacterium tuberculosis* has not yielded promising results in paraffin-embedded, formalin-fixed

Downloaded from http://karger.com/acy/article-pdf/67/6/573/4062920/000534193.pdf by Università Campus Bio-medico di Roma user on 06 February 2024

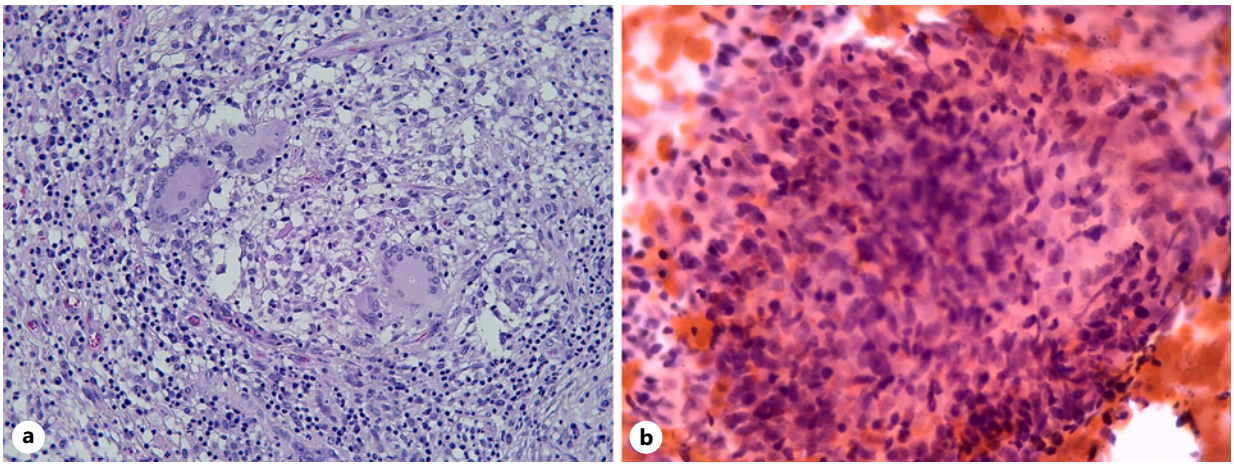

Fig. 2. a Histology of Langhans giant cells within a well-formed granuloma. **b** Granulomatous inflammation on cytology.

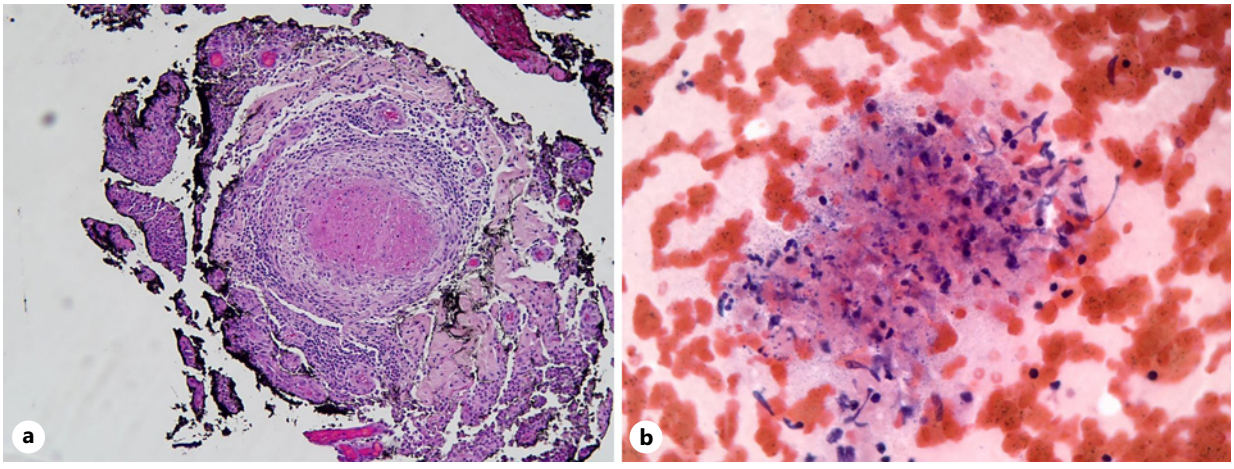

Fig. 3. a Necrotising granulomatous inflammation on histology. **b** Necrotising granulomatous inflammation on cytology.

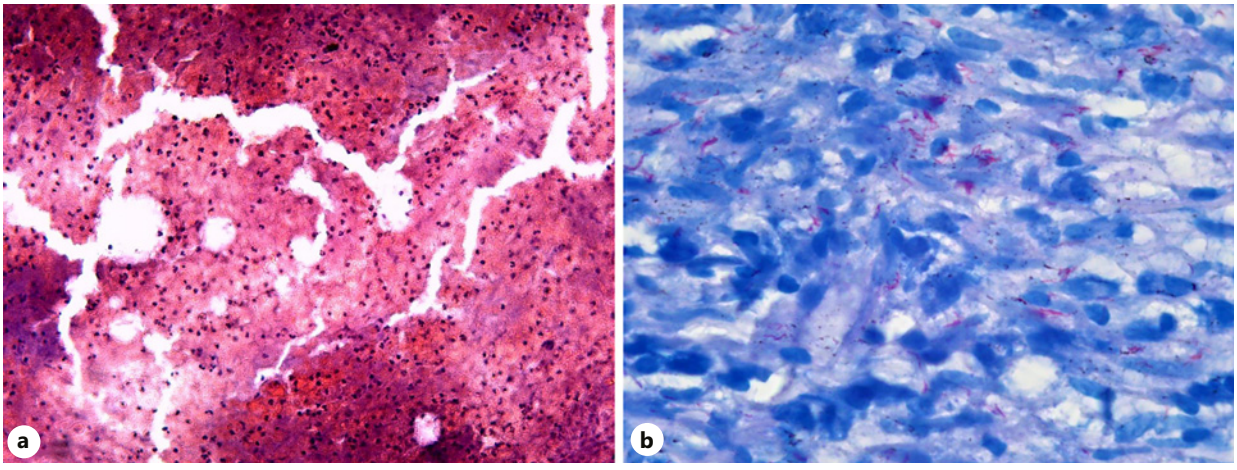

Fig. 4. a Necrosis and inflammatory cells on cytology. **b** A positive ZN stain showing acid-fast bacilli.

Downloaded from http://karger.com/acy/article-pdf/67/6/573/4062920/000534193.pdf by Università Campus Bio-medico di Roma user on 06 February 2024

tissue. Lakhoo et al. [27] showed that the sensitivity for nested mycobacterial PCR was only 64.1%, and the specificity was 68.2%. Therefore, due to the poor sensitivity and specificity of GXP PCR in paraffin-embedded tissue, coupled with the low sensitivity and specificity of acid-fast stains, submission of material for GXP and culture at the time of FNA or CNB is highly recommended. The cost-effectiveness of FNA plus GXP compared to CNB warrants further investigation.

Conclusion

This study supports using FNA combined with GXP as the primary diagnostic modality in diagnosing TBm. This test combination is advantageous in resource- and financially constrained environments as it is relatively simple to perform, cost-effective, and has a rapid turnaround time. This is crucial in low-resourced settings where patients may be significantly clinically unwell due to secondary illnesses, and early diagnosis and treatment are paramount.

Acknowledgments

The author would like to thank the following people who played a role in this research project: the co-authors, Dr. Carolina Nel, Professor Aylwyn Mannell, and Dr. Luvo Fatman, for their dedicated time and guidance; Mr Deepak Singh for his guidance with statistical analysis; and Dr. Pamela Michelow for her time and dedication.

Statement of Ethics

Since this was a retrospective study, no informed consent was required. All images are anonymised. This study protocol was reviewed and approved by the Health Research Ethics Committee (medical) of the University of the Witwatersrand, approval number M210643. Written informed consent from participants was not required in accordance with local/national guidelines.

Conflict of Interest Statement

The authors declare no conflict of interest.

Funding Sources

This research did not require funding.

Author Contributions

Dr. Carolina Nel and Prof Aylwyn Mannell contributed to the study design. Dr. Nine-Paula Olmesdahl and Dr. Luvo Fatman accomplished data collection. Dr. Nine-Paula Olmesdahl analysed the data. Dr. Nine-Paula Olmesdahl, Dr. Carolina Nel, Prof Aylwyn Mannell, and Dr. Luvo Fatman drafted different parts of the manuscript, and all approved the final version.

Data Availability Statement

As the database included in this study is de-identified, it is not available in an open-access repository. Supporting data can be requested by emailing the corresponding author.

References

1 Tuberculosis (TB) [internet]. Geneva: World Health Organization; 2020 Mar 24 [updated 2020 Mar 24; cited 2023 May 22]. 10 pp. Available from: https://www.who.int/news-room/fact-sheets/detail/tuberculosis.
2 Alirol E, Getaz L, Stoll B, Chappuis F, Loutan L. Urbanisation and infectious diseases in a globalised world. Lancet Infect Dis. 2011 Feb;11(2):131–41.
3 Baharoon S. Tuberculosis of the breast. Ann Thorac Med. 2008;3(3):110–4.
4 Global tuberculosis report 2017 [Internet]. Geneva: World Health Organization; 2017 Oct 30 [updated 2017 Oct 30; cited 2023 May 22]. Available from: https://apps.who.int/iris/handle/10665/259366.
5 Kibuuka D, Mpofu C, Neave P, Manda S. A spatial analysis of tuberculosis related mortality in South Africa. Int J Environ Res Public Health. 2021 Nov 12;18(22):11865.
6 Sivay, MV, Hudelson, SE, Wang, J, Agyei, Y, Hamilton, EL, Selin, A, et al. HIV-1 diversity among young women in rural South Africa: hptn 068. PLoS One. 2018 Jun;13(7):e0198999
7 Minnies S, Reeve BWP, Rockman L, Nyawo G, Naidoo CC, Kitchin N, et al. Xpert MTB/RIF Ultra is highly sensitive for the diagnosis of tuberculosis lymphadenitis in a high-HIV setting. J Clin Microbiol. 2021 Nov 18;59(12):e0131621.
8 Van Rie A, Page-Shipp L, Mellet K, Scott L, Mkhwnazi M, Jong E, et al. Diagnostic accuracy and effectiveness of the Xpert MTB/RIF assay for the diagnosis of HIV-associated lymph node tuberculosis. Eur J Clin Microbiol Infect Dis. 2013 Nov;32(11):1409–15.
9 Scott LE, Beylis N, Nicol M, Nkuna G, Molapo S, Berrie L, et al. Diagnostic accuracy of Xpert MTB/RIF for extrapulmonary tuberculosis specimens: establishing a laboratory testing algorithm for South Africa. J Clin Microbiol. 2014 Jun;52(6):1818–23.
10 Aljafari AS, Khalil EG, Elsiddig KE, El Hag IA, Ibrahim ME, Elsafi MEMO, et al. Diagnosis of tuberculous lymphadenitis by FNAC, microbiological methods and PCR: a comparative study. Cytopathology. 2004 Feb;15(1):44–8.
11 Khanna R, Prasanna GV, Gupta, P, Kumar, M, Khanna, S, Khanna, AK. Mammary tuberculosis: report on 52 cases. Postgrad Med J. 2002 Aug;78(921):422–4.
12 Bouziyane A, Benaguida H, Lamsisi M, Khoaja A, Benayad S, Ennachit M, et al. Tuberculosis of the breast: analysis of 17 cases. Pan Afr Med J. 2020;37:282.
13 Maroulis I, Spyropoulos C, Zolota V, Tzorakoleftherakis E. Mammary tuberculosis mimicking breast cancer: a case report. J Med Case Rep. 2008 Feb 1;2(1):34.

Downloaded from http://karger.com/acy/article-pdf/67/6/573/4062920/000534193.pdf by Università Campus Bio-medico di Roma user on 06 February 2024

14 Fukunaga H, Murakami T, Gondo T, Sugi K, Ishihara T. Sensitivity of acid-fast staining for Mycobacterium tuberculosis in formalin-fixed tissue. Am J Respir Crit Care Med. 2002 Oct 1;166(7):994–7.
15 Aslanzadeh J, de la Viuda M, Fille M, Smith WB, Namdari H. Comparison of culture and acid-fast bacilli stain to PCR for detection of Mycobacterium tuberculosis in clinical samples. Mol Cell Probes. 1998 Aug;12(4):207–11.
16 Boakes E, Woods A, Johnson N, Kadoglou N. Breast infection: a review of diagnosis and management practices. Eur J Breast Health. 2018 Jul 1;14(3):136–43.
17 Verma P, Sharma R, Sharma N, Gulati A, Parashar A, Kaundal A. Fine-needle aspiration cytology versus core-needle biopsy for breast lesions: a dilemma of superiority between the two. Acta Cytol. 2021;65(5):411–6.
18 Oyama T, Koibuchi Y, McKee G. Core needle biopsy (CNB) as a diagnostic method for breast lesions: comparison with fine needle aspiration cytology (FNA). Breast Cancer. 2004 Nov 1;11(4):339–42.
19 Field AS, Raymond WA, Rickard MT, Arnold L, Brachtel EF, Chaiwun B, et al. The International Academy of Cytology Yokohama System for reporting breast fine needle aspiration biopsy cytopathology: introduction and overview. Springer International Publishing; 2020. p. 1–9.
20 Field AS. Cytopathology in low medical infrastructure countries: why and how to integrate to capacitate health care. Clin Lab Med. 2018 Mar;38(1):175–82.
21 Philipo GS, Vuhahula E, Kimambo A, Mmbaga EJ, Van Loon K, Ng DL. Feasibility of fine-needle aspiration biopsy and rapid on-site evaluation for immediate triage in breast cancer screening in Tanzania. JCO Glob Oncol. 2021 Jan 25;7:146–152.
22 Tiemersma EW, van der Werf MJ, Borgdorff MW, Williams BG, Nagelkerke NJD. Natural history of tuberculosis: duration and fatality of untreated pulmonary tuberculosis in HIV negative patients: a systematic review. PLoS One. 2011 Apr 4;6(4):e17601.
23 Shawarira-Bote S, Shamu T, Chimbetete, CG. In HIV-positive adult men receiving efavirenz-based antiretroviral therapy at Newlands clinic, Harare, Zimbabwe. BMC Infect Dis. 2019;19:715.
24 Gupta D, Rajwanshi A, Gupta SK, Nijhawan R, Saran RK, Singh R. Fine needle aspiration cytology in the diagnosis of tuberculous mastitis. Acta Cytol. 1999;43(2):191–4.
25 Shinde SR, Chandawarkar RY, Deshmukh SP. Tuberculosis of the breast masquerading as carcinoma: a study of 100 patients. World J Surg. 1995;19(3):379–81.
26 Tortoli E, Russo C, Piersimoni C, Mazzola E, Dal Monte P, Pascarella M, et al. Clinical validation of Xpert MTB/RIF for the diagnosis of extrapulmonary tuberculosis. Eur Respir J. 2012 Aug;40(2):442–7.
27 Lakhoo DG. Determining the validity of the mycobacterium polymerase chain reaction assay in histological samples showing granulomatous inflammation with a negative Ziehl-Neelsen stain. 2016. [cited 2023 May 22]. Available from: https://www.semanticscholar.org/paper/Determining-the-validity-of-the-mycobacterium-chain-Lakhoo/4e120a8b50828012431d0c99864218fc621b6a29.

Downloaded from http://karger.com/acy/article-pdf/67/6/573/4062920/000534193.pdf by Università Campus Bio-medico di Roma user on 06 February 2024