

https://dspace.org/

A clinical study treatment of mandibular fractures using a resorbable polylactic polyglycolic copolymer mini-plating system

Kruger, Lance Ruvain

2014-04-30
http://hdl.handle.net10539/14628

Downloaded from a DSpace repository. https://dspace.org/

A clinical study of the treatment of mandibular fractures using a resorbable polylactic polyglycolic copolymer mini-plating system.

Lance Ruvain Kruger

A research report submitted to the Faculty of Health Sciences of the University of the Witwatersrand in partial fulfilment of the requirements for the degree of Master of Dentistry in the branch of Maxillofacial and Oral Surgery.

Johannesburg 1998.

I, Lance Ruvain Kruger, hereby declare that this research report is my own work and has not been presented for any degree of another university.



Date: 15 May, 1998

The work reported in this research report was performed in the Division of Maxillofacial and Oral Surgery, University of the Witwatersrand, Johannesburg, and the MRC/University of the Witwatersrand Dental Research Institute.

Dedicated to the two Lee's in my life.

" Real isn't how you are made," said the Skin Horse. "It's a thing that happens to you. When a child loves you for a long, long time, not just to play with, but REALLY loves you, then you become REAL."

"Does it hurt?" asked the Rabbit

"Sometimes," said the Skin Horse, for he was always truthful. "When you are Real you don't mind being hurt."

"Does it happen all at once, like being wound up," he asked "or bit by bit?"

"It doesn't happen all at once," said the Skin Horse. "You become. It takes a long time. That's why it doesn't often happen to people who break easily, or have sharp edges, or have to be carefully kept. Generally by the time you are Real, most of your hair has been loved off, and your eyes drop out and you get loose in the joints and very shabby. But these things don't matter at all, because once you are Real, you can't be ugly, except to people who don't understand ... but once you are Real you can't become unreal again. It lasts for always."

(Margery Williams The Velveteen Rabbit)

Abstract

Resorbable bone fixation devices have been investigated for several decades as an alternative to titanium bone plating systems that are currently used extensively for the fixation of bone fractures. These metal systems, although extremely effective for the semi-rigid or rigid fixation of bone fragments, have one major disadvantage, they will remain intact *in situ* unless removed during a second operation. The resorbable osteosynthesis systems however, undergo progressive degradation and are totally removed by the body after varying periods of time. The obvious benefits of these resorbable systems are the limited presence of these foreign bodies as well as the automatic degradation of the plates which, especially in children, could inhibit bone growth or migrate to unfavourable sites. The purpose of the study was to clinically evaluate the Lactosorb® resorbable bone plating system as a viable alternative to the conventional metal plating systems currently commercially available. Experience during the current study of 12 patients suggests that the mechanical characteristics influence its use. The inherent elasticity of the plates prevent the rigid fixation of the fracture site allowing for increased chance of postoperative displacement. I feel that although the resorbable system used in this study provided adequate stabilisation for the majority of the patients treated, it requires more refinement before acceptance for routine use in mandibular fractures. In the case of paediatric fractures, where an indication clearly exists, the system could be used in its current form, with smaller plates and screws to achieve a good result in the hands of a surgeon experienced in its use.

Acknowledgements

To: Professor John Lownie for his assistance as supervisor.

Professor Peter Cleaton Jones for his assistance as supervisor.

Selective Surgical the agents for Lactosorb® in South Africa for their support and assistance.

Gavin Schutte from Selective Surgical for his personal interest.

Assistants, theatre staff who helped with the clinical aspects of this study.

Family who undoubtedly saw a lot less of me in the interests of medical research.

Table of Contents

Initial pages :

Title page 1

Declaration 2

Dedication 3

Abstract 4

Acknowledgements 5

Table of contents 6

List of figures 9

List of tables 10

Chapter 1: INTRODUCTION

1.1 Introduction 11

1.2 Historical review of mandibular fractures and their treatment 12

1.3 Current status of mandibular fractures 22

1.4 Current concepts in mandibular fracture management 25

1.5 Fracture management in children 36

1.6 Complications of mandibular fracture management 38

1.7 Future treatment possibilities 43

Chapter 2: RESORBABLE OSTEOSYNTHESIS SYSTEMS

2.1 Characteristics of resorbable materials 45

2.2 Polymer processing 50

2.3 Ideal characteristics of a bio-resorbable material 51

2.4 Polymer resorption 52

2.5 Physiological response to bio-resorbable polymers 53

2.6 Polymer processing and packaging 54

2.7 Types of bio-resorbable polymer 55

2.8 Complications from bio-resorbable materials 55

2.9 Studies on resorbable implant materials 57

2.10 Lactosorb® bio-resorbable osteosynthesis system 64

2.11 Lactosorb® plate design 65

2.12 Mechanical properties of Lactosorb® 65

2.13 Objectives of study 68

Chapter 3: MATERIALS AND METHODS

3.1 Ethical approval for study 69

3.2 The clinical study 69

3.3 Patient selection 71

3.4 The treatment group 71

3.5 Patient history and details 76

3.6 Basic treatment plan 77

3.7 Treatment assessment 78

3.8 Data analysis 80

Chapter 4: RESULTS

4.1 Demography of sample 81

4.2 Cause of injury 82

4.3 Individual results of each patient 83

4.4 Overall results of the study 88

Chapter 5: DISCUSSION

5.1 General 92

5.2 Need for a resorbable plating system 92

5.3 Surgical technique 93

5.4 Mobility 94

5.5 Sepsis 95

5.6 Resorption 96

5.7 Cost factors 96

5.8 Conclusion 96

5.9 Future research 97

REFERENCES 99

APPENDIX A 105

APPENDIX B 106

APPENDIX C 107

APPENDIX D 108

APPENDIX E 109

APPENDIX F 110

APPENDIX G 111

APPENDIX H 112

APPENDIX I 113

APPENDIX J 114

APPENDIX K 115

APPENDIX L 116

APPENDIX M 117

List of Figures

Figure 2.1 Basic polymer types 46

Figure 2.2 Types of gross polymer chain structure 47

Figure 2.3 Crystalline and amorphous polymers 48

Figure 2.4 The glass transition temperature and glass transition range 49

Figure 2.5 Two phase degradation of bio-resorbable polymer 53

Figure 3.1 Informed consent form 70

Figure 3.2 Lactosorb® 2mm panel 72

Figure 3.3 Titanium template used for contouring of the Lactosorb® panel, Lactosorb® screws are also shown 73

Figure 3.4 Heat pack for contouring the Lactosorb® plate or panel 73

Figure 3.5 Screw-tap 74

Figure 3.6 Lactosorb® Hex screw driver 74

Figure 3.7 Lactosorb® panel secured in situ 75

Figure 3.8 Diagnosis and postoperative assessment form 76

List of Tables

Table 1.1 Intra-oral splinting techniques developed during the 1800's and 1900's 18

Table 1.2 The development of direct internal fixation techniques 20

Table 2.1 Types of bio-resorbable polymer 55

Table 2.2 Complications associated with the use of bio-resorbable materials 56

Table 4.1 Distribution of age and gender in sample 81

Table 4.2 Cause of injury and number of days before surgical intervention 82

Table 4.3 Follow-up of patients treated 88

Table 4.4 Patient assessment 2 weeks post surgery 89

Table 4.5 Patient assessment 6 weeks post surgery 90

Table 4.6 Patient assessment 3 months post surgery 90

Table 4.7 Patient assessment 6 months post surgery 91

CHAPTER 1

INTRODUCTION

1.1 Introduction

Titanium bone plating systems are currently used extensively for the fixation of traumatically or electively induced bone disjunctions. These systems, although extremely effective for the semi-rigid or rigid fixation of bone fragments, have one major disadvantage, they will remain intact *in situ* unless removed during a second operation. Indications for plate removal include sepsis, or 'stress shielding' a phenomenon in which plates inhibit bone remodelling to maximum strength as a result of their load shielding effects.[1]

Since initial bone stabilisation and healing is usually complete six weeks after injury there is no need for the retention of bone plates beyond this period under normal circumstances. An ideal bone plating system should be biologically inert with adequate fracture site stabilisation for the six-week healing period, with subsequent complete degradation and resorption in the body.

Resorbable bone fixation devices have been investigated for several decades, notably the polylactic acid polymers (PLA) and polyglycolic acid polymers (PGA).[2,3] Where high molecular weight polylactic acid devices have been used in maxillofacial trauma patients, foreign body reactions have been reported, largely due to the lack of complete resorption of the material after five years of

implantation.[4,5] On the other hand, the use of polyglycolic materials for orthopaedic applications have resulted in low rates of foreign body reactions. Polyglycolic materials, however, degrade rapidly with a 50% loss of their original strength after 2 weeks and total loss of strength and consistency after 6 weeks.[6] The combination of the two materials in varying ratios to form copolymers have produced products that combine the most favourable characteristics of both.

Lactosorb® (Biomet/Walther Lorenz, Jacksonville, Florida 32218, U.S.A), a copolymer that retains excellent peak tensile and flex loading properties for up to eight weeks has been developed. This copolymer is fully resorbed one year after placement, is biologically inert and is FDA-approved for midface use but no clinical trials have been undertaken on the use of the product for mandibular fractures.[7] Such a trial is the subject of this research report

1.2 Historical review of mandibular fractures and their treatment

Many of today's basic principles of the examination, diagnosis and treatment of mandibular fractures date from centuries ago. When specific methods were introduced is difficult to document but there have been phases of 'developmental drought' followed by spurts of profound surgical progress, the latter occurring principally during wars.

1.2.1 The Edwin Smith Papyrus[8]

The Edwin Smith Papyrus, an Egyptian treatise written in hieroglyphics, is the earliest known written record describing mandibular fractures. Smith was an American Egyptologist who purchased the document in Thebes in 1862. Sadly, he was unable to translate it. The translation was delayed until 1930 when it was done by Breasted who noted that it was probably a copy of an original written in 3000 BC by a physician associated with the pyramid builders at the time. The Smith Papyrus consists of 48 surgical cases. It is unique for a document of its type and time period as it systematically documents these cases dealing with the head and thorax.

Each case is well presented under five headings: title, examination, diagnosis, treatment and glossary. The diagnosis is directed towards one of the three following treatment options: "an ailment that I will treat", "an ailment with which I will contend", and "an ailment not to be treated".

A patient with a mandibular fracture is case number 24 of the document. In degree of seriousness the surgeon described it as less severe than a compound fracture of a long bone but fatal nonetheless:

> " If thou examinest a man having a fracture in his mandible, thou shouldst place thy hand upon it. Shouldst thou find that fracture crepitating under thy fingers, thou shouldst say concerning him: One

having a fracture in his mandible, over which a wound has been inflicted, and he has a fever from it. An ailment not to be treated."

1.2.2 The era of Hippocrates[8]

The next important mention, in the literature, of mandibular fractures occurred in the age of Greek enlightenment and Hippocrates. From *Corpus Hippocraticum* (the Hippocratic Collection) come various excerpts dealing with mandibular fractures. These excerpts not only diagnose and differentiate between different fracture types i.e.: incomplete and complete fractures, but describe, in detail, procedures for the reduction, and subsequent fixation, of the fracture. Of particular interest is the technique of intra-arch stabilisation by ligating together the teeth adjacent to the fracture. Then, indirect internal fixation methods were used in conjunction with external indirect fixation with leather strips and bandages. Indeed, one can easily draw analogies with the treatment methods used today. Many centuries passed before any modifications of the Hippocratic method took place.

1.2.3 The Roman influence

A Roman practitioner, Aulus Cornelius Celsus (30 BC - 50 AD), wrote the first medical books in Latin. Chapter 7 of his eighth book describes mandibular fractures in detail. Of interest is his description of a 'transverse' fracture involving disruption of the normal occlusal plane anatomy. Following reduction

he also eluded to the correct methods of fixation of the fracture. Like Hippocrates he used a combination of indirect internal fixation methods in conjunction with indirect external fixation with leather strips and bandages. He also recorded the normal healing time of mandibular fractures to be fourteen to twenty days. Various other Roman surgeons made minor adjustments to the Celsus methods of fixation but the basic principles remained.

1.2.4 The 11th century Italian influence[8]

The next major breakthrough, which even today is the basis of all treatment methods, was described in a textbook of surgery written in the eleventh century in Salerno, Italy. The importance of an intact inter-arch occlusion was emphasised because the patient would be unable to 'masticate' if there was an inter-arch occlusal discrepancy. A technique of manipulation of the fractured mandible was described to achieve an intact occlusion. A further development was described by the Italian Guglielmo Salicetti in 1275 in his book Cyrurgia. Although basic treatment methods were essentially those of Hippocrates, a later edition of the book included the first mention of intermaxillary fixation. The reader was advised to first wire the teeth adjacent to the fracture together and then to wire the injured jaw to the uninjured jaw. A similar approach was used by a French surgeon Robert Bunon (1702 - 1748) who related two cases of mandibular fractures treated by binding the teeth together. One case involved a body fracture of the mandible in which the premolars were lost and the adjacent teeth were mobile. The edentulous space was filled with a block of walrus bone

with two holes drilled through it. The mandibular teeth were then ligated to the block and this was used to stabilise the fracture site.

1.2.5 The development of extraoral devices in the 1700s and 1800s[8]

The first mention of an extraoral device used to stabilise a mandibular fracture was by Chopart and Desault in 1795, who took into account the effect of the perioral musculature in the displacement of fractured mandibles. Their extraoral device was, essentially, a screw clamp to sandwich the mandibular teeth between two metal sheets, one over the mandibular teeth and one under the chin. Counter pressure was then applied by screws immobilising the fracture. This device was characteristic of the eighteenth century which was dominated by the use of extraoral bandage devices for the provision of stability during the healing phase. Occasionally extra-oral methods were combined with ligation of the associated teeth using either thread or gold wire. Extraoral devices similar to the clamp-like device of Chopart and Desault dominated this period. Progression in design of these appliances led to the Kingsley splint, a variation of the original design by Hayward in 1860. The Kingsley splint used a metal intraoral splint securing the teeth, which was cast from a wax impression, and extraoral metal bars. These metal bars were secured with a bandage under the chin. Variations of this splint were used in the American civil war (1861-1865). A novel approach was adopted by an Irish born, American dentist, Thomas Brian Gunning (1840 - 1889). Gunning modified the above techniques to use reverse arms from an inter-dental splint. He also used double arms extraorally for anchorage to a head cap

and to a soft rubber chin support. The real breakthrough came with the advent of the Gunning splint. This splint was a customised single vulcanite splint for both the upper and the lower dental arch. In this way intermaxillary fixation was provided. A space was provided for the passage of food and liquids. In 1862 Thomas Gunning was thrown from his horse and suffered a fractured mandible. He reduced his own fracture and utilised his own vulcanite splint design for fixation of the fracture. J B Bean a civilian dentist in Atlanta, Georgia who treated jaw fractures in the confederate army, developed a custom-made vulcanite splint that was held in place with bandages.

1.2.6 The development of intraoral splinting techniques during the 1800s and 1900s[8]

As dentistry became more sophisticated during the 1800s, more types of splints appeared. Inter-maxillary fixation techniques were popular in the late 1800s and early 1900s. Initially silver clamps and splints were used later followed by other materials, orthodontic appliances and gold or nickel-silver arch bars. The history of the chronological development of splints and other appliances is summarised in table 1.1.

Table 1.1: Intraoral splinting techniques developed during the 1800s and 1900s.[8]

YEAR	SURGEON	DEVELOPMENT
1855	Muetter	Designed a silver clamp to fit over the teeth adjacent to the fracture site.
1864	White	Used model surgery techniques to reduce the fracture and then construct a cast-silver splint on the model thereby enabling him to fixate the reduced fracture clinically.
1874	Moon	The first surgeon to wire a metal splint to the mandibular teeth.
1887	William of Saliceto	Used intermaxillary fixation as an alternative approach to the fixation of mandibular fractures
1889	Sauer	Introduced the use of an arch wire or bar by adapting an iron wire to the dental arch.
1893	Thomas	The Thomas-splint. was two pieces of metal fitted respectively to the lingual and buccal cortical bone plates of the mandible held in place by spikes driven into the bone through the mucosa. This approach was more invasive than the previously used techniques and involved fixation of a splint directly to the underlying cortical bone.
1894	Martindale	Made a metal splint that was cemented onto the teeth.
1900s	Angle	Introduced various orthodontic appliances and bands as an adjunct to fixation.
1926	Ivy & Curtis	Introduced the use of half round German silver arch bars attached to the mandibular and the maxillary teeth by ligature wires.
1927	Jelenco	Introduced prefabricated arch bars of 18 carat gold or nickel silver.

1.2.7 Development of open reduction and direct internal fixation techniques[8]

The next logical step in the progression of mandibular fracture treatment was the technique of open reduction of the fracture site and direct internal fixation of the fracture using trans-osseous osteosynthesis methods. The obvious benefits of

this technique were the direct sight of the fracture, adequate mobilisation of fractured segments, a more controlled reduction and an anatomically correct reduction prior to fixation. Further benefits were the ability to remove fibrous tissue and denuded, devitalised bone from the fracture site. Fixation could also be carefully controlled and vital structures protected under direct vision. Already in 1846 Buck presented cases of internal direct fixation using a simple loop of iron wire. Other cases were reported by Kinock in 1859 who preferred a silver wire loop in his treatment. Silver was also used by Thomas who presented two cases, in 1869, in which he used his method for the open reduction of mandibular fractures. The wire was twisted into a spiral spring, which was used to tighten the wire at regular intervals. This 'Thomas principle' was used through the nineteenth century. Disadvantages of the open technique at the time were predominantly associated with the high rate of sepsis and increased risk of secondary infection. There was also a blatant disregard for the dentition and often healthy teeth were sacrificed. Examples of sepsis were recorded by Dorrance and Bransfield in 1941 who emphasised the need to remove the wires in such instances. Further mention was made of subsequent osteomyelitis and loss of large sections of compromised mandibular bone. Table 1.2 documents the progress made in direct fixation techniques through the 19th and 20th centuries, these techniques were modified by the development of alternatives to silver wire osteosynthesis.

Table 1.2 The development of direct internal fixation techniques

Year	Surgeon	Development
1881	Gilmer	Described a method of fracture fixation in mandibles using two heavy metal rods placed on either side of the fracture and wired together. These rods were forced through skin, bone and the mucous membrane and were stabilised by wires both extra-orally and intraorally.[8]
1886	Hansmann	A general surgeon in Hamburg used ' corrosion free ' metal plates for mandibular fixation in 1886.[10]
1888	Schede	The earliest reference to the use of true bone plates according to Dorrance and Bransfield.[8]
1895	Sir William Lane	A British surgeon, further pursued the principle of mandibular plating. [8]
1900s	Mahe	Used a combination of a mono-maxillary splint and multiple bone plates to secure a mandible with multi-segment fractures.[8]
1913	Pickerill	Treated an edentulous mandibular fracture by passing screws into the bone on either side of the fracture and fixating them and thus the fracture with a connecting steel bar.[10]
1915	Ivy	Recorded the use of Sherman's steel plates. The method was abandoned by Ivy because of the high rate of infection and bone necrosis.[8]
1917	Cole	Used a combination of silver plates and screws and wires on each side of the fracture site.[8]

In 1936 the Roger Anderson pin fixator was introduced as a 'modern' method of extraoral closed fixation.[11] Doherty, however, stated five years later that the use

of skeletal fixation devices offered no advantage over the traditional wiring procedures which he felt were dependable, simple and effective. The use of external fixation devices was nevertheless extremely popular in the 1940's. External fixators did not, however, always provide good stability to the fractured segments. They were therefore often combined with intraoral splints. Such combinations of treatments were used to achieve the required reduction, fixation, and mobilisation of the fracture. Intra-oral devices were usually combined with external fixators and traction devices. The traction devices were usually secured with Steinmann pins or plastic head caps but these devices proved to be problematic and were not viewed as ideal. The need for rigid internal fixation of mandibular fractures was clearly apparent. Most of the initial efforts at rigid internal fixation were, however, unsatisfactory. The original devices used were usually 4 holed metacarpal or Lane plates, made of Vitallium® or Tantalum®. These devices were not designed to create compression across the fracture sites so were used in conjunction with other techniques of immobilisation.[12]

During the 1950's, treatment methods remained essentially the same as in the previous decade. Open reduction techniques were used in conjunction with other immobilisation methods. In the 1960's bone-plating technology developed further. In 1960, Robinson and Yoon described the L plate.[12] This plate had a right angle lip that sat in a slot cut in the buccal bone plate and was secured to the underlying bone with two screws. In 1967, Dott reported results of 86 cases of edentulous mandible fractures treated with Vitallium® metacarpal plates, of these, he deemed 80 successful.[12] A year later Luhr introduced the dynamic

compression plate. This design was based on an eccentrically placed compression hole to compress the fracture site to promote primary bone healing.[12]

The 1980's heralded more widespread use of bone plating systems. Both dynamic compression plates and eccentric dynamic compression plates were advocated. These compression plate systems were mostly recommended for the treatment of edentulous mandible fractures. The advantage of the eccentric dynamic compression plate over the external compression plate was that the external holes were designed to produce compressive forces along the superior border of the mandible. This provided friction and stability over the entire length of the fracture site and eliminated the need for an additional superior border plate. Once again the use of these plates were indicated predominantly in the treatment of edentulous mandible fractures.[12]

1.3 Current status of mandibular fractures

The mandible is the most commonly fractured bone in facial trauma. Typically, these fractures are in males aged 20 and 30 years while the seasonal occurrence is highest in the summer months.[13]

1.3.1 The classification of mandibular fractures

Mandibular fractures are classified according to various criteria. The three main factors to consider are the 'cause of the fracture', the 'type of fracture' and the 'site of the fracture'.[14] Once the fracture has been classified it is important to correlate the 'fracture type' with treatment modalities available to establish an effective treatment protocol for the specific fracture, thus correlating the fracture with the degree and direction of displacement, stability of the fracture site before and after treatment and the presence or absence of complicating factors such as sepsis or occlusal instability.

1.3.1.1 Classification by cause of fracture

Fractures may be caused by direct trauma, indirect trauma, or excessive muscular contraction.

1.3.1.2 Classification by type of fracture

The type of fracture differentiates between a 'simple', 'compound', 'comminuted' and 'pathological' fracture. Simple fractures are closed linear fractures of the condyle, coronoid, ramus and edentulous body of the mandible. Compound fractures are usually related to the dentate mandibular body where the fracture line communicates with the mouth via the periodontal space or with the external environment via an overlying skin defect. Comminuted fractures are usually

caused by direct trauma to the mandible from a penetrating sharp object. These fractures are usually compound and may further be complicated by bone and soft tissue loss. Pathological fractures are usually caused by minimal trauma or even normal occlusal forces in a mandible predisposed to fracture as a result of a pre-existing pathological process such as osteomyelitis, neoplasia or a generalised degenerative skeletal condition.

1.3.1.3 Classification by the anatomical site of the fracture

The most clinically useful classification is by the site of the fracture. Common sites of fracture are dento-alveolar fractures, fractures of the condyle, the coronoid, the ramus, the angle, the body of the mandible, symphyseal fractures and parasymphyseal fractures. Fractures of the condyle are further subdivided into intracapsular and extracapsular fractures. This differentiation is of vital importance as the treatment protocol will differ between the two types of fracture. This anatomical classification will then be modified further to correlate with available treatment options.

Anatomical distribution of fractures varies with aetiology. Condylar and subcondylar fractures make up 26% to 36% of the total. Angle fractures make up 20% to 26%. Symphyseal and parasymphyseal fractures make up 14% to 23%. Body fractures are 11% to 21%. Ramus fractures are approximately 25% and coronoid fracture are approximately 1% to 2%.[13]

1.3.1.4 Classification by the degree and direction of displacement of the fracture

Fracture site displacement at the angle of the mandible may be vertically favourable, vertically unfavourable, horizontally favourable or horizontally unfavourable, this is determined by the tendency of the fracture site to distract under the influence of the local masticatory musculature and may modify the planned treatment protocol.[13]

1.4 Current concepts in mandibular fracture management

Basic principles of current fracture management are remarkably similar to the procedures used over the past two centuries. The mobilisation of the fracture site, debridement of all foreign and necrotic material and devitalised bone segments, reduction of the fractured segments into correct anatomical position with occlusal stability and the application of stable fixation to allow for fracture site healing all require attention in order to achieve a good, uncomplicated surgical result.

Fixation techniques can be classified into 'external' and 'internal' fixation. Internal fixation techniques can be further classified into 'indirect' and 'direct' fixation.

1.4.1 External fixation techniques

External fixation refers to the stabilisation of the fractured segments using extraoral appliances. This technique is indicated in instances of extensive comminution of large sections of the mandible. Other indications are large areas of bone loss, severely atrophic mandibles, fractures complicated by osteomyelitis and cases of infected non-union. These appliances require the insertion of titanium or stainless steel pins into each major bone fragment. These pins are then connected to a single cross bar with universal joints once the segments have been realigned. Self-tapping pins such as the Moule or Toller types are used as are Kirschner wires to transfix the fractured bone segments to one another. The Brenthurst splint apparatus uses clamps instead of pins that are attached to the segments.[14] The Morris Biphase apparatus and Hoffman pins can also be used.[13] This type of fixation is not particularly rigid and supplemental intermaxillary fixation is usually required.[14] Face frame appliances use the same principle of fixation pins connected to a face frame device with universal joints. The face frame is used where mandibular fractures are associated with other extensive midface fractures, particularly if comminuted. Bone healing in this case is usually by secondary intention with intermediate callus formation and subsequent osteoid matrix deposition with ossification and remodelling over a period.

1.4.2 Internal fixation techniques

Internal fixation methods are divided into indirect (closed) and direct (open) fixation.

1.4.2.1 Indirect internal fixation

Indirect or *closed internal fixation* refers to the use of intermaxillary fixation techniques to stabilise the fractured mandible generally to an intact maxilla. These techniques do not usually involve exposure of the fracture site and surgical intervention is minimal and of short duration. The most common intermaxillary fixation technique is the use of inter-dental eyelet loops that are linked with intermaxillary straight wires to establish the fixation. Other methods include the use of arch bars where condylar fractures and dento-alveolar components are involved. These indirect or closed internal fixation techniques usually provide adequate stability to allow for fracture healing by callus formation and organisation. The fracture site however is not rigidly fixated and an element of movement does occur which in certain cases may predispose to healing by fibrous union. Using this technique the mandible must be immobilised for four to six weeks and patients' average weight loss is 10 - 15 pounds because of reduced food intake.[13]

1.4.2.2 Direct internal fixation

Direct internal fixation or *open techniques* are divided into rigid and semi-rigid fixation. An example of semi-rigid fixation is the use of transosseous wire osteosynthesis. A small amount of movement of both the proximal and the distal segments occurs which predisposes to healing by callus formation or secondary intention healing. This technique is useful for superior border wiring of fractures of the angle of the mandible.[12] In true rigid fixation the fractured bone segments are reduced and fixated under compression which results in a preload and friction at the fracture site. These compressive forces are achieved with the use of specially designed compression plates. The preload prevents distraction of the segments as long as the static compressive force is greater than the dynamic tension caused by the muscles of mastication acting on the fracture site. The friction component stabilises the fracture against the influence of torsional forces. The compressive forces in conjunction with the friction at the fracture site are as a result of the minimisation of the interspace between the fracture segments. This allows for healing to occur by primary intention with no intermediate stage of callus formation. The mechanics of the dynamic compression plate use the spherical gliding principle to convert the inward movement of the screws into a horizontal movement as the screw is tightened. The bone fragments are brought together by the horizontal movement of the screw-plate-bone segment complex thereby building in the compression forces. These compression systems are usually bicortical systems where the fixation screws are placed through both the outer and the inner cortical bone plates.

1.4.2.3 Comparison between positional osteosynthesis (Champy) and direct compression osteosynthesis (Shetty)

In order to develop a treatment protocol for the surgical management of patients to be included in the current study, it was necessary to review the various techniques and approaches used for the stabilisation of mandibular fractures.

Champy[15] defined the ideal placement sites of osteosynthesis components. He based his principles on the premise that zones of compression and tension exist in the body of the mandible under the influence of the masticatory and accessory musculature. According to his principles the area proximal to the mental foramen requires the placement of a single plate below the dental roots and above the inferior alveolar canal. Anterior to the mental foramen two plates are placed below the apices of the teeth and 5mm from one another, which neutralises the torsional forces present in this region.[15] Using these principles of osteosynthesis the monocortical plating systems can be applied effectively. These systems rely on screws only engaging the outer cortical bone plate. The benefit of the monocortical plating systems are that they can be applied virtually anywhere in the mandible with relative ease usually via an intraoral approach.[13] The obvious benefit of these systems are that they minimise or negate the necessity for intermaxillary fixation.[9] Criticisms of miniplate osteosynthesis are increased morbidity, increased difficulty of the procedure, increased operating time, cost of equipment and materials, the necessity of a second procedure to remove the plates and an increased length of hospital stay.[9] Some authors advocate that

miniplate osteosynthesis should not be used for delayed treatment of infected fracture sites.[15] Another method of rigid fixation is the lag screw technique. An oversized hole greater than the diameter of the screw is drilled through the outer cortical bone plate with a countersink to accommodate the screw head. As the screw is tightened the inner cortical bone plate is pulled towards the outer cortical plate by the screw head in the countersink. Lag screws are most appropriate for oblique fractures. A more extensive form of rigid fixation is required where multiple segmental fractures are present or where large portions of the mandible are defective and continuity needs to be maintained. The reconstruction plate has been designed for this purpose. These plates are larger and stronger and usually rely on bicortical fixation.

A recent study by Renton and Weisenfeld,[9] compared three accepted treatment modalities for mandibular fracture site osteosynthesis. The aim of the study was to establish how miniplate osteosynthesis following Champy's principles compares with transosseous wire osteosynthesis and how non adherence to his principles alters the morbidity rate of miniplate osteosynthesis. Two hundred and five well documented cases of mandibular fractures treated with internal fixation were the study sample. The patients were assigned into three groups according to treatment modality used. The first group of 83 patients received miniplate fixation according to Champy's principles. The second group of 40 patients received miniplate fixation ignoring his principles and the third group of 82 patients had transosseous wire fixation. The outcome was measured using preoperative and postoperative variables. The preoperative variables used were

age, gender, mechanism of fracture, site and number of fractures, nerve function, associated injuries and treatment delay. Postoperative variables were duration of admission, duration of intermaxillary fixation, malocclusion, infection, dehiscence, union, removal of fixation and nerve function. Results showed no statistically significant differences between all three groups for the preoperative variables. Postoperative variables indicated a statistically higher complication rate for the transosseous wire group compared with the miniplate groups. Morbidity was reduced in the group following Champy's principles. The conclusion was that following Champy's principles results in a measurable reduction in postoperative complications compared to miniplate osteosynthesis techniques ignoring his methods.[9]

Shetty, et al, [16] presented the results of a study that questioned the efficacy of monocortical miniplate osteosynthesis by Champy's principles. The study determined the initial mechanical stability and functional capability of six contemporary internal fixation systems used to fix mandibular angle fractures. Six sets of identical mandible analogues (3 mandibles per set) were reduced and fixated by a variety of compressive and adaptive fixation systems namely: four compression systems [1] The eccentric dynamic compression plate, [2] The Wurzburg plate, [3] The Luhr plate and [4] The solitary lag screw technique and two adaptive fixation systems [A] The Champy miniplate and [B] The Mennen clamp plate.

The reduced and fixated analogues were placed in a straining frame. Simulated masticatory loads were applied to predetermined occlusal sites. Fracture line displacements were registered by displacement transducers and transmitted to a computer based data acquisition program. An 'instability factor' was computed from the force-displacement data recorded at various loading conditions and this was used to characterise each system's ability to resist relative motion at the fracture surfaces. Minimal variation was noted in the stability profiles of the individual compressive fixation systems. Comparison of the two adaptive systems used determined that fixation with Mennen plates at the lower border provided more stability than reduction by Champy miniplates. Although the eccentric dynamic compression plates and the Wurtzburg systems demonstrated similar load displacement characteristics, the Luhr system appeared to resist torsional movements more effectively than primary bending movements. Lag screw compressive fixation had a low instability factor but needs a solid buttress since the load is carried by the bone and not the screw itself. This negates its usefulness in comminuted and multisegment fracture types. The placement of compressive lag screw fixation is also technique sensitive. The fixation stability provided by the compressive and the adaptive systems differed significantly. Even at low masticatory loads the compressive systems provided two to three times as much stability as the adaptive systems.

Shetty et al,[16] quote Zaki and Carter [17] as stating that the bending rigidity of the Champy miniplate could hamper fine adaptation to the bone surface in clinical practice. According to Shetty and co-workers [16] it is logical that the absence of

any consequential preload by the miniplate permits fracture site displacement even when subjected to low masticatory forces. Shetty and his colleagues[16] believe that Champy's theories are based on the assumption that the superior border of the mandible is always in tension and the inferior border in compression, a theory that assumes simple cantilever loading. In reality they said that the configuration of the tension-compression stress regions in the mandible are a function of the point and magnitude of force application. Alterations in the loading conditions can cause a fluctuation in the magnitude and direction of stresses and introduce a significant torsional component to the distracting force. This occurs as a result of the curved beam nature of the mandible. Shetty et al[16] also stated that when these torsional components of force come into play the thin miniplate used in Champy's approach to fracture management is not capable of withstanding the displacing forces. They attributed this inability to the mechanical properties of the miniplate.[16] It would therefore appear that Shetty and his collegues[16] not only contradict Champy's principles of specific placement sites related to tension and compression zones, but also that miniplate osteosynthesis is unable to withstand the tortional forces on the mandible as a result of its curved beam nature. They supported this view by quoting a study by Kroon et al, [18] who studied the phenomenon of tension-compression reversal under bite loads. These loads were placed just anterior to a fractured mandibular angle reduced and fixated with a single Champy miniplate. Levy et al,[19] were also quoted, they said that miniplate fixation of angle fractures may not be as efficient as described by other investigators and suggested that the fixation be augmented with a second plate.

In defence of his mini plating system and theory of the management of mandibular angle fractures Champy [20] replied to certain points raised in the study of Shetty et al.[16] Champy felt that 'stable mandibular osteosynthesis' using Champy miniplates had been wrongly criticised. He acknowledged the existence of tortional and shearing forces as well as the tension and compression forces described in his theories. He still felt, however, that the 'most harmful' forces are the distractional forces acting on the fragments. He believed the 'other' forces, namely tortional and shearing to be of lesser importance. He went on to state that neutralisation of the forces of traction (distraction) are adequate to suppress the adverse effects of the other forces. He cited an *in vivo* experiment on two volunteer patients with fractures at the angle of the mandible. The tensional forces were measured with the aid of strain gauges. Champy's conclusion was that the forces measured are markedly less than the magnitude of the forces proposed in theoretical models. This work led to the development of osteosynthesis plates with an elastic limit of approximately 900 MPa even though the traction strains according to Champy never exceeded 380 MPa. Champy made the point that in 1974 his plates were five times less voluminous than plates used by other investigators. Champy was of the opinion that the thin plate is advantageous in that it makes adaptation to the fracture site easier and enables direct modelling on the bone surface. Champy admitted that although theoretically the decreased thickness of the Lodde' plate should lead to a higher modulus of instability, a statistical analysis of his surgical results contradict this prediction. Champy further explained why he disagrees with Shetty et al [16] and why he feels that his theory of tension zone osteosynthesis is still valid. As the

masticatory muscles form a strong 'hammock' around the angle and ascending ramus of the mandible the proximal segment will be displaced upward and forwards around an axis going through the condyle. The result is that the fragments will be compressed together on the lower border and the described tension zone will be apparent on the external oblique ridge region. He felt that this will correct and neutralise the phenomenon of inversion of the forces described [16] which are only produced anyway when vertical masticatory forces are exerted in the ipsilateral molar region by the patient. Champy[20] further stated that due to pain and postoperative discomfort these forces will be significantly diminished as the patient will exhibit a degree of guarding and loss of function. Champy[20] felt that Shetty et al's study[16] used a localised vertical force applied to the fracture site without taking into account the influence of muscle contraction on the segments or the complexity of masticatory forces.

I find the conflict between the Champy and Shetty theories interesting. Both surgeons make valid points based on solid scientific evidence and personal experience. They do, however, have opposite views on their treatment of fractures of the mandible. Shetty is a firm supporter of rigid fixation provided by compression plate osteosynthesis while Champy feels that sufficient stabilisation is achieved by using monocortical appositional miniplate osteosynthesis. Shetty feels that Champy does not take into account the effect of torsional forces and Champy believes that Shetty does not take into account the stabilising effect of the muscles of mastication and the fact that the postoperative patient will not subject himself/herself to significant masticatory forces. I tend to agree with

Shetty in that rigid fixation is required in order to achi primary bone healing and will only occur with compression plate osteosynthesis. On the other hand Champy is correct that in most cases monocortical appositional miniplate osteosynthesis at the area of maximal tension will give an acceptable surgical result with secondary bone healing. The choice of surgical approach should therefore be dictated by the nature of each individual fracture. Most fractures can be treated adequately by using Champy's principles. An obvious benefit will be a decrease in patient morbidity since the fracture site can be treated from an intraoral approach with minimal exposure of bone surface; small plates and screws can be used and monocortical fixation can be employed thereby reducing chances of vital structure damage. Use of Shetty's approach will increase the morbidity of the procedure because the lower border will have to be approached from an extraoral approach. This produces extraoral scarring with the possibility of vital structure damage. The plates are bulkier and bicortical screw placement is used with added possibility of damage to the intra-osseous neurovascular bundle. My conclusion is that operator experience, individual patient treatment need and personal preference will dictate the type of fixation method used.

1.5 Fracture management in children

The need for a resorbable osteosynthesis system is most apparent in the treatment of mandibular fractures in children. The mandible continues to grow until development is completed and the long term retention of metal plates could have deleterious effects, the most obvious being a retardation and/ or distortion

of normal bone growth and a migration of metal plates and screws with time. This might need an additional surgical procedure for removal of the metal components.

Although the prevalence of mandibular fractures is lower in children than in adults, a significant number of fractures does occur in the paediatric patient. The basic principles of fracture management are similar in children to adults but these fractures are usually more difficult to treat because of a mixed dentition or a full complement of primary teeth. The mandible in the paediatric patient has a finer bone structure and is more susceptible to fracture. A study by Cossio et al,[21] examined the common presentations of mandibular fractures in 59 paediatric patients. Boys were affected three times as often as girls. The most common cause of fractured mandibles was motor vehicle accidents - 40% of cases. Falls accounted for 20%, pedestrian vehicle accidents were 13, 5% and bicycle accidents were 5,1%. Anatomically most fractures occurred in the condyle followed by the symphysis, the angle and the body of the mandible. 49% of the patients had multiple fractures. Treatment was by closed reduction and inter-maxillary fixation. Archbars were used in 32 cases and one patient had an open reduction of the condyle. Seven patients received open reduction and internal fixation with miniplate osteosynthesis. Complications were, one malocclusion, one combined malocclusion with a residual deformity, one case of post operative infection and one case of joint ankylosis with retarded facial growth. Conclusions of the study were that boys have a prevalence of mandibular fractures three times higher than girls; the most common cause of mandibular fractures was

motor vehicle accidents while the most common site of fracture was the mandibular condyle.[21] This study showed the need for an osteosynthesis system that could be used on children with minimal complications.

1.6 Complications of mandibular fracture management

A variety of complications have been encountered with the treatment of mandibular fractures by direct semi-rigid and rigid fixation. These are infections with or without abscess formation, osteitis or osteomyelitis, nonunion, malunion, bone loss and residual deformities. These possible complications have been used in the evaluation and comparison of different osteosynthesis systems.

1.6.1 Infections with abscess formation

Fractures of the mandible are occasionally complicated by infection. This occurs more in the mandible than in the maxilla and midface probably due to the difference in structure and vascularity of these bones. Factors that predispose to infection are the presence of a tooth in the line of fracture, poor oral hygiene, advanced periodontal disease, comminution of bone, existing lesions through which the fracture passes, malnutrition and any other debilitating disease. A further cause of infection is a mucosal breach of the overlying intraoral mucosa. Patients with an infection usually present with a swelling at the site of fracture; an associated submandibular or submental abscess may be present. Treatment requires antibiotic therapy, attention to the predisposing cause and incision and

drainage of the associated abscess. Infection may extend to an osteitis or an osteomyelitis possibly with the formation of sequestra. At this stage treatment usually requires sequestrectomy and decortication of bone adjacent to the fracture with incision and drainage of any associated soft tissue abscess if present. It is obvious that the use of a foreign body as an osteosynthesis material could predispose to infection. The inherent bio-acceptability of the material will, therefore, determine its value as an acceptable material.

1.6.2 Non union or fibrous union

A good osteosynthesis material will provide rigid fixation of the fracture to facilitate ideal healing. Non union or fibrous union usually occurs as a result of lack of good apposition of the fractured segments. It commonly arises in fractures of the angle of the mandible where the proximal fragment is badly displaced. Another cause of non union is the interposition of soft tissue between the fractured segments. Inadequate reduction with a non rigid fixation technique where the fractured segments undergo excessive movement during healing usually results in a malunion or a non union. Treatment usually requires a second procedure to debride, mobilize, realign and fixate the fracture site with a more rigid fixation technique.

1.6.3 Malunion

An acceptable osteosynthesis material should allow good bony apposition of the fractured bone segments from a technical point of view. A poor osteosynthesis material may not be strong enough to prevent postoperative deviation of the fractured segments. Occasionally a malunited fracture of the mandible poses an aesthetic or functional problem. A deviation of the mandible may result in an aesthetic disability. A serious malocclusion may occur where fractured segments of the mandible have united in the incorrect position. This usually produces an open bite with the patient complaining of difficulty in eating or chewing food adequately, which in turn, may result in serious disabilities. Malunion can further be complicated by a dislocation of the associated condyle with the condylar head uniting in an anterior medial position. Treatment of malunited mandibular fractures usually needs formal osteotomy with work-up including adequate radiographic investigation and preoperative model surgery in order to adequately plan the procedure.

1.6.4 Residual defects

Most treated mandibular fractures have no resultant disability. Disabilities that may occur vary in degree and severity and are obviously related to the degree and severity of the initial injury. Residual disabilities may manifest as neural damage.[22] Neural fallout may occur involving the inferior alveolar branch of the mandibular trunk of the trigeminal nerve on the fractured side. This manifests as

a loss of sensation affecting the mandibular teeth on the affected side as well as a loss of sensation involving the lower lip on the same side which is supplied by the mental nerve branch on that side.

1.6.5 The incidence and nature of complications associated with direct fixation techniques

Bruce, et al[23], in their study of fractures of the edentulous mandible reported that 16% of their patients had some major complication. The most common complication was fibrous union which occurred in 17 out of 167 fractures. Four of the fractures with fibrous union became infected, one healed uneventfully after incision and drainage while two others had delayed union. They attributed some of their complications to the fact that the edentulous mandible is atrophic and already has a compromised blood supply. The atrophic mandible is usually in the geriatric patient and often these patients are medically compromised with this possibly influencing to the quality of the healing process.[23]

In a further study Ellis et al[24], researched the infection rate in 65 patients whose mandibular fractures were treated by open reduction and internal fixation using two dynamic compression plates placed through an intraoral incision with a transbuccal trochar instrumentation technique. In the first 20 cases the screws were inserted without tapping the drill holes. In the remaining 45 cases the drill holes were tapped. Overall, 32% of the fractures developed infections requiring secondary surgical intervention. The rate of infection was higher in the fractures

where the holes were not tapped (46%) compared to those where the holes were tapped prior to screw placement (29%). Only one case was malunited with a resulting malocclusion. The conclusion of the study was that although the use of two dynamic compression plates was found to be relatively easy it resulted in an unacceptable rate of infection.[24]

A study by Nakamura et al[25] examined the postoperative complications of osteosynthesis with stainless steel miniplates in 110 patients with mandibular fractures. Complications noted were malocclusion in 3,6%, exposure of miniplates in 3,6%, delayed union in 1,8%, and infection in 1%. Nakamura believed that the complication rates were within acceptable limits even when treatment was performed later than 24 hours post injury. He concluded that stainless steel miniplates are effective and suitable for osteosynthesis of mandibular fractures.[25]

Traditionally, treatment of comminuted mandibular fractures has needed closed reduction with external fixation in order to avoid stripping periosteum from the bony segments. Smith et al[26], examined the success rate of direct rigid fixation used to treat 16 commuted fractures of the mandible in 15 patients. Where possible AO stainless steel reconstruction plates were applied; where smaller plates were required titanium miniplates were used. Results were that all patients had a satisfactory facial form post operatively. None required further treatment for facial asymmetry or malocclusion. Complications were observed in three patients. Two of these patients developed infections which were caused by

loose hardware. The study suggested that rigid fixation of comminuted mandibular fractures is a viable treatment option and is associated with minimal patient morbidity.[26]

Complications in 96 patients with mandibular angle fractures treated over a three year period with closed reduction techniques were evaluated by Passeri et al [27]. An overall complication rate of 17% was seen, with infection the most common problem, in 17 fractures. Four of these patients had an associated malunion and or malocclusion. The conclusion of the researchers was that mandibular angle fractures in an inner city population are associated with a high incidence of post surgical complications.[27]

1.7 Future treatment possibilities

A review of the literature has shown that a varying number of complications are associated with direct internal fixation of mandibular fractures. Factors that contribute to these complications can be classified into those that are associated with the individual patient and those that are associated with the fracture site and procedure itself. Patient associated complications are a function of the state of health of the individual patient and the patient's ability to tolerate the procedure. Factors associated with the fracture site and method of fixation employed can be classified as local factors. As has been listed in the literature a certain percentage of complications are associated with the type of plating system used and the methods of placement of this plating system. A second procedure is

often required in these cases in order to remove the plating system used. Currently resorbable bone plating systems are available on the market. Certain of these systems have been proven to be biologically inert and do not cause any foreign reaction. These systems could be of benefit in the treatment of mandibular fractures. A benefit could be that once resorbed no possibility of long term foreign body reaction to the plating system exists. A further benefit is clearly in the treatment of mandibular fractures in children. Metal plating systems may retard bone growth in children when retained for long periods of time. Metal plates and screws used in the cranium have been found to migrate in children associated with growth of the cranium. An exciting prospect for the future is the possibility of widespread availability and use of resorbable bone plating systems that function comparably to their metal counterparts in fracture site osteosynthesis.

CHAPTER 2

RESORBABLE OSTEOSYNTHESIS SYSTEMS

2.1 Characteristics of resorbable materials

2.1.1 Structure of resorbable materials used for osteosynthesis

Resorbable osteosynthesis systems currently in use are engineered from polymers, materials that have two important characteristics. The first is the large size of the constituent molecules and the second is the presence of repeating subunits of monomers joined by covalent chemical bonds. Homopolymers are comprised of only one type of repeating monomer subunit, whereas a copolymer is made up of two different types. These two different types of monomer if arranged in random sequences are called 'random copolymers' or if in alternating reproducible segments or blocks are then called 'block copolymers'. A 'blend' of two or more types of polymer is achieved by physically melting, mixing and cooling the polymers. These polymer blends comprise polymers with physically intertwined chains that are not chemically bonded together. The basic polymer types are indicated in Figure 2.1.[28]

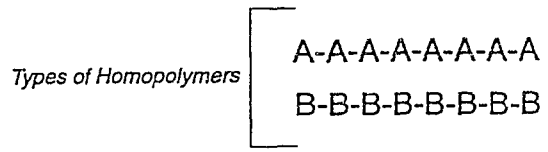

Random Copolymer

A-A-B-A-B-B-B-A-A-B-B-A-A-A-A-B-A

Block Copolymer

A-A-A-A-A-B-B-B-B-B-B-A-A-A-A-A

Blend of Two Homopolymers



Figure 2.1: Basic polymer types

Polymer chains can be arranged in a linear pattern or may be branched. Branched polymer chains may be crosslinked with neighbouring polymer chains. (Figure 2.2). These crosslinks are due to the chemical bonding of adjacent polymer branches. A mass of crosslinked polymer is therefore a single molecule of practically indeterminable molecular weight.

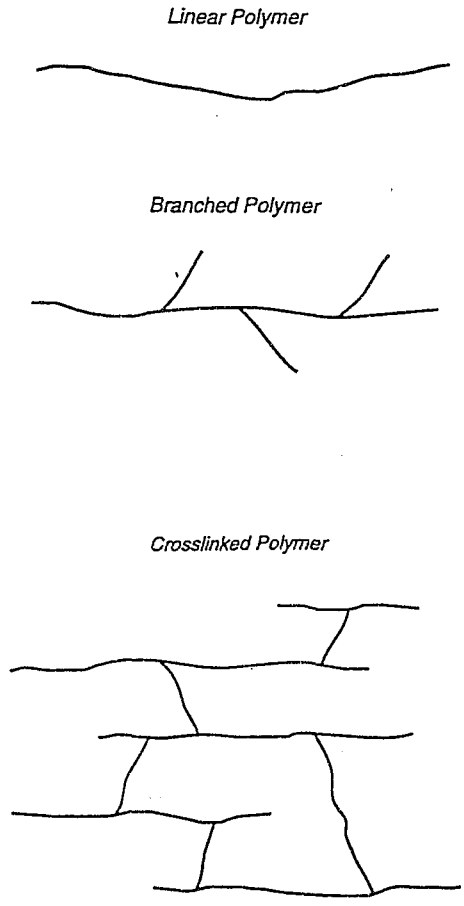

Figure 2.2: Types of gross polymer chain structure

2.1.2 Structure related to resorption characteristics of resorbable copolymers

The benefits of a resorbable plating system are directly related to the resorption characteristics of the particular polymer or copolymer combination used. Polymer is structured into three different types of regions, namely amorphous (unordered) regions, crystalline (ordered) regions and semi-crystalline (ordered/unordered)

regions. The more crystalline a polymer is, the longer is its resorption time before being metabolised in the body. In order for a polymer to contain significant crystalline regions certain criteria have to be met. These crystalline regions are made up of bonded molecules of similar size and shape which is facilitated by polymer chains with specific repeatability along their lengths. A homopolymer will therefore have many long segments lying close to and parallel to one another. On the other hand, a random copolymer is extremely difficult if not impossible to crystallise. Semi crystalline polymers have amorphous polymer regions between crystalline regions.

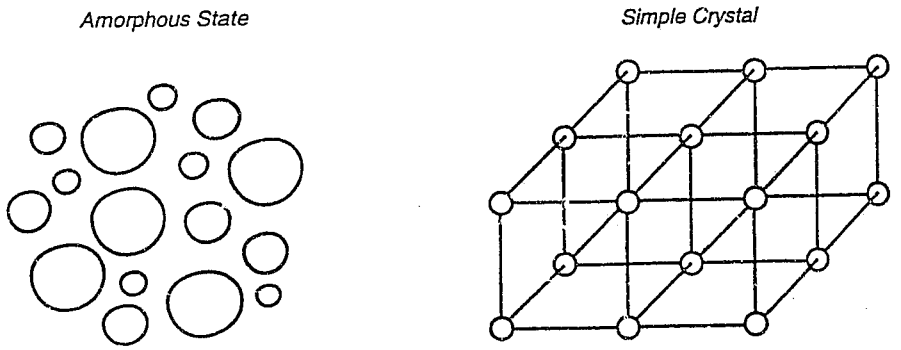

Figure 2.3: Crystalline and amorphous polymers

2.1.3 Thermal characteristics of polymers

The glass transition range is the temperature range above which a polymer is soft and flexible. This property has clinical usefulness because the polymer plate can be heated and moulded to lie passively against the fractured segments of bone to be stabilised. This temperature range is relatively narrow. Below this range of temperatures the polymer is stiff and brittle. The glass transitional temperature (Tg) is the midpoint temperature of the glass transitional range (Figure 2.4). An amorphous material like candle wax will gradually become softer as it is heated towards a liquid state. A crystalline substance like ice will, however, change from the solid to the liquid stage at a definite temperature of 32 degrees Farenheit (0°C). Materials with both crystalline and amorphous regions will have a melting point and a glass transition temperature at which they are flexible. The greater the crystalline content of the polymer the narrower is the glass transition range at which the material is malleable.[28]

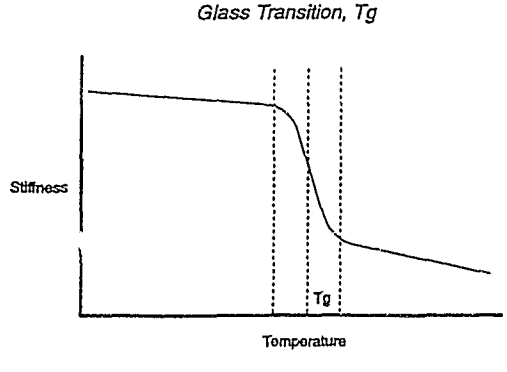

Figure 2.4: The glass transition temperature and glass transition range

2.1.4 Mechanical behaviour of polymers

Mechanical properties are defined by the stiffness, strength and the resilience of the polymer. An 'intensive property' does not change with the size of the material specimen, whereas an 'extensive' property changes in relation to the size of the polymer specimen.

Polymer deformation can be divided into two types. With elastic deformation the material will revert to its original shape or size after the load has been applied and released. Plastic deformation occurs when the elastic limit of a material has been exceeded and deformation caused by the load remains and is therefore permanent. Polymers are viscoelastic materials and their mechanical properties are time dependent. A polymer tends to be stiffer and more brittle if a load is applied to it quickly, therefore a load that is applied slowly will cause the polymer to be more flexible and less brittle.[28]

2.2 Polymer processing

A variety of methods are in use for the processing of polymer products. In injection moulding techniques the polymer pellets are heated to their glass transitional temperature and forced under pressure into metal pre-formed templates. They are then allowed to cool and are extracted from the moulds. Extrusion techniques involve a continuous bar of polymer that is heated and ejected from a die. It is cut into the correct lengths once it has passed through

the die. Orientation techniques involve the heating of a polymer to render it soft but it is never heated past its glass transitional temperature. The heated polymer is then pulled in a controlled fashion through a die. This aligns the polymer chains in the direction of pull, which strengthens the material in that particular direction of force application. With compression moulding techniques, a polymer resin sheet is softened by heating it on a heat platen then pressing it into a form between two heated moveable plates. Casting techniques involve dissolving the polymer in a solvent and pouring the solute into a mould until it reforms into the solid state. In machining the polymer is machined on a lathe or milling machine; the material retains its solid state and is physically shaped with a cutting tool.[28]

2.3 Ideal characteristics of a bio-resorbable material

A functional bio-resorbable implant material should exhibit certain characteristics to qualify for use in the human body. The material should retain enough strength for long enough to be effective for osteosynthesis. Neither the material nor its breakdown products should cause any adverse reactions in the body. The material should be fully degradable and should disappear completely from the site of placement and the rest of the body. Then, once the material has disappeared there should be no residual reaction or memory of its presence thereby circumventing the problems that may be associated with long term metallic implants, namely the risk of causing improper bone growth as well as transcranial migration in children. Bone weakening or stress shielding at the site of metal implant placement would also be avoided.

2.4 Polymer resorption

The need for complete polymer resorption with minimal residual effect has already been outlined. Polymer resorption occurs in two phases. The first phase is hydrolysis where water enters the polymer and chemically reacts with the polymer chains to break apart these chains thereby initiating degradation. The polymer then begins to lose shape; it starts breaking apart to form tiny pieces called particulates that extrude from its surface. The second phase, or metabolic phase, occurs within macrophages once they have ingested these particulates. The macrophages metabolise the polymer particulate to eventually form carbon dioxide and water (Figure 2.5). The sequence of events is initiated by the shortening of the polymer chains and the reduction in molecular weight of the polymer caused by the hydrolysis. This weakens the polymer and the mass of the polymer decreases. The strength of the implant will therefore decrease measurably before there is a significant change in actual mass of the implant .[28]

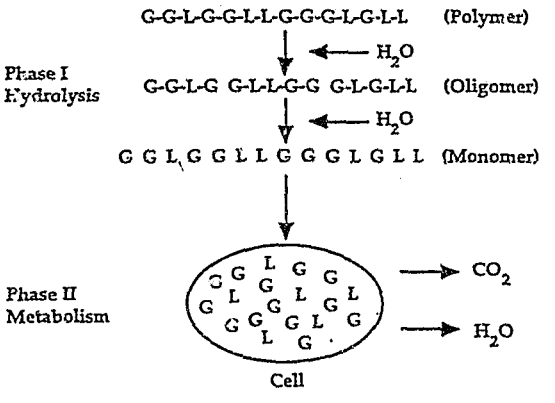

Figure 2.5: Two-phase degradation of bio-resorbable polymer

2.5 Physiological response to bio-resorbable polymers

All types of implant materials, whether they are bio-resorbable or not, are initially encapsulated in a fibrous membrane. While titanium and other metallic implant materials will remain inert in the fibrous capsule unless sepsis supervenes, the bio-resorbable implant materials will begin to hydrolyse. Normal healing occurs with a mild inflammatory reaction. As the mass of the bio-resorbable material decreases more fibrous tissue forms to fill in the residual gap left by the resorbed implant material. The amorphous polymers will resorb more quickly than the crystalline polymers because the amorphous regions of the polymer are more hydrophilic and will therefore undergo hydrolysis first. The

tightly packed crystalline regions of the polymer form relatively impermeable or hydrophobic regions of the polymer with less hydrolysis and degradation occurring. The crystalline regions are bound together by the amorphous interzones which therefore function as a 'glue'.[28]

2.6 Polymer processing and packaging

As a result of the rapid initiation of the degradation process by water the manufacturing process must occur under carefully controlled conditions to minimise the possibility of this occurring which would result in a reduction in polymer strength to below specification. Sterilisation procedures must also be carefully controlled in order to keep the polymer at its maximal strength and not to initiate degradation. This is usually achieved with gamma irradiation or ethylene oxide. Packaging of the polymer must maintain sterility and prevent any moisture from reaching the product. Metal foil packaging is usually used. Dessicant pouches are also usually included to absorb any moisture that may reach the polymer. Expiry dates and shelf life of the polymer must be adhered to as an element of degradation will still occur over a period of time and degradation will occur at a higher rate as temperature increases.[28]

2.7 Types of bio-resorbable polymer

Bioresorbable polymers are subdivided into 3 broad types depending on their biochemical composition and properties.[Table 2.1]

Table 2.1 : Types of bio-resorbable polymer.

POLYMER TYPE	
Alpha-hydroxy acids	These are most commonly the glycolic acids, L-lactic acid and dioxanone. Copolymers of L-lactic acid and glycolic acid (PLLA/PGA) are also commonly used. These copolymers tend to have a low crystalline content.
Polyglyconate	This is a copolymer of two parts glycolic acid and one part trimethylene carbonate.
Other copolymer combinations	Eg: Lactosorb bio-resorbable copolymer.

2.8 Complications from bio-resorbable materials

Four main types of complications have been reported with the use of bio-resorbable implant materials. These are both acute and more chronic.[Table 2.2].

Table 2.2: Complications associated with the use of bioresorbable materials

COMPLICATION	
Sterile sinus formation	5-8% cases associated with the Polyglycolic acid rod and pin implants have resulted in the formation of sterile sinuses usually within a period of three months of placement.[28]
Pronounced fibrous encapsulation of the implant	The use of poly-l-lactic screws and plates in facial bone and zygomatic fractures have resulted in pronounced fibrous encapsulation. Residual crystals of poly-l-lactic acid were found up to 5.7 years post placement.[28]
Bone resorption	Bone resorption has been reported with the use of polyglycolic acid pins in the treatment of malleolar fractures. This osteolysis resolved spontaneously one year post operatively.[28]
Synovitis and severe inflammation	Synovitis and severe inflammatory reactions have been reported with the use of Suretac polyglyconate devices in the shoulder.[28]

2.9 Studies on resorbable implant materials

A study by Finnegan et al [29] investigated the use of polyglycolic/polyglactic acid derivatives as screw fixation in potentially unstable fracture patterns. In the study ten juvenile sheep underwent an open proximal femoral epiphyseal osteotomy. After the femur had been osteotomised the proximal fragment was displaced a few millimeters in a posterior and inferior direction. In half the sheep fixation was with stainless steel screws; in the other half polyglactic acid screws were used. The first two sheep from each group where fixed with a single screw; the remaining six sheep were each fixed with two screws. None of the animals were immobilized postoperatively. Radiographs were taken immediately postoperatively and every four weeks until the sheep were killed at 12 weeks. All animals with single screw placement began limping after four weeks thereby indicating instability of the fracture site. At specimen recovery all single screw animals and all of the animals that received polyglactic acid implants had developed non-union at the osteotomy site. Animals that received fixation with two stainless steel screws healed completely. Histological examination revealed no evidence of peri-implant infiltrate, foreign body reaction or osteolysis. The conclusion of the study was that although the experimental model used was potentially more unstable than the majority of clinical cases the resorbable screws, at least at the time, could not be recommended as a method of fixation where inherent instability is likely. Histological findings proved that no inflammatory reaction or osteolytic process was found at the screw placement sites.[29]

A study, published a year later, by Tams, et al[30], evaluated bone healing after mandibular swing osteotomies that were fixed with bio-degradable polyglactic bone plates in four patients. A step osteotomy was treated with two polyglactic acid bone plates. A straight osteotomy was treated with one polyglactic acid bone plate. Bone healing was uneventful in all patients. Callus formation was observed only in the patient with the straight osteotomy. Radiographic changes were observed in one remaining patient after 5,5 years. Histological examination showed a nonspecific foreign body reaction which was evident on highly crystalline polyglactic acid remnants that were still present at the fracture site. The conclusion of the study was that polyglactic acid bone plates did provide enough strength to enable undisturbed bone healing. Long term degradation results were found to be comparable with the results of other studies on polymerized polyglactic acid implants.[30]

A self-reinforced polyglycolic acid membrane was used as a bio-resorbable material for orbital floor repair by Mac Vicar et al [31]. They noted no instances of infection, either superficial or deep. They also reported no clinical consequences as a result of the hydrolysis of the polyglactic acid panel. In their opinion there are no adverse effects from the absorption of the polyglactic acid material. This study showed that the polyglactic acid resorbable plate material is biologically inert in the human body. Surgical correction of orbital floor defects often requires the use of autogenous bone allografts to restore function. The use of autogenous grafts, however, increases the morbidity associated with the repair. A wide variety of alloplastic materials have been used for orbital floor reconstruction,

these include silicone, Teflon, ceramic polymers, polymethylmetacrylate, and polyethylene. The Teflon reinforced silicone materials have been the most widely used. Because they are bio-inert and non absorbable they become encapsulated by fibrous tissue and remain a potential nidus for infection. Mac Vicar and colleagues therefore felt that a material with a positive or bio-active character would be more suited to orbital floor reconstruction and proposed the bio-resorbable woven self-reinforced polyglycolic acid membrane that they studied.[31]

Eppley, et al, [32] compared healing in calvarial bone grafts that were fixated with resorbable and metallic implant fixation techniques. An animal calvarial bone graft healing model was used to compare the effects of a resorbable plate fixation system with that of conventional metallic fixation plates. Twenty mature rabbits were used in which bilateral parietal bone grafts were fixed into position with a titanium mesh plate on one side and a polymer mesh plate on the other site. The resorbable polymer used was the Lactosorb® polyglactic/polyglycolic copolymer panel. Histological evaluation compared the osteotomy line healing, the tissue response to the fixation material, and the amount of resorbable bone plate degradation after 2, 6, 9 and 12 months. At the two month stage no changes were noted in the dimensions of the resorbable plate. Both the grafts fixed by metal and polymer plates exhibited incomplete healing along the osteotomy lines. After six months the percentage reduction in the dimensions of the resorbable plates was 66%. Significant vertical shortening of screw length was also noted. Complete bone healing was seen along all osteotomy sites of both bone graft models. At the nine-month stage less than 1% of the resorbable mesh plate

remained. The remnants were only a small film beneath a collagenous capsule. On examination of the screw holes no residue was seen. After one year no evidence of polymer was seen either on the external cranial surface or within any of the screw holes. Bony union was observed across all osteotomy sites although screw hole outlines persisted. According to the researchers the resorbable plates demonstrated fixation stability similar to that of metal. A comparable osteotomy line healing was noted between the two materials. No adverse local inflammatory reaction was seen as the polymer progressed to complete degradation by one year.[32]

The application of bio-absorbable fixation devices in reconstructive craniofacial procedures in paediatric patients was evaluated by Kumar et al [33]. Twenty two cases were reviewed in which bio-absorbable plates and screws were used in craniofacial surgery for reconstruction over a seven month period. Postoperative follow up ranged from 2 to 16 weeks. The evaluation of the fixation devices looked at satisfactory fixation at the time of procedure while postoperative follow-up evaluated clinical wound healing, signs of infection, local inflammation and visibility or palpability of plates through the skin. Only one of the 22 patients presented with unsatisfactory wound healing. Fixation provided by the plates was satisfactory. No plates were visible through the skin but two patients had plates that were palpable 4 months post placement. The conclusion of the researchers was that their early experience with resorbable bone plate fixation suggested that it is an attractive option in paediatric plastic and craniofacial

surgery. They commented that with further experience this technology might be the standard of care in reconstruction of the paediatric calvarium.[33]

Montag, et al, [34] evaluated the Lactosorb® absorbable bone plate system over a 10 month period in 35 paediatric craniofacial patients. Of the 35 patients 22 had craniosynostosis, three had fibrous dysplasia, two had cranial vault defects, one had deformational plagiocephaly, two had malar fractures, one had neurofibromatosis, one had congenital anopthalmia, one had Goldenhar's syndrome, one had a frontal sinus mucocoele, and one had nasal encephalocoele. Each of the patients required cranial vault and/or periorbital reconstruction for which Lactosorb® 1. 5 millimetre thick mesh panels were used. Approximately 30 screws generally 4 to 5mm long, were used per case. Postoperative evaluation was at two weeks, one month, three months, and six months. At each visit the patients were assessed for wound healing, bone contour, stability, and visibility or palpability of the Lactosorb® plates. No complications were found associated with wound healing, contour, or stability. Palpable plates were identified in 26% of the patients but none were palpable after three months. The researchers concluded that the Lactosorb® bio-absorbable system proved itself to be reliable and easy to use in providing rigid bone fixation. They felt that the extra steps involved in its use did not increase the overall length of the operative procedure. They further commented that no fixation related complications were encountered in their series although they conceded that more experience and a longterm follow-up period are needed before definitive conclusions can be drawn. [34]

Eppley, has been intimately involved with the development and testing of the Lactosorb® product since its inception in the United States. A study by Eppley, et al, [35] documented the use of the Lactosorb bio-absorbable craniomaxillary fixation system in the treatment of 30 midface fractures. The fractures were, 3 LeFort I fractures, 2 LeFort III fractures, 13 zygomatico-maxillary complex fractures, 1 zygomatic arch fracture, 2 infraorbital rim fractures, 8 orbital floor fractures and 17 orbital rim fractures. Screw diameters were 2 mm and 1,5 mm. According to the researchers the application of the resorbable devices to the curved contours of the midface and orbit was uncomplicated. They commented that, in their experience, the use of a metal template to contour the heated Lactosorb® plate or panel, resulted in a quicker application time of the plate or panel than the time used to bend and contour titanium fixation plates. They further found that the placement of the screws with the method of thread tapping was uncomplicated. This was largely due to the presence of good bone in the region of the midface with the exception of the anterior maxillary sinus wall, which could pose a problem for resorbable screw retention. The patients were followed for two-years to study with 325 resorbable devices. More than half of the treated patients reached the critical one-year post-operative post-implantation period. This post-operative time is viewed as critical due to the complete resorption of the Lactosorb®, polymer at one year. None of the possible implant related complications occurred in any of these patients. These possible complications are erythema of the overlying skin, infection, fracture instability, relapse or radiographic evidence of osteolysis. In the patients who were more

than 6 months post-operative it was found that the devices were no longer palpable, and that fracture lines were showing radiographic evidence of healing. The only complication in the treatment group was one patient who had an ectropion of the lower lid after an orbital floor reconstruction. The conclusion of the study was that resorbable fixation devices can be successfully used in the treatment of the facial fracture patient. This particular study did however exclude patients with mandibular fractures because of the higher stress load placed on the mandible during function. The researchers commented on the ease of application of the Lactosorb® product in the difficult mid-facial region, as long as good bone was available for screw hole tapping. [35]

Another paediatric study was by Goldstein, et al, [36] who reported 8 paediatric patients, mean age 3,2 years, with congenital craniofacial deformities. Seven of the deformities were craniosynostosis and one was an encephalocele. All patients required a bi-frontal craniotomy with concomitant cranial vault or orbital reconstruction. All osteotomy sites were fixed plates and screws were from the Lactosorb® bio-resorbable cranio-fixation system. The plates were cut from a prefabricated mesh panel. Results of the study showed no perioperative or postoperative complications in seven of the eight patients. The researchers reported in one patient that the drill holes after tapping were too large for the prescribed screws. Despite extensive examination of the drill bit and tap, no clear explanation was found. The manufacturer modified the drill bits and tap and no subsequent problems have been found. Initially the plates were palpable, by three months the profile of the plates had significantly diminished and by six

months this was minimal. This study supported the use of resorbable fixation products in congenital craniofacial deformities with excellent short-term results. The researchers await longer-term results, which will be obtained when the patients, cranial bones are 90% of adult size at approximately four years of age.[36]

2.10 Lactosorb® bio-resorbable osteosynthesis system

The Lactosorb® bio-resorbable copolymer is composed of poly-l-lactic acid and polyglycolic acid in a ratio of 82:18. This copolymer degrades by hydrolysis into lactic acid and glycolic acid, which undergo further degradation via the Krebs cycle into carbon dioxide and water. The Lactosorb® copolymer is a 'random copolymer' which has a low crystalinity. The products comprising the Lactosorb® bio-resorbable osteosynthesis system are processed through the orientation process. The product cannot be autoclaved or sterilised/resterilised with alcohol, Cidex, ethylene oxide or other disinfectant solutions and must be discarded once removed from its sealed container. The product was developed by Biomet of Warsaw, USA. The Walther Lorenz Surgical Company, a subsidiary of Biomet, has received US Food and Drug Administration approval to market Lactosorb® for the following indications:

- Comminuted fractures of the naso-ethmoid infra-orbital areas.
- Comminuted fractures of the frontal sinus wall.
- Trauma of the mid-face or craniofacial skeleton.
- Reconstructive procedures of the mid-face or craniofacial skeleton

The copolymer retains significant strength after two months and undergoes complete resorption within one year post placement. It has been clinically used as PolySurgiClip, a vascular ligating clip. No clinical research has been published thus far on the use of the Lactosorb® plating system for the treatment of mandibular fractures so the current study is to evaluate the product according to several predetermined criteria as a treatment option for mandibular fractures.[28]

2.11 Lactosorb® plate design

The Lactosorb® plate design had to be modified to cater to the unique needs of a copolymer material. The standard metal plate is of a uniform width and uniform thickness of 2mm. The Lactosorb plate however differs from its metal counterpart. Although of uniform width, the thickness of the plate varies with a 2mm rail along the edges and a 1.5mm recess in the centre to accommodate the screw heads. The plates are available in different forms (Appendix A) and are fixed to the bone using Lactosorb® screws. Lactosorb® plates are temporarily malleable when heated in the heat pack provided with the kit.[28]

2.12 Mechanical properties of Lactosorb®

Mechanical testing of the Lactosorb® polymer osteosynthesis system has been performed according to stringent, standardized criteria. The bio-resorbable

polymer loses strength over time after implantation so testing needed to be conducted at time 0 as well as at various set periods over the resorption process. All the tested Lactosorb® products underwent the same processing as the clinical product with respect to packaging and Eto sterilisation. All testing took place after the devices were submerged in a phosphate buffer bath (pH of 7.23 - 7.31) after 2, 4, 6 and 8 week intervals and all the Lactosorb® plates were heated with the prescribed heat pack prior to testing or placement in the in-vitro bath.[28]

2.12.1 Testing methods used by manufacturer:[11]

Testing of screws

1. Pull out test: The screw pull out test records the point at which the screw is pulled out of the sample material. This pull out strength is usually a function of the thread depth and pitch and the density of the sample material.[11]
2. Single shear test:: The shear test records the strength of the screw as a force is applied perpendicular to the axis of the screw.[28]

Testing of plates

1. Tensile strength test: Force is applied along the axis of the plate and the point of fracture of the plate along the axis is recorded.[28]
2. Three point bend flex test:: This tests the flexural strength of the plate which mirrors some of the forces that the plate will be subjected to in vivo.[28]

2.12.2 Test results

Testing of screws

1. Pull out test:: The test compared the mean screw pull out of a 1.5mm Lactosorb ® screw with a 1mm metal screw. [28] The initial pull out strength of the resorbable screw was comparable with that of the metal screw and retained its strength for a period of two weeks before showing any signs of weakness. By four weeks the resorbable screw had lost a minimal amount of pull out strength. By six weeks the screw had lost approximately one quarter of its initial pull out strength and by 8 weeks post placement the pull out strength was approximately one quarter of the initial value. The mean screw pull out strength of a 2mm Lactosorb® screw is principally the same as that of the above mentioned 1.5mm screw. The strength values of the 2mm screw are however approximately one third higher than that of the 1.5mm screw. [11]
2. Single shear test:: The mean single shear load of the 1.5mm Lactosorb® screws remained remarkably constant for a six week period. At eight weeks however, a marked decrease in shear strength of the 1.5mm screw was noted. The shear load tests for the 2mm Lactosorb® screw mirror the results achieved in the above 1.5mm screws. The shear strength values of the 2mm screws were however double those of the 1.5mm screws.

Testing of plates

1. Tensile strength test: The mean tensile peak load of a 1.5mm Lactosorb® plate was compared with that of a metal micro-plate. The initial peak tensile strength of the Lactosorb® plate was slightly more than half that of its metal counterpart. The tensile strength reduction of the Lactosorb® plate remained relatively constant until the 6-week period. At eight weeks the plate tensile strength was reduced to approximately one third its original value.

2. Three point bend flex test:: The mean peak flex load strength of a Lactosorb® 1.5mm plate compared to a metal micro plate showed a greater initial flex strength of the Lactosorb® plate. At two weeks the flex strength of the Lactosorb® and the metal micro plate were practically equal. The Lactosorb® plate lost minimal strength by the 6-week period. At eight weeks the Lactosorb® plate still retained almost half of its flexural strength.

2.13 Objectives of the study

The clinical studies reviewed and the laboratory test results have shown that Lactosorb® has suitable biocompatibility and strength to be used in mandibular fracture fixation. The objective of this study was to evaluate the Lactosorb® copolymer resorbable bone fixation system in the treatment of mandibular fractures in a series of patients.

CHAPTER 3

MATERIALS AND METHODS

3.1 Ethical approval for study

As this study involved the clinical evaluation and treatment of patients, the protocol was approved by the Committee for Research on Human Subjects (Medical) of the University of the Witwatersrand before the study began. [clearance No: R14/49). Patients who fulfilled the study inclusion criteria received an informed consent form, which was signed by each participant after careful explanation. (Figure 3.1)

3.2 The clinical study

The clinical study was done in the Johannesburg group of four teaching hospitals served by the Division of Maxillofacial and Oral Surgery, Department of Surgery, University of the Witwatersrand. These are Johannesburg General Hospital, Hillbrow Hospital, Baragwanath Hospital, and the Oral and Dental Teaching Hospital.

Dear patient

A detailed clinical and radiological assessment of your condition has revealed that you have a fractured lower jaw. In order to repair the damage it is necessary to perform an operation under general anaesthetic. At this operation it will be necessary to reset your jaw into the correct position and to hold it in this position while it is healing. The standard method of keeping your jaw in this correct position is by screwing a plate across the broken ends of the jaw bone thereby stabilising it. These bone plates and screws are normally made of a metal called titanium which remains in place for the rest of your life and has been proven to be accepted by the body as a body friendly substance that normally does not cause any inflammation or infection. Very rarely these plates have to be removed in a second operation if they become loose or if the area of the fracture becomes infected. I will be grateful if you would agree to participate in a study to test a new type of bone plate and screw. These devices dissolve on their own after about one year. As it only takes six weeks for your jaw to heal, the plates last for more than long enough and then they disappear. The benefit to you is that the plates are eventually removed by your body. We will select certain patients for the study who will receive these dissolving plates. Participation is completely voluntary Should you not wish to participate in the study it will not affect your treatment in any way. You will then receive the titanium plates and screws given in the Maxillofacial unit at your hospital. Possible complications associated with both treatment methods include infection, blood vessel or nerve damage, pain and swelling following surgery, delayed wound healing, the fracture not healing and the device loosening or extruding through the skin outside or in the mouth. Should you elect to participate in the study your jaw will be fixed in an operation under anaesthetic and will also be wired closed for two weeks which is standard for treatment of jaw fractures. At your two week check-up appointment the wires will be removed. You will then need to attend further check-up appointments at six weeks, three months and six months after the operation. At all the check-up appointments your progress will be evaluated with a clinical examination of your mouth and X-rays will be taken and examined. If you are happy to participate in the study please sign below. A copy of this form will be given to you.

Your co-operation is appreciated

DR LANCE KRUGER (3210111 Code 6282)

I ..... , hospital number ....., have been fully informed of the requirements of a study to investigate resorbable bone plates and screws and agree to participate.

Signed:..... Address:..... Telephone:.....

All information obtained in this study will be kept confidential, you will not be identified in any report.

Figure 3.1 Informed consent form

3.3 Patient selection

3.3.1 Inclusion criteria

The following had to be present for inclusion in the study

- Reliability for follow-up: a fixed place of residence in the Gauteng area and a stable employment history and current employment address.
- Number of fractures: an isolated mandibular fracture with no other facial fractures.
- Age of fracture: less than 2 weeks old and involving the area between, and including, the symphesis and the angle of the mandible.

3.3.2 Exclusion criteria

If any of the following were present, a patient was not included in the study.

- Patients who were HIV positive or diabetics due to a higher risk of infection than other patients when foreign materials are placed in tissues.
- Patients who were medically unfit for a general anaesthetic.
- Patients with condylar or ramus fractures.
- Patients with an incomplete dentition where the provision of a stable occlusion was not possible.

3.4 The treatment group

Twelve patients who fulfilled the inclusion criteria and who gave informed consent were the study sample. The fracture sites were treated with Lactosorb® standard resorbable fixation plates or panels cut to the correct size (Figure 3.2).

A titanium template, supplied with the kit, was placed over the buccal cortex of the reduced mandible at the proposed fixation site to contour the Lactosorb® panel (Figure 3.3). The Lactosorb® plate was heated in the standard chemical heat pack which was activated by injecting 120 ml sterile water into it followed by agitating the water/crystal component of the heat pack (Figure 3.4) then shaped against the template. Once the Lactosorb® plate had regained its rigid state it was placed at the fracture site. Fixation of the Lactosorb® plate to the bone segments was achieved by drilling the necessary holes with a 2mm bur followed by tapping with the Lactosorb® 2.4mm tap (Figure 3.5) for Lactosorb® 2,5 mm by 9 mm screws (Figure 3.3). The screws were placed with the Lactosorb® hex head screwdriver which shears off the screw head abutment once the screw is secure (Figure 3.6). Figure 3.7 shows the Lactosorb® panel in place in the symphysis of the mandible, secured with screws each side of the fracture.



Figure: 3.2 Lactosorb 2mm panel.



Figure 3.3: Titanium template used for contouring of the Lactosorb® panel, Lactosorb® screws are also shown



Figure 3.4: Heat pack for contouring the Lactosorb ® plate or panel



Figure 3.5: Screw tap



Figure 3.6: Lactosorb® Hex screwdriver



Figure 3.7: Lactosorb© panel secured *in situ*

Each patient's history, preoperative details and postoperative follow-up were recorded on a standard form. (Figure 3.8).

3.5 Patient history and details

PATIENT NAME:..... AGE: ..... DATE:.....

PATIENT NUMBER:..... GENDER:.....

ADDRESS:.....

CONTACT NUMBER/S:.....

Date of injury	
Cause of injury	
Date of surgery	
Date of discharge	
Allergies	
Nerve function before surgery	Paraesthesia [L] Paraesthesia [R] Anaesthesia [L] Anaesthesia [R]
Removal from study - state reason	

SITE OF #	MIDLINE #	RT MANDIBLE #	LT MANDIBLE #
1	Symphysis		
2		Parasymphysis	
3			Parasymphysis
4		Body	
5			Body
6		Angle	
7			Angle

CODE	1	2	3	4	5	6	7
Clinical signs	No abnormal signs	Acute Sepsis	Chronic Sepsis	Mobility of Fracture site	Malunion	Dehiscence	Persistent pain

	A	B	C
Radiographic deviation	<4mm	4-6mm	>6mm

Figure 3.8 Diagnosis and postoperative assessment form

3.6 Basic treatment plan

Once patients had joined the study the following plan was followed for each by Registrars or Consultants in the Division of Maxillofacial and Oral Surgery.

- A preoperative panoramic radiograph was taken with the same Siemens Orthophos C D panelipse machine at 60-70 Kv.
- Surgical open reduction and fixation of the fracture was according to the standard departmental protocol as follows. All patients were treated under general anaesthesia. Teeth in the line of fracture were removed. Exposure of the fracture site was through a buccal or labial full mucoperiosteal flap with a relieving incision over unaffected bone. The fractured bone ends were mobilised, reduced and fixated with the allocated bone panel and screws. Primary closure of the mucosa was with 3/0 chromic suture material on a cutting needle. All patients in the study were maintained in inter-maxillary fixation for a two week period.
- The standardised preoperative and postoperative anti-microbial regime used was :

  Glycothymol mouthwash 10ml three times a day before operation for the tds 24 hours and for 4 days after operation.

  Amoxil 500 mg tds 24 hours preoperatively and for 4 days postoperatively.

  Flagyl 400 mg tds 24 hours preoperatively and for 4 days postoperatively.

  Erythromycin 500 mg tds 24 hrs preoperatively and for 4 days postoperatively, instead of Amoxil, for patients allergic to penicillin

- All patients were instructed to follow a semi-liquid diet for 6 weeks after surgery.
- Patients were discharged from the ward one day after surgery once a postoperative panoramic radiograph had been taken .
- Intermaxillary fixation (IMF):

  Patients were kept wired in intermaxillary fixation until their clinical and radiographic evaluation two weeks postoperatively at which time the interarch fixation was removed.

3.7 Treatment assessment

3.7.1 Radiographic evaluation:

A similar study by Renton and Weisenfeld[9], compared three techniques of mandibular fracture osteosynthesis using titanium plates. In their study displacement was assessed clinically using the occlusion as a guide. No radiographic measure of displacement was used. In this study I proposed to utilise panoramic radiographs to quantify displacement of the fracture site throughout the healing phase. These radiographs proved to be unsuitable. Distortion and non-reproducibility of these produced images that were too poor for exact measurement. The apposed fractured bone ends were therefore assessed on the standardised panoramic radiographs taken immediately after operation, at 2 and at 6 weeks, at 3 and at 6 months by measuring the amount of deviation of the segments at the lower border of the mandible relative to one

another. Deviation of less than 4mm was classed as a minimal displacement, 4-6mm as moderate displacement and greater than 6mm as severe displacement. Displacement of the approximated bone segments compared to the immediate postoperative result was chosen to indicate the efficacy of the plating system used.

3.7.2 Clinical evaluation:

The clinical evaluation was done concurrently with the radiographic evaluation at 2 weeks, 6 weeks, 3 months and 6 months postoperatively. The patients were examined and evaluated according to the following eight criteria:

[1] Acute sepsis was indicated by a temperature higher than 37°C associated with any pain, pus drainage or abscess formation.

[2] Chronic sepsis was diagnosed by radiographic signs of osteolysis with or without a draining sinus this being indicative of a low grade destructive process.

[3] Non union was indicated by mobility of fracture site on manual mobilisation by the examiner at the time of evaluation.

[4] Malunion was noted by deviation of the occlusion from a position of maximal intercuspation post surgery and can be seen clinically by a malocclusion of the teeth.

[5] Dehiscence was shown by an intraoral mucosal breach or extraoral skin breakdown at incision sites or in the area of the fracture.

[6] Persistent pain at fracture site was recorded at any of the post-operative visits once the patient was discharged from hospital but immediate post-operative pain existing at the time of discharge was not classed under this category.

[7] Nerve function was compared with that present preoperatively. A paraesthesia or anaesthesia at the distribution sites of the inferior alveolar branch of the trigeminal nerve indicated neural damage and was determined by pain discrimination with a needle prick test.

[8] Palpability of the device as assessed by clinical palpation of the bone plate under the mucosa over the site of fracture fixation and was recorded as being palpable or not.

Success was defined as a stable fracture site on manual mobilisation together with an intact occlusion and no radiographic signs of osteolysis at the fracture site at 6 weeks post operatively.

3.8 Data analysis

For this study descriptive statistics were used. Careful consideration at the study design stage indicated that the rate of suitable fractures, follow up of patients and time available did not allow collection of a comparable control group with treatment by metal plating. The loss of individuals to follow up might reduce sample size to below that suitable for statistical analysis.

CHAPTER 4

RESULTS

4.1 Demography of sample

Of the 12 patients in the sample two were female and 10 were male. Their ages ranged between 20 and 42 years (Table 4.1).

Table 4.1 Distribution of age and gender in sample

Patient	Age	Male	Female	Hospital
1.	31	X	-	Johannesburg
2.	25	X	-	Hillbrow
3.	20	X	-	Hillbrow
4.	27	X	-	Hillbrow
5.	38	X	-	Hillbrow
6.	41	X	-	Hillbrow
7.	37	X	-	Hillbrow
8.	33	X	-	Hillbrow
9.	39	-	X	Hillbrow
10.	42	X	-	Baragwanath
11.	29	-	X	Baragwanath
12.	22	X	-	Baragwanath

4.2 Cause of injury

Table 4.2 clearly indicates the aetiology of mandibular fractures in this sample group. Only one out of twelve of the fractures was accidental with the balance due to violence. The time between injury and surgical intervention varied between 3 and 17 days. The most common site of fracture was the symphysis with the other sites almost equal in incidence of fracture.

Table 4.2 Cause of injury and number of days before surgical intervention

Patient	Cause of injury	Delay between injury and surgical intervention	Site of fracture
1.	Assault	3 days	Symphysis, Right angle
2.	Assault	12 days	Right parasymphysis
3.	Assault	6 days	Left parasymphysis, Right angle
4.	Assault	7 days	Right body, Left angle
5.	Assault	2 days	Right parasymphysis, Left angle
6.	Assault	14 days	Left parasymphysis
7.	Assault	17 days	Left parasymphysis, Right angle
8.	Assault	3 days	Symphysis
9.	Fell onto chin	14 days	Right parasymphysis
10.	Assault	8 days	Right body, Left angle
11.	Assault	9 days	Symphysis
12.	Assault	5 days	Symphysis

4.3 Individual results of each patient

Details of each patient are in Appendices B to M. The surgical part of each patient's treatment will be presented to describe the intra-operative evaluation of the plating system studied. The progression of the operative learning curve and the patient to patient changes that were made during the surgical phase are vital in the understanding of this osteosynthesis system. A major contribution of the study has been in its determination of the required specifications for a bioresorbable mandibular plating system. All patients required open reduction under general anaesthesia.

4.3.1 Patient 1

The right angle was stabilised with a titanium plate and screws. The fracture in the symphysis was plated with a 2mm Lactosorb® mesh panel and six 2mm x 9mm Lactosorb® screws, three either side of the fracture. The surgical procedure was prolonged regarding the placement of the resorbable plates and screws due to operator inexperience. Difficulty was encountered with the contouring and passive placement of the Lactosorb® panel. Tapping of the screw holes was difficult and the threads were easily ruined. The screws were 9mm in length and seemed to be too short. It was also felt that the 2mm diameter screws were too small. The panel was, however, adequately secured and an acceptable surgical result was achieved.

The conclusion after surgery was that modifications to the procedure were needed for the next patient. A 2.2mm drill would be used with a 2.5mm screw tap to allow the use of a 2.5mm screw. It was also decided that an 11mm screw length would be more appropriate as this would equate to a 9 mm titanium screw in functional length. The panel form of the Lactosorb® plate was to be used again with the new drill bit-tap-screw combination.

4.3.2 Patient 2

The fracture in the parasymphysis was plated with a 2mm Lactosorb® mesh panel and six 2.5 mm x 11 mm Lactosorb® screws, three either side of the fracture. The surgical procedure using a 2.2mm drill with a 2.5mm tap was easier than the first case. Operator experience had improved and the drill-tap-screw combination worked well. Difficulty was once again encountered with the contouring and passive placement of the Lactosorb® panel the problem being eversion of the edges. Tapping of the screw holes was easier with the larger screw tap, the threads were more resilient, the purchase of the 11mm long screws was good. Thanks to this and the increased diameter screws the stabilisation of the panel was good. The conclusion after surgery was that the drill diameter to screw tap and screw size ratio were now correct for the mandible. The 11mm screw length also gave adequate purchase for stabilisation of the plate. The panel form of the Lactosorb® plate was still not ideal due to the difficulties encountered with the contouring and cutting of the panel.

4.3.3 Patient 3

The right angle was stabilised with a titanium plate and screws. The fracture in the parasymphysis was plated with a 2mm Lactosorb® mesh panel and six 2.5 mm x 11 mm Lactosorb ® screws, three either side of the fracture. The surgical procedure was uncomplicated. The drill-tap-screw combination worked well. As with the first and second cases difficulty was encountered with the contouring and passive placement of the Lactosorb® panel.

It was felt that the panel form of the Lactosorb® plate was clearly not ideal and that the preformed Lactosorb® plates would be used on subsequent patients.

4.3.4 Patient 4

The left angle was stabilised with a titanium plate and screws. The fracture in the right body was plated with two 6 hole 2mm extended Lactosorb ® plates and eight 2.5 mm x 11 mm Lactosorb® screws, four either side of the fracture. The surgical procedure was uncomplicated. The pre-formed plates were much easier to work with and could be contoured more efficiently than the bulkier panels used in the previous patients. The 11mm screws gave good purchase and the stabilisation with the plates was good.

The use of the Lactosorb® pre-formed plate was clearly an improvement on the panel form and the surgical result attained was better than the previous cases.

The ideal drill diameter - screw tap diameter - screw size and length – plate type combination for this product for the type of fracture studied was achieved.

4.3.5 Patient 5

The left angle was stable and required no surgical reduction and fixation. The fracture in the right parasymphysis was plated with two 6 hole 2mm extended Lactosorb® plates and eight 2.5 mm x 11 mm Lactosorb® screws, four either side of the fracture. The surgical procedure was uncomplicated.

4.3.6 Patient 6

The fracture in the left parasymphysis was plated with two 6 hole 2mm extended Lactosorb® plates and eight 2.5mm x 11mm Lactosorb® screws, three either side of the fracture. The surgical procedure was uncomplicated.

4.3.7 Patient 7

The right angle was stable with no surgical intervention required. The fracture in the parasymphysis was plated with two 2mm Lactosorb® plates and eight 2.5 mm x 11 mm Lactosorb® screws, four either side of the fracture. The surgical procedure was uncomplicated.

4.3.8. Patient 8

The fracture in the symphysis was plated with two 2mm Lactosorb® plates and eight 2.5mm x 11mm Lactosorb® screws, four either side of the fracture. The surgical procedure was uncomplicated.

4.3.8 Patient 9

The fracture in the parasymphysis was plated with two 2mm Lactosorb® plates and eight 2,5 mm x 11 mm Lactosorb® screws, four either side of the fracture. The surgical procedure was without complication.

4.3.9 Patient 10

The left angle was stabilised with a titanium plate and screws. The fracture in the right body was plated with two 6 hole 2mm extended Lactosorb® plates and eight 2.5mm x 11 mm Lactosorb® screws, four either side of the fracture. The surgical procedure was uncomplicated.

4.3.10 Patient 11

The fracture in the symphysis was plated with two 2mm Lactosorb® plates and eight 2.5 mm x 11 mm Lactosorb® screws, four either side of the fracture. The surgical procedure was uncomplicated.

4.3.11 Patient 12

The fracture in the symphysis was plated with two 2mm Lactosorb ® plates and eight 2.5mm x 11mm Lactosorb® screws, four either side of the fracture. The surgical procedure was uncomplicated.

4.4 Overall results of the study

All patients received an open reduction and plating of their mandiblular fracture with the Lactosorb® resorbable plating system. Some patients with unstable bilateral fractures received fixation of the second fracture with titanium plates and screws. The primary fracture treated with Lactosorb® was considered as the only fracture present for the purpose of this study. Of the twelve patients, one was followed up for 6 months, three were evaluated up to 4 months, 8 were seen six weeks post operatively, 9 two weeks after surgery and the remainder were lost to follow-up (Table 4.1).

Table 4.3: Follow-up of patients treated

Length of follow-up	2 weeks	6 weeks	3 months	6 months
Number of patients	9	8	4	1
Lost to follow-up	3	4	8	11

At two weeks post surgery 9 patients were assessed, all the plates were palpable beneath the mucosa on clinical evaluation. Seven of the 9 presented with

mobility of some degree at the fracture site. Two patients had no residual mobility of the fracture site. One patient had radiographic deviation of more than 4mm (Table 4.2).

Table 4.4: Patient assessment 2 weeks post surgery

Number of patients assessed	9
Number of patients with mobility	7
Number of patients with stable fractures	2
Number of patients with palpable plates	9
Number of patients with sepsis	0
Number of patients with malocclusion	0
Number of patients with radiographic deviation > 4mm	1

At six weeks 8 patients were evaluated. The plates and screws were still palpable intra-orally. Two of the patients had residual mobility of the fracture site. Two other patients had a mobile, painful tooth adjacent to the fracture but no mobility was noted of the fracture site. The remaining four presented with non mobile, healed fractures and no complications (Table 4.3).

Table 4.5: Patient assessment 6 weeks post surgery

Number of patients assessed	8
Number of patients with mobility	2
Number of patients with stable fractures	6
Number of patients with palpable plates	8
Number of patients with sepsis and/or tooth mobility	2
Number of patients with malocclusion	0
Number of patients with radiographic deviation > 4mm	1

At three months only four of the patients presented for follow-up. The two patients with mobile fractures seen at the 6 week follow-up still presented with mobility and a derangement of the occlusion. The remaining two had healed with no complication. The plates were still palpable in all four patients (Table 4.3).

Table 4.6: Patient assessment 3 months post surgery

Number of patients assessed	4
Number of patients with mobility	2
Number of patients with stable fractures	2
Number of patients with palpable plates	4
Number of patients with sepsis	0
Number of patients with malocclusion	2
Number of patients with radiographic deviation > 4mm	1

Only one patient was seen 6 months after his surgery. His fracture had healed completely with no residual complications. The occlusion was intact and the plate was no longer palpable beneath the mucosa (Table 4.4).

Table 4.7: Patient assessment 6 months post surgery

Number of patients assessed	1
Number of patients with mobility	0
Number of patients with stable fractures	1
Number of patients with palpable plates	0
Number of patients with sepsis	0
Number of patients with malocclusion	0
Number of patients with radiographic deviation > 4mm	0

CHAPTER 5

DISCUSSION

5.1 General

For a new technique to replace an established one, the new method must have advantages in some areas and be equivalent to the existing method in others. For the current investigation Lactosorb plates must be compared to titanium plating systems. With regard to mandibular fracture immobilisation, factors to consider are surgical technique, mobility, sepsis and effect on healing and resorption.

5.2 Need for a resorbable plating system

The purpose of the study was to clinically evaluate the Lactosorb® resorbable bone plating system as a viable alternative to the conventional metal plating systems currently commercially available. A clear indication for an acceptable resorbable fixation system exists in the treatment of paediatric fractures where retardation of bone growth and migration of plates and screws need to be avoided. There is also a specific need in developing populations for a resorbable plating system where follow-up is poor. As shown in this study, non compliance is prevalent in the level of the socio-economic population attending government health care facilities. Lack of patient follow-up may be associated with the additional cost to the patient of the visits. Resorbable plating systems could be beneficial by reducing the need for frequent follow-up visits. The success of the

copolymer for craniofacial fixation has been well documented in the literature as discussed in chapter 2 but no studies have been published thus far on the use of the Lactosorb® copolymer for the treatment of mandibular fractures. In the current study new ground was broken both in the surgical technique used and in the component combinations applicable to mandibular fractures.

5.3 Surgical technique

The surgical procedure differed from that of conventional metal plating systems in that it was more technique sensitive and demanded that the operator go through a learning curve before feeling comfortable with the system. The ideal combination of drill-screwtap-screw-plate was found in step-wise fashion by evaluating the success of each case at surgery and instituting the necessary changes for the next patient. The mesh panel was found to be cumbersome and allowed less stability of the fracture site. The panel had a tendency to flare away from the cortex of the mandible at the edges, which resulted in less of the panel being in contact with the bone. This problem did not occur with the railed plates possibly as a result of the increased stability afforded by the rails. The 2mm pre-formed Lactosorb® railed plates proved to be a more useful alternative than the panel. It was also found that the most effective screw for the mandible is 2,5mm in diameter by 11mm in length. The drill bit for this screw should be a 2,2mm diameter to suit a 2,5mm screw tap to allow for passive placement of the Lactosorb® screw. Of concern, however, is the fact that while this screw size proved to be correct for adequate retention of the plate in the adult mandible,

this size is exceptionally large for the paediatric mandible. The most critical steps in the use of the system are the drilling and tapping of the screw holes. The holes should be drilled at 90 degrees to the buccal cortex of the mandible and the screw tap should then be used without exerting pressure on the threads. Passive adaptation of the plates to the bone is essential in order to prevent displacement of the fracture site. The adaptation of the plates requires the use of metal templates and heat packs. This step is time consuming and accuracy of application is not as good as with titanium plates. My experience in this study differs with that of Eppley et al[35], who commented on the ease of application of Lactosorb® for the treatment of midface fractures. Although surgical time reduces in direct proportion to the experience of the operator, the resorbable plating system in its current form requiring screw hole tapping and plate contouring still requires a longer surgical time than its titanium counterpart.

5.4 Mobility

The study results brought certain points to the fore. Mobility of varying degree was noted in all cases post-operatively which clearly showed that the resorbable osteosynthesis system does not provide the rigid bone fixation necessary for ideal bone healing conditions. The inherent elasticity of the copolymer is responsible for the semi-rigid fixation which is associated with callus formation and secondary bone healing. In two of the cases mobility was still present 6 weeks after operation together with derangement of the occlusion. The two patients with residual fracture displacement were cases in which the degree of displacement of

the initial fracture was more severe than that typical for the other patients. This probably resulted in higher forces being placed on the Lactosorb® plates with resultant displacement. All the other cases showed minimal post-operative deviation. The percentage of fracture displacement in this study measured at six weeks after operation was 16,6%. This is higher than the figure of 9% for titanium miniplate osteosynthesis quoted by Renton and Weisenfeld[9].

5.5 Sepsis

The 2 cases in this study that presented with post operative sepsis were as a result of non vitality of a tooth adjacent to the fracture. This was clearly unrelated to the Lactosorb® plate or screws and resolved on removal of the offending tooth. If these 2 cases are counted as osteosynthesis related sepsis then the rate of infection in this study is 16,6%. If these 2 cases of sepsis are, however, considered to be unrelated to the plating system, then a sepsis rate of 0% is seen. This is in keeping with the results of Montag et al[34], Eppley et al[35] and Goldstein et al[36]. Sepsis rates found in the literature related to titanium plating systems were 17,7% found by Passeri et al[27], 32% by Ellis et al[24], and 1% by Nakamura et al[25]. I am, however, loathe to make any definitive conclusions in this regard based on this study, as the sample size was too small for conclusive statistical data analysis.

5.6 Resorption

Resorption of the plates and screws was significant by 6 months and the components could not be palpated beneath the mucosa by this stage. The successful resorption of the Lactosorb® system found in this study is in keeping with the results of Montag et al[34], Eppley et al[35] and Goldstein et al[36].

5.7 Cost factors

The cost of the resorbable plates and screws was approximately 60% higher than their titanium counterparts. The increased theatre time mentioned above also increases the overall cost of the resorbable plating system but the prevention of possible medium to long term foreign body sepsis as well as further procedures to remove the plates may attest to the long term cost effectiveness of the resorbable system, especially in developing populations.

5.8 Conclusion

The literature review, in this report, plus clinical experience in the surgical division shows a clear need for a resorbable bone plating system. Earlier studies by Montag et al[34], Eppley et al[35] and Goldstein et al[36], showed that the copolymer used in this study has excellent strength, flexibility, resorption characteristics and bio-acceptability. [28] Experience during the current study show it, however, to be lacking in terms of certain mechanical characteristics when compared to

metal plates. The plates are more bulky than titanium, requiring additional exposure of bone and stripping of periosteum. The inherent elasticity of the plates prevents the rigid fixation of a fracture site thereby allowing an increased chance of postoperative displacement. Other factors to consider are the template assisted adaptation of the plates to the bone, the tapping of the screw holes and the large diameter and length of the screws needed to provide adequate stabilisation of the plate. Increased cost of plates and surgical time are also factors to bear in mind.

I feel that although the resorbable system used in this study provided adequate stabilisation for the majority of the patients treated, it requires more refinement before being accepted for routine use in mandibular fractures. At this stage it should only be used in select cases where specifically required. Personally, given the choice I would elect for titanium miniplate osteosynthesis until further improvements have been made to the resorbable systems presently available. In contrast, in the case of paediatric fractures, where an indication clearly exists, the system could be used in its current form, with smaller plates and screws to achieve a good result in the hands of a surgeon experienced in its use.

5.9 Future research

Longer term follow-up in numbers adequate for statistical assessment is needed to evaluate this most promising new dimension in fracture osteosynthesis. I have no doubt that advances and improvements will make resorbable osteosynthesis

systems an acceptable alternative to their more traditional metal counterparts in the near future.

REFERENCES:

1. Kennedy MC, Tucker MR, Lester GE, Buckley MJ. The stress shielding effect of rigid internal fixation plates on mandibular bone grafts. A photon absorption densitometry and quantitative computerised tomographic evaluation. Int J Oral Maxillofac Surg 1989; 18: 307-310.

2. Suurnonen R. Biodegradable fracture-fixation devices in maxillofacial surgery. Int J Oral Maxillofac Surg 1993; 22: 50-57.

3. Bostman OM. Current concepts review: Absorbable implants for the fixation of fractures. J Bone Joint Surg [Am] 1991; 73: 148-153.

4. Bos RR, Boering G, Rozema FR, Leenslag JW. Resorbable poly (L-lactide) plates and screws for the fixation of zygomatic fractures. J Oral Maxillofac Surg 1987; 45: 751-753.

5. Bergsma EJ, Rozema FR, Bos RRM, de Bruijn WC. Foreign body reactions to resorbable Poly (L-lactide) bone plates and screws used for the fixation of unstable zygomatic fractures. J Oral Maxillofac Surg 1993 ; 51: 666-670.

6. Tormla P. Ultra-high-strength absorbable self-reinforced polyglycotide (SR-PGA) composite rods for internal fixation of bone fractures: In vitro and in-vivo study. J Biomed Mat Res 1991; 25:1-22.

7. Eppley BL, Sadove AM. A comparison of resorbable and metallic fixation in healing of calvarial bone grafts. Plastic Reconstructive Surg 1995; 96: 316-322.

8. Fonseca RJ, Walker RV. Oral And Maxillofacial Trauma. W B Saunders Company. Philadelphia. 1991; 359-372.

9. Renton TF, Wiesenfield D. Mandibular fracture osteosynthesis: a comparison of three techniques. Brit J Oral Maxillofacial Surg 1996; 34: 166-173.

10. Champy M, Lodde JP, Schmit R, Jaeger JH, Muster D. Mandibular osteosynthesis by miniature screwed plates via a buccal approach. J Maxillofac Surg 1978; 6: 14-21

11. Thoma KH. Treatment of jaw fractures, past and present. J Oral Surg 1959; 17: 30-35.

12. Buchbinder D. Treatment of fractures of the edentulous mandible, 1943 to 1993: A review of the literature. J Oral Maxillofac Surg 1993; 51: 1174-1180.

13. Matorin PA. Treatment of traumatic mandibular fractures. Grand Rounds Archives. Department of Otorhinolaryngology and Communicative Science. http:/www.bcm.tmc.edu/oto/grand. April 29; 1993: 1-5.

14. Banks P. Killey's Fractures of the mandible. Dental practitioner handbook. 3rd Edition. 1988.

15. Champy M, Lodde JP, Schmit R, Jaeger JH, Muster D. Mandibular osteosynthesis by miniature screwed plates via a buccal approach. J Maxillofac Surg 1978; 6: 14-21.

16. Shetty V, McBrearthy D, Fourney M, Caputo AA. Fracture line stability as a function of the internal fixation system: An in vitro comparison using a mandibular angle fracture model. J Oral Maxillofac Surg 1995; 53: 791-801.

17. Zaki GA, Carter JLB. A clinical and biomechanical assessment of the Hall surgical miniplate system. Br J Oral Maxillofac Surg 1990; 28: 254-257.

18. Kroon FH, Mathison M, Cordney JR, et al. The use of miniplates in mandibular fractures. An in vitro study. J Craniomaxillofac Surg 1991; 19: 199-204.

19. Levy FE, Smith RW, Odland RM, et al. Monocortical miniplate fixation of mandibular angle fractures. Arch Otolaryngol Head Neck Surg 1991; 117: 149-154.

20. Champy M, Kahn M. Fracture-line stability as a function of the internal fixation system: An in vitro comparison using a mandibular angle fracture model. J Oral Maxillofac Surg 1995; 53: 801-803.

21. Cossio PI, Galves FE, Perez JL, Garcia-Perla A, Guisado JMH. Mandibular fractures in children: A retrospective study of 99 fractures in 59 patients. Int J Oral Maxillofac Surg 1994; 23: 329-331.

22. Smith I. Facial fractures. S Afr J Surg 1973; 11: 187-195.

23. Bruce RA, Ellis E. The Second Chalmers J. Lyons Academy Study of Fractures of the Edentulous Mandible. J Oral Maxillofac Surg 1993; 51: 904-911.

24. Ellis E, Sinn DP. Treatment of mandibular angle fractures using two 2.4mm dynamic compression plates. J Oral Maxillofac Surg 1993; 51: 969-973.

25.Nakamura S, Takenoshita Y, Oka M. Complications of miniplate osteosynthesis for mandibular fractures. J Oral Maxillofac Surg 1994; 52: 233-238.

26. Smith BR, Johnson JV. Rigid fixation of comminuted mandibular fractures. J Oral Maxillofac Surg 1993; 51: 1320-1326.

27. Passeri LA, Ellis E, Sinn DP. Complications of non-rigid fixation of mandibular angle fractures. J Oral Maxillofac Surg 1993; 51: 382-384.

28. W Lorenz. Product training manual. Resorbable cranio-maxillofacial fixation. 1996. Jacksonville, Florida 32218 U.S.A.

29. Finnegan M, Richie M, Sawamura S, May H. Investigation of bio-absorbable screws in potentially unstable fractures in sheep. Department of Orthopaedic Surgery, University of Texas, South-western medical Centre, Dallas, Texas. www.swmed.edu/home_pages/facultystaff/may/researchLab/Posters/ors_95.html; 1995.

30. Tams J, Rozema FR, Bos RRM, Roodenburg JLN, Nikkels PGJ, Veremey A. Poly L-lactide bone plates and screws for internal fixation of mandibular swing osteotomies. Int J Oral Maxillofac Surg 1996; 25: 20-24.

31. McVicar I, Hatton PV, Brook IM. Self-reinforced polyglycolic acid membrane: a bio-resorbable material for orbital floor repair. Initial clinical report. Br J Oral Maxillofac Surg 1995; 33: 220-223.

32. Eppley B, Sadove M. A Comparison of resorbable and metallic fixation in healing of calvarial bone grafts. Plastic and Reconstructive Surgery 1995; 96: 316-322.

33. Kumar AV, Staffenberg DA, Petronio JA, Wood RJ. Bioabsorbable plates and screws in pediatric craniofacial surgery: A review of 22 cases. J Craniofac Surg 1997; 8: 97-99.

34. Montag ME, Morales L, Daane S. Bioabsorbables: Their use in pediatric craniofacial surgery. J Craniofac Surg 1997; 8: 100-102.

35. Eppley BA, Prevel CD. Nonmetallic fixation in traumatic midfacial fractures. J Craniofac Surg 1997; 8: 103-109.

36. Goldstein JA, Quereshy FA, Cohen AR. Early experience with biodegradable fixation for congenital pediatric craniofacial surgery. J Craniofac Surg 1997; 8: 110-115.

Appendix A

Lactosorb® plate, panel and screw design

PLATE TYPE	PANEL TYPE	SCREW SIZES
4 Hole straight	25mm x 25mm Mesh panel	1.5mm x 3mm
4 Hole extended straight	25mm x 50mm Mesh panel	1.5mm x 4mm
6 Hole straight	50mm x 50mm Mesh panel	1.5mm x 5mm
6 Hole extended straight		2mm x 5mm
8 Hole straight		2mm x 7mm
T Plate		2mm x 9mm
X Plate		2.5mm x 5mm
Extended X Plate		2mm x 7mm
Right L Plate		2mm x 9mm
Left L Plate		
Square Plate		
Curved 6 Hole plate		

Appendix B

POST SURGICAL EVALUATION – PATIENT 1

Fracture site	Number of plates	Plate types	Number and size of screws
Symphysis	1	Lactosorb® panel	6 x 2 x 9 mm
Right angle	1	Titanium miniplate	4 x 7mm titanium

	Time after surgery	Panelipse Taken	Clinical signs	Radiographic Deviation	Nerve function	Device palpable
1	On discharge	Yes	Mobility of fracture site	Less than 4mm	Intact	Yes
2	2 weeks	Yes	Mobility of fracture site & persistent pain	Less than 4mm	Intact	Yes
3	6 weeks	Yes	Mobility of fracture site	Less than 4mm	Intact	Yes

Appendix C

POST SURGICAL EVALUATION – PATIENT 2

Fracture site	Number of plates	Plate types	Number and size of screws
Right parasymphysis	1	Lactosorb® panel	6 x 2.5 x 11mm

	Time after surgery	Panelipse Taken	Clinical signs	Radiographic Deviation	Nerve function	Device palpable
1	On discharge	Yes	Mobility of fracture site	Less than 4mm	Intact	Yes
2	2 weeks	Yes	No abnormal signs	Less than 4mm	Intact	Yes
3	6 weeks	Yes	No abnormal signs	Less than 4mm	Intact	Yes
4	3 months	Yes	No abnormal signs	Less than 4mm	Intact	Yes
5	6 months	Yes	No abnormal signs	Less than 4mm	Intact	No

Appendix D

POST SURGICAL EVALUATION – PATIENT 3

Fracture site	Number of plates	Plate types	Number and size of screws
Left parasymphysis	1	Lactosorb® panel	6 x 2.5 x 11mm
Right angle	1	4 hole titanium miniplate	3 x 7 mm x 2mm

	Time after surgery	Panelipse taken	Clinical signs	Radiographic Deviation	Nerve function	Device palpable
1	On discharge	Yes	Mobility of fracture site	Less than 4mm	Intact	Yes
2	2 weeks	Yes	Mobility of fracture site	Less than 4mm	Intact	Yes
3	6 weeks	Yes	No abnormal signs	Less than 4mm	Intact	Yes

Appendix E

POST SURGICAL EVALUATION – PATIENT 4

Fracture site	Number of plates	Plate types	Number and size of screws
Right body	2	Lactosorb® 6 hole plate	8 x 2.5 x 11mm
Left angle	2	4 hole extended titanium plates	8 x 9mm titanium screws

	Time after surgery	Panelipse taken	Clinical signs	Radiographic Deviation	Nerve function	Device palpable
1	On discharge	Yes	Mobility of fracture site	Less than 4mm	Intact	Yes
2	2 weeks	Yes	Mobility of fracture site	Less than 4mm	Intact	Yes
3	6 weeks	Yes	No abnormal signs	Less than 4mm	Intact	Yes
4	3 months	Yes	No abnormal signs	Less than 4mm	Intact	No

Appendix F

POST SURGICAL EVALUATION – PATIENT 5

Fracture site	Number of plates	Plate types	Number and size of screws
Right parasymphysis	2	Lactosorb® plates	8 x 2.5 x 11mm
Left angle	Nil	Nil	Nil

	Time after surgery	Panelipse Taken	Clinical signs	Radiographic Deviation	Nerve function	Device palpable
1	On discharge	Yes	Mobility of tracture site	More than 4mm, less than 6mm	Intact	Yes
2	2 weeks	Yes	Mobility of tracture site	More than 4mm, less than 6mm	Intact	Yes
3	6 weeks	Yes	No residual mobility / occlusion a[illegible]ged	More than 4mm, less than 6mm	Intact	Yes

Appendix G

POST SURGICAL EVALUATION – PATIENT 6

Fracture site	Number of plates	Plate types	Number and size of screws
Left parasymphysis	2	Lactosorb® 6 hole plate	8 x 2.5 x 11mm

	Time after surgery	Panelipse Taken	Clinical signs	Radiographic Deviation	Nerve function	Device palpable
1	On discharge	Yes	Mobility of fracture site	Less than 4mm	Intact	Yes
2	2 weeks	Yes	Mobility of fracture site	Less than 4mm	Intact	Yes
3	6 weeks	Yes	Mobility of fracture site	Less than 4mm	Intact	Yes
4	3 months	Yes	Mobility of fracture site / occlusion deranged	Less than 4mm	Intact	No

Appendix H

POST SURGICAL EVALUATION – PATIENT 7

Fracture site	Number of plates	Plate types	Number and size of screws
Left parasymphysis	2	Lactosorb® panel	8 x 2.5 x 11mm
Right angle	Nil	Nil	Nil

	Time after surgery	Panelipse taken	Clinical signs	Radiographic Deviation	Nerve function	Device palpable
1	On discharge	Yes	Mobility of fracture site	Less than 4mm	Nil	Yes
2	2 weeks	Yes	Mobility of fracture site	Less than 4mm	Nil	Yes

Appendix I

POST SURGICAL EVALUATION – PATIENT 8

Fracture site	Number of plates	Plate types	Number and size of screws
Symphysis	2	Lactosorb® 6 hole plate	8 x 2.5 x 11mm

	Time after surgery	Panelipse taken	Clinical signs	Radiographic Deviation	Nerve function	Device palpable
1	On discharge	Yes	Mobility of fracture site	Less than 4mm	Intact	Yes
2	2 weeks	Yes	Mobility of fracture site	Less than 4mm	Intact	Yes
3	6 weeks	Yes	Tooth adjacent to fracture mobile	Less than 4mm	Intact	Yes

Appendix J

POST SURGICAL EVALUATION – PATIENT 9

Fracture site	Number of plates	Plate types	Number and size of screws
Right parasymphysis	2	Lactosorb® 6 hole plate	8 x 2.5 x11 mm

	Time after surgery	Panelipse Taken	Clinical signs	Radiographic Deviation	Nerve function	Device palpable
1	On discharge	Yes	No abnormal signs	Less than 4mm	Intact	Yes
2	2 weeks	Yes	No abnormal signs	Less than 4mm	Intact	Yes
3	6 weeks	Yes	Low grade infection & pain / mobile Tooth adjacent to fracture	Less than 4mm	Intact	Yes

Appendix K

POST SURGICAL EVALUATION – PATIENT 10

Fracture site	Number of plates	Plate types	Number and size of screws
Right body	2	Lactosorb® 6 hole plate	8 x 2.5 x 11mm
Left angle	1	4 hole titanium	4 x 7mm screws

	Time after surgery	Panelipse Taken	Clinical signs	Radiographic Deviation	Nerve function	Device palpable
1	On discharge	Yes	No abnormal signs	Less than 4mm	Paraesthesia RHS	Yes

Appendix L

POST SURGICAL EVALUATION – PATIENT 11

Fracture site	Number of plates	Plate types	Number and size of screws
Symphysis	2	Lactosorb® 6 hole plate	8 x 2.5 x 1.1mm

	Time after surgery	Panelipse Taken	Clinical signs	Radiographic Deviation	Nerve function	Device palpable
1	On discharge	Yes	No abnormal signs	Less than 4mm	Intact	Yes

Appendix M

POST SURGICAL EVALUATION – PATIENT 12

Fracture site	Number of plates	Plate types	Number and size of screws
Symphysis	2	Lactosorb® 6 hole extended	8 x 2.5 x11mm

	Time after surgery	Panelipse Taken	Clinical signs	Radiographic Deviation	Nerve function	Device palpable
1	On discharge	Yes	No abnormal signs	Less than 4mm	Intact	Yes

Author Kruger L R
Name of thesis A Clinical Study Of Treatment Of Mandibular Factures Using A Resorbable Polylactic Polyglycolic Copolymer Mini-Plating System Kruger L R 1999

PUBLISHER:
University of the Witwatersrand, Johannesburg
©2013

LEGAL NOTICES:

Copyright Notice: All materials on the University of the Witwatersrand, Johannesburg Library website are protected by South African copyright law and may not be distributed, transmitted, displayed, or otherwise published in any format, without the prior written permission of the copyright owner.

Disclaimer and Terms of Use: Provided that you maintain all copyright and other notices contained therein, you may download material (one machine readable copy and one print copy per page) for your personal and/or educational non-commercial use only.

The University of the Witwatersrand, Johannesburg, is not responsible for any errors or omissions and excludes any and all liability for any errors in or omissions from the information on the Library website.