

https://dspace.org/

Patterns of tissue damage by insect activity using pig (Sus Scrofa) carcasses as human analogues

Kgokong, Ntebogeng

2024
https://hdl.handle.net/10539/37692

Downloaded from a DSpace repository. https://dspace.org/

PATTERNS OF TISSUE DAMAGE BY INSECT ACTIVITY USING PIG *(SUS SCROFA)* CARCASSES AS HUMAN ANALOGUES

by

Ntebogeng Kgokong

A dissertation submitted to the Faculty of Health Science, University of the Witwatersrand, Johannesburg, in fulfilment of the requirements for the degree:

MSc (Med) in Forensic Medicine

Supervisors:

[a]Dr. Guinevere Gordon, [a]Mr. Lawrence Hill & [b]Prof. James Ian Phillips

[a]Department of Forensic Medicine and Pathology, School of Clinical Medicine, Faculty of Health Science, University of the Witwatersrand, Johannesburg, South Africa &

[b]The National Health Laboratory Service/ National Institute of Occupational Health. Department of Biomedical Technology, Faculty of Health Sciences, University of Johannesburg

Johannesburg, 2023

The financial assistance of the National Research Foundation (NRF) towards this research is hereby acknowledged. Opinions expressed and conclusions arrived at, are those of the author and are not, necessarily, to be attributed to the NRF.

WITS UNIVERSITY

NATIONAL INSTITUTE FOR OCCUPATIONAL HEALTH
Division of the National Health Laboratory Service

Declaration

I declare that this Dissertation is my own, unaided work. It is being submitted for the degree of Master of Science in Medicine at the University of the Witwatersrand, Johannesburg. It has not been submitted before for any degree or examination at any other university.



(Signature of candidate)

___17th__day of ___May_ 2023

Dedication

This dissertation is dedicated to my son, Gosego Kgokong. I worked hard to complete it just to show you, my angel, that with hard work and dedication you can conquer your dreams despite the challenges you may be faced with. I hope you will be able to grow up remembering this lesson. We are up for a very difficult journey but this dissertation has shown me that difficult situations are there to build you, even though during the process they may look like they are built to break you, in the end you see the value in them. I believe in you and know you will be able to achieve anything you put your mind to

To my mother, Patience Kgokong: Mama, thank you for pushing me and always wanting the best for me. Your sacrifices have never gone unnoticed. Your support through all my challenges has been what has kept me going. I know no other greater love than that that you have shown me.

And last but definitely not least, to myself. This has been a hard journey, filled with very few ups but definitely many downs, twists and turns. It has taken me a long time to reach the end but I finally did. I am very proud of myself and I dedicate this achievement to Ntebogeng Kgokong. You are all that you believe you can be, go and do it all for YOU.

I LOVE YOU!

"Though I fall I will rise. Though I sit in darkness the Lord will be my light" – Micah 7:8

Plagiarism declaration

I, **Ntebogeng Kgokong** (Student number: **302617**), am a student registered for the degree of **Master of Science in Medicine** in the academic year **2023**.

I hereby declare the following:

- I am aware that plagiarism (the use of someone else's work without their permission and/ or without acknowledging the original source) is wrong.
- I confirm that the work submitted for assessment for the above degree is my own unaided work except where I have explicitly indicated otherwise.
- I have followed the required conventions in referencing the thoughts and ideas of others.
- I have used the Harvard referencing style in this thesis.
- I understand that the University of the Witwatersrand may take disciplinary action against me if there is a belief that this is not my own unaided work or that I have failed to acknowledge the source of the ideas or words in my writing.
- I have included as an appendix a report from "*Turnitin*" (or other approved plagiarism detection) software indicating the level of plagiarism in my research document.

Signature:  Date: 04/05/2023

Abstract

Bite marks caused by insect activity on a decomposing body can cause misleading artefacts that can resemble peri-mortem injuries. The aim of this study was to perform a macroscopic and histological analysis on soft tissue exposed to insect activity for patterns of tissue damage using pig carcasses and to describe and measure the insect mouthparts by scanning electron microscopy in order to link bite marks noted to specific insect species.

Two pig carcasses were placed in galvanized steel cages to allow insect access and prevent scavenging. Tissue damage caused by insect activity was described, photographed, punch biopsied and histopathologically analysed. Sampling of insect damage was conducted every third day, and associated insects were collected and temperatures were recorded daily.

Six forensically important insect species were recorded namely, *Lucilia sericata, Calliphora vicina, Chrysomya albiceps, Chrysomya chloropyga, Dermeste*s *maculatus* and a species of ant (Family Formicidae).

Patterns caused by ants (Formicidae) were small, superficial lesions on the skin surface with skin parchmenting. Patterns of damage caused by dipteran larvae macroscopically were circular and irregular in shape and more pronounced on extremities. Patterns caused by coleopterans were circular in shape, and not as irregular in comparison to those by dipteran larvae and tended to tunnel deeper into the subcutaneous tissues. Epidermal-dermal separation and the complete removal of the epidermal layer were noted before decomposition could occur, which was attributable to insect activity. Mouthparts were described and measured but the differences in the mouthparts were such that the patterns, and not individual bite marks, were a better indicator of the order of insect causing the damage.

Acknowledgements

I would like to acknowledge the following funding entities that assisted in funding this research: The National Research Foundation (NRF) and Faculty of Health Sciences Research Committee (FRC).

I would like to thank my supervisors for their support and encouragement. It has been a long journey, my sincerest gratitude for sticking with it throughout. I am truly and eternally grateful.

The National Health Laboratory Services bursary for funding the last two years of this research project.
Dr Jessica Linden for assistance with the histology.

The staff in the Anatomical Pathology Laboratory at the National Institute for Occupational Health for assistance with the histology and microscopic imaging.

The South African Weather Service for provision of weather data for the duration of this study.

Table of Contents

Declaration ii

Dedication iii

Plagiarism declaration iv

Abstract v

Acknowledgements vi

List of Figures x

List of Tables xiv

Abbreviations and Nomenclature xv

CHAPTER ONE: Introduction 13

CHAPTER TWO: Literature Review 14

2.1 Forensic Entomology 14

2.2 Post-mortem Interval Determination 16

2.3 Forensic Entomology in the South African context 18

2.4 Other applications for medico-legal forensic entomology 19

2.5 Limitations in forensic entomology 21

2.6 The use of Pig carcasses as human analogues 24

2.7 The use of microscopy in forensic entomology 25

2.8 Insect mouthparts 25

2.9 Aims and Objectives 28

CHAPTER THREE: Materials and Methods 29

3.1 Study Design 29

3.2 Study site 29

3.3 Data Collection 31

3.3.1 Field study 31
3.3.2 Insect mouthparts 34
3.3.3 Histology 34
3.3.4 Scanning Electron Microscopy 36
CHAPTER FOUR: Results 39
4.1 Environmental conditions 39
4.2 Forensically important insects 40
4.3 Macroscopic imaging and decomposition 43
4.4 Microscopic imaging 52
4.4.1 Light microscopy 52
4.5 Association between bite marks and insect feeding activity 56
4.6 Mouth parts 60
Scanning Electron Microscope (Mouthparts) 60
CHAPTER FIVE: Discussion 65
5.1 Environmental conditions 65
5.2 Forensically important insects 67
5.3 Macroscopic imaging 68
5.4 Microscopic imaging 70
5.4.1 Light microscopy 70
5.4.2 Scanning Electron Microscopy 72
5.5 Matching bite marks and patterns to mouthparts 74
5.6 Limitations and Recommendations 77
CHAPTER SIX: Conclusion 79
CHAPTER SEVEN: References 81
APPENDIX A: Ethics Certificate 94

APPENDIX B: Turnit in report……. 95

List of Figures

Chapter Two

Figure 1: Post-mortem insect activity, particularly cockroach (a) and ant (b) scavenging may resemble abrasions caused by peri-mortem and ante-mortem inflicted injuries (photos courtesy of http://thehealthscience.com/showthread.php?168160-Post-mortem-Changes)……..... 23

Figure 2: The cephalopharyngeal skeleton of Dipteran larvae. m- mouthhooks, si- intermediate sclerite, sb - basal sclerite……...27

Chapter Three

Figure 3: A Google Earth image of the study site in Frankenwald……..…… 30

Figure 4: Research enclosure at the Frankenwald field site, Johannesburg. The piglets were placed in galvanised steel cages, fitted with diamond mesh to prevent mammal and avian scavengers (a), within an access-controlled field site (b). The boxes were meshed to allow arthropods access to the piglets, but to keep small vertebrate scavengers out……...…31

Figure 5: Keyes cutaneous round 5 mm stainless steel dermal punch body skin piercing tool.....33

Figure 6: The distance between the study site (Frankenwald) and the South African Weather Service weather station (Johannesburg Botanical Gardens) ……..…33

Figure 7: The histology processing machines **a)** The Tissue Tek VIP Processing machine **b)** The Leica Autostainer XL used to dewax and stain specimens for light microscope preparation and **c)** the Leica CV5030 coverslipping machine…….……..……...….. 35

Figure 8: A flow diagram of the staining process as conducted by the Leica Autostainer XL Machine……..…….. 36

Figure 9: a) The Emitech K550X argon gas gold sputtering machine. b) The Jeol JSM-5600…….…….. 37

Chapter Four

Figure 10: The temperature data recorded every 2 hours at the study site using an iButton. The graph shows the mean, maximum and minimum temperature for each day throughout the duration of the study at the study site……....……....… 39

Figure 11: The temperature data recorded at the Johannesburg Botanical Garden (the closest weather station to the study site). The graph shows the mean, maximum and minimum temperature for each day throughout the duration of the study at the study site……..…….40
Figure 12: Day 4. The pigs had started bloating this displaying the second stage of decomposition ……..…….43
Figure 13: Day 4- Pig 2. Bloating (distension of the body) was already evident, displaying the second stage of decomposition. This distention is caused by bacterial activity due to putrefaction. Dipteran activity was evident on and around the carcass……..…..44
Figure 14: Day 4 – Maggot masses (arrow) clusters noted around natural orifices……...…..44
Figure 15: Day 10- Pig 1. Rupture of the stomach contents was evident with maggot masses around the contents. Another maggot mass was observed in the ears…….……..……45
Figure 16: Day 7- A colony of Formicidae were also observed in and around the ears and neck region of the carcass……...46
Figure 17: The inferior aspect of pig 1 (closest to the bottom of the cage) after turning the pig over. This view shows lesions (arrows) on the trunk of the pig created by insect (particularly maggot) activity. Maggots are seen protruding from the lesions in some areas (a)…….…..….47
Figure 18: The inferior aspect of pig 2 (closest to the bottom of the cage) after turning the pig over. This view shows lesions (arrows) on the trunk of the pig created by insect (particularly fly larvae) activity. Maggots can be seen protruding from the lesions in some areas (a)……....47
Figure 19: : Lesions on the trunk of the Pig 1 showing *D. maculatus* larvae protruding out of one of the lesions (arrow).…….…....….48
Figure 20: The inferior aspect of Pig 2 (pressed against the bottom of the cage) after turning the pig over. This view shows circular and irregular shaped lesions on the surface of the skin created by insect activity. Note areas of yellow discolouration….…….……..49
Figure 21: The inferior aspect of Pig 1 (closest to the bottom of the cage) after turning the pig over. This aspect shows lesions on the head created by insect (particularly maggot) activity The inferior aspect of Pig 1 (pressed against the bottom of the cage) after turning the pig over. This view shows circular and irregular shaped lesions on the extremities created by insect

activity (particularly fly larvae). Decompositional changes can also be observed (blood pooling to the side closest to the bottom of the cage)……..…..49
Figure 22: Maggot masses noted underneath the pig once they were turned over……...….50
Figure 23: Day 13- Pig 1. A group of Formicidae observed in the area where the stomach ruptured. Note areas of yellow discolouration on the surface of the skin……. 50
Figure 24: Day 23 – Pig 2. The skin and most of the subcutaneous tissue had hardened…….....51
Figure 25: Light microscopy of the control biopsy (taken at day 0 during the Fresh Stage) showing H&E stained sections of a pig skin punch biopsy at low power (10X) magnification. There is representation of the (a) intact and undamaged epidermis (b) dermis, and (c) subcutaneous tissue…….……..… 52
Figure 26: A high power (40X) H&E stained sections of a pig skin punch biopsy as seen using the light microscope. (a) displaying the epidermal layer, (b) the dermal layer and (c) keratin……..….. 53
Figure 27: Low power magnification (20X) Aniline Blue stained sections of a pig skin punch biopsy as seen using the light microscope, displaying epidermal-dermal separation (single headed arrow) and the thinning of the epidermal layer and damage of the dermal layer (double headed arrows).……...…….…..….. 54
Figure 28: Sections of a pig skin punch biopsy stained with H&E as seen using the light microscope (10X). (a) There is separation of the epidermis from the dermis, which is evidence of skin damage caused by decomposition. In certain cases, the absence of the epidermis can be as a result of Formicidae activity. The epidermis is not represented in this section. (b) Dermis……55
Figure 29: H&E stained sections of a pig skin punch biopsy as seen using the light microscope at 40X magnification demonstrating the adipose tissue and small vessels (arrows) in the hypodermis/ subcutaneous……..……....55
Figure 30: Aniline Blue stained section of a pig skin punch biopsy as seen using the light microscope at 40X magnification demonstrating the dermal layer. No presence of the epidermal layer. Dermal layer shows areas of degradation (arrows) and areas of damage with spaces and fragmentation of components of the dermis noted…….……..56
Figure 31: An SEM micrograph showing the head of an adult *D. maculatus* beetle with the mouthparts. The gape (a) measured 431 µm and the mandibles (b) measured 386 µm in length……...……...61

Figure 32: An SEM micrograph showing the head of the larvae of a *C. vicina* fly with the mouthparts. The gape (a) measured 326 µm and the mandibles (b) measured 271 µm in length……..…61

Figure 33: An SEM micrograph showing the head of the larvae of a *Ch. albiceps* fly with the mouthparts. The gape (a) measured 250 µm and the mandibles (b) measured 163 µm in length.....62

Figure 34: An SEM micrograph showing the head of the larvae of a *Ch. chloropyga* fly with the mouthparts. The gape (a) measured 105 µm and the mandibles (b) measured 220 µm in length.…….63

Figure 35: An SEM micrograph showing the head of an adult Formicidae ant with the mouthparts and antennae. The gape (a) measured 760 µm and the mandibles (b) measured 1120 µm in length……..…63

Figure 36: The cepahlopharyngeal skeleton of the larva of a) *C. vicina* and b) *Ch. albiceps* at 4X maginification showing the m-mouth hooks, si- intermediate sclerite and sb-basal sclerite.64

Figure 37: An electron micrograph of the cephalopharyngeal skeleton of the larva of *Ch. cloropyga* showing the m- mouth hooks, si-intermediate sclerite and sb-basal sclerite……..65

List of Tables

Table 1: The insects collected from the pigs at the study site and identified using along with the day of collection with Accumulated Degree Days calculated from iButton temperatures recorded at the study site. The ADD was calculated according to Myburgh *et al.* (2013)……40-41

Table 2: The macroscopic lesions noted on the pigs along with the associated insects as well as the patterns of tissue damage noted……56-59

Abbreviations and Nomenclature

FEITUOVS - Forensic Entomology Investigation Team of the Universiteit van die Oranje Vry Staat

FPS – Forensic Pathology Service

H&E – Haematoxylin and Eosin

NIOH – National Institute for Occupational Health

OsO_4 – Osmium Tetroxide

PIA – Period of insect activity

PMI – Post-mortem interval

PMSI – Post-mortem submergence interval

SAWS – South African Weather Service

SEM – Scanning electron microscope

TOC – Time of colonization

Chapter 1: Introduction

Forensic Entomology is the study of forensically important insects and other arthropods in the investigation of medico-legal cases (Kim 2010). The first recorded use of forensic entomology was in 1235 in China, when a rice farm worker was hacked to death by a fellow worker. Criminalist Sung Tz'u asked all the workers to leave their sickles outside and by doing so, the murder weapon attracted numerous blowflies due to the presence of untraceable blood. This resulted in the owner of the sickle confessing to committing the murder (Benecke 2001, Gennard 2007). Currently, there are many applications of forensic entomology including in medico-legal cases. This application is concerned with the collection and interpretation of information relating to a death (Amendt *et al.* 2007) using insects, their development and secondary to that their behaviour as evidence (Wolff *et al.* 2001).

The role of insects in decomposition is a vital one, particularly in medico-legal cases. This is because insects begin colonising the body hours after death. Insect activity can result in morphological changes to the decomposing human body and it is important to be able to differentiate between morphological changes resulting from insect activity, decomposition changes and those resulting from ante-mortem injuries (injuries that happen prior to death), or perimortem injuries (which occur at or near the time of death) (Kemp 2016). Insect activity on a decomposing body can cause misleading artefacts (Rivers and Geiman 2017) that can alter wound sites and be obscurants to identifying features (Viero *et al.* 2018) such as tattoos. The alteration of wound sites can cause problems in their interpretation as they can resemble ante and perimortem injuries. It is important to then differentiate any morphological changes on a decomposing body from those that could be attributable to injuries and those that could be attributable to insect activity (Ortloff *et al.* 2016). This is particularly important in medico-legal cases as the incorrect interpretation of evidence can be problematic in investigations.

The aim of this research was to study the patterns of tissue damage caused by insect activity both macroscopically and microscopically, in order to describe the bite marks and patterns of feeding activity caused by specific insect species using pig carcasses as human analogues. In order to attribute morphological changes on a decomposing body to insect activity, investigation of bite marks (from insects) on the skin may be essential. The knowledge of the size and type of bite marks resulting from different forensically important insect species, and the mouthparts of the different forensically

important insect species, may be able to assist in attributing particular bite marks to the specific insect species that caused them.

Chapter 2: Literature Review

2.1 Forensic Entomology

Six centuries after the first recorded use of forensic entomology, in the late 19th century, its use was noted in Western countries (Byrd and Castner 2010), and this resulted in an increase in the number of empirical studies conducted, which contributed valuable information to the discipline. Developing countries such as South Africa (Williams and Villet 2006) and Brazil (Lopes de Carvalho and Linhares 2001) have contributed geographically specific data that has added to the significant development of the discipline, in these countries and across the world.

Today, in the 21st century, there are many applications of forensic entomology; these include urban forensic entomology, which deals with issues around insect infestation in domestic areas, such as individual homes, and privately-owned businesses (Hall, Whitaker and Richards 2012). The focus in this field of forensic entomology is usually legal cases between owners of residences and pest control companies (Vanin 2018). The second application of forensic entomology is stored-product forensic entomology, which is concerned with insects found in commercial products, such as stored food products. Temperature manipulation is used to regulate the development and growth of these insect pests, because temperature plays an important role in the development of insect species (Stejskal *et al.* 2019). This then prevents infestation of the stored food products by insect pests. The third focus of forensic entomology is the medico-legal aspect, which is concerned with the collection and interpretation of information relating to a death (Amendt *et al.* 2007) using insects, their development and secondary to that their behaviour as evidence (Wolff *et al.* 2001). This includes the species of Dipteran (fly) and Coleopteran (beetle) orders.

This field of Forensic Science has been widely used in the determination of what is known as the post-mortem interval (PMI), which is the approximation of the time interval after death or time of death (Lopes de Carvalho and Linhares 2001). The estimation of PMI is particularly useful in criminal investigative cases where the time interval after death exceeds the point at which the forensic pathologist can determine it (Amendt *et al.* 2011). A forensic pathologist may use various indicators (early post-mortem changes) on the deceased to determine the time of death. These include: early

post-mortem changes including algor mortis (the temperature changes that occur in the body post-mortem) (Vass 2001), livor mortis (also referred to as hypostasis, which is the intravascular pooling of blood due to gravity, resulting in the discolouration of the affected internal organs and the skin) (Vass 2001); and rigor mortis (post-mortem muscle stiffening as a result of the release of calcium stores within the muscle fibres causing the stiffening) (Knight 1997; Vass 2001).

Other early post-mortem changes that the pathologist can use for PMI determination are found in the skin. The skin undergoes post-mortem histological changes as soon as six hours following the time of death (Bardale *et al*. 2012); thus, skin changes are a good indicator of PMI. A study by Bardale *et al.* (2012), found no histological changes in the skin prior to six hours after death, however from hour six, changes could be seen. Another histological skin post-mortem change is focal dermal-epidermal separation (Kovarik, Stewart and Cockerell 2005; Bardale *et al*. 2012). This is the separation of the epidermal constituents from the dermis. The separation of the epidermis from the dermis results in the formation of blisters; this change is the gross result of a dermal-epidermal separation histological change (Bardale *et al.* 2012). Eccrine duct necrosis, which is cell death of the sweat gland ducts, is also a post-mortem histological skin change (Kovarik, Stewart and Cockerell 2005). Eccrine duct necrosis is characterized by ballooning and vacuolization of the epithelial duct cells and is associated with bullae (blister) formation.

These indicators can provide the forensic pathologist with an accurate estimation of the time interval after death only within the first 72-hours following death. Beyond this time, other decompositional changes will have begun and these may alter the abovementioned indicators. However, the 72-hour time frame and the occurrence of these indicators may be influenced and modified by various environmental and physical factors including, but not limited to: temperature, humidity, medium (whether the body is found on land or in water), the presence or absence of clothing and various other factors (Amendt, Krettek and Zehner 2004).

Smith (1988), Goff (2010), Horenstein, Rosso and Garcia (2011) describe five stages of decomposition. These include: the fresh stage, the bloated stage, active decay, post or advanced decay and the skeletonization stages. The fresh stage of decomposition can be noted by a change in the colour of the abdomen, with the first wave or early colonizing insects entering the body through

the natural orifices or any wounds located on the body (Goff 2009). During the bloated stage, the body distends significantly due to the digestive action of the anaerobic bacteria that are present in the digestive tract (Hyde *et al*. 2013). A large amount of maggot masses can be observed externally on the body, however even greater numbers of maggots are present internally (Goff 2010). Maggots are the larval stage of the order Diptera. The attraction of more adult insects, particularly Calliphoridae species, is at its greatest during this stage. This is due to the odour emitted by the decaying body caused by the digestion of tissue by bacteria (Horenstein, Rosso and Garcia 2011; Hyde *et al* 2013). In the stage of active decay, the abdomen breaks open and gasses such as hydrogen sulphide, methane and cadaverine (Hyde *et al*. 2013) among others, are released causing a decrease in the distention of the body. During this stage, species of Coleoptera can be observed, although some could have been present during the early stages. Towards the end of this stage, most of the Calliphoridae larvae are beginning to leave the body to pupate. The remaining flesh on the body (if any) indicates the post or advanced decay stage. During this stage, the wave of Calliphoridae species has been replaced by the coleopteran species. All that remains of the body during this stage is clothes bones and hair, with few (remaining) insects feeding on the body. Most of the insects that remain during this stage are those that are found in the soil environment (Goff 2010).

In cases where the body is discovered in the early stages of decomposition (the fresh and bloated stages), the forensic pathologist uses the early post-mortem changes that occur in the body to determine the PMI (Amendt *et al.* 2011). However, in cases where the body is discovered in the late stages of decomposition (active and post decay stages), or in the skeletal stage (Campobasso and Introna 2001), the early post-mortem changes are no longer present and the forensic pathologist is thus unable to determine the PMI (Wells and LaMotte 2010). Beyond the point at which the forensic pathologist can determine the PMI, a forensic entomologist can make use of the insects found on the body for the PMI determination.

2.2 Post-mortem Interval (PMI) Determination

Insects can begin colonizing the body seconds to minutes after death and this means they are good indicators of the approximate time of death (De Jong 1994; Anderson, 1997; Aballay, Domínguez, Campón 2012). This is due to the development of the different insect species' life cycles, and the

pattern of succession of the different insect species and orders, which correspond directly to the different stages of decomposition of the body (Byrd and Castner 2010).

The forensic entomologist's PMI determination can be by means of either one of two methods; determining the age of the oldest necrophagous (carrion eating) insect on the body (Ortloff, Peña and Riquelme 2012), or by use of the insect ecological succession. When determining the age and life cycle stage of the oldest necrophage, the entomologist will need to use a maggot growth curve, which estimates the age of the maggot from its size, weight or rate of development (Byrd and Castner 2010). The entomologist can also use a method known as thermal summation (Richards and Villet 2008; Ridgeway *et al.* 2014). This method makes use of not only the size and age of the necrophage, but also considers the environmental temperature (Amendt *et al.* 2011).

The determination of PMI by insect ecological succession is the phenomena where specific insect species will be found on the body at different stages of decomposition, and therefore signify the different decomposition stages of the body (Gennard 2007). There are four ecological categories of insects that may be present on the body, thus making hierarchical identification extremely important in the PMI determination (Amendt, Krettek and Zehner 2004). The categories are: necrophagous insects, which feed on carrion; predacious and parasitic insects, which feed on the necrophages (Amendt, Krettek and Zehner 2004); omnivorous insects, which feed on the carrion and the necrophages; and opportunistic or incidental insects, which use the body as an expansion of their environment (Gennard 2007).

The time taken for completion of the decomposition stages and transition between the different stages is dependent on not only the environmental factors in which the decomposing body is found, but also the type of carrion, as decomposition will also be size dependent (the larger the size of the decomposing body, the longer it will take to decompose) (Villet 2011). In the international context, particularly in colder climates, it is possible for a decomposing body to complete all five stages of decomposition from between 10 months and 2 years (Gennard 2007), whereas in the South African context and warmer climates, it is possible for a body to go from the fresh stage to skeletonization in less than 2 months (Gilbert 2014).

Ecological succession and its transitions between different stages are linked to the arrival of insects based on their dietary patterns and requirements. This in turn directs the time taken to transition between the various decomposition stages. The arrival of different insect species on the body is directed by their dietary preferences. These dietary preferences affect the cues used by different insect species to detect the decomposing body (Villet 2011). The necrophagous flies detect the body by the sulphur-containing gases emitted by the digestive action of anaerobic bacteria (Horenstein, Rosso and Garcia 2011; Hyde *et al* 2013). These gases are released in the bloated stage and cause the distention of the body (Goff 2010). Once the necrophagous flies have arrived at the body/carcass, the predatory insects use olfactory cues, emitted from the interaction of the necrophages and the body (Villet 2011). This interaction attracts the predatory insects to the body. The drivers then, of ecological succession, include the dietary requirements of different insect species attracted to the decomposing body, therefore the arrival of one species to the body requires the presence of the other, in order to maintain ecological succession. This is a phenomenon known as "facilitation", where the presence of one ecological category of insects affects the presence or absence of another. Maggots play a huge role in facilitation. They reduce the presence of the 'wet-phase' necrophages, to make way for the dry-phase necrophages that feed on the body that is more or less dried out, or that has no remaining flesh (Villet 2011).

Dietary requirements, facilitation and competition (intraspecific and interspecific), are a few of the many processes that drive ecological succession (Villet 2011). However, all these factors are driven by climatic conditions. How many and the types of species found on the body, how reproductively active they are, and their feeding patterns are all factors dependent on the climatic conditions in which the body is found. It is then important that forensic investigations be treated on a case-by-case basis, ensuring that conditions are known, because ecological succession can be region, temperature, climate, and species (both the carrion and insects on the carrion) specific. This information can thereby allow for PMI determination by ecological succession to be estimated or calculated.

2.3 Forensic Entomology in the South African context

The first record of forensic entomology in South Africa was of research conducted by Dr Andre Prins of the South African Museum between the late 1970's and 1989 (Williams and Villet 2006). He discovered the Asian *Chrysomya megacelpha*, a Calliphoridae species, and published his research on

the life cycles of six Calliphoridae species and assisted the South African police with murder cases associated with decomposition (Williams and Villet 2006). A few years after Dr Prins' work was published, the Forensic Entomology Investigation Team of the Universiteit van die Oranje Vry Staat (FEITUOVS) was established (Williams and Villet 2006). This team went on to document work on entomotoxicology in the South African context and provided an inventory of forensically important insects occurring in the Free State (previously known as the Oranje Vry Staat). South African empirical studies on PMI determination by use of insect ecological succession began in 1993 and these were pioneered by Professor MH Villet in the Eastern Cape Province (Williams and Villet 2006). In May 2000, the first documented case of the use of the forensic entomological data, collected by Dr Mervyn Mansell, was used as evidence in the conviction of a murderer in the Supreme High Court of South Africa (Williams and Villet 2006). This case and other high-profile cases involving work done by Mansell, aided in the acceptance of forensic entomological evidence in the South African legal system (Williams and Villet 2006). The development of forensic entomology in South Africa has also seen the introduction of the discipline in various institutions of higher education, with postgraduate students undertaking topics that have added significant geographically contextual knowledge to the discipline. This includes studies on the identification of various insects of forensic importance (Daniel, Midgley and Villet 2017; Lutz *et al.* 2018), and advances in entomotoxicology (Williams and Villet 2014; da Silva, Wilhelmi and Villet 2017). These scientific empirical studies and many other legal investigative cases undertaken by other South African researchers, have contributed to the development of the field of forensic entomology, particularly in the South African context (Williams and Villet 2006).

2.4 Other applications for medico-legal forensic entomology

Previously, the stored food function of forensic entomology was to determine the PMI, but it has also been used in a variety of applications, including indicating the cause of death. Benecke (1998) reported a case of a man who was found to have been infected by a drug resistant strain of bacteria. Red stained pupae were collected from the man's body and reared in a laboratory, however, the adult insects emerged earlier than what is documented for that species. Due to this and the uncommonly red stained pupae, tests were conducted on the pupae for a bacterium that produces a red pigmentation and they tested positive. This evidence was used to confirm that the man was infected by a sepsis causing bacteria that resulted in his death (Benecke 1998).

Another application of forensic entomology is to ascertain the possible movement of a corpse post-mortem (Marchenko 2001). The endemic nature of insects also makes it possible to determine whether the location, at which the body was found, is the location where death occurred or whether the corpse was moved from one location to another post-mortem (Marchenko 2001). If a certain species of insect is found on the body but is not endemic to the area in which the body is found, it may be suggestive of the body being in more than one location peri- or post-mortem (Marchenko 2001). The importance of geographically specific data is thus particularly important for this application of forensic entomology.

In cases where the body is found in the post decay stage of decomposition, where the only remains of the body are skin, bone and hair and no flesh are available for toxicological testing, the necrophagous larvae found on the corpse can be used (Amendt *et al.* 2011). Many of the recreational drugs (opiates, cocaine and amphetamines) used by people can be detected using the dipteran larvae and pupae casings (larval gut contents) as substitutes for the human tissue samples generally used for toxicological analyses (Amendt *et al.* 2011). The larvae feed on the corpse and in turn ingest drugs present in the tissue of the corpse. The drugs then remain in the larvae and the pupal casings of the insects. Empirical studies by Beyer, Enos and Stanjić (1980) demonstrate the use of *Cochliomyiamacellaria* (Calliphoridae) larvae to identify the presence of phenobarbital, a barbiturate, in a suspected drug overdose case.

Forensic entomology has also been used in the investigation of cases of myiasis. Myiasis is the colonization of living tissue by insects, particularly the larvae of the Dipteran order (Wells and LaMotte 2010). The insects that are the first colonizers of the body after death (mainly blowflies and fresh flies), are usually the insects that infest living tissue in cases of myiasis (Amendt *et al.* 2011). Myiasis can be divided into three forms according to the ecology of the insects that infest the living tissue: Obligate – the larvae found on the patient/person are non-carrion eating and feed only on living tissue (Trombetta *et al.* 2009); Facultative – adult flies take advantage of open wounds as nutrient rich areas for ovi-position (Trombetta *et al.* 2009); and Accidental parasites – these are insects that are not normally parasitic in nature, but may be accidentally inhaled or ingested resulting in an infestation of living tissue (Amendt *et al.* 2011). Myiasis commonly occurs in a setting of abuse and

neglect, primarily in the young, the elderly, and those in poor physical or mental health, as these are usually people that require others to take care of their personal hygiene (Amendt et al. 2011). Chronic alcohol and drug users are also susceptible to myiasis, as they are prone to self-neglect and injuries, leaving open wounds exposed to parasitic larvae (Amendt *et al.* 2011). The neglect of personal hygiene may also be a contributing factor. Analysing and determining the period of insect activity, similar to PMI determination, can provide a timeline of neglect and abuse in a patient (Amendt *et al.* 2011).

2.5 Limitations in forensic entomology

Although forensic entomology can contribute to evidence in death, particularly forensic investigations in evidence collection, there are limitations to this science. One of these is in the determination of PMI, which is done according to when the first insect colonized the body, which is an indication of the period of insect activity, so this may not be reflective of the exact time of death (Marchenko 1989). Factors such as burial, clothing, wrapping of the body and burning of human remains may delay and prevent insect colonization, or could result in insects that typically arrive later in the succession, to arrive earlier than expected (Anderson 2010). However, clothing and wrapping of a body was shown to only delay Dipteran oviposition (Bhadra, Hart and Hall 2014) during the winter season (Kelly 2006). Wrapping showed no significant difference in oviposition over the other seasons in South Africa (Kelly 2006; Kelly *et al.* 2009).

Since the development and advancement of the field of forensic entomology in South Africa since 2000, the term PMI has been replaced with terms that are more descriptive to the circumstances surrounding the body on which the insects are colonising (Villet and Amendt 2011). Terms such as period of insect activity (PIA), time of colonisation (TOC) (Anderson 2010), and post-mortem submergence interval (PMSI) (Merritt and Wallace 2010), have in recent literature been used to describe what most literature refers to as the PMI. These terms are better suited to describe PMI as they do not refer to the actual time of death, but to the time interval at which insects begin to colonise the body (Villet and Amendt 2011).

While the insects that colonise a body can be a source of important information, their effects may also cause misleading artefacts. The feeding activity of insects on a body can alter evidence such as

bloodstains. This can be as a result of insects walking or crawling through wet fluid evidence and in so doing either altering existing stains or creating new ones (Rivers and Geiman 2017). This can cause interference when attempting to reconstruct the possible crime scene. This can result in not only the misinterpretation, but also the loss of potential evidence and thus an incorrect determination of evidence in a criminal investigation. However, in South Africa the police just let the land owners clean the body disposal site(s) before the forensic entomologists have had an opportunity to visit the site.

Empirical studies by Komar and Beattie (1998) indicated how insect activity on a body can produce artefacts that resemble peri-mortem (events at or near the time of death) sexual assault. In cases where the body is discovered in the active decay and later stages of decomposition, the only evidence of sexual assault that may remain is the clothing pattern of the victim; the physical arrangement of the clothing may be suggestive of sexual assault (Komar and Beattie 1998). Clothing patterns can also be the only evidence available of possible peri-mortem wounds for forensic investigation in cases where bodies are found in the advanced stages of decomposition- this is true particularly for gunshot and stab wounds (Komar and Beattie 1998). Decomposition and insect activity can alter the distinctive features of gunshot and stab wounds on clothing (Bostock, Parks and Williams 2019). The study of clothing damage for possible stab wound evidence, rips and tears is known as clothing damage analysis (Bostock, Parks and Williams 2019). This, however, can be complicated by insect activity and by insect disturbance of the clothing pattern on the body. Maggot masses have been shown to disturb and modify clothing patterns in order to access the body (Komar and Beattie 1998). Although most maggots are known to enter the body from the natural orifices, wound sites have also been shown to be easy access sites for maggots. The disturbance, without thorough investigation of the crime scene, may result in the misinterpretation of evidence, particularly if insects are not found on the body at the point of discovery (Komar and Beattie 1998).

Dried ant bites can resemble ante-mortem (which refers to events occurring before death), and peri-mortem inflicted injuries (Anderson Parker *et al.* 2010). Ants are omnivorous and feed on both the necrophagous insects colonizing the body, and on the body itself (Amendt *et al.* 2011). They are also opportunistic feeders and will feed on anything that is in their microenvironment, including a body if it is found within an area where the ants are active. Once the ant-bites on the corpse have aged and dried, particularly cutaneous bites, they may resemble abrasions (Figure 1) caused by blunt force trauma (Campobasso *et al.* 2009), and cigarette or chemical burns (Amendt *et al.* 2011). Ant bites

may also alter existing wounds and injuries (Campobasso *et al.* 2009) and this can also create ambiguous evidence regarding the weapons causing the wounds, and the events leading up to death (Anderson Parker *et al.* 2010).

The adults and larvae of dermestid species also produce artefacts. Because they feed on severely decomposed bodies towards the final stages of decomposition, the remaining tissue may contain homogenous, round holes that can resemble gunshot wounds. The dermestid larvae produce jagged, irregular edges that are dissimilar to the smooth edges produced by feeding fly maggots (Byrd and Castner 2010).

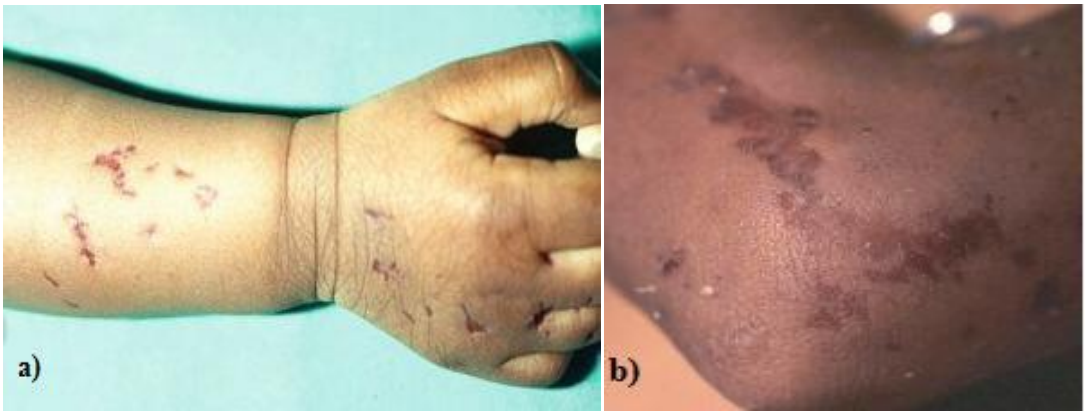

Figure 1: Post-mortem insect activity, particularly cockroach (a) and ant (b) scavenging may resemble abrasions caused by peri-mortem and ante-mortem inflicted injuries (photos courtesy of http://thehealthscience.com/showthread.php?168160-Post-mortem-Changes).

Insect activity can also produce artefacts that resemble gunshot wounds. A case study reported by Prahlow and McClain (1997), demonstrates a homeless man who presented with multiple abdominal wounds that resembled small calibre gunshot wounds. Upon further investigation of the scene, pupa casings were discovered and although the species was never determined, the defects were deemed to be as a result of larval activity (Prahlow and McClain 1997).

Experimental studies by Ururahy-Rodrigues *et al.* (2008) demonstrate how *Coprophanaeus lancifer*, a coleopteran species, not only produces post-mortem artefacts that resemble peri-mortem and ante-mortem injuries, but can also cause displacement of the body from where it was originally placed.

The abovementioned examples of insect produced post-mortem artefacts demonstrate the importance of thorough scene investigations and empirical research studies into the effects of post-mortem insect

activity on a body and how these can be identified as post-mortem artefacts caused by insect activity (and not misinterpreted as evidence), in criminal investigative cases (Prahlow and McClain 1997; Ururahy-Rodrigues *et al*. 2008).

2.6 The use of Pig carcasses as human analogues

The use of pig carcasses in forensic entomology research is well documented, with studies varying from the ecological succession of arthropods on a pig carcass, the determination of post-mortem artefacts caused by insect activity (Ururahy-Rodrigues *et al.* 2008), and the distribution of various drugs and their effect on arthropod development in the field of entomotoxicology (Introna, Campobasso and Goff 2001). Ideally, using human bodies would be preferable as the results of these studies are applied to processes that occur in humans, however, due to ethical and practical reasons, this is not possible thereby necessitating the use of human models.

Pig models have been used widely within this field because they have similar internal anatomy as well as physiological properties to those of humans (Schoenly *et al.* 2006), but also because of the ease of their experimental manipulation, control and replication. Pig models are also more uniform than humans, in that humans of the same age and sex, race can have a great variance and in certain instances variances in diet (Matuszewski *et al.* 2019). However, different animal species can and have been used as human analogues and this is dependent on the purpose of the study. Recommendations in terms of human analogues by Matuszewski *et al.* (2019), are that human models are only required for comparative purposes with other animal models and for final validation studies because they are not adequately available for research purposes. Due to the fact that pig analogues are more uniform, more readily available, inexpensive and have a greater similarity to humans than other models (Schoenly *et al.* 2006), they are a more sensible choice as human analogues than any other model (Matuszewski *et al.* 2019).

Pig models are not only anatomically and physiologically similar to humans, but empirical studies have also shown that the histological and biochemical properties of pig skin closely resemble those of human skin (Godin and Touiton 2007). The focus of the current study will be on histology, and it is for this reason that pigs were chosen as a human analogue in this study.

2.7 The use of microscopy in forensic entomology

There is extensive use of microscopy in the forensic sciences, with various microscopy imaging techniques being employed in the analysis and identification of body fluids (Virkler and Lednev 2009), and various fragments (paint, fibres and gunshot residues), collected at a crime scene (Zadora and Brozek-Mucha 2003). These include the use of the scanning electron microscope (SEM), which uses an electron beam to scan the surface of the sample and forms an image by utilising primary electrons (electrons that are back-scattered by the specimen), or secondary electrons (which are those that are emitted by the specimen). The electron beam is emitted by an electron gun and this beam scans the specimen, secondary or backscattered which is located at the top of the microscope and the image created can then be viewed on a monitor connected to the microscope (Reimer 1985).

In the field of forensic entomology, the number of empirical studies using microscopy imaging techniques to study insect bite marks is limited. An Argentinian study by Zanetti, Visciarelli and Centeno (2014), employed macroscopic imaging techniques (using a digital camera), in the analysis of coleopteran bite marks on porcine tissue under controlled laboratory conditions. This study was able to document the patterns of bite marks resulting from the feeding patterns of *D. maculatus* on pig trotters using macro photography. The patterns observed were that both the larval and adult stages of *D.maculatus* fed on the soft tissue of the pig trotters, resulting in holes/lesions on the soft tissue. Over time and with continued feeding, the number of lesions increased, and existing lesions became larger in size. The edges of the lesions were serpiginous and not smooth and this was reported to be due to the biting action of *D.maculatus.* Once the soft tissue was no longer present, mandibular marks were noted on bones (Zanetti, Visciarelli and Centeno 2014).

At present, this Argentinian study is the first to conduct a macroscopic documentation of insect bite marks on skin, however, no microscopic imaging studies have been documented on insect bite marks globally. The present study was the first to attempt to document the patterns of tissue damage on skin caused by insect activity microscopically.

2.8 Insect mouthparts

Different insect species have different mouthparts, and these are adapted to their feeding patterns and the type of food they consume. The mouthparts are not only for feeding. Insects that feed on liquids

have sucking mouthparts, a proboscis, which functions like a straw and draws up fluid. This type is seen in some adult members of the Diptera order (Karolyi *et al.* 2014). In the adult housefly and a few other fly species, this proboscis is sponge-like and draws up liquefied food through capillary action (Chapman 2009).

Insects with chewing mouthparts have a pair of mandibles that are located on either side of the mouth. These are typically the largest structures in the mouthparts and are used to chew, tear and bite. Chewing mouthparts are the most common in adult insect. Adult beetles have mandibulate mouthparts, which means they use their mouthparts for chewing/grinding before ingestion of the food. These are considered primitive and are made up five different structures namely; the labrum, the labium, the mandibles, maxillae and the hypopharynx, each with different functions (Chapman 2009). The labrum lies immediately in front of the mouth and is formed from the fusion of a pair of cuticles on either side of the mouth (Chapman 2009). Its use is mainly for the containment of food. Structurally, when the beetle is not feeding the labrum rests on the mandibles which are immediately behind it. The mandibles are on either side of the mouth and are described as a pair of jaws for chewing and grinding. This happens by the transverse movement of the pair of mandibles meeting in front of the mouth to create the grinding movement. The mandibles are cusped on the biting surface and these cusps are hardened to create the biting/grinding action when the mandibles come together. The maxillae then lie behind the mandibles. They are also a pair of mobile appendages. The mobility allows for the manipulation of the food behind the mandibles and move the ground up food towards the mouth (Chapman 1998; Chapman 2009).
The hypopharynx, which is also attached to the mandibular segment is described as a tongue-like structure that is membranous.
Behind the hypopharynx is the labium that is similar in structure to the maxillae but is fused in the midline, also known as the "back lip". It acts as a scoop that prevents food from moving backwards.

Fly larvae have a pair of hooks that resemble mandibles and are also used for tearing and biting. The shape and morphology of these hooks are distinct and are often used to distinguish among species of the same families (Chapman 1998; Fusari, Dantas and Pinho 2018). These mouthparts are also known as cephalopharyngeal skeleton. These are made up of sclerotized structures. The cephalopharyngeal skeleton is important in the biting and particularly the blowfly larvae that feed on a corpse. The

cephalopharyngeal skeleton is mostly internal with the only visible part of this being the distal end of the pair of mouth hooks. The skeleton is made up of the mouth hooks, the intermediate sclerite and the basal sclerite.

The mouth hooks are a pair of scleritized structures. The distal end of these mouth hooks is curved downwards, sickle shaped and sharp to allow for chewing and grinding. Higher up the hooks become more enlargened and take on a triangular shape. A joint is form between the intermediate sclerite and the proximal end of each mouth hook.

The intermediate sclerite is distal to the mouth hooks and it is shaped in the form of an H with two anterior and two posterior arms. The anterior arms are connected to the mouth hooks and the posterior end of the arms connected to the basal sclerite.

The basal sclerite is in the thorax of the larvae and also being the largest part of the cephalopharyngeal skeleton. The muscles attached to the basal sclerite allow it to act as a suction pump.

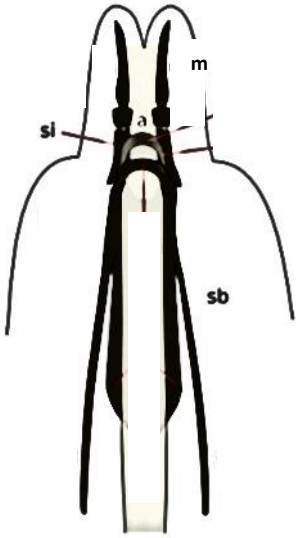

Figure 2: The cephalopharyngeal skeleton of Dipteran larvae. m- mouthhooks, si- intermediate sclerite, sb - basal sclerite

Mouthparts play an important role in insect morphology; they are not only for feeding but assist in processing and manipulating the food to allow for feeding (Chapman 2009). In omnivorous insects like the ant (de Souza *et al.* 2020), mouthparts are also used to decapitate, dismember and capture their prey (Schmidt 2014).

2.9 Aims and Objectives

This study's aim was to perform a macroscopic and histological analysis on soft tissue exposed to insect activity for patterns of tissue damage, using pig carcasses as human analogues.

The objectives of this study were:

1. To macroscopically (by use of digital camera), identify and describe the patterns of tissue damage caused by various insect species
2. To identify and describe the patterns of tissue damage caused by insect activity using a light microscope
3. To identify and describe the mouthparts of the insects collected using a scanning electron microscope
4. To attempt to match the insect bites on the skin to the species, by the shape and size of insects' mouthparts.

The research question was: What are the patterns of soft tissue damage in pig models, resulting from insect feeding activity?

Chapter 3: Materials and Methods

3.1 Study Design

This was a prospective, descriptive and observational study. The study was conducted on two deceased piglets, that were used as human analogues. The piglets were donated by TOPIGS SA which is pig breeding farm located in Dorstfontein. The piglets died of natural causes most likely due to red gut (haemorrhagic bowel syndrome) which is a common cause of death for young pigs in breeding farms. The number of piglets used was not a factor as multiple biopsies were able to be taken from multiple areas of the carcasses. As this was a descriptive study, the sample size was the number of biopsies taken and not the number of pigs. The piglets were between four and eight weeks of age and were of the species *Sus scorfa domesticus* (Linnaeus 1758).

3.1.1 Ethics

The University of the Witwatersrand's Animal Ethics Screening Committee (AESC) has granted this research project ethical clearance (Ethics clearance certificate number: 2013/21/01).

3.2 Study site

The study was conducted at Frankenwald Johannesburg North (Figure 2) (coordinates 26°04'14" S 28°06'12Ë), for the duration of the study. Frankenwald is a research site owned by the University of the Witwatersrand. It is located in Kelvin, Sandton. An open area, that is not residential in nature, was used for this study because the processes of autolysis and putrefaction are gas producing processes (nitrogen, methane, hydrogen sulphide and many other), which result in the release of foul-smelling odours (Campobasso and Introna 2001). The area where the study was conducted was fenced off to limit any public disturbance as well as any disturbance from large vertebrates such as dogs. The area is characterised by the presence of sparse vegetation (Figure 3), particularly in the winter months due to the absence of rainfall.



Figure 3: A Google Earth image of the study site in Frankenwald

An experimental observation was conducted in the winter months, June to August of 2015. The timing of the study was due to the availability of the donated pigs from TOPIGS SA. Johannesburg is at an altitude of 1.7 km above sea level and is characterised by a subtropical climatic zone, with warm to hot summers and characteristic rainfall during these months. The winters are cool to cold, with minimal winter rainfall recorded. The average annual rainfall is approximately 700 mm. The coldest months in Johannesburg are July and August (Goldreich 1992).

The insect rearing was conducted in the entomology laboratory at the Johannesburg Forensic Pathology Services in Braamfontein (coordinates 26°11’27”S 28°02’36E), and all the histology and microscopic imaging was done at the Pathology Division at the National Institute for Occupational

Health (coordinates 26°11’28”S 28°02’36E). Insect rearing was only conducted to confirm species identifications from larvae collected during the study.

3.3 Data Collection

3.3.1 Field study

Two piglet carcasses were placed in Gelvanised steel mesh cages. This was to prevent scavenging of the piglet carcasses by small vertebrates such as rodents but allow for entrance of carrion-feeding arthropod fauna (Figure 4a). The cages were kept in a fenced off area to limit human disturbance to the researchers only (Figure 4b).



Figure 4: Research enclosure at the Frankenwald field site, Johannesburg. The piglets were placed in galvanised steel cages, fitted with diamond mesh to prevent mammal and avian scavengers (a), within an access-controlled field site (b). The boxes were meshed to allow arthropods access to the piglets, but to keep small vertebrate scavengers out.

The field site enclosure has no vegetation and is in direct sunlight with no shade from external vegetation. The carcasses were exposed to these conditions until they reached the active decay stage of decomposition. Sampling commenced on the day the piglets were placed at the field site. Initial photographs of the fresh and undamaged were taken. All the carcasses were observed and photographed every third day to record the progress of decomposition and the presence of bit marks and feeding activity. The pigs were turned over to ensure analysis of the tissue damage by noting the site of damage, the shape of lesions noted, discolouration noted on the surface of the skin as well as all insects present in or around the lesions noted. Both the superior and inferior aspects of each pig was recorded. Once the photos of the inferior aspect (the surface of the pig that was on the cage) of

each pig were captured, the pigs were returned to their original placement. This was done each time images of the pigs were captured.

Insects that were noted to be in or around areas of damaged were collected every three days. An average of five individuals of each species were collected from areas of insect damage.
Some of the insects collected were killed immediately in a killing jar, with ethyl acetate, at the study site and preserved. The killing jar is a sealable glass jar with a thin layer of dried Plaster of Paris, which is porous and retains the ethyl acetate, which is used as a killing agent. The killed specimens were then were taken to the laboratory for identification. Living maggots and beetle larvae were also collected and placed in a screw top plastic specimen jar. These were also taken to the lab for rearing. These were reared to the adult stage in the laboratory, after collection and an identification guide by Lutz *et al.* (2018) was used to identify the blowflies. The rearing was done by placing insects into plastic containers lined with sawdust. A fine mesh was used for the lid to allow for ventilation but prevented the insects from escaping. Chicken livers were used as a food source for the maggots and corned beef was used as a food source for the beetle larvae. Both maggots and beetle larvae were reared to adult stage. Once they reach the adult stage, the insects were killed in an ethyl acetate killing jar and identified to species level. All specimens were clearly labelled with the date of collection and region/site (on the carcass) of collection.

Due to the fact that temperature is one of the many abiotic factors that affect decomposition, which thereby affects insect succession, daily ambient temperature was measured using a Thermacron® iButton® (Model: DS1922L) which was placed on the inside of the cage in a protective container at the study site for the two months' duration of the study. The iButton recorded temperatures in one of the mesh cages near the carcass. These temperatures were recorded every two hours and mean temperatures for each day were calculated with a record of the minimum and maximum temperatures for each day over the duration of the study. Temperature data from a weather station closest to the study site were requested from the South African Weather Service (SAWS). This data was obtained from the Johannesburg Botanical gardens (station number 0475879 0, JHB BOT TUIN coordinates 26°09'21"S 27°59'56"E) which is approximately 18 km from the study site (Figure 4). This data was sourced from the SAWS for comparative purposes with the temperature data recorded in the study from the iButton. The environmental conditions at the study site were recorded and SAWS data was

A t-test was used to compare the iButton temperature data and the SAWS temperature data at 95% CI.

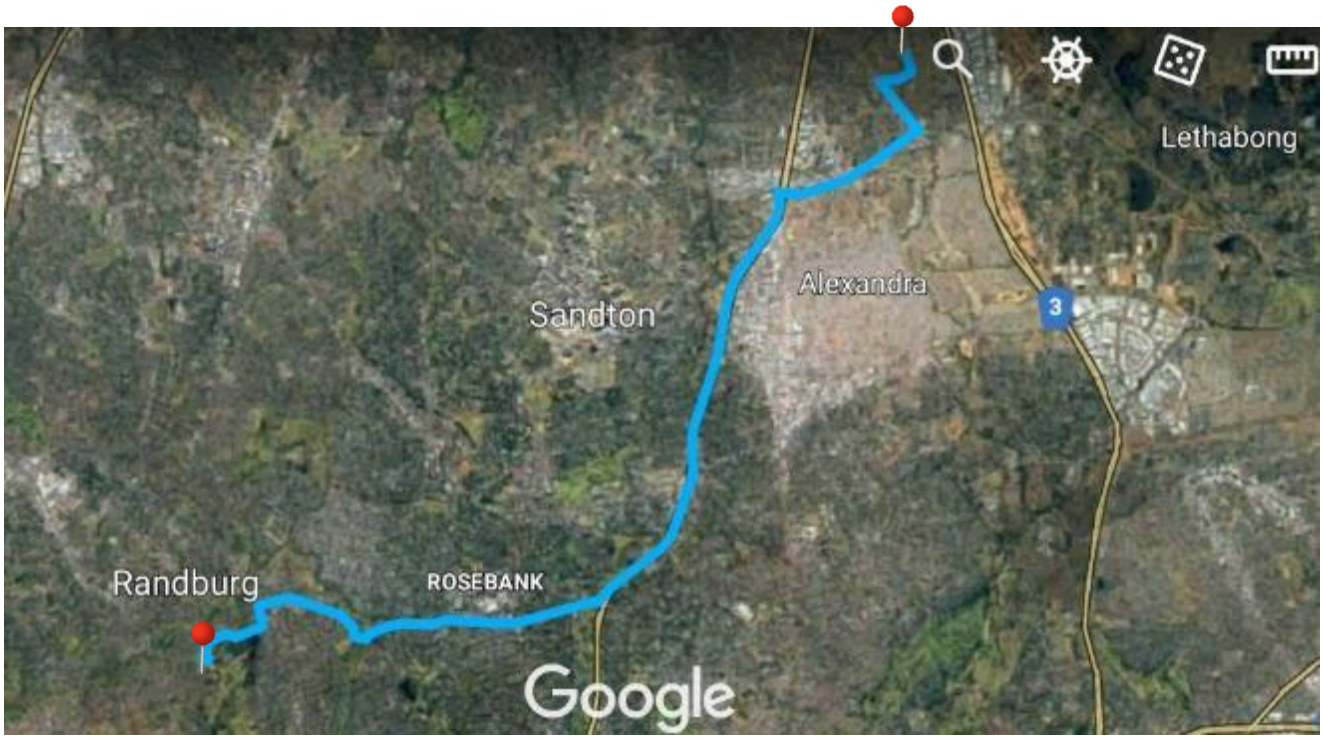

Figure 6: The distance (approx. 18km) between the study site (Frankenwald) and the South African Weather Service weather station (Johannesburg Botanical Gardens)

An initial biopsy (Day 0) on the day the pigs were placed at the study site was taken as a control for comparative purposes. The sectioned biopsies were then prepared for histological analysis (as described in 3.3.3 below). The section consisted of the entire depth of the lesion(s) (i.e. skin and subcutaneous tissue). The lesions caused by the different insect species were collected and sectioned using a Keyes cutaneous round 5 mm stainless steel dermal punch body skin piercing tool (Figure 5). Biopsies were taken from different lesions over the first three stages of decomposition: namely the fresh stage, the bloated stage and the active stage (no lesions were sectioned more than once over the duration of the study as biopsied lesions had a higher likelihood of oviposition by adult insects, thus affecting the pattern of subsequent bite marks). Only these stages were chosen because from the stage of active decay the skin began to slough off, which made collecting a biopsy of the skin difficult. Insects were, however, collected up to the post decay stage.



Figure 5: Keyes cutaneous round 5 mm stainless steel dermal punch body skin piercing tool

3.3.2 Insect mouthparts

The mouthparts of each insect species identified in the field study were examined using a Jeol JSM 5000 SEM. Following identification, one representative from each insect species used in the study was placed in 100% ethanol solution for 10 minutes. Once the insect had been removed from the ethanol, the head showing the mouthparts were dissected away from body of the insect using a Kyowa 1065 high power stereo zoom binocular microscope and then prepared for the SEM (as described in 3.3.4). Carbon tabs were labelled with the name of each species collected and the dissected mouthparts were placed on the allocated carbon tab and viewed using the SEM.

3.3.3 Histology

All histological and SEM preparations were performed at the histology laboratory in the Pathology Division of the National Institute of Occupational Health (NIOH).

Fixation: The labelled 5 mm skin biopsies were fixed, a process that ensures the specimen's stability by the coagulation of proteins. Fixation was achieved by immersing the specimen in a 10% sodium phosphate buffered formalin saline solution for 24 hours.

Dehydration: The specimens were then put through a series of increasing ethanol concentrations (50%, 70%, 80%, 90% and finally 100%) for dehydration and then into xylene.

Clearing, impregnation and embedding: The processes of dehydration, clearing, impregnation and embedding were all done by the Tissue Tek VIP 5JR™ (Sakura) machine overnight (Figure 7a). Samples are taken through a series of steps where samples are immersed in a clearing agent over a

period of time. The agent is then flushed out of the Tissue Tek and replaced with an impregnation agent, paraffin wax. This completely removes the clearing agent from the tissue and replaces it with the paraffin wax. The impregnated specimens were then embedded in molten paraffin wax using labelled specimen cassettes. Once they had hardened, the specimens were then ready for sectioning.

Sectioning: The formalin fixed, paraffin embedded specimens in their cassette were sectioned at 5 µm using a microtome. The sectioned specimens were placed into a water bath of between 60-65°C and then onto clean labelled glass microscope slides. Placing the sections into a water bath ensures that the sections adhere to the slide. The slides were then placed onto a slide warmer to melt the wax around the specimen in preparation for the staining and specimen adherence to the slide as well.

Dewaxing and staining: The sectioned specimens were dewaxed and stained with Haematoxylin and Eosin (H&E) using the Leica Autostainer XL (Figure 7b). The processes and time the machine took for each process can be seen in Figure 8. From then, the slides were placed into a Leica CV 5030 auto cover slide mounting machine, which mounts a glass slide coverslip onto the slide using entalin as a mounting medium (Figure 7c).



Figure 7: The histology processing machines **a)** The Tissue Tek VIP Processing machine **b)** The Leica Autostainer XL used to dewax and stain specimens for light microscope preparation and **c)** the Leica CV5030 coverslipping machine.

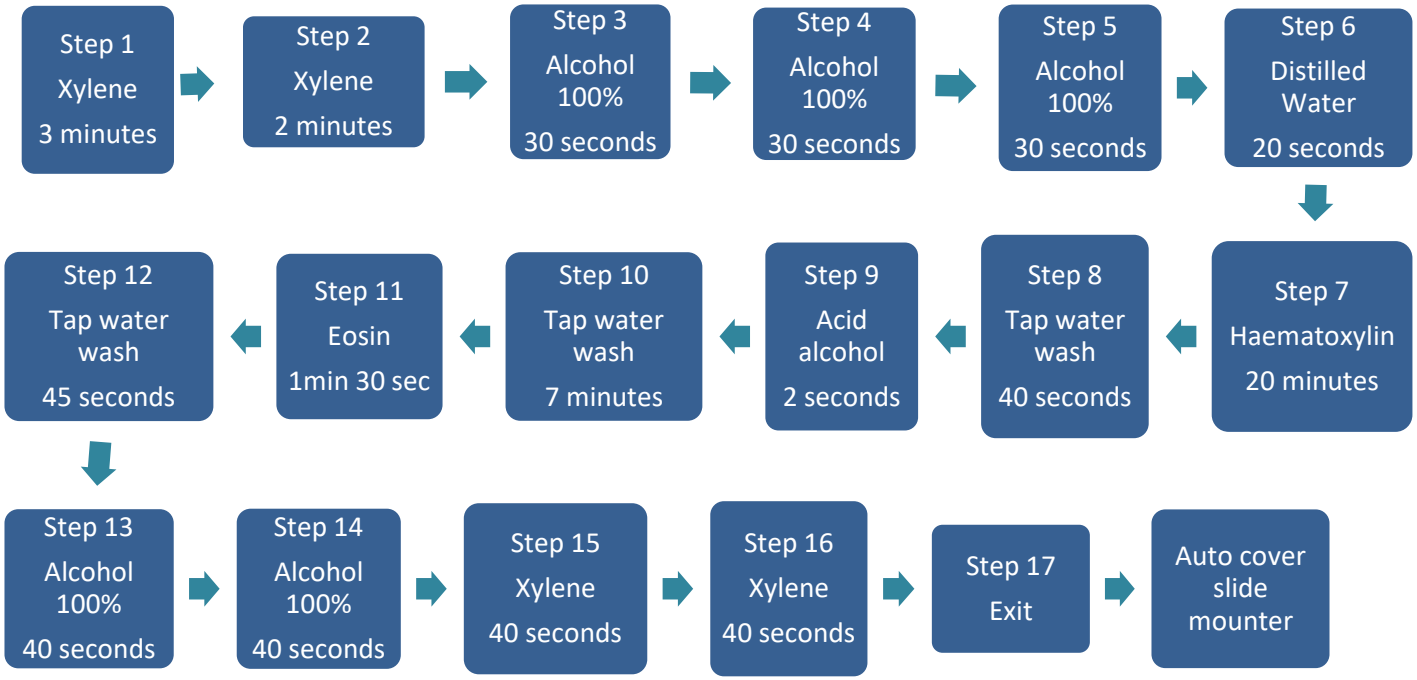

Figure 8: A flow diagram of the staining process as conducted by the Leica Autostainer XL Machine.

3.3.4 Scanning Electron Microscopy

The dissected mouthparts for SEM required fixation, which was achieved by immersing them in a 10% buffered formalin saline solution for 24 hours. The specimens were then rinsed by immersing them in a Millonig's buffered solution for one hour and then placed into a 1% osmium tetroxide (OSO_4) solution for one hour. The OSO_4 solution was created by dissolving 0.1g of crystallized OSO_4 into 10ml of distilled water. The solution was then placed on a sonicator at 20°C for 10 minutes to ensure that the OSO_4 crystals dissolve. The specimens were then rinsed with the Millonig's buffered solution and immersed into increasing alcohol concentrations (starting at 50%, then 70%, and finally 100%), for dehydration. The specimens were then placed into acetone for one hour (two 30-minute intervals), and then air dried. Biological specimens that are viewed using the SEM are required to be completely dry since the specimen chamber is at high vacuum. The dried specimens were then mounted onto labelled carbon adhesives and gold coated using an Emitech K550X argon gas-sputtering machine (Figure 9a). Once they had been coated, the specimens were then ready to be viewed using the Joel JSM 5600 SEM (Figure 9b).



Figure 9. a) The Emitech K550X argon gas gold sputtering machine. **b)** The Jeol JSM-5600

Data Analysis

Data analysis and all statistical tests were performed in Microsoft Excel 2016 using the Data Analysis toolpack. An $\alpha \leq 0.05$ was used for all statistical analyses. Temperature data recorded by the ibuttons was compared to temperature from the SAWS and t-tests were used to identify any differences in the temperatures of the study site and to ensure accurate measures of temperatures at the site. The analysis for each objective is described below.

Objective 1. To macroscopically (by use of digital camera), identify and describe the patterns of tissue damage caused by various insect species. Patterns of tissue damage were described qualitatively from visual observations made throughout the decomposition of the carcasses. No statistical analyses were performed.

Objective 2. To identify and describe the patterns of tissue damage caused by insect activity using a light microscope. Visual descriptions of the tissue damage and the patterns caused were made. No statistical analyses were performed

Objective 3. To identify and describe the mouthparts of the insects collected using a scanning electron microscope. Visual descriptions and measurements were made of mouthparts of collected insects. Only a single individual of each species was used for SEM analysis due to cost. No statistical analyses were performed.

Objective 4. To attempt to match the insect bites on the skin to the species, by the shape and size of insects' mouthparts. Based on the results of the descriptive characteristics of objectives 2 and 3, descriptions of the associations between the bite marks and mouth parts were attempted. Only descriptive assocations were made and no statistical analyses were performed.

Chapter 4: Results

Environmental conditions at the study site and forensically important insect species collected and identified are presented. Tissue damage was also analysed using macroscopic and microscopic imaging techniques.

4.1 Environmental conditions

The temperatures recorded by the iButton in the area around the pig carcasses over the duration of the study are included in Figure 10. The overall mean temperature for the duration of the study was 11.56°C (±2.2). The highest recorded daily mean temperature was 16.9°C on 2 August 2015 and the lowest recorded mean was 7.7°C on 18 June 2015. The highest daily maximum recorded temperature of 30.8°C was on 27 July 2015, with the lowest daily minimum temperature (below zero) being -2.9°C (Figure 11), recorded on 19 June 2015. There was no rainfall throughout the duration of the study. Most of the days were sunny and partly cloudy for the duration of the study.

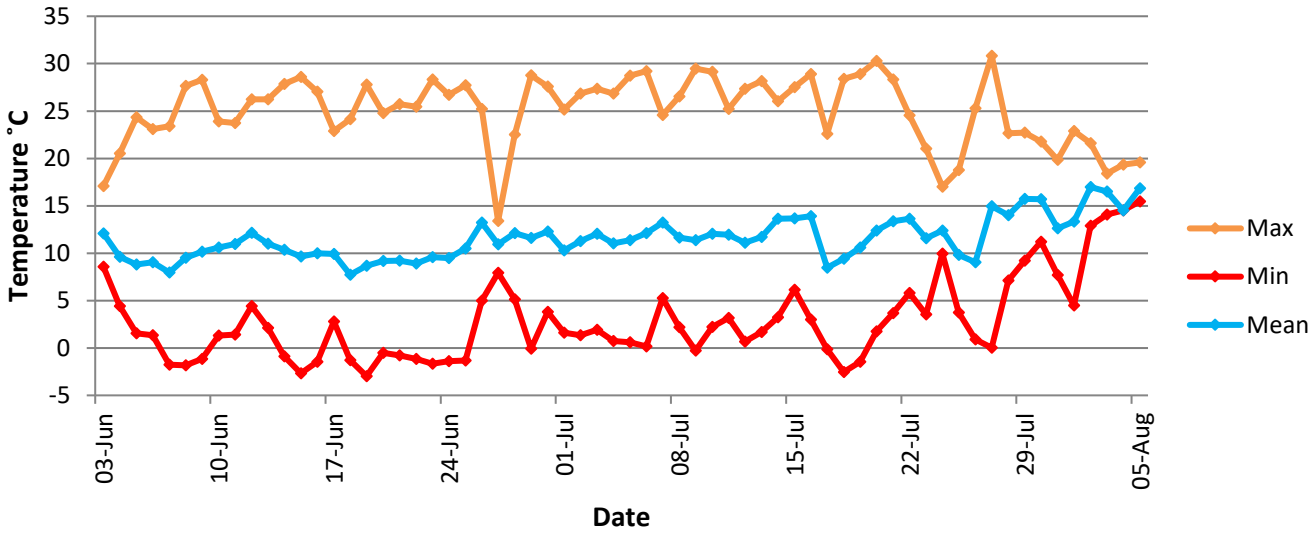

Figure 10: The temperature data recorded every two hours at the study site using an iButton. The graph shows the mean, maximum and minimum temperature for each day throughout the duration of the study at the study site.

Temperatures recorded at the Johannesburg Botanical Gardens weather station are presented in Figure 11. The overall mean temperature recorded at the weather station for the duration of the study was 11.87°C (±1.8). The highest daily mean temperature recorded was 14.8°C on 20 July 2015 and the

lowest recorded daily mean was 7.9°C on 17 July 2015 (Figure 10). The highest daily mean temperature recorded was 14.8°C on 20 July 2015, and the lowest recorded daily mean was 7.9°C, on 17 July 2015 (Figure 10). The highest maximum temperature recorded was 23.9°C on 4 August, and lowest minimum temperature recorded was 0°C on 18 July 2015.

There was no significant difference in the mean temperatures between those recorded by the iButton in the area around the carcasses and the SAWS temperatures (t-test: p = 0.245, *n* = 64, d.f = 63). However, there was a significant difference between the maximum temperatures recorded by the iButton in the area around the pig carcasses and the SAWS temperature recorded at the weather station (t-test: p<0.001, *n* = 64, d.f = 63). The same was also true for the minimum temperatures between the iButton and SAWS temperature recordings (t-test: p = 0.013, *n* = 64, d.f = 63).

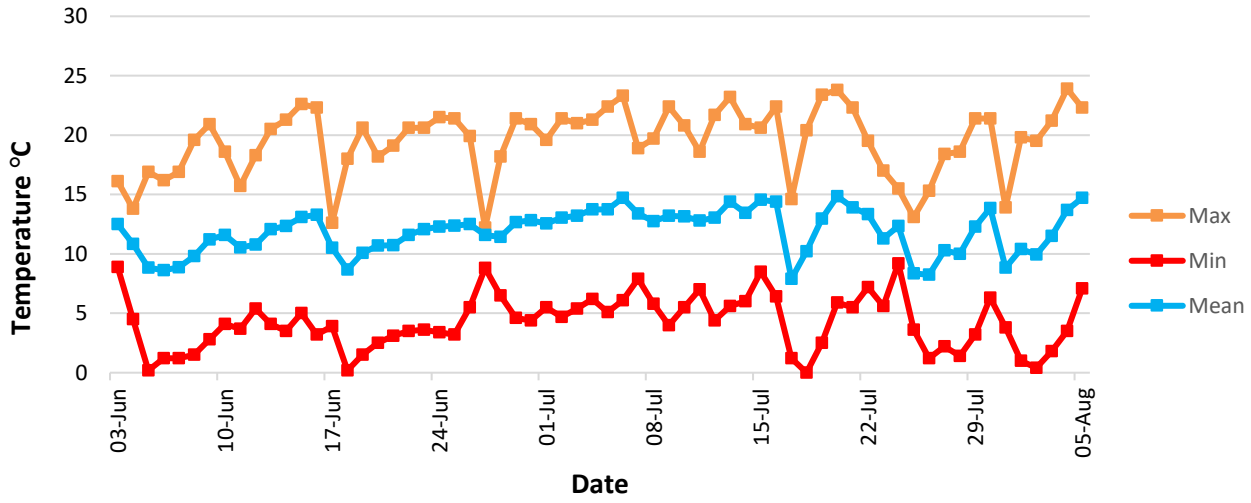

Figure 11: The temperature data recorded at the Johannesburg Botanical Garden (the closest weather station to the study site). The graph shows the mean, maximum and minimum temperature for each day, throughout the duration of the study, at the study site.

4.2 Forensically important insects

There were five insect species noted on the pig carcasses. Four were Dipteran fly species, namely, *Lucilia sericata, Calliphora vicina, Chrysomya albiceps* and *Chrysomya chloropyga*. One was a Coleopteran beetle species, namely, *Dermestes. maculatus,* was noted. One ant species was of the order Hymenopteran and family Formicidae (Table 1) was noted.

Table 1: The insects collected from the pigs at the study site and identified using the day of collection combined with Accumulated Degree Days, calculated from iButton temperatures recorded at the study site. The ADD was calculated according to Myburgh *et al.* (2013).

Stage of decomposition	Day of collection	ADD	Site of collection	Species collected
Fresh Stage One of the pigs had a pre-existing wound on the neck. The other pig had no wounds on it and no other marks. No post-mortem changes were evident on either of the pig carcasses.	Day 0 (no insect collection)	12.09°C	No insects collected	No insects collected
Bloating Fly egg clusters were observed in the natural orifices (the ears, the mouth and the snout) in the early bloating stage (Figure 9). The pigs were visibly bloated with their girth showing notable distention (Figure 10). Adult flies were noted on and around the pigs. No other insect orders were observed. Towards the end of the bloating stage larval masses were noted in the natural orifices where the egg clusters were observed. The larvae in the ears particularly, were observed in a white foam-like mass. Because maggot masses were largely observed in the natural orifices, skin biopsies could not be taken of the bite marks.	Day 4	39.6°C	Pig 1 abdomen	*L. sericata* (Larvae) *C. vicina* (Larvae) *Ch. albiceps* (Larvae)
	Day 7	67.2°C	Pig 1 abdomen	*L. sericata* (Larvae) *Formicidae* (Adult)
	Day 7	67.2°C	Pig 2 head	*C. vicina* (Larvae) *L. sericata* (Larvae)
Active decay Distention had drastically decreased due to rupture of the abdomen (Figure 13). There was a strong odour emanating from the pigs. The ecology of the environment around the pigs was also starting to become variegated, with different lifecycle stages all present at the same time. Dipteran maggots were observed moving away from the pig carcasses to pupate. Dipteran pupal casings were observed in and around the cages and adult flies were still present in the environment. *D. maculatus* adults were observed within the environment of the decaying carcasses. A colony of Formicidae were also noted on and around the carcasses (Figure 14). The presence of larvae on the carcasses had largely increased and with the abdominal rupture, the larvae were also present not only on the natural orifices but on the abdominal region as well.	Day 10	100.9°C	Pig 2 head	*Formicidae* (Adult)
	Day 10	100.9°C	Pig 1 abdomen	*Ch. albiceps* (Larvae) *C. vicina* (Larvae)
	Day 10	100.9°C	Pig 1 ears	*C. vicina* (Larvae) *Ch. chloropyga* (Larvae) *Ch. albiceps* (Larvae)
	Day 14	142.0°C	Pig 2 abdomen	*C. vicina* (Larvae)
	Day 14	142.0°C	Pig 1 anus	*L. sericata* (Larvae)
	Day 14	142.0°C	Pig 1 Abdomen	*Formicidae (Adult)*

	Day 17	168.3°C	Pig 1 chest/abdomen area	*D. maculatus (Adult)*
	Day 17	168.3°C	Pig 1 anus	*Ch. albiceps (Larvae)* *D. maculatus (Adult)*
	Day 17	168.3°C	Pig 2 abdomen	*C. vicina (Larvae)* *Ch. albiceps (Larvae)* *Formicidae (Adult)*
Transitional stage between active decay and post The transitional stage between the late decay and post decay stages the ecology in the environment of the pigs was noted by the drastic decrease in the Dipteran species noted in the earlier stages. Empty pupal casings were noted around the cage. There was an increase in the number of *D. maculatus* adults and larvae. During this stage, no biopsies were taken as the subcutaneous tissue remaining had dried out. The skin had also hardened. Formicidae species were still present in the environment near the carcasses, as well as *D. maculatus* adults and larvae.	Day 21	205.2°C	Pig 1 abdomen	*Ch. albiceps (Larvae)* *D. maculatus (Larvae)*
	Day 21	205.2°C	Pig 2 abdomen	*Ch. albiceps (Larvae)* *D. maculatus (Larvae)* *D. maculatus* (Larvae)
	Day 21	205.2°C	Cage	*D. maculatus* (Larvae) *D. maculatus* (Adult)
	Day 21	205.2°C	Pig 1 Chest area/Abdomen	*D. maculatus* (Adult)

4.3 Macroscopic imaging and decomposition

Macroscopic imaging was carried out at the various decomposition stages.

Fresh stage (Day 0): The carcasses were placed at the study site in a fresh state, with no signs of discolouration or post-mortem changes. The neck on one of the carcasses had a pre-existing wound (Figure 12), which extended from below the right ear to below the mouth region.



Figure 12: Day 0. The first day the pigs were placed at the study site. Pig were in a fresh state showing no decompositional changes

Bloating stage (Days 4-10): The pigs' bodies were visibly bloated with their girth showing significant distention (Figure 13). There was discoloration on the abdomen, the area had turned to a darker shade of pink. Tissue damage during this stage was noted mainly in the natural orifices where maggot activity was more pronounced. Marks were noted on the skin of the pigs, these marks were undulations and were a darker pink to the colour of the pigs' skin. Later on, towards the transition between bloated stage and active decay small lesions were observed in the natural orifices. These lesions were not uniform in size nor were they uniform in shape and were more clustered in the areas where maggot masses were initially noted.



Figure 13: Day 4- Pig 2. Bloating (distension of the body) was already evident, displaying the second stage of decomposition. This distention is caused by bacterial activity due to putrefaction. Dipteran activity was evident on and around the carcass.



Figure 14: Day 4 – Maggot masses (arrow) clusters noted around natural orifices

Active decay stage (Day 11): The high levels of feeding decrease the ability to clearly identify the areas of bite marks or bite mark patterns. Maggot masses were largely seen on areas that were already including the ruptured region. Individual bite marks were difficult to visualise with the naked eye especially on open 'wounds' or areas that had already been ingested by larvae from the bloating stage. However, areas where insect larvae (both dipteran and coleopteran) were noted were biopsied. These were in the abdominal areas, leg areas and the face areas of both pigs.



Figure 15: Day 10- Pig 1. Rupture of the stomach contents was evident with maggot masses around the contents. Another maggot mass was observed in the ears.

Tissue damage continued in the natural orifices during the transition between the bloated stage and the active decay stage. The initial spaces that were occupied by the maggots in the natural orifices were now larger irregular shaped lesions. These were however difficult to observe due to the frothing that occurs with the presence of maggot masses. Due to the presence of different species and orders in this stage it was not noted which insect caused the tissue damage, however the insects around the damage were documented. These included Formicidae species in some areas, in other areas larvae of *D.maculatus* were noted and in other areas, Dipteran larvae/maggots were noted around the areas of tissue damage. Areas of undulations and marks on the pig skin also increased in frequency on the pig

skin. Areas that had open wounds, such as the neck area of one of the pigs (Figure 16) had a lot of insect activity around it, which increased the size of the wound dramatically. When compared to Figure 12 (Day 4) the wound had lengthened over time and this increase was noted on Day 7.



Figure 16: Day 7- A group of Formicidae were also observed in and around the ears and neck region of the carcass.

The pigs were turned over, photographed and areas that were closest to the bottom of the cage had visible lesions on them with maggots protruding from these areas on some occasions (Figure 17 and Figure 18). The larvae of *D. maculatus* were also observed protruding out of the lesions noted on the trunk. These pits and undulations were observed on the trunk of both pigs (Figure 17, Figure 18 and Figure 19) and were more rounded in shape but irregular in size and were not uniform in shape and size.



Figure 17: The inferior aspect of pig 1 (closest to the bottom of the cage) after turning the pig over. This view shows lesions (arrows) on the trunk of the pig created by insect (particularly maggot) activity. Maggots are seen protruding from the lesions in some areas (a).



Figure 18: The inferior aspect of pig 2 (closest to the bottom of the cage) after turning the pig over. This view shows lesions (arrows) on the trunk of the pig created by insect (particularly fly larvae) activity. Maggots can be seen protruding from the lesions in some areas (a).



Figure 19: Lesions on the trunk of the Pig 1 showing *D. maculatus* larvae protruding out of one of the lesions (arrow).

Lesions were also observed on the extremities, including the face (Figure 20) and legs (Figure 21), and not only on the trunk. Similar to the lesions observed on the trunk, the lesions on the extremities some were also irregular and some were circular in shape, the sizes were also irregular, and were not uniform in all instances. Some of the lesions were rounded, with others more oval in shape and those particularly on the head and face area, were more irregular shaped. There was also more insect activity on the sides of the carcass that were closest to the bottom of the cage compared to the sides that faced the surface of the cage (not touching the bottom).

When the pig carcasses were turned over, more maggots were noted on the bottom of the cage than on the superior aspect of the pig (Figure 22). Most of the skin damage (the lesions) were noted in areas where insect activity, particularly maggot activity, was highest. The wound area around the neck had maggots present, but also had a group of Formicidae. After the rupture of the stomach of one of pig 1, Formicidae adults could also be noted in that area (Figure 23). There were areas of discolouration on the surface of the skin where the ants were observed were also noted.

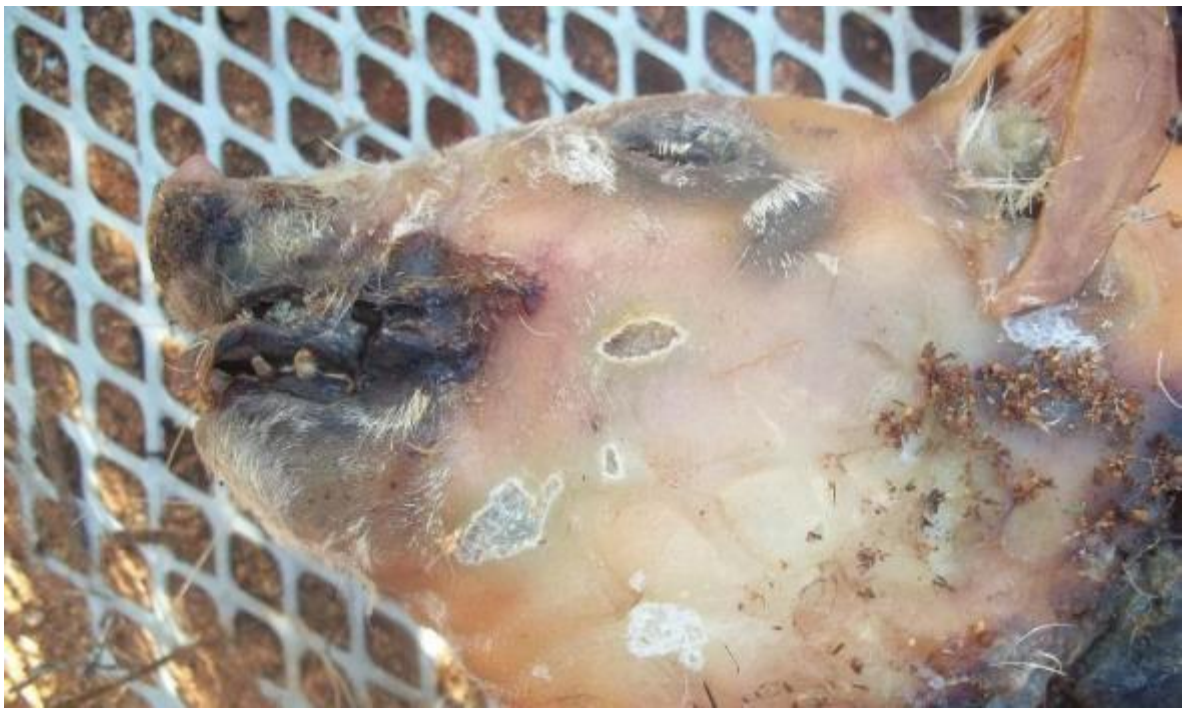

Figure 20: The inferior aspect of Pig 2 (pressed against the bottom of the cage) after turning the pig over. This view shows circular and irregular shaped lesions on the surface of the skin created by insect activity. Note areas of yellow discolouration.



Figure 21: The inferior aspect of Pig 1 (pressed against the bottom of the cage) after turning the pig over. This view shows circular and irregular shaped lesions on the extremities created by insect activity (particularly fly

larvae). Decompositional changes can also be observed (blood pooling to the side closest to the bottom of the cage)



Figure 22: Maggot masses noted underneath the pig once they were turned over.



Figure 23: Day 13- Pig 1. A group of Formicidae observed in the area where the stomach ruptured. Note areas of yellow discolouration on the surface of the skin.

Transitional stage between active and post decay (Day 23): During this stage, no biopsies were taken as the subcutaneous tissue remaining had hardened and could not be biopsied (Figure 24). The skin had hardened and most of what remained of the carcasses later in this stage were bones. Formicidae species were still present in the environment near the carcasses and *D. maculatus* adults and larvae.



Figure 24: Day 23 – Pig 2. The skin and most of the subcutaneous tissue had hardened.

4.4 Microscopic imaging

Microscopic imaging included two microscopic imaging techniques; namely light microscopy of epidermal pits, undulations and lesions and scanning electron microscopy of insect mouth parts.

4.4.1 Light microscopy

Only the areas of the skin where bite marks were noted were biopsied. No other areas of the skin were biopsied. On Day 0, the initial control biopsy was collected, and no further skin punch biopsies were collected until the larvae had begun feeding on the epidermal tissue. The initial biopsies taken (on Day 0) show no post-mortem skin changes. There was no separation of the epidermal layer from the dermal layer of the skin and the dermis showed no degradation (Figure 25 and 26).

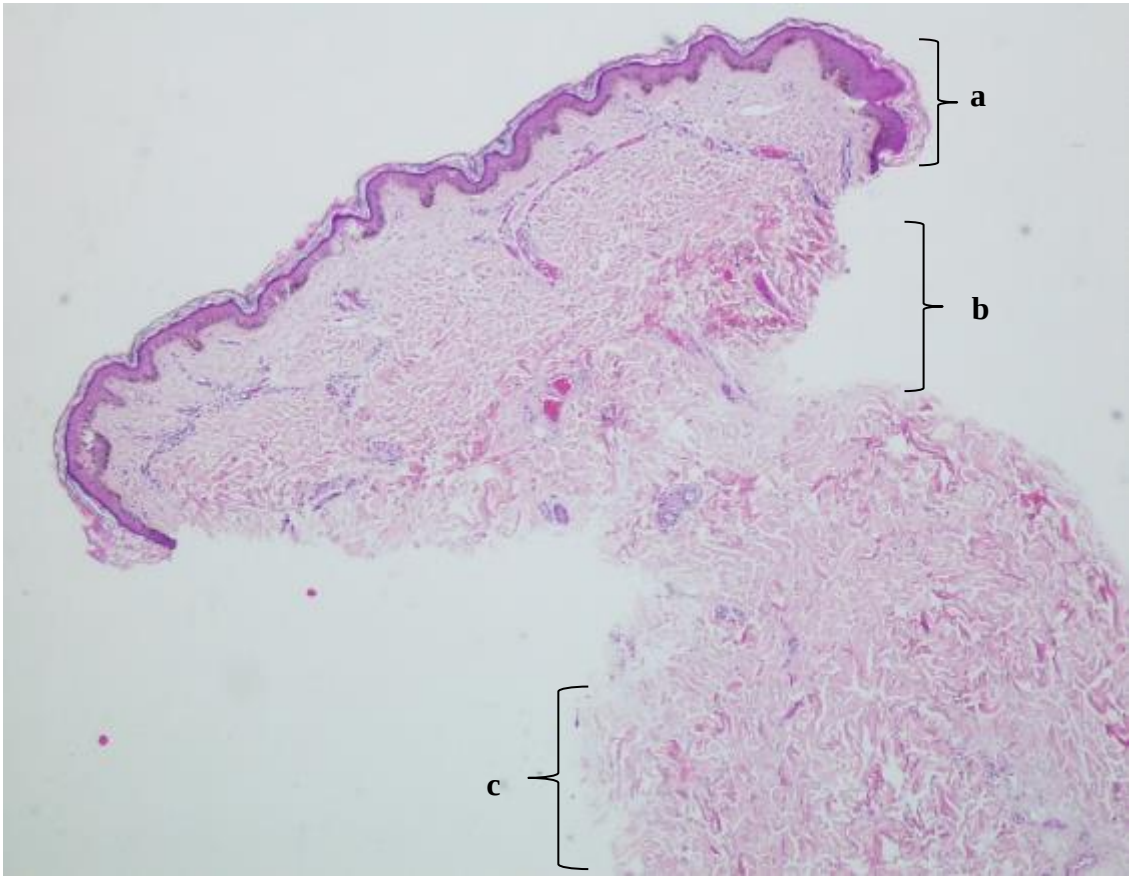

Figure 25: Light microscopy of the control biopsy (taken at day 0 during the Fresh Stage) showing H&E stained sections of a pig skin punch biopsy at low power (10X) magnification. There is representation of the (a) intact and undamaged epidermis (b) dermis, and (c) subcutaneous tissue.

Biopsies that were taken once decomposition had begun showed pathological/histological changes that were not observed on the biopsy taken on Day 0. These changes were noted in biopsies that were taken (as early as) on Day 4. Thinning of the epidermal layer with signs of separation were noted in a biopsy taken on Day 4 (Figure 27). Early signs of dermal degradation were also seen on this biopsy.

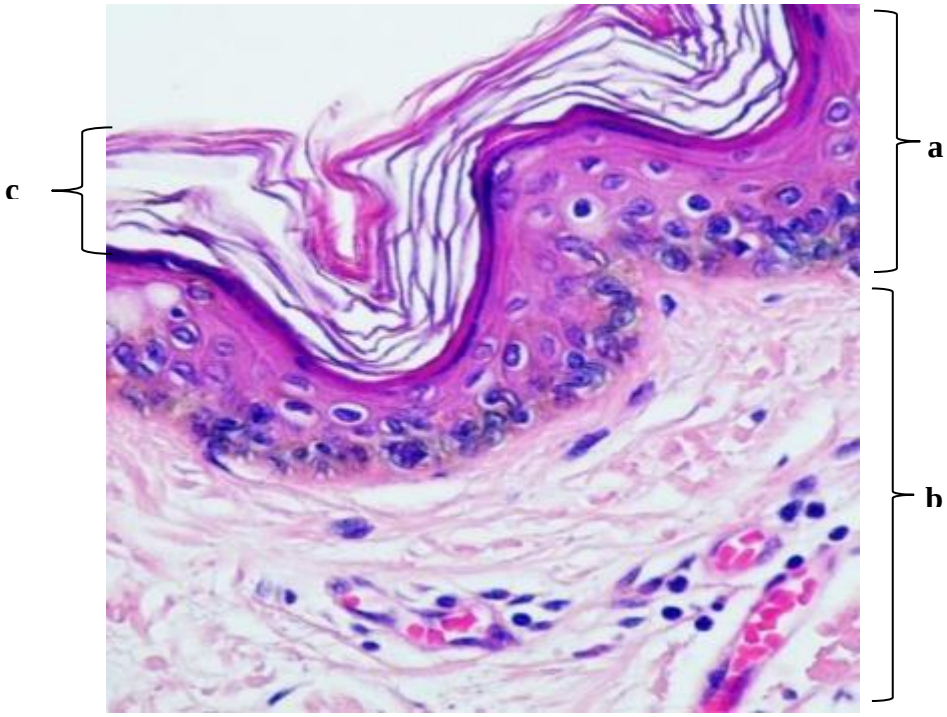

Figure 26: Day 0 (Fresh Stage)- High power magnification (40X) H&E stained sections of a pig skin punch biopsy of the control using the light microscope, displaying the (a) epidermis, (b) dermis and (c) keratin.

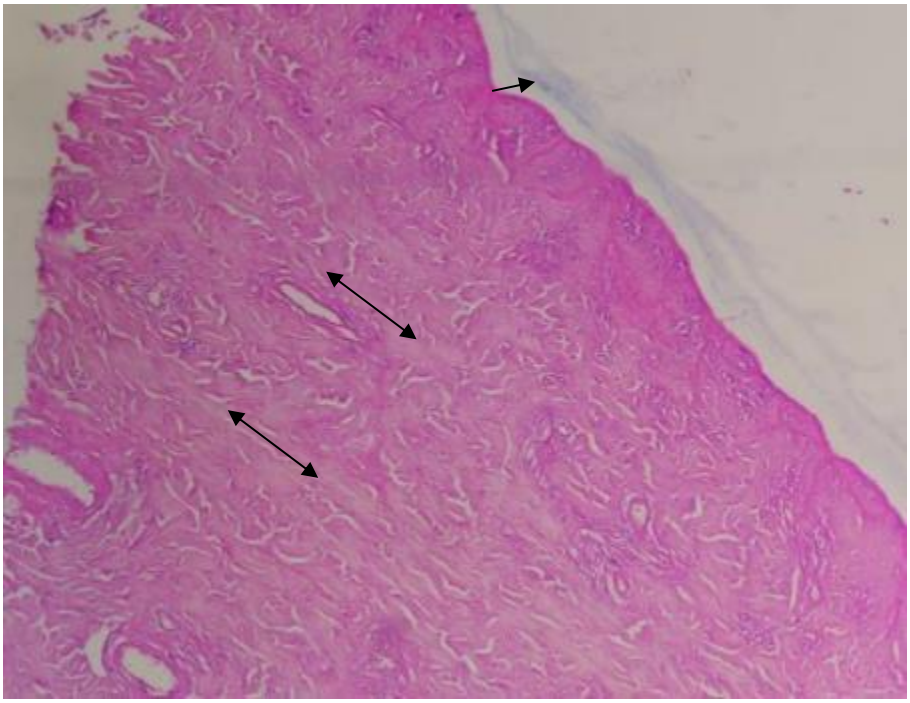

Figure 27: Low power magnification (20X) Aniline Blue stained sections of a pig skin punch biopsy as seen using the light microscope, displaying epidermal-dermal separation (single headed arrow) and the thinning of the epidermal layer and damage of the dermal layer (double headed arrows).

In biopsies that were taken in the active stages of decomposition the epidermal layer was no longer present showing epidermal-dermal separation. Once thinning had occurred in the earlier stages, the epidermal layer had completely separated from the dermal layer (Figure 28 and Figure 30). In the earlier stages of there was no notable damage beyond the layer of the skin, all structures below the surface of the skin (subcutaneous layer) remained intact (Figure 29). The areas of dermal degradation in these stages of decomposition (active) were more notable and spanned a larger area of the biopsy compared to those in the earlier stage of decomposition (bloated stage).

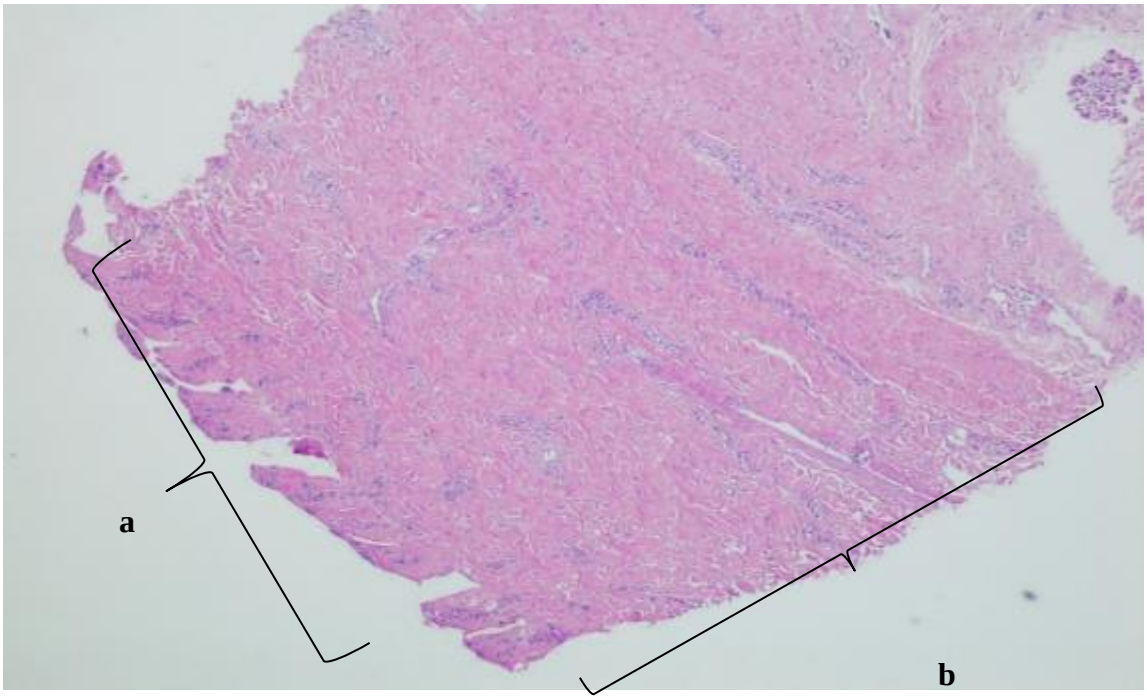

Figure 28: Sections of a pig skin punch biopsy stained with H&E as seen using the light microscope (10X). (a) There is separation of the epidermis from the dermis, which is evidence of skin damage caused by decomposition. In certain cases, the absence of the epidermis can be as a result of Formicidae activity. The epidermis is not represented in this section. (b) Dermis.

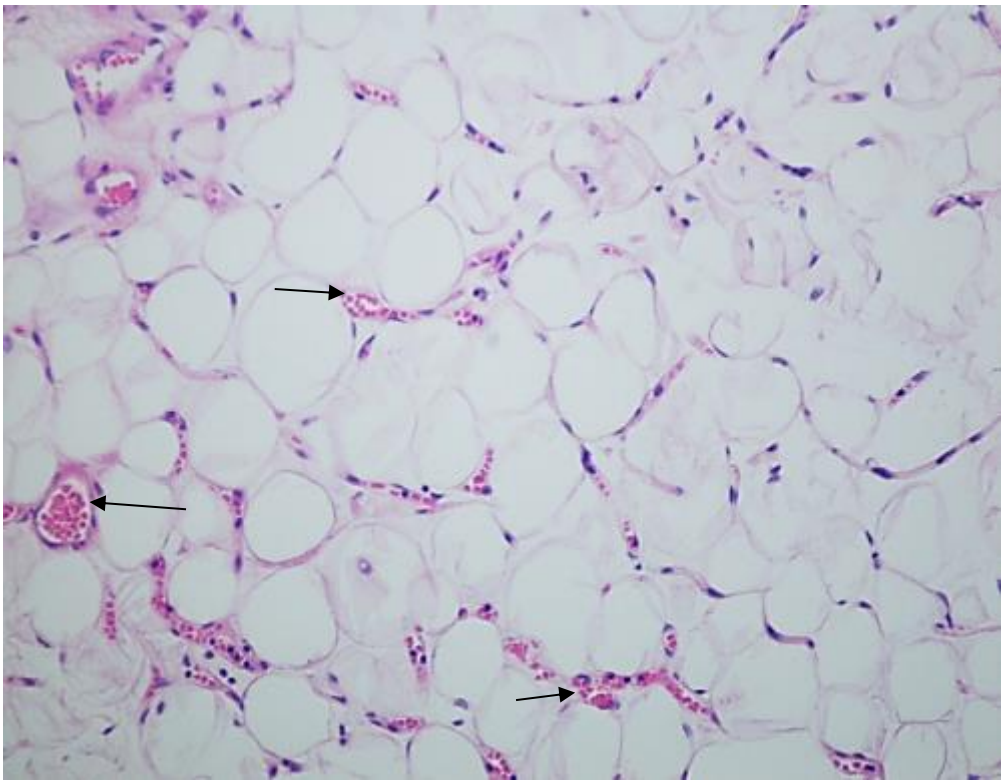

Figure 29: Sections of a pig skin punch biopsy stained with H&E seen using the light microscope at 40X magnification demonstrating the adipose tissue and small vessels (arrows) in the hypodermis/ subcutaneous.

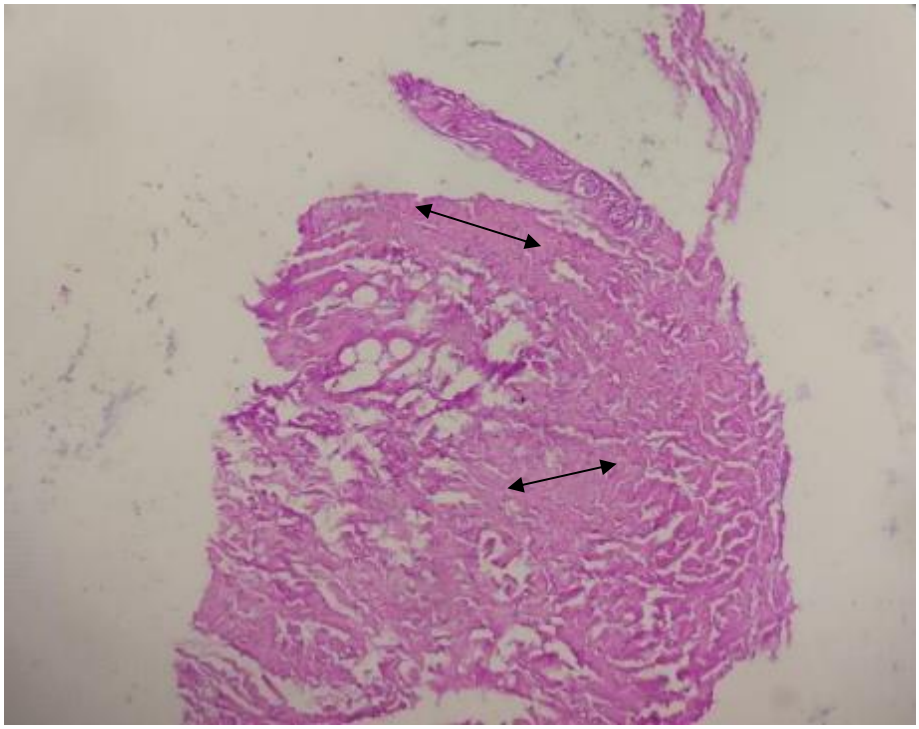

Figure 30: Aniline Blue stained section of a pig skin punch biopsy seen using the light microscope at 40X magnification demonstrating the dermal layer. No epidermal layer can be seen. The dermal layer shows areas of degradation (arrows) and areas of damage with spaces and fragmentation of components of the dermis noted.

4.5 Association between bite marks and insect feeding activity

Macroscopic patterns

Patterns of tissue damage that could be attributed to insect activity were noted macroscopically (Table 2). Lesions of different sizes and shapes were noted macroscopically, and these were attributed to all insect species collected and identified, as all insect species were identified in all the lesions noted. The sizes of lesions remained inconsistent and irregular depending on the insects noted.

Table 2: The macroscopic lesions noted on the pigs along with the associated insects as well as the patterns of tissue damage noted.

Lesion	**Insect(s) associated**	**Pattern description**
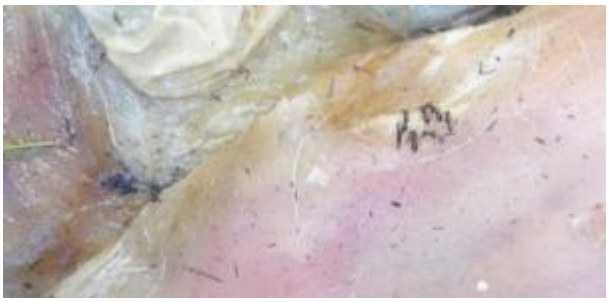	Formicidae (Ants)	Superficial skin loss which is also referred to as parchmenting (noted by discolouration from pink to yellow) Areas of skin loss
	Formicidae (Ants)	Extension of already existing wounds Parchmenting with skin discolouration

	Diptera larvae Coleopteran larvae	Circular skin lesions Circular lesions Tunnels in skin into the connective tissue
	Coleopteran larvae	Circular lesions Tunnels in skin into the connective tissue
	Formicidae (Ants) Diptera larvae	Superficial skin loss which is also referred to as parchmenting(noted by discolouration from pink to yellow) Areas of skin loss Lesions are irregular in shape Skin loss is superficial and does not burrow into the connective tissue

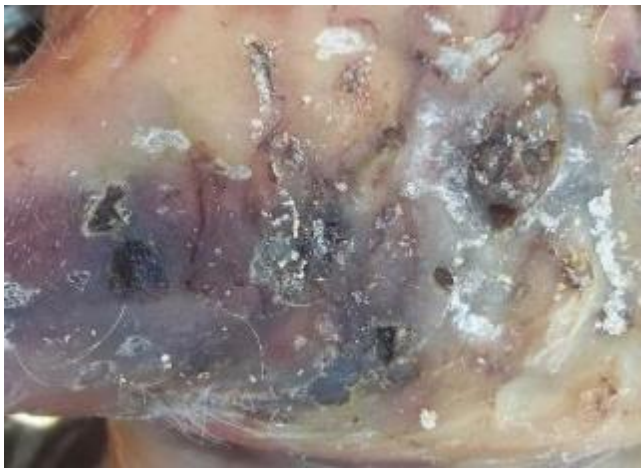	Formicidae (Ants) Diptera larvae	Superficial skin loss which is also referred to as parchmenting(noted by discolouration from pink to yellow) Areas of skin loss Circular and irregular shaped lesions Skin loss is superficial and does not burrow into the connective tissue
	Diptera larvae	Circular lesions
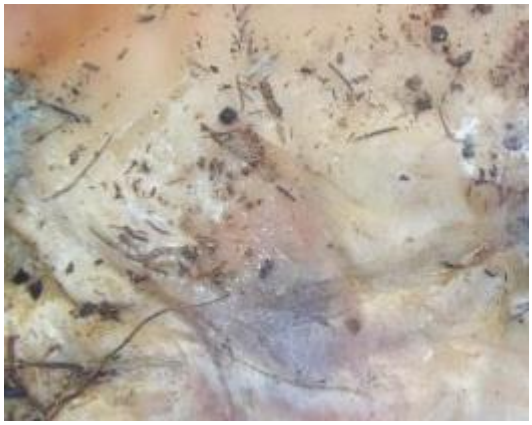	Formicidae (Ants)	Parchmenting with areas of discolouration from pink to yellow Areas of skin loss

Some areas were noted to show evidence of multiple insects even though some of those were not identified in those areas. This was true for the discolouration and parchmenting noted in multiple areas of the pigs' bodies, however, the ants were only noted in two areas.

4.6 Mouth parts

Scanning Electron Microscope (Mouthparts)

The SEM micrographs of the insects identified and collected during the study are presented below. There were two adult species collected, *D. maculatus* (Figure 31) and Formicidae (Figure 35) and the blowfly species were collected in the larval stages. *Dermestes maculatus* had a pair of mandibles on either side of the head that measured 386 µm. These are used as chewing/ grinding mouthparts. Grinding happens by the transverse movement of the pair of mandibles meeting in front of the mouth to create the grinding movement. They are also sclerized. The mandibles are cusped on the biting surface and these cusps are hardened to create the biting/grinding action when the mandibles come together. The gape (space between the two mandibles on either side of the head) measured 431 µm (Figure 30). The labrum was noted on the front of the mouth and its function is the containment of food while the mandibles are grinding.

The larvae of all the blowfly species identified had a pair of mouth hooks, one on either side of the head (Figure 31-34). These are used as mandibles for the grinding of food.

The mandibles on *C. vicina* measured 272 µm in length and the gape measured 326 µm (Figure 31). The mandibles on the *Ch. albiceps* measured 163 µm in length and the gape measured 250 µm (Figure 32). The mandibles on the *Ch. chloropyga* measured 220 µm in length and the gape measured 105 µm (Figure 33). The mandibles on the Formicidae measured 1120 µm in length and the gape measured 760 µm (Figure 34).

Formicidae, also had a pair of mandibles, one on either side of the head with Formicidae also having a pair of maxillae visible in the micrograph (Figure 35). The maxillae also form part of the mouth parts and are behind the mandibles. They are used to bring the ground up food to the mouth.

Only one individual per species of all the insects collected and identified was imaged using SEM.



Figure 31: An SEM micrograph showing the head of an adult *D. maculatus* beetle with the mouthparts. The gape (a) measured 431 µm and the mandibles (b) measured 386 µm in length.



Figure 32: An SEM micrograph showing the head of the larvae of a *C. vicina* fly with the mouthparts. The gape (a) measured 326 µm and the mandibles (b) measured 271 µm in length.



Figure 33: An SEM micrograph showing the head of the larvae of a *Ch. albiceps* fly with the mouthparts. The gape (a) measured 250 µm and the mandibles (b) measured 163 µm in length.



Figure 34: An SEM micrograph showing the head of the larvae of a *Ch. chloropyga* fly with the mouthparts. The gape (a) measured 105 µm and the mandibles (b) measured 220 µm in length.



Figure 35: An SEM micrograph showing the head of an adult Formicidae ant with the mouthparts and antennae. The gape (a) measured 760 µm and the mandibles (b) measured 1120 µm in length.



Figure 36: The cepahlopharyngeal skeleton of the larva of a) *C. vicina* and b) *Ch. albiceps* at 4X maginification showing the m-mouth hooks, si- intermediate sclerite and sb-basal sclerite

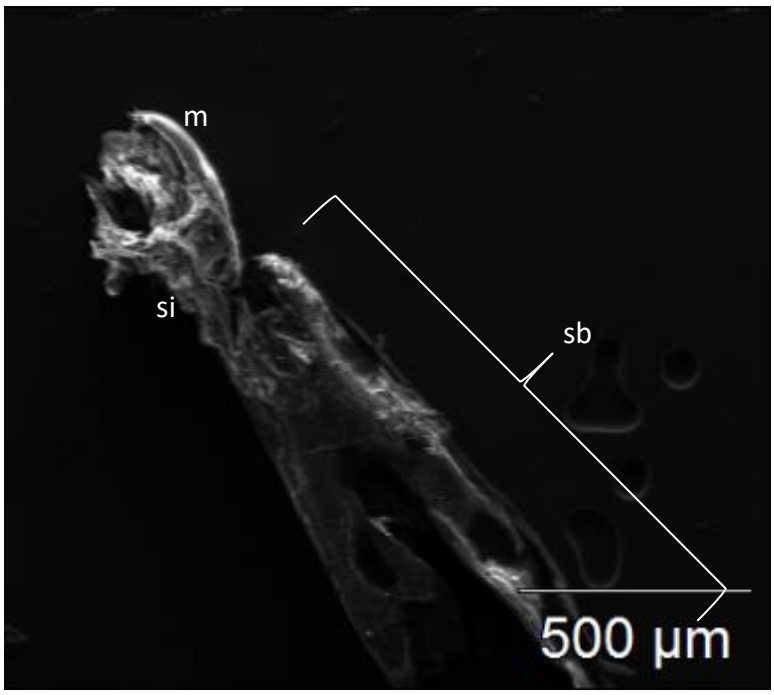

Figure 37: A micrograph of the cephalopharyngeal skeleton of the larva of *Ch. cloropyga* showing the m-mouth hooks, si-intermediate sclerite and sb-basal sclerite.

The cephalopharyngeal skeleton of the larvae of the calliphorids show a pair mouth hooks that are curved downwards followed by the intermediate sclerite at the proximal end of the mouth hooks. The intermediate sclerite connects to the basal sclerite (Figure 35 and Figure 36).

Chapter 5: Discussion

In the present study, skin damage on piglets (*Sus scrofa)* caused by insect activity was analysed. Skin damage was anlaysed both macroscopically and microscopically by light and scanning electron microscopy (SEM). All the forensically important insects on the pigs were collected and documented along with the environmental conditions at the study site. This is because environmental conditions are important in the availability and the development of forensically important insect species.

5.1 Environmental conditions

The maximum and minimum temperatures recorded in the area around the pig carcasses and the SAWS weather station differed significantly. Villet and Richards (2008) detailed the importance of choosing the most representative measure for all variables in the calculations of PMI by thermal summation particularly when it comes to summary statistics (maximum, minimum, medians, means etc.). However, maximums and minimums are outliers and are not the most representative measures for the PMI estimation. The most representative measure, being the mean, displayed no significant difference between the two sites in the present study. The temperature difference may be as a result of the area where the carcasses were placed, in direct sunlight during the day, for the duration of the study. In this study, the two pig carcasses were placed in an open area with no buildings or trees, consequently the iButton was in direct sunlight. This can explain the reason that the iButton maximum and minimum temperatures were significantly different when compared to the SAWS temperatures at the Johannesburg Botanical Gardens weather station. A study by Hofer *et al.* (2017). in London compared temperatures recorded on pig heads (as analogues for human carcasses) placed in different environments (sheltered and unsheltered). Two loggers were placed in the unsheltered environment, one covered in a Stevenson screen and one that was not (Hofer *et al*. 2017). A Stevenson screen is a meteorological screen/shelter used to enclose a data instrument and protect it from rain, heat radiation and other external factors that can affect readings however still allowing adequate ventilation (Harrison 2010). In the Hofer *et al*. (2017) study, the placement of the data logger in a Stevenson screen showed no particular precedence to that that was not placed in Stevenson screen; however, recommendation of its use is advised to ensure adherence to the World Meteorological Organization (WMO) recommendations with regards to measurement of meteorological variables.

The difference in temperatures may also have been due to the distance (approximately 20km) between the study area and the weather station. Differences in temperatures between the carcass microclimate and the weather service were not unique to the current study. Gillbert (2014) also noted differences in temperatures recorded between those recorded around the carcass and those at a weather station.

Temperature is an important factor when considering the presence, activity and development of insects (Charabidze and Hedouin 2019). However due to the fact that mean temperatures are used in the determination of PMI, and that the mean temperatures between the study site and the SAWS weather station showed no significant difference, the differences in minimum and maximum temperatures may be notable but may not significantly affect PMI estimation.

The maximum temperatures were particularly high (a temperature of 30°C on 27 2015 July was noted) for winter temperatures in Johannesburg. The high daytime temperatures could also explain why the pig carcasses went through all the decomposition stages within two months in winter. In a postgraduate study by Gilbert (2014), pig carcasses studied at the Melville Koppies in Johannesburg, which is approximately 20km from the current study site, went from the fresh stage to skeletonized within 59 days during the summer and one year during the winter. In the Gilbert (2014) study, the pigs in the winter trial were exposed to temperatures of between 5°C and 14°C for an extended period, thus decreasing the rate of decomposition. The size of the carcasses (in the present study) could also have a contributory factor in the rapid decomposition. A study by Simon, Adlam and Moffat (2010) found that when the carcass is exposed to insect activity, the rate of decomposition is faster in smaller carcasses than larger ones. However, when insects were not present; bodies were either submerged in water, indoors or buried; the rate of decomposition remained the same regardless of carcass size (Simmons, Adlam and Moffat 2010). This indicates that decomposition rate is size dependent when there is insect activity. The piglets in this study were eight weeks old and were small in size; this along with the relatively high temperatures (with a maximum of 30.8°C) and insect activity contributed to the fast decomposition rate, even though it was winter.

5.2 Forensically important insects

The distribution of different insect species is determined by seasonality. According to literature some species are more abundant during the hot spring and summer months, with a decrease in abundance during the cold autumn winter months (Williams 2003; Beck *et al*. 2018).

The present study was conducted in the winter months of 2015 (June to August) and four Dipteran fly species were noted; *L. sericata, C. vicina Ch. albiceps* and *Ch. chloropyga One colepteran species was noted; Dermestes maculatus* and one hymentopteran hymenopteran species of the family Formicidae.

The succession noted in the current study was similar to that noted in other studies. In the current study *L. sericata* was collected and identified in the bloated and active decay stages of decomposition. Similarly, in a Spanish study by Arnaldos *et al*. (2015), that sought to determine diptera succession in the early stage of decomposition, *L. sericata* was identified in the bloated, active and advanced stages of decomposition. A postgraduate study conducted in the Eastern Cape by Williams (2003) found that the *L. sericata* species peaked mostly in the summer months with minimal appearance in the winter months. It is worthy to note that although in the same country, average seasonal temperatures between Johannesburg and Grahamstown tend to differ not only due to differences in altitude between the two areas but also due to climate differences. Grahamstown is in a more arid climatic zone (Beck *et al.* 2018) with low rainfall patterns receiving below 25 cm of rainfall throughout the year. This compared to the temperate climatic zone of Johannesburg which receives moderate rainfall annually averaging around 800 mm (Kazemi and Mohorko 2017). Temperatures in the Karoo are usually extremely hot in the summer and severely cold in the winter (Mucinda *et al*. 2006). Although temperatures in the temperate climatic zone of Johannesburg drop in the winter, they may not drop as severely as they do in Grahamstown possibly resulting in the differences in *L. sericata* species noted between the two studies in the winter months.

In the current study, *Ch. albiceps* was collected and identified in all stages of decomposition. This was similar to a study by Keshavarzi *et al.* (2019) in Iran. In this Iranian study, insect species were collected off carrion that was placed in both indoor and outdoor habitats. *Ch. albiceps* was one of the first species to arrive on the carrion and it was collected in all stages of decomposition in the outdoor carrion. The succession of *Ch. albiceps* followed a similar pattern as the Iranian study. The presence

of *Ch. albiceps* in the winter months as seen in the current study agrees with what has been reported in the study by Williams (2003) in the Eastern Cape.

The distribution of *Ch. albiceps* is predicted to be in all parts of South Africa except for areas at relatively high altitudes (Richards, Price and Villet 2009) and this is because relative humidity is low at high altitudes. This is similar to the Williams (2003) study where it was noted that the distribution of blowflies is influenced more by moisture than by temperature and this is due to the fact that blowfly eggs dehydrate easily particularly when the amount of water vapour found in the air is low. A study by Richards, Price and Villet (2009) found that *Chrysomya albiceps* are commonly found at altitudes below 1800 m. The present study was conducted in Johannesburg which is at 1783m altitude. The Richards, Price and Villet. (2009) study also found that the distribution of *Ch. chloropyga* was throughout all nine provinces of South Africa, they are commonly found in temperate regions of the world. *Ch. chloropyga* were identified in the present study in an area that has been identified as a temperate region.

Adults of *D. maculatus* are usually noted in the early stages of decompositions; in some instances, as early as five to eleven days post-mortem (Shaver and Kaufman 2012). A similar trend of the early arrival of *D. maculatus* adults was noted in this study, with *D. maculatus* adults noted at day 14. *D. maculatus* larvae, however, are only noted in the late or post decay stages. This is only once all the tissues have dried up (Samish, Argaman and Perelman 1992; Shaver and Kaufman 2012). In this study *D. maculatus* larvae were noted in the advanced stage and the post decay stages of decomposition.

These results provide preliminary information on geographically important forensic species in the Highveld region which is similar to what another study found in the Highveld region (Gilbert 2014).

5.3 Macroscopic imaging

Taphonomic marks have been studied and described in empirical studies. These include studies on taphonomic marks or changes on human and animal carcasses caused by vertebrates, particularly carnivores (Zanetti, Visciarelli and Centeno 2014). These marks would include teeth marks (mammals) and pecking (avian) on different tissue on the remains. In the current study, during the

bloated stage, lesions and undulations were noted on the piglet skin particularly on the extremities, the trunk and the face. Over time, these lesions were observed on the piglet skin and these became larger in size and number. Lesions caused by insect activity were particularly noted in the active stage of decomposition. These lesions were of different shapes and sizes, were not uniform and some had irregular shapes. Lesions that were also noted in the wounded areas of the piglets were irregular and non-uniform. The feeding patterns of ants produce irregular, serpiginous scalloped areas of skin loss which is one of the reasons for ant post-mortem artefacts (Viero *et al.* 2018). The irregular shaped lesions seen in the current study could have also been caused by ant feeding activity.

Ants were only noted on the skin surface that was not touching the ground. This is typical to ant behaviour as is noted in a case review by Byard and Heath (2014). They noted that in all the cases reviewed in their study ants were only present on the skin surface that was not pressed against the ground or floor where the bodies were found. Skin damage in their study was only noted on the edges of the surface that was against the ground and on the surface that was not pressed against the floor. This is able to denote the position in which the body is found, as the ants have no access to the skin surface that is pressed against the ground (Byard and Heath 2014). The same was true for the present study for the ants as they were only photographed on the surface that was not against the ground. However, the opposite was true for the maggots.

Only maggot masses were noted on the surface of the skin that was closest/pressed against the cage and the lesions that were mostly noted on the surface had maggots protruding from them. These lesions became larger in size over the duration of the study however the rounded shape of these lesions remained consistent. The already existing wounds on the pigs (around the neck region on the ventral aspect) became larger in size (both in length and width) over the duration of the study and this was as a result of the biting action of the insects around the wounds. Insect activity around the pre-existing neck wound joined with the wound causing the wound edges to extend. Ants were also observed on the pig carcasses particularly on pre-existing wounds. Although the lesions seen on the pigs could not be definitively associated to the ants noted near the pre-existing wounds, the extension of the edges of the neck wounds could have been as a result of ant feeding activity because they were observed in this area. A study by Bonacci and Vercillo (2015) stated that lesions found in the presence of ants could be attributable to ant activity. This is because ants are known to cause post-mortem artefacts and lesions on the skin.

Zanetti, Visciarelli and Centeno (2014) noted taphonomic marks caused by *D.maculatus* in their study. In the Zanetti, Visciarelli and Centeno (2014) study *D.maculatus* caused irregular shaped lesions of different sizes on pig trotters. The lesions became larger in size with time and also increased in number. Similar lesions, some rounded, others more oval in shape and others with irregular shapes were noted in the current study. These were noted in different areas of the decomposing pigs (trunk, head and extremities). A case study by Schroeder *et al*. (2002) on a man found dead in his living room, showed similar marks as well as rounded and irregular shaped lesions caused by adult *D. maculatus*. In this study it was stated that these marks are "characteristic" of the feeding of beetles.

Literature only notes macroscopic taphonomic marks/lesions caused by coleopteran species (Schroeder *et al*. (2002), Zanetti, Visciarelli and Centeno (2014)), however in this study lesions were noted from both Coleopteran and Dipteran species. These macroscopic lesions noted were in keeping with the literature states; non-uniform in both size and shape and this was true for both *D. maculatus* and the Dipteran larvae.

5.4 Microscopic imaging

5.4.1 Light microscopy

Due to skin damage by decomposition the skin goes through many decomposition changes that can be seen microscopically. Damage to the skin starts with damage to the dermis layer, which can be visualised by Aniline blue stain as was done in an empirical study by Bonacci and Vercillo (2015). They describe a case study of a man whose body was discovered in the rural area of Italy. The body displayed irregular shaped lesions which they described macroscopically as well as microscopically. They biopsied the skin lesions and were able to histologically visualise areas of skin damage caused by Formicidae activity. The biopsies were stained with the Aniline blue stain and areas of damaged skin were noted by red colouration. The lesions in the current study were stained by Aniline Blue, however contrary to the Bonacci and Vercillo (2015), study areas of red discolouration were not noted in any biopsies. This could be due to the fact that this discolouration was attributed to chemical changes in the skin released by *Tapinoma nigerrimum* to facilitate its feeding in the Bonacci and Vercillo (2015) study.

Histological changes of the skin have been studied as a method to determine PMI. A study conducted in India by Bardale *et al*. (2012) noted post-mortem dermal degradation on day 2 of decomposition. However, a similar study conducted in Knoxville Tennessee noted dermal degradation between 6 – 9 hours post-mortem, with disintegration of the dermis after 18 hours. (Kovarik, Stewart and Cockerell 2005). Both environmental and temperature variations may contribute to the differences noted in the dermal degradation in these two studies. In the current study, biopsies were only taken after skin lesions caused by insect activity were noted. Areas of microscopic skin damage were also noted in the current study. These, however, could not be solely attributed to insect activity as decomposition can also result in changes in the skin. Epidermal-dermal separation is one of the initial microscopic decomposition skin changes noted (Kovarik, Stewart and Cockerell 2005).

Bonacci and Vercillo (2015) conducted histological analyses of skin lesions observed on human skin and established that it can assist with the determination of insect activity on lesions observed macroscopically. The same was observed with the current study. The lesions observed macroscopically in the current study, although not on human skin, were studied histologically and dermal degeneration was noted after a few days of decomposition (Day 4). The dermis began to separate from the epidermis. This epidermal-dermal separation can be attributed to either insect activity, particularly Formicidae, decomposition or both (Kovarik, Stewart and Cockerell 2005, Bonacci and Vercillo 2015). Although ant (Formicidae) activity can result in artefacts, the presence of lesions on the body can be an indication of Formicidae activity (Bonacci and Vercillo 2015) which was noted and documented in the current study. Skin lesions caused by ants are defined by the absence of the epidermis layer without any haemorrhaging of the subcutaneous layers. This is important in the differentiation of ant produced post-mortem artefacts and ante-mortem injuries, however, because dermal degradation can also be a result of decomposition, histological analyses remains important in the distinction.

Due to the hierarchical order in which insects arrive on a decomposing body the determination of ecological categories of these insects assists in the determination of PMI. Of the four ecological orders, members of the Formicidae family are usually categorised as omnivorous, which means they feed on the carrion as well as on the necrophages (Gennard 2007). In the Bonacci and Vercillo (2015) case study described above, Formicidae were identified on the body. Secreted chemicals were also

identified on the skin. Ants secrete chemicals for various social functions, which include pheromones for alarm signalling, and formic acid for the digestion of tissue prior to ingestion. These may be the cause of the skin damage observed histologically, as well as the macroscopic lesions observed. In the current study, members of the Formicidae family were observed on the skin and histological observation of skin damage was also noted, however, this damage was attributed to Formicidae activity by the presence of Formicidae in the lesions at the time of biopsy.

The feeding patterns of members of the Formicidae family, particularly on skin, are such that they result in the thinning and in some instances the absence of the epidermis. By histological analyses, lesions caused by ant feeding patterns are characterised by the absence of only the epidermal layer. This is dependent on the duration of feeding before discovery of the body, as the epidermis may not be completely absent but thinning and areas of damage of this layer may also be observed (Viero *et al.* 2018). This was evident in some of the lesions biopsied in the current study. In some biopsies, the epidermal layer was still present, although thinning and separating from the dermis.

5.4.2 Scanning Electron Microscopy (SEM)

The Calliphoridae larvae collected and preserved for SEM for the duration of the current study, had a pair of vertical fang-like mouth hooks that move in a pincer-like horizontal plane when used for feeding. This was true for all the calliphorid species identified in this study. These hooks are hardened and used to tear and cut through carrion during feeding (Byrd and Castner 2010). These pair of hooks could have been what resulted in the circular lesions noted in the current study. These lesions were associated with calliphorid larvae that were seen protruding from some lesions. The macroscopic patterns caused by these fang-like mouth hooks included circular and irregular shaped and sized lesions.

The two adult species collected, *D. maculatus* have a pair of mandibles which they also used to tear and chew with. These mandibles are evidence of chewing mouthparts which all Coleoptera have. The association of these mouthparts to the lesions noted in this study can be made to the *D. maculatus* larvae and adults. Both the adults and larvae burrowed beyond the level of the skin and were noted in lesions and holes that were deeper in nature to those of the Diptera larvae.

Formicidae also have a pair of mandibles which are also primitive mouthparts. They are used for tearing and chewing. It has been reported that ants are forensically important insects as they form part of the insect succession during decomposition. Ants are present in the early stages of decomposition and can be predatory on other insects found on the body or can feed on the body itself (Viero *et al.* 2018). Ants feed on the superficial layers of the skin and have a particular preference for the epidermis (Ventura, Gallo and De Stefano 2010). It is these pair of mandibles that enable ants to tear off the epidermis resulting in the epidermis-dermal separation noted in the microscopic findings in the current study as well as the removal skin seen on the surface of the skin seen macroscopically where ants were noted. Another finding that can be associated to the ant mouth parts was the skin loss on the surface of the skin that resulted in discolouration on the piglets from pink to yellow also referred to as parchmenting.

Sizing of the mouthparts allows determination of the force required for biting and chewing. This can in turn have implications on the chopping and grinding of hard food sources. This is true for Coleopteran species as they feed on the carcass in the late and post decay stages (Goyens *et al.* 2014). Dermestid beetles feed on the corpse in the final stages of decomposition, skin has usually hardened by then and the remaining subcutaneous tissue has also hardened in some instances. Sizing of mouthparts, then in Dermestid beetles can play in an important role to their ability to gain access to their food through the hardened skin that remains on the corpse. In the current study, an increase in the number of *D. maculatus* was observed in the later stages of decomposition compared to the few individuals noted in earlier stages of decomposition. The remaining skin and subcutaneous tissue had hardened in this stage. This shows the importance of measurements of mouthpart sizes particularly in the ability to access food sources in insect species. The omnivorous nature of Formicidae means that they feed on other insects found on the carcass, this requiring mandibular strength and increased bite forces for the decapitation and dismemberment of their prey (Schmidt 2014). *Dermestes maculatus* requires greater force for biting and chewing due to the stage of decomposition they are found in but also the larvae require a greater amount of force to be able to burrow deep into the skin and soft tissues to leave the deep tunnels and lesions observed not only in the current study but in other literature (Viero *et al.* 2018).

The cephalopharyngeal skeleton of the larvae in this study matched those of larvae in other studies (Martin-Vega, Diaz-Aranda and Baz 2014; Chapman 1998) containing the mouth hooks, the intermediate sclerite as well as the basal sclerite. This showing that the structure of the larvae mouthparts is primitive and have a grinding function, this resulting in the circular and sometimes irregular shaped lesions noted in this study. When the mouthparts were viewed on the head only the distal mouth hooks on the cephalopharyngeal skeleton could be observed. This is as described in Chapman (1998). He stated that only the distal ends of the mouth hooks on the cephalopharyngeal skeleton can be observed on the larvae and the proximal cephalopharyngeal skeleton is in the thorax of the larvae (Chapman 1998).

5.5 Matching bite marks and patterns to mouthparts

Macroscopic patterns

Patterns of tissue damage that could be attributed to insect activity were noted macroscopically. Lesions of various sizes and shapes were noted macroscopically and these were attributed to all insect species collected and identified. Calliphorid larvae were observed in some of the lesions noted and these have been reported to cause circular lesions on skin and soft tissue (Viero *et al*. 2018). A similar finding was observed in the current study. It was noted that circular and irregular shaped lesions were noted on the face, limbs and body of the piglets and these were attributed to dipteran larvae of all species collected as all species were identified in the lesions. These patterns were noted in the early stages of decomposition, suggesting that dipteran larvae feed on the fresher and softer tissue. These circular lesions result in artefacts that can be misinterpreted in crime scene investigations. Misinterpreted dipteran lesions are associated with a differential diagnosis of antemortem abrasions, cigarette and acid burns among many others (Viero *et al*. 2018). Dipteran larvae are usually found in the beginning and early stages of decomposition, therefore even though dipteran larvae were not noted on the patterns observed on the face and extremities, patterns described match those of dipteran larvae which were noted in the ears. The presence of dipteran larvae in the early stages of decomposition also suggests that they do not require more highly developed mouthparts like those of the adult beetles.

Patterns of tissue damage that were noted from *D. maculatus* larvae were burrowed holes that were also circular in shape, however, these were much deeper holes and they burrowed past the skin surface to the soft tissues below the skin. These patterns were noted in the later stages of decomposition when the tissue was harder (due to decompositional changes) requiring the mouthparts of beetles to be more developed. Viero *et al*. (2018) report a similar occurrence with beetles, particularly those of the Dermistidae, Cleridae and Heristidae families, to cause small holes, pits and tunnels into the connective tissue. These then result in artefacts that can be misinterpreted as imprints of blunt force trauma (Viero *et al*. 2018).

Parchmenting is a commonly noted artefact caused by Formicidae activity and because ants are usually found in the early stages of decomposition. It has been noted in literature that areas of soft tissue and skin damage cause by ants will discolour and become orange-pink to yellow in colour (Viero *et al*. 2018). The same areas of discolouration were noted in the current study, areas where ants were noted on the surface of the skin were discoloured from pink and had a more yellow appearance with areas of superficial skin loss (parchmenting). Emperical studies have also skin damage caused by ants to be superficial, localized particularly to the epidermis. The damage includes small holes that are very shallow and irregular in shape (Ventura, Gallo and De Stefano 2010). This can be as a result of their size. Ants are smaller in comparison to the abovementioned dipteran and coleopteran species. Their size also then means their mouthparts are smaller resulting in the small, subtle and superficial patterns noted. The discolouration along with the superficial areas of skin loss caused by ant feeding can be misinterpreted as burns, ante-mortem lesions as well as abrasions, all causing post-mortem artefacts (Viero *et al*. 2018).

All the larvae had a pair of mouth hooks on either side of the head and the *D. maculatus* adult had a pair of mandibles, one on either side of the head, all insects had primitive mouthparts which are mandibulate mouthparts (Labandeira 1997). This means they have mandibulate mouthparts, which are used for chewing or grinding before ingestion of the food. These are considered primitive and are made up five different structures namely; the labrum, the labium, the mandibles, maxillae and the hypopharynx. Regardless of this the patterns and characteristics of the observed lesions and skin damages could be linked to insects that caused them by reference to previous literature. The pair of mouth hooks on the ant's mouthparts are used for biting and chewing and cause small lesion mainly superficially on the surface of the skin.

The microscopic findings could not be attributed to insect activity only but could also be as a result of decomposition. The bite marks/lesions could not be linked to a particular species according to the measurements obtained by SEM. One of the reasons this could have occurred is as a result of the highly elastic nature of the skin. The interpretation of bite marks on skin can be distorted by various factors, one of them being the elasticity of skin (Sheasby and MacDonald 2001). Skin is not only highly elastic but the elasticity is also variable depending on the site of the body as well as the age of the individual (Sheasby and MacDonald 2001). The elasticity is also affected by the thickness of the skin as well as the presence or absence of supporting structures such as bones at the site of the bite. This is not only true for insect bite marks but also for human bite marks on skin (Sheasby and MacDonald 2001). Each bite mark will result in a unique mark even though the bites were from the same assailant. It is for this reason that bitemarks from the same insect can be variable not only in size but in shape as well due to the abovementioned factors. A similar phenomenon is noted with stab wounds. The victim would usually present with wounds that are smaller in size when compared to the size of the weapon and one of the reasons for this is skin elasticity (Hosoya, Harada and Kanetake 2020). This could have been the case in the current study, the variability in shape and size of the bite marks and lesions noted in this study could not be attributed or linked to a particular insect species due to the highly elastic nature of skin.

Macroscopic imaging can be an important source of information in linking bite marks or tissue damage to insect activity as was noted in the current study. Even without the presence of the insects linked to the bite marks, the patterns observed were able to allow linking of the lesions and/or skin damage to the insect that caused it.

Microscopic patterns

Areas of epidermal-dermal separation were noted in biopsies that were taken in the bloated stage of decomposition. It has been noted that ants arrive at the body in the directly after death or in the early stages of decomposition (Viero *et al.* 2018) and ants are associated with parchmenting which are areas of superficial skin loss. In addition to this being a decomposition ant activity could be attributable to this pattern of tissue damage noted microscopically. Areas of dermal thinning were also noted microscopically. This again may be a pattern attributable to ant feeding. This linking microscopically observed patterns of tissue damage to insect activity.

The results in this study show that patterns of tissue damage and their linkage to insects that cause the patterns is multifactorial and depends not only on the mouthparts but the site on the body where the patterns are identified, the stage of decomposition when those patterns are made as this determines the type of insects present on the body. The position the body is in as this determines the accessibility of the insects to the body, existing wounds and various other factors discussed. These are all important factors for forensic investigators to note in medico legal cases as it is a combination of these factors that will assist in determining the insects that may have caused the patterns noted.

5.6 Limitations and Recommendations

One of the many post-mortem decomposition changes noted on a body/carcass is the sloughing off skin. This sloughing process made biopsy and analysis of skin under the microscope challenging. A recommendation to overcome this would be to study patterns of tissue damage during the fresh stage before decomposition sloughing occurs. A laboratory study could also be conducted where pig trotters are used to study taphonomic marks on the skin as was done in the Zanetti, Visciarelli and Centeno (2014) study.

Although there were some limitations to this study in the evaluation of skin damage caused by insect activity, useful information was garnered, and some important deductions can be made from this information.

Differences in recorded temperatures between the carcass microclimate and the weather station were noted in this study and these differences could have an impact in thermal summation calculations, which could in turn affect PMI estimations. A way in which to prevent these differences is to have the study area closer to the weather station to ensure that the temperature differences are not as a result of distance.

Another limitation to this study was funding. The cost involved in running an SEM is quite high and access to the SEM at another institution was limited. This affected my use of the microscope and limited areas of the study including how many individuals per species I could measure and get electron micrographs of. A suggestion for the improvement of this would be the provision of funding

which will allow the student/principal investigator sufficient access to resources and in so doing improve the study in areas such as allowing for mouthpart measurements for multiple individuals per species, multiple electron micrographs to be acquired, as well as for seasonality studies to be conducted.

Chapter 6: Conclusion

The aim of this study was to perform a macroscopic and histological analysis on soft tissue exposed to insect activity for patterns of tissue damage, using piglet cadavers as a human model and this aim was achieved both macroscopically and partially microscopically. Patterns of bite marks/lesions were identified and described and these were attributable to insect activity noted on the pig carcasses (both Dipteran Coleopteran and Formicidae). These patterns were linked to insects that caused them, however, could not attributed to a particular insect species. Linkages between insects and skin damage in the current study were also possible through both macroscopic and histological analysis. In the current study, insects identified from the piglets were preserved, their mouthparts dissected out and using SEM techniques these mouthparts were then observed and described. The description and measurement of these mouthparts were able to assist in identifying the type of insects that left the bite marks on the skin which is an important finding that can assist in the identification of insects from the patterns noted even after the insects have migrated off or once the body has been moved.

The most common forensically important dipteran species in Gauteng (Gilbert 2014) were noted in this study. The species were noted in the winter warranting a summer observation to ascertain whether the same would be noted and any additional species that would be noted in summer and whether the same patterns of damage can be caused by different species that may or may not be identified in the summer season.

On macroscopic observation (gross) patterns and tissue damage was noted. Patterns that were described as caused by ants (family Formicidae) were small, barely noticeable lesions, these were noted to be superficial and only noted to not go beyond the surface of the skin. The noticeable feature of this pattern was the discolouration of the skin from pink to yellow also referred to as parchmenting. This was a particularly notable observation as similar observations were noted in previous studies. The patterns that were described to be caused by dipteran larvae macroscopically were circular in shape with some being of irregular shape. Skin loss was also not burrow into the connective tissue below the skin. The patterns that were described to be caused by coleopteran larvae and adults were circular in shape, not very irregular in comparison the lesions caused by dipteran larvae. The lesions were tunneled deeper, beyond the surface of the skin and into the connective tissue, and were not noted to be limited to the surface of the skin as was the case with the dipeteran larvae.

The findings made microscopically were congruous to those made macroscopically. Epidermal-dermal separation as well as the complete removal of the epidermal layer was noted before decomposition could occur, this demonstrated that this pattern was attributable to insect activity and not decompositional changes. The insect responsible for the removal of the superficial epidermal layer being Formicidae. Mouth parts described in the current study along with their functionality were also able to confirm the patterns caused by each insect order even though this was not able to segregate species within each order.

The current study has therefore found that a multi-factorial approach is necessary in the linkage of bite marks to insect orders and that the mouthparts are not the only factors associated with bite mark patterns. Knowledge of the behaviour, stage of decomposition, and many other factors all play an integral role in the patterns and the linkage of these to insect orders.

References

Aballay, F.H., Domínguez, M.C., Campón, F.F. (2012). Adult Fanniidae associated to pig carcasses during the winter season in a semiarid environment: Initial examination of their potential as complementary PMI indicators. *Forensic Science International* 219(1-3), p. 284.e1-284.e4.

Amendt, J., Campobasso, C.P., Gaudry, E., *et al.* (2007). Best practice in forensic entomology-standards and guidelines. *International Journal of Legal Medicine*. 120, p. 90-104.

Amendt, J., Krettek, R. and Zenher, R. (2004) Forensic Entomology. *Naturwissenschaften*. 91, p.51-65.

Amendt, J., Richards, C.S., Campobassso, C.P. *et al.* (2011). Forensic entomology: applications and limitations. *Forensic Science Medical Pathology*. 7, p.379-392.

Anderson, G.S. (2010). Chapter 5: Insect succession on carrion and its relationship to determining time of death. In: Byrd JH, Castner JL (eds) *Forensic entomology: the utility of arthropods in legal investigations*. CRC Press, Boca Raton.

Anderson G.S. (1997). The Use of Insects to Determine Time of Decapitation: A Case-Study from British Columbia. *Journal of Forensic Sciences*. 42 (5), p. 947-950, https://doi.org/10.1520/JFS14239J.

Anderson, G.S. (2010). Chapter 5: Factors that influence insect succession on carrion', in Byrd, J.H. and Castner, J.L.(eds), *Forensic entomology: the utility of arthropods in legal investigations*, 2nd edn, CRC Press, Boca Raton Florida.

Anderson Parker, M., Benecke, M., Byrd, J.H., *et al*. (2010). Chapter 18: Entomological alteration of bloodstain evidence', in Byrd, JH &Castner, JL (eds), *Forensic entomology: the utility of arthropods in legal investigations*, 2nd edn, CRC Press, Boca Raton Florida.

Arnaldos, M.I., Khedre, A., Presa, J.J., Clemente, M.E., *et al*. (2015). Diptera Succession during Early Decomposition Stages in a Mediterranean Pinewood Umbrage. *Austin Journal of Forensic Science and Criminology*. 2(4), p. 1-10

Bardale, R.V., Tumram, N., Dixit, P.G., *et al*. (2012). Evaluation of Histologic Changes of the skin in post-mortem period. *The American Journal of Forensic Medicine and Pathology*. 33(4), p. 357-361.

Beck, H.E., Zimmermann, N.E., McVicar, T.R., *et al*. (2018). Present and future Köppen-Geiger climate classification maps at 1-km resolution. *Scientific Data* 5(182014) doi:10.1038/sdata.2018.214.

Benecke, M. (1998). Six forensic entomology cases: description and commentary. *Journal of Forensic Science*. 43(4), p. 797-805.

Benecke, M. (2001). A brief history of forensic entomology. *Forensic Science International.* 120(1-2), p. 2-14

Beyer, J.C., Enos, W.F. and Stajić, M. (1980). Drug identification through analysis of maggots. *Journal of Forensic Sciences*. 25(2), p. 411-412.

Bhadra, P., Hart, A.J and Hall, M.J (2014). Factors affecting accessibility to blowflies of bodies disposed in suitcases. *Forensic Science International.* 239, p. 62-72

Bonacci, T. and Vercillo, V. 2015. Outdoor post-mortem bite injuries by *Tapinoma nigerrium* (Hymenoptera, Formicidae) on a human corpse: Case report. *Journal of Forensic and Legal Medicine*. 33, p. 5-8.

Bostock, E., Parks, G.M.B., Williams, G. (2019). The effect of insect activity on clothing damage evidence following a period of decomposition. *Crime, Security and Society*. p.37-41.

Byard, R.W., & Heath, K.J. (2014). Patterned postmortem ant abrasions outlining clothing and body position after death. *Journal of Forensic and Legal Medicine.* 26, p.10–13. doi:10.1016/j.jflm.2014.04.022

Byrd, J.H. and Castner, J.L. (2010). *Forensic entomology: the utility of arthropods in legal investigations*, 2nd edn, CRC Press, Boca Raton Florida.

Castner, J.L 2010, Chapter 1: General Entomology and Insect Biology, in Byrd, J.H. and Castner, J.L.(eds), *Forensic entomology: the utility of arthropods in legal investigations*, 2nd edn, CRC Press, Boca Raton Florida.

Campobasso, C.D. and Introna, F. (2001), 'The forensic entomologist in the context of the forensic pathologist's role', *Forensic Science International*. 120, p 132-139.

Campobasso, C.D., Marchetti, D., Introna, F. *et al*. (2009). Post-mortem artifacts made by ants and the effect of ant activity on decompositional rates. *American Journal of Forensic Medicine and Pathology*. 30(1), p. 84-87.

Chapman R.F. (1998). Chapter 2: Mouthparts and feeding. In: Chapman RF (eds) Insects: Structure and Function 4th edn. Cambridge University Press, Cambridge UK.

Chapman RF. 2009. Chapter 173: Mouthparts. In: Resh VH, Cadré (eds) Encyclopedia of Insects 2nd edn. Elsevier Oxford p. 663-668.

Charabidze, D. and Hedouin, V. (2019). Temperature: the weak point in forensic entomology. *International Journal of Legal Medicine.* 133(2), p. 633-639.

da Silva, E., Wilhelmi, B. and Villet, M.H. (2017). Forensic entomotoxicology revisited - towards professional standardization of study designs. *International Journal of Legal Medicine*. 131, p. 1399-1412.

Daniel, C.A., Midgley, J.M. and Villet, M.H. (2017). Identification of larvae of the Afrotropical species of *Thanatophilus* Leach, 1817 (Coleoptera, Silphidae). *African Invertebrates.* 58, p. 1-10.

De Jong, G.D. (1994). An annotated checklist of the *Calliphordae* (Diptera) of Colorado, with notes on carrion associations and forensic importance. *Journal of Kansas Entomological Society*. 67(4), p. 378-385.

de Souza, A. A. da F., de Rosa, C. T. A., Arantes, L. C., *et al.* (2020). Artifacts Caused by Leaf-Cutting Ants of the Genus Atta (Hymenoptera: Formicidae): Postmortem Bite Injuries and the Tearing of Clothes. *Journal of Forensic Sciences.* doi:10.1111/1556-4029.14279

Fusari, L., Dantas, G.P.S. and Pinho, L.C. (2018). Chapter 16: Order Diptera. In: Hamada, N., Thorp H. and Rogers D.C. (eds), Thorp and Covich's Freshwater Invertebrates 4th edn, Volume 3: Keys to Neotropical Hexapoda. Academic Press

Gennard, D.E. (2007). *Forensic entomology: an introduction*, John Wiley & Sons, West Sussex.

Gilbert, A.E. (2014). Forensic Entomology in the Gauteng Highveld. MSc thesis. University of the Witwatersrand, Johannesburg.

Godin, B. and Touiton, E. (2007), Transdermal skin delivery: Predictions for humans from *in vivo*, *ex vivo* and animal models. *Advanced Drug Delivery Reviews*. p. 1-10.

Goff, L. (2009). Early post-mortem changes and stages of decomposition in exposed cadavers. *Experimental and Applied Acarology.* 49, p. 21-36.

Goff, L. (2010). Chapter 1: Early post-mortem changes and stages of decomposition. In: Amedt J, Grassberger M, Campobasso CP, Goff ML (eds), Current concepts in Forensic Entomology. Springer Dordrecht, Heidelberg, London, New York.

Goldreich, Y. (1992). Urban climate studies in Johannesburg, a sub-tropical city located on a ridge – a review. *Atmospheric Environment. Part B. Urban Atmosphere.* 26(3), p. 407-420.

Goyens, J., Dirckx, J., Dierick, M., *et al*. (2014). Biomechanical determinants of bite force dimorphism in Cyclommatus metallifer stag beetles. *Journal of Experimental Biology* 217, p. 1065-1071.

Hall, M., Whitaker, A., and Richards, C. (2012). Chapter 8: Forensic Entomology. In: Marquez-Grant, N. and Roberts, J. (eds), Forensic Ecology Handbook: From Crime Scene to Court, 1st edn. John Wiley & Sons, Ltd.

Harrison, R.G. (2010). Natural ventilation effects on temperatures within Stevenson screens. *Quarterly Journal of the Royal Meteorological Society* 136, p. 253-259.

Hofer, I.M.J., Hart, A.J., Martin-Vega, D., *et al*. (2017). Optimising crime scene temperature collection for forensic entomology casework. *Forensic Science International* 270, p. 129-138.

Horenstein, B., Rosso, B., and Garcia, M. (2011). Seasonal structure and dynamics of sacrosaprophagousfauna on pig carrion in rural area of Cordoba (Argentina): Their importance in forensic science. *Forensic Science International* 217(1-3), p. 146-156.

Hosoya, T., Harada, K. and Kanetake, J. (2020) An autopsy case: Unusual characteristics of stab wounds inflicted by a survival knife. *Legal Medicine* 47, 101762. https://doi.org/10.1016/j.legalmed.2020.101762

Hyde, E.R., Haarmann, D.P., Lynne, A.M., *et al*. (2013). The Living Dead: Bacterial community structure of a cadaver at the onset and end of the bloat stage of decomposition. *PLOS ONE* 8(10): e77733. https://doi.org/10.1371/journal.pone.0077733 .

Introna, F., Campobasso, C.P. and Goff, M.L. (2001). Entomotoxicology. *Forensic Science International*. 120, p. 42-47.

Karolyi, F., Colville, J.F., Handschuh, S., Metscher, B.D. *et al* (2014). One proboscis, two tasks: Adaptations to blood-feeding and nectar-extracting in long-proboscid horse flies (Tabanidae, Philoliche). *Arthropod Structure & Development* 43 (5), p. 403-413.

Kazemi, F. and Mohorko, R. (2013). Review on the roles and effects of growing media on plant performance in green roofs in world climates. *Urban Forestry & Urban Greening*, 23, p.13-26

Kelly, J.A. (2006). The influence of clothing wrapping and physical trauma on carcass decomposition and arthropod succession in central South Africa. PhD Thesis. University of the Free State, Bloemfontein.

Kelly, J.A., van de Linde, T.C. and Anderson, G. (2009). The Influence of Clothing and Wrapping on Carcass Decomposition and Arthropod Succession During the Warmer Seasons in Central South Africa. *Journal of Forensic Science.* 54(5), p. 1105-1112.

Kemp, W.L (2016). Postmortem change and its effect on evaluation of fractures. *Academic Forensic Pathology* 6(1), p. 28-44.

Keshavarzi, D., Zaimy, M.A., Ahmed Yusuf, M., *et al.* Insect succession on carrion in Fars Province, southwestern Iran. *Egyptian Journal of Forensic Science.* 9(18) https://doi.org/10.1186/s41935-019-0124-8

Kim, K.C. (2010), 'Foreword', in Byrd, J.H. and Castner, J.L.(eds), Forensic entomology: the utility of arthropods in legal investigations, 2nd edn, CRC Press, Boca Raton Florida.

Knight, B. (1997). *Simpson's Forensic Medicine,* 11th edn. Oxford University Press, London.

Komar, D. and Beattie, O. (1998). Post-mortem insect activity may mimic perimortem sexual assault clothing patterns. *Journal of Forensic Science*. 43(4), p. 792-796.

Kovarik, C., Stewart, D. and Cockerell, C. (2005). Gross and histologic post-mortem changes of the skin. *The American Journal of Forensic Medicine and Pathology.* 26, p. 305-308.

Labandeira, C. (1997). Insect Mouthparts: Ascertaining the Paleobiology of Insect Feeding Strategies. *Annual Review of Ecology, Evolution and Systematics.* 28, p. 1853-193

Lopes de Carvalho, L.M and Linhares, A.X. (2001). Seasonality of insect succession and pig carcass decomposition in a natural forest area in southeastern Brazil. *Journal of Forensic Science*. 46(3), p. 604-608.

Lutz, L., Williams, K.A., Villet, M.H., *et al*. (2018). Species identification of African blowflies (Diptera: Calliphoridae) of forensic importance. *International Journal of Legal Medicine*. 132, p. 831–842.

Marchenko M.I. (1989). Method of retrospective determination of insect development onset in a cadaver. *Sudebno-meditsinskaia ekspertiza* 32(1), p. 17–20.

Marchenko, M.I. (2001). Medicolegal relevance of cadaver entomofauna for the determination of time of death', *Forensic Science International*. 120, p. 89-109.

Martin-Vega, D., Diaz-Aranda L.M., Baz, A. 2014. The immature stage of the necrophagous fly Liopiophila varipes and considerartions on the genus Liopiophila (Dipetera:Piophilidae). *Deutsche Entomologische Zeitschrift (neue Folge).* 61(1), p.37-42

Martin-Vega, D., Diaz-Aranda L.M., Baz, A., *et al*. 2017. Effect of Temperature on the Survival and Development of Three Forensically Relevant Dermestes Species (Coleoptera: Dermestidae). *Journal of Medical Entomology*. 54(5), p. 1140-1150.

Matuszewski, S., Hall, M.J.R., Moreau, G. *et al*. (2019). Pigs vs people: the use of pigs as analogues for humans in forensic entomology and taphonomy research. *International Journal of Legal Medicine.* https://doi.org/10.1007/s00414-019-02074-5

Merritt, R.W. and Wallace, J.R. (2010). The role of aquatic insects in forensic investigations In: Byrd JH, Castner JL (eds), Forensic entomology: the utility of arthropods in legal investigations, 2nd edn. CRC Press, Boca Raton. p. 177-222.

Mucinda, L., Rutherford, M.C., Palmer, A. *et al*. (2006) Nama Karoo Biome

Myburgh. J., L'Abbé, E.N., Steyn M., Becker P.J. (2013). Estimating the Post-mortem Interval (PMI) Using Accumulated Degree-Days (ADD) in a Temperate Region of South Africa. *Forensic Science International.* 229(1-3), p. 1-6.

Ortloff, A., Peña, P. and Riquelme, M. (2012). Preliminary study of the succession pattern of necrobiont insects, colonising species and larvae on pig carcasses in Temuco (Chile) for forensic applications. *Forensic Science International*. 222, p. 36-41.

Ortloff, A., Albornoz, S.,Romero, M. *et al.* (2016). Skin artefacts due to post-mortem damage caused by Notiothauma reedi: A insect of forensic importance in forest communities of Chile. *Egyptian Journal of Forensic Science*. 6(4), p. 411-415.

Prahlow, J.A. and McClain, J.L. (1997). Lesions that simulate gunshot wounds. *Journal of Clinical Forensic Medicine*. 4, p. 121-126

Reimer, L. 1985. Scanning Electron Microscopy. Physics of Image formation and Microanalysis. Berlin Springer Verlag.

Richards, C.S., Price, B.W. and Villet, M.H. (2009). Thermal ecophysiology of seven carrion-feeding blowflies in Southern Africa. *Entomologia Experimentalis et Applicata.* 131 p. 11-19

Richards, C.S. and Villet, M.H. (2008). Factors affecting accuracy and precision of thermal summation models of insect development used to estimate post-mortem intervals. *International Journal of Legal Medicine*. 122, p. 401-408

Ridgeway, J.A., Midgley, J.M., Collet, I.J. *et al*. (2014). Advantages of using development models of the carrion beetles *Thanatophilus micans* (Fabricius) and *T. mutilatus* (Castelneau) (Coleoptera: Silphidae) for estimating minimum post mortem intervals, verified with case data. *International Journal of Legal Medicine*. 128, p. 207-220.

Rivers, D. and Geiman, T. (2017). Insect Artefacts are More than Just altered Bloodstains. *Insects*. 8(2), p. 37 doi: 10.3390/insects8020037.

Salimi, M., Rassi, Y., Oshaghi, M., *et al*. (2018). Temperature requirements for the growth of immature stages of blowflies species, Chrysomya albiceps and Calliphora vicina, (Diptera:Calliphoridae) under laboratory conditions. *Egyptian Journal of Forensic Science*. 8(28) doi:10.1186/s41935-018-0060-z.

Samish, M., Argaman, Q. and Perelman D. (1992). Research Note: The Hide Beetle, *Dermestes maculatus* DeGeer (Dermestidae), Feeds on live Turkeys. *Poultry Science* 71, p. 388-390

Schmidt, C.A. (2014). Morphological and Functional Diversity of Ant Mandibles.Tree of Life Web Project http://tolweb.org/treehouses/?treehouse_id=2482 [Accessed 16 December 2019]

Schoenly, K.G., Haskell, N.H., Mills, D.K. (2006). Recreating Death's acre in the school yard: Using Pig Carcasses as Model Corpses, to teach concepts of Forensic Entomology and Ecological Succession. *The American Biology Teacher*, 68(7), p.402-410.

Schroeder. H., Klotzbach, H., Osterhelweg, L. *et al* (2002) Larder beetles (Coleoptera Dermestidae) as an accelerating factor for decomposition of a human corpse. *Forensic Science International.* 127(3), p.231-236.

Shaver, B. and Kaufman, P.E. (2012). Common name: hide beetle scientific name: Dermestes maculatus DeGeer (Insecta: Coleoptera: Dermestidae). *Featured Creatures. Entomology and Nematology* University of Florida.

Sheasby, D.R. and MacDonald, D.G. (2001). A forensic classification of distortion in human bite marks. *Forensic Science International.* 122(1), p. 75-78

Simmons T., Adlam R.E., Moffat C. (2010). Debugging Decomposition Data – Comparative Taphonomic Studies and the Influence of Insects and Carcass Size on Decomposition Rate. *Journal of Forensic Science*. 55(1), p. 8-13.

Smith, K.G.V. (1988). A Manual of Forensic Entomology. *Journal of New York Entomological Scoiety*. 96(4), p. 489-491.

Stejskal, V., Vendl, T., Li, Z., *et al*. (2019). Minimal Thermal Requirements for the development and the activity of stored product and food industry pests (Acari, Coleoptera, Lepidoptera, Pscoptera, Diptera and Blattodea): A review. *Insects.* 10(149) doi:10.3390/insects10050149

Trombetta, L., Olivia, A., Galache, A., *et al*. (2009). Cutaneous myiasis due to *Cochliomyiahominivorax* in a drug user. *Journal of Infection in Developing Countries*. 3(11), p. 873-876.

Ururahy-Rodrigues, A., Rafael, J.A., Wanderley, R.F., *et al*. (2008). *Coprophanaeus lancifer* (Linnaeus, 1767) (Coleoptera, Scarabaeidae) activity moves a man-size pig carcass: Relevant data for forensic taphonomy. *Forensic Science International.* 182, p. 19-22.

Vanin, S. (2018). Forensic Entomology: an overview. *Crime Security and Society.* 1(1) doi: https://doi.org/10.5920/css.2018.05

Vass, A.A. (2001). Beyond the grave – understanding human decomposition. *Microbiology Today*. 28, p. 190-192.

Ventura, F., Gallo, M. and De Stefano (2010). Postmortem skin damage due to ants. Description of 3 cases. *American Journal of Forensic Medicine and Pathology.* 31, p. 120-121.

Viero, A., Montisci, M., Pelletti, G. *et al.* (2018). Crime scene and body alterations caused by arthropods: implications in death investigation. *International Journal of Legal Medicine.* 133, p.307-319.

Villet, M. (2011). Forensic ecology of carrion in Africa. *Pest Technology*. 5(1), p. 1-15.

Villet, M.H. and Amendt, J. (2011). Advances in Entomological Methods for Death Time Estimation. In: Turk, E. (eds), Forensic Pathology Reviews. Forensic Pathology Reviews, 6. Humana Press, Hamburg Germany.

Villet, M.H., Richards, C.S., Midgley, J.M. (2010). Contemporary precision, bias and accuracy of minimum post-mortem intervals estimated using development of carrion-feeding insects. In: Amend, J., Campobasso, C.P., Goff, M.L., Grassberger, M. (eds), Current concepts in forensic entomology, Springer, Heidelberg.

Villet, M.H., and Richards, C.S. (2008). Factors affecting accuracy and precision of thermal summation models of insect development used to estimate post-mortem intervals. *International Journal of Legal Medicine*. 122(5), p. 401-408.

Virkler, K. and Lednev, I.K. (2009). Analysis of Body Fluids for Forensic Purposes: from laboratory testing to non-destructive rapid confirmatory identification at a crime scene. *Forensic Science International.* 188(1-3), p. 1-17.

Wells, L.R. and LaMotte, J.D. (2010). Chapter 9: Estimating the post-mortem interval. In Byrd, J.H. and Castner, J.L.(eds), Forensic entomology: the utility of arthropods in legal investigations, 2nd edn, CRC Press, Boca Raton Florida.

Williams K.A. (2003) Spatial and temporal occurrence of forensically important South African blowflies (Diptera: Calliphoridae). MSc Thesis. Rhodes University, Grahamstown.

Williams, K.A. and Villet, M.H. (2006). A history of Southern African research relevant to forensic entomology. *South African Journal of Science.* 102, p. 59-65.

Williams, K.A. and Villet, M.H. (2014). Effects of hydrocortisone and sodium methohexital on growth rate of *Chrysomya chloropyga* weidemann (Diptera: Calliphoridae): developmental and behavioural indications of presence of drugs. *Durban Natural Science Museum Novitates.* 37, p. 25-29

Wolff, M., Uribe, A., Ortiz, A. *et al.* (2001). A preliminary study of forensic entomology in Mendellìn, Colombia. *Forensic Science International*. 120, p. 53-59.

Zadora, G. and Brozek-Mucha, Z. (2003). SEM-EDX- a useful tool for forensic examinations. *Materials Chemistry and Physics*. 81(2), p. 345-348.

Zanetti, N.I., Visciarelli, E.C. and Centeno, N.D. (2014). Taphonomic marks on pig tissue due to cadaveric Coleoptera activity under controlled conditions. *Journal of Forensic Science.* 59(4), p. 997-1001.

APPENDIX A: Ethics Certificate

STRICTLY CONFIDENTIAL

ANIMAL ETHICS SCREENING COMMITTEE (AESC)

CLEARANCE CERTIFICATE NO. 2013/21/01

APPLICANT: Ms N Kgokong

SCHOOL: Pathology
DEPARTMENT: Forensic Medicine
LOCATION:

PROJECT TITLE: Patterns of tissue damage by insect activity using pigs (Sus scrofta) carcases as a human analogue

Number and Species

6 juvenile pigs

Approval was given for to the use of animals for the project described above at an AESC meeting held on 20130430. This approval remains valid until 20150429.

The use of these animals is subject to AESC guidelines for the use and care of animals, is limited to the procedures described in the application form and is subject to any additional conditions listed below:

1. **The animals must be sourced from a registered abattoir**
2. **The means of killing the animals is to be reported**
3. **The Committee wishes to know whether the animals are to be killed for the purposes of this study**
4. **Permission will be required from the Parks Authority**

Signed: _____ (Chairperson, AESC) Date: 6/5/13

I am satisfied that the persons listed in this application are competent to perform the procedures therein, in terms of Section 23 (1) (c) of the Veterinary and Para-Veterinary Professions Act (19 of 1982)

Signed: _____ (Registered Veterinarian) Date: 6/5/13

cc: Supervisor: Dr G Gordon
Director: CAS

Works 2000/lain0015/AESCCert.wps

APPENDIX B: Turnitin Report

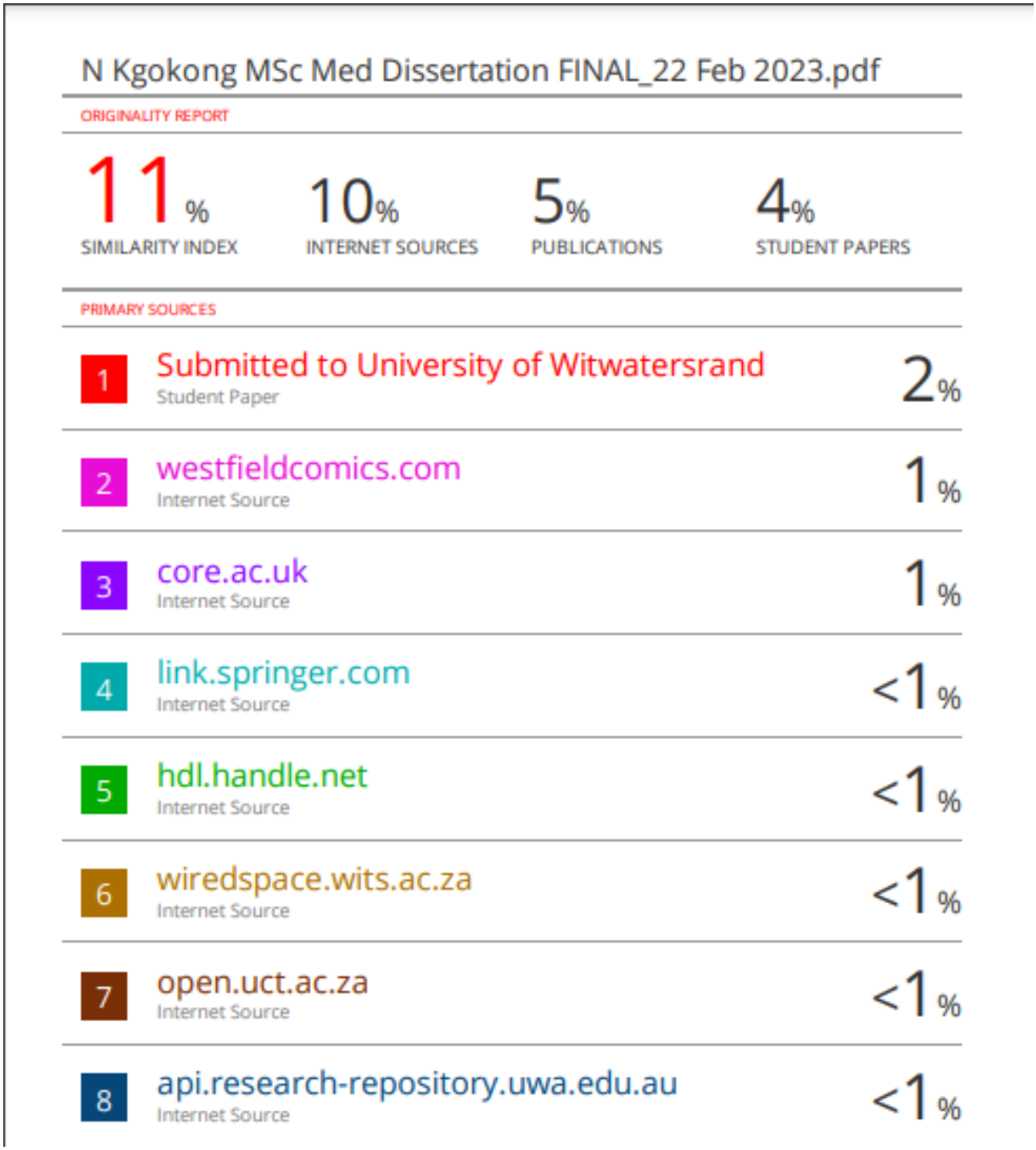

N Kgokong MSc Med Dissertation FINAL_22 Feb 2023.pdf

ORIGINALITY REPORT

11%	10%	5%	4%
SIMILARITY INDEX	INTERNET SOURCES	PUBLICATIONS	STUDENT PAPERS

PRIMARY SOURCES

1	Submitted to University of Witwatersrand Student Paper	2%
2	westfieldcomics.com Internet Source	1%
3	core.ac.uk Internet Source	1%
4	link.springer.com Internet Source	<1%
5	hdl.handle.net Internet Source	<1%
6	wiredspace.wits.ac.za Internet Source	<1%
7	open.uct.ac.za Internet Source	<1%
8	api.research-repository.uwa.edu.au Internet Source	<1%