

https://dspace.org/

# The prevalence of incidental physiological intracranial calcifications in the South African adult population as seen on computed tomography

**Koranteng, Promise Nonceba**

**2016**
http://hdl.handle.net/10539/23172

Downloaded from a DSpace repository. https://dspace.org/

# The prevalence of incidental physiological intracranial calcifications in the South African adult population as seen on computed tomography

Dr Promise Nonceba Koranteng

Department of Diagnostic Radiology

University of Witwatersrand

A research report submitted to the Faculty of Health Sciences, University of the Witwatersrand, Johannesburg, in partial fulfilment of the requirements for the degree of Master of Medicine in Diagnostic Radiology

Johannesburg, 2016

# Declaration

I, Promise Nonceba Koranteng, declare that this research report is my own work. It is being submitted for the degree of MMed (RadDiag) at the University of the Witwatersrand, Johannesburg. It has not been submitted before for any degree or examination at this or any other University.

Dr Promise Nonceba Koranteng

On this 22nd day of March 2016.

To Kwaku, my rock, for your never-ending support.

## Publications and presentations

This work has never been published.

# Abstract

**INTRODUCTION**:

Computed Tomography (CT) is an imaging modality extensively used in radiology departments. Intracranial calcifications are incidentally seen on brain CT scan in patients that are scanned for numerous reasons. These calcifications can be physiological or due to a pathological process. It is therefore essential for the reporting radiologist to be aware of the normal areas of physiological calcifications, to avoid incorrect diagnoses. There is minimal available data of the prevalence of physiological calcifications in the adult South African population to compare to the rest of the world.

**AIM**:

To determine the prevalence of physiological intracranial calcifications in the South African adult population as seen on non-contrasted computed tomography of the brain.

**METHOD**:

This was a retrospective study to evaluate 450 non-contrasted CT brain scans of male and female adult patients that met ascertained criteria for the presence of physiological and pathological calcifications.

**RESULTS**:

Overall, 98.2% of the patients had some form of physiological calcification with no significant association with gender. Choroid plexus calcifications were the most common (87.8%), followed by the pineal gland (76.0%). Habenular and dural calcifications were found in 48.9% and 44.0% respectively. Petroclinoid ligament calcifications were

identified in 15.6%, basal ganglia in 9.8% and arachnoid region calcification was found in 2,9%. The least common area of intracranial calcifications was the lens (0.7%). Pathological calcifications were found in 8.7% of patients.

**CONCLUSION:**

The vast majority of the patients had some form of physiological calcification with no significant gender specific predilection. Choroid plexus (the most common calcification) basal ganglia, vascular and dural calcifications showed an increased prevalence with age. Pathological calcifications were uncommon.

# Acknowledgements

I would like to acknowledge the following individuals:

- My amazing supervisor, Dr LT Hlabangana for her outstanding support in this project and helping me reach my potential. Her excellence and passion had a great impact.
- Dr Sakhele Mabuza and Dr Kathleen Jacobs for taking their time to assist in data reading.
- Dr Susan Lucas and Prof Savvas Andronikou for their input into making this project a success.
- Prof V Mngomezulu, Head of Department of Diagnostic Radiology for making research a priority in the department.
- Petra Gaylard Statistician, for the tremendous statistical analysis.
- Kwaku, for always understanding and supporting me.
- My mother for always encouraging me to do my best.
- My colleagues and friends for standing by me through it all.

## Table of Contents

**Declaration** ..... ii

**Publications and presentations** ..... iv

**Abstract** ..... v

**Acknowledgements** ..... vii

**List of Figures** ..... x

**List of Tables** ..... xii

**1. Introduction** ..... 1

**1.1. Rationale** ..... 4

**1.2. Normal physiological calcifications** ..... 5

**1.3. Pathological calcifications** ..... 15

**1.4. Epidemiology of intracranial calcifications worldwide** ..... 16

1.4.1. Epidermiology of intracranial calcifications in the developed world ..... 18

1.4.2. Epidermiology of intracranial calcifications in the developing world ..... 19

**1.5. Aims and objectives** ..... 20

1.5.1 Aim ..... 20

1.5.2 Objectives ..... 21

**2. Materials and Methods** ..... 21

**2.1. Research paradigm** ..... 21

**2.2. Sample** ..... 22

2.2.1. Sample size calculation ..... 22

**2.3. Method** ..... 23

**2.4. Inclusion criteria** ..... 25

**2.5. Exclusion criteria** ..... 25

**2.6. Data collection** ..... 26

**2.5. Statistical analysis** ..... **27**

**3. Results** ..... **28**

**3.1. Demographics** ..... **28**

**3.2. Physiological calcification** ..... **31**

3.2.1. Individual physiological calcifications ..... 33

**3.3. Pathological calcification** ..... **36**

**4. Discussion** ..... **37**

**4.1. Demographics** ..... **37**

**4.2. Physiological calcifications** ..... **41**

**4.3. Pathological calcifications** ..... **45**

4.4. Results in context ..... 47

**4.5. Current applications /recommendations** ..... **49**

**4.6. Limitations of the current study** ..... **50**

**4.7. Future applications or future recommendations for research** ..... **50**

**5. Conclusion** ..... **51**

**Appendix A: Ethics Clearance Certificate** ..... **53**

**Appendix B: Readers tick sheet for patient data** ..... **54**

**6. References** ..... **55**

## List of Figures

Figure 1A: A non-contrast CT brain scan of a 38 year old male patient who sustained a head injury in a motor vehicle accident demonstrating incidental bilateral choroid plexus calcifications in the lateral ventricles ..... 6

Figure 1B (i and ii): Axial and sagittal plane, non-contrasted CT brain scan of a middle aged male patient demonstrating incidental pineal gland calcifications (arrow). Image (i) demonstrates the dense, central and round nature of the pineal gland calcifications. ..... 7

Figure 1C: An axial image of a male patient demonstrating bilateral habenular calcifications (arrow). ..... 8

Figure 1D: Axial image of an elderly patient with bilateral, symetrical and coarse basal ganglia calcifications demonstrated by the arrows. ..... 9

Figure 1E (i and ii): Axial (i) and sagittal (ii) images of a non-contrast CT brain scan of the 40 year old male patient with dense calcifications of the falx. There is a right parietal subgaleal haematoma noted from sustained head injury (i). ..... 10

Figure 1F (i and ii): A non-contrast CT scan (brain and bone window) of a 99-year-old female patient who sustained a head injury from a minor fall demonstrating bilateral mural calcifications of the Internal Carotid arteries. ..... 12

Figure 1G (i and ii): Para-sagittal images(i bone window, ii brain window) of the previous patient at the level of the petroclinoid ligaments with bilaterally calcified posterior clinoid ligaments. ..... 13

Figure 1H: An image of a CT brain scan, bony window, of a 75-year-old male patient through the orbits demonstrating unilateral lens calcifications on the left. ..... 14

Figure 3.1: Histogram demonstrating the proportion of male and female patient with regard to the different age categories. ..... 31

Figure 3.2: The proportion of patients with incidental physiological calcifications by age group category ..... 32

Figure 3.3: Histogram of the proportion of patients with presence of incidental calcifications. ..... 33

Figure 3.4: Association of the common physiological calcifications with the different age groups. ..... 35

# List of Tables

Table 1.1. Classification and examples of diseases that may have pathological calcifications ..... 15

Table 2.1: Comparison between four reviewed studies demonstrating their different evaluated parameters and findings ..... 17

Table 3.1: The frequency and percentage of the study population according to age group ..... 29

Table 3.2: Proportion of the study population age group by gender. ..... 30

Table 3.3: The proportion of unilateral and bilateral calcifications in choroid plexus, petroclinoid ligaments and basal ganglia. ..... 36

Table 4.1: Comparison of reviewed previous literature with the current study ..... 48

# 1. Introduction

Calcifications in any organ system are as a result of calcium accumulation and deposition, which can be associated with multiple disease entities (1). These calcifications can be demonstrated by different radiological modalities including conventional plain film radiography and cross sectional imaging (2). They are often encountered incidentally in patients undergoing imaging for different pathological indications.

In the advent of cross sectional imaging, computed tomography (CT), is currently widely used as a tool for many clinical applications (3). Computed tomography has been one of the advancing cross-sectional modalities (3) and has demonstrated high sensitivity in detection of calcifications (1). It has allowed easier identification of calcifications. The accuracy of detecting calcifications on CT is much better than that of classical radiological methods as very small calcifications that might not be visible on plain film can be demonstrated on CT (2). CT has significantly improved the accuracy of localizing calcifications due to its multi-planar reconstruction (MPR) and 3-Dimensional (3-D) reconstruction capabilities (2, 3).

A CT image is made up of numerous pixels and each pixel contains numeric information related to the composition and nature of the tissue. This value ends up in the final clinical CT image after the image has been reconstructed and is called a CT number or Hounsfield unit (HU). The HU ranges from -1000, which corresponds with air, 0 with water, to +1000, which corresponds with dense bone. Calcifications and contrast agents range up to +3000. This is the feature of CT that allows accurate definition of calcifications (3). A major disadvantage in

CT is artefact that can cause inaccurate diagnosis and the inability to detect pathology. Possible artefacts that can compromise image quality in CT scans are streak artefact, partial voluming and motion artefact. Partial voluming occurs when a voxel (volume element) contains different tissue types. It is not representative of either tissue but instead is a weighted average of the two different values(3).

Intracranial calcifications can be physiological or pathological. Physiological calcifications are those that are unaccompanied by any evidence of disease with no demonstrable cause. Calcifications are often caused by deposition of calcium in blood vessels of different organs, in this case, blood vessels of different brain structures(1).
The most common sites of physiological intracranial calcifications include the habenular, pineal gland, basal ganglia, choroid plexus, falx, tentorium, petroclinoid ligaments and sagittal sinus(4). Other areas that can calcify are the lens and pituitary gland(5).

Another way to classify intracranial calcifications according to location is to describe whether they are intra or extra-axial. Intra-axial brain calcifications can further be classified according to aetiology, namely neoplastic, vascular, infectious, congenital, endocrine or metabolic. This classification includes both pathological and physiological calcifications(2).

The most common acquired infections that are typically associated with intracranial calcifications are neurocysticercosis, tuberculosis, and cryptococcus(6, 7). Cysticercosis is a common parasitic infection worldwide and is endemic in South Africa. Neurocysticercosis

exists in both active and inactive (calcified) forms in the brain (7).

In the South African setting, there is a high HIV prevalence, which has increased the prevalence of opportunistic infections including tuberculosis and cryptococcus (8). The concomitant HIV and tuberculosis epidemics are one of the greatest health care challenges in the South African population. In 2007, South Africa had 17% of the global HIV prevalence. There has been an escalation in drug resistance with regard to both HIV and tuberculosis, which further compounds the problem. Opportunistic infections and increasing resistance to conventional treatment may alter the incidence of the different manifestations including intracranial disease. Hence, intracranial calcifications can result from previous infection(2). In addition, there may be coexistence of physiological and pathological calcifications. This demonstrates significance of differentiating between the two types of intracranial calcifications. It is therefore essential for radiologists to have knowledge of physiological calcifications to avoid misinterpretation (9, 10).

The introduction of Picture Archiving and Communication Systems (PACS) has greatly advanced radiology departments throughout the world. PACS is a system for storage and transfer of radiologic images that has been developed to allow rapid retrieval of images. It allows access to images acquired from different modalities and simultaneous access at different sites. Primary constituents of PACS are image acquisition device, data management systems (to control flow of information), storage device and display stations for example, computer monitors (3, 11). These systems provide easy accessibility to images, which in this project was used to acquire patient data.

## 1.1. Rationale

Radiology Departments in South Africa perform large numbers of brain computed tomography scans including a sizeable proportion from the Trauma/Emergency department. Differentiating pathological from physiological incidentally detected intracranial calcifications in the South African setting is complicated by the prevalence of pathological intracranial calcifications from tuberculosis and neurocysticercal granulomas, as these diseases are endemic in the population. These calcifications vary in their location and frequency according to age, and this affects whether they are considered physiological or pathological by the reporting radiologist. The South African population may differ in the frequency and age of onset of physiological calcification compared to western populations. In addition, high prevalence diseases in South Africa that may cause bilateral basal ganglia calcification at an early age, such as HIV may confound the ability of radiologists to distinguish physiological from pathological. It is thus essential for the reporting radiologist to have knowledge of physiological calcifications in the brain to avoid misinterpretation. The recognition of distribution and appearance of intracranial calcification may assist in narrowing down the differential diagnosis and prevent misdiagnosis. There has not been much literature evaluating the prevalence of these calcifications in the South African population compared to the rest of the world.

## 1.2. Normal physiological calcifications

**Choroid plexus**

The choroid plexus is made up of secretory epithelium located within all four ventricles of the brain. The tela choroidea, which is a double layer of pia matter, contacts the ependymal lining of the ventricles and forms the choroid plexus. It is found in the temporal horns and body of the lateral ventricles, roof of the third ventricle and fourth ventricles. The main function is production of cerebrospinal fluid which creates the blood-cerebrospinal fluid barrier (5). This is one of the most common sites of incidental areas of physiological calcifications (see Figure 1A). Alves G et al, conducted a retrospective study in a Brazilian subtropical city on pineal and choroid plexus calcifications on CT and concluded that both these areas are likely to have calcifications in 50% of brain CT scans (12). Daghighi et al found choroid plexus calcifications in 66.7% of their study population, making it the second most common area of physiological calcifications (1).

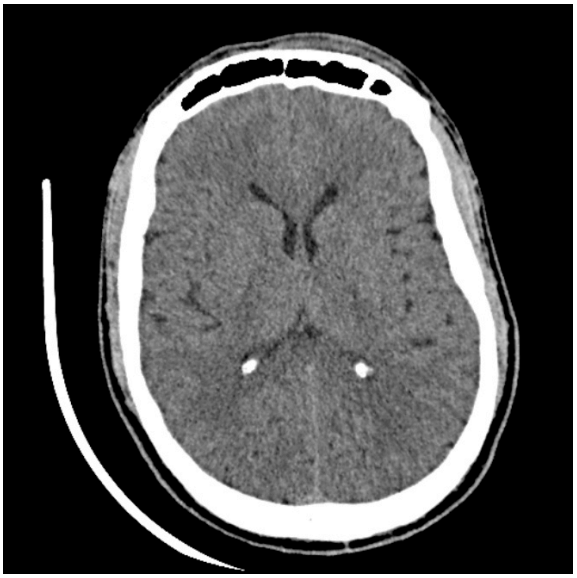

**Figure 1A: A non-contrast CT brain scan of a 38 year old male patient who sustained a head injury in a motor vehicle accident demonstrating incidental bilateral choroid plexus calcifications in the lateral ventricles**

**Pineal gland**

The pineal gland is an unpaired, midline endocrine gland that is attached to the postreior wall of the third ventricle by a pineal stalk. It is connected to the habenular superiorly by the superior lamina of the stalk and to the posterior commisure by the inferior lamina.

It is a small endocrine gland that produces the hormone melatonin, a derivative of serotonin. The main function of the hormone is modulation of the sleep/wake pattern. It is also an important endocrine gland in regulating mammalian reproductive function, such as the onset of puberty (5) . Calcifications in the gland are known to be common and are said to increase with age. These are mostly seen on CT however, there have been reports of calcifications being visualised on conventional plain films (12). The most common patterns of calcifications

are globular or concentric. These are generally less than 10mm in size. Larger calcifications are suspicious for underlying pathology, especially in children. Patterns that should raise suspicion of underlying pathology are peripheral and “exploded” calcifications (5). Neoplasms are the most common cause of pineal calcifications other than normal calcifications. Figure 1B demonstrates dense, globular pineal gland calcification.

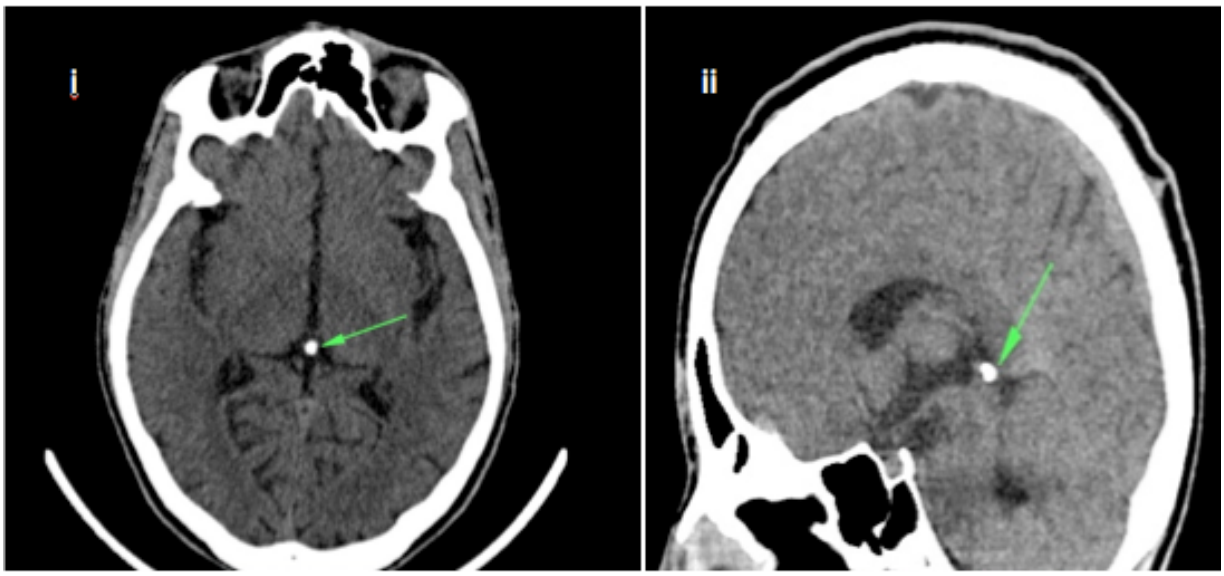


**Figure 1B (i and ii): Axial and sagittal plane, non-contrasted CT brain scan of a middle aged male patient demonstrating incidental pineal gland calcifications (arrow). Image (i) demonstrates the dense, central and round nature of the pineal gland calcifications.**

**Habenular commisure**

These are a band of nerve fibers positioned anterior to the pineal gland and connects the habenular nuclei on both sides of the diencephalon (5). These fibres have a central role in regulation of the limbic system. Habenula calcifications are often curvilinear and seen in 15% of the adult population (4). Figure 1C is an axial CT brain image demonstrating bilateral habenular calcifications. Sedghizadeh et al, (2012), concluded that the majority of calcifications appeared in the pineal/habenula region (80%). Pineal and habenular calcifications were reported as a combination in their study due to inability to definitively distinguish their location on cone beam CT (CBCT). Discrimination between the two is cumbersome due to their close anatomical proximity. There is lack of brain tissue detail on CBCT as compared to conventional CT (13). Daghighi et al found that 20.1% of their study population had habenular calcifications and 18.7% of that population had co-existent pineal and habenular calcifications (1).



**Figure 1C: An axial image of a male patient demonstrating bilateral habenular calcifications (arrow).**

**Basal ganglia**

The basal ganglia is made up of a group of deep subcortical nuclei, namely the striatum (caudate nucleus and putamen) and globus pallidus. These nuclei are primarily involved in motor control, with other associated roles including motor learning, emotions, executive functions and behaviour (5). According to Adams A,E, globus pallididus calcifications is almost always the site of calcifications in the basal ganglia and calcifications are usually bilateral and symetrical. About 40 to 70% of autopsies demonstrate microscopic basal ganglia calcifications. There was no assossiation with the clinical symptoms as these were attributed to other findings. There is therefore no justification for further invasive tests (14).

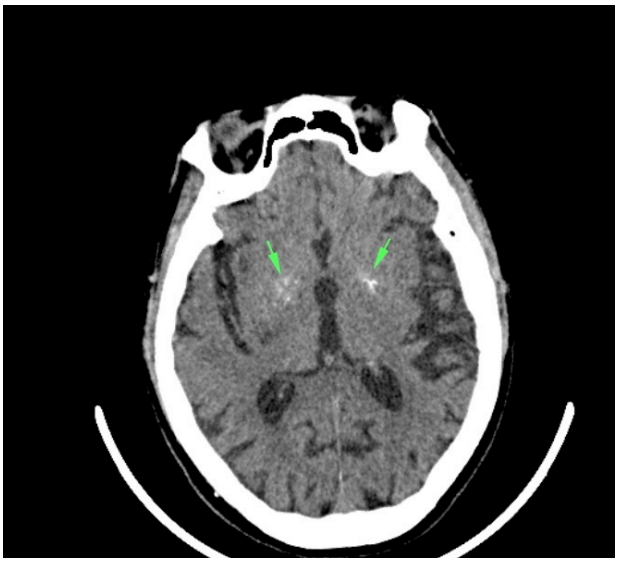

**Figure 1D: Axial image of an elderly patient with bilateral, symetrical and coarse basal ganglia calcifications demonstrated by the arrows.**

**Dura matter, falx and tentorium cerebelli**

The dura matter is the outer part of the three meninges covering the brain parenchyma and spinal canal. It is a dense fibro-collagenous sheet that is made up of two closely adherent layers, the outer periosteal and the inner meningeal layer. These layers separate only in regions where they enclose intervening venous sinuses. The periosteal layer is tightly adherent to the inner aspect of the calvarium. The inner layer folds inwards to form the falx cerebri, falx and tentorium cerebelli (5).

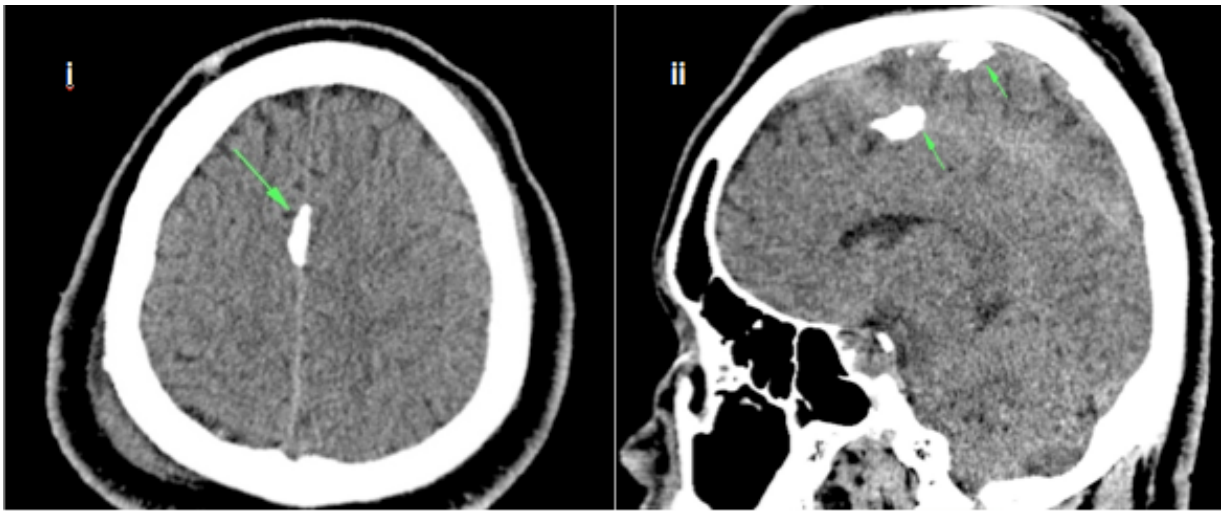


**Figure 1E (i and ii): Axial (i) and sagittal (ii) images of a non-contrast CT brain scan of the 40 year old male patient with dense calcifications of the falx. There is a right parietal subgaleal haematoma noted from sustained head injury (i).**

**Arachnoid granulations**

These are enlarged arachnoid villi that project from the arachnoid space into the lumen of the venous sinuses. They are also known as Pacchionian granulations, after an Italian anatomist who wrote extensively on dural anatomy. They are lined by endothelium and most commonly found along the superior sagittal sinus. Their main function is cerebrospinal fluid absorption whereby they act as a one way valve allowing CSF to flow into the venous sinuses (5, 15).

**Vascular**

Large intracranial vessels commonly have incidental calcifications and this is usually age-related and neurodegenerative. They may be associated with artherosclerosis. The internal carotid artery, especially carotid siphon is the most commonly affected. Figure 1F demonstrates bilateral internal carotid artery calcifications in an elderly patient. Some studies advise the reporting radiologist to mention this as there might be an association with artherosclerosis and increased risk of ischaemic cerebrovascular accidents (15). In comparison to the internal carotd artery, the anterior and middle carotid arteries demonstrate less prevalence of calcifications. The vertebral-basilar arteries are the second most involved arteries. Intracranial internal carotid artery calcifications and their association with vascular risk factors and ischaemic cerebrovascular disease were assessed by de Weert et al.

According to the study, older age and male patients have an increased prevalence. There was however, no correlation of intracranial internal artery calcifications with the presence and type of ischaemic cerebrovascular disease (16).

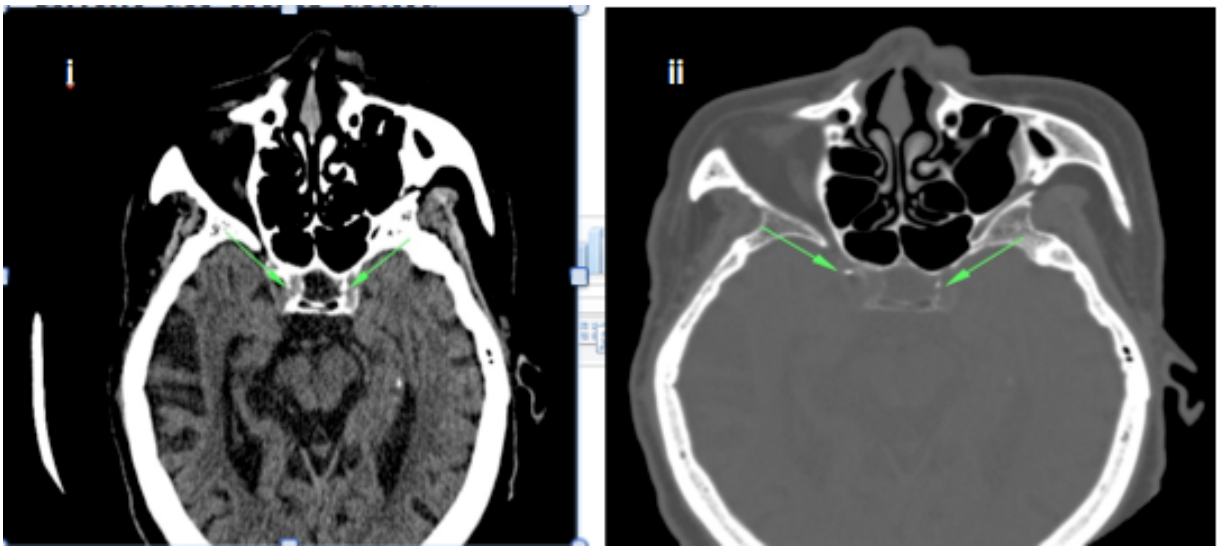


**Figure 1F (i and ii): A non-contrast CT scan (brain and bone window) of a 99-year-old female patient who sustained a head injury from a minor fall demonstrating bilateral mural calcifications of the Internal Carotid arteries.**

**Petroclinoid ligaments**

These are dural folds extending from the anterior and posterior clinoid processes (Figure 1G) to the petrous apex, a portion of temporal bone. These ligaments may have age-related degenerative calcifications. These are an uncommon area of intracranial calcifications.

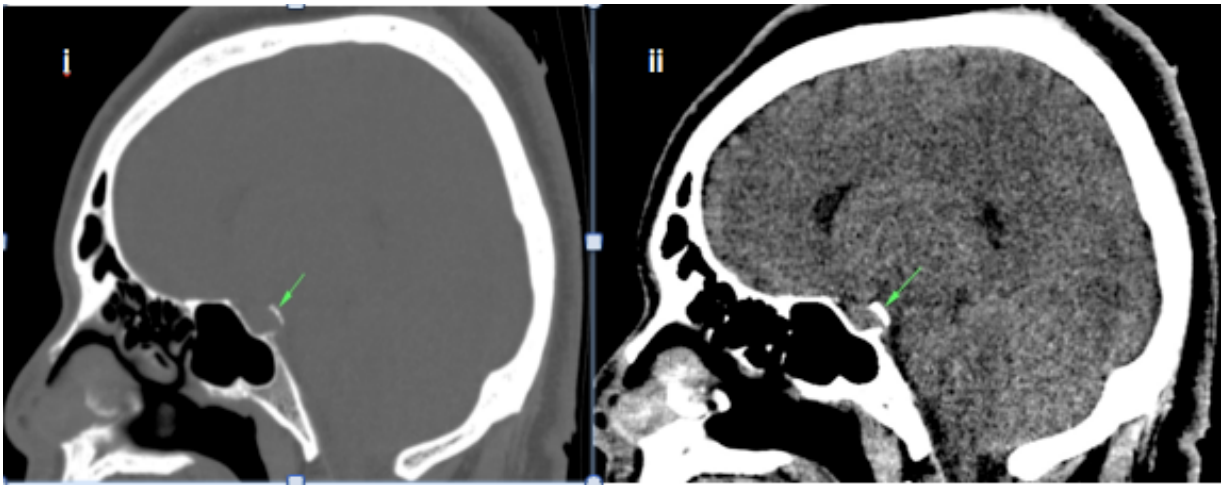


**Figure 1G (i and ii): Para-sagittal images(i bone window, ii brain window) of the previous patient at the level of the petroclinoid ligaments with bilaterally calcified posterior clinoid ligaments.**

**Pituitary gland**

The pituitary gland is situated within the sella, which is a midline, concave depression of the basi-sphenoid in the middle cranial fossa. It is an endocrine gland made up of three components, the adenohypophysis, pars intermedia and neurohypophysis. The different parts of the gland store and secrete hormones including adrenocorticotropic hormone (ACTH) somatostrophins, lactotrophins, vasopressin and oxytocin (5).

**Lens**

The lens is located in the anterior portion of the globe and forms the posterior aspect of the anterior chamber. It is biconvex and its main function is accomodation. This involves refraction of light before it focuses on the retina (5). A study by Daghighi et al concluded that 0.9% of their study population had calcifications in the lens and other non-defined areas and these did not demonstrate an increase with older age (1). The lens is an uncommon area of physiological calcifications. Figure 1H is an axial bone window image of an elderly patient with left lens calcifications.

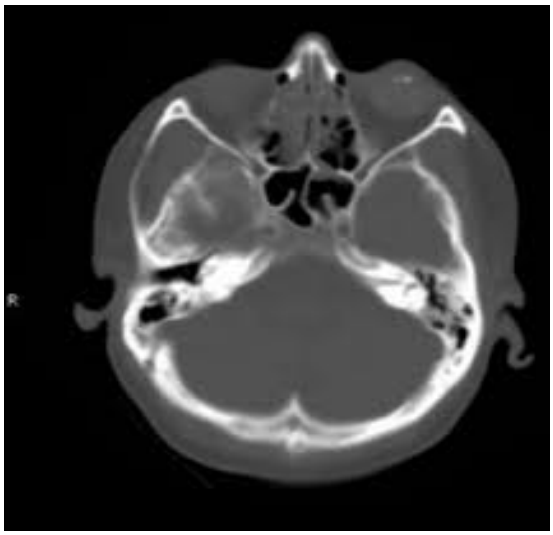

**Figure 1H: An image of a CT brain scan, bony window, of a 75-year-old male patient through the orbits demonstrating unilateral lens calcifications on the left.**

## 1.3. Pathological calcifications

Pathological calcifications are found in multiple disease entities and can be broadly characterised into congenital, infectious, neoplastic, vascular, post traumatic and metabolic. Table 1.1 below gives examples of intracranial pathological calcifications.

**Table 1.1. Classification and examples of diseases that may have pathological calcifications (4, 13)**

| **Classification** | **Example of patholological calcification** |
|---|---|
| Congenital | Sturge-Weber Syndrome, Tuberous sclerosis, Neurofibromatosis |
| Infections | Cytomegalovirus, Toxoplasmosis, Tuberculosis, Neurocysticercosis, |
| Metabolic | Hypoparathyroidism, Farh disease, Pseudo-hypoparathyroidism |
| Neoplastic | Intra-axial: Medulloblastoma, Pilocytic astrocytoma, Germ cell tumours<br>Extra-axial: Craniopharyngioma, Meningioma |
| Previous trauma | Resolved haematoma |
| Vascular malformations | Arterio-venous malformations, Cavernous malformations |

## 1.4. Epidemiology of intracranial calcifications worldwide

Extensive studies have been conducted worldwide to determine the prevalence of physiological intracranial calcifications. Some of the assessed variables in these studies included the presence of physiological calcifications, distinguishing pathological from physiological intracranial calcifications, determining the male to female ratio and association with age. These publications are expanded on in the sections below and summarised in Table 2.1.

**Table 2.1: Comparison between four reviewed studies demonstrating their different evaluated parameters and findings (1, 10, 13, 17)**

| Topic | **Intracranial physiological calcifications in adults on computed tomography in Tabriz, Iran** | **Intracranial calcifications evaluated with cone beam CT** | **CT patterns of physiological intracranial calcifications in a central African city** | **Incidence of normal pineal and choroid plexus calcifications on computed tomography** |
|---|---|---|---|---|
| Year of publication | 2007 | 2012 | 2011 | 2009 |
| Study type | Retrospective | Retrospective | Prospective | Cross sectional descriptive |
| Country | Iran, Tabriz | USA, California | Douala, Cameroon | Ethiopia, Addis Ababa |
| Age group | 15-85 | 13-82 | 0-89 | |
| Study population number | 1569 | 500 | 132 | 518 |
| **RESULTS:** | | | | |
| Physiological (%) | 50% | 176 (35.2%) | | - |
| Pathological (%) | Not assessed | 0% | - | - |
| Ethnic predilection | Not assessed | None | Not assessed | Not assessed |
| Male: female | 1:1.2 | 3:2 | 1.42:1 | Male >Female |
| Choroid plexus | 66.2% | 12% bilaterally | 56.82% | 43.3% |
| Pineal gland | 71.0% | 80% combined | 37.42% | 72.0% |
| Habenular | 20.1% | 80% combined | | - |
| Basal ganglia | 0.8% | Not assessed | 0.76% (dentate nucleus) | - |
| Falx | 7.3% 9 (tentorium, sagittal sinus or falx) | Not assessed | 15.9% | - |
| Vascular | 6.6% | Not assessed | | - |
| Petroclinoid ligaments | Not assessed | 8% bilaterally | | - |
| Lens | 0.9% and non-defined areas | Not assessed | | - |

### 1.4.1. Epidermiology of intracranial calcifications in the developed world

Sedghizadeh performed a study at the University of California in 2012 to evaluate the presence of pathological and physiological intracranial calcifications on cone beam CT. Five hundred (500) CBCT scans that met their ascertainment criteria were retrospectively evaluated. The ages ranged from 13 years to 82 years with a mean age of 52 years. Their results demonstrated that out of the 500 patients, 176 had evidence of intracranial physiological calcifications (35.2%). None of the study population demonstrated any evidence pathological calcifications. There was a 3:2 male-to-female ratio and no ethnic predilection. The most common area of calcifications was in the pineal/habenular region (80%), with less appearing in the choroid plexus bilaterally (12%), and a smaller subset found in the petroclinoid ligament region bilaterally (8%). In conclusion, the findings were that physiological calcifications might be a usual finding whereas pathological calcifications were uncommon (13).

In 1988, Kwak et al evaluated 2877 patient's CT Brain scans for the prevalence of pineal, choroid plexus and basal ganglia calcifications. Their examination was based on the frequency of occurrence and association with age and gender. Pathological calcifications were not evaluated. They concluded that pineal gland calcifications were the most commonly seen, making up 67.7%, followed by 57.6% in choroid plexus of lateral ventricles and 7.5% in basal ganglia. Pineal calcifications were found to increase with age. There was an overall gradual increase in calcifications in patients aged over 40 years with calcifications seen in

81.5% of patients over 80 years of age. In patients aged 20 to to 79 years, there was a higher incidence of calcifications in male patients compared to females (18).

### 1.4.2. Epidermiology of intracranial calcifications in the developing world

A study conducted in 2007 in Tabriz, Iran determined the prevalence of intracranial physiological calcifications in adults on CT. Of the 1569 patients ranging from 15 to 85 years of age, none were found to have pathological calcifications. Pineal calcifications were the most common (71%) followed by 66.2% in the choroid plexus. Habenular calcifications were found in 20.1% of the study population while 7.3% had tentorium cerebelli, falx cerebri or sagittal sinus calcifications. Vascular calcifications were demonstrated in 6.6% of individuals and 0.8% in basal ganglia. The least calcifications were found in the lens and other non-defined calcifications. Generally there was a higher frequency in males with all types of calcifications and an increase with age, with the exception of the lens and other non-defined areas (1).

Uduma et al prospectively evaluated intracranial calcifications in Douala, Cameroon (2011), in central Africa to establish the earliest age range of detection. The study population included 132 patients. The most common area of calcifications was choroid plexus, constituting 56.82% of the study population. Pineal gland calcifications were second most common, with evidence of both commonly coexisting with advancing age. The least area of these calcifications was in the dentate nucleus. Of the 132 CT brain scans assessed, 163

separate calcifications were identified due to co-existent calcifications. The study concluded that physiological intracranial calcifications were first seen at 10-19 years of age (10).

Admassie et al conducted a study in Addis Ababa in 2012 to determine the incidence of normal calcifications of pineal gland and choroid plexus. The difference with this study compared to the others is that only two areas of physiological calcifications were evaluated. Important variables in this study were to determine association with age and gender. Their study results revealed that pineal gland calcifications were more prevalent (72%) than choroid plexus calcifications (43.3%). The incidence of pineal gland calcifications and choroid plexus were higher in males than females (13.1% and 6.0% respectively). Frequency of both types of calcifications increased with age in both males and females. In comparison to other studies, this study displayed similar findings with regard to pineal gland calcifications whereas choroid plexus calcifications were showed to be much lower (17).

## 1.5. Aims and objectives

### 1.5.1 Aim

This study aims to determine the prevalence of intracranial calcifications and to categorise these according to location, age, gender and whether they are perceived to be physiological or pathological by the radiologists.

### 1.5.2 Objectives

- To determine proportion of the study population that has incidentally found intracranial calcification on CT scan based on appearance and Hounsfield Units.
- To classify these calcifications as to whether they are physiological or pathological based on their location, appearance and association with other structures eg, solid masses.
- To classify physiological calcifications according to their location and determine the incidence within each of the ten normal locations.
- To correlate incidental physiological calcifications prevalence with age and gender, therefore determining if there is an association.

# 2. Materials and Methods

## 2.1. Research paradigm

The study was a retrospective, quantitative, cross-sectional study reviewing non-contrasted CT brain scans of patients presenting to the Trauma Department at Chris Hani Baragwanath Academic Hospital after sustaining head injury from non-specified mechanism of injury. Scans were collected dating from the first of June 2013 until the required number of scans was acquired.

## 2.2. Sample

The study population (450) included adult male and female patients presenting to the Trauma Department at Chris Hani Baragwanath Academic Hospital that were referred to the Radiology Department for non-contrasted brain CT scan. Head trauma included diverse types of mechanism of injury ranging from minor falls to motor-vehicle accidents.

### 2.2.1. Sample size calculation

**Descriptive analysis**

An estimate for precision was based on the reporting of a 50% proportion (worst-case) with 5% precision, and the 5% significance level. This required a sample size of 384.

Reporting a 5% proportion with 2% precision required a sample size of 456.

Thus the sample size of 450 was adequate for descriptive reporting, except for the reporting of very low proportions (<5%) with adequate precision.

Sample size for prevalence (or proportions) was determined using the formula:

$$n = \frac{Z^2 P(1-P)}{d^2}$$

where n = sample size,

Z = Z-statistic for the chosen level of confidence,

P = expected prevalence or proportion

d = precision (19)

**Inferential statistics**

This relates to the association between individual calcification features (classified as presence/absence), age or gender of the patient. Based on the fact that age was divided into seven age categories, a chi-square ($X^2$) test with (5*1=) 5 degrees of freedom was required. The detection of a small, medium, or large effect size (w=0.1, 0.3, or 0.5 respectively) with 80% power and at the 5 significance level, required sample sizes of 1283, 143, and 52, respectively.

The sample size of 450 was adequate for the detection of effect sizes up to w=0.16, i.e. fairly small effect sizes (20).

## 2.3. Method

- The study population was identified from the CT request forms acquired from Radiology Department records.
- The CT scans were performed on either one of two CT scanner machines, a 64-slice Multiple Detector Computed Tomography (MDCT) and a 128-slice MDCT Toshiba CT scanner.
- Data was collected from Picture Archiving and Communications Systems (PACS).
- The retrieved data was transferred from PACS onto an external hard drive, which was then loaded and reviewed by the readers on Apple MacBook Pro computers using Osirix DICOM (Digital Imaging and Communications in Medicine) software. Images

viewed on Osirix are diagnostically accurate and are comparable to reading scans from an actual CT console/monitor.

- Three Readers assessed the data and the most popular opinion was considered and recorded. The additional use of Hounsfield units by individual readers eliminated bias as this is a standard measure and is consistent. Hounsfield units (from about 140) were therefore used to confirm calcifications.
- The readers included the primary investigator and two other intermediate level (34 months and 22 months) registrars employed by the Radiology Department.
- The readers were able to manipulate the images using data reformatting capabilities of Osirix. The images were viewed in axial, coronal and sagittal planes.
- A data sheet designed by the primary investigator and supervisor was provided for the readers to use. This was in the form of a tick sheet, with specific pre-determined criteria for allocating the intracranial calcifications (See Appendix B).
- The readers were blind to each other and blind to the original patient data.
- The readers were trained before the study on how to use the tick sheet and to clarify where all these calcifications are found. Training was done by the principal investigator on an individual basis using Osirix software on a Macbook Pro in a duration of 2 hours. This was done on different CT brain images using brain window, bone window and MPR properties of the software. Training was for the detection and localising the calcifications. Both readers were allowed to enquire further at a later stage for any uncertainties for reinforcement. The training also included differentiation of physiological versus pathological calcifications.

## 2.4. Inclusion criteria

- Male and female patients who were 14 years and older.
- Patients referred to the Radiology department from the Trauma department at Chris Hani Baragwanath Academic Hospital.

## 2.5. Exclusion criteria

- Patients with incomplete data.
- Patients referred for Non-contrast CT scans of the brain for indications other than trauma.
- CT scans compromised by artefacts.
- Contrast enhanced CT brain scans.
- Repeat scans.

## 2.6. Data collection

Data was collected according to predefined criteria as described above. This data was collected over a period of 5 months. The CT scans were retrieved from PACS with assistance from the PACS system administrator. This was done by saving the scans onto an external hard-drive. These scans were then loaded on Osirix software for analysis by three readers. A data collection sheet designed by the primary investigator and supervisor was provided for the readers to use. This was in the form of a tick sheet with specific, pre-determined criteria for allocating the intracranial calcifications.

For every CT scan, the appearance of physiological and pathological intracranial calcifications was assessed and indicated on the tick sheet. Data included presence of calcifications, their location in the brain and whether the calcifications were seen to be physiological or pathological. Density of the calcifications was not assessed as a parameter in this study.

## 2.5. Statistical analysis

Data analysis was carried out using SAS (Statistical System Analysis). This is a software system developed by SAS Institute, North Carolina State University, used for data analysis and reporting .

The $X^2$ test was used to assess the association between the presence or absence of a calcifications, gender or age group. Fisher's exact test was used for 2 x 2 tables or where the requirements for the $X^2$ test could not be met. The strength of the associations was measured by Cramer's V and the phi coefficient respectively. The following scale of interpretation was used:

| | |
|---|---|
| 0.50 and above | high/strong association |
| 0.30 to 0.49 | moderate association |
| 0.10 to 0.29 | weak association |
| below 0.10 | little if any association (21) |

The Cochran-Mantel-Haenszel test was used to determine the association between presence or absence of a feature and gender, stratifying for age.

Further, the Cochran-Armitage test for trend was used to test for a linear association between the presence or absence of a feature and increasing patient age (categorised). The analyses was conducted on the overall data, and stratified by gender.

The 5% significance level was used throughout, in other words, p-values <0.05 indicate significant results.

# 3. Results

## 3.1. Demographics

### Age

For the total number of the study population (450), the patients were grouped into seven age categories. This was the most commonly used categorisation of age groups in reviewed literature. Table 3.1 demonstrate the frequency and percentages of the different age groups. The mean age of the study population was 38.4 years (standard deviation=16.0 years; range 15-90 years). The age of the population group was not normally distributed, with an overall median age of 34 years. The youngest age group (14 to 19 year old) made up the least proportion (5.6%) of the total study population demonstrating less probability of traumatic head injury in comparison to older age groups. Patients between the ages of 20 and 39 made up the largest proportion of the study population. Patients in their 50's and older made up a much smaller proportion of the study population in comparison to those younger than 40 years of age.

**Table 3.1: The frequency and percentage of the study population according to age group**

| Variable | Category | Frequency | Percent % |
|---|---|---|---|
| Age group | 14-19 year old | 25 | 5,6 |
| | 20-29 year old | 144 | 32,0 |
| | 30-39 year old | 113 | 25,1 |
| | 40-49 year old | 70 | 15,6 |
| | 50-59 year old | 43 | 9,6 |
| | 60-69 year old | 28 | 6,2 |
| | 70 year and older | 27 | 6,0 |
| Gender (Total= 450) | Female | 151 | 33,6 |
| | Male | 299 | 66,4 |

**Gender**

Table 3.1 demonstrates that of the total study sample size, the number of male patients was 299 and female was 151 (66.4% and 33.6% respectively). The mean age and standard deviation for males was 37.4 years and 16 years while it was 40 years and 16 years for females. Table 3.2 demonstrates that within all the age group categories, there were more male patients than females. The median age of male patients (33 years) was significantly lower than that of the female patients (38 years) (Wilcoxon rank sum test; p=0.021). There was however an increase in the number of females per age group as the decades increased, as seen in Figure 3.1. This could possibly signify that with increasing age, the incidence of head injury could be comparable between males and females, unlike in younger patients.

A conclusion drawn from the test of association between gender and age group is that while the overall test for association was not significant (p=0.07), the test for trend was significant (p=0.040), indicating a linear decrease in the proportion of males with increasing age group, as illustrated below.

**Table 3.2: Proportion of the study population age group by gender.**

| Table of Age by Gender | | | |
|---|---|---|---|
| **Age** | **Gender** | | |
| | **Female (Percentage)** | **Male (Percentage)** | **Total (Percentage)** |
| **14-19 year old** | 9 (36.0%) | 16 (64.0%) | 25 (5.6%) |
| **20-29 year old** | 40 (27.8%) | 104 (72.2%) | 144 (32.0%) |
| **30-39 year old** | 31 (27.4%) | 82 (72.6%) | 113 (25.1%) |
| **40-49 year old** | 32 (45.7%) | 38 (54.2%) | 70 (15.6%) |
| **50-59 year old** | 19 (44.2%) | 24 (55.8%) | 43 (9.5%) |
| **60-69 year old** | 9 (32.1%) | 19 (67.9%) | 28 (6.2%) |
| **70 years and older** | 11 (40.7%) | 16 (59.3%) | 27 (6.0%) |
| **Total** | 151 (33.6%) | 299 (66.4%) | 450 (100%) |

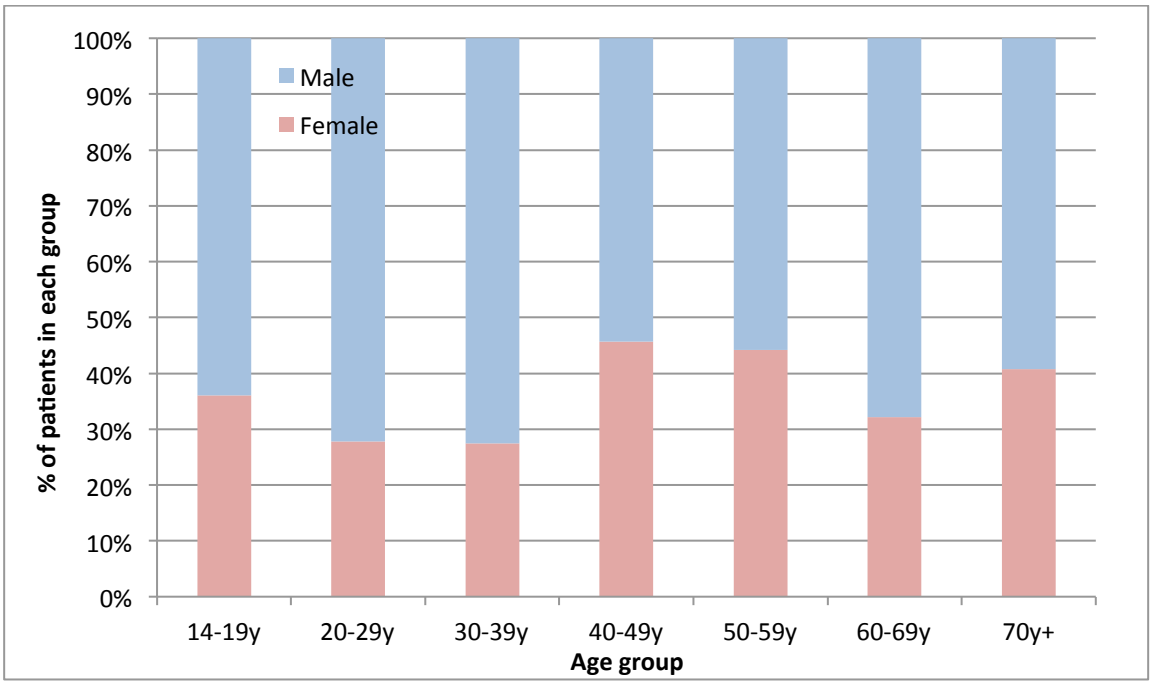


**Figure 3.1: Histogram demonstrating the proportion of male and female patient with regard to the different age categories.**

## 3.2. Physiological calcification

Overall, 98.2% of the patients had some form of physiological calcification with only 1.8% patients having no identified calcification. Most of the calcifications were co-existent in individual patients. There was no significant association with gender. The overall test for association with age was not significant (p=0.15), however, the test for trend was significant (p=0.011). Figure 3.2 demonstrates that the proportion of patients with calcification increased with increasing age group. All patients from the age of 40 and above had physiological calcifications present. Of the total number of patients with calcifications (442),

149 were female and 293 were male. This was 98.7% of the total female population and 98% of the male population.

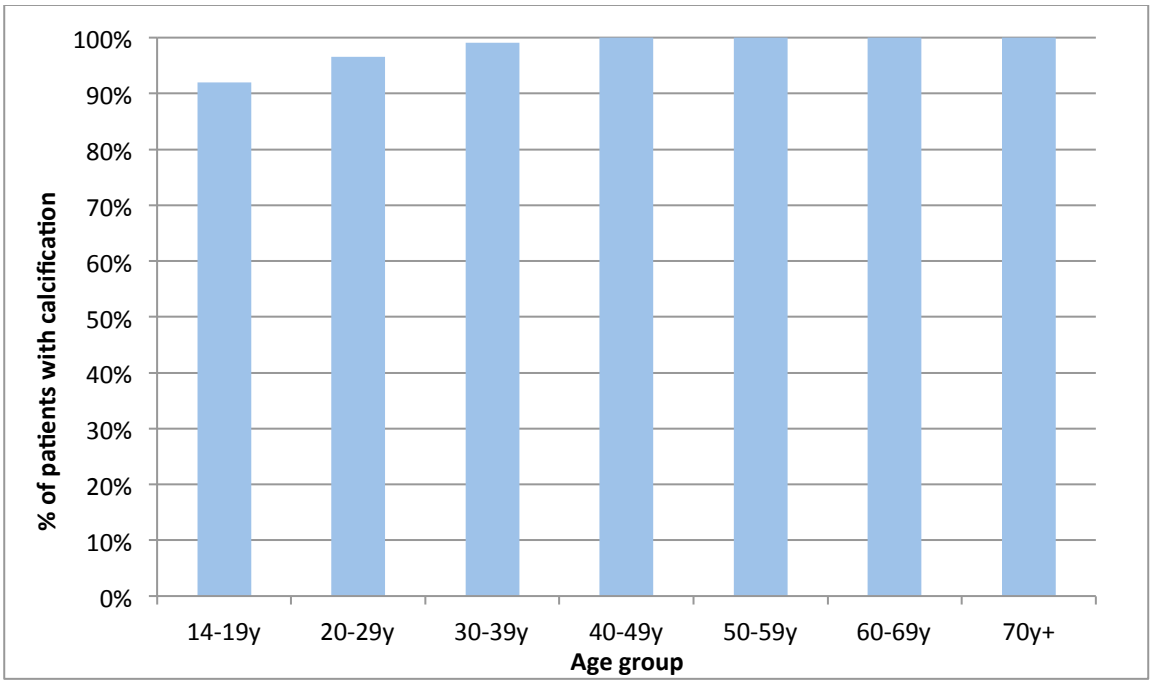


**Figure 3.2: The proportion of patients with incidental physiological calcifications by age group category**

Splitting the above analysis by gender, the significant trend with age remained significant for males (p=0.043), but not for females (p=0.09).

### 3.2.1. Individual physiological calcifications

The overall proportion of patients with visualised physiological intracranial calcifications is shown in Figure 3.3 below. Note that the percentages do not sum to 100% since a patient could have more than one area of calcification. The choroid plexus was the most commonly affected area with 87.8% of patients having presence of calcifications, followed by the pineal gland (76.0%). None of the patients had physiological pituitary calcifications, however, one patient was found to have a large, calcified sella mass, which was classified as pathological calcification. This will be discusses under pathological calcifications.

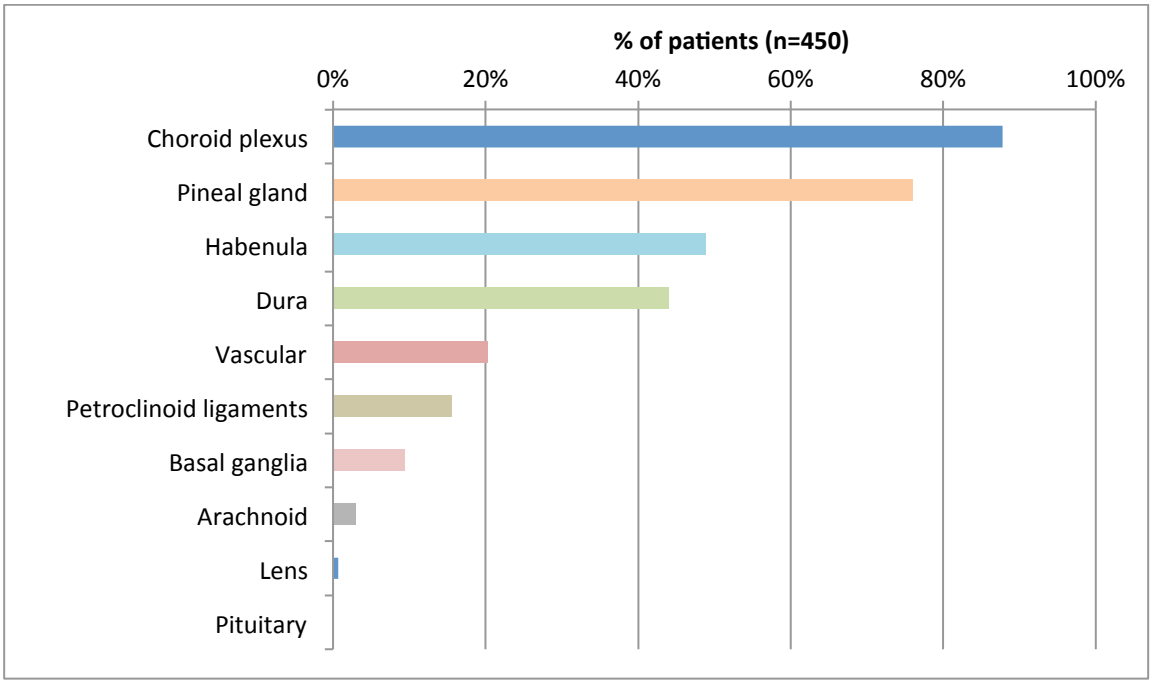


**Figure 3.3: Histogram of the proportion of patients with presence of incidental calcifications.**

Two of these areas were weakly associated with gender including vascular calcifications, which were more predominant in females (26.5%) than males (17.1%) and arachnoid calcifications were found to be more predominant in females (5.3%) than males (1.7%).

Figure 3.4 is a histogram of the associations of the commonly found areas of physiological calcifications with the different age groups. It demonstrates that several areas were associated with age group. Choroid plexus (p= 0.0001), pineal gland (p= 0.0003), dura (p= 0.0004) and basal ganglia (p= 0.0005) calcifications were found to be weakly associated with age. Vascular ($p < 0.0001$) calcifications were moderately associated with age. All of these also had a significant test for trend.

As illustrated in Figure 3.4 below, the presence of choroid plexus, pineal, dural, basal ganglia and vascular calcifications increased with increasing age group.

For choroid plexus, dural, and vascular calcifications, the trend was significant for both male and female sub-groups. In males, the p- value for trend was 0.011 for choroid plexus calcifications, 0.012 for dural calcifications and was less than 0.0001 for vascular calcifications. In females it was 0.0027 for choroid plexus, 0.028 for dura and less than 0.0001 for vascular calcifications. The trend for association in pineal gland and basal ganglia was only significant for males ($p = 0.0003$ for pineal gland and $p <0.0001$ for basal ganglia), and not for females.

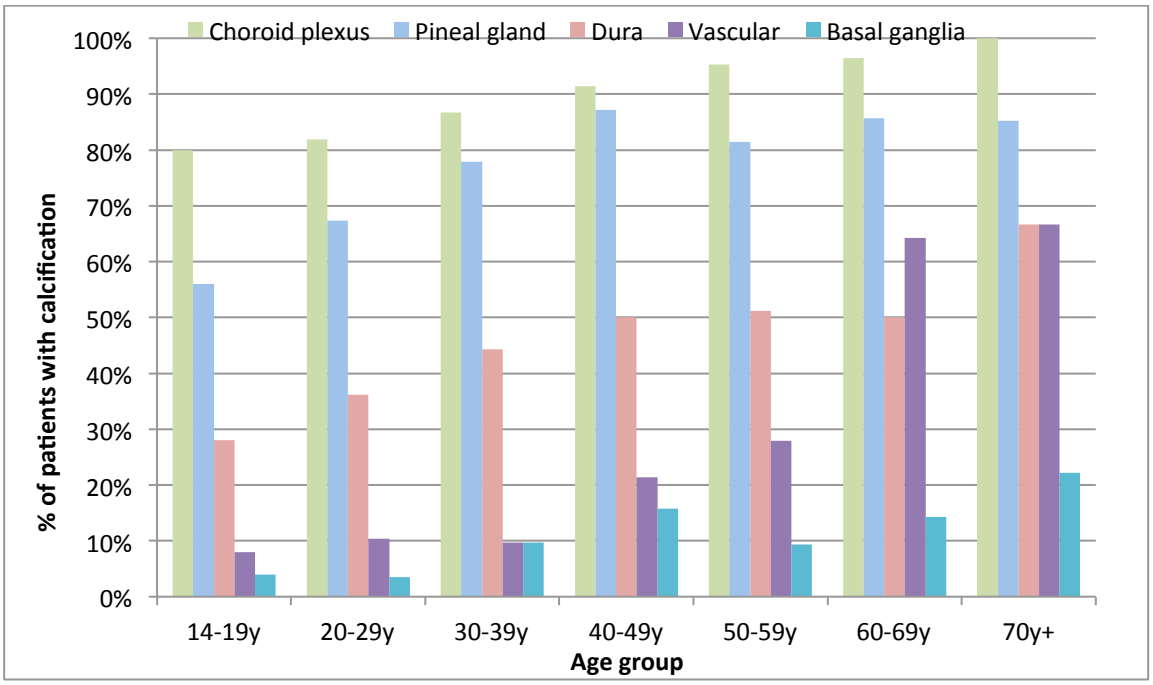


**Figure 3.4: Association of the common physiological calcifications with the different age groups.**

Bilateral structures including choroid plexus, petroclinoid ligaments and basal ganglia were assessed for laterality. The results are tabulated in Table 3.3, which demonstrates that all three areas predominantly have bilateral calcifications.

**Table 3.3: The proportion of unilateral and bilateral calcifications in choroid plexus, petroclinoid ligaments and basal ganglia.**

| Physiological calcification | Category | Total | Percentage |
|---|---|---|---|
| Choroid plexus (n=395) | Unilateral | 27 | 6.8% |
| | Bilateral | 368 | 93.1% |
| Petroclinoid ligaments (n=70) | Unilateral | 24 | 34.3% |
| | Bilateral | 46 | 65.7% |
| Basal ganglia (n=42) | Unilateral | 6 | 14.3% |
| | Bilateral | 36 | 85.7% |

## 3.3. Pathological calcification

Pathological calcifications were found in 39 out of the 450 patients, making them 8.7% of the total study population. The majority (20.6%) of these were multiple intra-axial well-defined focal calcifications. The remainder of patients had single calcification in any of the cerebral hemispheres. One patient was noted to have a large, hypodense sella mass with multiple intra-lesional calcifications.

# 4. Discussion

## 4.1. Demographics

The aim of this study was to retrospectively review non-contrasted CT-Brain scans and determine the prevalence of intracranial calcifications in the adult South African population. There has not been much literature with regard to this topic with no known trends for comparison to the rest of the world. The study did not entail on a descriptive evaluation of the calcifications in terms of pattern, shape, or density as this was purely for quantitative purposes.

The results show that the demographic data from this study was not generalisable to the South African population. The age and gender distributions are not representative of the South African population, and the age versus gender distribution is also skewed and not representative of the composition of the South African population. This, however, does not impact the results of the study with regard to the incidental findings of physiological calcifications.

Furthermore, looking at the results by age would mean adjustment of the differences in gender with respect to age and when analysing the results by gender, there needs to be adjustment for the differences in gender with respect to age. For these analyses, the bottom two and top two age groups were combined, due to small sub-group sizes. This combination of age groups did not make make any difference in the overall conclusion.

Our population size was calculated to be 450 using statistical testing for significance. This was found to be adequate for the study. With regard to population size, Kwak et al had the largest population of 2877. They however only evaluated pineal, basal ganglia and choroid plexus calcifications whereas we included other known areas of calcifications (18). This was followed by the study done in Iran, which had a population of 1569 (1) The study with the more similar population size to ours had 500 patients (13). The study with the least population size was that done in Cameroon which only had a sample size of 132 (10).

The study sample was randomised however, resulted in an excess of male (66.4%) to female (33.6%) patients. This is not a true representative sample of the entire South African population however, it is a reflection of the South African population involved in traumatic injury. Nicol A, et al conducted a study titled Trauma surveillance in Cape Town, South Africa, with the aim of formalizing injury data collection in their trauma centre. An analysis of their demographics demonstrated that most violent injuries occurred in males (71.3%) younger than 40 years of age (74.6%) (22). Our sample is a more accurate representation of the population in South Africa involved in trauma and should not be extrapolated to represent the entire South African population. Hence the evaluation of non-contrasted CT brain scans.

From previously reviewed literature, it has been clear that the male to female ratio of the study population differs from one study to the other. The study conducted by Kwak et al in Japan had a total of 2877 and 1450 were male while 1427 were female (18). Uduma et al

analysed a total of 132 patients with 75 males (56.82%) and 57 females (43.18%). Dhaghighi et al had a total of 1569 patients and 928 (59.1%) were female while 641 (49.1%) were male (1).

While most of the studies included patients from teenage years and above, one study evaluated consecutive scans regardless of age. Their study population included patients of all ages. According to their study, no calcifications were identified in patients less than 9 years of age and they concluded that any calcifications should be further worked up, as it is most likely a pathological finding. Malignancy would need to be excluded (10).

In our study, the two largest age groups were 20 to 29 and 30 to 39 year olds. This demonstrates the higher prevalence of traumatic head injuries compared to other age groups (22). The predominance of younger patients, typical of trauma patients, is clearly seen. Secondly, young males are more likely to sustain injuries compared to females and the elderly, which further compounds the inaccurate representation of the South African population. Evaluation of patients with no known co-morbidities would have rendered the study more biased owing to the fact that certain disease entities might predispose to calcium or other mineral deposition within different organs. For this reason, referrals from the Trauma department were considered to be more appropriate for the study. This did not however eliminate those patients with co-morbidities. It merely reduced the likelihood of pathological patients, as these patients were walk-ins from the community. Data analysis concluded the study sample to be adequate for evaluation.

Our study showed that the majority of patients (98.2%) had incidentally identified physiological calcifications. In comparison other literature, our study had the highest prevalence of identified incidental calcifications in the population. One study identified 50% (1) of the entire study population and another only found 35.2% (13) of the population to have incidental calcifications. A single patient could have co-existent calcifications. In fact, most of our evaluated population had multiple areas of calcifications. That said, it should be highlighted that the most commonly encountered calcifications were the most commonly co-existent. According to Uduma et al, of the 132 patients evaluated, 163 individual calcifications were found to co-exist. According to their findings, choroid plexus and pineal calcifications were co-existent with advancing age (10). Daghighi et al found that 18.7% of their population had both pineal and habenular calcifications (1). Our study population was 450 in total however, there were 1374 calcifications identified. This demonstares the co-existense of calcifications.

## 4.2. Physiological calcifications

The presence or absence of physiological calcifications was the major parameter in this study with laterality evaluated in bilateral structures namely, basal ganglia, choroid plexus and petroclinoid ligaments. Habenular calcifications were not evaluated for laterality as these were found to be at times cumbersome. Calcification density and pattern was not included as a parameter as the clinical significance is yet to be understood. Hounsfield Units were used by the readers to confirm calcification if readers were uncertain however, this was not always used as the readers were well experienced.

Figure 3.3 is a histogram demonstrating the frequency of physiological calcifications in the study population. Choroid plexus (87.8%) calcifications were the most commonly encountered incidental calcifications. Table 3.3 on laterality shows that most choroid plexus calcifications were bilateral (93.1%) while only 6.8% were unilateral.

Kiroglu et al concluded that choroid plexus calcifications are a common finding and are usually in the atrial portion of the lateral ventricles. Calcifications were not commonly seen in the third or the fourth ventricle (4). Similarly, our study also demonstrated most choroid plexus calcifications to be in the lateral ventricles. The infrequent finding of unilateral choroid plexus calcifications could influence certain clinical settings where there is suspicion of pathology.

Our study demonstrated that the second most common area where physiological calcifications were found was in the pineal gland. Alves G et al conducted a retrospective study on pineal and choroid plexus calcifications on CT and described that pineal and choroid plexus calcifications were the two most commonly found incidental physiological calcifications with pineal being more common than choroid plexus. There was a strong association with age as their prevalence increased with older age and these were considered to be degenerative. Furthermore, they concluded that pineal calcifications were more likely in men than women due to the physiological function of the gland, which involves melatonin and sexual hormones. Their study did not confirm postulations regarding possible association with latitude or altitude but this could be was considered a feasible explanation for the different findings in their population (12). Our study, similar to Alves G et al, demonstrated increasing prevalence of both choroid plexus and pineal gland calcifications however, choroid plexus calcifications more prevalent than pineal calcifications. A definite association of pineal gland calcifications and increased prevalence in males was also found in our study. Both studies also demonstrated an association between pineal gland calcifications with increasing age. A similar study in Addis Ababa aimed to determine the incidence of pineal gland and choroid plexus calcifications demonstrated the overall pineal gland calcifications to be more than those in the choroid plexus. Their outcome on pineal gland calcifications were in line with other studies however, the proportion of choroid plexus calcifications was lower than expected (17). Kwak et al found 67.7% pineal calcifications and 57.6% choroid plexus calcifications in their study population with pineal calcifications prevalence increasing with age (18).

The only other study that had the highest prevalence of choroid plexus calcifications was in the study done by Uduma et al in Central Africa. They found 56.82% choroid plexus calcifications and 37.42% pineal calcifications. The common factor between the studies is that both were conducted in Africa with most patients of black ethnicity. This is a feasible hypothesis for the diverse findings compared to other studies in developed countries regarding pineal and choroid plexus calcifications. Overall, with regard to gender, our findings were that of male predominance which was in keeping with all other reviewed literature.

A significant proportion of patients had habenular (48.9%) calcifications. These are bilateral structures however, may be difficult to asses therefore we only assessed for presence and not laterality. Additionally, their proximity to the pineal gland can confound localising the calcification as pineal or habenular. One study combined the findings of pineal and habenular region. They found 80% of their study population to have these pineal/habenular calcifications (13).

Dural calcifications were found in 44% of the population. Most of these were encountered in the falx cerebri with some noted in the tentorium cerebelli and other dural folds. They ranged from a single small calcification to multiple, large and dense calcifications. Daghighi et al reported 7.3% of dural calcifications, which included falx cerebri and tentorium cerebelli (1), which is much lower than our findings. A similar study found these in 15.91% of their population (10).

Despite the extensive appearance of some of these calcifications, they were still considered physiological. In paediatric patients, these should be considered suspicious (15). Petroclinoid ligament calcifications were 15.6% and most of them were bilateral.

Basal ganglia calcifications were seen in 9.8% of the population, which was also much higher than the previously reported 0.3% to 1.5% (4). Brain Calcinosis Syndrome has been used to describe basal ganglia calcifications as this area is commonly involved in accumulation of calcium in the brain parenchyma (10). One study reported 1.52% (10) and another reported a lower prevalence of 0.8% (1).

Vascular calcifications were found in 20.2% of the population with a clear association with older age ($p < 0.0001$). Most of these were found in bilateral internal carotid arteries. The Internal carotid artery, especially carotid siphon was the most commonly affected. de Weert et al and Anvekar concluded that vascular calcifications were associated with older age, male gender and atherosclerosis in other vessels. These two studies however, had conflicting views regarding association with ischemic cardiovascular disease (15, 16). Our study demonstrated a significant p-value of less than 0.0001 for both male and female populations. The difference between our study and the previous one is the evaluation of atherosclerosis and association with ischaemic cardiovascular disease, which was not included as a measured parameter in our study.

Arachnoid calcifications were minimal with only 2.9% of the population being found to contain these. Calcifications were rarely noted in the lens (0.7%).

None of the study population had physiological pituitary calcifications however, one had a sella pathological calcification, which will de discussed in the section on pathological calcifications below.

## 4.3. Pathological calcifications

Of the 450 patients evaluated, only 8.7% had pathological calcifications. There was no particular grouping of these calcifications as they can implicate numerous various intracranial structures and disease entities. The most commonly found in this category was focal calcified granulomas, which were either single or multiple. The majority of which were single focal calcifications. Multiple calcified granulomas have been described in neurocysticercosis. Cysticercosis is a parasitic infection caused by a tapeworm, *Taenia solium*, which is endemic to South Africa predominantly in the Eastern Cape province. It is acquired by ingestion of infected pork and can affect multiple organs. Neurological manifestations include different stages of the disease seen on CT and MRI.

There are four different stages of the disease namely: vesicular, colloid vesicular, granular nodular and calcified nodular. The vesicular stage is the acute phase of the disease with

disease progression to eventually form calcified nodules, which is the healed phase of the disease(23). In endemic areas, like South Africa it is a common cause of acquired epilepsy. Our study had a few patients with features of calcified nodules (36 of the total 39), making them 92% of patients with pathological calcifications.

Tuberculous calcified granulomas are also another cause of calcified granulomas that have been well described in its healed phase.

One patient was found to have a large, lobulated heterogeneous soft tissue sella mass with intra-lesional dense calcifications. There had been no prior history or admissions and the patient had been previously well. The differential diagnosis for calcified sella masses includes tumours such as craniopharyngioma, teratomas, meningioma and astrocytomas. Calcifications are rare in pituitary macroadenoma. An important lesion not be missed in this region is an aneurysm, which may have calcifications. Further workup on this patient would be advised.

As previously mentioned, physiological and pathological calcifications can co-exist. From this study it was established that all patients with pathological calcifications also had physiological calcifications. There was however no particular pattern of association. The co-existence of these calcifications was random.

## 4.4. Results in context

The table below compares the different reviewed literature with results from our study. This is aimed at comparing the South African adult population intracranial calcification trends to establish the similarities and differences that we have with other populations.

**Table 4.1: Comparison of reviewed previous literature with the current study**

| Topic | **Intracranial physiological calcifications in adults on computed tomography in Tabriz, Iran** | **Intracranial calcifications evaluated with cone beam CT** | **CT patterns of physiological intracranial calcifications in a central African city** | **Incidence of normal pineal and choroid plexus calcifications on computed tomography** | **Prevalence of incidental physiological calcifications in the adult South African population as seen on CT** |
|---|---|---|---|---|---|
| Year of publication | 2007 | 2012 | 2011 | 2009 | 2015 |
| Study type | Retrospective | Retrospective | Prospective | Cross sectional descriptive | Retrospective |
| Country | Iran, Tabriz | USA, California | Douala, Cameroon | Ethiopia, Addis Ababa | South Africa |
| Age group | 15-85 | 13-82 | 0-89 | | 14 years and older |
| Study population number | 1569 | 500 | 132 | 518 | 450 |
| **RESULTS:** | | | | | |
| Physiological (%) | 50% | 176 (35.2%) | | - | 98.2% |
| Pathological (%) | Not assessed | 0% | - | - | 8.7% |
| Ethnic predilection | Not assessed | None | Not assessed | Not assessed | Not assessed |
| Male: female | 1:1.2 | 3:2 | 1.42:1 | Male >Female | Male> Female |
| Choroid plexus | 66.2% | 12% bilaterally | 56.82% | 43.3% | 87.8% |
| Pineal gland | 71.0% | 80% combined | 37.42% | 72.0% | 76.0% |
| Habenula | 20.1% | 80% combined | | - | 48.9% |
| Basal ganglia | 0.8% | Not assessed | 0.76% (dentate nucleus) | - | 9.8% |
| Falx | 7.3% 9 (tentorium, sagittal sinus or falx) | Not assessed | 15.9% | - | 44.0% |
| Vascular | 6.6% | Not assessed | | - | 20.2% |
| Petroclinoid ligaments | Not assessed | 8% bilaterally | | - | 15.6% |
| Lens | 0.9% and non-defined areas | Not assessed | | - | 0.7% |

Table 4.1 above illustrates the comparison with previous studies from different parts of the world demonstrating that our study assessed more areas of calcifications whereas some of the other studies concentrated on only a few calcifications. An example is the fourth study, conducted in Ethiopia, that only evaluated pineal and basal ganglia calcifications. The studies had different parameters including age, gender and ethnic predilection. The most common finding of all the studies is that most of the physiological calcifications prevalence tends to increase with age. Additionally, there was an association between males and increase in calcifications, as seen by the male to female ratio. All studies concluded that pineal and choroid plexus calcifications were the most commonly seen however, two studies (including ours) differed in that choroid plexus calcifications were more prevalent than pineal.

## 4.5. Current applications /recommendations

In our clinical setting, incidental physiological calcifications are generally not mentioned by the reporting radiologist. Reporting these may result in unnecessary confusion with referring clinicians who might not be aware of some areas of physiological calcifications. Knowledge of these areas is clearly of significance to avoid misdiagnosis. Awareness of particular trends in different age groups, gender and location improves the index of suspicion when criteria for these calcifications are not met. Unless the mentioning of a physiological calcification will make a difference in patient management, it is recommended that it should not be mentioned when reporting.

For example, since we have concluded that bilateral choroid plexus calcifications are the most commonly identified, these should not be mentioned but a young patient with calcifications in the lens should have an ophthalmologist referral, hence it would make sense to report this.

## 4.6. Limitations of the current study

Some of the scans were difficult to access on PACS. This was due to multiple factors including poor data capturing and power failures that caused the system to shut down and which sometimes resulted in loss of data. Poor data capturing of patient details was found to be worse after hours and this was the time where most patients presented with head injury. Our exclusion criteria included inadequate data and this was the most problematic aspect of data collection. This emphasises the importance of a well functioning system with adequate and competent staff for good patient data capturing to allow easier access.

That said, Chris Hani Baragwanath Academic Hospital has just recently acquired PACS and it is still a process of improvement with regard to staff training.

## 4.7. Future applications or future recommendations for research

Chris Hani Baragwanath Academic Hospital caters mostly for the black population of Gauteng and nearby provinces. The study population was therefore, predominantly patients of black ethnicity. An area of interest would be to conduct a study and take into

account the diverse races of South Africa to assess if there are differences within different racial groups. Consideration of a cross continental study would also yield interesting results. Conducting a study that includes a younger population group to evaluate incidence in younger patients and determine the age of earliest appearance of intracranial calcifications.

During the study it was realised that there may be difficulty interpreting tissue composition accurately on CT scan. This is due to multiple factors including artefacts. Without having HU, this would have been a very difficult task. A study on inter- and intra-observer variability in detecting intracranial calcifications especially in junior registrars would be interesting.

South Africa has a very high HIV infection prevalence and there is currently no clear association between HIV and physiological intracranial calcifications. It would be of interest have an understanding of the consequences of the infection, if any.
Another recommendation would be to conduct a study with a larger sample size and a more accurate and representative population to improve statistical and clinical significance.

## 5. Conclusion

Our overall finding was the high prevalence of incidental intracranial calcifications compared to all reviewed literature. The reason for our higher prevalence of incidental physiological calcifications is yet to be uncovered. The study concluded that the majority

of patients over the age of 14 had incidental intracranial calcifications with choroid plexus being significantly higher than all known areas, followed by pineal calcifications. Most reviewed literature is in agreement that the choroid plexus and pineal calcifications are the most frequently seen calcifications. However, most concluded that choroid plexus were second to pineal calcifications. Co-existence was a common factor in some of the studies including ours. The only other study with comparable findings was also in Africa. This has sparked interest, as the populations of these studies have ethnic similarities compared to the other studies. It raises a question as to whether ethnicity may result in possible differences in the prevalence of physiological calcifications. Presence of choroid plexus, pineal, dural, basal ganglia and vascular calcifications increased with increasing age. This finding was across the board with all reviewed literature. The lens had minimal incidence of calcifications with no physiological calcifications found in the pituitary. Pathological intracranial calcifications were rare and were predominantly calcified granulomas.

Despite having multiple studies on this topic, there are minimal identified associations of intracranial physiological calcifications with ethnicity and geographical regions. Our study results can be used to ascertain that in our setting certain calcifications are seen more than others and therefore have a high index of suspicion for pathology in atypical findings. This opens the door for more studies related to this topic. This may include topics around individual calcifications and their relationships with clinical, geographical or ethnic factors. This topic can be further expanded into relationship between the appearance, for example, shape, density and pattern of these calcifications and pathology.

**Appendix A: Ethics Clearance Certificate.**

**Appendix B: Readers tick sheet for patient data.**

# Appendix A: Ethics Clearance Certificate

M140120

HUMAN RESEARCH ETHICS COMMITTEE (MEDICAL)

CLEARANCE CERTIFICATE NO. M140120

| | |
|---|---|
| NAME: (Principal Investigator) | Promise N Koranteng |
| DEPARTMENT: | Department of Diagnostic Radiology<br>CH Baragwanath Academic Hospital |
| PROJECT TITLE: | The Prevalence of Incidental Physiological Intracranial Calcification in South African Adult Population |
| DATE CONSIDERED: | 31/01/2014 |
| DECISION: | Approved unconditionally |
| CONDITIONS: | |
| SUPERVISOR: | Dr Linda Hlabangana |

APPROVED BY: Professor PE Cleaton-Jones, Chairperson, HREC (Medical)

DATE OF APPROVAL: 21/05/2014

**This clearance certificate is valid for 5 years from date of approval. Extension may be applied for.**

DECLARATION OF INVESTIGATORS

To be completed in duplicate and **ONE COPY** returned to the Secretary in Room 10004, 10th floor, Senate House, University.

I/we fully understand the conditions under which I am/we are authorized to carry out the above-mentioned research and I/we undertake to ensure compliance with these conditions. Should any departure be contemplated, from the

PLEASE QUOTE THE PROTOCOL NUMBER IN ALL ENQUIRIES

## Appendix B: Readers tick sheet for patient data

| Physiological calcification | | | | | | | | | | | | | | Pathological calcifications | |
|---|---|---|---|---|---|---|---|---|---|---|---|---|---|---|---|
| Patient number | Date of birth | Age | Gender | Basal Ganglia | Choroid plexus | Pineal gland | Habenula | Arachnoid | Dura | Lens | Vascular | Petroclinoid ligaments | Pituitary | Yes | Description |
| Pt-001 | | | | | | | | | | | | | | | |
| Pt-002 | | | | | | | | | | | | | | | |
| Pt-003 | | | | | | | | | | | | | | | |
| Pt-004 | | | | | | | | | | | | | | | |
| Pt-005 | | | | | | | | | | | | | | | |
| Pt-006 | | | | | | | | | | | | | | | |
| Pt-007 | | | | | | | | | | | | | | | |
| Pt-008 | | | | | | | | | | | | | | | |
| Pt-009 | | | | | | | | | | | | | | | |

# 6. References


(1) Daghighi MH, Rezaei V, Zarrintan S, et al. Intracranial physiological calcifications in adults on computed tomography in Tabriz, Iran. Folia morphologica. 2007 May;66(2):115-9.

(2) Celzo FG, Venstermans C, De Belder F, et al. Brain stones revisited- between a rock and a hard place. Insights Imaging. 2013;4:625-35.

(3) Bushberg JT, Seibert AJ, Leidholdt Jr EM, et al. The essential physics of medical imaging. Third ed. Mitchell CW, editor. Philadelphia, USA: Lippincott Williams and Wilkins; 2012.

(4) Kiroglu Y, Calli C, N K, et al. Intracranial calcifications on CT. Diagnostic and interventional radiology. 2010 Dec;16(4):263-9.

(5) Harnsberger HR, Osborn AG, Ross JS, et al. Diagnostic and Surgical Imaging Anatomy: Brain, Head and Neck, Spine. First ed. Salt Lake City, Utah: Amirsys Inc.; 2006.

(6) Kim HS, Kim DM, Ju CI, et al. Intracranial calcification caused by a brain abscess : a rare cause of intracranial calcification. Journal of Korean Neurosurgical Society. 2013 Aug;54(2):148-50.

(7) Van As AD, Joubert J. Neurocysticercosis in 578 epileptic patients. SAMJ. 1991;80:327-8.

(8) Kasprowicz VO, Achkar JM, D W. The Tuberculosis and HIV Epidemic in South Africa and the KwaZulu Natal Research Institute for Tuberculosis and HIV. The Journal of Infectious Diseases. 2011;204:1099-101.

(9) Grech R, Grech S, Mizzi A. Intracranial calcifications. A pictorial review. The neuroradiology journal. 2012 Sep;25(4):427-51.

(10) Uduma FU, Pius F, Mathieu M. Computed tomographic pattern of physiological intracranial calcifications in a city in central Africa. Global journal of health science. 2012 Jan;4(1):184-91.

(11) Choplin RH, Boehme II JM, Maynard DC. PACS mini refresher course. Radiographics. 1992;12:127-9.

(12) Alves G, Cordensi I, Magno P, et al. Pineal gland and choroid plexus calcifications on CT: A retrospective study in a Brazilian subtropical city. The Internet Journal of Human Anatomy. 2013;2(1).

(13) Sedghizadeh PP, Nguyen M, Enciso R. Intracranial physiological calcifications evaluated with cone beam CT. Dento maxillo facial radiology. 2012 Dec;41(8):675-8.

(14) Adams AE. Basal ganglia calcification. Characteristics of CT scans and clinical findings. Neurosurgical review. 1980;3(3):201-3.

(15) Anvekar B. Intracranial calcifications. Solapur, Maharashtra, India: S P Institute of Neurosciences2011.

(16) de Weert TT, Cakir H, Rozie S, et al. Intracranial internal carotid artery calcifications: association with vascular risk factors and ischemic cerebrovascular disease. AJNR American journal of neuroradiology. 2009 Jan;30(1):177-84.

(17) Admassie D, Mekonnen A. Incidence of normal pineal and chroids plexus calcification on brain CT (computerized tomography) at Tikur Anbessa Teaching Hospital Addis Ababa, Ethiopia. Ethiopian medical journal. 2009 Jan;47(1):55-60.
(18) Kwak R, Takeuchi F, Ito S, et al. [Intracranial physiological calcification on computed tomography (Part 1): Calcification of the pineal region]. No to shinkei = Brain and nerve. 1988 Jun;40(6):569-74.
(19) Daniel WW. Biostatistics: A foundationfor analysis in the Health Sciences. 7th edition ed. New York: John Wiley and Sons.; 1999.
(20) Faul F, Erdfelder E, Lang A, et al. G*Power 3: A flexible statistical power analysis program for social, behavioural and biochemical sciences. Behaviour Research Method. . 2009:175-91.
(21) Inc SI. SAS Software, version 9.3 for Windows. version 9.3 for Windows ed. Cary, NC, USA2002-2010.
(22) Nicol A, Knowlton LM, Schuurman N, et al. Trauma Surveillance in Cape Town, South Africa: An Analysis of 9236 Consecutive Trauma Center Admissions. JAMA surgery. 2014 Jun;149(6):549-56.
(23) Osborn AG, Blaser SI, Salzman KL, et al. Diagnostic Imaging: Brain. Salt Lake City, Utah: Amirsys; 2004.