

https://dspace.org/

Outcomes of surgical repair of Tetralogy of Fallot in an African tertiary care centre with emphasis on post-operative pulmonary regurgitation

Ngwezi, Deliwe Precious

2012-01-17
http://hdl.handle.net/10539/11032

Downloaded from a DSpace repository. https://dspace.org/

1. INTRODUCTION

Tetralogy of Fallot (TOF) is one of the commonest forms of cyanotic congenital heart disease with a prevalence of 0,26 per 1000 live births. Significant advances have been made in the surgical repair of this defect with 90% of patients surviving to adulthood (1). The surgical techniques are varied depending on the complexity of the underlying anatomy. The surgical approach can be either a single stage repair or a two stage repair. The latter consists of an initial palliative procedure called a Blalock –Taussig shunt (BTS) or central shunt (Potts or Waterston shunt) followed by a complete repair at a later stage. The local definitions of the various repair techniques are as follows: a simple repair which includes closure of ventricular septal defect (VSD) and resection of infundibular muscle bundles with or without right ventricular outflow tract(RVOT) patch only (personal communication with Dr K Vanderdonck, Paediatric Cardiac Surgeon at the Charlotte Maxeke Johannesburg Academic Hospital (CMJAH)). If the patient has a hypoplastic pulmonary valve, a more complex type of repair is undertaken which consists of the above approach plus pulmonary valvotomy, or transannular patch (TAP) with or without a monocusp , or a conduit using a homograft or xenograft all of which may eventually result in various degrees of pulmonary regurgitation (PR).

Pulmonary regurgitation which is one of the commonest sequelae after surgical repair of TOF was for a long time thought to be well tolerated (1, 2). Over time, evidence has emerged that severe PR post repair of TOF has detrimental effects on the right ventricle (RV) and it is not the benign lesion it was thought to be (3-5). In the early post operative period children appear to tolerate severe PR very well. However, it does seem that a prolonged volume overload on the

RV caused by severe PR results in progressive deterioration of myocardial function, arrhythmias and risk of sudden cardiac death. The volume overload on the RV in turn results in the development of RV dilatation, tricuspid regurgitation and right atrial enlargement which has been shown to improve with pulmonary valve replacement (PVR)(4, 6).

The optimum timing for PVR is not yet certain especially in asymptomatic patients with severe PR(4, 6). The guidelines for PVR have been established, however these are still in evolution (6). Symptomatic patients who undergo a PVR procedure, experience marked improvement in their symptoms. In addition, it has also been noted that RV function assessed echocardiographically improves and cardiomegaly diagnosed on Chest X-Ray(CXR) reduces after treatment of the PR (6). Right ventricular dysfunction may persist if treatment is delayed and left too late (4, 6).

Palliative and corrective surgery for TOF has been offered at CMJAH for over three decades. Various surgical techniques have been employed over this period of time. To my knowledge, there has never been a study conducted to assess the outcomes of surgical repair of TOF with emphasis on PR at CMJAH. A search of the medical and other scientific literature through Pubmed, Google Scholar, Google, and Medline using the keywords “tetralogy of Fallot”, “repair of tetralogy of Fallot”, “outcomes”, “pulmonary regurgitation”, “sub-Saharan” and “African continent” was undertaken. The search revealed an extensive repository of data from the developed countries. There was no published data on this topic from the sub-Saharan or African continent, hence the undertaking of this research in order to document similar outcomes of patients undergoing surgery for TOF in a tertiary African centre for the first time.

The hypothesis for this research is as follows: “Patients undergoing repair of TOF with a TAP develop severe PR and symptoms 5-10 years after surgery, requiring re-operation to replace the pulmonary valve. Those having simple repair without reconstruction of the right ventricular outflow tract remain well after surgery and do not develop severe PR and symptoms”.

The aim of the study is to assess the outcomes of children who underwent complete repair of TOF at CMJAH with or without a right ventricular outflow conduit with emphasis on the development of severe PR and symptoms over time.

A literature survey follows in which a review of the historical aspects of TOF, epidemiology, genetics, embryology, anatomy, clinical features including diagnosis and history of surgical treatment is outlined. Subsequent chapters describe the methodology, results, discussion and future recommendations that arose from the study.

2. LITERATURE SURVEY

2.1 History of Tetralogy of Fallot

Tetralogy of Fallot is a worldwide known eponym which describes a cyanotic congenital heart malformation consisting of four anatomic abnormalities that are described below. Although it is named after Etienne-Louis Arthur Fallot, a University of Marseilles professor who published a 98 page article detailing the clinical and pathological findings in 1888, he was not the first to report on these cardiac pathologies now known as tetralogy of Fallot (7).

The first anatomic description of this malformation occurred as early as 1671 and is credited to the Danish anatomist Niels Stensen (7, 8). Other noteworthy investigators documented similar anatomic findings viz. Edward Sandifort (1777), William Hunter (1784), J.P Farre (1814), and Thomas Bevill Peacock (1864)(7).

In his original work published in 1888, Fallot gave credit to the previous authors who reported similar cardiac abnormalities. He used the term "tetralogie" in French as a descriptor (from the Greek "tetralogia"- a collection of four works), and classified the anatomical and clinical findings into four characteristics as follows: 1) pulmonary artery stenosis (PS) , 2) VSD, 3) rightward deviation of the aorta's origin and 4) right ventricular hypertrophy(RVH). Fallot went on to further diagnose the condition clinically which set him apart from the others (7).

The eponym "tetralogy of Fallot" was coined by Maude Abbott, the early 20th century paediatric cardiology founder in a 1924 article that classified congenital heart defects (7). Various authors including Maude Abbott have been credited for popularizing the eponym " tetralogy of Fallot"(7).

2.2 Epidemiology

Tetralogy of Fallot is one of the most common forms of cyanotic congenital heart disease. Studies conducted prior to the era of echocardiography, reported varying prevalence rates of tetralogy of Fallot (8). Echocardiography has impacted on the prevalence of TOF substantially as it has afforded an increase in the accurate diagnosis of cardiac disease. The overall prevalence of TOF from all studies ranges from 0,26 -0,48 per 1000 live births (9) .The true prevalence of TOF with PS, which is the focus of this study, is not usually defined in most studies because all forms of TOF are grouped together regardless of pulmonary valve (PV) anatomy i.e TOF with Pulmonary Atresia (PA) or Absent PV Syndrome (8).

The Baltimore-Washington Infant Study (BWIS) conducted between 1981-1982 is the most recent and possibly the most accurate study to assess the prevalence of the different subgroups of TOF. In this study the overall prevalence of TOF was 0,33 per 1000 live births, accounting for 6,8% of all forms of congenital heart disease. In particular, the prevalence of TOF with (PS) was 0,26 per 1000 live births and accounted for 5,4% of all lesions observed in the BWIS cohort(9).

2.3 Genetics of TOF with Pulmonary Stenosis

Environmental and genetic factors have been implicated in the development of congenital heart disease (CHD) which includes TOF with PS. There is a growing evidence of a complex interplay between the environment and genetic predisposition of the individual resulting in CHD (10). Several environmental teratogens have been recognised in the pathogenesis of TOF including maternal diabetes, phenylketonuria, retinoic acids for treatment of acne, trimethadione and alcohol(8). Genetic factors are also thought to contribute to the development

of TOF with PS. An increased recurrence rate has been observed in siblings and offspring of affected individuals and there are also reports of unique families with multiple affected members within and across generations. TOF was found in 11,9% of patients with chromosomal abnormalities in the BWIS. These included trisomy 21, trisomy 18, and trisomy 13 in decreasing order of frequency (8).

Other genetic syndromes that have been associated with TOF include 22q11 deletion syndrome previously known as DiGeorge/Velocardiofacial Syndrome (VCFS) and Allagile Syndrome associated with a deletion of chromosome 20p12 or the mutation of JAG 1 gene (10). The estimated 22q11 deletion frequency in TOF is 8-35% (10). The study of the non-syndromic genetic aetiology of TOF with PS has proved to be difficult because of the lack of large families with multiple affected members to be able to provide linkage analysis and cytogenetic clues as to the specific loci that may be involved. The link between the NKX2,5 gene and TOF in two patients (one with PS and one with PA) has been reported. This finding needs verification and if positively linked in other patients may provide the way to identify disease related genetic foci in patients with non-syndromic TOF and PS (8).

2.4 Embryologic Considerations of TOF

Three hypotheses have been advanced in attempt to elucidate the development of TOF with PS.

2.4.1 The malrotation and malseptation theory (8).

2.4.2 The hypoplasia and underdevelopment of the infundibulum (11).

2.4.3 Neural crest cells hypothesis (12).

2.4.1 The Malrotation and Malseptation Hypothesis

The embryologic precursors to the ventricular outflow tracts and great arteries are the bulbus cordis and truncus arteriosus respectively and these are collectively known as the conotruncus. The conotruncus in normal development is situated over the right ventricle. A complex process of rotation, septation, differential cell growth and death takes place. The anatomy seen in TOF is believed to result from incomplete rotation and faulty septation of the conotruncus. The truncal-bulbar ridges normally undergo spatial growth and rotation. Malrotation of these ridges results in misalignment of the outlet and trabecular septum and consequent straddling of the aorta over the malaligned VSD. The subpulmonic obstruction is created by abnormal anterior septation of the conotruncus by the bulbo-truncal ridges (8).

2.4.2 The Hypoplasia and Underdevelopment of the Infundibulum Hypothesis

Van Praagh (11) proposed a different concept in the development of TOF whereby only one abnormality results in the underdevelopment of the sub-pulmonary infundibulum as follows:

2.4.2.1 Pulmonary Outflow Tract Obstruction

The infundibulum is typically small and with time it hypertrophies, causing the crista supraventricularis to be deviated anteriorly, superiorly and leftward.

2.4.2.2 Ventricular Septal Defect (VSD)

The VSD forms as a result of failure of the crista supraventricularis to be carried in a posterior, inferior and rightward direction. The absence of this movement results in a space that is created above the ventricular septum and septal band otherwise known as the VSD.

2.4.2.3 Aortic Override

Aortic override in tetralogy of Fallot occurs in various degrees as a consequence of abnormal aortic-mitral relationship with the aortic valve being set rightward, anterior and superiorly.

2.4.3 Neural Crest Cells Hypothesis

Neural crest cells are a group of specialized ectodermal cells derived from the neural folds of the developing neural tube. They are capable of migrating to various regions of the developing embryo and thereby taking part in the formation of particular organs e.g central nervous system, endocrine and para-endocrine cells, pigment cell, connective tissues and the outflow tract of the heart. The cardiac neural crest migrates from the neural fold into the pharyngeal arches 3,4,6. The cells in the pharyngeal arches which are derived from the neural crest, provide support for the vascular endothelium of the aortic arch arteries and form the aortico-pulmonary septum. Experimental studies performed on chick embryos showed that ablation of the neural crest resulted in a variety of malformations of the heart and great vessels. These consist of outflow tract abnormalities namely persistent truncus arteriosus, TOF, and aortic arch abnormalities. It is believed that the abnormal migration of the neural crest cells in humans is evidenced by the manifestation of the phenotypic appearance of DiGeorge Syndrome with the associated cardiac abnormalities (12).

2.5 Anatomy In TOF

The anatomic findings in TOF as described previously consist of:

2.5.1 PS

2.5.2 Large non-restrictive peri-membranous VSD

2.5.3 Aortic Override

2.5.4 RVH

Pulmonic stenosis in TOF manifests mainly within the subpulmonic or infundibular septum, however, additional areas of obstruction can be found along the entire right ventricular outflow tract at valvar, supravalvar and branch pulmonary artery level (8).

2.6 Clinical Features And Diagnosis

The symptoms and signs in a typical case of TOF are very specific. A history of cyanosis is the outstanding feature. In some children cyanosis may only be noticeable when they cry and this may bring on a syncopal episode. A history of squatting on walking in older children is characteristic. Physical examination may reveal cyanosis, clubbing of fingers, toes, and plethoric conjunctivae. A systolic murmur which is of crescendo-decrescendo type usually audible along the 2nd or 3rd left intercostal space is a sign of pulmonary stenosis. The intensity of the murmur may vary depending on the degree of the stenosis, being shorter and softer if severe. The CXR characteristically shows oligaemic lung fields, and a normal sized heart which maybe boot-shaped. The ECG inevitably has features of right axis deviation (RAD), evidence of RVH and right atrial enlargement (RAE). Atypical cases with mild PS may not have all the specific features mentioned and may be difficult to differentiate from patients with a left to right shunt due to a VSD (13).

Echocardiography is an important diagnostic tool to confirm the diagnosis. Cardiac catheterization may be a necessary additional imaging modality to further define the anatomy in the more complex forms of TOF and it also provides percutaneous access to the heart in the case where intracardiac interventions may be required (8).

2.7 History Of Surgical Treatment

Prior to the advent of cardiac surgery for TOF, the families of affected children lived with the grim prospect of inevitable death before the end of the first decade of life. However, there have been a few cases recorded of individuals who reached adulthood with an unoperated TOF(14). The first inroads into the surgical management of TOF came in 1945 when Alfred Blalock, a surgeon and Helen Taussig a paediatric cardiologist brought hope to the families of children born with TOF through their ground-breaking innovation of a systemic –pulmonary artery shunt, called the Blalock-Taussig shunt (BTS). Sadly this great historic moment robbed an African-American experimental researcher known as Vivien Thomas, working in Dr Blalock's laboratory of a well deserved recognition as one of the contributors in the field of pediatric cardiology. He was instrumental in the actual creation of an experimental animal model of cyanosis followed by a second experiment to reverse the cyanotic state by crafting a shunt (15). The anastomoses of the subclavian artery to the pulmonary artery allowed blood to enter the pulmonary arteries from the systemic circulation and to bypass the PS which was the anatomical feature limiting pulmonary blood flow. As a result, the patient experienced improved oxygenation and reduction in cyanosis (7, 13,15).

Other innovative types of palliative shunts emerged later such as the Potts-Smith procedure in 1946 comprising an anastomosis between the left pulmonary artery and descending aorta (13).

Another invention was the Waterston –Cooley shunt created in 1962 which entailed an anastomosis between the ascending aorta and right pulmonary artery. From our own University of the Witwatersrand in 1961, a cardiothoracic surgeon by the name of Mr D Fuller performed a similar shunt from ascending aorta to right pulmonary artery, however the procedure was never published (Personal communication with Prof S Levin, Emeritus Professor of Paediatric Cardiology, University of the Witwatersrand). Both the Potts and Waterston shunts are no longer in use because they were in some cases complicated by pulmonary hypertension and pulmonary vascular obstructive disease as a consequence of overshunting. They are mentioned for historical purposes. One of the first attempts to repair TOF in1948 was done by Brock of England who performed an infundibulectomy on a patient with TOF in an attempt to increase pulmonary blood flow (16).

With the advent of cardio-pulmonary bypass, Walton C Lillehei and colleagues performed the first full correction of TOF on 31 August 1954 which was successful. The VSD was closed with a patch and the muscles in the infundibulum were excised to widen the outflow tract. The recognition that some cases of TOF are associated with severe underdevelopment or hypoplasia of the pulmonary valves led to an innovative concept in the mid 1950s that incorporated re-construction of a right ventricular outflow roof for these complex types of TOF. An incision extending below the pulmonary annulus or across the annulus to widen the RVOT is made, followed by reconstruction of the RVOT using an RVOT patch or TAP. This technique, inevitably results in various degrees of PR because of disruption of the pulmonary valve annulus and the pulmonary valve itself (2). The literature seems to suggest unequivocally that the right ventricular response to the volume overload resulting from severe PR is excellent provided that there are no co-existent residual stenostic lesions (2). Freedom

from operation to replace the pulmonary valve to treat the PR has been documented to be as long as 20 years (2).

More recent studies suggest that severe pulmonary regurgitation is not as benign as previously thought. The RV dilatation and tricuspid regurgitation that occurs, may be a substrate for malignant ventricular arrhythmias, sudden death and heart failure. A prolonged QRS duration on an electrocardiogram (ECG) in patients with severe PR can predict the possibility of malignant arrhythmias (17).

Various surgical methods have been devised over time in an attempt to minimize the degree of PR following a TAP to treat TOF with a hypoplastic pulmonary valve. One such operation is the implantation of a "monocusp" at the time of the TAP. A monocusp TAP is a functional single cusp pulmonary valve which may be constructed from alternative tissue sources such as homografts harvested from cadavers, bovine and porcine pericardial patches, autologous pericardial patches and synthetic materials such as Gore-Tex or polytetrafluorethylene (PTFE). Unfortunately, the advantage derived from reducing the severity of PR with this technique has only short term to mid-term, but no long term benefits (18). The monocusp has been found to maintain its structure and functionality for a very short period only. A better approach is the replacement of the pulmonary valve using a whole homograft conduit with the trileaflet PV left intact, or a xenograft valved conduit in older patients. These conduits however, cannot be inserted in young patients whose body dimensions limit the placement of adult size valves or conduits at the initial surgery.

Commercially available bioprosthetic valved conduits (xenografts) are constructed using porcine valves (the Hancock and Shelhigh bioprosthetic valve) or bovine jugular veins (the Contegra valve) (19). Although they last longer than the "monocusp TAP valve", both the homograft valved conduits and xenograft valved conduits eventually fail. There is both a short and long term risk of calcific degeneration of the functional parts resulting in stenosis and PR and may require replacement within 5 -10 years after insertion. Of the porcine xenografts, the Shelhigh bioprosthetic appears to have worst durability record, and many patients have required replacement as early as 2 years after insertion because of calcific degeneration (20). The Contegra graft has better durability comparable to the valved homograft conduit in the short term period, but because of their more recent use, the long term results are not known. Although homografts conduits have a history of early calcification and degeneration in young infants, they remain the gold standard because their durability qualities have been studied for a longer time and their shortcomings are well documented in this age group (19).

Despite advances in biological technology the perfect long lasting right ventricular outflow tract conduit has not been developed. Most of the existing commercially available conduits appear to fail within a short period of time due to rapid degeneration particularly in the younger patient. However, the overall survival of patients with TOF in the modern day era is excellent with as many as 90 -93 % reaching adulthood (1).

3 PATIENTS AND METHODS

3.1 Patients

A retrospective clinical audit of patient files with a diagnosis of TOF at CMJAH was conducted. The paediatric cardiology computer database established in 1994 was accessed for patient data. A computer generated list of patients seen for the first time from 01/01/1994 to 31/12/2003 with a diagnosis of TOF who underwent surgical repair at CMJAH and followed up to 31/12/2008 were retrieved from the database and their clinical files obtained from the Paediatric Cardiac clinic for data capturing. The conclusion of the search after 2003 and termination of data capturing after 2008 allowed for a 5 to 15 year (long term) follow-up.

An initial interrogation of the database revealed 176 patients with a diagnosis of TOF. Of these patients, 125 clinic files were located and 51 files were missing. A further 53 patient files were excluded because they did not meet the criteria of the classical description of TOF. Finally, only 72 patients met the inclusion criteria and were suitable for analysis. The inclusion and exclusion criteria were as follows:

3.1.1 Inclusion criteria: Patients undergoing surgery with the following diagnosis

3.1.1.1 Classical TOF described as: subvalvar/valvar/supravalvar PS with a VSD, aortic override and RVH.

3.1.1.2 Acyanotic TOF with the same description as classical TOF

3.1.2 Exclusion Criteria: Patients undergoing surgery with the following diagnosis (Not Classical TOF)

3.1.2.1 TOF with absent pulmonary valve syndrome

3.1.2.2 Endocardial cushion defect with pulmonary stenosis

3.1.2.3 Double outlet right ventricle with pulmonary stenosis

3.1.2.4 Double chamber right ventricle

3.1.2.5 Patients with surgery done elsewhere

3.1.2.6 First presentation in adulthood

3.1.2.7 Pulmonary atresia with VSD

Patient consent was not necessary because the study design incorporated a retrospective analysis of patient files. Ethics approval was obtained from the University of Witwatersrand Ethics Committee (Appendix A).

3.2. Methods

Three categories of data were extracted from each of the patient files. The first category was demographic data consisting of age at first visit, sex and ethnic group. The second category was operative data with the following descriptions: a palliative central shunt or a BTS, primary corrective surgery, initial palliative surgery followed by corrective surgery, age at palliation, age at corrective surgery, anatomic findings recorded in the surgical reports, surgical technique used, follow- up data and death. The third category of data collected was specific post-operative follow- up details detected clinically, on CXR, ECG, and echocardiography (ECHO).

The presence of cardiomegaly detected clinically by palpation and/ or on CXR was sought. ECG features that were recorded included the presence of arrhythmias, QRS duration greater than 180 milliseconds (ms) and heart block.

ECHO is the most accurate non-invasive means of detecting PR and its effects on the right heart. The following ECHO parameters were recorded: severity of PR using color flow Doppler mapping and pressure half time (P1/2t). The PR severity was graded from 1 to 4 using color flow Doppler (1 = no PR, 2= mild PR, 3= moderate PR or 4 =severe PR, [Appendix B]) (21). The assessment of PR using P1/2t was graded as follows: <100m/s = severe PR, and > 100m/s = mild to moderate PR (22). Thus severe PR was defined on echocardiographic grounds as grade 4 on color flow Doppler, together with a P1/2t of <100m/s. The presence and severity of PS and tricuspid regurgitation (TR) was also recorded. The severity grading used for both was 1 - 4. The grading for PS was: (1= no PS, 2= mild PS, 3= moderate PS, 4 = severe PS, [Appendix B]) (23). The severity of grading for TR was: (1= no TR, 2= mild TR, 3= moderate TR, 4 = severe TR, [Appendix B]) (24). The right ventricular (RV) size was recorded if documented in the ECHO report. The New York Heart Association (NYHA) functional class grading, from I –IV [Appendix C] was recorded if documented in the case notes of older children.

Three post operative periods within which data was collected were divided up as follows: the immediate post operative period (< 1 year); intermediate post operative period (1- 5 years) and long term period (>5 years).

3.2.1 Statistical Method

The data obtained was entered onto Excel spreadsheet and statistical analysis was done using a statistical software package STATA 10.0. Other descriptive statistics were done. Comparison between two groups was made using the Chi –square test and where applicable the Fisher's Exact test was used. A p value < 0.05 was considered to indicate a significant difference between patient groups.

4 RESULTS

4.1 Summary of database search

The database search is summarized in the flow diagram Figure 1.

FIGURE 1: SUMMARY OF DATABASE SEARCH

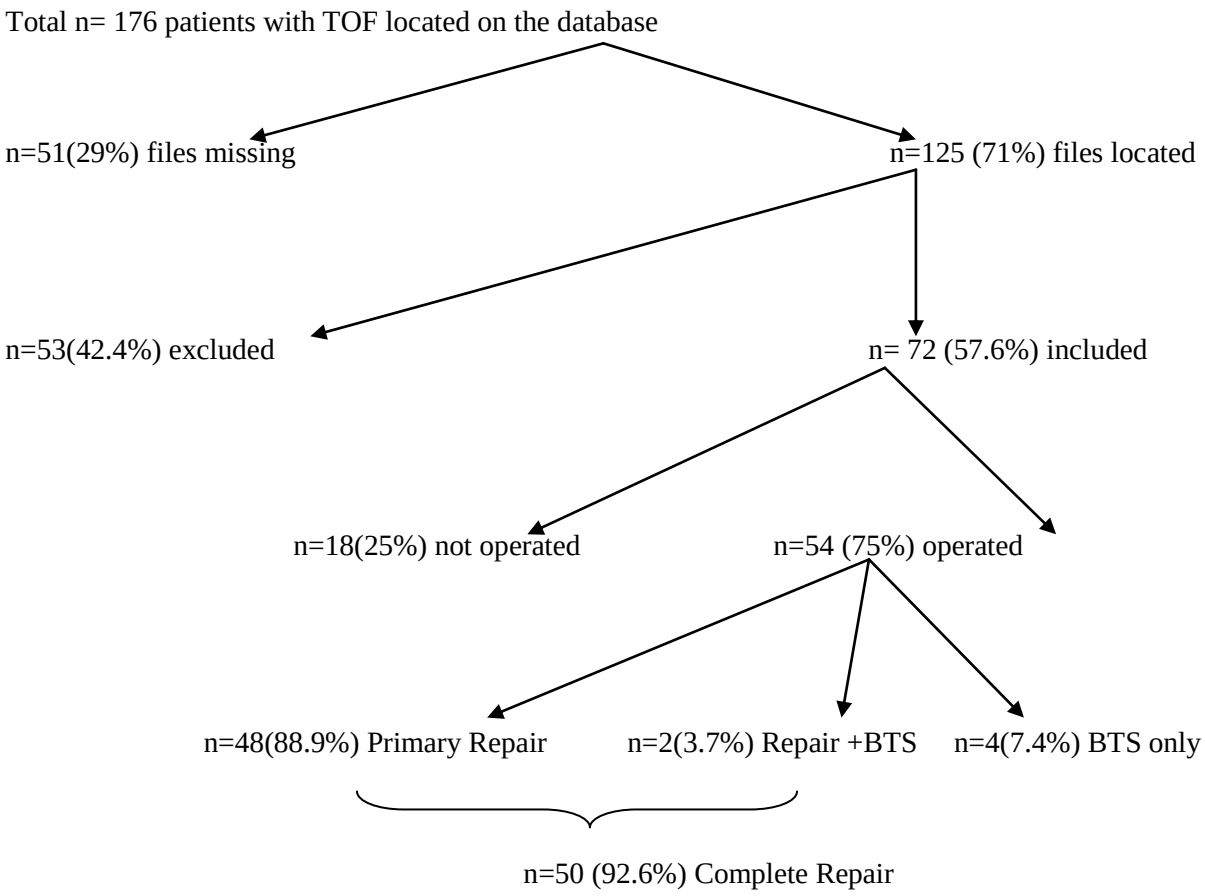

A total of 176 patients with a diagnosis of TOF were found on the database. Of these patients, only 125 files (71%) were located, and 51(29%) were not found. In the final audit, 72 files (58%) were suitable for analysis, whilst 53 (42%) did not fulfill the inclusion criteria. A total of 54 (75%) patients had surgery. Forty eight patients (88.9%) underwent a single stage repair,

2(3.7%) of whom had an initial palliative shunt and 4 (7.4%) patients had a palliative shunt as their only operation (Figure 1). Ultimately 50(92.6%) patients underwent complete repair of TOF.

4.2 Demographic and clinical data

Table 1: DEMOGRAPHIC AND CLINICAL DATA OF PATIENTS DIAGNOSED WITH TOF (n=72)

Variable	Number (n=72)	%	Median(25-75 percentile, months)	AV (months)	SD	RANGE(months)
SEX: Male	46	63.9				
Female	26	36.1				
RACE: Black	53	73.6				
White	8	11.1				
Indian	5	6.9				
Coloured	6	8.3				
AV Age First Visit			13(4-27)	25.41	35.26	0.03-177

% = Percentage; AV = Average; SD =Standard Deviation

A total of forty six males (63.9%) and twenty six females (36.1%) were diagnosed with TOF. The majority of patients were black (73.6%). The median age at first presentation was 13 months (range, 0.03-177 months). Twenty five percent of patients were below 4 months of age and 75% below 27 months at the first visit (Table1). Figure 2 illustrates an age related and frequency distribution of patients at the first visit. There is a total of 69 patients because 3 patients did not have ages documented in their files.

FIGURE 2: PATIENTS WITHIN THE VARIOUS AGE GROUPS AT FIRST PRESENTATION PRIOR TO SURGERY (n=69)

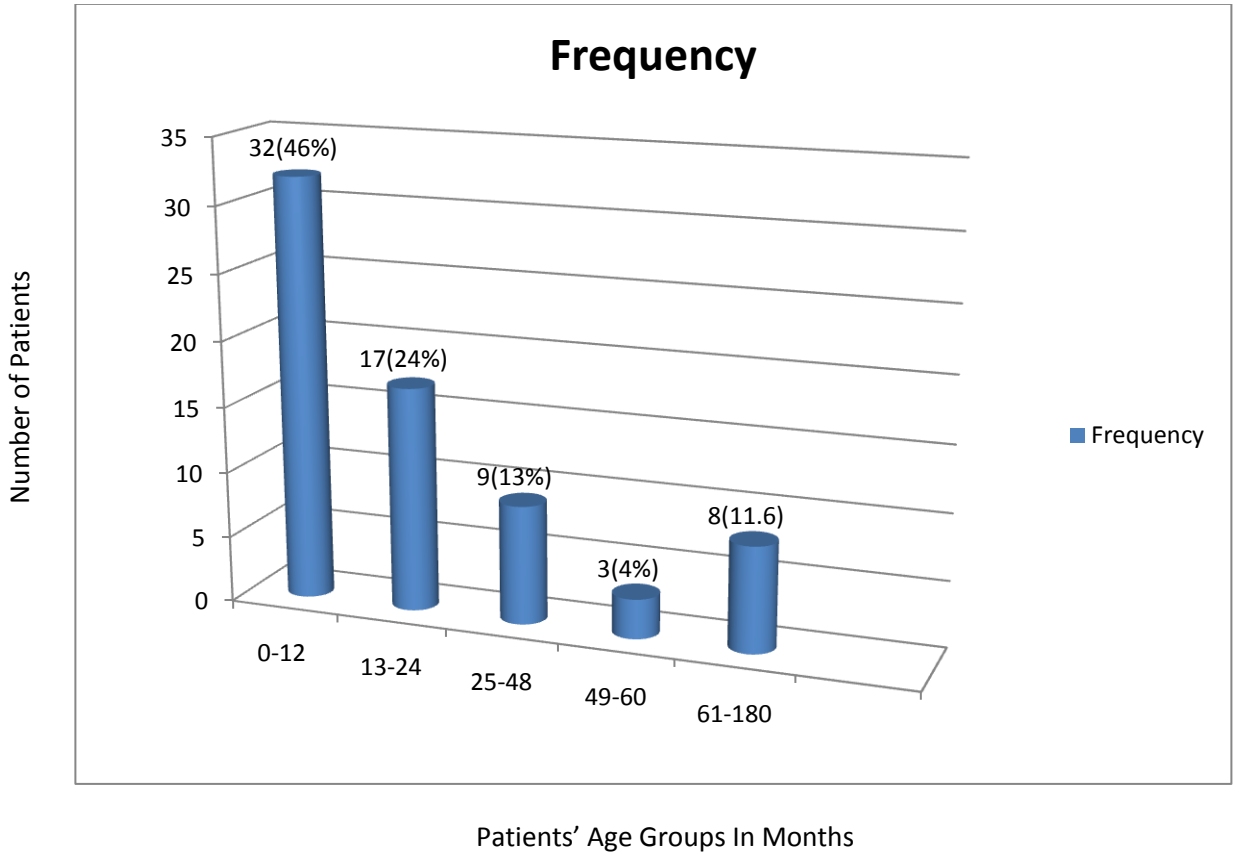

4.3 Demographic and clinical data on patients with corrective surgery

Table 2: DEMOGRAPHIC AND CLINICAL DATA OF PATIENTS WITH CORRECTIVE SURGERY FOR TOF (n=50)

Variable	Number (n=50)	%	Median(25-75 percentile, months)	AV (months)	SD	RANGE(months)
SEX: Male	29	58				
Female	21	42				
RACE: Black	37	74				
White	5	10				
Indian	4	8				
Coloured	4	8				
AV Age At Repair			39.5(20-68)	53.5	46.8	3-210
Av Age at Palliation			18(6-22)	15.8	10.3	1.5-29

% = Percentage; AV = Average; SD =Standard Deviation

A total of fifty patients underwent corrective surgery for TOF. Twenty nine patients (58%) were males and 21 (42%) were females. The median age at surgical repair was 39.5 months (range, 3-210 months). Twenty five percent of patients were below 20 months and 75% were below 68 months at time of repair (Table 2). Figure 3 illustrates the frequency of the various age groups undergoing repair for TOF.

FIGURE 3: PATIENTS WITHIN THE VARIOUS AGE GROUPS AT TIME OF REPAIR (n=50)

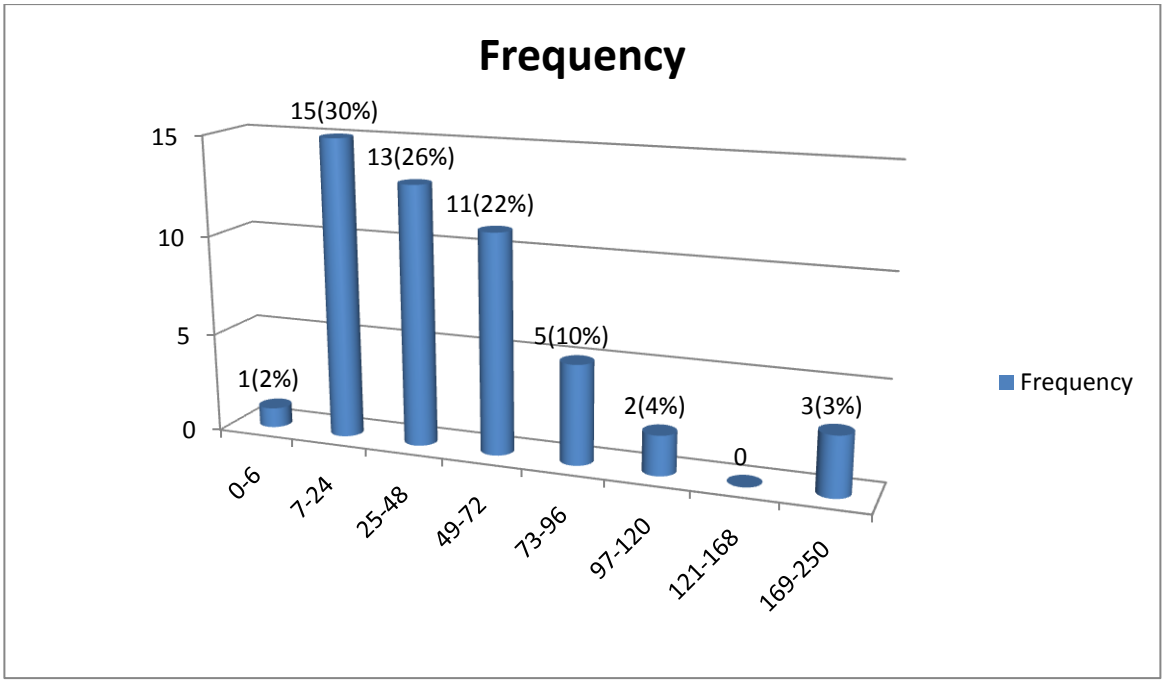

Patients' Age Groups In Months

TABLE 3: SUMMARY OF ANATOMIC FINDINGS AND REPAIR TECHNIQUE

Type of Repair	**Type of Anatomy**	**Total number =50 (%)**
MR+RVOT patch	Simple : Infundibular stenosis only	20(40%)
MR+ RVOT patch + Pulmonary Valvotomy	Complex: PV stenosis	10(20%)
MR+RVOT patch +TAP	Complex: Multilevel stenosis	7(14%)
MR+RVOT patch +TAP+Monocusp	Complex:Multilevel stenosis	8(16%)
Homograft	Complex:Multilevel stenosis	2(4%)
Xenograft	Complex: Multilevel stenosis	3(6%)

MR= muscle resection; RVOT= right ventricular outflow tract;

TAP= transannular patch

Twenty (40%) of the fifty patients undergoing complete repair had a simple surgical repair for a simple anatomy, and thirty (60%) were diagnosed to have complex anatomy with hypoplastic main pulmonary arteries for which various RVOT repair techniques were employed. The anatomic findings of the patients at surgery and the type of repair are presented in Table3.

The majority of patients with complex anatomy were females 16 (76.2%) and 5(23.8%) had simple anatomy. Fewer male patients had complex anatomy, numbering 14(45.3%), whereas a larger number 15(51.7%) presented with simple anatomy. There was a significant statistical difference between those patients presenting with simple anatomy and those with complex anatomy, p=0.047 (Table 4).

TABLE 4: CORRELATION OF ANATOMIC CLASSIFICATION AND SEX

Gender	**Simple Anatomy**	**Complex Anatomy**	**Total number**	**P-value**
Female	5(23.8%)	16(76.2%)	21	
Male	15(51.7%)	14(48.3%)	29	
Total number	20(40%)	30(60%)	50	p=0.047

4.4 Analysis of Post Operative PR

TABLE 5: COMPARISON OF POST OPERATIVE PR BETWEEN SIMPLE REPAIR AND TAP

	Simple Repair (original sample, n=20)		TAP (original sample, n=15)		
Time Intervals	Total n(%)	Severe PR n(%)	Total n(%)	Severe PR n (%)	p-value
< 1 year post op	9(64.3%)	0(0%)	5(35.7%)	2(40%)	p=0.110
1-5 years post op	11(73.3%)	1(9.1%)	4(26.7%)	1(25%)	p=0.476
>5 years post op	12(54.6%)	2(20%)	10(45.5%)	8(80%)	p=0.005

n= number; % =percentage; TAP =transannular patch; PR=pulmonary regurgitation

During the extraction of data from the clinical records it became apparent that a large amount of data was absent from the patient files. As a consequence, the use of pressure half time to

assess the severity of PR had to be abandoned. The only method of assessing PR using echocardiography which was consistently documented, was color Doppler flow imaging.

In the immediate post-op follow-up period, none of the patients who underwent a simple repair developed severe PR, while 2 patients who had a TAP for complex anatomy were found to have severe PR, p=0.110 (Table 5). One patient in the simple group and one in the TAP group developed severe PR in the intermediate period of follow-up, p= 0.476. In the long term follow-up period, 2(20%) patients with simple repair had progressed to severe PR, and 8 (80%) patients with TAP developed severe PR with a statistically significant result, p=0,005. Another observation which warrants attention is the minority of patients (n=2) who underwent simple repair and in the long term period (>5 years) developed severe PR. Both patients had infundibular muscle resection and a RVOT patch. It is likely that the RVOT patch technique used by the surgeon impinged on the pulmonary valve apparatus, thereby compromising the competence of the valve resulting in severe PR.

RV dilatation assessed echocardiographically was another parameter that was inconsistently documented within the patient records. The following data was extracted and partially analyzed: 10 patients who had TAP surgery were noted to develop RV dilatation on echocardiography over time. Two (18.2%) patients were noted to have RV dilatation in the immediate post-operative period, 3(27.3%) in the intermediate period and 5 (45.5%) patients were in the long term period of follow-up. Although this result could not be tested for statistical power, the conclusion reached by inference is that as time progresses, TAP repair with its associated PR, becomes a risk factor for RVdilatation.

4.5 Analysis of subgroup repaired with conduits

A total of five out of thirty patients (16.7%) in the complex anatomy category had conduits inserted at the initial surgery. Two patients (40%) had homografts and 3 (60%) had xenografts inserted. Post operative data was available for the 2 patients in the homograft group one of whom is mentally retarded from cerebral palsy (CP) and only 1 out of 3 patients in the xenograft group. In the immediate post operative period, both patients with the homograft had mild PS and no PR documented on ECHO. During the intermediate period, 1 patient developed moderate PR and remained with mild PS. The patient with CP did not have ECHO data captured during the intermediate period. Observation in the long term period showed the CP patient to have progressed to moderate PS and mild PR following calcific degenerative changes that occurred within the homograft conduit. The other patient had no ECHO data captured during the long term period and is lost to follow up. The patient with a xenograft developed mild PR and PS during the immediate post operative period. The degree of PR and PS were both recorded as moderate in the intermediate post operative period and both PR and PS became severe in the long term period. This patient was eventually lost to follow up, but was documented to be asymptomatic at the last visit.

4.6 Electrocardiogram

Electrocardiographical (ECG) data that was intended to be analyzed was also poorly documented in the case files hence only ECG analysis during the immediate post operative period will be provided. Nine out of 41(22%) patients with ECG's had a right bundle branch

block pattern (RBBB) which implies injury to the right bundle branch of the conducting system at the time of surgery. Three (7.3%) patients had a bifascicular block pattern. Eight out of 41(19.5%) patients had a QRS duration noted in the case files. None of the patients had a prolonged QRS duration greater than 180ms, which has been associated with a higher risk for malignant arrhythmias. Two out of the 8(25%) patients had severe PR and neither were shown to have prolongation of the QRS interval. Only the patient with CP showed evidence of ventricular ectopics (VE) on ECG. This patient, however, had moderate PS and mild PR documented on ECHO in the long term period.

TABLE 6 SUMMARY OF CLINICAL FEATURES OF THE SYMPTOMATIC PATIENTS WITH SEVERE PR

Pt	Initial Repair	Age at Initial Repair	Symptoms	Echo Findings	Redo Op	Age at Redo	Interval to Redo Op
1	TAP	18 mo	Chest pain, Effort intolerance	Severe PR/Dilated RV	PVR 25/03/2009	15 years	13 years
2	TAP	17 mo	Effort Intolerance	Severe PR/Dilated RV+Dysfunction Residual RPA stenosis	PVR 27/06/2005	8 years	6 years
3	Pulm Valvotomy + MR	21 mo	Chest Pain	Severe PR/Dilated RV	Awaiting Redo	-	-

MR=muscle resection; PR=pulmonary regurgitation; PVR=pulmonary valve replacement; RV=right ventricle; RPA =right pulmonary artery; TAP=transannular patch; mo=months; Pulm=Pulmonary; Pt =Patient

4.7 Effort Tolerance

Again there was a paucity of data regarding the level of effort tolerance and New York Heart Association (NYHA) functional class during post operative follow-up in the majority of the files. Only the immediate and long term post operative period will be commented upon.

Three out of 41(7.3%) patients were documented to be in NYHA functional class I during the immediate post operative period as reported by the parents. All three patients had undergone TAP repair for complex anatomy. One out of 3 patients had severe PR documented during this immediate post-operative period. All 3 patients had developed severe PR in the long term period and only 2 out of 3 were charted as NYHA functional class I. None of the patients were subjected to objective exercise testing.

Symptomatic Patients

Three out of the 50(6%) patients who underwent correction developed symptoms, 2(66.7%) of whom underwent TAP surgery and 1(33.3%) had a pulmonary valvotomy (Table 6). The main symptoms recorded were effort intolerance and chest pain. Two out of the 15(13.3%) patients who previously had a TAP repair, have required pulmonary valve replacement (PVR) 6 to 13 years after initial surgery (Patients 1 and 2, Table 6). Patient 3, who had a previous pulmonary valvotomy is awaiting a PVR.

4.8 Follow Up of Patients

Figure 4: Follow Up of Surgically Corrected Patients

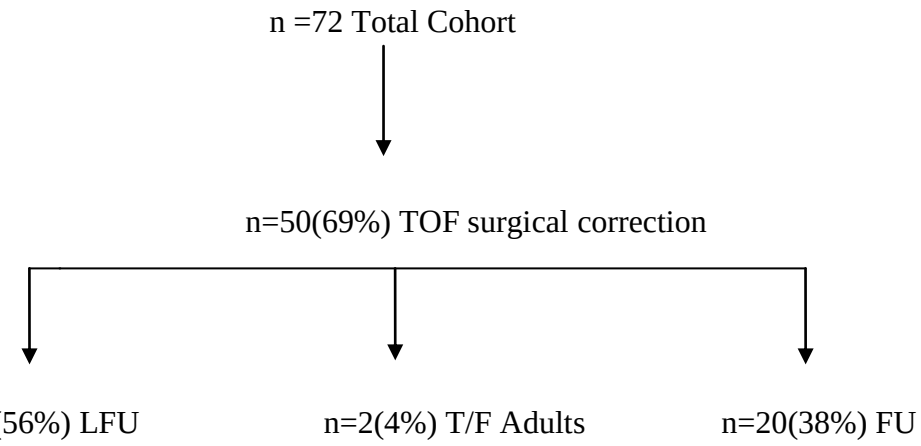

n=number; TOF =Tetralogy of Fallot; LFU= Lost To Follow up; FU= Follow Up;

T/F=Transferred To

A total of 28 out of 50(56%) surgically corrected patients were lost to follow up (LFU), 2(4%) patients were transferred to adult cardiology clinic and 20(40%) are still being followed up at the outpatient cardiac clinic as shown in figure 4.

Figure 5: Follow Up of Uncorrected Patients

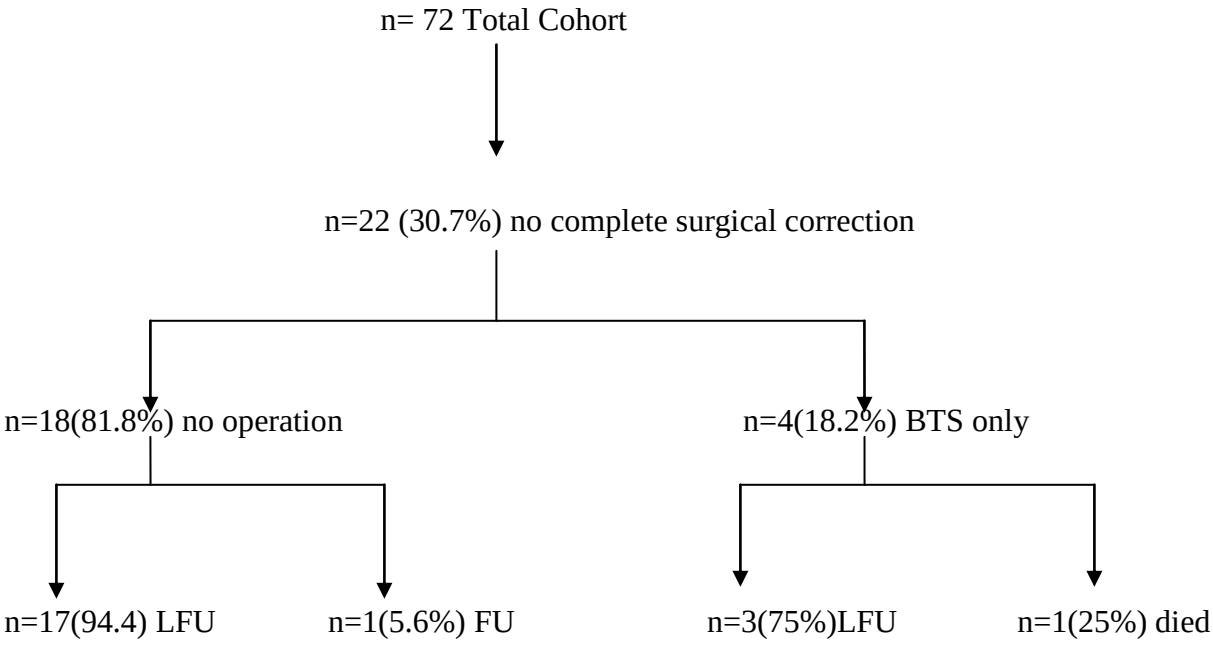

n=number; LFU =Lost To Follow Up; FU= Follow Up

A total of 22(30.7%) patients did not have full correction of TOF. Eighteen out of 22(81.8%) patients had no operation at all and 4(18.2%) had a BTS as their only operation. Seventeen (94.4%) of the unoperated patients and 3(75%) of the palliated ones were lost to follow up as illustrated in figure 5.

TABLE 7: COMPARISON OF PATIENTS LOST TO FOLLOW UP IN RELATION TO TYPE OF REPAIR

Type of repair	Anatomy	LFU n (%)	P value
MR+RVOT patch	Simple anatomy	13(46.4%)	
TAP	Complex anatomy	6	
Homograft	Complex anatomy	1 15(53.6%)	
Xenograft	Complex anatomy	1	
Pulm Valvotomy	Complex anatomy	5	
TAP+monocusp	Complex anatomy	2	
Total		28(56%)	p=0.629

MR=muscle resection; RVOT=right ventricular outflow tract; TAP=transannular patch;

Pulm =pulmonary; LFU=Lost To Follow Up

Table 7 shows a comparison of the simple and complex anatomy repair groups in relation to lost follow up. Thirteen patients (46.4%) in the simple anatomy group and 15 (53.6%) in the complex group were lost to follow up. There was no statistical significance regarding the numbers lost to follow up between the two groups, p=0.629.

4.9 Mortality

Five (7%) patients out of 72 who were diagnosed to have TOF died. Three patients died without receiving any surgery. One out of 50 (2%) surgically corrected patients, with complex anatomy died during the post operative period following insertion of a xenograft, and 1 out of 4(25%) patients who received a BTS died at home whilst awaiting corrective surgery.

5 DISCUSSION

This current study is the first to attempt to assess the surgical outcomes of patients with TOF in the sub-Saharan region. The greatest difficulty experienced, which mitigates against a comprehensive assessment of these patients, is the paucity of data documented which does not permit proper statistical analysis and comparisons with other centres. Nevertheless, sufficient information was obtained to show that the demographic, and clinical features of patients developing severe PR are similar to those reported elsewhere in more resource replete countries (1, 5). The marked male predominance in patients with TOF is consistent with previous studies (5,26, 27).The majority of the patients with TOF analyzed 53(74%) out of 72, were black which reflects the change in racial demographics in a hospital that was previously predominantly white prior to 1994, before the change in political dispensation. The patient records that were included in the study belong to the post 1994 landmark era that heralded the change in racial mix of the patients presenting for treatment to the CMJAH.

In South Africa and sub-Saharan Africa, many patients present at an advanced stage of their disease, especially amongst the previously disadvantaged black population who have poor access to proper medical care especially in remote areas. Consequently many children with congenital heart defects living in poorly resourced communities are likely to die undiagnosed. Nevertheless, the median age (13months) at first presentation and median age (39.5months) at surgery compares favourably to other studies (1, 27). The youngest patient to have corrective surgery was 3 months old, while the oldest was 17 years old. The majority of the patients at our centre undergo primary repair during infancy and early childhood. This finding is consistent with the experience of developed countries (2). The major determinant of a

successful post operative outcome of younger patients with TOF, has been the improvement in surgical skills (3, 25, 26). Unfortunately, the skills in primary repair of TOF in the neonatal period are highly specialized and have not yet been developed enough at our centre to be able to offer good outcomes for neonates that are provided in other centres where resources are plentiful (25).

The evolution in the surgical techniques has progressed from the creation of a palliative systemic to pulmonary artery shunt devised by Drs Blalock and Taussig, to the first successful repair of TOF almost 10 years later (2,13,15). The early convention of surgical treatment of patients with TOF involved an initial BTS in small babies followed by corrective surgery when the patient was older. There is a tendency in more advanced centers in the modern era to undertake early corrective repair of TOF irrespective of age, despite the contention by some surgeons that a staged repair with an early systemic to pulmonary artery shunt may have superior outcomes (25). The surgical convention followed by our institution is to place a palliative BTS in neonates or older patients with uncontrolled hypercyanotic spells followed by corrective surgery later on. Six of the study patients had a palliative BTS at a median age 18 months (1.5-29 months), two of whom proceeded to eventual corrective surgery. The indication for palliation in all patients was uncontrolled hypercyanotic spells. There was no operative mortality for patients undergoing shunt surgery. One patient who had a BTS died at home while waiting for corrective surgery. No patient belonging to the study cohort received a central shunt such as the one described by Waterston and Cooley, which has been abandoned in most centres because of the risk of overshunting and the danger of patients developing pulmonary

vascular disease. The decision to choose a BTS for patients instead of other palliative techniques reflects a shift in the use of more reliable and safer surgical techniques over time.

The majority of patients (60%) in this study were found to have complex anatomy at the time of operation, similar to other studies (1, 5) requiring various forms of complex repairs that incorporated a TAP or conduit insertion. The remaining 40% underwent simple repairs for less complex TOF anatomy. In contrast Kirklin JK et al (27) differed in their findings, with the majority (66%) of their patients undergoing a simple repair and the remainder, 31% having a complex repair in the form of a TAP. The disparity exists because the authors of this study included pulmonary valvotomy as part of a simple TOF repair, whereas our surgeons grouped the need for a pulmonary valvotomy under complex repair of TOF.

An interesting observation was the finding of a female predominance amongst the patients needing a complex repair, which to the best of my knowledge has not been unequivocally proven by other researchers. This fact suggests that although more males with TOF present to our institution, more females have complex anatomy. However this finding must be interpreted with caution in view of the small sample. It could just be a statistical aberration.

Pulmonary regurgitation, which is a frequent complication following repair of TOF has recently been proven unequivocally to be detrimental to the RV, often leading to the need for PVR (3, 4, 27, 28). The commonest surgical procedure during TOF repair resulting in severe

PR is a TAP. A surprising finding was the development of severe PR in 2 patients who underwent a simple repair (infundibular muscle resection and RVOT patch) more than 5 years post surgery (Table 5). Both patients were asymptomatic at their last follow-up. The mechanism for the evolution of PR in those two patients has been attributed to an aggressive infundibulectomy with subsequent formation of RVOT aneurysms which resulted in akinetic regions and poor forward flow (4, 6). Despite the small numbers, this study has corroborated many of the findings reported in previous studies mentioned above, that PR and RV dilatation in the immediate post operative period does increase in severity over time after TAP and in some cases also following simple repairs. It can therefore be said that pulmonary regurgitation is a late consequence of all repair types of TOF and is not specific to TAP. Consequently the need for a PVR after TOF repair is not related to the type of repair undertaken (5).

The effects of severe PR on the RV have been reported in an experimental model mimicking repaired TOF using two month old piglets (29). Evidence of right ventricular modeling, significant fibrosis, myocyte hypertrophy and a prolonged QRS duration secondary to pressure-volume overload was noted as early as four months after the surgery (29). Some patients undergo a form of beneficial myocardial adaptation with the onset of severe PR, and in some instances patients have survived more than 20 years after surgery before needing PVR (2,4, 26). The fact that the RV is capable of adapting to increased volume for prolonged periods, has been well demonstrated in patients with isolated congenital pulmonary valve incompetence who undergo myocardial adaptation and compensate for up to forty years before the myocardial coping mechanisms fail due to the ongoing severe PR (27).

The combination of PR and residual stenotic lesions seems to lessen the period of adaptation (27) such as occurred in patient 2 (Table 6), who had residual right pulmonary artery stenosis and severe PR post TAP. This patient required a PVR at eight years of age following an interval of six years from the initial operation. In contrast, patient 1(Table 6) who was documented to have severe PR without associated PS, experienced a longer period of thirteen years following a TAP repair before needing a PVR, after which his reduced effort tolerance symptoms and functional status improved dramatically.

Many studies (26) on post-operative exercise testing in patients with TOF report excellent subjective exercise tolerance, however more objective exercise testing reveals less than normal capacity even during the period of successful adaptation in patients post-TAP repair (27). Although no formal exercise testing was performed on the study patients, 3 patients who had TAP repair, between the ages 18 to 60 months were documented to have been asked about their effort tolerance through their parents and recorded in a New York Heart Association functional class format. One out of 3 patients had severe PR and reported NYHA class 1 symptoms in the immediate post op period. All three patients had severe PR in the long term period (>5years) and were still in NYHA class1. This indirectly supports the observation that PR is well tolerated after repair of TOF using a TAP during childhood.

The optimum timing for PVR is still uncertain especially in the asymptomatic patients (4, 6). There is universal agreement that the presence of symptoms due to PR is an indication for PVR (6). The recent awareness that possible irreversible changes may occur within the RV in the presence of severe PR has spurred on investigators to encourage early re-operation in these

patients before RV failure occurs (4, 5). In addition, the surgical procedure for PVR carries a low peri-operative risk and a low mortality of 1-4% (4, 6). The concern, however, is the longevity of the prostheses which is limited, and may result in the need for recurrent re-operations to replace the pulmonary valve several times during the patient's life time.

The durability of RVOT prosthesis in 3 out of 5 study patients who had valved conduits inserted during their initial repair was noted. The two patients who had homografts inserted, developed over time a combination of mild to moderate PS and PR. Neither patient progressed to severe PR. One patient was lost to follow up and the other patient with cerebral palsy has evidence of calcific degeneration on echocardiogram 10 years after surgery but remains asymptomatic. The patient continues to be followed up. Only one patient who had a xenograft inserted was found to have post operative echo data. Mild PS and PR was documented in the immediate post op period that eventually progressed to severe PS and PR in the long term period. Unfortunately this patient was also lost to follow up, but was noted to be asymptomatic at the last clinic visit. Although the overall durability of most RVOT prosthesis is generally limited to 5 -10 years at the most (18, 19), none of the study patients with valved conduits including the patients lost to follow-up has had re-operation. These patients had a minimum follow-up of 1 year to 10 years at the most post surgery.

Despite the improved outcome following repair of TOF (1, 2, 26), other complications such as arrhythmias remain a life threatening cause of morbidity and mortality (1, 17). Sudden cardiac death has been attributed to sustained ventricular arrhythmias in 6% of patients after repair of TOF (1, 26). Complete heart block and sick sinus sinus syndrome have also been implicated in

sudden cardiac death post-operatively (26). RV dilatation and the stretch that occurs with severe PR has been implicated and is thought to cause slowed interventricular conduction which creates a mechano-electrical substrate for re-entry circuits predisposing to sustained ventricular tachycardia (4, 17). A prolonged QRS duration of ≥ 180 ms has been shown to be a sensitive predictor of life threatening ventricular arrhythmias and has also been correlated with marked RV dilatation (17). In this study, 9 out of 41 patients who had ECG's recorded post operatively including the two patients who underwent PVR, did not have a prolonged QRS duration. Two patients out of 9 patients with ECG's were diagnosed to have severe PR and neither were shown to have prolonged QRS duration. One patient was found to have ventricular ectopics following TOF repair. Three patients had a bifascicular block (Left Anterior Hemiblock + a Right Bundle Branch Block pattern), an observation which is almost universally present in 9-15% of patients who have had TOF repair through a right ventriculotomy and may be less frequently be accompanied by a left posterior hemiblock. The implication of this finding has not been explained (6).

The most plausible explanation for the poor follow up of the study patients is two-fold. Firstly, it is likely that the patients feel symptomatically better after surgery and therefore do not feel compelled to return for routine check-ups until problems re-surface. Secondly, it may be that socio-economic constraints hinder compliance with follow up hospital visits by patients originating from rural parts of South Africa and neighboring countries. A study in China, which has been classified as a developing economy similar to South Africa, has similarly attributed poor follow up in their cohort of patients to financial constraints (30). There was no statistical

difference between the complex and simple repair groups regarding follow up in the study cohort (Table7).

Overall mortality for repair of TOF has declined drastically since the early surgical era from 40% in 1954 (2) to 2% by the end of the twentieth century (31). The long term survival of 90-93% for patients with repaired TOF closely approximates that of the normal population (1). It is encouraging that our centre, from a developing continent, achieved a peri-operative mortality of 2% following the repair of fifty patients with TOF. This finding demonstrates the excellent skills and experience of our surgeons in repairing this defect and their commendable post-operative management of these patients despite enormous economical and infrastructural constraints. Longer term survival of patients undergoing surgery for TOF was regarded as beyond the scope of the study and therefore was not included.

6 LIMITATIONS

Charlotte Maxeke Johannesburg Academic Hospital is one of the three tertiary hospitals under the auspices of the University of the Witwatersrand and the only hospital offering cardio-thoracic surgery for children and adults within the Southern Gauteng region. It serves a mixed, although predominantly black population since the introduction of a new political dispensation in 1994. Many of the white patients previously served by the hospital have been lost to follow up within the private sector.

This study, by nature of it being a retrospective clinical audit, has suffered immensely from a lack of relevant data in the clinical notes charted in the patient files. Consequently most of the data sought could not be recorded, analyzed and tested for statistical significance. An attempt was made to provide a longitudinal post-operative follow up study of the development of pulmonary regurgitation in patients undergoing repair of TOF, and its effects on the RV using several modalities including echocardiography. All echo reports were extracted for each patient for analysis, the rationale being an attempt at avoiding selection bias. However, there were many inconsistencies in the frequency and indications for doing echocardiographical studies post surgery which in the end did lead to a form of selection bias.

Furthermore, the echocardiograms were performed by various clinicians and a trained clinical technologist which resulted in the poor validation of the reports for inter- and intra- observer reproducibility, which may also have introduced an element of bias.

Although relevant information was sparse because of the poor documentation, there was enough data to make conclusions that were similar to other centres outside of Africa.

7. CONCLUSIONS AND RECOMMENDATIONS

Surgical repair for TOF has brought hope to children and families affected by this anomaly. However the notion that it is corrected and cured is a fallacy irrespective of the surgical method employed. Pulmonary regurgitation remains a worrying complication even for the patients who undergo simple repair, a finding which has surprisingly refuted a portion of the hypothesis in this study.

Severe pulmonary regurgitation is undoubtedly a sequel of the transannular patch technique with or without a monocusp and it is generally well tolerated during childhood with the exception of few cases. Right ventricular outflow conduits eventually degenerate resulting in pulmonary stenosis and or pulmonary regurgitation. These patients will eventually need a PVR and only in exceptional cases before 5 – 10 years post operatively. Fortunately the majority remain asymptomatic for more than 10 years. This assertion corroborates the hypothesis in this study.

Quantitative assessment of the degrees of severity of PR and RV function are crucial and require meticulous interrogation by clinical examination, chest x-ray, ECG, echocardiogram, cardiac magnetic resonance imaging (CMRI), angiography and objective exercise testing. Together these various modalities will guide and inform decision making on which patients to be sent for PVR at the appropriate time.

Despite the excellent outcome with regards to mortality and survival for patients with repaired TOF, the reality of sudden death secondary to lethal ventricular arrhythmias continues to rear its ugly head. Therefore all patients irrespective of the surgical technique used to repair the defect, require vigilant lifelong follow up with particular focus on PR and rhythm disturbances.

The post-operative follow up of all patients at the outpatient department requires a compulsory and standardized policy with regards clinical notes, investigations and documentation of these results in the files. There is a need for objective exercise testing to determine functional capacity for children post surgery. Although exercise testing is an inexpensive tool requiring appropriate equipment suited for children, it would offer invaluable information.

Ideally, the management of these patients require a multi-disciplinary team with additional members not currently available at our institution such as a social worker, child psychologist, physiotherapist, occupational therapist, spiritual support, a nurse to assist with parent and patient counseling and the importance of follow up and lastly administrative support. A team approach should address all the needs of the patients and their families and place less pressure on the few clinicians currently attempting to meet all these needs.

Lastly, there is a need for a large prospective study to include the other two tertiary hospitals attached to the University of the Witwatersrand, to systematically document the effects of PR following the repair of TOF on right ventricular function using advanced echo techniques and cardiac MRI. A South African registry of patients undergoing surgery is a necessity.