

https://dspace.org/

Difficulties in distinguishing silicosis and pulmonary tuberculosis in silicaexposed gold miners A Report of four cases

Botembetume Maboso; Jim te Water Naude; David Rees; Hillel Goodman; Rodney Ehrlich

WILEY-BLACKWELL
https://hdl.handle.net/10539/39808
WOS

Downloaded from a DSpace repository. https://dspace.org/

Check for updates

Received: 10 October 2022 | Revised: 25 December 2022 | Accepted: 16 January 2023

DOI: 10.1002/ajim.23460

CASE REPORT

AMERICAN JOURNAL OF INDUSTRIAL MEDICINE WILEY

Difficulties in distinguishing silicosis and pulmonary tuberculosis in silica-exposed gold miners: A report of four cases

Botembetume Maboso MD, DOH[1] |
Jim te Water Naude MBChB, MPhil (MCH), FCPHM[2] |
David Rees MBBCH, DOH, MSC(Med), PhD[3] |
Hillel Goodman MBChB, MPraxMed, MFGP, MRCR, FFRad(D)[4] |
Rodney Ehrlich MBChB, DOH, FCPHM(SA)(Occ Med), PhD[1]

[1]Division of Occupational Medicine, School of Public Health and Family Medicine, University of Cape Town, Rondebosch, South Africa

[2]Diagnostic Medicine, Cape Town, South Africa

[3]School of Public Health, University of the Witwatersrand, Johannesburg, South Africa

[4]Retired

Correspondence
Botembetume Maboso, MD, DOH, Division of Occupational Medicine, School of Public Health and Family Medicine, University of Cape Town, Rondebosch, South Africa.
Email: botembetume@gmail.com

Abstract

Silicosis and tuberculosis (TB) are both global health concerns, with high prevalence among miners from the South African gold mines. Although knowledge has accumulated about these two conditions as distinct diseases since the early 20th century, and despite progress in technology with multiple diagnostic tools and treatment options available for TB, the challenge of distinguishing and therefore efficiently managing these two conditions in this population remains as current as it was 100 years ago. To illustrate the diagnostic and health service problems of distinguishing TB and silicosis clinically and radiologically in former gold miners from the South African mines living in resource-poor areas, we discuss four cases reviewed for this report by a panel of experts. For each case, occupational history, past and current medical history, physical examination, radiological and laboratory findings are described. Common themes are: (1) poor agreement between radiological and clinical presentation; (2) poor agreement between radiology findings and detection of active TB on sputum Xpert MTB/RIF testing; and (3) difficulty in distinguishing the clinical and radiological presentations of silicosis and tuberculosis. Possible consequences at the population level are undertreatment or overtreatment of TB, and underdiagnosis or overdiagnosis of silicosis. There is a need for training of practitioners who are screening or attending to former gold miners in the clinical and radiological features of combined disease, using a curated database of miners' chest X-ray images. Investment in protocols for management of both acute and chronic silicotuberculosis in ex-miners is needed, as is clinical, epidemiologic, and operations research.

KEYWORDS
chest radiology, gold miners, silicosis, silicotuberculosis, South Africa, tuberculosis

This is an open access article under the terms of the Creative Commons Attribution-NonCommercial-NoDerivs License, which permits use and distribution in any medium, provided the original work is properly cited, the use is non-commercial and no modifications or adaptations are made.
© 2023 The Authors. *American Journal of Industrial Medicine* Published by Wiley Periodicals LLC.

1 | INTRODUCTION

Silicosis and tuberculosis (TB) singularly and in combination are global health concerns.[1,2] Southern Africa is one of the regions highly affected by both diseases in mining populations. Gold miners in particular are exposed to hazardous concentrations of respirable crystalline silica which may cause respiratory, renal and auto-immune disease.[3] Among these is susceptibility to pulmonary TB, heightened by exposure to silica with or without radiological silicosis, even after exposure to silica dust has ended.[4,5] Owing to this and other factors associated with migrant labor and congregate settings, mining is an amplifier of TB in communities in sub-Saharan Africa.[6,7]

Very high prevalences of silicosis and TB in ex-goldminer populations in South Africa and living across its borders have been recorded in recent decades.[8–10] In a recent study of ex-miners in Lesotho, which is the source of this report, prevalences found were: silicosis 42%, chest X-ray (CXR) suggestive of TB 60.9% and active TB 6.2%.[10] Silicosis and TB in miners exposed to airborne respiratory hazards, singly or combined, have been compensable occupational diseases since the early 20th century under South African legislation.[11] The diagnosis of TB whether active disease or post TB CXR abnormality is therefore of both public health and occupational health importance.

Knowledge about silicosis and TB as distinct diseases in gold miners has accumulated since the early twentieth century.[12–15] However, despite progress in technology and the multiple diagnostic tools and treatment options for TB that have been developed, the challenge of distinguishing and therefore efficiently managing these two conditions in this population remains as current as it was three quarters of a century ago.[12,16–19] While computed tomography (CT) scanning is able to identify features of silicosis not visible on the plain CXR and has a role to play in distinguishing old/healed TB from active TB and TB from silicosis,[20] this technology is generally not available in low resource settings.

The focus of this report is therefore on plain CXR. The objective is to discuss cases chosen specifically to illustrate the major diagnostic problems occurring during clinical and radiological assessment of silicosis and TB in this population of ex-miners, rather than as novel or unusual presentations. The cases were drawn from Lesotho, a low income country bordering on South Africa. The country has a population of 2.2 million,[21] and suffers the world's highest annual TB incidence of 650 per 100,000.[1]

2 | MATERIALS AND METHODS

This study analyzed information collected at an Occupational Health Service Centre (OHSC) in the town of Mafeteng as part of the TB in the Mining Sector in Southern Africa (TIMS) programme.[22] B. M. served as medical officer at this clinic. Invitations to miners who had worked in the South African mining industry to attend screening were extended throughout Lesotho by means of public gatherings, public media, word of mouth, and via civil society organizations. The miners were invited to visit one of the two Service Centres in Lesotho for screening for TB and silicosis. The screening protocol for all attendees included history, physical examination, postero-anterior digital CXR, sputum Xpert MTB/RIF test (a nucleic acid amplification test produced by Cepheid), spirometry and pulse oximetry (Aquarius G91025, Aquarius Electronics) at rest. All attendees were offered these investigations irrespective of symptoms. Spirometry was performed according to American Thoracic Society/European Respiratory Society criteria[23] using European Community of Coal and Steel (ECCS) reference values × 0.9.[24] Approximately 2700 ex-gold miners were examined.

The Centre at which miners were examined was program specific. It was therefore unable to investigate complex cases to a precise diagnosis through CT or bronchoscopy, for example. Its primary role was screening for active TB, with referral to district hospitals where necessary. A secondary objective was screening for compensable disease, which includes silicosis, old/healed TB and silicotuberculosis that meet statutory criteria under South Africa's Occupational Diseases in Mines and Works Act (ODMWA).[25] Attendees were therefore aware of the possibility of compensation for occupational lung disease. For all those with suspected occupational disease, a claim was submitted to the Medical Bureau for Occupational Diseases (MBOD) in Johannesburg, the certifying agency.

Selection of the cases for this report was made by B. M. in consultation with R. E., D. R., J. T. W. N., and H. G. For each case, the medical assessment is described, including occupational history, past and current medical history, physical examination, radiological and laboratory findings. Only spirometric values as a percent of predicted were available from the secondary database compiled for research purposes. For reasons of infection control, those known or suspected with active TB did not undergo spirometry. For purposes of this report, the CXRs and case histories obtained at the Centre visits were reviewed by B. M., three occupational medicine specialists, R. E., D. R., J. T. W. N. and a radiologist H. G., with extensive combined experience in reading CXRs of gold miners (the "panel"). As the Centre did not have pulmonology facilities, and no formal responses were received from district hospitals regarding referrals to them, each case report is based on the primary assessment, taking the CXR and occupational and medical history into account.

In this report, silicotuberculosis is defined as a combination of silicosis and TB, whether the latter is active or old/healed disease or both. Silicosis is defined as abnormalities on CXR that are consistent with the ILO Classification profusion 1/1 or above or with progressive massive fibrosis (PMF).[26] Radiological TB is defined as any abnormality suggestive of active or old/healed TB.

Permission to analyse and publish clinical data was provided by the Wits Health Consortium-TIMS project. Ethical clearance was obtained from the National Health Research Ethics Committee of Lesotho (ID: 142-2018), and the University of Cape Town Human Research Ethics Committee (HERC REF 699/2020). As the choice of the cases was made retrospectively from a secondary database, the requirement for individual consent was waived.

10970274, 2023, 4, Downloaded from https://onlinelibrary.wiley.com/doi/10.1002/ajim.23460 by South African Medical Research, Wiley Online Library on [08/02/2024]. See the Terms and Conditions (https://onlinelibrary.wiley.com/terms-and-conditions) on Wiley Online Library for rules of use; OA articles are governed by the applicable Creative Commons License

TABLE 1 Summary of occupational and medical history and current clinical status.

	Case 1	Case 2	Case 3	Case 4
Age (years)	61	67	73	67
Length of mining service (years)	21	35	8	40
Interval from mining work to consultation/CXR (years)	18	7	7	9
Episodes of past TB treatment	4	1	0	2
HIV status	Negative	Positive	Negative	Negative
Symptom status at clinic visit	Denied any symptoms	Chronic productive cough, progressive shortness of breath	Denied any symptoms	Acute exacerbation of chronic productive cough, respiratory distress
TB treatment status at clinic visit (Xpert MTB/RIF test status)	On treatment based on CXR features (negative)	On TB treatment based on CXR features and symptoms (negative)	No treatment (negative)	No treatment (negative)
Blood oxygen saturation %[a]	94	93	97	88
Panel assessment	Silico-tuberculosis[b]	Silico-tuberculosis	Silico-tuberculosis	Tuberculosis

Abbreviation: CXR, chest X-ray.

[a]Normal ≥ 95%

[b]See text for definition.

3 | CASE DESCRIPTIONS

Table 1 provides a summary of the occupational and medical features of the four cases.

3.1 | Case 1

This was a 61 year-old man, former smoker and HIV positive on antiretroviral therapy, who had worked in gold mines from 1978 to 1999 (21 years) as a rock drill operator. When he visited the Centre in 2017, he had already been treated four times for pulmonary TB and was undergoing a fifth course of TB treatment. This current treatment was initiated on the basis of CXR findings and chronic productive cough (recorded in his medical booklet), as the Xpert MTB/RIF sputum test was negative. At his visit, he had no physical complaints, did not look physically ill and was afebrile, but had a slightly reduced oxygen saturation of 94% in room air (normal value ≥95%).

The attendee's medical booklet had previous TB treatments documented, which indicated that the first TB episode was associated with a positive acid-fast bacilli (AFB) sputum smear test. The only evidence of the second and third TB treatments was his TB directly observed treatment cards, which did not document whether the decision to treat was on bacteriological grounds. The fourth and fifth treatments were based on persistent cough with a non-improved X-ray, as recorded in the medical booklet.

The CXR taken on the day of the visit to the Centre (Figure 1) shows extensive fibrosis of the left lung with volume loss and compensatory hyperinflation of the right lung. Extensive pleural thickening of the left hemithorax is present, as are cystic changes, areas of calcification, and features suggestive of bronchiectasis.

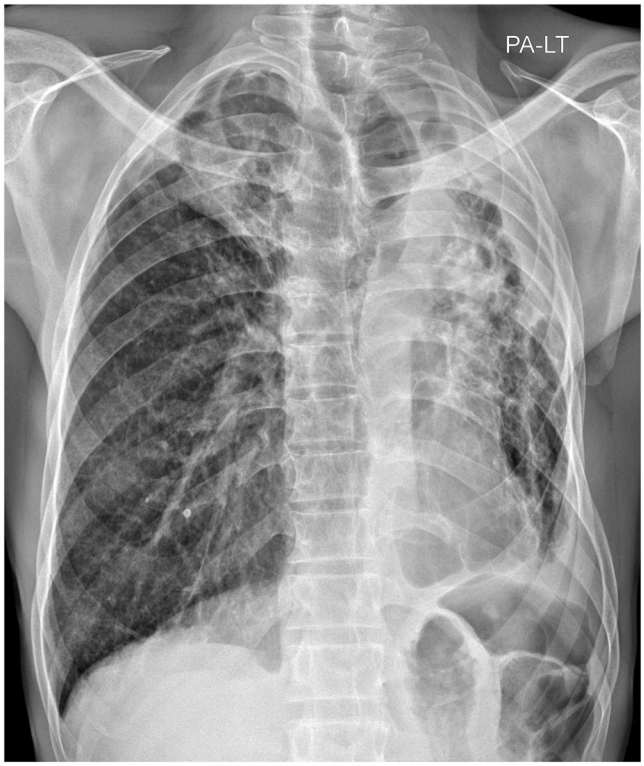

FIGURE 1 Chest X-ray (from 2017) of a 61 year-old ex-gold miner with 21 years of underground gold mining, HIV positive, and on his fifth episode of treatment for TB.

The right lung shows uniform opacities of about 2–3 mm diameter in the upper part of the middle zone (ILO Classification profusion q/q 1/1).

The panel assessed this CXR image as silicotuberculosis. Although the panel could not recognize any signs of active TB, it

10970274, 2023, 4, Downloaded from https://onlinelibrary.wiley.com/doi/10.1002/ajim.23460 by South African Medical Research, Wiley Online Library on [08/02/2024]. See the Terms and Conditions (https://onlinelibrary.wiley.com/terms-and-conditions) on Wiley Online Library for rules of use; OA articles are governed by the applicable Creative Commons License

noted that it was not possible to exclude active TB on radiological grounds alone. Given that the attendee was already undergoing TB treatment and that monitoring of treatment was not in the scope of the Centre, the patient was referred back to his treating facility.

3.2 | Case 2

This was a 67 year old man, former smoker and HIV negative, who had worked in gold mines from 1976 to 2011 (35 years) as a winch operator. He had been treated for pulmonary TB in 2008. In January 2018 when he visited the Centre, he was on TB treatment initiated a week earlier based reportedly on a history of persistent productive cough and abnormal CXR. Xpert MTB/RIF sputum test at the time of diagnosis was negative. At his visit he reported a chronic productive cough with progressive shortness of breath. He did not appear physically ill and was apyrexial, although with an abnormal oxygen saturation of 93% in room air.

In October 2019, the same individual visited the Centre again for follow up. Symptoms persisted and physical examination were unchanged. His CXR images are shown in Figure 2A,B.

Both CXRs show bilateral, multiple nodules of q size, mostly in the upper and middle zones, with extensive fibrotic changes noted bilaterally. Cystic and peribronchiolar changes, pleural thickening and diffuse loss of bronchovascular markings are also identifiable. Cavities are noted in the upper zones bilaterally in Figure 2A. The image taken after 12 months of treatment reveals reduction in thickness of the wall of the right upper lobe cavity and generally less opacification in the lungs (Figure 2B). These changes were interpreted as a positive response to treatment. The extent of technical difference between the two images was examined but considered a less likely interpretation. Although lung hyperinflation was noted in both CXRs, forced expiratory volume in one second and forced vital capacity as a percentage of predicted (measured only at the second visit) were >80%. The panel's assessment was silicotuberculosis, including both old/healed and active TB.

3.3 | Case 3

This was a 73 year old man, former smoker and HIV negative, who had worked in one gold mine as a general underground miner from 1992 to 2000 (8 years). When he visited the Centre in 2017, he had no medical complaint and denied any cough or shortness of breath, and gave no history of TB. Physical examination revealed no abnormality of note, with oxygen saturation normal (97%) in room air. His sputum Xpert MTB/RIF test was negative.

Surprisingly in view of his lack of symptoms, his CXR (Figure 3) showed marked volume loss of the left lung with extensive pleural thickening with calcification. This was read as consistent with old healed TB, with other causes not definitively excluded. Uniform rounded opacities read as ILO q/r 2/2 were noted in the right upper and mid zone. The panel's assessment was silicotuberculosis.

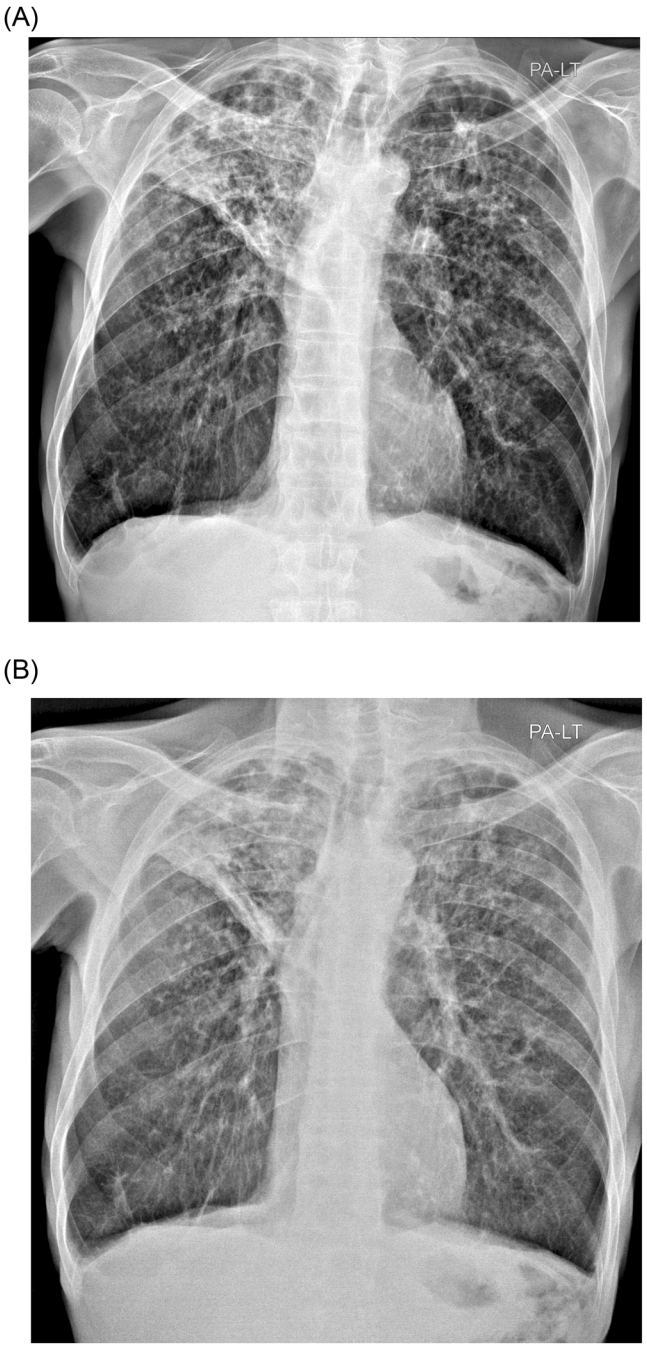

FIGURE 2 (A), (B) Chest X-rays of a 67 year-old ex-gold miner with 35 years of underground gold mining, obtained in January 2018 (on the right) and October 2019 (on the left).

3.4 | Case 4

This was a 67 year old man, former smoker and HIV negative, who had worked in underground gold mines from 1968 to 2008 (40 years) as a rock drill operator, winch operator and loader operator. When he visited the Centre in 2017, he complained of acute exacerbation of a chronic productive cough and longstanding progressive shortness of breath. Other recent clinical features were chest pain, blood-stained sputum, decreased appetite and intermittent fever. He was on

10970274, 2023, 4, Downloaded from https://onlinelibrary.wiley.com/doi/10.1002/ajim.23460 by South African Medical Research, Wiley Online Library on [08/02/2024]. See the Terms and Conditions (https://onlinelibrary.wiley.com/terms-and-conditions) on Wiley Online Library for rules of use; OA articles are governed by the applicable Creative Commons License

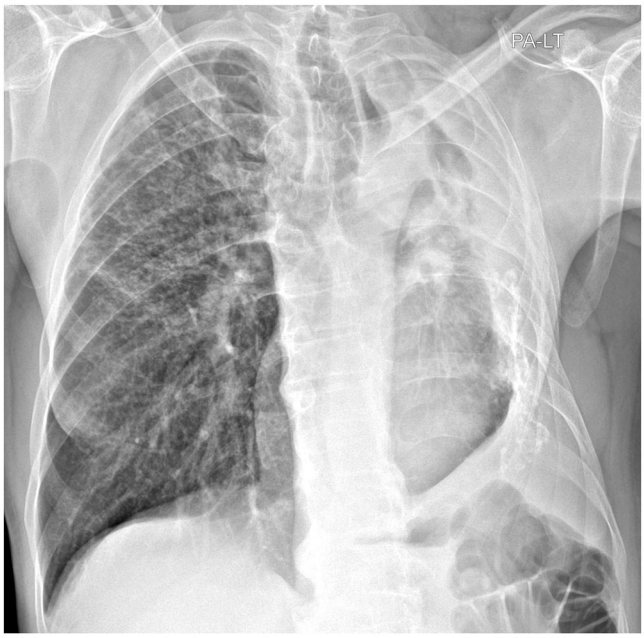

FIGURE 3 CXR (from 2017) of a 73-year-old ex-gold miner with 8 years of underground gold mining.

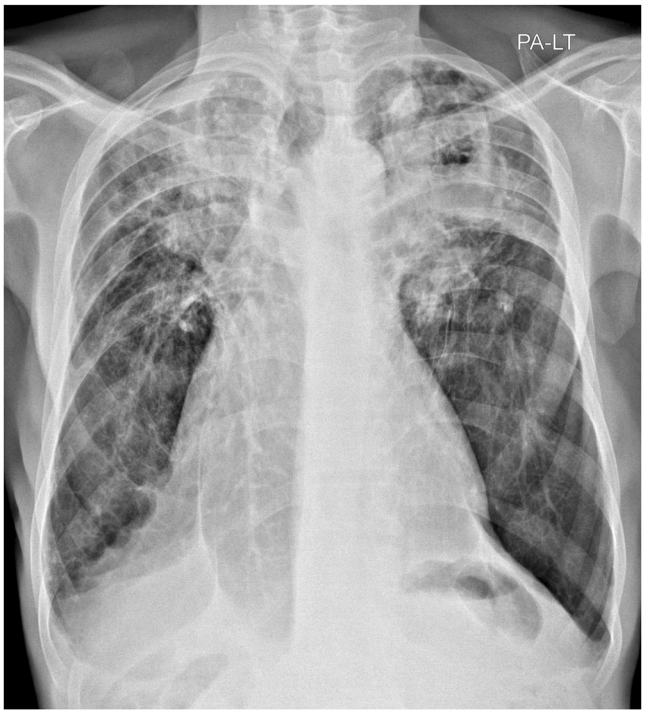

FIGURE 4 Chest X-ray (from 2017), of a 67 year-old ex-gold miner with 40 years of underground gold mining.

treatment for obstructive lung disease, which he described as "asthma," initiated 4 months earlier. He had a history of past pulmonary TB treatment in 1996 and 2002.

Physical examination revealed an ill-looking patient with reduced oxygen saturation (88%) in room air. He was orthopneic, with tachypnoea and tachycardia, hepatomegaly with raised jugular venous pressure and bilateral pitting pedal edema, consistent with cor pulmonale. Xpert MTB/RIF sputum tests performed on two different occasions were negative.

The apical zones of the CXR in Figure 4 below showed patchy areas of confluent opacification and sparse nodulation varying in size and shape, cystic change, an apical pleural cap on the right, and a rightward deviation of the trachea indicating volume loss. An enlarged right heart silhouette was also noted. The panel's assessment was that the radiological abnormalities were not consistent with silicosis, neither in respect of nodular profusion (read as ILO 0/0) nor of progressive massive fibrosis (PMF). Accordingly their radiological assessment was TB, with cor pulmonale. This finding is dealt with further in the Discussion.

The patient was referred as an emergency to the district hospital for high-level care, but died 2 days later. Under South Africa's statutory compensation legislation, and with consent of the next of kin, the heart and lungs were removed and transported to a central pathology laboratory in Johannesburg. Macroscopic examination of the organs at the time of removal by author (B.M.) revealed an area of firm, blackened tissue in the upper zones with diffuse small blackened nodules predominantly in the upper lobes with extension into the lower lobes. Myocardial hypertrophy was also noted. No histology report could be retrieved from Johannesburg. However, it transpired that the miner had previously received maximum compensation allowed under the Act for "second degree" occupational disease.

4 | DISCUSSION

Over 84 years ago, Taylor and Alexander[12] reported on the diagnostic problem arising from radiological overlap between silicosis and TB. The difficulty in radiologically distinguishing TB from silicosis is therefore longstanding. There are features described in the literature which guide the distinction.[16–20,27] Trachea in the midline, nodules of uniform size and distribution and regular shape favor silicosis. Consolidation, adenopathy, cystic disease/cavitation, asymmetric nodules of various size and shape, clustering of nodules, irregular masses, parenchymal distortion and pleural effusion favor TB. Emphysema, massive fibrosis and adenopathy may accompany either disease.

Features which might distinguish active TB disease from old/healed TB include adenopathy, non-thin walled cavities, ill-defined opacities ("soft infiltrates"), patchy consolidation, diffuse miliary pattern and pleural effusion. CXR changes of recent origin should also be taken as a marker of possible active TB.[18,19] However, given the wide-ranging radiological manifestations of silicosis, old/healed TB and active TB disease, these three conditions may display considerable overlap. TB may mimic silicosis, particularly when nodular, miliary or involving confluent fibrosis; or, alternatively, mask silicosis.

10970274, 2023, 4, Downloaded from https://onlinelibrary.wiley.com/doi/10.1002/ajim.23460 by South African Medical Research, Wiley Online Library on [08/02/2024]. See the Terms and Conditions (https://onlinelibrary.wiley.com/terms-and-conditions) on Wiley Online Library for rules of use; OA articles are governed by the applicable Creative Commons License

Against this background, clinicians involved in the diagnosis of occupational lung disease in miners, typically in low resource settings such as Lesotho, need to understand the diagnostic uncertainty and settle on appropriate management and treatment protocols. Clinical and health service issues arising from each of the cases are considered below.

4.1 | Case 1: Recurrent TB, HIV infection

Gold miners suffer high prevalences of both HIV infection[9,10] and latent TB infection—89% in one study[28]—making them susceptible to TB recurrence, both reinfection and reactivation. HIV infection is a strong risk factor for recurrent TB due to reinfection, studied mainly in the congregate settings of migrant labour and mining.[29] Although recurrent TB among former miners has been poorly studied because of loss to follow-up, ex-miners have a number of risk factors contributing to lifelong risk recurrence—high community infection rates,[1] silicosis, alone and synergistically in combination with HIV,[4,30] and post TB lung scarring.[31] Even without silicosis, accumulated silica lung load may confer a lifelong vulnerability to impairment of the lung's defences against Mycobacterium TB.[32,33]

Another feature of Case 1 was recurrent TB treatment with apparently negative bacteriological tests in four of five courses of treatment. Active TB in HIV positive individuals poses diagnostic difficulties due to atypical clinical and CXR presentations. and negative TB bacteriology associated with paucibacillary TB.[34] Given these considerations and that practitioners have to maintain a low threshold for investigation for TB in ex-miners, it is understandable that empirical treatment for TB in this population is common. However, the fact that in Case 1 the ex-miner had silicosis and had been treated empirically on four occasions raises the question of overtreatment.

Since distinguishing nodular TB from silicosis may be particularly difficult,[18,19] the corollary of the above is potential under or overdiagnosis of silicosis. Underdiagnosis is more likely where an occupational history is not taken or the examiner is unfamiliar with mining work or with the range of radiological features of silicosis. Overdiagnosis of silicosis is also a possibility in nodular presentations of TB.[18,35]

4.2 | Case 2: Active TB superimposed on chronic silicotuberculosis

Sputum Xpert MTB/RIF has been shown to be capable of high sensitivity against culture, with sensitivity lower where the sputum smear is negative or the individual is HIV positive.[36] However its sensitivity in the presence of chronic (prior) silicotuberculosis has not to our knowledge been determined. As with Case 1, the clinician is faced with the problem of excluding active TB given a negative Xpert MTB/RIF test, nonspecific respiratory symptoms and a CXR showing extensive abnormalities consistent with silicosis and old-healed TB. In this case, the apparent regression of cavities with treatment was taken as supporting a diagnosis of active TB and empirical treatment.

The extent and pace of radiological changes in post TB lung have been sparsely studied.[36] As it is well established that silicosis can progress in the absence of silica exposure,[37,38] it follows that silicotuberculosis may show radiological progression— in nodular fibrosis, coalescence and mass formation - in the absence of active TB. Cavities suggestive of active TB need to be distinguished from the cystic or cavitatory appearance that may accompany post-TB fibrosis ("fibrocystic" or "fibrocavitatory").[27] Radiological progression of silicotuberculosis other than due to newly confirmed active TB is thus a poorly characterized phenomenon, especially since in South Africa miners with combined disease are required to leave the industry and are generally lost to follow-up.

4.3 | Case 3: No symptoms, negative Xpert MTB/RIF test, no history of TB treatment, but with silicotuberculosis on CXR

The reporting by individuals with active TB or fairly advanced silicosis of minimal or no respiratory symptoms is well established in the literature.[39,40] However, apart from habituation to chronic low grade symptoms, the phenomenon in the presence of the severe combined lung disease is difficult to explain.

The absence of a TB history presents a similar puzzle. Given the high susceptibility of ex-goldminers to TB and the negative sputum test, it has become practice to call this "old" "healed," "inactive" or "prior" TB. Different explanations present themselves for the absence of a TB history. It is possible that some ex-miners cannot recall their TB treatment. Alternatively the diagnosis may have been missed by reliance on sputum smear testing, with its limited sensitivity for culture positive TB. Low grade or "indolent" phenotypes of active TB may not have elicited TB testing.[18,39] However, it remains surprising that TB disease that causes the extensive lung destruction as seen in this case would go unnoticed or remain asymptomatic. These phenomena warrant further research.

4.4 | Case 4: Extensive fibrosis, previous TB and cor pulmonale

The panel regarded all the radiological changes seen in Case 4 as consistent with old TB, on a number of grounds. TB fibrosis usually produces asymmetrical changes and spreads out from the hilar areas of the lung, as seen in Figure 4. These features are typically coarser than those of PMF and include destructive changes, cavities and distortion of the normal lung anatomy as well as nodules of varying size and shape.

In the absence of histology, the discrete nodules noted macroscopically post mortem cannot distinguish silicosis from TB. However, in a compensation setting, adjudicators might take other factors into consideration. These include the 40 year history of silica

10970274, 2023, 4, Downloaded from https://onlinelibrary.wiley.com/doi/10.1002/ajim.23460 by South African Medical Research, Wiley Online Library on [08/02/2024]. See the Terms and Conditions (https://onlinelibrary.wiley.com/terms-and-conditions) on Wiley Online Library for rules of use; OA articles are governed by the applicable Creative Commons License

exposure and the possibility of effacement of the nodular appearance of silicosis by confluence and contraction of the upper zone as part of the development of tuberculous fibrosis. For living miners with access to CT, it remains an open question whether this imaging technique would be able to distinguish between the fibrotic features produced by TB from those of silicosis.

Extensive or confluent fibrosis has long presented difficulty in distinguishing complicated silicosis (PMF) from TB radiologically. The historical article cited earlier[12] presents a classification of silicosis (without TB) in which advanced disease (the "third stage") includes various features of PMF—coalescence of fibrotic nodules or areas, massive fibrosis resembling consolidation, pleural thickening and emphysema. A contrary opinion from the same pre-TB treatment era was that TB was close to being a necessary factor in the development of PMF.[41] Modern experience would, however, support the contention that while prior TB may be a risk factor for PMF,[17] the latter does not require TB as a precursor nor co-factor, a view reinforced by outbreaks of PMF in low TB burden settings.[42,43]

4.5 | Recommendations

4.5.1 | Striking a balance between underdiagnosis and overdiagnosis of TB

Underdiagnosis of active TB among Southern African miners is a public health concern. In one report, over 50% of miners who had active TB diagnosed at autopsy were undiagnosed in life.[44] Given the high mortality and morbidity associated with TB and transmission of the disease within communities, compensation and TB screening programs for former gold miners should offer sputum Xpert MTB/RIF testing to all such miners whether symptomatic or not. Examiners need to be rigorous when assessing the CXRs of silica-exposed workers to ensure that diagnosis of TB is not missed. Since subtle radiographic changes may be the initial manifestation of TB, it may be difficult to diagnose TB without comparison with earlier images.[18,19,45] There is therefore a case for investment in systematic digital record keeping of CXRs, TB tests and treatment of miners, starting while in service. These records should in turn be accessible to all healthcare providers who attend to former miners. Such a program should be part of current regional cooperation in Southern Africa on silicosis and TB.[46]

While clinicians should seek bacteriological confirmation of TB before initiating TB treatment, empirical treatment is justified in specific circumstances.[47] However, where there is a combination of low resources and high prevalences of HIV, silicosis and post TB CXR abnormalities, there is a risk of overtreatment. Besides unnecessary use of scarce resources, TB treatment is itself associated with morbidity which may be difficult to detect and manage in this setting. A recent study of Xpert MTB/RIF in an African setting has shown it to have high sensitivity against culture (> 90%). However, for Xpert-negative cases the authors stressed the need for compliance with TB algorithms, including considering other diagnoses before commencing empirical treatment.[48] In respect of smear negative TB or HIV infection, greater sensitivity against culture has been shown with the newer Xpert MTB/RIF Ultra (Cepheid) than Xpert MTB/RIF, a development which could reduce recourse to empirical treatment.[49]

With regard to silicosis, in labour sending areas such as Lesotho, an occupational history should be taken in all adults presenting with lung disease, and silicosis considered in all former gold miners with abnormal CXRs. When active TB is diagnosed in the presence of radiological changes and an exposure history compatible with silicosis, an interim diagnosis of silicosis can be considered, but revisited with a follow up CXR after completion of treatment to determine the extent of radiological clearing. Apart from diagnosis of silicosis and TB treatment decisions, the identification of old/healed TB remains important in this ex-goldminer population where silicosis in combination with TB, whether old/healed or active, is a second degree compensable disease.[25]

4.6 | CXR classification of silicotuberculosis

In the early version of what is now the 2011 ILO International Classification of Radiographs of Pneumoconioses there was an additional symbol for active TB ("tba")[50] which was dropped from later revisions.[26] Beyond the symbol tb, readers still have a number of options for elaborating the reading of silicotuberculosis, including cavity (cv), pleural effusion (ef), marked distortion of an intrathoracic structure (di), bullae (bu), and significant apical pleural thickening (at). A judgement about active disease is not called for by the Classification, and important TB descriptors such as extent of disease, massive fibrosis, and bronchiectasis are absent. The latter are, however, relevant to detection and treatment of active disease, and to assessment of prognosis (including recurrent disease) and likely impairment in adjudication for compensation.

There is currently considerable interest in "post-TB lung" as a chronic condition requiring follow up and in some circumstances treatment.[36,51] For these reasons, whether using the ILO Classification or not, readers should attempt to describe TB in greater detail than provided for by the Classification. The current "Comment" section of the ILO reading form could be used for this purpose, although that requires ignoring the instruction that it should be used for "non dust-related disease". Alternatively, a previous attempt at providing classification of TB in the presence of silicosis could be revived.[52]

CXR reading courses combining silicosis and TB, whether active or old/healed, are needed for medical practitioners serving mining or ex-mining populations where silicotuberculosis is common. This requires chest imaging teaching sets exemplifying silicosis, TB and combined disease across the range from subtle to florid, as well as of progression of such features over time or regression with TB treatment. Such sets could serve as informal standard films for readers as an adjunct to the ILO Classification.

10970274, 2023, 4, Downloaded from https://onlinelibrary.wiley.com/doi/10.1002/ajim.23460 by South African Medical Research, Wiley Online Library on [08/02/2024]. See the Terms and Conditions (https://onlinelibrary.wiley.com/terms-and-conditions) on Wiley Online Library for rules of use; OA articles are governed by the applicable Creative Commons License

4.6.1 | Health care social security beyond current workers' compensation system

Gold-mining related diseases, such as silicosis, COPD or TB, are either progressive or leave long-term sequelae that may significantly affect the life of ex-goldminers years after they leave the mine. The example here is Case 4. This ex-goldminer had a history of past TB treatment on two occasions, and had received maximum compensation under ODMWA. His current medical evaluation took place only because of the TIMS programme, 7 years after certified for maximum workers' compensation certification. With no financial capacity, in a country with very poorly resourced medical care, options such as diagnostic investigation of complications or palliative treatment such as oxygen therapy remained beyond his reach. While Section 36A of ODMWA[25] makes provision for medical expenses for compensable disease to be paid by the mine owner (or the Compensation Commissioner, or both) for both employed and former miners, this provision has to our knowledge never been honored. A political, economic and legal strategy is required to find the means to do so.

4.6.2 | Research on silicotuberculosis

In 1938 Taylor and Alexander reported that the United States, Canada, Great Britain, Germany, Italy, Australia and South Africa had the greatest number of published studies on silicosis.[12] South Africa remains the only one of these countries where silicotuberculosis continues to impose such a heavy population burden. Advanced mining technology in the mature industrialized part of the world has substantially reduced silica exposure with some exceptions, while the TB burden has declined to low levels.

However, South Africa has been joined by other countries such as India and China with large numbers employed in mining, quarrying and stone-work in high TB burden settings, with resultant silicotuberculosis.[53,54] These countries should take the lead in encouraging and funding studies that would assist practitioners to distinguish silicosis from TB and to devise optimal screening and treatment protocols. An example is the ability of CT scanning to disentangle silicosis from old and active TB in populations affected by both diseases. South Africa, with its miner autopsy system, for example, is well placed to conduct clinico-pathological correlation studies.[7] Collaboration among affected countries and sharing of similar or different experiences in diagnosing and managing combined disease should also be pursued.

4.7 | Strengths and limitations

To our knowledge, this is one of the first reports of the modern era to examine the difficulty of distinguishing TB and silicosis among migrant ex-gold miners a relatively long time after exposure to dust has ceased. A major limitation was that the evaluation was limited to CXR, as the Centre where the ex-miners were examined did not have access to pulmonology expertise nor CT scanning. A lesser limitation was the lack of access to Mycobacterium TB culture, the gold standard for active disease, since Xpert MTB/RIF was used in all cases. However, since these limitations reflect the situation facing health care providers in areas where ex-miners live, the considerations and recommendations arising from these cases are of practical relevance to many practitioners and populations around the globe.

5 | CONCLUSION

We have demonstrated with the four cases drawn from Lesotho that ex-gold miners from the South African mines may present with complex lung disease with poor agreement between radiological findings and clinical presentation, poor agreement between CXR findings suggestive of TB and Xpert MTB/RIF sputum results, and overlap of clinical and radiological presentation of silicosis and TB.

While CT may help distinguish old/healed TB from an active TB lesion and from silicosis, its limited accessibility and high cost make it impractical in this setting. The lesions observed in the lungs of ex-gold miners are permanent and progressive in most, if not all, of those affected. As these ex-miners continue living in high TB burden communities and given their impaired lung defences due to silicosis and silica loading and their high prevalence of latent TB infection, TB re-infection and reactivation impose a lifelong population burden.[55] To this burden must be added missed diagnosis of silicosis in which abnormal findings are attributed to TB, with consequent loss of the opportunity for proper assessment of prognosis and opportunity for workers' compensation.

6 | INSTITUTIONS AT WHICH THE WORK WAS PERFORMED

Wits Health Consortium—TB in the Mining Sector in Southern Africa (TIMS) project Mafeteng Occupational Health Centre, Mafeteng District, Lesotho; University of Cape Town; University of the Witwatersrand.

AUTHOR CONTRIBUTIONS

Conception and design of the work: Botembetume Maboso and Rodney Ehrlich. *Case data acquisition*: Botembetume Maboso. *Assessment of cases, including chest X-ray reading*: All authors. *Drafting of the paper*: Botembetume Maboso and Rodney Ehrlich. *Revision and finalization of paper*: All authors. All authors approve the final version to be published, and agree to be accountable for all aspects of the work in ensuring that questions related to the accuracy or integrity of any part of the work are appropriately investigated and resolved.

ACKNOWLEDGMENTS

The authors thank the Foundation for Human Rights for providing financial support for this work. The data were derived from the TB in the Mining Sector in Southern Africa program under the aegis of the

10970274, 2023, 4, Downloaded from https://onlinelibrary.wiley.com/doi/10.1002/ajim.23460 by South African Medical Research, Wiley Online Library on [08/02/2024]. See the Terms and Conditions (https://onlinelibrary.wiley.com/terms-and-conditions) on Wiley Online Library for rules of use; OA articles are governed by the applicable Creative Commons License

Wits Health Consortium and Government of Lesotho. Grant sponsor: Part of the research for this article was conducted with the support of the Foundation for Human Rights, Johannesburg. The funder played no role in the conception, design or reporting of the study, nor in the decision to publish.

CONFLICT OF INTEREST STATEMENT

Prof. Ehrlich has written expert testimony for plaintiff attorneys in silicosis litigation. The remaining authors declare no conflict of interest.

DATA AVAILABILITY STATEMENT

Research data are not shared.

DISCLOSURE BY AJIM EDITOR OF RECORD

John Meyer declares that he has no conflict of interest in the review and publication decision regarding this article.

ETHICS APPROVAL AND INFORMED CONSENT

Permission to analyse and publish the data was provided by the Wits Health Consortium-TIMS project and ethical clearance obtained from the Human Research Ethics Committee of Lesotho (ID: 142-2018), and the UCT-Human Research Committee (HERC REF 699/2020). The need for informed consent was waived on the basis that the case descriptions were based on secondary anonymized data.

ORCID

Botembetume Maboso http://orcid.org/0000-0002-5087-9012
Rodney Ehrlich http://orcid.org/0000-0001-5736-9237

REFERENCES

1. World Health Organization. Global tuberculosis report 2021. https://www.who.int/teams/global-tuberculosis-programme/tb-reports/global-tuberculosis-report-2021
2. Hoy RF, Jeebhay MF, Cavalin C, et al. Current global perspectives on silicosis—convergence of old and newly emergent hazards. *Respirology*. 2022;27(6):387-398.
3. Ehrlich R. Commentary: silica—a multisystem hazard. *Int J Epidemiol*. 2021;50(4):1226-1228.
4. Ehrlich R, Akugizibwe P, Siegfried N, Rees D. The association between silica exposure, silicosis and tuberculosis: a systematic review and meta-analysis. *BMC Public Health*. 2021;21(1):953.
5. Hnizdo E, Murray J. Risk of pulmonary tuberculosis relative to silicosis and exposure to silica dust in South African gold miners. *Occup Environ Med*. 1998;55:496-502.
6. Basu S, Stuckler D, Gonsalves G, Lurie M. The production of consumption: addressing the impact of mineral mining on tuberculosis in southern Africa. *Global Health*. 2009;5:11.
7. Chang ST, Chihota VN, Fielding KL, et al. Small contribution of gold mines to the ongoing tuberculosis epidemic in South Africa: a modeling-based study. *BMC Med*. 2018;16(1):52.
8. Steen TW, Gyi KM, White NW, et al. Prevalence of occupational lung disease among Botswana men formerly employed in the South African mining industry. *Occup Environ Med*. 1997;54:19-26.
9. Park HH, Girdler-Brown BV, Churchyard GJ, White NW, Ehrlich RI. Incidence of tuberculosis and HIV and progression of silicosis and lung function impairment among former Basotho gold miners. *Am J Ind Med*. 2009;52:901-908.
10. Maboso B, Moyo D, Muteba K, et al. Occupational lung disease among Basotho ex-miners in a large outreach medical assessment programme. *Occup Health South Afr*. 2020;26:145-152.
11. Ehrlich R. A century of miners' compensation in South Africa. *Am J Ind Med*. 2012;55:560-569.
12. Taylor H, Alexander H Silicosis and silicotuberculosis. *JAMA*. 1938;111:400-408.
13. Schepers GW. Silicosis and tuberculosis. *Ind Med Surg*. 1964;33:381-399.
14. Mintz F. *Hard Rock Miners' Phthisis in 19th and Early 20th Century Britain: from diagnosis to compensation*. UC Berkeley Electronic Theses and Dissertations. 2009. https://escholarship.org/uc/item/6dw7r368
15. Madl AK, Donovan EP, Gaffney SH, et al. State-of-the-science review of the occupational health hazards of crystalline silica in abrasive blasting operations and related requirements for respiratory protection. *J Toxicol Environ Health B Crit Rev*. 2008;11(7):548-608.
16. Lee JH. The diagnosis of tuberculosis in the presence of silicosis. *Can Med Assoc J*. 1948;58:349-353.
17. Ng TP, Chan SL. Factors associated with massive fibrosis in silicosis. *Thorax*. 1991;46:229-232.
18. Solomon A. Silicosis and tuberculosis: part 2—a radiographic presentation of nodular tuberculosis and silicosis. *Int J Occup Environ Health*. 2001;7(1):54-57.
19. Solomon A, Rees D. The chest radiograph in silica associated with tuberculosis. *Occup Health South Afr*, 26:266-276.
20. Skoura E, Zumla A, Bomanji J. Imaging in tuberculosis. *Int J Infect Dis*. 2015;32:87-93.
21. The World Bank in Lesotho. https://www.worldbank.org/en/country/lesotho/overview
22. TB in the Mining Sector in Southern Africa (TIMS). https://www.timssa.co.za/Whoweare/AboutTIMS.aspx
23. Miller MR, Hankinson J, Brusasco V, et al. Standardisation of spirometry. *Eur Respir J*. 2005;26:319-338.
24. Quanjer PH. Standardized lung function testing. Report working party standardization of lung function tests. European community for coal and steel. *Bull Eur Physiopathol Respir*. 1983;19(suppl 5):1-95.
25. Occupational Diseases in Mines and Works, Act 78 of 1973. [Updated to 1 October 2019]. http://www.saflii.org/za/legis/consol_act/odimawa1973385.pdf
26. International LabourOrganization. Classification of Radiographs of Pneumoconioses, Revised edition 2011. https://www.ilo.org/safework/info/publications/WCMS_168260/lang–en/index.htmsafework/documents/publication/wcms_168260.pdf
27. Roy M, Ellis S. Radiological diagnosis and follow-up of pulmonary tuberculosis. *Postgrad Med J*. 2010;86:663-674.
28. Hanifa Y, Grant AD, Lewis J, Corbett EL, Fielding K, Churchyard G. Prevalence of latent tuberculosis infection among gold miners in South Africa. *Int J Tuberc Lung Dis*. 2009;13:39-46.
29. Sonnenberg P, Murray J, Glynn JR, Shearer S, Kambashi B, Godfrey-Faussett P. HIV-1 and recurrence, relapse, and reinfection of tuberculosis after cure: a cohort study in South African mineworkers. *The Lancet*. 2001;358(9294):1687-1693.
30. Corbett EL, Churchyard GJ, Clayton TC, et al. HIV infection and silicosis: the impact of two potent risk factors on the incidence of mycobacterial disease in South African miners. *AIDS*. 2000;14:2759-2768.
31. Mallory KF, Churchyard GJ, Kleinschmidt I, De Cock KM, Corbett EL. The impact of HIV infection on recurrence of tuberculosis in South African gold miners. *Int J Tuberc Lung Dis*. 2000;4(5):455-462.
32. Pasula R, Britigan BE, Turner J, Martin II WJ. Airway delivery of silica increases susceptibility to mycobacterial infection in mice: potential role of repopulating macrophages. *J Immunol*. 2009;182:7102-7109.

10970274, 2023, 4, Downloaded from https://onlinelibrary.wiley.com/doi/10.1002/ajim.23460 by South African Medical Research, Wiley Online Library on [08/02/2024]. See the Terms and Conditions (https://onlinelibrary.wiley.com/terms-and-conditions) on Wiley Online Library for rules of use; OA articles are governed by the applicable Creative Commons License

33. Konečný P, Ehrlich R, Gulumian M, Jacobs M. Immunity to the dual threat of silica exposure and Mycobacterium tuberculosis. *Front Immunol*. 2019;9:3069.
34. Montales MT, Chaudhury A, Beebe A, Patil S, Patil N. HIV-associated TB syndemic: a growing clinical challenge worldwide. *Front Public Health*. 2015;3:281.
35. Charalambous S, Churchyard GJ, Murray J, De Cock KM, Corbett EL. Persistent radiological changes following miliary tuberculosis in miners exposed to silica dust. *Int J Tuberc Lung Dis*. 2001;5(11):1044-1050.
36. Meghji J, Simpson H, Squire SB, Mortimer K. A systematic review of the prevalence and pattern of imaging defined post-TB lung disease. *PLoS One*. 2016;11(8):e0161176.
37. Hessel PA, Sluis-Cremer GK, Hnizdo E, Faure MH, Glyn-Thomas R, Wiles F. Progression of silicosis in relation to silica dust exposure. *Ann Occup Hyg*. 1998;32:689-696.
38. Albez FS, Araz Ö, Yılmazel Uçar E, et al. Long-term follow-up of young denim sandblasters in Turkey. *Occup Med*. 2022;72(6):403-410.
39. Wong EB. It is time to focus on asymptomatic tuberculosis. *Clin Infect Dis*. 2021;72(12):e1044-e1046.
40. Cullinan P, Reid P. Pneumoconiosis. *Prim Care Respir J*. 2013;22(2):249-252.
41. Gardner LU. The massive conglomerate lesions of silicosis. *Trans Am Clin Climatol Assoc*. 1939;55:65-72.
42. Weissman DN. Progressive massive fibrosis: an overview of the recent literature. *Pharmacol Ther*. 2022;240:108232.
43. León-Jiménez A, Hidalgo-Molina A, Conde-Sánchez MÁ, et al. Artificial stone silicosis. *Chest*. 2020;158(3):1060-1068.
44. Field N, Murray J, Wong ML, et al. Missed opportunities in TB diagnosis: a TB process-based performance review tool to evaluate and improve clinical care. *BMC Public Health*. 2011;11:127-133.
45. Sureka B, Mittal A, Mittal M, Thukral B. Silicotuberculosis: importance of evaluation of serial radiographs. *Ann Afr Med*. 2013;12(4):255-256.
46. Southern African Development Community (SADC). Declaration on tuberculosis in the mining sector. 2012. http://www.stoptb.org/assets/documents/news/Declaration%20on%20Tuberculosis%20in%20the%20Mining%20Sector2012English.pdf
47. World Health Organization. Improving the diagnosis and treatment of smear-negative pulmonary and extrapulmonary tuberculosis among adults and adolescents. 2007. WHO/HTM/TB/2007.379 WHO/HIV/2007.01
48. Kendall EA, Kamoga C, Kitonsa PJ, et al. Empiric treatment of pulmonary TB in the Xpert era: correspondence of sputum culture, Xpert MTB/RIF, and clinical diagnoses. *PLoS One*. 2019;14(7):e0220251.
49. Shapiro AE, Ross JM, Yao M, et al. Xpert MTB/RIF and Xpert Ultra assays for screening for pulmonary tuberculosis and rifampicin resistance in adults, irrespective of signs or symptoms. *Cochrane Database Syst Rev*. 2021;3(3):CD013694.
50. Sluis-Cremer GK. UICC-Cincinnati classification of the radiographic appearances of pneumoconiosis. *S Afr Med J*. 1972;46:1959-1962.
51. Migliori GB, Marx FM, Ambrosino N, et al. Clinical standards for the assessment, management and rehabilitation of post-TB lung disease. *Int J Tuberc Lung Dis*. 2021;25(10):797-813.
52. Solomon A, Rees D, Felix M, Venter E. Silicosis and tuberculosis: a proposed radiographic classification of tuberculosis to accompany the ILO international classification of radiographs of pneumoconioses. *Int J Occup Environ Health*. 2000;6(3):215-219.
53. Nandi S, Dhatrak S, Sarkar K. Silicosis, progressive massive fibrosis and silico-tuberculosis among workers with occupational exposure to silica dusts in sandstone mines of Rajasthan state: an urgent need for initiating national silicosis control programme in India. *J Family Med Prim Care*. 2021;10(2):686-691.
54. Chen SY, Hayes RB, Wang JM, Liang SR, Blair A. nonmalignant respiratory disease among hematite mine workers in China. *Scand J Work Environ Health*. 1989;15:319-322.
55. Ehrlich R. The crisis of tuberculosis and silicosis in the South African mining industry. Online presentation. 2012. https://www.ehrn.co.za/download/lecture_series_04.pdf

How to cite this article: Maboso B, te Water Naude J, Rees D, Goodman H, Ehrlich R. Difficulties in distinguishing silicosis and pulmonary tuberculosis in silica-exposed gold miners: a report of four cases. *Am J Ind Med*. 2023;66:339-348. doi:10.1002/ajim.23460

10970274, 2023, 4, Downloaded from https://onlinelibrary.wiley.com/doi/10.1002/ajim.23460 by South African Medical Research, Wiley Online Library on [08/02/2024]. See the Terms and Conditions (https://onlinelibrary.wiley.com/terms-and-conditions) on Wiley Online Library for rules of use; OA articles are governed by the applicable Creative Commons License