

https://dspace.org/

Secondary degenerative changes in the intervertebral disc due to zygapophyseal (para-vertebral) facet joint lesions.

Boshoff, Willem Hendrik

2007-02-22T12:45:38Z
http://hdl.handle.net/10539/2089

Downloaded from a DSpace repository. https://dspace.org/

2.0 LITERATURE REVIEW

2.1 The Articular Facet Joints

2.1.1 Introduction

“The concept of intervertebral disc rupture has overshadowed the role of the facet joints in producing back and leg pain. Recently, the pendulum has shifted away from the disc as a source of most back problems, towards an awareness that the entire interspinal segment is important and that the facet joints have a key role to play” (Lippitt, 1984)

In summarizing an extensive literature review on the effect of immobilization on connective tissue degeneration, Lantz (1988) states that every connective tissue component of an articulation is affected by immobilization, each has its own pattern of degeneration and each contributes in its own unique way to joint stiffness following immobilization. The process follows a very predictable pattern of degeneration. However, the degeneration, which occurs upon immobilization, differs significantly from that seen in diseases such as osteoarthritis. Articular degeneration is a predictable sequel to immobilization. The most notable effect of *“immobilization degeneration”*, and the characteristic most responsible for its use in modelling the degenerative changes of osteoarthritis, is alteration of the articular cartilage. The articular surfaces are normally smooth and regular with a glossy appearance, when the surface degenerates it looses this hyaline lustre and becomes dull and chalky, leading to ulcerative changes with exposure of the underlying cancellous bone

2.1.2 Anatomical consideration of the “facet” joints of the vertebral column

The joints commonly referred to as the “facet joints” are in fact the articulating surfaces of the articular pillars projecting from the mammillary processes of the vertebra (Figure 2.1), also called the zygopophyses, which articulate with the pedicle of the vertebral body.

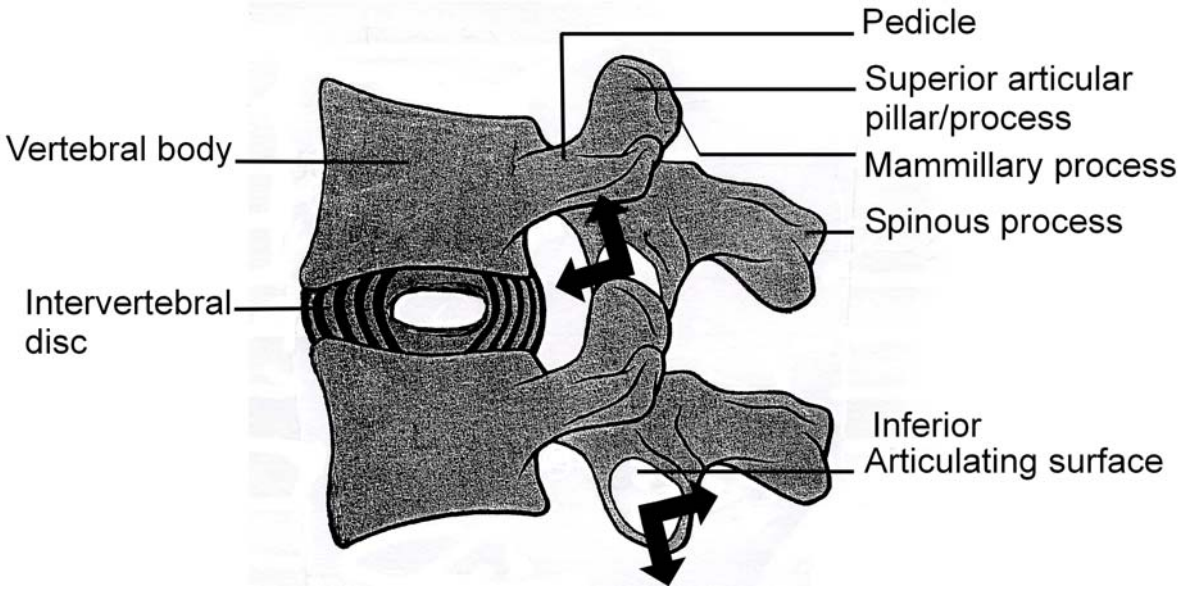

Figure 2.1: Lateral view of the vertebral segment, showing the positions of the articular facet surface. Arrows show the gliding pattern of the joint surfaces. Compiled by W H Boshoff. Adapted from I A Kapandji, Physiology of Joints P81

The facet joints are formed by the superior and inferior articular processes of the successive vertebra. Each superior articular process has a prominence on its dorsolateral surface called the mammillary process. (Figure 2.1)

The facet joint is a true synovial joint with hyaline cartilage surfaces and the joint space enclosed in a fibrous capsule which is lined with a synovial membrane. The joints are aligned obliquely to the sagittal plane and occasionally this obliquity varies from side to side resulting in facet asymmetry or tropism, which probably leads to altered spinal mechanics of the segment involved and this may lead to premature degenerative arthritis. (Adams and Hutton, 1980)

An integral component of the function of a diarthrodial joint, such as the facet joint is the ability of the joint surface and capsule to allow movement. The hyaline cartilage surface of a facet joint is supported by an articular process of the vertebra also called the zygapophysis. The nature of hyaline cartilage is that of a flexible somewhat elastic semitransparent substance with an opalescent bluish tint. It is composed of basophilic fibrils containing interstitial substance with cavities (l*acunae*) in which the chondrocytes occur. (Dorlands, 1965)

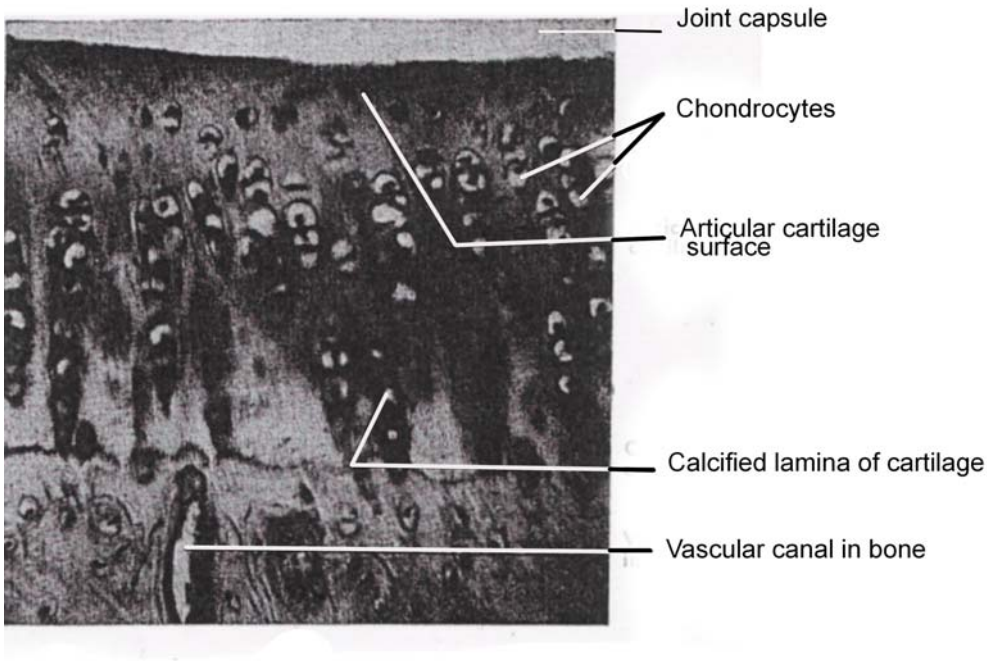

Figure 2.2: Section of the glenoid cavity of a rabbit, showing the hyaline articular cartilage and the vascular canal in the underlying bone. X 170. Adapted from Cunningham, Textbook of Anatomy 10th Edition p 216

2.1.3 The Anatomy of a diarthrodial joint

In order to better, understand the function of the facet joint and the effect of lack of flexibility or hypokinetic disease, one needs to re-examine the structure and physiology that allows a diarthrodial articulation to contribute to motion and the ability of the joint surface to maintain itself.

2.1.3.1 Articular hyaline cartilage

Articular hyaline cartilage covers the articular surfaces in synovial joints, providing an extremely smooth, resistant surface bathed by synovial fluid, allowing almost frictionless movement. Its elasticity, which dissipates the effects of concussion, gives the whole articulation some flexibility, particularly near the extremes of movement. It is constructed to resist large compressive forces generated by weight transmission, occurring especially during movement. Articular cartilage does not ossify and varies from 1-7mm in thickness; it is moulded to the shape of the underlying bone. On the convex surface, it is most dense and thickest in the centre, the reverse being true for

the concavity. The thickness decreases from maturity to old age. (Giles, 1986 and Grays Anatomy 37th Edition, 1989)

2.1.3.2 Articular capsules

The articular capsules form a complete envelope for the free movement of the joint. The capsule is made up of an external layer composed of white fibrous tissue and an internal layer, which is specialized, and described as the synovial membrane. The whole forms a closed sac called the synovial cavity. Synovial fluid is secreted from the inner membrane and appears as a thick, viscous glassy fluid similar to the white of an egg. The membrane is not limited to the inner capsule but forms folds or projections composed of connective tissue, fat and blood vessels commonly surrounding the margin of the articular cartilage, filling clefts and cavities. The cavity of a normal joint contains only enough fluid to moisten and lubricate the articular surfaces. (Grays Anatomy 37th Edition, 1989)

The cells of articular cartilage divide by mitosis, more noticeable in young subjects. Progressive loss of superficial cells from young surfaces and their replacement from deeper layers is as yet unconfirmed. There is progressive reduction in cellularity of cartilage with advancing age, accounting for the variable lipid content of the matrix. Articular cartilage may derive nutriment by diffusion from three sources (a) vessels of the synovial membrane,(b) synovial fluid and hypochondral vessels of an adjacent medullary cavity and (c) some capillaries which occasionally traverse the calcified cartilage and have been estimated to contact 1-7% of the osseous aspect of the cartilage. (Grays Anatomy 37th Edition, 1989)

The synovial cavities of diarthrodial joints are one of the specialised fluid systems that exist in the body. The cavity is filled with synovial fluid, which performs a special function. The functions of synovial fluid are those of nourishing and lubricating the hyaline cartilage. The fluid originates from the synovial folds on the borders of the articulation lying within the joint capsule. In states of homeostasis, there is a balance in the production and absorption of the synovial fluid, firstly by a breakdown via a polysaccharide esterase (Kleiner and Oerten, 1966) and then by absorption into the

lymphatic system. Disturbance of this system will lead to poor lubrication and nourishment, with eventual disruption of the hyaline cartilage (Cramer et al, 2004).

Comment:
An over production of fluid will lead to intra-articular swelling and tightening of the capsule. As a rule, intra-articular oedema is usually noticed in the initial stage of joint injury as may occur in the action of hyperextension. As the joint becomes immobilised by the oedema, the production of the synovial fluid is compromised and the joint goes into the early stage of degeneration from lack of nourishment. This in turn, is aggravated by the lack of movement (Figure 2.3).

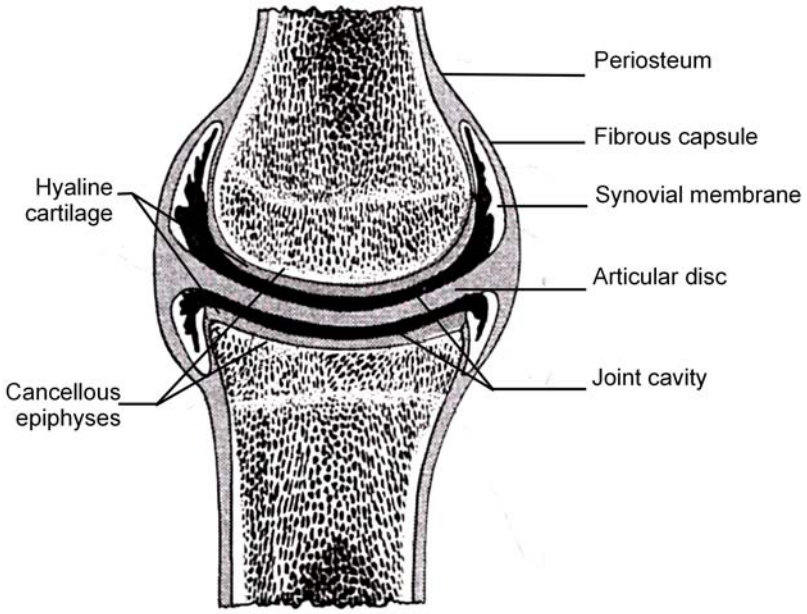

Figure 2.3: Diagram of a synovial joint and articular disc dividing the joint cavity into two compartments. Adapted from Cunningham's Textbook of Anatomy 10th Edition p 216

Nourishment of the joint surface is, however, not limited to the synovial fluid alone. It also arises from the cancellous epiphysis and underlying cortex. From there it enters the matrix layer (figure 2.3) of the hyaline cartilage. In a study by Bird and Sweet (2002), they conclude that intracortical pressure against an impermeable cartilage

matrix, will translate laterally the need to nourish the joint surface. This lateral pressure forms an exostosis or spurring at the musculo-ligamentous attachment often in degenerative joints disease and reported as traction spurring. (Figure 2.4)

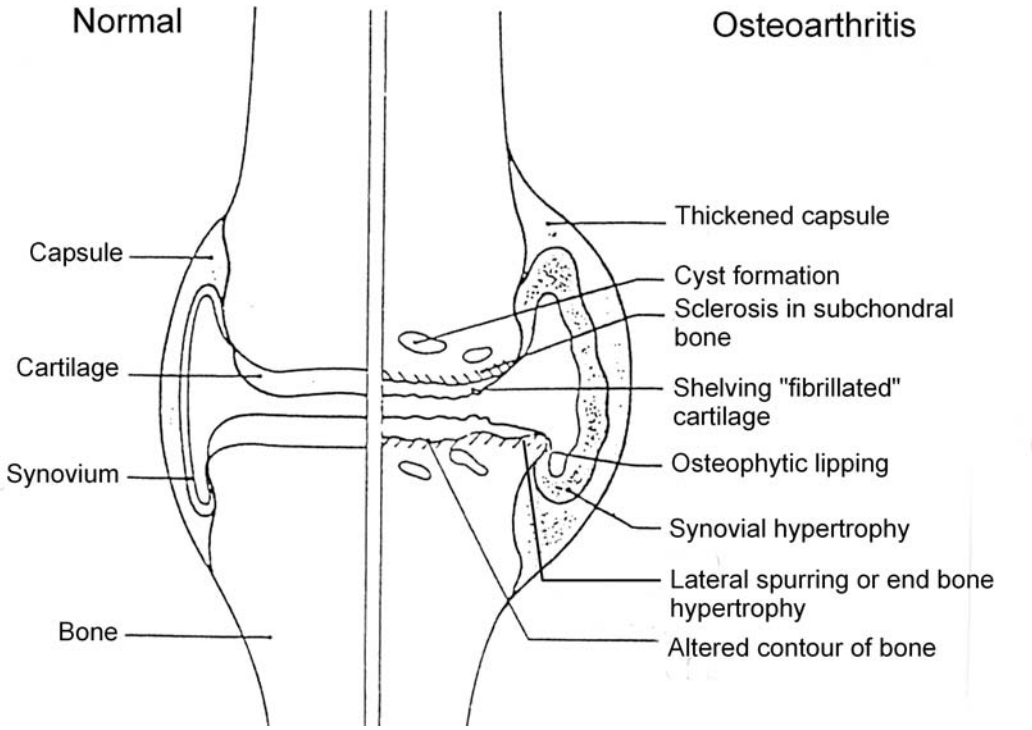

Figure 2.4: Schematic representation of a comparison between a normal and osteoarthritic synovial joint

Comment:
A synovial joint, like a pond, needs to be flushed regularly or the fluid / water will stagnate / degenerate and undergo chemical changes. Fluid that is produced must in turn also be removed. The nourishment of a joint, therefore, appears to function on a “demand – supply “ system.

A primary factor controlling the rate of lymph flow is affected by the degree of motion in the tissue. (Tripton et al, 1975)

The greater the motion the greater the lymph flow which, lessens the protein concentration, causing an increased negativity of the interstitial fluid pressure influencing the production and absorption of interstitial fluid. (Guyton, 1966)

Comment:
This observation was made with specific reference to interstitial fluids, but the concept may be adapted to synovial cavities as well. In a state of homeostasis, the production, breakdown and absorption of intracapsular fluid via the lymphatic and venous systems must be kept in balance. Alteration of the rule will result in malfunction and degeneration.

In the synovial cavities, as in other potential spaces, excess proteins are likely to collect and must be returned to the circulatory system through the lymphatics; otherwise the space swells".(Guyton, 1966) (See figure 2.4)

Exercise physiologists, in studying the effects of hypokinesia, subsequent to Guyton (1966), are confirming the observations made then and substantiating it with current research: -

"It must be appreciated that immobilisation of a joint for any reason, induces changes in the surrounding structures such as muscle, capsule, cartilage, tendon, ligaments and bone." (Tripton et al, 1968)

"Functional changes are not surprising with immobilisation, because gross and cellular changes are seen in capsular structures or cartilage surfaces within short periods" (Akeson et al, 1977)

"In general, 6 weeks of immobilisation will require a minimum of 20 weeks for recovery to become evident." (Tripton et al, 1968, 1975)

Immobilisation in casts of the knee of dogs, for up to 8 weeks, led, even after 6 days, to a marked reduction in proteoglycan synthesis. (Palmaski et al, 1979)

The above studies have shown that synovial joints are functionally and physiologically maintained when in a state of kinesia, and lack of movement will result in degeneration of the intracapsular structures. Examination of inclusions observed in the intracapsular zone of the zygapophyseal joint is extensively described. (Giles et al, 1986, Suiger et al, 1990, Giles 1986)

The presence of enlarged synovial folds, which randomly appear in a joint, could have clinical significance, contributing to facet orientated low back pain when they are pinched between joint surfaces. This pinching will produce an oedema of the affected synovial fold, limiting movement due to pain, initiating early hypokinesia. (Kraft and Levinthal, 1951; Kirkaldy-Willis, 1984)

The intracapsular homeostasis of a synovial, and in this case, the zygapophyseal joint, is influenced by a balance in the production of the enzymes hyaluronidase and collagenase.

2.1.4 Hyaluronidase

Hyaluronic acid is a polysaccharide, which seems to bind water in forming a kind of a gel that transports nutrients and lubricates the joint surface (Kleiner and Oerten, 1966). Hyaluronidase, the enzyme, hydrolyses the mucopolysaccharides, and new molecules are formed as replacements (Oerten and Neuhaus, 1970).

2.1.5 Collagenase

Chronic rheumatoid arthritis (RA) in man is characterised by a disruption of the intra-articular collagenous structures (See figure 2.4). Investigations have indicated that this might be due to an overproduction of collagenase from a proliferating synovium. Oerten and Neuhaus, 1970, identified high collagenase activity in the synovium of specimens from patients with RA whereas none was found in a control group. This could account for the destruction of collagen, a ground substance of cartilage, in patients with this type of joint inflammation.

Comment:
The viscosity of the synovial fluid appears to be controlled by a balance in the production of the mucopolysaccharides and hyaluronidase.

Articular cartilage is elastic and recovery is possible from repeated intermittent pressure, a property that enables the cartilage to absorb the shocks to which the articulation is subjected. (Kleiner and Oerten, 1966)

Comment:
The assumption can be made that in the presence of healthy mucopolysaccharides, surface nourishment can be affected by imbibition and osmosis, similarly seen in the anulus fibrosus. It can also be assumed, that when the joint is immobilised, the homeostasis will be disrupted and the esterase mentioned above will inadvertently play a role in the destruction of the joint surface.

Studies previously mentioned and also those more recently published by Cramer et al, 2004, show that the joint surface has regenerative properties, provided movement is restored and the destruction of the cartilaginous surface is not too extensive.

2.1.6 Degenerative changes in the zygapophyseal joints in cadaver studies

Giles, 1986; 1988; Suiger et al, 1990 and Kraft and Levinthal, 1951, have performed extensive studies on the degenerative changes observed in facet joints such as pannus and enlargement of the synovium with destruction of the hyaline cartilage surface.

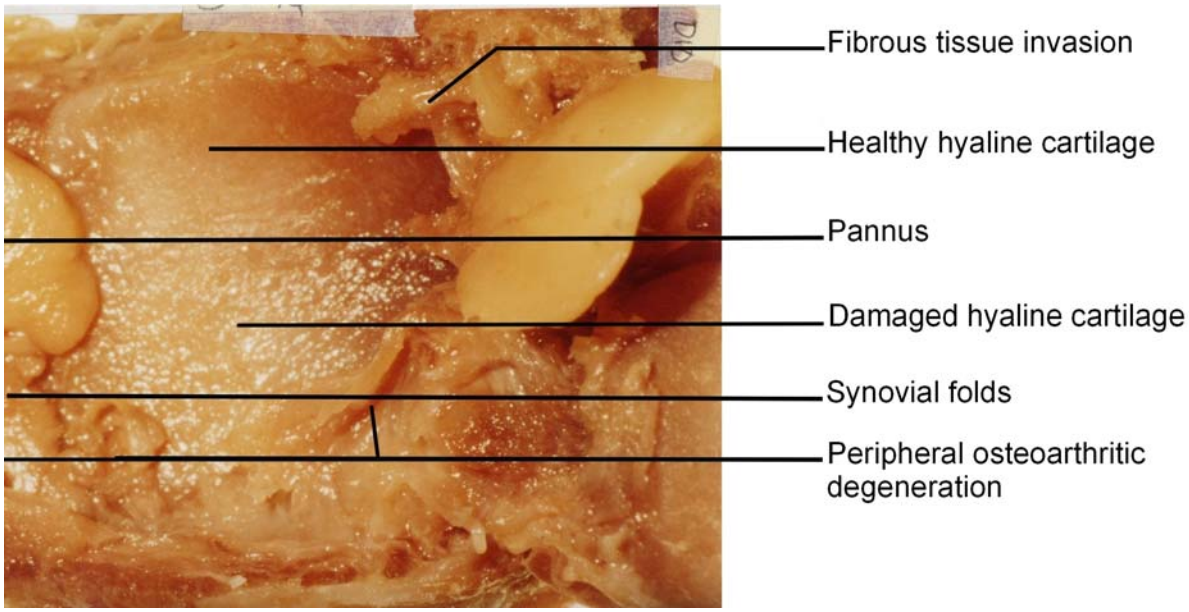

Figure 2.5: Photograph of an exposed degenerated unilateral facet joint and surface related structures. (Dissection by W H Boshoff)

2.1.7 Destructive changes in zygapophyseal-joints

Giles, 1986; Giles et al1986; Suiger et al, 1990 and Kraft and Levinthal, 1951, have adequately discussed destruction of the hyaline cartilage surface of zygapophyseal-joints with accompanying proliferation in synovial folds.

Figure 2.6, adapted from Giles et al, 1986, illustrates the anatomic degenerative changes in the articular capsule, showing synovial fold enlargement. It is interesting to note that the size of the synovial fold is almost one third that of the articulating cartilage, exposing it to possible impingement and intra articular proliferation. (See schematic explanatory drawing, Figure 2.7 and 2.8)

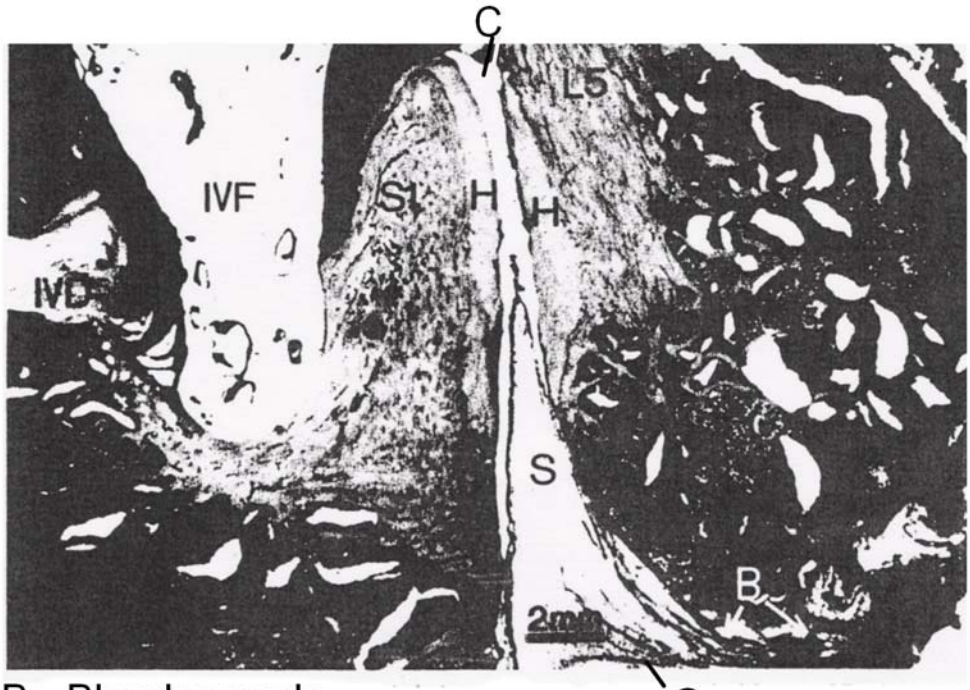

B - Blood vessels
H - Hyaline cartilage
IVD - Intervertebral disc of L5/S1
IVF - Intervetebral foramen
L5 - Inferior articular process of L5
S - Synovial Fold (Intra-articular)
S 1 - Superior articular process of S1
C - Joint capsule

Figure 2.6: Histological slide of the L5/S1 facet joint, stained in Ehrlich's Haematoxylin and light green, from Giles et al (1986)

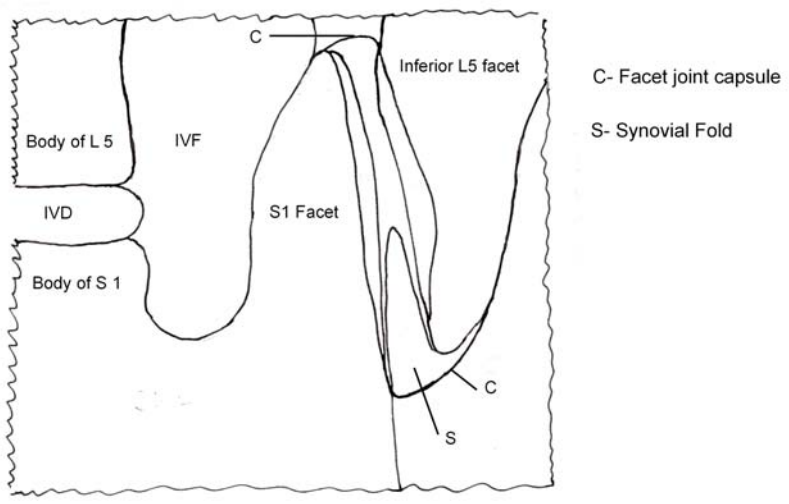

Figure 2.7: Schematic diagram of Figure 2.6

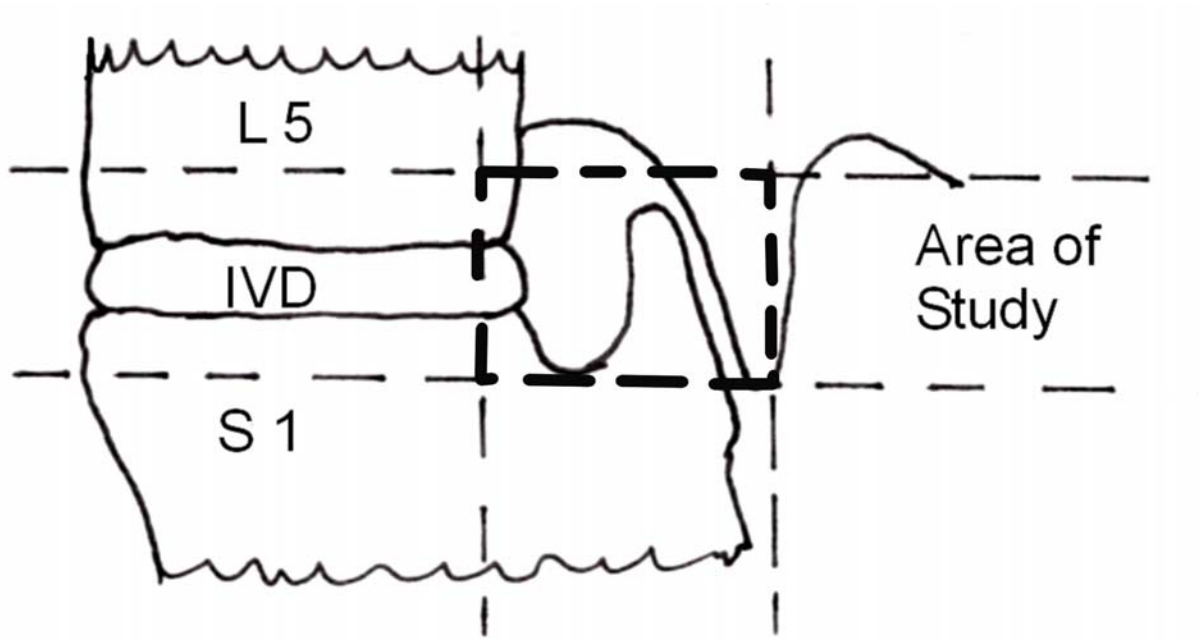

Figure 2.8: Schematic diagram within the bold lines of the area of study, in **figure 2.6 and 2.7**

In a study by Lewin, 1964, the author states that degenerative changes in the articular surface have been observed, and also reported by others, in the absence of disc degeneration. This degeneration was also observed to be more prominent in the lower three joint levels of the lumbar vertebrae. Cases were also reported of extreme disc narrowing without osteophytic spurring but with gross osteoarthritic changes in the apophyseal joints. This leads to the possible conclusion that facet surface degeneration cannot only be assumed to be secondary to disc degeneration.

Comment:
The literature therefore, reports the occurrence of degeneration on the hyaline cartilage surface of the facet joints, prior to the signs of disc degeneration.

2.2 The Intervertebral Disc (IVD)

2.2.1 Anatomy

In the discussion of fine joint structures, Ghadially (1978) elaborates on the intervertebral disc (IVD) and the cartilaginous end plates. The IVD consists of an outer fibrocartilagenous ***anulus fibrosus*** and an inner ***nucleus pulposus***, which in early life is gelatinous in consistency but later also becomes a predominantly fibrocartilagenous structure.

The cartilaginous plates covering the adjacent vertebral bodies, between which the IVD is interposed, were at one time considered part of the IVD (Bohring, 1930; Harris and MacNab, 1954). This was a concept that regarded the structure as a 'total disc', for it is this structure, including the hyaline cartilaginous end plates, that is visualised on x-ray (Taylor, 1975). However, Gray (1973) and Walmsley (1953) had a different concept, which lead to Gray (1973), in an anatomical text describing the disc as consisting of 2 parts only, i.e. the *nucleus pulposus* and anulus fibrosus, whilst the cartilaginous end plates are considered part of the vertebral bodies.

The intervertebral discs are derived from two embryonic structures; the notochord which forms the nucleus pulposus and the mesenchymal cells from the sclerotome which migrate to surround the notochord to form the anulus fibrosus. (Keyes and Compere, 1932)

In the 18-week-old embryo, the *nucleus pulposus* begins to be infiltrated by ingrowths from the *anulus fibrosus* and at birth, the mucoid nucleus pulposus contains a few notochordal cells interlaced with strands of fibrocartilage from the surrounding anulus fibrosus. This process of cellular ingrowth continues throughout life to where, in the adult and senile disc, it is a firmer and denser fibrocartilage structure. (Ghadially, 1978)

In the immature anulus fibrosus, the fibrillar arrangement is obvious as individual strands, almost at right angles to the alternating concentric layers. With age,

however, the individual strands appear to coalesce forming strands of collagen, which appear to increase in thickness with age. (Happy et al, 1969)

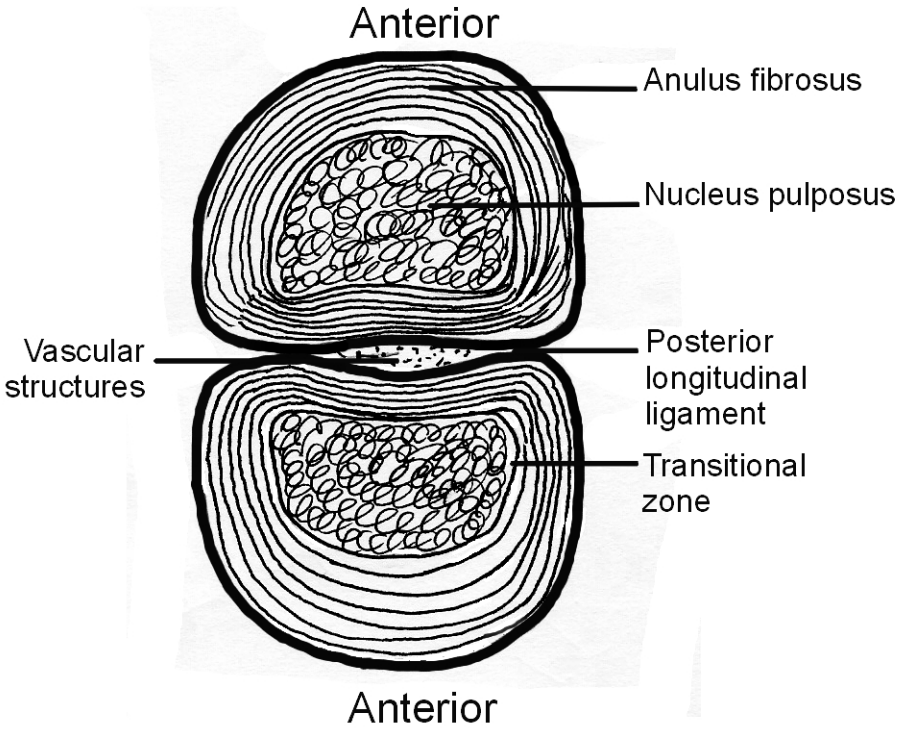

Figure 2.9: Schematic presentation of an intervertebral disc, that had been transversely cut through the centre

Figure 2.9 is a schematic representation of the juxta- apposing halves of the intervertebral disc that has been cut transversely through the middle of the disc. The incision was made from the anterior aspect up to the posterior longitudinal ligament, exposing the intradiscal structures. A macroscopic examination was made of the migration of the nucleus pulposus and its impression on the anulus fibrosus.

The outer surface of the anulus has a well-defined lamella structure, which becomes less defined deeply towards the *nucleus pulposus*. The inner region where the anulus blends with the nucleus, there is an area of absence of distinct demarcation between the two and this is often referred to as a *transitional zone* (Akeson et al, 1977).
Note in fig.2.10, the loss of definition in the posterior anular rings of specimen C, as compared to the same section thought specimen D, where the posterior anular rings are clearly visible. The *transitional zone* is clearly demarcated and varies in size and shape. At times, the posterior outer anular rings are barely visible.

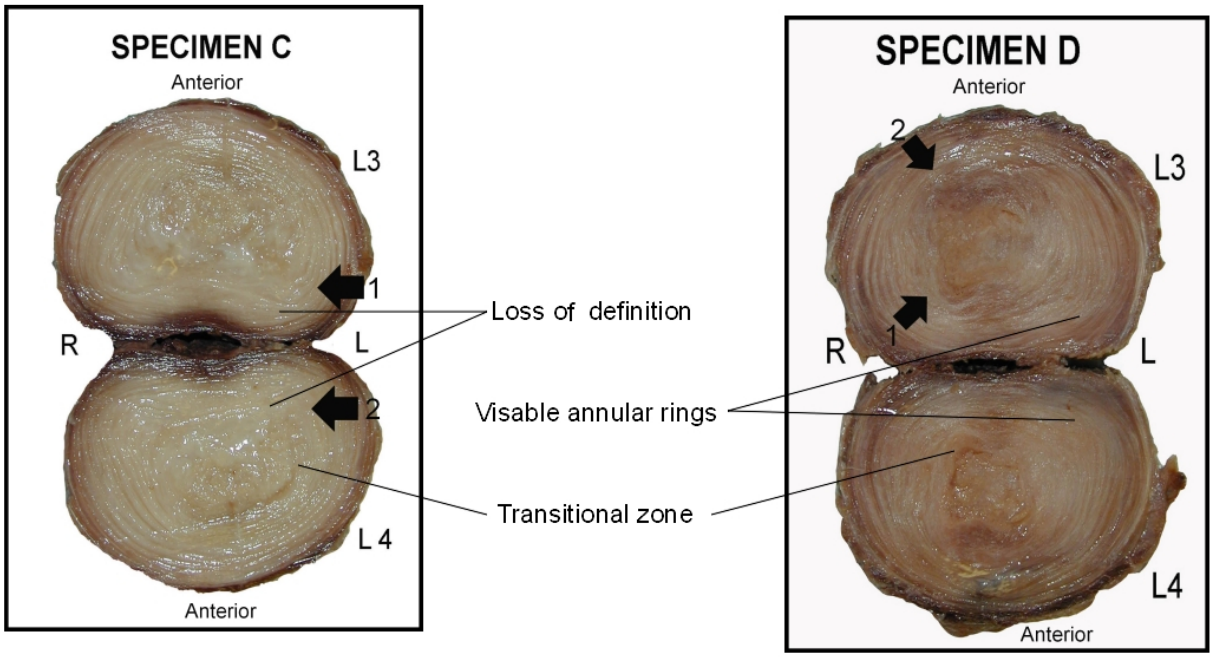

Figure 2.10: Transverse section through the middle of L3/4 disc, of specimen C and D. (Dissection by W H Boshoff)

In earlier literature, experimental observations were made by Akeson et al (1973), where it was concluded that discal failure in the vertebral column occurred in the vertebral body rather than in the anulus. Smith (1969), in an earlier study researched the same conclusion

2.2.2 Physical properties of the intervertebral disc

The intervertebral disc is the largest avascular structure in the body. Its nutrition as well as the disposal of metabolic waste products depends upon exchange with the blood vessels outside the disc (Urban et al, 1978).

It has been suggested that nutritional deficiencies could lead to disc degeneration (Damant et al, 1968).

In experimental work done by Maroudes et al (1975), it was concluded that of the central region of the end plate, about 1/3 was available for diffusion of nutriments as compared with only about 1/10 in the peripheral zone. Thus, only about 40% of the

bone-disc interface is permeable, with the most permeable area being the central nucleus area, and the least the outer anulus (Urban et al, 1978).

Urban et al (1978) also found that the anulus is completely permeable to solute diffusion. Because the area exposed to blood vessels at the posterior aspect is smaller than the anterior, diffusion at the anterior pole is more effective .This phenomenon is important in considering disc degeneration.

Urban et al (1978) showed in studies on anaesthetised dogs, that diffusion appears to be the main mechanism by which small molecular solutes are transported in the discs. This diffusion was found to be enhanced by movement. Their findings suggest that the intra-discal solute transport is predominantly by passive diffusion, whereas extra-discal solute exchange is via the periphery of the anulus and the end plates. When considering that the bone-disc interface at the periphery is only partially permeable, and if the end plate route becomes impaired, there would be a build up of waste products with resultant nutritional deficiency. This could ultimately lead to degenerative changes in the affected structures. The study on the nutrition of the IVD was very comprehensive and even though slightly out of date, forms a very sound basis for the understanding of disc nutrition and the possible reasons behind the origin of degenerative changes.

2.2.3 Vertebral movement at the intervertebral disc level

The foregoing research by Urban et al (1978); Damant et al (1968); Maroudes et al (1975); Akeson (1977); Smith (1969) and Guyton (1966), suggests that the intervertebral disc is nourished by way of diffusion and osmosis.

Guyton (1966) discusses 3 routes of net diffusion through a membrane by:

a) Concentration gradient
b) Electrical gradient
c) Pressure gradient

In the action of flexion and extension of the vertebral column, the disc can be compared to functioning like a sponge, where positive and negative hydraulic pressures influence the bulk flow in the tissues of the intervertebral disc.

Comment:
The component of pressure (hydraulic) gradient is most applicable to the anulus in kinetic movement.

Limitation of movement could then theoretically, influence interdiscal nourishment and this in turn, could lead to early degenerative changes. In a study on disc repair with movement, Sengupta (2004) states that if a favourable environment is created in the motion segment by unloading the disc and permitting near normal motion, the disc may be able to repair itself. Holm and Nachemson (1982) stated that the main mechanism for intradiscal solute transport is positive diffusion; this process is enhanced by movement.

White and Punjabi (1978) mentioned the example of returning astronauts, suggesting that due to the lack of axial pressure on the intervertebral disc, there was an observed increase in the disc height and fluid. Conversely, maintained axial pressure of 8 hours could show a decrease of up to 2mm in disc height.

The IVD needs to be seen to be a dynamic structure which responds to movement allowed by surrounding structures i.e. facet joints, ligaments and muscles. In a study done by Kourtis et al (2004), they found that maintaining the disc in a state of hyperextension for more than 10 minutes the exercise caused increased disc height. This suggests that the IVD could imbibe fluid and solvents fairly rapidly to increase in height, the findings of Akeson et al (1978) support this theory.

Comment:
It is interesting to note that this nourishment mechanism seems to be available on demand. The author is not clear on where the ‘storage area’ may be.

Thus, even though studies by Urban et al (1978), suggest that interdiscal solute transport is predominantly passive diffusion, and extradiscal solute exchange is from the periphery of the anulus and the end plates, the role of movement in facilitating the processes of nourishment is important and needs to be taken into consideration in most cases of disc degeneration.

In a study on disc repair with movement, Sengupta (2004) states that if a favourable environment is created in the motion segment, by unloading the disc and permitting near normal motion, the disc may be able to repair itself. This observation has been confirmed by Cramer et al (2004) in a study on a small animal model, where fixing movement at the interspinous level caused discal narrowing and restoring movement caused the disc to regain its original size.

2.2.4 Cartilage

The cartilage degeneration of osteoarthritis (OA) is progressive and may not be associated with clinical symptoms in the early stages (Smith et al, 1988). Bland and Cooper (1954) stated that the mammalian synovial joint does not show wear and tear unless subjected to severe malalignment, trauma or excessive loads as the co-efficient of joint friction is similar to that of ice sliding on ice. The reference to malalignment should be seen in parallel with malfunction, as alignment and function are interdependent. It is; therefore, appropriate to assume that a functional joint is also a well aligned joint. This view is further supported by Smith et al, 1988, where they state that the perceived association between physical training and OA is due instead, to joint injury and malalignment.

Reynolds (1975) exercised non chondro-dystrophic dogs at various intervals and in a variety of ways and found that the nutrition to the discs was enhanced by exercise as compared to a control group just sitting in cages. Interestingly, more frequent or more violent exercise did not further enhance the nutrition or transport of solutes into or out of the disc. The matter of lack of movement and immobilisation is again considered and the detrimental effects to disc viscosity is emphasised. (Cole et al, 1985; Holm and Nachemson, 1982)

Comment:
The author is of the opinion that disc narrowing is not necessarily also disc degeneration. The term degeneration is used loosely to describe any condition associated with discal change. For the purpose of better description, the following terminology is suggested: (See annexture)

1) Physiological Disc Narrowing

The intervertebral disc decreases in height under axial loading and returns to its previous state in unloading. This narrowing or altered state is not degenerative but dysfunctional and is regained when the unit regains function again.

The imbibition pressure of the nucleus is considerable since it can reach 250mm Hg. With age, the water absorbing ability of the disc decreases, reducing its state of preloading. This explains the loss of height and flexibility in the aged (Kapandji 1974).

2) Pathological Disc Narrowing

According to Dorlands Illustrated Medical Dictionary, degeneration is "a change of tissue to a lower or less functionally active form." This implies that degeneration is a more pathological state of irreversible change. Maintained physiological narrowing over extended periods can pre-empt disc degeneration and it will impair disc nutrition. Degeneration in turn can lead to fissuring in the anulus, herniation of the nucleus pulposus through the fissure in the anular ring leading to eventual bulging and rupture of the anulus.

3) Discal Lesion

Dorland's description of a *lesion* is "any pathological or discontinuity of tissue or loss of function of a part".

This is probably the more correct term to use unless the exact state of the disc is known. It incorporates both physiological and degenerative/pathological disc narrowing and thus not specific in the origin of the condition.

2.3 Conclusion

The foregoing discussion supports the purpose of this study, in that the intervertebral disc is to be regarded as a dynamic structure that maintains its viscosity by a process of imbibing and expelling solutes by means of pressure gradients and osmosis and that **movement** is a prime factor in the disc nourishment.