

https://dspace.org/

The healing of circumscribed defects in the mandibles of albino rats

Retief, D. H.; Cleaton-Jones, P. E.

1970

http://hdl.handle.net/10539/19576

Retief,D.H., Cleaton-Jones, P.E.1970. The healing of circumscribed defects in the mandibles of albino rats. Journal of the dental association of South Africa;25(2):34-41

Downloaded from a DSpace repository. https://dspace.org/

THE Journal OF THE D.A.S.A.

DIE Tydskrif VAN DIE T.V.S.A.

FEB., 1970

VOL. 25, No. 2

THE HEALING OF CIRCUMSCRIBED DEFECTS IN THE MANDIBLES OF ALBINO RATS

D. H. RETIEF AND P. E. CLEATON-JONES

Dental Research Unit of the University of the Witwatersrand and the South African Medical Research Council, Johannesburg.

NUMEROUS papers have been published on the repair of circumscribed defects in a number of bones of experimental animals (Melcher and Irving 1962; Kramer, Killey and Wright 1968; Ågsen 1968).

The repair of extraction wounds in the jaws of experimental animals has also been extensively studied (Huebsch *et al* 1952; Boyne and Kruger 1962; Pietrokovski 1967; Tudo 1968; Huebsch and Hansen 1969; Mesrobian and Shklar 1969), as has the healing of mandibular defects associated with operative procedures (Thompson 1958; Costich, Youngblood and Walden 1964). Melcher (1967) described the wound repair in the periodontium of the rat incisor; and Retief and Dreyer (1967) described the healing of circumscribed defects in the rat mandible associated with local neural damage.

The present study was undertaken to elucidate the repair mechanism of circumscribed defects in the rat mandible.

MATERIALS AND METHODS

Eighty Albino rats (Wistar strain) of both sexes ranging in weight from 150-250 grammes were used. The operations were performed under either open ether or neurolept anaesthesia ("Hypnorm"—N V Philips—Duphar, 0.2 ml/100 gm body weight).

To expose the underlying muscles, a longitudinal midline incision, approximately 2.0 cm long, was made in the skin of the ventral aspect of the neck extending from the symphysis menti towards the sternum. The underlying digastric and superficial masseter muscles were separated by blunt dissection and the tendinous insertion of the deep masseteric muscle on the oblique masseteric ridge exposed. This was then cut and reflected to expose the lateral aspect of the mandible. Using a slowly-running, water-cooled No. 3 round bur, defects were made in the mandible on both sides just above the masseteric ridge and in line with the distal root of the first molar (Fig. 1). This technique enabled it to be achieved with a single skin incision. The depth of the defects was about two-thirds of the diameter of the bur head; this ensured that it extended through the cortex into the medullary bone. The defects were cleared of debris, the overlying soft tissues approximated, and the digastric and masseteric muscles sutured with catgut. The skin incisions were sutured with silk. The animals were housed in separate cages and allowed food and water *ad libitum*.

The animals were sacrificed by means of coal gas—at weekly intervals for the

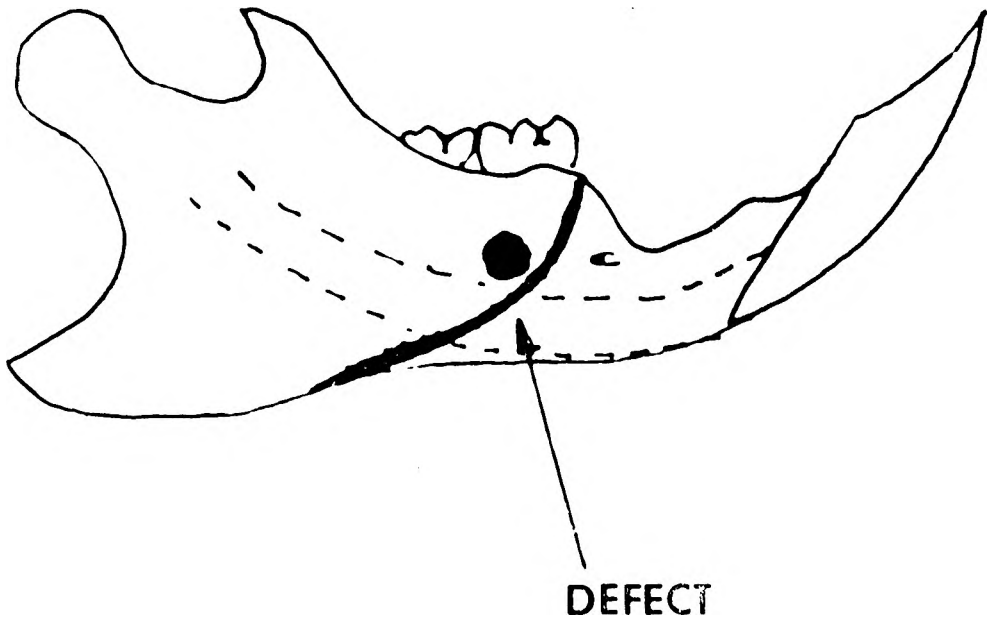

FIG. 1. The position of the defect above the oblique masseteric ridge and in line with the distal root of the first molar.



FIG. 2.—Defect in mandible of rat one week after operation. The defect is completely filled with endosteal callus. The margins of the defect are indicated by arrows. (× 96).

first eight weeks, and thereafter at three- and six-monthly periods. The mandibles were removed, fixed in formol-saline, decalcified in nitric acid and eventually embedded in wax. Serial transverse sections, 6.0 microns thick, were cut and stained with haematoxylin and eosin and Masson's trichrome.

RESULTS

One week.

At this early stage the defect was already completely filled with endosteal callus arising from the cut medullary trabeculae in its floor and from the cut cortical bone at its margins (Fig. 2). The trabeculae of the endosteal callus were laid down perpendicular to the floor of the defect. They were covered by squat osteoblasts, and there was active bone formation throughout the defect.

The spaces between the endosteal trabeculae were filled with a loose connective tissue containing many thin-walled blood vessels.

There was no evidence of periosteal callus formation at or near the margins of the defect.

Two weeks.

A marked proliferation of periosteal callus at both margins of the defect had covered the underlying endosteal callus and thus completely bridged it (Fig. 3). Active bone formation was still present below the periosteum, and the periosteal callus had projected beyond the margins of the defect.

The bony trabeculae within the defect were covered by flattened and apparently inactive osteoblasts.

The spaces between the trabeculae were still filled with loose connective tissue. The blood vessels appeared more numerous.

The cortex of the mandible adjacent to the defect contained many blood vessels around which there was perivascular bone resorption.

No osteoclasts were seen in the defect or were associated with the perivascular resorption adjacent to it.

Three weeks.

The defect was filled with bony trabeculae which projected beyond its margins.

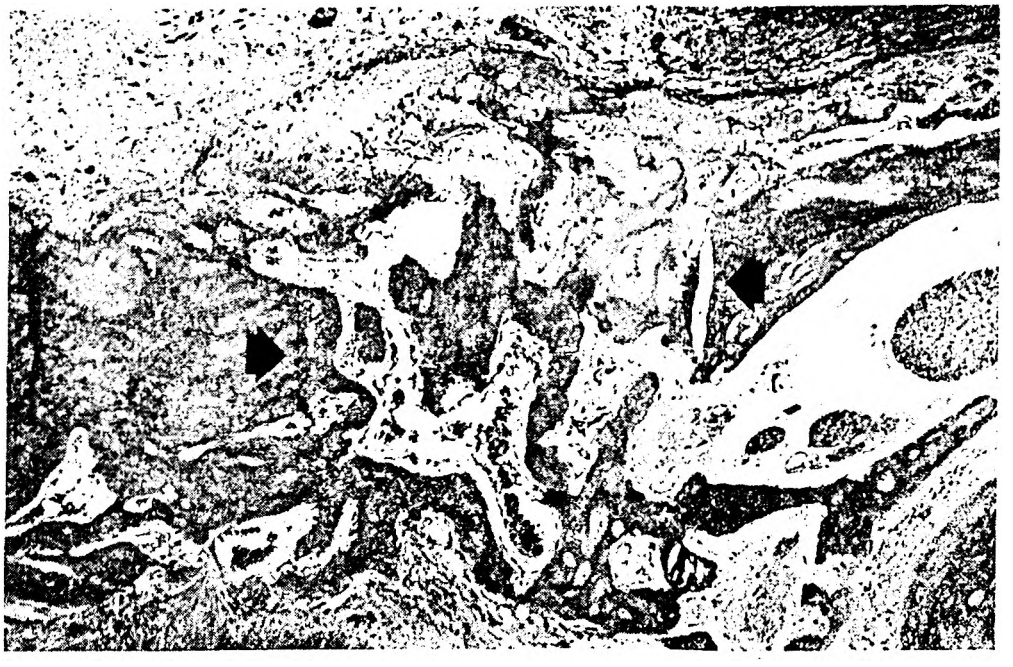

FIG. 3. Defect in mandible of rat two weeks after operation. The defect has been filled and bridged by proliferation of bone from the endosteal and periosteal surfaces. (× 64).

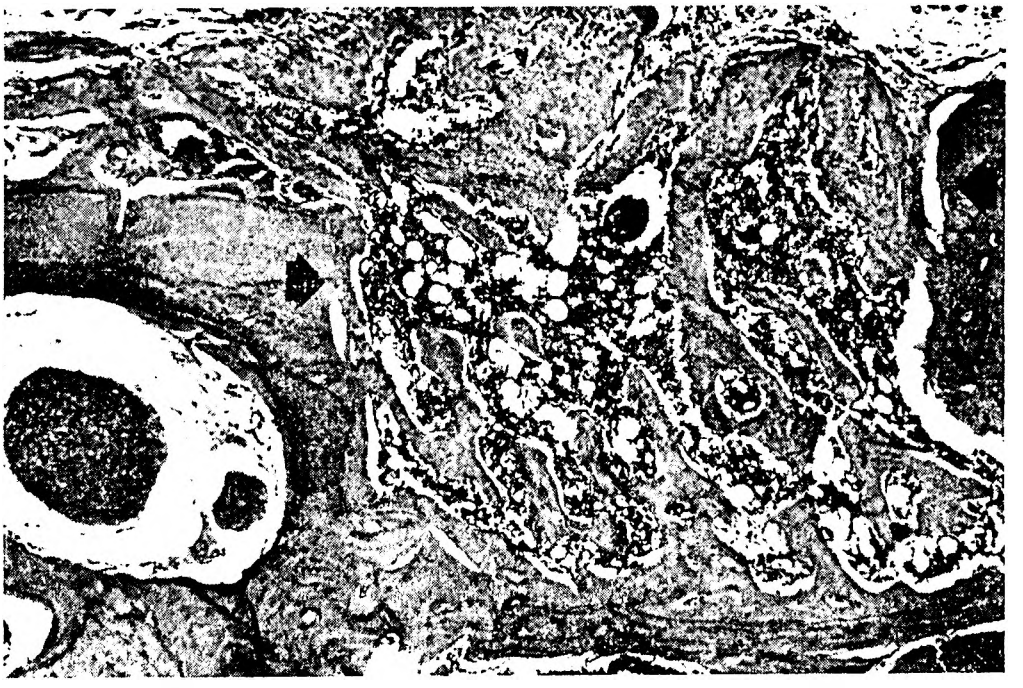

FIG. 4. Defect in mandible of rat three weeks after operation. The spaces between the trabeculae are filled by bone marrow. (× 64).



FIG. 5. Defect in mandible of rat six weeks after operation. A more compact type of bone is present. (× 64).



FIG. 6.—A higher magnification from Fig. 5 showing perivascular bone activity. (× 400).

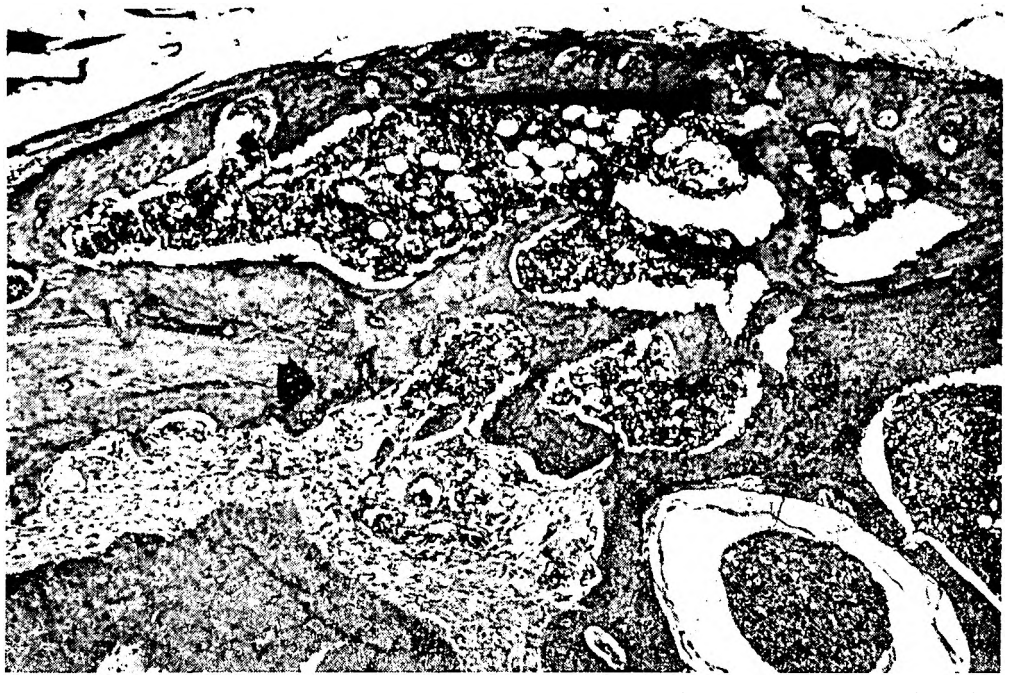

FIG. 7. Defect in mandible of rat three months after operation. A marked subperiosteal bulge above the defect is still present. (× 64).

There was no evidence of active new bone formation (Fig. 4).

Active haemopoietic tissue had replaced the loose connective tissue between the trabeculae in the defect and perivascular resorption had partly obliterated the cement line at its upper margin.

Six weeks.

There was remodelling of the bone within the defect and the callus still projected beyond its margins (Fig. 5). Active perivascular bone resorption and deposition was seen throughout the callus (Fig. 6).

Three months.

A greater degree of remodelling had taken place, but the original contour of the mandible had not yet been restored (Fig. 7).

Six months.

The defect was filled with compact bone and the contour of the mandible had returned practically to normal. In places the cement lines, indicating the junction of the callus with the bone at the margins of the defect, could still be seen.

DISCUSSION

In the Albino rat, during the first seven days after operation, organisation of the haematoma, maturation of the granulation tissue and proliferation of osteoblasts occur in the defect. The healing during this period was not studied in this series.

The healing of defects communicating with the oral cavity may be affected by its bacterial flora or by impaction of food debris; this was demonstrated by Mesrobian *et al* (1969) who showed that a marked inflammatory response influences the initial stage of the healing of extraction wounds in Syrian hamsters. Thus an extraoral approach for the preparation of the mandibular defects was used.

Thompson (1958) showed that a bur speed of 500 r.p.m. produces hardly any degeneration of the osteocytes in the bone adjoining defects prepared in the mandibles of dogs. If the speed was too slow,

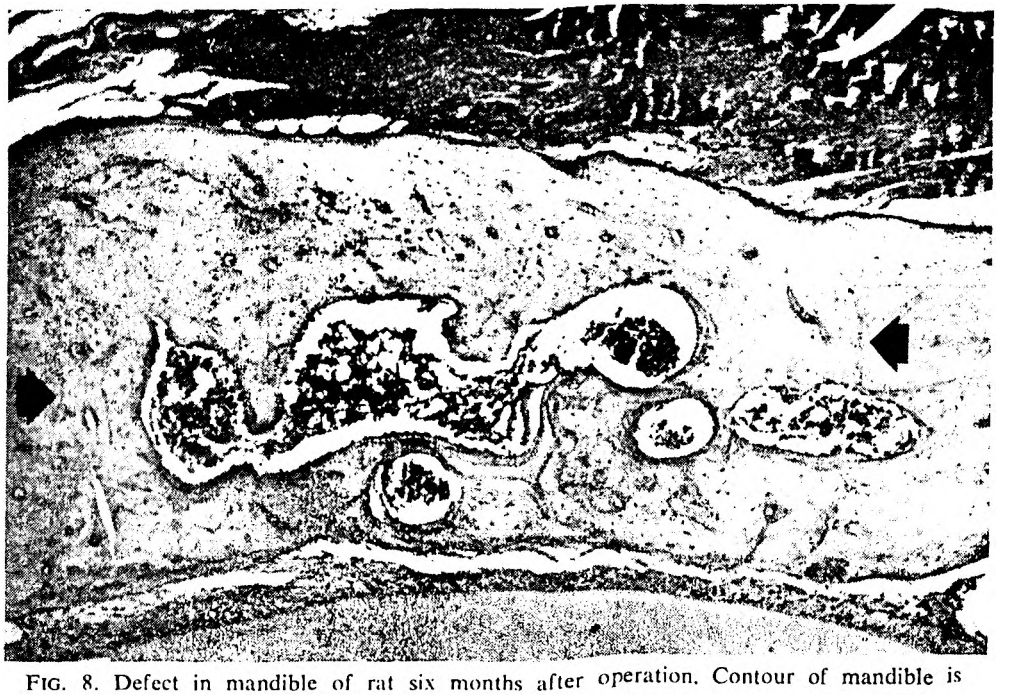

FIG. 8. Defect in mandible of rat six months after operation. Contour of mandible is practically returned to normal. (× 64).

however, fragmentation of the margins of the defect was observed. The degeneration that occurred at higher speeds varied from slight, as revealed by a lighter staining of the cytoplasm and by pyknosis, to complete disintegration of the osteocytes, leaving the lacunae adjoining the margins of the defect devoid of cellular elements. During the preparation of the defects in this series the bur was run at a slow speed and cooled with water. In only a few sections was there evidence of mild thermal necrosis of bone as manifested by empty lacunae in the bone adjoining some of the defects.

The defect has to be positioned carefully. If it is prepared too far above the masseteric ridge, the underlying inferior alveolar nerve might suffer injury. Retief and Dreyer (1967) described the effect of local neural damage on the repair of mandibular defects in the rat and showed that it completely altered and adversely affected the healing pattern. Whenever subsequent microscopic examination revealed that the inferior alveolar nerve had been damaged during the preparation of the defect, the specimen was not included in this study. If the defect is made too far posteriorly above the oblique masseteric ridge the underlying continuously erupting incisor might be damaged. Melcher (1967) showed that the defect, when penetrating that tooth, was not occluded by healing callus 42 days later.

In his study of the repair of femoral defects in rats, Melcher (1962) described the presence of cartilage between the bone trabeculae and the fibrous layer of the periosteum in almost all of them; and he found that in a number of them it formed the full thickness of the leading edge of the subperiosteal callus. Chondrogenesis does not form part of the healing of mandibular defects in the rat.

During the remodelling of the callus in mandibular defects, no osteoclasts were seen in association with its resorption. Because of the transient nature of these cells it is not implied that osteoclasts play no part in the remodelling of the callus but the authors were not able to demonstrate their presence. Their observations in this study indicate that remodelling is a perivascular phenomenon. From the third week onwards numerous areas of resorption around blood vessels are present followed at a later stage by perivascular new bone formation.

It is accepted that in the repair of fractures of long bones both the periosteum and endosteum are of great importance whereas in the healing of a cavity in a bone the periosteum plays little or no part while the cells of the endosteum and bone marrow play a more important role (Kramer 1968). Melcher (1962) described the early appearance of periosteal callus during the healing of femoral defects in rats. In his study endosteal callus was initiated after the subperiosteal callus had begun to develop and the periosteal callus reached the margin of the defect before endosteal callus proliferation had filled the defect. The healing pattern is different during the repair of mandibular defects in rats. The endosteal callus is the first to appear and proliferates to such an extent that the defect is completely filled at one week. At this stage there is no evidence of periosteal callus formation near the margins of the defect. Only later does its formation commence, but it then proliferates rapidly and by two weeks it extends over the underlying endosteal callus to bridge the defect completely.

Subsequent remodelling up to six months after operation appears to be perivascular.

SUMMARY

The healing pattern of circumscribed defects in the mandibles of Albino rats is described.

Endosteal callus plays the major role and fills the defect within one week after operation. Only then does the periosteal callus proliferate to bridge the defect by the second week.

Remodelling appears to be perivascular and by six months the original contour of the mandible is restored.

REFERENCES

AGSEN, E. High-speed or conventional dental equipment for the removal of bone in oral surgery. Acta Odont. Scand., 26: 223-246, 1968.

BOYNE, P. J. and KRUGER, G. O. Fluorescence microscopy of alveolar bone repair. Oral Surg., Oral Med. and Oral Path., 15 (3): 265-281, 1962.

COSTITCH, E. R., YOUNGBLOOD, P. J. and WALDEN, J. M. A study of the effects of highspeed rotary instruments on bone repair in dogs. Oral Surg., Oral Med. and Oral Path., 17 (5): 563-571, 1964.

HUEBSCH, R. F., COLEMAN, R. D., FRANDSEN, A. M. and BECKS, H. The healing process following molar extractions. I Normal male rats. Oral Surg., Oral Med. and Oral Path., 5:864-876, 1952.

HUEBSCH, R. F. and HANSEN, L. S. A histopathologic study of extraction wounds in dogs. Oral Surg., Oral Med. and Oral Path., 28 (2):187-196, 1969.

KRAMER, I. R. H., KILLEY, H. C. and WRIGHT, H. C. A histological and radiological comparison of the healing of defects in the rabbit calvarium with and without implanted heterogeneous anorganic bone. Archs. oral Biol., 13:1095-1106, 1968.

KRAMER, I. R. H., KILLEY, H. C. and WRIGHT, H. C. The replacement of bone. Austr. dent. J. 13:17-24, 1968.

MELCHER, A. H. and IRVING, J. T. The healing mechanism in artificially created circumscribed defects in the femora of albino rats. J. Bone & Joint Surg., 44B(4):928-936, 1962.

MELCHER, A. H. Wound repair in the periodontium of the rat incisor. Archs. oral Biol., 12:1645-1647, 1967.

MESROBIAN, A. Z. and SHKLAR, G. The effects of dietary zinc sulfate supplements on the healing of experimental extraction wounds. Oral Surg., Oral Med. and Oral Path., 28 (2):259-265, 1969.

PIETROKOVSKI, J. Extraction wound healing after tooth fracture in rats. J. dent. Res., 46 (1):232-240, 1967.

RETIEF, D. H. and DREYER, C. J. Effects of neural damage on the repair of bony defects in the rat. Archs. oral Biol., 12: 1035-1039, 1967.

THOMPSON, H. C. Effect of drilling directly into bone. J. oral Surg., 16:22-30, 1958.

TUDO, H. Healing mechanism of tooth extraction wounds in rats. Archs. oral Biol., 13: 1429-1443, 1968.

BURNING TONGUE IN OLDER PATIENTS

ARTHUR ELFENBAUM, D.D.S.

Reproduced from the J. Canad. dent. Assn, 35:10, with due acknowledgments to the author and publishers

Burning tongue, a manifestation of glossitis is most commonly a sympton of disease elsewhere. Prominent systemic causes include avitaminosis, particularly of the B group, and anaemia, including pernicious anaemia, iron deficiency anaemia and Plummer-Vinson syndrome with dysphagia. Since the tongue often serves as a mirror of disease elsewhere, it is most important to investigate thoroughly every patient who complains of glossodynia.

MORE people attain advanced age than ever before, even though the average span of modern life is scarcely two years longer than the biblical three score and ten years. At the turn of the century, only 3 per cent of the American population was 65 or more years old. That proportion has more than tripled during the intervening years and may soon exceed 12 per cent of the general population which is also growing rapidly. To dentistry this means more elderly patients in most offices and that geriatric dentistry will become an important phase of clinical practice.

One of the most challenging disorders in older patients is glossodynia [*glosso-* + *οδυνη* pain]. At one time glossodynia was also known as glossopyrosis [*glosso-* + *πυρωσις* burning].

CLINICAL FEATURES

Patients who complain of glossodynia are generally in the climacteric years of life, known in women as the menopausal and post-menopausal periods. If glossodynia occurs in a younger woman, the patient has likely had a hysterectomy so that the resulting induced menopause interferes with the secretion of the sex hormones.

Before he examines a patient with glossodynia, the dentist must obtain a detailed dental and medical history. It is important to ascertain the onset, duration and character of the symptoms. What causes a remission or exacerbation? Are there