

https://dspace.org/

Does repeat large loop excision of the transformation zone (LLETZ) achieve a cure for histologically proven persistent HGSIL at margins?

May, Jabulile,

2021

https://hdl.handle.net/10539/32407

May, Jabulile (2020) Does repeat large loop excision of the transformation zone (LLETZ) achieve a cure for histologically proven persistent HGSIL at margins? University of the Witwatersrand, Johannesburg, <http://hdl.handle.net/10539/32407>

Downloaded from a DSpace repository. https://dspace.org/

DOES REPEAT LARGE LOOP EXCISION OF THE TRANSFORMATION ZONE (LLETZ) ACHIEVE A CURE FOR HISTOLOGICALLY PROVEN PERSISTENT HGSIL AT MARGINS?

May Jabulile

Student No: 1933372

Department of Obstetrics and Gynaecology, Charlotte Maxeke Johannesburg Academic Hospital, University of Witwatersrand, Johannesburg, South Africa

2020

DECLARATION

I, Jabulile May declare that this research report is my own, unaided work. It is being submitted for the Masters in medicine in Obstetrics and Gynaecology at the University of the Witwatersrand, Johannesburg. It has not been submitted before for any degree or examination at any other University.

Signature _____

____Day of _____20___ in _____

ABSTRACT

Background

Cervical cancer is the second most common malignant neoplasm in women world-wide. CIN is a precursor lesion of cervical cancer and effective treatment of this lesion can prevent progression to cervical cancer. LLETZ has been shown to be effective treatment for CIN lesions with minimal complications. The aim of this study was to establish if repeat LLETZ achieves a cure for histologically proven persistent high grade CIN lesions at margins.

Study Design

This was a retrospective quantitative descriptive study, done at the Charlotte Maxeke Johannesburg Academic Hospital colposcopy clinic in South Africa. Data were collected from patient files (1500) seen at the colposcopy clinic for a period of 10 years (2006-2016). These were patients who initially had HGSIL, were treated using LLETZ and the repeat cytology showed persistent HGSIL, so they subsequently had a second LLETZ done. A total of 71 patients met the inclusion criteria.

Results

Overall, HGSIL (reported as CIN2, 3 and HGSIL) was found in 74.6% of the women at the second/repeat LLETZ and 22.1% had LGSIL (reported as CIN1 and LGSIL). Ecto-cervical margins were positive in 5 (8.5%) of the patients who had the initial LLETZ biopsy, negative in 3 (5.1%) and unreported in 1 (1.7%). Compared to positive margins in 8 (13.6%), negative margins in 15 (37.3%) and unreported in 3 (5.1%) at the second LLETZ.

Endo-cervical margins were positive in 17 (28.8%) of patients who had an initial LLETZ biopsy as compared to 11 (18.6%) at the second LLETZ. This showed an improvement of 35.4% from the first to the second biopsy. In 55.9% of patients, there was both ecto-cervical and endo-cervical margin involvement post the initial LLETZ as compared to 37.3% post repeat LLETZ. This was an improvement of about 33.3% post repeat LLETZ.

There was no association between previous ecto-margins status (Pearson chi2 (98) = 106.7434 Pr = 0.257), previous endo-margins status (Pearson chi2 (10) = 2.8432 Pr = 0.985), both ecto and endo-margins status (Pearson chi2 (98) = 109.7042 Pr = 0.197) of the initial LLETZ and repeated LLETZ margin status. The cytology results post LLETZ had 22 (37.3%) patients with persistent HGSIL, 1 (1.7%) ASCUS-H, 21 (35.6%) LGSIL, 2(3.4%) ASCUS and 13 (22.0%) had normal cytology report. There was regression of the lesions in 61.0% of women post second LLETZ.

Conclusion

Patients above 35 years of age with positive margins are at high risk or persistent CIN lesions as opposed to younger patient and those with negative margins. Repeat LLETZ offers improvement in margins (endo- and ecto - cervical) status, but it doesn't offer a complete cure. It reduced the positive margin status and increased negative repeat cytology findings.

ACKNOWLEDGEMENTS

I would like to thank my supervisor Dr Langanani Mbodi for the motivation, patience, and relentless support throughout this whole journey.

To my family, a special thank you, for their continued support during this process and learning experience.

LIST OF ABBREVIATIONS

AGC	Atypical Glandular Cells
AGS-NOS	Atypical Glandular Cells – Not Otherwise Specified
ASCCP	American Society for Colposcopy and Cervical Pathology
ASC-US	Atypical Squamous Cells of Undetermined Significance
ASC-H	Atypical Squamous Cells - Cannot Exclude HGSIL
CSS	Cause Specific Survival
CIN	Cervical Intraepithelial Neoplasia
CMJAH	Charlotte Maxeke Johannesburg Academic Hospital
CEO	Chief Executive Officer
CKC	Cold Knife Conization
HGSIL/HSIL	High Grade Squamous Intraepithelial Lesion
HIV	Human Immunodeficiency Virus
HPV	Human Papilloma Virus
FIGO	International Federation of Obstetrics and Gynaecology
LLETZ	Large Loop Excision of the Transformation Zone
LGSIL/LSIL	Low Grade Squamous Intraepithelial Lesion
NHLS	National Health Laboratory Services
NILM	Negative for Intraepithelial Lesion or Malignancy
OS	Overall Survival
PAP- SMEAR	Papanicolaou smear
PFS	Progression Free Survival

RCI	Reid's Colposcopic Index
SAS	Statistical Analysis Software
SCC	Squamous Cell Carcinoma
TZ	Transformation Zone
WITS	University of Witwatersrand
WHO	World Health Organisation
WHREC	Wits Human Research Ethics Committee

TABLE OF CONTENTS

Declaration ……. i

Abstract …… ii - iii

Acknowledgements ……. iv

List of Abbreviations …….. v- vi

List of Tables ……. ix

List of Figures…… x

Chapter 1: Protocol, Literature Review and Justification of the study……1

1.1 Introduction and Background ……. 1-4

1.2 Management of cervical intra-epithelial lesions ……..... 5-6

1.3 Reid's colposcopic index…… 7-8

1.4 The rate of disease persistence / positive margins…….. 9

1.5 Persistence of disease after second/ repeat LLETZ……..10

1.6 Justification of the Study……..11-16

1.7 References ……17-19

Chapter 2 (Submissible Article) …………20

Abstract……21-22

2.1 Introduction……23-24

2.2 Research methodology……25-26

2.3 Colposcopy and LLETZ procedure……26-27

Chapter 3……..28

Results

3.1 Study population and exclusions……28

3.2 Demographics ……..29

3.3 Risk factors ……30

3.4 Referral criteria……30

3.5 LLETZ procedure……31-33

3.6 LLETZ and Margin status……34-36

3.7 HPV Status……36

3.8 Papanicolaou Smear post LLETZ ……36

3.9 HIV Status vs Pap smear after repeat LLETZ……37

Chapter 4: Discussion……38-40

Chapter 5: Limitation and Recommendations……41

Chapter 6: Conclusion……42

References……43-44

Annexures…….

A: Data collection sheet…… 45-48

B: HREC Clearance Certificate…… 49

C: Colposcopy Clinic Clerking Sheet…… 50-51

D: Permission Letter from the CEO of CMJAH…… 52

LIST OF TABLES

Table 1.1: The natural history of Squamous Intraepithelial Neoplasia

Table 1.2: SASOG guidelines for cervical cancer screening in South Africa (2015)

Table 1.3: Recommendations for the treatment of cervical intra-epithelial lesions

Table 1.4: The Reid Colposcopy Index

Table 3.1: Histology results as reported post second LLETZ

Table 3.2: Table showing the cytology results post second LLETZ

LIST OF FIGURES

Figure 3.1: Flow diagram showing the study population and exclusions

Figure 3.2: Chart showing the percentage distribution of patients according to reproductive age

Figure 3.3: Chart showing the colposcopy findings in numbers, at both first and second colposcopy examinations

Figure 3.4: Chart showing the involvement of ecto-cervical margins at both LLETZ biopsies

Figure 3.5: Chart showing the involvement of endo-cervical margins at both LLETZ biopsies

Figure 3.6: A graph illustrating the involvement of both margins at LLETZ biopsy

Figure 3.7: Pap smear results against HIV status

CHAPTER 1: LITERATURE REVIEW

1.1 INTRODUCTION AND BACKGROUND

Cervical cancer is the second most common malignant neoplasm in women worldwide. [1] Cervical intraepithelial neoplasia (CIN) is a precursor lesion of cervical cancer and is classified by histology as CIN 1, CIN 2, or CIN 3. Cervical screening using cytology combined with Human Papilloma virus (HPV) testing has resulted in a considerable increase in the number of women diagnosed with CIN in recent decades. [2]

CIN2 and CIN3 are equivalent to high grade squamous intra-epithelial lesions (HGSIL) as per Bethesda Classification system (2001) used to classify the results of the Papanicolaou smear (Pap smear). The Bethesda system is used to differentiate between the high risk and low risk intra-epithelial lesions. There is significant evidence that CIN lesions in conjunction with persistent high-risk HPV (types 16/18/31, etc.) infection that are not treated, progress to cervical cancer. The rate of progression is almost double in immune-compromised women. [3] Therefore, treatment of these lesions is necessary in order to prevent significant morbidity and mortality.

High-grade squamous intraepithelial lesion is a common pre-neoplastic condition of the cervix that encompasses moderate (CIN 2) or severe (CIN 3) dysplasia. Large Loop Excision of the Transformation zone (LLETZ) biopsies were introduced in 1989 by Prendiville et al, to treat lesions that could be visualized by colposcopy. Depending on the type of transformation zone and the extent of the lesion, the lesion could either be ablated or excised. Ablative therapy can be used for patients with Type 1 transformation zone lesion, where the whole transformation zone is visible and in the ecto-cervical region. Type 2 and 3 transformation zone lesions needs excision. [4]

LLETZ has been proven to be a safe method for treating lesions that involve the endocervix and has several advantages over cold-knife conization, including shorter operating times, less blood loss, and fewer complications overall. [4]

Table 1.1.: The natural history of Squamous Intra-epithelial Lesions [5]

Baseline cytology	**Regression at 24 months**	**Progression to HSIL at 24 months**	**Progression to invasive cancer**
ASCUS	68.2%	7.1%	0.3%
LSIL	47.4%	20.8%	0.2%
HSIL	35.0%	23.4% (persistence)	1.4%

‘

The table above illustrates the probability of pre-cancer lesions becoming invasive. The rate of regression lowers as severity increases although some studies suggest progression rate as high as 50% for HSIL and 1% for LSIL, hence the need to treat and further follow up HSIL. [5, 6]

The prognosis of CIN 1/ low grade squamous intraepithelial lesion (LGSIL) is very good and a high number of patients show regression to normal (70-80%).[5] Other studies have shown that young patients with CIN 2, can be treated conservatively, if under the age of 30 years. A regression of 57% and a progression to CIN 3 of 13% was seen in patients who were treated with just colposcopy and punch biopsies. [7]

The possibility of detecting high grade lesions is highest if women are screened between 35-45 years of age, and the mean age for detection of CIN 2 is 35 years and CIN 3 is 40 years.[8] Invasive cancers are rare before the age of 30, therefore the WHO recommends initiation of screening at the age of 30 in developing countries.[8]

The HIV infected women have a greater risk of having multiple high-risk HPV infections and faster progression to high grade lesions compared to HIV negative women. Women infected with HIV or having AIDS, had a 20 times higher rate risk of getting invasive cervical cancer compared to the HIV negative patients in a cancer registry and AIDS registry linkage study in Italy.[8] It is recommended that HIV positive women should undergo cervical cancer screening as soon as their HIV status is known.[10]

LLETZ has a cure rate of more than 90% to treat CIN 2/3 lesions. Cone biopsy is rarely performed for CIN lesion treatment, because it requires regional or general anaesthesia and hospitalisation, and has a higher rate of complications. The only indications for cold knife conization are, biopsy proven micro-invasive cancer or adenocarcinoma in situ, conditions that require meticulous microscopic evaluation of the cone specimen. Hysterectomy is not required to treat CIN lesions.[8]

Cone biopsy is said to be better in patient that have adenocarcinoma in situ because the specimen is usually larger and deeper cut as compared to a LLETZ. The risk for premature labour is higher post cone biopsy in pre-menopausal women, as compared to LLETZ in the same group.[9] In most post-menopausal patients and those who have completed their families, hysterectomy is deemed to be the better intervention [3].

Table 1.2: SASOG guidelines for cervical cancer screening in South Africa (2015).[11]

	LOW RESOURCE	HIGH RESOURCE
Initiate screen:	Age 25 At diagnosis of HIV positivity	Age 25 At diagnosis of HIV positivity
End screen:	Age 55 or hysterectomy Only after previous negative tests Never end if HIV positive	Age 65 or hysterectomy Only after previous negative tests Never end if HIV positive
Interval - HPV test	10 years if HIV negative or unknown 5 years if HIV positive	5 years if HIV neg or unknown 3 years if HIV positive
Interval - cytology	5 years if HIV negative or unknown 3 years if HIV positive	3 years if HIV negative or unknown Yearly if HIV positive
Timing:	Ten-yearly: At ages 25, 35, 45, 55 Five yearly: Also at ages 30, 40, 50. Three yearly: At ages 25, 28, 30, 33, 36, 40, 43, 46, etc.	Five yearly: Also at ages 30, 40, 50. Three yearly: At ages 25, 28, 30, 33, 36, 40, 43, 46, etc. Yearly: each year
Follow-up:	After single abnormal screening test or after treatment: • HIV negative and < 35 years: 5 yearly until normal. • HIV positive or > 35 years: yearly until normal. Back to SCREEN when normal Treat after second abnormal test	After single abnormal screening test or after treatment: • HIV negative and < 35 years: yearly until normal. • HIV positive or > 35 years: yearly until normal. Back to SCREEN when normal Treat after second abnormal test

Adapted from SASOG guidelines [11]

Human Papilloma Virus (HPV) and Cervical Intra-Epithelial Neoplasia

HPV is a critical precursor to the development of both squamous cell carcinoma and adenocarcinoma of the cervix. Approximately 90% of HPV infections clear within 2 years due to natural immunity and CIN 1 lesions disappear.[10] There is a lot of research currently on HPV testing being used in conjunction with cytology, in the follow up of patients that have been treated with LLETZ.

Human papilloma virus (HPV) persistence is associated with an increase chance of progression to cervical cancer and higher risk of recurrence of CIN post treatment. Testing for HPV is currently not available in our setting but has been shown to be a useful guide in predicting recurrence of CIN when combined with Pap smear, in the follow up of patients treated with LLETZ [2].

1.2 Management of Cervical Intra-Epithelial Lesions

The aim of the management is to prevent progression of the disease to cervical cancer. There are guidelines in different countries, based on resource availability and patient profile, which aim to assess and prevent the progression of the disease. [11]

The majority of CIN 1 lesions are due to a transient HPV infection and 60-80% resolve within 2 years especially in younger women, therefore because of the very low progression risk, the CIN 1 lesions are treated only if they persist for more than 2 years and/or increase in severity. CIN 3 lesions are the true cervical cancer precursors and if left untreated, the majority of them will progress to invasive disease. Studies have demonstrated that nearly 40-64% of proven CIN 2 lesions would regress in 2 years, especially in younger women. CIN 2 associated with high risk HPV type 16 or 18 is less likely to regress and has to be treated. [8]

In South Africa, we have a burden of HIV and studies have shown that the progression of the disease in immunocompromised women is faster, compared to those with competent immune systems. The management therefore differs depending on the immune status, the age and menopausal state of the patient [3]. Post-menopausal women are followed up at 6 monthly intervals because increasing age on its own is an independent factor for recurrence of CIN [13]. The table below describes the recommended management strategies for abnormal cytology.

Table 1.3: Recommendations for the Treatment of Cervical Intra-Epithelial Lesions

RESULTS	INTERVENTION/ MANAGEMENT
NILM	Repeat In 5- 10 years
LGSIL / CIN 1 / ASC-US	Repeat Smear In 6 Month, If Persistent, For Colposcopy +- LLETZ
HGSIL / CIN2,3 / ASC-H	Colposcopy and LLETZ
AGC-NOS	Repeat Pap Smear in 3/12
AGC	Colposcopy +- Cone Biopsy
ADENOCARCINOMA IN SITU	Colposcopy +- Cone Biopsy

Adapted from Kruger TF, et al [3]

1.3 Reid's Colposcopy Index (RCI) Scoring for decision making at Colposcopy

Diagnosis and classification of dysplasia is made at colposcopy followed by biopsy or large loop excision of the transformation zone (LLETZ). When LLETZ is combined with the colposcopic examination, it offers the opportunity for diagnosis and treatment (See and treat).

It is recommended that standardized representations of colposcopy findings in a form of a drawing, using symbolic and scoring methods such as the RCI and Swede score be done. [14,15] The RCI proposed by Reid and Scalzi predicts the histological diagnosis on the basis of 4 colposcopic features.[14] A modified version of the RCI has iodine testing omitted as a parameter. A score ranging from 0 to 2 is given for every colposcopic sign and this is added to give a final score. Table 4 below explains the allocation of points for every colposcopic sign.

Table 1.4: The Reid Colposcopic Index [15]

Colposcopic Signs	0 Point	1 Point	2 Points
Colour of acetowhite (AW) area	Low intensity acetowhitening, snow-white, shiny AW, indistinct AW, transparent AW, AW beyond the transformation zone	Grey-white AW with shiny surface	Dull, oyster-white, Grey
AW lesion, margin and surface configuration	Feathered margins, angular, jagged lesions, flat lesions with indistinct margins, microcondylomatous or micro papillary surface	Regular lesions with smooth, straight outlines	Rolled, peeling edges, internal demarcations (a central area of high-grade change and peripheral area of low-grade change)
Vessels	Fine/uniform vessels, poorly formed patterns of fine punctations and or fine mosaic, vessels beyond the margin of the transformation zone; fine vessels within microcondylomatous or micro papillary lesions	Absent vessels	Well defined coarse punctuation or coarse mosaic
Iodine staining	Positive iodine uptake giving mahogany brown colour, negative uptake of lesions scoring 3 points or less on the above three categories	Partial iodine uptake by a lesion scoring – or more points on above three categories – variegated, speckled appearance	Negative iodine uptake by a lesion scoring 4 or more points on the above three criteria

A total score of 0 to 2 points is likely to be CIN 1; 3 to 4 is an overlapping lesion: likely CIN 1-2; 5 to 8 likely to be CIN 2-3 lesions.

1.4 The Rate of Disease Persistence/Positive Margins

A strong relationship has been established between high risk HPV types 16 and 18, and cervical intraepithelial lesions and cancer. The therapeutic outcomes of a LLETZ have been found to be similar to a cone biopsy[1].

Several studies have investigated the recurrence rate following LLETZ and it was found to range from 11.3% to 54%. [1, 12, 16, 17, 18] The factors associated with recurrence are age (independent predictor), positive margins on previous LLETZ specimens [13] and women with persistent high-risk human papilloma virus infection. [15] The recurrence rate is 4.6 times higher in patients more than 35 years of age compared to those less than 35 years of age [13]. A study done in the United Kingdom found that in women older than 50 years of age, the time of recurrence was 73, 2 months, and 47.2 months in those with positive margins. Therefore, the British guidelines (2004) state that women with high grade lesions at an age more than 50 years should have a repeat LLETZ. [19]

A positive margin after LLETZ (defined by histopathology) is a well-defined predictor of persistent or recurrent disease and regression after HSIL is much lower as compared to LSIL. It is thus reasonable to assume that patients with HSIL are more likely to have persistence or recurrence than patients with LSIL: therefore, a wait and see approach would carry a high risk for persistence in patients with HSIL at the margins.[13]

Current international guidelines suggest that patients who have had a LLETZ procedure done should be followed up in 4 to 6 months by cytology with or without colposcopy, then cytology and HPV testing in 12 months, then yearly for 2 years until the results are negative [20]. One study found that patients who had a repeat colposcopy at less than 6 months post LLETZ, were most likely to have an unsatisfactory colposcopy (22%) because of the residual damage from the previous intervention, therefore the advice was to have a repeat cytology at 6 months, then colposcopy at 12 months with HPV testing [2].

1.5 Persistence of Disease after Second/Repeat LLETZ

According to the American Society for Colposcopy and Cervical Pathology (ASCCP) guidelines: "If CIN2, 3 is identified at the margins of an excisional procedure or post endocervical curettage (ECC) procedure, cytology and ECC at 4–6 month is preferred, but repeat excision is acceptable and hysterectomy is acceptable if re-excision is not feasible".[13]

There is no strong association between the type of transformation zone (TZ) and incomplete excision, but there is a good association with the size of such TZs. In large type 2 and large type 3 TZs, there is an almost doubling in the risk of incomplete excision when compared to small type 1 TZs. When presented with a large type 2 or 3 TZ that needs excision, it is recommended that larger removals should be performed and women counselled accordingly.[9]

Zhu M et al (2015), on their study in China, found that the rates of HGSIL persistence/recurrence in patients who had a subsequent LLETZ and hysterectomy were 31.82 % (7/22) and 20.90 % (14/67), respectively, while that in patients who were selected for close follow-up (cytology or cytology combined with colposcopy-guided biopsy) was 4.02 % (6/149). The predictive factors for persistence/recurrence in a group of patients with HGSIL and HGSIL-involved margins were the patients' age and diameter of the tumour (size). The age more than 35 years was the only independent predictive factor. [13]

A study done in Turkey showed that the risk factors for persistence of CIN2 AND 3 disease, was multiple sweeps needed during conisation of the initial lesion, the lesion covering more than 50% of the cervical circumference and positive margins at histology. [21]

It is still unclear why older women may be more susceptible to persistence or recurrent disease. One possible reason may be altered immunity or positive selection over time towards higher oncogenic risk. In clinical practice, patients below 35 years of age often desire fertility or uterus preservation, thus conservative management is usually considered during follow up. Therefore, patients who are younger than 35 years need close follow up post LLETZ and for those who are older, a subsequent LLETZ or a carefully considered hysterectomy is reasonable.[13]

1.6 Justification of the Study

Cervical cancer is a significant cause of morbidity and mortality in women worldwide. Cervical screening guideline are already in place and there are various treatment modalities available, LLETZ being the most superior, which can be used to prevent the progression of the disease. It is common to have disease persistence at both ecto- and endocervical margins after therapeutic excision. In view of the fear of progression of HGSIL/CIN 2,3 into invasive malignancy, therapy orientated repeat LLETZ have been done on those with positive margins. Does this offer a cure? There is a need to review outcome and relevance.

The Aim of the Study

The aim of this study was to look at the effectiveness of a repeat LLETZ in patients with histologically proven positive margins on follow up, post LLETZ for HGSIL/CIN 2, 3 at Charlotte Maxeke Johannesburg Academic Hospital.

General Objectives

To determine the effectiveness of a repeat LLETZ in offering cure, following incomplete resection of the dysplastic lesions at margins at Charlotte Maxeke Johannesburg Academic Hospital Colposcopy clinic.

Specific Objectives

1. To describe the socio-demographic factors and the comorbid diseases of these patients.
2. To describe the treatment modalities offered to patients with persistent/ recurring positive margins at Charlotte Maxeke Johannesburg Academic Hospital.
3. To describe the outcome of patients who were treated with a repeat LLETZ for incomplete margins
4. To describe complications of the procedure.
5. To compare the treatment strategies (and outcome) at Charlotte Maxeke Johannesburg Academic hospital Colposcopy clinic for persistent positive margins, with those of other institutions.
6. To compare accuracy of colposcopic diagnosis with histological findings

Study Setting

The study was conducted at the CMJAH colposcopy clinic located at area 176 of the Gynaecology unit of the Department of Obstetrics and Gynaecology. Patients seen in this unit were referred by the CMJAH Gynaecology ward, area 164, level 2 hospitals within the cluster, Community Health Centres as well as Private Gynaecology and Specialized units within the CMJAH such as Transplant (Renal and Hepatic) units and other Surgical Departments. The referral criteria are as per the South African Guidelines.

Colposcopy and LLETZ were done by Oncology unit consultants and a consultant doing sessions. The clinic ran 3 days of the week. Patients records including initial assessment, histology and follow up care, are kept within the unit and were manually retrieved and sorted. A total of 120 patients were seen at the colposcopy clinic on a monthly basis (new and follow up).

Colposcopy and LLETZ Procedure

At CMJAH, the “see and treat one step approach” is undertaken on all patients who undergo colposcopy assessment. The most common procedure done during colposcopy examination of the cervix is the LLETZ.

Before the colposcopy procedure, all the patients were counselled on the indication and complications of the procedure (LLETZ) and a history of allergies ascertained. During the procedure, acetic acid was used to paint the cervix to ascertain the abnormal epithelium, which will stain white in almost all the patients. Lugol’s iodine was not often used because of the unavailability of the resource most of the time.

The areas on the cervix that stain white with the acetic acid were excised using LLETZ. The size of the loop is usually determined by the surface area that need to be removed. However, the size of the loop used was not recorded. Bleeding areas were cauterized and a betadine-soaked tampon inserted to both stop further bleeding and prevent infection. The patients were then counselled about the findings of the procedure, advised to avoid intercourse and given prophylactic oral antibiotics for 7 days.

The specimen taken was then sent for histology and the patient advised to come back in 6 months for results. Since the results were released earlier than the return date, if results reveal any abnormality or cervical cancer, the patient was called back earlier for possible repeat LLETZ/ hysterectomy. A repeat pap smear was done in 6 months after LLETZ. A repeat colposcopy and LLETZ was done if margins were involved, at the colposcopists’ discretion. If the histology showed an invasive cancer, the patient was booked for either CKC, Trachelectomy or a hysterectomy depending on the clinical stage and fertility desires. The Reid colposcopy index that considers four signs namely, lesion margin, colour/density of aceto-whitening, blood vessels, and iodine staining (12), was used.

Inclusion Criteria

- All patients who were referred to the colposcopy clinic with an initial assessment of HGSIL on cytology and had confirmation from initial LLETZ and were reported as having involvement of margins and repeat LLETZ was subsequently done between 2007 and 2016.
- All patients who were initially referred as low grade SIL or abnormal cytology other than HGSIL, but had a LLETZ done at Colposcopy following a Colposcopy diagnosis of CIN 2 or 3 with margins involved and repeat LLETZ done subsequently in period 2007 to 2016.

Exclusion Criteria

- Patient who had negative or free margins after initial LLETZ.
- Patients who had surgery (Hysterectomy and Cone Biopsy) done after first abnormal LLETZ.
- Patent who had margin involvement by HGSIL but were observed and followed up with cytology, a repeat LLETZ was not done.

Study sample

All women who met the inclusion criteria. This was a retrospective study for the period of 10 years (January 2007 to December 2016) of patients treated at CMJAH colposcopy clinic.

Study Design

The study was a retrospective quantitative case-control study, using medical records of patients at Charlotte Maxeke Johannesburg Academic hospital colposcopy clinic.

Data Collection

Files from the colposcopy clinic were retrieved dating back from 2007 to 2016 and information transferred to the data collection sheet (Appendix A). Histology results were confirmed from the NHLS laboratory online service if no hard copiers were available in the file. Biographic data and medical conditions were as reflected on the initial assessment chart at the colposcopy clinic (Appendix B).

Data Analysis

Descriptive analysis of the data was carried out. Categorical variables were summarized by frequency and percentage tabulation, and illustrated by means of bar charts. Continuous variables were summarized by the mean, standard deviation, median and interquartile range, and their distribution illustrated by means of histograms. Data analysis was carried out in STATA ® software. The 5% significance level was used. Precision was managed by using 95% confidence intervals.

The X^2 test was used to assess the relationships between treatment group and demographic and clinical characteristics, staging, morphological appearance of the cervical intra-epithelial lesion, prognostic factors and categorical outcomes at 6 months. Fisher's exact test was used where the requirements for the X^2 test cannot be met. Cox proportional hazards regression was used to analyse the relationship between treatment group and disease recurrence.

Ethical Requirements and Permission to Conduct Study

Permission to perform the study was obtained from the Charlotte Maxeke Hospital Chief Executive Officer (CEO) (see appendix D) and the head of Obstetrics and Gynaecology department at the hospital. Approval from the University of Witwatersrand Human Research Ethics Committee (WHREC) was granted (see appendix B) before the study was conducted**.**

Funding

This study was not funded by any source.

REFERENCES

1. Fihlo A.C, Garbelot E, Guarconi JRA, et al. Positive Endocervical Margins at Conization: Repeat Conization or Colposcopic Follow-Up? A Retrospective Study. Brazil. J Clin Med Res. 2015;7(7):540-544. DOI.org/10.14740/jocmr2171w
2. Jiang Yan Ming, Chang-Xian Chen, Li Li. Meta-analysis of cold-knife conization versus loop electrosurgical excision procedure for cervical intraepithelial neoplasia. China. OncoTargets and Therapy 2016:9 3907–3915. DOI.org/10.2147/OTT.S108832
3. Kruger TF, Botha MH. Clinical Gynaecology 4th Edition. Chapter 41: Carcinoma Of The Cervix. 2015. South Africa. Pg 546-552.
4. Tyler LN, Andrews N, Parrish RS, et al. Significance of Margin and Extent of Dysplasia in Loop Electrosurgery Excision Procedure Biopsies Performed for High-Grade Squamous Intraepithelial Lesion in Predicting Persistent Disease. Arkansas. Arch Pathol Lab Med. 2007;131: 622–624. Accessed on the 22/10/2019.
5. Eijsink JJ, de Bock GH, Kuiper JL, et al. Routine follow-up intervals in patients with high-grade squamous intraepithelial lesions (HSIL) and free excision margins can safely be increased in the first two years after Large Loop Excision of the Transformation Zone (LLETZ). Gynecol Oncol. 2009; 113(3):348-51. DOI:10.1016/j.ygno.2008.11.022
6. Ostör AG. Natural history of cervical intraepithelial neoplasia: a critical review. Int J Gynecol Pathol. 1993; 12(2):186-92. https://doi.org/10.1097/00004347-199304000-00018
7. Godfrey M.A.L, Nikolopoulos M, Garner J.E, et al. Conservative management of cervical intraepithelial neoplasia grade 2 (CIN2) in women under 30 years of age: A cohort study. London, UK. *European Journal of Obstetrics & Gynaecology and Reproductive Biology 228 (2018) 267-273.* https://doi.org/10.1016/j.ejogrb.2018.07.018
8. Basu P, Mittal S, Vale D.M, et al. Secondary prevention of cervical cancer. France. *Best Practice & Research Clinical Obstetrics and Gynaecology 47 (2018) 73-85.* DOI:10.1016/j.bpobgyn.2017.08.012
9. Prendiville W. Treatment of CIN - what are the risks. Cytopathology 2009, 20, 145–153. DOI:10.1111/j.1365-2303.2009.00669.x

10. Basu P, Taghavi K, Hu S.Y, et al. Management of cervical premalignant lesions. France. *Current Problems in Cancer 42 (2018) 129-126.* https://doi.org/10.1016/j.currproblcancer.2018.01.010

11. South African Society of Obstetricians and Gynaecologists (SASOG). Cervical Screening guidelines. South Africa. 2015
12. National Health and Medical Research Council. Screening to Prevent Cervical Cancer: Guidelines for the Management of Asymptomatic Women with Screen Detected Abnormalities. Canberra: Commonwealth of Australia, 2005; 61. Available from http://www.nhmrc.gov.au/guidelines-publications/wh39.
13. Zhu M, He Y, Baak JPA, et al. Factors that influence persistence or recurrence of high-grade squamous intraepithelial lesion with positive margins after the loop electrosurgical excision procedure: a retrospective study. China. BMC Cancer (2015) 15:744. DOI10.1186/s12885-015-1748-.
14. Reid R, Scalzi P. Genital warts and cervical cancer. VII. An improved colposcopic index for differentiating benign papilloma-viral infections from high grade cervical intraepithelial neoplasia. Am J Obstet Gynecol. 1985; 153(6): 611-8.
15. Bowring J, Strander B, Young M, Evans H, Walker P. The Swede score: Evaluation of a scoring system designed to improve the predictive value of colposcopy. J Low Genit Tract Dis. 2010; 14(4):301-5. DOI: 10.1097/LGT.0b013e3181d77756.
16. Sellors JW, Sankaranarayanan R. Colposcopy and Treatment of Cervical Intraepithelial Neoplasia: A Beginners' Manual. Chapter 7: Colsposcopic assessment of cervical intraepithelial neoplasia. International Agency for Research on Cancer, Lyon; 2003. Pg 55-68.
17. Woo YL, Bradley C, Jackson E, et al. Long-term cytological and histological outcomes in women managed with loop excision treatment under local anaesthetic for high-grade cervical intraepithelial neoplasia. Cambridge, UK. Cytopathology 2011, 22, 334–339. DOI:10.1111/j.1365-2303.2010.00824.x
18. Thompson V, Marin R. Is Colposcopy necessary at twelve months after large loop excision of the transformation zone? A clinical audit. Australia. Australian and New Zealand Journal of Obstetrics and Gynaecology 2013; 53: 571–573. DOI:10.1111/ajo.12153

19. Moss E.L, Moran A, Douce G, et al. Cervical cytology/histology discrepancy: a 4-year review of patient outcome. United Kingdom. Cytopathology 2010, 21, 389–394. 2010 Blackwell Publishing Ltd. DOI:10.1111/j.1365-2303.2010.00754.x
20. Manchanda R, Baldwin P, Crawford R, et al. Effect of margin status on cervical intraepithelial neoplasia recurrence following LLETZ in women over 50 years. United Kingdom. Gynaecological oncology. DOI: 10.1111/j.1471-0528.2008.01853.x
21. Ayhan A, Tuncer H.A, Reyhan N.H, et al. Risk factors for residual disease after cervical conisation in patients with cervical intraepithelial neoplasia grades 2 and 3 and positive margins. Turkey. *European Journal of Obstetrics & Gynaecology and Reproductive Biology 201 (2016) 1-6.*
*DOI:*http://dx.doi.org/10.1016/j.ejogrb.2016.03.021

CHAPTER 2:

SUBMISSIBLE ARTICLE

Does Repeat Large Loop Excision of the Transformation Zone (LLETZ) Achieve A Cure For Histologically Proven Persistent High Grade Squamous Intra-epithelial Lesions (HGSIL) At Margins?

Authors: Dr J May

Dr L Mbodi

ABSTRACT

Objectives

Cervical cancer is the second most common malignant neoplasm in women world-wide. CIN is a precursor lesion of cervical cancer and effective treatment of this lesion can prevent progression to cervical cancer. LLETZ has been shown to be effective treatment for CIN lesions with minimal complications. The aim of this study was to establish if repeat LLETZ achieves a cure for histologically proven persistent high grade CIN lesions at margins.

Study Design

This was a retrospective study, done at the Charlotte Maxeke Johannesburg Academic Hospital colposcopy clinic in South Africa. Data was collected from patient files (1500) seen at the colposcopy clinic for a period of 10 years (2006-2016). These were patients who initially had HGSIL, were treated using LLETZ and the repeat cytology showed persistent HGSIL, so they subsequently had a second LLETZ done. A total of 71 patients met the inclusion criteria.

Results

Overall, HGSIL (reported as CIN2, 3 and HGSIL) was found in 74.6% of the women at the second/repeat LLETZ and 22.1% had LGSIL (reported as CIN1 and LGSIL). Ecto-cervical margins were positive in (5) 8.5% of the patients who had the initial LLETZ biopsy, negative in 3 (5.1%) and unreported in 1 (1.7%). Compared to positive margins in 8 (13.6%), negative margins in 15 (37.3%) and unreported in 3 (5.1%) at the second LLETZ.

Endo-cervical margins were positive in 17 (28.8%) of patients who had an initial LLETZ biopsy as compared to 11 (18.6%) at the second LLETZ. This showed an improvement of 35.4% from the first to the second biopsy. In 55.9% of patients, there was both ecto-cervical and endo-cervical margin involvement post the initial LLETZ as compared to 37.3% post repeat LLETZ. This was an improvement of about 33.3% post repeat LLETZ.

There was no association between previous ecto-margins status (Pearson chi2 (98) = 106.7434 Pr = 0.257), previous endo-margins status (Pearson chi2 (10) = 2.8432 Pr = 0.985), both ecto and endo-margins status (Pearson chi2 (98) = 109.7042 Pr = 0.197) of the initial LLETZ and repeated LLETZ margin status. The cytology results post LLETZ had 22 (37.3%) patients with persistent HGSIL, 1 (1.7%) ASCUS-H, 21 (35.6%) LGSIL, 2(3.4%) ASCUS and 13 (22.0%) had normal cytology report. There was regression of the lesions in 61.0% of women post second LLETZ.

Conclusion

Patients above 35 years of age with positive margins are at high risk or persistent CIN lesions as opposed to younger patient and those with negative margins. Repeat LLETZ offers improvement in margins (endo- and ecto - cervical) status, but it doesn't offer a complete cure. It reduced the positive margin status and increased negative repeat cytology findings.

2.1 INTRODUCTION

Cervical cancer is the second most common malignant neoplasm in women worldwide [1]. Cervical intraepithelial neoplasia (CIN) is a precursor lesion of cervical cancer and is classified by histology as CIN 1, CIN 2, or CIN 3. Cervical screening using cytology combined with Human Papilloma virus (HPV) testing has resulted in a considerable increase in the number of women diagnosed with CIN in recent decades [2].

CIN2 and CIN3 are equivalent to high grade squamous intra-epithelial lesions (HGSIL) as per Bethesda Classification system (2001) used to classify the results of the Papanicolaou smear (Pap smear). The Bethesda system is used to differentiate between the high risk and low risk intra-epithelial lesions. There is significant evidence that CIN lesions in conjunction with persistent high-risk HPV (types 16/18/31, etc.) infection that are not treated, progress to cervical cancer. The rate of progression is almost double in immune-compromised women [3]. Therefore, treatment of these lesions is necessary in order to prevent significant morbidity and mortality.

High-grade squamous intraepithelial lesion is a common pre-neoplastic condition of the cervix that encompasses moderate (CIN 2) or severe (CIN 3) dysplasia. LLETZ biopsies were introduced in 1989 by Prendiville et al, to treat lesions that could be visualized by colposcopy. Type 2 and 3 transformation zone lesions need excision and LLETZ has been proven to be superior compared to cold knife conisation, in terms of complications [4].

LLETZ has been proven to be a safe method for treating lesions that involve the endocervix and has several advantages over cold-knife conization, including shorter operating times, less blood loss, and fewer complications overall. [4] Few studies have been conducted that evaluate the rate of persistence of disease after the repeat conisation for persistent or residual high grade CIN lesion 2 and 3.

Several studies have investigated the recurrence rate following LLETZ and it was found to range from 11.3% to 54%. [1, 5, 6, 7, 8] The factors associated with recurrence are age (independent predictor), positive margins on previous LLETZ specimens [5] and women with persistent high-risk human papilloma virus infection.[7] Zhu M et al (2015), in their study in China, found that the rates of HGSIL persistence/recurrence in patients who had a subsequent LLETZ and hysterectomy were 31.82 % (7/22) and 20.90 % (14/67), respectively, while that in patients who were selected for close follow-up (cytology or cytology combined with colposcopy-guided biopsy) was 4.02% (6/149). The predictive factors for persistence/recurrence in a group of patients with HGSIL and HGSIL-involved margins, were the patients' age and diameter of the tumour (size). The age more than 35 years was the only independent predictive factor [5].

A study done in Turkey found that the risk factors for residual disease post initial conisation were, multiple sweeps at the initial conisation of the lesion, as well as lesions that cover more that 50% of the cervical circumference.[9]

The purpose of this study was to determine if repeat LLETZ provides a cure for histology proven persistent HGSIL at margins, it was a retrospective study of patients who were followed up at the Charlotte Maxeke Johannesburg Academic hospital (CMJAH) Colposcopy clinic over a period of ten years (2007-2016).

2.2 RESEARCH METHODOLOGY

The study was conducted at the CMJAH colposcopy clinic located at area 176 of the Gynaecology unit of the Department of Obstetrics and Gynaecology. Patients seen in this unit were referred by the CMJAH Gynaecology ward, area 164, level 2 hospitals within the cluster, Community Health Centers as well as Private Gynaecology and Specialized units within the CMJAH such as Transplant (Renal and Hepatic) units and other Surgical Departments. The referral criteria are as per the South African Guidelines. Colposcopy and LLETZ were done by Oncology unit consultants and a consultant doing sessions. The clinic ran 3 days of the week. Patients records including initial assessment, histology and follow up care, are kept within the unit and were manually retrieved and sorted. A total of 120 patients were seen at the colposcopy clinic on a monthly basis (new and follow up).

The data was collected retrospectively from patient files by the main researcher at CMJAH Colposcopy clinic. The colposcopy clinic keeps all the patients' records/files separately from the main hospital records store. All files are accessible to healthcare workers. The files were manually selected from a total of 1500 files based on the inclusion criteria and only 71 were found to meet the criteria.

Patients selected were those who had, in the files, 2 or more histology results of the LLETZ procedure with cervical cytology done between each LLETZ and had a diagnosis of CIN 2/3. Where histology results were not found in the file or where the indication for a repeat LLETZ were not found, patients were excluded. Twelve (12) patients were excluded because of lack of follow up Pap smears (6), no available histology results (2), and no colposcopy findings noted (4). The total number of patient files included were 59.

All the data was collected as per data collection sheet (Annexure A) and entered directly into the RedCap® tool and then migrated to the STATA Statistical Software for analysis. The results that were not included in the files were traced back to the NHLS laboratory service via Track care Lab Results service. Biographic data and medical conditions were collected as reflected on the initial assessment chart at the colposcopy clinic (Annexure C).

In this study, quantitative techniques and descriptive analysis of the data was carried out. Categorical variables were summarized by frequency and percentage tabulation, and illustrated by means of bar charts. Continuous variables were summarized by the mean, standard deviation, median and interquartile range, and their distribution illustrated by means of histograms. Data analysis was carried out in STATA Software. The 5% significance level was used. Precision was managed by using 95% confidence interval.

The X^2 test was used to assess the relationships between treatment group and demographic and clinical characteristics. Fisher's exact test was used where the requirements for the X^2 test were not met. Cox proportional hazards regression was used to analyse the relationship between treatment group and disease recurrence.

2.3 Colposcopy and LLETZ Procedure

At CMJAH, the "see and treat one step approach" is undertaken on all patients who undergo colposcopy assessment. The most common procedure done during colposcopy examination of the cervix is the LLETZ.

Before the colposcopy procedure, all the patients were counselled on the indication and complications of the procedure (LLETZ) and a history of allergies ascertained. During the procedure, acetic acid was used to paint the cervix to ascertain the abnormal epithelium, which will stain white in almost all the patients. Lugol's iodine was not often used because of the unavailability of the resource most of the time. The areas on the cervix that stain white with the acetic acid were excised using LLETZ. The size of the loop is usually determined by the surface area that need to be removed. However, the size of the loop used was not recorded. Bleeding areas were cauterized and a betadine-soaked tampon inserted to both stop further bleeding and prevent infection.

The patients were then counselled about the findings of the procedure, advised to avoid intercourse and given prophylactic oral antibiotics for 7 days.

The specimen taken was then sent for histology and the patient advised to come back in 6 months for results. Since the results were released earlier than the return date, if results reveal any abnormality or cervical cancer, the patient was called back earlier for possible repeat LLETZ/ hysterectomy. A repeat pap smear was done in 6 months after LLETZ. A repeat colposcopy and LLETZ was done if margins were involved, at the colposcopists' discretion. If the histology showed an invasive cancer, the patient was booked for either CKC, Trachelectomy or a hysterectomy depending on the clinical stage and fertility desires. The Reid colposcopy index that considers four signs namely, lesion margin, colour/density of aceto-whitening, blood vessels, and iodine staining (12), was used.

For the purpose of this study, a cure for HGSIL post LLETZ was defined as any regression from HGSIL (CIN2/CIN3) either to LGSIL, ASCUS or NILM (normal) findings on subsequent smear. The appearance of ASCUS-H was considered as persistence of the disease.

CHAPTER 3: RESULTS

3.1 Study Population and Exclusions

A total number of 71 out of 1500 patients had repeat colposcopy and LLETZ for the study period at the CMJAH Colposcopy clinic. Of these, 59 patients met the inclusion criteria and 12 patients were excluded. The twelve (12) patients that were excluded had lack of follow up pap smears (6), histology results (2), no colposcopy findings noted (4).

Patients selected, were those who had, in the files, 2 or more histology results of the LLETZ procedure with cervical cytology done between each LLETZ and had a diagnosis of CIN 2/3. Where histology results were not found or where the indication for a repeat LLETZ were not found, patients were excluded.

These patients were mostly referred from their closest facility with a high-grade intraepithelial lesion on Pap smear and were subsequently treated and followed up at the colposcopy clinic between 2007 and 2016.

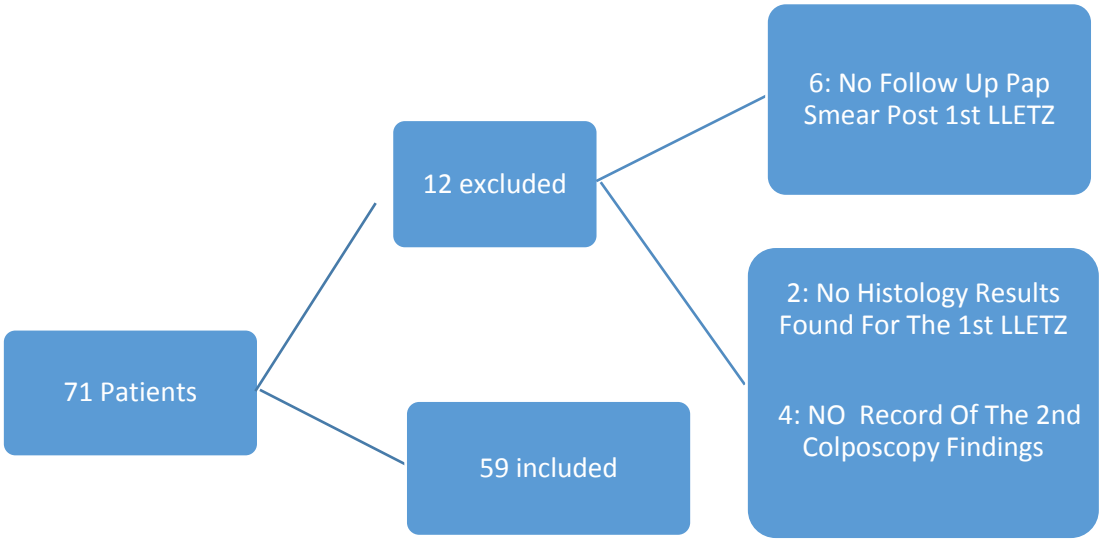

Figure 3.1: The study population and exclusions.

3.2 Demographics

The mean age of women seen and treated for high grade intraepithelial lesions was 36.9 years (SD±6.54), the youngest being 24 years of age and the oldest patient being 58 years. The mean parity was 2(SD±1.07) with only 5% of these patients being nulliparous at first presentation. There were 54 patients (91.5%) who were of African race and the other 5 (8.47%) patients whose racial status was not recorded in their files. None of the patients who met the criteria for the study and whose racial group was recorded, were white or coloured.

The majority (96.6% vs 3.4%) of the patients were pre- menopausal and a few were post-menopausal. Figure 2 below illustrates the menopausal status. At least half (50.9%) of the patients were not using any form of contraception and information on contraceptive use was not available in 7 (11%) patients. The most commonly used contraceptive method in our study was barrier (condoms) (45.6%). There were 6 (27.3%) who were on injectable contraceptives and 27.3% who were on oral contraceptive pills (the type of oral contraception was not specified in the colposcopy clinic clerking sheet).

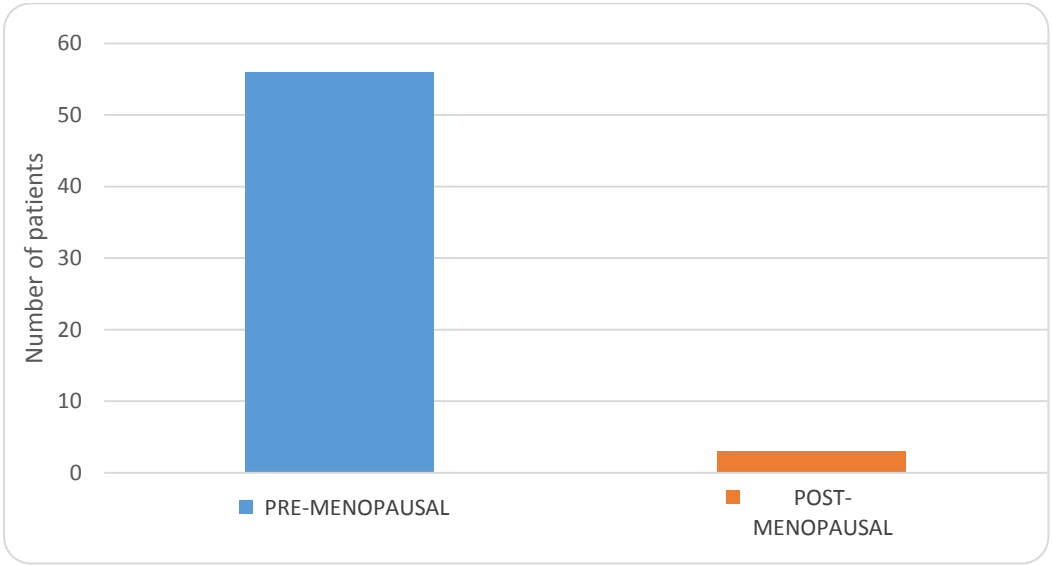

Figure 3.2: The distribution of patients according to reproductive age.

3.3 Risk Factors

None of the patients were asked about their smoking history during the treatment and subsequent follow up, even though this was part of the clerking sheet.

The HIV status was not known in 5.08% of the patients. There were 44(74.58%) patients who were HIV positive and 12(20.34%) who were HIV negative. Of the patients who were HIV positive, their mean CD4 count was 365 copies/ml (SD±210.38) and 29 (64.4%) were on antiretroviral treatment. The mean duration of months on treatment was 4.7 months for all those on treatment.

3.4 Referral Criteria

Most of the patients were referred from the local clinics and CHC'S (78%) and 7 (11.9%) were referred by their private general practitioners. The majority of the patients (98.3%) were referred with a high-grade intraepithelial lesion (HSIL) on Pap smear and only 1 (1.7%) was referred for atypical squamous cells of unknown significance but HSIL could not be excluded (ASCUS-H).

3.5 LLETZ Procedure

The majority of the patients (94.9%) had their first colposcopy done by a consultant and acetic acid was used to mark the abnormal areas in 88.1% of the patients. There was an abnormal acetic acid stain in 43 (72.9%) patients and the lesion was resected with a LLETZ. At the first colposcopy, Lugols' iodine was used for only 1 patient (1.7%) and the reason this was done was because there was no aceto-whitening achieved. There was no iodine used in 52 patients (88.1%), and in 10.2% of the patients, there was no information given on the use of either Lugols' iodine or Acetic acid. This compared to the second colposcopy where Lugols' iodine was only used in 1 patient and none was used in 40 (69.5%) and it was unknown in 18 (30.5%) patients.

Blue light was not used to assess vessels structure in 49 (83.05%) and it was unknown if this was used on the rest of the patients (10). Most of the patients were not assessed using the Reids' Colposcopy index scoring system. They were noted as having aceto-white abnormal changes at colposcopy (71.2%) or not. At least 3 (5.1%) were assessed as having severe dysplasia using the Reids' Colposcopy index score, 3.4% had inflammatory changes and 8.5% with moderate dysplasia. The rest of the patients where not classified as to the type of dysplasia that was found. In 6 (10.17 %) of the patients, the colposcopy findings were not noted and there was no mention of the size of the loop in any of the LLETZ procedure notes. The mean number of specimens collected at Colposcopy and LLETZ was 1.5, which the smallest amount being 1 specimen and the most being 4 pieces.

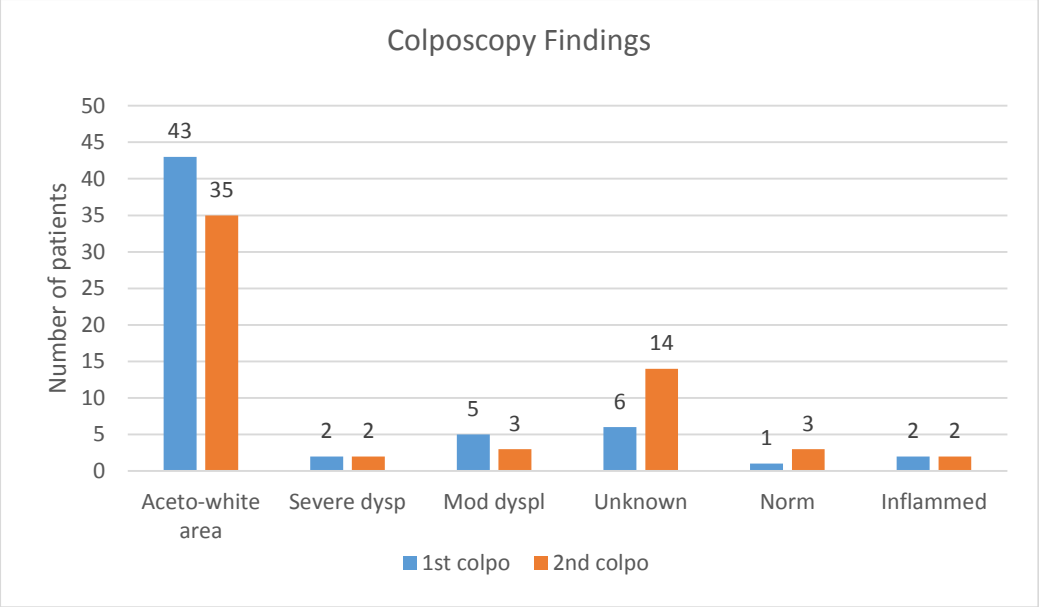

Figure 3.3: Colposcopy findings (in numbers) at both first and second examinations.

Only in 1% of the procedures there was a comment on the file regarding the difficulty of achieving haemostasis during the procedure.

The histology results from the first colposcopy and LLETZ procedure were reported in different nomenclature, as CIN 3 in 33 (55.9%), HGSIL in 16 (27.1%) and CIN 2 in 10 (17.0%) patients. All these lesions according to the Bethesda system are considered to be high grade intraepithelial lesions (HGSIL) and precursors for cervical cancer if not treated. Most of the patients had lesions incompletely excised at first colposcopy and LLETZ evidenced by margins involvement.

The majority of patients, 50 (84.8%), had the lesion involving the endo-cervical margins only and 38 (64.4%) had only the ecto-cervical margins involved. In 55.9% of patients, there was both ecto-cervical and endo-cervical margin involvement post the initial LLETZ as compared to 37.3% post repeat/second LLETZ. This was an improvement of about 18.6% post repeat LLETZ.

The second colposcopy and LLETZ were done at 12 months or more from the first procedure in patients who had persistent high-grade lesion diagnosed on a repeat Pap smear results (done 6-months after LLETZ).

The second colposcopy and LLETZ was done by a consultant in 56 (94.9%) of the patients and the other 3 (5.1%) were done by a registrar. The majority of the colposcopic diagnosis and LLETZ procedures were done using acetic acid (69.5%) staining and there was very poor documentation in the other patient files as to the method used to stain the cervix. Most of the patients, 35 (59.3%), had an aceto-whitening abnormality noted at colposcopy with only 2 (3.4%) noted to have severe dysplasia, 2 (3.4%) with inflammatory changes and 3 (5.1%) noted to have mild dysplasia and a normal cervix. The rest did not have comments on dysplasia at colposcopy. Comments about the haemostasis were only made in 4 (6.8%) patients post the second LLETZ.

The mean number of specimens taken at the second LLETZ was 1.5 with the greatest number of specimens being 4. The histology post second LLETZ found that HGSIL lesions (CIN2, 3 HGSIL) were found in 74.6% at the second or repeat LLETZ and 22.1% were LGSIL (CIN1, LGSIL) lesions. HGSIL were reported as CIN 2 in 17%, CIN 3 in 30.5% and HGSIL in 27.1%. LGSIL lesions were reported as LGSIL dysplasia in 11.9%, CIN 1 in 6 (10.2%). It is noted that there is still a different reporting method by different pathologists where an older system is still used and others conforming to the newer reporting system.

Table 3.1: The histology results as reported post second LLETZ.

HISTOLOGY RESULTS	NO.	Percentage (%)
CIN 1	6	10.2
CIN 2	10	5.9
CIN 3	18	30.5
HGSIL	16	27.1
ADENO-CA	1	1.7
OTHER	1	1.7

3.6 Repeat LLETZ and margin status

Ecto-cervical margins were positive in (5) 8.5% of the patients who had the initial LLETZ biopsy, negative in 3 (5.1%) and unreported in 1 (1.7%). This is in comparison to positive margins in 8 (13.6%), negative margins in 15 (37.3%) and unreported in 3 (5.1%) at the second LLETZ.

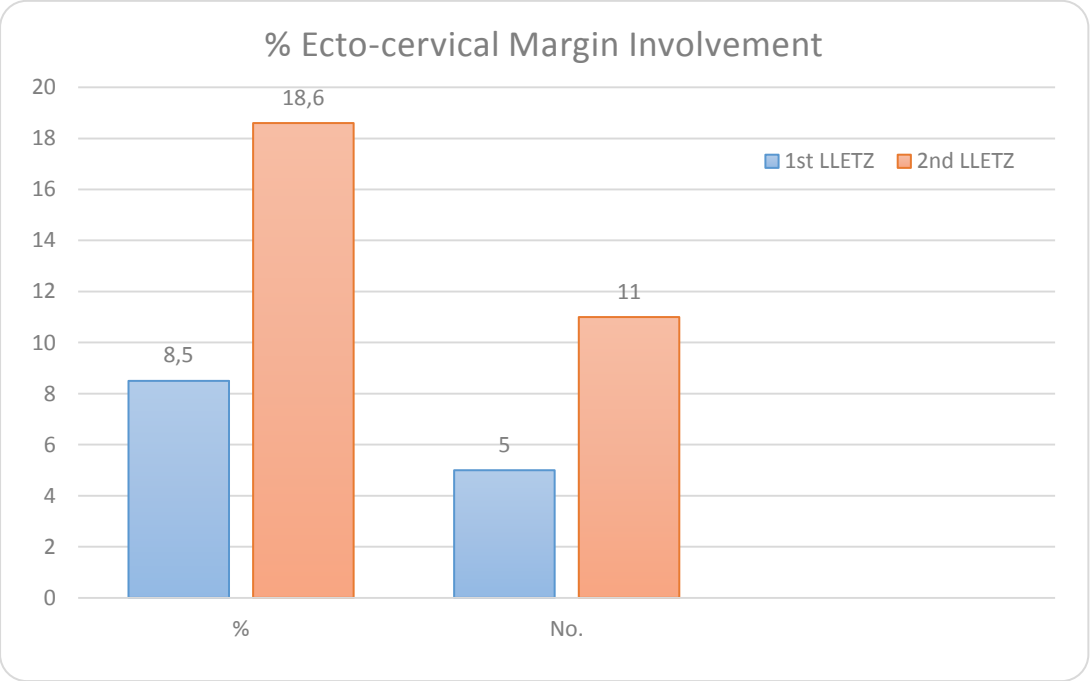

Figure 3.4: The involvement of Ecto-cervical margins at both LLETZ biopsies.

Endo-cervical margins were positive in 17 (28.8%) of patients who had an initial LLETZ biopsy as compared to 11 (18.6%) at the second LLETZ. This showed an improvement of 35.4% from the first to the second biopsy and it is a statistically significant change.

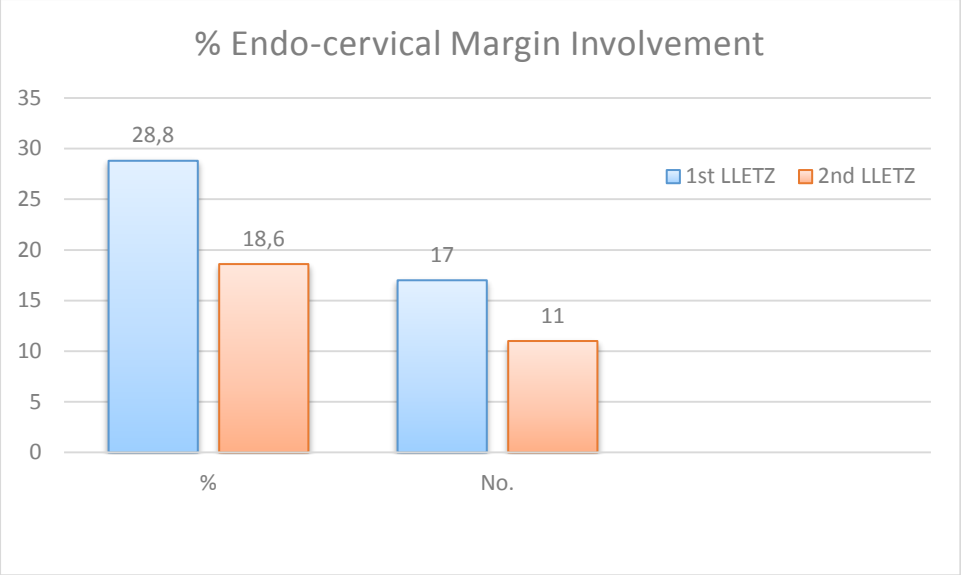

Figure 3.5: The Involvement of Endo-cervical margins at both LLETZ Biopsies.

The histology results with both the endo-cervical and ecto-cervical margins status is as illustrated below in figure 3.6.

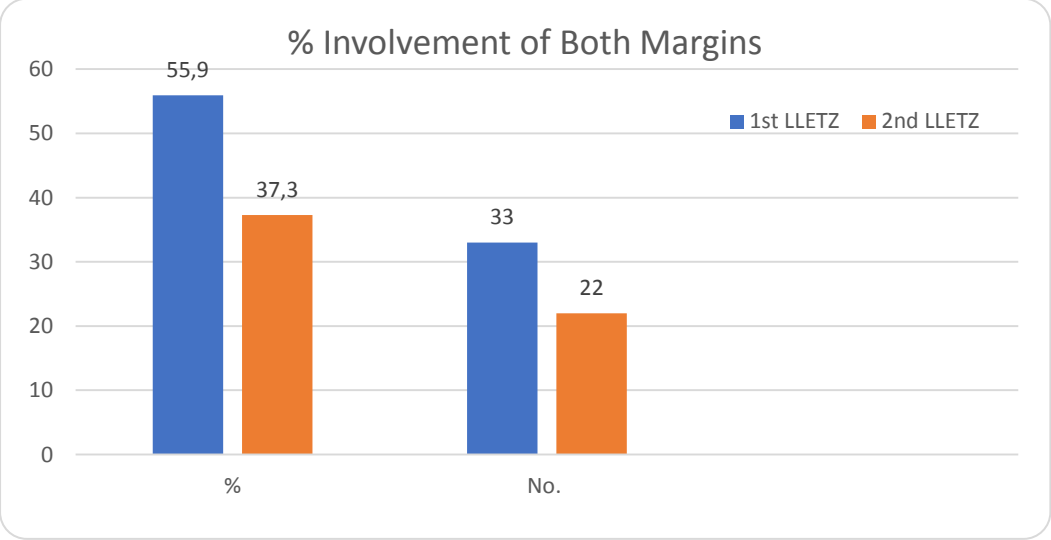

Figure 3.6: The involvement of both the endo-cervical and ecto-cervical margins status.

There was involvement of both endo-cervical and ecto-cervical margins in 33 (55.9%) at the first LLETZ as compared to 22 (37.3%) after the second LLETZ biopsy. There was an improvement of 33.3% from the first to the second LLETZ.

There was no statistical association between previous ecto-margins status (Pearson chi2 (98) = 106.7434 Pr = 0.257), previous endo-margins status (Pearson chi2 (10) = 2.8432 Pr = 0.985), both ecto and endo-margins status (Pearson chi2 (98) = 109.7042 Pr = 0.197) and repeated LLETZ margin status on second LLETZ.

3.7 HPV Status

Only 19 (32.2%) of the histology results had reports that included HPV changes and 40 (67.8%) were not reported. In those who were reported to have HPV changes at the first LLETZ biopsy, there was persistent HPV infection changes at the repeat LLETZ.

3.8 Papanicolaou Smear Post Second LLETZ

The post second/repeat LLETZ Pap smear was done after 24 weeks (6 months) in 27 (45.8%) patients and in 11 (18.6%) it was done after 28 weeks. Only 8 (13.6%) had a post LLETZ Pap smear within 20 weeks of the procedure. The mean number of weeks post LLETZ was 27.3(SD±). The Pap smear results post LLETZ had 22 (37.3%) patients with persistent high grade squamous intra-epithelial lesions, 1 (1.7%) with ASCUS-H, 21 (35.6%) had LGSIL, 2(3.4%) had ASCUS and 13 (22.0%) had NILM. There was regression of the lesions in 61.0% of women post second LLETZ.

Table 3.2: Table showing the cytology (Pap smear) results post second LLETZ.

Pap smear results post second LLETZ	Number (Percentage)
HGSIL	22 (37.3%)
ASC-H	1 (1.7%)
LGSIL	21 (35.6%)
ASC-US	2 (3.4%)
NILM	13 (22.0%)

3.9 HIV Status vs Pap Smear after repeat LLETZ

The diagram below shows a comparison between HIV positive and HIV negative patients regarding persistence of high-grade dysplasia and regression to lower grades or normal on patients who had a second LLETZ for persistent disease. The majority of patients showed regression after second LLETZ amid their HIV positive status.

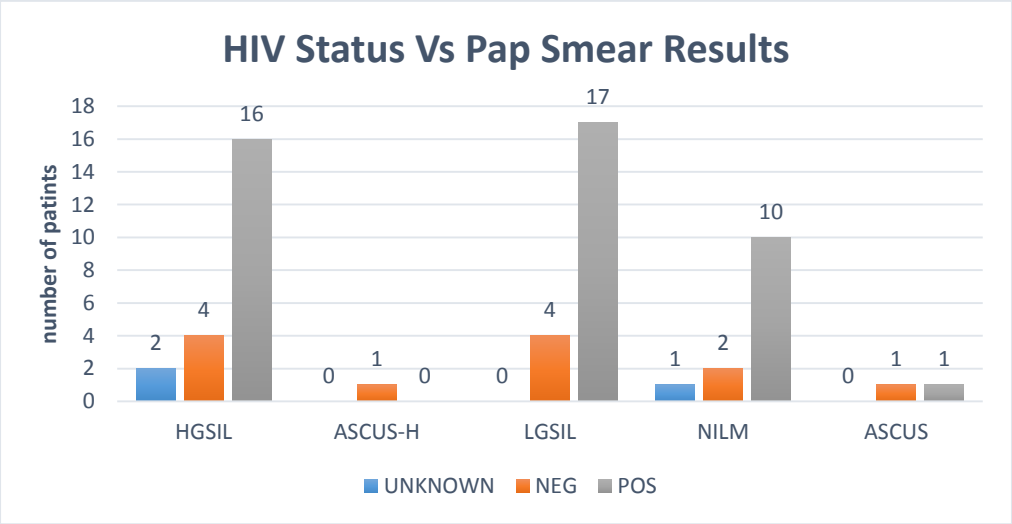

Figure 3.7: The Pap smear results after second/repeat LLETZ versus HIV status.

The majority of patients (74.6%) who were HIV positive also had a higher incidence of positive endo- cervical margins (25.6%), ecto-cervical margins (7.0%), and both margins (62.8%) reported on first LLETZ with regression to 13.9%, a worsening to 11.6% and regression to 39.5% respectively, after the second LLETZ. However, there was no statistically significant association found (p =0.66).

There was no statistically significant association between the Pap smear results, histology result and the use of contraception (p value=0.8 and 0.4). There was no statistically significant association found between the colposcopist rank and the involvement by HGSIL at the margins (p = 0.3).

CHAPTER 4: DISCUSSION

Our patients' mean age was 36 years with only 2 postmenopausal patients. We presume that this is due to the fact that most of our post-menopausal patients who presented with persistent HGSIL opted for hysterectomy and were excluded in the study. An International study showed that age >35 years alone was independent risk factor for persistent CIN disease,[5] which is in keeping with our study results.

Our study showed that there was regression of disease post the second LLETZ from HGSIL in 61% of patients, to LGSIL, ASCUS, and NILM on cytology. Thirty-nine percent (39%) had persistent HGSIL after the 2nd LLETZ, and some opted for another LLETZ because of desire for future fertility. There were others who were booked or referred for hysterectomy. A study by Zhu, et al, also found that the persistence rate of HGSIL was 31.82% following the subsequent LLETZ.[12] The recurrence rate ranged from 11.3% to 54% in several studies.[1, 5, 6,7,8]

In patients who had both ecto- and endo-cervical margins involved at the first LLETZ histology results, there was a 33.3% reduction at the subsequent LLETZ. Repeat LLETZ was associated with more than 50% reduction in positive margins and minimal change to negative margin status. Therefore, the repeat LLETZ for persistent high-grade cervical lesion proved to be of utmost benefit in our study in terms of margin status, and the subsequent Pap smear results did show a 61% regression to lesser dysplastic state of disease when a repeat LLETZ was done for positive margins. This is in agreement with a study done in Turkey that showed that the risk factors for persistent disease post second conisation include positive margins, which could be seen as inadequate treatment, as well as multiple sweeps of the LLETZ biopsy, especially in lesion that involve more than 50% of the cervix.[9]

Other institutions in South Africa observe patients who are under 35 years, with persistent high-grade lesions (CIN2 and 3) post LLETZ by doing 6 monthly cytology testing for 3 years. If the CIN lesion persists then an intervention is done. At CHBAH, a patient who present with persistent HSIL on cytology post LLETZ, gets a repeat LLETZ as long as the cervix still has length (can be done 2-3 times), otherwise a hysterectomy is offered. Therefore, there is no consensus in terms of the treatment of persistent CIN lesion post LLETZ worldwide.

Treatment and intervention are institutionalised and individualised according to the patient and fertility desires of the patient.

The presence of HGSIL disease on all HPV reported specimens supports the pathogenesis of the majority of cervical dysplasia and these findings were expected. Jian Yan Ming et al, and Thompson V et al, reported that patients with cervical dysplasia and proven HPV positivity, were likely to persist after destructive procedures such as LLETZ, Laser and Cryotherapy. The sensitivity of persistent HPV positive testing was up to 100% in a systematic analysis done by Paraskevaidis E, et al.[2; 7]

Most of our patients (74.6%) were HIV positive and there was poor documentation of their CD4 counts as well as viral loads. The majority of patients (64.4%) were on antiretroviral treatment but others were not despite CD4 counts of less than 350 copies/ml. Perhaps this is because the South African HIV Guidelines regarding initiation of HAART have changed at least 3 times in a space of 10 years regarding when to start patients on anti-retroviral therapy based on their CD4 counts. The current guidelines from 2015 state that every HIV positive patient should be started on antiretroviral therapy regardless of CD4 count. [10]

There was regression of HGSIL lesions after repeat LLETZ in 47.5% of patients who were HIV positive but the results were not significant. It is not known whether this is related to the use and duration of HAART and regaining immunity or just an incidental finding. There are no international studies that have investigated the persistence of HGSIL after LLETZ in patients who are on HAART compared to those who are not. A study done in Soweto, South Africa, showed that there was a higher risk of cytological abnormalities at follow up in patients who were immune-compromised and in those with incomplete excision during treatment. However, the HIV status of the patients was subjective, which could have caused biases. They also emphasised that patients who were negative according to their knowledge could also be in the window period or seroconvert later in the study.[11]

In those patients who were HIV positive and had both endo- and ecto-cervical margin involvement (62.8%), 55.6% of them show persistence of the CIN lesion at both margins post the second LLETZ. Only 14.8% of them had free margins at the subsequent LLETZ biopsy. Most international studies did not include HIV status as one of the measured factors or variables to be observed in patients with persistent disease or recurrent disease.

There is currently no HPV testing done in South African public hospitals but we noted that some of the histology results reported the presence of HPV changes which is an important indicator of persistent disease especially in patients where HPV is persistent at histology. In our study, those who were reported to have HPV at the first LLETZ biopsy had persistent HPV infection even at the repeat LLETZ. The inclusion of HPV or HPV changes is currently not a standardised protocol and hence few had such reported. We expected the HPV positivity to be higher that what was found if the testing was standard due to prevalence of HIV in our population.

A well-functioning Colposcopy clinic is expected to have a checklist, adopt a diagnostic method (Reid's or Swede), and use both Acetic acid and Lugols' iodine to identify dysplastic tissues and to accurately identify areas requiring resection. In our study, the colposcopy clinic had poor recording, no standard protocols were followed towards formulation of a colposcopy diagnosis and there was almost no use of Lugols' iodine.

Colposcopy findings were not recorded using the Reid's Colposcopy Index score in more than half of the patients. Therefore, it was difficult to correlate the clinical findings with the histology results. The histology results mostly reported the presence of a high- grade or low-grade intraepithelial lesion or squamous cell carcinoma and some of the colposcopy findings ranged from moderate to severe dysplasia and others inflammatory changed were noted.

CHAPTER 5: LIMITATIONS AND RECOMMENDATIONS

This study was conducted as retrospective study, which in its nature has limitations. It was conducted in one academic hospital in Johannesburg and the sample size was small with only 59 patients. There might have been bias as the study outcome was dependant on the skills of colposcopist on the adequacy of the resection at repeat LLETZ for treating HGSIL that was persistent after the first LLETZ.

It is expected that there will be a lot of gaps and bias in a retrospective study. However, in our setting, there was a lot of missing variables from the clerking sheet used at colposcopy clinic. A lot of parameters were omitted with no reasons specified on the files. Information at every clinic visit is essential for research and review of programmes. It is unacceptable to omit information during an examination and hence we feel that skills workshops on colposcopy are needed for colposcopists to improve. CMJAH colposcopy is a tertiary hospital clinic. The non-availability of lugols' iodine should not be acceptable and the clerking sheet should be updated regularly.

Despite our limitations our study results clearly showed an improvement post second LLETZ biopsy. There is a need for HPV testing in the public sector so that these patient who are at risk of recurrence or persistent of CIN lesions are not missed; thus can be treated timeously.

CHAPTER 6: CONCLUSION

Our study showed that patients who are above 35 years of age, and have positive margins on histology of the first LLETZ specimen were at higher risk of persistent CIN lesions as opposed to younger patient and those with negative margin involvement which was in keeping with previous studies.

Repeat LLETZ offers improvement in margins (endo- and ecto - cervical) status, even though it doesn't offer a complete cure. It has reduced the positive margin status and increased the rate of negative repeat Pap smear findings.

In HIV positive patients, there is higher persistence of disease post the initial LLETZ but more studies need to be conducted to ascertain whether persistence of the disease in these patients is due to poor immunity as well as investigate if their chances or persistence are less with improving immunity due to antiretroviral treatment.

The practice of repeat LLETZ however, on these patients with persistent HSIL lesions should be balanced against obstetric risks such as cervical incompetence, stenosis and preterm labour. Although this was not demonstrated in our study, it should be noted that a repeat LLETZ increases risk of injury to the bladder, rectum and vaginal mucosa.

REFERENCES

1. Fihlo A.C, Garbelot E, Guarconi JRA, et al. Positive Endocervical Margins at Conization: Repeat Conization or Colposcopic Follow-Up? A Retrospective Study. Brazil. J Clin Med Res. 2015;7(7):540-544. DOI.org/10.14740/jocmr2171w
2. Jiang Yan Ming, Chang-Xian Chen, Li Li. Meta-analysis of cold-knife conization versus loop electrosurgical excision procedure for cervical intraepithelial neoplasia. China. OncoTargets and Therapy 2016:9 3907–3915. DOI.org/10.2147/OTT.S108832
3. Kruger TF, Botha MH. Clinical Gynaecology 4th Edition. Chapter 41: Carcinoma of The Cervix. 2015. South Africa. Pg 546-552.
4. Tyler LN, Andrews N, Parrish RS, et al. Significance of Margin and Extent of Dysplasia in Loop Electrosurgery Excision Procedure Biopsies Performed for High-Grade Squamous Intraepithelial Lesion in Predicting Persistent Disease. Arkansas. Arch Pathol Lab Med. 2007; 131: 622-624. Accessed on the 22/10/2019.
5. Zhu M, He Y, Baak JPA, et al. Factors that influence persistence or recurrence of high-grade squamous intraepithelial lesion with positive margins after the loop electrosurgical excision procedure: a retrospective study. China. BMC Cancer (2015) 15:744. DOI10.1186/s12885-015-1748-.
6. Sellors JW, Sankaranarayanan R. Colposcopy and Treatment of Cervical Intraepithelial Neoplasia: A Beginners' Manual. Chapter 7: Colsposcopic assessment of cervical intraepithelial neoplasia. International Agency for Research on Cancer, Lyon; 2003. Pg 55-68.
7. Woo YL, Bradley C, Jackson E, et al. Long-term cytological and histological outcomes in women managed with loop excision treatment under local anaesthetic for high-grade cervical intraepithelial neoplasia. Cambridge, UK. Cytopathology 2011, 22, 334–339. DOI:10.1111/j.1365-2303.2010.00824.x
8. Thompson V, Marin R. Is Colposcopy necessary at twelve months after large loop excision of the transformation zone? A clinical audit. Australia. Australian and New Zealand Journal of Obstetrics and Gynaecology 2013; 53: 571–573. DOI:10.1111/ajo.12153

9. Ayhan A, Tuncer H.A, Reyhan N.H, et al. Risk factors for residual disease after cervical conisation in patients with cervical intraepithelial neoplasia grades 2 and 3 and positive margins. Turkey. *European Journal of Obstetrics & Gynaecology and Reproductive Biology 201 (2016) 1-6.* *DOI:*http://dx.doi.org/10.1016/j.ejogrb.2016.03.021
10. Bowring J, Strander B, Young M, Evans H, Walker P. The Swede score: Evaluation of a scoring system designed to improve the predictive value of colposcopy. J Low Genit Tract Dis. 2010; 14(4):301-5. DOI: 10.1097/LGT.0b013e3181d77756.
11. Adam Y, Van Gelderen C.J, De Bruyn G, et al. predictors of persistent cytologic abnormalities after treatment of cervical intraepithelial neoplasia in Soweto, South Africa: a cohort study in a HIV prevalence population. BMC Cancer 2008, 8:211. DOI: 10.1186/1471-2407-8-211.

ANNEXURE A: DATA COLLECTION SHEET **Study number**

Demographic data

Age at first consult (years)												
Race	African		Asian		White		Coloured		Other		Unknown	
Parity	0		1		2		3 &more		Unknown			
Gravidity	0		1		2		3 &more		Unknown			
Smoking	Yes		No		Unknown							
Reproductive age	Adolescent			Pre-menopausal				Post-menopausal				

HIV Status at First Consultation

Positive		**Negative**		**Unknown**								
If positive	CD4 Count			Viral load			Unknown					
	Treatment		Yes			No			Unknown			
	If yes, duration in months											

Contraceptives

Yes		**No**		**Unknown**								
COC		Injectables			IUCD				Other			
Duration of use (in months)							Unknown					

Referring Cytology

Date done		**Date referred**		**Referring institution**			
Results	NILM		CIN 1		CIN2	CIN 3	
	GCC		AGUS		ASUC	ASCU-H	
	ACIS		SCC		Adeno-Ca	Unknown	
	Other						

First Colposcopy & LLETZ

Date done		**Colposcopist**		**Registrar**		**Consultant**		**Oncologist**				
Blue light	Y	N	U	Acetic acid	Y	N	U	Lugol's iodine	Y	N	U	
Findings	Normal		Inflammatory		Metaplasia		Mild Dysplasia					
	Mod Dysplasia		Severe Dysplasia		Ca In Situ							
	Invasive Squam Ca		Invasive Adeno Ca		Other		Unknown					
Loop Used (Specify size and type)												
Margins	**Ecto**	Free	Involved	Unknown		**Endo**	Free	Involved	Unknown			
Hemostasis		Easy		Difficult		**Unknown**						
Number of specimen		1		2		3		4>	Unknown			
Histology results												

Y=Yes N= No U= Unknown

Second Colposcopy & LLETZ

Date done		**Colposcopist**		**Registrar**		**Consultant**		**Oncologist**				
Blue light	Y	N	U	Acetic acid	Y	N	U	Lugol's iodine	Y	N	U	
Findings	Normal		Inflammatory		Metaplasia		Mild Dysplasia					
	Mod Dysplasia		Severe Dysplasia		Ca In Situ							
	Invasive Squam Ca		Invasive Adeno Ca		Other		Unknown					
Loop Used (Specify size and type)												
Margins	**Ecto**	Free	Involved	Unknown		**Endo**	Free	Involved	Unknown			
Hemostasis		Easy		Difficult		**Unknown**						
Number of specimen		1		2		3		4>	Unknown			
Histology results												

Post Colposcopy Pap Smear

Date done				**Duration Colposcopy (in weeks)**				
Results	NILM		CIN 1		CIN2		CIN 3	
	GCC		AGUS		ASUC		ASCU-H	
	ACIS		SCC		Adeno-Ca		Unknown	
	Other							

ANNEXURE B: HREC CLEARANCE CERTIFICATE

UNIVERSITY OF THE WITWATERSRAND, JOHANNESBURG

R14/40 Dr Jabulile May

HUMAN RESEARCH ETHICS COMMITTEE (MEDICAL)

CLEARANCE CERTIFICATE NO. M180214

NAME: (Principal Investigator)	Dr Jabulile May
DEPARTMENT:	Obstetrics and Gynaecology Charlotte Maxeke Johannesburg Academic Hospital
PROJECT TITLE:	Does repeat large loop excision of the transformation zone achieve a cure for histologically proven persistent high grade squamous intrsepithelial lesion at margins?
DATE CONSIDERED:	23/02/2018
DECISION:	Approved unconditionally
CONDITIONS:	
SUPERVISOR:	Dr Langanani Mbodi
APPROVED BY:	Prof C Penny, Chairperson, HREC (Medical)
DATE OF APPROVAL:	30/04/2018

This clearance certificate is valid for 5 years from date of approval. Extension may be applied for.

DECLARATION OF INVESTIGATORS

To be completed in duplicate and **ONE COPY** returned to the Research Office Secretary in Room 301 Third floor, Faculty of Health Sciences, Phillip Tobias Building, 29 Princess of Wales Terrace, Parktown, 2193 University of the Witwatersrand. I/We fully understand the conditions under which I am/we are authorized to carry out the above mentioned research and I/we undertake to ensure compliance with these conditions. Should any departure be contemplated, from the research protocol as approved, I/we undertake to resubmit the application to the Committee. **I agree to submit a yearly progress report.** The date for annual re-certification will be one year after the date of convened meeting where the study was initially reviewed. In this case, the study was initially reviewed in January and will therefore be due in the month of January each year. Unreported changes to the application may invalidate the clearance given by the HREC (Medical).

Principal Investigator Signature _____ Date _____

PLEASE QUOTE THE PROTOCOL NUMBER IN ALL ENQUIRIES

ANNEXURE C: COLPOSCOPY CLINIC CLERKING SHEET

JH 287

DEPARTMENT OF OBSTETRICS AND GYNAECOLOGY
WITS UNIVERSITY

NAME: ..... REF NUMBER: ..... DATE: .....

AGE: ..... REFERRED FROM: ..... RACE: .....

GRAV: ..... PARA: ..... L.M.P.: .....

ADOLESCENT		PREGNANT		O.C.		
PRE-MENOPAUSAL		NOT PREGNANT		IUCD.		DURATION YRS.
POST MENOPAUSAL				D.P.		

LAST CYTOLOGY RESULT

NEG	AYT	POS	UNX

DATE OF TEST

				2	0		

COLPOSCOPY:

- NORMAL SQ.
- COLUMNAR
- T. ZONE
- WHITE FOCAL LESION
- LEUKOPLAKIA
- MOSAIC
- PUNCTATION
- ABNORMAL VESSELS
- CA OBVIOUS
- INDECISIVE
- OTHER

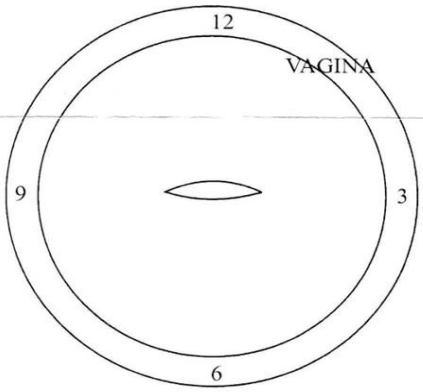

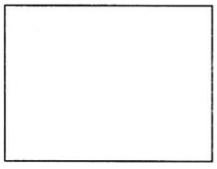

VAGINA

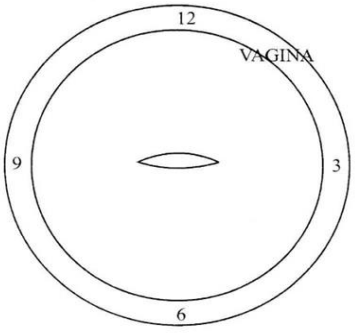

BIOPSIES		
	A	HISTO
	B	E.M.
	C	CULTURE

COLPOSCOPIC DIAGNOSIS:

NORMAL	
T. ZONE	
INFLAMMATORY	
METAPLASIA	
MILD DYSPLASIA	
MOD. DYSPLASIA	
SEVERE DYSPLASIA	
CA IN SITU	
INV. SQUAMOUS	
INV. ADENOMAT	
OTHER	

PROCEDURE:

DIRECTED BIOPSY	
CONE BIOPSY	
HYSTERECTOMY	
CRYOSURGERY	

PHOTOGRAPHY -	YES	NO

FOLLOW UP VISITS:

ANNEXURE D: Permission Letter from the CEO of CMJAH

GAUTENG PROVINCE
HEALTH
REPUBLIC OF SOUTH AFRICA

CHARLOTTE MAXEKE JOHANNESBURG ACADEMIC HOSPITAL

Enquiries:
Ms. N. Mzila
Office of the Clinical Director
Tell: (011): 488-4812
Email: Nolwazi.Mzila@gauteng.gov.za
20 July 2018

NDOH_201807_008

Dear Dr. J. May

STUDY TITLE: Does Repeat Lletz Achieve A Cure for Histologically Proven Persistent HGSIL At Margins?

Permission is granted for you to conduct the above recruitment activities as described in your request provided:

1. Charlotte Maxeke Johannesburg Academic Hospital will not anyway incur or inherit costs as result of the said study.
2. Your study shall not disrupt services at the study sites.
3. Strict confidentiality shall be observed at all times.
4. Informed consent shall be solicited from patients participating in your study.

Please liaise with the HOD and Unit Manager or sister in charge to agree on the dates and time that would suit all parties.

Kindly forward this office with the results of your study on completion of the research.

Supported / not supported

Dr. M.I. Mofokeng
Clinical Director
DATE: 2018/07/25

Approved/not approved

Ms. G. Bogoshi
Chief Executive Officer
Date: 26.07.2018