

https://dspace.org/

The transitional dentition of cercopithecus aethiops with special reference to the mandibular anterior teeth.

Gavronsky, Gerald

1980
http://hdl.handle.net/10539/22762

Downloaded from a DSpace repository. https://dspace.org/

THE TRANSITIONAL DENTITION OF CERCOPITHECUS AETHIOPS WITH SPECIAL REFERENCE TO THE MANDIBULAR ANTERIOR TEETH

GERALD GAVRONSKY

A DISSERTATION SUBMITTED IN PARTIAL FULFILMENT OF THE REQUIREMENTS FOR THE DEGREE OF MASTER OF DENTISTRY OF THE UNIVERSITY OF THE WITWATERSRAND, JOHANNESBURG

JOHANNESBURG 1980

DECLARATION

I declare that this dissertation is my own work. It has not been submitted to any other University in fulfilment of any requirement for any other degree.



Gerald Gavronsky

ACKNOWLEDGEMENTS

I wish to express my gratitude to the following persons for their help in the preparation of this dissertation:

To my supervisor, Professor Brian Preston, for his expert guidance, his words of encouragement when most needed and for numerous suggestions for improvements to the text.

To Alexis Samuels for her painstaking typing of the script.

To my daughter, Claire, for her expert assistance in the production of the photographs.

This work is dedicated to my wife, Olive, for her patience and understanding, and for her willingness to play second fiddle to this opus.

ABSTRACT

This dissertation studies the development of the anterior successional teeth prior to eruption, their eruption paths and position of emergence of these teeth in Cercopithecus aethiops, the vervet monkey.

The eruption of the permanent dentition is divided into four stages, equivalent to four chapters, with a fifth chapter devoted to an analysis of the pattern or sequence of eruption. This pattern is compared to those of other workers and possible reasons for tooth sequence polymorphism are discussed.

Twenty three skulls, fourteen female and nine male are examined and a representative sample chosen from each phase of dental development for dissection.

Photographs of each stage are presented, accompanied by a descriptive text but no measurements are recorded.

This is a visual and descriptive presentation which 'opens the window' to those aspects of the Cercopithecoid dentition which are not as readily observable by other methods such as clinical examination or radiography.

REVIEW OF THE LITERATURE

Baume and Becks (1950) in their description of the development of the dentition of Macaca mulatta divided their forty one specimens of unknown age chronologically into four periods according to the developmental stage of the dentitions. The interval during which the deciduous incisors are replaced by the permanent ones is denoted as the third period and under this heading they devote one paragraph to features related to root resorption and exfoliation of the deciduous incisors and the positional relationship of the permanent successors.

Drennan (1932) in referring to what he terms "eruption canals" states : "These interesting bony channels through which the permanent teeth pass on their way to the surface have had very little attention paid to them in dental literature". He also refers to eruption foramina and these and the eruption canals are described and illustrated as they appear in specimens of a young gorilla, orang and baboon. Text books of oral anatomy usually refer to these eruption canals as gubernacular canals as they contain strands of vascular connective tissue called the gubernacular cords or more simply the gubernaculum.

Ockerse (1959) describes the anatomy, the eruption sequence and the eruption times of the teeth of Cercopithecus aethiops, but makes no reference to eruption paths or sites of eruption.

Moyers (1958) states : "From an orthodontic standpoint, perhaps the most important phase of the life cycle of a tooth is the process of eruption". He continues : "Much has been written about the expected time of eruption of each permanent tooth. Due to the great amount of variability, the exact moment of arrival is of little importance. What is significant is the order of eruption and site of eruption".

Although Moyers (1958) is referring to the human dentition knowledge gained from the eruptive processes in the primate dentition may enhance our understanding of the problems related to abnormal paths and sites of eruption as well as the non-eruption of teeth in man.

The establishment of good statistical norms for various stages of dental development in man and other primates is of great value. It is hardly necessary to stress the value of such data to the experimental biologist and to the student of evolution. Of less obvious significance is the value of such information to the cultural anthropologist, paleontologist, nutritionist, pathologist and medicolegal expert (Hurme and Van Wagenen, 1953).

Although the present study is essentially descriptive in form it is believed that it will assist future workers in obtaining statistical data suitable for clinical application.

AIMS OF THIS STUDY

PRIMARY

a. To present visually, using photographic reproductions supported by a descriptive text, the stages of exfoliation of the deciduous anterior teeth and the development, path of eruption and emergence of their permanent successors in Cercopithecus aethiops.

b. To compare the eruption sequence of the permanent dentition of the present sample taken from a natural non-captive environment, with Ockerse's (1959) sample, the majority of which were bred in captivity. The related data of Krogman (1930) and Schultz (1935) are included in this comparison.

SECONDARY

c. To investigate the contribution of the gubernacular canals to the eruption of the successional dentition.

MATERIAL AND METHODS

The sample used in this study consisted of fourteen female and nine male vervet skulls which represent successive stages of tooth development from approximately eight months of age to adulthood.

TABLE 1. These estimated ages are based on the tables of Ockerse (1959) and are younger than those presented in the study by Schultz (1933) on the sequence and ages of tooth eruption in Rhesus Macaques.

	ESTIMATED AGE	SEX	SKULL NO		ESTIMATED AGE	SEX	SKULL NO
1	6- 8months	F	2	13	20-24months	M	16
2	9-12months	M	15	14	20-24months	F	3
3	9-12months	F	21	15	24-30months	F	10
4	12months	M	23	16	24-30months	F	12
5	12-15months	M	22	17	24-30months	F	14
6	15months	F	5	18	30-36months	F	13
7	18months	F	4	19	30-36months	F	11
8	20months	M	19	20	36-40months	M	17
9	20months	F	7	21	36-40months	M	18
10	20-24months	F	6	22	40-42months	F	24
11	20-24months	M	20	23	+48months	M	25
12	20-24months	F	9				

Exposure of the crypts of the unerupted permanent anterior teeth was accomplished using rotating discs and stones, plus chipping with hand instruments. Care was taken to minimise

the displacement of the developing tooth germs and their predecessors, when a certain proportion of the roots had been resorbed, resulting in excess mobility of these deciduous teeth. Where necessary a small drop of clear adhesive was used to retain teeth in their original relationships during the bone stripping procedures.

The camera used was a Pentax ME Super with a 1:4 100mm macro lens. For ultra close up views a 2x tele convertor was added to the lens system. The light source was a 500 watt flood placed to the right of the camera with a mirror, on the left side of the specimen being photographed, acting as a reflector.

The photographs were taken before and after the dissection of the alveolar cortex and removal of certain teeth. It was found necessary to retouch a few of the photographs when some detail related to the depth of field on the original specimen was not clearly reproduced on the photograph.

PREFACE

Although there are many publications in dental, anatomical and paleontological literature which include the eruption sequence and eruption times of living and fossil primates, (Gregory and Hellman,1926. Krogman,1930. Schultz,1933. Clements and Zuckerman,1953. Garn and Koski,1957. Swindler, 1976), a limited amount of information is available on the development of the successional teeth prior to eruption, their eruption paths and position of emergence of these teeth in living primates.

My initial interest was related to the primate or ape spaces, more correctly termed diastemata, which are such a marked feature in primate dentitions (Montagu,1943) but which are only occasionally present in the deciduous dentition of man.

The original plan was to study and attempt to classify these diastemata in a series of Vervet monkey dentitions ranging from the primary through to the permanent dentition. Numerous measurements, drawings and photographs were made, but the study had to be discarded as I could not find satisfactory solutions to the many technical difficulties encountered.

During these investigations some interesting features relating to the paths and sites of eruption of the permanent anterior teeth were noted.

After studying a recent publication on the development of the human dentition by Van der Linden and Duterloo (1976) I was inspired to follow a similar format for my investigation of the development of the permanent anterior teeth of Cercopithecus aethiops. This was discussed with my supervisor, Professor C.B. Preston, who encouraged me in this direction and whose suggestions, encouragement and guidance were invaluable to me.

Cercopithecus, better known as the vervet monkey, was chosen for this study because specimens are readily available in the Transvaal, certain areas of which form their natural habitat, and because they are considered to be suitable for dental biological studies (Ockerse,1959, Retief and Austin, 1972).

Although vervet monkeys from about six months through to adulthood are available for research, very young specimens are rarely obtainable. It was therefore necessary to limit this investigation to the transitional dentition period and in the youngest specimen the first permanent molars have already erupted. According to Ockerse (1959) the eruption times of these teeth range from eight to twelve months.

In the preface to their atlas van der Linden and Duterloo (1976) comment that their study focuses on those aspects of dental development which the clinician cannot observe in the living individual.

The anatomical features which form the body of the present work were observed visually and recorded using photographic and roentgenographic techniques prior to and

after removal of segments of the overlying cortical and cancellous jaw bone.

This is therefore essentially a descriptive presentation, the text is limited to a discussion of features which are seen in the illustrations. No attempt was made to include every anatomical detail and relationship nor have any measurements other than time been recorded as this was outside the scope of the study.

The mandibular anterior teeth were chosen to illustrate and represent the stages in development and eruption of the successional teeth. A limited number of illustrations representative of the changes in the maxilla are however included.

The human and vervet dentitions are similar in that they are both diphyodont, their teeth are heterodont, and their dental formulae are similar :

$$\frac{I_2C_1M_2}{I_2C_1M_2}$$ for the deciduous dentition and

$$\frac{I_2C_1P_2M_3}{I_2C_1P_2M_3}$$ for the permanent dentition.

CONTENTS

	PAGE
Declaration	i
Acknowledgements	ii
Dedication	iii
Abstract	iv
Review of the Literature	v
Aims of this Study	vii
Materials and Methods	viii
Preface	x
Contents	xiii
List of Tables	xiv
Chapter 1 The Early Transitional Phase ..	1
Chapter 2 The Mid-Transitional Phase ..	19
Chapter 3 The Late Transitional Phase ..	43
Chapter 4 The Adult Dentition ..	51
Chapter 5 Patterns of Eruption ..	59
Conclusions	70
References	73

LIST OF TABLES

	PAGE
Table I	viii
Table II	20
Table III	61

CHAPTER 1



THE EARLY TRANSITIONAL PHASE

INTRODUCTION

By the seventy-fifth day postnatally all the deciduous teeth of the vervet monkey have erupted, the central incisors appearing as early as six to fourteen days after birth.

A delay of approximately six months occurs between the completion of the deciduous dentition and the start of eruption of the permanent dentition. This stage is equivalent to that in the human dentition which lasts from two-and-a-half to about six years of age, seven times as long as that in the vervet monkey.

The first permanent tooth to emerge, at about eight months, is the lower first molar followed shortly thereafter by the upper first molar.

The early transitional phase extends over a period of about three to six months from the eruption of the first permanent molars at eight to twelve months, until the central incisors emerge at an average age of fifteen months (Ockerse, 1959).

The bulk of this chapter is devoted to one specimen, number fifteen, to demonstrate certain gross anatomical features of the skull as a whole and more detailed views of the unerupted permanent anterior teeth and the relationship to their deciduous predecessors.

The symphyseal region of the mandible with particular reference to the simian shelf is also discussed.



Figure 1 - 1

In the eight to twelve month old skull of Cercopithecus the most prominent features of the frontal aspect are the large circular to ovoid orbits in close proximity to each other. The apertura piriformis is small in relation to the orbits and pear-shaped, the widest portion being at mid-level. The apertura encroaches minimally into the area between the orbits and the short narrow nasal bones form its upper border.

The deciduous central and lateral incisors are well aligned with little or no spacing present and the tips of the canines are well below the level of the incisal edges of the upper anteriors.

The crowns of the upper central incisors and the four lower incisors are considerably wider at the incisal level than at their cervical margins and the crowns show marked signs of attrition of the incisal edges.

The morphology of the tooth bearing areas of the jaws is influenced by the shape and size of the underlying roots. The ridges over both upper and lower canines are especially prominent.

Marked resorption of the alveolar margin related to both upper and lower anterior teeth has resulted in the exposure of approximately one half of the deciduous central and lateral incisors and about one third of the roots of the canines.



Figure 1 - 2

From the lateral aspect the neuro-cranium dominates in size over the splanchnocranium. However the bimaxillary prognathism, even in the primary dentition, is fully evident.

The relationship of the almost square ramus to the body of the mandible is close to a right angle. The lower border of the mandible runs parallel to the occlusal plane, with only a suggestion of an antegonial notch.

Antero-superior to the notch or concavity, the developing second permanent molar has formed a distinct bulge on the lateral aspect of the body of the mandible.

The exact cuspal interdigitation of the deciduous molars and first permanent molar is well demonstrated and the terminal plane shows a distinct mesial step.

The first permanent molars erupt and occlude directly into the equivalent of the human dentition Angle Class 1 molar relationship. The tip of the lower canine crown encroaches into the wide diastema between the upper lateral incisor and canine.



Figure 1 - 3



Figure 1 - 4

A close up view of the frontal aspect of the mandible (fig. 1 - 3) shows in addition to the two mental foramina laterally, the central foramen symphyseosum which penetrates through the lingual surface, opening in a depression inferior to the mandibular torus (fig. 1 - 4). The triangular area of bone below the central canal is known as the simian shelf. The extensive loss of both labial and lingual alveolar bone, is clearly shown.

Attrition of the incisors shortens the crowns and bevels the lingual surfaces.



Figure 1 - 5

The elongated, narrow V-shape of the mandible is evident from the superior aspect, but the buccal segments of the U-shaped dental arch are parallel, crossing the underlying supporting bone from the buccal in the first deciduous molar region to lingual at the distal edges of the first permanent molars.

Early opening of the crypts of the second permanent molars can be seen. These teeth do not normally emerge until after the permanent incisors have erupted.





Figure 1 - 6 Figure 1 - 7

A magnified view of the anterior segment of the mandibular arch (fig. 1 - 6) shows the gradual downward slope of the lingual surface of the body ending at the well-defined mandibular torus. This ridge of bone is a site for muscle attachments.

The openings of the gubernacular canals related to the six anterior teeth are clearly evident. The lunar-shaped depression on the distal surface of each of the canines is due to attrition from the opposing upper canines.

The distal border of the crown of the lower deciduous canine is normally concave, ending in a small cusp near the neck. The concavity is accentuated by wear as seen from the lateral aspect (fig. 1 - 7).

Diastemata or primate spaces are present both mesial and distal to the lower canines and these, with the diastema mesial to the upper canine are constant features in primate dentitions.

The mental foramen is situated directly below the distal root of the first deciduous molar and the surface bulges of the underlying roots anteriorly and developing crowns posteriorly are highlighted.



Figure 1 - 8



Figure 1 - 9

Removal of the deciduous incisors reveals the incisal edges of the permanent centrals erupting lingually in the mandible and palatally in the maxilla. The sockets of the upper and lower deciduous lateral incisors are still intact.

The sutures which separate the premaxilla from the maxilla run between the lateral incisors and canines (fig. 1 - 9).

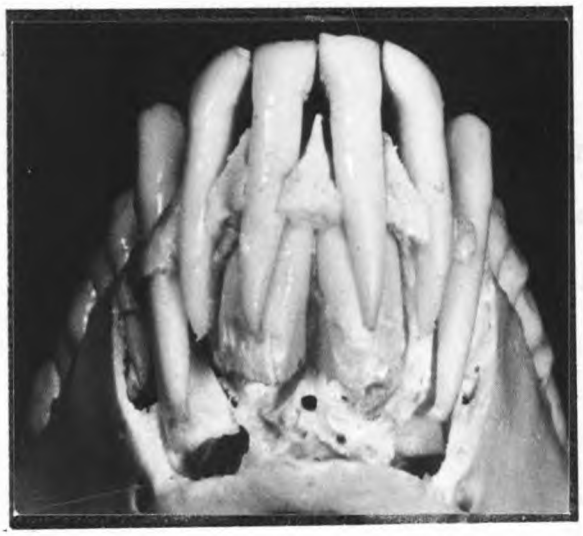

Figure 1 - 10



Figure 1 - 11

The anterior segment of the labial wall has been removed to reveal the roots of the deciduous incisors and canines and the developing parts of the corresponding permanent teeth all situated lingual to these roots. The apices of the roots of the deciduous central and lateral incisors are about half way between the alveolar margin and lower border of the mandible.

The deciduous canines are longer teeth than the incisors and their apices are much closer to the lower border of the mandible.

The lingual surfaces of the deciduous central incisor roots are in intimate contact with the crowns of the underlying permanent centrals, whereas a layer of bone intervenes between the roots of the deciduous laterals and canines and their successors. This bone forms the anterior walls of the sockets of the successional tooth crowns.

The relationship of these crowns is a reflection of the limitation of space available in the anterior segment of the mandible at this stage of development of the larger crowns

of the permanent anteriors, necessitating a more lingual position of the crowns of the laterals and canines.

The former are the most lingually disposed of the anterior teeth.



Figure 1 - 12

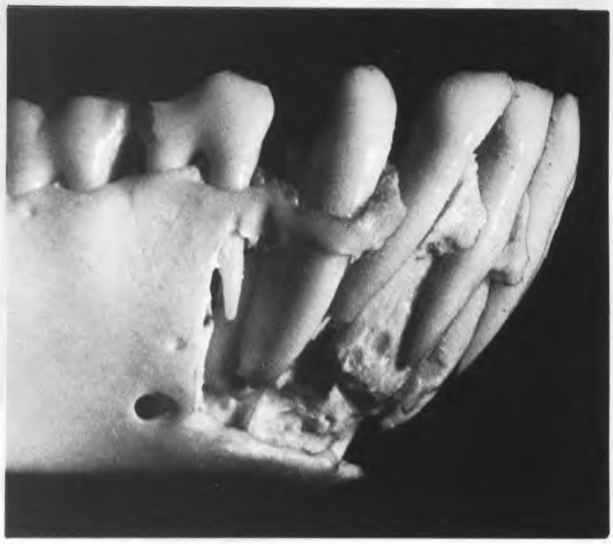

Figure 1 - 13

The deciduous teeth have been removed to reveal the full length of the permanent central incisor crowns which are close to eruption through the lingual cortical plate and separated by a thin wall of bone.

The central foramen which penetrates the full width of the symphysis is clearly seen (fig. 1 - 12).

The permanent central incisor crowns and overlying roots of the deciduous incisors slope palatally to their cervical borders, reflecting a similar incline of the frontal cortical plate and lack of any bony chin prominence.

The lateral aspect (fig. 1 - 13) gives a direct view of the contact of the root of the deciduous central incisor and underlying permanent crown with early resorption causing a flattening of the deciduous root on the interface.

The different levels of the apices of the deciduous anteriors previously described is well shown. However there is minimal resorption of the apices and very little shortening if any of the roots of the deciduous incisors.

The apical half of the root of the deciduous first molar has been exposed.

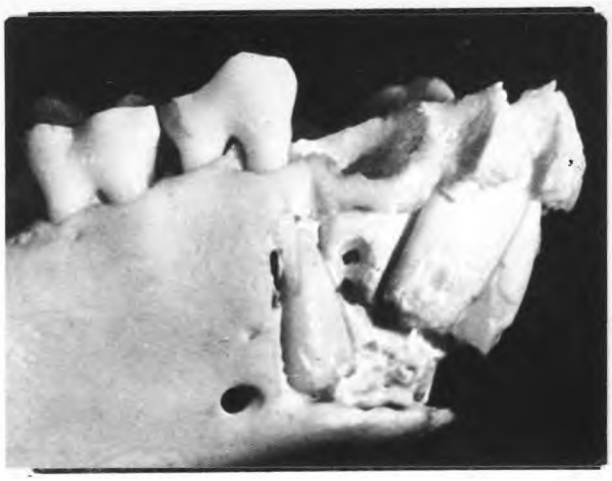

Figure 1 - 14



Figure 1 - 15

In the right lateral view a section of the bony socket has been removed to reveal the crown and part of the open apex of the deciduous right lateral incisor, partly hidden by the crown of the permanent canine (fig. 1 - 14).

In figure 1 - 15 the bone separating the roots of the deciduous left lateral incisor and canine and their successors is clearly evident, as are the wide open apices of the permanent central incisors.



Figure 1 - 16



Figure 1 - 17

Removal of the crown of the right central incisor gives a clearer view of the lingually placed lateral incisor and the thin bony wall of the socket which separates the latter from

the crowns of the permanent central incisor and canine (fig. 1 - 16).

In figure 1 - 17 the crown of the right canine has been removed to reveal its large deep crypt lined by smooth cortical bone which is characteristic of an early stage of root formation.



Figure 1 - 18



Figure 1 - 19

A small section of the crown of the permanent left lateral incisor has been exposed (fig. 1 - 18). Removal of the equivalent crown on the opposite side (fig. 1 - 19) reveals a deep crypt, also smooth walled, and the large gubernacular canal at its apex. Similar canals can be seen for the permanent central incisors and right canine.

The orientation of the crowns of the permanent anterior teeth in relation to each other can be evaluated from the location of their crypts.

The high narrow inner walls of the crypts of the incisors conform with the flattened lingual borders of these teeth shown in figure 2 - 24.



Figure 1 - 20A



Figure 1 - 20B

Two lingual views of a mandible at the same stage of development as in Figures 1 - 6 to 1 - 21, with all the deciduous and successional teeth removed, show the extent to which the successional incisors and canines occupy the space between the buccal and the lingual cortical walls.

The permanent central and lateral incisor crowns almost fill this volume down to the level of the foramen symphyseosum and the prominence of the supporting bone lingually, the mandibular torus, would appear necessary to accommodate the underlying crowns of the successional incisors and canines.

The so-called simian shelf seen below the central canal in Figure 1 - 20A forms the lower segment of the symphyseal region, and especially at this stage of development could act as a supporting and strengthening strut of bone for the mandible.





Figure 1 - 21 Figure 1 - 22

Cross sectional views of two mandibles, Figure 1 - 22 about eighteen months of age, and Figure 1 - 23 approximately twenty-four months showing the central incisors at different stages of eruption, with the roots only partly formed, and the anatomy of the supporting bone at the symphysis.

The simian shelf appears almost as an appendage below the thicker mandibular torus surrounding the developing incisor root. The angle of view in the above figures gives the shelf a vertical appearance whereas its true disposition is more horizontal as seen in figure 1 - 20A.

When one considers that the anterior surface of the mandible slopes backwards and downwards with no chin prominence, it is logical that a similar slope of the lingual symphyseal surface, which more or less parallels the labial wall, is essential for the reasons given in relation to Figures 1 - 20A and 1 - 20B.

After eruption and labial repositioning of the permanent incisors, only the roots of these teeth now occupy the

central thickened region of the mandible and the simian shelf below continues to develop.

It is assumed that the simian shelf serves not only as an area for muscle attachment but also to strengthen the mandible particularly in the male whose very large canines could exert considerable leverage and stress particularly across the incisor region.

Scott (1963), in discussing the symphyseal region of the mandible and its three accessory structures, the mandibular torus, the simian shelf and the chin states that these processes appear to be modifications designed to strengthen the symphyseal arch, the chin taking over in man the function of the shelf. However its poor development in certain Primates such as the Gibbons and Cebidae, both of which have large canines, indicates that the degree of correlation is limited. There would appear to be a closer correlation with the size of the muscles of mastication and of the dentition as a whole. Scott believes that the accessory structures mentioned above and also the brow ridges have a strong hereditary basis: "They can perhaps be classified as hereditary features depending upon functional activity for their maximum development. In this they correspond to other features of the skull such as the mandibular rami, the lateral pterygoid plates and the zygomatic arches".

CHAPTER 2



THE MID-TRANSITIONAL PHASE

INTRODUCTION

According to Ockerse's (1959) tables of eruption times for Cercopithecus aethiops the permanent lower central incisors erupt between twelve and fifteen months of age with the lateral incisors appearing some five to six months later at twenty to twenty four months.

Their counterparts in the maxilla erupt at fifteen to eighteen months and twenty to twenty four months respectively.

TABLE II. The sequence of eruption and the approximate eruption times of the permanent teeth of the vervet monkey (After Ockerse).

Teeth	Eruption Times
$\frac{M_1 \mid M_1}{}$	8 - 12 months
$\frac{M_1 \mid M_1}{}$	9 - 12 months
$\frac{I_1 \mid I_1}{}$	12 - 15 months
$\frac{I_1 \mid I_1}{}$	15 - 18 months
$\frac{I_2 \mid I_2}{I_2 \mid I_2}$	20 - 24 months
$\frac{M_2 \mid M_2}{M_2 \mid M_2}$	20 - 24 months
$\frac{P_2 \mid P_2}{P_2 \mid P_2}$	20 - 24 months
$\frac{P_1 \mid P_1}{P_1 \mid P_1}$	30 - 36 months
$\frac{C \mid C}{C \mid C}$	36 - 40 months
$\frac{M_3 \mid M_3}{M_3 \mid M_3}$	42 - 48 months

The mid-transitional period follows closely on the early phase and covers a total of about twelve months, during which time the upper and lower central and lateral incisors erupt.

Seven different specimens are used in this chapter to show the paths of eruption of the anterior teeth, their spatial relationships, and the developmental anatomy of their roots.



Figure 2 - 1A



Figure 2 - 1B



Figure 2 - 2A



Figure 2 - 2B

Anterior and occlusal views of two different mandibles show the early stage of eruption of the permanent lower central incisors. Although the lateral incisors can be seen through the enlarged gubernacular canals these teeth would not have pierced the overlying soft tissue at this stage, and so would not be considered as having erupted in the clinical sense.

The central incisors do not necessarily erupt simultaneously and because they are positioned lingual to their predecessors in a narrower segment of the arch they tend to be rotated and overlap each other.

Extensive resorption of the bone covering the roots of the deciduous central incisors takes place and they tend to be displaced labially due to pressure from their permanent successors. However the deciduous incisors remain in situ until their successors are almost fully erupted, which allows for a continuity in function of the incisors with minimal interference to the nutritional requirements of these animals.



Figure 2 - 3



Figure 2 - 4



Figure 2 - 5



Figure 2 - 6

This series of the same mandible shows the relative positions of the permanent central and lateral incisors after successive removal of the deciduous incisors.

The occlusal view (fig. 2 - 6) shows only a mild rotation of the right central incisor with the lateral incisors tucked in lingually to the permanent central incisors and deciduous canines.

An interesting feature is the appearance of the sockets of the deciduous incisors. Those belonging to the centrals are narrowed antero-posteriorly, whereas the lateral incisor sockets have not yet been affected by labial migration of the permanent lateral incisors.



Figure 2 - 7

The extensive resorption of the roots of the deciduous central incisors and very slight areas of resorption of the lateral incisors removed from the sockets (fig. 2 - 6), clearly reflects the pattern of eruption of the permanent incisors at this stage.



Figure 2 - 8

In the maxillary arch from the same skull the deciduous central and lateral incisors have not yet exfoliated but the incisal edges of their successors are just emerging through the palatal surface openings of the gubernacular canals. These are placed palatal to the central deciduous incisors but disto-palatal to the lateral deciduous incisors in line with the diastema between the lateral incisors and canines.

This eruption sequence follows the sequence detailed by Ockerse (TableII).



Figure 2 - 9



Figure 2 - 10

The maxilla of a specimen fifteen to eighteen months of age, slightly more advanced than the previous example in figure 2 - 8.

The permanent central incisors are at different stages of eruption and the deciduous incisor on the right is about to be shed, the whole of the labial surface of its crown having been exposed, with a small segment of alveolar bone still adherent to its surface.

Both deciduous lateral incisors are in an advanced state of exfoliation with the greater part of their labial surfaces exposed. Note the increased size of the apertura piriformis with the lower border extending well down between the roots of the permanent central incisors.

The gubernacular canals adjacent to the palatal surfaces of the deciduous canines are clearly shown.





Figure 2 - 11 Figure 2 - 12

An eighteen to twenty month old skull, both upper and lower permanent central incisors having fully erupted, and three of the four deciduous lateral incisors still present but with only their apical portions still contained within bone.

Figure 2 - 11 shows the mesial inclination of the upper and lower central incisors which are in overlapping contact near their mesio-incisal edges.

The rough uneven crestal borders of alveolar bone labial to the central incisors associated with the exfoliation of their predecessors are still evident, only partial regeneration having occurred at this stage.

The lower border of the apertura piriformis is now V-shaped and adjacent to the midline interdental alveolar crest.

The right lateral aspect of the jaws in occlusion (fig. 2 - 12) shows the increased procumbency of the upper and lower central incisors and the presence of an overjet and a mild anterior open bite. Note the deep overlap of the deciduous canine and first molar by the upper canine and the early state of eruption of the permanent right lateral incisor distal to its predecessor.





Figure 2 - 13 Figure 2 - 14

A more detailed view of the anterior surface of the mandible of the same skull as in Figure 2 - 11. The extremely small size of the crowns of the deciduous lateral incisors due to extensive attrition is in stark contrast to the large elongated crowns of the permanent central incisors.

It is interesting to note that the incisal edges of these four teeth are at the same horizontal level, thus continuing an optimal level of functional efficiency for the maximum period of time.

The overlapping and crowding of the permanent incisors seen from the occlusal aspect (fig. 2 - 14) is a temporary phenomenon due to the comparative lingual position of these teeth. After the loss of the deciduous lateral incisors pressure from tongue movements will reposition the permanent incisors labially into a well aligned anterior segment of the mandibular arch. This is a more or less constant feature of the lower anteriors in Cercopithecus Aethiops unlike that seen in man where lower incisor crowding is commonplace.

The gubernacular canals lingual to the deciduous canines are more distant from these teeth when compared to those in the maxillary arch (cf. figures 2 - 8 and 2 - 10).



Figure 2 - 15



Figure 2 - 16



Figure 2 - 17

Another skull in the same age group, eighteen to twenty months, as the previous skull in Figure 2 - 11. All four deciduous lateral incisors have recently exfoliated and in contrast to the previous specimen a diastema is present between the permanent lower central incisors.

The orbits are still the dominant feature in the frontal view and the zygomatic arches appear to be better developed and more prominent laterally.

An anterior open bite is again present and the mesial inclination of the permanent upper central incisors is due to their roots being placed lateral to the V-shaped lower half of the apertura piriformis.

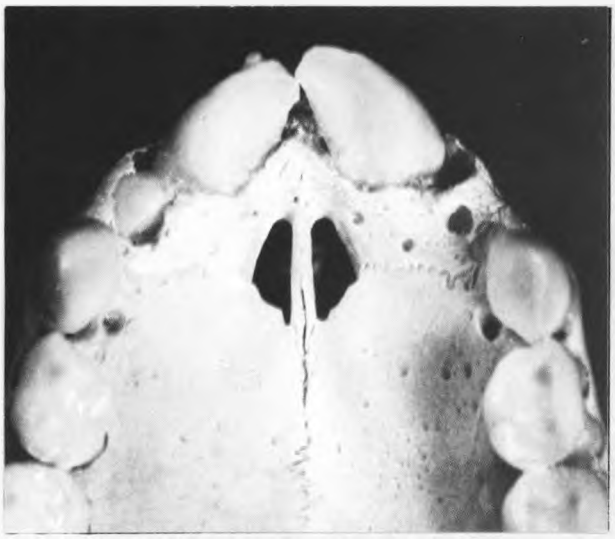

Figure 2 - 18



Figure 2 - 19

The occlusal views of the maxilla and mandible re-emphasize the constancy of position of the gubernacular canals. The left canal for the maxillary permanent lateral incisor is still intact, just prior to the eruption of the lateral, but on the right side the lateral incisor has enlarged the canal opening to form the definitive socket for this tooth.

Whereas the permanent upper lateral incisors erupt distal to the central incisors into the space provided by the diastemata situated between the deciduous lateral incisors and canines, the equivalent smaller diastema in the mandible does not allow enough space for the permanent lower lateral incisors, which therefore erupt lingual to their final normal position in the dental arch.



Figure 2 - 20A



Figure 2 - 20B

The labial plate has been removed from the anterior segment of the mandible to reveal the incompletely formed roots of the permanent lower central and lateral incisors. The labial surface of these teeth is distinctly convex in shape from the incisal edges down to the root apices which are still open.

The convexity is more marked in the lateral incisors than the canines and at this stage of eruption of the lateral incisors they are more lingually placed than the central incisors with the root apices at a lower level and postero-lateral to the apices of the central incisor roots. The latter are above the level of the central canal.

The space between the crowns of the central incisors continues downwards to the roots which are separated by a thick bony septum. The partially formed crowns of the lower permanent canines are close to the inferior border of the mandible and disto-lingual to the roots of the permanent lateral incisors.

Resorption of the deciduous canine roots adjacent to their apices is in accordance with their relationship to the crowns of their successors. The crown of the first premolar, disto-labial to the unerupted permanent canine, has been partly



Figure 2 - 21



Figure 2 - 22

A lateral view of the dissected mandible shows the crown of the permanent lower canine positioned lingual to the root of its predecessor and the mesial root of the deciduous first molar.

Part of the narrower lingual extension of the crown of the right central incisor can be seen, and the convex labial surface of the crown continues into its root with only a very slight narrowing to mark the indistinct cervical margin of the crown.

This applies to the lateral incisors as well.

An inferior view, Figure 2 - 22, gives a clearer picture of the relationships of the anterior teeth, the open apices, and the unusual shape of the lateral incisors.



Figure 2 - 23A

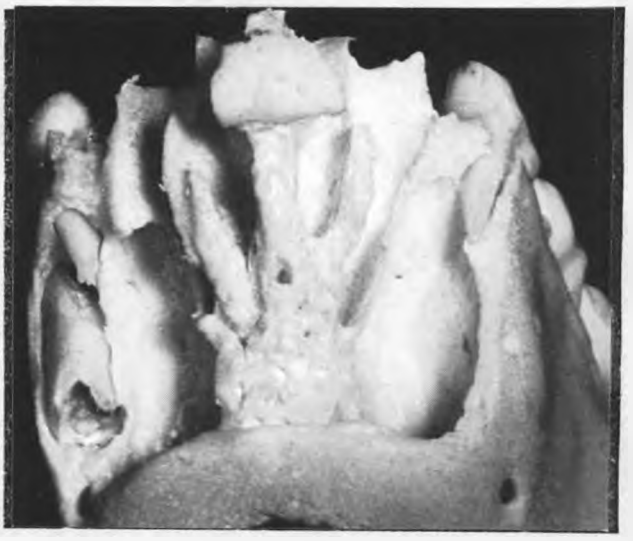

Figure 2 - 23B

Two views of the mandible after removal of the erupted and unerupted anterior teeth to show the full extent of the sockets and their relation to each other. The deep narrow socket of the right lateral incisor and the thin bony walls which separate all the crowns and roots, except for the central incisors, can be clearly seen.



Figure 2 - 24

The isolated crowns of the permanent canine, lateral and central incisors, from left to right, shows the difference in size and development at this stage and the flattened partly formed roots of the central and lateral incisors.



Figure 2 - 25



Figure 2 - 26

The skull of a twenty to twenty four month old specimen, with all the permanent upper and lower central and lateral incisors almost fully erupted and approaching edge-to-edge incisal contact. The incisors are also in lateral contact within each arch.

There is almost total resportion of the bone overlying the labial surfaces of the roots of the deciduous canines which are over-erupted and about to be shed.

The tip of the crown of the right canine is just emerging mesial to the root of its predecessor.

The deciduous lower canines are also in an advanced state of exfoliation.

Both maxilla and mandible have increased in size vertically and horizontally to accommodate the permanent second molars, which are close to full occlusal contact, and the developing roots of the remaining permanent teeth both erupted and approaching eruption.

The increased procumbency of the permanent upper and lower incisors is clearly shown. Note the partly erupted crown of the lower second premolar (fig. 2 - 26).



Figure 2 - 27A



Figure 2 - 27B

With the labial plate removed a more advanced stage of crown and root development of the permanent anterior teeth of the skull in Figure 2 - 25 is revealed.

The smoothly convex labial surfaces of the incisors converge both incisally and apically appearing together to form a segment of a sphere.

The close proximity of the apices of the roots of the incisors is due to the limited space available between the crowns of the permanent canines.

Root formation of the permanent incisors is about three-quarters complete, while that of the canines is in its earliest stage.

The deciduous canines are being displaced laterally by the erupting crowns of their permanent successors and their roots show mild resorption lingually near their apices. The different crown and root relationships are more clearly shown in the inferior view (fig. 2 - 27B).



Figure 2 - 28



Figure 2 - 29

Moving towards a view of the buccal aspect, note the open apices of the central and lateral incisors. The crown of the permanent canine lies immediately distal to the latter and directly lingual to the root of the deciduous canine. The apex of this root is level with the mid-point, vertically, of the crown of the permanent canine.

The sloping distal surface of the lateral incisor is a normal anatomical feature and not due to wear (Ockerse 1959).

The partly exposed crown of the first premolar lies just distal to the crown of the permanent canine and the second premolar is erupting directly beneath the resorbed crown of its predecessor.

Removal of the left canines exposes the smooth lingual surface of compact bone of the socket of the permanent canine leading up to the entrance to its gubernacular canal clearly shown in this view. The gubernacular canals connect the crypts of the permanent teeth with oral mucosa.

These canals contain strands of vascular connective tissue known as gubernacular cords.

During tooth eruption, the gubernacular cords decrease in length but increase in thickness, producing a widening of their canals. Whether the gubernaculum provides a duct, a path of least resistance or is actively engaged in pulling the tooth during the early prefunction phase of eruption has not been established (Berkovitz et.al., 1978).

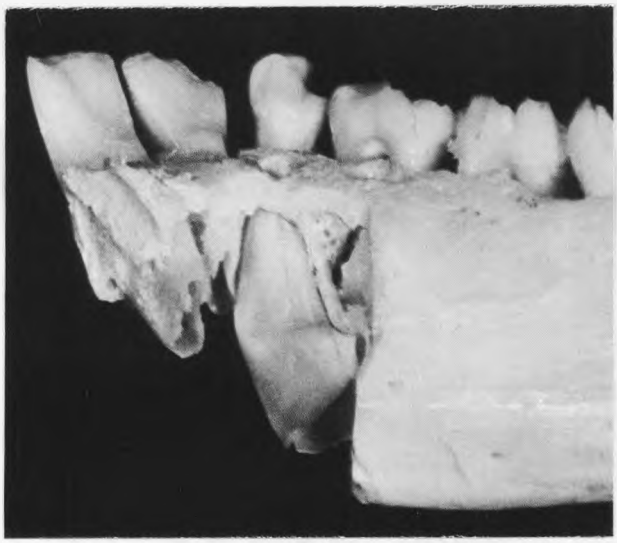

Figure 2 - 30

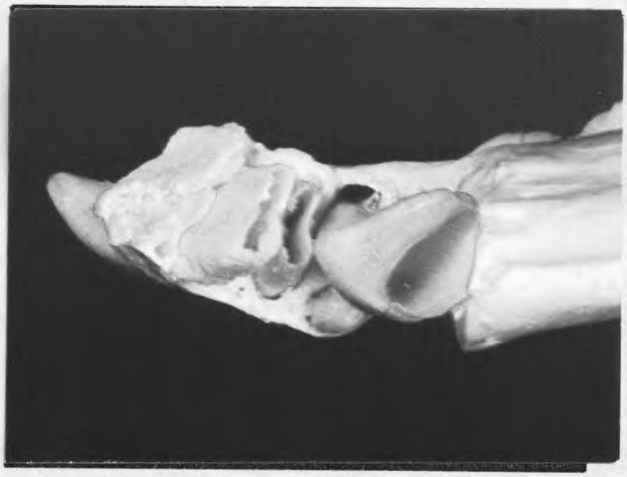

Figure 2 - 31



Figure 2 - 32

Lingual and inferior views of a sectioned mandible at the same stage of development as the previous specimen in Figures 2 - 28 and 2 - 29 show the lingually inclined roots of the permanent incisors as well as the flattened shape of their roots. The large developing root of the canine with its oval-shaped opening occupies the greater portion of the distance between the lingual and labial cortical plates of the mandible in this region. The partly resorbed root of the deciduous canine lies labial to and in contact with the crown of the permanent canine, the tip of which approaches the entrance to the gubernacular canal, well exposed after removal of the permanent canine, with the deciduous canine left in situ.



Figure 2 - 33

The occlusal view of the mandible (fig. 2 - 26) shows the labial displacement of the crowns of the exfoliating deciduous canines. The surface opening of the left gubernacular canal is intact, but resorption of alveolar bone on the right side has opened the canal to reveal the erupting permanent canine directly lingual to its predecessor.



Figure 2 - 34

The occlusal view of the upper arch of the same skull as in Figure 2 - 25 shows the deciduous and permanent canines at the same stage of exfoliation and eruption respectively as the opposing mandible.

Similarly the permanent canines erupt palatally to their predecessors which are finally lost only when the tips of the crowns of the permanent canines are about level with the incisal edges of the permanent incisors (fig. 3 - 6).

The central incisors are in contact at the mid-line but there is a small space between the central and lateral incisors. The large D-shaped openings of the incisive foramina are a prominent feature in the anterior part of the hard palate.

The maxillo-premaxillary sutures are now interrupted by the enlarging sockets for the permanent canines.



Figure 2 - 35A



Figure 2 - 35B

Removal of a small section of the labial plate lateral to the apertura piriformis shows the limited amount of space available for the roots of the permanent central and lateral incisors, which at this stage are almost fully formed. A very thin bony wall separates the root of the central incisor from the nasal passage.

The large size of the erupting crown and partly formed root of the permanent canine overshadows all the other maxillary teeth and its apex is situated close to the inferior margin of the orbit.

The space between the crowns of the permanent central and lateral incisors, not usually present in the deciduous dentition, indicates the increased procumbency of the permanent incisors clearly seen in Figure 2 - 35B.

As in the mandible the minimally resorbed root of the deciduous canine is gradually displaced laterally and incisally with the eruption of its successor, finally exfoliating with the bulk of its root still intact.

CHAPTER 3



THE LATE TRANSITIONAL PHASE

INTRODUCTION

The eruption of the permanent canines and premolars has been chosen as the beginning of the late transitional phase for the purpose of this study.

However no distinct line in relation to time can be drawn to separate the late from the mid-transitional phase of tooth eruption in Cercopithecus aethiops.

The one phase merges into the other as is shown in Table II.



Figure 3 - 1



Figure 3 - 2



Figure 3 - 3A



Figure 3 - 3B

A specimen of similar age to that in Figure 2 - 26, the upper canines still in situ but with the permanent lower canines erupted to the level of the incisors, and inclined disto-buccally so that the wide open apices are almost directly below those of the lateral incisors.

The canine roots are also considerably larger and more prominent than the roots of the laterals (figs. 3 - 3A and 3 - 3B).

The roots of the incisors are almost fully developed with their apices well above those of the canines.

Note that the lower lateral incisors have moved from a lingual position and all the upper and lower incisors are now well aligned, with a minimal overbite and overjet. There is no attrition of the incisal edges.



Figure 3 - 4



Figure 3 - 5



Figure 3 - 6



Figure 3 - 7

The eruption sequence of the permanent teeth of the vervet monkey as given by Ockerse (1959) and of the rhesus monkey according to Schultz (1935) records the premolars to be ahead of the canines.

In the above specimen, aged between thirty and thirty-six months, it is not possible to state whether the first lower premolars, which appear to be fully erupted, emerged before the upper or lower canines. However the latter are in an advanced state of eruption, ahead of the upper premolars and the lower right second premolars, whose predecessor is still in situ (fig. 3 - 4).

The left permanent canine has erupted to the incisal level of the adjacent lateral incisor, but the deciduous canine remains in position and functional with about one third of its root still contained in its socket (fig. 3 - 6).

The upper and lower incisors are not evenly aligned, a diastema is present between the upper central incisors and there is an anterior open bite with a point contact only between the upper right central incisor and the lower right lateral incisor (fig. 3 - 5). Mild attrition of the incisal edges of the upper and lower central incisors is evident (fig. 3 - 7).



Figure 3 - 8



Figure 3 - 8A



Figure 3 - 9

Three views of the previous specimen (figs. 3 - 4 and 3 - 5) after removal of the labial plate of the mandible. Further development and elongation of the roots of the canines has taken place, but their apices are now some distance from the lower border of the mandible following vertical bone growth. (fig. 3 - 8).

The canine crowns tilt labially but are vertically disposed from the lateral aspect, compared to the labial tilt of the incisors (fig. 3 - 9).

The lower first premolar has a distinctive shape. The crown is compressed laterally and the flattened mesio-labial surface shears against the upper canine. This type of premolar is termed sectorial. The angulation of the crown to the root can be seen in Figure 3 - 9.

CHAPTER 4



THE ADULT DENTITION

INTRODUCTION

The vervet monkey attains dental maturity at forty to forty-eight months of age with the eruption of the third permanent molars (Ockerse, 1959).

Two skulls are described in this chapter, one female and one male. It is generally only in the adult stage that sexual dimorphism becomes evident.

No dissection was done on these skulls as the only notable difference between young adult specimens and those in the late transitional phase, in relation to the roots of the anterior teeth, is the completion of growth of the apical portion of the canines.

Certain features of tooth anatomy, attrition, and intra-arch and inter-arch occlusal and incisal relationships are discussed.

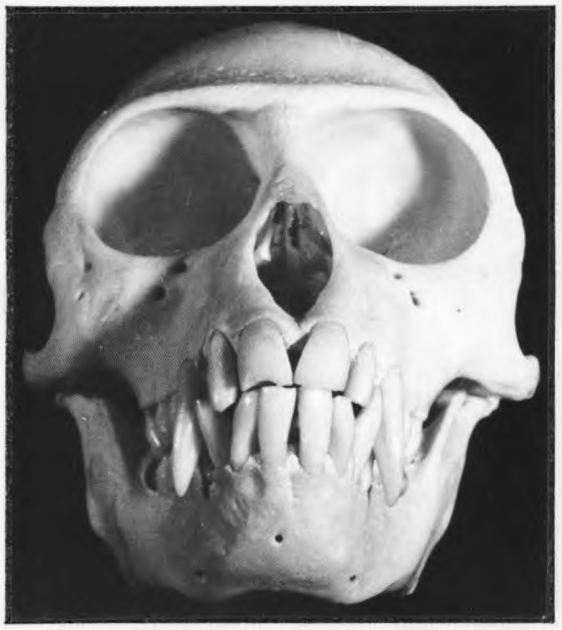

Figure 4 - 1



Figure 4 - 2



Figure 4 - 3



Figure 4 - 4

The skull of a young adult female Vervet monkey from the frontal and lateral aspects (figs. 4 - 1 and 4 - 2) illustrate the proportional increase in size and prominence of the face, mainly antero-posteriorly, in relation to the cranium.

The lower incisor crowns are long and narrow with the laterals very slightly smaller than the centrals.

The upper central incisors are spatulate, the lateral incisors proportionately narrower, and more rounded labially and incisally.

Attrition of the incisal edges of the upper and lower incisors is a constant feature in the Vervet, is already evident in the adolescent and fairly marked in the young adult as is seen in Figure 4 - 1. This wear would appear to maintain an edge-to-edge relationship between the upper and lower incisors.

Careful examination of the functional relationship of the upper to lower lateral incisors reveals the possible influence of the masticatory forces on their respective positions in the arches.

The step on the distal corner of the lower right lateral incisors (fig. 4 - 3) contacts with the mesial corner of the opposing upper lateral incisor (fig. 4-1).

This incisal contact would appear to direct a distal force on the upper lateral and a mesial force on the lower lateral incisor, resulting in a space between the upper and lateral incisors, but maintaining lateral contact between the four lower incisors.

The upper canines occlude with the elongated mesio-buccal surface of the sectorial (Le Gros Clark,1971) lower first premolars and protrude beyond the necks of the latter.

The lower canines are shorter and narrower than their counterparts in the maxilla and in the female intrude into the prominent diastema between the upper laterals and canines.

In the above specimen (fig. 4 - 2) the tip of the lower right canine has been fractured and is shorter than the left canine.

The normal buccal occlusion (fig. 4 - 2) is also a constant feature of all the specimens examined and this concurs with Preston and Evans (1976) who state that in their sample of forty-six adult Vervet monkeys no clinical evidence of malocclusions or craniofacial dysplasias were observed.

The early stage of eruption of the lower third molars is shown in Figure 4 - 4.



Figure 4 - 5



Figure 4 - 6



Figure 4 - 7

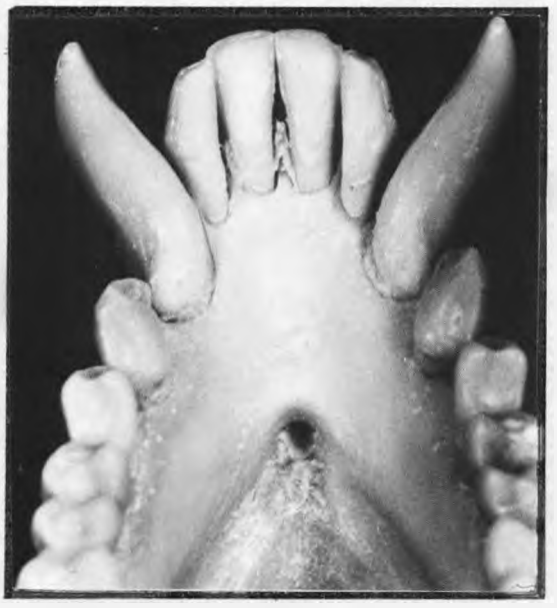

Figure 4 - 8

The third molars are fully erupted and in occlusion in this male specimen which is therefore older than the female skull depicted in Figure 4 - 1. However the moderate degree of attrition of the incisors and canines categorises this skull as a young adult.

Marked differences exist between this male specimen and the previous young adult female :

i) The male skull as a whole is larger and the jaws and teeth more prognathous.

ii) The orbits in the male are larger and more rectangular in shape, with heavier supra-orbital ridges.

iii) The temporal ridges are more clearly defined and closer to the vertex of the frontal bone which is raised in its central portion. The heavier masticatory muscles also necessitate thicker and more prominent zygomatic arches.

iv) The most striking difference, however, is in the size of both upper and lower canines. The upper canine crowns of the male specimen are almost twice the length of those in the female and project beyond the antero-inferior border of the mandible. The lower canines in the male are considerably larger in all dimensions, clearly shown in figure 4 - 8, and they fit neatly into the upper pre-canine diastema but with the tips spreading labially and outside the alveolar ridge and ending level with the alveolar margin of the upper canines.

v) Because of the large size of the lower canines, the narrow pre-canine diastema present in the adult female skull is almost obliterated in the male. Another interesting feature is that the larger lower male canines slide along the distal surfaces of the upper lateral incisors thus holding them in contact with the adjacent central incisors and negating the possible distal force from the lower laterals seen in the female.

The intra-arch and inter-arch relationships of all the teeth in the male skull illustrated here conforms to an 'ideal' occlusion for Cercopithecus aethiops.

CHAPTER 5



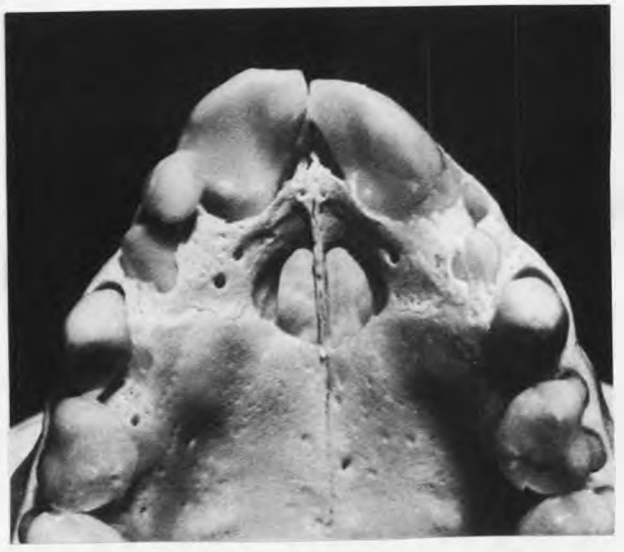



PATTERNS OF ERUPTION

INTRODUCTION

In the course of examination of the skulls used in this dissertation it was noted that the sequence of eruption of certain permanent teeth did not match the formulae recorded in previous publications.

The number of specimens in the present study is relatively small compared to the large numbers used by previous workers and it is possible that with a far bigger sample, the average sequence of eruption would conform to those already published.

Garn and Lewis (1963) mention, however, that it is often assumed, to begin with, that the tooth eruption sequence in individuals is fairly represented by massed-data tabulation. According to these authors it is also often assumed that the order of emergence through the alveolus is necessarily the same as the sequence of eruption through the gums.

To consider the first point, means or medians are notoriously poor indicators of the usual sequence of events (Garn and Lewis 1963).

With this in mind it was felt that some variations in the sequence of eruption of the canines and premolars noted in specimens included in the present study should be recorded. A possible explanation for the variations observed is offered here as a point for further study and discussion.

TABLE III. The dental formulae, complete and incomplete, of 23 skulls of Cercopithecus aethiops. These are separated into five periods of development of the permanent dentition (Schultz, 1933). Note the very early eruption of the lower canine (C) in specimen 19. F = Female. M = Male.

FIRST PERIOD

SKULL	TEETH IN OCCLUSION	INCOMPLETELY ERUPTED	UNERUPTED
2F		M_1 / M_1	
15M	M_1 / M_1		
21F	M_1 / M_1		

SECOND PERIOD

22M	M_1 / M_1	I_1I_2 / I_1I_2	M_2 / M_2
23M	M_1 / M_1	I_1 I_2 / I_1I_2	M_2 / M_2
4F	M_1I_1 / M_1I_1	I_2 / I_2	M_2 C $P_1P_2M_3$ / M_2 C $P_1P_2M_3$

TABLE III - Cont.

THIRD PERIOD

SKULL	TEETH IN OCCLUSION	INCOMPLETELY ERUPTED	UNERUPTED
19M	$\frac{M_1}{M_1I_1}$	$\frac{I_1I_2\ M_2}{I_2\quad M_2\ C}$	
7F	$\frac{M_1I_1}{M_1I_1I_2}$	$\frac{I_2\ M_2}{M_2}$	$\frac{C\quad P_1P_2M_3}{C\ P_1\quad P_2M_3}$
20M	$\frac{M_1I_1I_2}{M_1I_1I_2}$	$\frac{M_2}{M_2}$	
5F	$\frac{M_1I_1I_2}{M_1I_1I_2}$	$\frac{M_2}{M_2}$	
16M	$\frac{M_1I_1I_2}{M_1I_1I_2}$	$\frac{M_2}{M_2}$	
6F	$\frac{M_1I_1I_2}{M_1I_1I_2}$	$\frac{M_2}{M_2}$	$\frac{C\ P_1P_2M_3}{CP_1P_2\ M_3}$
9F	$\frac{M_1I_1I_2}{M_1I_1I_2}$	$\frac{M_2}{M_2}$	$\frac{CP_1P_2\ M_3}{CP_1P_2\ M_3}$

TABLE III - Cont.

FOURTH PERIOD

SKULL	TEETH IN OCCLUSION	INCOMPLETELY ERUPTED	UNERUPTED
12F	$\frac{M_1 I_1 I_2}{M_1 I_1 I_2 M_2}$	$\frac{M_2}{C}$	$\frac{P_1 P_2 C \quad M_3}{P_1 P_2 M_3}$
10F	$\frac{M_1 I_1 I_2 M_2}{M_1 I_1 I_2 M_2}$	$\frac{C}{C}$	$\frac{P_2 P_1 M_3}{P_2 P_1 \quad M_3}$
3F	$\frac{M_1 I_1 I_2 M_2}{M_1 I_1 I_2 M_2}$	$\frac{C}{}$	$\frac{P_1 \quad P_2 M_3}{P_2 P_1 C \quad M_3}$
11M	$\frac{M_1 I_1 I_2 M_2}{M_1 I_1 I_2 M_2}$	$\frac{P_2 P_1 \quad C}{P_2 \quad P_1}$	$\frac{M_3}{C \; M_3}$
13F	$\frac{M_1 I_1 I_2 M_2}{M_1 I_1 I_2 M_2}$	$\frac{P_2 C}{P_2 C \; P_1}$	$\frac{P_1 M_3}{M_3}$
18M	$\frac{M_1 I_1 I_2 M_2}{M_1 I_1 I_2 M_2}$	$\frac{P_2 \quad C \; P_1}{C \; P_2 P_1}$	$\frac{M_3}{M_3}$
14F	$\frac{M_1 I_1 I_2 M_2 P_2}{M_1 I_1 I_2 M_2 P_2}$	$\frac{P_1}{}$	$\frac{C \; M_3}{P_1 C \; M_3}$
17M	$\frac{M_1 I_1 I_2 M_2 P_1}{M_1 I_1 I_2 M_2 P_1}$	$\frac{C \; P_2}{C}$	$\frac{M_3}{P_2 M_3}$

FIFTH PERIOD

24F	$\frac{M_1 I_1 I_2 M_2 C P_1 P_2}{M_1 I_1 I_2 M_2 C P_1 P_2}$	$\frac{M_3}{M_3}$
25M	$\frac{M_1 I_1 I_2 M_2 C P_1 P_2 M_3}{M_1 I_1 I_2 M_2 C P_1 P_2 M_3}$	

A total of twenty-three skulls were examined, of which thirteen were female and ten male. The dental development ranged from an early mixed dentition specimen equivalent to the first period in the formation of the permanent dentition (Schultz 1933) to a mature adult skull which would fall into his fifth and last period.

The dental formulae, which are not complete in every skull, are recorded in Table III. The sequences recorded for the unerupted teeth in the last column were based partly on careful examination of the specimens, and partly on radiographic evidence which Garn and Lewis (1963) recommend. In those cases where the teeth were some distance from the alveolar border or in a few where radiographs were not available, an accurate assessment of the potential sequence of eruption was not possible. These teeth were then omitted from the last column in Table III.

In order to compare the findings of the present study with those of previous researchers three representative patterns were selected from the literature :

Cercopithecus aethiops (Ockerse,1959)

M_1	I_1	I_2	M_2	P_2	P_1	C	M_3
M_1	I_1	I_2	M_2	P_2	P_1	C	M_3

Rhesus macaque (Schultz, 1935)

M_1	i_1	i_2	M_2	P_1	P_2	C	M_3
M_1	i_1	i_2	M_2	P_2	P_1	C	M_3

Rhesus macaque ("Pithecus rhesus") (Krogman, 1930)

M_1	i_1	i_2	P_1	P_2	M_2	C	M_3
M_1	i_1	i_2	P_1	P_2	M_2	C	M_3

Ockerse's sequence differs from those of Schultz and Krogman in the order of eruption of the premolars, whereas Krogman's pattern places the second molars after the premolars compared to the other two sequences shown above.

An analysis of the dental formulae in Table III shows that in the first three periods, the sequence of eruption of the first permanent molars, the incisors and the second molars, coincides with the patterns of Ockerse and Schultz depicted above. Skull number nineteen is exceptional in that the lower canine has erupted very early but this specimen is included in the third period or group because of the incomplete eruption of the lateral incisors and second molars.

It is in the fourth period of eruption that the patterns in Table III differ from those of the above authors.

Thirteen of the twenty-three formulae in the third and fourth periods of eruption include the canines and premolars in the incompletely erupted and unerupted columns. The canines, either upper or lower, precede the premolars in nine of the thirteen specimens. The first premolars take precedence in one skull, number seventeen, and the second premolars in the remaining three specimens.

When the sequence of eruption of the premolars only is examined, P_1 is ahead of P_2 in six cases, and P_2 precedes P_1 in the same number of skulls.

Conclusions to be drawn from the above figures have to be influenced by the possibility that any sequence recorded in the unerupted column is open to question.

In the nine specimens in which the canines erupt before the premolars, no less than four are grouped in this last column, so that clear evidence of canine precedence exists in only five cases as compared to the four where one or more premolars are the first to erupt.

This may not be statistically significant but it does bear out the point made by Garn and Lewis (1963) in the introduction to this chapter that means or medians (as represented by the three eruption sequences given above) are poor indicators of the sequence of events in individuals. The present study also agrees with Schultz's (1933) observation that the patterns in his fourth period are very irregular.

In the present study a tooth was considered to have erupted if the tip of the crown was above the adjacent alveolar border, but in the case of the premolars only if the deciduous predecessor had also been shed.

A final observation, which is controversial, relates to the possible difference between animals born and bred in captivity and wild-shot animals.

Schultz (1933), in a footnote, states emphatically that captivity does not in any way influence the sequence of tooth eruption.

In contrast to this view, Garn and Lewis (1963) in discussing tooth sequence polymorphism in anthropoids state : "The polymorphism frequencies, more than the "typical" eruption sequences may prove useful in the future, especially as domestication or zooification apparently affects the eruption sequence in the great apes".

Ockerse's large sample of vervets were captive animals whereas the small sample in the present study were wild-shot specimens. It is assumed that Ockerse's eruption sequence was based on gingival emergence as compared to the alveolar eruption determination in this study.

The question arises whether these differences contribute to the variation in the canine-premolar eruption sequence between Ockerse's pattern and that reflected in Table III .