

https://dspace.org/

Perianal surgery in HIV infected patients

Tun, Myint

2009-05-05T07:33:09Z
http://hdl.handle.net/10539/6921

Downloaded from a DSpace repository. https://dspace.org/

PERIANAL SURGERY

IN

HIV INFECTED PATIENTS

Myint Tun

A research report submitted to the Faculty of Health Sciences, University of the Witwatersrand, Johannesburg, in partial fulfilment of the requirements for the degree of Master of Medicine in the branch of General Surgery

Johannesburg, 2008

DECLARATION

I, Dr. Myint Tun, declare that this research report is my own work. It is being submitted for the degree of Master of Medicine in the branch of General Surgery in the University of the Witwatersrand, Johannesburg. It has not been submitted before for any degree or examination at this or any other university.



.....(DR. M. TUN)

.....7th.....day of .....JULY.....2008

DEDICATION

To my beloved country, Myanmar

PRESENTATIONS

1. Tun M, Oettle GJ: Perianal Surgery in HIV infected Patients: Poster presentation, South African Digestive Diseases Week Congress; 2003 Aug 7; Sandton Convention Centre, South Africa.
2. Tun M: Perianal Surgey in HIV infected Patients: Oral presentation, Bert Myburgh Research Forum; 2003 Nov 11; University of the Witwatersrand, South Africa.
3. Tun M, Oettle GJ: Anal Ulcers and Fissures in HIV infected Patients: Oral presentation, 32nd Annual Meeting of The Surgical Research Society of South Africa; 2004 May 21; Eskom Convention Centre, South Africa.
4. Tun M, Oettle GJ: Management of Haemorrhoids in HIV infected Patients: Oral presentation, 32nd Annual Meeting of The Surgical Research Society of South Africa; 2004 May 21; Eskom Convention Centre, South Africa.
5. Tun M, Oettle GJ: Anal Ulcers and Fissures in HIV infected Persons: Poster presentation, 19th World Congress of International Society for Digestive Surgery; 2004 Dec 8; Yokohama, Japan.

6. Tun M, Oettle GJ: Fistula-in-ano in HIV infected Persons: Poster presentation, 19th World Congress of International Society for Digestive Surgery; 2004 Dec 8; Yokohama, Japan.

7. Tun M, Oettle GJ: Management of Haemorrhoids in HIV infected Patients: Poster presentation, 19th World Congress of International Society for Digestive Surgery; 2004 Dec 8; Yokohama, Japan.

ABSTRACT

Introduction

Human immunodeficiency virus (HIV) infection is becoming a global epidemic. In HIV-infected individuals, anorectal diseases are common and the commonest indications for surgical intervention. However, it has not been clear whether the cause and management of anorectal conditions differ in patients who are HIV negative and those who are HIV positive.

Aim

To compare the presentation of perianal diseases in HIV +ve and HIV –ve patients and to determine the best therapy for perianal diseases in HIV +ve patients

Methods

The study period was from 1999 to 2002. Patients seen at Helen Joseph Hospital during the author's gastroenterology fellowship period and those from his private practice were recruited. Those who agreed to HIV testing and who were treated by the author were included in the study. The patients were categorized according to HIV status, CDC classification and perianal pathology. Standardized questionnaires were used

for every patient. Patients were reviewed every two weeks after the procedure until fit for discharge.

Results

The sample comprised 241 patients: 100 HIV+ve (63 males and 37 females) and 141 HIV-ve (61 males and 80 females). The mean age of the HIV+ve patients was 34,8y (range 17-62y), and the mean age of the HIV-ve patients was 41y (range 5-82y). Follow-up was from two weeks to two years. The pathology included 62 (25 +ve, 37 -ve) haemorrhoids, 67 (27 +ve, 40 –ve) fistulas, 59 (25 +ve, 34 -ve) abscesses, 46 (11 +ve, 35 -ve) fissures, 24 (22 +ve, 2 -ve) anal ulcers, four (3 +ve, 1 -ve) anal warts, two (both +ve) pilonidal sinuses, three (all -ve) anal cancers and two (1 +ve, 1 -ve) hidradenitis suppurativa. Nine patients with haemorrhoids (4+ve, 5-ve) were treated conservatively, 11 patients with haemorrhoids (6+ve, 5-ve) had rubber band ligation and 42 patients with haemorrhoids (15+ve, 27-ve) had haemorrhoidectomy. Thirteen patients (1+ve, 12-ve; $p<0.001$) had complex fistulas and 8 patients (7+ve, 1-ve; $p=0.006$) had multiple fistulas. Ten HIV -ve patients with complex fistulas and seven patients with trans-sphincteric fistulas (3+ve, 4-ve) needed more than six weeks to heal after treatment. Thirty patients with anal fissures had sentinel piles, but there were none in the patients with anal ulcers ($p<0.0001$).

Thirteen HIV +ve patients with anal ulcers had an abnormally weak anal tone, but only one HIV +ve patient with anal fissure had a weak anal tone ($p<0.001$). In the patients with anal fissure, 37 (8+ve, 29-ve) had a high anal tone, but none of the patients with anal ulcers had increased anal tone ($p<0.0001$). Of the 59 patients with perianal suppuration, 23 (8+ve, 15-ve) had primary fistulotomy as well as drainage of the abscess.

Conclusions

Multiple fistulas were more commonly seen in advanced HIV patients, whereas *complex* fistulas were more commonly seen in HIV negative individuals. Healing after fistula surgery is determined more by the type of fistula than the HIV status or stage.

Anal fistulas associated with perianal suppuration can be treated the same way in both HIV negative and positive patients, without increased complications.

Careful physical examination is essential to differentiate between anal ulcers and fissures. Both conditions are common, and have similar symptoms in HIV positive patients. They can, however, be readily and safely distinguished on clinical examination, since fissures are associated with high anal tone,

and a sentinel pile, while the AIDS ulcer lacks the sentinel pile, and the pressure is low.

Anal malignancies, especially squamous cell carcinoma, have been uncommon in our experience.

With the addition of anti-retroviral therapy and antibiotics, haemorrhoids may be safely treated according to standard principles (rubber band ligation and haemorrhoidectomy, as appropriate).

Our practice has favoured a conservative approach in patients with *advanced* HIV disease. However, anti-retroviral therapy and antibiotics may improve the safety and outcome after surgical procedures.

ACKNOWLEDGEMENT

Special thanks to Professor GJ Oettle for his tireless supervision, invaluable academic input and kind moral support

TABLE OF CONTENTS

	Page
DECLARATION	II
DEDICATION	III
PRESENTATIONS	IV
ABSTRACT	VI
ACKNOWLEDGEMENT	X
TABLE OF CONTENTS	XI
LIST OF TABLES	XIII
LIST OF FIGURES	XV
LIST OF APPENDIXES	XVI
1 INTRODUCTION	1
2 STUDY OBJECTIVES	4
3.0 MATERIALS AND METHODS	4
3.1 Patient selection	4
3.2 Study Methods	4
3.3 End point of study	5
3.4 Data analysis	6
3.5 Ethics	6
4.0 RESULTS AND DISCUSSIONS	7
4.1 Haemorrhoids	9
4.2 Fistula in ano	19

4.3 Anal ulcer and fissure 31

4.4 Perianal suppuration 45

4.5 Anal cancers and warts 53

5 CONCLUSION 55

APPENDIXES 57

REFERENCES 65

LIST OF TABLES

Table		Page
4.1	Perianal diseases and HIV infectivity	8
4.2	Patients presenting with haemorrhoids	10
4.3	Symptoms of haemorrhoids	10
4.4	Past history of patients with haemorrhoids	12
4.5	Abnormal physical signs of haemorrhoids	12
4.6	Treatment of haemorrhoids	12
4.7	Gender and HIV status of patients with anal fistula	20
4.8	Symptoms of anal fistula	20
4.9	Types of fistula and HIV status of patients	27
4.10	Histology of anal fistula	27
4.11	Treatment of anal fistula	27
4.12	Age and HIV status of patients with anal ulcer	33
4.13	Age and HIV status of patients with anal fissure	33
4.14	Symptoms of anal ulcer	34
4.15	Symptoms of anal fissure	34
4.16	Previous history of patients with anal ulcer	35
4.17	Previous history of patients with anal fissure	35
4.18	Physical signs of anal ulcer	36
4.19	Physical signs of anal fissure	36
4.20	Histology of anal ulcer	37

4.21 Histology of anal fissure 37

4.22 Treatment of anal ulcer 38

4.23 Treatment of anal fissure 38

4.24 Ages and HIV status of patients with perianal suppuration 47

4.25 Symptoms of perianal suppuration 47

4.26 Findings in perianal suppuration 48

4.27 Treatment of perianal suppuration 49

LISTS OF FIGURES

Figure	Page
4.1 Healing after haemorrhoids treatment	14
4.2 Healing vs CD4 after haemorrhoids treatment	14
4.3 Different types of anal fistulas	22
4.4 Healing after treatment of anal fistula	25
4.5 CD4 vs healing after treatment of fistula	25
4.6 Healing vs type of anal fistula	26
4.7 Healing after treatment of anal ulcer	40
4.8 Healing vs CD4 count after treatment of anal ulcer	40
4.9 Healing after treatment of anal fissure	41
4.10 Healing vs CD4 count after treatment of anal fissure	41
4.11 Healing after treatment of perianal suppuration	50
4.12 Healing vs CD4 after treatment of perianal suppuration	50
D.1 Haemorrhoids and anal fistula	61
D.2 Fistulotomy and seton suture	61
D.3 Ischiorectal abscess	62
D.4 Adenocarcinoma of long standing anal fistula	62
D.5 Anal warts	63
D.6 Anal ulcer	63

LIST OF APPENDIXES

Appendix	Page
A Approval of protocol by Postgraduate Committee	57
B Questionnaires used in this study	58
C CDC classification of HIV infection	59
D Atlas of perianal diseases	60
E Ethics clearance certificate by Human Research Ethics Committee (Medical)	64

1 INTRODUCTION

Human immunodeficiency virus (HIV) infection is becoming a global epidemic. According to an estimate of the global HIV situation made by the joint United Nations Programme on HIV/AIDS (UNAIDS) and the World Health Organization (WHO), nearly 30 million adults and children have been infected with HIV.[1] In South Africa, 18.8% of general population and 24% to 30% of pregnant women are HIV positive (data courtesy of Reproductive Health and HIV Research Unit, University of the Witwatersrand). However, medical and surgical therapies for these patients have dramatically improved recently as the result of the advent of combination anti-retroviral drug regimens.[2,3]

Anorectal diseases are common in HIV-infected individuals and are the commonest indications for surgical intervention in these patients. For some, anorectal symptoms may represent the first manifestation of the HIV-infection. Recurrent anorectal disease associated with systemic symptoms may indicate the possibility of AIDS. Cyclomegalovirus (CMV), fungal or chronic perianal herpes simplex infection lasting more than one month, or anorectal lymphoma or Kaposi's sarcoma in the presence of HIV antibody seropositivity establishes the diagnosis of AIDS.[4]

It has not been clear whether the cause and management of anorectal conditions differ in patients who are HIV negative and those who are HIV positive.

There are also variable reports concerning the results of surgical procedures, including wound healing.[5,6] Healing of anorectal disease after surgery is largely determined by the stage of HIV infection. In early reports, the overall healing rate after surgery was extremely poor. Rectal perforation, incontinence, and persistent drainage were reported as complications in 90% of all diagnostic or therapeutic procedures.[7] In contrast, ten years later, Safvi et al reported that HIV positive patients without AIDS have an acceptable outcome after anorectal surgery and that a poor outcome was mostly limited to those with pre-existing AIDS.[8] However, healing rates are not uniformly predicted by CD4 lymphocyte counts alone. Some individuals with long standing HIV infection remain remarkably well despite low CD4 counts, perhaps because of a lower viral load or infection with a less virulent strain of the virus.[9]

With improved retroviral therapy, HIV-positive patients are achieving a longer life expectancy. Consequently, these patients appear to have higher risk for anal malignancy, especially in HIV positive homosexual men[10]. They do poorly

with concurrent radiation and chemotherapy, unless first placed on anti-retroviral therapy.[11] When they undergo surgery, there is not only the risk of wound healing disorders, but a shorter post-operative survival time as well.[11,12]

Currently, the best management of anorectal diseases in patients infected with HIV is unclear and the effective management of these conditions presents the surgeon a considerable challenge.[6]

In the literature, one recommendation for the approach to anorectal symptoms in HIV-infected patients is

> "Although HAART has dramatically altered the occurrence of gastrointestinal complications, many of the same principles of management established before HAART remain applicable. Healing of anorectal diseases following surgical or medical therapy may largely be determined by the stage of HIV infection. HIV positive patients without AIDS have favourable outcomes following anorectal surgery with acceptable wound healing, whereas patients with AIDS are more likely to have a poor outcome".[13]

This is a very general recommendation and there is no clear guide in the current literature for the treatment of perianal diseases in HIV positive patients.

2 STUDY OBJECTIVES

1. To compare the presentation of perianal diseases in HIV +ve and HIV –ve patients
2. To determine the outcome of therapy for perianal diseases in HIV +ve patients

3.0 MATERIALS AND METHODS

3.1 Patient selection

The study population included patients treated by the author in the Colo-rectal Unit at Helen Joseph Hospital as well as in his private practice at Lesedi Private Hospital from 1999 to 2002. Every patient was informed and those who agreed to have their data recorded were included in the study.

3.2 Study methods

The patients were categorized according to HIV status and type of pathology, such as haemorrhoids, fistula-in ano, anal fissure, anal ulcer, anal warts, perianal suppuration, pilonidal sinus, anal cancer and hidradenitis suppurativa.

Every patient was interviewed by using standardized questionnaires (Appendix B) regarding faecal incontinence,

sexual behaviour including anal receptive intercourse and obstetric history.

CDC classification (Appendix C) was used for staging HIV positive patients. Patients received standard counselling about the surgical procedures appropriate in their case and had to consent to these separately.

At the time of the study, the South African health authorities had not approved anti-retroviral therapy (ART) for state patients; thus only private patients were on treatment, which was initiated if their CD4 count was <250/μL.

Prophylactic antibiotics (Augmentin®) were given before surgery and continued post-operatively if necessary.

Patients received specialist care by the author. None of them had any experimental treatment.

Each of them was reviewed every two weeks after the procedure until fit for discharge. Any post-surgical complications, such as bleeding, incontinence, stricture and sepsis, were recorded at each follow-up visit.

3.3 End point of study

Time to discharge was decided when there was no more pain, no more rectal bleeding, no discharge and no tenderness at the surgical wound.

3.4 Data analysis

Cases were stratified according to HIV status. Presentation, treatment and outcome were compared. Microsoft Exel and Statistica version 8 software were used to calculate medians, ranges, means, SD and *p* values.

3.5 Ethics

Approval was obtained from the Postgraduate Committee of the University of the Witwatersrand and the Human Research Ethics Committee (Medical) of the university (M02-04-29) (Appendixes A and E).

4.0 RESULTS AND DISCUSSIONS

A total of 241 patients were included in the study, in which 100 (41.5%) were HIV positive and 141 (58.5%) were HIV negative. The mean age of HIV positive patients was 34,9 yr (range 17-62) and the mean age of HIV negative patients was 41,0 yr (range 5-82) ($p<0.001$).

The HIV positive patients were evenly distributed across the three CDC classifications, 31% at stage II, 34% at stage III and 35% at stage IV. (Note that Stage I refers to the clinically unidentifiable stage of early infection.)

The pathology included 62 haemorrhoids, 67 fistulas, 59 abscesses, 46 fissures, 24 anal ulcers, four anal warts, two pilonidal sinuses, three anal cancers and two hidradenitis suppurativa. Dual pathologies were seen in 28 patients (Table 4.1).

Table 4.1 Perineal diseases and HIV infectivity

Diseases	HIV+ve n	%	HIV –ve n	%	P	Total n	%
Haemorrhoids	25	10.4	37	15.4	0.47	62	25.8
Fistulas	27	11.2	40	16.6	0.81	67	27.8
Ulcers	22	9.1	2	0.8	<0.001	24	9.9
Fissures	11	4.6	35	14.5	0.0071	46	19.1
Suppurations	25	10.4	34	14.1	0.88	59	24.5
Anal warts	3	1.2	1	0.4	0.19	4	1.6
Cancers	-	-	3	1.2	0.0822	3	1.2
Pilonidal sinuses	-	-	2	0.8	0.1566	2	0.8
Hidradenitis suppurativa	1	0.4	1	0.4	NaN	2	0.8
(Dual pathology)	(13) (13)		(15)	(10,6)	0.578	(28)	(11.6)
Total	100		141			241	100

(Percentages express the fraction of the entire sample)

4.1 Haemorrhoids

4.1.1 Demography:

One quarter of both HIV positive and HIV negative patients (25/100 and 37/141; p=0.4) presented with haemorrhoids (Table 4.1). Nearly half of all the patients with haemorrhoids were HIV negative males (29/62). However, the proportion of men and women were similar in HIV positive patients (Table 4.2).

4.1.2 Presentation

4.1.2.1 Symptoms

The main presenting symptoms of haemorrhoids were a mass in twelve HIV negative patients and seven HIV positive patients (12/37 vs 7/25; p=0.7), proctalgia in seven HIV negative patients and one HIV positive patient (p<0.001), bleeding in nine HIV negative and ten HIV positive patients (9/37 vs 10/25; p=0.1) (Table 4.3).

Table 4.2 Patients presenting with haemorrhoids, by HIV status and gender

HIV	Male		Female		Total	
	n	%	n	%	n	%
Negative	29	47	8	13	37	60
Stage II	7		6		13	
Stage III	2		2		4	
Stage IV	6		2		8	
Total +ve	15	24	10	16	25	40
	44		18		62	100

(Percentages express the fraction of the entire sample of patients with haemorrhoids)

Table 4.3 Symptoms of haemorrhoids

HIIV	Mass	Proctalgia	Bleeding	Sepsis	Pruritis ani	Incontinence
Negative	12	7	9	1	1	-
Stage II	6	-	3	2	-	-
Stage III	-	-	4	-	-	-
Stage IV	1	1	3	-	-	1

4.1.2.2 Past medical and social history

A higher proportion of HIV positive patients with haemorrhoids had a previous history of haemorrhoids (11/37 vs 12/25; p=0.07) and of anal receptive intercourse (1/37 vs 4/25; p=0.08) (Table 4.4).

4.1.2.3 Physical signs

Prolapsed haemorrhoids were a common finding in both HIV positive and negative patients (12/37 vs 7/25; p=0.7).

Nine HIV positive patients had abnormally weak anal tone and eight of them were at advanced HIV stages, III and IV. Weak anal tone was a common finding in HIV positive patients with haemorrhoids (Table 4.5).

4.1.2.4 Investigations

4.1.2.4.1 Biochemistry

Two HIV negative patients and three HIV positive patients had a haemoglobin less than 8g/dl. One HIV negative patient was diabetic. Two HIV positive patients had low albumin, less than 20g/l, and high urea, more than 8 mmol/l. Only one HIV positive patient was syphilis serology reactive.

Table 4.4 Past history of patients with haemorrhoids

HIV	Previous Haemorrhoids	BOH	STD	Anal intercourse
Negative	11	2	-	1
Stage II Stage III Stage III	3 4 5	- - -	- 1 -	3 1 -

B O H: Bad Obstetric History
S T D: Sexually Transmitted Diseases

Table 4.5 Abnormal physical signs of the patients with haemorrhoids

HIV	Prolapsed haemorrhoids	High anal tone	Low anal tone
Negative (N=37)	12	-	-
Stage II (N=13) Stage III (N=4) Stage IV (N=8)	6 - 1	1 - -	1 2 6

Table 4.6 Treatment of haemorrhoids

HIV	Conservative	RBL	Surgery
Negative (N=37)	5	5	27
Stage II (N=13) Stage III (N=4) Stage IV (N=8)	2 - 2	3 2 1	8 2 5

RBL= rubber band ligation

4.1.3 Treatment and its outcome

Every patient was initially offered conservative treatment with laxatives, topical application such as Anusol® ointment and local application of ice packs.

Regardless of HIV status, those patients not responding to the conservative treatment underwent either rubber band ligation (RBL) for Grade I and II haemorrhoids or haemorrhoidectomy for Grade III and IV haemorrhoids. In this study, nine patients were treated conservatively, eleven with RBL, and forty-two with haemorrhoidectomy. As can be seen from Table 4.6, similar proportions of both HIV negative and positive patients received each of the three options of treatment.

Healing after haemorrhoidectomy was more rapid in HIV negative than HIV positive patients. The majority healed in less than three weeks (19/27 HIV –ve vs 4/15 HIV +ve, p=0.008).

All HIV positive patients who had healed in three weeks were at the early stage of HIV, stage II. No HIV negative patients took longer than six weeks for healing, but one HIV stage III patient and three HIV stage IV patients did (0/37 vs 4/25; p=0.023) (Figure 4.1).

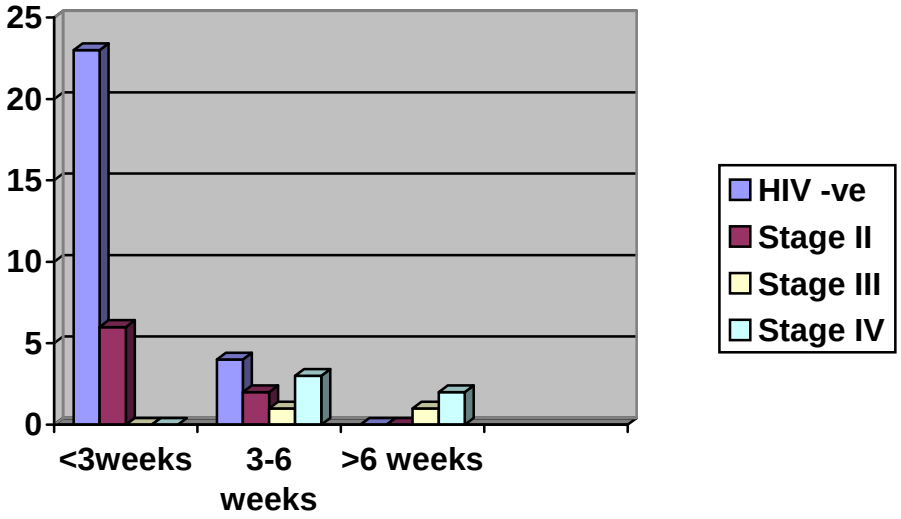

Figure 4.1 Healing after haemorrhoids treatment

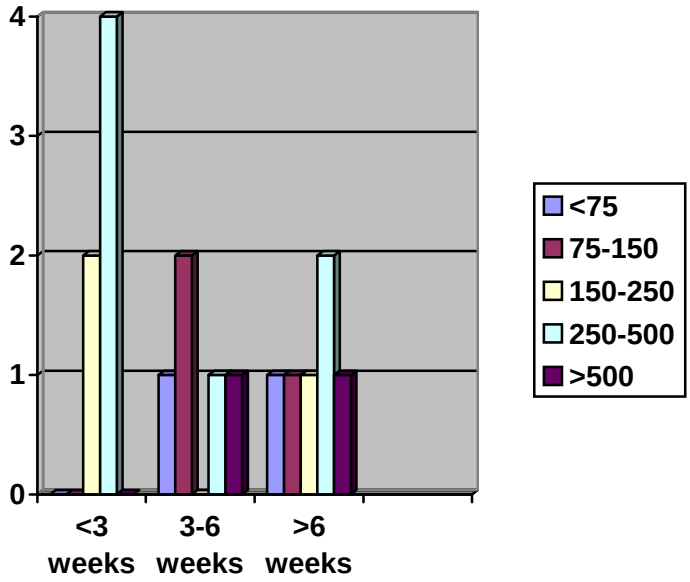

Figure 4.2 Healing vs CD4 count after haemorrhoids treatment (Totals in Figure 4.2 are not the same as in Figure 4.1 because some patients had dual pathology)

Although only a small number of patients (n=17) had CD4 counts measured, the CD4 counts did not appear to predict the healing time after haemorrhoidectomy. As shown in Figure 4.2, healing took longer than six weeks in six patients. Among them, one had a CD4 count more than 500/μL and the other had a CD4 count more than 250/μL.

In our experience, complications after haemorrhoid treatment were infrequent in both HIV negative (one post-operative anal stricture) and positive (one post-operative faecal incontinence) patients. Both of them were treated conservatively. There were no septic complications after haemorrhoid treatment in this study.

4.1.4 Discussion

In this study, 25% of the HIV positive patients with proctological symptoms had haemorrhoids. This finding is consistent with the literature which reports 6-18% occurrence.[5,15-17] It was not different from HIV negative patients in our experience (25/100 vs 37/141; p=0.8).

Both HIV positive and negative patients had typical presenting symptoms of prolapse, pain (proctalgia), bleeding and sepsis.

Although it has not been previously described in the literature, HIV negative patients had more pain (7/37 vs 1/25; p=0.087) and HIV positive patients had more bleeding (9/37 vs 10/25; p=0.1) in our experience.

Both groups of patients had previous haemorrhoidal problems (11/37 vs 10/25; p=0.40). More HIV positive patients admitted practising anal receptive-intercourse (1/37 vs 4/25; p=0.039).

More than a third of HIV positive patients had weak anal tone, but none of HIV negative patients had (0/37 vs 9/25; p=0.001). Although not a diagnostic criteria of AIDS according to CDC classification,[4] the majority of stage IV HIV patients with haemorrhoids (6/8) had abnormally weak anal tone (Table 4.5).

In the literature, immune deficient patients are reported to be more susceptible to serious complications, such as sepsis and delayed healing, after treatment for haemorrhoids.[17-19] For this reason, every HIV positive patient was offered conservative treatment initially. However, failure of conservative management and the patient's request for definitive treatment led to more invasive treatments, rubber band ligation in six patients and haemorrhoidectomy in fifteen patients. Indications for these procedures were similar in both HIV positive and negative patients.

As mentioned above, post-haemorrhoidectomy complications were infrequent in our experience. No patients had post-operative septic complications, in contrast to reports in the literature.[7,18,19]

According to Moore et al,[2] rubber band ligation can be safely performed in selected HIV positive patients. However, none of his eleven patients had AIDS. Encouraging outcomes after anorectal surgery, including haemorrhoidectomy, again in seropositive patients who did not have AIDS, were described by Safvi.[8]

In our study, six patients with AIDS had haemorrhoid treatments (one had rubber band ligation and the others had haemorrhoidectomy). It is probable that the absence of septic complications was related to the usage of peri-operative antibiotics as well as anti-retroviral therapy for the patients with advanced HIV stage.

Although there were no septic complications, HIV positive patients did have delayed wound healing. All patients with delayed wound healing more than six weeks were advanced stage HIV-positive patients. In this respect, we agree with the report by Morandi[19] of a high incidence of delayed wound healing in AIDS patients.

The CD4 count was not a good predictor for wound healing after haemorrhoidectomy in this study, and this finding is consistent with the literature.[9]

4.2 Fistula in ano

4.2.1 Demography

Nearly one third of both HIV positive and negative patients presented with fistulas. As shown in Table 4.7, anal fistulas were more common in males in our experience, (male: female ratio approximately 3:1 in both +ve and –ve patients), consistent with the general tendency in this disease.

4.2.2 Presentation

4.2.2.1 Symptoms

The main presenting symptoms were small nodules, in five HIV negative and sixteen HIV positive patients (5/40 vs 16/27; p=0.0001); pain, in five HIV negative and seventeen HIV positive patients (5/40 vs 17/27; p=0.0001); discharge, in the majority of patients (38/40 vs 25/27; p=0.65); and incontinence, in sixteen HIV positive patients. None of the HIV negative patients presented with incontinence (0/40 vs 16/27; p<0.0001) (Table 4.8).

Table 4.7 Gender and HIV status of patients with anal fistula

HIV	Male	%	Female	%	Total
Negative	32	80	8	20	40
Stage II	5		-		5
Stage III	8		4		12
Stage IV	7		3		10
Total +ve	20	74.1	7	25.9	27
Total	52		15		67

Table 4.8 Symptoms of anal fistula

HIV	Nodule	Proctalgia	Discharge	Incontinence
Negative (N=40)	5	5	38	-
Stage II (N=5)	2	2	3	-
Stage III (N=12)	7	8	12	6
Stage IV (N=10)	7	7	10	10

4.2.2.2 Past history

Eight HIV negative (8/40) and twelve HIV positive (12/27) patients with fistula gave a history of previous abscess ($p=0.032$). No patients had a prior obstetric problem or any sexually transmitted diseases (STD), or practised anal receptive intercourse.

4.2.2.3 Physical signs

Anal fistulas were classified depending on the course of the fistula tract in relation to the anal sphincters (Figure 4.3):

Inter-sphincteric: the tract passes between the internal and external anal sphincters

Trans-sphincteric: the tract passes through the external anal sphincter

Supra-sphincteric: the tract passes above the external anal sphincter

Extra-sphincteric: the tract passes through the entire sphincter mechanism with a supralevator internal opening

Complex: a fistula with a secondary tract and/or tract course around more than half of the circumference of the external sphincter

Multiple: Multiple fistulas, presenting more than two fistulas

Recto-vaginal fistula: fistula between the rectum and vagina

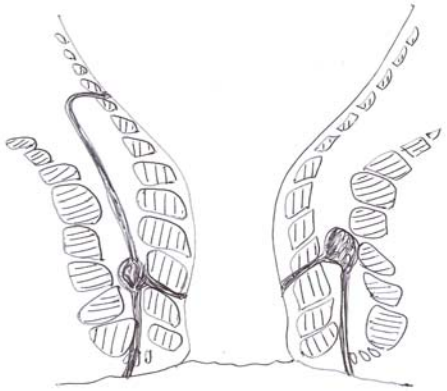

Inter-sphincteric fistula

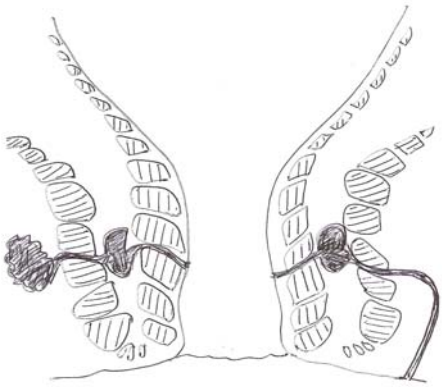

Trans-sphincteric fistula

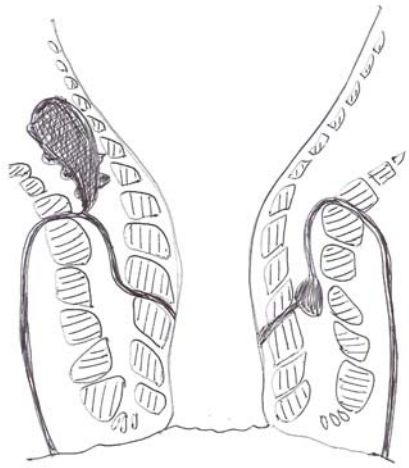

Supra-sphincteric fistula

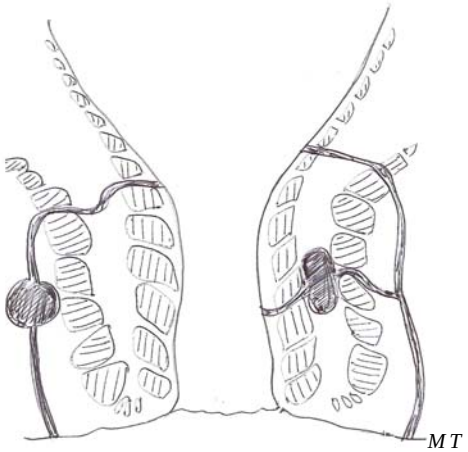

Extra-sphincteric fisula

Figure 4.3 Different types of anal fistula

4.2.2.4 Investigations

4.2.2.4.1 Biochemistry

Thirteen patients with fistulas had abnormal blood biochemistry. Two HIV negative and four HIV positive patients had low albumin, less than 20g/l. One HIV negative patient was diabetic. Three HIV positive patients at stage IV had low haemoglobin (less than 8g/dl), and high urea (more than 8 mmol/l).

4.2.2.4.2 Histology

The histology of fistulas was requested in 29 cases especially in patients with complex or multiple fistulas. Most of them showed non-specific histology. However, two HIV negative patients with long standing fistula had malignant lesions and two HIV positive patients with multiple fistulas had the granulomatous histology suggestive of tuberculosis
(Table 4.10).

4.2.3 Treatment and its outcome

Treatment was determined individually, depending on the type of fistula and the severity of sepsis (Table 4.11).

Fistulotomy, laying open of the fistula tract, was used for low fistulas, where the internal opening was below the level of the dentate line.

A seton stitch (usually a silicone feeding tube, 5F to 8F) was used for the high fistulas where the internal opening was above the dentate line.

Colostomy was used for multiple fistulas with severe infection.

Each patient received prophylactic intravenous antibiotics, 1.2 gm of Augmentin®. In severe sepsis, the antibiotic was continued if necessary.

Patients were reviewed at two weekly intervals after the procedure until healing. Seton stitches were tightened at the same time until they cut through the fistulas. Healing was recorded when the patient became pain free, there was no more rectal bleeding, no discharge and no tenderness at the surgical wound.

The Figures 4.4, 4.5 and 4.6 show that the healing time was not determined by HIV status and CD4, but by the types of fistulas, in which complex fistulas and trans-sphincteric fistulas needed a longer healing time. Fourteen HIV negative patients had a healing time longer than six weeks. Ten HIV negative patients with complex fistulas and seven patients (4 –ve and 3 +ve) with trans-sphincteric fistulas needed more than six weeks to heal.

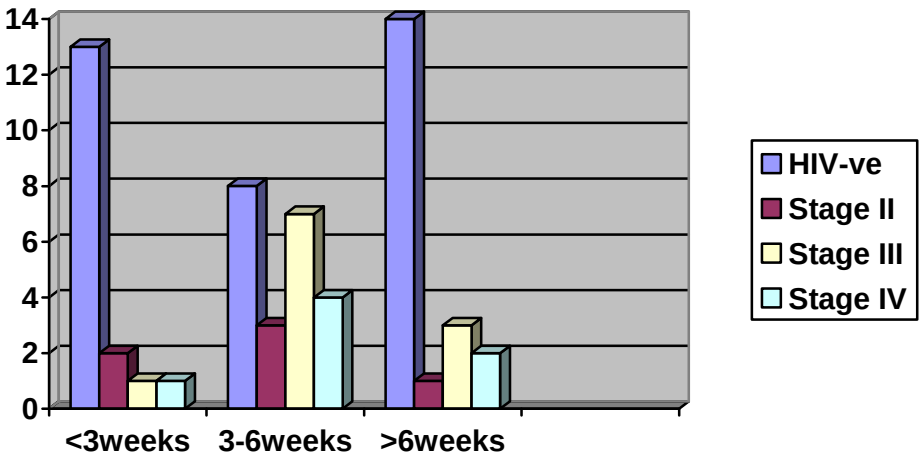

Figure 4.4 Healing after treatment of fistulas

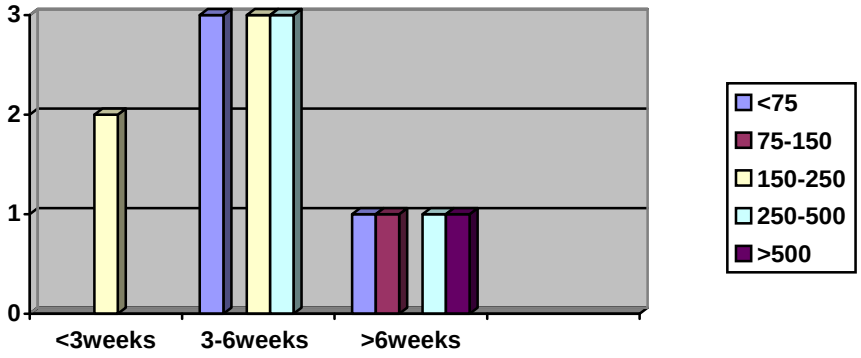

Figure 4.5 CD4 vs healing after treatment of fistulas

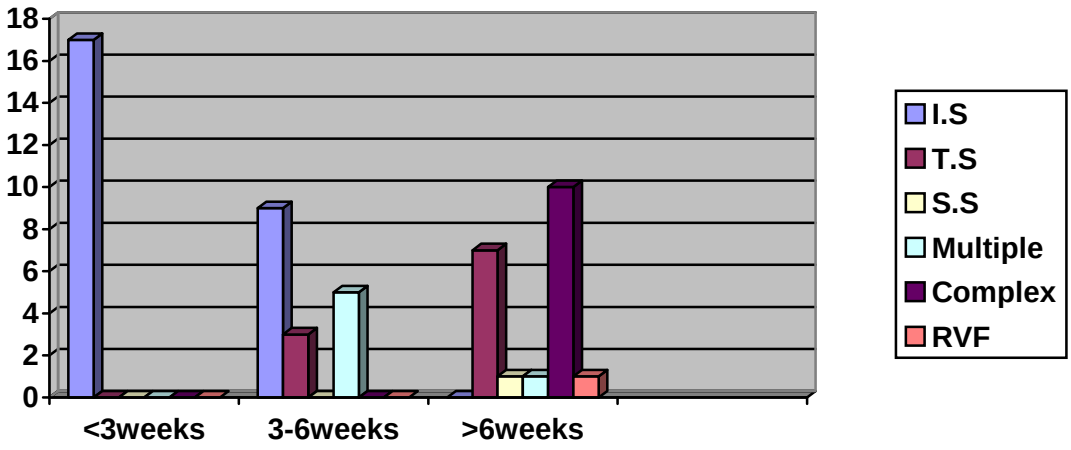

Figure 4.6 Healing vs type of fistula

I.S: Intersphincteric

T.S: Transsphincteric

S.S: Suprasphincteric

RVF: Rectovaginal

Four patients with AIDS died during follow-up as the result of their poor general condition. One HIV negative patient had post-operative faecal incontinence after fistulotomy, which was successfully managed conservatively.

Table 4.9 Type of fistula and HIV status of patients

HIV	Inter-sphincteric	Trans-sphincteric	Supra-sphincteric	Recto-vaginal	Multiple	Complex
Negative	16	9	1	-	1	12
Stage II	2	3	-	-	-	-
Stage III	8	2	-	-	2	1
Stage IV	3	1	-	1	5	-
Total +ve	13	6	-	1	7	1
Total	29	15	1	1	8	13

Table 4.10 Histology of fistulas

HIV	Non-specific	TB	Malignant
Negative	16	-	2
Stage II	1	1	-
Stage III	2	-	-
Stage IV	6	1	-

Table 4.11 Treatment of fistulas

HIV	Fistulotomy	Seton stitch	Colostomy	
Negative	21	19	-	40
Stage II	3	4	-	
Stage III	7	4	-	
Stage IV	2	2	5	
	12	10	5	27

4.2.4 Discussion

Nearly one third of the patients in this study presented with anal fistulas.

In the literature, it has been reported that anal fistulas are commonly seen in HIV positive individuals.[20,21] Although some aspects of anal fistulas have been examined, not much is known about anal fistulas in HIV positive patients.

According to Manookian, HIV status influences the anatomy of anal fistulas and HIV positive patients were more likely to have incomplete anal fistulas (blind tracts, sinuses) than others. However, their symptoms are similar in both HIV positive and negative patients.[21]

In our experience, both HIV negative and positive patients presented with similar symptoms of perineal nodules, pain and discharge. However, more than half of HIV positive patients presented with anal incontinence and all of them were in the advanced stages of HIV, either at stage III or IV.

Concerning types of fistulas, both groups had almost similar presentations of simple fistulas. However, HIV negative patients had more complex fistulas (12/40 HIV negative vs 1/27 HIV positive, $p<0.001$) and HIV positive patients had more

multiple fistulas (7/27 HIV positive vs 1/40 HIV negative, p=0.006) (Table 4.9). One possible reason for unexpectedly large numbers of complex fistulas in the patients without HIV may be because of a referral bias to a specialised colorectal service.

Nearly a quarter (6/25) of HIV positive patients had low anal tone and most of them were at stage IV.

Although the majority of biopsy results were non-specific (16/18 HIV negative and 9/11 HIV positive), two HIV positive patients' biopsies showed mycobacterium infection (TB) and two of HIV negative patients' showed malignant pathology. This diagnosis was not considered on clinical grounds prior to the histological report. Although this is only a small sample (eleven HIV positive patients), it is possible that tuberculous fistulas are not uncommon and we propose sending tissue for histological examination routinely.

Nadal et al studied healing after anal fistulotomy. They concluded that HIV positive patients with low CD4 counts should have surgical treatment only in emergency cases, as they tend to have post-operative complications. Those patients in the earlier HIV stage should have the same surgery as HIV negative patients.[22]

In our experience, healing after the treatment of fistulas was not determined by the HIV status of patients, but rather by the

types of fistulas. Those that had healing times longer than six weeks were mostly HIV negative patients (Figure 4.4).

CD4 counts were not a good indicator for healing time, as a number of patients with reasonable CD4 counts had longer healing times (Figure 4.5).

However, it was the types of fistulas that determined the healing time. Trans-sphincteric fistulas and complex fistulas needed longer to heal. Inter-sphincteric fistulas healed faster (Figure 4.6). In contrast to the concerns in the literature,[22] septic complications were not a problem in our experience. Using prophylactic antibiotics and draining seton sutures might account for this. However, four HIV positive patients died during the course of follow-up. All of them were in stage IV HIV and presented with multiple fistulas; they were treated with diverting colostomy.

In our experience, the individuals in the stage IV, presenting with multiple fistulas had a very poor prognosis; however their deaths were related to the advanced stage of their disease, rather than the fistula or their treatment.

4.3 Anal Ulcer and fissure

4.3.1 Demography

In this series, 24 patients (14 males and 10 females) had anal ulcers and 46 patients (19 males and 27 females) had anal fissures. In general, HIV negative patients were older than HIV positive patients (Tables 4.12 and 4.13).

4.3.2 Presentation

4.3.2.1 Symptoms

Both anal ulcers and fissures had similar presenting symptoms of proctalgia, bleeding and incontinence (Tables 4.14 and 4.15). In our experience, it was very difficult to differentiate these two conditions in terms of their symptoms particularly in HIV infected individuals.

4.3.2.2 Past medical and social history

A history of proctalgia was commonly reported. Four HIV positive patients with anal ulcers and five HIV negative patients with anal fissures admitted practising anal receptive intercourse (Tables 4.16 and 4.17).

4.3.2.3 Physical signs

Careful examination differentiates these two confusing pathologies.

Sentinel piles were present in thirty patients with anal fissures (30/46), but none in patients with anal ulcers ($p<0.0001$).

Abnormally weak anal tone was detected in the majority of anal ulcers in HIV positive patients (13/22), but only one stage IV HIV patient with anal fissure had a weak anal tone (1/11) ($p<0.001$). The majority of anal fissures in both HIV positive (8/11) and negative (29/35) ($p=0.46$) patients had a higher anal tone, but none of the patients with anal ulcers had increased tone ($p<0.0001$) (Tables 4.18 and 4.19).

4.3.2.4 Investigations

4.3.2.4.1 Biochemistry

HIV positive patients, especially in advanced stages, had a tendency to abnormal blood biochemistry. Five HIV positive patients with anal ulcers and one HIV positive patient with anal fissure had low albumin (less than 20g/l) and raised urea (more than 8 mmol/l). Two HIV negative patients, one with anal ulcer and the other with anal fissure, were anaemic, haemoglobin level less than 8g/dl. One HIV negative patient with anal fissure was syphilis serology positive.

4.3.2.4.2 Histology

The majority of biopsies were non-specific. However, biopsy is mandatory to exclude other pathologies, such as TB and malignancy. One HIV negative patient had a malignant ulcer and two HIV positive patients had tuberculous ulcers (Tables 4.20 and 4.21).

Table 4.12 Age and HIV status of patients with anal ulcer

HIV	n	Age: median (range)
Negative	2	64 y (52-76)
Stage II Stage III Stage IV	3 5 14	35 y (25-64) 34 y (32-36) 37 y (24-62)
	22	35 y (25-64)

Table 4.13 Age and HIV status of patients with anal fissure

HIV	n	Age: median (range)
Negative	35	42 y (19-64)
Stage II Stage III Stage IV	6 3 2	32 y (23-64) 35 y (34-39) 30,37 y
	11	34 yr (23-64)

Table 4.14 Symptoms of anal ulcer

HIV	n	Proctalgia	Bleeding	Incontinence
Negative	2	2	2	-
Stage II Stage III Stage IV	3 5 14	3 5 14	- 2 3	- 3 14

Table 4.15 Symptoms of anal fissure

HIV	n	Proctalgia	Bleeding	Incontinence
Negative	35	35	20	-
Stage II Stage III Stage IV	6 3 2	6 3 2	3 1 -	- - 2
	11	11	4	2

Table 4.16 Previous history of patients with anal ulcer

HIV	Previous proctalgia	BOH	STD	Anal intercourse
Negative	2	1	-	-
Stage II	1	-	-	-
Stage III	3	-	-	1
Stage IV	10	-	-	1

Table 4.17 Previous history of patients with anal fissure

HIV	Previous proctalgia	BOH	STD	Anal intercourse
Negative	15	-	-	5
Stage II	4	-	1	1
Stage III	-	-	-	-
Stage IV	1	-	-	-

Table 4.18 Physical signs of anal ulcer

HIV	Sentinel pile	Anal mucosal defect			Anal tone	
		anterior	posterior	multiple	high	low
Negative	-	-	2	-	-	-
Stage II	-	-	3	-	-	1
Stage III	-	-	5	-	-	2
Stage IV	-	2	11	1	-	10

Table 4.19 Physical signs of anal fissure

HIV	Sentinel pile	Anal mucosal defect			Anal tone	
		anterior	posterior	multiple	high	low
Negative	26	7	27	1	29	-
Stage II	4	1	4	1	6	-
Stage III	-	1	2	-	2	-
Stage IV	-	-	2	-	-	1

Table 4.20 Histology of anal ulcer

HIV	Non-specific	TB	Malignant	CMV proctitis
Negative	1	-	1	-
Stage II Stage III Stage IV	2 3 12	1 1 -	- - -	- - 1

Table 4.21 Histology of anal fissure

HIV	Non-specific	TB	Malignant	Bilharzia
Negative	32	-	-	1
Stage II Stage III Stage IV	5 3 2	- - -	- - -	- - -

Table 4.22 Treatment of anal ulcer

HIV	Biopsy and conservative	Debridement and suture	Lateral sphincterotomy	Colostomy
Negative	2	-	-	-
Stage II Stage III Stage IV	- 3 6	- 4 2	2 - -	- - 1

Table 4.23 Treatment of anal fissure

HIV	Biopsy and conservative	Debridement and suture	Lateral sphincterotomy	Colostomy
Negative	7	-	28	-
Stage II Stage III Stage IV	2 1 1	- - -	4 2 1	- - -

4.3.3 Treatment and its outcome

Treatment started with analgesics and local glyceryl trinitrate. Examination under anaesthesia (EUA) was performed in each patient and the type of surgical treatment was determined according to the findings. Each patient received prophylactic IVI Augmentin® 1.2 gm. Oral antibiotics (Augmentin® 625 mg t.d.s) were prescribed post-operatively in HIV positive patients until the sepsis was controlled.

Patients were reviewed every two weeks after the procedure until the patient became pain free, and there was no discharge or tenderness at the surgical wound.

Figures 4.7, 4.8, 4.9 and 4.10 show the healing time after the procedure.

Ten HIV positive patients with anal ulcer needed more than six weeks for healing of the surgical wound to occur and all of them had advanced HIV disease, ie. stages III and IV.

The majority of HIV negative patients healed in less than three weeks after their operation for anal fissures.

The CD4 count did not correlate with healing after the procedures in either condition.

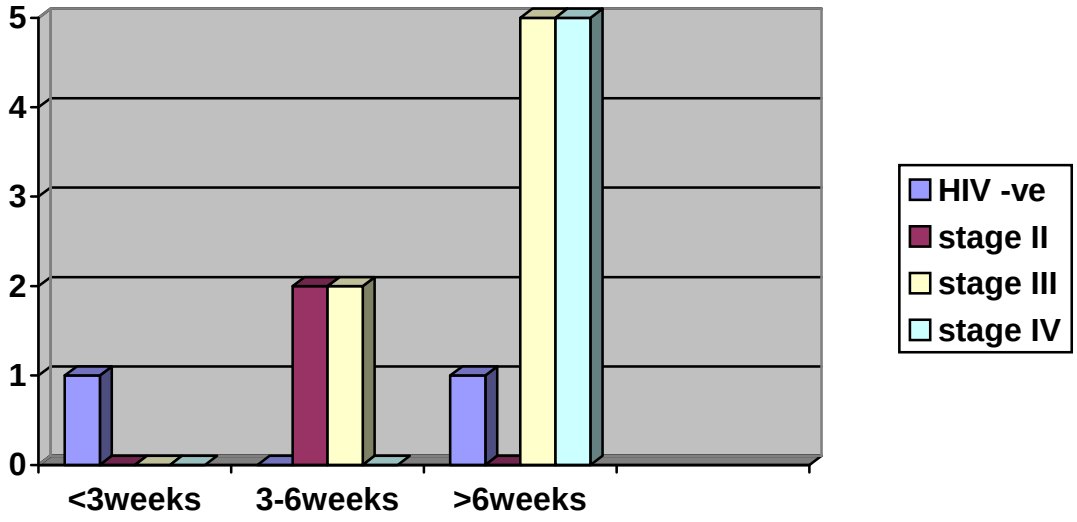

Figure 4.7 Healing after treatment of anal ulcer

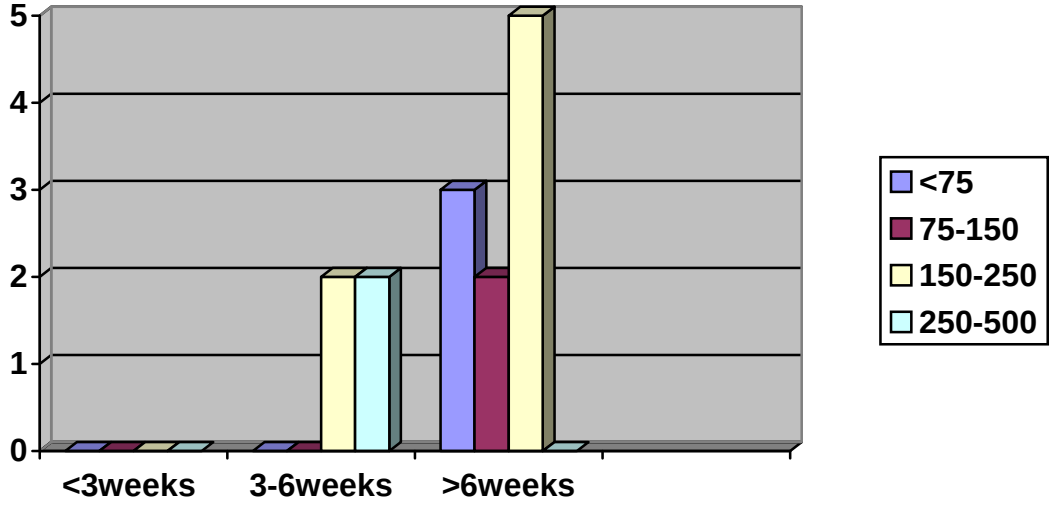

Figure 4.8 Healing vs CD4 count after treatment of anal ulcer

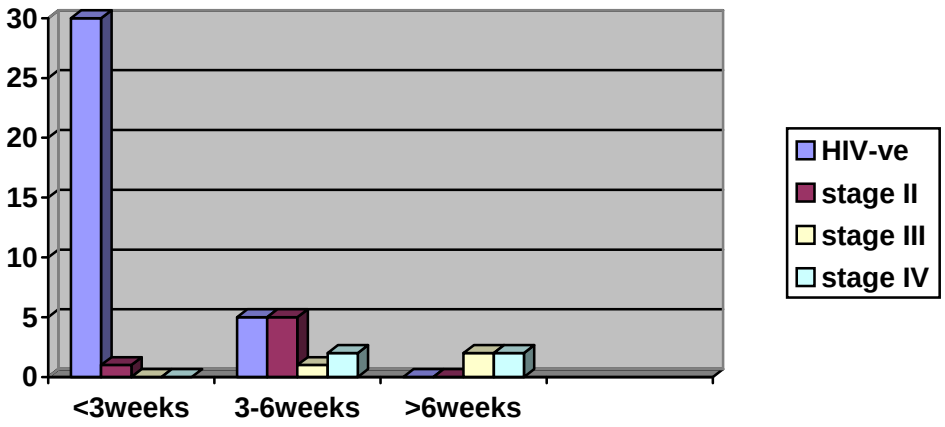

Figure 4.9 Healing after treatment of anal fissure

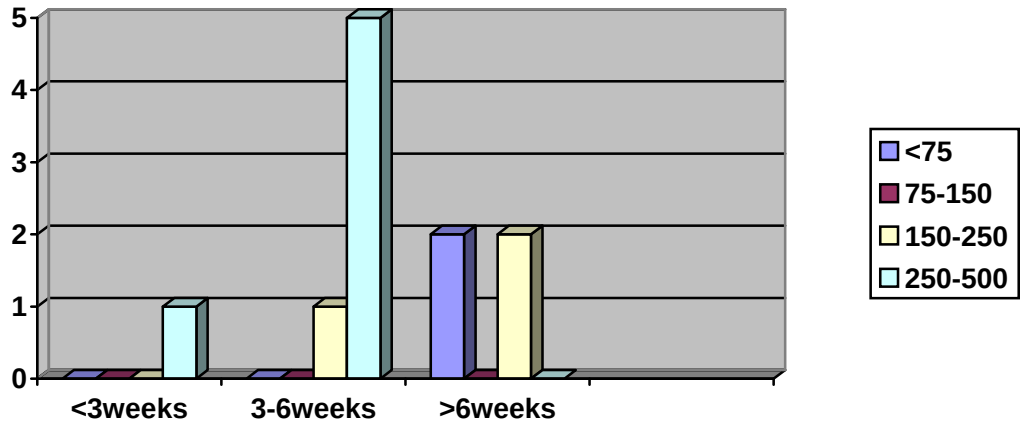

Figure 4.10 Healing vs CD4 count after treatment of anal fissure

Post-operative faecal incontinence was fortunately infrequent after treatment of both conditions. One HIV +ve patient with anal ulcer became severely incontinent after lateral sphincterotomy and needed to have diversion colostomy. Two patients with anal fissure, one HIV negative and one stage III HIV, were also incontinent after lateral sphincterotomy, but both recovered fully after a few weeks of conservative treatment. There were four deaths in patients with anal ulcers and one in the anal fissure patients. All of them were patients with AIDS and their deaths were unrelated to the surgery.

4.3.4 Discussion

Pain is the most common symptom of HIV positive patients requiring anorectal surgery.[4] Both anal ulcers and fissures present with severe pain and similar clinical pictures except that anal ulcers tend to have a wider ulcer base and a more proximal position than anal fissures, consistent with previous reports.[4,23,24]

Many HIV positive patients suffered from chronic diarrhoea, which is recognized as a predisposing factor for anal fissures.[24] In our experience, 11% of HIV positive patients presented with anal fissures and 22% of them presented with anal ulcers. The

majority of anal ulcers were seen in the advanced HIV individuals (Table 4.12).

Proctalgia and rectal bleeding were common symptoms in both conditions. However, no HIV negative patients had anal incontinence (Table 4.14 and 4.15). The majority of HIV positive patients (17/22) with anal ulcers, but only two HIV positive patients with anal fissures (2/11), were incontinent ($p<0.05$), and all of them were at advanced HIV stages.

Both anal ulcers and fissures are located commonly at the posterior part of anal canal in these patients. For these reasons, it can be difficult to differentiate between anal ulcers and fissures in some patients.

Two clinical criteria assist in making the distinction readily and reliably: the presence of a sentinel pile, and the anal tone (measured digitally).

A sentinel pile was present in 26/35 HIV negative patients and 4/11 HIV positive patients, but in none of the patients with anal ulcer ($p<0.0001$).

Higher anal tone was detected in 29/35 HIV negative patients and 8/11 HIV positive patients with anal fissures, in contrast to 13/22 HIV positive patients with anal ulcers who had low anal tone. No anal ulcers presented with high anal tone ($p<0.0001$) (Tables 4.18 and 4.19).

In accordance with the literature,[23,24] conservative treatment was started for both conditions. Surgical treatment was reserved for those not responding to conservative treatment (Tables 4.22 and 23).

In six HIV positive patients, the anal ulcers were treated with debridement and suturing of the ulcers. They achieved better pain relief after operation although healing was prolonged after the procedure (> 6 weeks). However, after lateral sphincterotomy, one HIV positive patient with an anal ulcer developed severe incontinence and no pain relief at all. For those patients with anal fissures, seven HIV positive patients had lateral sphincterotomy and all of them had improvement as did their HIV negative counterparts. Lateral sphincterotomy should not be used as a surgical treatment for anal ulcers.

Concerning healing after surgery, patients with advanced HIV and low CD4 count tend to have delayed healing times.

During the follow-up period, four HIV positive patients with anal ulcers and one HIV positive patient with anal fissure died; all of them were suffering from AIDS (ie. stage IV disease). None of the HIV positive patients had post-operative septic complications.

4.4 Perianal suppuration

4.4.1 Demography

Nearly one third of both HIV positive and negative patients presented with perianal suppuration. Regardless of HIV status, perianal suppuration was more common in males (Table 4.24).

4.4.2 Presentation

4.4.2.1 Symptoms

The main symptoms were boils (26/39 HIV –ve vs 12/31 HIV +ve; p=0.02), spreading infection (1/39 HIV-ve vs 3/31 HIV +ve; p=0.23), discharge (11/39 HIV –ve vs 11/31 HIV +ve; p=0.51) and incontinence (0/39 HIV –ve vs 4/31 HIV +ve; p=0.034) (Table 4.25).

4.4.2.2 Past medical and social history

No female patients had a bad obstetric history and none had practised anal receptive intercourse.

4.4.2.3 Physical signs

Eighteen HIV negative patients and twenty HIV positive patients had other pathologies, such as pilonidal sinus, hidradenitis suppurativa, fistula, ulcer and haemorrhoids. The

findings were similar in both HIV negative and positive individuals, except eight advanced HIV positive patients had abnormally weak anal tone (Table 4.26).

4.4.2.4 Investigations

Three HIV negative patients with sepsis were diagnosed as diabetic. Six of the stage IV HIV positive patients had abnormal blood results, a low albumin level. One stage III HIV positive patient was syphilis serology reactive. Two patients (one HIV negative and the other stage III HIV positive) with multiple abscesses were found to have mycobacterium infection on their pus swab.

4.4.3 Treatment and its outcome

Every patient was treated as a surgical emergency.

The treatment was individualized depending on the type of pathology, severity of the sepsis and the patient's general condition (Table 4.27). Peri-operative antibiotics (Augmentin®) were given to every patient routinely.

Each patient was reviewed every two weeks after surgery.

Two of the stage IV HIV infected patients died during the course of follow-up due to their poor general condition, unrelated to their surgery.

Ten advanced HIV stage (stage III and IV) patients, one HIV negative and one early HIV stage (stage II) healed six weeks after operation. Advanced HIV stage predicted longer healing time ($p<0.001$). Ten HIV positive patients with CD4 count more than 500/µl (10/14) healed within three weeks (Figures 4.11 and 4.12).

No other post-operative complications were noted.

Table 4.24 Age and HIV status of patients with perianal suppuration

HIV	Male	Female	Age: median (range)
Negative	27	12	40 y (5-70)
Stage II Stage III Stage IV	5 8 10	3 4 1	35 y (16-52) 33 y (20-54) 35 y (32-48)
	23	8	34 y (16-52)

Table 4.25 Symptoms of perianal suppuration

HIV	Boils	Spreading infection	Discharge	Ulcer	"pile"	Incontinence
Negative	26	1	11	-	2	-
Stage II Stage III Stage IV	5 7 -	- 2 1	1 3 7	- - 2	2 - -	- 1 3
	12	3	11	2	2	4

Table 4.26 Findings in perianal suppuration

Findings	HIV negative	HIV stage II	HIV stage III	HIV stage IV
Site of abscess				
Subcutaneous	17	4	3	3
Submucous	-	1	-	-
Intersphincteric	3	1	-	1
Ischiorectal	11	1	6	1
Multiple	1	2	1	5
Pararectal	2	-	-	-
Associated pathology				
Sphincter defect	-	-	1	-
Necrotizing fasciitis	1	-	2	1
Fistulas	11	1	3	7
Ulcer	-	-	-	2
Haemorrhoids	2	2	-	-
Pilonidal sinus	3	-	-	-
Hidradenitis supp.	1	-	1	-
Low anal tone	-	-	1	7

Table 4.27 Treatment of perianal suppuration

Treatment	HIV negative	HIV stage II	HIV stage III	HIV stage IV
Incision & drainage (I&D)	20	6	7	2
I&D and fistulotomy	15	2	1	5
I&D and rubber band ligation	1	-	-	-
Debridement	1	-	2	1
Debridement & colostomy	1	-	-	-
I&D and seton suture	1	-	1	1
I&D and colostomy	-	-	1	2

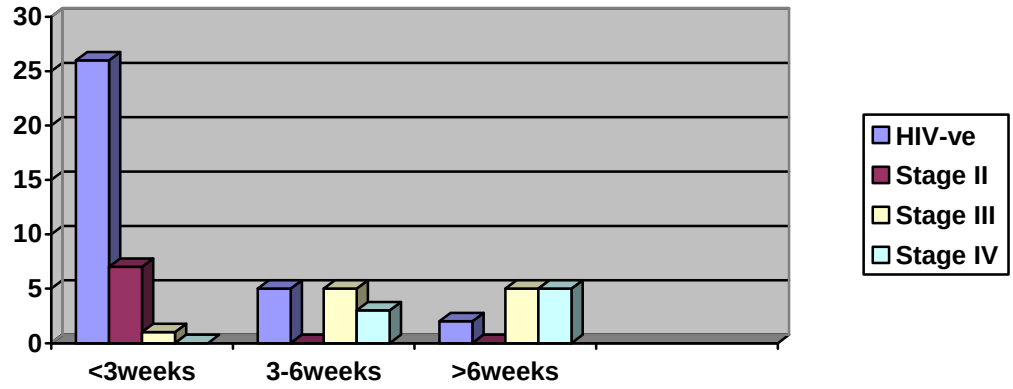

Figure 4.11 Time to Healing after treatment of perianal suppuration

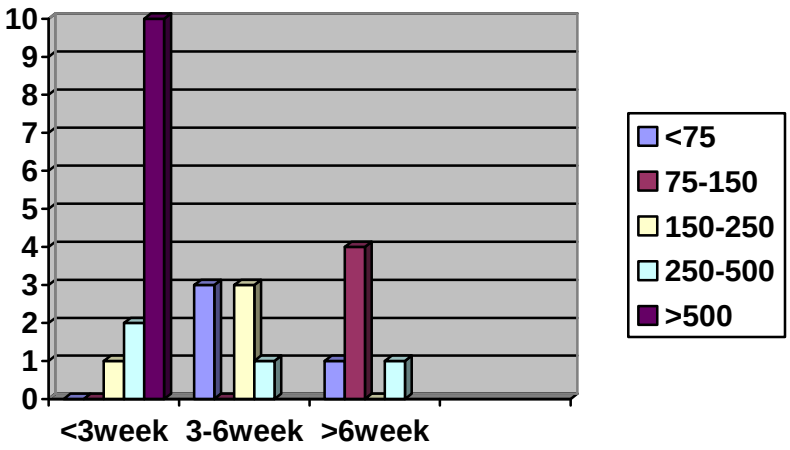

Figure 4.12 Healing vs CD4 after treatment of perianal suppuration

(Totals in Figure 4.12 are not the same as Figure 4.11 because some patients had dual pathologies)

4.4.3 Discussion

It is well recognized that a major cause of morbidity and mortality in the immunocompromised patient is infection and up to 34% of HIV infected patients have been reported as having fistula-in-ano and perianal abscess.[8,25] In this study, one third of patients, regardless of HIV status, presented with perianal suppuration. However, multiple abscesses, spreading infection, such as necrotizing fascitis, and incontinence were more common in advanced HIV staged patients (Tables 4.25 and 4.26).

In the literature, there is a consensus regarding the importance of the proper management of perianal sepsis in immunocompromised patients. Although most surgeons recommend incision and drainage for perianal suppuration, there was controversy about the proper management of associated fistula. Some surgeons, concerned about prolonged or absent wound healing and incontinence, advocate a conservative approach. Others believe that the fistula should be treated at the time of drainage as in the general population.[22,25,26]

In our experience, four advanced HIV infected patients had preoperative incontinence and eight advanced HIV infected patients had low anal tone preoperatively. But none of our

patients suffered postoperative sphincter damage and incontinence. As shown in the Table 4.27, eight HIV positive patients had primary fistulotomy and two advanced HIV positive patients had seton suture. All of them achieved control of sepsis and there was no recurrence of sepsis after the treatment.

One HIV negative patient and three advanced HIV positive patients needed a colostomy due to severe sepsis. Although two HIV patients died as a result of their poor general condition, the sepsis was well controlled after colostomy.

Advanced HIV infection and a low CD4 count were the main causes of delayed wound healing in our experience (Figures 4.11 and 4.12). None of patients with CD4 count more than 500/µl took longer to heal than six weeks, but ten advanced HIV positive patients did.

4.5 Anal cancers and warts

Four HIV negative patients had anal malignancies: one squamous cell carcinoma (SCC) and three adenocarcinoma (one of the latter was a cancer arising in a fistula). Interestingly, there were no anal malignancies in the 100 consecutive HIV positive patients with anorectal symptoms in this series.

Four patients had anal warts and all of them underwent excision biopsies which showed benign histology with human papilloma virus (HPV) infection. Three of them were at the advanced HIV stage, two at stage III and one at stage IV. All HIV positive patients had delayed healing longer than six weeks after wart excision. Two HIV positive patients recurred six weeks after excision.

4.5.1 Discussion

In the literature, HIV positive patients have a higher risk for anal malignancies, particularly squamous cell carcinoma of the anus (SCCA).[11] However, this was not so in our experience. Although HIV status had not been linked with the patient's histology for ethical reasons, there were only sixteen recorded cases of SCCA from 2000 to 2007 at the Chris Hani Baragwanath Hospital, the main referral centre for Soweto with its population of over one million. (Data courtesy of the Department of Anatomical Pathology, Chris Hani Baragwanath

Hospital.) In our experience, SCCA is an uncommon pathology in both HIV positive and negative patients.

The scarcity of SCCA is not merely a function of referral bias- i.e. that patients might not choose to be treated in Soweto or in public hospitals. It is still an uncommon disease in South Africa,[27] despite the ravages of HIV. The Central Laboratory of the NHLS at the Johannesburg Hospital (which serves the rest of the Witwatersrand, as well as hospitals from Klerksdorp and Nelspruit, with a population at least ten times that of Soweto) only diagnosed on average only 12 cases per year during the same period (2001-2007).

Due to the strong association between anorectal human papilloma virus (HPV) infection and SCCA,[27] each patient with anal warts was offered excision biopsy. Advanced HIV patients had delayed wound healing and half of them recurred after six weeks after surgery. Although our sample had only a small number of patients, we agree with the literature that anorectal condylomata in immunodeficient patients are more aggressive, with high recurrences and possible high neoplastic transformation rates.[27]

5 CONCLUSION

Our experience confirms that of other workers in the field, in which conservative treatment is preferable in patients at the advanced HIV stages, III and IV. However, procedure related septic complications did not occur in our study patients.

A possible reason was the usage of antiretroviral drugs and preoperative antibiotics, which might prevent the septic complications and made the surgical procedures safer, especially after haemorrhoidectomy and rubber band ligation.

Advanced HIV stages predict longer healing time except in patients with anal fistula, in whom the *type* of fistula is the main factor of delayed wound healing.

When comparing the distribution of multiple versus complex fistulas, HIV positive patients were more likely to suffer from multiple fistulas, especially at the advanced stages and imply a poor prognosis, while complex fistulas were more commonly seen in HIV negative patients.

Both anal ulcer and fissure are common in HIV positive patients and careful physical examination can differentiate between these two confusing pathologies. Weak anal tone and absence of sentinel pile are the pathognomonic findings in anal ulcer and the contrary is true in anal fissure. Lateral sphincterotomy is a relatively safe procedure for anal fissure.

However, it is contraindicated in anal ulcer of HIV positive patients. Our experience showed that HIV related anal ulcers are associated with abnormally weak anal tone and sphincterotomy can risk further sphincter damage.

Perianal suppuration is a surgical emergency in immunocomprised patients due to high morbidities and mortalities. Associated fistula can be treated similarly in both HIV negative and positive patients without increased complications.

In our experience, anal malignancies, especially SCCA, are uncommon in HIV positive patients.

APPENDIXES

Appendix A Approval of protocol

Faculty of Health Sciences

UNIVERSITY OF THE WITWATERSRAND, JOHANNESBURG

7 York Road PARKTOWN Johannesburg 2193 Telegrams WITSMED Telex 4-24655.SA
FAX 643-4318 TELEPHONE 717-2075/2076
E-MAIL healthpg@health.wits.ac.za

DR M TUN
P O BOX 96595
BRIXTON
2019

APPLICATION NUMBER 9613898D
STATUS (DEG 27) (MMR00) PZZ

2003-03-27

Dear Dr Tun

Approval of protocol entitled Perianal pathology and HIV infection

I should like to advise you that the protocol and title that you have submitted for the degree of Master Of Medicine (In Surgery) have been approved by the Postgraduate Committee at its recent meeting. Please remember that any amendment to this title has to be endorsed by your Head of Department and formally approved by the Postgraduate Committee.

Prof GJ Oettle has/have been appointed as your supervisor/s. Please maintain regular contact with your supervisor who must be kept advised of your progress.

Please note that approval by the Postgraduate Committee is always given subject to permission from the relevant Ethics Committee, and a copy of your clearance certificate should be lodged with the Faculty Office as soon as possible, if this has not already been done.

Yours sincerely

ME Fick (Mrs)
Faculty Registrar
Faculty of Health Sciences

Telephone 717-2075/2076

Copies - Head of Department____Supervisor/s

Appendix B Questionnaires

Case Number:(_____)

Name..... Age..... Sex..... Race..... Hospital number.....

History:Continenece,preop..... postop.....

Sexual behavior.....anal /vaginal

Obstetric h/o: P( )G( ) , Vag/ CS , Difficult /Prolonged/ Forceps , Postpartum continence/tears.

Diagnosis:abscess(a)type.....(b)Organisms(pus swab).....

Fistula (a)type.....Hemorrhoids.....

Ulcers(a)description.....(b)site.....

Fissure(a)extent.....(b)position.....Malignancy.....

EUA(a)state of rectal mucosa..... (b)sphincter tone: H./N./L.

Others.....

Operation.& Other treatment.....

HIV:asymptomatic.....generalized lymphadenopathy..... unexplained fever/diarrhoea.....
.neuropathy..... infectious diseases.....others.....

Tests	Peroperative ( )	1 week ( )	2 week ( )	4 week ( )	6 w (
FBC					
Albumin Glucose					
HIV(Elisa)					
CD4:CD8					
VDRL					
HSV Culture					
CMV Culture					
Stool Culture&Parasites					
TB Culture					
Tissue Histology					
Healing/followup					

Healing:W=worse,I=i.s.q,B=better,H=healed.

Remarks.

Appendix C

CDC classification of HIV infection[x]

Stage I	Acute infection
Stage II	Infection without symptoms[+]
Stage III	Persistent generalized lymphadenopathy
Stage IV	Other diseases
(A)	Constitutional disease
(B)	Neurologic disease
(C)	Secondary infectious diseases
(D)	Secondary cancers[+]
(E)	Other conditions

x :Adapted from the Centres for Disease Control (CDC) Classification system[4]

+ : Patients in stages II and IV may be sub-classified according to the results of laboratory tests

Appendix D Atlas



Figure D.1 Haemorrhoids and anal fistula



Figure D.2 Fistulotomy and seton suture



Figure D.3 Ischiorectal abscess



Figure D.4 Adenocarcinoma from long standing anal fistula



Figure D.5 Anal warts

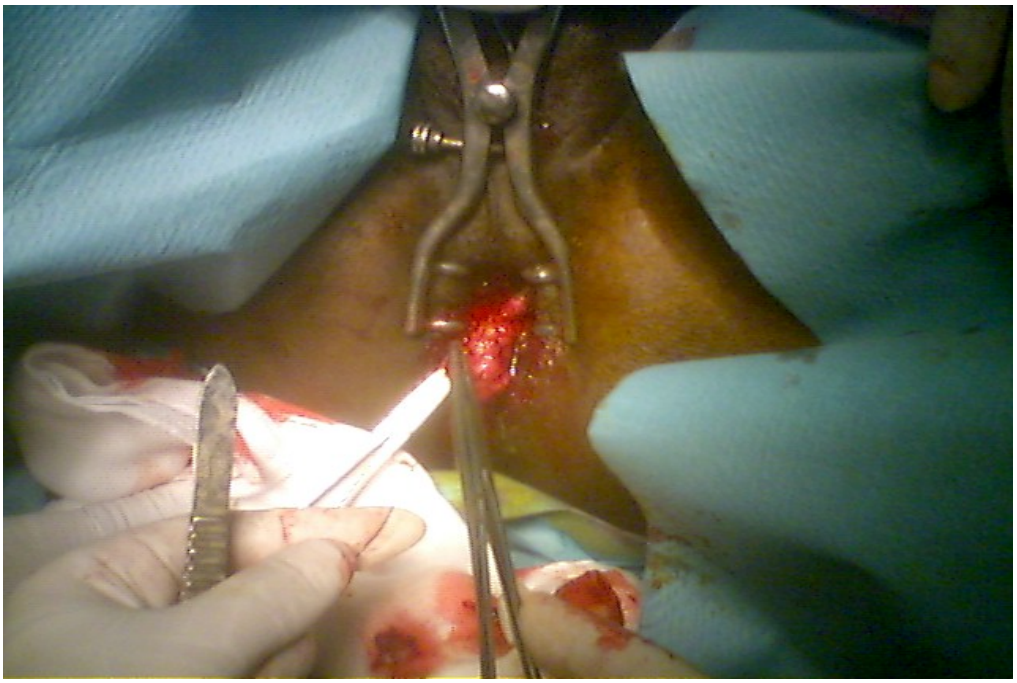

Figure D.6 Anal ulcer (note the erosive nature of anal ulcers in HIV positive patients)

Appendix E Ethic clearance certificate

UNIVERSITY OF THE WITWATERSRAND, JOHANNESBURG

Division of the Deputy Registrar (Research)

COMMITTEE FOR RESEARCH ON HUMAN SUBJECTS (MEDICAL)
Ref: R14/49 Tun

CLEARANCE CERTIFICATE **PROTOCOL NUMBER** M02-04-29

PROJECT Peri-Anal Manifestations of HIV Infected Person

INVESTIGATORS Mr M Tun

DEPARTMENT School of Clinical Medicine, CH Baragwanath Hospital

DATE CONSIDERED 02-04-50

DECISION OF THE COMMITTEE *

Approved unconditionally

DATE 02-05-20 **CHAIRMAN**.....(Professor P E Cleaton-Jones)

* Guidelines for written "informed consent" attached where applicable.

c c Supervisor: Prof GJ Oettlé
Dept of School of Clinical Medicine, Helen Joseph Hospital

Works2\lain0015\HumEth97.wdb\M 02-04-29

DECLARATION OF INVESTIGATOR(S)

To be completed in duplicate and **ONE COPY** returned to the Secretary at Room 10001, 10th Senate House, University.

I/we fully understand the conditions under which I am/we are authorized to carry out the abovemer research and I/we guarantee to ensure compliance with these conditions. Should any departure

PLEASE QUOTE THE PROTOCOL NUMBER IN ALL ENQUIRIES

REFERENCES

1. UNAIDS/WHO global AIDS statistics. *AIDS Care* 1999; 11:253-64.

2. Moore BA, Fleshner PR. Rubber band ligation for haemorrhoidal disease can be safely performed in select HIV-positive patients. *Dis Colon Rectum* 2001; 44:1079-1082.

3. Hammer SM, Katzenstein DA, Hughes MD. A trial comparing nucleoside monotherapy with combination therapy in HIV-infected adults with CD4 cell counts from 200 to 500 per cubic millimetre. *N Engl J Med* 1996; 335:1081-90.

4. CDC Revision of the CDC surveillance case definition for acquired immunodeficiency syndrome. *MMWR* 1987: 36:3S.

5. Yuhun R, Orsay C, Delpino A, Pearl R, Kay S, Abcarian H. Anorectal disease in HIV-infected patients. *Dis Colon Rectum* 1998; 41:1367-1370.

6. Lord VN. Anorectal surgery in patients infected with human immunodeficiency virus. *Ann Surg* 1997; 226:92-99.

7.Wolkomir AF, Barone JE, Hardy HW, et al. Abdominal and anorectal surgery and the acquired immune deficiency syndrome in heterosexual intravenous drug users. *Dis Colon Rectum* 1990; 33:267.

8. Safvi A, Gottesman I, Dailey TH. Anorectal surgery in the HIV+ patients. Update. *Dis Colon Rectum* 1991; 34:299.

9. Ffrench R, Stewart GJ, Penny R, Levy JA. How HIV produces immune deficiency. *Med J Aust* 1996; 164:166-171.

10. Critchlow CW, Surawicz CM, Holmes KK, et al. Prospective study of high grade anal squamous intraepithelial neoplasia in a cohort of homosexual men. Influence of HIV infection, immune suppression and human papillomavirus infection. *AIDS* 1995; 9:1255.

11.Place RJ, Gregorcyk SG, Huber PJ, Simmang CL. Outcome analysis of HIV-positive patients with anal squamous cell carcinoma. *Dis Colon Rectum* 2001; 44:506-512.

12. Consten ECJ, Slors FJM, Noten HJ, Oosting H, Dunner SA, van Lanshot JJB. Anorectal surgery in human immunodeficiency virus infected patients: clinical outcome in relation to immune status. *Dis Colon Rectum* 1995; 38:1169-1175.

13. Wilcox CM. Gastrointestinal consequences of infection with acquired immunedeficiency syndrome. In: Feldman M, Friedman LS, Brandt LJ, Sleisenger MH, editors. *Sleisenger & Fordtran's Gastrointestinal and Liver Disease.* Philadelphia: Saunders, 2006:667-682.

14. Orkin BA, Smith LF. Perineal manifestations of HIV infection. *Dis Colon Rectum* 1992; 35:310-314.

15. Nadal SR, Manzione CR, Galvao VM, Salim VR, Speranzini MB. Perianal diseases in HIV positive patients compared with a seronegative population. *Dis Colon Rectum* 1999; 42:649-654.

16. Guy RJ, Seow-Choen F. Septic complications after treatment of haemorrhoids. *Br J Surg* 2003; 90:147-156.

17. Applebaum GD, Donovan S. *Escherichia coli* meningitis in a human immunodeficiency virus-infected man after outpatient haemorrhoidectomy. *Clin Infect Dis* 1999; 29:448-449.

18. Buchmann P, Seefeld U. Rubber band ligation for piles can be disastrous in HIV-positive patients. *Int J Colorectal Dis* 1989; 4:57-58.

19. Morandi E, Merlini D, Salvaggio A, Foschi D, Trabucchi E. Prospective study of healing time after haemorrhoidectomy. *Dis Colon Rectum* 1999; 42:1140-1144.

20. Carr ND, Mercey D, Slack WW. Non-condylomatous perianal disease in homosexual men. *Br J Surg* 1989; 76:1067-1069.

21. Manookian CM, Sokol TP, Headrick C, Fleshner PR. Does HIV status influence the anatomy of anal fistulas? *Dis Colon Rectum* 1998; 41:1529-1533.

22. Nadal SR, Manzione CR, Galvao VDM, Salim VRM, Speranzini MB. Healing after anal fistulotomy. *Dis Colon Rectum* 1998; 41:177-179.

23.Nadal SR, Manione CR, Horta SHC, de MouraGalvao V. Management of idiopathic ulcer of the anal canal by excision in HIV-positive patients. *Dis Colon Rectum* 1999; 42:1598-1601.

24. Modeso VL, Gottesman L. Sexually transmitted diseases and anal manifestations of AIDS. *Surg Clin N Am* 1994; 74:1433-1466.

25. Munoz-Villasmil J, Sands L, Hellinger M. Management of perianal sepsis in immunosuppressed patients. *Am Surg* 2001; 67:484- 486.

26. Consten EC, Slors JF, Danner SA, et al. Severe complications of perianal sepsis in patients with human immunodeficiency virus. *Br J Surg* 1996; 83:778-780.

27. Mqoqi N, Kellett P, Sitas F, Jula M. Incidence of Histologically Diagnosed Cancer in South Africa, 1998-1999. *National Cancer Registry* 2004:88-89.

28. De la Fuente SG, Ludwig KA, Mantyh CR. Preoperative immune status determines anal condyloma recurrence after surgical excision. *Dis Colon Rectum* 2003; 46:367-372.