

https://dspace.org/

Morphometric analysis of the immature human infra-orbital canal

Smit, Surraine

2019
https://hdl.handle.net/10539/27902

Downloaded from a DSpace repository. https://dspace.org/

MORPHOMETRIC ANALYSIS OF THE IMMATURE HUMAN INFRA-ORBITAL CANAL

Surraine Smit

A Dissertation submitted to the Faculty of Health Sciences, University of the Witwatersrand, Johannesburg, in fulfilment of the requirements for the degree of Master of Science (Medicine)

Johannesburg, South Africa, 2019

DECLARATION

I, Surraine Smit, declare that this dissertation entitled “Morphometric analysis of the immature human infra-orbital canal” is my own work. It is being submitted for the Degree of Master of Science in Medicine at the University of the Witwatersrand, Johannesburg. It has not been submitted before for any degree or examination at any other University.



Surraine Smit

22nd Day of May 2019 in Johannesburg .

To my mom, who made countless sacrifices to enable me to realise my dreams

Susan Smit

PRESENTATIONS ARISING FROM THIS STUDY

2018: **Faculty of Health Sciences Research Day and Postgraduate Expo, Faculty of Health Sciences, University of the Witwatersrand**

Poster Presentation

Morphological analysis of the immature human infra-orbital canal

S. Smit, E.F. Hutchinson, B. Kramer

2018: **9th Cross Faculty Postgraduate Symposium, University of the Witwatersrand**

Poster Presentation

Morphometric analysis of the fetal and neonatal human infra-orbital canal

S. Smit, E.F. Hutchinson, B. Kramer

ABSTRACT

The infra-orbital neurovascular supply, plays a vital role in the development and growth of the immature maxilla and the associated midfacial region. While the infra-orbital canal serves as a conduit for the nerves innervating these midfacial structures, the development and growth of the canal itself is not well understood. A comprehensive understanding of changes in the morphometry of the infra-orbital canal, particularly during the late prenatal and early postnatal periods of growth, may facilitate the early detection of potential aberrant growth patterns and dental abnormalities occurring during these stages of life. The aim of this study was thus to describe changes in the morphology, dimensions and branching pattern of the infra-orbital canal during early stages of development and growth. The sample included 50 fetal and neonatal maxillae (18 skeletonized crania and 32 cadavers). The skeletonized individuals were sourced from the Raymond A. Dart Collection of Human Skeletons, while the paediatric remains were obtained from the Paediatric Collection of the School of Anatomical Sciences, University of the Witwatersrand. The sample was subdivided into a late prenatal (30 gestational weeks to birth) and a postnatal (birth to 1 year) age group. Maxillae were scanned using a Nikon XTH 225 L micro-CT unit and analysis conducted using VG studiomax v3.2. Measurements included the maximum width, height and surface area of the two foramina associated with the infra-orbital canal and the total length of the canal. The boundaries of the canal walls and the branching pattern of the infra-orbital canal were also described. All the measurements and dimensions of the infra-orbital canal were larger in the late prenatal group when compared with the early postnatal group, while the walls of the canal were more defined in the postnatal group. The branching pattern of the infra-orbital canal reflected the developmental stage of the associated surrounding structures. Precise knowledge of the changes in the infra-orbital canal morphometry during periods of development and growth is imperative for understanding the distribution patterns of the infra-orbital neurovascular supply to the immature midfacial region and in predicting aberrant craniofacial and dental growth patterns.

ACKNOWLEDGEMENTS

The completion of my dissertation is the result of the generous inputs by various people, to whom I am deeply indebted. First and above all, I praise my Heavenly Father for giving me the opportunity to undertake this research project and the showers of blessings he bestowed upon me throughout this journey. His grace and unconditional love gave me the strength and perseverance to overcome many challenging moments and to complete this project.

The greatest blessings of all were my supervisors, Dr Hutchinson and Professor Kramer, to whom I would like to extend my sincerest gratitude and appreciation. Thank you for always encouraging and guiding me to do my best and imparting your skills and expertise to me. It was an absolute privilege to have you as my mentors!

I would also like to thank the staff in the faculty who assisted me. Thank you Mr. Brendon Billings (Collections Curator) and Professor Maryna Steyn, for granting me access to the Paediatric Collection and the Raymond A. Dart Collection of Human Skeletons, School of Anatomical Sciences, University of the Witwatersrand. A special note of thanks to Dr Hutchinson who helped me with the transportation and mounting of specimens. I would also like to acknowledge the Faculty Research Committee (FRC), School of Anatomical Sciences, University of the Witwatersrand for their financial contribution towards this project.

The members of the MIXRAD Facility at the South African Nuclear Energy Corporation (NECSA) helped me tremendously by patiently guiding me through the process of micro-CT scanning and data-analysis. Dr Frikkie de Beer was very generous in granting me access to their facilities and equipment. I gratefully thank Mr. Jakobus Hoffmann and Mr. Lunga Bam for making the long hours of analysis a delightful experience!

Finally, my deepest gratitude to my friends and family who always stand by my side. Thank you for your continuous love, support and encouragement in all of my pursuits. This journey would not have been possible without each of you!

TABLE OF CONTENTS

DECLARATION ..... **ii**
PRESENTATIONS ARISING FROM THIS STUDY ..... **iv**
ABSTRACT ..... **v**
LIST OF ABBREVIATIONS ..... **viii**
LIST OF FIGURES ..... **x**
LIST OF TABLES ..... **xii**
INTRODUCTION **1**
AIM AND OBJECTIVES **5**
MATERIALS AND METHODS **5**
DATA ANALYSIS **12**
RESULTS **13**
CONCLUSION **26**
REFERENCES **28**
APPENDICES **31**
Appendix A : Human Research Ethics Committee (Medical) waiver **31**
Appendix B : Turnitin Report……..... **32**

LIST OF ABBREVIATIONS

Ant Un	-	Anterior dentition undifferentiated
C	-	Canine
CI	-	Central Incisor
CL	-	Canal length
CT	-	Computed tomography
EFH	-	“External” foramina height
EFSA	-	“External” foramen surface area
EFW	-	“External” foramina width
HREC	-	Human Research Ethics Committee
IFH	-	“Internal” foramina height
IFSA	-	“Internal” foramen surface area
IFW	-	“Internal” foramina width
LI	-	Lateral Incisor
MANOVA	-	Multivariate Analysis of Variance
Micro-CT	-	Micro-focus computed tomography
MIXRAD	-	Micro-focus X-ray Radiography and Tomography
MS	-	Maxillary sinus
ns	-	Nasion
NECSA	-	South African Nuclear Energy Corporation
Or	-	Orbit
PAST	-	Paleontological Statistics
pc	-	Piriform curvature
PCA	-	Principal Component Analysis
PC1	-	Principal Component 1
PC2	-	Principal Component 2
PM1	-	Premolar 1/ 1st deciduous molar
PM2	-	Premolar 2/ 2nd deciduous molar

SD	-	Standard Deviation
SPSS	-	Statistical Package for the Social Sciences

LIST OF FIGURES

Figure 1: A vertical reference plane (red grid) inserted in relation to the nasal aperture of an early postnatal individual in the coronal plane by selecting three fiducial points on the skull. (Fiducial points = ns, nasion; pc, piriform curvature) 7

Figure 2: Coronal section indicating the maximum height (a) and width (b) of the right “external” infra-orbital foramen of a late postnatal individual. Note that all the boundaries of the foramen are evident 8

Figure 3: Coronal section indicating the horizontal reference plane (a) in an early postnatal individual 9

Figure 4: Sagittal view indicating the integrity of the roof (a) and floor (b) of the right infra-orbital canal in an early postnatal individual. Note that the roof of the canal is absent posteriorly (as indicated by the yellow arrows) 9

Figure 5:Transverse view indicating the patchy integrity of both the medial (a) and lateral (b) wall of a left infra-orbital canal in an early postnatal individual. The yellow arrows indicate areas where the walls have bony islets 10

Figure 6: Transverse view indicating the integrity of the lateral (a) and medial (b) wall of a left infra- orbital canal in an early postnatal individual. Both the lateral and medial walls are complete 10

Figure 7: Sagittal view of a left infra-orbital canal in an early postnatal individual. The canal does not have an internal angulation. The length of the infra-orbital canal (a) was thus measured between the midpoints of the “external” (b) and “internal” (c) infra-orbital foramina. [Note that the position of the boundaries of the “internal” and “external” infra-orbital foramina were determined in the coronal plane] 11

Figure 8: Sagittal view of a left infra-orbital canal in an early postnatal individual. An internal angulation in the floor of the canal is evident. The measurements were taken from the internal angulation marker (a) to the midpoint of the “internal” (b) and “external” (c) infra-orbital foramina, respectively. [Note

that the position of the boundaries of the “internal” and “external” infra-orbital foramina were determined in the coronal plane]..... 11

Figure 9: Principal component analysis (PCA) depicting the level of size and shape variance of the averaged values of the left and right infra-orbital canal between the late prenatal (blue: 30.5 gestational week – birth) and the early postnatal (red: 40.5 gestational weeks – end of 1 year) age groups. Plots indicating the relative influence of each measurement on PC1 (size and shape) and PC2 (size) is also shown. (IFSA, “internal” foramen surface area; EFSA, “external” foramen surface area; IFH, “internal” foramina height; EFH, “external” foramina height; IFW, “internal” foramina width, EFW, “external” foramina width; CL, canal length)..... 15

Figure 10: The integrity of the walls of a late prenatal (b and d) and an early postnatal (a and c) individual. Fig. a and Fig. b: Sagittal view indicating the roof and floor of the left infra-orbital canal. Note that the roof of the infra-orbital canal in the late prenatal individual (Fig. b) is absent along the posterior third of the canal (yellow arrows), while the roof of the infra-orbital canal in the early postnatal individual (Fig. a) is complete. Fig. c and Fig. d: Transverse view indicating the medial and lateral walls of the left infra-orbital canal. Note that the bone forming the walls of the infra-orbital canal in the late prenatal individual (b and d) has a consistent appearance, while the bone surrounding the infra-orbital canal in the early postnatal individual (a and c), has a trabeculated appearance. (Infra-orbital canal is indicated by a green star)..... 16

Figure 11: Coronal view of the accessory “external” infra-orbital foramen (a) situated lateral to the main infra-orbital foramen (b) on the right side of the face in a late prenatal individual 17

LIST OF TABLES

Table 1: Mean in mm and standard deviation (SD) of each of the dimensions of the infra-orbital canal across the late prenatal (group 1) and early postnatal (group 2) periods of assessment 14

Table 2: Variations in branching patterns of the infra-orbital canal in the late prenatal and early postnatal groups. The number of branches that presented with a particular branching pattern is indicated underneath the pattern. The main branch of the infra-orbital canal is indicated in black, while the primary branches are red and the secondary branches are blue. Ant Un, anterior dentition undifferentiated; CI, central incisor; LI, lateral incisor; C, canine; PM1, 1st premolar; PM2, 2nd premolar; MS, maxillary sinus; Or, orbit 19

INTRODUCTION

The infra-orbital canal, by acting as a conduit for the infra-orbital neurovascular structures, serves an important role in the development and growth of the maxilla. A clear understanding of the developmental patterns of the canal is necessary for studying the distribution patterns of the neurovascular structures contained therein (Yenigun *et al*., 2016), particularly during the dynamic late prenatal and early postnatal stages. A comprehensive understanding of the development and growth of the infra-orbital canal and its secondary bony canals found within the maxilla may assist in interpreting not only their normal anatomical location, course and branching pattern in the adult, but may also provide valuable insights into abberant growth patterns and dental abnormalities which may occur during the prenatal and postnatal stages of life (Caspersen *et al*., 2010). These insights into the normal anatomy of the infra-orbital canal during the earlier stages of life are particularly important during surgical procedures, as damage to the infra-orbital nerve can cause permanent paraesthesia (Açar *et al*., 2017). Although extensive literature exists describing the anatomy of the infra-orbital canal in the adult population, there is limited information regarding the developmental patterns of the canal in immature individuals (Caspersen *et al*., 2009). Studies conducted by Moss and Greenberg (1967) and Caspersen *et al*. (2010) have indicated that the topographic constancy of the infra-orbital canal provides a reference plane for the study of the growth of the maxilla in sub-adults and adults. Caspersen *et al*. (2009) noted that the inclination of the infra-orbital canal was closely associated with the growth and morphology of the maxilla, demonstrating that the orientation of the infra-orbital canal changes with age.

In human adults, the infra-orbital canal is described as a bony canal situated within the supero-lateral wall of the maxillary sinus (Uzun *et al*., 2016). The canal extends from the inferior orbital fissure situated in the floor of the orbit and from there, the infra-orbital canal courses anterio-medially in the roof of the maxillary sinus towards the anterior dentition (Scarfe *et al*., 1998). The anterior end of the infra-orbital canal terminates as the infra-orbital foramen (Stan *et al*., 2013). The infra-orbital foramen is situated approximately 5-8 mm inferior to the midpoint of the adult inferior orbital rim (Scarfe *et al*., 1998). The length of the infra-orbital canal in adults may vary

between 21.4 and 28.4 mm (Moss and Greenberg, 1967; Kazkayasi *et al*., 2003; Hwang *et al*., 2013).

Important neurovascular structures, such as the infra-orbital artery and nerve course through the infra-orbital canal (Uzun *et al*., 2016). The infra-orbital nerve is a terminal branch of the maxillary division of the trigeminal nerve, providing innervation to the ipsilateral midface (Scarfe *et al*., 1998). The maxillary division of the trigeminal nerve transverses the foramen rotundum, entering the pterygopalantine fossa where it gives off palatine and nasal branches. It then enters the orbit by passing through the infra-orbital fissure where it is named the infra-orbital nerve, which then courses through the infra-orbital canal (Kazkayasi *et al*., 2003). Within the infra-orbital canal, the infra-orbital nerve divides into three distinct divisions: an anterior-, middle- and posterior superior alveolar nerve (Uzun *et al*., 2016). Together these nerves form the superior dental plexus which innervates the dentition, associated gingivae and periosteum as well as the nasal cavity and adjacent maxillary sinus (Scarfe *et al*., 1998). The anterior division of the infra-orbital nerve follows an oblique course and continues medially and inferiorly over the anterior wall of the maxilla, appearing in the soft tissues of the face as it courses through the infra-orbital foramen (Scarfe *et al*., 1998). Here, it divides further into nasal, palpebral and labial branches to innervate the skin on the lateral surface of the nose, the lower eyelid, conjunctiva, and upper lip including the skin, mucous membrane and gingiva (Kazkayasi *et al*., 2003). As the superior dental plexus is present by the 6th week of gestation (Pearson, 1977) and it is known that the presence of a nerve will induce bone development (Chávez-Lomelí *et al*., 1996), the course of the nerve determines not only the position, but also the direction of the infra-orbital canal.

Various studies have described the location, course and anatomical characteristics of the infra-orbital canal, foramen and nerve (Kazkayasi *et al*., 2001; Ghaus and Faruqi, 2008; Caspersen *et al*., 2009; Hwang *et al*., 2013). The latter studies, however, are largely based on adult populations and have been performed on dried adult skulls by inserting radiopaque pins into the infra-orbital foramen or by tracing and measuring the outcomes on radiographs. Furthermore, these cephalometric studies were limited in the depth of their inferences as they were unable to accurately evaluate the course and the length of the infra-orbital canal and infra-

orbital groove inside the bony structures (Kazkayasi *et al*., 2001; Hwang *et al*., 2013). In addition, the age related changes of these structures were not assessed.

There is limited information regarding the changes that the infra-orbital canal undergoes (Caspersen *et al*., 2009), specifically during the late prenatal and early postnatal stages. The bone forming infra-orbital canal develops from an ossification centre located in the region of the early prenatal future infra-orbital foramen which develops at week 10 of gestation (Caspersen *et al*., 2009). The region of the infra-orbital foramen is the site of the first ossification of the maxillary bone with bone formation occurring as a series of radiating trabeculae which later transform into smooth plate-like bone (Moss and Greenberg, 1967). In embryos and fetuses, the developing infra-orbital canal appears as a groove which gradually develops into a canal due to the apposition of bone on both sides of the groove that meet in the midline, creating the infra-orbital suture (Moss and Greenberg, 1967). The fetal stage at which closure of the canal begins still remains unclear (Moss and Greenberg, 1967). The topography of the developing groove and canal is thought to be somewhat variable. Moss and Greenberg (1967) found that in most skulls with deciduous teeth, there was no internal angulation present between the developing infra-orbital groove and canal, while skulls with mixed dentition and permanent teeth had an infra-orbital canal with a downward slope to the anterior portion. In most cases, the plane of the groove and the canal formed two limbs in the shape of an inverted V with the apex above the mesio-buccal root of the first molar. It is approximately in this region where the anterior superior alveolar nerve branches off from the infra-orbital nerve (Pearson, 1977). The development of canals is determined by the paths of nerves (Chávez-Lomelí *et al*., 1996). Hence, the course of the infra-orbital canal may be influenced by the nerve distribution and the development of the associated dentition.

The walls of the infra-orbital canal, especially the roof, are very thin (Kazkayasi *et al*., 2001), making it an extremely weak area in the orbital floor (Açar *et al*., 2017). As the integrity of the bony walls of the canal is often variable, the infra-orbital canal complex is classified into three categories by using the developmental features of the walls. These categories include: a) a true canal (all of the walls are intact and without defect) (69%), b) a canal with an inconsistent roof (the roof contains bony islets while the rest of the walls are complete) (6%) or c) an open canal represented by a groove

(absent roof, especially along the posterior third of the canal) (25%) (Scarfe *et al*., 1998; Uzun *et al*., 2016; Yenigun *et al*., 2016).

Due to the thinness of its walls, the infra-orbital canal is often damaged during trauma (Prasad and Khanal, 2016). Maxillofacial trauma is characterised by fractures that affect the central midface or the lateral midface (Schuknecht and Grätz, 2005). As described by Phillips and Turco (2017), Le Fort (1901) named those areas that are most frequently injured the “great lines of weakness” of the viscerocranium. Most fractures involve the infra-orbital canal, foramen or fissure which can result in permanent paraesthesia (Yenigun *et al*., 2016). Le Fort fractures can also result in discontinuity of the midface, producing instability and potential facial deformity (Schuknecht and Grätz, 2005; Phillips and Turco, 2017).

Within the dental setting, an increase in the incidence of accessory canals with large diameters located in the path of dental implants has been observed (Machado et al., 2016), making this region susceptible to injuries during routine surgeries (Von Arx *et al*., 2013).Thus, attention has been drawn to the incidence of radiographically visible accessory canals in the anterior maxilla, which may carry neurovascular structures to neighbouring areas, such as the canalis sinuosus (Von Arx *et al*., 2013; Machado *et al*., 2016). The tortuous canalis sinuosus generally takes origin from the lateral aspect of the infra-orbital canal, approximately 25 mm posterior to the infra-orbital foramen (Von Arx *et al*., 2013), and may emerge medially or laterally in relation to the infra-orbital foramen (Gurler *et al*., 2017). The canalis sinuosus courses inferior to the infra-orbital foramen towards the lower margin of the anterior nasal aperture, opening next to the nasal septum, close to the incisive canal (Von Arx *et al*., 2013; Gurler *et al*., 2017). Contained within the canalis sinuosus are the alveolar nerves and vessels, innervating the incisors, canines and adjacent soft tissues (Gurler *et al*., 2017). The terminal portion of the canalis sinuosus was most frequently found palatal to the anterior maxillary teeth, especially to the central incisors, according to Gurler *et al*. (2017). These variations in position of the accessory canals were all investigated in adult populations. Machado *et al*. (2016), however, also reported a tendency of observing increased numbers of accessory canals in older subjects (≥60 years), more than in younger subjects (≤20 years), at which stage, it was suggested the canals may not have yet developed. To increase the success rate of surgical intervention, detailed knowledge of the anatomical variations and normal morphology

of the bony canals situated within the maxilla is crucial for surgeons during maxillofacial, orbital and dental surgery and procedures such as nerve blocks for trigeminal (Uzun *et al*., 2016). Precise knowledge of the development and growth pattern of the infra-orbital canal may assist in interpreting the normal anatomy as well as changes in the morphology of the canal that are associated with craniofacial abnormalities. The use of recently available technology, such as micro-CT, may offer the opportunity of enhancing the details of knowledge of the canal.

AIM AND OBJECTIVES

The aim of this study was to describe the morphometry of the infra-orbital canal during the functionally intricate late prenatal and early postnatal periods. The following objectives were pursued:

1. The dimensions (i.e. surface area, maximum height and maximum width) of the infra-orbital canal were measured at both the “internal” and “external” foramina of the canal.
2. The integrity of the bone forming the boundaries along the course of the infra-orbital canal in the maxilla was classified.
3. The branching patterns of the infra-orbital canal were described and the length of the canal was measured.

MATERIALS AND METHODS

The use of cadaveric material falls under the National Health Act 61 of 2003 of the Republic of South Africa. Clearance to utilise the cadavers and skeletonised specimens for this study was obtained from the University of the Witwatersrand’s Human Research Ethics Committee (HREC-medical, W-CJ-140604-1) (Appendix A).

A total of 50 maxillae from fetal and neonatal human individuals were assessed. The majority of these maxillae (n=32) were sourced from paediatric cadavers housed in

the Paediatric Collection, School of Anatomical Sciences, University of the Witwatersrand. The remaining 18 skeletonized maxillae were obtained from the Raymond A. Dart Collection of Human Skeletons, School of Anatomical Sciences, University of the Witwatersrand.

The ages of the individuals ranged from 30 gestational weeks to 1 year postnatal. The gestational ages of all individuals were estimated by means of standard body measurements which included the crown-rump length, head circumference and toe-heel length (Lubchenco *et al*., 1966; Hansen *et al*., 2003). The ages of the skeletonized individuals were estimated by using dental development standards (Alqahtani *et al*., 2010). On the basis of these age estimations, the sample was subdivided into a late prenatal (30 gestational weeks to birth) and an early postnatal (birth to 1 year) age group. The grouping of these cohorts was based on the contrasting biomechanical demands of the two periods of growth (Nowlan, 2015).

Maxillae with any evidence of congenital abnormalities, general damage, pathoses or surgical intervention were excluded from this study. The cadavers were fixed in a 5% formalin solution. It has been shown that this low concentration of formalin has no statistically significant effect on the shrinkage of human tissues (Kerns *et al*., 2008).

All maxillae were scanned at the MIXRAD (Micro-focus X-ray Radiography and Tomography) facility at the South African Nuclear Energy Corporation (NECSA), using a Nikon XTH 225L micro-CT X-ray unit (Nikon Metrology, Leuven, Belgium). The scanning setup was optimized for the highest possible spatial resolution by conducting “region of interest” scans. As such the scanning conditions ranged between 150kV/148 µm and 150kV/100 µm to compensate for the varying sizes of the sample. A 0.25 mm thick copper filter was used to optimise X-ray penetrations through the specimens. The specimens were secured in place by mounting each in a polystyrene mould. Scanning at 360˚ was facilitated by placing the mounted maxilla on a rotating sample manipulator. The maximum magnification was used to improve the visualization of the structures that were analysed. Nikon CTPro software (Nikon Metrology, Leuven, Belgium) was utilised to reconstruct the scans of the specimens. The scans were then imported into VGStudio Max v2.3 (Volume graphics GmbH, Heidelberg, Germany) as volume files.

During data collection, a surface determination was applied to all scans which allowed for a clear selection of skeletal landmarks on the skull. Furthermore, a surface determination was applied to the scans prior to each alignment of the slices to a particular plane and the insertion of reference planes or markers. In order to standardize the orientation of the micro-CT slices, the transverse slices were aligned to the Frankfort horizontal plane, while the coronal slices were aligned to a vertical reference plane which was determined by selecting three fiducial points in relation to the nasal aperture. The three points selected were the nasion (ns) and the piriform curvature (pc) (the most infero-lateral points of the piriform aperture) bilaterally (Fig. 1).

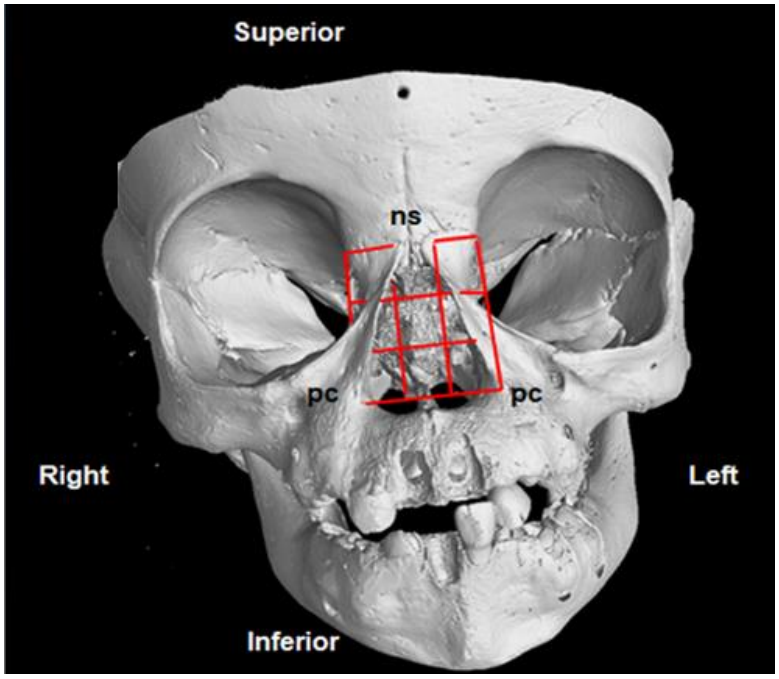

Figure 1: A vertical reference plane (red grid) inserted in relation to the nasal aperture of an early postnatal individual in the coronal plane by selecting three fiducial points on the skull. (Fiducial points = ns, nasion; pc, piriform curvature)

It should be noted that the infra-orbital groove was not part of the scope of this study and that the infra-orbital canal was the primary focus. In the assessment of the dimensions of the infra-orbital canal, an “internal” and an “external” infra-orbital foramen were defined bilaterally as regions of interest. The infra-orbital foramen proper was termed the “external” foramen for the purposes of this study, while the

“internal” infra-orbital foramen had to be defined as it was utilised for measurements of the canal. The foramen situated at the internal opening of the canal was termed the “internal” infra-orbital foramen. Both the “internal” and “external” infra-orbital foramina were defined as the openings of the canal and were identified through serial visual scanning of the region. The openings were determined as the position where all boundaries of the foramina were evident. The maximum width, maximum height and surface area of the “internal” and “external” infra-orbital foramina respectively were measured bilaterally in the coronal plane (Fig. 2). In order to assess the maximum width of each foramen, a horizontal reference plane was established by selecting a minimum of three reference points along the most horizontal plane of the nasal floor, where the triangular median palatal process fuses with the secondary palate (fused palatal shelves) (Fig. 3). Through serial scanning, this plane was identified as the most consistent horizontal point of the surrounding facial structures throughout all the CT slices. The maximum width of each foramen was measured parallel to this plane. The maximum width of each foramen was measured from its most lingual to its most buccal point in the horizontal plane, while the maximum height of the foramen was measured from the most superior to the most inferior point, perpendicular to the maximum width (Fig. 2). The surface area of each foramen was automatically determined by the software.

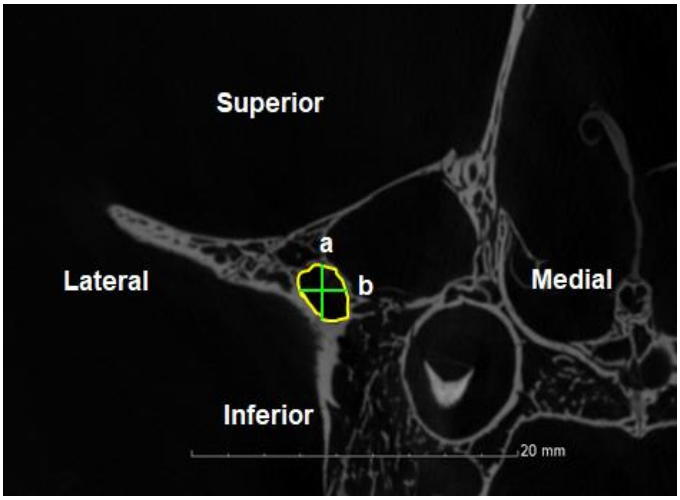

Figure 2: Coronal section indicating the maximum height (a) and width (b) of the right “external” infra-orbital foramen of a late postnatal individual. Note that all the boundaries of the foramen are evident

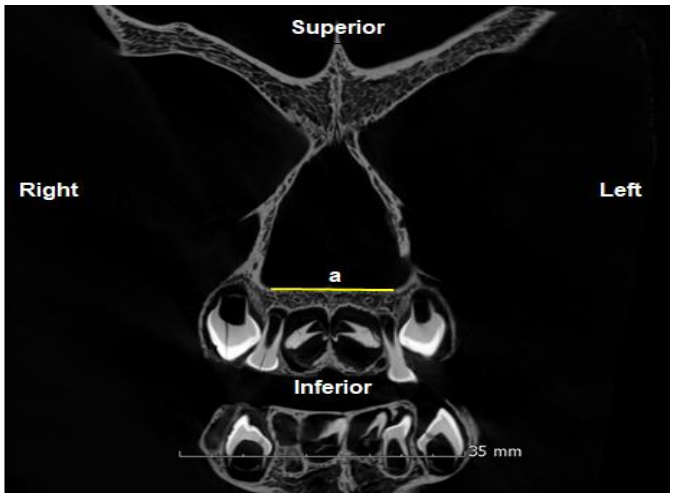

Figure 3: Coronal section indicating the horizontal reference plane (a) in an early postnatal individual

To describe the integrity of the walls of the infra-orbital canal relative to their surrounding structures, a combination of transverse and sagittally aligned slices were used. To standardize the assessment of the walls of the canal, the transverse slices were aligned to the midpoint of the height of the “internal” foramina, while the sagittal slices were aligned to the midpoint of the width of the “internal” foramina. A standard magnification (2mm) was utilized to assess the walls of the canal. In order to study the integrity of the walls throughout their entire length, the roof and floor were analysed in the sagittal plane (Fig. 4), while the medial and lateral walls of the canal were analysed in the transverse plane (Fig. 5 and Fig. 6). The integrity of the walls of the canal were classified as being absent (no bone is present at the posterior end of the canal) (Fig. 4), patchy (the wall consists of bony islets and may show signs of completion in certain areas, but is still incomplete) (Fig. 5) or complete (definitive bony walls without any defect) (Fig. 6).

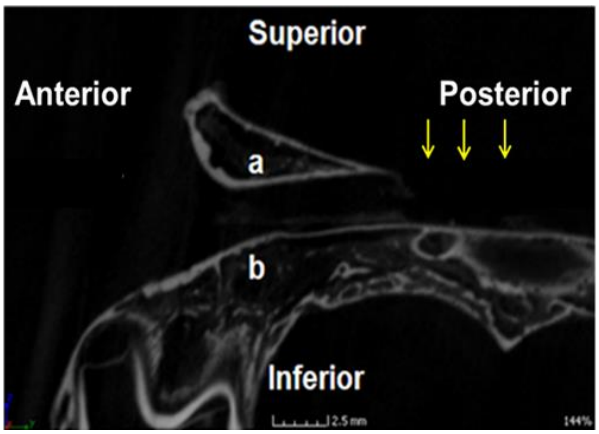

Figure 4: Sagittal view indicating the integrity of the roof (a) and floor (b) of the right infra-orbital canal in an early postnatal individual. Note that the roof of the canal is absent posteriorly (as indicated by the yellow arrows).

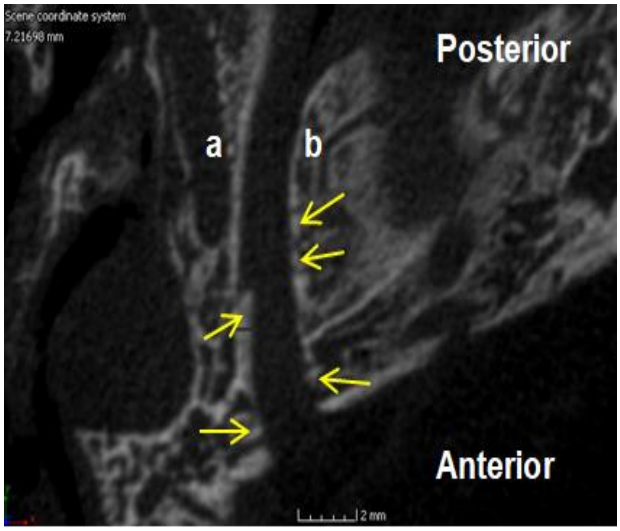

Figure 5: Transverse view indicating the patchy integrity of both the medial (a) and lateral (b) wall of a left infra-orbital canal in an early postnatal individual. The yellow arrows indicate areas where the walls have bony islets

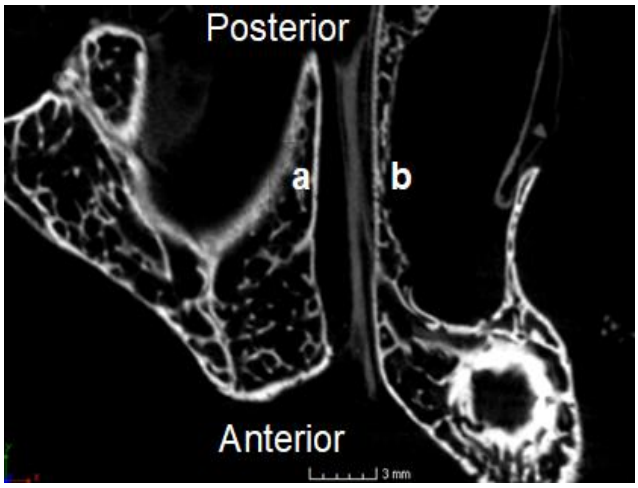

Figure 6: Transverse view indicating the integrity of the lateral (a) and medial (b) wall of a left infra-orbital canal in an early postnatal individual. Both the lateral and medial walls are complete

For the measurement of the length of the canal, all slices were aligned to the midpoint of the “external” foramen in the sagittal plane. The length of the canal, which was determined in the sagittal plane, was measured between the midpoints of the “internal” and “external” foramina which had been previously determined (Fig. 7). In cases where the canal had an internal angulation in its floor (Fig. 8) a marker was inserted at the point where the angle of the canal changed. Measurements were taken from the marker to the midpoint of the “internal” and “external” foramina

respectively (Fig. 8). The two measurements were then summed for each canal to determine the total length of the canal.

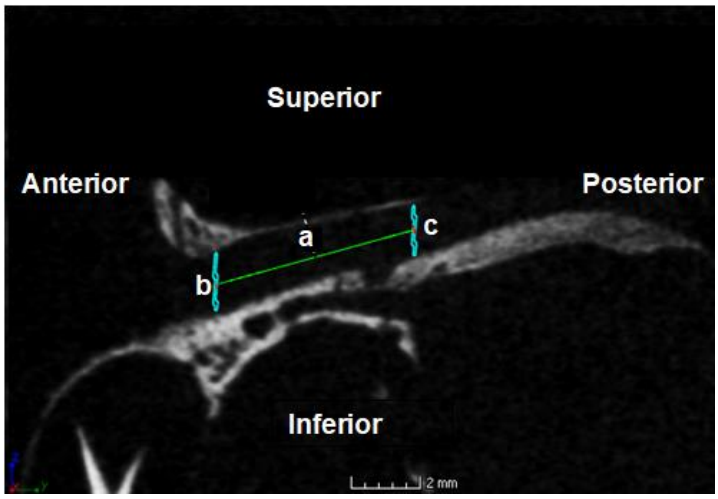

Figure 7: Sagittal view of a left infra-orbital canal in an early postnatal individual. The canal does not have an internal angulation. The length of the infra-orbital canal (a) was thus measured between the midpoints of the "external" (b) and "internal" (c) infra-orbital foramina. [Note that the position of the boundaries of the "internal" and "external" infra-orbital foramina were determined in the coronal plane]

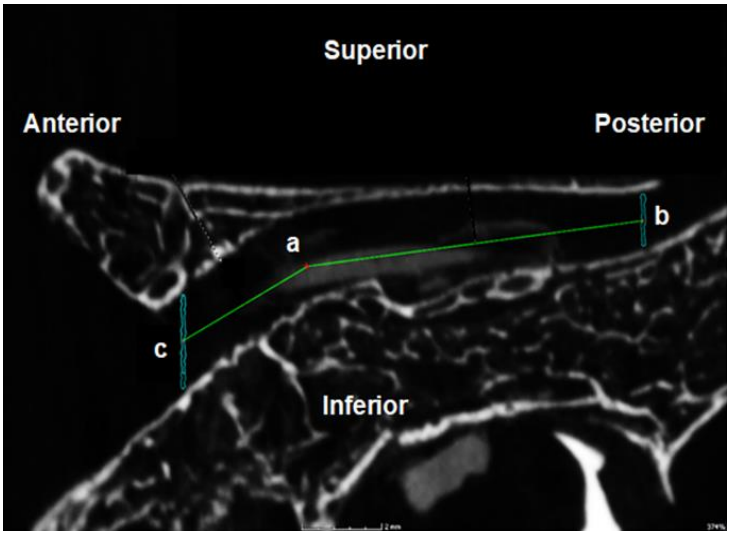

Figure 8: Sagittal view of a left infra-orbital canal in an early postnatal individual. An internal angulation in the floor of the canal is evident. The measurements were taken from the internal angulation marker (a) to the midpoint of the "internal" (b) and "external" (c) infra-orbital foramina, respectively. [Note that the positions of the boundaries of the "internal" and "external" infra-orbital foramina were determined in the coronal plane]

In order to comprehensively study the morphology and branching pattern of the canal within the maxilla, the infra-orbital region of interest was expanded to include the entire canal and all its associated branches bilaterally. The branching pattern of the infra-orbital canal relative to the surrounding structures such as the orbit, maxillary sinus and dentition was assessed by aligning the slices to a coronal plane. Utilising three-dimensional extraction, each branch of the canal was traced from its point of origin to the specific region of the maxilla where it terminated. The number of branches, their frequency of occurrence and the structure/s to which they lead were recorded.

DATA ANALYSIS

All statistical analyses were performed with the use of PAST (Paleontological Statistics) (Paleontological Association, London, UK) and SPSS (Statistical Package for the Social Sciences) v.25 (IBM, Armok, NY, USA) statistical programmes. To assess whether the data were parametric in nature, a Shapiro Wilk's test was performed. A paired sample "t"-test was used to compare all measurements on the left and right side. As the data were found to be parametric and no significant differences were observed between left and right sides, descriptive statistics (mean and standard deviation) were calculated for the mean value (left and right combined) of each measurement of the infra-orbital canal.

A multivariate analysis of variance (MANOVA) with a Tukey's *post hoc* test allowed for the assessment of variance between the dependent variables (measurements) and the independent variables (age). In this study, a value of $p \leq 0.05$ was considered to be statistically significant. The degree of variance in size and shape of the infra-orbital canal between the late prenatal and early postnatal age groups was assessed by a principal component analysis (PCA). Principal component 1 (PC1) represented changes in sample variance related to both size and shape of the canal, while principal component 2 (PC2) represented changes in sample variance in size only. The PCA further illustrated the influence that each measurement had on variance expressed along PC1 and PC2.

Qualitative data, such as the branching pattern of the infra-orbital canal and frequency of occurrence of each branch being directed towards a specific structure/s, were assessed using contingency and frequency tables. The branches of the infra-orbital canal were categorized according to their relationship with the dentition, maxillary sinus and the orbit. When possible, each specific tooth to which the branch of the infra-orbital canal led was noted e.g. the anterior dentition included the central incisor, lateral incisor and canine, while the posterior dentition included the first premolar/ 1st deciduous molar, second premolar/ 2nd deciduous molar, first permanent molar and second permanent molar. In cases where the branches of the canal did not completely extend to a specific tooth, the region where the canal was located was classified as “heading towards either the anterior or posterior dentition” or as “undifferentiated”.

The reproducibility of all measurements was determined with the use of five specimens (representing different ages). Each measurement was taken by two independent observers at different times. In addition, each measurement was taken twice by the primary researcher to assess intra-observer error. A Lin’s concordance correlation co-efficient of reproducibility was then conducted on to assess the inter-observer error and to provide information on the degree of association between the measurements (Allan, 1982). Values ranging between 0.8 and 1 were considered as acceptable levels of repeatability.

RESULTS

A high level of inter-observer repeatability (74 – 100%) was observed across all the measurements.

Measurements of the canal

A general increase in the size of all the dimensions of the infra-orbital canal was observed when comparing the late prenatal and early postnatal age groups (Table 1). No significant differences ($p \leq 0.05$) were observed between the age groups in terms of the measurements of the dimensions of the “internal” foramen and length of the canal, as these parameters increased when comparing the age groups. However, when comparing the other variables between the age groups, significant

differences were observed in the mean surface area (p≤ 0.024) and maximum width (p≤ 0.052) of the “external” foramen.

Table 1: Mean in mm and standard deviation (SD) of each of the dimensions of the infra-orbital canal across the late prenatal (group 1) and early postnatal (group 2) periods of assessment

Measurement	**Group 1 (n=27): (30 weeks – birth)**		**Group 2 (n=23) (40.5 weeks – 1 year)**	
	Mean (mm)	**SD**	**Mean (mm)**	**SD**
“External” foramina width	2.02	±0.23	2.19	±0.39
“External” foramina height	1.93	±0.50	2.31	±0.88
“External” foramina surface area	7.23	±2.61	9.72	±4.72
“Internal” foramina width	2.04	±0.30	2.09	±0.33
“Internal” foramina height	1.64	±0.20	1.91	±0.98
“Internal” foramina surface area	5.93	±1.44	6.79	±2.51
Canal length	6.17	±2.55	7.72	±3.45

A low level of variance was observed in the sample, as indicated by the high degree of overlap between the late prenatal and early postnatal age groups in the principal component analysis (Fig. 9). The surface area of the “internal” and “external” foramina respectively, as well as the canal length were observed to have the highest level of influence on the variance observed between the two age groups. All three measurements were observed to influence changes in variance along PC1 and PC2 and as such reflected changes in the size and shape of the canal across both age groups (Fig. 9).

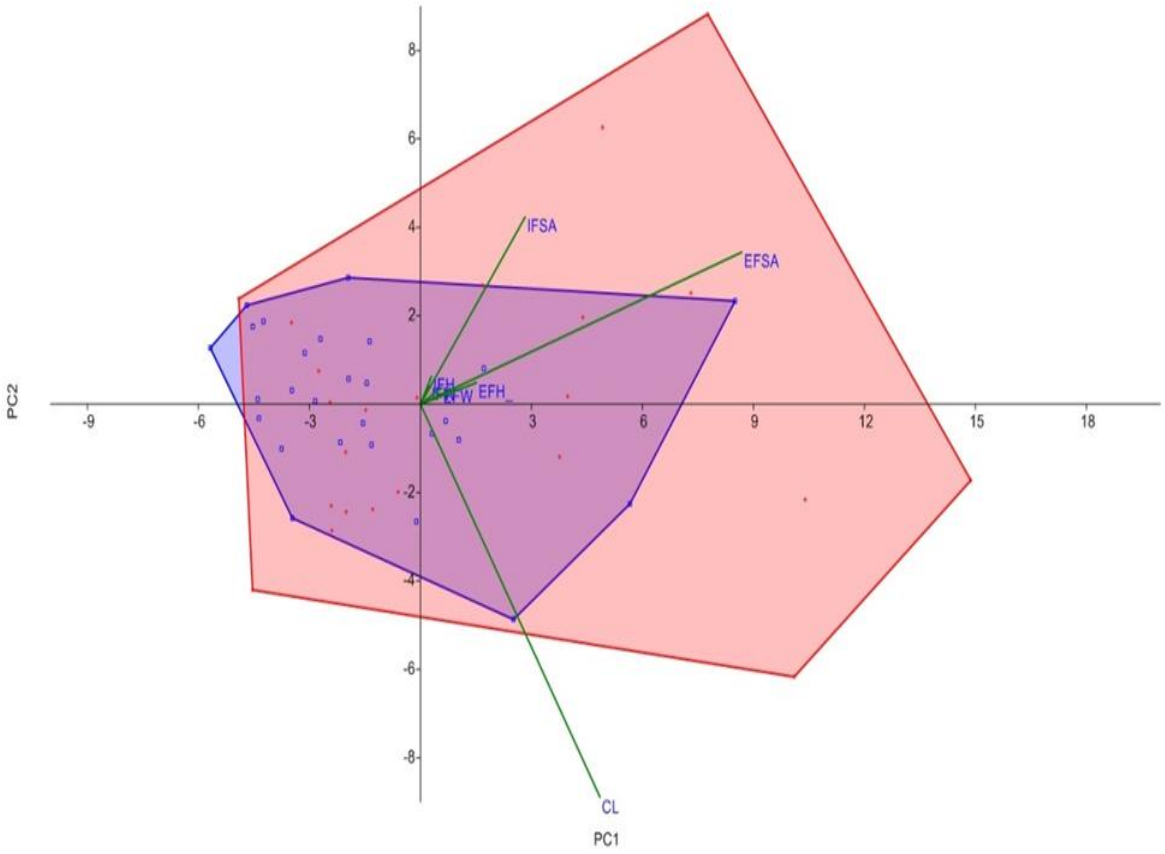

Figure 9: Principal component analysis (PCA) depicting the level of size and shape variance of the averaged values of the left and right infra-orbital canal between the late prenatal (blue: 30.5 gestational week – birth) and the early postnatal (red: 40.5 gestational weeks – end of 1 year) age groups. Plots indicating the relative influence of each measurement on PC1 (size and shape) and PC2 (size) are also shown. (IFSA, "internal" foramen surface area; EFSA, "external" foramen surface area; IFH, "internal" foramen height; EFH, "external" foramen height; IFW, "internal" foramen width, EFW, "external" foramen width; CL, canal length)

Integrity of the walls of the infra-orbital canal

In relation to the assessment of the integrity of the walls of the infra-orbital canal, it was found that the degree of bone development varied between the late prenatal and early postnatal group. The floor of the canal, as seen in the sagittal plane, appeared to be thick and well developed throughout the entire length of the canal in both age groups when compared with the roof, which was much thinner and patchy in some cases, especially in the late prenatal group. In fact, the roof of the canal was present in only 10 prenatal (18.5%) and 6 postnatal (10%) canals (Fig. 10a). In the sagittal sections of the remaining individuals (71.5%), the roof was absent at the

posterior end along one half to one quarter of the length of the canal. The absence of a roof created a groove (Fig. 10b). The degree of ossification of the medial and lateral wall, seen in the transverse plane, varied along the length of the canal, especially in the late prenatal group. In addition, the bone surrounding the infra-orbital canal had a homogenous appearance in the prenatal group but showed trabeculations in the early postnatal group (Fig. 10).

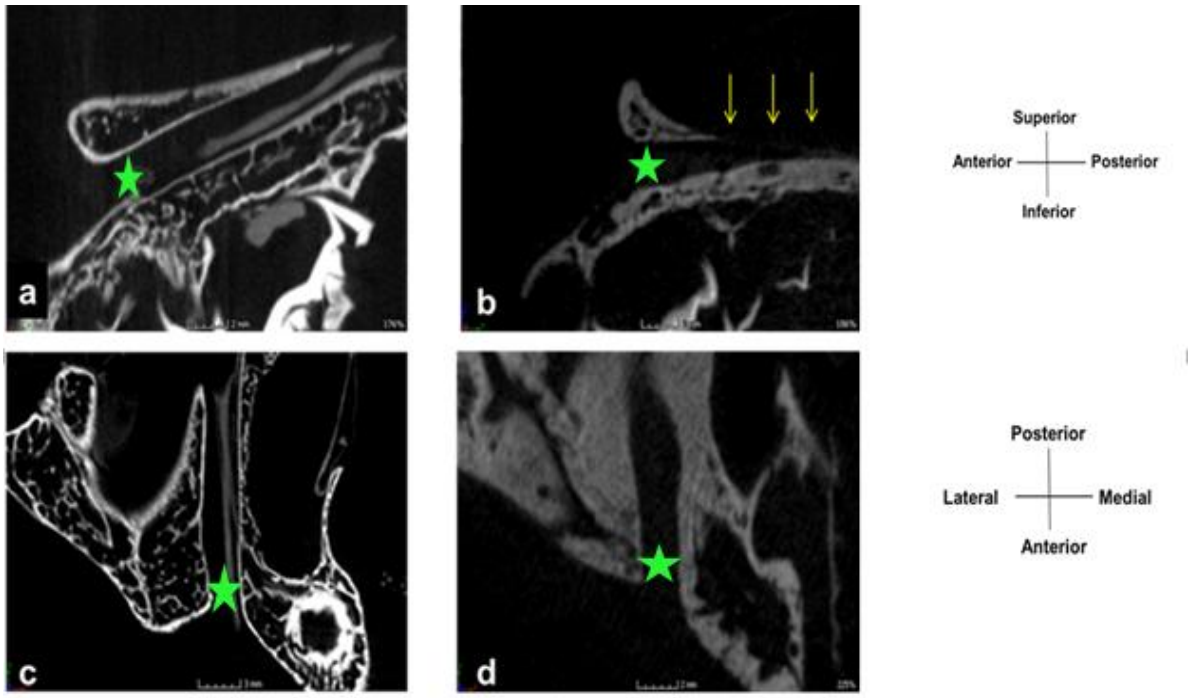

Figure 10: The integrity of the walls of a late prenatal (b and d) and an early postnatal (a and c) individual. Fig. a and Fig. b: Sagittal view indicating the roof and floor of the left infra-orbital canal. Note that the roof of the infra-orbital canal in the late prenatal individual (Fig. b) is absent along the posterior third of the canal (yellow arrows), while the roof of the infra-orbital canal in the early postnatal individual (Fig. a) is complete. Fig. c and Fig. d: Transverse view indicating the medial and lateral walls of the left infra-orbital canal. Note that the bone forming the walls of the infra-orbital canal in the late prenatal individual (b and d) has a consistent appearance, while the bone surrounding the infra-orbital canal in the early postnatal individual (a and c), has a trabeculated appearance. (Infra-orbital canal is indicated by a green star)

Branching patterns

During the assessment of the branching patterns of the infra-orbital canal, a single infra-orbital canal extending from the “internal” infra-orbital foramen to the “external” infra-orbital foramen was observed bilaterally in all individuals. The infra-orbital canal

coursed in an antero-medial direction. The anterior portion of the canal was directed medially and inferiorly and emerged on to the external surface of the skull as the “external” infra-orbital foramen. An accessory “external” foramen was observed lateral to the main infra-orbital foramen in only one late prenatal individual (5%) on the left side of the skull (Fig. 11).

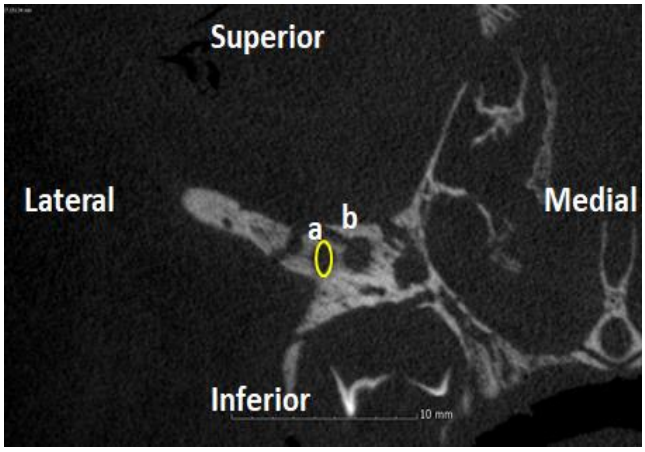

Figure 11: Coronal view of the accessory “external” infra-orbital foramen (a) situated lateral to the main infra-orbital foramen (b) on the right side of the face in a late prenatal individual

When comparing the number of branches arising from the infra-orbital canal and the branching patterns between the left and right sides, variations were observed bilaterally within the same specimen as well as between different specimens. These variations are illustrated in Table 2. The number of branches given off by the infra-orbital canal varied between zero and three branches and the origin of these branches was dependent on the number of branches that were present. Only one individual presented with a canal (on the right side of the skull) which had no branches. In the majority of canals (55%), the infra-orbital canal gave rise to only one branch, originating anywhere along the anterior to posterior extent of the canal. In some individuals (Table 2), the single branch subdivided into multiple branches, heading towards various structures. In cases where the infra-orbital canal gave rise to two independent branches (42%), the branches arose either from the anterior or the posterior third of the canal, respectively. The structures towards which the canal was directed varied. Subdivisions of one branch were also observed (Table 2). Only two individuals had an infra-orbital canal with three branches (2%). The branching pattern of these two individuals also varied (Table 2). No significant differences ($p \geq 0.05$) were observed between the branching patterns of the late prenatal and early postnatal groups, except for the difference ($p \leq 0.015$) in the pattern found between

the late prenatal and early postnatal group with respect to the right undifferentiated anterior dentition.

Table 2: Variations in branching patterns of the infra-orbital canal in the late prenatal and early postnatal groups. The number of individuals that presented with a particular branching pattern is indicated underneath the pattern. The main branch of the infra-orbital canal is indicated in black, while the primary branches are red and the secondary branches are blue. Ant Un, anterior dentition undifferentiated; CI, central incisor; LI, lateral incisor; C, canine; PM1, 1st premolar/ 1st deciduous molar; PM2, 2nd premolar/ 2nd deciduous molar; MS, maxillary sinus; Or, orbit

No. Branches	Variations					
No branches						
Late prenatal **Early Postnatal**	**0** **1**					
1 Branch **No subdivisions**						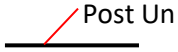
Late prenatal **Early postnatal**	**9** **6**	**3** **4**	**5** **2**	**5** **2**	**0** **2**	**2** **3**
1 Branch **2 subdivisions**	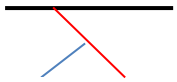	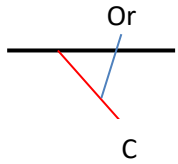				
Late prenatal **Early postnatal**	**1** **2**	**1** **0**				
1 Branch **3 subdivisions**	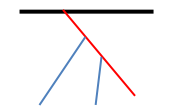	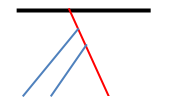	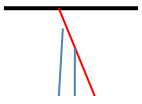			
Late prenatal **Early postnatal**	**0** **1**	**1** **1**	**1**			
1 Branch **5 subdivisions**	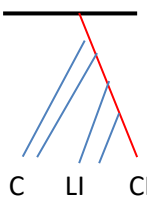					
Late prenatal **Early postnatal**	**0** **1**					

2 Branches No subdivisions	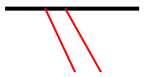	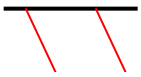	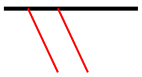		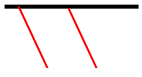	
Late prenatal **Early postnatal**	**4** **2**	**3** **1**	**3** **5**	**3** **1**	**2** **0**	**2** **4**
	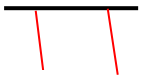		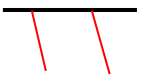	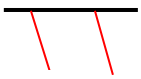	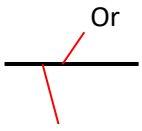	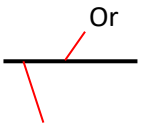
Late prenatal **Early postnatal**	**2** **2**	**0** **1**	**0** **1**	**1** **1**	**1** **1**	**1** **0**
	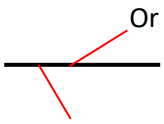					
Late prenatal **Early postnatal**	**1** **1**					
2 Branches 1 branch subdivides into multiple branches	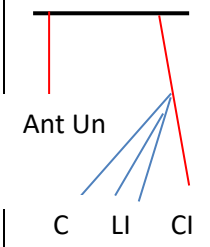	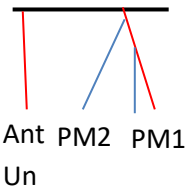	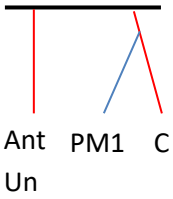	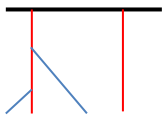		
Late prenatal **Early postnatal**	**1** **0**	**1** **0**	**1** **0**	**1** **1**		
3 Branches	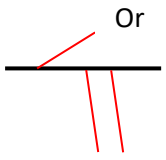	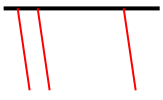				
Late prenatal **Early postnatal**	**0** **1**	**1** **1**				

DISCUSSION

Early detection and treatment of aberrant craniofacial growth is vital within a maxillo-facial and orthodontic context (Yenigun *et al*., 2016). While the infra-orbital canal may be used as a reference point in sub-adults and adults to evaluate the growth pattern of the maxilla (Moss and Greenberg, 1967; Caspersen *et al*., 2009), there is a paucity of information regarding the growth trajectory and changes in the morphology of the infra-orbital canal during the functionally complex late prenatal and early postnatal stages (Lee *et al*., 2006, Ghaus and Faruqi, 2008). Thus, understanding the growth and branching pattern of the infra-orbital canal may assist in interpreting the functional relationships between the maxilla, dentition and associated craniofacial structures during this intricate period of development.

While this study provides valuable insights into the morphometry of the infra-orbital canal during the early stages of development, there were some limitations. The cross-sectional nature of this study is considered to be a limitation as the data was collected at only a single moment in time. This “snapshot” nature limits the depth of inferences that can be made regarding development and growth trajectories of the maxilla. In addition, the sample size of this study may be considered to be small. Despite these limitations, the advanced scanning modalities used in this study provide an advantage over other studies that have investigated the infra-orbital canal. Previous studies which have considered the location, course and contents of the infra-orbital canal relative to surrounding structures, made use of imaging techniques such as cone beam computerized tomography or panoramic radiographs (Scarfe *et al*. 1998; Caspersen *et al*., 2009). Although these latter scanning modalities provide the opportunity to study the infra-orbital canal in a non-invasive manner with low radiation doses, they have several limitations. Cone beam computerized tomography and panoramic scans are not only restricted to a two dimensional perspective, but have also been shown to have lower resolution for the analysis of neonatal specimens (Van Dessel *et al*., 2013). In contrast, micro-CT scanning provides a higher spatial resolution and allows for the visualization of the infra-orbital canal in a three dimensional context (Swain and Xue, 2009). The high spatial resolution used in the current study allowed for observation of the branching pattern and the integrity of the walls of the infra-orbital canal in more detail.

The infra-orbital canal and both the “internal” and “external” infra-orbital foramina as defined in this study, were present in all individuals in both age groups. This concurs with the literature describing the presence of the infra-orbital canal during the early stages of development (Moss and Greenberg, 1967; Schwartz and Langdon, 1991; Ghaus and Faruqi, 2008). Although various studies have measured the length of the infra-orbital canal, it should be noted that the inner point of the canal has not been clearly defined, as in this study. During the 10th gestational week, the “external’ infra-orbital foramen starts to develop (Caspersen *et al*., 2009). This foramen will eventually delineate the infra-orbital canal due to the gradual apposition of bone on both sides of the infra-orbital groove (Moss and Greenberg, 1967). Although the exact developmental stage at which closure of the canal begins is still unknown, (Caspersen *et al*., 2009), it is evident from this study that closure of the walls of the canal has already commenced at the late prenatal stages of development and that the canal has already begun to grow in length at 30 gestational weeks. Since the region surrounding the infra-orbital foramen is the first ossification site of the maxilla (Moss and Greenberg, 1967), any deviation in the process of bone formation of the maxilla might affect development of the infra-orbital canal (Rusu *et al*., 2015). Rusu *et al*. (2015) reported a case in which ossification of the maxilla occurred internal, instead of inferior to the future infra-orbital canal. This resulted in the abnormal positioning of the infra-orbital canal in the lateral wall of the maxillary sinus.

The position of the infra-orbital canal in the adult has been classified according to the relationship it has with the maxillary sinus: a) infra-orbital canal type I: within the roof of the maxilla, b) type II: partially protruding into the maxillary sinus, c) type III: totally protruding into the maxillary sinus with a stalk, d) type IV: on the outer limit of the zygomatic recess of the maxillary bone (Uzun *et al.,* 2016; Yenigun *et al*., 2016; Açar *et al*., 2017). Uzun *et al*. (2016) hypothesized that these variations in the course of the infra-orbital canal might be associated with the pneumatisation process of the maxillary sinus. In addition, Yenigun *et al*. (2016) investigated the morphological variations of neighbouring structures and found a correlation between the presence of the agger nasi cell and an infra-orbital canal completely protruding into the maxillary sinus. Açar *et al*. (2017) found no correlation between the position of the infra-orbital canal and the Haller cell and maxillary sinus septa. The relationship between features of the maxillary sinus and the position of the infra-orbital canal

needs to be investigated in more detail in future studies. Knowledge of the relationship between these structures is crucial during surgical procedures in which maxillary sinus diseases such as maxillary polyposis, benign sinonasal tumours, and antrochoanal polyps are treated through the canine fossa region where the infra-orbital nerve and its branches are located (Robinson and Wormald, 2005).

The majority of the variations of the infra-orbital canal in the adult have been described in terms of the shape, size and number of infra-orbital foramina (Kazkayasi *et al*., 2001; Uzun *et al*., 2016; Dağıstan *et al*., 2017). The position of the "external" infra-orbital foramen, has been found to vary between adult individuals relative to various osseous reference points such as the supraorbital foramen, infra-orbital margin, facial midline and anterior nasal spine (Kazkayasi *et al*., 2001; Hwang *et al*., 2013). Although it is a rare occurrence to find an accessory foramen (0.5% – 18.2%), studies have reported that the number of accessory foramina may vary from one to five (Hindy and Abdel-Raouf, 1993; Kazkayasi *et al*., 2001; Rusu *et al*., 2015; Dağıstan *et al*. 2017). The latter studies were conducted on different adult populations of Egyptian, American and Turkish origin. It may then be possible that the variations in the number of accessory foramina may be related to genetic variations or geographical differences, where environmental factors, such as different climates, might cause accessory foramina to form or influence the positioning and dimensions of the "external" infra-orbital foramen (Churcher, 1959). The finding of the accessory in one individual in the present study is in accordance with the incidence described in the literature (Kazkayasi *et al*., 2001; Rusu *et al*., 2015; Dağıstan *et al*. 2017). From the current study, it is suggested that this accessory foramen may convey a separate branch of the infra-orbital nerve to the midface, since it had no other apparent branches that led to surrounding structures. Kazkayasi *et al*. (2003) reported that a possible reason for the appearance of an accessory foramen may be a vein piercing the maxilla at that location.

The dimensions of the "external" infra-orbital foramen (such as the mean surface area and width) in the early postnatal group were observed to be larger when compared with the late prenatal group. The mean widths of the "external" infra-orbital foramen were 2.02 ± 0.23 mm and 2.19 ± 0.39 mm respectively in the late prenatal and early postnatal groups. Dağıstan *et al*. (2017) found the width of the "external" infra-orbital foramen to be 3.17 ± 0.56 mm in an adult population. When the

measurements of the “external” infra-orbital foramen in the current study are compared with the study conducted by Dağıstan *et al*. (2017) on an adult population, the width of the “external” infra-orbital foramen in the prenatal and postnatal group is approximately 64% to 69% of the width of the foramen in an adult. Thus, it appears that the infra-orbital canal will continue to enlarge with cranial growth after birth.

There is conflicting evidence in the literature regarding not only which vessels run through the “external” infra-orbital foramen, but also the possible influence that the diameter of the vessels exiting the “external” infra-orbital foramen have on the diameter of the foramen (Churcher, 1959; Washburn, 1963; Kazkayasi *et a*l., 2003; Muschlinski, 2008). Churcher (1959) and Muschlinski (2008) reported that both the infra-orbital nerve and infra-orbital artery are transmitted through the “external” infra-orbital foramen, while Washburn (1963) and Kazkayasi *et al*. (2003) found that only the infra-orbital nerve exits through the infra-orbital foramen. Churcher (1959) proposed that the “external” infra-orbital foramina area might be affected by the infra-orbital artery. This suggestion is based on differences in global climates, where populations in colder climates are hypothesized to have larger infra-orbital arteries to warm the face, and therefore have larger infra-orbital foramina than equatorial populations. Muschlinski (2008), however, found no correlation between the area of the infra-orbital artery and the area of “external” infra-orbital foramen, although a strong correlation was found between the size of the infra-orbital foramen and the infra-orbital nerve. Muschlinski (2008) and Kandel *et al*. (2000) suggested that the increase in nerve diameter, resulting in an increase in foramen diameter, might be attributed to regions in the maxilla containing more mechanoreceptors. Kandel *et al*. (2000) suggested that regions containing higher-receptor densities require more nerve fibres for innervation. Kazkayasi *et al*. (2003) also investigated the infra-orbital nerve and its fascicles microscopically in 10 adult cadavers and also found that the infra-orbital nerve enlarged elliptically from the “internal” infra-orbital foramen to the infra-orbital margin, but did not provide a possible explanation for their finding. Taking the studies of Muschlinski (2008) and Kandel *et al*. (2000) into account, the increase in width of the nerve may be attributed to an increase in nerve fibres leading towards certain mechanoreceptors.

Moss and Greenberg (1967) analysed the development and growth of the maxilla and showed that bone modelling and remodelling in the area of the infra-orbital canal

and “external” infra-orbital foramen occurs as a result of the biomechanical forces of surrounding structures such as the growth of palatal and dental structures. It was found that the orientation and width of the infra-orbital canal is also influenced by the expansion of the orbits in a horizontal direction which will cease at the end of the tenth year of development (Moss and Greenberg, 1967). These craniofacial changes may explain the increase in the width of the “external” infra-orbital foramen in the postnatal group of the current study. The increase in width of this foramen may result from the increase in width of the orbits during the early postnatal stages.

The integrity of the walls of the infra-orbital canal of individuals in the current study was found to be highly variable. This complicates the classification of the degree of ossification since the ossification pattern of the walls was not consistent along the entire length of the canal. The roof was observed to be very thin and not always complete along the posterior third of the canal in the majority of individuals in both age groups (late prenatal group: n=19/27; early postnatal group: n=17/23) while the floor of the canal was very thick and well developed. These findings are in concordance with the results reported in the literature (Moss and Greenberg, 1967; Kazkayasi *et al*., 2003; Uzun *et al*., 2016) and are indicative of interplay between the infra-orbital fissure and the infra-orbital canal. However, it still remains unclear what the developmental relationship is between these two structures. De Haan *et al*. (2006) investigated the development of the orbit in prenatal individuals and found that the ethmoid bone had not ossified completely by term. Furthermore, almost 50% of the floor of the orbit (roof of the infra-orbital canal) was still formed by the superior tarsal muscle (providing a supportive framework for the development of the eye and orbit) which has reduced in thickness from the 18th week of gestation and was still being replaced by collagenous fibres. This explains the thinness of the roof of the canal observed in the present study. According to Scott (1959), the size of the orbital cavity has reached approximately 95% of the adult size during the 7th year of growth. At the same stage, further antero-inferior growth of the maxilla involves the deposition of bone in the floor of the orbit. Extensive deposition of bone in the floor will result in covering the infra-orbital groove. Scott (1959) further stated that this deposition of bone is a rare occurrence and in cases where it does occur, the roof will remain very thin compared with the thick floor of the infra-orbital canal. The presence of a well-developed floor, however, may not be true for all adult individuals

as cases where the infra-orbital nerve bulges into the maxillary sinus have been reported (Uzun *et al*., 2016; Yenigun *et al*., 2016). In the current study, the roof was unexpectedly found to be complete in more prenatal than postnatal individuals. Inter-individual differences regarding bone formation in the orbit might be a possible explanation for this finding.

The increase in dimensions of the canal observed in the early postnatal group of this study affected both the size and shape of the canal. Ghaus and Faruqi (2008) found the average length of the infra-orbital canal to be 0.67 mm – 3.20 mm in fetuses ranging between the ages of 16 to 34 weeks. The mean length of the infra-orbital canal was 6.17 ± 2.55 mm and 7.72 ± 3.35 mm respectively in the late prenatal and early postnatal groups of this study. Hwang *et al*. (2013) and Açar *et al*. (2017) measured the length of the infra-orbital canal in adult populations using computed tomographic scans. In both studies, the length of the canal was found to be greater than in the current sample of late prenatal and early postnatal individuals (28.4 mm - Hwang *et al*., 2013; 29.5 mm - Açar *et al*., 2017). Thus, the length of the infra-orbital canal during the assessed period of growth is approximately 21% to 27% of the average length in an adult. The discrepancy in the mean length of the infra-orbital canal found in adult populations may be attributed to differences in reference points and definitions of the infra-orbital canal, groove and the angulation found between these structures (Hwang *et al*., 2013). The presence of the internal angulation can be variable, being either present or absent in an adult individual (Moss and Greenberg, 1967). In the present study, an internal angulation was present in only 14 individuals (late prenatal: n=9; early postnatal: n=5). Differences in the presence of the internal angulation in the floor of the infra-orbital canal between the prenatal and postnatal individuals may be attributed to inter-individual variation. It is clear from the current study that the presence of an internal angulation between the infra-orbital canal and groove develops from a very early stage.

According to Kazkayasi *et al*. (2001), the course and length of the infra-orbital canal undergoes changes related to the growth of the skull. Their cephalometric study found that as the maxilla expands laterally and superiorly, the infra-orbital canal grows parallel to it. As the maxillary tuberosity grows, the length of the infra-orbital canal is increased by appositional growth at the posterior end of the canal (Moss and Greenberg, 1967).

During the assessment of the branching pattern of the infra-orbital canal, a bilateral single infra-orbital canal was observed in all individuals. Canals have been shown to develop around the nerve paths (Chávez-Lomelí *et al*., 1996). Nerve fibres are present at early stages of development (Pearson, 1977). By the 5th week of development, even before an indication of tooth development, the maxillary nerve is already present in the maxillary process (Pearson, 1977). Generally, the morphological tooth classes (incisor, canine, premolar and molar) correspond to branching patterns of the anterior, middle and posterior superior alveolar nerves (Schwartz and Langdon, 1991).

Variations in the number of branches and in the branching pattern of the canal bilaterally within the same specimen, as well as between different specimens, were found in the current study. Similar variations were observed in prenatal studies on the maxillary nerve by Pearson (1977) and Schwartz and Langdon (1991). A high incidence of a right undifferentiated branch in the prenatal group when compared to the postnatal group was found. This is expected as the branches of the canal in the prenatal group are still developing and have not yet reached their specific targets. Thus more branches were found to be “undifferentiated”, when compared to the postnatal group.

CONCLUSION

In conclusion, the dimensions of the infra-orbital canal increased and the walls and bone surrounding the canal became more defined in the postnatal stages. Furthermore, the branching pattern of the infra-orbital canal develops parallel to the associated surrounding structures. The description of the morphometry of the infra-orbital canal during the late prenatal and early postnatal stages may provide valuable insights to predict not only aberrant growth patterns, but may also help to obtain a better interpretation of the multifaceted relationships between the craniofacial bones. Moss and Greenberg (1967) and Caspersen (2010) stated that the constancy in positioning of the infra-orbital canal can be used to study the growth of the maxilla in sub-adults and adults. The growth of the maxilla and its surrounding structures,

however, is dynamic with changes in shape and function throughout the lifespan. It may be of value if future studies investigate the positioning of the infra-orbital canal relative to various points of the maxilla in various stages of development to determine to which specific landmarks the positioning of the canal can be considered as being constant. Furthermore, more research is required to interpret the complex relationship between the infra-orbital fissure and the infra-orbital canal, particularly during the early stages of development.

REFERENCES

1. Açar, G., Özen, K.E., Güler, İ. and Büyükmumcu, M. 2017. Computed tomography evaluation of the morphometry and variations of the infraorbital canal relating to endoscopic surgery. *Brazilian Journal of Otorhinolaryngology*: 1 – 9.
2. Allan, J.C. 1982. Learning about statistics: A primer in simple statistical methods for students of the medical, biological, paramedical, social and behavioural sciences. (1st edition) Macmillan South Africa, Johannesburg, RSA.
3. Alqahtani, S.J., Hector, M.P. and Liveridge H.M. 2010. Brief communication: the London atlas of human tooth development and eruption. *The American Journal of Physical Anthropology* 142: 481 – 490.
4. Caspersen, L.M., Christensen, I.J. and Kjær, I. 2009. Inclination of the infraorbital canal studied on dry skulls expresses the maxillary growth pattern: a new contribution to the understanding of change in inclination of ectopic canines during puberty. *Acta Odontologica Scandinavica* 67(6): 341 – 345.
5. Caspersen, L.M., Christensen, I.J. and Kjær, I. 2010. Maxillary canine ectopia and maxillary canine premolar transposition are associated with deviations in the maxilla. *Dental Anthropology* 23(2): 37 – 41.
6. Chávez-Lomelí, M.E., Mansilla Lory, J. and Kjear, I. 1996. The human mandibular canal arises from three separate canals innervating different tooth groups. *Journal of Dental Research* 75 (8): 1540 – 1544.
7. Churcher, C. 1959. The specific status of the new world red fox. *Journal of Mammalogy* 40: 513 – 520.
8. Dağıstan, S.,Miloğlu, Ö., Altun. O. and Umar, E.K. 2017. Retrospective morphometric analysis of the infraorbital foramen with cone beam computed tomography. *Nigerian Journal of Clinical Practice* 20 (9): 1053 – 1064.
9. De Haan, A.B., Willekens, B., Klooster, J., Los, A.A. van Zwieten, J. and Botha, C.P. 2006. The prenatal development of the human orbit. *Strabismus* 14 (1): 51 – 56.
10. Ghaus, F. and Faruqi, N.A. 2008. Morphometric analysis of infraorbital foramen and infraorbital canal in human feotuses. *International Journal of Morphology* 26 (2): 289 – 293.
11. Gurler, G., Delilbasi, C., Ogut, E.E., Aydin, K., Saku, S.L. 2017. Evaluation of the morphology of the canalis sinuosus using cone-beam computed tomography in patients with maxillary impacted canines. *Imaging Science in Dentistry* 47: 69 – 74.
12. Hansen, K., Sung, C.J. and Huang, C. 2003. Reference values for second trimester fetal and neonatal organ weights and measurements. *Paediatrics and Developmental Pathology* 6: 160 – 167.
13. Hindy, A.M. and Abdel-Raouf, F. 1993. A study of infraorbital foramen, canal

and nerve in adult Egyptians. *Egyptian Dental Journal* 39 (4): 573 – 580.
14. Hwang, S.H., Kim, S.W., Park, C.S., Kim, S.W., Cho, J.H. and Kang, J.M. 2013. Morphometric analysis of the infraorbital groove, canal, and foramen on three-dimensional reconstruction of computed tomography scans. *Surgical and Radiologic Anatomy* 35 (7): 565 – 571.
15. Kandel, E., Schwartz, J. and Jessell, T. 2000. Principles of Neural Science. (4th edition). New York: MaGraw-Hill.
16. Kazkayasi, M., Ergin, A., Ersoy, M., Bengi, O., Tekdemir, I. and Elhan, A. 2001. Certain anatomical relations and the precise morphometry of the infraorbital foramen–canal and groove: An anatomical and cephalometric study. *The Laryngoscope* 111 (4): 609 – 614.
17. Kazkayasi, M., Ergin, A., Ersoy, M., Tekdemir, I. and Elhan, A. 2003. Microscopic anatomy of the infraorbital canal, nerve, and foramen. *Otolaryngology—Head and Neck Surgery* 129(6): 692 – 697.
18. Kerns, M.J.J., Darst, M.A., Olsen, T.G., Fenster, M., Hall, P. and Grevey, S. 2008. Shrinkage of cutaneous specimens: formalin or other factors involved? *Journal of Cutaneous Pathology* 35: 1093 – 1096.
19. Lee, U.Y., Nam, S.H. and Choi, K.N. 2006. Morphological characteristics of the infraorbital foramen and infraorbital canal using three-dimensional models. *Surgical and Radiologic Anatomy* 28: 115 – 120.
20. Lubchenco, L.O., Hansman, C. and Boyd, E. 1966. Intrauterine growth in length and head circumference as estimated from live births at gestational ages from 26 to 42 weeks. *Paediatrics* 37: 403 – 408.
21. Machado, V., B.R. Chrcanovic, M.B. Felippe, L.R.C. Manhaes and P.S.P. de Carvalho. 2016. Assessment of accessory canals of the canalis sinuosus: A study of 1000 cone beam computed tomography examinations. *International Journal of Oral and Maxillofacial Surgery* 45: 1586 – 1591.
22. Moss, M.L. and Greenberg, S.N. 1967. Functional cranial analysis of the human maxillary bone: I, Basal bone. *The Angle Orthodontist* 37(3): 151 – 164.
23. Muchlinski, M.N. 2008. The Relationship between the infra-orbital foramen, nerve, and maxillary mechanoreception: Implications for interpreting the paleoecology of fossil mammals based on infraorbital foramen size. *The Anatomical Record* 291: 1221 – 1226.
24. Nowlan, N.C., 2015. Biomechanics of foetal movement. *European Cells and Materials* 29: 1 – 21.
25. Pearson, A.A. 1977. The early innervation of the developing deciduous teeth. *Journal of Anatomy* 123 (3): 563 – 577.
26. Phillips, B.J. and Turco, L.M. 2017. Le Fort fractures: A collective review. *Bulletin of Emergency and Trauma* 5 (4): 221 – 230.
27. Prasad, V.N. and Khanal, A. 2016. Computed tomography evaluation of maxillofacial injuries. *Journal of College of Medical Sciences-Nepal 12* (4): 131 – 136.

28. Robinson, S. and Wormald, P.J. 2005. Patterns of innervation of the anterior maxilla: A cadaver study with relevance to canine fossa puncture of the maxillary sinus. *The Laryngoscope* 115 (10) 1785 – 178.
29. Rusu, M.C., Sandulescu, M. and Ilie, O.C. 2015. Infra-orbital canal bilaterally replaced by a latero-antral canal. *Surgical and Radiologic Anatomy* 37 (9): 1149 – 1153.
30. Scarfe, W.C., Langlais, R.P., Ohba, T., Kawamata, A. and Maselle, I. 1998. Panoramic radiographic patterns of the infraorbital canal and anterior superior dental plexus. *Dentomaxillofacial Radiology* 27 (2): 85 – 92.
31. Scott, J.H. 1959. Further studies on the growth of the human face. *Dental Journal* 52: 263 – 269.
32. Schuknecht, B. and K.W. Grätz. 2005. Radiologic assessment of maxillofacial, mandibular, and skull base trauma. *European Radiology* 15: 560 – 568.
33. Schwartz, J.H. and Langdon, L.H. 1991. Innervation of the human upper primary dentition: Implications for understanding tooth initiation and rethinking growth and eruption patterns. *American Journal of Physical Anthropology* 86: 273 – 286.
34. Stan, M.C., Bordei, P., Dina, C. and Iliescu, D.M. 2013. Characteristics of some anatomical landmarks on the anterior face of the maxilla. *Medical Tomitana* 19 (2): 79 – 83.
35. Swain, M.V. and Xue, J. 2009. State of the art micro-CT applications in dental research. *International Journal of Oral Science* 4: 177.
36. Uzun, Ç., Șanverdi, Ș.E., Üstüner, E., Gürses, M.A. and Șalvarlı, Ș. 2016. Evaluation of Infraorbital Canal Anatomy and Related Anatomical Structures with Multi-Detector Ct. *Journal of Ankara University Faculty of Medicine* 69 (2): 89 – 93.
37. Van Dessel, J., Huang, Y., Depypere, M., Rubira-Bullen, I., Maes, F. and Jacobs, R. 2013. A comparative evaluation of cone beam CT and micro-CT on trabecular bone structures in the human mandible. *Dento-maxillo facial radiology* 42 (8): 20130145.
38. Von Arx, T., Lozanoff, S., Sendi, P. and. Bornstein, M. 2013. Assessment of bone channels other than the nasopalatine canal in the anterior maxilla using limited cone beam computed tomography. *Surgical and Radiologic Anatomy* 35: 783 – 790.
39. Washburn S. 1963. The study of race. *American Anthropologist* 65: 521 – 531.
40. Yenigun, A., Gun, C., Uysal, I.I. and Nayman, A. 2016. Radiological classification of the infraorbital canal and correlation with variants of neighbouring structures. *European Archives of Oto-Rhino-Laryngology 273* (1): 139 – 144.

APPENDICES

Appendix A : Human Research Ethics Committee (Medical) waiver

Human Research Ethics Committee (Medical)

Research Office Secretariat: Senate House Room SH 10005, 10th floor. Tel +27 (0)11-717-1252
Medical School Secretariat: Medical School Room 10M07, 10th Floor. Tel +27 (0)11-717-2700
Private Bag 3, Wits 2050, www.wits.ac.za. Fax +27 (0)11-717-1265

Ref: W-CJ-140604-1 25/01/2016

TO WHOM IT MAY CONCERN:

Waiver: This certifies that the following research does not require clearance from the Human Research Ethics Committee (Medical).

Investigator: School of Anatomical Sciences (Head: Prof M Steyn - Previously Prof T J M Daly, initial approval 04/06/2014 – recertified 27/01/2016).

Project title: Research on Cadaveric Material.

Reason: In terms of Chapter 8, sections 62-64 of the National Health Act No 61 of 2003 donated bodies and their tissues may be used for, among other purposes, health, and research. Use of such Material is subject only to permission from the responsible person in the School of Anatomical Sciences – the Head or person designed by the Head.

Professor Peter Cleaton-Jones

Chair: Human Research Ethics Committee (Medical)

UNIVERSITY OF THE WITWATERSRAND
OFFICE OF THE DEPUTY VICE CHANCELLOR RESEARCH
29 JAN 2016
RESEARCH OFFICE HREC (Medical)
JOHANNESBURG

Copy - HREC (Medical) Secretariat: Rhulani Mkansi, Zanele Ndlovu.

Appendix B : Turnitin Report

turnitin

Digital Receipt

This receipt acknowledges that Turnitin received your paper. Below you will find the receipt information regarding your submission.

The first page of your submissions is displayed below.

Submission author:	Surraine Smit
Assignment title:	/ANAT8001A _ 2019
Submission title:	706964:MSc_Dissertation_Surraine..
File name:	-4ecd-aaed-f8e94b4f17da_MSc_D..
File size:	1.77M
Page count:	46
Word count:	11,273
Character count:	62,705
Submission date:	26-Feb-2019 04:51PM (UTC+0200)
Submission ID:	1084111309

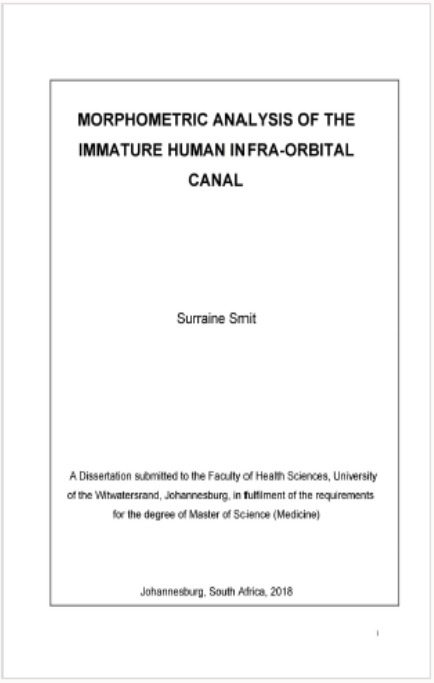

MORPHOMETRIC ANALYSIS OF THE IMMATURE HUMAN INFRA-ORBITAL CANAL

Surraine Smit

A Dissertation submitted to the Faculty of Health Sciences, University of the Witwatersrand, Johannesburg, in fulfilment of the requirements for the degree of Master of Science (Medicine)

Johannesburg, South Africa, 2018

Copyright 2019 Turnitin. All rights reserved.

706964:MSc_Dissertation_Surraine_Smit_Final.pdf

ORIGINALITY REPORT

16%	8%	14%	2%
SIMILARITY INDEX	INTERNET SOURCES	PUBLICATIONS	STUDENT PAPERS