

A STUDY OF MUSCLE TWITCH RESPONSES, THE EFFECT OF ANAESTHETIC
AGENTS AND THE CORRELATION WITH HISTOLOGY, HISTOCHEMISTRY,
ELECTRON MICROSCOPY AND CLINICAL PRESENTATION

by

Jane Louise Markus Ralph, B.Sc. (Physiotherapy)(Witwatersrand)

A dissertation submitted in fulfilment of the requirements for the
degree of Master of Science in Physiotherapy in the Faculty of
Medicine, University of the Witwatersrand, Johannesburg

Johannesburg 1980

TO MY
parents and husband,
whose encouragement and guidance have been
my inspiration

DECLARATION

I declare that this dissertation is my own, unaided work. It is being submitted for the degree of Master of Science in Physiotherapy in the University of the Witwatersrand, Johannesburg. It has not been submitted before for any degree or examination in any other University, nor has it been prepared under the aegis or with the assistance of any other body or organization or person outside the University of the Witwatersrand, Johannesburg.

Markus Ralph

Twelfth day of December, 1980.

ABSTRACT

Studies were carried out on muscle specimens from patients with various neuromuscular disorders, including malignant hyperthermia carriers, in order to determine the value of muscle tension tests in the diagnosis of malignant hyperthermia. It was found that when the results of muscle tension studies were considered together with those of other tests, this technique facilitated the detection of malignant hyperthermia carriers. When used alone, however, the study of muscle tension could not be regarded as infallibly predictive.

Physiotherapeutical investigations showed that chest physiotherapy may be of great value in treating certain neuromuscular conditions. In addition, physiotherapy appeared to improve functional activities in patients with progressive diseases such as spinal muscular atrophy and peroneal muscular atrophy, despite having no effect on actual muscle strength.

Several other unexpected but interesting findings emerged, one of these being the need to devise a more accurate and objective means of assessing patients with generalized muscular weakness.

ACKNOWLEDGEMENTS

I am most grateful to Dr H. Isaacs, my supervisor, for his guidance, encouragement and assistance; and for so readily making available the use of his Neuromuscular Research Laboratory.

I also wish to thank the following persons:-

Mrs J.C. Beenhakker (Acting Head of the Department of Physiotherapy, University of the Witwatersrand), my supervisor, for her support.

Miss M. Badenhorst (Senior Technician, Neuromuscular Research Laboratory, University of the Witwatersrand Medical School), for her invaluable help in connection with the collection of data and teaching of laboratory techniques.

Mrs G.M. Dawson (Secretary to Dr H. Isaacs), for her efficient organizing of appointments, and aid in familiarizing the author with the filing system.

Mrs P.J. Thornley, for typing Table 2.

CONTENTS

	<u>Page</u>
<u>ABSTRACT</u>	i
<u>ACKNOWLEDGEMENTS</u>	ii
<u>LIST OF TABLES</u>	vi
<u>LIST OF ILLUSTRATIONS</u>	vii
<u>LIST OF ABBREVIATIONS USED</u>	ix
<u>INTRODUCTION</u>	1
<u>HISTORICAL REVIEW</u>	4
<u>SKELETAL MUSCLE</u>	5
General structure	5
Striations	5
Chemical composition and properties of the myofibril	6
Sarcoplasmic reticulum and transverse tubular system	6
Ultrastructure of the sarcoplasmic reticulum membrane ...	10
Chemical composition of the sarcoplasmic reticulum	11
Subunit structure of myosin	12
Subunit structure of actin, tropomyosin and troponin	13
<u>EXCITATION AND REGULATION OF CONTRACTION IN STRIATED MUSCLE</u> ..	14
Nerve conduction	14
Neuromuscular transmission	14
<u>EXCITATION-CONTRACTION COUPLING</u>	16
Electrical properties of muscle	16
Inward spread of contraction activation along the T system	16
Identity of the "activator"	17
Site of calcium accumulation	17
Calcium binding by membrane components of the sarcoplasmic reticulum	18
Rate of calcium binding by the sarcoplasmic reticulum mem- branes	19
Active calcium transport across the sarcoplasmic reticulum membrane	19
Mechanism of coupling between ATPase and calcium transport	20

	<u>Page</u>
Calcium release from the sarcoplasmic reticulum and ATP synthesis	21
Cross-bridge activation	22
Sliding filament theory	23
Chemical properties of cross-bridge activity	24
ENERGY - REGENERATION OF ATP	26
HEAT	27
MUSCLE TENSION	28
MECHANICAL PROPERTIES OF MUSCLE	31
CLASSIFICATION OF FIBRE TYPES	32
HISTOCHEMICAL PROPERTIES OF FIBRE TYPES	33
HISTOLOGICAL STAINING METHODS	36
HISTOCHEMICAL REACTIONS	36
ELECTRON MICROSCOPY	38
ELECTROMYOGRAPHY AND NERVE CONDUCTION VELOCITY TESTS	38
<u>MATERIALS AND METHODS</u>	40
BIOPSY PROCEDURE	41
HISTOLOGY AND HISTOCHEMISTRY	43
Preparation of specimens	43
Cryostat sectioning	43
Staining techniques	43
ELECTRON MICROSCOPY	48
MUSCLE TENSION STUDIES	50
Construction of apparatus	50
Experimental procedure	50
<u>RESULTS</u>	56
<u>DISCUSSION</u>	74
DIAGNOSTIC ASPECTS	75
Muscle tension studies	75
Histology and histochemistry	80

	<u>Page</u>
Electron microscopy	80
Electroneuromyography	81
Prognosis	82
PHYSIOTHERAPEUTICAL AND RELATED ASPECTS	82
<u>CONCLUSION</u>	89
<u>APPENDIX 1</u> - THE ASSESSMENT FORM USED	91
<u>APPENDIX 2</u> - SUMMARIES OF CASE HISTORIES	101
<u>APPENDIX 3</u> - SYNOPSES OF SELECTED NEUROMUSCULAR DISORDERS ...	153
<u>APPENDIX 4</u> - EXAMPLES OF NORMAL AND ABNORMAL MUSCLE TENSION TRACINGS	196
<u>REFERENCES</u>	201

LIST OF TABLES

	<u>Page</u>
<u>Table 1</u> - Histochemical reactions of human muscle. Diagrammatic representation of the intensity of the histochemical reaction in different fibre types	34
<u>Table 2</u> - Summaries of biopsy findings and clinical assessments of patients	57
<u>Table 3</u> - Reaction of muscle to caffeine	59
<u>Table 4</u> - Increase in tension of muscle following administration of 4% halothane	66
<u>Table 5</u> - Increase in tension of muscle following administration of 2 ml succinylcholine	71
<u>Table 6</u> - Clinical sensory changes in the three types of peroneal muscular atrophy	163
<u>Table 7</u> - Sural nerve biopsy findings in the three types of peroneal muscular atrophy	164

LIST OF ILLUSTRATIONS

	<u>Page</u>
<u>Figure 1</u> - Electron micrograph showing the structure of normal muscle	7
<u>Figure 2a</u> - The length/tension curve for an isolated frog muscle fibre, showing the relation between filament overlap and contractile force	29
<u>Figure 2b</u> - Critical stages in the overlap between actin and myosin filaments, as a sarcomere shortens	29
<u>Figure 3</u> - Apparatus used for muscle tension studies	53
<u>Figure 4</u> - Caffeine-induced contraction of muscle isolated from patients with various neuromuscular diseases and from controls	63
<u>Figure 5</u> - Halothane-induced contraction of muscle isolated from patients with various neuromuscular diseases and from controls	69
<u>Figure 6</u> - Succinylcholine-induced contraction of muscle isolated from patients with various neuromuscular diseases and from controls	72
<u>Figure 7</u> - Mild form of spinal muscular atrophy (Case 4)	157
<u>Figure 8</u> - Mild form of spinal muscular atrophy (Case 4)	157
<u>Figure 9</u> - Intermediate form of spinal muscular atrophy (Case 6)	159
<u>Figure 10</u> - Intermediate form of spinal muscular atrophy (Case 6)	159
<u>Figure 11</u> - Peroneal muscular atrophy (Case 15)	165
<u>Figure 12</u> - Peroneal muscular atrophy (Case 9)	165
<u>Figure 13</u> - Peroneal muscular atrophy (Case 14)	167

	<u>Page</u>
<u>Figure 14</u> - Peroneal muscular atrophy (Case 14)	167
<u>Figure 15</u> - Hypertrophic form of peroneal muscular atrophy (Case 14)	169
<u>Figure 16</u> - Myasthenia gravis (Case 18)	178
<u>Figure 17</u> - Myasthenia gravis (No case number)	178
<u>Figure 18</u> - Stiff man syndrome (Case 27)	185
<u>Figure 19</u> - Stiff man syndrome (Case 27)	185
<u>Figure 20</u> - Stiff man syndrome (Case 27)	187
<u>Figure 21</u> - Stiff man syndrome (Case 27)	187
<u>Figure 22</u> - Malignant hyperthermia (Case 28)	191
<u>Figure 23</u> - Malignant hyperthermia (Case 28)	191
<u>Figure 24</u> - Malignant hyperthermia (No case number)	193
<u>Figure 25</u> - Example of a normal muscle tension tracing (Normal 13)	197
<u>Figure 26</u> - Example of an abnormal muscle tension tracing (Case 29)	199

LIST OF ABBREVIATIONS USED*

A band	-	anisotropic band
ADP	-	adenosine diphosphate
ATP	-	adenosine triphosphate
ATPase	-	adenosine triphosphatase
CPK	-	creatine phosphokinase
EDTA	-	ethylenediaminetetra-acetic acid
E_{Ca}^{O} MgATP	-	enzyme-calcium-substrate
EP	-	phosphorylated intermediate
EM	-	electron microscopy
EMG	-	electromyography
EPL	-	end plate
F-actin	-	fibrous actin
G-actin	-	globular actin
GABA	-	gamma-aminobutyric acid
H & E	-	haematoxylin and eosin
HMM	-	heavy meromyosin
H zone	-	Henson's zone
I band	-	isotropic band
LMM	-	light meromyosin
M ₅₅	-	55,000 dalton m-protein
MgATP	-	magnesium adenosine triphosphate
MH	-	malignant hyperthermia
MJS	-	myoneural junctional studies
MNT	-	motor nerve terminal

* Some of the more commonly used abbreviations have not been included in this list.

ms^{-1}	- metres per second
M.Str.	- muscle strength
mV	- millivolt/s
MW	- molecular weight
NAD^{+}	- oxidized nicotinamide-adenine dinucleotide
NADH	- reduced nicotinamide-adenine dinucleotide
NADH-TR	- reduced nicotinamide-adenine dinucleotide-tetrazolium reductase
NCS	- nerve conduction studies
PAS	- periodic acid Schiff
PMA	- peroneal muscular atrophy
S-1	- subfragment-1
S-2	- subfragment-2
SEC	- series elastic components
SMA	- spinal muscular atrophy
SMS	- stiff man syndrome
SR	- sarcoplasmic reticulum
T tubule	- transverse tubule
TN-C	- calcium-binding component of troponin
TN-I	- inhibitory component of troponin
TN-T	- tropomyosin-binding component of troponin
Δ	- diagnosis

ms^{-1}	- metres per second
M.Str.	- muscle strength
mV	- millivolt/s
MW	- molecular weight
NAD^+	- oxidized nicotinamide-adenine dinucleotide
NADH	- reduced nicotinamide-adenine dinucleotide
NADH-TR	- reduced nicotinamide-adenine dinucleotide-tetrazolium reductase
NCS	- nerve conduction studies
PAS	- periodic acid Schiff
PMA	- peroneal muscular atrophy
S-1	- subfragment-1
S-2	- subfragment-2
SEC	- series elastic components
SMA	- spinal muscular atrophy
SMS	- stiff man syndrome
SR	- sarcoplasmic reticulum
T tubule	- transverse tubule
TN-C	- calcium-binding component of troponin
TN-I	- inhibitory component of troponin
TN-T	- tropomyosin-binding component of troponin
Δ	- diagnosis

INTRODUCTION

For a number of years, a high level of serum creatine phosphokinase (CPK) in conjunction with certain histological, histochemical and electron microscopical findings, had been used as an indication that a patient might be a carrier of malignant hyperthermia (MH). A high CPK level could not, however, be considered as diagnostic, since it occurs in several disorders other than MH. Likewise, muscle biopsy results are non-specific and variable, similar pictures being seen in a variety of neuromuscular diseases. In vitro muscle tension studies using halothane were, therefore, carried out by earlier authors in an attempt to establish whether this test could be used as a positive means of detecting patients who are carriers of MH. Although muscle tension studies had been in use since 1958 and had yielded encouraging results, work had been restricted mainly to the reactions of muscle obtained from normal patients as compared to muscle from patients suspected of being carriers of MH.

Kalow et al. (1970) showed that muscle from known MH patients was more sensitive to caffeine than that of normal patients; and increasing amounts of caffeine had been used in muscle tension studies, to compare the reactions of muscle from normal and MH-susceptible patients. Nevertheless, the reaction to caffeine of muscle from patients with different neuromuscular disorders had not been adequately examined. Further research was, therefore, required in order to determine the value of the caffeine test in screening for MH.

A positive reaction to halothane was recently obtained in the Neuro-muscular Research Laboratory in Johannesburg in a patient with Parkinson's disease, who was considered not to be a carrier of MH. This showed the need for further investigation, to determine the reaction to halothane of muscle from patients with various other neuromuscular disorders.

The work presented in this dissertation was undertaken in order to clarify the value of muscle tension studies in the diagnosis of MH. Prior to commencement of this research, the validity of muscle tension studies as a specific predictive means of detecting carriers of MH, had only really been questioned by Bradley et al. (1973). These authors demonstrated that administration of halothane to muscle of known carriers of MH, may result in a false negative response. In the present

investigation, results of muscle tension studies (using halothane, caffeine and in special cases, succinylcholine as testing media) were considered in conjunction with histopathological (including electron microscopical), electromyographical and clinical findings, to see whether any distinctive pattern emerged which could indicate predisposition to a possible MH incident. The purpose was also to ascertain whether MH was more common in one type of neuromuscular disorder than in any other of those studied.

Physiotherapy is concerned, inter alia, with muscle. In the past, physiotherapists have treated the many progressive and non-progressive neuromuscular disorders without much thought as to what they actually hoped to achieve. Consequently, clinical assessments and re-examination of the patients were carried out by the therapist or in the hope of determining the value of physiotherapy in these conditions; and in an attempt to establish more specifically the role of physiotherapists in the treatment of patients with certain disorders discussed in this dissertation. Unfortunately, the patient sample who could have physiotherapy was inadequate; but several interesting and thought-provoking results emerged, nevertheless.

HISTORICAL REVIEW

SKELETAL MUSCLE

General structure

The basic unit of skeletal muscle is the muscle fibre, a long, cylindrical structure which ranges from approximately 1 to 40 mm in length and 10 to 100 μm in diameter. The diameter of the fibre increases with age and under the influence of strenuous muscular activity. Each fibre is surrounded by a delicate, elastic, connective tissue sheath, the sarcolemma, beneath which numerous elliptical nuclei are situated. Most of the interior of the muscle fibre is formed by a large number of threadlike structures known as myofibrils, each of which measures about 1 to 2 μm in diameter. These are grouped together into bundles of fascicles surrounded by perimysial connective tissue. Each myofibril is further sub-divided into thin actin and thick myosin filaments, as observed in early studies of the ultrastructure of muscle by Hall *et al.* (1946) and Draper and Hodge (1949). The two sets of filaments are arranged in a double hexagonal array, each thick filament being surrounded by six thin ones (H.E. Huxley, 1953a).

Cross-bridges, which are projections localized on the thick myosin filaments (Elliott, 1964), extend towards the actin filaments. Since there are six thin filaments around each thick one, there are six cross-bridges leaving each thick filament for every 400 \AA interval of its length.

The intermyofibrillar space contains aqueous sarcoplasm in which glycogen granules and various subcellular organelles such as mitochondria, sarcoplasmic reticulum (SR) and the transverse tubular (T-tubular) system are found. Other structures present include muscle spindles, blood vessels and nerve endings.

Striations

The characteristic, cross-striated or banded pattern of the myofibril has been attributed to differences in the refractive indexes of the partially overlapping, interdigitating actin and myosin filaments (H.E. Huxley, 1956). This repeated pattern of light, isotropic

(I - singly refractile) and dark, anisotropic (A - birefringent) bands extends throughout the length of the parallel myofibrils. A dense, narrow Z line bisects the I band, and the unit formed by the material encompassed between two adjacent Z lines, constitutes a sarcomere (Fig. 1). The thick myosin filaments are confined to, and characterize the A band. The thin actin filaments, attached to the Z line of the I band, extend into the A band, except in a narrow, less dense, central region known as the H zone (Henson's zone), where only thick filaments are found. An additional striation, the M line, is caused by a slight thickening of the myosin filaments and is observed in the middle of the H zone.

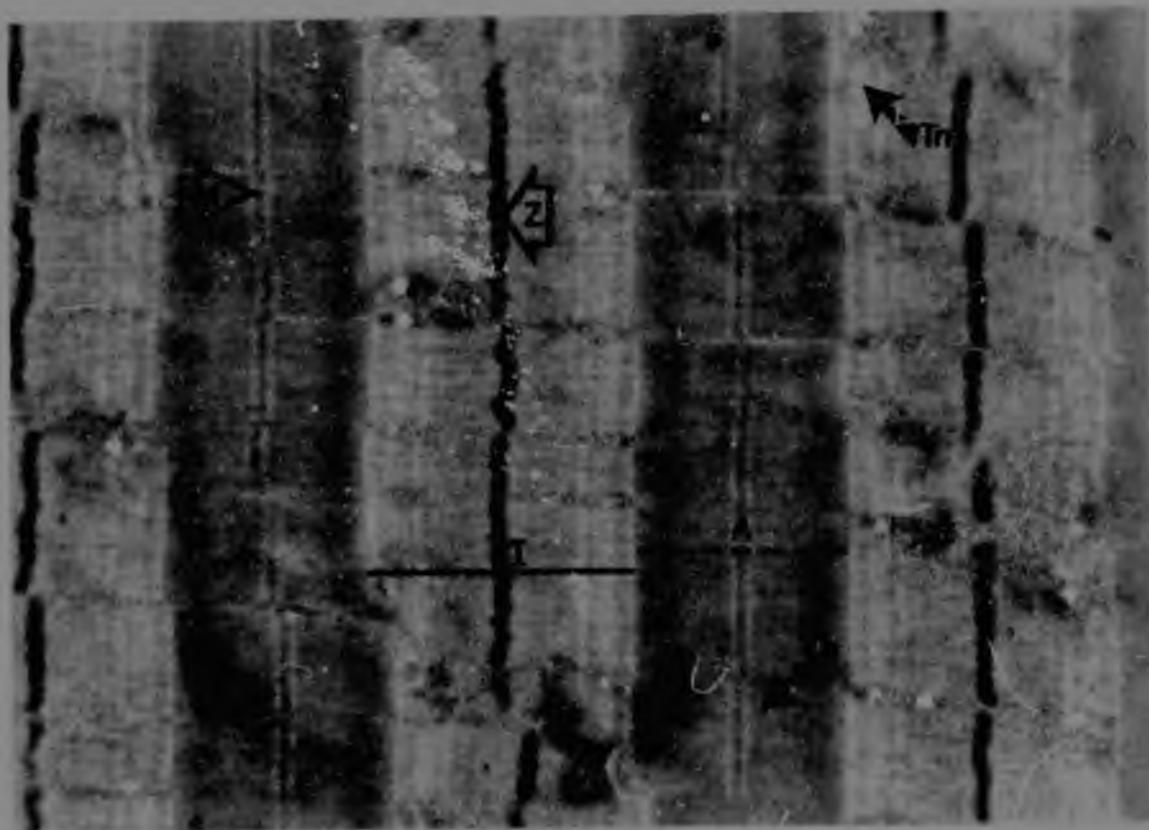
Chemical composition and properties of the myofibril

The actin and myosin filaments interact under the influence of tropomyosin, troponin and other regulatory proteins to form the basic contractile mechanism of muscle. Myosin accounts for approximately 54% of the total structural protein content of fibrils, while the amount of actin in fibrils is estimated as being only 20% to 25% (Hanson and Huxley, 1957). Tropomyosin and troponin, which together constitute "native" tropomyosin (Ebashi and Endo, 1968), are distributed along the actin filaments, and are present in smaller quantities - about 7% and 2%, respectively (Carlson and Wilkie, 1974). Troponin comprises three different subunits, troponin T (TN-T), troponin I (TN-I) and troponin C (TN-C), and is considered to be the calcium receptor of muscle (Endo, 1977). The released calcium ion binds with one of the troponin subunits, TN-C, thus initiating the contractile reaction by changing the conformational state of the regulatory proteins. Other myofibrillar protein complexes include: C-protein, part of the thick filament (Starr and Offer, 1971; Offer, 1972); M-line protein, of which one component has been shown to be the enzyme creatine phosphokinase (Morimoto and Harrington, 1972; Herasymowych *et al.*, 1980); α -actinin, the major component of the Z band (Stromer *et al.*, 1969; Goll *et al.*, 1972), and β -actinin in the I-band region (Maruyama, 1965) - the functions of both of which are as yet unknown.

Sarcoplasmic reticulum and transverse tubular system

An elaborate, membranous structure in the intermyofibrillar sarco-

Figure 1. Electron micrograph showing the structure of normal muscle.
(x 10000)



(Key: A - A band; H - H zone; I - I band; M - M line;
Th - thick myosin filament; In - thin actin fila-
ment; Z - Z line)

plasm, said to have first been observed by Retzius in the late nineteenth century, was later described by Sjöstrand (1956). This structure can be sub-divided into two components: the SR and the T-tubular system (Porter and Palade, 1957; Andersson-Cedergren, 1959). These two structures occupy about 15% of the cell volume (Peachey, 1965).

The SR is a continuous network of longitudinally orientated, membrane-limited tubules of varying sizes, shapes and densities. These tubules form a complicated lace-like sleeve around the myofibrils (Porter and Palade, 1957). The SR covers a surface area of approximately 3,000 - 10,000 cm² per cm³ of muscle (Peachey, 1965) and is responsible for the regulation of the sarcoplasmic calcium ion concentration, thereby controlling contraction and relaxation of muscle (Tonomura, 1973).

The T-tubular system is a system of tubules which traverse around the myofibrils. The tubules lie primarily in a plane which is transverse to the long axis of the fibre and SR, although short, longitudinal excursions of T tubules were seen by Andersson-Cedergren (1959), H.E. Huxley (1964) and Page (1965). The T system arises as a funnel-like invagination of the sarcolemma (Peachey, 1968), the lumen of which forms a functional continuity with the extracellular space, as was first shown by H.E. Huxley (1964). This was confirmed by Endo (1964), Franzini-Armstrong and Porter (1964), Eisenberg and Eisenberg (1968) and Peachey and Schild (1968). It is thought that the T system permits the transmission of an action potential from the cell membrane to the SR, causing calcium ions to be released (Bastian and Nakajima, 1974; Costantin, 1975; Franzini-Armstrong, 1975). This idea is supported by A.F. Huxley and Taylor's earlier (1958) experiments, in which they found that a local contraction of significant magnitude occurred only when the plasma membrane surface was locally depolarized exactly at the position of the T system. The T tubules are flanked at regular intervals by a pair of longitudinal, dilated, terminal cisternae of the SR, forming a complex known as a triad (Porter and Palade, 1957). This triadic junction has the unique property that the gap between the terminal cisternae and T tubule is nearly or completely bridged by evaginations or "feet" from the terminal wall of the SR cisternae (Franzini-Armstrong, 1968; Kelly, 1969). Although this close associ-

ation exists between the T system and SR, there is no open communication between them. There are two triads per sarcomere, one at the level of each A-I band (Andersson-Cedergrén 1959).

Ultrastructure of the sarcoplasmic reticulum membrane

The calcium-transporting membrane of the SR is composed of vesicles (Porter and Palade, 1957; Porter, 1961; Franzini-Armstrong and Porter, 1964; Peachey, 1965; Sarzała *et al.*, 1975) enclosed by a single, triple-layered, asymmetrical membrane about 60Å thick (Hasselbach and Elfvin, 1967). These vesicles can be further resolved into light, intermediate and heavy vesicles (Meissner, 1975). Light vesicles appear as empty sacs by electron microscopy (Meissner, 1974) and are composed of almost equal amounts of phospholipid and calcium-pump protein, this accounting for approximately 90% of the total protein. Heavy vesicles contain, in addition to the calcium-pump protein, two other major protein components. These are the calcium-binding and M_{55} proteins, which account for the electron dense material observed inside heavy vesicles (Meissner, 1975). These vesicles contain half the amount of phospholipid of light vesicles, in accordance with their high content of calcium-binding protein. Intermediate vesicles have a calcium-binding and M_{55} protein content somewhere between that of light and heavy vesicles. Heavy vesicles retain twice as many calcium ions as do light vesicles, while the latter accumulate three times as many calcium ions (Meissner, 1974). Thus, the three types of vesicles differ in composition, morphology and function. From these data, Meissner (1975) concluded that the heavy vesicles containing electron dense material are derived from the terminal cisternae of the SR, while light vesicles, which appear empty, originate from the longitudinal sections of the SR (Meissner and McKinley, 1976). Further ultrastructural characterization was then carried out by means of negative staining of the SR vesicles. This revealed the presence of particles about 40Å in diameter on their outer surface (Deamer and Baskin, 1969; Ikemoto *et al.*, 1971; MacLennan *et al.*, 1971; MacLennan *et al.*, 1974). The particles are uniformly distributed and are present on the majority of vesicles. A second type of particle, 80 - 90Å in diameter, is found on the internal surface of vesicles and has been identified with the adenosine triphosphatase (ATPase) protein (Deamer and Baskin, 1969; MacLennan

et al., 1971; Scales and Inesi, 1976). The latter are present on approximately 70% of vesicles and cover about 20% of the vesicle surface (Deamer and Baskin, 1969).

Chemical composition of the sarcoplasmic reticulum

Seven proteins have been isolated from the SR. These comprise two groups: a series of water-soluble, hydrophobic (extrinsic) proteins and a group of water-insoluble (intrinsic) proteins (MacLennan et al., 1974).

The Ca^{2+} -dependent ATPase of the intrinsic proteins is a membrane-forming enzyme, consisting of a major ATPase peptide (molecular weight (MW) $\sim 102,000$); a proteolipid (MW $\sim 12,000$); variable amounts of a high molecular-weight protein; and neutral lipids and phospholipids (MacLennan, 1970; MacLennan et al., 1971). These intrinsic proteins form the trilaminar, asymmetrical structure of the SR membrane (Inesi and Asai, 1968; Ikemoto et al., 1971; MacLennan et al., 1971; MacLennan et al., 1974) and account for the globular structures on the inner surface of the SR membrane (Deamer and Baskin, 1969). It should be noted, however, that the above conclusions are not in agreement with those of Hasselbach and Elfvin (1967), Thorley-Lawson and Green (1973) and Yu et al. (1975), who considered the Ca^{2+} -ATPase to be either on or projecting from the outer surface of the SR vesicles.

The extrinsic proteins are a series of highly acidic proteins of different molecular weights and are thought to possess the common property of binding calcium that has been transported to the interior by the Ca^{2+} -dependent ATPase (MacLennan and Wong, 1971; MacLennan et al., 1974). The largest of these proteins, the M_{55} protein (MW $\sim 55,000$), is the least acidic and has the highest affinity for calcium. Calsequestrin (MW $\sim 46,500$) and the other acidic proteins (with molecular weights ranging between 20,000 and 38,000) have far lower calcium-binding values. These values have been discussed in detail by Ostwald and MacLennan (1974). The amino acid composition was given by Meissner et al. (1973) and this, together with the differences in molecular weight and calcium-binding activity, makes them clearly distinguishable from one another.

The localization of the protein components of SR vesicles is debated and there are conflicting views. For example, calsequestrin was

said to be on the internal surface of vesicles by MacLennan and Wong (1971) and Stewart *et al.* (1976), but on the external surface by Thorley-Lawson and Green (1973); while Yu *et al.* (1976) reported that calsequestrin and related Ca^{2+} -binding proteins are either buried within the membrane structure or located on the internal surface of the vesicles.

Subunit structure of myosin

The myosin filament is formed by an aggregation of rod-like, α -helically arranged structures known as myosin molecules, which are approximately $1,600\text{\AA}$ long (Pepe, 1967). The myosin molecule is divided into two subfragments, heavy meromyosin (HMM) and light meromyosin (LMM) (Mihályi and Szent-Györgyi, 1953; Szent-Györgyi, 1953; Lowey and Cohen, 1962).

HMM accounts for 70% of the molecular mass of myosin and is in the form of a tail (subfragment-2 (HMM S-2)) (Lowey *et al.*, 1969), which terminates in two globular subunits or heads (HMM subfragments-1 (HMM S-1)) (Mueller and Perry, 1962), both 190\AA in length (Offer and Elliott, 1978). These globular heads, each with a diameter of approximately 64\AA , consist of two heavy chains and four light chains (Trotta *et al.*, 1968); A-1, A-2 and two DTNB chains (Carlson and Wilkie, 1974). The heads interact with actin and hydrolyze ATP (Hanson *et al.*, 1971; Lowey and Steiner, 1972).

In contrast, LMM, attached to the tail of HMM, consists of a simple, double-stranded, α -helical rod with a diameter of $15 - 20\text{\AA}$ (H.E. Huxley, 1963; Zobel and Carlson, 1963; Rice *et al.*, 1966) and is composed of a dispersed system of polypeptides called protomyosin. The rod-like tails of the myosin molecules (LMM) are arranged in a tail-to-tail fashion and form the shaft of the thick filament. Further aggregation towards the tapered ends of the thick filament occurs in a head-to-tail fashion (H.E. Huxley, 1963), the HMM S-1 portions projecting laterally and outwards at the surface to form the cross-bridges. In the centre of the thick filaments is a bare zone, or pseudo-H zone, which arises from the tail-to-tail (antiparallel packing - H.E. Huxley, 1963) arrangement of the LMM. No myosin cross-bridges

are found in this pseudo-H zone (Pepe, 1968).

It is assumed that the cross-bridges, projecting at intervals of approximately 143\AA , are constructed from the head pieces of the myosin molecule, since recent studies suggest that the ATPase activity and actin-combining sites are completely localized in the head portion S-1 of HMM, the light chains forming the structural units necessary for these physiological functions (Tonomura, 1973). Thus, it is evident that the many varied functions of myosin are confined to particular regions of its structure.

Chemically, the myosin molecule consists of numerous amino acid residues distributed uniformly throughout the molecule, the composition of each subunit having been discussed in detail by Tonomura (1973).

Subunit structure of actin, tropomyosin and troponin

In muscle, actin occurs in the fibrous (F-actin) form. The actin filament, with a diameter of about 80\AA (Hanson and Lowy, 1963; Moore *et al.*, 1970), has a tertiary structure. It consists of a double-stranded helix of actin subunits and "native" tropomyosin. The latter comprises two proteins troponin and tropomyosin. The two intertwining F-actin chains cross at intervals of 355\AA to 370\AA , in which length there are thirteen relatively globular monomers (H.E. Huxley and Brown, 1967; Moore *et al.*, 1970). Each of these globular subunits represents one G-actin monomer, of which there are 350 - 400 per thin filament, each with a diameter of about 55\AA (H.E. Huxley, 1953b; Selby and Bear, 1956; Hanson and Lowy, 1963; Moore *et al.*, 1970). G-actin is the compact mass which forms the repeating subunit of F-actin, the latter being formed by polymerization of the G-actin monomer (Hanson and Lowy, 1963). The molecular weight of G-actin is 46,000 to 47,000 daltons.

The two regulatory proteins, tropomyosin and troponin, form a structural component of the actin filament. Tropomyosin is a fibrous protein with a molecular weight about 66,000 - 70,000 daltons (Holtzer *et al.*, 1965; Woods, 1967). The tropomyosin molecule consists of two α -helical, polypeptide chains which form a coiled coil (*sic*) measuring about 400 - 410\AA in length and 18\AA in width (Caspar *et al.*, 1969;

Millward and Woods, 1970; Longley, 1977). There is one tropomyosin molecule in the groove of each double-stranded actin filament (Spudich *et al.*, 1972). This arrangement occurs in a regular, periodic fashion, namely, one tropomyosin molecule for every seven actin monomers.

Troponin, a fairly globular protein (MW 80,000), is situated about 100Å or 150Å from the end of each tropomyosin molecule (Cohen *et al.*, 1972) and is spaced about every 400Å along the thin filament (Ohtsuki *et al.*, 1967). There is one troponin molecule for each tropomyosin molecule. Troponin comprises three distinct peptide chains of different molecular weights. These are calcium-binding protein or TN-C (MW 18,000); inhibitory protein or TN-I (MW 22,000); and tropomyosin-binding protein or TN-T, the protein with a mass of 37,000 - 39,000 daltons (Greaser and Gergely, 1971).

In the absence of calcium, troponin, together with tropomyosin, maintains the dissociation of actin and nucleotide-containing myosin.

EXCITATION AND REGULATION OF CONTRACTION IN STRIATED MUSCLE

Nerve conduction

When nerve is stimulated, either electrically or chemically, the potential difference across the membrane of the nerve decreases. This results in increased permeability of the membrane to sodium ions, which move across the membrane into the cell and carry the early inward membrane current (Hodgkin and Huxley, 1952a,b). The accompanying change in the membrane ionic environment is the start of a propagated action potential, which is associated with a wave of depolarization that passes along the length of the nerve fibre to the nerve terminals.

Neuromuscular transmission

The arrival of a nerve action potential at the neuromuscular junction causes depolarization of the nerve terminal membrane. There is

an increase in calcium conductance, and calcium ions diffuse across the nerve membrane into the presynaptic end-plate region. This results in a brief but powerful acceleration in release of the transmitter, acetylcholine (Hubbard *et al.*, 1968; Katz and Miledi, 1968; Kosower and Werman, 1971). The exact role of calcium ions in the release of transmitter is not fully understood. However, it is known that a decrease in the calcium ion concentration in the end-plate region or an increase in the magnesium ion concentration in the presence of calcium ions, results in a neuromuscular block caused by a reduction in the amount of acetylcholine released (Hubbard *et al.*, 1968). The transmitter is released from the synaptic vesicles in the form of small "packages" or quanta, each containing many thousands of molecules of acetylcholine (Kriebel *et al.*, 1976; Wernig, 1976). It then diffuses across the narrow gap between the nerve and muscle membranes, a distance of about 1 μm , and attaches to the end-plate receptors of the muscle fibre membrane. The acetylcholine receptor is a protein now thought to consist of more than one polypeptide chain (Nathanson and Hall, 1980). A local end-plate potential is generated as a result of summation of many (100 - 250) units of transmitter released simultaneously (Dei Castillo and Katz, 1954); and which, at a critical magnitude, causes depolarization of the muscle fibre membrane by altering the permeability to sodium. This change in ionic gradient gives rise to the muscle action potential, which propagates along the length of the fibres at a velocity of 0.5 - 5 ms^{-1} .

Shortly after acetylcholine has acted, it is removed from the end-plate region by diffusion and hydrolysis. The enzyme acetylcholinesterase, found on the surface of the postsynaptic membrane, hydrolyzes acetylcholine to acetate and choline. The choline is reabsorbed by presynaptic nerve terminals and reacylated by acetyl coenzyme A to form a new molecule of acetylcholine.

Neuromuscular transmission is also regulated by the action of the hormones norepinephrine and epinephrine, which facilitate transmission (Bowman and Raper, 1967; Kuba, 1970; Kuba and Tomita, 1971).

EXCITATION-CONTRACTION COUPLING

Electrical properties of muscle

The muscle action potential, or spike potential as it is frequently called, is (as stated earlier) dependent on the intracellular/extracellular ionic environment. The ionic distribution is such that the concentration of potassium is higher inside the myofibril, while the predominant cation outside the membrane is sodium. The resting transmembrane potential of mammalian skeletal muscle is approximately -90 mV, the inside of the fibril being negative with respect to the outside. When stimulated, the potential is reduced to +30 to +40 mV and there is a concomitant increase in the permeability of the membrane to sodium, potassium and chloride ions. Although the electrical properties of skeletal muscle are similar to those of nerve fibres, chloride ions play a greater role in muscle than in nerve (Hodgkin and Horowitz, 1959).

Inward spread of contraction activation along the T system

It is now generally accepted that the T tubules of skeletal muscle form the active intermediary pathway for excitation-contraction coupling between the surface membrane and the interior of the muscle fibre (A.F. Huxley, 1971; Bastian and Nakajima, 1974). The action potential is conducted from the muscle fibre membrane into the muscle cell by depolarization of the T system (Gage and Eisenberg, 1967). The tubular action potential is the result of active conducting changes similar to those which occur in the surface membranes of nerve and muscle cells. When the T system membranes become depolarized, the current is carried into the fibre and initiates the spread of depolarization along the tubules to the SR (Costantin, 1970; Peachey, 1972). Activation of the SR causes calcium ions to be released into the sarcoplasm, which leads to muscle contraction. However, the exact mechanism by which the tubular action potential induces release of activator (calcium ions) from the SR, is not yet known. It has been postulated that the close proximity of the T tubules to the terminal cisternae of the SR at the triadic junction (Peachey, 1965) causes a potential dif-

ference across the SR membrane, resulting in release of calcium ions. An alternative mechanism, suggested by Kasai and Miyamoto (1973) and Nakajima and Endo (1973) following their experiments on skinned muscle fibres, was that the change in ionic environment results in a massive influx of salt and water into the vesicles. This causes osmotic swelling and an increase in membrane permeability which depolarizes the SR membrane, thus resulting in release of calcium ions.

Identity of the "activator"

The earliest evidence for a physiological role of calcium came from the work of Ringer and Buxton (1887), who found that the isolated frog heart no longer contracted when calcium was not added to the bathing solution. Since the study by Heilbrunn and Wiercinski (1947), calcium has become recognized as the "activator" of muscular contraction. Muscle will not contract in the absence of calcium, not even in the presence of a high concentration of potassium. Inesi and Malan (1976) and Taylor and Godt (1977) demonstrated that direct stimulation of the muscle fibre caused calcium ions to be released, resulting in muscular contraction. Jöbsis and O'Connor (1966) and Ashley and Ridgway (1968) had previously obtained similar results. It was also observed by various workers that during relaxation, the free calcium ion concentration became markedly reduced.

Site of calcium accumulation

Winegrad (1965, 1970), using autoradiographic techniques, showed that during the relaxation phase of muscle, calcium is taken up mainly by the longitudinal sacs of the SR and subsequently accumulated in the terminal cisternae (sacs) of the SR (Costantin *et al.*, 1965; Podolsky *et al.*, 1970), where the calcium concentration in resting muscle is highest.

The calcium accumulated in the SR is bound in vast quantities to the calcium-binding protein, calsequestrin, and to the 55,000 dalton protein localized on the interior surfaces of the SR membrane vesicles. The calcium concentrations on the surfaces of calcium-loaded SR vesicles may be as high as 20 mM (MacLennan and Wong, 1971). The

aforementioned proteins play a major role in binding and sequestering the large number of calcium ions on the surfaces of the SR vesicles, in order to reduce the calcium concentration in the sarcoplasm to the level in the resting fibre.

Calcium binding by membrane components of the sarcoplasmic reticulum

Calcium is taken up by the SR following transport of calcium ions through the membrane into the vesicles (Hasselbach, 1964). Early studies by Marsh (1951, 1952) and Bendall (1952, 1958) showed that an aqueous extract of muscle had a relaxing effect on myofibrillar bundles. It was shown by Ebashi (1958) that this "relaxing factor" was associated with the granular fraction known as the Kielley-Meyerhof ATPase (Kielley and Meyerhof, 1948, 1950). The methods of preparation employed indicated that the relaxing factor consisted of vesicular structures derived from the SR of muscle (Ebashi and Lipmann, 1962; Muscatello *et al.*, 1962). Bozler (1954, 1955), Watanabe and Sleator (1957), Ebashi (1961) and Seidel and Gergely (1963) reported that muscular contraction and relaxation was regulated by calcium. The discovery by Ebashi (1961), Ebashi and Lipmann (1962) and Hasselbach and Makinose (1961, 1963) that calcium ions are accumulated by the SR in the presence of magnesium ions and ATP, revealed the importance of the SR in muscle relaxation.

Calcium binding to the SR high-affinity binding sites, namely on the ATPase protein (Cohen and Selinger, 1969; C'evallier and Butow, 1971; Fiehn and Migala, 1971), is thought to represent the initial reaction of the membrane with calcium, i.e. it causes enzyme activation (Inesi *et al.*, 1980). The initial reaction is followed by a secondary process, namely the binding of calcium ions by the M_{55} protein (high-affinity calcium-binding protein) and the lower affinity sites of calsequestrin; but which nevertheless have an extremely high capacity for binding calcium. This secondary process takes place on the inner surfaces of the SR vesicles (Ikemoto *et al.*, 1972, 1974).

Thus, the uptake of calcium ions involves active transport across the SR membrane; and one mole of ATP is hydrolyzed for every two moles of calcium accumulated (Weber *et al.*, 1966; Friedman and Makinose,

1970; Yamada et al., 1970, Tada et al., 1978). Information concerning the amount of calcium accumulated by each protein fraction has been reviewed by Tada et al. (1978).

Rate of calcium binding by the sarcoplasmic reticulum membranes

The rate of calcium uptake found experimentally, differs from that which occurs in muscle in vivo. This discrepancy is attributed to the "unphysiological" state of SR preparations (Ishii and Endo, 1968). The rates of uptake of calcium by the SR have been discussed by these and other authors.

In certain diseases, the rates of calcium uptake are affected. For example, Samaha and Gergely (1969) suggested that the SR is probably the site where the primary cause of muscular dystrophy is to be found. In Duchenne muscular dystrophy, the initial and total calcium uptake rates and ATPase activities of the SR are low. In myotonic dystrophy, there is high initial, and normal total calcium uptake.

In another myopathy, malignant hyperthermia, it was shown that the rates of ATPase activity, initial calcium uptake and total calcium uptake by the SR were reduced (Isaacs and Heffron, 1975). The rates of ATPase activity and initial calcium uptake by the SR were found to be normal in another patient, while total calcium uptake was halved (Isaacs et al., 1975).

The rate of calcium uptake by the SR of normal muscle varies according to the type of muscle fibre. In slow fibres, the rate of uptake is slower than that in fast fibres.

Active calcium transport across the sarcoplasmic reticulum membrane

As was mentioned previously, calcium taken up by the SR becomes bound to it. Transport of calcium by the SR from the external solution against a concentration gradient, requires energy. This energy is derived from hydrolysis of ATP (Hasselbach and Makinose, 1961; Martonosi, 1971), acetylphosphate (De Meis, 1969; Pucell and Martonosi, 1971) or carbomyolphosphate (Pucell and Martonosi, 1971) by transport ATPase, which is dependent on membrane phospholipids for its activity

(Martonosi et al., 1968).

It was concluded from experiments on the rate of calcium binding by the SR that binding of calcium to the surface of the SR is dependent on the presence of magnesium ions and ATP (Ohnishi and Ebashi, 1963, 1964). Duggan (1977) showed that potassium also stimulates uptake of calcium and thus increases the rate of relaxation. It has been found that two moles of calcium are accumulated when one mole of ATP is hydrolyzed, while one mole of phosphate is liberated (see review by Tada et al., 1978).

Mechanism of coupling between ATPase and calcium transport

Pardee (1968a,b) pointed out that during transport of ions, a carrier protein has to perform at least three successive functions. Firstly, it has to recognize the specific ion amongst the many other solutes present in the system, and bind it. It then has to translocate these ions across the membrane (which requires energy) and, finally, release the ions and revert to its original state. These three steps will be described below.

There are two types of ATP hydrolysis which supply energy for the active transport of calcium across the membrane. These are the calcium-independent (basic ATPase) and the calcium-dependent (extra ATPase) ATPase activities (Hasselbach and Makinose, 1962; Inesi et al., 1976), both of which require magnesium for their activation.

Magnesium ions play at least two important roles in ATP hydrolysis. The first is to enhance decomposition of the phosphorylated intermediate formed during ATP hydrolysis and the second is to form an equimolar complex with ATP, namely MgATP, which serves as a true substrate for calcium-dependent ATPase (Vianna, 1975).

Kanazawa et al. (1971) proposed a scheme for the overall calcium-magnesium-dependent ATPase reaction, to explain the coupling mechanism between ATPase and calcium transport. At the outer surface of the membrane, two moles of calcium and one mole of MgATP (substrate - as mentioned previously) bind in a random sequence to one mole of ATPase (enzyme), forming the first Michaelis enzyme-substrate-calcium complex

($E_{MgATP}^{Ca_2^O}$). When the ATP concentration is high, the ATPase reaction is accelerated and the ATP acts not only as a substrate but also as a regulator, controlling enzyme activity. Thus, a similar (second) Michaelis complex is formed ($E_{MgATP}^{Ca_2^O}$). The formation of a second complex was also found to occur in myosin ATPase (Tonomura, 1973) and Na^+-K^+ -dependent ATPase (Tonomura and Fukushima, 1974). Calcium is then translocated from outside to inside the membrane when the phosphorylated intermediate (EP) is formed (Kanazawa *et al.*, 1970). After this, calcium is released from the enzyme into the interior of the vesicle, because of reduction in the affinity of the enzyme for calcium ions during EP formation; and binding of calcium to the extrinsic proteins takes place. At the same time, magnesium, having an increased affinity for the phosphorylated intermediate, accelerates decomposition of EP into ADP and phosphate, both of which are liberated from the enzyme to the exterior of the vesicle (Panet *et al.*, 1971; Inesi *et al.*, 1974). An efflux of magnesium and potassium is associated with the influx of calcium (Kanazawa *et al.*, 1971). It can be seen from the above that the formation of one mole of EP results in transport of two moles of calcium from the outside to the inside of the membrane, where they replace $(1+n)$ moles of magnesium and $2(1-n)$ moles of potassium, of which one mole of magnesium is required for the decay of EP (Tonomura, 1973).

Calcium release from the sarcoplasmic reticulum and ATP synthesis

The results of experiments by Barlogie *et al.* (1971) on calcium ion efflux in the presence of ADP, inorganic phosphate, magnesium, and a high concentration gradient of calcium ions across the membrane, led these authors to suggest that the Ca^{2+} - Mg^{2+} -dependent ATPase reaction of the SR is reversible. All the reaction products of calcium accumulation are required for the reverse reaction when calcium is released from the SR (Martonosi *et al.*, 1974). As for calcium uptake, magnesium ions activate the reaction (Yamada *et al.*, 1972).

When ADP is added to the calcium-loaded vesicles in the presence of magnesium, there is a rapid calcium efflux and simultaneous synthesis of ATP from ADP and inorganic phosphate (Makinose, 1971; Yamada and Tonomura, 1972; De Meis and Carvalho, 1974; De Meis and Sorenson, 1975;

De Meis, 1976). The phosphoprotein formed during ATP synthesis is indistinguishable from that formed during calcium accumulation. One mole of ATP is synthesized for every two calcium ions released from the vesicles (Makinose, 1972; Panet and Selinger, 1972). ATP synthesis is energized by the calcium concentration gradient across the membrane. Thus, the SR acts as an energy converter which transduces osmotic energy into chemical energy and vice versa (Yamada et al., 1972).

Cross-bridge activation

When calcium is released from the SR, the level of free calcium in the sarcoplasm is raised and calcium binds to the myofibrils, causing contraction to take place because of the formation of force-generating complexes between actin and myosin.

At free calcium levels above $10^{-7}M$ or, when the calcium concentration becomes high enough to saturate troponin (Fuchs and Briggs, 1968), TN-C, which has a high binding affinity for calcium, binds four calcium ions and thereby causes a change in the conformational state of the TN-C molecule (Endo, 1977). This activated TN-C binds with TN-I, resulting in reversal of inhibition by TN-I of actin-activated ATP hydrolysis (Hartshorne and Dreizen, 1972; Perry et al., 1972). TN-T binds with tropomyosin in a 1:1 ratio (Hartshorne and Mueller, 1969; Greaser et al., 1972) and is thought to increase the affinity of TN-C and TN-I for the tropomyosin-containing actin filament by providing them with additional binding sites (Spudich et al., 1972). Thus, TN-I is bound to the actin filament not only through its actin-binding site but also possibly by TN-T; while TN-C is bound via TN-I and through TN-T to the actin filament (Weber and Murray, 1973). It is thought that TN-T also creates "calcium-sensitivity" by regulating the state of actin according to the amount of calcium in the sarcoplasm (Eisenberg and Kielley, 1972a; Greaser et al., 1972).

From the above data, it is evident that TN-C initiates the contractile reaction by changing the conformational state of the regulatory proteins (Adrian et al., 1976). Troponin does not bind to the myosin molecule (Greaser et al., 1972).

Sliding filament theory

During relaxation, the calcium concentration in the sarcoplasm is low, i.e. less than $10^{-7}M$. At this time, the troponin complex is bound to actin and tropomyosin in such a way that the tropomyosin molecule interferes sterically with the binding of the myosin heads to the actin filament (Haselgrove, 1972). This prevents activation of actomyosin ATPase (H.E. Huxley, 1972), the activity of which is low in resting muscle. Dissociation of actin and myosin is maintained in this manner.

When calcium is released from the SR and binds to troponin, this inhibitory effect on the cross-bridge/sliding filament mechanism is removed. The action of troponin on the tropomyosin molecule alters the position of tropomyosin, thus exposing the active actin site for the attachment of the HMM S-1 moiety of the myosin molecule.

The cross-bridges formed by HMM S-1 and S-2 produce the inter-filamentary sliding force, doing so by binding several sites on the myosin head sequentially with reactive sites on the actin filament (A.F. Huxley and Simmons, 1971). These reactive sites on the actin filament are arranged in order of increasing myosin/actin affinities. The S-1 moiety attaches to the first site on the actin molecule and by means of rotation of the head, the other sites attach in sequential fashion. The force produced by rotation of the myosin head on actin results in sliding of the thick myosin filament further towards the Z line (H.E. Huxley, 1969; Borejdo *et al.*, 1979; H.E. Huxley *et al.*, 1980). Once the head has finished rotating, it detaches from the actin filament. The HMM S-1 moiety then reattaches at another site further along the actin filament. The cycle of cross-bridge attachment, rotation and detachment is repeated, each time increasing the overlap between the actin and myosin filaments and resulting in shortening of the sarcomere length, which causes the muscle to contract. The cross-bridges attach in an asynchronous manner, so that at any instant some of them are attached while others are detached, and in the process, moving towards the next reactive site on the actin filament. In this way, the sliding filament mechanism first suggested by A.F. Huxley and Niedergerke (1954) and H.E. Huxley and Hanson (1954) and, later, by Pringle (1967) and H.E. Huxley (1968), is produced.

The actions of the two individual heads of the myosin molecule during contraction and relaxation have still to be resolved. It has been reported that the ATPases of the two heads of myosin act equally and independently (Murphy and Morales, 1970; Margossian and Lcwey, 1973; Gadasí et al., 1974; Cooke and Franks, 1977; Reisler, 1980). In contrast, a study by Inoue and Tonomura (1976) provided evidence that the heads are structurally and functionally dissimilar. Tokiwa and Morales (1971) stated that they are an interacting pair. Others have suggested that the two heads of the myosin molecule may attach to adjacent G-actin subunits in the actin filaments (Offer and Elliott, 1978).

Takeuchi and Tonomura (1971) concluded that both the S-1 moieties of the double-headed, HMM fragment can combine simultaneously with actin, each with a different monomer, while Eisenberg and Kielley (1972b) wrote that only one HMM head binds to actin.

Chemical properties of cross-bridge activity

The energy required for muscular contraction is derived from hydrolysis of ATP, mediated by the contractile protein actomyosin. The ATP is not utilized directly to produce cross-bridge force but instead dissociates the actin/myosin cross-bridge and prepares the myosin head for reattachment to the actin molecule. The ATP and actin-combining properties of myosin are associated with the HMM S-1 component. Two competing reactions are involved (Finlayson et al., 1969; Eisenberg and Moos, 1970): dissociation of actomyosin by ATP hydrolysis; and activation of myosin ATPase by actin, involving interaction of myosin and actin, which is dependent on the HMM of the cross-bridges (Chaplain, 1969; H.E. Huxley, 1969). There is recent evidence that calcium-dependent phosphorylation of myosin light chains plays a major role in regulating actin/myosin interaction in skeletal muscle (Bárány et al., 1980; Stull et al., 1980).

When calcium is released from the SR, its influence on troponin and subsequently on tropomyosin (see previous section), exposes the active site for the myosin S-1 head. Owing to an increased affinity of myosin for actin, the HMM S-1 molecule then attaches to the active

site by the action of calcium on the troponin and tropomyosin molecules. The combination of actin filaments with myosin cross-bridges activates myosin ATPase (Lymn and Taylor, 1970, 1971; Taylor et al., 1970; Moos, 1972), initiating hydrolysis of the MgATP (Bárány and Bárány, 1972), which is bound to the ATPase site on the head region of the HMM molecule. Magnesium is the only ion necessary for ATPase activity, since calcium does not have a direct influence on the contractile activity of actin or myosin. Hydrolysis of MgATP by ATPase is accelerated by actin (Eisenberg and Moos, 1970; Bremel et al., 1972) and the free energy released is utilized for the dissociation of the myosin head from the actin filament (Leadbeater and Perry, 1963; Lymn and Taylor, 1971; Takeuchi and Tonomura, 1971). During hydrolysis, myosin-bound ATP is rapidly converted to myosin.ADP.P intermediate (Lymn and Taylor, 1970, 1971; Bagshaw et al., 1972). It is thought that the force produced during contraction is dependent on the formation of a force-generating complex between actin and myosin.ADP.P intermediate (Weber and Murray, 1973). The intermediate is then converted into the enzyme/product complex and ADP and inorganic phosphate are released once the head of the myosin molecule has started to rotate. After the head has rotated fully, ATP is again bound to the ATPase site in the presence of magnesium. This, together with inorganic phosphate, causes the myosin cross-bridge to detach from the actin site. The cycle is repeated. This transient shortening acts as an intermediate step (A.F. Huxley, 1957; Davies, 1963; Podolsky and Teicholz, 1970) in the process of sarcomere shortening (i.e. in the sliding filament mechanism). In resting muscle, 90% of myosin is present as myosin.ADP.P intermediate and 10% as myosin ATP (Marston and Tregear, 1972). Thus, it is evident that MgATP is required for contraction and relaxation.

When the calcium concentration is low (less than $10^{-7}M$), troponin, in conjunction with tropomyosin, causes relaxation by reducing the actin-activated rate of ATP hydrolysis to about 10 - 20% (Eisenberg and Kielley, 1970; Weber and Bremel, 1971; Bremel and Weber, 1972); that is, 80 - 90% of all the actin monomers become inactivated (Bremel and Weber, 1972). Relaxation does not, however, occur when the concentration of ATP is low (Weber and Winicur, 1961; Weber and Herz, 1963).

site by the action of calcium on the troponin and tropomyosin molecules. The combination of actin filaments with myosin cross-bridges activates myosin ATPase (Lymn and Taylor, 1970, 1971; Taylor *et al.*, 1970; Moos, 1972), initiating hydrolysis of the MgATP (Bárány and Bárány, 1972), which is bound to the ATPase site on the head region of the HMM molecule. Magnesium is the only ion necessary for ATPase activity, since calcium does not have a direct influence on the contractile activity of actin or myosin. Hydrolysis of MgATP by ATPase is accelerated by actin (Eisenberg and Moos, 1970; Bremel *et al.*, 1972) and the free energy released is utilized for the dissociation of the myosin head from the actin filament (Leadbeater and Perry, 1963; Lymn and Taylor, 1971; Takeuchi and Tonomura, 1971). During hydrolysis, myosin-bound ATP is rapidly converted to myosin.ADP.P intermediate (Lymn and Taylor, 1970, 1971; Bagshaw *et al.*, 1972). It is thought that the force produced during contraction is dependent on the formation of a force-generating complex between actin and myosin.ADP.P intermediate (Weber and Murray, 1973). The intermediate is then converted into the enzyme/product complex and ADP and inorganic phosphate are released once the head of the myosin molecule has started to rotate. After the head has rotated fully, ATP is again bound to the ATPase site in the presence of magnesium. This, together with inorganic phosphate, causes the myosin cross-bridge to detach from the actin site. The cycle is repeated. This transient shortening acts as an intermediate step (A.F. Huxley, 1957; Davies, 1963; Podolsky and Teicholz, 1970) in the process of sarcomere shortening (i.e. in the sliding filament mechanism). In resting muscle, 90% of myosin is present as myosin.ADP.P intermediate and 10% as myosin ATP (Marston and Tregear, 1972). Thus, it is evident that MgATP is required for contraction and relaxation.

When the calcium concentration is low (less than $10^{-7}M$), troponin, in conjunction with tropomyosin, causes relaxation by reducing the actin-activated rate of ATP hydrolysis to about 10 - 20% (Eisenberg and Kielley, 1970; Weber and Bremel, 1971; Bremel and Weber, 1972); that is, 80 - 90% of all the actin monomers become inactivated (Bremel and Weber, 1972). Relaxation does not, however, occur when the concentration of ATP is low (Weber and Winicur, 1961; Weber and Herz, 1963).

Muscle becomes inextensible and rigid (Bate-Smith and Bendall, 1947; Weber and Portzehl, 1952) and most or all of the myosin heads become attached to actin (H.E. Huxley and Brown, 1967; H.E. Huxley, 1968; Miller and Tregear, 1971; H.E. Huxley, 1972). This state is known as rigor mortis and is the result of failure of the cross-bridges to detach from the actin filaments.

A review of the various cross-bridge models has been provided by Eisenberg and Greene (1980) who, in addition, proposed a new biochemical model of cross-bridge action in vivo.

ENERGY - REGENERATION OF ATP

Muscular activity derives its energy from the hydrolysis of ATP by actomyosin, which results in the formation of ADP and inorganic phosphate. Since the concentration of ATP in muscle is only 2 - 4 mM, it is rapidly used up during sustained contraction. The ADP and inorganic phosphate formed are resynthesized into ATP by mitochondria, the energy required being supplied by respiration through the electron-transport mechanism.

During contraction, glycogen is converted into pyruvic acid via the Embden-Meyerhof glycolytic cycle, which takes place in the sarcoplasm. In the glycolytic cycle, NAD^+ (oxidized nicotinamide-adenine dinucleotide) is the hydrogen carrier; and in the presence of oxygen, NADH (reduced nicotinamide-adenine dinucleotide) transfers its hydrogen and two extra electrons to the cytochrome chain in the mitochondrion.

The end product of glycolysis under aerobic conditions is pyruvic acid. This, after entering the mitochondrion, first combines with coenzyme A and then proceeds, via the Krebs tricarboxylic acid (citric acid) cycle, to produce carbon dioxide and hydrogen. The latter, in combination with hydrogen from NAD^+ , is transferred to the cytochrome chain; and in the presence of oxygen and the electrons from NADH, water is formed. ATP is regenerated by rephosphorylation of ADP by an energy-rich phosphagen compound, creatine phosphate. This reaction is

thought to occur in three steps along the cytochrome chain. ADP released during activity activates oxidative phosphorylation, which continues until ATP and phosphocreatine have been restored to their resting levels. In this manner, the levels of ATP in muscle are maintained.

HEAT

During contraction and relaxation of muscle, heat is produced. Heat liberated during the contractile process is known as initial heat (which is heat of activation and maintenance, heat of shortening and heat of relaxation). Heat of activation and maintenance is caused by chemical processes which change the muscle from a relaxed to an active state; and it is produced irrespective of whether or not muscle shortening occurs. Heat of shortening is liberated partly as a result of transformation of energy from the chemical into mechanical form (i.e. most likely by energy produced by the cross-bridges, as actin and myosin filaments slide over one another). Heat is formed in this manner only if muscle shortening takes place during contraction. Heat of relaxation is produced from potential energy formed during contraction of muscle. This is a physical process and not a chemical one.

Once contraction and relaxation have occurred, heat of recovery is produced as a result of the chemical sequences of recovery, the main process being resynthesis of ATP. Liberation of recovery heat is, therefore, largely dependent on oxidation. As a consequence, most heat of recovery is not produced in the absence of oxygen, only 5% resulting from anaerobic metabolic processes. The amount of recovery heat generated is roughly equivalent to that of initial heat.

A detailed description of heat production and a review of previous literature has been provided by Hill (1965).

thought to occur in three steps along the cytochrome chain. ADP released during activity activates oxidative phosphorylation, which continues until ATP and phosphocreatine have been restored to their resting levels. In this manner, the levels of ATP in muscle are maintained.

HEAT

During contraction and relaxation of muscle, heat is produced. Heat liberated during the contractile process is known as initial heat (which is heat of activation and maintenance, heat of shortening and heat of relaxation). Heat of activation and maintenance is caused by chemical processes which change the muscle from a relaxed to an active state; and it is produced irrespective of whether or not muscle shortening occurs. Heat of shortening is liberated partly as a result of transformation of energy from the chemical into mechanical form (i.e. most likely by energy produced by the cross-bridges, as actin and myosin filaments slide over one another). Heat is formed in this manner only if muscle shortening takes place during contraction. Heat of relaxation is produced from potential energy formed during contraction of muscle. This is a physical process and not a chemical one.

Once contraction and relaxation have occurred, heat of recovery is produced as a result of the chemical sequences of recovery, the main process being resynthesis of ATP. Liberation of recovery heat is, therefore, largely dependent on oxidation. As a consequence, most heat of recovery is not produced in the absence of oxygen, only 5% resulting from anaerobic metabolic processes. The amount of recovery heat generated is roughly equivalent to that of initial heat.

A detailed description of heat production and a review of previous literature has been provided by Hill (1965).

MUSCLE TENSION

In the sliding filament mechanism of muscular contraction, individual sarcomeres shorten because of the force produced by the action of the cross-bridges on actin filaments, which results in interdigitation of actin and myosin filaments. The force produced in this manner is known as muscle tension.

When tension is plotted graphically as a function of sarcomere length, it is found that tension increases linearly with decreasing sarcomere length (i.e. tension increases proportionally as the number of interacting cross-bridges increase). Once maximum tension caused by the contraction process has been attained, it remains at this high level until the free ends of two actin filaments meet. As further shortening of the sarcomere occurs, the two actin filaments overlap, resulting in a decrease in tension. This overlapping of the thin filaments interferes with the formation of cross-bridges between thick and thin filaments, causing a rapid decline in tension. Tension decreases even more rapidly when shortening proceeds beyond the point at which myosin filaments crumple up against the Z line (Fig. 2).

When a fibre is stretched to such an extent that the actin and myosin filaments are unable to interdigitate at all, stimulation will not produce tension beyond the passive elastic tension of the resting state, owing to inability of myosin filaments to form cross-bridges with actin.

As a muscle contracts, the number of myosin cross-bridges that can interact with actin filaments increases linearly according to the distance of filament overlap. Thus, the tension is proportional to the amount of overlap of the two filaments. The interaction of each cross-bridge with the actin filament results in an increment in tension, so that the total tension produced by a sarcomere is proportional to the number of cross-bridges that interact with actin filaments (A.F. Huxley and Niedergerke, 1954). As regards the length/tension relation, it has been shown that muscles with longer sarcomeres (i.e. actin/myosin filaments) develop greater tensions; and as a result, the velocity of shortening is more rapid. Maximum tension is independent of the

Figure 2a. The length/tension curve for an isolated frog muscle fibre, showing the relation between filament overlap and contractile force. (From Gordon et al., 1966,

Figure 2b. Critical stages in the overlap between actin and myosin filaments, as a sarcomere shortens. The first diagram in the series is a schematic representation of filaments, giving the symbols used for relevant morphological features. (From Gordon et al., 1966)

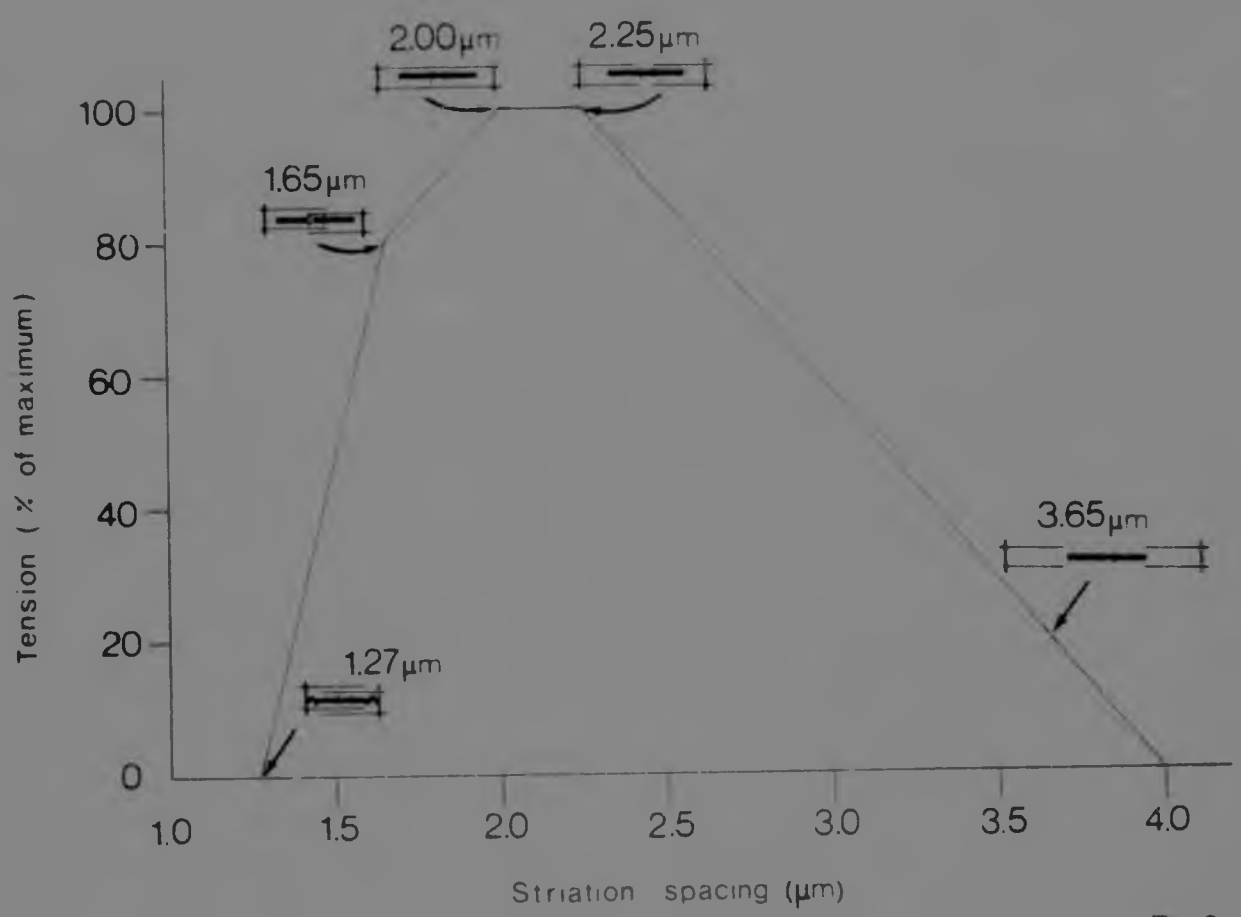


Fig. 2a

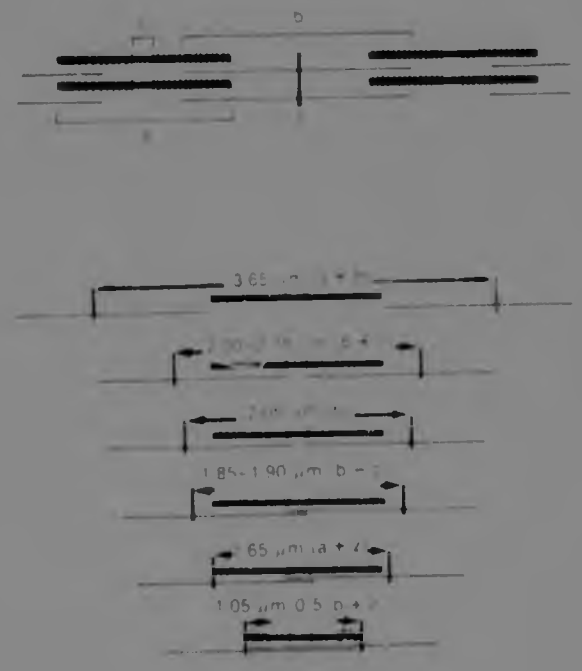


Fig. 2b

number of sarcomeres in series, but does increase proportionally with the number of myofibrils working in parallel. Consequently, a thick muscle can lift a heavier load than a thin muscle, irrespective of its length.

Muscle not only has a contractile component (the sarcomeres), but also a non-contractile, elastic component. The latter includes the sarcolemma, connective tissue and other non-contractile material parallel to the contractile elements; as well as tendons, connective tissue attaching muscle fibres to tendons, the cross-bridge links, and Z-line material, all joined in series with the myofibrils. The four last mentioned are collectively referred to as the series elastic components (SEC). When the sarcomeres contract, the SEC are stretched while tension is developed. This stretching of the SEC retards the development of tension in the muscle and accommodates for the abrupt changes in cross-bridge activity. Once the tension in the SEC equals the weight of the load to be lifted, external shortening occurs.

MECHANICAL PROPERTIES OF MUSCLE

Contraction can be expressed in two different ways: either in terms of tension or in terms of shortening. Two types of mechanical recording are used to measure activity occurring in the contractile system. When a contracting muscle is maintained at a constant length, tension is developed and this is measured by means of a strain gauge or some other form of tension recorder. Although no visible external shortening of the muscle occurs, there is a small degree of internal shortening caused by stretching of elastic components in series with the muscle fibres. This is called an isometric contraction. The duration of this type of contraction varies in different skeletal muscles. When the other method of recording activity is used, the tension remains constant, and changes in muscle length are measured as the muscle contracts against a load. This is known as an isotonic contraction.

CLASSIFICATION OF FIBRE TYPES

Almost all skeletal muscles are composed of two main types of fibre which are present in about equal numbers and distributed in a "chequer-board" pattern. These are fibres of small diameter, type 1 (slow twitch) fibres; and those with a large diameter, type 2 (fast twitch) fibres. Type 2 fibres are further sub-divided into 2A, 2B and 2C fibres. These are easily distinguishable from each other by their different histochemical reactions (described later). Slow and fast twitch fibres are often referred to as red and white fibres, respectively. This is because there is an abundance of a reddish protein, myoglobin, in red fibres and a relatively low content of myoglobin in white fibres.

The ratio of red to white fibres in a muscle determines the overall function of the muscle; that is, whether it is a slow-acting or a fast-acting muscle. Thus, muscles composed predominantly of type 1 fibres, such as those required to maintain posture, are capable of sustained contraction over prolonged periods of time. Type 2 fibres, on the other hand, are more suited to short, rapid bursts of activity and fatigue relatively quickly with continuous activity. Recent studies have revealed interesting differences in the rate of shortening, as well as in the rate of tension development in calcium-activated slow and fast twitch fibres (Stephenson and Forrester, 1980).

During sustained contraction, large amounts of energy are required. For this reason, red fibres are richly supplied with capillaries and the sarcoplasm contains large numbers of mitochondria, located along the periphery of the fibres and between myofibrils. White fibres have relatively few mitochondria and far fewer capillaries supplying them. Thus, type 1 fibres receive energy mainly from oxidative metabolism (Krebs cycle), while type 2 fibres depend mainly on the anaerobic metabolism of the glycolytic pathways for their energy, i.e. glycogen acts as an energy substrate (Brooke and Kaiser, 1970).



























HISTOCHEMICAL PROPERTIES OF FIBRE TYPES


During the past two decades, development of new histochemical techniques which demonstrate the enzyme systems at a cytological level, have provided a better understanding of pathological disorders associated with various muscular diseases. Different methods of classifying muscle fibre types have been employed but the nomenclature used in the ensuing chapters will be according to the two fibre type system described by Dubowitz and Brooke (1973), who adopted a histochemical approach to the classification of fibres.

Histochemically, type 1 fibres exhibit high activity with oxidative enzymes such as reduced nicotinamide-adenine dinucleotide-tetrazolium reductase (NADH-TR), owing to the presence of large numbers of mitochondria. These fibres show less activity when techniques to demonstrate phosphorylase are used. Type 2 fibres, on the other hand, are deficient in Krebs cycle oxidative enzymes but have a high phosphorylase content, as well as of other enzymes linked with the glycolytic cycle. This has been described by Dubowitz and Pearse (1960) as a "reciprocal relationship between phosphorylase and oxidative enzyme content". The routine, myofibrillar ATPase (pH 9.4) reaction is an alternative method often used for histochemical identification of the two fibre types (Engel, 1962, 1970). Type 1 fibres have a light appearance (weak reaction) when stained in this way, while type 2 fibres are dark in colour (strong reaction). This is the reverse reaction to that which occurs when muscle is stained with NADH-TR. The ATPase stain has an advantage in that it can also be used to identify the subgroups of type 2 fibres, by alteration of the preincubation pH's (Brooke and Kaiser, 1970). At pH 4.6 or less, type 2A fibres react weakly; at pH 4.3 or less, type 2B fibres are weakly reacting; and at both pH 4.6 and 4.3, type 2C fibres react strongly (Table 1).

The structural and histochemical differences between type 1 and type 2 fibres have been described and tabulated by Dubowitz (1968) and Dubowitz and Brooke (1973).


Table 1. Histochemical reactions of human muscle. Diagrammatic representation of the intensity of the histochemical reaction in different fibre types. (Modified from Brooke and Kaiser, 1974)

MUSCLE FIBRE TYPE	1	2A	2B	2C
Routine ATPase				
ATPase preincubated pH 4.6				
ATPase preincubated pH 4.3				
NADH-TR				
PAS	 + 			
Phosphorylase	 + 			

 = 0

 = 1+

 = 2+

 = 3+

HISTOLOGICAL STAINING METHODS

Histological stains are used to demonstrate the morphology of muscle fibres, the non-contractile components in muscle and abnormal structures. Staining methods are either progressive or regressive, or a combination of these. With progressive staining, the specimen is stained to the desired colour. With regressive methods, the tissue is first overstained and then excessive stain is removed in a substance which dissolves the dye. Differentiation is complete when a satisfactory amount of stain is left in the tissue. The three methods of staining that were routinely used in this study for biopsy specimens were haematoxylin and eosin (H & E), modified Gomori trichrome and periodic acid Schiff (PAS). The PAS stain demonstrates the presence of glycogen. The periodic acid oxidizes 1:2 glycol groups, forming dialdehydes which react with Schiff's reagent to produce a reddish-purple stain. Because the PAS stain also gives a positive reaction with other polysaccharides, neutral mucopolysaccharides, muco- and glyco-proteins, glycolipids and some unsaturated lipids and phospholipids, the specificity of its reaction for glycogen can be checked by using a control method with diastase (saliva) or α -amylase digestion. Sections stained with H & E or modified trichrome demonstrate muscle fibre relationships and variations in individual muscle fibre size. A crude approximation of the results of enzyme histochemistry for determination of fibre type can also be made in this way. With both staining methods, type 1 fibres stain more deeply than type 2 fibres.

HISTOCHEMICAL REACTIONS

Histochemical techniques are used to demonstrate specific chemical properties at various sites in muscle. The different enzyme reactions reveal a reciprocity in staining of individual fibre types and from this the selective fibre type involvement in certain diseases can be determined (Brooke and Kaiser, 1974). Other features such as various structural changes in muscle, the absence of a specific enzyme or an excess

or deficit of a certain storage product can also be revealed by histo-enzymatic methods. Most enzyme histochemical reactions show one of two patterns: the myofibrillar pattern as revealed by the routine ATPase reaction; or the intermyofibrillar network pattern as demonstrated in the oxidative enzyme reactions.

Histochemical information used in this study for the interpretation of muscle biopsy material was derived mainly from the NADH-TR, phosphorylase and ATPase reactions. When the mitochondrial NADH-TR oxidative enzyme procedure is used, tetrazolium, a soluble, relatively colourless substance under normal conditions, is reduced to form an insoluble, intensely coloured formazan compound which is deposited at the site of enzyme activity (Pearson and Mostofi, 1973). As in oxidative enzyme reactions, phosphorylase also demonstrates the intermyofibrillar network. Muscle sections are incubated in a solution containing glucose-1-phosphate, which results in glucose units being added on to pre-existing glycogen in the tissue. This reaction is dependent on the amount of phosphorylase present in the muscle. The routine ATPase reaction is carried out at pH 9.4 and is localized to the myofibrils, becoming essentially a myosin ATPase reaction. Under the influence of the enzyme ATPase, phosphate is produced from ATP, the former combining with calcium to form calcium phosphate, which is precipitated at the site of enzyme activity. Calcium is then exchanged for cobalt, resulting in the formation of black, insoluble cobaltous sulphide by the action of ammonium sulphide (Dubowitz and Brooke, 1973). During the complex series of reactions involved in this process, the intermyofibrillar network is dissolved out of the section by the action of calcium on the dry tissue (Brooke and Kaiser, 1969). When the pH of the preincubating solution used for the ATPase reaction is altered to 4.6 and 4.3, the intermyofibrillar network is well demonstrated. Similarly, if the muscle sections are preincubated in an ethylenediaminetetra-acetic acid (EDTA) solution, the myofibrillar network is preserved. This results in reversal of the ATPase staining pattern in the muscle fibres (Dreus and Engel, 1966).

ELECTRON MICROSCOPY

The electron microscope has contributed to diagnosis by revealing subcellular structures not visible under the light microscope. Electron microscopy does, however, have certain limitations. In view of the increased magnification and resolution gained with use of electron optics, as well as the time-consuming nature of preparation, only small volumes of tissue can be effectively examined. This can create sampling and interpretation restrictions. Another problem encountered is that muscle reacts to disease processes in a limited number of ways, and consequently the changes that are observed with the electron microscope are non-specific. However, when considered together with observations made with the light microscope, the additional subcellular information enlarges the perspective of structural changes, resulting in an improved ability to differentiate between and classify disease entities.

ELECTROMYOGRAPHY AND NERVE CONDUCTION VELOCITY TESTS

Electromyographic (EMG) studies demonstrate the coordination of muscles and are used to investigate and record the intrinsic electrical properties of muscle. Muscles are examined at rest, during minimal activity and during maximal contraction. The amount of activity that occurs in the contracting muscle is recorded on a cathode ray oscilloscope screen and on a continuous-strip photographic recording device. An auditory electrical response is obtained by means of a loudspeaker attachment which acts as a transducer. EMG is non-specific in so far as it only categorizes muscle into one of three groups: normal, myopathic or neuropathic; and it cannot demonstrate the type of myopathy or site of the denervating process. It may, however, reveal specific changes such as those which occur in myotonia and myasthenia gravis.

Another application of electromyography in the study of neuromuscular function is by means of nerve conduction studies. This technique

was introduced by Harvey and Masland (1941) and is used to compare nerve conduction velocities in normal and abnormal peripheral nerves. It is particularly valuable in the diagnosis of peripheral neuropathies, where the conduction velocities may be reduced to almost half the normal rate. A specialized knowledge of normal conduction values is essential, owing to the effects of numerous, variable physical factors such as age, sex, temperature, drugs, alcohol, individual variation and fluctuation in conduction velocities in different peripheral nerves. Consequently, this technique can only be effectively used and interpreted by an experienced operator.

Electromyography and nerve conduction studies are discussed in detail by Basmajian (1974) and Smorto and Basmajian (1979).

MATERIALS AND METHODS

Eighty-three patients were fully assessed by the author and muscle tension studies were carried out on samples of muscle from all of them.

Thirty patients with various neuromuscular disorders were selected from among those being treated by Dr H. Isaacs at the University of the Witwatersrand Clinical Neuromuscular Research Unit. The conditions included different forms of spinal muscular atrophy, myasthenia gravis, Charcot-Marie-Tooth disease (peroneal muscular atrophy), malignant hyperthermia and stiff man syndrome. These thirty patients were relevant to the present report and are discussed in this dissertation. The patients were from various parts of South Africa.

Owing to the similarity of the clinical patterns in muscular dystrophies, some neurogenic atrophies and certain myopathies, every case was fully considered in order to establish the exact diagnosis and so that an appropriate prognosis could be given. This entailed four lines of investigation: a detailed examination and obtaining of the neurological history (Appendix 1), serum enzyme tests, electromyographic studies and muscle biopsy, the latter followed by muscle tension studies and by histological, histochemical and electron microscopic examination.

The level in serum of the enzyme creatine phosphokinase (CPK), which leaks out of muscle during certain disease processes, such as occur in degenerative myopathies, was used for the purpose of providing preliminary diagnostic information. The tests were conducted by various private laboratories in Johannesburg. EMG and nerve conduction studies were carried out and evaluated by Dr Isaacs at the Neuromuscular Research Laboratory, one week prior to biopsy. Concentric bipolar needle electrodes were used and the results recorded on a Disa 3-channel Electromyograph.

BIOPSY PROCEDURE

All muscle biopsies were carried out by Dr Isaacs at the Princess Nursing Home in Johannesburg. Patients were instructed to discontinue

any medication for a period of one week prior to biopsy.

The site for biopsy was chosen according to the severity of disease in the limbs. Muscle that was moderately affected was selected, since it is difficult to determine the nature of the pathological process in muscle with advanced disease or with minimal involvement. Areas where intramuscular injections had been given or EMG studies had been done were avoided, in view of the fact that a focal myopathy with inflammatory characteristics is normally caused by these intrusions.

Local anaesthesia was used in most cases although in a few instances involving children, general anaesthesia was necessary. The skin and subcutaneous tissue in the vicinity of the biopsy site was infiltrated with 1% lignocaine (without adrenaline). A longitudinal incision of approximately 4.5 cm was made in the skin overlying the muscle. The skin was retracted and the fascia incised to expose the muscle belly. A cylinder of muscle measuring about 2.5 cm in length by 0.75 cm in width was removed by placing a suture at either end and then isolating the strip of muscle by sharp dissection with a scalpel, followed by detachment underneath, using either scalpel or scissors. Immediately after removal, the specimen was stretched on a wooden tongue depressor by securing the sutures over the split ends of the spatula. A gauze swab wetted with saline was wrapped around the sample to keep it moist in preparation for enzyme histochemical tests. Another strip of muscle of similar size for muscle tension studies was then removed in the manner described above. This was placed directly into a bottle containing Krebs solution. A third specimen, measuring approximately 2.5 cm by 0.25 cm, was removed using an isometric clamp. The muscle was kept in the clamp for 90 seconds after removal to prevent it from contracting, after which it was taken out of the clamp and fixed at room temperature in 5% glutaraldehyde in phosphate buffer (pH 7.2), for electron microscopy. Following muscle biopsy, the fascial layers were sutured with absorbable material to prevent muscle herniation and the skin reapproximated using interrupted sutures. The stitches were removed seven days following biopsy.

HISTOLOGY AND HISTOCHEMISTRY

Preparation of specimens

The stretched muscle specimen was removed from the spatula as soon after biopsy as possible and cut into small pieces (about 2 mm by 6 mm in size). Muscle that had been damaged by forceps or sutures was discarded. The trimmed pieces of muscle were orientated accordingly for the cutting of transverse and longitudinal sections and mounted in 10% tragacanth gum, directly on to a microtome chuck. A beaker containing isopentane was cooled to about -160°C by immersing it in a Dewar flask of liquid nitrogen. The chucks with the embedded specimens were then immersed in the isopentane for a few seconds until frozen and placed in a cryostat at a temperature of -15°C to -25°C until sectioning was carried out.

Cryostat sectioning

Serial sections were cut at $10\ \mu\text{m}$ in a cryostat. Sections were picked up on glass microscope slides for purposes of histology, and on coverslips for histochemical staining. Ten slides were made, eight having transverse sections of muscle and two with longitudinal sections. All those used for histochemical tests were cross sections.

Staining techniques

The frozen muscle sections on coverslips and slides were stained according to standard procedures but with slight modifications. Details are, therefore, given below. All routine biopsy tissue was dealt with by Miss M. Badenhorst. Other (experimental) biopsy material was used by the author.

Haematoxylin and Eosin

(3 slides - 2 with transverse sections; 1 with longitudinal sections)

Haematoxylin (modified Mayer's)

50 g ammonium or potassium alum
2 g haematoxylin
50 g chloral hydrate

1 g citric acid
0.4 g sodium iodate
1000 ml distilled water

Dissolve each in the distilled water in the above sequence.

*Eosin/Erythrosin stock

8 g eosin
2 g erythrosin
1000 ml distilled water

Working solution

20 g calcium chloride
250 ml stock solution*
750 ml distilled water

- a. Stain with modified Mayer's haematoxylin for 5 min.
- b. Wash in tap water.
- c. Flood slide with 1% eosin for 3 min.
- d. Rinse in tap water.
- e. Dehydrate rapidly in ascending alcohols.
- f. Clear in xylene and mount in DPX.

Modified Gomori trichrome

(3 slides - 2 with transverse sections; 1 with longitudinal sections)

Modified Gomori trichrome

3 g chromotrope 2R
1.5 g fast green
3 g phosphotungstic acid
5 ml glacial acetic acid
500 ml distilled water

Adjust to pH 3.4 with 1N NaOH.

- a. Fix in 5% acetic ethanol (pH 3.4) for 10 min.
- b. Wash in distilled water.
- c. Stain with haematoxylin for 3 min.
- d. Rinse three times in distilled water.
- e. Stain with modified gomori's trichrome for 20 min.
- f. Rinse twice in 0.2% acetic acid for 5 min.
- g. Dehydrate through alcohols to xylene and mount in DPX.

Periodic Acid Schiff (PAS) technique for glycogen

(4 slides - 4 with transverse sections)

Schiff's reagent

10 g basic fuchsin
 19 g sodium metabisulphite
 15 ml hydrochloric acid
 1000 ml distilled water

Shake intermittently for 2 - 3 h. Add approximately 5 g activated charcoal. Shake well and filter. Solution must be clear. If solution is yellow, add more charcoal; if pink, add a few drops concentrated hydrochloric acid.

- a. Fix in 5% acetic ethanol for 10 min.
- b. Wash in distilled water.
- c. Incubate two slides with saliva for 10 min at 37°C (control slides).
- d. Place all slides in 0.5% periodic acid (aqueous) for 5 min.
- e. Rinse in distilled water.
- f. Stain in Schiff's reagent for 20 min.
- g. Rinse in distilled water.
- h. Stain with haematoxylin for 3 - 4 min.
- i. Wash well in tap water.
- j. Dehydrate in ascending alcohols to xylene and mount in DPX.

NADH-tetrazolium reductase

(2 coverslips with transverse sections)

NAD stock solution

1 g polyvinylpyrrolidon (PVP)
 2.5 ml MTT (3-(4,5-dimethyl-thiazolyl-2)-2,5-diphenyl tetrazolium
 bromide)
 2.5 ml tris buffer (pH 8 - 12.5 ml tris, 15 ml 1N hydrochloric acid
 and 30 ml distilled water)
 0.3 ml 0.5M cobaltous chloride
 4.7 ml distilled water

Adjust to pH 7.0 with tris buffer pH 12.
 Store in freezer.

Incubating solution

1 ml NAD stock solution
 6 mg NADH

- a. Place 0.1 - 0.2 ml incubating solution on coverslips in a petri dish.
- b. Incubate for 1½ h at 37°C.
- c. Fix in 10% formal calcium for 5 - 30 min.
- d. Rinse in distilled water.
- e. Mount in glycerine jelly.
- f. Seal sides of coverslips with clear nail varnish.

Phosphorylase

(2 coverslips with transverse sections)

Stock solution

50 mg glucose-1-phosphate
10 mg adenosine-5-phosphate
2 mg glycogen
10 ml veronal buffer* (pH 5.6 - 6.0)
15 ml distilled water
1 drop insulin (20 units/ml)

*Veronal buffer

5 ml veronal acetate
8 ml 0.1N hydrochloric acid
12 ml distilled water
Adjust to pH 5.6 - 6.0.

Incubating solution

8 ml stock solution
2 ml ethanol

Formal chloral hydrate

0.5 g chloral hydrate
50 ml formaldehyde
450 ml distilled water

- a. Incubate sections for 1½ h at 37°C in incubating solution.
- b. Rinse in 40% alcohol.
- c. Rinse in distilled water.
- d. Dry for a few minutes in oven at 37°C.
- e. Fix in ethanol for 3 min.
- f. Stain in dilute Gram's iodine (diluted 1 ml in 10 ml) for 3 min.
- g. Fix in formal chloral hydrate for 30 s.
- h. Blot and leave to dry.
- i. Clear in xylene and mount in DPX.

Adenosine triphosphatase

(8 coverslips with transverse sections)

Dry all coverslips for 3 h or overnight in Columbia jars to prevent precipitate forming.

2 coverslips for each of the following:

i) pH 9.4

Incubating solution

3.8 mg adenosine-5-triphosphate (no salt)
 2.5 ml 0.18M calcium chloride (1.998 g/100 ml)
 5.0 ml 0.1M sodium barbiturate (2.062 g/100 ml)
 0.75 ml distilled water

Adjust to pH 9.4 with 0.1N NaOH.

- a. Preincubate at room temperature in 0.18M calcium chloride for 15 min.
- b. Rinse in distilled water.
- c. Incubate sections in incubating solution for 45 min at 37°C.
- d. Wash well in distilled water.
- e. Place in 2% cobalt chloride for 3 min.
- f. Wash in several changes of distilled water for 3 min.
- g. Place in dilute solution ammonium sulphide (4 drops/10 ml H₂O) for 30 s.
- h. Rinse under running tap for 5 min.
- i. Dehydrate through alcohols to xylene and mount in DPX.

ii) pH 4.6 and pH 4.3

Incubating medium (ATP)

20 mg ATP sodium salt
 2 ml 0.1M sodium barbiturate
 1 ml 0.18M calcium chloride
 7 ml distilled water

Adjust to pH 9.4 with 0.1N NaOH.

- a. Preincubate at room temperature in veronal buffer at pH 4.6 and pH 4.3 for 15 min.
- b. Incubate in ATP medium for 45 min at 37°C.
- c. Treat with 1% calcium chloride for 10 min.
- d. Stain with 2% cobalt chloride for 3 min.
- e. Rinse 4 - 8 times in 0.01M sodium barbiturate.
- f. Rinse three times with distilled water.

- g. Develop in dilute ammonium sulphide for 30 s.
- h. Wash well in tap water.
- i. Dehydrate through alcohols to xylene and mount in DPX.

iii) ATP/EDTA (reversal pattern of ATP pH 9.4)

ATP incubating solution

15 mg ATP sodium salt
1 ml 0.18M calcium chloride (1.998 g/100 ml)
2 ml 0.1M sodium barbiturate (2.062 g/100 ml)
7 ml distilled water

Adjust to pH 9.4 with 0.1N NaOH.

Preincubation solution

0.0584 g EDTA
20 ml distilled water

Adjust to pH 4.35 with acetic acid.

- a. Preincubate at room temperature in EDTA solution for 15 min.
- b. Wash in ATP incubating solution (without ATP added) for 3 min.
- c. Incubate in ATP medium at 37°C for 30 min.
- d. Rinse in 2% calcium chloride for 3 min.
- e. Rinse in distilled water.
- f. Place in 2% cobalt chloride for 3 min.
- g. Rinse three times in distilled water for 3 min.
- h. Develop in dilute ammonium sulphide for 30 s.
- i. Wash under running tap.
- j. Dehydrate in ascending alcohols, clear in xylene and mount in DPX.

ELECTRON MICROSCOPY

Techniques of fixation and tissue preparation

After removal of tissue from the patient, the muscle was placed directly into 5% glutaraldehyde in phosphate buffer and left for 1 h at room temperature. 0.1M phosphate buffer (pH 7.2) is made by combining

the following:

14 ml 0.1M sodium dihydrogen phosphate (NaH_2PO_4);
 36 ml 0.1M disodium hydrogen phosphate (Na_2HPO_4);
 50 ml distilled water.

1. Cut specimen into small pieces (not larger than 1 x 1 x 1 mm) and fix for further 2 h in 5% glutaraldehyde in phosphate buffer.
2. Wash in phosphate buffer three times for 5 min each time.
3. Post-fix in 1% osmium tetroxide in phosphate buffer for 2 h.
4. Wash in buffer three times for 10 min each time.
5. Dehydrate in ascending alcohols of 50%, 70%, 80% and 90% for 15 min in each and finally in 100% alcohol for 15 min repeated twice.
6. Clear in propylene oxide for 30 min.
7. Infiltrate with propylene oxide/resin (1:1) for 1 h.
8. Infiltrate with resin overnight.

Resin: 15 ml araldite M
 25 ml Epon 812
 55 ml DDSA
 3 ml dibutyl phthalate

9. Transfer to fresh resin with DMP 30 added and leave for 24 h at room temperature, followed by embedding and a further 48 h at 60°C.
 (DMP 30 is added to resin just before use - 1 drop DMP 30 per 1 ml resin, plus 1 drop DMP 30 for each 5 ml resin)
10. Sections are cut on glass knives and placed on 300 mesh copper grids.
11. Stain specimens for 3 min \pm in saturated aqueous uranyl acetate.
12. Rinse in 50% methanol.
13. Allow to dry.
14. Stain with lead citrate for 2 min.

Lead citrate: 0.25 g lead citrate
 0.5 ml concentrated sodium hydroxide
 25 ml filtered distilled water
 Spin for 10 min at 3000 r.p.m.

15. Rinse for 10 s in dilute sodium hydroxide solution.
16. Rinse three times for 10 s each time in distilled water.

MUSCLE TENSION STUDIES

Construction of apparatus

The apparatus used for muscle tension studies (Fig. 3) was designed by Dr H. Isaacs and Mr J.J.A. Heffron of the Neuromuscular Research Unit, University of the Witwatersrand, Johannesburg. It consisted of a large metal bath filled with water which was circulated constantly and maintained at a temperature of 37°C by a Haake E32 heating apparatus. A small plastic bath, clamped in position, contained an oxygen disperser connected to a Fluotec distributor and an oxygen cylinder. An outlet pipe provided a rapid and easy method of emptying the contents of the plastic bath. A stainless steel mobile lever, to which one end of the piece of muscle was attached, was fixed to a force transducer. The signal from the force transducer was amplified and displayed by a Riken Denshi recorder on a continuous strip chart, thus measuring the isotonic contraction of the muscle fibres. The speed at which the graph paper moved on which muscle tension was recorded, was 20 millimetres per minute. Muscle twitches were produced by electrical stimulation of the muscle via platinum electrodes which were connected to a Multitone ten pulse stimulator. The frequency of stimulation of muscle was once every 2.5 seconds. The duration of the impulse was 3 milliseconds and the output 100 volts.

Experimental procedure

Preparation

Fresh Krebs solution (5000 ml at pH 7.4) was made up prior to biopsy. This contained the following: 118 mM NaCl, 3.4 mM KCl, 0.8 mM MgSO₄, 1.2 mM KH₂PO₄, 11.1 mM glucose, 25.0 mM NaHCO₃, and 2.5 mM CaCl₂·6H₂O. The solution was heated to 37°C and maintained at this temperature for the duration of the tests. Various concentrations of caffeine were weighed out in preparation for tests on the muscle.

The strip of muscle, measuring approximately 3 cm by 0.75 cm, was placed in 10 ml Krebs solution (at room temperature) immediately after

biopsy and taken directly to the laboratory. Small strips about 2.5 cm long and 0.3 cm wide were prepared. After weighing, 0.5 grade copper wire was tied to one end of the piece of muscle to be studied. The opposite end of the preparation was attached directly to a fixed, steel hook, after which the wire on the other end was hooked on to the mobile, stainless steel lever. The mounted muscle was then immersed in the plastic bath, which had been filled with 500 ml Krebs solution (at 37°C). This was perfused continuously with oxygen containing 5% carbon dioxide ("carbogen").

The mounted specimen was ready for the first test within twenty-one minutes of being removed from the patient.

Method

The muscle was weighted sufficiently to obtain maximum contraction. The resting base-line tension was established and then adjusted to 2 grammes. Stimulation of the muscle was started, and once a steady base line had been obtained, 0.5 mM caffeine was added to the contents of the plastic bath. Successive doses of caffeine (1.0, 2.0, 4.0, 8.0, 16.0 and 32.0 mM) were added as soon as the maximal contraction plateau induced by the previous dose of caffeine had been reached.

The Krebs solution was then replaced by 500 ml fresh solution. 4% halothane, vapourized in the Fluotec vapourizer, was administered together with the 5% carbon dioxide/oxygen gas mixture. If the muscle reacted in such a way that the possibility of malignant hyperthermia in the patient concerned was indicated, the administration of halothane was discontinued and 2 ml sodium dantrolene was added to the solution by syringe. Stimulation was continued until the muscle had fully recovered.

Finally, succinylcholine was added to fresh Krebs solution when muscle from a patient with suspected malignant hyperthermia was being tested.

The muscle was in many cases stimulated continuously, until it had gone into rigor.

Data recorded

The muscle was weighed to ensure that specimens of similar size were used for each muscle tension experiment.

The amount of caffeine (in mM) added to the muscle bathing solution and the corresponding increase in resting tension (in g), were recorded. The amplitude of increase in muscle tension (muscle contraction) was measured from the initial resting base line to the plateau, i.e. when no further increase in tension occurred following the addition of a particular amount of caffeine.

The time (in min) taken for 4% halothane to raise the resting tension was noted, together with the corresponding increase in muscle tension.

Original tracings obtained from muscle tension studies have not been included in this dissertation, since these are the personal property of Dr H. Isaacs and may be required for other research. Furthermore, many tracings were far too long to be photographed. Examples of normal and abnormal tracings have, however, been included (Appendix 4).

Figure 3. Apparatus used for muscle tension studies.




Figure 3a. General view of apparatus.

(Key: B - plastic bath containing Krebs solution, in which muscle specimen was immersed; F - Flutec distributor; H - Haake E32 heating apparatus; R - Riken Denshi recorder; S - Multitone ten pulse stimulator)




Figure 3b. Plastic bath containing Krebs solution, in which muscle specimen was immersed.

(Key: Arrows indicate where the respective ends of the muscle specimen were attached; E - platinum electrodes for stimulating muscle; T - transducer)

RESULTS

Table 2. Summaries of biopsy findings and clinical assessments of patients.*

(Key: Name of muscle in parenthesis in first column indicates biopsy site; Δ - diagnosis; CPK - creatine phosphokinase; EM - electron microscopy; EMG - electromyography; EPL - end plates; MG - myasthenia gravis; MH - malignant hyperthermia; MJS - myoneural junctional studies; MNT - motor nerve terminals; M.Str. - muscle strength; NCS - nerve conduction studies; PMA - peroneal muscular atrophy; SMA - spinal muscular atrophy; *S - stiff man syndrome)

*FOR MORE DETAILED ASSESSMENTS OF PATIENTS, SEE APPENDIX 2.

TABLE 3. Reaction of muscle to caffeine (figures denote tension in grammes)

Patient	Condition	Caffeine concentration						
		0.5mM	1mM	2mM	4mM	8mM	16mM	32mM
†Case 1 (K.R.)	*SMA	0.02	0.03	0.04	0.62	2.40	4.70+	-
†Case 2 (K.V.)	"	0.23	0.62	1.06	1.30	2.06	-	-
Case 3 (C.R.)	"	10.00+	-	-	-	-	-	-
†Case 4 (S.B.)	"	0.00	0.00	0.00	0.00	0.00	0.00	5.00+
Case 5 (P.E.)	"	1.05	3.63	7.13+	-	-	-	-
†Case 6 (F.C.)	"	0.20	0.44	6.00+	-	-	-	-
Case 7 (J-M.K.)	"	no caffeine test						
Case 8 (C.P.)	"	no caffeine test						
Case 9 (D.K.)	*LMT	0.00	0.69	1.56	4.17	6.32	-	-
†Case 10 (R.D.)	"	0.40	0.87	1.34	3.35+	-	-	-
†Case 11 (A.L.)	"	muscle no longer viable						
†Case 12 (P.D.)	"	0.06	0.12	1.08	1.86	2.26	-	-
†Case 13 (I.daR.)	"	0.45	0.93	1.96	-	-	-	-

TABLE 3 (continued)

Patient	Condition	Caffeine concentration							
		0.5mM	1mM	2mM	4mM	8mM	16mM	32mM	
†Case 14 (M.R.)	*CMT	0.03	0.85	2.86	4.52	5.90	-	-	
†Case 15 (R.S.)	"	0.50	0.85	1.11	7.70+	-	-	-	
Case 16 (A.V.)	"	0.29	0.93	1.12	-	-	-	-	
Case 17 (D.A.)	*MG	0.02	0.04	6.95	8.85	-	-	-	
Case 18 (J.B.)	"	0.26	0.55	0.56	0.79	0.92	1.33	1.86	
†Case 19 (J.T.)	"	0.58	1.43	1.56	3.26	5.16+	-	-	
Case 20 (M.M.)	"	0.62	1.36	1.57	2.50	4.44	5.58+	-	
†Case 21 (J.G.)	"	0.00	0.00	0.20	0.98	2.08	6.93+	-	
†Case 22 (A.S.)	"	0.16	0.22	0.37	1.16	3.64+	-	-	
Case 23 (D.F.)	"	0.01	0.02	0.03	0.04	0.06	0.08	0.10	
†Case 24 (L.M.)	"	-	-	5.38	-	-	-	-	
Case 25 (A.V.)	"	0.00	0.00	0.00	0.00	0.48	0.99	1.24	
Case 26 (P.G.)	"	0.27	1.15	1.56	3.40	7.35+	-	-	

TABLE 3 (continued)

Patient	Condition	Caffeine concentration						
		0.5mM	1mM	2mM	4mM	8mM	16mM	32mM
Case 27 (Z.M.)	*SMS	0.00	0.00	0.02	0.32	1.78	2.32	3.70
Case 28 (A.K.)	*MH	no caffeine test						
†Case 29 (O.M.)	"	0.87	2.03	7.80+	-	-	-	-
Case 30 (C.P.)	"	no caffeine test						
†Control 1	Normal	0.00	0.00	0.00	0.00	0.85	3.20	7.20+
†Control 2	"	0.00	0.00	0.00	0.64	1.30	3.27+	-
†Control 3	"	0.00	0.00	0.00	0.00	0.73	4.46	-
†Control 4	"	0.00	0.00	0.00	0.00	0.52	2.16+	-
†Control 5	"	0.00	0.00	0.00	0.00	0.00	4.53	7.53
†Control 6	"	0.00	0.00	0.00	0.08	0.38	1.65	4.72+
†Control 7	"	0.00	0.00	0.00	0.28	1.59	4.40+	-
†Control 8	"	0.00	0.00	0.00	0.05	0.20	0.51	4.50+
†Control 9	"	0.00	0.00	0.00	0.00	0.15	6.90+	-

TABLE 3 (continued)

Patient	Condition	Caffeine concentration						
		0.5mM	1mM	2mM	4mM	8mM	16mM	32mM
†Control 10	Normal	0.00	0.00	0.00	0.25	0.60	1.45	13.75+
†Control 11	"	0.00	0.00	0.00	0.00	0.16	0.69	1.55
†Control 12	"	0.00	0.00	0.00	0.00	0.64	1.90	-
†Control 13	"	0.00	0.00	0.00	0.80	2.38	-	-
†Control 14	"	0.00	0.00	0.00	0.00	1.22	5.70+	-
†Control 15	"	0.00	0.00	0.00	0.00	0.78	2.16	2.92+

† Dagger indicates that the halothane test was carried out before the caffeine test (reverse order in all other cases).

* SMA - spinal muscular atrophy; CMT - Charcot-Marie-Tooth disease; MG - myasthenia gravis; SMS - stiff man syndrome; MH - malignant hyperthermia.

*Figure 4. Caffeine-induced contraction of muscle isolated from patients with various neuromuscular diseases and from controls.

(The abscissa indicates the concentration of caffeine in the tissue bath, while the ordinate denotes the maximal increase of isotonic contraction produced by addition of the corresponding amount of caffeine)

*THE GRAPH LINES HAVE BEEN DRAWN ON TWO PAGES SO AS TO REDUCE SUPERIMPOSITION OF DATA.

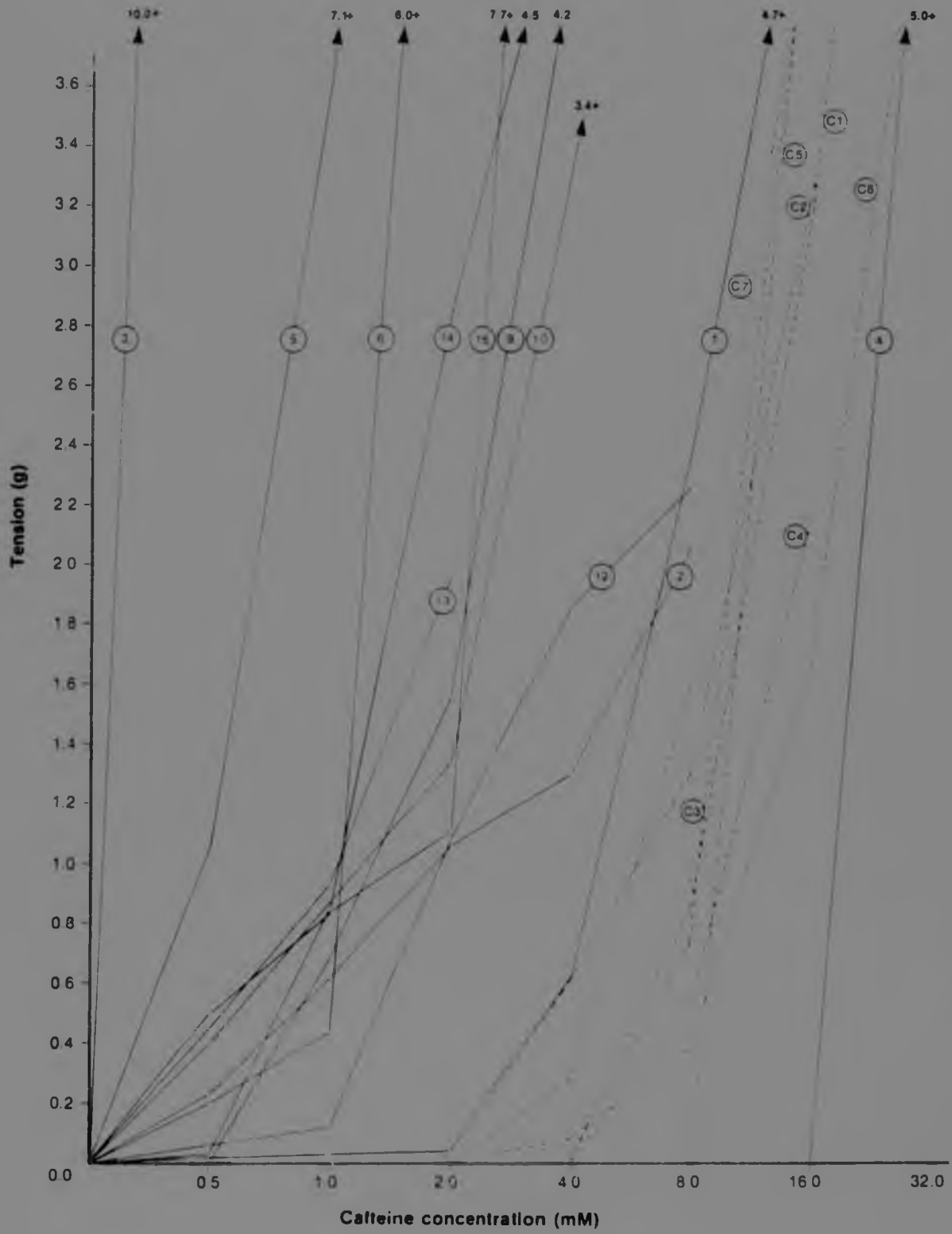


Fig. 4a

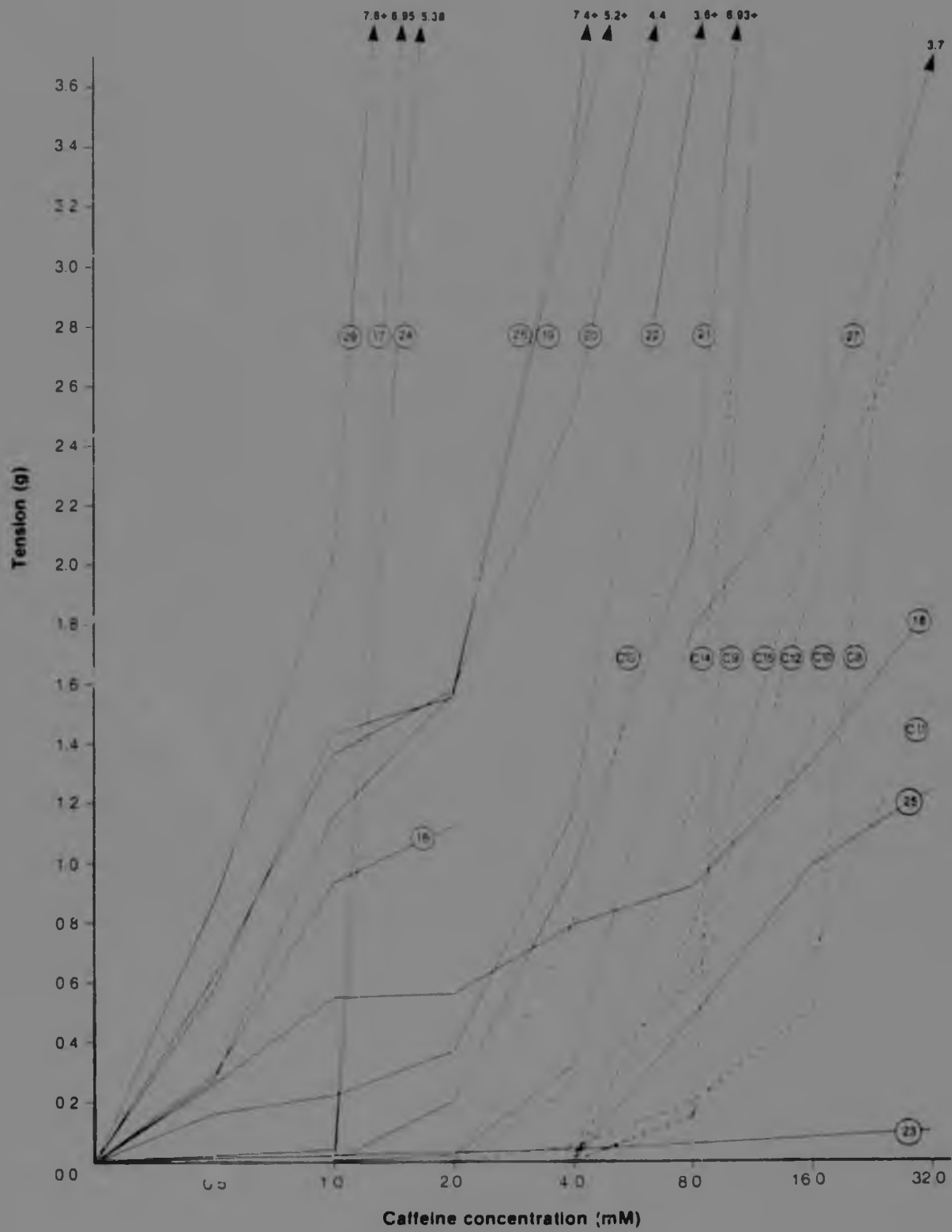


Fig. 4b

TABLE 4. Increase in tension of muscle following administration of 4% halothane (figures denote tension in grammes)

Patient	Condition	Time elapsed in minutes												
		0.5	1.0	1.5	2.0	2.5	3.0	3.5	4.0	4.5	5.0	5.5	6.0	
Case 1 (K.R.)	*SMA	0.16	0.39	0.61	0.79	0.93	1.09	1.26	1.42	1.55	-	-	-	-
Case 2 (K.V.)	"	negative response (relaxation occurred)												
†Case 3 (C.R.)	"	no response												
Case 4 (S.B.)	"	no response												
†Case 5 (P.E.)	"	no response												
Case 6 (F.C.)	"	no response												
Case 7 (J-M.K.)	"	negative response (relaxation occurred)												
Case 8 (C.P.)	"	0.06	0.07	0.09	0.10	0.10	0.10	0.10	0.10	0.10	0.09	0.07	0.06	
†Case 9 (D.K.)	*CMT	negative response (relaxation occurred)												
Case 10 (R.D.)	"	negative response (relaxation occurred)												
Case 11 (A.L.)	"	no response												
Case 12 (P.D.)	"	negative response (relaxation occurred)												
Case 13 (I.daR.)	"	no response												

TABLE 4 (continued)

Patient	Condition	Time elapsed in minutes																
		0.5	1.0	1.5	2.0	2.5	3.0	3.5	4.0	4.5	5.0	5.5	6.0					
Case 14 (M.R.)	*CMT	negative response																
Case 15 (R.S.)	"	no response																
†Case 16 (A.V.)	"	0.03	0.08	0.13	0.21	0.28	0.40	0.43	0.51	0.59	0.66	0.66	0.66	0.69				
†Case 17 (D.A.)	*MG	0.10	0.10	0.10	0.22	0.30	0.35	0.39	0.31	0.25	-	-	-	-				
†Case 18 (J.B.)	"	0.00	0.17	0.20	0.31	0.21	-	-	-	-	-	-	-	-				
Case 19 (J.T.)	"	no response																
†Case 20 (M.M.)	"	0.10	0.81	1.25	1.06	0.70	0.19	-	-	-	-	-	-	-				
Case 21 (J.G.)	"	0.00	0.10	0.63	1.11	1.30	0.98	0.50	0.17	0.03	0.00	-	-	-				
Case 22 (A.S.)	"	no response																
†Case 23 (D.F.)	"	no response																
Case 24 (L.M.)	"	no response																
†Case 25 (A.V.)	"	0.25	0.30	1.02	1.73	2.32	2.50	2.46	2.41	2.13	2.04	1.99	1.99	1.90				
†Case 26 (P.G.)	"	0.49	0.70	0.79	1.12	1.53	1.65	1.89	1.70	1.84	2.00	1.96	1.96	1.90				

TABLE 4 (continued)

Patient	Condition	Time elapsed in minutes												
		0.5	1.0	1.5	2.0	2.5	3.0	3.5	4.0	4.5	5.0	5.5	6.0	
†Case 27 (Z.M.)	*SMS	0.71	1.76	2.43	2.71	3.14	3.28	3.43	3.46	3.43	3.36	3.29	-	
Case 28 (A.K.)	*MH	no response												
Case 29 (G.M.)	"	0.00	0.34	0.73	0.52	0.35	0.17	0.14	0.12	0.09	-	-	-	
Case 30 (C.P.)	"	no response												
Controls 1 to 15	Normal	negative response (relaxation occurred) or there was no response												

† Dagger indicates that the caffeine test was carried out before the halothane test (reverse order in all other cases).

* SMA - spinal muscular atrophy; CMT - Charcot-Marie-Tooth disease; MG - myasthenia gravis; SMS - stiff man syndrome; MH - malignant hyperthermia.

Figure 5. Halothane-induced contraction of muscle isolated from patients with various neuromuscular diseases and from controls.

The abscissa indicates the time elapsed in minutes, while the ordinate denotes the maximal increase of isotonic contraction produced by addition of 4% halothane)




TABLE 5. Increase in tension of muscle following administration of 2 ml succinylcholine (figures denote tension in grammes)

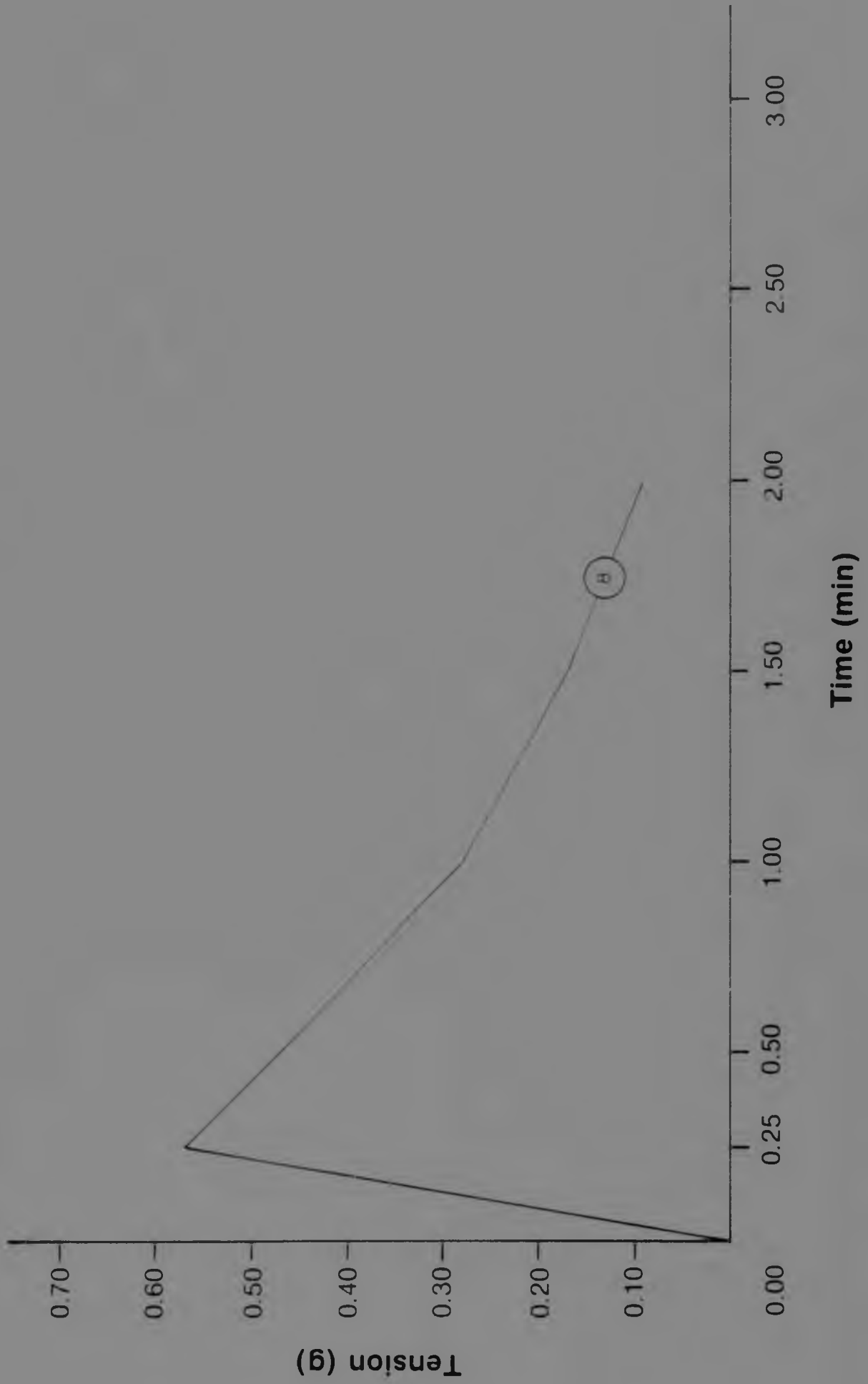
Patient	Condition	Time elapsed in minutes						
		0.25	0.50	1.00	1.50	2.00	2.50	3.00
Case 7 (J-M.K.)	*SMA	Negative response (relaxation occurred)						
**Case 8 (C.P.)	"	0.57	0.47	0.28	0.17	0.09	-	-
Case 28 (A.K.)	*MH	Negative response (relaxation occurred)						
Case 29 (O.M.)	"	Negative response (relaxation occurred)						
Case 30 (C.P.)	"	No response						

* SMA - spinal muscular atrophy; MH - malignant hyperthermia.

** In addition, the reaction to 2 ml methohexital was determined; the corresponding figures being: 0.88, 0.67, 0.38, 0.24, 0.16, 0.11, 0.08 and 0.07.

Figure 6. Succinylcholine-induced contraction of muscle isolated from patients with various neuromuscular diseases and from controls.

(The abscissa indicates the time elapsed in minutes, while the ordinate denotes the maximal increase of isotonic contraction produced by addition of 2 ml succinylcholine)



DISCUSSION

DIAGNOSTIC ASPECTS

Muscle tension studies

The methods adopted initially for muscle tension experiments in this study and based on techniques employed by Kalow *et al.* (1970), were found to be too crude. The apparatus and procedure were, therefore, modified. The changes involved alteration of the manner in which the muscle specimen was attached to the apparatus (see "Materials and methods"), as well as improvement in the method of stimulation by insertion of the electrodes directly into the muscle fibres (as opposed to stimulation from outside the muscle). As a result, a far more sensitive reaction was obtained, from which a more accurate and scientific analysis could be made. The tests were conducted in the internationally accepted sequence recommended in 1977 by H. Isaacs, F.R. Ellis, W. Kalow, B.A. Britt and M.A. Denborough at the second international symposium on malignant hyperthermia, held in Denver, Colorado, U.S.A.

As was mentioned previously in the section "Materials and methods", the muscle specimen used for the purpose of tension studies was immersed in Krebs solution (maintained at 37°C) for the entire duration of the tests. A solution similar to Krebs, but having a higher concentration of calcium, was inadvertently used in preliminary experiments not documented in this report. It was interesting to note that this resulted in the muscle losing its viability far more quickly than when the correct Krebs solution was used. The cause could perhaps be attributed to muscle sarcoplasm becoming so saturated with calcium from the bathing Krebs solution that the SR was not able to re-accumulate all the calcium in the sarcoplasm following contraction of the muscle fibres; and/or release of calcium from the SR may have been diminished by the increased concentration of sarcoplasmic calcium. Consequently the fibres would remain in a partially contracted state and normal relaxation would not take place. Subsequent contractions would have decreased amplitude, resulting in the muscle fibres losing, far more quickly, their ability to contract. This experience demonstrated the importance of having various substances present in quantities and combinations that will ensure that an as near normal environment as possible obtains

to that of the muscle in situ.

Another factor which became evident during preliminary studies was that muscle rigor occurred approximately two hours following removal of a muscle specimen from a patient. Thus, biopsy specimens could not be transported long distances for testing, since the muscle would not have remained viable for long enough.

Cases 29 and 30 in the present study, patients suspected of being carriers of MH, showed that it is unlikely that muscle tension studies can be used as an infallible predictive method of testing for MH carriers. Muscle in case 29 reacted only slightly to the administration of 4% halothane. This occurred within the first 1.5 minutes of testing, following which muscle tension slowly returned to normal (Table 4; Fig. 5). Case 30, on the other hand, showed no positive reaction to halothane. There were high CPK levels in both cases 29 and 30, alterations in muscle structure at the electron microscopic level and family histories of previous anaesthetic deaths (Table 2; Appendix 2).

Varying positivity in reactions to halothane was also observed in several other patients (cases 1, 8, 16, 17, 18, 20, 21, 25, 26 and 27), who were not suspected of being carriers of MH (Table 4; Fig. 5). In all except numbers 1, 8 and 21 of the ten aforementioned cases, the caffeine test was carried out first, followed by a change of Krebs solution and then the halothane test. Following detection of many positive reactions to halothane, it was thought that despite the change of Krebs solution, caffeine appeared to potentiate a halothane contraction*. As a result of these observations, the sequence of all subsequent tests was reversed, so that the halothane test was carried out before the caffeine test. Consequently, the positive reactions to halothane obtained in cases 1 and 21, who were believed not to be carriers of MH, could not be accounted for (Table 4; Fig. 5). No caffeine test was carried out in case 8, but the positive reaction of muscle obtained from this

*Calculations from results in this dissertation showed that ~16% of cases reacted positively to halothane when the halothane test was carried out prior to the caffeine test, while ~64% of cases reacted positively to the administration of halothane when the caffeine test was carried out before the halothane test. These results indicated that caffeine did, in fact, appear to potentiate a halothane contraction.

patient to the administration of 4% halothane, together with positive results in other tests, led to this patient being considered a possible carrier of MH (Table 4; Fig. 5). From the abovementioned results concerning the reaction of muscle to halothane, it became evident that it is possible to obtain both false positive results (in some neuromuscular disorders) and false negative results (in known carriers of MH - Bradley *et al.* (1973) and the present study). These findings support the statement made by Isaacs (1977) that: "There is at the present time no infallible predictive test to identify the carrier-state of MH" and that "... the occasional case will defy identification".

Perhaps the negative response to halothane obtained *in vitro* for known carriers of MH could be compared to the *in vivo* reactions observed by Aldrette in 1977 (Dr H. Isaacs, personal communication). This worker found that a MH carrier may react adversely to halothane administration on one occasion and show no reaction to halothane on a subsequent occasion(s), or *vice versa*. This was also demonstrated by Mogensen *et al.* (1974). Emotional stress has been thought to contribute to predisposition to MH *in vivo* (Mogensen *et al.*, 1974; Wingard and Gatz, 1977), thus accounting for the variable reaction to halothane anaesthesia seen in the same individual (Mogensen *et al.*, 1974). A possible explanation for the negative *in vitro* response may be that, owing to the absence of neural influences from higher centres *in vitro*, environmental factors such as emotional stress are eliminated.

Case 28, a known carrier of MH from previous biopsy results (Dr H. Isaacs, personal communication; initial tracing not available), was given 8 mg/kg of sodium dantrolene orally, four hours prior to the second biopsy. On exposure of the muscle specimen to 4% halothane, no reaction was obtained (Table 4). However, when 6% halothane was administered a gradual increase in muscle tension to 1.53 grammes occurred during the first 3 minutes, following which tension decreased to its original resting level within a further 4 minutes. When 6% halothane and 2.5 ml succinylcholine were subsequently added simultaneously, tension increased only slightly, and then returned to normal within 5 minutes. The use of orally administered sodium dantrolene to prevent the development of MH in susceptible swine, has been discussed by various authors (Anderson and Jones, 1976; Gronert *et al.*, 1976;

patient to the administration of 4% halothane, together with positive results in other tests, led to this patient being considered a possible carrier of MH (Table 4; Fig. 5). From the abovementioned results concerning the reaction of muscle to halothane, it became evident that it is possible to obtain both false positive results (in some neuromuscular disorders) and false negative results (in known carriers of MH - Bradley *et al.* (1973) and the present study). These findings support the statement made by Isaacs (1977) that: "There is at the present time no infallible predictive test to identify the carrier-state of MH" and that "... the occasional case will defy identification".

Perhaps the negative response to halothane obtained *in vitro* for known carriers of MH could be compared to the *in vivo* reactions observed by Aldrette in 1977 (Dr H. Isaacs, personal communication). This worker found that a MH carrier may react adversely to halothane administration on one occasion and show no reaction to halothane on a subsequent occasion(s), or *vice versa*. This was also demonstrated by Mogensen *et al.* (1974). Emotional stress has been thought to contribute to predisposition to MH *in vivo* (Mogensen *et al.*, 1974; Wingard and Gatz, 1977), thus accounting for the variable reaction to halothane anaesthesia seen in the same individual (Mogensen *et al.*, 1974). A possible explanation for the negative *in vitro* response may be that, owing to the absence of neural influences from higher centres *in vitro*, environmental factors such as emotional stress are eliminated.

Case 28, a known carrier of MH from previous biopsy results (Dr H. Isaacs, personal communication; initial tracing not available), was given 8 mg/kg of sodium dantrolene orally, four hours prior to the second biopsy. On exposure of the muscle specimen to 4% halothane, no reaction was obtained (Table 4). However, when 6% halothane was administered a gradual increase in muscle tension to 1.53 grammes occurred during the first 3 minutes, following which tension decreased to its original resting level within a further 4 minutes. When 6% halothane and 2.5 ml succinylcholine were subsequently added simultaneously, tension increased only slightly, and then returned to normal within 5 minutes. The use of orally administered sodium dantrolene to prevent the development of MH in susceptible swine, has been discussed by various authors (Anderson and Jones, 1976; Gronert *et al.*, 1976;

Harrison, 1977; Kerr et al., 1977; Flewelling and Nelson, 1980); and, more recently, it has been shown for man (Pandit et al., 1979). It is thought that sodium dantrolene blocks the excitation-contraction coupling mechanism by suppressing the amount of calcium released from the SR (Ellis and Carpenter, 1974; Putney and Bianchi, 1974).

As stated previously, caffeine appeared to potentiate a halothane contracture when administered before halothane. However, halothane did not appear to precipitate a caffeine contracture when the order in which the tests were carried out was reversed. This was established by comparing caffeine contractures when the caffeine test was done first (early graphs not documented in this study but which were included in the comparison under discussion) with results from when the tests were reversed and halothane was administered first. Muscle from MH carriers has been shown (by means of muscle tension studies) to be more sensitive to caffeine than normal muscle (Kalow et al., 1970). However, it appears from the present study (Table 3; Fig. 4) that diseased muscle in general is also frequently more sensitive to caffeine than normal muscle. When the halothane test preceded the caffeine test, approximately 79% of muscle specimens from patients with different neuromuscular disorders reacted much sooner to the addition of caffeine (i.e. reacted significantly before the addition of 4 mM - Table 3; Fig. 4) than did muscle from normal patients. Even when all 132* tracings done by the author over the three-year period were taken into account, a similar percentage was obtained. This abnormal response to caffeine of diseased muscle in various neuromuscular disorders may be attributable to abnormal uptake and/or release of calcium, either from the SR or sarcolemma, as a result of destruction of muscle fibres. It has previously been suggested that the reason for the positive reaction of muscle to caffeine and halothane in MH patients could be a consequence of either of these two abnormalities (Britt et al., 1973). Whatever the cause may be, the above results contribute to showing the invalidity of this test as a single predictive means of detecting carriers of MH - i.e. because diseased muscle in general may react to caffeine in a similar way to that of carriers of MH.

* 83 of these patients were assessed clinically by the author.

Caffeine tests were not carried out in cases 7, 8, 28 and 30, since the muscle specimens concerned were tested in early experiments when the procedure was to use only halothane and succinylcholine. The caffeine graph for case 11 has not been included, since the muscle did not remain viable long enough to enable the test to be completed. Case 23, whose muscle proved to be normal on histological and histochemical examination, and who was clinically abnormal only in the presence of weakness of the ocular muscles and diplopoea (Table 2; Appendix 2), showed very little reaction to caffeine. Cases 1, 4, 25 and 27 also reacted fairly normally to caffeine (Table 3; Fig. 4). Case 18, on the other hand, although initially more sensitive to caffeine than is usual, was not greatly affected by further addition of the drug (Table 3; Fig. 4b). No one type of disease appeared to be more sensitive to caffeine than another. Clinical symptoms did not appear to correlate with caffeine or halothane contractures either. Even those cases having similar clinical pictures and histological and histochemical findings did not produce similar reactions to halothane or caffeine when muscle was tested.

As is well known, various anaesthetic agents other than halothane and succinylcholine have been shown to cause MH incidents. Case 8, when anaesthetized (general anaesthesia) for the purpose of obtaining biopsy material, reacted adversely to the administration of methohexital. When given 2 ml of methohexital to induce relaxation for the purpose of intubation, the patient went into opisthotonus for approximately 1.5 minutes, after which relaxation occurred and it was possible to complete the operation. Because of this adverse reaction, methohexital was included as one of the media for in vitro testing. Muscle tension studies revealed a similar reaction to that which had occurred during anaesthesia. The muscle contracted initially when the drug was added and subsequently relaxed. It should be noted that this was the only patient in whom a positive response to succinylcholine was obtained in vitro (Table 5; Fig. 6). In view of this fact, as well as the positive reaction to methohexital and slightly elevated CPK level, this patient was considered to be at high anaesthetic risk*.

* Excessive release of calcium into the sarcoplasm occurs in these circumstances.

Histology and histochemistry

Histological findings and results of histochemical tests carried out on nerve and muscle biopsy specimens, were studied in conjunction with the initial clinical assessment of each individual. It was noted that the degree to which muscle was altered by the disease process often did not correlate with clinical findings. This was probably because muscle selected for biopsy was frequently only moderately affected by disease. Had the most severely affected muscle been chosen, correlation may have been more accurate; but owing to extensive destruction of muscle in the more affected areas, biopsy of such muscle would not have provided the necessary information as to the nature of the pathological changes taking place. When biopsy results from patients who were clinically similar to each other and having the same disease were compared, a marked similarity was usually observed, e.g. cases 9 and 14; 10 and 16; 20 and 21; and 4 and 5 (Table 2; Appendix 2). No comparison could be made and no correlation was expected with regard to clinical picture and biopsy results in carriers of MH, owing to the diversity of subclinical myopathies associated with this syndrome. Nerve findings in general were non-specific, except in cases of peroneal muscular atrophy (PMA), where observations such as "onion-peeling" in sural nerve biopsy tissue were indicative that the hypertrophic type of PMA was involved.

Electron microscopy

Electron microscopical observations have been included in this report only in special cases, such as for suspected carriers of MH; or in regard to significant findings not observed on histological and histochemical examination at the light microscope level. Cases 28, 29 and 30 were all suspected carriers of MH. Cases 28 and 30 had an increased number of mitochondria, appearing in rows in case 28 (Table 2; Appendix 2). In cases 29 and 30, there was evidence of folding of the basement membrane. Myofibrillar depletion was observed in cases 28 and 30, while in cases 29 and 30 there was loss of myofilaments (Table 2; Appendix 2). These structural changes, all of which were previously known to occur in carriers of MH, provided additional evidence relating to diagnosis of the condition in these patients. Ultrastructural

studies in case 8 revealed several very enlarged mitochondria showing loss of cristae (Table 2; Appendix 2). Lipid was seen in many degenerating mitochondria. These observations in case 8 contributed to the child being regarded as a suspected carrier of MH. Of note in case 27, were distended mitochondria with ruptured cristae and areas of myofilamentous and Z-line disruption (Table 2; Appendix 2). These fine structural details, together with the very positive reaction of the muscle of this patient to halothane in vitro (despite the possibility that the caffeine potentiated a halothane contraction), should perhaps be regarded as an equivocal diagnostic result as far as MH is concerned.

Electroneuromyography

Electromyography (EMG) is a preliminary means of determining whether the underlying pathology is the result of neuropathic or myopathic changes. Although EMG results in most diseases are non-specific, they can be of diagnostic value when considered together with other findings. EMG can reveal where active denervation is present, as in case 9. Furthermore, data summarized in Table 2 confirm that the presence of high voltage polyphasic activity is a most valuable indication of denervation which has been followed by reinnervation. In many of the chronic neuropathies, adjacent healthy neurones sprout to take over a larger number of muscle fibres, thus increasing the voltage, duration and shape of the motor-unit activity.

Myoneural junctional studies are of great value in the diagnosis of myasthenia gravis (MG), where a typical picture of rapid fatiguing of muscles (i.e. a progressive decline in amplitude of muscular response) is demonstrated by repeated stimulation of a nerve (e.g. cases 17 to 23 - Table 2; Appendix 2).

Motor nerve conduction studies can facilitate the diagnosis of cases involving the hypertrophic form of PMA, in which conduction velocities are markedly slowed. On the other hand, conduction study results in MG, for example, are normal. Consequently, EMG and nerve conduction study findings, when considered together with other information, serve as a fairly positive means of diagnosing MG.

Prognosis

When initial clinical assessments were compared with those done later on, it became evident in retrospect that the histological and histochemical information, together with initial clinical data and knowledge of the "usual" pattern or course followed by individual diseases, normally provided a fairly accurate guide as to the expected rate of deterioration of each patient in ensuing years. However, owing to the unpredictability of disease, the prognosis can sometimes be wrong. For example, case 2 (one of spinal muscular atrophy), who at the time of biopsy showed evidence of active breakdown of muscle fibres, had altered very little in clinical picture when re-assessed 1½ years later (Table 2; Appendix 2). A far more marked deterioration in muscle strength had been anticipated on the basis of biopsy findings than was actually found on re-assessment. This illustrates why biopsy results are used only as a general guide as to how the disease is likely to progress.

PHYSIOTHERAPEUTICAL AND RELATED ASPECTS

As far as physiotherapy per se is concerned, nine patients were treated by the author. Some of these have not been included in this study, as several of the conditions involved did not correspond with the five categories finally selected for this report. A factor which reduced the number of patients who in the normal course of events might otherwise have been treated (either by the author or by another physiotherapist) was that several patients lived on farms some distance from a town or were stationed in places where physiotherapy was not available. Other patients were not prepared to have physiotherapy. It would have been preferable for every patient to have received physiotherapy, but this was not possible under the circumstances.

As is well known, active exercise aggravates the condition MG, these patients becoming weaker with repetitive movement. When questioned, all patients with MG included in this study (with the exception of those with the purely ocular form of MG) stated that they became

weaker with increased activity. Unless there is actual improvement in the disease, either following surgery (thymectomy) or the administration of drugs such as pyridostigmine, it is not possible to improve a patient's vital capacity or exercise tolerance, in view of the involvement of the muscles of respiration. Consequently, in patients with associated respiratory symptoms, but not so severe as to require mechanical ventilation, it is necessary to teach the patient an economical breathing pattern and about lung clearance, in order to prevent chest infections (common in these patients) from occurring. Such patients should also be advised that in the event of a chest infection developing, the necessary drugs prescribed by the doctor should be taken. Physiotherapy during this period would be advisable in order to reduce possible strain on other organs, which could result in deterioration in general health and restriction of normal daily activities.

Chest infections are also fairly common in the intermediate and mild forms of SMA, even when there is no associated scoliosis and/or kyphosis (Dubowitz, 1977a; Benady, 1978). As a result of these studies, and following the demise of a patient (case 4; Appendix 2), who had a mild kyphoscoliosis, the importance of chest physiotherapy and of educating families of such patients had become very evident to the present author. The cause of death in case 4 was established as respiratory failure following a chest infection. The kyphoscoliosis, although not severe at the time of assessment, caused a restrictive lung condition which resulted in decreased lung function. As a consequence, this child was very susceptible to chest infections. However, despite her deformities and marked generalized muscle wasting, she was completely functional* and coped well at school.

The question raised here, therefore, is whether instruction of parents and families of patients with the intermediate and mild forms

* It had been established by means of muscle biopsy that she was afflicted with a slowly progressive form of SMA, the long-term prognosis being fairly good. Because of this, the physician concerned decided not to apply a plastazote jacket or Milwaukee brace, since either of these methods of limiting further deformity would, at this stage, not only have restricted her normal functional activities, but would also have decreased chest expansion and mobility, resulting in more rapid deterioration of general muscle strength.

of SMA (with or without scoliosis) would not be appropriate. They could be shown how to assist these patients in maintaining as near maximal chest expansion and lung clearance as possible at all times. This would help prevent recurrent chest infections; and in some instances (as in case 4), premature death. Furthermore, patients could be advised to have physiotherapy when chest infections do occur. At this time, drugs and aids such as intermittent positive pressure breathing could also be given, which would obviate the need for patients to be confined to bed for longer than really necessary. A further consideration is that because the intercostal muscles are affected, "frog breathing" (a passive, positive pressure form of breathing) could be taught. This would increase alveolar expansion, causing release of surfactant and resultant increase in alveolar patency, thus maintaining fairly good lung function. This breathing technique could also be taught to patients immobilized in a brace, where lung and chest expansion are restricted. Further studies are needed to establish whether chest physiotherapy could play an important role in preventing lung infections in these patients. Consideration should also be given to whether early bracing of patients with a mild scoliosis (as recommended by Dubowitz, 1977a,b) is desirable. This course of action would presumably inhibit functional activities, resulting in a concomitant decrease in muscle strength. The alternative of later immobilization, preceded by intensive chest physiotherapy, might prove to be a better approach to management of the condition.

Five patients received regular physiotherapy (Appendix 2). Three suffered from SMA (cases 7, 2 and X, the last mentioned being the sister of case 2); and two had PMA (cases 9 and Y, the latter being similar to case 9, although affected to a slightly greater degree by the disease). Details concerning cases X and Y are not given in this dissertation because not enough muscle was available following biopsy to enable muscle tension studies to be performed. There was marked improvement in the functional abilities and activities of all five patients (Table 2; Appendix 2), following varying periods of treatment. However, when individual muscles and muscle group actions were tested in cases 2, X, 9 and Y, it was found that muscle strength had remained unchanged from the time of original assessment, except in case 9, in whose upper limbs muscle strength had deteriorated slightly (Appendix 2). From this, one

can only surmise that although the strength of individual muscles did not improve, these patients not only learnt trick movements, but also learnt to compensate for their disabilities by effective use of gravity, body weight, momentum and several other means such as the use of muscles in the strongest range of motion. Questioning revealed that physiotherapy had a beneficial psychological effect on the parents by altering their mental attitude and approach towards their children. They stated that once therapy had commenced, they no longer felt as helpless as before, since they were able to assist in their childrens' "rehabilitation" by trying to continue teaching the children what was taught to them by the therapist during treatment periods. Besides this continuous exercise programme, the psychological "boost" provided by the parents may also have contributed towards the patients' improvement. Case 7, who had a very mild form of SMA, improved not only functionally, but also in muscle strength.

Case 27 was also treated by physiotherapeutic means, but only for a limited period (Appendix 2). This interesting patient was difficult to treat because of the unknown aetiology of stiff man syndrome (SMS), as well as the profound influence of extraneous factors such as noise and touch on muscular spasms. It was impossible to establish whether the slight improvement in function was attributable to drugs alone or to a combination of drugs and physiotherapy. It has been stated in two publications that cold (weather) aggravates the condition SMS (Moersch and Woltman, 1956; Maiua et al., 1980), while in one case it was found that heat treatment resulted in an improvement in the condition (Maida et al., 1980). It would have been interesting to have compared cold and heat as forms of therapy, but unfortunately the child was removed from hospital and could not be traced.

An interesting observation concerning one of the patients with PMA, case 14, was that clawing of the toes had been reduced following the continuous wearing of orthotics for a period of ten months (Appendix 2). This was especially noticeable on the right foot, where the toes were almost straight. Bilateral pes cavus was not as marked as previously and the patient could walk, run and climb stairs far better than before. She stated that her ankles were more stable when wearing the orthotics. Further investigation is required to establish whether the wearing of

orthotics does, in actual fact, improve the functions of the feet; or whether it was pure chance that this occurred in this patient.

As stated in the materials and methods section, biopsy specimens were removed from muscle which was clinically only moderately affected by the disease process, in order to make an accurate diagnosis. At the same time, this makes the correlation of clinical picture with biopsy findings rather difficult, since one cannot be sure that the muscle selected in different patients is representative of the same stage of the disease. Another factor contributing to inaccuracy of correlation, not only with biopsy findings, but also when determining the degree of improvement or deterioration in a patient's condition, is that at present no really accurate method of assessing muscle strength is available. The system chosen for this study was that of Daniels *et al.* (1956); and documentation of grading that of Kendall and Kendall (1939). This is a subjective and relatively simple method of assessing muscle strength, and one requiring no apparatus. However, experience in applying the technique and knowledge of variables such as the following and how these affect muscle strength are essential when this method of assessment is used: age, sex, occupation, sporting and other activities, general health, pain, temperature, fatigue, muscle bulk, psychological attitude, motivation and several others. Despite possession of this knowledge and experience, it is inevitable that results will nevertheless sometimes differ. This occurs as a result of the inability of an individual to apply exactly the same amount of resistance every time when performing the test, differences in muscle strength of assessors, and differing interpretations of the various grades of strength by individual assessors.

The Cybex II (Elliott, 1978), a modern, sophisticated apparatus from which data obtained can be computerized and more accurately compared, provides an objective means of testing muscle strength. It was unfortunate that this expensive machine was not available for the purposes of the present study. However, although at the present time this highly technical method appears to be the most effective and accurate way of assessing muscle strength, it too, has its limitations. These include inability to test several muscles around the shoulder girdle, and only being able to resist, in isolation, the rotatory component

involved in certain muscle actions.

Another problem encountered when initially assessing muscle strength of a patient in whom the entire body is to a greater or lesser extent affected by disease, is that it is impossible to know what the patient's strength was prior to onset of the disease. One can only compare the patient in question with another, similar, normal person, taking all the variables mentioned previously into consideration, as well as the patient's account of how strong he or she was and how much muscle wasting had occurred. This method is a very subjective and unscientific means of testing muscle strength.

The field of assessment of muscle strength requires far more study in order to establish a method of testing which would take into account all aspects of muscle action. Muscles very seldom act in isolation. Rotation is incorporated in most movement and functional activities, yet the methods used most extensively for testing muscle strength attempt to isolate individual muscle actions and involve movements in the cardinal planes.

With the rapid advancement of computer technology, a future method of assessing "original" muscle strength in a patient with generalized muscle weakness may simply involve feeding results obtained from assessments of patients (using highly technical and accurate apparatus and methods) into a computer. This information could then automatically and rapidly be compared with a selected number of previously established, normal control groups. Initially, this would involve determining the mean muscle strength of many similar, normal individuals, either by means of the Cybex II, or an even more accurate and sophisticated apparatus, not yet devised. Variables such as age, sex, occupation, muscle bulk, sporting and other activities, psychological influences, balance and co-ordination, initial muscle resting tension, range of motion of joints and general health and metabolism* would all have to be considered (and tested) when planning the selection of normal, control groups. Full-length photographs of patients prior to onset of disease,

* This would include cardiac and lung function tests, which would take into account many important individual differences, such as circulatory variations, endurance, etc.

as well as a subjective account given by patients of their muscle strength, could be computerized for purposes of comparison; and may provide additional useful, supplementary information. All tests would have to be carried out under strictly controlled environmental and other conditions: these including temperature, noise, lighting, comfort, starting positions, load, speed of contraction, resting period prior to testing, number of times each activity is performed, and the time interval between the testing of each muscle or muscle group. It would also be necessary to ensure that the patient has practised all the movements and understands what is required of him/her.

Although this sounds not only like a major task, but also a highly hypothetical situation, it may not, in fact, be all that far-fetched. If research into the different areas were to be started by many investigators (including physiotherapists, engineers, kinaesiologists, physiologists, etc.) in an attempt to devise the ideal testing apparatus and methods, this would probably not prove to be as difficult as it may seem. Once achieved, these new techniques would become a matter of routine. This new method of testing muscle strength would be an invaluable aid, not only to physiotherapists, but also to practitioners, researchers in sport, physiologists, etc., thus opening up a whole new field of study for further research.

During the course of the present study, the author became familiar with several techniques which provided her with a better knowledge and understanding of the structure and functions of muscle. This background knowledge will assist the author in future studies, which will attempt to supply scientific explanations for results obtained following use of one (or more) of the many physiotherapeutical techniques employed in the treatment of patients.

CONCLUSION

Muscle tension studies were carried out in order to evaluate the technique as a single, diagnostic test for carriers of MH. Results of investigation of muscle specimens from patients with various neuromuscular disorders, including MH carriers and normal people, showed that this test is not as reliable as originally thought. Both false positive and false negative reactions to the administration of 4% halothane were obtained. Although muscle from MH patients was more sensitive to the addition of caffeine than normal muscle, that of patients suffering from other neuromuscular diseases appeared, on occasion, to be abnormally sensitive as well. This finding indicated that muscle tension studies can only be used as an additional means of testing suspected carriers of MH. Histological, histochemical, electron microscopical and electro-neuromyographical findings alone, proved to be non-specific in the detection of patients with MH. When considered together, however, these techniques isolate the carriers of MH.

Patients who received physiotherapy all improved functionally to a varying extent, even though muscle strength remained unchanged. This demonstrated the need for physiotherapy, both to assist these patients with their functional activities, and because improvement in this respect gives the patient psychological support. The latter aspect is also important as far as the families involved are concerned; and the need to show families how to assist affected patients, became evident.

From observation of patients with associated respiratory symptoms, the need for chest physiotherapy became apparent, not only so that the patient can be taught an economical breathing pattern in order to maintain as near maximal chest expansion as possible, but also to ensure as effective lung clearance as possible. This may assist in prevention of recurrent chest infections (common in these patients). Families of patients could be shown how to help maintain a clear chest. They should emphasize the importance of this to the patient, and by so doing would provide psychological aid.

The need for further research in the field of muscle testing techniques became obvious. At present, no truly accurate, objective methods or apparatus are available for assessing and comparing patients with generalized muscular weakness; and which take into account all the aspects involved in muscle action.

A P P E N D I X 1THE ASSESSMENT FORM USED

(Assessments were carried out prior to biopsy because some patients experience pain and slight loss of function following biopsy. Also, patients from whom nerve tissue is removed, lose sensation in the area supplied by that nerve)

A S S E S S M E N T

NAME:

ADDRESS:

Home Tel. No.

OCCUPATION:

Business Tel. No.

AGE:

DIAGNOSIS:

SUBJECTIVE

1. Early History:

Surgery -

Previous medical treatment -

Effects -

Previous physiotherapy -

2. Recent History:

General observation -

General Health -

Weight - previous Date

present Date

Psychological attitude -

Habits -

Onset and history of illness -

Present medication -

Effects -

3. Family history:

4. Social history:

5. Daily functional activities:

Capabilities

Difficulties

6. Recreational activities:

Sport - previous Date
present Date

Comments -

Hobbies - previous Date
present Date

Comments -

7. Observation:

Skin - texture
colour

Nails -

Muscle bulk -

Oedema -

Scars -

Lesions -

8. Palpation and measurement:

Oedema -

Skin temperature -

Sweating -

Muscle bulk -

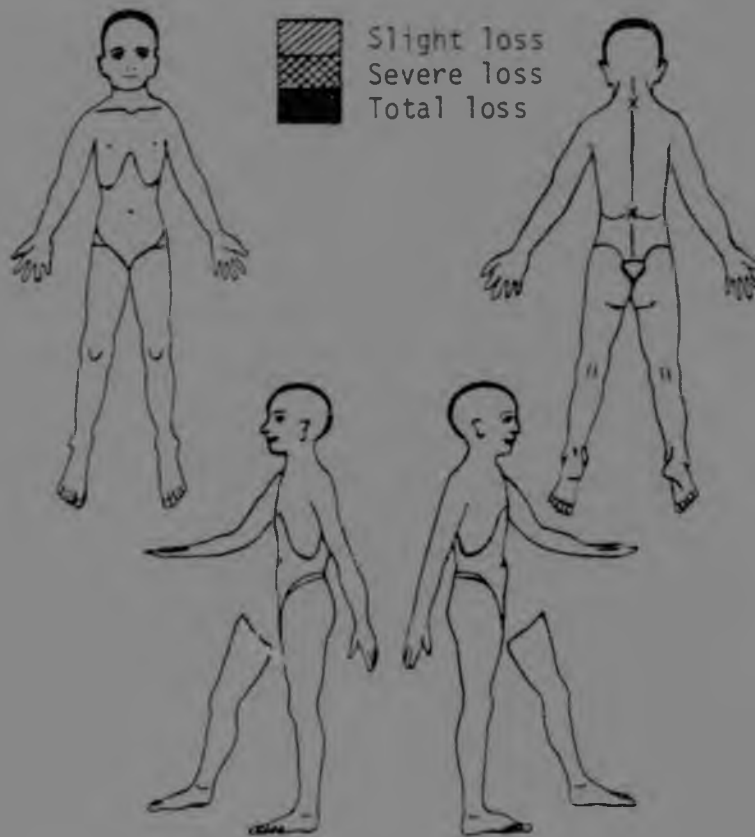
Scars -

Tenderness -

Muscle activity -

9. Sensation:

Skin - Hot/cold —
Sharp/blunt —
Light touch/pressure —



Vibration sense -

Joint position sense -

Stereognosis -

10. Reflexes:

Cutaneous reflexes - abdominal
sole of foot

Tendon reflexes - knee
ankle
elbow

11. Muscle power and joint range:

	<u>Right</u>	<u>Left</u>	<u>Range of motion</u>	
			<u>Active</u>	<u>Passive</u>
<u>Supine:</u>				
Neck flexion				
Trunk flexion				
Trunk rotation				
Pelvic elevation				
Hip external rotation				
Hip internal rotation				
Knee extension				
Foot dorsiflexion (with inversion)				
Foot eversion (from plantarflexion)				
Foot inversion (from plantarflexion)				
Toe flexion				
Interphalangeal joints				
Metatarsophalangeal joints				
Toe extension				
Hallux flexion				
Hallux extension				
Shoulder horizontal flexion				

	<u>Right</u>	<u>Left</u>	<u>Range of motion</u>	
			<u>Active</u>	<u>Passive</u>
<u>Side lying:</u>				
Hip abduction				
Hip adduction				
<u>Prone:</u>				
Neck extension				
Trunk extension				
Hip extension				
Knee flexion				
Scapular adduction with upward rotation				
with downward rotation				
Scapular depression (with adduction)				
Shoulder extension				
Shoulder abduction (horizontal)				
Shoulder external rotation				
Shoulder internal rotation				
Elbow extension				
<u>Sitting:</u>				
Hip flexion				
Hip flexion, abduction and external rotation				
Scapular elevation				
Scapular abduction				
Shoulder flexion to 90°				
Shoulder abduction to 90°				
Elbow flexion				
Forearm supination				

	<u>Right</u>	<u>Left</u>	<u>Range of motion</u>	
			<u>Active</u>	<u>Passive</u>
Forearm pronation				
Wrist flexion				
Wrist extension				
Finger flexion				
Interphalangeal joints				
Metacarpophalangeal joints				
Finger extension				
Finger abduction				
Finger adduction				
Thumb flexion				
Thumb extension				
Thumb adduction				
Thumb abduction				
Thumb opposition				
<u>Standing:</u>				
Ankle plantarflexion				
with knee extended				
with knee flexed				
<u>Hand grips:</u>				
Pincer				
Power				
Hook				
Key				
Lumbrical				
<u>Dominant hand:</u>				
<u>Facial muscles:</u>				
<u>Jaw muscles:</u>				

12. Function and balance: (in the developmental sequence)

13. Co-ordination:

14. Posture:

15. Gait:

SUBJECTIVE AND OBJECTIVE

16. Speech, tongue movements, swallowing:

17. Hearing:

18. Vision:

19. Respiratory function:

ADDITIONAL RESULTS

20. X-rays: (Date)

21. Blood tests:

22. Serum enzyme tests:

23. Other:

LATER RESULTS

24. Electroneuromyography:

Electromyography -

Nerve conduction studies -

Myoneural junctional studies -

25. Histology:

26. Histochemistry:

27. Nerve studies:

28. Electron microscopy:

29. Muscle tension studies:

APPENDIX 2SUMMARIES OF CASE HISTORIES*

*(Grading of muscle strength: Normal, good, fair plus, fair, poor, trace, zero. For further details, see Kendall and Kendall, 1939)

SPINAL MUSCULAR ATROPHY
(SMA)

CASE 1 (K.R.)

This lean, 15-year-old, white girl had been treated for two years for an idiopathic scoliosis and had been wearing a Milwaukee brace for 18 months. It was subsequently noted that she had marked winging of the scapulae and she was referred to Dr Isaacs for EMG studies and muscle biopsy. Questioning revealed that there were other members of the family with kyphoscoliosis. The only abnormality she had noticed was that following gymnastic classes at school, her "arms" became very weak and she could not lift herself up. She took part in other sports as well, but with no ill effect.

On examination, there was slight generalized muscular weakness, this being more obvious in the upper than the lower extremities. There was marked wasting of the serratus anterior and pectoralis group of muscles; and the latter showed evidence of digitation, strength being fair plus. There was slight weakness of some of the muscles in the hands, although her grips were strong. She had a marked scoliosis, pronounced lumbar lordosis and thoracic curve, with associated winging of the scapulae. Her gait was normal and balance good. Sensation was normal.

EMG - Muscles of the upper extremities, neck and back were examined. Most muscles showed an increase in polyphasic activity but on the whole the voltages were normal. Several of the muscles, particularly serratus anterior, showed a marked fall-out of motor-unit activity.

NCS - These were normal.

Muscle tension studies - See Figs 4a and 5; and Tables 3 and 4.

Muscle biopsy - Specimens were removed from the deltoid muscle. On histological examination, the muscle fibres appeared fairly normal. Histochemical study, however, showed gross abnormality. There was grouping of both fibre types. Some type 1 fibres showed evidence of targetoid formation and had a "moth-eaten" appearance.

Re-assessment - This patient was seen 10 months later and there was no evidence of deterioration or improvement. She was still very active and was playing the same sports as before.

CASE 2 (K.V.)

This 2½-year-old, white girl's development was apparently normal until she started walking. Although unable to walk unaided, she was observed to have a distinct Trendelenberg gait when led by the hands. At the time, her parents thought that she was copying her 5-year-old sister who also had spinal atrophy and walked with a marked Trendelenberg gait.


On assessment, strength in the upper limbs was found to be good, while in the lower extremities it was poor to fair, with the exception of the ankles, which were fair plus. Strength of the trunk muscles was fair plus. Reflexes were all absent. Gait (when holding on to objects) was poor owing to pelvic instability, and she fell quite often. No fasciculation of tongue or skeletal muscles was noted and there was no bulbar involvement or respiratory difficulty, although it was reported that she was prone to chest infections during the winter months. A slight tremor in the upper and lower extremities was apparent. There was no evidence of any sensory disturbances. The CPK level was raised (to 238). The family history was negative.

EMG - Muscles of the upper and lower extremities were examined. Many of the motor units were polyphasic in appearance, the motor-unit activity being of high to normal voltage. There was no evidence of any low-voltage myopathic units.

NCS - These were normal.

Muscle tension studies - See Fig. 4a; and Tables 3 and 4.

PERONEAL MUSCULAR ATROPHY
(PMA)



NCS - These were normal.

Muscle tension studies - See Fig. 4a; and Tables 3 and 4.

Muscle and nerve biopsy - Muscle samples were removed from the peroneus brevis muscle. Nerve tissue was taken from the sural nerve. Histology revealed widespread areas of grouped fibre atrophy. Many small, angulated fibres were present, as well as some hypertrophic fibres. Histochemical studies showed grouping of both fibre types. Hypertrophic fibres were of both the type 1 and type 2 varieties. Type 1 fibres showed targetoid degeneration and had a "moth-eaten" appearance. Sural nerve studies showed grouping of nerve fibres of the same size, as well as loss of fibres. Some fibres showed evidence of degeneration of myelin. There was no "onion-peeling".

Re-assessment - This patient was seen one year later. He went to the army one month after the biopsy had been carried out and was discharged 2 weeks later because he could not walk. On re-assessment, his muscle strength was found to have deteriorated. The patient explained that his upper limbs were weak and that he could no longer take part in sport. He fell far more often than before, and was unable to run very fast because he "tripped over his own feet". He could not skip. His left ankle was said to be permanently swollen and painful; and some days it was so bad that he was unable to walk. The patient also found that his left leg tired rapidly. On examination, there was marked wasting of both legs, especially on the left side. Slight wasting of the small muscles of the hands was also noted. He walked with a distinct limp and when weight-bearing on the left lower limb, he hyperextended the knee. Hyperextension of the knee was also seen in standing. He had a slight equinovarus deformity of the foot on the left when walking and most of the body weight was distributed on the lateral border of the foot. When he was tired, the equinovarus was accentuated and caused him to trip and fall. General muscle strength was slightly weak, with the exceptions of toe extension, which was poor; ankle dorsiflexion, eversion and plantarflexion, all of which were fair; elbow extension, which was fair; and adduction of the right index finger, which was zero. The left side

Muscle biopsy - Tissue was removed from the vastus lateralis muscle under general anaesthesia. Histological and histochemical studies showed evidence of large areas of grouped, atrophic muscle fibres. Many of the type 1 and type 2 fibres were in the process of active breakdown. Muscle was under-developed in some areas, while in other parts, several fibres had become hypertrophied and contained centrally orientated nuclei. There was excessive branching of motor nerve terminals and many motor end plates were small and club-like, while others were abnormally large. Myelin deposition of nerve terminals and intramuscular nerves was irregular.

Re-assessment - When re-examined 1½ years later, having had physiotherapy during the intervening period, there was little evidence of any deterioration in muscle strength. Functionally she had improved. Whereas previously she was unable to walk independently or ride her tricycle, she was later able to do so, although she still had a marked Trendelenberg gait and walked with hyperextended knees and her arms in abduction. Her balance in standing was poor and she was still unable to kneel. Physiotherapy had included: assistance with functional activities, general strengthening techniques including proprioceptive neuromuscular facilitation, exercises on the pezzi ball, and the neuro-developmental (Bobath) method of treatment.

CASE 3 (C.R.)

This very thin, 8½-year-old, white girl was abnormal virtually from birth and was unable to hold her head erect at the correct age, although her mother thought that she was able to sit unsupported at 6 months. The child's weakness remained undetected until she was 1 year old. When she commenced walking at approximately two years of age, her gait was seen to be abnormal and she fell quite often. She was subsequently never able to run, had difficulty walking up inclines or climbing stairs and tired very quickly. She had received anti-influenza injections annually, because of susceptibility to chest infections. She was doing

well at school). The family history was negative, but her younger sister also had SMA. The OPI level was raised (to 59).

On examination, she had generalized, moderate weakness; and her musculature was thin, on the whole, and under-developed. She walked slowly and with a distinct Trendelenberg gait. The left leg was internally rotated and crossed over the right leg (slightly) during the swing phase of gait. External rotation of the left leg was limited. There was an associated kyphoscoliosis resulting in some limitation of all movements of the entire dorsolumbar spinal area, as well as slight limitation of these movements in the cervical spinal region. Trunk side flexion was more limited on flexion to the left. Balance was fair. She was unable to rise from a squatting position in a normal way; and rose in a manner typical of a patient with muscular dystrophy - namely, with the support of her hands on her knees. There was no pes cavus. Sensation was normal. All tendon reflexes were absent, although cutaneous responses were normal.

EMG - Muscles of upper and lower extremities were tested. This revealed increased polyphasic activity of fairly high voltage and some fall-out of motor-unit activity.

NCS - These were normal.

Muscle tension studies - See Fig. 4a; and Tables 3 and 4.

Muscle biopsy - Specimens were removed from the vastus lateralis muscle. Histology revealed variation in fibre size. Histochemical studies showed that type 2 fibres were very small, and they were reduced in number. Type 1 fibres demonstrated targetoid formation and had a 'moth-eaten' appearance. Motor nerve terminals branched excessively and the end plates varied abnormally from fibre to fibre.

Re-assessment - This child was never re-assessed. Six months after the biopsy was performed, she died from respiratory failure, following a chest infection. Her mother stated that the kyphoscoliosis had

deteriorated and that she had several successive chest infections during the intervening period.

CASE 4 (S.B.)

A 48-year-old, white man presented with an 8-year history of pain and progressive weakness in the upper extremities. It commenced with pain in the shoulders and rapid fatiguing when raising the arms above the head. During the ensuing years, his upper extremities became weaker and he experienced burning sensations in various parts of the body, particularly over an area on the left thigh, dorsum of the left foot and in the upper limbs. He also noticed that his condition became very much worse in cold weather; and during strenuous exertion, the muscles readily went into cramp. No family history of neurogenic disorder could be obtained.

On examination, there was marked wasting of the small muscles of the hands and the muscles of the left leg, particularly tibialis anterior. Generally, muscle strength was good, although in the more distal muscles of the upper and lower extremities it was fair to fair plus. Range of motion (both active and passive) of all joints was normal, except for active dorsiflexion of the left foot, which was limited by 10° . Reflexes in the upper extremities were brisk as were the knee jerks, while both ankle tendon reflexes were depressed. Posture and gait were normal.

Muscle tension studies - See Fig. 4a; and Tables 3 and 4.

Muscle biopsy - Tissue was removed from the vastus lateralis muscle. Histological studies showed marked variation in fibre size, evidence of scattered atrophy of fibres, slightly increased central nuclear migration, and an increase in the amount of fibrous tissue. Histochemistry revealed grouping of individual fibre types. Type 1 fibres showed evidence of targetoid formation and had a "moth-eaten" appearance.

Re-assessment - When seen one year later, the patient's condition had remained unchanged.

CASE 5 (P.E.)

A 44-year-old, white man presented with weakness of his left lower extremity. He was unable to run and as a result was no longer able to play tennis or football. He experienced difficulty climbing stairs and had to use his arms, by pulling on the banister. He also noticed that he tired quite easily. His ailment had first commenced 3 years previously when, following a 2-mile walk, he became dizzy and started staggering. This was accompanied by a strange loss of feeling in the fingertips of his left hand but which lasted only a few days. He subsequently complained of a "floppiness" of his left lower extremity, a condition which never seemed to resolve. There was no family history of any neuromuscular disorder.

On examination, muscle strength in the upper extremities was found to be normal. There was slight wasting of the left lower extremity, with slight weakness of the right lower extremity and in the abdominal muscles. The left lower extremity was weaker than the right, muscle strength being nevertheless fair plus, especially hip abduction, ankle eversion and toe extension, even though all movements were performed through full range against gravity and with slight resistance. When walking, the patient had a slight limp and tended to circumduct the left leg. Sensation was normal, as was his balance.

EMG - Muscles of the lower extremities were examined. Motor-unit activity in the anterior tibial, peroneal and quadriceps femoris muscles on the left side showed inadequate recruitment. However, this was better on the right side. There were occasional, high-voltage polyphasic units present. During fatigue studies, it was noted that the muscles fatigued abnormally.

NCS - There was slowing of nerve conduction, particularly in the right lateral popliteal nerve, in which the conduction velocity was 38 ms^{-1} .

Muscle tension studies - See Fig. 4a; and Tables 3 and 4.

Muscle biopsy - Samples were removed from the vastus lateralis muscle. Histological studies showed marked variation in fibre size, with areas of grouped fibre atrophy as well as single fibre atrophy. Histochemistry demonstrated small areas of grouping of both fibre types. Several type 1 fibres had a "moth-eaten" appearance. Motor end-plate studies revealed variation in size and formation of the end plates, with excessive branching of motor nerve terminals.

Re-assessment - When seen 17 months later, this patient's condition had remained unchanged.

CASE 6 (F.C.)

This obese, jovial, 43-year-old, white woman first developed weakness of her extremities at approximately 18 years of age. Thereafter, the disease progressed slowly and it was not until she consulted a doctor about pain in her right hip, that generalized weakness was detected. Her main complaints were that she had difficulty in combing her hair or performing any task which involved elevation of one or both upper limbs. She was unable to climb stairs without the aid of a banister and had also noticed that she walked with a slight limp - "as though one leg was shorter than the other". She was a heavy smoker.

On examination, there was marked weakness of all proximal limb muscle groups, strength in these muscles being only fair. The right side was slightly more affected than the left. There was winging of both scapulae, which was more prominent on the right side. The distal muscles of all extremities were slightly weak and although strength in her hands was good, the patient had to change her job owing to inability to

maintain a strong grip for any length of time. There was also evidence of slight weakness of the facial muscles. Eye movements were normal. The patient had a slight Trendelenberg gait, which was more obvious during mid-stance phase of the right lower extremity. A mild kyphosis was also noted. Passive and active range of motion of all joints was normal. Tendon reflexes were present and equal on both sides, as were peripheral pulses. There was no sensory loss. Questioning revealed that the patient had two children, aged 24 and 23, both of whom had weakness similar to hers. However, according to the patient, there was no previous history of neuromuscular disorder in the family.

EMG - Muscles of the upper extremities and trunk were examined. Many motor units, particularly of the more proximal muscles and especially trapezius, supra- and infraspinatus, showed fall-out of motor-unit activity. Much of the remaining motor-unit activity was of low voltage and some of it polyphasic. Other areas had normal motor-unit activity. Generally, muscle was found to fatigue abnormally.

NCS - These were normal.

Muscle tension studies - See Fig. 4a; and Tables 3 and 4.

Muscle biopsy - Tissue was removed from the vastus lateralis muscle. Histological studies revealed a marked variation in muscle fibre size. There was an increase in the amount of fat and fibrous tissue within the muscle. Histochemistry showed marked grouping, particularly of type 1 fibres. Type 1 fibres tended to be small. Several type 1 fibres were irregular in shape and had a "moth-eaten" appearance. Some hypertrophic type 1 and type 2 fibres were seen.

Re-assessment - This patient was re-assessed two years later. 1½ years prior to this she had a hysterectomy, following which she became weaker. At the time of re-assessment, she was unable to flex or abduct the shoulders beyond 80°, and consequently she could not perform any activities requiring this action. She found she tired very quickly, although she was still able to do her job. Her general muscle strength had

deteriorated to some extent and as a consequence she now walked with a marked Tredelenberg gait. She had pain in the right upper extremity on all resisted movements but had learnt to compensate by using her left hand and forearm for most activities. She had stopped smoking and, as a result, had gained 20 kilograms in weight. Despite the deterioration in her condition, this woman was still quite active and tried to lead as normal a life as possible.

CASE 7 (J-M.K.)

This 2-year-old, white boy was relatively inactive at birth and was in an incubator for twelve days. He was very hypotonic, had a weak cry and had difficulty in sucking. On the fourth day, he had two convulsive attacks and subsequently, after receiving penicillin, had a true grand mal seizure. Once out of the incubator, he began to improve, and from this time onwards he had physiotherapy. Motor development was delayed and he only walked at eighteen months of age. He held his head up at eleven months and crawled at fourteen months. Intellectually, he was above average and began speaking at eleven months. At about thirteen months, it was noticed that he had marked drooping of both eyelids and slanting of the eyes. He was always very susceptible to upper respiratory tract infections. There was no history of any neuromuscular disorder in the family.

On assessment, muscle strength on the right side of the body was good to normal, while on the left side it was fair plus to good. The patient's head was in an extended position, to compensate for the drooping eyelids. He had a distinct limp when walking, this becoming more pronounced when running. His teeth were very small and pointed. Reflexes were present and equal on both sides and sensation was normal.

EMG - Muscles of both upper and lower extremities were examined. The motor units seen were of normal size and duration and there was no evidence of denervation activity.

NCS - Nerve conduction studies were normal.

Muscle tension studies - See Tables 3, 4 and 5.

Muscle biopsy - Tissue was removed from the deltoid muscle. Histology revealed normal muscle tissue. Histochemistry, however, showed areas of fibre type grouping, mainly of the type 1 variety. Motor nerve and nerve terminals with end plates were normal.

Re-assessment - When seen 2 years later, this child had a normal gait, and muscle strength was almost normal for his age. He had been attending a school for disabled children where he had physiotherapy for one hour, three times a week. Treatment was based mainly on the neurodevelopmental (Bobath) method of handling, although general strengthening techniques such as proprioceptive neuromuscular facilitation, exercises on the pezzi ball and functional activities were also used. The most evident residual deformity was drooping of the eyelids, but even this had improved. His neck was held in slight extension, to compensate for the ptosis.

CASE 8 (C.P.)

This 5-year-old, white boy had normal early milestones and walked at 13 months. At 18 months, his mother noticed that he was "slapping" his feet down when he walked and that he had a very arched back. When he was 3 years old, he started walking on his toes; and at the age of four, appeared to fall far more often than other children of the same age. He managed to keep up with other children, although he tired easily. He experienced great difficulty climbing stairs and running, although he was able to do both.

On examination, this small child walked on his toes and had a slight Trendelenberg gait. He had a marked hyperlordosis and 5° hip flexion contractures. Dorsiflexion of the ankles was very limited,

both actively and passively, and his calf muscles were somewhat larger than would have been expected for a child of his age and stature. Muscle strength was generally good to normal except for hip abduction on both sides, which was fair. Tendon reflexes were decreased. Balance was fair in standing but normal in all other positions. Co-ordination was good. There was evidence of an extra fold over the inner canthus of the left eye and the patient had previously had surgery for squint correction. At 91, the CPK level was slightly elevated.

EMG - Muscles of the lower extremities were examined. The motor units visualized were mostly within normal limits, although some appeared to be excessively polyphasic. N. denervation activity was noted.

NCS - Nerve conduction studies were normal.

Muscle tension studies - On exposure to methohexital, the muscle went into spasm, but relaxed after a few minutes. On re-administration of a greater concentration of methohexital, it once again contracted and recovered spontaneously after a few minutes. The muscle was also unduly sensitive to succinylcholine. See Figs 5 and 6; and Tables 3, 4 and 5.

Muscle and nerve biopsy - Tissue was removed from the gastrocnemius muscle and sural nerve. Histological and histochemical studies revealed small, under-developed type 2 fibres, although the distribution and number of type 2 fibres was normal. There was no evidence of denervation activity or grouping of individual fibre types.

Biopsy findings of the sural nerve were relatively normal, except that many axons showed "whorling" of myelin, indicating that either myelination or demyelination was taking place.

Electron microscopy showed normal to very large mitochondria, with loss of cristae. Lipid was seen in many degenerating mitochondria.

Re-assessment - This child was re-examined 2½ years later. One year prior to the re-assessment, he had bilateral lengthening of tendo

calcaneus. Following the operation, his calf muscles returned to a normal size. He no longer walked on his toes and his gait was almost normal. He was able to climb stairs easily, but still tired more than other children. The hip abductors had improved in strength and were only slightly weak. General muscle strength remained unchanged. Balance was normal in all positions. He still had 5° hip flexion contractures and a marked hyperlordosis, but it was noticed that his mother had a similar posture, although not as exaggerated.

PERONEAL MUSCULAR ATROPHY
(PMA)

the left. Muscle strength was normal, with no evidence of fatiguing with progressive exercise. Balance and co-ordination were normal.

EMG - Muscles of the upper extremities were examined. Motor units were of normal size and duration and recruited normally on volition. There was some evidence of fatiguing of the facial muscles.

NCS - These were normal.

MJS - On repeated stimulation of the myoneural junction, there was fall-off of induced activity to below 20% of normal. Recovery was good. Response to intravenous edrophonium was reasonable at the peripheral level only.

Muscle tension studies - See Figs 4b and 5; and Tables 3 and 4.

Muscle biopsy - Specimens were removed from the deltoid muscle. Muscle histology was normal on the whole, with occasional evidence of a small fibre. Muscle histochemistry revealed a slight increase in the number of type 1 fibres. Motor nerve terminal and end-plate studies showed normal terminal branching and myelination. Many of the terminals were small and under-developed, while some tended to "ramble".

Re-assessment - When seen one year later, after the patient had been on a course of prednisolone for the entire period, results were found to be excellent. The patient no longer had diplopia, although blurring of vision did occur following long periods of reading or after the drinking of an alcoholic beverage. He did not tire in the afternoons any more, and no longer fell as he used to before treatment was started.

CASE 22 (A.S.)

Case 22, 36-year-old, white woman's disease commenced when she

CASE 9 (D.K.)

A 13-year-old, white boy presented with a five-year history of difficulty with his feet. When he was eight, his mother noticed that his toes had started curling inwards and that he subsequently started walking on his toes. He had great difficulty in running and unless he was very careful, would often fall. The mother also reported that his balance was poor and that this was especially marked when he rose in the mornings. Over the past year and a half, weakness had developed in his legs and the deformity had become worse. The family history revealed that one of the mother's sister's children had developed hammer toes, but this patient was not followed up.

On examination of the boy under discussion, it was found that there was pes cavus and marked wasting and weakness of the distal muscles of the lower limbs. Dorsiflexion of the right ankle was impossible, while on the left side he was able to initiate a contraction. Muscle strength of toe extension bilaterally was poor, while that of toe flexion was fair. There was also slight weakness of the plantarflexors of both feet and bilateral shortening of tendo calcaneus. The more proximal muscles of the lower extremities were slightly weak. The patient had a high-stepping gait and although he walked on the balls of his feet, when he put his foot down on the ground, the arches were flat. His gait was worse when he walked bare-footed. His balance in standing was poor. Apart from slight wasting and weakness of the small muscles of the hands, the upper limbs seemed normal. Reflexes were all absent and sensation was slightly diminished in the feet.

EMG - Muscles of the upper and lower extremities were examined. There was marked fall-out of motor-unit activity, almost resulting in a picture of single motor-unit activity in the peroneal group of muscles. There was evidence of denervation activity in the anterior tibial muscles and in several other muscles tested. A strength/duration curve of the right abductor pollicis brevis muscle showed a pattern of partial denervation.

NCS - Conduction velocities in the legs were dramatically reduced. Conduction in the right median nerve was slowed to 41 ms^{-1} .

Muscle tension studies - See Fig. 4a; and Tables 3 and 4.

Muscle biopsy - Specimens were removed from the peroneus brevis muscle. Histological and histochemical tests revealed large areas of grouped fibre atrophy affecting type 1 and type 2 fibres, the former being affected to a greater extent. Some small, angulated type 1 fibres were seen. Type 1 fibres showed targetoid formation and had a "moth-eaten" appearance. Motor nerve terminals showed excessive branching and shortening of internodal lengths. Motor nerve end plates varied markedly with respect to fibre size and shape.

Re-assessment - This patient was re-examined after $1\frac{1}{2}$ years. His high-stepping gait was not as exaggerated as before and balance had improved slightly. His mother had noticed the improvement in his balance and said that he did not fall as often as he used to. Muscle strength in the lower limbs had not altered but his upper limbs had become more involved. The small muscles of the hands were weaker and there was more proximal weakness of the upper extremities as well. Apart from having lost a lot of weight, his clinical picture was otherwise unchanged.

CASE 10 (R.D.)

This 14-year-old, white boy had first observed the abnormal appearance of his feet three years previously. His toes started splaying and he noticed that he had very high insteps. His main complaint was that he experienced pain in the knees. He was a very active, healthy young man who took part in many competitive sports. There was no family history of neurogenic disorder.

Physical examination showed some wasting of the lower extremities, which was more evident in the legs. Muscle power in the lower

extremities was generally good, except in the tibialis anterior and peroneal muscles, in which it was fair. This resulted in weakness of dorsiflexion, in- and eversion. Instability of his ankles was the most likely cause of pain in his knees. Knee flexion and extension were also slightly weak. His gait was normal, even though he had obvious pes cavus. All reflexes were present and equal. The upper extremities were normal and there was no palpable evidence of thickening of nerves. Sensation was normal.

EMG - Muscles of the upper and lower extremities were examined. In the lower limbs, particularly in the peroneal and anterior tibial muscles, there was increased polyphasic activity. No evidence of active denervation activity was detected.

NCS - These were within normal limits.

Muscle tension studies - See Fig. 4a; and Tables 3 and 4.

Muscle biopsy - Tissue was removed from the peroneus brevis muscle. Histology revealed increased variation in fibre size, while some of the smaller fibres showed an increase in the number of centrally orientated nuclei. Histochemical tests showed that most of the smaller fibres were of the type 1 variety. There was a tendency to minor grouping of both fibre types. The overall fibre type count showed a deficit of type 1 fibres. Motor nerve terminals showed increased branching, indicating denervation and re-innervation activity. There was increased variation in size of end plates.

Re-assessment - When the patient was re-examined 10 months later, his condition was found to have remained the same. He was still as active as before.

CASE 11 (A.L.)

A hypertensive, 50-year-old, white woman presented with a four-year history of progressive numbness and tingling in the feet and, to a lesser extent, in the hands. This was associated with weakness, particularly in the lower extremities. She experienced great difficulty climbing stairs and walking without shoes. She was unable to open bottles and frequently dropped objects because she could not maintain a firm grip. Questioning revealed that despite her participation in numerous sporting activities as a young girl, her lower extremities never developed properly and were always "tired". She also recalled having fallen quite often. There was a family history of neurogenic disorder in that her father and one of her sisters had experienced tingling in the hands.

On examination of the patient under discussion, there was wasting and weakness of both lower limbs, which was more marked distally, especially in the tibialis anterior and peroneal muscles, in which muscle strength was assessed as being fair. The patient had marked pes cavus and clawing of toes, with resultant limitation of toe extension. Her lower limbs were cold and the skin was mottled. Ankle reflexes were absent, while those of the knee, biceps and triceps were just obtainable. There was wasting of the small muscles of the hands and she had a weak grip. Sensation was diminished in a glove-and-stocking fashion. The patient walked with difficulty and an associated mild ataxia was present. Her balance was poor, especially in the kneeling and standing positions. Under stress, her condition deteriorated.

EMG - Muscles of both upper and lower extremities were tested. The extensor pollicis brevis muscles showed very little evidence of motor-unit activity, while the tibialis anterior muscles showed high-voltage polyphasic activity. The fall-out of motor-unit activity and high-voltage, polyphasic activity was evident in most muscles, particularly those situated more peripherally.

NCS - Conduction velocities in the legs were equally slowed to 24.5 ms^{-1} .

The right ulnar nerve conduction velocity was slowed to 24.5 ms^{-1} , while that of the right median nerve was normal. The response of the muscle to direct stimulation revealed a pattern of partial denervation.

Muscle tension studies - See Tables 3 and 4.

Muscle and nerve biopsy - Specimens were removed from the peroneus brevis muscle and nerve tissue from the sural nerve. Histology and histochemistry revealed large areas of grouped atrophy affecting both fibre types. The remaining, normal fibres were almost entirely of the type 1 variety. There was also an increase in the amount of fat and fibrous tissue. There was increased branching of motor nerve terminals. Motor end plates were abnormally diverse in size and shape. Cross-section of the sural nerve revealed depletion of the nerve population and shrinkage of the nerve in general.

Re-assessment - This patient was re-examined 2 years later. Apart from reported, infrequent recurrences of numbness in her hands and feet, sensation was normal. As a consequence, her gait had improved but she still had some difficulty in walking bare-footed or in shoes with very low heels. When wearing shoes with a 3.5 cm heel, her gait was almost normal. The mild ataxia was no longer evident. Although her general muscle strength remained unchanged, she found that she no longer dropped things as frequently as when the numbness had been present continuously. Otherwise, her condition had remained unaltered since the initial assessment.

CASE 12 (P.D.)

This slightly-built, 9-year-old, white boy apparently had normal early milestones but did not walk until approximately seventeen months of age. From the time he started walking, it was noticed that he had an abnormal gait, was knock-kneed and had flat feet. He was subse-

quently fitted with special shoes to correct the pes planus and genu valgum, but the underlying muscular problem was not detected. He wore the special shoes for two years. When he was 4½ years old his mother noticed that he had developed very high arches, was walking "pigeon-toed" and had slight clawing of the toes. As time progressed, clawing of the toes became worse; and it was not until recently that his condition was diagnosed as PMA. He had never been a strong child and although he played tennis and soccer at school, he could not kick the soccer ball properly. He was unable to run very fast because his feet tended to drag and he tired easily. He could not throw a cricket ball as far as other boys of his age. When he was tired, his handwriting became illegible. The family history was negative.

On examination, he had a slight Trendelenberg gait. The right lower limb showed some degree of internal rotation. Slight genu valgum was evident on both sides, as was mild, bilateral pes equinovarus. When standing, he had marked genu recurvatum. Muscle power was generally good, the left side of the body being more affected than the right. Muscle strength of the peroneal and anterior compartment groups of muscles was fair plus. Balance and co-ordination were normal. Tendon reflexes were reduced in the ankles. Sensation was slightly diminished in both hands.

EMG - Muscles of the lower extremities were tested. Motor-unit activity was of high voltage in the more distal muscles such as tibialis anterior, and there was some fall-out of motor-unit activity. This was the same in the peroneal group of muscles.

NCS - Nerve conduction velocities were normal.

Muscle tension studies - See Fig. 4a; and Tables 3 and 4.

Muscle biopsy - Specimens were removed from the peroneus brevis muscle. Histological study revealed scattered, isolated, atrophic muscle fibres. Muscle histochemistry showed early grouping of individual fibre types. Some type 1 fibres were morphologically abnormal. Motor nerve terminals

and end plates showed some increased variability in size and there was slight increase in branching of the former.

Re-assessment - When re-examined 1 year later, this child's condition had remained unchanged.

CASE 13 (I.daR.)

This short, overweight, 43-year-old, white woman complained of continuous pain in the right "arm". She had been told that when three weeks old, she had an operation on her right upper arm for what her mother had described as some lesion over the elbow, resulting in exudation of material from the middle of the upper arm. Pain was worst at the site of the operation and she experienced a "pulling" sensation on the dorsum of the right hand and wrist. She was unable to do any hard work and tended to drop objects because of weakness and rapid fatigue of her grip.

On examination, there was a scar and little fat over the lateral aspect of the right upper arm at the mid-shaft level of the humerus. A healed scar was present over the right elbow. Pain on palpation was most marked over the head of the radius and mid-biceps region on the right side. There was slight muscle wasting around the right shoulder girdle. As far as muscle strength is concerned, shoulder flexion and extension were good, while shoulder abduction was fair plus. Elbow flexion and extension were good and although at first the patient seemed to have a strong "power" grip, this fatigued quite rapidly. Otherwise, her general muscle strength appeared to be normal, although there was slight distal weakness in the upper and lower extremities. All tendon reflexes were absent. Peripheral pulses were present and equal. Sensation was normal.

EMG - Muscles of both upper extremities were examined. This showed a fall-out of motor-unit activity in most muscles tested, but was more

evident as the electrodes were placed distally. Remaining motor units tended to be of high voltage and polyphasic.

NCS - Nerve conduction velocities were very slow in all nerves tested, that in both the right median and left ulnar nerves being 15 ms^{-1} . The right ulnar nerve conduction velocity was 17.5 ms^{-1} , while that in the left median nerve was 16 ms^{-1} .

Muscle tension studies - See Fig. 4a; and Tables 3 and 4.

Muscle and nerve biopsy - Specimens were removed from the peroneus brevis muscle. Nerve tissue was taken from the lateral cutaneous nerve. Histological tests showed marked variation in fibre size. There was much single fibre atrophy. In some areas, grouped atrophy was seen. Histochemical examination revealed involvement of both fibre types, although type 2 fibres were more affected, many of these being small and angular. Type 1 fibres showed evidence of targetoid formation and had a "moth-eaten" appearance.

Study of the lateral cutaneous nerve showed some degenerating fibres as well as some very well-myelinated fibres. There was marked loss of fibres of intermediate size and reduction in the number of small myelinated fibres. Some "onion-peeling" was seen. There was an increase in the amount of collagen.

Re-assessment - When re-assessed 1½ years later, this patient's condition was unchanged.

CASE 14 (M.R.)

This tall 15-year-old, white girl's disease was first detected when she was about 8 years of age. Over the years, her condition became progressively worse and more incapacitating. Her main complaint was that she had difficulty in walking and running. Unless she

concentrated while carrying out these activities, she would trip and fall. She stated that she was unable to grip the ground with her toes as they were "curled inwards". She could not balance when wearing high-heeled shoes because her ankles were too weak, and she often tripped when going up or down stairs. She had not noticed any weakness in her hands and could perform all functional tasks involving the hands without any difficulty. Questioning revealed that at least five out of six known members of the family were affected to a varying extent by the same disease. The mother had high arches and although her muscle strength was normal, ankle and knee reflexes were absent.

On examination of the girl, there was marked, bilateral pes cavus and clawing of the toes. Dorsiflexion and eversion of the right ankle were slightly weak while on the left they were only fair. Flexion of the toes at the metatarsophalangeal joints and extension of the interphalangeal joints was poor. The small muscles of the hands showed evidence of slight wasting as well as slight weakness. When walking, there was marked pes cavus at the beginning of, and during mid-stance phase of gait, but this changed to an accentuated pes planus at the end of stance phase and "push-off" phase of gait. The patient could not run very fast without tripping and falling. During the entire gait cycle, her toes seldom touched the ground. Joint position sense was just within normal limits. Balance and sensation were normal. Knee and ankle jerks, and those in the upper extremities, were absent.

EMG - Muscles of both upper and lower extremities were tested. There was marked fall-out of motor-unit activity in the more distal muscles but no evidence of active denervation.

NCS - Nerve conduction studies revealed marked slowing in the legs. The right median nerve conduction velocity was dramatically slowed to 21 ms^{-1} .

Muscle tension studies - See Fig. 4a; and Tables 3 and 4.

Muscle and nerve biopsy - Muscle specimens were removed from the

peroneus brevis muscle. Nerve was taken from the anterior tibial nerve. Muscle histology showed marked variation in fibre size and numerous centrally orientated nuclei. Histochemistry revealed extensive grouping of fibres, the majority of these being of type 1 variety. Type 1 fibres showed targetoid formation and had a "moth-eaten" appearance. Several small, angulated, type 2 fibres were seen. Studies of the anterior tibial nerve revealed an overall loss of large and small myelinated fibres, most fibres being of intermediate size. There was an increase in endoneural space. Larger and smaller fibres showed "onion-peeling", typical of the hypertrophic type of PMA.

Re-assessment - The patient was re-assessed one year later. Two months following the biopsy, orthotics were fitted to both feet. She subsequently found that the toes on the right foot were relatively straight, whereas in the left foot there was little change. She could run far better when wearing the orthotics and had noticed a decrease in severity of pes cavus. She no longer tripped when going up or down stairs but was still unable to balance on a beam or wear high-heeled shoes. On examination, these reported findings were confirmed, although the patient's general gait pattern had not altered. Her right toes did touch the ground to a greater extent than before, but this was nevertheless still ineffective as far as gait was concerned. Functionally, she now had difficulty opening bottles and turning on taps. It was found that her upper extremities had become involved as a result of the disease process, particularly pronation and supination, muscle strength in both actions being only fair. There was marked deterioration in strength of the abdominal muscles and long toe extensors, both being poor. Hip abduction was good on the left side and fair on the right, but this did not appear to alter the original gait pattern. Otherwise, she had slight generalized weakness. Active and passive dorsiflexion of both ankles was limited by about 15° . Circulation in the feet and hands was poor and distinct cyanosis was present. The patient commented that during the winter months, the cyanosis was far worse. When taking a hot bath, she experienced tingling and a numb feeling in the feet, which lasted for approximately one minute. When sensation was tested, this was diminished in both legs; and the patient could not distinguish between sharp and blunt instruments. Response to heat and cold and light

and heavy touch were slightly abnormal. Sensation in the hands was normal, other than in the left fourth finger from the level of the proximal interphalangeal joint to the tip of the finger on both the dorsal and palmar surfaces. Joint position sense was just within normal limits, except for the left hallux, of which she was unable to tell the position at any time. Balance in standing was fair. Despite her disability, the patient was still able to play social tennis and had learnt to avoid activities with which she knew she could not cope.

CASE 15 (R.S.)

This lean, active, 17-year-old, white boy had not experienced muscular weakness until a trolley ran over his left ankle. His ankle had subsequently been very swollen. He noticed that he fell quite often and could not walk long distances. He was no longer able to play soccer but still swam and was very good at boxing. When he was younger, he had flat feet and wore special corrective shoes for 1½ years. There was no family history of neuromuscular disorder.

On examination, the patient was found to have slight wasting of muscles in both legs and a mild, bilateral pes cavus. His muscle strength was generally normal except for dorsiflexion and eversion of both ankles, which were fair plus. This weakness was more evident in the left leg than the right. Reflexes were present and equal on both sides. Balance and sensation were normal. Marked swelling of the left ankle was apparent.

EMG - Muscles of the lower extremities were examined. In the extensor digitorum brevis muscles, there was fall-out of motor-unit activity, and much of the remaining motor-unit activity was of high voltage and long duration. There was also fall-out of motor-unit activity in the tibialis anterior and peroneus longus muscles. In addition, the peroneus longus muscles showed evidence of denervation activity.

CASE 28 (A.K.)

This 32-year-old, Asian man had a muscle biopsy two years previously, following an adverse reaction of a family member (nephew) to the administration of halothane, while undergoing an operation for removal of an extra finger. Results of histological, histochemical and electron microscopical examination, together with a positive reaction to halothane, obtained during muscle tension studies, indicated that this patient was possibly a carrier of MH (Dr Isaacs, personal communication; original results and tracings not available). The serum CPK level was markedly raised.

On examination, there was thickening of the metacarpophalangeal joints of both hands and early "swan-necking" deformity of the fourth fingers. A distinct lisp was evident when the patient spoke; and hearing on the left side was defective. The patient was normal in respect of all other tests which were carried out during the assessment.

Muscle tension studies - The patient was given 8 mg/kg of oral sodium dantrolene four hours before the muscle biopsy was carried out, to examine the effect of this drug as a possible prophylactic measure when dealing with patients having MH. For results of muscle tension studies, see Tables 3, 4 and 5.

Muscle biopsy - Specimens were removed from the tibialis anterior muscle. Histology revealed the presence of many multinucleated fibres as well as single and small groups of atrophic fibres. Histochemical tests showed grouping of type 1 fibres.

Electron microscopy revealed large areas of loss of myofibrils, with some disorganization as far as orientation of fibres was concerned. There was some loss of Z-line banding. Mitochondria appeared in rows.

Re-assessment - The patient's condition had remained unchanged when he was re-examined three years later.

NCS - These were normal.

Muscle tension studies - See Fig. 4a; and Tables 3 and 4.

Muscle and nerve biopsy - Muscle samples were removed from the peroneus brevis muscle. Nerve tissue was taken from the sural nerve. Histology revealed widespread areas of grouped fibre atrophy. Many small, angulated fibres were present, as well as some hypertrophic fibres. Histochemical studies showed grouping of both fibre types. Hypertrophic fibres were of both the type 1 and type 2 varieties. Type 1 fibres showed targetoid formation and had a "moth-eaten" appearance. Sural nerve studies showed grouping of nerve fibres of the same size, as well as loss of fibres. Some fibres showed evidence of degeneration of myelin. There was no "onion-peeling".

Re-assessment - This patient was seen one year later. He went to the army one month after the biopsy had been carried out and was discharged 2 weeks later because he could not walk. On re-assessment, his muscle strength was found to have deteriorated. The patient explained that his upper limbs were weak and that he could no longer take part in sport. He fell far more often than before, and was unable to run very fast because he "tripped over his own feet". He could not skip. His left ankle was said to be permanently swollen and painful; and some days it was so bad that he was unable to walk. The patient also found that his left leg tired rapidly. On examination, there was marked wasting of both legs, especially on the left side. Slight wasting of the small muscles of the hands was also noted. He walked with a distinct limp and when weight-bearing on the left lower limb, he hyperextended the knee. Hyperextension of the knee was also seen in standing. He had a slight equinovarus deformity of the foot on the left when walking and most of the body weight was distributed on the lateral border of the foot. When he was tired, the equinovarus was accentuated and caused him to trip and fall. General muscle strength was slightly weak, with the exceptions of toe extension, which was poor; ankle dorsiflexion, eversion and plantarflexion, all of which were fair; elbow extension, which was fair; and adduction of the right index finger, which was zero. The left side

was always seen to be more affected than the right. Elbow and knee extension caused pain in the contracting muscles. Range of motion was full passively, but active extension of the hallux of both feet was limited and adduction of the right index finger was impossible (as mentioned above). Balance in standing and running was fair, but normal in all other positions. Sensation was slightly diminished on the left side, from the level of the clavicle downwards, including upper and lower extremities. Despite deterioration in muscle strength, the patient was still able to continue in his job as a boiler maker.

CASE 16 (A.V.)

A well-built, 16-year-old, white boy presented with a one-year history of trouble with his feet, which during that period had become progressively worse. He noticed that, like his father, he had very high arches and tended to walk on the "backs of his heels", which caused him to waddle when walking. He played rugby without any difficulty but found that in athletics he was unable to sprint.

Examination revealed marked pes cavus and hammer toes. There was bilateral thickening of the plantar surface of the forefoot. He had a waddling gait, resulting mainly from walking on the backs of his heels and lateral borders of his feet. He had an inadequate heel/toe action. Apart from dorsiflexion and eversion, which were slightly weak, his muscle strength was generally normal. There was no sensory loss and all reflexes were present and equal. His balance was normal, except that in running it was poor.

EMG - Muscles of both upper and lower extremities were examined. High-voltage, polyphasic activity was observed in the abductor pollicis brevis muscle and first dorsal interosseous muscle of the right hand, as well as in the tibialis anterior muscle on both sides. Activity in the more proximal muscles was normal.

NCS - Conduction velocities were normal, but the response of the lateral popliteal nerves to repetitive stimulation, failed to evoke an adequate muscle response to both dorsiflexion and eversion.

Muscle tension studies - See Figs 4b and 5; and Tables 3 and 4.

Muscle biopsy - Tissue was removed from the peroneus brevis muscle. Histologically, the muscle appeared to fall within normal limits of variation. Histochemistry revealed grouping of both fibre types, particularly type 1 fibres. Type 2 fibre atrophy was prevalent. Motor nerve end plates varied abnormally and there was evidence of increased branching of motor nerve terminals.

Re-assessment - The patient was re-examined two years later. One year prior to re-assessment, he had undergone an operation to lengthen the posterior tibialis muscles, in order to correct the pes cavus deformity. It was found that although this had corrected the deformity to some extent in the left foot, it had not been as successful on the right side. However, his gait had improved and he was consequently able to walk normally. He still had marked hammer toes and was unable to run very fast without falling. His condition otherwise remained unchanged.

MYASTHENIA GRAVIS
(MG)

CASE 17 (D.A.)

This 31-year-old, white woman had blurred and double vision from the age of eight. When she was eight years old, a "rheumatic condition" was diagnosed, as she was always ill and very tired. Four years ago, she had a general anaesthetic, following which she remained in what must have been a myasthenic coma, for four days. Subsequent to this, she developed progressive generalized weakness and dysphagia. More recently, in addition to her previous symptoms, she had experienced continuous diplopoea, ptosis and dyspnoea. It was not until then that a diagnosis of myasthenia gravis was made. Questioning revealed that she had a scoliosis, for which she wore a brace. Exercise made her dizzy and worsened her condition. Functionally, she was very restricted as she could not maintain a strong grip for any length of time and, as a consequence, dropped things regularly. At times, especially when very tired, she had difficulty swallowing and developed severe ptosis and diplopoea. If she talked for long periods, she "lost her voice". She could only climb a few stairs before becoming extremely weak and dyspnoeic. Occasionally, she would spend up to four days in bed, owing to extreme fatigue. The family history was negative.

On examination, this lean woman had constant diplopoea, which was more marked when she looked downwards. She had slight dyspnoea at rest, but with active exercise this became markedly worse. There was evidence of ptosis, and following the assessment her voice had become so quiet that it was difficult to hear what she was saying. Muscle strength was fair in the trunk, but otherwise generally good, although she fatigued very rapidly. Balance in sitting and standing was poor. Reflexes were brisk and equal on both sides.

EMG - Muscles of the upper and lower extremities were examined. Motor-unit activity was normal.

NCS - These were normal.

MJS - On repetitive stimulation of the myoneural junction, there was a

fall-off of induced activity to below 50% of normal.

Muscle tension studies - See Figs 4b and 5; and Tables 3 and 4.

Muscle biopsy - Samples were removed from the deltoid muscle. Muscle histology and histochemistry revealed normal muscle. Motor nerve terminals showed irregular myelinization and axonal branching.

Re-assessment - This patient was re-assessed 1½ years later. She had undergone thymectomy eight months prior to the examination. Generally, her muscle strength had remained unchanged, although she did not fatigue as rapidly, and no longer spent periods of several days in bed as she used to before the operation. She no longer dropped objects as often as previously and seldom experienced any difficulty in swallowing. Her voice was much stronger, although it still became faint after long periods of speaking. Improvement in diplopoea, dyspnoea and ptosis was only slight.

CASE 18 (J.B.)

This 34-year-old, white housewife gave a five-year history of diplopoea, generalized muscle weakness and numbness. Her condition was originally diagnosed as neurosis and treated accordingly. She became progressively worse until finally, a diagnosis of myasthenia gravis was made. She was treated with pyridostigmine; and at the time of assessment was taking excessively high doses in order to be able to lead a relatively normal life. When she did not take pyridostigmine, weakness was so severe that eventually she became bedridden and completely lost sensation in the hands and feet. She experienced difficulty in carrying out all daily activities, owing to rapid fatigue and dyspnoea, and was forced to rest at regular intervals before she could continue with her chores. She had no appetite and as a consequence had lost 16 kilograms in one year. At times she had difficulty keeping her eyes open

and when tired, she developed both diplopoea and dysphagia. Prior to the onset of her disease she was an active person: she had played badminton and swam a lot. There was no family history of thyroid or neuromuscular disease.

On examination, this ill-looking woman was observed to have generalized wasting of muscles. When walking, she had a slight limp and was unable to walk in shoes with high heels. Muscle strength of the neck flexors and extensors, shoulder girdle and pelvic girdle regions was fair, while in the rest of the body it was generally good. However, her muscles fatigued rapidly and she could not walk further than approximately 100 metres at a time, following which she became very weak and dyspnoeic and had to lie down. Her vital capacity was 2.4 litres. She was unable to hold her arms above her head for longer than 5 seconds, with the result that her functional activities were extremely limited. Sensation over the entire body was slightly diminished, a deficiency which was more marked on the left side of the body than on the right. She also had numbness around the eyes and mouth. Tendon reflexes were hyper-reactive, while cutaneous responses were normal.

EMG - Muscles of the upper extremities were examined. Motor units were found to be excessively polyphasic in many areas, particularly in more proximal muscle groups. Recruitment was generally normal but excessive fatiguing was noted during isometric contraction.

NCS - These were normal.

MJS - Repetitive stimulation of the myoneural junction yielded evidence of abnormal fatiguing. Administration of 10 mg of edrophonium intravenously resulted in considerable improvement in muscle strength and eye movements.

Muscle tension studies - See Figs 4b and 5; and Tables 3 and 4.

Muscle biopsy - Specimens were removed from the deltoid muscle. Histology and histochemistry revealed atrophy of single fibres, as well as

some small areas of grouped atrophy involving both fibre types. Motor nerve terminal study showed increased branching. Motor end plates had an elongated and dysplastic appearance.

Re-assessment - This patient was re-assessed 1½ years later. Her thymus gland had been removed 2 months after the biopsy. She claimed that she was completely normal for a period of 7 months following the thymectomy. Thereafter, her previous signs and symptoms slowly started recurring. She again took increasingly high doses of pyridostigmine; and at the time of re-assessment, she was taking dangerously high doses. Her general muscle strength was found to be almost normal. She still fatigued rapidly and had all the previous signs and symptoms, but these were not as severe as before. The only marked improvement was in sensation, which was now normal.

CASE 19 (J.T.)

A diagnosis of myasthenia gravis had been made 8 years previously in the case of this obese, 44-year-old, white woman when she had presented with generalized muscle weakness, difficulty in swallowing, slurring of speech and diplopoea. For some time her disease was fairly well controlled with pyridostigmine, but over the years she became progressively worse and had to take increasing amounts of the drug in order to alleviate her symptoms. Despite the excessively high doses of pyridostigmine, she was still weak at the time of assessment. She was unable to lift a kettle of water and because of rapid fatiguing of muscles, could not even comb her hair properly. She had been an active woman but could no longer take part in any sport, as exercise increased the rapidity with which she weakened. Her condition was worse in the afternoons and evenings, when in addition to weakness (which also affected the facial muscles), she experienced severe diplopoea, slurring of speech and dyspnoea, the latter even being evident when she woke in the mornings. This patient had also suffered from hypothyroidism for ten years; but it had been well controlled. Questioning revealed a

history of thyrcid disease in the family.

On physical examination, the patient's general muscle strength was found to be fair plus. However, her muscles fatigued rapidly, not only with repetitive exercise, but also while performing a particular exercise for the first time. In the latter case, the rate of fatiguing was dependent on the degree of resistance, and duration of the exercise. She had constant double vision, which was particularly marked when she looked downwards or to the left. Her vital capacity was markedly reduced (to 1.3 litres). Balance reactions were slow in both standing and sitting. Sensation was slightly diminished on the left side of the body. There was evidence of hyperreflexia.

EMG - Muscles of the upper extremities were examined. There was increased polyphasic activity of fairly high voltage in proximal muscle groups. It disappeared at the level of the deltoid muscle and was evident again in the extensor muscles of the forearm and small muscles of the hand. A fairly positive Jolly test was obtained following repeated stimulation of the orbicularis oculi muscles.

NCS - These were normal.

MJS - Abnormal muscle fatigue was observed on rapid, repeated stimulation of the myoneural junction.

Muscle tension studies - See Fig. 4b; and Tables 3 and 4.

Muscle biopsy - Specimens were removed from the deltoid muscle. Histology revealed scattered loss of individual muscle fibres and some variation in fibre size. Muscle histochemistry was normal. Motor nerve terminals showed the usual degree of branching. The end plates, however, were abnormal in that many were hypoplastic and elongated, with a tendency to "ramble".

Re-assessment - The patient was seen one year later. Six months

previously, a thymectomy had been carried out and she had not been taking any drugs since. During the operation, the phrenic nerve was accidentally cut. This resulted in paralysis of the left side of the diaphragm. The patient was given intensive physiotherapy and her breathing subsequently improved. However, she still had some difficulty when swimming, playing sports, climbing stairs and following intensive exercise. She no longer tired to the same extent as before and was again playing tennis and golf. Speech, vision and swallowing were normal. When tested, her muscle strength was normal, with no evidence of muscle fatigue.

CASE 20 (M.M.)

Six months previously, this 53-year-old, white woman had noticed that she developed double vision during the course of the day (but had normal vision in the mornings). This lasted ten days. Three weeks before she sought medical advice diplopoea recurred: again it only became evident with fatigue. There was no family history of neuromuscular disease.

On examination, excessive fatiguing of the superior recti muscles was observed, particularly on the right side. On looking upwards, the patient became giddy; and as a consequence could no longer play tennis. Although not a very strong woman, her muscle strength was normal.

EMG - Muscles of the upper extremities were examined. There was increased polyphasic activity, particularly in the more proximal muscles.

NCS - These were normal.

MJS - On repetitive stimulation fatiguing was noticed only in the facial muscles. Eye muscle movements improved markedly when 10 mg of edrophonium was given intravenously.

Muscle tension studies - See Figs 4b and 5; and Tables 3 and 4.

Muscle biopsy - Tissue was removed from the deltoid muscle. Scattered atrophy of muscle fibres was demonstrated histologically. Histochemical investigation revealed that both type 1 and type 2 fibres were atrophic. Motor nerve terminals did not show any evidence of excessive branching but internodal distances appeared somewhat shortened. Motor end plates were normal.

Re-assessment - This patient refused treatment; and when seen two years later, her condition had deteriorated. Questioning revealed that she was always tired and at times had difficulty in keeping her eyes open. Diplopoea was constant and aggravated by fatigue. She noticed that she could not talk very loudly when tired. On examination, lateral deviation of the left eye was observed. The patient said that this became worse when she was tired. Muscle strength was good but with some evidence of muscle fatigue on repetitive exercising.

CASE 21 (J.G.)

A 27-year-old, white man first experienced periodic blurring of vision ten years earlier. This occurred following long periods of study and disappeared with rest. Over the ensuing years his condition became progressively worse until the time he was first examined, when double vision was occurring during two periods of the day - in the afternoon and early evening. These times corresponded with fatiguing of his eye muscles. He became very tired in the afternoons and frequently fell asleep at work. When he was tired, he noticed that he became clumsy and would fall quite often. He was a very active man, who played squash and sailed. There was no family history of neuromuscular disease.

On assessment, it was noticed that the patient had a nasal tone of voice. He had double vision, particularly when looking up to the right and down to the right; as well as blurring of vision on lateral gaze to

PERONEAL MUSCULAR ATROPHY
(Charcot-Marie-Tooth disease)

Peroneal muscular atrophy (PMA) is a slowly progressive, hereditary neuropathy, primarily affecting the anterior horn cells, peripheral nerves and nerve roots (Hughes and Brownell, 1972). It is inherited as either an autosomal dominant (more common) or autosomal recessive trait (Dyck and Lambert, 1968a). Although the disease was originally thought to commence mainly in childhood and adolescence, a number of studies have shown that there is considerable variation in the age of onset. PMA has a predilection for the muscles innervated by the peroneal nerve, leading to weakness and wasting of these muscles. Hence the derivation of the name, peroneal muscular atrophy.

PMA is characterized by predominantly distal weakness and wasting, the most common initial symptom being some form of gait abnormality and/or foot deformity such as pes cavus, equinovarus, pes planus or hammer toes (Brust *et al.*, 1978). The lower extremities are usually affected to a greater extent than the upper extremities. As the disease progresses, more proximal muscle groups become involved and weakness and wasting of the intrinsic muscles of the hands, forearms and upper arms occurs. The clinical severity varies considerably and the classical "inverted champagne bottle" legs are often not evident (Dyck, 1975). In fact, in many instances, patients remain remarkably free of any serious disability until very late in life. Sensory abnormalities are often encountered, these being more severe peripherally (Table 6).

Various classifications of peroneal muscular atrophy have evolved since the description of the syndrome in 1886 by Charcot and Marie in France and Tooth in England; and these have remained a matter of controversy ever since. Dyck and Lambert (1968a,b) proposed the first systematic classification based on combined clinical, genetic, electrophysiological and pathological studies. They defined two main types of PMA: the hypertrophic form (PMA and Dejerine-Sottas subgroups), which showed nerve hypertrophy, demyelination and reduced nerve conduction velocities; and the neuronal type, in which there was no nerve hypertrophy, and nerve conduction velocities were normal or only slightly slower than normal, but with a characteristic loss of large nerve fibres

developed ptosis and intermittent diplopoea seven months before she was seen in a clinical situation. She complained that more recently she had begun choking when eating or drinking, had constant blurring of vision, slurred speech, and pains and weakness in her upper and lower extremities. She said that objects dropped out of her hands because she had a weak grip, as a result of which she was unable to perform her normal daily chores. Her condition was worse at the end of the day, at which time all symptoms became exaggerated. There was a family history of diabetes, but no evidence of this in the patient.

On examination, general muscle strength was good. However, the patient fatigued rapidly and as a consequence had to rest at regular intervals. She had drooping of the eyelids, which rapidly became worse on sustained, upward gazing. Double vision resulted when she looked sideways or upwards. Speech was slurred. Reflexes were all present and equal. Sensation was normal.

EMG - Muscles of the upper extremities were examined. Slightly increased polyphasic activity was seen in the deltoid and biceps muscles. Many of the motor units were of high voltage.

NCS - These were normal.

MJS - Abnormal fatiguing was seen when the myoneural junction was repeatedly stimulated.

Muscle tension studies - See Fig. 4b; and Tables 3 and 4.

Muscle biopsy - Tissue was removed from the deltoid muscle. All tests carried out were within normal limits.

Re-assessment - This patient was examined one year later. Ten months before this she had a thymectomy, following which she developed angina pectoris. Her general condition had deteriorated; with the exception of drooping of the eyelids, which was not evident when she was examined.

Diplopoea had become a constant feature, while dysphagia occurred more frequently. Pain and weakness in the limbs was more marked and she now fell quite often. She commented that owing to severe breathlessness, she was unable to walk more than 100 metres. On re-assessment, the legs were seen to be swollen and the hands and feet were blue. Sensation was diminished in the lower extremities. Following the examination, she was very dyspnoeic.

CASE 23 (H.F.)

A healthy-looking, athletic, 23-year-old, white man gave a two-year history of double vision. Questioning revealed that the condition became worse when he was tired and that at times he noticed drooping of the eyelids, which seemed to result in double vision on downward gazing as well as on upward gazing to the left. He had also found that reading for long periods resulted in deterioration of the diplopoea. He had not noticed any change in the tone of his voice after long periods of speaking, and there was no dysphagia. He took part in athletics, squash and tennis and had never found that he fatigued more rapidly than other (normal) males of his age. He complained that until he obtained an appropriate medical certificate, he was not allowed to continue in his occupation as a pilot; and in the meantime had to be content with being a co-pilot.

On examination, his muscle strength was found to be normal and no abnormal fatiguing was noted.

EMG - Muscles of the upper extremities and face were tested. The motor units were of normal size and duration and recruitment was normal on volition. Repetitive stimulation of the orbicularis oculi muscle revealed a positive Jolly test on the right side.

NCS - These were normal.

MJS - The myoneural junction in the abductor pollicis brevis muscle fell just below normal limits when repetitively stimulated. Double vision improved to some extent after administration of 10 mg of edrophonium intravenously.

Muscle tension studies - See Fig. 4b; and Tables 3 and 4.

Muscle biopsy - Specimens were removed from the deltoid muscle. Muscle histology and histochemistry were within normal limits. Motor nerve terminals showed a slight increase in branching, and myelin was a little thickened and irregular. Motor end plates showed some variability, which was slightly in excess of that normally found.

Re-assessment - This patient was seen 2 years later. He had been taking prednisolone ever since the biopsy; and the dosage was, at the time of re-assessment, slowly being reduced. He still had slight double vision when he was tired or had been doing a lot of reading. Generally, his condition had improved markedly.

CASE 24 (L.M.)

This medium-built, 35-year-old, white man presented with generalized muscular weakness, diplopoea and difficulty in chewing and swallowing, despite relatively high doses of pyridostigmine. He had a low tone of voice which became accentuated when he was tired. He fatigued rapidly and as a consequence had difficulty with normal functional activities such as brushing his teeth, combing his hair and climbing stairs. He was no longer able to continue in his job as a motor mechanic. His condition was far worse at the end of the day, by which time he had severe pain in his back. He often could not finish a meal as his jaw muscles became so tired that he could not chew his food. There was no family history of thyroid or neuromuscular disease.

On examination, muscle strength in outer range of movement was

generally fair plus, although in his hands it was good. However, his muscles fatigued so rapidly that he was unable to raise his arms above his head and could not climb more than two stairs before having to sit down in order to recover. Balance in all positions was fair and sensation was normal. Respiration was not affected in any way. Tendon reflexes were hyper-reactive, while cutaneous responses were normal. Diploopia was most evident when the patient looked upwards and to the right.

Muscle tension studies - See Fig. 4b; and Tables 3 and 4.

Muscle biopsy - Tissue was taken from the deltoid muscle. Apart from a slight increase in the number of type 1 fibres muscle appeared normal. Nerve was normal.

Re-assessment - This patient had a thymectomy soon after biopsy and was re-examined 2½ years later. The thymectomy was followed by a six-week course of radiation therapy. Recovery was slow and only commenced twelve weeks post-operatively. When re-assessed, his muscle strength was normal, with little evidence of fatigue when performing repetitive exercises. Other than slight weakness of knee extension when he did not take pyridostigmine, this man was completely normal and had resumed all his previous activities.

CASE 25 (A.V.)

This 69-year-old, retired, white gentleman presented with severe muscular pains which mainly affected the proximal muscle groups of the upper extremities. Seven years prior to this he had experienced severe diploopia accompanied by muscle weakness. A thymectomy was carried out following which his vision and muscle strength returned to normal. Three years later, he had a recurrence of symptoms and was given pyridostigmine, which he had been taking ever since. This helped considerably,

although it did not cure either the diplopoea or weakness. More recently, he had developed muscular pains which were thought to be caused by the pyridostigmine. There was no family history of neuromuscular disease.

On examination, there was found to be some wasting of muscles. This was most evident in the lower extremities, particularly in the proximal muscle groups. Muscle strength in the lower limbs was good, with some muscle fatigue following repetitive exercises. Strength of the upper limbs could not be adequately assessed, because of intense pain suffered by the patient. Eye movements were defective.

EMG - Muscles of the upper extremities were examined. Motor units in the more proximal muscles were excessively polyphasic. The response to isometric contraction showed early onset of fatigue tremor.

NCS - These were normal.

MJS - Unfortunately, the patient had taken pyridostigmine two hours prior to the test, with the result that there was no evidence of fatigue on repetitive stimulation.

Muscle tension studies - See Figs 4b and 5; and Tables 3 and 4.

Muscle biopsy - Specimens were removed from the deltoid muscle. Muscle histology and histochemistry revealed scattered, singly occurring, atrophic fibres as well as occasional groups of two or three atrophic fibres. In addition, histochemical staining showed that atrophy involved both fibre types. Motor nerve terminal study revealed excessive branching of terminals; and motor end plates showed excessive variability. Many of the end plates had the typical hypoplastic, long-branching appearance seen in myasthenia gravis.

Re-assessment - This patient was re-examined 2 years later. He had been taking prednisolone for 2 years. When examined, his eye movements were normal and he no longer had double vision. Muscle strength was

normal.

CASE 26 (M.G.)

This worried-looking, 43-year-old, white housewife had an eight-year history of myasthenia gravis, which had first commenced following a hysterectomy. On the fifth day after the operation, she developed severe double vision and marked, generalized, muscular weakness. This was treated with neostigmine, with fairly good results. Recently, double vision had recurred. It became worse when the patient was tired, at which time she also developed drooping of the eyelids. During the day she noticed that she became progressively weaker and was often forced to sleep for a few hours in order to regain her strength. As a result of the development of fatigue and inco-ordination, she frequently dropped objects and consequently could not perform her normal, daily household chores effectively; and, at times, not at all. She occasionally had difficulty in swallowing and tended to aspirate fluids. She had a low tone of voice but had never lost her voice completely. She was a known case of porphyria but was well informed as to how to control this illness. The family history was negative.

On examination, the patient developed double vision when she looked upwards, and particularly if she looked to the left. Muscle strength was normal, but on repetitive, resisted exercise she fatigued rapidly. Reflexes were generally depressed but equal.

EMG - Muscles of the upper extremities and face were examined. Motor-unit activity was generally within normal limits, although some increased polyphasic activity was noted in more proximal muscles. Repeated stimulation of the orbicularis oculi muscle revealed a positive Jolly test.

NCS - These were normal.

MJS - No abnormal fatiguing was noted on repetitive stimulation.

Muscle tension studies - See Figs 4b and 5; and Tables 3 and 4.

Muscle biopsy - Tissue was removed from the deltoid muscle. Histological studies revealed normal muscle structure, although occasional, scattered, atrophic fibres were seen. Muscle histochemistry results were again within normal limits, apart from there being a slight increase in the number of type 1 fibres. Motor nerve end plates were normal, but with some evidence of increased branching of nerve terminals. Myelin deposition in nerve terminals was very irregular.

Re-assessment - This patient was re-examined 2 years later. She had been treated with prednisolone for a period of 20 months. She no longer developed weakness during the day and as a result had been able to resume her normal household activities. Muscle strength was normal. Although she still became tired with repetitive exercise, fatigue now developed slowly. Double vision and slight ptosis occurred infrequently and only when she was very tired. She was completely independent and was again able to drive her car.

STIFF MAN SYNDROME
(SMS)

CASE 27 (Z.M.)

A shy, 8-year-old, black girl had an 18-month history of progressive muscle stiffness and spasms affecting the trunk and limbs. The disease apparently commenced with symptoms in the trunk and proximal limb muscles and gradually spread to the distal limb musculature, the spasms becoming more painful and intense, resulting in physical incapacitation. Intellectual development of the child was normal. There was no previous history of any serious illness and the family history was "negative".

On examination, this frightened, emaciated girl was lying in a position of opisthotonus, although when seen one day later, she was in an almost completely flexed position. However, spasms were predominantly extensor in nature and were continuous when she was awake. The spasms were aggravated by external stimuli such as noise, skin contact, emotional stimuli and active or passive movement of the limbs. In view of this, muscle strength could not be assessed. Cutaneous and deep reflexes were also difficult to test because muscular spasm was constantly present; and because of severe extensor spasm, which occurred in response to tactile stimuli. The hands were usually held in a flexed position, with strong opposition of the thumbs. Passive range of motion of all joints was normal except for dorsiflexion of the right ankle, which was limited by approximately 20°. This was tested during general anaesthesia at the time of muscle and nerve biopsy. Sensation appeared to be normal. The facial and oropharyngeal muscles and muscles of mastication were unaffected by the disease. The patient was, for the most part, mildly pyrexial, owing to the continuous muscle activity. Her temperature, however, varied according to the state of muscular contraction.

EMG - Spontaneous motor-unit activity of normal amplitude and duration, involving both agonists and antagonists, was observed at rest. This activity was aggravated by emotional disturbance, touch and movement. Voluntary muscle contraction in one area caused diffusion of contraction to all muscles, both agonists and antagonists. There was no denervation activity.

NCS - Conduction velocities in both motor and sensory nerve fibres were normal.

Muscle tension studies - See Figs 4b and 5; and Tables 3 and 4.

Muscle and nerve biopsy - Specimens were taken from the vastus lateralis muscle. A piece of the sural nerve was removed. Muscle histology and histochemistry did not reveal any abnormalities.

Sural nerve biopsy findings were normal.

Electron microscopy showed that there were areas of myofilamentous and Z-line disruption as well as of mitochondrial accumulation. Many of the mitochondria were distended and their cristae were ruptured. There was swelling of the SR as well as loss of myofibrils.

Re-assessment - The only available re-examination information concerning this child was that obtained four weeks following commencement of treatment, because soon after that, the patient's mother removed her from hospital; and she was not subsequently seen or heard of. During the four-week period in hospital she was given high doses of diazepam. This had a variable, but beneficial effect on the spasms. She also received physiotherapy daily, this having involved mainly the use of the neurodevelopmental treatment (Bobath) method. On re-examination, there was still a considerable amount of spasm, which limited all functional activities - except for movement of the arms when the child was lying in a partially flexed position and rolled over in order to change her position. However, the contracture of the right ankle was not as marked as before.

MALIGNANT HYPERTHERMIA
(MH)

CASE 29 (O.M.)

This healthy, 20-year-old, coloured man was one of ten children, of whom three had died from hyperthermia during anaesthesia. All three patients had died while undergoing relatively simple, uncomplicated operations - hysterectomy, removal of thyroglossal cyst and excision of a semimebranous bursa. In each case (except the last mentioned who was given methoxyflurane instead of halothane), the anaesthetic agents used were all of the following: thiopentone, nitrous oxide/oxygen, succinylcholine and halothane. The CPK serum enzyme levels of sixty-four members of the family were subsequently determined. The patient under discussion was one of many members found to have an abnormally high CPK level, this being 466.3 units.

On examination of this active patient, he was found to be clinically normal, with no evidence of weakness or any muscular disorder.

Muscle tension studies - See Figs 4b and 5; and Tables 3, 4 and 5.

Muscle biopsy - Tissue was removed from the deltoid muscle. Histological and histochemical studies demonstrated that muscle was normal on the whole.

Electron microscopy revealed a slightly folded basement membrane and occasional areas showing loss of filaments.

Re-assessment - On re-assessment one year later, the patient was found to have remained unchanged since the original examination.

CASE 30 (C.P.)

The younger brother of this 6-year-old, white girl died while undergoing a minor operation. The cause of the boy's death was initially considered to have been haemorrhage; but it was later confirmed that he

died as a result of malignant hyperthermia. On a previous occasion, he reacted adversely to an unknown anaesthetic when having four teeth extracted. There was, in addition, a history of severe headaches and muscle cramps. At times, the muscle cramps were so intense that he would scream and arch his back from the pain. He also suffered from regular bleeding from the nose. Questioning revealed that the father was similarly prone to muscle cramps. There was no previous history of anaesthetic deaths in the family. The young girl in question had previously undergone surgery (to correct a squint) without incident, although the anaesthetic agents used were not known. She too, like her father and brother, frequently experienced muscle cramps, although these were not as intense as they had been in her brother's case. Her serum CPK level was markedly raised.

On examination, this slender girl had an obvious squint of the left eye, owing to inadequate activity of the left lateral rectus muscle. Apart from this, all other observations and tests showed nothing abnormal.

Muscle tension studies - See Tables 3, 4 and 5.

Muscle biopsy - Specimens were removed from the deltoid muscle. Histological findings were basically normal, although the average size of the fibres was smaller than usual. Muscle histochemistry revealed areas of limited extent where there was grouping of individual fibres, particularly of the type 1 variety.

Electron microscopy showed that there were regions of myofilament disarrangement, some filaments lying at right angles to adjacent ones. Large areas of contracted muscle having very little structure, were seen. Some myofibrils had a banded pattern, with accompanying loss of myofilaments. In parts, the Z lines appeared smeared and widened. There were also areas of myofibrillar depletion, which was usually accompanied by an increase in number of mitochondria, especially evident at the basement membrane. The basement membrane was folded in places.

Re-assessment - When the patient was seen 2½ years later, no change was detected.

A P P E N D I X 3

SYNOPSIS OF SELECTED NEUROMUSCULAR DISORDERS

SPINAL MUSCULAR ATROPHY

The spinal muscular atrophy (SMA) syndrome is the collective name for a heterogenous group of genetically determined disorders (Emery, 1971; Bunday and Lovelace, 1975). They are characterized by degeneration of the anterior horn cells of the spinal cord and, sometimes, the cranial nerve motor nuclei; but with no evidence of pyramidal tract or peripheral nerve involvement (Byers and Banker, 1961).

Various attempts have been made to classify the spinal muscular atrophies, but much confusion still prevails. Recently, Pearn (1980) added yet another "suggested" classification of the SMA's, in which peroneal muscular atrophy (see next disease discussed) was not distinguished as a separate disease. Dubowitz and Brooke (1973) divided the SMA's into three broad categories on the basis of clinical severity. This provided a practical approach to the classification of SMA on the basis of: a severe form (Werdnig-Hoffmann's disease), a mild form (Kugelberg-Welander syndrome) and an intermediate form. The severe, Werdnig-Hoffmann's disease, having an early infantile onset and rapidly progressive course, leads to death usually within the first year of life, as a result of marked intercostal weakness and susceptibility to respiratory infections. There is generalized hypotonia and often an associated bulbar weakness, with difficulty in swallowing and a weak cry. Tendon reflexes are absent. The legs are more severely affected than the arms and these children are never able to sit without support. Children with the intermediate form usually have normal early milestones and can sit unsupported. However, they are unable to walk or stand, the legs being affected to a greater extent than the arms. Fasciculations, particularly of the tongue, may be seen. Scoliosis is a common complication in this group (Schwentker and Gibson, 1976; Galasko, 1977; Benady, 1978), as are joint contractures (Benady, 1978). Tendon reflexes are reduced or absent and there may be intercostal weakness. The prognosis in this group depends very much on the state of the respiratory function. Weakness in the mild, Kugelberg-Welander syndrome is confined mainly to the proximal muscles of the lower limbs but ambulation is achieved. Affected persons have a waddling gait and in this respect very much resemble patients with limb-girdle muscular

dystrophy. The Kugelberg-Welander syndrome is usually non-progressive, although in some cases deterioration may occur over long periods of time. Occasionally, there may be a rapid decrease in muscle strength. Some cases, however, appear to improve with time, probably as a result of compensatory reinnervation of muscle. Another feature observed, and one not unlike that occurring in the early stages of Duchenne muscular dystrophy, was hypertrophy of the calf muscles (Kugelberg and Welander, 1956). This has subsequently been seen by many authors in both the intermediate and Kugelberg-Welander types of SMA. Hypertrophy of the calf muscles appears to be more prevalent in males (Bouwsma and van Wijngaarden, 1980).

Muscle biopsy findings in the severe and intermediate forms of SMA are very similar. Large groups of atrophic type 1 and type 2 fibres are seen in all biopsies, although, unlike other forms of neurogenic atrophy in which angulated fibres are common, the majority of atrophic fibres in SMA are circular (Figs 9, 10). Pyknotic nuclear clumps may be observed in the atrophic fibres, while the presence of central nuclei is uncommon. Interspersed with atrophic bundles are fascicles containing markedly hypertrophied fibres (Fig. 10). However, the extent of atrophy and hypertrophy varies greatly; and when numerous sections from one muscle specimen are examined, some may be found to contain normal fibres, while others may have both atrophic and normal or hypertrophic fibres in varying proportions. Large bands of fibrous tissue surrounding fascicles are often seen. An increased number of muscle spindles may also be observed. In the mild forms of SMA (Kugelberg-Welander syndrome), smaller groups of atrophic fibres are present, and angulated fibres are common. Giant fibres do not occur as frequently in the severe and intermediate forms, although enlarged fibres are plentiful (Fig. 7). The enlarged fibres show fibre type grouping, with type 2 fibre predominance a common feature. Central cores, target fibres (Fig. 8) and "whorled or coiled fibres", seldom seen in the severe or intermediate forms of SMA, are often observed in the mild forms (Dubowitz and Brooke, 1973).

EMG findings are typical of denervation.

Motor nerve conduction velocity studies have shown that in infants

suffering from the severe form of SMA, conduction is slow, while velocities in children affected to a lesser degree with SMA are normal or fast (Moosa and Dubowitz, 1976; Schwartz and Moosa, 1977). Most reports in the literature have emphasized that in SMA there is no sensory involvement, although a few cases with reduced sensory nerve conduction velocities have been described, the more recent ones by Marshall and Duchon (1975) and Schwartz and Moosa (1977).

It has been found that the acute, rapidly progressive, infantile form of SMA is a clinically and genetically distinct entity from the rest (Lubowitz, 1977a). The separate existence of chronic forms of late childhood and juvenile SMA's, often collectively known as the Kugelberg-Welander syndrome, has remained a matter of controversy. However, although the age of onset of Kugelberg-Welander syndrome is usually in adolescence, some papers report its appearance for the first time in adult life (Meadows et al., 1969; Emery et al., 1976a; Pearn et al., 1978a).

The mode of inheritance of the various chronic SMA's has been described as autosomal recessive, autosomal dominant and sex-linked recessive (Emery, 1971; Furukawa and Toyokura, 1976), although geneticists are still debating how many genes there actually are for each of the different variants. Emery et al. (1976b) and Pearn et al. (1978b) concluded that in the majority of the more chronic forms of SMA (excluding those of adult onset), an autosomal recessive gene(s) was responsible for the condition, with only a small group of cases being inherited as a trait for which a dominant gene(s) is responsible. In SMA of adult onset, at least three separate genes (autosomal recessive, autosomal dominant and X-linked recessive) appear to be involved (Pearn et al., 1978a). At present, however, agreement concerning the type of inheritance has only been reached with regard to acute, Werunig-Hoffmann's disease, which is caused by an autosomal recessive gene (Pearn et al., 1973; Pearn, 1978).

Figure 7. Mild form of spinal muscular atrophy. Case 4.

Biopsy specimen shows marked variation in fibre size and scattered atrophy of fibres. A slight increase in the number of centrally orientated nuclei and an increase in amount of fibrous tissue are evident.

(H & E; x 320)

Figure 8. Mild form of spinal muscular atrophy. Case 4.

Grouping of individual fibre types is seen. Type 1 fibres show targetoid formation and have a "moth-eaten" appearance.

(NAD; x 320)

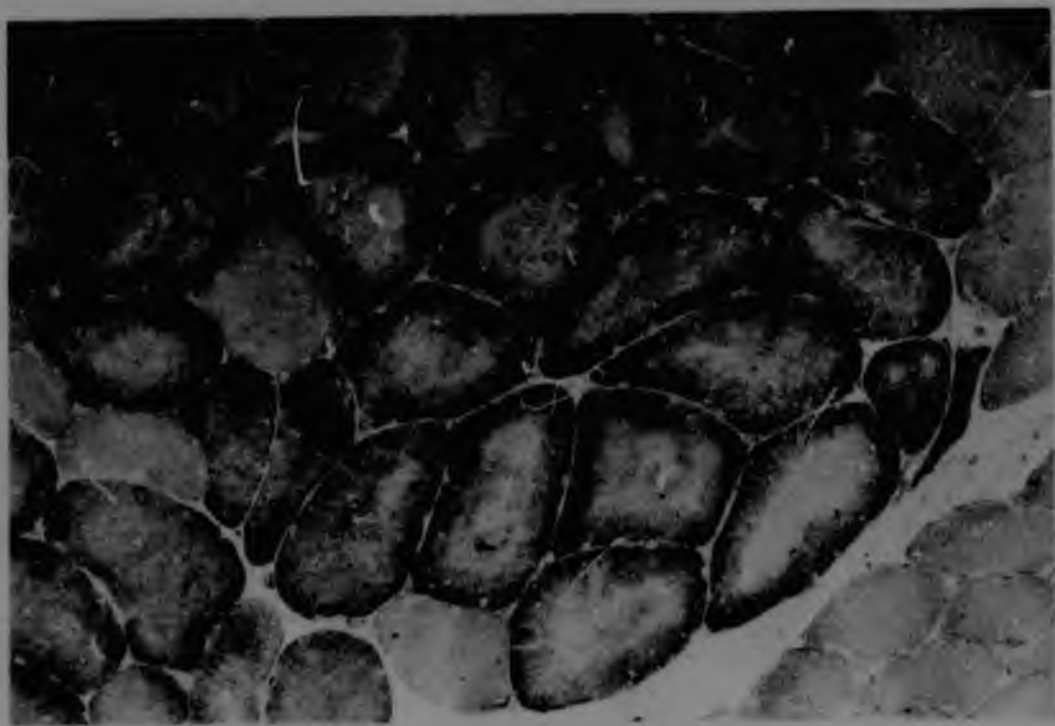
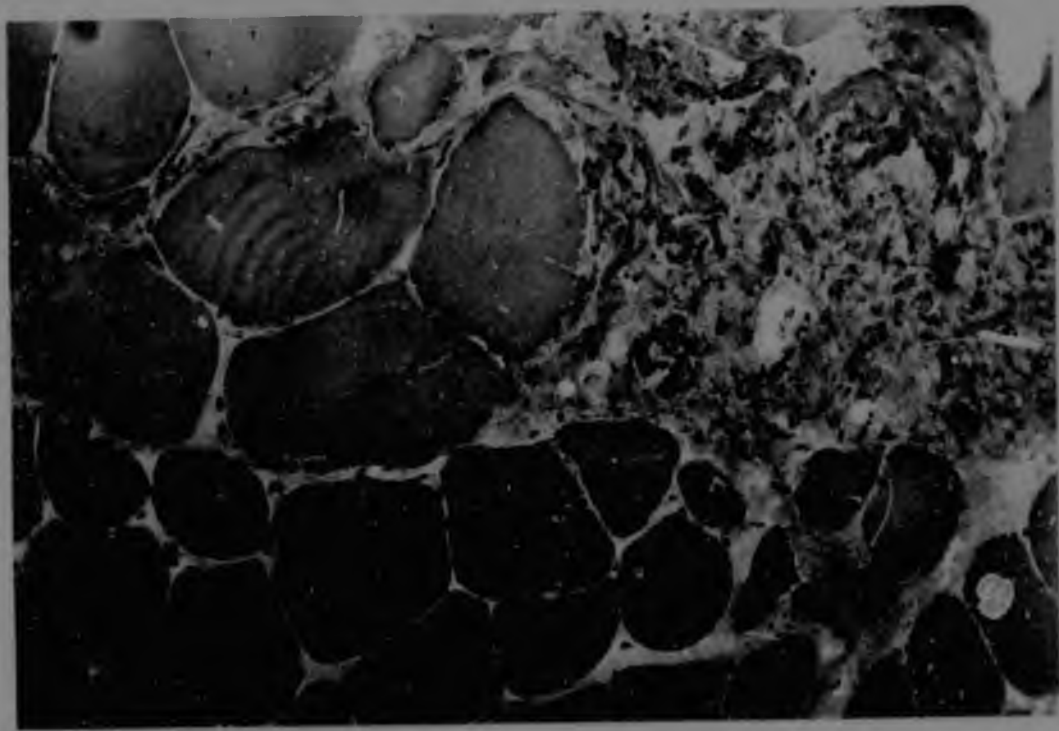


Figure 9. Intermediate form of spinal muscular atrophy.
Case 6.



Marked grouping, particularly of type 1 fibres, is observed; and type 1 fibres tend to be small. Several type 1 fibres also have an irregular shape and "moth-eaten" appearance.

(NAD; x 320)

Figure 10. Intermediate form of spinal muscular atrophy.
Case 6.

There is marked grouping, particularly of type 1 fibres. Many of these tend to be small and circular in shape. Some hypertrophic type 1 and type 2 fibres are present.

(ATPase, preincubated at pH 4.3; x 320)



Recent relevant literature on spinal muscular atrophy not cited in text
or references

1. Fredericks, E.J. & Russman, B.S. (1979). Bedside evaluation of large motor units in childhood spinal muscular atrophy. Neurology, Minn. 29: 398-400.
2. Guinter, R.H., Hennried, L.S. & Kaplan, A.M. (1977). Infantile neurogenic muscular atrophy with prolonged survival. J. Pediatr. 90: 95-97.
3. Hashimoto, O., Asada, M., Ohta, M. & Kuroiwa, Y. (1976). Clinical observations of juvenile nonprogressive muscular atrophy localized in hand and forearm. J. Neurol. 211: 105-110.
4. O'Sullivan, D.J. & McLeod, J.G. (1978). Distal chronic spinal muscular atrophy involving the hands. J. Neurol. Neurosurg. Psychiat. 41: 653-658.
5. Pearn, J.H. (1978a). Autosomal dominant spinal muscular atrophy. A clinical and genetic study. J. neurol. Sci. 38: 263-275.
6. Pearn, J.H. (1978b). Incidence, prevalence, and gene frequency studies of chronic childhood spinal muscular atrophy. J. med. Genet. 15: 409-413.
7. Pearn, J.H. & Hudgson, P. (1978). Anterior-horn cell degeneration and gross calf hypertrophy with adolescent onset. A new spinal muscular atrophy syndrome. Lancet 1: 1059-1061.
8. Ryniewicz, B. & Pawińska, M. (1978). Preliminary immunological studies in spinal muscular atrophy. Eur. J. Pediatr. 128: 57-60.
9. Skre, H., Mellgren, S.I., Bergsholm, P. & Slagsvold, J.E. (1978). Unusual type of neural muscular atrophy with a possible X-chromosomal inheritance pattern. Acta neurol. scand. 58: 249-260.

found in biopsy tissue of the sural nerve (Table 7). In addition, a third (rare) spinal type was distinguished, characterized by the absence of sensory impairment or nerve enlargement, and with normal nerve conduction velocities. This sub-division differed from those of Humberstone (1972), Salisachs (1974), Marsden (1975) and Davis *et al.* (1978). Dyck (1975) proposed a more advanced nomenclature, but at present the three-type classification of hypertrophic, neuronal and spinal (Behse and Buchthal, 1977; Buchthal and Behse, 1977) appears to be the most convenient for diagnostic purposes. Many other disorders have been reported in association with PMA, the better recognized ones being tremor (Salisachs, 1976; Buchthal and Behse, 1977), ataxia (Thomas *et al.*, 1974; Brust *et al.*, 1978), spastic paraparesis (Dyck and Lambert, 1968b) and optic atrophy (McLeod *et al.*, 1978).

Muscle biopsy findings may include the presence of: small angulated fibres (Fig. 13), grouping of atrophic fibres (Fig. 11), pyknotic nuclear lumps and central nuclei, all of which are characteristic of the many denervating diseases. Grouping of atrophic fibres affects both the type 1 and type 2 varieties. Type 1 fibre predominance may also be observed (Fig. 14). Changed cytoarchitecture in respect of, for example, target, targetoid and "moth-eaten, whorled" fibres is more prevalent in PMA than in other types of neuropathies (Fig. 12). A striking feature of PMA, as compared with other chronic peripheral neuropathies, may be the presence of hypertrophic type 1 fibres, these being quite common (Dubowitz and Brooke, 1973).

EMG studies demonstrate the presence of denervation.

TABLE 6. Clinical sensory changes in the three types of peroneal muscular atrophy.

TYPE	% patients with sensory loss	
	Buchthal and Behse (1977)	Brust <i>et al.</i> (1978)
Hypertrophic ..	70%	78%
Neuronal	90%	57%
Spinal	0%	0%

TABLE 7. Sural nerve biopsy findings in the three types of peroneal muscular atrophy.

Hypertrophic†	Neuronal*	Spinal
†Numerous onion-bulb formations present Signs of extensive demyelination and remyelination †Marked increase in size of endoneurial space †Extensive loss of both large and small myelinated fibres	Onion-bulb formations virtually absent and seen only under the electron microscope Demyelination and remyelination absent or rare Endoneurial space normal or only slightly enlarged Loss of large myelinated nerve fibres only (main abnormality)	All nerve biopsy findings normal

* Based on information in Behse and Buchthal, 1977.

† See Figure 15.

Figure 11. Peroneal muscular atrophy. Case 15.

Biopsy revealed large areas of grouped fibre atrophy. Many small, angulated fibres, and some hypertrophic fibres are seen.

(H & E; x 320)

Figure 12. Peroneal muscular atrophy. Case 9.

Type 1 fibres show targetoid formation and have a "moth-eaten" appearance. A few small, angulated type 1 fibres are to be observed.

(NAD; x 1280)

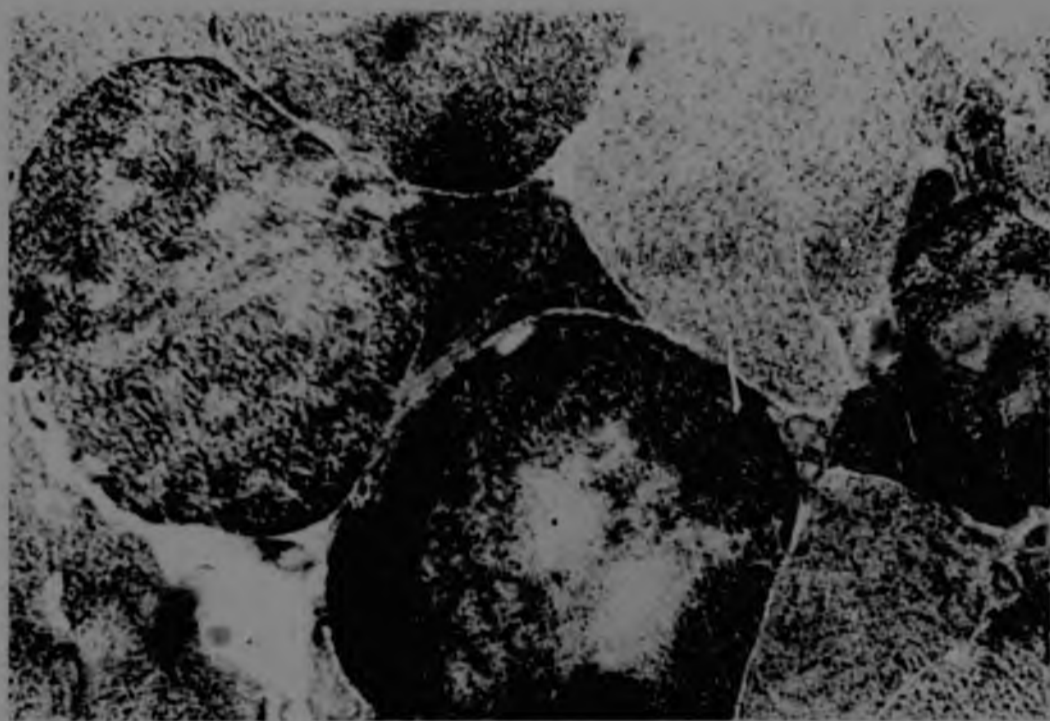
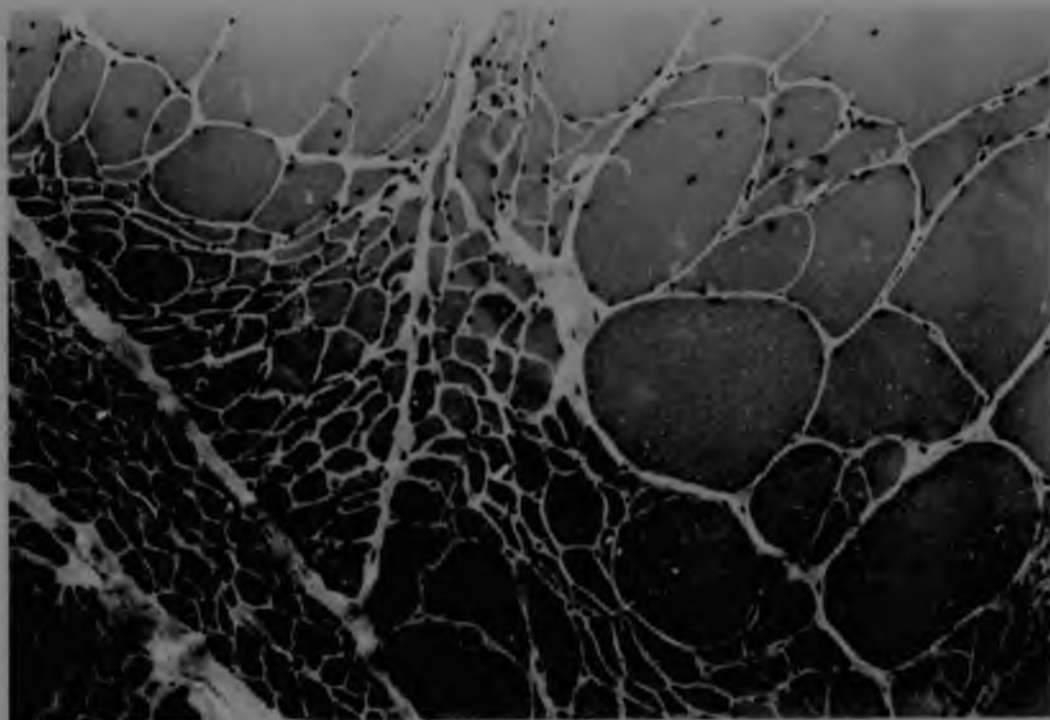


Figure 13. Peroneal muscular atrophy. Case 14.

There is extensive grouping of type 1 fibres.
Several of the type 2 fibres are small and
angular.

(Routine ATPase, pH 9.4; x 320)

Figure 14. Peroneal muscular atrophy. Case 14.

Marked grouping of type 1 fibres can be seen.

(EDTA/ATP; x 320)

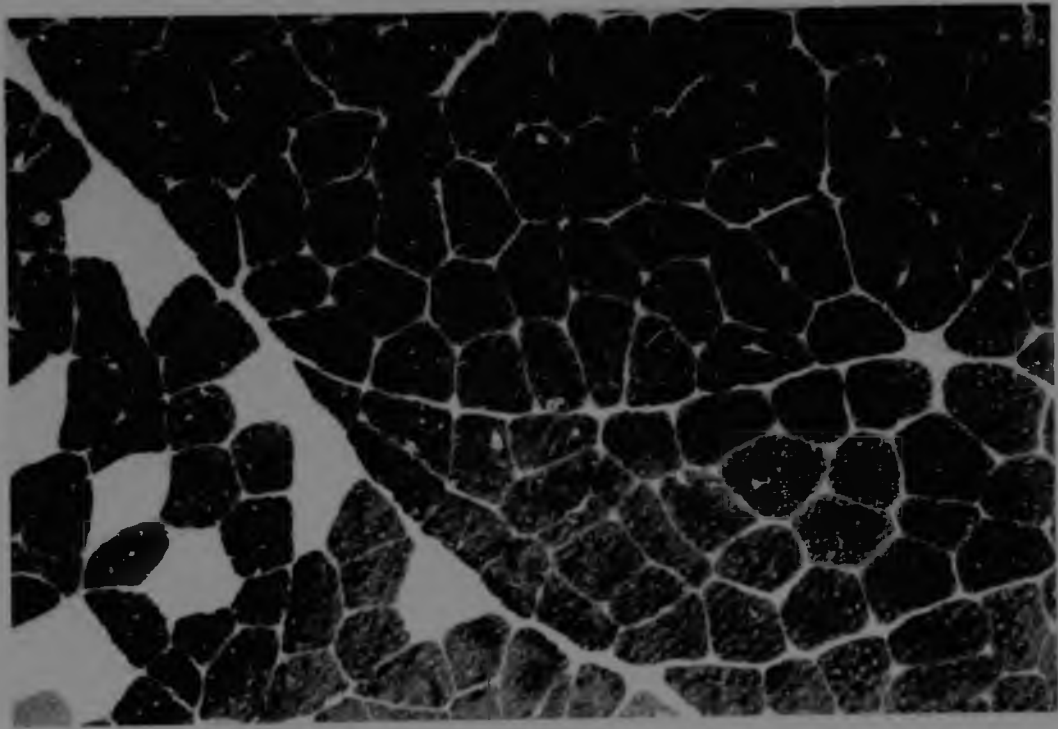
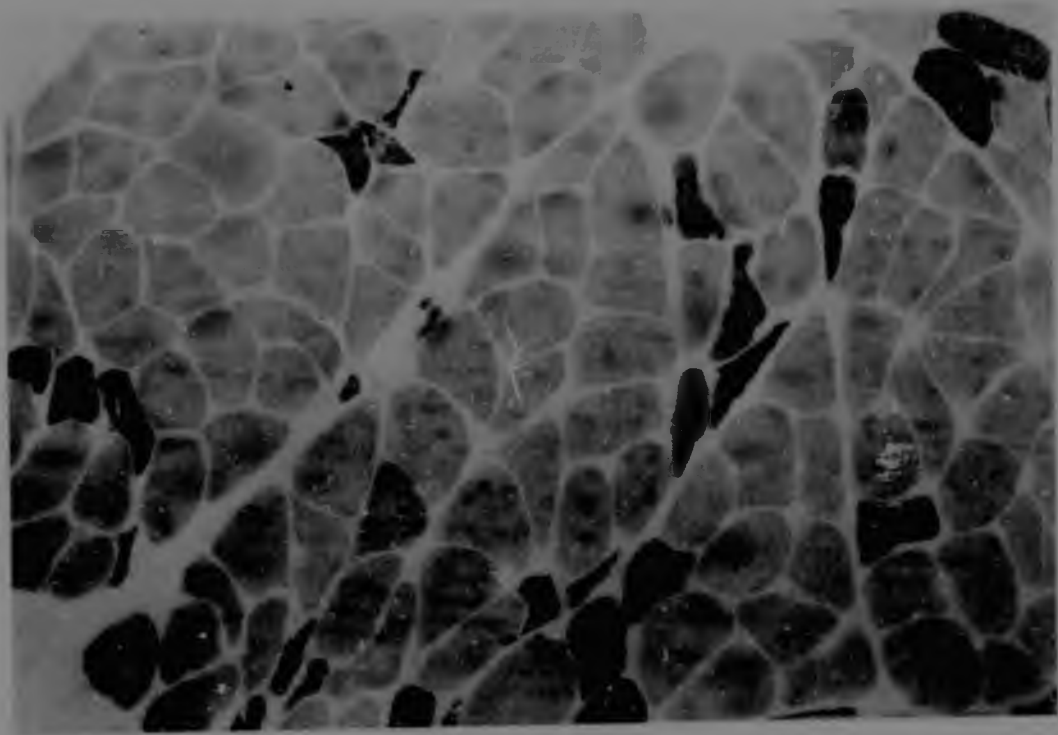
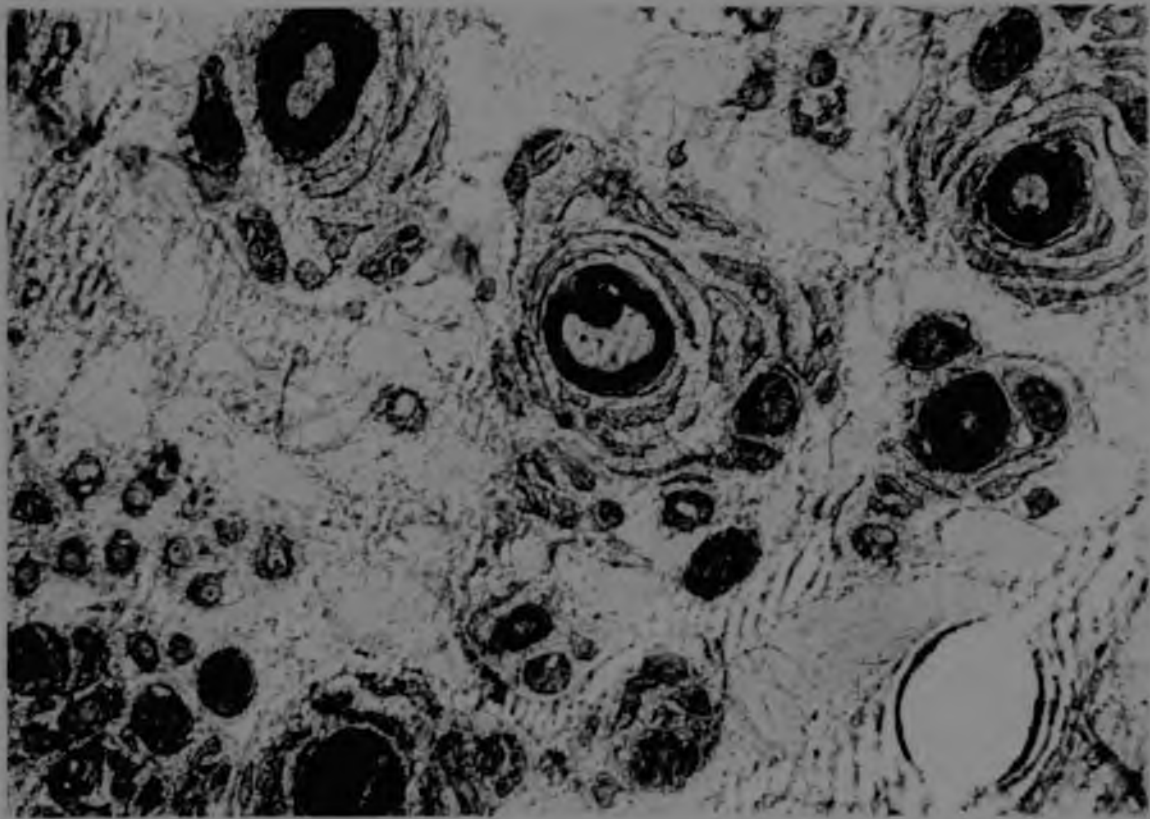


Figure 15. Hypertrophic form of peroneal muscular atrophy.
Case 14.

Electron micrograph of a section through the anterior tibial nerve, showing loss of large and small myelinated nerve fibres. An increase in endoneural space is evident, as well as "onion-peeling" of both larger and smaller nerve fibres.

(x 2000)



Recent relevant literature on peroneal muscular atrophy not cited in text or references

1. Bird, T.D. & Kraft, G.H. (1978). Charcot-Marie-Tooth disease: data for genetic counseling relating age to risk. Clin. Genet. 14: 43-49.
2. Bradley, W.G., Madrid, R. & Davis, C.J.F. (1977). The peroneal muscular atrophy syndrome. Clinical, genetic, electrophysiological and nerve biopsy studies. Part 3. Clinical, electrophysiological and pathological correlations. J. neurol. Sci. 32: 123-136.
3. De Weerd, C.J. (1978). Charcot-Marie-Tooth disease with sex-linked inheritance, linkage studies and abnormal serum alkaline phosphatase levels. Eur. Neurol. 17: 336-344.
4. Harding, A.E. & Thomas, P.K. (1980). Hereditary distal spinal muscular atrophy. A report on 34 cases and a review of the literature. J. neurol. Sci. 45: 337-348.
5. Madrid, R., Bradley, W.G. & Davis, C.J.F. (1977). The peroneal muscular atrophy syndrome. Clinical, genetic, electrophysiological and nerve biopsy studies. Part 2. Observations on pathological changes in sural nerve biopsies. J. neurol. Sci. 32: 91-122.
6. Melgaard, B. & Zilstorff, K. (1979). Central vestibular involvement in peroneal muscle atrophy: a preliminary report. Ann. Neurol. 5: 118-120.
7. Probst, A., Ulrich, J., Kaeser, H.E. & Heitz, P. (1977). Scapulo-peroneal muscular atrophy. Full autopsy report. Unusual findings in the anterior horn of the spinal cord. Lipid storage in muscle. Eur. Neurol. 16: 181-196.
8. Salisachs, F. & Lapresle, J. (1977). Argyll-Robertson-like pupils in the neural type of Charcot-Marie-Tooth disease. Eur. Neurol. 16: 172-175.

9. Spector, R.H., Lawton Smith, J. & Chavis, P.S. (1978). Charcot-Marie-Tooth disease mimicking ocular myasthenia gravis. Ann. Ophthalm. 10: 1033-1036.
10. Vasilescu, C. & Florescu, A. (1977). Motor and sensory conduction velocity in Charcot-Marie-Tooth disease. J. Neurol. 214: 305-312.
11. Waxman, S.G. & Ouellette, E.M. (1979). Ultrastructural and cytochemical observations in a case of dominantly inherited hypertrophic (Charcot-Marie-Tooth) neuropathy. J. Neuropath. exp. Neurol. 38: 586-595.
12. Williams, L.L. (1979). Pyruvate oxidation in Charcot-Marie-Tooth disease. Neurology, Minneap. 29: 1492-1498.
13. Williams, L.L. & Penn, G.M. (1979). Selective IgA deficiency in Charcot-Marie-Tooth disease. Am. J. clin. Path. 72: 800-806.

MYASTHENIA GRAVIS

Myasthenia gravis (MG) is a neuromuscular disorder which was first described by Willis in the seventeenth century. It is characterized by weakness and abnormal fatigue of skeletal muscles, which becomes worse following muscular activity and improves with rest. The prevalence of this syndrome is thought to be 2 - 10 per 100,000, with the onset occurring before age 20 in approximately 20% of cases.

The initial clinical manifestations are frequently ocular. Variable ptosis and/or external ophthalmoplegia with diplopoea are the most common early complaints (Mattis, 1941). In nearly all cases, the ocular muscles are ultimately affected. Occasionally the disease remains confined to the extraocular muscles, this condition being known as ocular myasthenia. The oropharyngeal muscles are often also involved, causing difficulties in respect of swallowing, chewing and prolonged speech. Characteristically, the voice becomes nasal initially and later slurred, with syllable retardation and decreased amplitude. However, any muscle may be affected first by the disease. Other muscles that may be involved include: (1) the face muscles, leading to loss of facial expression; (2) the respiratory muscles (intercostal muscles and diaphragm), in which case respiratory distress or failure can result; and (3) any of the limb muscles, which causes disabilities such as difficulty in keeping the arms outstretched or rising from a chair (proximal muscles being affected to a greater extent than distal groups). (4) There can be weakness of the neck and trunk muscles, resulting in poor posture.

For many years, it was thought that the principal abnormality in MG lay in the presynaptic nerve terminals of the neuromuscular junction (Elmqvist *et al.*, 1964). It was not until the discovery of two neurotoxins, α -bungarotoxin and α -cobra toxin (derived from certain snake venoms), which bind specifically to acetylcholine receptors (Lee, 1972), that the identification of the acetylcholine receptor abnormality in MG was elucidated. More recent evidence has indicated that the basic physiological defect occurs as a result of reduction in the number of available acetylcholine receptor sites at the neuromuscular end-plate

region (Fambrough et al., 1973; Berder et al., 1975, 1976; Engel et al., 1977a). It has been suggested that this receptor deficit is due to an autoimmune response, in which an inflammatory or tumorous process within the thymus gland could cause exposure of acetylcholine receptor proteins (found in normal thymic myoid tissue and similar to those in muscle) to thymic lymphocytes. This, in turn, could subsequently cause anti-acetylcholine receptor antibodies to be produced, capable of cross-reacting with peripheral acetylcholine receptor proteins, and thus preventing acetylcholine from gaining access to acetylcholine protein receptors on the postsynaptic muscle membrane. This would result in a sub-threshold end-plate potential of insufficient magnitude to produce a muscular contraction (Simpson, 1960).

Recently, several authors have reported the presence of acetylcholine receptor antibodies in 85% - 93% of patients with MG (Lindstrom et al., 1976; Mittag et al., 1976; Lefvert et al., 1978; Oda et al., 1980). The antibody titre corresponded to some extent with clinical severity (Bradley et al., 1978; Lefvert et al., 1978): low titres were found in mild or purely ocular MG, following thymectomy or in patients receiving immunosuppressive therapy; and high titres in more severely affected patients. Pathological changes of the thymus have been found in 75% - 82% of patients with MG. Of these, approximately 85% showed thymic hyperplasia, while between 8% and 15% had associated thymomas (Seybold et al., 1950; Castleman, 1966; Namba et al., 1976). Thus, both humoral* and cell-mediated** immune reactions have been implicated in the pathogenesis of MG. However, the mechanism by which the immune response to acetylcholine receptor is initiated is still uncertain, although a persistent viral infection of the thymus has been suggested (Datta and Schwartz, 1974; Tindall et al., 1978).

MG sometimes occurs in association with other disorders, often with an autoimmune basis. The ones more commonly encountered are rheumatoid arthritis (Simpson, 1960) and various thyroid abnormalities

* Acetylcholine receptor antibody production - Almon et al., 1974; Alarionov et al., 1975; Namba et al., 1976.

** Thymoma/hyperplasia leading to the production of lymphocytes - Abramsky et al., 1975; Richman et al., 1979.

(Osserman et al., 1967).

MG can be classed in three broad categories: adult myasthenia; juvenile myasthenia; and myasthenia occurring in the newborn. The adult and juvenile types are very similar in both clinical picture and pathogenesis. The adult form can occur at any age, although it is more commonly seen in younger patients, often in their twenties, and is more prevalent in females. Another form, appearing in later life, is more common in males. The latter group is often associated with thymomas, while individuals of the former group usually have thymic hyperplasia. In juvenile myasthenia, the first symptoms always appear after one year of age, with 75% of cases occurring after the age of ten (Millichap and Dodge, 1960). Girls are more frequently affected than boys and approximately 20% of cases have a complete and permanent remission of symptoms. Another, rare form of juvenile myasthenia occurs in children between the ages of 2 and 10 (Lieberman 1942; Bastedo, 1950). In this fulminating form, there is an acute bulbar paralysis which progresses rapidly to dyspnoea and cyanosis within 24 hours. If not treated promptly, the condition can be fatal.

MG in the newborn is sub-divided into: transient neonatal, congenital and familial infantile myasthenia; and acetylcholinesterase deficiency. Transient neonatal myasthenia, in which a transitory weakness lasting 5 - 47 days occurs, is found in 12% of babies born to myasthenic mothers. The cause is thought to be the result of diffusion of acetylcholine receptor antibody from the mother through the placenta (Keesey et al., 1977). However, results from a study by Lefvert et al. (1978) led to the suggestion that additional factors, besides a passive transfer of maternal receptor antibodies, may contribute to this form of MG. Weakness is usually evident within the first few hours of birth, the most frequent clinical feature being difficulty in feeding, although generalized hypotonia and facial weakness are also common. Only one case of transient neonatal myasthenia followed by the juvenile form has been reported (Osserman, 1958). Congenital MG is clinically apparent at birth or shortly thereafter and occurs in 1% of cases of mothers with MG. It appears to be genetically inherited, males being affected more often than females. The most prominent feature of this type of MG is involvement of the extraocular muscles, which is frequently

accompanied by facial weakness. It is generally non-progressive, although mild fatiguing of muscles, progressing to generalized weakness, has been reported in some cases. Familial infantile myasthenia, like congenital myasthenia, also has a high familial incidence. Severe respiratory and feeding difficulties occur at birth, but the extraocular muscles remain unaffected. There is a tendency for spontaneous remission to occur, although a subsequent recurrence of apnoea is not uncommon. Acetylcholinesterase deficiency, a "new" myasthenic syndrome, has been recorded only once (Engel *et al.*, 1977b). Ptosis was evident at 5 days of age. There was progression within one year to intermittent strabismus and muscle fatigue on exertion. All tests for myasthenia were negative and anticholinesterase drugs had no effect. At age 11, respiratory distress was seen to accompany a cold; and at 14, there was evidence of an associated bulbar palsy. Numerous investigations revealed small nerve terminals, decreased acetylcholine release, and a deficiency in the amount of end-plate acetylcholinesterase. Although antiacetylcholinesterase and guanidine did not improve the condition, prednisone had a beneficial effect.

Limb-girdle myasthenia occurs in adolescence and is characterized by rapid onset of proximal weakness but with no involvement of the extraocular muscles (McQuillen, 1966). In addition, several "myasthenic" syndromes have been described which resemble true myasthenia gravis in clinical picture. These include malignancy (Eaton-Lambert syndrome; although this may occasionally occur in the absence of malignancy), collagen vascular disease (such as systemic lupus erythematosus and rheumatoid arthritis), and the effects of certain antibiotics and botulism.

It will be evident from the above synopsis that prompt diagnosis and treatment of myasthenia is essential. In some types, this may have a life-saving effect. Diagnosis is usually established by means of an "edrophonium test" and EMG studies. A positive "edrophonium test", observed in true myasthenic patients, occurs when muscle strength and respiratory function are substantially improved by the intravenous injection of edrophonium (Osserman, 1958). Characteristic EMG findings, observed with repeated motor nerve stimulation, show a progressive decrease in amplitude of muscle action potentials (Özdemir and Young,

1976). Thymomas can be detected by several means. Keesey et al. (1980) have suggested that a combination of chest radiography, computed tomography of the thorax and antistriational antibody tests be used for purposes of diagnosis.

Muscle biopsy, which only demonstrates changes secondary to those occurring at the neuromuscular junction, may supply additional information (Figs 16, 17). Focal atrophy of type 2 fibres (Fig. 17), not seen in other illnesses, is found in over 50% of patients with myasthenia (Dubowitz and Brooke, 1973). However, atrophy of type 1 fibres is also sometimes present (Fig. 17); in which case the condition cannot be differentiated from that of denervation. Lymphorrhages have also been observed (Engel and McFarlin, 1966).

Electron microscopic studies of the neuromuscular junction in MG have revealed a decrease in both the mean nerve terminal area and the area of postsynaptic membrane per nerve terminal. The postsynaptic membrane is simplified, the secondary synaptic clefts being shallower, widened and more disorganized than in a normal end plate (Engel and Santa, 1971). Postsynaptic regions denuded of their nerve terminal, have also been observed (Santa et al., 1972).

Treatment of MG includes the administration of anticholinesterase drugs such as pyridostigmine; steroid therapy, for example the use of prednisone; and thymectomy. Plasma exchange, used in conjunction with immunosuppressive drugs, has been found to be of great value in the treatment of an acute myasthenic crisis (Dau et al., 1977; Pollard et al., 1980; Samtleben et al., 1980). All these forms of treatment have a variable effect. There is controversy in the literature concerning the response to surgery, and it is still uncertain whether or not all patients with MG should undergo thymectomy. It should be noted that Jenkins et al. (1975) have shown that besides the normal indication for thymectomy in patients who have an associated thymoma, early thymectomy is also beneficial in improving the rate of remission in patients with MG who have no associated thymoma.

Figure 16. Myasthenia gravis. Case 18.

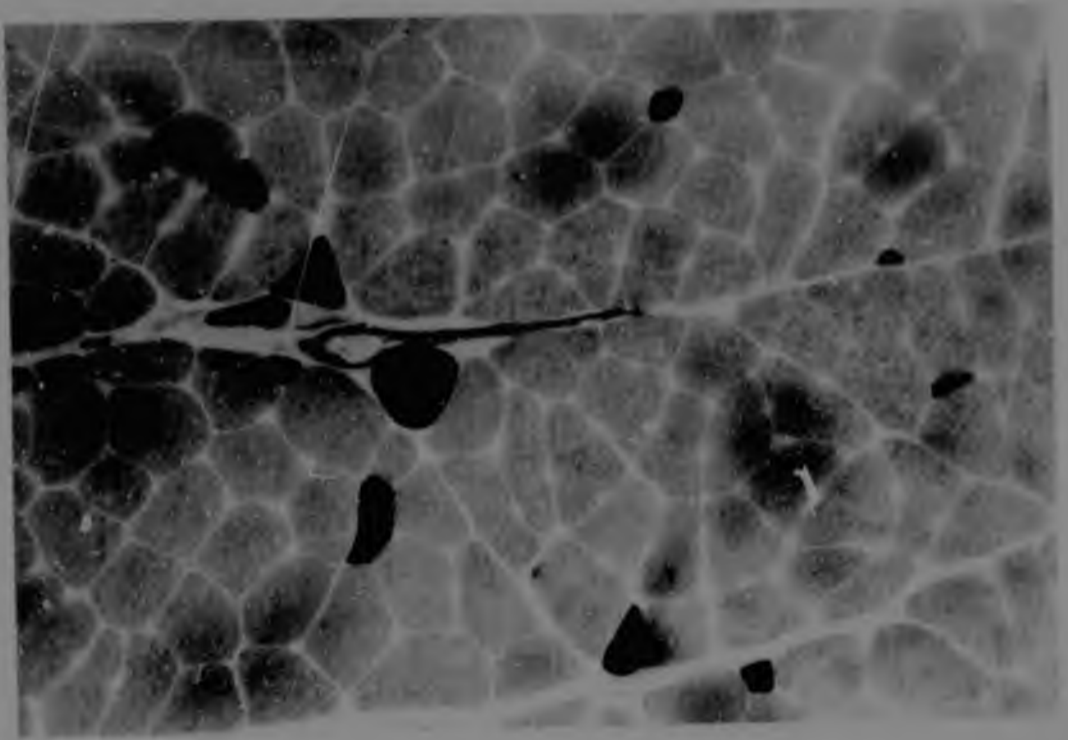
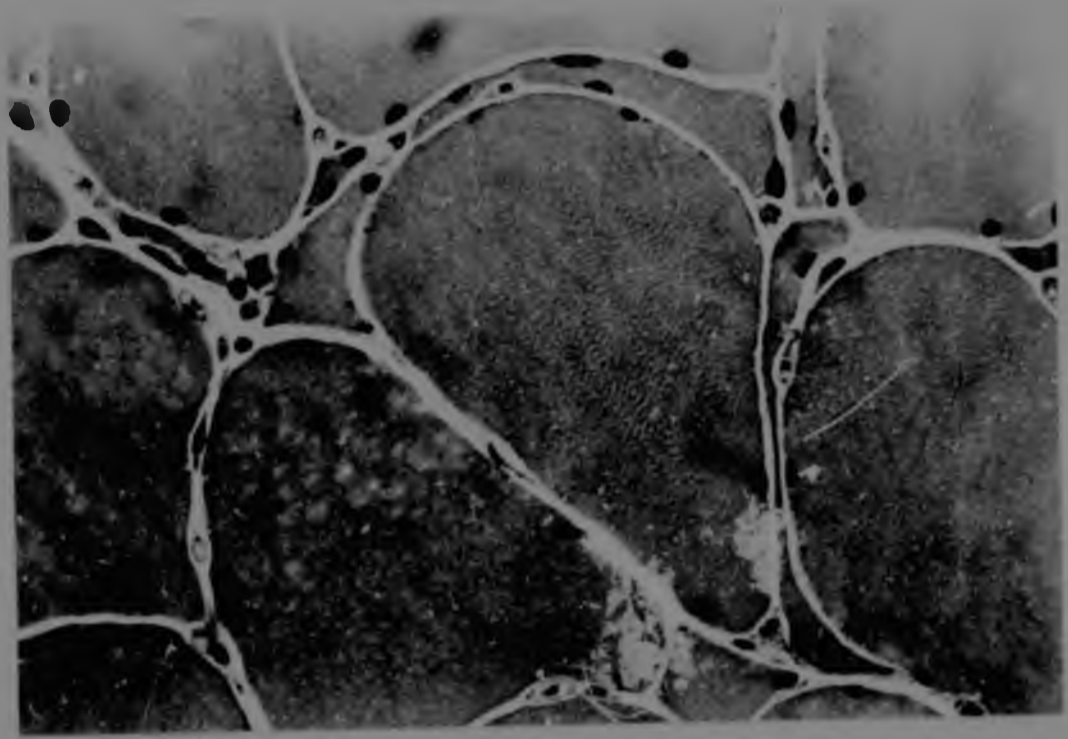
Small groups of atrophic fibres can be seen.

(H & E; x 1280)

Figure 17. Myasthenia gravis. No case number.

Biopsy demonstrated single, focal, type 2 fibre atrophy and occasional, single, type 1 fibre atrophy. There are large areas of type 1 fibre grouping.

(Routine ATPase, pH 9.4; x 320)



Recent relevant literature on myasthenia gravis not cited in the text
or references

1. Abramsky, O. & Brenner, T. (1979). α -fetoprotein inhibits antibody binding to acetylcholine receptor.
Isr. J. med. Sci. 15: 943-945.
2. Cuénoud, S., Feltkamp, T.E.W., Fulpius, B.W. & Oosterhuis, H.J.G.H. (1980). Antibodies to acetylcholine receptor in patients with thymoma but without myasthenia gravis.
Neurology, Minneap. 30: 201-203.
3. Cull-Candy, S.G., Miledi, R., Trautmann, A. & Uchitel, O.D. (1980). On the release of transmitter at normal, myasthenia gravis and myasthenic syndrome affected human end-plates.
J. Physiol., Lond. 299: 621-638.
4. De Troyer, A. & Borenstein, S. (1980). Acute changes in respiratory mechanics after pyridostigmine injection in patients with myasthenia gravis.
Am. Rev. resp. Dis. 121: 629-638.
5. Fenichel, G.M. (1978). Clinical syndromes of myasthenia in infancy and childhood.
Archs Neurol., Chicago 35: 97-103.
6. Fraser, K., Simpson, J.A. & Crawford, J. (1978). The place of surgery in the treatment of myasthenia gravis.
Br. J. Surg. 65: 301-304.
7. Ito, Y., Miledi, R., Vincent, A. & Newsom-Davis, J. (1978). Acetylcholine receptors and end-plate electrophysiology in myasthenia gravis.
Brain 101: 345-368.
8. Kadrie, H.A. & Brown, W.F. (1978). Neuromuscular transmission in myasthenic single motor units.
J. Neurol. Neurosurg. Psychiat. 41: 205-214.
9. Kornfeld, P., Genkins, G., Papatestas, A.E. & Horowitz, S.H. (1978). Steroid therapy in myasthenia gravis associated with thymoma.
Mt Sinai J. Med. 45: 106-115.

10. Newsom-Davis, J., Vincent, A., Wilson, S.G. & Ward, C.D. (1979). Long-term effects of repeated plasma exchange in myasthenia gravis.
Lancet 1: 464-468.
11. Osher, R.H. & Glaser, J.S. (1980). Myasthenic sustained gaze fatigue.
Am. J. Ophthalm. 89: 443-445.
12. Scopetta, C., Tonali, P., Evoli, A., David, P., Crucitti, F. & Vaccario, M.L. (1979). Treatment of myasthenia gravis. Report on 139 patients.
J. Neurol. 222: 11-21.
13. Sneddon, J. (1980). Myasthenia gravis: a study of social, medical, and emotional problems in 26 patients.
Lancet 1: 526-528.
14. Tindall, R.S.A. (1980). Humoral immunity in myasthenia gravis: effect of steroids and thymectomy.
Neurology, Minneap. 30: 554-557

STIFF MAN SYNDROME

Stiff man syndrome (SMS) is a rare neuromuscular disorder, first described by Moersch and Woltman (1955). There are fewer than 40 recorded cases of this syndrome, which appears to be more prevalent in males than in females. The average age of onset is between 43 and 46 years, although it may occur at any age. The rate of onset of the disease is variable, ranging from days to months or years.

SMS is characterized by slowly progressive, fairly symmetrical, fluctuating muscular rigidity and spasms, the severity and extent of which varies in different individuals. Pain is usually associated with muscular spasms which are either localized (like cramp) or generalized and far more severe (more common). The latter type is characterized by violent contractions of both agonistic and antagonistic muscles. In several patients, the spasms have been of such intensity as to result in spontaneous fracture of the femur (Cohen, 1966); and in two cases, a Smith-Petersen nail was subsequently bent following a further, severe spasm (Asher, 1958; O'Connor, 1958). These severe attacks cause intense pain and result in profuse perspiring. The duration and frequency of the spasms is variable, an attack lasting from minutes to hours and occurring as frequently as 12 times or more per day. Various factors may cause an attack to take place, namely noise; cold weather; active or passive movement; painful stimulation or sometimes even stroking of the skin; and emotional disturbances such as excitement or stress. It is not surprising, therefore, that prior to Moersch and Woltman's (1956) description of SMS, these patients were diagnosed as being "hysterical".

Although muscular spasm is the most striking feature of SMS, spasms are superimposed on a slowly progressive, persistent, muscular contraction or tautness of striated muscles. This rigidity is usually the first symptom to be observed and is most often evident in the trunk and sometimes neck muscles, but later extends to the extremities, proximal muscles being affected more than distal ones; and the legs being involved to a greater extent than the arms (Moersch and Woltman, 1956). The facial and oropharyngeal muscles, however, remain unaffected by the

disease process. Muscle strength is usually normal or only slightly decreased, despite patients' frequent complaints of weakness. Muscle stretch reflexes and tendon reflexes are essentially normal, although these are often difficult to evaluate, owing to the muscular spasms and rigidity. Sensation is normal.

A kyphosis or lordosis may occur as a result of generalized muscular rigidity. Some patients have difficulty in breathing and eating, owing to severe spasm of the thoracic and abdominal muscles. With progressive involvement of the lower extremities, gait becomes stiff and laborious and these patients have a tendency to fall "like a wooden man" (Moersch and Woltman, 1956). Eventually, ambulation is impossible. Similarly, as rigidity in the trunk muscles increases, the patient finds it progressively more difficult to bend or sit up. Finally, this too becomes impossible, leading to a completely bedridden, physically incapacitated state. Nocturnal myoclonus has been associated with several cases (Martinelli *et al.*, 1978). Approximately 10% of patients with SMS have epilepsy.

Electromyographic studies reveal a similar picture in all cases of SMS: no evidence of lower motor neurone disease or myopathy; normal motor and sensory nerve conduction velocities in all extremities; an absence of muscular fasciculations or fibrillations; and the presence of continuous, apparently normal, motor-unit activity in both agonistic and antagonistic muscle groups at "rest". Muscle biopsy and brain and spinal cord necropsy studies have been non-specific (Figs 18, 19, 21), all findings either being consistent with those associated with the normal ageing process, or in the case of muscle biopsy, being attributable to the prolonged, severe muscular spasms and rigidity. In one case, an 8-year-old black girl, specific changes in the mitochondria (Fig. 20) which could not have occurred as a result of the muscular spasms or rigidity, remain unexplained (Isaacs, 1979).

The pathogenesis of SMS is at present obscure, although there have been various suggestions as to the possible cause. It was found that administration of L-dopa, a drug which lowers the concentration of S-adenosylmethionine in the brain, resulting in an increase in the concentration of norepinephrine, causes increased muscular rigidity

(Schmidt *et al.*, 1975). On the other hand, diazepam and baclofen, which increase the activity of the gamma-aminobutyric acid (GABA) system and reduce the activity of both brain and spinal catecholaminergic neurons, result in a decrease in frequency and severity of muscular spasms (Howard, 1963). In view of these pharmacological results, it was postulated that an imbalance between the GABA and catecholaminergic neuronal systems was the cause of SMS. Some doubt has been cast on the suggested involvement of the GABA system though, because of the failure of SMS to respond to administration of dipropylacetate, a drug which increases the concentration of GABA in the brain. It was also noted that the severity of muscular spasms is correlated directly with the concentration of MHPG (3-methoxy-4-hydroxy-phenyl glycol) excreted in the urine, namely, a high urinary MHPG concentration being associated with severe muscular spasms (Schmidt *et al.*, 1975). MHPG is a major metabolite required for the production of norepinephrine in the brain. It is thought that diazepam reduces the formation of norepinephrine in the CNS, which results in a lowered urinary MHPG concentration and consequently in a reduction in the intensity of muscular spasms. However, treatment by means of the various drugs results only in symptomatic relief, particularly of the severity and frequency of muscular spasms. Even these are altered only to a certain extent. Other forms of treatment which have been used include psychotherapy, shock treatment, hypnosis and physiotherapy, all of which had little or no effect on the condition.

Recently, Maida *et al.* (1980), using computed tomography, reported atrophy of the brain stem in a case of SMS. From this observation, and the presence of abnormal CSF levels, they concluded that a possible cause of SMS in some cases may be an inflammatory process.

Although the clinical features of SMS resemble those of tetanus, there are distinct differences between these two diseases. In SMS, the muscular spasms are not as violent as in tetanus, muscular relaxation occurs more gradually and the jaw muscles are unaffected by the spasms. Trismus, a common feature of tetanus, is not found in SMS; and whereas the duration of the consequences of tetanus is only weeks or months, SMS persists indefinitely.

Figure 18. Stiff man syndrome. Case 27.

Normal muscle.

(H & E; x 320)

Figure 19. Stiff man syndrome. Case 27.

Normal muscle.

(EDTA/ATP; x 320)

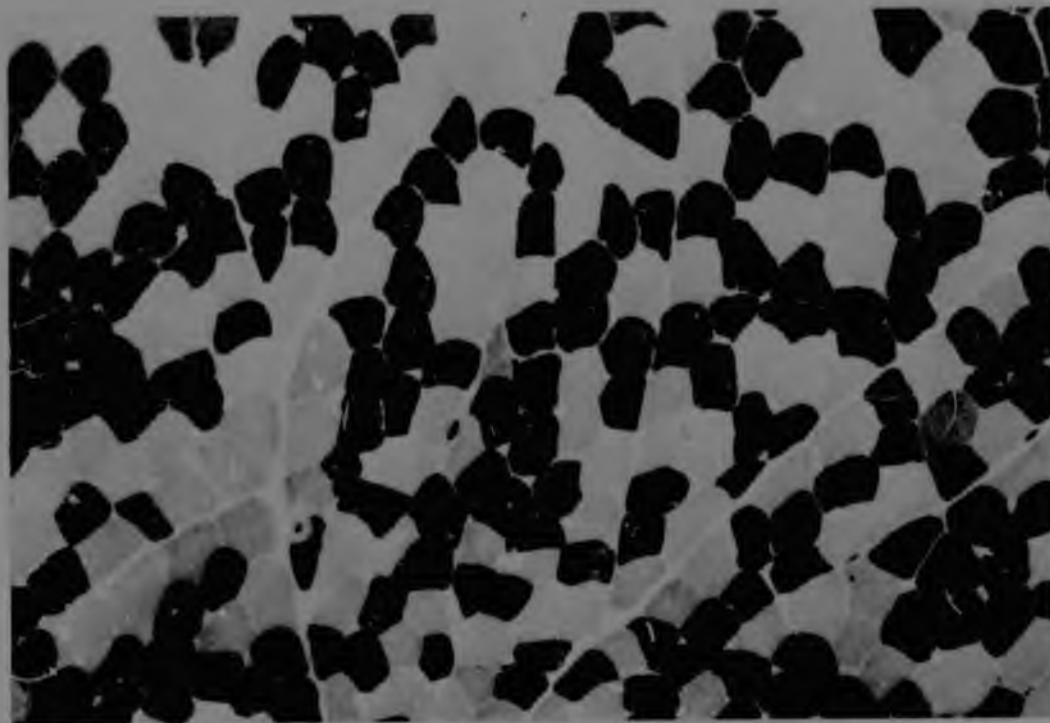
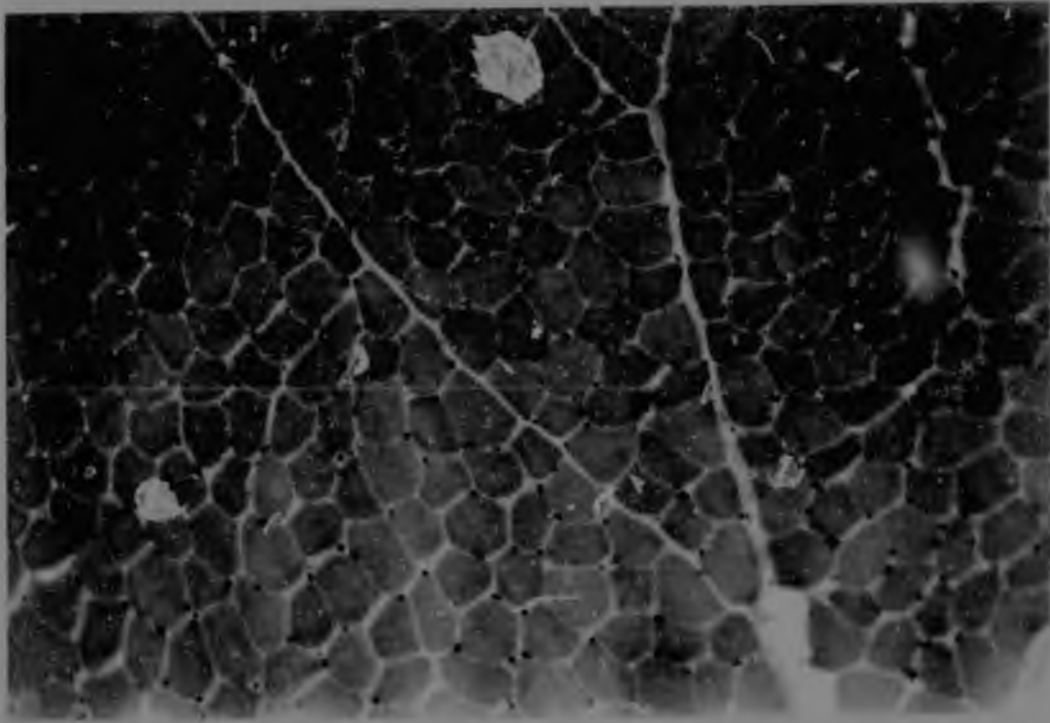


Figure 20. Stiff man syndrome. Case 27.

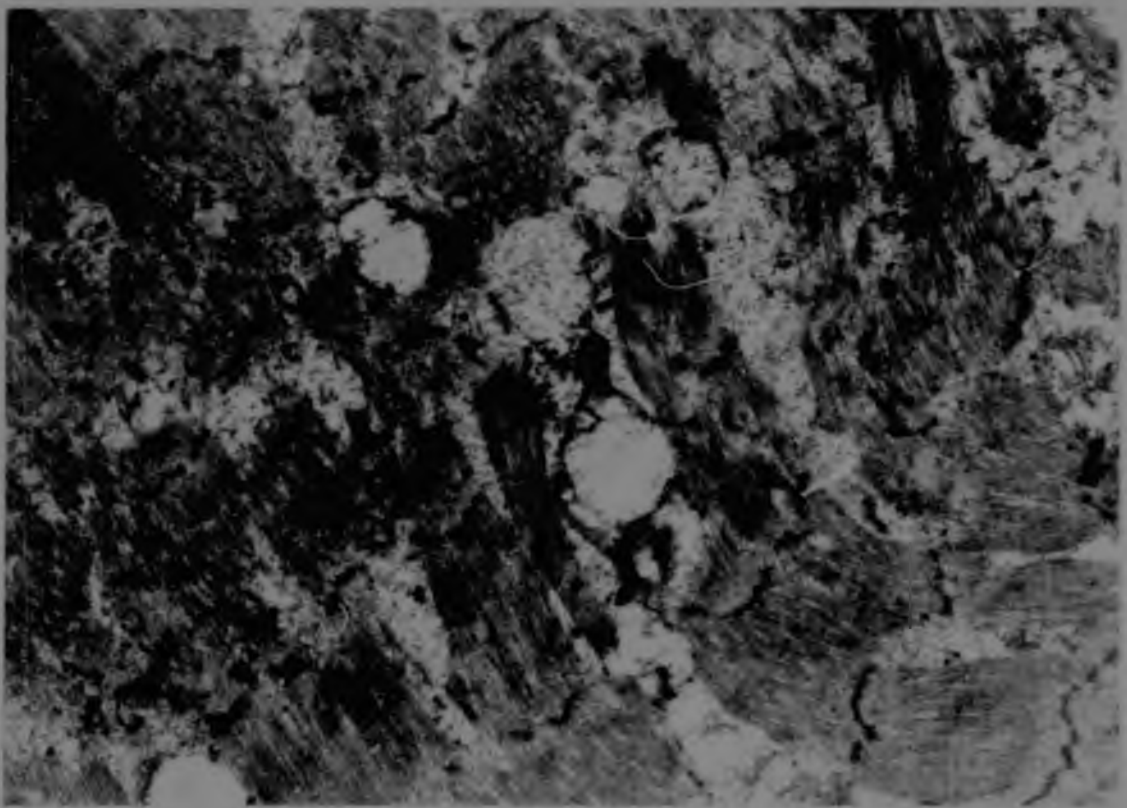

Electron micrograph demonstrating swelling of the SR and distended mitochondria with ruptured cristae.

(x 12000)

Figure 21. Stiff man syndrome. Case 27.

Electron micrograph showing myofilamentous and Z-line disruption as well as loss of myofibrils.

(x 12000)



MALIGNANT HYPERTHERMIA

Since the report by Denborough and Lovell (1960) of ten hyperpyrexial deaths in the same family, the malignant hyperthermia (MH) syndrome has become recognized as one of the most common causes of anaesthetic-induced deaths. This rare but often fatal complication which can accompany general anaesthesia, has an estimated frequency of one per fourteen thousand anaesthetic events and a 64% mortality rate (Britt and Kalow, 1970). It is inherited as an autosomal dominant characteristic with variable penetrance (Denborough *et al.*, 1962; Britt *et al.*, 1969).

Malignant hyperthermia is the result of an abnormal muscle response in susceptible individuals to various trigger agents, of which certain anaesthetics (especially halothane and succinylcholine) have been found to be the most common.

It has been discovered that in a large number of families, MH is associated with one of a number of myopathies (Denborough *et al.*, 1970; Steers *et al.*, 1970), many of these being subclinical in nature (Isaacs and Barlow, 1970a). The aetiology of this metabolic disorder is obscure. However, it is thought that the syndrome occurs as a result of impaired binding of calcium ions to the membranes of the SR, leading to uncoupling of oxidative phosphorylation and a resultant hypermetabolic, exothermic state (Britt *et al.*, 1973). Several other hypotheses regarding causation have been reviewed by Britt (1979).

The syndrome is characterized by a rapid increase in body temperature during anaesthesia, and in most cases by an associated hypertonus or muscle rigidity, which is often a distinctive feature of the episode (Britt and Kalow, 1970). However, muscle rigidity and rise in temperature sometimes occur only in the advanced stages of a MH crisis, by which time the patient's life has become seriously endangered. The result is decerebration, cardiac and renal failure and, finally, death. The longer the duration of the anaesthesia and the higher the absolute maximum temperature, the greater is the mortality rate (Britt and Kalow, 1970). Britt (1974) found that the most reliable initial symptom in nearly all cases was tachycardia or other arrhythmias, often associated with unstable blood pressure, flushing or mottling cyanosis of the skin

and tachypnoea. Laboratory findings have included respiratory and metabolic acidosis, hyperkalaemia, hypermagnesaemia, increased blood levels of glucose, lactate and pyruvate, hyperphosphataemia, myoglobinuria, and elevated serum creatine phosphokinase (CPK) and other enzyme levels (Britt and Kalow, 1970).

Once a case of MH has occurred in a family, a number of tests need to be carried out to determine whether or not other members of the family are carriers. Laboratory investigation includes muscle in vitro contraction studies and histopathological and serum enzyme studies. A raised CPK level has been used in diagnosis (Isaacs and Barlow, 1970b, 1973), although when considered alone its value is limited, owing to the increased CPK activity that occurs in various other diseases not related to MH. Muscle biopsy findings have proved to be non-specific (Figs 22, 23), the most striking abnormality being seen on electron microscopic examination of the mitochondria. Common features are rows of distended mitochondria with distended/ruptured cristae (Fig. 24) (Isaacs et al., 1973). In vitro muscle tension studies would appear to be the most reliable test, although even here some equivocal results have been obtained. Consequently, it has been concluded that even when a combination of the above criteria are used in an attempt to identify MH susceptible patients, a few cases may go undetected (Isaacs, 1977).

It has recently been suggested that "malignant hyperthermia" is a misnomer; and the name "acute familial perianesthetic rhabdomyolysis" has been proposed (Zsigmond, 1980).

Figure 22. Malignant hyperthermia. Case 28.

Note single fibre atrophy, fibre splitting and multinucleated fibres.

(H & E; x 1280)

Figure 23. Malignant hyperthermia. Case 28.

This section shows grouping of both fibre types.

(ATPase, preincubated at pH 4.3; x 320)


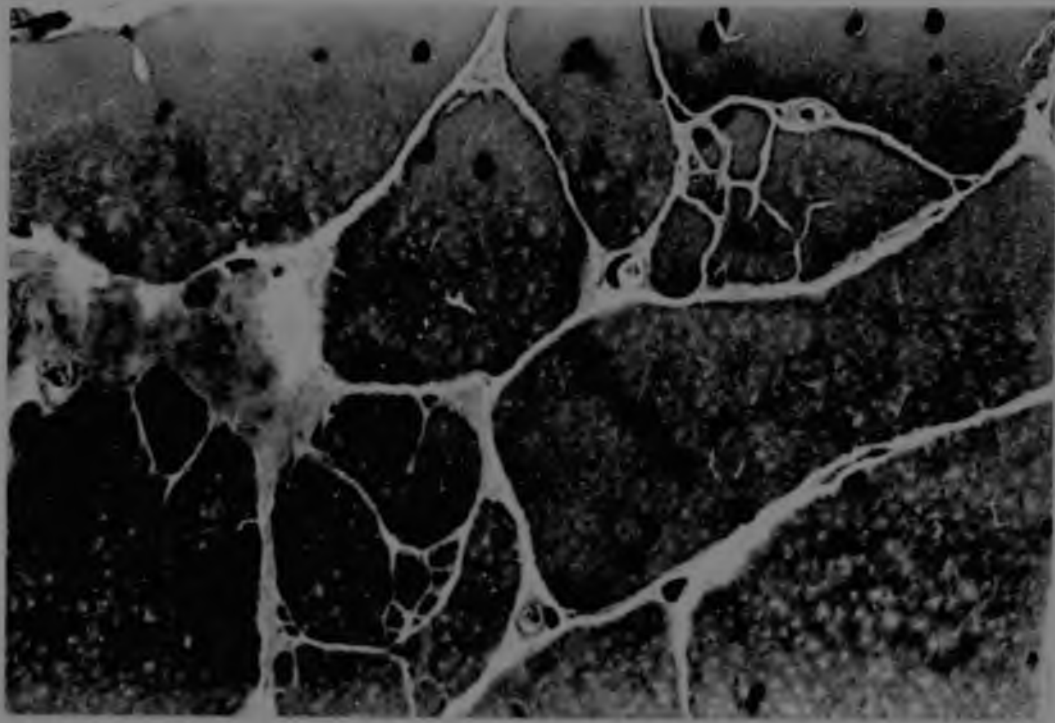



Figure 24. Malignant hyperthermia. No case number.

Electron micrograph illustrating mitochondrial distension and showing ruptured cristae. The SR also appears to be swollen.

(x 12000)



Recent relevant literature on malignant hyperthermia not cited in text
or references

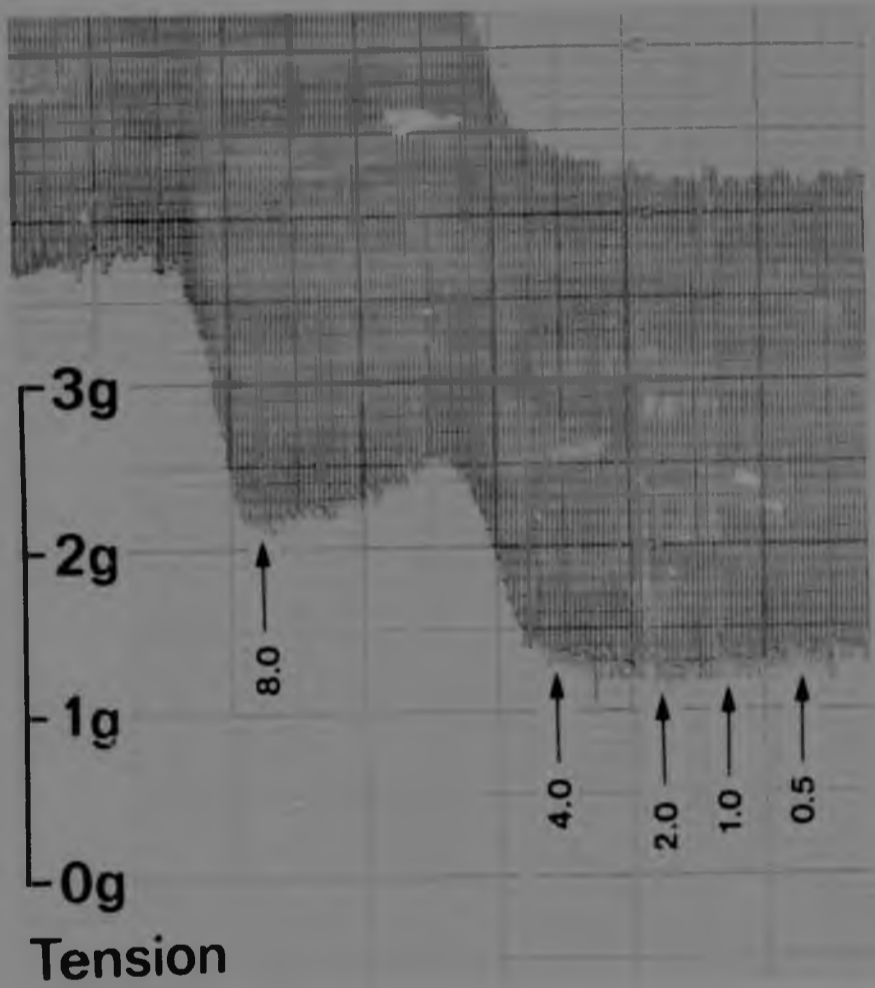
1. Bennett, D., Cain, P., Ellis, F.R., Halsall, J. & Louis, C.F. (1978). Effect of halothane on the rate of acid production, lactate production and pyruvate dehydrogenase activity of malignant hyperpyrexia human muscle.
Br. J. Anaesth. 50: 799-803.
2. Pitt, B.A., Endrenyi, L., Frodis, W., Scott, E. & Kalow, W. (1980). Comparison of effects of several inhalation anaesthetics on caffeine-induced contractures of normal and malignant hyperthermic skeletal muscle.
Can. Anaesth. Soc. J. 27: 12-15.
3. Fraley, D.S., Lemoncelli, G.L. & Coleman, A. (1978). Severe hypertension associated with pancuronium bromide.
Anesth. Analg. 57: 265-267.
4. Flewellen, E.H., Nelson, T.E. & Bee, D.E. (1980). Porcine malignant hyperthermia - failure of dantrolene dose response to diagnose susceptibility (halothane effect).
Can. Anaesth. Soc. J. 27: 16-21.
5. Frank, J.P., Harati, Y., Butler, I.J., Nelson, T.E. & Scott, C.I. (1980). Central core disease and malignant hyperthermia syndrome.
Ann. Neurol. 7: 11-17.
6. Mann, S.C. & Boger, W.P. (1978). Psychotropic drugs, summer heat and humidity, and hyperpyrexia: a danger restated.
Am. J. Psychiat. 135: 1097-1100.
7. Theilade, D. & Rosendal, T. (1978). Malignant hyperpyrexia. A case report of successful treatment and subsequent uneventful general anaesthesia.
Anaesthesia 33: 606-610.

A P P E N D I X 4

EXAMPLES OF NORMAL AND ABNORMAL MUSCLE TENSION TRACINGS

Figure 25. Example of a normal muscle tension tracing.
(Normal 13)

Figure 25. Example of a normal muscle tension tracing.
(Normal 13)



Change of Krebs solution -----


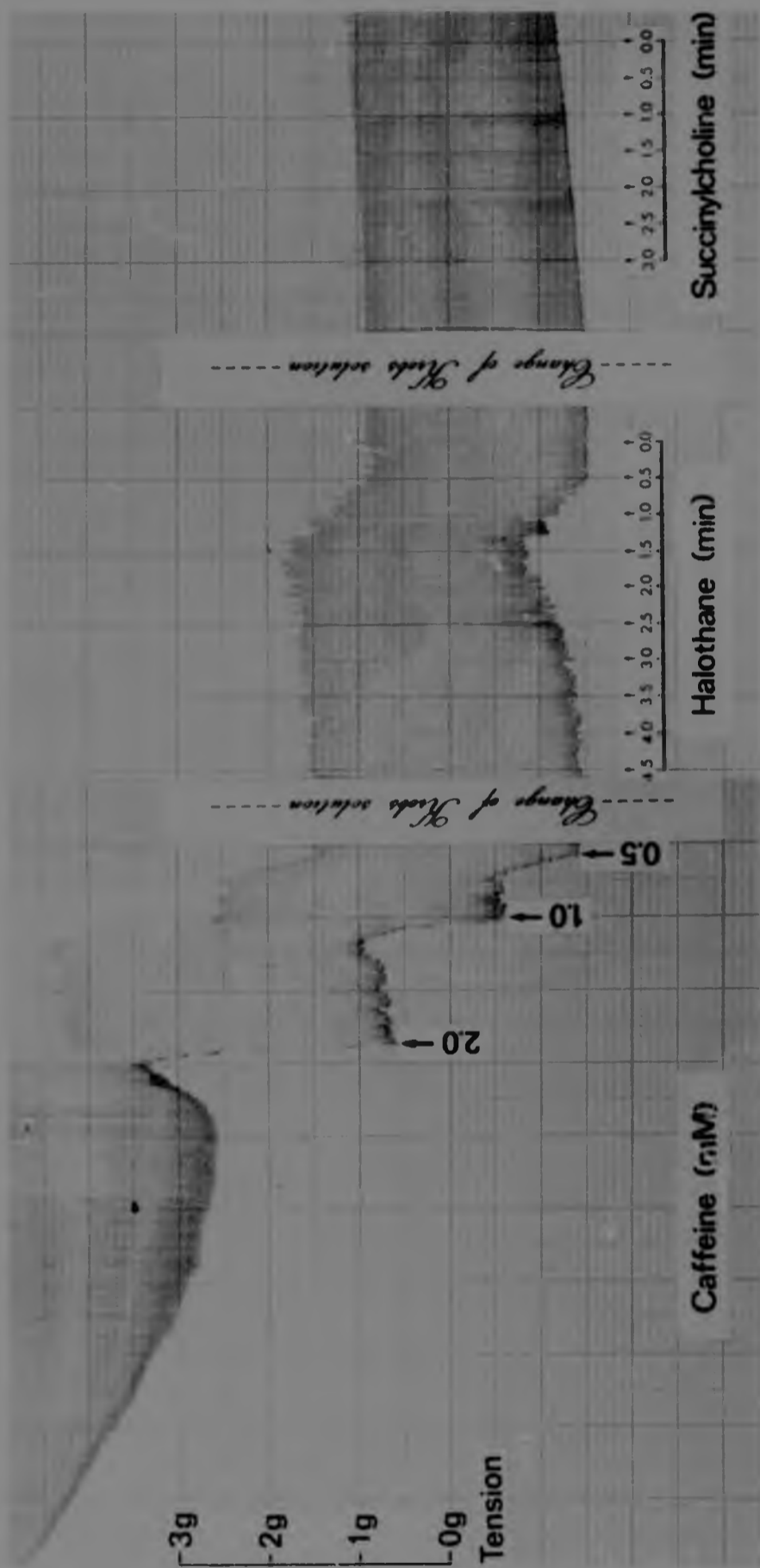


Figure 26. Example of an abnormal muscle tension tracing.
(Case 29)

Downloaded from ascelibrary.org by Seattle University on 06/01/15. Copyright ASCE, For All Rights Reserved, No part of this document may be reproduced, stored in a retrieval system, or transmitted, in any form or by any means, electronic, mechanical, photocopying, recording, or by any information storage or retrieval system, without permission in writing from ASCE.



REFERENCES

The names of journals have, as far as possible, been abbreviated in accordance with the 4th edition of Butterworths World list of scientific periodicals (vol. 1: 1963, vol. 2: 1964 and vol. 3: 1965).

ABRAMSKY, O., AHARONOV, A., WEBB, C. & FUCHS, S. (1975). Cellular immune response to acetylcholine receptor-rich fraction, in patients with myasthenia gravis.
Clin. exp. Immunol. 19: 11-16.

ADRIAN, R.H., CHANDLER, W.K. & RAKOWSKI, R.F. (1976). Charge movement and mechanical repriming in skeletal muscle.
J. Physiol., Lond. 254: 361-388.

AHARONOV, A., TARRAB-HAZDAI, R., ABRAMSKY, O. & FUCHS, S. (1975). Humoral antibodies to acetylcholine receptor in patients with myasthenia gravis.
Lancet 2: 340-342.

ALMON, R.R., ANDREW, C.G. & APPEL, S.H. (1974). Serum globulin in myasthenia gravis: inhibition of α -bungarotoxin binding to acetylcholine receptors.
Science, N.Y. 186: 55-57.

ANDERSON, I.L. & JONES, E.W. (1976). Porcine malignant hyperthermia: effect of dantrolene sodium on in-vitro halothane-induced contraction of susceptible muscle.
Anesthesiology 44: 57-61.

ANDERSSON-CEDERGREN, E. (1959). Ultrastructure of motor end plate and sarcoplasmic components of mouse skeletal muscle fiber as revealed by three-dimensional reconstructions from serial sections.
J. Ultrastruct. Res., Suppl. no. 1: 1-191.

ASHER, R. (1958). A woman with stiff-man syndrome.
Br. med. J. 1: 265-266.

The names of journals have, as far as possible, been abbreviated in accordance with the 4th edition of Butterworth's World list of scientific periodicals (vol. 1: 1963, vol. 2: 1964 and vol. 3: 1965).

- ABRAMSKY, O., AHARONOV, A., WEBB, C. & FUCHS, S. (1975). Cellular immune response to acetylcholine receptor-rich fraction, in patients with myasthenia gravis. Clin. exp. Immunol. 19: 11-16.
- ADRIAN, R.H., CHANDLER, W.K. & RAKOWSKI, R.F. (1976). Charge movement and mechanical repriming in skeletal muscle. J. Physiol., Lond. 254: 361-388.
- AHARONOV, A., TARRAB-HAZDAI, R., ABRAMSKY, O. & FUCHS, S. (1975). Humoral antibodies to acetylcholine receptor in patients with myasthenia gravis. Lancet 2: 340-342.
- ALMON, R.R., ANDREW, C.G. & APPEL, S.H. (1974). Serum globulin in myasthenia gravis: inhibition of α -bungarotoxin binding to acetylcholine receptors. Science, N.Y. 186: 55-57.
- ANDERSON, I.L. & JONES, E.W. (1976). Porcine malignant hyperthermia: effect of dantrolene sodium on in-vitro halothane-induced contraction of susceptible muscle. Anesthesiology 44: 57-61.
- ANDERSSON-CEDERGREN, E. (1959). Ultrastructure of motor end plate and sarcoplasmic components of mouse skeletal muscle fiber as revealed by three-dimensional reconstructions from serial sections. J. Ultrastruct. Res., Suppl. no. 1: 1-191.
- ASHER, R. (1958). A woman with stiff-man syndrome. Br. med. J. 1: 265-266.

- ASHLEY, C.C. & RIDGWAY, E.B. (1968). Simultaneous recording of membrane potential, calcium transient and tension in single muscle fibres.
Nature, Lond. 219: 1168-1169.
- BAGSHAW, C.R., ECCLESTON, J.F., TRENTAM, D.R., YATES, D.W. & GOODY, R.S. (1972). Transient kinetic studies of the Mg^{++} -dependent ATPase of myosin and its proteolytic subfragments.
Cold Spring Harb. Symp. quant. Biol. 37: 127-135.
- BÁRÁNY, M. & BÁRÁNY, K. (1972). A proposal for the mechanism of contraction in intact frog muscle.
Cold Spring Harb. Symp. quant. Biol. 37: 157-167.
- BÁRÁNY, K., BÁRÁNY, M., GILLIS, J.M. & KUSHMERICK, M.J. (1980). Myosin light chain phosphorylation during the contraction cycle of frog muscle.
Fedn Proc. Fedn Am. Socs exp. Biol. 39: 1547-1551.
- BARLOGIE, B., HASSELBACH, W. & MAKINOSE, M. (1971). Activation of calcium efflux by ADP and inorganic phosphate.
Fedn Eur. biochem. Soc. Lett. 12: 267-268.
- BASMAJIAN, J.V. (1974). Muscles alive. Their functions revealed by electromyography. (3rd ed.). Williams and Wilkins, Baltimore.
- BASTEDO, D.L.A. (1950). Acute fulminating myasthenia gravis in children.
Can. med. Ass. J. 63: 388-389.
- BASTIAN, J. & NAKAJIMA, S. (1974). Action potential in the transverse tubules and its role in the activation of skeletal muscle.
J. gen. Physiol. 63: 257-278.
- BATE-SMITH, E.C. & BENDALL, J.R. (1947). Rigor mortis and adenosinetriphosphate.
J. Physiol., Lond. 106: 177-185.

- BEHSE, F. & BUCHTHAL, F. (1977). Peroneal muscular atrophy (PMA) and related disorders. II. Histological findings in sural nerves.
Brain 100: 67-85.
- BENADY, S.G. (1978). Spinal muscular atrophy in childhood: review of 50 cases.
Devl Med. Child Neurol. 20: 746-757.
- BENDALL, J.R. (1952) Effect of the 'Marsh factor' on the shortening of muscle fibre models in the presence of adenosine triphosphate.
Nature, Lond. 170: 1058-1060.
- BENDALL, J.R. (1958). Muscle-relaxing factors.
Nature, Lond. 181: 1188-1190.
- BENDER, A.N., ENGEL, W.K., RINGEL, S.P., DANIELS, M.P. & VOGEL, Z. (1975). Myasthenia gravis: a serum factor blocking acetylcholine receptors of the human neuromuscular junction.
Lancet 1: 607-609.
- BENDER, A.N., RINGEL, S.P. & ENGEL, W.K. (1976). The acetylcholine receptor in normal and pathologic states. Immunoperoxidase visualization of alpha-bungarotoxin binding at a light and electron-microscopic level.
Neurology, Minneap. 26: 477-483.
- BOREJDO, J., PUTNAM, S. & MORALES, M.F. (1979). Fluctuations in polarized fluorescence: evidence that muscle cross bridges rotate repetitively during contraction.
Proc. natn. Acad. Sci. U.S.A. 76: 6346-6350.
- BOUWSMA, G. & VAN WIJNGAARDEN, G.K. (1980). Spinal muscular atrophy and hypertrophy of the calves.
J. neurol. Sci. 44: 275-279.
- BOWMAN, W.C. & RAPER, C. (1967). Adrenotropic receptors in skeletal muscle.
Ann. N.Y. Acad. Sci. 139: 741-753.

- BOZLER, E. (1954). Relaxation in extracted muscle fibers.
J. gen. Physiol. 38: 149-159.
- BOZLER, E. (1955). Binding of calcium and magnesium by the contractile elements.
J. gen. Physiol. 38: 735-742.
- BRADLEY, W.G., WARD, M., MURCHISON, D., HALL, L. & WOOLF, N. (1973). Clinical, electrophysiological and pathological studies on malignant hyperpyrexia.
Proc. R. Soc. Med. 66: 67-68.
- BRADLEY, R.J., DWYER, D., MORLEY, B.J., ROBINSON, G., KEMP, G.E. & OH, S.J. (1978). Humoral immunity in myasthenia gravis: relationship to disease severity and steroid treatment.
Lancet 2: 96.
- BREMEL, R.D. & WEBER, A. (1972). Cooperation within actin filament vertebrate skeletal muscle.
Nature (New Biol.) 238: 97-101.
- BREMEL, R.D., MURRAY, J.M. & WEBER, A. (1972). Manifestations of cooperative behaviour in the regulated actin filament during actin-activated ATP hydrolysis in the presence of calcium.
Cold Spring Harb. Symp. quant. Biol. 37: 267-275.
- BRITT, B.A. (1974). Malignant hyperthermia: a pharmacogenetic disease of skeletal and cardiac muscle.
New Engl. J. Med. 290: 1140-1142.
- BRITT, B.A. (1979). Etiology and pathophysiology of malignant hyperthermia.
Fedn Proc. Fedn Am. Socs exp. Biol. 38: 44-48.
- BRITT, B.A. & KALOW, W. (1970). Malignant hyperthermia: a statistical review.
Can. Anaesth. Soc. J. 17: 293-315.
- BRITT, B.A., LOCHER, W.G. & KALOW, W. (1969). Hereditary aspects of malignant hyperthermia.
Can. Anaesth. Soc. J. 16: 89-98.

- BRITT, B.A., KALOW, W., GORDON, A., HUMPHREY, J.G. & REWCASTLE, N.B. (1973). Malignant hyperthermia: an investigation of five patients.
Can. Anaesth. Soc. J. 20: 431-467.
- BROOKE, M.H. & KAISER, K.K. (1969). Some comments on the histochemical characterization of muscle adenosine triphosphatase.
J. Histochem. Cytochem. 17: 431-432.
- BROOKE, M.H. & KAISER, K.K. (1970). Muscle fibre types: how many and what kind?
Archs Neurol., Chicago 23: 369-379.
- BROOKE, M.H. & KAISER, K.K. (1974). The use and abuse of muscle histochemistry.
Ann. N.Y. Acad. Sci. 228: 121-144.
- BRUST, J.C.M., LOVELACE, R.E. & DEVI, S. (1978). Clinical and electrodiagnostic features of Charcot-Marie-Tooth syndrome.
Acta neurol. scand. 58, Suppl. no. 68: 5-142.
- BUCHTHAL, F. & BEHSE, F. (1977). Peroneal muscular atrophy (PMA) and related disorders. I. Clinical manifestations as related to biopsy findings, nerve conduction and electromyography.
Brain 100: 41-66.
- BUNDEY, S. & LOVELACE, R.E. (1975). A clinical and genetic study of chronic proximal spinal muscular atrophy.
Brain 98: 455-472.
- BYERS, R.K. & BANKER, B.Q. (1961). Infantile muscular atrophy.
Archs Neurol., Chicago 5: 140-164.
- CARLSON, F.D. & WILKIE, D.R. (1974). Muscle physiology. Prentice-Hall, New Jersey.
- CASPAR, D.L.D., COHEN, C. & LONGLEY, W. (1969). Tropomyosin: crystal structure, polymorphism and molecular interactions.
J. molec. Biol. 41: 87-107.

- CASTLEMAN, B. (1966). The pathology of the thymus gland in myasthenia gravis.
Ann. N.Y. Acad. Sci. 135: 496-503.
- CHAPLAIN, R.A. (1969). Changes of adenosine triphosphatase activity and tension with fibre electric junction in glycerinated insect fibrillar flight muscle.
Pflügers Arch. ges. Physiol. 307: 120-126.
- CHEVALLIER, J. & BUTOW, R.A. (1971). Calcium binding to the sarcoplasmic reticulum of rabbit skeletal muscle.
Biochemistry, N.Y. 10: 2733-2737.
- COHEN, L. (1966). Stiff-man syndrome. Two patients treated with diazepam.
J. Am. med. Ass. 195: 222-224.
- COHEN, A. & SELINGER, Z. (1969). Calcium binding properties of sarcoplasmic reticulum membranes.
Biochim. biophys. Acta 183: 27-35.
- COHEN, C., CASPAR, D.L.D., JOHNSON, J.P., NAUSS, K., MARGOSSIAN, S.S. & PARRY, D.A.D. (1972). Tropomyosin-troponin assembly.
Cold Spring Harb. Symp. quant. Biol. 37: 287-297.
- COOKE, R. & FRANKS, K.E. (1977). The production of force by single-headed myosin.
Biophys. J. 17: 41a.
- COSTANTIN, L.L. (1970). The role of sodium current in the radial spread of contraction in frog muscle fibers.
J. gen. Physiol. 55: 703-715.
- COSTANTIN, L.L. (1975). Electrical properties of the transverse tubular system.
Fedn Proc. Fedn Am. Socs exp. Biol. 34: 1390-1394.
- COSTANTIN, L.L., FRANZINI-ARMSTRONG, C. & PODOLSKY, R.J. (1965). Localization of calcium-accumulating structures in striated muscle fibers.
Science, N.Y. 147: 158-160.

- DANIELS, L., WILLIAMS, M. & WORTHINGHAM, C. (1956). Muscle testing. Techniques of manual examination. (2nd ed.). Saunders, Philadelphia.
- DATTA, S.K. & SCHWARTZ, R.S. (1974). Infectious (?) myasthenia. New Engl. J. Med. 291: 1304-1305.
- DAU, P.C., LINDSTROM, J.M., CASSEL, C.K., DENYS, E.H., SHEV, E.E. & SPITLER, I.E. (1977). Plasmapheresis and immunosuppressive drug therapy in myasthenia gravis. New Engl. J. Med. 297: 1134-1140.
- DAVIES, R.E. (1963). A molecular theory of muscle contraction: calcium-dependent contractions with hydrogen bond formation plus ATP-dependent extensions of part of the myosin-actin cross-bridges. Nature, Lond. 199: 1068-1074.
- DAVIS, C.J.F., BRADLEY, W.G. & MADRID, R. (1978). The peroneal muscular atrophy syndrome. Clinical, genetic, electrophysiological and nerve biopsy studies. I. Clinical, genetic and electrophysiological findings and classification. J. génét. hum. 26: 311-349.
- DEAMER, D.W. & BASKIN, R.J. (1969). Ultrastructure of sarcoplasmic reticulum preparations. J. Cell Biol. 42: 296-307.
- DEL CASTILLO, J. & KATZ, B. (1954). Quantal components of the end-plate potential. J. Physiol., Lond. 124: 560-573.
- DE MEIS, L. (1969). Ca^{2+} uptake and acetyl phosphatase of skeletal muscle microsomes. Inhibition by Na^+ , K^+ , Li^+ , and adenosine triphosphate. J. biol. Chem. 244: 3733-3739.
- DE MEIS, L. (1976). Regulation of steady state level of phosphoenzyme and ATP synthesis in sarcoplasmic reticulum vesicles during reversal of the Ca^{2+} pump. J. biol. Chem. 251: 2055-2062.

- DANIELS, L., WILLIAMS, M. & WORTHINGHAM, C. (1956). Muscle testing. Techniques of manual examination. (2nd ed.). Saunders, Philadelphia.
- DATTA, S.K. & SCHWARTZ, R.S. (1974). Infectious ? myasthenia. New Engl. J. Med. 291: 1304-1305.
- DAU, P.C., LINDSTROM, J.M., CASSEL, C.K., DENYS, E.H., SHEV, E.E. & SPITLER, L.E. (1977). Plasmapheresis and immunosuppressive drug therapy in myasthenia gravis. New Engl. J. Med. 297: 1134-1140.
- DAVIES, R.E. (1963). A molecular theory of muscle contraction: calcium-dependent contractions with hydrogen bond formation plus ATP-dependent extensions of part of the myosin-actin cross-bridges. Nature, Lond. 199: 1068-1074.
- DAVIS, C.J.F., BRADLEY, W.G. & MADRID, R. (1978). The peroneal muscular atrophy syndrome. Clinical, genetic, electrophysiological and nerve biopsy studies. I. Clinical, genetic and electrophysiological findings and classification. J. génét. hum. 26: 311-349.
- DEAMER, D.W. & BASKIN, R.J. (1969). Ultrastructure of sarcoplasmic reticulum preparations. J. Cell Biol. 42: 296-307.
- DEL CASTILLO, J. & KATZ, B. (1954). Quantal components of the end-plate potential. J. Physiol., Lond. 124: 560-573.
- DE MEIS, L. (1969). Ca^{2+} uptake and acetyl phosphatase of skeletal muscle microsomes. Inhibition by Na^+ , K^+ , Li^+ , and adenosine triphosphate. J. biol. Chem. 244: 3733-3739.
- DE MEIS, L. (1976). Regulation of steady state level of phosphoenzyme and ATP synthesis in sarcoplasmic reticulum vesicles during reversal of the Ca^{2+} pump. J. biol. Chem. 251: 2055-2062.

- DE MEIS, L. & CARVALHO, M.G.C. (1974). Role of the Ca^{2+} concentration gradient in the adenosine 5'-triphosphate - inorganic phosphate exchange catalyzed by sarcoplasmic reticulum. Biochemistry, N.Y. 13: 5032-5038.
- DE MEIS, L. & SORENSON, M.M. (1975). $ATP \leftrightarrow P_i$ exchange and membrane phosphorylation in sarcoplasmic reticulum vesicles: activation by silver in the absence of a Ca^{2+} concentration gradient. Biochemistry, N.Y. 14: 2739-2744.
- DENBOROUGH, M.A. & LOVELL, R.R.H. (1960). Anaesthetic deaths in a family. Lancet 2: 45.
- DENBOROUGH, M.A., FORSTER, J.F.A., LOVELL, R.R.H., MAPLESTONE, P.A. & VILLIERS, J.D. (1962). Anaesthetic deaths in a family. Br. J. Anaesth. 34: 395-396.
- DENBOROUGH, M.A., KING, J.O., EBELING, P. & ZAPF, P. (1970). Myopathy and malignant hyperpyrexia. Lancet 1: 1138-1140.
- DRAPER, M.H. & HODGE, A.J. (1949). Studies on muscle with the electron microscope. I. The ultrastructure of toad striated muscle. Aust. J. exp. Biol. med. Sci. 27: 465-503.
- DREWS, G.A. & ENGEL, W.K. (1966). Reversal of the ATPase reaction in muscle fibres by EDTA. Nature, Lond. 212: 1551-1553.
- DUBOWITZ, V. (1968). Developing and diseased muscle. A histochemical study (SIMP Research Monograph no. 2). Spastics International Medical Publications & William Heineman Medical Books, New York.
- DUBOWITZ, V. (1977a). Muscle disorders in childhood. Isr. J. med. Sci. 13: 89-92.
- DUBOWITZ, V. (1977b). Analysis of neuromuscular disease. Physiotherapy, Lond. 63: 38-45.

- DUBOWITZ, V. & BROOKE, M.H. (1973). Muscle biopsy: A modern approach. Saunders, London.
- DUBOWITZ, V. & PEARSE, A.G.E. (1960). Histology. Reciprocal relationship of phosphorylase and oxidative enzymes in skeletal muscle.
Nature, Lond. 185: 701-702.
- DUGGAN, P.F. (1977). Calcium uptake and associated adenosine triphosphatase activity in fragmented sarcoplasmic reticulum.
J. biol. Chem. 252: 1620-1627.
- DYCK, P.J. (1975). Inherited neuronal degeneration and atrophy affecting peripheral motor, sensory, and autonomic neurons. In: Peripheral Neuropathy (eds P.J. Dyck, P.K. Thomas & E.H. Lambert), pp. 825-867. Saunders, Philadelphia.
- DYCK, P.J. & LAMBERT, E.H. (1968a). Lower motor and primary sensory neuron diseases with peroneal muscular atrophy. I. Neurologic, genetic, and electrophysiologic findings in hereditary polyneuropathies.
Archs Neurol., Chicago 18: 603-618.
- DYCK, P.J. & LAMBERT, E.H. (1968b). Lower motor and primary sensory neuron diseases with peroneal muscular atrophy. II. Neurologic, genetic and electrophysiologic findings in various neuronal degenerations.
Archs Neurol., Chicago 18: 619-625.
- EBASHI, S. (1958). A granule-bound relaxation factor in skeletal muscle.
Archs Biochem. Biophys. 76: 410-423.
- EBASHI, S. (1961). Calcium binding activity of vesicular relaxing factor.
J. Biochem., Tokyo 50: 236-244.
- EBASHI, S. & ENDO, M. (1968). Calcium ion and muscle contraction.
Prog. Biophys. molec. Biol. 18: 123-183.

- EBASHI, S. & LIPMANN, F. (1962). Adenosine triphosphate-linked concentration of calcium ions in a particulate fraction of rabbit muscle.
J. Cell Biol. 1: 339-400.
- EISENBERG, B. & EISENBERG, R.S. (1968). Selective disruption of the sarcotubular system in frog sartorius muscle. A quantitative study with exogenous peroxidase as a marker.
J. Cell Biol. 39: 451-467.
- EISENBERG, E. & GREENE, L.E. (1980). The relation of muscle biochemistry to muscle physiology.
A. Rev. Physiol. 42: 293-309.
- EISENBERG, E. & KIELLEY, W.W. (1970). Native tropomyosin: effect on the interaction of actin with heavy meromyosin and subfragment-1.
Biochem. biophys. Res. Commun. 40: 50-56.
- EISENBERG, E. & KIELLEY, W.W. (1972a). Reconstitution of active troponin-tropomyosin complex in the absence of urea from its 4 column-purified components.
Fedn Proc. Fedn Am. Socs exp. Biol. 31: 502Abs.
- EISENBERG, E. & KIELLEY, W.W. (1972b). Evidence for a refractory state of heavy meromyosin and subfragment-1 unable to bind to actin in the presence of ATP.
Cold Spring Harb. Symp. quant. Biol. 37: 145-152.
- EISENBERG, E. & MOOS, C. (1970). Actin activation of heavy meromyosin adenosine triphosphatase. Dependence on adenosine triphosphate and actin concentrations.
J. Biol. Chem. 245: 2451-2456.
- ELLIOTT, G.F. (1964). X-ray diffraction studies on striated and smooth muscles.
Proc. R. Soc. B160: 467-472.
- ELLIOTT, J. (1978). Assessing muscle strength isokinetically.
J. Am. med. Ass. 240: 2408-2409.

- ELLIS, K.O. & CARPENTER, J.F. (1974). Mechanism of control of skeletal-muscle contraction by dantrolene sodium. Archs phys. Med. Rehabil. 55: 362-369.
- ELMQVIST, D., HOFMANN, W.W., KUGELBERG, J. & QUASTEL, D.M.J. (1964). An electrophysiological investigation of neuromuscular transmission in myasthenia gravis. J. Physiol., Lond. 174: 417-434.
- EMERY, A.E.H. (1971). The nosology of the spinal muscular atrophies. J. med. Genet. 8: 481-495.
- EMERY, A.E.H., HAUSMANOWA-PETRUSEWICZ, I., DAVIE, A.M., HOLLOWAY, S., SKINNER, R. & BORKOWSKA, J. (1976a). International collaborative study of the spinal muscular atrophies. Part 1: Analysis of clinical and laboratory data. J. neurol Sci. 29: 83-94.
- EMERY, A.E.H., DAVIE, A.M., HOLLOWAY, S. & SKINNER, R. (1976b). International collaborative study of the spinal muscular atrophies. Part 2: Analysis of genetic data. J. neurol. Sci. 30: 375-384.
- ENDO, M. (1964). Entry of a dye into the sarcotubular system of muscle. Nature, Lond. 202: 1115-1116.
- ENDO, M. (1977). Calcium release from the sarcoplasmic reticulum. Physiol. Rev. 57: 71-108.
- ENGEL, A.G. & SANTA, T. (1971). Histometric analysis of the ultrastructure of the neuromuscular junction in myasthenia gravis and in the myasthenic syndrome. Ann. N.Y. Acad. Sci. 183: 46-63.
- ENGEL, A.G., LINDSTROM, J.M., LAMBERT, E.H. & LENNON, V.A. (1977a). Ultrastructural localization of the acetylcholine receptor in myasthenia gravis and in its experimental autoimmune model. Neurology, Minneap. 27: 307-315.

- ENGEL, A.G., LAMBERT, E.H. & GOMEZ, M.R. (1977b). A new myasthenic syndrome with end-plate acetylcholinesterase deficiency, small nerve terminals and reduced acetylcholine release. Ann. Neurol. 1: 315-330.
- ENGEL, W.K. (1962). The essentiality of histo- and cytochemical studies of skeletal muscle in the investigation of neuromuscular disease. Neurology, Minneap. 12: 778-794.
- ENGEL, W.K. (1970). Selective and nonselective susceptibility of muscle fibre types. A new approach to human neuromuscular diseases. Archs Neurol., Chicago 22: 97-117.
- ENGEL, W.K. & McFARLIN, D.E. (1966). Discussion. Ann. N.Y. Acad. Sci. 135: 68-78.
- FAMBROUGH, D.M., DRACHMAN, D.B. & SATYAMURTI, S. (1973). Neuromuscular junction in myasthenia gravis: decreased acetylcholine receptors. Science, N.Y. 182: 293-295.
- FIEHN, W. & MIGALA, A. (1971). Calcium binding to sarcoplasmic membranes. Eur. J. Biochem. 20: 245-248.
- FINLAYSON, B., LYMN, R.W. & TAYLOR, E.W. (1969). Studies on the kinetics of formation and dissociation of the actomyosin complex. Biochemistry, N.Y. 8: 811-819.
- FLEWELLEN, E.H. & NELSON, T.E. (1980). Dantrolene dose response in malignant hyperthermia-susceptible (MHS) swine: method to obtain prophylaxis and therapeusis. Anesthesiology 52: 303-308.
- FRANZINI-ARMSTRONG, C. (1968). The triadic junction in frog muscle fibres. J. Cell Biol. 39: 6a.

- FRANZINI-ARMSTRONG, C. (1975). Membrane particles and transmission at the triad.
Fedn Proc. Fedn Am. Socs exp. Biol. 34: 1382-1389.
- FRANZINI-ARMSTRONG, C. & PORTER, K.R. (1964). Sarcolemmal invaginations constituting the T system in fish muscle fibres.
J. Cell Biol. 22: 675-696.
- FRIEDMAN, Z & MAKINOSE, M. (1970). Phosphorylation of skeletal muscle microsomes by acetylphosphate.
Fedn Eur. biochem. Soc. Lett. 11: 69-72.
- FUCHS, F. & BRIGGS, F.N. (1968). The site of calcium binding in relation to the activation of myofibrillar contraction.
J. gen. Physiol. 51: 655-676.
- FURUKAWA, T. & TOYOKURA, Y. (1976). Chronic spinal muscular atrophy of facioscapulohumeral type.
J. med. Genet. 13: 285-289.
- GADASI, H., OPLATKA, A., LAMED, R. & MUHLRAD, A. (1974). A comparative study of muscle contraction and superprecipitation using trinitrophenylated myosin and active myosin subfragments.
Biochem. biophys. Res. Commun. 58: 913-918.
- GAGE, P.W. & EISENBERG, R.S. (1967). Action potentials without contraction in frog skeletal muscle fibers with disrupted transverse tubules.
Science, N.Y. 158: 1702-1703.
- GALASKO, C.S.B. (1977). Incidence of orthopaedic problems in children with muscle disease.
Isr. J. med. Sci. 13: 165-176.
- GENKINS, G., PAPATESTAS, A.E., HOROWITZ, S.H. & KGRNFELD, P. (1975). Studies in myasthenia gravis: early thymectomy. Electrophysiologic and pathologic correlations.
Am. J. Med. 58: 517-524.

- GOLL, D.E., SUZUKI, A., TEMPLE, J. & HOLMES, G.R. (1972). Studies on purified α -actinin. I. Effect of temperature and tropomyosin on the α -actinin/F-actin interaction. J. molec. Biol. 67: 469-488.
- GORDON, A.M., HUXLEY, A.F. & JULIAN, F.J. (1966). The variation in isometric tension with sarcomere length in vertebrate muscle fibres. J. Physiol., Lond. 184: 170-192.
- GREASER, M.L. & GERGELY, J. (1971). Reconstitution of troponin activity from three protein components. J. biol. Chem. 246. 4226-4233.
- GREASER, M.L., YAMAGUCHI, M., BREKKE, C., POTTER, J. & GERGELY, J. (1972). Troponin subunits and their interactions. Cold Spring Harb. Symp. quant. Biol. 37: 235-244.
- GRONERT, G.A., MILDE, J.H. & THEYE, R.A. (1976). Dantrolene in porcine malignant hyperthermia. Anesthesiology 44: 488-495.
- HALL, C.E., JAKUS, M.A. & SCHMITT, F.O. (1946). An investigation of cross striations and myosin filaments in muscle. Biol. Bull. mar. biol. Lab., Woods Hole 90: 32-50.
- HANSON, J. & HUXLEY, H.E. (1957). Quantative studies on the structure of cross-striated myofibrils. II. Investigations by biochemical techniques. Biochim. biophys. Acta 23: 250-260.
- HANSON, J. & LOWY, J. (1963). The structure of F-actin and of actin filaments isolated from muscle. J. molec. Biol. 6: 46-60.
- HANSON, J., O'BRIEN, E.J. & BENNETT, P.M. (1971). Structure of the myosin-containing filament assembly (A-segment) separated from frog skeletal muscle. J. molec. Biol. 58: 865-871.

- HARRISON, G.G. (1977). The prophylaxis of malignant hyperthermia by oral dantrolene sodium in swine.
Br. J. Anaesth. 49: 315-317.
- HARTSHORNE, D.J. & DREIZEN, P. (1972). Studies on the subunit composition of troponin.
Cold Spring Harb. Symp. quant. Biol. 37: 225-234.
- HARTSHORNE, D.J. & MUELLER, H. (1969). The preparation of tropomyosin and troponin from natural actomyosin.
Biochim. biophys. Acta 175: 301-319.
- HARVEY, A.M. & MASLAND, R.L. (1941) A method for the study of neuromuscular transmission in human subjects.
Johns Hopkins Hosp. Bull. 68: 81-93.
- HASELGROVE, J.C. (1972). X-ray evidence for a conformational change in the actin-containing filaments of vertebrate striated muscle.
Cold Spring Harb. Symp. quant. Biol. 37: 341-352.
- HASSELBACH, W. (1964). Relaxing factor and the relaxation of muscle.
Prog. Biophys. molec. Biol. 14: 167-222.
- HASSELBACH, W. & ELFVIN, L-G. (1967). Structural and chemical asymmetry of the calcium-transporting membranes of the sarcotubular system as revealed by electron microscopy.
J. Ultrastruct. Res. 17: 598-622.
- HASSELBACH, W. & MAKINOSE, M. (1961). Die Calciumpumpe der „Erschlaffungsgrana“ des Muskels und ihre Abhängigkeit von der ATP-Spaltung.
Biochem. Z. 333: 518-528.
- HASSELBACH, W. & MAKINOSE, M. (1962). ATP and active transport.
Biochem. biophys. Res. Commun. 7: 132-136.

- HASSELBACH, W. & MAKINOSE, M. (1963). Über den Mechanismus des Calciumtransportes durch die Membranen des Sarkoplasmatischen Reticulums.
Biochem. Z. 339: 94-111.
- HEILBRUNN, L.V. & WIERCINSKI, F.J. (1947). The action of various cations on muscle protoplasm.
J. cell. comp. Physiol. 29: 15-32.
- HERASYMOWYCH, O.S., MANI, R.S., KAY, C.M., BRADLEY, R.D. & SCRABA, D.G. (1980). Ultrastructure studies on the binding of creatine kinase and the 165,000 molecular weight component to the M-band of muscle.
J. molec. biol. 136: 193-198.
- HILL, A.V. (1965). Trails and trials in physiology. Edward Arnold, London.
- HODGKIN, A.L. & HOROWICZ, P. (1959). The influence of potassium and chloride ions on the membrane potential of single muscle fibres.
J. Physiol., Lond. 148: 127-160.
- HODGKIN, A.L. & HUXLEY, A.F. (1952a). Currents carried by sodium and potassium ions through the membrane of the giant axon of Loligo.
J. Physiol., Lond. 116: 449-472.
- HODGKIN, A.L. & HUXLEY, A.F. (1952b). A quantitative description of membrane current and its application to conduction and excitation in nerve.
J. Physiol., Lond. 117: 500-544.
- HOLTZER, A., CLARK, R. & LOWEY, S. (1965) The conformation of native and denatured tropomyosin B.
Biochemistry, N.Y. 4: 2401-2411.
- HOWARD, F.M. (1963). A new and effective drug in the treatment of the stiff-man syndrome: preliminary report.
Staff Meet. Mayo Clin. 38: 203-212.

- HUBBARD, J.I., JONES, S.F. & LANDAU, E.M. (1968). On the mechanism by which calcium and magnesium affect the release of transmitter by nerve impulses.
J. Physiol., Lond. 196: 75-86.
- HUGHES, J.T. & BROWNELL, B. (1972). Pathology of peroneal muscular atrophy (Charcot-Marie-Tooth disease).
J. Neurol. Neurosurg. Psychiat. 35: 648-657.
- HUMBERSTONE, P.M. (1972). Nerve conduction studies in Charcot-Marie-Tooth disease.
Acta neurol. scand. 48: 176-190.
- HUXLEY, A.F. (1957). Muscle structure and theories of contraction.
Prog. Biophys. biophys. Chem. 7: 255-318.
- HUXLEY, A.F. (1971). The activation of striated muscle and its mechanical response.
Proc. R. Soc. B178: 1-27.
- HUXLEY, A.F. & NIEDERGERKE, R. (1954). Structural changes in muscle during contraction.
Nature, Lond. 173: 971-973.
- HUXLEY, A.F. & SIMMONS, R.M. (1971). Proposed mechanism of force generation in striated muscle.
Nature, Lond. 233: 533-538.
- HUXLEY, A.F. & TAYLOR, R.E. (1958). Local activation of striated muscle fibres.
J. Physiol., Lond. 144: 426-441.
- HUXLEY, H.E. (1953a). Electron microscope studies of the organisation of the filaments in striated muscle.
Biochim. biophys. Acta 12: 387-394.
- HUXLEY, H.E. (1953b). X-ray analysis and the problem of muscle.
Proc. R. Soc. B141: 59-62.
- HUXLEY, H.E. (1956). The ultra-structure of striated muscle.
Br. med. Bull. 12: 171-173.

- HUXLEY, H.E. (1963). Electron microscope studies on the structure of natural and synthetic protein filaments from striated muscle.
J. molec. Biol. 7: 281-308.
- HUXLEY, H.E. (1964). Evidence for continuity between the central elements of the triads and extracellular space in frog sartorius muscle.
Nature, Lond. 202: 1067-1071.
- HUXLEY, H.E. (1968). Structural difference between resting and rigor muscle; evidence from intensity changes in the low-angle equatorial x-ray diagram.
J. molec. Biol. 37: 507-520.
- HUXLEY, H.E. (1969). The mechanism of muscular contraction. Recent structural studies suggest a revealing model for cross-bridge action at variable filament spacing.
Science, N.Y. 164: 1356-1366.
- HUXLEY, H.E. (1972). Structural changes in the actin- and myosin-containing filaments during contraction.
Cold Spring Harb. Symp. quant. Biol. 37: 361-376.
- HUXLEY, H.E. & BROWN, W. (1967). The low-angle x-ray diagram of vertebrate striated muscle and its behaviour during contraction and rigor.
J. molec. Biol. 30: 383-434.
- HUXLEY, H.E. & HANSON, J. (1954). Changes in the cross-striations of muscle during contraction and stretch and their structural interpretation.
Nature, Lond. 173: 973-976.
- HUXLEY, H.E., FARUQI, A.R., BORDAS, J., KOCH, M.H.J. & MILCH, J.R. (1980). The use of synchrotron radiation in time-resolved x-ray diffraction studies of myosin layer-line reflections during muscle contraction.
Nature, Lond. 284: 140-143.

- IKEMOTO, N., SRETER, F.A. & GERGELY, J. (1971). Structural features of the surface of the vesicles of FSR - lack of functional role in Ca^{2+} uptake and ATPase activity. Archs Biochem. Biophys. 147: 571-582.
- IKEMOTO, N., BHATNAGAR, G.M., NAGY, B. & GERGELY, J. (1972). Interaction of divalent cations with the 55,000-dalton protein component of the sarcoplasmic reticulum. Studies of fluorescence and circular dichroism. J. biol. Chem. 247: 7835-7837.
- IKEMOTO, N., NAGY, B., BHATNAGAR, G.M. & GERGELY, J. (1974). Studies on a metal-binding protein of the sarcoplasmic reticulum. J. biol. Chem. 249: 2357-2365.
- INESI, G. & ASAI, H. (1968). Trypsin digestion of fragmented sarcoplasmic reticulum. Archs Biochem. Biophys. 126: 469-477.
- INESI, G. & MALAN, N. (1976). Mechanisms of calcium release in sarcoplasmic reticulum. Life Sci. 18: 773-779.
- INESI, G., COHEN, J.A. & COAN, C.R. (1976). Two functional states of sarcoplasmic reticulum ATPase. Biochemistry, N.Y. 15: 5293-5298.
- INESI, G., MARING, E., MURPHY, A.J. & MCFARLAND, B.H. (1974). A study of the phosphorylated intermediate of sarcoplasmic reticulum ATPase. Archs Biochem. Biophys. 138: 285-294.
- INESI, G., KURZMACK, M., COAN, C. & LEWIS, D.E. (1980). Co-operative calcium binding and ATPase activation in sarcoplasmic reticulum vesicles. J. biol. Chem. 255: 3025-3031.

- INOUE, A. & TONOMURA, Y. (1976). Separation of subfragment-1 of H-meromyosin into two equimolar fractions with and without formation of the reactive enzyme-phosphate-ADP complex. J. Biochem., Tokyo 79: 419-434.
- ISAACS, H. (1977). Comments on predictive tests for malignant hyperthermia. In: Second international symposium on malignant hyperthermia (eds J.A. Aldrette & B.A. Britt), pp. 351-362. Grune & Stratton, New York.
- ISAACS, H. (1979). Stiff man syndrome in a black girl. J. Neurol. Neurosurg. Psychiat. 42: 988-994.
- ISAACS, H. & BARLOW, M.B. (1970a). Malignant hyperpyrexia during anaesthesia: possible association with subclinical myopathy. Br. med. J. 1: 275-277.
- ISAACS, H. & BARLOW, M.B. (1970b). The genetic background to malignant hyperpyrexia revealed by serum creatine phosphokinase estimations in asymptomatic relatives. Br. J. Anaesth. 42: 1077-1084.
- ISAACS, H. & BARLOW, M.B. (1973). Malignant hyperpyrexia. Further muscle studies in asymptomatic carriers identified by creatinine phosphokinase screening. J. Neurol. Neurosurg. Psychiat. 36: 228-243.
- ISAACS, H. & HEFFRON, J.J.A. (1975). Morphological and biochemical defects in muscles of human carriers of the malignant hyperthermia syndrome. Br. J. Anaesth. 47: 475-481.
- ISAACS, H., FRERE, G. & MITCHELL, J. (1973). Histological, histochemical and ultramicroscopic findings in muscle biopsies from carriers of the trait for malignant hyperpyrexia. Br. J. Anaesth. 45: 860-868.
- ISAACS, H., HEFFRON, J.J.A. & BADENHORST, M. (1975). 'Picture frame' fibres in a carrier of the trait for malignant hyperpyrexia. S.Afr. med. J. 49: 1923-1926.

- JÖBSIS, F.F. & O'CONNOR, M.J. (1966). Calcium release and re-absorption in the sartorius muscle of the toad.
Biochem. biophys. Res. Commun. 25: 246-252.
- KALOW, W., BRITT, B.A., TERREAU, M.E. & HAIST, C. (1970). Metabolic error of muscle metabolism after recovery from malignant hyperthermia.
Lancet 2: 895-898.
- KANAZAWA, T., YAMADA, S. & TONOMURA, Y. (1970). ATP formation from ADP and a phosphorylated intermediate of Ca^{2+} -dependent ATPase in fragmented sarcoplasmic reticulum.
J. Biochem., Tokyo 68: 593-595.
- KANAZAWA, T., YAMADA, S., YAMAMOTO, T. & TONOMURA, Y. (1971). Reaction mechanism of the Ca^{2+} -dependent ATPase of sarcoplasmic reticulum from skeletal muscle. V. Vectorial requirements for calcium and magnesium ions of three partial reactions of ATPase: formation and decomposition of a phosphorylated intermediate and ATP-formation from ADP and the intermediate.
J. Biochem., Tokyo 70: 95-123.
- KASAI, M. & MIYAMOTO, H. (1973). Depolarization induced calcium release from sarcoplasmic reticulum membrane fragments by changing ionic environment.
Fedn Eur. biochem. Soc. Lett. 34: 299-301.
- KATZ, B. & MILEDI, R. (1968). The role of calcium in neuromuscular facilitation.
J. Physiol., Lond. 195: 481-492.
- KEESEY, J., LINDSTROM, J., COKELY, H. & HERRMANN, C. (1977). Anti-acetylcholine receptor antibody in neonatal myasthenia gravis.
New Engl. J. Med. 296: 55.
- KEESEY, J., BEIN, M., MINK, J., SAMPLE, F., SARTI, D., MULDER, D., HERRMANN, C. & PETER, J.B. (1980). Detection of thymoma in myasthenia gravis.
Neurology, Minneap. 30: 233-239.

- KELLY, D.E. (1969). The fine structure of skeletal muscle triad junctions.
J. Ultrastruct. Res. 29: 37-49.
- KENDALL, H.O. & KENDALL, F.P. (Revised 1939). Care during the recovery period in paralytic poliomyelitis. Public Health Bulletin (U.S. Public Health Service) no. 242, Washington.
- KERR, D.D., WINGARD, D.W. & GATZ, E.E. (1977). Prevention of porcine malignant hyperthermia by oral dantrolene. In: Second international symposium on malignant hyperthermia (eds J.A. Aldrette & B.A. Britt), pp. 499-508. Grune & Stratton, New York.
- KIELLEY, W.W. & MEYERHOF, O. (1948). Studies on adenosinetriphosphatase of muscle. II. A new magnesium-activated adenosinetriphosphatase.
J. biol. Chem. 176: 591-601.
- KIELLEY, W.W. & MEYERHOF, O. (1950). Studies on adenosinetriphosphatase of muscle. III. The lipoprotein nature of the magnesium-activated adenosinetriphosphatase.
J. biol. Chem. 183: 391-401.
- KOSOWER, E.M. & WERMAN, R. (1971). New step in transmitter release at the myoneural junction.
Nature (New Biol.) 233: 121-123.
- KRIEBEL, M.E., LLADOS, F. & MATTESON, D.R. (1976). Spontaneous subminiature end-plate potentials in mouse diaphragm muscle: evidence for synchronous release.
J. Physiol., Lond. 262: 553-581.
- KUBA, K. (1970). Effects of catecholamines on the neuromuscular junction in the rat diaphragm.
J. Physiol., Lond. 211: 551-570.
- KUBA, K. & TOMITA, T. (1971). Noradrenaline action on nerve terminal in the rat diaphragm.
J. Physiol., Lond. 217: 19-31.

- KUGELBERG, E. & WELANDER, L. (1956). Heredofamilial juvenile muscular atrophy simulating muscular dystrophy. Archs Neurol. Psychiat. 75: 500-509.
- LEADBEATER, L. & PERRY, S.V. (1963). The effect of actin on the magnesium-activated adenosine triphosphatase of heavy mero-myosin. Biochem. J. 87: 233-238.
- LEE, C.Y. (1972). Chemistry and pharmacology of polypeptide toxins in snake venoms. A. Rev. Pharmac. 12: 265-286.
- LEFVERT, A.K., BERGSTRÖM, K., MATELL, G., OSTERMAN, P.O. & PIRSKANEN, R. (1978). Determination of acetylcholine receptor antibody in myasthenia gravis: clinical usefulness and pathogenetic implications. J. Neurol. Neurosurg. Psychiat. 41: 394-403.
- LIEBERMAN, A.T. (1942). Myasthenia gravis with acute fulminating onset in a child five years old. J. Am. med. Ass. 120: 1209-1211.
- LINDSTROM, J.M., SEYBOLD, M.E., LENNON, V.A., WHITTINGHAM, S. & DUANE, D.D. (1976). Antibody to acetylcholine receptor in myasthenia gravis. Prevalence, clinical correlates, and diagnostic value. Neurology, Minneap. 26: 1054-1059.
- LONGLEY, W. (1977). A new crystalline form of tropomyosin. J. molec. Biol. 115: 381-387.
- LOWEY, S. & COHEN, C. (1962). Studies on the structure of myosin. J. molec. Biol. 4: 293-308.
- LOWEY, S. & STEINER, L.A. (1972). An immunochemical approach to the structure of myosin and the thick filament. J. molec. Biol. 65: 111-126.

- LOWEY, S., SLAYTER, H.S., WEEDS, A.G. & BAKER, H. (1969). Sub-structure of the myosin molecule. I. Subfragments of myosin by enzymic degradation.
J. molec. Biol. 42: 1-29.
- LYMN, R.W. & TAYLOR, E.W. (1970). Transient state phosphate production in the hydrolysis of nucleoside triphosphates by myosin.
Biochemistry, N.Y. 9: 2975-2983.
- LYMN, R.W. & TAYLOR, E.W. (1971). Mechanism of adenosine triphosphate hydrolysis by actomyosin.
Biochemistry, N.Y. 10: 4617-4624.
- MACLENNAN, D.H. (1970). Purification and properties of an adenosine triphosphatase from sarcoplasmic reticulum.
J. biol. Chem. 245: 4508-4518.
- MACLENNAN, D.H. & WONG, P.T.S. (1971). Isolation of a calcium-sequestering protein from sarcoplasmic reticulum (rabbit/deoxycholate/column chromatography/transport).
Proc. natn. Acad. Sci. U.S.A. 68: 1231-1235.
- MACLENNAN, D.H., SEEMAN, P., ILES, G.H. & YIP, C.C. (1971). Membrane formation by the adenosine triphosphatase of sarcoplasmic reticulum.
J. biol. Chem. 246: 2702-2710.
- MACLENNAN, D.H., OSTWALD, T.J. & STEWART, P.S. (1974). Structural components of the sarcoplasmic reticulum membrane.
Ann. N.Y. Acad. Sci. 227: 527-536.
- MAIDA, E., REISNER, T., SUMMER, K. & SANDOR-EGGERTH, H. (1980). Stiff-man syndrome with abnormalities in CSF and computerized tomography findings.
Archs Neurol., Chicago 37: 182-183.
- MAKINOSE, M. (1971). Calcium efflux dependent formation of ATP from ADP and orthophosphate by the membranes of the sarcoplasmic vesicles.
Fedn Eur. biochem. Soc. Lett. 12: 269-270.

- MAKINOSE, M. (1972). Phosphoprotein formation during osmo-chemical energy conversion in the membrane of the sarcoplasmic reticulum. Fedn Eur. biochem. Soc. Lett. 25: 113-115.
- MARGOSSIAN, S.S. & LOWEY, S. (1973). Substructure of the myosin molecule. IV. Interactions of myosin and its subfragments with adenosine triphosphate and F-actin. J. molec. Biol. 74: 313-330.
- MARSDEN, C.D. (1975). Inherited neuronal atrophy and degeneration predominantly of lower motor neurons. In: Peripheral neuropathy (eds P.J. Dyck, P.K. Thomas & E.H. Lambert), pp. 771-790. Saunders, Philadelphia.
- MARSH, B.B. (1951). A factor modifying muscle fibre synæresis. Nature, Lond. 167: 1065-1066.
- MARSH, B.B. (1952). The effects of adenosine triphosphate on the fibre volume of a muscle homogenate. Biochim. biophys. Acta 9: 247-260.
- MARSHALL, A. & DUCHEN, L.W. (1975). Sensory system involvement in infantile spinal muscular atrophy. J. neurol. Sci. 26: 349-359.
- MARSTON, S.B. & TREGGAR, R.T. (1972). Evidence for a complex between myosin and ADP in relaxed muscle fibres. Nature (New Biol.) 235: 23-24.
- MARTINELLI, P., PAZZAGLIA, P., MONTAGNA, P., COCCAGNA, G., RIZZUTO, N., SIMONATI, S. & LUGARESI, E. (1978). Stiff-man syndrome associated with nocturnal myoclonus and epilepsy. J. Neurol. Neurosurg. Psychiat. 41: 458-462.
- MARTONOSI, A. (1971). The structure and function of sarcoplasmic reticulum membranes. In: Biomembranes, vol. 1 (ed. L.A. Manson), pp. 191-256. Plenum Press, New York.

- MARTONOSI, A., DONLEY, J. & HALPIN, R.A. (1968). Sarcoplasmic reticulum. III. The role of phospholipids in the adenosine triphosphatase activity and Ca^{++} transport. J. biol. Chem. 243: 61-70.
- MARTONOSI, A., LAGWINSKA, E. & OLIVER, M. (1974). Elementary processes in the hydrolysis of ATP by sarcoplasmic reticulum membranes. Ann. N.Y. Acad. Sci. 227: 549-567.
- MARUYAMA, K. (1965). Some physico-chemical properties of β -actinin, "actin-factor", isolated from striated muscle. Biochim. biophys. Acta 102: 542-548.
- MATTIS, R.D. (1941). Ocular manifestations in myasthenia gravis. Archs Ophthal. 26: 969-982.
- McLEOD, J.G., LOW, P.A. & MORGAN, J.A. (1978). Charcot-Marie-Tooth disease with Leber optic atrophy. Neurology, Minneap. 28: 179-184.
- McQUILLEN, M.P. (1966). Familial limb-girdle myasthenia. Brain 89: 121-132.
- MEADOWS, J.C., MARSDEN, C.D. & HARRIS, D.G.F. (1969). Chronic spinal muscular atrophy in adults. Part 1: The Kugelberg-Welander syndrome. J. neurol. Sci. 9: 527-550.
- MEISSNER, G. (1974). Heterogeneity of sarcoplasmic reticulum (SR) vesicles. Fedn Proc. Fedn Am. Socs exp. Biol. 33: 1283.
- MEISSNER, G. (1975). Isolation and characterization of two types of sarcoplasmic reticulum vesicles. Biochim. biophys. Acta 389: 51-68.
- MEISSNER, G. & McKINLEY, D. (1976). Permeability of sarcoplasmic reticulum membrane. The effect of changed ionic environments on Ca^{2+} release. J. memb. Biol. 30: 79-98.

- MEISSNER, G., CONNER, G.E. & FLEISCHER, S. (1973). Isolation of sarcoplasmic reticulum by zonal centrifugation and purification of Ca^{2+} -pump and Ca^{2+} -binding proteins. Biochim. biophys. Acta 298: 246-269.
- MIHÁLYI, E. & SZENT-GYÖRGYI, A.G. (1953). Trypsin digestion of muscle proteins. I. Ultracentrifugal analysis of the process. J. biol. Chem. 201: 189-196.
- MILLER, A. & TREGGAR, R.T. (1971). X-ray studies on the structure and function of vertebrate and invertebrate muscle. In: Contractility of muscle cells and related processes (ed. R.J. Podolsky), pp. 205-228. Prentice-Hall, New York.
- MILLICHAP, J.G. & DODGE, P.R. (1950). Diagnosis and treatment of myasthenia gravis in infancy, childhood and adolescence. A study of 51 patients. Neurology, Minneap. 10: 1007-1014.
- MILLWARD, G.R. & WOODS, E.F. (1970). Crystals of tropomyosin from various sources. J. molec. Biol. 52: 585-588.
- MITTAG, T., KORNFELD, P., TORMAY, A. & WOO, C. (1976). Detection of anti-acetylcholine receptor factors in serum and thymus from patients with myasthenia gravis. New Engl. J. Med. 294: 691-694.
- MOERSCH, F.P. & WOLTMAN, H.W. (1956). Progressive fluctuating muscular rigidity and spasm ("stiff-man" syndrome): report of a case and some observations in 13 other cases. Proc. Staff Meet. Mayo Clin. 31: 421-427.
- MOGENSEN, J.V., MISFELDT, B.B. & HANEL, H.K. (1974). Preoperative excitement and malignant hyperthermia. Lancet 1: 461.

- MOORE, P.B., HUXLEY, H.E. & DeROSIER, D.J. (1970). Three-dimensional reconstruction of F-actin, thin filaments and decorated thin filaments.
J. molec. Biol. 50: 279-295.
- MOOS, C. (1972). Actin activation of heavy meromyosin and subfragment-1 ATPases; steady state kinetics studies.
Cold Spring Harb. Symp. quant. Biol. 37: 137-143.
- MOOSA, A. & DUBOWITZ, V. (1976). Motor nerve conduction velocity in spinal muscular atrophy of childhood.
Archs dis. Childh. 51: 974-977.
- MORIMOTO, K. & HARRINGTON, W.F. (1972). Isolation and physical chemical properties of an M-line protein from skeletal muscle.
J. biol. Chem. 247: 3052-3061.
- MUELLER, H. & PERRY, S.V. (1962). The degradation of heavy meromyosin by trypsin.
Biochem. J. 85: 431-439.
- MURPHY, A.J. & MORALES, M.F. (1970). Number and location of adenosine triphosphatase.
Biochemistry, N.Y. 9: 1528-1532.
- MUSCATELLO, U., ANDERSSON-CEDERGREN, E. & AZZONE, G.F. (1962). The mechanism of muscle-fiber relaxation. Adenosine triphosphatase and relaxing activity of the sarcotubular system.
Biochim. biophys. Acta 63: 55-74.
- NAKAJIMA, Y. & ENDO, M. (1973). Release of calcium induced by 'depolarisation' of the sarcoplasmic reticulum membrane.
Nature (New Biol.) 246: 216-218.
- NAMBA, T., NAKATA, Y. & GROB, D. (1976). The role of humoral and cellular immune factors in neuromuscular block in myasthenia gravis.
Ann. N.Y. Acad. Sci. 274: 493-515.

- NATHANSON, N.M. & HALL, Z.W. (1980). In situ labeling of torpedo and rat muscle acetylcholine receptor by a photoaffinity derivative of α -bungarotoxin.
J. biol. Chem. 255: 1698-1703.
- O'CONNOR, D.C.J. (1958). Stiff-man syndrome.
Br. med. J. 1: 645.
- ODA, K., GOTO, I., KUROIWA, Y., ONOUE, K. & ITO, Y. (1980). Myasthenia gravis: antibodies to acetylcholine receptor with human and rat antigens.
Neurology, Minneap. 30: 543-546.
- OFFER, G. (1972). C-protein and the periodicity in the thick filaments of vertebrate skeletal muscle.
Cold Spring Harb. Symp. quant. Biol. 37: 87-93.
- OFFER, G. & ELLIOTT, A. (1978). Can a myosin molecule bind to two actin filaments?
Nature, Lond. 271: 325-329.
- OHNISHI, T. & EBASHI, S. (1963). Spectrophotometrical measurement of instantaneous calcium binding of the relaxing factor of muscle.
J. Biochem., Tokyo 54: 506-511.
- OHNISHI, T. & EBASHI, S. (1964). The velocity of calcium binding of isolated sarcoplasmic reticulum.
J. Biochem., Tokyo 55: 599-603.
- OHTSUKI, J., MASAKI, T., NONOMURA, Y. & EBASHI, S. (1967). Periodic distribution of troponin along the thin filament.
J. Biochem., Tokyo 61: 817-819.
- OSSERMAN, K.E. (1958). Myasthenia gravis. Grune & Stratton, New York.
- OSSERMAN, K.E., TSAIRIS, P. & WEINER, L.B. (1967). Myasthenia gravis and thyroid disease: clinical and immunologic correlation.
J. Mt Sinai Hosp. 34: 469-483.

- OSTWALD, T.J. & MACLENNAN, D.H. (1974). Isolation of a high affinity calcium-binding protein from sarcoplasmic reticulum. J. biol. Chem 249: 974-979.
- ÖZDEMİR, C. & YOUNG, R.R. (1976). The results to be expected from electrical testing in the diagnosis of myasthenia gravis. Ann. N.Y. Acad. Sci. 274: 203-222.
- PAGE, S.G. (1965). A comparison of the fine structures of frog slow and twitch muscle fibres. J. Cell Biol. 26: 477-497.
- PANDIT, S.K., KOTHARY, S.P. & COHEN, P.J. (1979). Orally administered dantrolene for prophylaxis of malignant hyperthermia. Anesthesiology 50: 156-158.
- PANET, R. & SELINGER, Z. (1972). Synthesis of ATP coupled to Ca^{2+} release from sarcoplasmic reticulum vesicles. Biochim. biophys. Acta 255: 34-42.
- PANET, R., PICK, U. & SELINGER, Z. (1971). The role of calcium and magnesium in the adenosine triphosphatase reaction of sarcoplasmic reticulum. J. biol. Chem. 246: 7349-7356.
- PARDEE, A.B. (1968a). Membrane transport proteins. Proteins that appear to be parts of membrane transport systems are being isolated and characterized. Science, N.Y. 162: 632-637.
- PARDEE, A.B. (1968b). Biochemical studies on active transport. J. gen. Physiol. 52: 279s-283s.
- *PEACHEY, L.D. (1965). The sarcoplasmic reticulum and transverse tubules of the frog's sartorius. J. Cell Biol. 25(2): 209-231.

*Part number given, since each part commences with "page 1".

- PEACHEY, L.D. (1968). Muscle.
A. Rev. Physiol. 30: 401-440.
- PEACHEY, L.D. (1972). Electrical events in the T-system of frog skeletal muscle.
Cold Spring Harb. Symp. quant. Biol. 37: 479-487.
- PEACHEY, L.D. & SCHILD, R.F. (1968). The distribution of the T-system along the sarcomeres of frog and toad sartorius muscles.
J. Physiol., Lond. 194: 249-258.
- PEARN, J.H. (1978). Genetic studies of acute infantile spinal muscular atrophy (SMA type I). An analysis of sex ratios, segregation ratios, and sex influence.
J. med. Genet. 15: 414-417.
- PEARN, J.H. (1980). Classification of spinal muscular atrophies.
Lancet 1: 919-922.
- PEARN, J.H., CARTER, C.O. & WILSON, J. (1973). The genetic identity of acute infantile spinal muscular atrophy.
Brain 96: 463-470.
- PEARN, J.H., HUDGSON, P. & WALTON, J.N. (1978a). A clinical and genetic study of spinal muscular atrophy of adult onset. The autosomal recessive form as a discrete disease entity.
Brain 101: 591-606.
- PEARN, J.H., BUNDEY, S., CARTER, C.O., WILSON, J., GARDNER-MEDWIN, D. & WALTON, J.N. (1978b). A genetic study of subacute and chronic spinal muscular atrophy in childhood. A nosological analysis of 124 index patients.
J. neurol. Sci. 37: 227-248.
- PEARSON, C.M. & MOSTOFI, M.D. (1973). The striated muscle (International Academy of Pathology Monograph no. 12). Williams & Wilkins, Baltimore.

- PEPE, F.A. (1967). The myosin filament. I. Structural organization from antibody staining observed in electron microscopy. J. molec. Biol. 27: 203-225.
- PEPE, F.A. (1968). Analysis of antibody staining patterns obtained with striated myofibrils in fluorescence microscopy and electron microscopy. Int. Rev. Cytol. 24: 193-231.
- PERRY, S.V., COLE, H.A., HEAD, J.F. & WILSON, F.J. (1972). Localization and mode of action of the inhibitory protein component of the troponin complex. Cold Spring Harb. Symp. quant. Biol. 37: 251-262.
- PODOLSKY, R.J. & TEICHOLZ, L.E. (1970). The relation between calcium and contraction kinetics in skinned muscle fibers. J. Physiol., Lond. 211: 19-35.
- PODOLSKY, R.J., HALL, T. & HATCHETT, S.L. (1970). Identification of oxalate precipitates in striated muscle fibres. J. Cell Biol. 44: 699-702.
- POLLARD, J.D., BASTEN, A., HASSALL, J.E., KRONENBERG, H., COBCROFT, R. & DAWKINS, R. (1980). Current trends in the management of myasthenia gravis: plasmapheresis and immunosuppressive therapy. Aust. N.Z. J. Med. 10: 212-217.
- PORTER, K.R. (1961). The sarcoplasmic reticulum. Its recent history and present status. J. biophys. biochem. Cytol. Suppl. no. 10: 219-226.
- PORTER, K.R. & PALADE, G.E. (1957). Studies on the endoplasmic reticulum. III. Its form and distribution in striated muscle cells. J. biophys. biochem. Cytol. 3: 269-299.
- PRINGLE, J.W.S. (1967). The contractile mechanism of insect fibrillar muscle. Prog. Biophys. molec. Biol. 17: 1-60.

- PUCCELL, A. & MARTONOSI, A. (1971). Sarcoplasmic reticulum. XIV. Acetylphosphate and carbamylphosphate as energy sources for Ca^{++} transport. J. biol. Chem. 246: 3389-3397.
- PUTNEY, J.W. & BIANCHI, C.P. (1974). Site of action of dantrolene in frog sartorius muscle. J. Pharmac. exp. Ther. 189: 202-212.
- REISLER, E. (1980). On the question of co-operative interaction of myosin heads with F-actin in the presence of ATP. J. molec. Biol. 138: 93-107.
- RICE, R.V., BRADY, A.C., DEPUE, R.H. & KELLY, R.E. (1966). Morphology of individual macromolecules and their ordered aggregates by electron microscopy. Biochem. Z. 345: 370-394.
- RICHMAN, D.P., ANTEL, J.P., PATRICK, J.W. & ARNASON, B.G.W. (1979). Cellular immunity to acetylcholine receptor in myasthenia gravis: relationship to histocompatibility type and antigenic site. Neurology, Minneap. 29: 291-296.
- RINGER, S. & BUXTON, D.W. (1887). Upon the similarity and dissimilarity of the behaviour of cardiac and skeletal muscle when brought into relation with solutions containing sodium, calcium and potassium salts. J. Physiol., Lond. 8: 288-295.
- SALISACHS, P. (1974). Wide spectrum of motor conduction velocity in Charcot-Marie-Tooth disease. An anatomico-physiological interpretation. J. neurol Sci. 23: 25-31.
- SALISACHS, P. (1976). Charcot-Marie-Tooth disease associated with "essential tremor". J. neurol. Sci. 28: 17-40.

- SAMAHA, F.J. & GERGELY, J. (1969). Biochemical abnormalities of the sarcoplasmic reticulum in muscular dystrophy. New Engl. J. Med. 280: 184-188.
- SAMTLEBEN, W., BESINGER, U.A., TOYKA, K.V., FATEH-MOGHADAM, A., BREHM, G. & GURLAND, H.J. (1980). Plasma-separation in myasthenia gravis: a new method of rapid plasma exchange. Klin. Wschr. 58: 47-49.
- SANTA, T., ENGEL, A.G. & LAMBERT, E.H. (1972). Histometric study of neuromuscular junction ultrastructure. I. Myasthenia gravis. Neurology, Minneap. 22: 71-82.
- SARZAŁA, M.G., PIARSKA, M., ZUBRZYCKA, E. & MICHALAK, M. (1975). Changes in the structure, composition and function of sarcoplasmic-reticulum membrane during development. Eur. J. Biochem. 57: 25-34.
- SCALES, D. & INESI, G. (1976). Assembly of ATPase protein in sarcoplasmic reticulum membranes. Biophys. J. 16: 735-751.
- SCHMIDT, R.T., STAHL, S.M. & SPEHLMANN, R. (1975). A pharmacologic study of the stiff-man syndrome. Correlation of clinical symptoms with urinary 3-methoxy-4-hydroxy-phenyl glycol excretion. Neurology, Minneap. 25: 622-626.
- SCHWARTZ, M.S. & MOOSA, A. (1977). Sensory nerve conduction in the spinal muscular atrophies. Devl. Med. Child Neurol. 19: 50-53.
- SCHWENTKER, E.P. & GIBSON, D.A. (1976). The orthopaedic aspects of spinal muscular atrophy. J. Bone Jt. Surg. 58A: 32-38.

- SEIDEL, J.C. & GERGELY, J. (1963). Studies on myofibrillar adenosine triphosphatase with calcium-free adenosine triphosphate. I. The effect of ethylenediaminetetraacetate, calcium, magnesium, and adenosine triphosphate. J. biol. Chem. 238: 3648-3653.
- SELBY, C.C. & BEAR, R.S. (1956). The structure of actin-rich filaments of muscles according to x-ray diffraction. J. biophys. biochem. Cytol. 2: 71-85.
- SEYBOLD, W.D., McDONALD, J.R., CLAGETT, O.T. & GOOD, C.A. (1950). Tumors of the thymus. J. Thorac. Surg. 20: 195-215.
- SIMPSON, J.A. (1960). Myasthenia gravis: a new hypothesis. Scott. med. J. 5: 419-436.
- SJÖSTRAND, F.S. (1956). The ultrastructure of cells as revealed by the electron microscope. Int. Rev. Cytol. 5: 455-533.
- SMORTO, M.P. & BASMAJIAN, J.V. (1979). Clinical electroneurography. An introduction to nerve conduction tests. (2nd ed.). Williams and Wilkins, Baltimore.
- SPUDICH, J.A., HUXLEY, H.E. & FINCH, J.T. (1972). Regulation of skeletal muscle contraction. II. Structural studies of the interaction of the tropomyosin-troponin complex with actin. J. molec. Biol. 72: 619-632.
- STARR, R. & OFFER, G. (1971). Polypeptide chains of intermediate molecular weight in myosin preparations. Fedn Eur. biochem. Soc. Lett. 15: 40-44.
- STEERS, A.J.W., TALLACK, J.A. & THOMPSON, D.E.A. (1970). Fulminating hyperpyrexia during anaesthesia in a member of a myopathic family. Br. med. J. 2: 341-343.

- STEPHENSON, D.G. & FORREST, Q.G. (1980). Different isometric force- $[Ca^{2+}]$ relationships in slow and fast twitch skinned muscle fibres of the rat.
Biochim. Biophys. Acta 589: 358-362.
- STEWART, P.S., MACLENNAN, D.H. & SHAMOO, A.E. (1976). Isolation and characterization of tryptic fragments of the adenosine triphosphatase of sarcoplasmic reticulum.
J. Biol. Chem. 251: 712-719.
- STROMER, M.H., HARTSHORNE, D.J., MUELLER, H. & RICE, R.V. (1969). The effect of various protein fractions on Z- and M-line reconstitution.
J. Cell Biol. 40: 167-178.
- STULL, J.T., MANNING, D.R., HIGH, C.W. & BLUMENTHAL, D.K. (1980). Phosphorylation of contractile proteins in heart and skeletal muscle.
Fedn Proc. Fedn Am. Socs exp. Biol. 39: 1552-1557.
- SZENT-GYÖRGYI, A.G. (1953). Meromyosins, the subunits of myosin.
Archs Biochem. Biophys. 42: 305-320.
- TADA, M., YAMAMOTO, T. & TONOMURA, Y. (1978). Molecular mechanism of active calcium transport by sarcoplasmic reticulum.
Physiol. Rev. 58: 1-79.
- TAKEUCHI, K. & TONOMURA, Y. (1971). Formation of acto-H-meromyosin and acto-subfragment-1 complexes and their dissociation by adenosine triphosphate.
J. Biochem., Tokyo 70: 1011-1026.
- TAYLOR, S.R. & GODT, P.E. (1977). Calcium release and contraction in vertebrate skeletal muscle.
Symp. Soc. exp. Biol. 30: 361-380.
- TAYLOR, E.W., LYMN, P.W. & MOLL, G. (1970). Myosin - product complex and its effect on the steady-state rate of nucleoside triphosphate hydrolysis.
Biochemistry, N.Y. 9: 2984-2991.

- THOMAS, P.K., CALNE, D.B. & STEWART, G. (1974). Hereditary motor and sensory polyneuropathy (peroneal muscular atrophy). Ann. hum. Genet. 38: 111-153.
- THORLEY-LAWSON, D.A. & GREEN, N.M. (1973). Studies on the location and orientation of proteins in the sarcoplasmic reticulum. Eur. J. Biochem. 40: 403-413.
- TINDALL, R.S.A., CLOUD, R., LUBY, J. & ROSENBERG, R.N. (1978). Serum antibodies to cytomegalovirus in myasthenia gravis: effects of thymectomy and steroids. Neurology, Minneap. 28: 273-277.
- TOKIWA, T. & MORALES, M.F. (1971). Independent and cooperative reactions of myosin heads with F-actin in the presence of adenosine triphosphate. Biochemistry, N.Y. 10: 1722-1727.
- TONOMURA, Y. (1973). Muscle proteins, muscle contraction and cation transport. University Press, Baltimore.
- TONOMURA, Y. & FUKUSHIMA, Y. (1974). Kinetic properties of phosphorylated intermediates in the reaction of Na^+ , K^+ -ATPase. Ann. N.Y. Acad. Sci. 242: 92-105.
- TROTTA, P.P., DREIZEN, P. & STRACHER, A. (1968). Studies on subfragment-1, a biologically active fragment of myosin. Proc. natn. Acad. Sci. U.S.A. 61: 659-666.
- VIANNA, A.L. (1975). Interaction of calcium and magnesium in activating and inhibiting the nucleoside triphosphatase of sarcoplasmic reticulum vesicles. Biochim. biophys. Acta 410: 389-406.
- WATANABE, S. & SLEATOR, W. (1957). EDTA relaxation of glycerol-treated muscle fibers, and the effects of magnesium, calcium and manganese ions. Archs Biochem. Biophys. 68: 81-101.

- WEBER, A. & BREMEL, R.D. (1971). Regulation of contraction and relaxation in the myofibril. In: Contractility of muscle cells and related processes (ed. R.J. Podolsky), pp. 37-53. Prentice-Hall, New York.
- WEBER, A. & HERZ, R. (1963). The binding of calcium to actomyosin systems in relation to their biological activity. J. biol. Chem. 238: 599-605.
- WEBER, A. & MURRAY, J.M. (1973). Molecular control mechanisms in muscle contraction. Physiol. Rev. 53: 612-673.
- WEBER, A. & WINICUR, S. (1961). The role of calcium in the super-precipitation of actomyosin. J. biol. Chem. 236: 3198-3202.
- WEBER, H.H. & PORTZEHL, H. (1952). Kontraktion, ATP-Cyclus und fibrilläre Proteine des Muskels. Ergebn. Physiol. 47: 370-468.
- WEBER, A., HERZ, R. & REISS, I. (1966). Study of the kinetics of calcium transport by isolated fragmented sarcoplasmic reticulum. Biochem. Z. 345. 329-369.
- WERNIG, A. (1976). Localization of active sites in the neuromuscular junction of the frog. Brain Res., Osaka 118: 63-72.
- WINEGRAD, S. (1965). The location of muscle calcium with respect to the myofibrils. J. gen. Physiol. 48: 997-1002.
- WINEGRAD, S. (1970). The intracellular site of calcium activation of contraction in frog skeletal muscle. J. gen. Physiol. 55: 77-88.
- WINGARD, D.W. & GATZ, E.E. (1977). Some observations on stress susceptible patients. In: Second international symposium on malignant hyperthermia (eds J.A. Aldrette & B.A. Britt), pp. 363-372. Grune & Stratton, New York.

- WOODS, E.F. (1967). Molecular weight and subunit structure of tropomyosin B.
J. biol. Chem. 242: 2859-2871.
- YAMADA, S. & TONOMURA, Y. (1972). Phosphorylation of the Ca^{2+} - Mg^{2+} -dependent ATPase of the sarcoplasmic reticulum coupled with cation translocation.
J. Biochem., Tokyo 71: 1101-1104.
- YAMADA, S., YAMAMOTO, T. & TONOMURA, Y. (1970). Reaction mechanism of the Ca^{2+} -dependent ATPase of sarcoplasmic reticulum from skeletal muscle III. Ca^{2+} -uptake and ATP-splitting.
J. Biochem., Tokyo 67: 789-794.
- YAMADA, S., SUMIDA, M. & TONOMURA, Y. (1972). Reaction mechanism of the Ca^{2+} -dependent ATPase of sarcoplasmic reticulum from skeletal muscle. VIII. Molecular mechanism of the conversion of osmotic energy to chemical energy in the sarcoplasmic reticulum.
J. Biochem., Tokyo 72: 1537-1548.
- YU, B.P., MASORO, E.J. & MORLEY, T.F. (1975). Use of diazotized di-iodosulfanilic acid to localize the protein components in sarcoplasmic reticulum membranes.
Life Sci. 17: 343-348.
- YU, B.P., MASORO, E.J. & MORLEY, T.F. (1976). Analysis of the arrangement of protein components in the sarcoplasmic reticulum of rat skeletal muscle.
J. biol. Chem. 251: 2037-2043.
- ZOBEL, C.R. & CARLSON, F.D. (1963). An electron microscopic investigation of myosin and some of its aggregates.
J. molec. Biol. 7: 78-89.
- ZSIGMOND, E.K. (1980). Malignant hyperthermia - a misnomer.
J. Am. med. Ass. 243: 513.



Author Ralph J L M

Name of thesis A study of muscle twitch responses, the effect of anaesthetic agents and the correlation with histology, histochemistry, electron microscopy and clinical presentation 1980

PUBLISHER:

University of the Witwatersrand, Johannesburg

©2013

LEGAL NOTICES:

Copyright Notice: All materials on the University of the Witwatersrand, Johannesburg Library website are protected by South African copyright law and may not be distributed, transmitted, displayed, or otherwise published in any format, without the prior written permission of the copyright owner.

Disclaimer and Terms of Use: Provided that you maintain all copyright and other notices contained therein, you may download material (one machine readable copy and one print copy per page) for your personal and/or educational non-commercial use only.

The University of the Witwatersrand, Johannesburg, is not responsible for any errors or omissions and excludes any and all liability for any errors in or omissions from the information on the Library website.