

https://dspace.org/

spontaneous idiopathic repzture of urinary bladder a systermic revie of case series and report

Abdullah Laher; Deshin Reddy; N Lawrentschuk; Ahmed Adam

WILEY-BLACKWELL
https://hdl.handle.net/10539/40284
WOS

Downloaded from a DSpace repository. https://dspace.org/

BJU Int 2023; **131:** 660–674 doi:10.1111/bju.15974

Check for updates

BJUI
BJU International

Review

Spontaneous (idiopathic) rupture of the urinary bladder: a systematic review of case series and reports

Deshin Reddy[1], Abdullah Ebrahim Laher[1], Nathan Lawrentschuk[3] and Ahmed Adam[2]

[1]Department of Emergency Medicine, Faculty of Health Sciences, University of the Witwatersrand, Johannesburg, South Africa, [2]Department of Urology, Royal Melbourne Hospital, Melbourne, Vic., Australia, and [3]Division of Urology, Faculty of Health Sciences, University of the Witwatersrand, Johannesburg, South Africa

Objectives

To perform a systematic review of all cases of spontaneous rupture of the urinary bladder (SRUB) and to describe the demographic data, associated comorbidities, clinical presentation, diagnosis, relevant laboratory findings, associated factors, management, morbidity and mortality associated with the presentation of SRUB.

Methods

The study protocol was registered with the International Prospective Register of Systematic Reviews (PROSPERO). A search was carried out across the following electronic databases: PubMed, Web of Science, Scopus, Google Scholar and the Cochrane Database of Systematic Reviews. Full texts of selected studies were analysed, and data extracted. The review was reported in accordance with the Preferred Reporting Items for Systematic Reviews and Meta-Analyses (PRISMA).

Results

A total of 278 articles comprising 240 case reports and 38 case series, with a total of 351 patients were included. The median (interquartile range [IQR]) age of all included patients was 47.5 (33–65) years. The median (IQR) time to presentation was 48 (24–96) h, with the major presenting symptom being abdominal pain (76%). In patients in whom the diagnosis was made prior to any intervention, the condition was misdiagnosed in 64% of cases. The diagnosis was confirmed during explorative open surgery in 42% of cases. Pelvic radiation (13%) and alcohol intoxication (11%) were the most common associated factors. Intraperitoneal rupture (89%) was much more common, with the dome of the bladder being most frequently involved (55%). The overall mortality was 15%.

Conclusion

This review identified a number of key factors that appear to be associated with an increased incidence of SRUB. It also emphasized the high rate of misdiagnosis and challenge in confirming the diagnosis. Overall, it highlighted the importance of the need for increased awareness and maintaining a high index of suspicion for this condition.

Keywords

spontaneous bladder rupture, idiopathic bladder rupture, atraumatic bladder rupture, uroperitoneum, urinary ascites, pseudo-renal failure, SRUB, #Urology, #UroTrauma

Introduction

Rupture of the urinary bladder is a potentially life-threatening urological emergency requiring prompt diagnosis and treatment. The vast majority of cases of bladder rupture are secondary to bladder injury or trauma, however, in 3.4% of cases there is no history of trauma [1]. In general, the diagnosis is challenging, placing this particular subset of patients at considerable risk due to time delays in definitive management [2]. Much of the aetiology and risk factors associated with this condition appear to be poorly understood.

Spontaneous rupture of the urinary bladder (SRUB) is defined as perforation or rupture of the bladder in the absence of trauma or direct stimulation [3,4]. This term also excludes cases where the rupture has occurred as a direct result or complication of instrumentation or previous bladder surgery, such as cystoscopy or transurethral resection of bladder tumour (TURBT).

Spontaneous rupture of the urinary bladder appears to be a relatively rare condition, with the incidence previously been described as 1:126 000 [5,6]. Later studies have indicated that the actual incidence may be as high as 1:50 000 [7].

© 2023 BJU International.
Published by John Wiley & Sons Ltd. www.bjui.org

Despite the relatively low reported incidence of SRUB, the mortality rate appears to be significant, ranging from 47% to 80% [6,8]. It seems that the risk of mortality may be somewhat related to the underlying undiagnosed condition associated with the bladder rupture [9,10]. This systematic review aims to determine and describe the potential risk factors, other associated factors, diagnosis, management, morbidity and mortality of patients with SRUB.

Methods

Protocol and Ethics

The protocol was registered with the International Prospective Register of Systematic Reviews (PROSPERO) in March 2021 (registration ID: CRD42021232134). An ethics waiver (W-CBP-210323-01) was received from the University of Witwatersrand Human Research Ethics Committee (Clinical) in March 2021.

Search Strategy

A search was carried out in November 2021 across the following sources: PubMed, Web of Science, Scopus, Google Scholar, and the Cochrane Database of Systematic Reviews. Additionally, a backwards citation search (pearl referencing) was also performed on articles that were retrieved, to identify articles that were missed during the search of the above databases.

For the PubMed database search, the following Medical Subject Headings (MeSH) terms were verified and indexed in the search builder: 'urinary bladder' and 'rupture, spontaneous'. Once the search was executed, the following limits were applied: human species and English language. No time limit was applied. Similarly, the search strategy for the Web of Science, Scopus and Google Scholar databases was conducted using the following terms: 'urinary bladder' AND 'rupture' AND 'spontaneous'. The limits applied were the same as stated above for the PubMed database search. The Cochrane Library search strategy was carried out in the Systematic Review section. The all-text filter was used in conjunction with the above search terms and limits.

Inclusion and Exclusion Criteria

Studies were included if: (i) they reported on SRUB; (ii) the full text was available in English; and (iii) they were pertaining to human subjects. Studies were excluded if: (i) there was any preceding history of trauma; (ii) there was a history of any known structural bladder abnormality or known bladder lesion (e.g., bladder malignancy or exstrophy); (iii) bladder rupture was secondary to a complication of a surgical procedure or a known medical condition, e.g., tubo-ovarian complex or appendicitis; (iv) there was a history of any instrumentation or bladder surgery that could have been directly linked to the rupture (e.g., augmentation, cystoscopy, neobladder, partial cystectomy, bladder stone removal or TURBT) [11,12]; (v) intrapartum bladder rupture was a result of suspected traumatic vaginal delivery or as an iatrogenic complication during caesarean section; or (vi) bladder rupture was diagnosed in the antenatal period or presented during the neonatal period. Additionally, studies were also excluded in the event that an abstract did not contain all necessary information or the full text was not available.

Study Selection

Electronic search limits were first applied as part of the initial screening process. After removal of duplicates, an initial cursory abstract screening was thereafter carried out where irrelevant studies and studies for which the full text was unavailable were removed. This was followed by a more thorough abstract screening in which studies fulfilling exclusion criteria were removed. Full-text reports were thereafter reviewed. Exclusion criteria were again applied, resulting in the final number of studies included in the review (Fig. 1).

Data Extraction and Methodology Evaluation

The review was carried out using the framework outlined by the Preferred Reporting Items for Systematic Reviews and Meta-Analyses (PRISMA). Two reviewers independently screened the articles using eligibility and exclusion criteria (D.R. and A.L.). Any disagreements or uncertainties related to whether a study should be included were resolved by a third reviewer (A.A.). Data were extracted from individual studies and collated in an Excel spreadsheet (Microsoft Corporation, Redmond, WA, USA). Data for individual variables (gender, age, comorbidities, clinical presentation, examination findings, diagnostic data, authors' assessment of exposure, serum laboratory variables, management and outcome) were tallied and represented as frequency and percentage. If data were not specified in the text, this was recorded as 'not specified'.

Assessment of Methodological Quality of the Included Studies

Since all studies meeting the inclusion criteria were case reports and case series, a modification to the tool proposed by Murad et al. [13] was used to assess the methodological quality of the included manuscripts. This modified tool has been used in several other systematic reviews of case reports [14,15]. The original tool comprises four domains with eight questions in total. Since two of the questions pertain specifically to drug reactions, these were omitted. The included questions were as follows: (i) Does/do the patient(s) represent(s) the whole experience of the investigator or is the

1464410x, 2023, 6, Downloaded from https://bjui-journals.onlinelibrary.wiley.com/doi/10.1111/bju.15974 by South African Medical Research, Wiley Online Library on [27/01/2024]. See the Terms and Conditions (https://onlinelibrary.wiley.com/terms-and-conditions) on Wiley Online Library for rules of use; OA articles are governed by the applicable Creative Commons License

Fig. 1 Study search strategy PRISMA flow diagram.

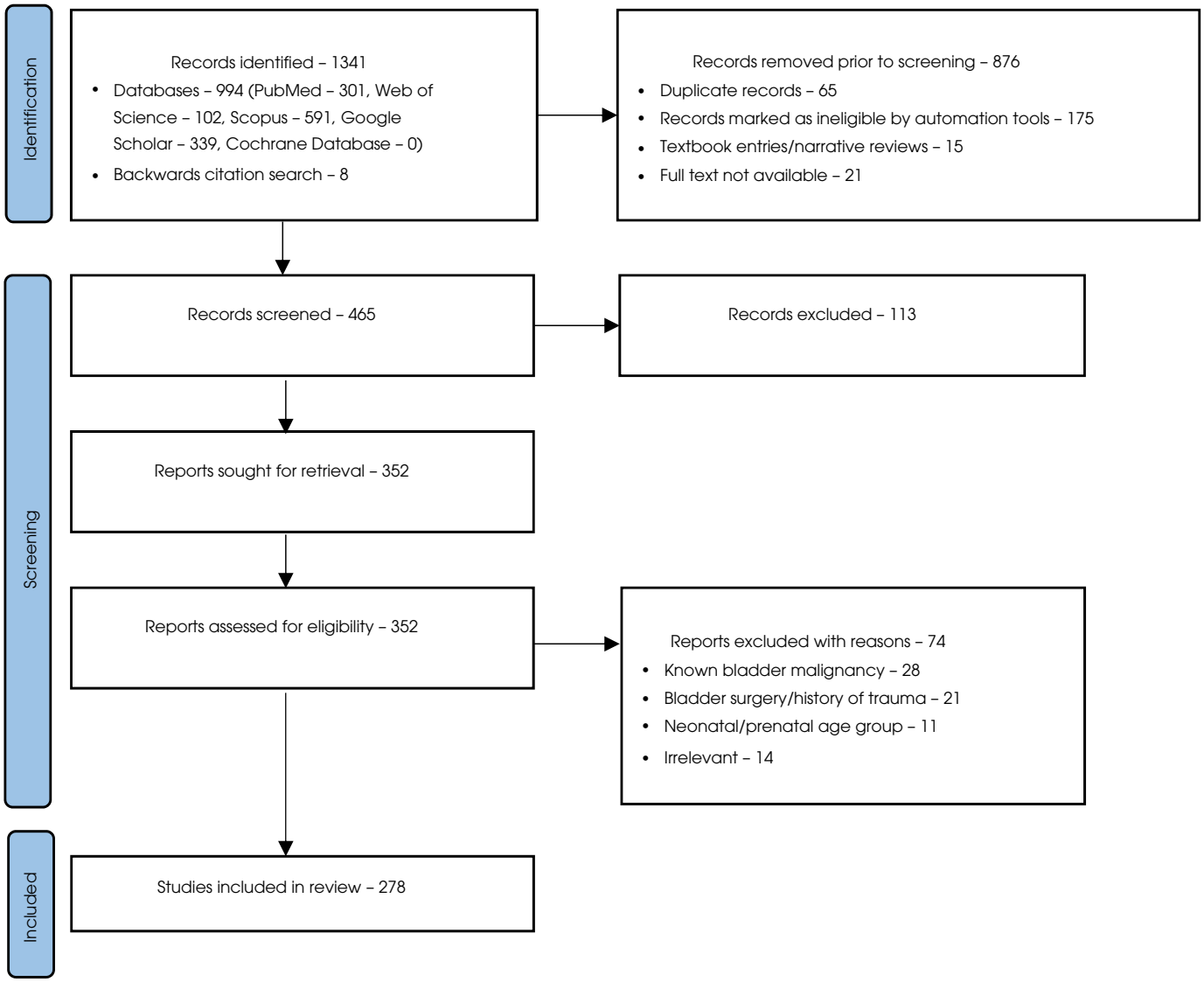

selection method unclear to the extent that other patients with similar presentation may not have been reported? (ii) Was the condition adequately ascertained? (iii) Was the outcome adequately ascertained? (iv) Were other alternative causes that may explain the observation ruled out? (v) Was follow-up long enough for outcomes to occur? (vi) Is/are the case(s) described with sufficient details to allow other investigators to replicate the research or to allow practitioners to make inferences related to their own practice?

The overall methodological quality of each of the included articles was described as either low, intermediate, or high quality. High quality was defined as a 'yes' answer to four or more of the included questions, while intermediate quality was defined as a 'yes' answer to three of the included questions and low quality was defined as a 'yes' answer to less than three of the included questions (Table S1).

Data Synthesis

The outcomes reported were summary data pertaining to the presentation of SRUB and included patient demographics, comorbidities, clinical presentation, diagnosis, relevant laboratory findings, associated factors, site of bladder rupture, management, morbidity and mortality. Since all included studies were case reports, summative statistics and a narrative synthesis approach was primarily used to describe the findings.

Results

The electronic search yielded a total of 1341 studies as follows: PubMed (301), Web of Science (102), Scopus (591), Google Scholar (339), Cochrane Database of Systematic Reviews (0) and, backwards citation search (pearl referencing)

 © 2023 BJU International.

1464410x, 2023, 6, Downloaded from https://bjui-journals.onlinelibrary.wiley.com/doi/10.1111/bju.15974 by South African Medical Research, Wiley Online Library on [27/01/2024]. See the Terms and Conditions (https://onlinelibrary.wiley.com/terms-and-conditions) on Wiley Online Library for rules of use; OA articles are governed by the applicable Creative Commons License

Table 1 Demographic details, comorbidities, time to presentation and diagnosis, laboratory variables, site of rupture, management and recurrence related to spontaneous rupture of the urinary bladder.

	n (%)/median (IQR)
Sex (*n* = 351), *n* (%)	
Male	158 (45)
Female	173 (49)
Unspecified	20 (5.7)
Age (*n* = 331)	
Median age (IQR), years	47.5 (33–65)
<20 years, *n* (%)	21 (6.3)
21–40 years, *n* (%)	111 (34)
41–60 years, *n* (%)	88 (27)
>60 years, *n* (%)	111 (34)
Major comorbidities (*n* = 351), *n* (%)	
Comorbid disease present	153 (44)
None	51 (15)
Not specified	147 (42)
Cardiovascular	63 (18)
Diabetes mellitus	21 (6.0)
Hypertension	15 (4.3)
Dyslipidaemia	7 (2.0)
CVA	7 (2.0)
Malignancy	44 (13)
Cervical cancer	21 (6.0)
Bladder cancer	5 (1.4)
Prostate cancer	4 (1.2)
Neurological	36 (10)
Paraplegia	10 (2.9)
Multiple sclerosis	7 (2.0)
Quadriplegia	3 (0.9)
Urological	35 (10)
BPH	11 (3.2)
Urolithiasis	9 (2.6)
Vesicolith	6 (1.7)
Psychiatric	12 (3.4)
Schizophrenia	5 (1.4)
Depression	3 (0.9)
Renal	9 (2.6)
Infection	8 (2.3)
Pulmonary	6 (1.7)
Genetic/autoimmune	7 (2.0)
Gynaecological	7 (2.0)
Rheumatological/orthopaedic	5 (1.4)
Other	12 (3.4)
Median time to presentation (IQR), h	48 (24–96)
Serum laboratory variables	
Median urea (IQR), mmol/L	21.5 (13.0–35.0)
Median creatinine (IQR), μmol/L	393.0 (199.8–590.8)
Peritoneal site of rupture (*n* = 351), *n* (%)	
Intraperitoneal	314 (89)
Extraperitoneal	26 (7.4)
Not specified	11 (3.1)
Anatomical site of rupture (*n* = 351), *n* (%)	
Dome	192 (55)
Posterior wall	48 (14)
Inferolateral wall	20 (5.7)
Anterior wall	14 (4.0)
Dome extending to posterior wall	5 (1.4)
Dome extending to anterior wall	1 (0.3)
Posterior wall extending to inferolateral wall	1 (0.3)
Not specified	70 (20)
Management (*n* = 351), *n* (%)	
Open repair	249 (71)
Conservative	47 (13)
Laparoscopic repair	14 (4.0)
HBO	4 (1.1)
Cystectomy	2 (0.6)
Open repair + HBO	1 (0.3)
Demised prior to intervention (post-mortem)	12 (3.4)
Not specified	22 (6.3)
Management excluding cases diagnosed on laparotomy and post mortem (*n* = 195), *n* (%)	
Open repair	107 (55)
Conservative	47 (24)
Laparoscopic repair	14 (7.2)
HBO	4 (2.1)
Open repair + HBO	1 (0.5)
Not specified	22 (6.3)
Recurrence (*n* = 18), *n* (%)	
Open repair	10 (55)
Conservative	7 (39)
Laparoscopic repair	1 (0.6)

CVA, cerebrovascular accident; HBO, hyperbaric oxygen; IQR, interquartile range.

(8). Automatic search limits excluded 175 studies and a further 36 were removed as they were irrelevant. After duplicates were removed (665), a total of 465 abstracts were fully reviewed. Once exclusion criteria were applied to the abstracts, 352 studies remained for full-text review. After again applying the exclusion criteria to the full texts, a total of 278 manuscripts remained and were included in the final review [1–10,16–283]. Details of the above are described in Fig. 1.

Design of the Included Publications

All included studies were either case reports (240) or case series (38) and comprised a total of 351 patients.

Demographics

The age range of all included patients was 9 months to 91 years (Fig. S1), with a median (interquartile range [IQR]) age of 47.5 (33–65) years. There was a bimodal age distribution with peaks at 21–40 years and ≥60 years (111/331; 34% for both). This was followed by the 41–60-year-old age group (88/331; 27%) and the under 20-year-old age group (21/331; 6.3%). Of the total number of cases that specified gender, the distribution had a slight female predominance (*n* = 173/331; 52% [Table 1]).

Comorbidities

A total of 153 patients (44%) had reported at least one comorbid condition, with the most frequent comorbidities being diabetes mellitus (*n* = 21; 6.0%), cervical adenocarcinoma (*n* = 21; 6.0%) and hypertension (*n* = 15; 4.3%). The most common group of comorbid conditions was cardiovascular-related disease (*n* = 63; 18%), followed by malignancy (*n* = 44; 13%). Most malignancies were pelvic in origin (*n* = 40/44; 91% [Table 1]).

1464410x, 2023, 6, Downloaded from https://bjui-journals.onlinelibrary.wiley.com/doi/10.1111/bju.15974 by South African Medical Research, Wiley Online Library on [27/01/2024]. See the Terms and Conditions (https://onlinelibrary.wiley.com/terms-and-conditions) on Wiley Online Library for rules of use; OA articles are governed by the applicable Creative Commons License

Clinical Presentation

The median (IQR) time to presentation was 48 (24–96) h. The major presenting symptoms were abdominal pain (n = 267; 76%), of which the majority was unspecified abdominal pain (n = 128; 36%), followed by nausea and/or vomiting (n = 79; 23%), abdominal distention (n = 74; 21%), and acute urinary retention or difficulty voiding (n = 63; 18%). Notably, urinary symptoms were present in almost three-quarters of patients (n = 259; 74%). The most common examination findings were abdominal distention (n = 131; 37%), abdominal tenderness (n = 84; 24%) and fever (n = 34; 9.7%). Of those in whom abdominal tenderness was reported, 34/84 (40%) had generalized peritonitis. Only one case study reported that abdominal examination was within normal limits (Table S2).

Diagnosis

The median (IQR) time to diagnosis was 48 (24–96) h. Of those cases that reported on the relevant data, the diagnosis was made in the emergency department in 28/253 cases (11%). In patients in whom the diagnosis was made prior to any intervention, the condition was misdiagnosed in 119/185 cases (64%), with the most common misdiagnosis being hollow viscus perforation (n = 41/119; 34% [Table 2]).

The diagnosis was confirmed during explorative open surgery in 147 cases (42%), which excludes cases where the diagnosis was made at autopsy (n = 11; 3.1%). This was followed by cases where the diagnosis was confirmed by plain-film X-ray cystography (n = 72; 21%) and CT with cystography (n = 47; 13% [Table 2]).

Median Urea and Creatinine

The median (IQR) serum urea and creatinine levels were 21.5 (13–35) mmol/L and 393 (200–591) μmol/L, respectively (Table 1). A total of 12 patients (3.4%) were misdiagnosed with primary acute renal failure and received renal replacement therapy (Table 2).

Associated Factors

Rupture was considered idiopathic in 79 cases (23%), where no exposure could be clearly identified. The most common associated factors related to SRUB were pelvic radiation (n = 45; 13%), followed by alcohol intoxication (n = 39; 11%) and post vaginal delivery (n = 25; 7.1%).

The most common associated factors in the two most prevalent age groups were alcohol intoxication (n = 26/111; 23%) in the age group 21–40 years and pelvic radiation (n = 23/111; 21%) in the age group older than 60 years. Where the exposure was deemed to be infection or inflammation-related, *Mycobacterium tuberculosis* was the most prevalent causative agent (n = 10/49; 20% [Table 3]).

Site of Bladder Rupture

Intraperitoneal rupture (n = 314; 89%) was much more common than extraperitoneal rupture (n = 26; 7.4%), with the dome of the bladder being most frequently involved (n = 192; 55% [Table 1]).

Management

Most patients were managed with open repair (n = 249; 71%), followed by conservative management with catheterization on free drainage (n = 47; 13%). A total of 14 patients (4.0%) underwent laparoscopic repair. After excluding patients who were incidentally diagnosed with SRUB during exploratory laparotomy (n = 156, 44%), 107/195 patients (55%) were managed with open repair and 47/195 (24%) were managed conservatively. Overall, the rate of recurrence was higher with conservative management (n = 7/30; 23%) compared to open repair (n = 10/147; 6.8% [Table 1]).

Morbidity

The overall number of reported morbidities was 95 (27%), with the most common morbidity being rupture recurrence (17/351; 4.8%); most of which were single episodes. This was followed by sepsis or sepsis-related complications (n = 9; 2.6%), intra-abdominal organ complications (n = 9; 2.6%), respiratory tract complications (n = 8, 2.3%) and other bladder-related (non-recurrence) complications (n = 8, 2.3% [Table 2]).

Mortality

The overall number of reported deaths was 51 (15%). Most deaths occurred within 72 h of presentation (n = 15/51; 29% [Table 2]). A total of 13 patients (3.7%) died prior to the correct diagnosis or intervention (i.e., the cause of death was determined at autopsy). A total of 38 (11%) patients died despite intervention.

Discussion

Spontaneous rupture of the urinary bladder appears to be a disease that predominantly affects young adults and the elderly (Table 1), with an almost equal incidence among males and females. The incidence of comorbidities reflects the underlying factors related to SRUB. The major comorbid disease found was diabetes mellitus, which is likely associated with some degree of autonomic bladder neuropathy [284]. There was also a high incidence of extravesical pelvic organ

 © 2023 BJU International.

1464410x, 2023, 6, Downloaded from https://bjui-journals.onlinelibrary.wiley.com/doi/10.1111/bju.15974 by South African Medical Research, Wiley Online Library on [27/01/2024]. See the Terms and Conditions (https://onlinelibrary.wiley.com/terms-and-conditions) on Wiley Online Library for rules of use; OA articles are governed by the applicable Creative Commons License

Table 2 Diagnostic data and morbidity and mortality related to spontaneous rupture of the urinary bladder.

	n (%)/median (IQR)
Median time to diagnosis from presentation (IQR), h	48 (24–96)
Diagnosis made (*n* = 351), *n* (%)	
In emergency department	28 (8.0)
Outside of emergency department	225 (64)
Not specified	98 (28)
A diagnosis made prior to intervention	185 (53)
Incorrect	119/185 (64)
Correct	66/185 (36)
No diagnosis made prior to intervention	166 (47)
Misdiagnoses (*n* = 119), *n* (%)	
Gastrointestinal	102 (86)
Hollow viscus perforation	41 (34)
Bowel obstruction	13 (11)
Acute peritonitis unspecified	10 (8.4)
Urological	12 (10)
Acute urinary retention	4 (3.4)
Urosepsis	3 (2.5)
Obstructive uropathy	2 (1.7)
Renal	14 (12)
Primary acute renal failure	12 (10)
Pyelonephritis	1 (0.8)
UTI not specified	1 (0.8)
Gynaecological/obstetrics	7 (5.9)
Recurrence of gynaecological malignancy	2 (1.7)
Ruptured/torsion of ovarian cyst	2 (1.7)
PV bleeding	1 (0.8)
Diagnostic modalities used to confirm diagnosis (*n* = 351), *n* (%)	
Exploratory laparotomy	147 (42)
Plain-film cystography	72 (21)
CT with cystography	47 (13)
CT without cystography	26 (7.4)
Cystoscopy	23 (6.6)
Exploratory laparoscopy	11 (3.1)
Autopsy	11 (3.1)
Formal US	6 (1.7)
Plain-film IV pyelography	1 (0.3)
MRI pelvis	1 (0.3)
Tc-99m DTPA renography	1 (0.3)
Voiding cystourethrogram	1 (0.3)
Bladder doppler US	1 (0.3)
Data not available	3 (0.9)
Use of bedside US in emergency department (*n* = 351), *n* (%)	
Yes	11 (3.1)
No	297 (85)
Not specified	43 (12)
Morbidity (*n* = 351), *n* (%)	
No morbidity	124 (35)
Not specified	132 (38)
Total morbidities	95 (27)
Respiratory	8 (2.3)
Cardiac	2 (0.6)
Bowel/intra-abdominal organ	9 (2.6)
Gynaecological	3 (0.9)
Urological	19 (5.4)
Bladder-related complications (partial/total cystectomy/cystoplasty/conduit)	8 (2.3)
Non-bladder related	6 (1.7)
Chronic catheterisation	5 (1.4)
Sepsis and related complications	9 (2.6)
Necrotising fasciitis	2 (0.6)
Wound complications	3 (0.9)
Metabolic	1 (0.3)
Recurrence	17 (4.8)
Single episode of recurrence	13 (3.7)
Multiple episodes of recurrence	4 (1.1)
Missed during surgical intervention	3 (0.9)
Failed conservative management	3 (0.9)
Survival and mortality (*n* = 351), *n* (%)	
Survival to hospital discharge	225 (64)
Not specified	75 (21)
Total deaths	51 (15)
Time not specified	11 (3.1)
<3 days	15 (4.3)
3–7 days	8 (2.3)
8–31 days	11 (3.1)
1–6 months	5 (1.4)
>6 months	1 (0.3)

DTPA, diethylenetriamine penta-acetate; HBO, hyperbaric oxygen; IQR, interquartile range; IV, intravenous; PV, per vagina; Tc-99m, technetium-99m; US, ultrasonography.

malignancy, with all of such patients having received pelvic radiation.

The major presenting symptoms were abdominal pain, which was predominantly localized to the lower abdomen, followed by nausea and vomiting, abdominal distention and difficulty in passing urine or acute urinary retention. Patients with ascites and abdominal distention in the setting of acute-onset abdominal pain should have this diagnosis excluded, particularly those with concomitant urinary symptoms.

The underlying pathogenesis of SRUB has previously been attributed to a predisposition of compromised bladder wall integrity in combination with increased intravesical pressure and/or increased intra-abdominal pressure [223]. Radiation exposure has been noted as a cause of spontaneous bladder rupture in the literature [169,241]. This is probably attributable to the effects of radiation cystitis, where the initial mucosal insult of oedema and hyperaemia culminates in fibrosis and loss of bladder wall integrity [285]. It is important to note that these patients can present with SRUB many years after treatment has been completed [169,241,259]; hence, the diagnosis of SRUB should always be considered in patients with a medical history of pelvic radiation.

Alcohol intoxication was found to be the second most common exposure in this review (Table 3). The pathogenesis is thought to be secondary to alcohol-induced diuresis leading to increased intravesical pressure, coupled with impaired awareness of bladder filling and the need to void [8]. There may be significant overlap here between traumatic bladder rupture and SRUB because intoxicated patients are less reliable historians and may not recall a history of trauma.

1464410x, 2023, 6, Downloaded from https://bjui-journals.onlinelibrary.wiley.com/doi/10.1111/bju.15974 by South African Medical Research, Wiley Online Library on [27/01/2024]. See the Terms and Conditions (https://onlinelibrary.wiley.com/terms-and-conditions) on Wiley Online Library for rules of use; OA articles are governed by the applicable Creative Commons License

Table 3 Cumulative incidence of factors associated with spontaneous rupture of the urinary bladder.*

Factors associated with bladder rupture (*n* = 351)	*n* (%)
BOO	44 (13)
Intravesical	10 (2.8)
Vesicolith	9 (2.6)
Bladder neck papilloma	1 (0.3)
Extravesical	34 (9.7)
Urological	27 (7.7)
Prostatic enlargement	17 (4.8)
BPH	16 (4.6)
Prostate cancer	1 (0.3)
Urethral catheterisation	6 (1.7)
Urethral stricture	4 (1.1)
Non-urological	7 (2.0)
Uterine fibroids/adenomyosis	2 (0.6)
Faecal impaction	2 (0.6)
Pelvic organ prolapse	3 (0.9)
Type not specified	5 (1.4)
Pregnancy associated	32 (9.1)
Post NVD	25 (7.1)
Intrapartum	5 (1.4)
Other	2 (0.6)
Infection/inflammation	49 (14)
Cystitis uncertain/unspecified origin	11 (3.1)
Tuberculosis	10 (2.8)
Fungal	7 (2.0)
Parasitic	6 (1.7)
Bacterial (non-tuberculosis)	5 (1.4)
Gangrenous/necrotising	4 (1.1)
Eosinophilic	2 (0.6)
Granulomatous (non-tuberculosis)	2 (0.6)
Viral	1 (0.3)
Interstitial	1 (0.3)
Over-distention/delayed voiding	69 (20)
Drug-associated	46 (13)
Alcohol	39 (11)
Anticholinergic	4 (1.1)
Benzodiazepine	1 (0.3)
Opioid	1 (0.3)
Drug not specified	1 (0.3)
Non-drug associated	23 (6.6)
Neurogenic bladder	23 (6.6)
Increased IAP	2 (0.6)
Vomiting	1 (0.3)
Seizures	1 (0.3)
Bladder wall lesion	88 (24)
Malignancy associated	67 (19)
Radiation-associated fibrosis (pelvic malignancies of non-bladder origin)	45 (13)
Bladder TCC	10 (2.8)
Bladder SCC	7 (2.0)
Bladder unspecified type	4 (1.1)
Bladder leiomyosarcoma	1 (0.3)
Non-malignancy associated	19 (5.4)
Bladder diverticulum	17 (4.8)
Bladder amyloidosis	1 (0.3)
Fatty infiltration of bladder	1 (0.3)
Other	2 (0.3)
Warfarin toxicity	1 (0.3)
Haemophilia	1 (0.3)
Not identified (idiopathic)	79 (23)
Top five associated factors stratified by age group	
<20-year age group (*n* = 21)	
Bladder diverticulum	3 (14)
BOO (unknown origin)	3 (14)
Neurogenic bladder	3 (14)
Alcohol intoxication	3 (14)
Idiopathic	2 (9.5)
21–40-year age group (*n* = 111)	
Alcohol intoxication	26 (23)
Post NVD	21 (19)
Idiopathic	13 (12)
Cystitis (tuberculosis)	8 (7.2)
Neurogenic bladder	7 (6.3)
41–60-year age group (*n* = 88)	
Idiopathic	15 (17)
Neurogenic bladder	14 (16)
Alcohol intoxication	12 (14)
Pelvic radiation	10 (11)
Bladder diverticulum	7 (7.8)
>60-year age group (*n* = 111)	
Pelvic radiation	23 (21)
BOO (BPH)	15 (14)
Bladder diverticulum	14 (13)
Idiopathic	10 (9.0)
Neurogenic bladder	10 (9.0)

*IAP, intra-abdominal pressure; NVD, normal vaginal delivery; SCC, squamous cell carcinoma; TCC, transitional cell carcinoma. *Not all authors reported on the presence or absence of all associated factors. Hence, it is possible that a patient may have had some associated factors that were not reported.*

Conversely, in patients presenting with abdominal pain and particularly those with urinary symptoms several days after an alcohol binge, consideration must be given to SRUB as part of the differential diagnosis.

Having undergone normal vaginal delivery was the third most prevalent associated factor (Table 3). Again, this diagnosis may be easily missed and attributed to other more likely pathologies [250]. It is important to note the risk of SRUB is increased when the bladder is not emptied prior to delivery and where there is perineal trauma leading to a degree of BOO and urinary retention [38]. A review of SRUB in pregnancy and the puerperium found that the majority (70%) occurred during normal vaginal delivery [250].

Neurogenic bladder was found to be among the five most prevalent associated factors across all age groups (Table 3). Due to neurological dysfunction, these patients may not present with typical features of abdominal pain. Additionally, the bladder wall is often compromised in these patients, for example, because of diverticulae or chronic inflammation, which places the patients at further risk of spontaneous rupture. Furthermore, many of these patients also have chronic indwelling urinary catheters which also contributes to bladder wall inflammation and rupture [33] as well as bowel erosion, with resultant fistula formation [286]. It is also important to consider a diagnosis of SRUB in cases where patients with chronic neurological conditions may not yet have been formally diagnosed with a neurogenic bladder, such as a previous

 © 2023 BJU International.

1464410x, 2023, 6, Downloaded from https://bjui-journals.onlinelibrary.wiley.com/doi/10.1111/bju.15974 by South African Medical Research, Wiley Online Library on [27/01/2024]. See the Terms and Conditions (https://onlinelibrary.wiley.com/terms-and-conditions) on Wiley Online Library for rules of use; OA articles are governed by the applicable Creative Commons License

cerebrovascular event, diabetes mellitus or multiple sclerosis.

The diagnosis of SRUB was largely made during explorative surgery (Table 2). To date, there have been no studies that have attempted to describe the 'gold standard' diagnostic method, hence, evidence from the trauma literature has been used as a guide. CT without cystography has a low specificity in the diagnosis of traumatic bladder rupture (61%) compared to that of plain-film retrograde cystography (96%) [287]. Previously, retrograde cystography was considered the gold standard diagnostic method for traumatic bladder rupture, but this has since shifted to CT cystography, which has shown comparable specificity [288]. CT has the distinct advantage of being less invasive than conventional cystography, is easier to perform and is able to detect other intra-abdominal pathology while excluding bladder rupture [8]. With the continued growth in use of point-of-care ultrasonography in the emergency department, there appears to be some promise in its utility [47] and there is potential for further studies to investigate ultrasonographic signs and techniques to aid in making the diagnosis in the emergency department.

A low index of suspicion and nonspecific clinical presentation are likely the major contributing factors to the high rate of misdiagnosis associated with SRUB.

Another confounding issue contributing to the misdiagnosis of SRUB is the peritoneal reabsorption of urea and creatinine that has escaped through the bladder wall defect, leading to elevated serum readings when laboratory investigations are performed. These results may easily be misinterpreted as renal failure [30,31,52,71,75,77,88,94,95,103,156,179,180,233], which is further confounded by presentation with oliguria or anuria [143,168,183], leading to the initiation of renal replacement therapy. When the diagnosis is made reasonably early and the defect repaired or bladder drained to allow sufficient healing to occur, the levels of urea and creatinine generally resolve spontaneously within 24 h [179]. It is important to note that, although there is no initial insult to the kidneys, if the diagnosis is delayed this may lead to acute kidney injury and associated life-threatening complications including electrolyte abnormalities [144].

The dome of the bladder is anatomically the most vulnerable region. As the bladder distends, the dome stretches, resulting in a thinner wall, it also rises above the pelvis and away from the support offered by the bony pelvic structures, thereby making the bladder dome more prone to SRUB [175].

In many cases where open repair was performed, the patient was taken for an exploratory laparotomy where SRUB was an incidental finding [272,274,279,280]. After excluding patients who were incidentally diagnosed with SRUB at exploratory laparotomy, a higher proportion of patients were managed conservatively (47/195; 24% vs. 47/351; 13%). This is likely a better reflection of the actual management related to this condition. Very few studies described successful management with laparoscopic surgery [49,122,263,270]. Laparoscopic repair in the hands of an experienced surgeon may be a better option but this remains to be validated by the evidence.

There is a lack of literature related to the mortality associated with SRUB. In this review, the overall mortality rate, where reported, was 51/276 (18%), with the highest number of deaths (15/51; 29%) occurring within 72 h of presentation. This underscores the need to make the diagnosis in a timely manner so definitive management may be implemented.

A limitation of this study relates to the heterogenous nature of case reports in general. Case reports are often fraught with inconsistencies and bias, which may lead to inaccuracies when pooling data from multiple sources. For example, estimates of proportions reported in this paper are expected to be inaccurate because of publication bias or reporting inconsistencies, hence, these should be taken as a guide only. For example, case reports with death as an outcome may be more likely to be written-up and published, leading to an overestimate of the actual mortality associated with SRUB. Conversely, non-systematic reporting of associated features of SRUB such as pelvic radiation or alcohol intoxication may have resulted in an underestimation of these factors; for example, some reports may not have mentioned these despite them being present. Comprehensive registration and reporting of cases would give a more accurate approximation but this is challenging for such a rare presentation.

In the past, there were few guidelines available to guide authors on the content of case reports to provide a measure of standardization. This has since improved with the introduction of several widely accepted tools, such as the tool proposed by Murad et al. [13], and the CARE (CAse REport) guidelines [289]. The hope is that, as the usage of such tools becomes more common, reporting on rare diseases will also become more standardized.

There were missing datapoints in several of the papers that were included. These were reported as 'not specified' in the study summary results and were excluded from individual analyses, which is the reason for the smaller denominators for some variables.

In conclusion, this review identified a number of key factors across different age groups that appear to be associated with an increased incidence of SRUB. It also emphasized the high rate of misdiagnosis and challenges encountered in confirming the diagnosis. Overall, this study highlights the importance of maintaining a high index of suspicion for SRUB in the appropriate patient. However, a number of important gaps were also identified as potential targets for future research.

1464410x, 2023, 6, Downloaded from https://bjui-journals.onlinelibrary.wiley.com/doi/10.1111/bju.15974 by South African Medical Research, Wiley Online Library on [27/01/2024]. See the Terms and Conditions (https://onlinelibrary.wiley.com/terms-and-conditions) on Wiley Online Library for rules of use; OA articles are governed by the applicable Creative Commons License

Acknowledgements

We would like to thank Mr Devind Peter and the staff at the Faculty of Health Sciences and Wartenweiler Libraries, University of Witwatersrand (Johannesburg, South Africa) for their valued assistance with retrieval of full-texts articles.

Funding

None.

Disclosures of Interest

The authors hereby certify that this submission is not under publication consideration elsewhere and is free from any conflict of interest.

References

1 **Murata R, Kamiizumi Y, Tani Y et al.** Spontaneous rupture of the urinary bladder due to bacterial cystitis. *J Surg Case Rep* 2018; 2018: rjy253
2 **Sholklapper T, Elmahdy S.** Delayed diagnosis of atraumatic urinary bladder rupture. *Urol Case Rep* 2021; 38: 101723
3 **Galbraith JG, Butler JS, McGreal GT.** Opioid toxicity as a cause of spontaneous urinary bladder rupture. *Am J Emerg Med* 2011; 29: 239.e1–3
4 **Sisk IR, Wear JB.** Spontaneous rupture of the urinary bladder. *J Urol* 1929; 21: 517–22
5 **Bastable JRG, Jode LRD, Warren RP.** Spontaneous rupture of the bladder. *Br J Urol* 1959; 31: 78–86
6 **Hansen HJ, Eldrup J.** Spontaneous rupture of the urinary bladder – a late complication to radiotherapy: case report. *Scand J Urol Nephrol* 1989; 23: 309–10
7 **Su PH, Hou SK, How CK, Kao WF, Yen DHT, Huang MS.** Diagnosis of spontaneous urinary bladder rupture in the ED. *Am J Emerg Med* 2012; 30: 379–82
8 **Muneer M, Abdelrahman H, El-Menyar A, Zarour A, Awad A, Al-Thani H.** Spontaneous atraumatic urinary bladder rupture secondary to alcohol intoxication: a case report and review of literature. *Am J Case Rep* 2015; 16: 778–81
9 **Limon O, Unluer EE, Unay FC, Oyar O, Sener A.** An unusual cause of death: spontaneous urinary bladder perforation. *Am J Emerg Med* 2012; 30: 2081.e3–5
10 **Ioan B, Manoilescu I, Dicu Șerban D, Neagu M, Panaitescu A, Damian S.** Idiopathic spontaneous rupture of the urinary bladder – a rare cause of death. *Romanian J Legal Med* 2015; 23: 9–13
11 **Gill JD, Cast JEI, Thomas PJ, Simms MS.** Orthotopic neobladder perforation: an unusual presentation of small bowel obstruction. *J Surg Case Rep* 2013; 2013: rjt045
12 **Lee T, Kozminski DJ, Bloom DA, Wan J, Park JM.** Bladder perforation after augmentation cystoplasty: determining the best management option. *J Pediatr Urol* 2017; 13: 274.e1–7
13 **Murad MH, Sultan S, Haffar S, Bazerbachi F.** EBM implementation: methodological quality and synthesis of case series and case reports. *BMJ Evid Based Med* 2018; 23: 60
14 **van Welie M, Qu LG, Adam A, Lawrentschuk N, Laher AE.** Recurrent testicular torsion post orchidopexy – an occult emergency: a systematic review. *ANZ J Surg* 2022; 92: 2043–52
15 **Malinga DM, Laher AE, McDowall J, Adam A.** Coronavirus disease 2019 (COVID-19) and priapism: an unexplored association. *Curr Urol* 2022; 16: 55
16 **Ping LS.** Spontaneous rupture of bladder diverticulum: a case report of non-traumatic extraperitoneal urinary bladder rupture managed with surgical intervention. *Int Surg J* 2021; 8: 3437–40
17 **Alton BH.** Spontaneous intraperitoneal rupture of a tuberculous bladder. *N Engl J Med* 1931; 205: 1177–81
18 **Cave HW.** Spontaneous intraperitoneal perforation of the bladder. *Am J Surg* 1935; 28: 242–52
19 **Marbury WB, Fry W.** Spontaneous rupture of urinary bladder. Report of case of second rupture. *Ann Surg* 1943; 117: 760–5
20 **Lipow EG, Vogel J.** Spontaneous rupture of the bladder. *J Urol* 1942; 47: 277–82
21 **Wyatt TE, Douglass HL.** Spontaneous rupture of the tuberculous bladder. *J Urol* 1938; 40: 506–12
22 **Oppenheimer GD, Druckerman LJ.** Recurrent non-traumatic intraperitoneal rupture of the urinary bladder; recovery. *J Urol* 1947; 57: 238–41
23 **Stone E.** Spontaneous rupture of the urinary bladder: report of two cases. *Arch Surg* 1931; 23: 129–44
24 **Habek D, Pavelić-Turudić T, Vukelić M, Mazul-Sunko B.** Acute abdomen due to bladder perforation in a patient with multiple sclerosis. *Cent Eur J Med* 2013; 8: 362–3
25 **Kodama K, Takase Y, Saito K.** Extraperitoneal rupture of a bladder diverticulum and the role of multidetector computed tomography cystography. *Urol Case Rep* 2016; 9: 30–2
26 **Roberts C, Oligbo N, Swinhoe J.** Spontaneous bladder rupture following normal vaginal delivery: a postpartum emergency. *Br J Obstet Gynaecol* 1996; 103: 381–2
27 **Dangerfield DC, Smith N, Snow TM.** Spontaneous rupture of the urinary bladder secondary to total uterine prolapse. *Clin Radiol Extra* 2003; 58: 25–6
28 **Daignault MC, Saul T, Lewiss RE.** Bedside ultrasound diagnosis of atraumatic bladder rupture in an alcohol-intoxicated patient: a case report. *Crit Ultrasound J* 2012; 4: 1–5
29 **Zijoo R, Zijoo R, Dirweesh A, Ordonez FM, Kaji A.** Spontaneous rupture of urinary bladder in a young alcoholic male. *J Med Cases* 2016; 7: 245–7
30 **Sharma D, Garg G, Pandey S, Goel A.** Giant vesicle calculi leading to spontaneous bladder rupture and acute renal failure: an unusual presentation. *BMJ Case Rep* 2018; 2018: bcr2018225888
31 **Colombo G, Furlan L, Mucci F, Zannoni S, Andrisani MC, Solbiati M.** Ascites, abdominal pain, and acute renal failure in a middle-aged woman. *Intern Emerg Med* 2020; 15: 299–302
32 **Sabat D, Panigrahi P, Sahoo R, Acharya M, Ch SM.** Spontaneous puerperal extraperitoneal bladder wall rupture in young woman with diagnostic dilemma. *J Family Med Prim Care* 2015; 4: 601
33 **Mitchell T, Al-Hayek S, Patel B, Court F, Gilbert H.** Acute abdomen caused by bladder rupture attributable to neurogenic bladder dysfunction following a stroke: a case report. *J Med Case Rep* 2011; 5: 254
34 **Welp A, Fields EC, Randall L, Brown FK, Sullivan SA.** Acute extraperitoneal spontaneous bladder rupture in cervical cancer patient undergoing chemoradiation: a case report and review of the literature. *Gynecol Oncol Rep* 2020; 34: 100656
35 **Bergeron E, Lewinshtein D, Bure L, Vallee C.** Pneumoperitoneum and peritonitis secondary to perforation of an infected bladder. *Int J Surg Case Rep* 2021; 81: 105783
36 **Peeters P, Colle I, Sennesael J, Verbeelen D.** Relapsing ascites and uremia due to urinary bladder leakage. *Eur J Intern Med* 2001; 12: 60–3
37 **Ruston MA, Taube M, Smedley F, Edwards L.** Ruptured bladder following a phosphate enema. *Br J Urol* 1988; 62: 616–7
38 **Ekuma-Nkama EN, Garg VK, Barayan S.** Spontaneous rupture of bladder in a primipara. *Ann Saudi Med* 1997; 17: 646–7
39 **Li L, Li J, Tao J et al.** Alcohol intoxication-induced spontaneous bladder rupture. *Am J Case Rep* 2011; 12: 206–9

 © 2023 BJU International.

1464410x, 2023, 6, Downloaded from https://bjui-journals.onlinelibrary.wiley.com/doi/10.1111/bju.15974 by South African Medical Research, Wiley Online Library on [27/01/2024]. See the Terms and Conditions (https://onlinelibrary.wiley.com/terms-and-conditions) on Wiley Online Library for rules of use; OA articles are governed by the applicable Creative Commons License

40 **Al Edwan GM**, **Mansi HH**, **ONM A**, **Shaban MM**. Squamous cell carcinoma of the bladder presented with spontaneous intraperitoneal bladder rupture: a case report. *Int J Surg Case Rep* 2018; 48: 61–4

41 **Kopp RP**, **Dato PE**, **Sur RL**. Bladder perforation associated with hot tub. *J Sex Med* 2011; 8: 321–4

42 **Elsaharty SA**, **Tjong E**, **Gadiok G**. Spontaneous intraperitoneal urinary bladder rupture due to alcohol-intoxication. *Urology* 2020; 145: e12–6

43 **Chakraborty A**, **Mandal K**, **Bhunia A**, **Hasnat S**, **Dutta S**. Spontaneous intraperitoneal bladder rupture: a rare case report. *J Clin Diagn Res* 2019; 13: PD11–3

44 **Jayathillake A**, **Robinson R**, **Al-Samarii A**, **Manoharan M**. Spontaneous rupture of bladder presenting as peritonitis. *N Zeal Med J* 2002; 115: U222

45 **Mukhtar O**, **Moua T**. Where is the sodium? A case report of spontaneous rupture of the urinary bladder. *Chest* 2021; 160: 612A

46 **Raj SN**, **Anuar SS**, **Hamid G**. Spontaneous rupture of urinary bladder (SRUB); a case series. *BJU Int* 2021; 128: 25–6

47 **Rahaman A**, **Saad-Abdullah A-N**, **Suresh K**. Spontaneous rupture of urinary bladder diagnosed by bedside ultrasound; a case report. *Front Emerg Med* 2020; 4: e80

48 **Asano T**, **Ohtsuka Y**. Spontaneous bladder rupture due to bladder carcinoma: a case report required emergency radical cystectomy. *Urol Case Rep* 2020; 33: 101412

49 **Xu Z**, **Wang X**, **Wang J**, **Li Z**, **Du J**. Emergency laparoscopic exploration of postpartum spontaneous rupture of the urinary bladder: a case report and review of literature. *J Emerg Med Case Rep* 2019; 10: 7–10

50 **Mitchell RJ**, **Hamilton SGI**. Spontaneous perforation of bladder diverticula. *Br J Surg* 1971; 58: 712

51 **Goel A**. Carcinoma urinary bladder presenting as acute abdomen. *Int Urol Nephrol* 2001; 33: 491–2

52 **Sung CW**, **Chang CC**, **Chen SY**, **Tseng WP**. Spontaneous rupture of urinary bladder diverticulum with pseudo-acute renal failure. *Intern Emerg Med* 2018; 13: 619–22

53 **Sallami S**, **Gargouri MM**, **Tayeb M**, **Slima MB**, **Makhlouf M**. Spontaneous intraperitoneal perforation of the bladder secondary to tuberculosis. *UroToday Int J* 2010; 3: 14

54 **Bierton C**, **Eteuati J**. Perforated viscus; not always bowel: case report of spontaneous bladder rupture. *ANZ J Surg* 2019; 89: E412–3

55 **da Silva M**, **Barroso F**, **Dorgam Maués CA et al.** Surgical management of spontaneous post-partum bladder rupture in an Amazonian emergency hospital. *Urol Case Rep* 2020; 33: 101376

56 **Gaikwad PR**, **Sharma S**, **Kanitkar SV**, **Kachane T**. Spontaneous rupture of the urinary bladder in the puerperium. *J Obstet Gynecol India* 2011; 61: 208–9

57 **Selling Rasmusen J**. Spontaneous bladder rupture in association with carcinoma: case report. *Scand J Urol Nephrol* 1994; 28: 323–6

58 **Zhao ZG**, **Bai QK**, **Xie XH et al.** Computed tomography manifestations of spontaneous bladder rupture associated with alcohol bingeing. *J Med Imaging Health Inform* 2015; 5: 1567–70

59 **Li YX**, **Vaux K**, **Coleman P**. Spontaneous uroperitoneum and elevated Ca-125. *Eur J Intern Med* 2008; 19: e47–8

60 **Olanipekun T**, **Effoe V**, **Turner J**, **Flood M**. Bladder necrosis and perforation in end-stage renal disease and recurrent urinary tract infection: a rare medical emergency. *Int J Crit Illn Inj Sci* 2019; 9: 101–4

61 **Agarwal MM**, **Singh SK**, **Naja V**, **Mavuduru R**, **Mandal AK**. Spontaneous bladder rupture: a diagnostic and treatment dilemma case studies and literature review. *UroToday Int J* 2009; 2

62 **Pal DK**, **Bag AK**. Spontaneous rupture of urinary bladder in puerperium. *Indian J Surg* 2005; 67: 325–6

63 **Alshareef TA**, **Almaiman W**, **Figueroa VH**, **Gooden MA**, **Bägli DJ**, **Harvey E**. Idiopathic urinary bladder perforation in early childhood. *Kidney Int Rep* 2018; 3: 1497–500

64 **Kawanami D**, **Yoshikawa Y**, **Tsujino D**, **Sakamoto M**, **Sakamoto Y**, **Utsunomiya K**. A case of acute abdomen caused by bladder rupture attributable to diabetic neurogenic bladder. *Diabetol Int* 2014; 5: 144–7

65 **Jutley RS**, **Mason RG**. Lessons to be learned: a case study approach "Spontaneous" intraperitoneal bladder rupture in a psychiatric patient – with diagnostic difficulties. *J R Soc Promot Health* 2001; 121: 125–7

66 **Cekic SG**, **Ulukent SC**, **Yildirim GY**, **Esmer AC**, **Akca A**, **Kublay A**. A case of spontaneous bladder rupture following vaginal delivery in a mutilated woman. *Clin Exp Obstet Gynecol* 2017; 44: 941–3

67 **de Leon J**, **Liu S**, **Ng WY**, **McGregor R**, **Tse V**. Spontaneous bladder rupture in a patient with adult Ehlers-Danlos syndrome without bladder diverticulae. *UroToday Int J* 2011; 4: art29

68 **Jairam A**, **Kachhela R**, **Mukherjee D**, **Hooda AK**. Urinary ascites after an alcohol binge: an uncommon treatable cause of acute kidney injury. *Indian J Nephrol* 2014; 24: 255–6

69 **Heffernan SJ**. Recurrent spontaneous rupture of the urinary bladder. *Irish J Med Sci* 1960; 35: 87–90

70 **Chen CH**, **Chang YT**, **Huang NC**, **Huang FD**. New-onset massive ascites with acute kidney injury due to spontaneous rupture of the urinary bladder. *J Acute Med* 2019; 9: 64–8

71 **Eckardt KU**, **Bittner R**, **Dudenhausen JW**, **Frei U**. Post-partum "acute renal failure". *Nephrol Dial Transplant* 2002; 17: 1703–5

72 **Farahzadi A**, **Mohammadipour S**. A late presentation of spontaneous bladder rupture during labor. *Urol Case Rep* 2016; 8: 24–5

73 **Ajape AA**, **Abdulkadir AY**, **Babata AL**, **Adesiyun OAM**. Spontaneous intra-peritoneal urinary bladder rupture complicating benign prostate hyperplasia: case report. *Ann Afr Surg* 2011; 7: 62–5

74 **Tan BL**, **Sheen-Chen SM**, **Chen FC**, **Liu PP**. Spontaneous intraperitoneal bladder rupture. *Formos J Surg* 2002; 35: 48–51

75 **Zhou C**, **Ying X**, **Feng W**. Pseudo-acute renal failure due to intraperitoneal urine leakage. *Internal Med* 2015; 54: 1777–80

76 **Mardani M**, **Tehrani S**, **Hemmatian M**. Spontaneous bladder rupture in a patient with human T-cell lymphotropic virus type 1: a case report. *Arch Clin Infect Dis* 2014; 9: e19339

77 **Ridinger HA**, **Kavitt RT**, **Green JK**. Urinary ascites and renal failure from unrecognized bladder rupture. *Am J Med* 2012; 125: e1–2

78 **White S**, **Wigram NJ**. A case of spontaneous rupture of the urinary bladder. *Br J Surg* 1916; 4: 324–5

79 **Zhang Y**, **Yuan S**, **Alshayyah RWA et al.** Spontaneous rupture of urinary bladder: two case reports and review of literature. *Front Surg* 2021; 8: 721705

80 **Mahfouz IA**, **Sayer T**, **Phillips C**, **Abu Mahfouz I**, **Sayer T**, **Phillips C**. Conservative management of spontaneous rupture of the urinary bladder. *Int Urogynecol J* 2011; 22: 629–31

81 **Watanabe Y**, **Yamazaki S**, **Yokoyama H et al.** A rare case of recurrent generalized peritonitis caused by spontaneous urinary bladder rupture after radiotherapy: a case report and literature review. *Medicines* 2021; 8: 67

82 **Webb JC**, **Gilson G**, **Gordon L**. Late second stage rupture of the uterus and bladder with vaginal birth after cesarean section: a case report and review of the literature. *J Matern Fetal Med* 2000; 9: 362–5

83 **Stabile G**, **Cracco F**, **De Santo D et al.** Spontaneous bladder rupture after normal vaginal delivery: description of a rare complication and systematic review of the literature. *Diagnostics (Basel)* 2021; 11: 1885

84 **Sahin T**, **Oner U**, **Baser O**, **Kurtuncu I**. Spontaneous bladder rupture secondary to warfarin overdose: a case report. *BMC Emerg Med* 2019; 19: 80

85 **Kumar RV**, **Banerjee GK**, **Bhadauria RP**, **Ahlawat R**. Spontaneous bladder perforation: an unusual management problem of tuberculous cystitis. *ANZ J Surg* 1997; 67: 69–70

86 **Abuzoda U**, **Pozyczka A**, **Preston J**. Spontaneous bladder rupture during labour diagnosed at caesarean section. *J Obstet Gynaecol* 2003; 23: 670–1

1464410x, 2023, 6, Downloaded from https://bjui-journals.onlinelibrary.wiley.com/doi/10.1111/bju.15974 by South African Medical Research, Wiley Online Library on [27/01/2024]. See the Terms and Conditions (https://onlinelibrary.wiley.com/terms-and-conditions) on Wiley Online Library for rules of use; OA articles are governed by the applicable Creative Commons License

87 **Izumi J**, **Hirano H**, **Kato T**, **Ito T**, **Kinoshita K**, **Wakabayashi T**. CT findings of spontaneous intraperitoneal rupture of the urinary bladder: two case reports. *Jpn J Radiol* 2012; 30: 284–7

88 **Charalampidis S**, **Petrides C**, **Charalampous C**, **Stavrou S**. Hyponatremic renal pseudofailure and massive ascites following normal vaginal delivery: a diagnostic and therapeutic challenge. *Ren Fail* 2012; 34: 237–40

89 **Hwang EC**, **Kwon DD**, **Kim CJ et al.** Eosinophilic cystitis causing spontaneous rupture of the urinary bladder in a child. *Int J Urol* 2006; 13: 449–50

90 **Basavaraj DR**, **Zachariah KK**, **Feggetter JGW**. Acute abdomen – remember spontaneous perforation of the urinary bladder. *J R Coll Surg Edinb* 2001; 46: 316–7

91 **Sharma K**, **Singh V**, **Gupta S**, **Sankhwar S**. Xanthogranulomatous cystitis with malacoplakia, leading to spontaneous intraperitoneal perforation of the urinary bladder in a 9-year-old girl. *BMJ Case Rep* 2015; 2015: bcr2015210786

92 **Woo J**. Spontaneous rupture of the bladder in a patient with cor pulmonale presenting as acute abdominal emergency. *Postgrad Med J* 1986; 62: 702

93 **Kam J**, **Ainsworth H**, **Winter M**, **Lee WG**, **Ruthven S**. Silent bladder perforation. *Br J Hosp Med (Lond)* 2015; 76: 486–7

94 **Stebbing J**, **Ezra DG**, **Cackett PD**, **Greenstein AS**. Ascites and apparent renal failure treated with a Foley catheter. *J R Soc Med* 1999; 92: 582–3

95 **Yeh HC**, **Ting IW**, **Huang WY**, **Huang JW**. The case: ascites with oliguric acute renal failure. *Kidney Int* 2008; 74: 249–50

96 **Brown R**, **Griffiths JM**. Perforation of the herniated bladder. *Br J Urol* 1993; 71: 102–3

97 **Misra UK**, **Kalita J**, **Vajpeyee A**, **Mandhani A**, **Sharma RK**. Bladder rupture: a rare complication of tonic-clonic seizures. *QJM* 2003; 96: 542–3

98 **Garfinkle SE**, **Chiu GW**, **Cohen SE**, **Wolfman EFJ**. Spontaneous perforation of the neurogenic urinary bladder. *West J Med* 1976; 124: 64–6

99 **Png KS**, **Chong YL**, **Ng CK**. Two cases of intraperitoneal bladder rupture following vaginal delivery. *Singapore Med J* 2008; 49: e327–9

100 **Hayashi W**, **Nishino T**, **Namie S**, **Obata Y**, **Furukawa M**, **Kohno S**. Spontaneous bladder rupture diagnosis based on urinary appearance of mesothelial cells: a case report. *J Med Case Rep* 2014; 8: 46

101 **Kivlin D**, **Ross C**, **Lester K**, **Metro M**, **Ginsberg P**. A case series of spontaneous rupture of the urinary bladder. *Curr Urol* 2014; 8: 53–6

102 **Hariharasudhan S**, **Krishnamoorthy S**, **Shroff S**. Spontaneous rupture of urinary bladder (SRUB) in a young male, presenting as anuria – a case report and review of literature. *Open Urol Nephrol J* 2014; 7: 64–6

103 **Mark A**, **Meister M**, **Opara B**, **Chow R**. Nontraumatic urinary bladder rupture presenting as renal pseudo-failure and ascites. *Radiol Case Rep* 2017; 12: 304–7

104 **Pradhan AA**. Spontaneous rupture of bladder: a rare clinical entity. *Med J Armed Forces India* 2007; 63: 92–3

105 **Pal RP**, **Terry TR**, **Khan MA**. Spontaneous intra-peritoneal perforation of the bladder secondary to peritoneal tuberculosis. *Br J Med Surg Urol* 2009; 2: 213–4

106 **Ouafidi B**, **Bouab M**, **Kiram H et al.** Spontaneous bladder rupture following non traumatic vaginal delivery in a multiparous woman: a rare case report. *Int J Surg Case Rep* 2021; 87: 106349

107 **Palthe S**, **Dijkstra GA**, **Steffens MG**. A case of spontaneous urinary bladder rupture secondary to urinary retention due to an urethral stricture. *Urol Case Rep* 2018; 17: 85–7

108 **Watson HS**, **Culkin DJ**, **Wheeler JS**, **Mata J**, **Venable D**. Spontaneous intraperitoneal vesical rupture in association with neuropathic bladder. *Paraplegia* 1990; 28: 158–63

109 **Raghavendran M**, **Kumar KG**, **Venugopal A**, **Prasad S**, **Venkatesh HA**. Spontaneous bladder rupture masquerading as pseudo-diverticulum. *Urol Case Rep* 2017; 12: 73–5

110 **Kibel AS**, **Staskin DR**, **Grigoriev VE**. Intraperitoneal bladder rupture after normal vaginal delivery. *J Urol* 1995; 153(3 Pt 1): 725–7

111 **Kaur N**, **Attam A**, **Gupta A**. Spontaneous bladder rupture caused by a giant vesical calculus. *Int Urol Nephrol* 2006; 38: 487–9

112 **Oh SB**, **Ahn JH**. Successful conservative management of a spontaneous intraperitoneal rupture of bladder diverticulum in a critical patient: a case report. A CARE-compliant article. *Medicine* 2020; 99: e19262

113 **Elem B**. Spontaneous rupture of the bladder associated with schistosomiasis haematobium. *Br J Urol* 1977; 49: 426

114 **Christensen JB**, **Wara P**, **Hillstøm C**. Spontaneous rupture of the urine bladder. Report of three cases. *Scand J Urol Nephrol* 1986; 20: 73–4

115 **Keeler LL**, **Sant GR**. Spontaneous rupture of a bladder diverticulum. *J Urol* 1990; 143: 349–51

116 **Zhao LP**, **Tankovic J**, **Decré D**, **Maury E**. A rare cause of subcutaneous crepitation. *Intensive Care Med* 2016; 42: 1500–1

117 **Piser JA**, **Kamer M**, **Rowland RG**. Spontaneous bladder rupture owing to atherosclerotic emboli: a case report. *J Urol* 1986; 136: 1068–70

118 **Jurisic D**, **Glavan E**, **Cugura JF**, **Vidovic D**. Splenic rupture following idiopathic rupture of the urinary bladder presenting as acute abdomen. *J Postgrad Med* 2007; 53: 39–40

119 **Lapointe SP**, **Pharand D**, **Lapointe S**, **Drouin G**. Spontaneous rupture of the bladder as a complication of total vaginal prolapse. *J Urol* 1997; 158 (3 Pt 1): 884

120 **Davis JL 3rd**, **Callender CO**. Spontaneous bladder rupture and cytomegalovirus infection complicating renal transplantation: cause or coincidence? *J Natl Med Assoc* 1982; 74: 1131–5

121 **Powell JM**, **Williams G**. Spontaneous perforation of the bladder in association with malignant disease and schistosomiasis. *Br J Urol* 1983; 55: 126

122 **Lua LL**, **Evans T**, **Gomez N**. Simultaneous uterine and bladder rupture following successful vaginal birth after cesarean delivery: laparoscopic repair of defect. *J Minim Invasive Gynecol* 2017; 24: 329–32

123 **Vohra SB**, **Kapur S**. Diagnosis of bladder rupture by arterial blood gas analysis. *Anaesthesia* 2007; 62: 534–5

124 **Ramcharan K**, **Poon-King TM**, **Indar R**. Spontaneous intraperitoneal rupture of a neurogenic bladder; the importance of ascitic fluid urea and electrolytes in diagnosis. *Postgrad Med J* 1987; 63: 999–1000

125 **Itoh N**, **Kounami T**. Spontaneous rupture of a bladder diverticulum: ultrasonographic diagnosis. *J Urol* 1994; 152: 1206–7

126 **Comiter CV**, **McDonald M**, **Minton J**, **Yalla SV**. Fungal bezoar and bladder rupture secondary to candida tropicalis. *Urology* 1996; 47: 439–41

127 **Stein RJ**, **Matoka DJ**, **Noh PH**, **Docimo SG**. Spontaneous perforation of congenital bladder diverticulum. *Urology* 2005; 66: 881

128 **Kong CHC**, **Ali SAM**, **Singam P**, **Hong GE**, **Cheok LB**, **Zainuddin ZM**. Spontaneous bladder perforation: a rare complication of tuberculosis. *Int J Infect Dis* 2010; 14(Suppl 3): e250–2

129 **Huffman JL**, **Schraut W**, **Bagley DH**. Atraumatic perforation of bladder. Necessary differential in evaluation of acute condition of abdomen. *Urology* 1983; 22: 30–5

130 **Doig CM**. Perforation of a tuberculous bladder. *Lancet* 1969; 2: 271–2

131 **Wystrychowski A**, **Nowicki M**, **Kokot F**. Hyponatraemic renal pseudofailure-don't forget the possibility of uroperitoneum. *Nephrol Dial Transplant* 1996; 11: 2491–2

132 **Sørensen VT**, **Asklin B**, **Brunkwall P**. Extraperitoneal perforation of the urinary bladder in association with urothelial cancer in a female. *Scand J Urol Nephrol* 1991; 25: 277–8

133 **Jee LD**, **Millar AJ**. Ruptured bladder following circumcision using the Plastibell device. *Br J Urol* 1990; 65: 216–7

134 **Sailo SL**, **Sailo L**. Spontaneous puerperal bladder perforation presenting with urinary retention. *Urol J* 2014; 11: 1854

135 **Imataki O**, **Uchida S**, **Kushida Y**, **Uemura M**. Bladder rupture after chronic hemorrhagic cystitis in a stem cell transplantation recipient. *Transplantation* 2017; 101: e280–1

1464410x, 2023, 6, Downloaded from https://bjui-journals.onlinelibrary.wiley.com/doi/10.1111/bju.15974 by South African Medical Research, Wiley Online Library on [27/01/2024]. See the Terms and Conditions (https://onlinelibrary.wiley.com/terms-and-conditions) on Wiley Online Library for rules of use; OA articles are governed by the applicable Creative Commons License

136 **Dueñas-García OF**, **Rico H**, **Gorbea-Sanchez V**, **Herrerias-Canedo T**. Bladder rupture caused by postpartum urinary retention. *Obstet Gynecol* 2008; 112(2 Pt 2): 481–2

137 **Wandabwa J**, **Otim T**, **Kiondo P**. Spontaneous rupture of bladder in puerperium. *Afr Health Sci* 2004; 4: 138–9

138 **Zhang X**, **Zhang G**, **Zhang L**, **Sun C**, **Liu N**, **Chen M**. Spontaneous rupture of the urinary bladder caused by eosinophilic cystitis in a male after binge drinking: a case report. *Medicine* 2017; 96: e9170

139 **Hemal AK**. Fatal intraperitoneal perforation of the bladder: 2 case reports. *Trop Doct* 1990; 20: 186–7

140 **Oteng-Ntim E**, **Iskaros J**, **Dinneen M**, **Penn Z**. Simultaneous intrapartum uterine and bladder rupture. *J Obstet Gynaecol* 2002; 22: 685–6

141 **Harding AE**, **Scott J**, **Jefferson M**. Bladder rupture in multiple sclerosis. *Br Med J* 1977; 1: 270

142 **Patel RI**, **Haas C**, **Spirnak JP**, **Erhardt C**. Spontaneous extraperitoneal bladder rupture. *J Urol* 1998; 159: 2089–90

143 **Horino T**, **Okazaki M**, **Nishikawa H et al.** A case with spontaneous bladder rupture mimicking acute kidney injury. *Clin Nephrol* 2009; 72: 391–3

144 **Newland MC**, **Hosman SL**, **Newland JR**, **Landers DF**. Unusual etiology of hyperkalemia in an immunocompromised patient. *J Clin Anesth* 1991; 3: 470–2

145 **Qiao P**, **Tian D**, **Bao Q**. Delayed diagnosis of spontaneous bladder rupture: a rare case report. *BMC Womens Health* 2018; 18: 124

146 **Bennett AH**, **Delrio A**. Idiopathic rupture of the bladder: association with methamphetamine and alcohol. *J Urol* 1980; 124: 429–30

147 **Dooldeniya MD**, **Khafagy R**, **Mashaly H**, **Browning AJ**, **Sundaram SK**, **Biyani CS**. Lower abdominal pain in women after binge drinking. *BMJ* 2007; 335: 992–3

148 **Habek D**, **Marton I**, **Luetic AT et al.** Acute abdomen syndrome due to spontaneous intraperitoneal bladder rupture following vaginal delivery. *Z Geburtshilfe Neonatol* 2018; 222: 34–6

149 **Uysal E**, **Dokur M**, **Ikidag MA**, **Kirdak T**. Idiopathic spontaneous bladder perforation: a rare case. *Urol J* 2015; 12: 2119–21

150 **Evans RA**, **Reece RW**, **Smith MJ**. Idiopathic rupture of the bladder. *J Urol* 1976; 116: 565–7

151 **Shroff S**, **Lee JO**, **Townsend AR**. Spontaneous rupture of bladder in pregnancy. A case report. *Urol Int* 1994; 52: 179–80

152 **Ortega-Carnicer J**, **Alcázar R**, **Ambrós A**, **Gómez-Grande ML**. Acute postrenal failure and pseudomyocardial infarction after spontaneous bladder rupture. *Intensive Care Med* 2000; 26: 353–4

153 **Altman B**, **Horsburgh AG**. Spontaneous rupture of the bladder. *Br J Urol* 1966; 38: 85–8

154 **Britto MM**, **Yao HHI**, **Campbell N**. Delayed diagnosis of spontaneous rupture of a congenital bladder diverticulum as a rare cause of an acute abdomen. *ANZ J Surg* 2019; 89: E385–7

155 **Basiri A**, **Radfar MH**. Conservative management of early bladder rupture after postoperative radiotherapy for prostate cancer. *Urol J* 2008; 5: 269–71

156 **Ratliff DA**, **Scoble JE**. Spontaneous perforation of the bladder presenting as apparent acute renal failure. *Br J Urol* 1987; 60: 369

157 **Lee JY**, **Cass AS**. Spontaneous bladder and uterine rupture with attempted vaginal delivery after cesarean section. *J Urol* 1992; 147: 691–2

158 **Hong YH**, **Mahdy A**. Postvoid abdominal pain may be a symptom of spontaneous bladder rupture. *Int Urogynecol J* 2017; 28: 161–2

159 **Marcus EL**, **Prat O**. Urinary bladder rupture in an elderly patient: case report. *Can Fam Physician* 1995; 41: 1945–7

160 **Budd JS**. Spontaneous intraperitoneal rupture of the bladder in association with transitional cell carcinoma. *Postgrad Med J* 1988; 64: 165–6

161 **Mardani M**, **Shahzadi M**, **Rakhshani N**, **Rahnavardi M**, **Rezvani J**, **Sharifinejad A**. Spontaneous perforation of urinary bladder secondary to *Candida* cystitis: acute abdomen of urologic origin. *Surg Infect (Larchmt)* 2008; 9: 525–7

162 **Labanaris AP**, **Zugor V**, **Reinhold Nützel R**, **Kühn R**. Spontaneous rupture of the urinary bladder 10 years after curative radiotherapy. *ScientificWorldJournal* 2008; 8: 405–8

163 **Cusano A**, **Abarzua-Cabezas F**, **Meraney A**. Spontaneous bladder perforation unrelated to trauma or surgery. *BMJ Case Rep* 2014; 2014: bcr2014204161

164 **McCarthy FP**, **Ades A**, **Ang WC**. Spontaneous combined bladder and uterine rupture in pregnancy. *Aust N Z J Obstet Gynaecol* 2009; 49: 234–5

165 **Gough M**, **McDermott EW**, **Lyons B**, **Hederman WP**. Perforation of bladder carcinoma presenting as acute abdomen. *Br J Urol* 1992; 69: 541–2

166 **O'Neill GF**, **Alexander JH**. Spontaneous bladder rupture in a patient with widespread superficial transitional cell carcinoma. *ANZ J Surg* 1998; 68: 79

167 **Harada T**, **Suyama Y**, **Hiratsuka Y**, **Shimizu T**. An arterial perihepatic enhancement caused by spontaneous bladder rupture. *Urology* 2017; 100: e7–8

168 **Gupta A**, **Biyani M**, **Gupta M**, **Saltel ME**. Hypercreatinemia: think beyond acute kidney injury. *Can J Urol* 2011; 18: 6066–8

169 **Ketata S**, **Boulaire JL**, **Al-Ahdab N**, **Bargain A**, **Damamme A**. Spontaneous intraperitoneal perforation of the bladder: a late complication of radiation therapy for prostate cancer. *Clin Genitourin Cancer* 2007; 5: 287–90

170 **Rawat J**, **Singh S**, **Chaubey D**. Spontaneous bladder rupture: unusual presentation in a haemophilic child. *BMJ Case Rep* 2017; 2017: bcr2017220943

171 **Aubia J**, **Mir M**, **Llorach I et al.** Bladder involvement in systemic amyloidosis causing massive hemorrhage in hemodialysis. *Ren Fail* 1992; 14: 197–9

172 **Ibrahimi A**, **Dergamoun H**, **Ziani I et al.** Successful conservative management of a spontaneous intraperitoneal urinary bladder rupture secondary to benign prostatic hyperplasia: a case report. *Pan Afr Med J* 2021; 38: 268

173 **Puri M**, **Pathania OP**, **Pasrija S**, **Dholakia M**. Asymptomatic bladder rupture in a primigravida: late manifestation and delayed diagnosis. *ANZ J Obstet Gynaecol* 2005; 45: 535–6

174 **Kumar S**, **Rao MS**. Concealed rupture of a normal bladder following an alcoholic bout. *J Trauma* 1982; 22: 165–6

175 **Wan YL**, **Yu TZ**, **Lee TY**, **Tsai CC**. Spontaneous intraperitoneal rupture of bladder with spontaneous healing. *Clin Imaging* 1992; 16: 247–9

176 **Smith RB**, **Kettlewell MG**. Rupture of a bladder diverticulum in multiple sclerosis. *Br J Urol* 1976; 48: 382

177 **Jorion JL**, **Michel M**. Spontaneous rupture of bladder diverticula in a girl with Ehlers-Danlos syndrome. *J Pediatr Surg* 1999; 34: 483–4

178 **Wujanto R**, **Brough R**, **O'Reilly PH**. Spontaneous perforation of squamous cell bladder carcinoma associated with hypercalcaemia. *Br J Urol* 1989; 63: 647–8

179 **Matsumura M**, **Ando N**, **Kumabe A**, **Dhaliwal G**. Pseudo-renal failure: bladder rupture with urinary ascites. *BMJ Case Rep* 2015; 2015: bcr2015212671

180 **Pintar TJ**, **Wilke RA**. Urinary ascites: spontaneous bladder rupture presenting as acute oliguric renal failure. *Am J Med* 1998; 105: 347–9

181 **Gupta K**, **Dev B**, **Chadga HC**. Spontaneous intraperitoneal rupture of the bladder in an adult female. *Cent European J Urol* 2010; 63: 149–50

182 **Neel KF**. Spontaneous bladder rupture in a non-augmented neuropathic bladder. *Saudi Med J* 2004; 25: 220–1

14644108x, 2023, 6, Downloaded from https://bjui-journals.onlinelibrary.wiley.com/doi/10.1111/bju.15974 by South African Medical Research, Wiley Online Library on [27/01/2024]. See the Terms and Conditions (https://onlinelibrary.wiley.com/terms-and-conditions) on Wiley Online Library for rules of use; OA articles are governed by the applicable Creative Commons License

183 **Wong MH**, **Lim SK**, **Ng KL**, **Ng KP**. Pseudo-acute kidney injury with recurrent ascites due to intraperitoneal urine leakage. *Intern Med J* 2012; 42: 848–9

184 **Aber A**, **Hyder SA**, **Arumuham V**. An unusual case of spontaneous bladder perforation with associated autodialysis of the ensuing urinary ascites. *Case Rep Med* 2011; 2011: 145084

185 **Goto S**, **Yamadori M**, **Igaki N**, **Kim JI**, **Fukagawa M**. Pseudo-azotaemia due to intraperitoneal urine leakage: a report of two cases. *NDT Plus* 2010; 3: 474–6

186 **Bultitude MF**, **Lilas L**, **Tay A**, **Glass JM**. Bladder rupture fourteen years after radiotherapy for transitional cell carcinoma. *J Surg* 2004; 2: 54–5

187 **Al-Qassim Z**, **Mohammed A**, **England R**, **Khan Z**. Idiopathic spontaneous rupture of the urinary bladder (SRUB). A case report and review of literature. *Cent European J Urol* 2012; 65: 235–7

188 **Monsellato I**, **Morello A**, **Argenio G**, **Canepa MC**, **Lenti LM**, **Priora F**. Spontaneous bladder rupture mimicking a jejuno-ileal perforation. *G Chir* 2018; 34: 315–8

189 **Addar MH**, **Stuart GCE**, **Nation JG**, **Shumsky AG**. Spontaneous rupture of the urinary bladder: a late complication of radiotherapy – case report and review of the literature. *Gynecol Oncol* 1996; 62: 314–6

190 **Crawford R**, **Oliver TRW**, **Abboudi H**, **Shah S**. Spontaneous rupture of the bladder during vomiting. *BMJ Case Rep* 2017; 2017: bcr2016217914

191 **Parker H**, **Hoonpongsimanont W**, **Vaca F**, **Lotfipour S**. Spontaneous bladder rupture in association with alcoholic binge: a case report and review of the literature. *J Emerg Med* 2009; 37: 386–9

192 **Secrest KM**, **Maki CJ**. A rare cause of urinary peritonitis: intra-abdominal adhesion rupture. *Urology* 2019; 129: 21–3

193 **Mauerhofer E**, **Lüscher M**, **Poyet C et al.** Acute abdominal pain accompanied by high creatinine in a female patient with schizophrenia. *Urology* 2015; 85: 495–8

194 **Lee C**, **Park MU**, **Fabrega AJ**, **Macramalle E**. Spontaneous rupture of a normal bladder. *South Med J* 1991; 84: 392–3

195 **Bliss BP**, **Saunders M**, **Clark WGB**. Recurring spontaneous rupture of urinary bladder following subarachnoid haemorrhages. *Br J Surg* 1964; 51: 446

196 **Vandenbroek NR**. Spontaneous perforation of the bladder – a report of 2 cases. *Trop Geogr Med* 1995; 47: 229–30

197 **Kerigh BF**, **Boostani R**, **Ghoreifi A**. Recurrent spontaneous rupture of the urinary bladder in a patient with human T-lymphotropic virus type 1-associated myelopathy: a case report and literature review. *Nephrourol Mon* 2014; 6: e11764

198 **Snauwaert C**, **Geerts A**, **Colle I**, **van Vlierberghe H**. Ascites: not always the usual suspects. *Acta Gastroenterol Belg* 2012; 75: 45–8

199 **Wheeler MH**. Recurrent spontaneous rupture of urinary-bladder. *Br J Surg* 1972; 59: 983–4

200 **Inoue Y**, **Fujino Y**, **Onodera M et al.** Investigation of patients with spontaneous rupture of the urinary bladder. *Open J Clin Diagn* 2015; 5: 141

201 **Tabaru A**, **Endou M**, **Miura Y**, **Otsuki M**. Generalized peritonitis caused by spontaneous intraperitoneal rupture of the urinary bladder. *Intern Med* 1996; 35: 880–2

202 **Saleem MA**, **Mahmoud AM**, **Gopinath BR**. Spontaneous urinary bladder rupture: a rare differential for lower abdominal pain in a female patient. *Singapore Med J* 2009; 50: e410–1

203 **Raju PGS**. Spontaneous rupture of the urinary-bladder 42 years after irradiation. *Saudi Med J* 1994; 15: 460

204 **Magliolo A**, **Grizzle KB**. Spontaneous rupture of the urinary bladder leading to proteus peritonitis. *J Investig Med* 2019; 67: 493

205 **Feigal WM**, **Polzak JA**. Spontaneous rupture of the urinary bladder. *J Urol* 1946; 56: 196–9

206 **Baker SC**. Spontaneous rupture of the urinary bladder. *J Ir Med Assoc* 1964; 54: 96–7

207 **Maxwell DR**, **Baugh DO**, **Kleit SA**, **Szwed JJ**. Spontaneous rupture of the urinary bladder. *J Indiana State Med Assoc* 1973; 66: 35–7

208 **Juul P**, **Højhus H**. Spontaneous rupture of the urinary bladder. *Scand J Urol Nephrol* 1985; 19: 155–6

209 **Karamooz M**, **Seebode JJ**. Spontaneous rupture of the urinary bladder. *J Med Soc N J* 1977; 74: 419–22

210 **Macalister CL**. Spontaneous rupture of the urinary bladder. *Proc R Soc Med* 1955; 48: 693–7

211 **Taylor RAR**. Spontaneous rupture of the urinary bladder. *Br J Urol* 1948; 20: 117–20

212 **Ihekwaba FN**. Spontaneous rupture of the urinary bladder. Case reports and review of literature. *Niger Med J* 1979; 9: 389–93

213 **Jackman FR**. Recurrent spontaneous rupture of the urinary bladder. *Br J Urol* 1976; 48: 54

214 **Yarwood GR**. Spontaneous rupture of the normal urinary bladder. *Br J Urol* 1959; 31: 87–8

215 **Hughes P**, **Ravi N**. A rare case of spontaneous rupture of the urinary bladder. *Ir Med J* 2012; 105: 155–6

216 **Singh A**, **Soni R**. Spontaneous rupture of urinary bladder. *J Indian Med Assoc* 1978; 70: 10–1

217 **Faraj R**, **O'Donovan P**, **Jones A**, **Hill S**. Spontaneous rupture of urinary bladder in second trimester of pregnancy: a case report. *Aust N Z J Obstet Gynaecol* 2008; 48: 520

218 **Kekre AN**, **Kekre N**, **Nath V**, **Seshadri L**. Spontaneous rupture of the urinary bladder in the puerperium. *Aust N Z J Obstet Gynaecol* 1997; 37: 473–4

219 **Nemser MM**, **Weinberger HA**. Spontaneous rupture of the urinary bladder in a male. *J Urol* 1952; 68: 603–7

220 **Jenkinson LR**. Spontaneous intraperitoneal rupture of the urinary bladder. *Postgrad Med J* 1981; 57: 269–70

221 **Loganathan A**, **Wood J**, **Pridgeon S**. Idiopathic spontaneous rupture of the urinary bladder: an unusual presentation of intraperitoneal bladder rupture managed conservatively. *Urol Case Rep* 2019; 24: 100873

222 **Rangarajan M**, **Jayakar S**. Rare case of spontaneous rupture of a urinary bladder carcinoma causing intestinal obstruction and peritonitis. *Surg Pract* 2007; 11: 44–7

223 **Maddocks RA**, **Leadbetter GW Jr**. Spontaneous bladder rupture: rare cause of peritonitis. *J Am Coll Emerg Physicians* 1976; 5: 591–3

224 **Radha Krishna Y**, **Das K**, **Ghoshal UC**, **Choudhuri G**. Acute hemorrhagic ascites: look beyond the gastrointestinal tract. *Indian J Gastroenterol* 2007; 26: 189–90

225 **Clinton-Thomas CL**. Idiopathic spontaneous rupture of the bladder. *Br J Urol* 1955; 27: 235–8

226 **Göğüş C**, **Türkölmez K**, **Savaş B**, **Sertçelik A**, **Baltaci S**. Spontaneous bladder rupture due to chronic cystitis 20 years after cystolithotomy. *Urol Int* 2002; 69: 327–8

227 **Petković S**. Spontaneous rupture of a leiomyosarcoma of the bladder. *Br J Urol* 1946; 18: 69–71

228 **Danso AP**. Spontaneous rupture of the urinary bladder. *Cent Afr J Med* 1987; 32: 246–51

229 **Leahy O**, **Grummet J**. Splash! The spontaneous rupture of a bladder diverticulum: a rare cause of an acute abdomen. *ANZ J Surg* 2013; 83: 792–3

230 **Albino G**, **Bilardi F**, **Gattulli D**, **Maggi P**, **Corvasce A**, **Marucco EC**. Spontaneous rupture of urinary bladder: a case report and review. *Arch Ital Urol Androl* 2012; 84: 224–6

231 **Sarma DR**, **John A**. Spontaneous rupture of the urinary bladder. *Br J Hosp Med* 2015; 76: 427

232 **Huston B**, **Mills K**, **Froloff V**, **McGee M**. Bladder rupture after intentional medication overdose. *Am J Forensic Med Pathol* 2012; 33: 184–5

1464410x, 2023, 6, Downloaded from https://bjui-journals.onlinelibrary.wiley.com/doi/10.1111/bju.15974 by South African Medical Research, Wiley Online Library on [27/01/2024]. See the Terms and Conditions (https://onlinelibrary.wiley.com/terms-and-conditions) on Wiley Online Library for rules of use; OA articles are governed by the applicable Creative Commons License

233 **Kato A**, **Yoshida KIK**, **Tsuru N et al.** Spontaneous rupture of the urinary bladder presenting as oliguric acute renal failure. *Intern Med* 2006; 45: 815–8

234 **Chute DJ**, **Cox J**, **Archer ME**, **Bready RJ**, **Reiber K**. Spontaneous rupture of urinary bladder associated with massive fecal impaction (fecaloma). *Am J Forensic Med Pathol* 2009; 30: 280–3

235 **Dubey IB**, **Mohanty D**, **Jain BK**. Diverse presentation of spontaneous rupture of urinary bladder: review of two cases and literature. *Am J Emerg Med* 2012; 30: 832.e1–3

236 **Tainsh JM**. Spontaneous rupture of the bladder. *Lancet* 1954; 263: 863–4

237 **Munshi IA**, **Hong JJ**, **Mueller CM**, **Barie PS**. Spontaneous rupture of the urinary bladder in the alcoholic patient. *J Trauma* 1999; 46: 1133–4

238 **Taniguchi K**, **Iida R**, **Ota K et al.** Spontaneous rupture of the urinary bladder (SRUB): recovery from cardiopulmonary arrest. *Am J Emerg Med* 2017; 35: 1584.e5–7

239 **Shaked A**, **Meretyk S**, **Pode D**, **Caine M**. Nontraumatic spontaneous rupture of the urinary bladder. *Can J Surg* 1986; 29: 107–9

240 **Crastnopal P**, **Artz R**, **Rosett L**. Recurrent spontaneous rupture of the urinary bladder; report of the fourth case. *Arch Surg* 1950; 60: 1093–101

241 **Nishimura T**, **Suzuki K**, **Iijima M et al.** Spontaneous rupture of bladder diverticulum after postoperative radiotherapy for carcinoma of the uterine cervix: a case report. *Radiat Med* 2000; 18: 261–5

242 **Nobel W**. Spontaneous rupture of the bladder complicating treatment of fracture of the lumbar spine. *Bull Hosp Joint Dis* 1945; 6: 144–8

243 **Lavelle MA**. Recurrent spontaneous rupture of the urinary bladder. *Br J Clin Pract* 1990; 44: 790–2

244 **Escue HM**. Spontaneous rupture of vesical diverticulum. *Urol Cutaneous Rev* 1949; 53: 468

245 **Elem B**. Spontaneous rupture of urinary bladder. *Med J Zambia* 1980; 14: 25–6

246 **Carmon M**, **Nissan A**, **Pappo I**, **Perlberg S**, **Seror D**, **Haskel Y**. Spontaneous rupture of the urinary bladder complicated by extensive fascitis: the importance of a high index of suspicion. *Urol Int* 1994; 52: 38–40

247 **Nishiyama T**, **Terunuma M**, **Sugahara S**, **Yahata K**. Spontaneous right uretero-cutaneous fistula complicated by spontaneous rupture of the urinary bladder. *Int Urol Nephrol* 1995; 27: 275–8

248 **Hershman H**, **Allen HL**. Spontaneous rupture of the normal urinary bladder. Report of one case. *Surgery* 1954; 35: 805–8

249 **Fujikawa K**, **Yamamichi F**, **Nonomura M**, **Soeda A**, **Takeuchi H**. Spontaneous rupture of the urinary bladder is not a rare complication of radiotherapy for cervical cancer: report of six cases. *Gynecol Oncol* 1999; 73: 439–42

250 **Markou GA**, **Metaxas GE**, **Vautier-Rit S**, **Muray JMJM**, **Poncelet C**. Immediate post-partum bladder rupture. Is serum creatinine evaluation relevant? *Gynecol Obstet Fertil* 2016; 44: 607–8

251 **Thomas GK**. Spontaneous rupture of the bladder. *Br J Surg* 1956; 44: 328–30

252 **Agapitidis N**, **Papadopoulos N**, **Papastamatiou L**. A rare case of spontaneous rupture of the urinary bladder. *South Med J* 1976; 69: 244–5

253 **Daines SL**, **Hodgson NB**. Spontaneous rupture of a necrotic bladder. *J Urol* 1969; 102: 431–3

254 **Hammar B**. Spontaneous rupture of the bladder. *Br J Urol* 1961; 33: 289–91

255 **Chen WF**, **Huang SC**, **Yu TJ**. Spontaneous rupture of the bladder in childhood: report of one case. *Zhonghua Min Guo Xiao Er Ke Yi Xue Hui Za Zhi* 1994; 35: 444–8

256 **Zerin JM**, **Lebowitz RL**. Spontaneous extraperitoneal rupture of the urinary bladder in children. *Radiology* 1989; 170: 487–8

257 **Dixon C**, **Strohl E**. Spontaneous rupture of urinary bladder. *Am J Surg* 1936; 33: 110–3

258 **Sawalmeh H**, **Al-Ozaibi L**, **Hussein A**, **Al-Badri F**. Spontaneous rupture of the urinary bladder (SRUB); a case report and review of literature. *Int J Surg Case Rep* 2015; 16: 116–8

259 **Schein M**, **Weinstein S**, **Rosen A**, **Decker GAG**. Spontaneous rupture of the urinary bladder – delayed sequel of pelvic irradiation. a case report. *S Afr Med J* 1986; 70: 841–2

260 **Shin JY**, **Yoon SM**, **Choi HJ et al.** A case of post-radiotherapy urethral stricture with spontaneous bladder rupture, mimicking obstructive uropathy due to cancer metastasis. *Electrolyte Blood Press* 2014; 12: 26–9

261 **Sinha SN**, **Ghosh EN**. Spontaneous rupture of urinary bladder. *Indian J Surg* 1977; 39: 267–70

262 **Morton W**. Spontaneous rupture of the urinary bladder. *Br Med J* 1936; 1: 14

263 **Modina P**, **Vidal L**, **David CI**, **Leal C**, **Escowich R**, **Bergero MA**. Spontaneous bladder rupture: laparoscopic management of rare complications after nontraumatic vaginal delivery. *Urol Case Rep* 2020; 33: 101377

264 **Cornelis T**, **Bargman JM**. Sudden increase in "urine" output in a peritoneal dialysis patient. *Perit Dial Int* 2010; 30: 574–6

265 **Saphir O**, **Shapiro IJ**. Fatty infiltration of urinary bladder with spontaneous rupture. *Am J Surg* 1935; 29: 263–7

266 **Ashraf SM**, **Ansari MN**, **Raza SM**. Spontaneous rupture of urinary bladder. *Med Surg* 1974; 14: 5

267 **Gimmon Z**. Diagnostic difficulties in patients with a ruptured bladder. *Br J Surg* 1995; 82: 997

268 **Basu A**, **Mojahid I**, **Williamson EP**. Spontaneous bladder rupture resulting from giant vesical calculus. *Br J Urol* 1994; 74: 385–6

269 **Atalay AC**, **Karaman MI**. Spontaneous rupture of a bladder with invasive bladder carcinoma. *Int Urol Nephrol* 1998; 30: 723–4

270 **Tay KP**, **Ravintharan T**, **Lim PH**, **Chng HC**. Emergency laparoscopic repair of spontaneous and traumatic bladder rupture. *Br J Urol* 1995; 75: 550–1

271 **Nissi R**, **Talvensaari-Mattila A**, **Santala M**. Recurrent bladder rupture after cauda equina syndrome. *Int J Gynaecol Obstet* 2012; 117: 86–7

272 **Wieloch M**, **Bazylińska K**, **Ziemniak P**. Spontaneous, idiopathic urinary bladder perforation–case report. *Pol Przegl Chir* 2013; 85: 727–9

273 **Bourgeois S**, **Decupere M**, **Devriendt D**, **Lesage K**, **van Moerkercke W**. A case of pseudorenal failure – spontaneous rupture of the urinary bladder. *Acta Gastroenterol Belg* 2017; 80: 419–21

274 **Kamat MH**, **Corgan FJ**, **Seebode JJ**. Spontaneous rupture of the bladder. *Arch Surg* 1970; 100: 735–7

275 **Lynn SJ**, **Mark SD**, **Searle M**. Idiopathic spontaneous bladder rupture in an intoxicated patient. *Clin Nephrol* 2003; 60: 430–2

276 **Aanestad O**, **Eilard T**. Severe candida cystitis with perforation of the urinary bladder. *Scand J Urol Nephrol* 1997; 31: 311–2

277 **Marshall GA**, **Dixon CM**, **McAninch JW**. Substance abuse-related spontaneous bladder rupture: report of 2 cases and review of the literature. *J Urol* 1991; 145: 135–7

278 **Tuncer R**, **Keskin E**, **Tunali N**. Imperforate hymen as a cause of bladder perforation and intestinal obstruction. *Br J Urol* 1997; 79: 993–4

279 **Haddad FS**, **Wachtel TL**. Spontaneous intraperitoneal rupture of the bladder. *Urol Int* 1987; 42: 467–9

280 **Murray SG**, **Wachter RM**, **Cho KC**, **Dhaliwal G**. Clinical problem-solving a breakthrough diagnosis. *N Engl J Med* 2015; 373: 1865–70

281 **Hamer AJ**, **Nicholson S**, **Padfield CJ**. Spontaneous rupture of the bladder in interstitial cystitis. *Br J Urol* 1992; 69: 102

282 **Cumes D**, **Kessler R**. Intraperitoneal rupture of pseudodiverticulum of bladder. *Urology* 1979; 14: 515–7

283 **Shumaker BP**, **Pontes JE**, **Pierce JMJ**. Idiopathic rupture of bladder. *Urology* 1980; 15: 566–8

284 **Golbidi S**, **Laher I**. Bladder dysfunction in diabetes mellitus. *Front Pharmacol* 2010; 1: 136

1464410x, 2023, 6, Downloaded from https://bjui-journals.onlinelibrary.wiley.com/doi/10.1111/bju.15974 by South African Medical Research, Wiley Online Library on [27/01/2024]. See the Terms and Conditions (https://onlinelibrary.wiley.com/terms-and-conditions) on Wiley Online Library for rules of use; OA articles are governed by the applicable Creative Commons License

285 **Williams JA Jr**, **Clarke D**. Pelvic radiation necrosis and radiation cystitis. In **Kindwall EP** ed, *Hyperbaric Medicine Practice*. Arizona: Best Publishing, 1994: 505

286 **Hawary A**, **Clarke L**, **Taylor A**, **Duffy P**. Enterovesical fistula: a rare complication of urethral catheterization. *Adv Urol* 2009; 2009: 591204

287 **Hsieh CH**, **Chen RJ**, **Fang JF et al.** Diagnosis and management of bladder injury by trauma surgeons. *Am J Surg* 2002; 184: 143–7

288 **Quagliano P**, **Delair SM**, **Malhotra AK**. Diagnosis of blunt bladder injury: a prospective comparative study of computed tomography cystography and conventional retrograde cystography. *J Trauma* 2006; 61: 410–21

289 **Riley DS**, **Barber MS**, **Kienle GS et al.** CARE guidelines for case reports: explanation and elaboration document. *J Clin Epidemiol* 2017; 89: 218–35

Correspondence: Deshin Reddy, Division of Emergency Medicine, Department of Family Medicine and Primary Care, School of Clinical Medicine, Faculty of Health Sciences, Univeristy of Witwatersrand, Private Bag X3, Johannesburg 2050, South Africa.

e-mail: deshinr@gmail.com

Abbreviations: IQR, interquartile range; SRUB, spontaneous rupture of the urinary bladder; TURBT, transurethral resection of bladder tumour.

Supporting Information

Additional Supporting Information may be found in the online version of this article:

Table S1. Clinical presentation of patients diagnosed with SRUB.

Table S2. Methodological quality assessment of the included reports and series.

Fig. S1. Histogram of ages of patients presenting with spontaneous rupture of the urinary bladder (SRUB).

 © 2023 BJU International.

1464410x, 2023, 6, Downloaded from https://bjui-journals.onlinelibrary.wiley.com/doi/10.1111/bju.15974 by South African Medical Research, Wiley Online Library on [27/01/2024]. See the Terms and Conditions (https://onlinelibrary.wiley.com/terms-and-conditions) on Wiley Online Library for rules of use; OA articles are governed by the applicable Creative Commons License