DSPACE

https://dspace.org/

Conchomeatoplasty - ventilatory implications

Van Schalkwyk, Cornelis Rudolf

2014-04-07
http://hdl.handle.net10539/14521

Downloaded from a DSpace repository. https://dspace.org/

CONCHOMEATOPLASTY - VENTILATORY IMPLICATIONS

Cornelis Rudolf van Schalkwyk

A research report submitted to the Faculty of Health Sciences, University of the Witwatersrand, Johannesburg, in partial fulfillment of the requirements for the degree of Master of Medicine in the branch of Otorhinolaryngology.

Johannesburg, 1999

Declaration

I, Cornelis Rudolf van Schalkwyk declare that this research report is my own work. It is being submitted for the degree of Master of Medicine in the branch of Otorhinolaryngology in the University of the Witwatersrand, Johannesburg. It has not been submitted before for any degree or examination at this or any other University.

Signed: _____

Date: 30 MARCH 1999

Dedication

This work is dedicated to my father.

His vision was the inspiration.

His encouragement made it happen.

And to my wife and children, for making it all worthwhile.

Publications and Presentations arising from this study

Publications:

Van Schalkwyk CR, Van Schalkwyk D. Conchomeatoplasty: a viable operation. In: McCafferty G, Coman W, Carrol R, editors. Proceedings of the Sixteenth World Congress of Otorhinolaryngology Head and Neck Surgery; 1997 March 2-7; Sydney (Australia). Bologna: Monduzzi Editore, 1997:1081-84.

Presentations:

The findings of this study were presented at:

- The combined Third Scientific Meeting of the Pan African Federation of Oto-Rhino-Laryngological Societies and The 32nd Annual Academic Meeting of the South African Society of Otorhinolaryngology in Durban (South Africa) Oct 1996.
- The Sixteenth World Congress of Otorhinolaryngology Head and Neck Surgery in Sydney (Australia) March 1997.

Abstract

Chronic or recurrent otitis externa is a problematic entity for clinicians to control. One of the contributing causes to this problem is poor ventilation of the external auditory canal leading to high humidity and consequent maceration of the canal skin. Over the years several surgical procedures have been developed to widen the external auditory canal and therefore improve ventilation. Clinically these procedures have been quite successful in controlling chronic otitis externa.

The improvement has always been ascribed to improved ventilation. This increase in ventilation has, however, never been documented, nor quantified. One of the successful procedures is that of conchomeatoplasty. This study set out to demonstrate an improvement in ventilation and if possible to quantify this improvement, following conchomeatoplasty.

The operation was performed on thirty consecutive cadaver specimens and preoperative as well as postoperative measurements of the external ear canals were performed. Silicone moulds of the canals were taken and sectioned in an identical manner to obtain the required measurements. Statistical analysis demonstrated a consistent increase in canal diameter and by applying Poiseuille's equation to the results it was possible to demonstrate a five fold increase in the ventilatory capacity of

the lateral external auditory canal at one of the narrowest points of the cartilaginous canal.

This is the first documentation of improved ventilation following any type of meatoplasty. The method that was developed for measuring and comparing external canal sizes is unique and original and will allow for future comparison of different surgical techniques in an objective and scientific manner.

Acknowledgements

It is with sincere appreciation that I would like to acknowledge the help of the following people:

- Professor William A McIntosh from the Department of Otorhinolaryngology at the University of the Witwatersrand for the advice and encouragement given as supervisor of this project.
- Professor Beverly Kramer and Mr A Ladner from the Department of Anatomy at the University of the Witwatersrand for giving me access to their facilities and material in order to perform the laboratory studies.
- Ms Shamim Ebrahim from the Audiology Department at the Johannesburg General Hospital for helping with the earmould material.
- Dr Piet Becker from the MRC Department of Statistics for the initial statistical evaluations.

Table of contents

	Page
Declaration	ii
Dedication	iii
Publications and Presentations	iv
Abstract	v
Acknowledgements	vii
Table of contents	viii
Nomenclature	x
Chapter 1 - Introduction	1
Chapter 2 - Materials and Methods	4
2.1 Subjects	5
2.2 Intervention	7
2.3 Measurements	9
2.4 Measurement validation	12
Chapter 3 - Results	14
3.1 Description of measurement points	15
3.2 Results for points 1-4	16
3.3 Statistical analysis	20

(continued) **Page**

Chapter 4 - Discussion 22

4.1 Anatomy and physiology 23

4.2 Conchomeatoplasty effects 25

4.2.1 Preservation of canal skin 25

4.2.2 Increase in AP diameter 26

4.2.3 Improvement in ventilation 27

4.2.4 Poiseuille's equation 28

4.3 Further applications 31

4.4 Evidence-based medicine 32

Chapter 5 - Conclusions 34

References 36

Nomenclature

AP	Anteroposterior
EAC	External Auditory Canal
Postop	Postoperative
Preop	Preoperative
S	Surface area of skin in contact with circulating air
V	Volume of air circulating

Chapter 1

Introduction

Otitis externa is a common problem dealt with on a regular basis by otorhinolaryngologists.[1,20] In most cases the management is straightforward and almost all patients respond well to medical therapy.[2] A wick followed by the application of an ointment containing a combination of steroid, antibiotic and antifungal components will settle most episodes. The steroid aids in relieving swelling and pruritis whereas the antibiotic and antifungal preparations address the infective components.

On occasion however a patient presents with recurrent or chronic otitis externa and in these cases the management may become quite problematic.[2,21] Although the mainstay of treatment remains medical, the factors giving rise to repeated infections need to be addressed.[4,7] Chronic moisture, humidity and retained debris lead to maceration of the canal skin and create an ideal environment for bacterial and fungal growth.[5] Very often this is the end product of poor ventilation of the external canal and no matter how often the infection is cleared up medically, unless the underlying cause is corrected, the risk of recurrent infections remains a constant companion.[6]

Repeated infection of the external ear canal is associated with significant morbidity. Apart from the acute symptoms of intractable pain and occasionally conductive hearing loss, recurrent episodes of otitis externa carry the risk of fibrous obliteration of the ear canal.[1,7,8,20-22,24] In an attempt to address the problems of recurrent otitis externa that is resistant to medical therapy, several surgical approaches have been

developed.[3-6,8-18,20-23] The main thrust of surgery is towards maintaining functional canal skin and to promoting improved ventilation of the external ear canal.[22]

One of the successful techniques employed in the surgical treatment of recalcitrant otitis externa is that of conchomeatoplasty.[6] A significant proportion of the clinical improvement seen after meatoplasty has always been attributed to improved ventilation.[3,5,6,12-14,17,19,22,23] This improvement, however, has never been scientifically documented nor quantified.

This study was designed to determine whether conchomeatoplasty leads to a demonstrable improvement in ventilation of the external auditory canal and if so, whether this improvement can be quantified.

Chapter 2

Materials and Methods

2.1 Subjects

Conchomeatoplasties were performed on fifteen consecutive cadaver specimens used for general anatomy dissection in the laboratories of the Department of Anatomy at the University of the Witwatersrand. Both ears were operated on each specimen, giving a total of thirty studied ears.

Specimen Details:

Number	Age	Weight (kg)	Length (m)	Sex	Race
AD7313	76	66	1.85	M	White
AD7242	82	85	1.75	M	White
AD7354	58	39	1.61	F	White
AD7276	50	46	1.69	M	Black
AD7375	74	58	1.69	M	White
AD7255	60	43	1.63	M	Black
AD7271	31	74	1.65	F	White
AD7292	74	80	1.82	M	White
AD7279	75	61	1.58	F	White
AD7356	59	48	1.63	F	White
AD7260	71	52	1.73	M	Black
AD7357	76	65	1.68	M	White
AD7287	60	60	1.82	M	White
AD7334	72	47	1.67	F	White
AD7285	76	44	1.54	F	White

Exclusion criteria:

- Congenitally abnormal ears.
- Ears showing signs of previous trauma or surgery.
- Ears damaged by previous dissection.

Each subject acted as its own control in that pre and postoperative measurements were compared. By using an unselected cadaver specimen group, it allowed for measurements to made in a short time span; eliminated selection bias and allowed for comparison of pure measurement without possible confounding issues such as underlying infection or dermatological conditions.

2.2 Intervention

The procedure that was performed on each specimen is a **conchomeatoplasty**. First described by Hunsaker in 1988, the operation has been designed to enlarge the external auditory meatus to allow adequate ventilation.[6] The conchal cartilage and underlying soft tissue are resected to create a funnel-shaped meatus. In addition, a full-thickness skin graft from the redundant conchal skin is grafted to augment the meatal skin, which increases the circumference of the meatus.

The operation entails an incision around the conchal bowl from "six o'clock" around to "twelve o'clock" (Fig 1). It joins up to a release incision made between the tragus and anterior crus of the helix. The incision extends through cartilage and subcutaneous tissue down to bone along its entire length. The resultant inferomedially based skin flap is raised off the conchal cartilage and all tissue deep to it (cartilage and subcutaneous tissue) are removed. The skin flap is draped back into the conchal bowl and excess skin on the posterior aspect is trimmed off (Fig 2). This full-thickness skin is used as a free skin graft in the superior aspect of the canal. Flap and graft are then sutured into position (Fig 3).



Fig 1. Incision around conchal bowl

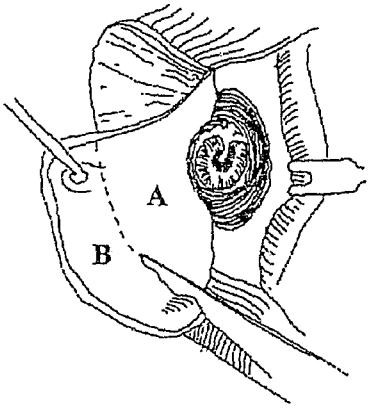

Fig 2. Skin flap draped into conchal bowl. Excess skin excised. A indicates pedicled flap. B indicates redundant skin to be used as free skin graft.

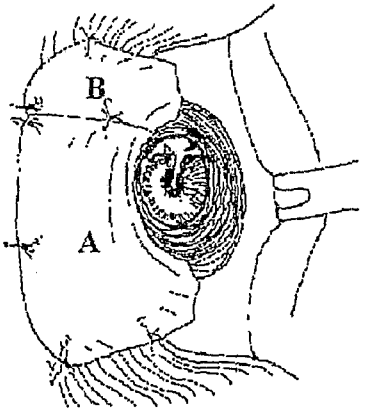

Fig 3. Flap and skin graft sutured into position

2.3 Measurements

All canals were inspected prior to intervention for any exclusion criteria or for debris that may have interfered with measurements.

Casts were made of the ear canals with a silicone material normally used in the preparation of hearing aids ("A-Zilicone®" by Oticon, Denmark). The procedure followed was the same as for hearing aid fitment:

- Otoscopic examination of the ear canal
- Sponge stopper placed against the tympanic membrane to aid in removal of cast
- Silicone introduced into the canal ensuring complete filling of the canal
- Adequate time allowed for curing of moulds
- Mould removed and inspected for air bubbles or other abnormalities

The surgical procedure was then performed and another impression taken to reflect the postoperative situation. The pre and postoperative moulds for each ear were packed separately to ensure that specimens were accurately archived and that the correct comparisons were made.

The surgical procedure alters the shape of the inferior, posterior and superior aspects of the lateral external ear canal. The anterior aspect, however, remains unchanged and a point along the anterior canal wall that could be identified on both the pre and postoperative moulds was therefore used as a reference point for all measurements and sections (A in Fig 4). This ensured that measurements compared the same points along the long axis of the canal.

The silicone moulds were sectioned in an axial plane using a scalpel blade. Care was taken to ensure that the two inferior halves were compared.

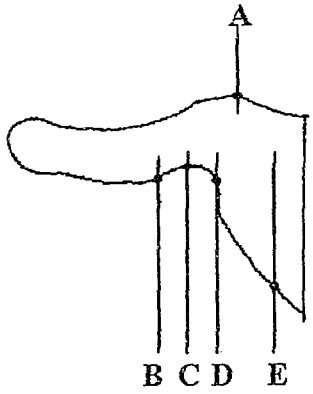

Fig 4. Preoperative mould

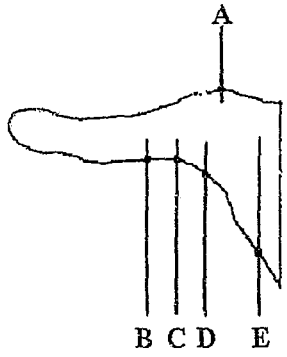

Fig 5. Postoperative mould

The preoperative specimen was examined and the impression of the conchal cartilage was usually readily identifiable on the posterior aspect of the mould. The most medial aspect of this impression (B in Fig 4) was identified and the AP diameter at this point was measured. Three further measurements of the AP diameter were made along the long axis of the ear canal:

- At the most prominent point of the conchal impression (C in Fig 4)
- 5mm lateral to the first point (D in Fig 4)
- 10mm lateral to the first point (E in Fig 4)

A line perpendicular to the long axis of the canal was then drawn on the mould lateral to the most lateral measurement. The line was referenced to the previously described point on the anterior canal wall and all four measurement points were in turn referenced back to this line. Using the common reference point on the anterior canal wall of the postoperative specimen, an identical lateral perpendicular line was drawn on the mould. Working from lateral to medial according to the references obtained from the preoperative specimen, the four measurement points were marked off and the AP diameters determined.

Measurements were made with a dial vernier sensitive to 0.02mm. The consistent and reproducible nature of the measurement technique was tested and demonstrated in the validation section of this study (See section 2.4).

2.4 Measurement validation

This method of determining AP diameter measurements of the external ear canal has never been described before. It was therefore necessary to determine and demonstrate the reproducible nature of these measurements.

Eleven moulds were made of a single postoperative specimen and sectioned in the usual way. The anterior canal wall reference point was easily identifiable and the AP diameter for each mould was determined at this point.

Results:

Mould number	Measurement (mm)
1	4.70
2	4.72
3	4.76
4	4.70
5	4.76
6	4.74
7	4.76
8	4.76
9	4.74
10	4.76
11	4.74

Validation data analysis:

N	Mean	Standard deviation	Minimum	Maximum
11	4.74	0.0236643	4.70	4.76

It is clear from these results that the moulds are easily standardised and that it is possible to reproduce all measurements just as easily and reliably.

Chapter 3

Results

3.1 Description of Measurement Points

The four points used for measuring are:

- **Point 1** - Most medial aspect of the conchal fold impression
- **Point 2** - Most prominent point of the conchal fold impression
- **Point 3** - 5mm lateral to Point 1
- **Point 4** - 10mm lateral to Point 1

All values are given in millimetres.

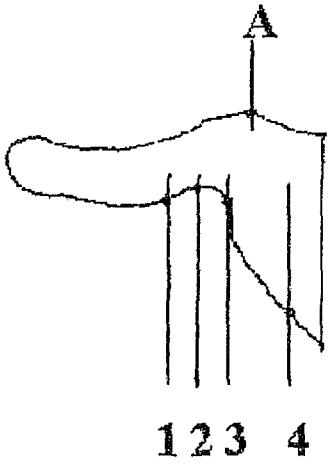

Fig 4. Preoperative mould

3.2 Results for Points 1-4

Point 1

Most medial aspect of the conchal fold impression

Specimen	Left ears		Right ears	
	Preop	Postop	Preop	Postop
7313	4.30	6.58	1.74	2.58
7242	2.82	4.24	1.82	2.34
7354	4.82	6.90	2.84	4.36
7276	2.18	3.94	5.74	6.62
7375	7.94	9.10	7.40	7.40
7255	2.54	4.26	4.10	4.72
7271	2.90	4.12	2.32	3.04
7292	3.88	4.12	2.40	2.94
7279	2.00	2.00	1.52	1.54
7356	1.86	3.56	1.50	1.50
7260	5.88	7.06	3.90	5.18
7357	4.04	5.18	2.92	4.60
7287	4.22	5.62	4.86	4.98
7334	2.86	4.70	3.42	4.46
7285	2.64	3.16	3.28	4.20

<u>Mean values:</u>

Preoperative 3.49mm

Postoperative 4.50mm

Difference 1.01mm

% Increase 29%

Point 2

Most prominent point of the conchal fold impression

Specimen	Left ears		Right ears	
	Preop	Postop	Preop	Postop
7313	5.52	8.28	2.82	4.46
7242	2.26	5.20	1.88	3.14
7354	4.98	7.94	3.40	5.44
7276	2.66	5.04	5.94	7.96
7375	8.40	10.86	7.90	10.00
7255	3.26	6.04	2.54	4.88
7271	3.68	5.56	2.74	3.76
7292	4.06	6.10	3.54	4.96
7279	1.86	3.04	1.74	2.52
7356	3.38	7.96	2.38	2.48
7260	4.92	7.48	3.52	6.64
7357	4.44	6.84	3.90	5.84
7287	4.44	6.58	5.50	6.20
7334	4.08	5.86	4.50	5.98
7285	2.72	3.36	4.22	7.42

Mean values:

Preoperative 3.91mm

Postoperative 5.93mm

Difference 2.02mm

% Increase 52%

Point 3

5mm lateral to point 1

Specimen	Left ears		Right ears	
	Preop	Postop	Preop	Postop
7313	6.38	9.88	5.26	8.52
7242	3.10	6.70	2.78	3.92
7354	7.92	12.06	8.00	9.08
7276	5.22	8.18	12.40	12.72
7375	9.56	12.16	9.10	11.54
7255	6.82	8.80	4.20	6.20
7271	6.18	8.60	5.76	6.98
7292	4.98	8.80	4.48	6.86
7279	3.18	4.62	3.46	4.02
7356	5.42	8.82	3.54	4.54
7260	7.84	9.18	4.82	6.96
7357	5.52	9.66	5.26	8.94
7287	5.86	8.04	6.76	7.48
7334	6.38	9.74	7.34	11.80
7285	3.08	3.94	6.50	10.70

<u>Mean values:</u>

Preoperative 5.90mm

Postoperative 8.32mm

Difference 2.41mm

% Increase 41%

Point 4

10mm lateral to point 1

Specimen	Left ears		Right ears	
	Preop	Postop	Preop	Postop
7313	8.86	14.70	5.68	12.04
7242	5.42	11.98	6.94	8.14
7354	11.18	14.54	13.44	14.44
7276	13.90	16.98	*	*
7375	*	*	15.36	19.16
7255	14.82	17.06	10.12	11.46
7271	11.28	12.00	*	*
7292	11.90	19.38	13.66	18.40
7279	8.30	8.38	8.70	9.66
7356	*	*	9.44	10.24
7260	11.76	12.90	*	*
7357	10.62	12.68	*	*
7287	12.28	12.60	11.36	14.30
7334	17.38	19.14	18.04	20.74
7285	5.86	9.22	18.66	18.96

* Some of the measurements at 10mm lateral to the most medial impression of the conchal fold fell outside the physical limits of the mould - hence no value.

Mean values:

Preoperative 11.46mm

Postoperative 14.13mm

Difference 2.67mm

% Increase 23%

3.3 Statistical analysis

A four-factor analysis of variance was used to determine statistical significance of all the data at a confidence limit of 95%. The four factors being:

- Points : 1-4
- Sides : Left and Right
- Specimens : Fifteen
- Operation : Pre and Post

Overall analysis is significant when considering all four factors with $p<0.05$.

Not surprisingly, the only factor that does not demonstrate statistically significant differences in comparison is Sides with an F value of 1.12 and $p = 0.2916$.

The most important variable for statistical analysis is the **difference** between pre and postoperative measurements. Student's paired t-test was applied to the data to determine statistical validity.

Results:

Point	n	Mean	Standard deviation	T value	Prob>T
1	30	1.01	0.6597094	8.4021115	0.0001
2	30	2.02	0.9271377	11.9413743	0.0001
3	30	2.41	1.2448923	10.6092847	0.0001
4	24	2.67	2.1589515	6.0642967	0.0001

For a confidence limit of 95% the differences between pre and postoperative measurements at all four points have been found to be statistically significant with $p<0.05$.

Chapter 4

Discussion

4.1 Anatomy and Physiology

The external auditory canal (EAC) is the only skin-lined cul-de-sac in the human body.[25] Although the skin is contiguous with the rest of the body surface, it demonstrates certain unique localised adaptations.[26] The primary function of the EAC is to permit the effective transmission of sound from the environment to the tympanic membrane. In order to achieve this it is essential to have a self-cleaning mechanism to maintain a clear passage.

The epidermis of the lateral cartilaginous portion of the EAC contains glands and hair follicles and is identical to skin in other parts of the body. The epithelium covering the tympanic membrane and deep bony meatus, however, differs from body skin in several respects. It is devoid of adnexae, is extremely thin and shows a peculiar pattern of keratinocyte migration.[27] On the tympanic membrane the keratinocytes migrate in a centrifugal direction from the centre. This migration continues peripherally and then laterally along the bony canal wall. It ceases at the junction with the cartilaginous canal where the rows of hair act as ramps to separate the migrating keratin squames from the underlying skin. The purpose of epithelial migration in the EAC is to keep the canal free of debris.[25]

The maintenance of homeostasis in the EAC is dependent on several factors such as epithelial migration, cerumen production, pH and humidity control. These are all

aimed at maintaining an intact epithelium and normal flora. Otitis externa does not occur in the presence of normal intact epithelium.[25]

One of the mechanisms of introducing trauma to the canal skin is by impaired ventilation. This occurs in two ways. Firstly inadequate ventilation of the EAC prevents control of humidity and may lead to stagnation of water. Stagnant water produces epithelial maceration and damage. The increased incidence of otitis externa in humid climates is a well-documented phenomenon.[26] Secondly, Portmann believes that squamous epithelium needs to be adequately aerated at its surface in order to function normally.[14] Inadequate ventilation that prevents normal functioning of the deep canal skin may cause interference with normal keratin migration and lead to an accumulation of debris in the canal. The combination of high humidity and retained keratin debris promotes maceration of the canal skin and creates an ideal environment for bacterial and fungal growth.[5]

Adequate ventilation of the external ear canal is therefore important to ensure normal function of the epithelium and hence to maintain normal homeostasis.

4.2 Conchomeatoplasty effects

4.2.1 Preservation of canal skin

By raising a conchomeatal flap and leaving it pedicled on its inferior and medial aspects, the maximum amount of canal skin is preserved in its natural position. The implication is that normal epithelial migration is not compromised and therefore the canal retains its self-cleaning function.

This is in contrast to other meatoplasty techniques that rely on skin grafting of the external canal.[3,8,9,11,16-18,20-24] In these cases the canal is lined with a split-thickness skin graft, usually from the upper arm. Although good cover is obtained, the transplanted skin does not behave like native epithelium of the external auditory canal. Apocrine and sebaceous glands, which aid in cleansing and the prevention of infection, are absent.[24] Also, the squamous epithelial migratory pattern is altered, predisposing to debris accumulation and localised infection.[9] These patients need to be counselled that periodic inspection and cleaning of the external canal may be required.

4.2.2 Increase in AP diameter

By excising the conchal cartilage ar. . subcutaneous tissue a funnel-shaped meatus is created. In addition, by placing a full-thickness skin graft in the superior aspect of the canal the meatal skin is augmented, which increases the circumference of th(neatus.[6] As expected the maximum effect is found at the point where the conchal fold is most prominent (Point 2). At this point the increase amounted to 52%.

The measurements made on the postoperative specimens demonstrate quite clearly that the surgical procedure of conchomeatoplasty leads to a consistent increase in the AP diameter of the lateral external auditory canal.

4.2.3 Improvement in ventilation

Chronic moisture is a major cause of chronic otitis externa. A narrow external canal leading to poor ventilation is often associated with chronic otitis externa.[6,7] As mentioned before, surface aeration of squamous epithelium appears to be vital for normal function and Portmann proposes a relationship between V (Volume of air circulating) and S (Surface area of skin in contact with the circulating air).[14] The higher the value of V/S the better the chance of having normally functioning squamous epithelium.[3]

Conchomeatoplasty achieves an improvement at both levels:

- By increasing the AP diameter, the volume of the EAC is increased and therefore the volume of circulating air, (V) is increased.
- The surface area of the canal skin (S) is decreased because redundant skin at the posterior aspect of the conchal flap is excised (Only a portion of this skin is utilised for the full-thickness skin graft in the superior aspect of the canal).

The improvement in ventilation resulting from conchomeatoplasty is directly related to the increase in volume of the external auditory meatus. This increase in volume may be calculated from the increase in the AP diameter as demonstrated.

4.2.4 Poiseuille's Equation

The second limb of the aim of this study was to determine whether the improvement in ventilation could be quantified.

Poiseuille's equation is used to determine the flow rate (volume per unit time) for laminar, non-pulsatile fluid flow. It can be applied to any fluid flowing through any "pipe", including air, provided that variations in flow rate over time are ignored.[28]

Obviously, the use of Poiseuille's Equation on airflow through the external auditory canal is suspect. While flow definitely occurs due to the presence of a pressure differential (See page 30), it is debatable whether this is true laminar flow or whether it is a circulatory pattern. However, for purposes of comparing the pre and postoperative situations, the potential for flow is assumed to have a direct relationship to ventilatory capacity and Poiseuille's equation does allow the determination of both qualitative and quantitative order of magnitude information about the effect of EAC size on flow.

$$Q = \frac{\Delta P \, \pi \, r^4}{8 \, \eta \, l}$$

Q = Flow through external auditory canal

ΔP = Pressure difference between two ends of canal

π = Constant

r = Radius of external auditory canal

η = Viscosity

l = Length of external auditory canal

The argument for the validity of Poiseuille's equation as applied to the external auditory canal is as follows:

- It is accepted that the Poiseuille equation may be applied to air flow.[28]
- ΔP refers to the pressure differential between the medial and lateral ends of the EAC. The air temperature in the external canal next to the drum head is in the same range as body temperature.[29] If it is accepted that ambient temperature is usually less than normal body temperature then it stands to reason that there is a temperature gradient between the medial and lateral ends of the canal. Because this occurs in a cavity it implies that a similar pressure gradient should exist. ΔP, however, remains a constant when comparing pre and postoperative flows.
- π, η and l all remain constant in comparing pre and postoperative situations.

Accepting that the Poiseuille equation has a valid application, it becomes apparent that the change in radius of the external canal brought about by conchomeatoplasty has a significant effect on the ventilatory capacity of the EAC. For example, the flow capacity is doubled by an increase of only 19% in the radius of the canal.[30] At the point of maximum benefit, i.e. the conchal fold impression, the increase in diameter from 3.91mm to 5.93mm translates to more than a 5 fold increase in ventilatory capacity of the lateral external auditory canal.

4.3 Further applications

Examining the alteration both in shape and size of the canal after conchomeatoplasty, it becomes clear that the benefit of this procedure is not only limited to improving ventilation. It can also be applied for a number of other indications.[6]

- Problems with hearing aid fitment due to a narrow external canal can be significantly alleviated.
- Wax buildup due to a prominent conchal ledge can be avoided to a large degree. This is especially so since the normal configuration of the canal skin is maintained and therefore epithelial migration is not disturbed.[24,27]
- Conductive hearing loss due to a collapsing external canal can be eliminated.[6]
- Aural toilet is greatly facilitated.[5]

4.4 Evidence-based Medicine

'Hence it comes through defect of Observation, that so many Prescriptions we meet with in the works of the most learned Practitioners fall often short in performing the cures that they promise.'

Dr Johannes Bird, 1657[31]

The question may well be justifiably asked: why go to all the trouble of trying to document something that seems so obvious and logical? The answer is quite simple. In all the referenced literature concerning the topic of surgical treatment for chronic or recurrent otitis externa, not a single article scientifically documents the reason for the clinical improvement seen.

The Medical profession prides itself on not being gullible, and rightly believes in its ability to avoid the error of accepting a result not supported by adequate evidence.[32] As recently as 1982, however, Mitchell was still writing, 'Be prepared for the advice of today to be the discarded or derided dogma of tomorrow.'[33] The introduction of evidence based medicine on a large scale is resulting in a systematic search for, and incorporation of, the valid and useful subsets of such evidence that keeps clinicians up to date and effective.[34]

The demonstration and documentation of improved ventilation of the lateral external auditory canal as achieved by conchomeatoplasty contributes to the database of evidence based medicine. Clinical improvements seen after procedures such as conchomeatoplasty are prone to be scorned as anecdotal and unscientific by many medical scientists. The qualitative methods used in this study helps to bridge the gap between scientific evidence and clinical practice.[35] The value of this was noted long ago when Abelard urged, "The first key to wisdom is assiduous and frequent questioning.... For by doubting we come to enquiry, and by enquiry we arrive at the truth."[31]

Chapter 5

Conclusions

The surgical procedure of conchomeatoplasty was investigated in terms of its ability to bring about a demonstrable and significant improvement in the ventilatory capacity of the lateral external auditory canal. Laboratory experiments on cadaver material have demonstrated a consistent and statistically significant increase in the AP diameter and therefore the volume of the EAC.

By applying Poiseuille's equation to the results of the experiments, a qualitative as well as quantitative improvement in ventilatory capacity of the lateral external auditory canal was documented. This improvement amounted to a 5 fold increase in ventilatory capacity at the point where the conchal cartilage projected most prominently into the posterior canal wall, which is also one of the narrowest points of the cartilaginous canal. The documentation of this improvement in ventilation supports the clinical contention of improved ventilation leading to an improvement in chronic or recalcitrant otitis externa.

This method of measurement has never been described before. Neither has the ventilatory improvement of any meatoplasty or canalplasty procedure been documented before.

The measurement technique developed for this study will enable future comparisons of different surgical techniques to be undertaken in an objective and unbiased fashion.

References

1. Bojrab DI, Bruderly T, Abdulrazzak Y. Otitis externa. Otolaryngol Clin North Am 1996 Oct;29(5):761-82.

2. Selesnick SH. Otitis externa: Management of the recalcitrant case. Am J Otol 1994 May;15(3):408-12.

3. Goodman WS, Middleton WC. The management of chronic external otitis. J Otolaryngol 1984;13(3):183-86.

4. Grenner J. Meatoplasty of the ear canal. J Otolaryngol 1996;25(3):188-90.

5. Martin-Hirsch DP, Smelt GJC. Conchal flap meatoplasty. J Laryngol Otol 1993 Nov;107:1029-31.

6. Hunsaker DH. Conchomeatoplasty for chronic otitis externa. Arch Otolaryngol Head Neck Surg 1988 April;114:395-98.

7. Hirsch BE. Infections of the external ear. Am J Otolaryngol 1992 May;13(3):145-55.

8. Herdman RCD, Wright JLW. Surgical treatment of obliterative otitis externa. Clin Otolaryngol 1990;15:11-14.

9. Harvey SA. Skin grafting in Otology. Laryngoscope 1997 Sep;107:1199-202.

10. Donaldson JA, Duckert LG. Meatoplasty. Laryngoscope 1981 Oct;91:1757-58.

11. Chole RA. Meatoplasty using inferiorly based island pedicle flap for congenital aural atresia. Laryngoscope 1983 July;93:954-55.

12. Osborne JE, Martin FW. Endaural meatoplasty for mastoid cavities. Clin Otolaryngol 1990;15:453-55.

13. Mikaelian DO. Revision meatoplasty. Laryngoscope 1989 June;99:662-64.

14. Portmann M. Meatoplasty and conchoplasty in cases of open technique. Laryngoscope 1983 April;93:520-22.

15. Mirck PGB. The M-meatoplasty of the external auditory canal. Laryngoscope 1996 March;106:367-69.

16. Stucker FJ, Shaw GY. Revision meatoplasty: Management emphasizing de-epithelialized postauricular flaps. Otolaryngol Head Neck Surg 1991 Sep;105(3):433-39.

17. Cremers CWRJ, Smeets JHJM. Acquired atresia of the external auditory canal. Surgical treatment and results. Arch Otolaryngol Head Neck Surg 1993 Feb;119:162-64.

18. McDonald TJ, Facer GV , Clark JL. Surgical treatment of stenosis of the external auditory canal. Laryngoscope 1986 Aug;96:830-33.

19. Lambert PR, Dodson EE. Congenital malformations of the external auditory canal. Otolaryngol Clin North Am 1996 Oct;29(5):741-60.

20. Eichel BS, Simonton KM. Stenosis of the external auditory meatus secondary to chronic external otitis treated by a simplified surgical method: Report of a case. Laryngoscope 1965;75:16-21.

21. Paparella MM. Surgical treatment of intractable external otitis. Laryngoscope 1966;76:1136-47.

22. Parisier SC, Levenson MJ, Hanson MB. Canalplasty. Otolaryngol Clin North Am 1996 Oct;29(5):867-86.

23. Paparella MM, Meyerhoff WL. Meatoplasty. Laryngoscope 1978;88:357-59.

24. McCary WS, Kryzer TC, Lambert PR. Application of split-thickness skin grafts for acquired diseases of the external canal. Am J Otol 1995 Nov;16(6):801-5.

25. Kelly KE, Mohs DC. The external auditory canal. Anatomy and physiology. Otolaryngol Clin North Am 1996 Oct;29(5):725-39.

26. Jahn AF, Hawke M. Infections of the external ear. In: Cummings CW, Fredrickson JM, et al, editors. Otolaryngology-Head and Neck Surgery, ed 2, vol 4. St. Louis: Mosby-Year Book, 1993:2787-94.

27. Vennix PPCA, Kuijpers W, Peters TA Tonnaer ELGM, Ramaekers FCS. Epidermal differentiation in the human external auditory meatus. Laryngoscope 1996 April;106:470-75.

28. Koehler KR. "Poiseuille's equation." College physics for students of biology and chemistry.1996. <http://www.physics.uq.edu.au:8001/ph128/text.html> (13 July 1998).

29. Pau HW, Hartwein J, Westhofen M. Lufttemperatur im ausseren gehorgang. Experimentelle untersuchungen in bezug auf die radikalhohlen-chirurgie [abstract]. Laryngorhinootologie 1990 March;69(3):135-39.

30. Ganong WF. Review of medical physiology. 13th ed. Norwalk, Connecticut: Appleton & Lange, 1987:482-83.

31. Walker ARP, Labadarios D. Evidence-based medicine - how much does it explain? [editorial]. S Afr Med J 1996 Aug;86(8):939-40.

32. Riffenburgh RH. Reverse gullibility and scientific evidence. Arch Otolaryngol Head Neck Surg 1996 June;122:600-1.

33. Mitchell JRA. "But will it help my patients with myocardial infarction?" The implications of recent trials for everyday country folk. BMJ 1982 [illegible] ,285:1140-48.

34. Ellis J, Mulligan I, Rowe J, Sackett DL. Inpatient general medicine is evidence based. Lancet 1995 Aug;346:407-10.

35. Green J, Britten N. Qualitative research and evidence based medicine. BMJ 1998;316:1230-32.

Author Van Schalkwyk C R
Name of thesis Conchomeatoplasty Ventilatory Implications Van Schalkwyk C R 1999

PUBLISHER:
University of the Witwatersrand, Johannesburg
©2013

LEGAL NOTICES:

Copyright Notice: All materials on the University of the Witwatersrand, Johannesburg Library website are protected by South African copyright law and may not be distributed, transmitted, displayed, or otherwise published in any format, without the prior written permission of the copyright owner.

Disclaimer and Terms of Use: Provided that you maintain all copyright and other notices contained therein, you may download material (one machine readable copy and one print copy per page) for your personal and/or educational non-commercial use only.

The University of the Witwatersrand, Johannesburg, is not responsible for any errors or omissions and excludes any and all liability for any errors in or omissions from the information on the Library website.