

https://dspace.org/

Problems of calcification of teeth and bone

Irving., J. T.

1958-08
http://hdl.handle.net/10539/19181
Irving, J. T. 1958. Problems of calcification of teeth and bone. Journal of the DASA; 13(8): 295-302

Downloaded from a DSpace repository. https://dspace.org/

THE Journal OF THE D.A.S.A.

DIE Tydskrif VAN DIE T.V.S.A.

AUG., 1958.
Vol. 13. No. 8.

PROBLEMS OF CALCIFICATION OF TEETH AND BONE*

J. T. IRVING, M.A., PH.D., M.D., F. ODONT. SOC. S.A.

Joint Dental Research Unit of the C.S.I.R. and the University of the Witwatersrand, Johannesburg

WITHIN the last decade, interest in calcification processes in teeth and bone has increased to a great extent, as can be seen from the large number of books and accounts of symposia devoted to this subject that have recently appeared (e.g. McLean and Urist, 1955; Irving, 1957). In this paper, a brief review of current views will be given and an account of some of the research work done at the Unit.

The chemical composition of dentin and bone appears to be very similar. The organic matrix is composed of collagen with a very small amount of mucopolysaccharide in the ground substance, and the inorganic phase consists of apatite crystals. Epiphyseal cartilage, and cartilage in general, has a much higher content of mucopolysaccharides, chiefly chondroitin sulphate. The chemistry of enamel is not so well defined. The protein matrix, eukeratin, differs from keratin in having an appreciable content of hydroxyproline (Hess *et al*, 1953). Mucopolysaccharides are present in enamel, at least during the early stages of its formation. The inorganic phase consists of apatite crystals, but these are bigger than those of dentin or bone.

The processes of calcification of dentin and bone are essentially similar. In dentin a collagenous matrix is laid down (predentin) and calcified a definite period later — 24 hours in the case of the rat incisor. In intramembranous bone formation, a similar matrix is laid down and calcified almost but not quite simultaneously; a narrow preosseous matrix is usually found (Vincent, 1955). In endochondral calcification, bone is laid down on a cartilaginous scaffold, and is subsequently remodelled to a considerable extent, the process of laying down of bone being virtually the same as in intramembranous bone. Enamel formation is much less understood. It would appear that calcification is a gradual process, accompanied by the removal of protein and water (Deakins and Burt, 1944).

The inorganic phase in all three tissues is an apatite, probably with the formula $[Ca_3(PO_4)_2]_n.Ca(OH)_2$. The crystals of this compound are minute and are barely visible under the electron microscope. They are surrounded by a water of hydration and their total surface area is tremendous — over 100 acres in an adult man. Both isoionic and heteroionic exchange of many ions can take place in the

*Based on a paper read to the Northern Transvaal Branch of the Dental Association of South Africa on June 26, 1958.

apatite lattice and adsorption can occur on the surface of the crystal. Thus although the crystalline structure is that of an apatite, the chemical composition can vary widely. During growth crystals form and the existing ones increase in size, and even after growth has ceased, recrystallization and exchange of ions goes on continually (McLean and Urist, 1955). These latter processes are faster in bone, but also occur in dentin and enamel.

Collagen is the protein of all connective tissues. It is laid down by fibroblasts in soft tissues, by the pulp (probably as Korff fibres) in dentin, and by osteoblasts in bone. It is metabolically very inert. Recently it has been much studied, especially with the electron microscope, when it is seen as fibrils with a characteristic cross-banding at 640 Å intervals. Chemically all collagens seem very similar as far as amino acid content is concerned, having a low content of aromatic amino acids and containing glycine and hydroxyproline in large amounts. The cross-bandings are thought to be high in acidic and basic amino acids, and it is here that apatite crystals are predominantly deposited during calcification (Robinson and Watson, 1955).

A problem that has interested the Dental Research Unit is why all tissues containing collagen do not calcify. It was decided (Solomons and Irving, 1958) to see if there were any fundamental differences between the collagens of soft and hard tissues, using Sanger's dinitrofluorobenzene (DNFB) method (1945). This reagent reacts with free amino groups in proteins and forms a stable dinitrophenyl (DNP) compound; after hydrolysis of the protein, the DNP compounds can be separated and estimated by means of chromatography (Fig. 1). Proteins have two types of free amino groups — the terminal groups at the end of the polypeptide chain and those on side chains such as the ϵ amino group of amino acids like lysine and hydroxylysine. The following tissues were investigated: ox hide and achilles tendon, rat tail tendon, ox bone and dentin, and human dentin.

Soft tissue collagens had no N-terminal amino groups and about two-thirds of their ϵ amino groups reacted with DNFB. Human and ox dentin had no free N-terminal amino groups and ox bone had a very minute amount. About 10 per cent of the total number of ϵ amino groups of the hard tissues reacted with DNFB, these results applying to the fully calcified tissues.

The hard tissues were then decalcified by putting them into solutions of hyrdochloric acid, trichloracetic acid or ethylene-diaminetetra-acetic acid (EDTA) at 4° C. and at intervals the number of free N-terminal and ϵ amino groups was determined, and at the same time the degree of demineralization was estimated.

Dentin.—The reactive N-terminal amino groups either did not change or rose to an insignificant extent during the demineralization of both ox and human dentin. On the other hand, the number of reactive ϵ amino groups (chiefly of lysine and hydroxylysine) rose in a linear manner when plotted against demineralization, so that when decalcification was complete, over 96 per cent of the total number in the protein reacted (Fig. 2).

Bone. When decalcification of this tissue was first carried out, followed by dinitrophenylation, most erratic results were obtained as decalcification proceeded. While the number of N-terminal amino groups did not alter, the amount of free ϵ amino groups rose or fell in an unpredictable manner. It is possible, using EDTA, to combine the processes of demineralization and dinitrophenylation so that they can be carried out simultaneously. When this was done, it was found that a linear relationship also obtained with bone, between the number of reactive ϵ amino groups and the degree of decalcification, over 93 per cent of the ϵ amino groups being free to react with complete demineralization (Fig. 2). In the case of dentin, it did not matter if the two procedures were simultaneous or successive. There is some difference, probably at the molecular level, between the collagen of dentin and bone. When the apatite crystals have been removed from bone collagen, it must undergo some molecular rearrangement during which the ϵ amino groups have their activity masked, unless they are "caught" at once by DNFB. Dentin collagen is much more stable, but it too, if stored for a long time, loses the reactivity of its ϵ amino groups.

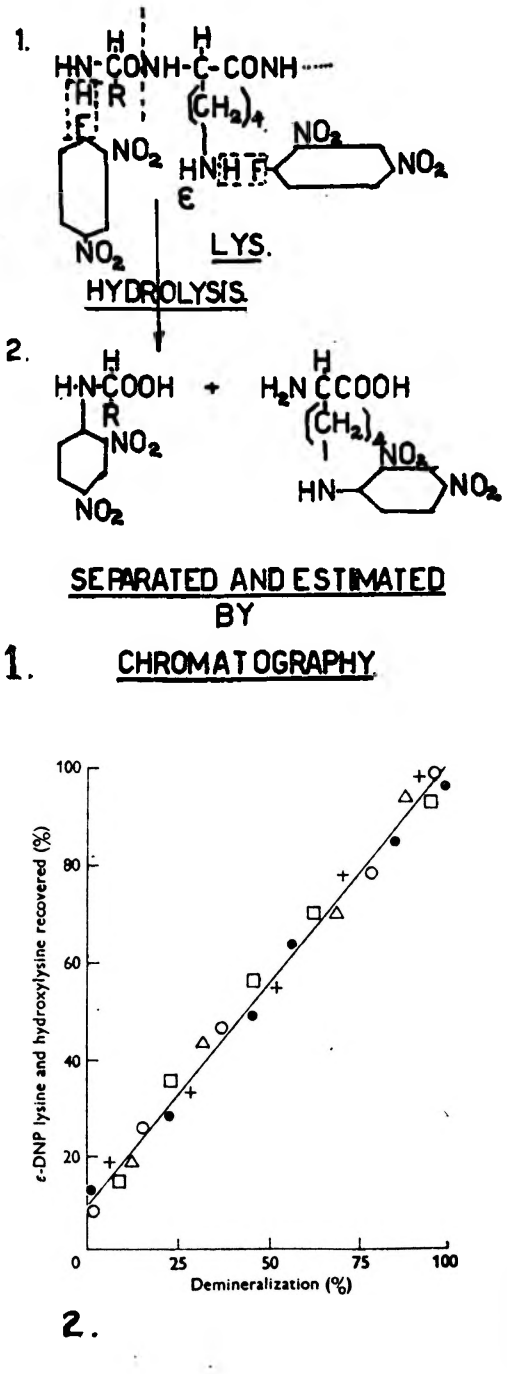

Soft tissue collagen. This was treated with the demineralizing agents employed on dentin and bone, but no change at all occurred in the number of reactive N-terminal and ε amino groups.

Thus there seems to be a fundamental difference between the collagens of soft and hard tissues, and possibly between those of dentin and bone. Soft tissue collagen has only about two-thirds of its ε amino groups in a reactive state, whereas in hard tissue collagen, after complete decalcification, virtually all these groups are free. Furthermore, it is obvious that there is a very intimate association between the ε amino groups and the apatite crystal. The concept we have developed is that calcification being a process of crystallization of apatite, a specific

FIG. 1.—Chemical reactions involved in Sanger's DNFB method.

FIG. 2.—Availability of ε-lysyl and hydroxylysyl amino groups of hard tissue collagens to DNFB during demineralization. ○, ●, denote successive demineralization and dinitrophenylation of ox dentin and human dentin respectively; +, □, △, denote simultaneous demineralization and dinitrophenylation of ox dentin, ox bone and human dentin respectively. (Reproduced with permission from the *Biochemical Journal*).

collagen, with charges at specific points on the amino acid chain, could form a "template" for the seeding of the crystals. The fact that the crystals are first deposited at the cross-banding, where basic and acidic amino acids are believed to be concentrated, supports this idea. Thus for calcification to occur in a tissue, a specific type of collagen must be present and this may well explain why some tissues containing collagen will calcify, while others do not.

In order to see if "natural" decalcification or lack of calcification was accompanied by an increase in the number of reactive ε amino groups, calf bone was compared with ox bone, and dentin from rats with rickets with dentin from normal rats. In each case, the number of free ε amino groups in the calcified tissue was more than double in the young or rachitic material, than in the mature bone or dentin, which

appears to be an interesting confirmation of our concept.

Another aspect of calcification in which we have become increasingly interested is the role played by mucopolysaccharides in the mineralization of tissues. These mucopolysaccharides are polysaccharides incorporating hexosamines, and the best studied are the acid mucopolysaccharides having hexuronic acid in their molecule, and a group esterified with sulphuric acid known as the chondroitin sulphates, which occur in large amounts in cartilage, and as heparin, the well known anticoagulant. The ground substance of all connective tissues contains mucopolysaccharides; cartilage has a high content of chondroitin sulphate, but dentin and bone contain much less.

The interest in this context is the evidence that mucopolysaccharides and especially chondroitin sulphate, are concerned in calcification. Using radiosulphur Bélanger (1955a) found a relationship between the distribution of this element and the site of calcification in epiphyseal cartilage. Earlier Boyd and Neuman (1951) had suggested that the binding of calcium by cartilage was connected with its sulphate content. Acid mucopolysaccharides stain metachromatically with toluidine blue and metachromasia has been found to be greatest in areas of cartilage about to become calcified and in areas about to become bone (Freeman, 1956). Vincent (1955) found a preosseous zone in osteones which was orthochromatic with toluidine blue but the reaction changed to metachromasia where the tissue began "to manifest a strong affinity for calcium" (Lacroix, 1956). Other experiments which show competition of calcium with other ions such as strontium and also with toluidine blue, during calcification, support the idea that chondroitin sulphate is involved.

Work with growing teeth, using radiosulphur, has shown very similar results. Bélanger (1954) found sulphur to be laid down at the dentin-predentin junction shortly after injection, and to move "outwards" with the accretion of more dentin. The same was seen in newly formed enamel (Bélanger, 1955b), and the interpretation in each tissue was that a sulphated mucopolysaccharide was involved in calcification.

FIG. 4.—Longitudinal section of labial side of rat incisor tooth stained with Sudan Black after pyridine treatment. (*a*) enamel organ, (*b*) organic enamel, (*c*) dentin, (*d*) predentin, (*e*) odontoblasts. Note deeply stained line at dentin-predentin junction and also the deeper staining of the enamel nearest the ameloblasts and also to the left of the section, as the enamel is calcifying. x. 140.

FIG. 5.—Part of the maxillary alveolar bone of rat stained with Sudan Black after pyridine treatment. At the top is an osteoclast, and below (*a*) a row of osteoblasts. A deeply staining line is seen on the appositional side separated from the osteoblasts by a narrow preosseous layer. x 430. (Reproduced with permission from *Nature*).

FIG. 6.—Longitudinal section of tibial epiphyseal cartilage of young rat, stained with Sudan Black after pyridine treatment. Note the staining of the matrix between the hypertrophic cells (*a*). x 220.

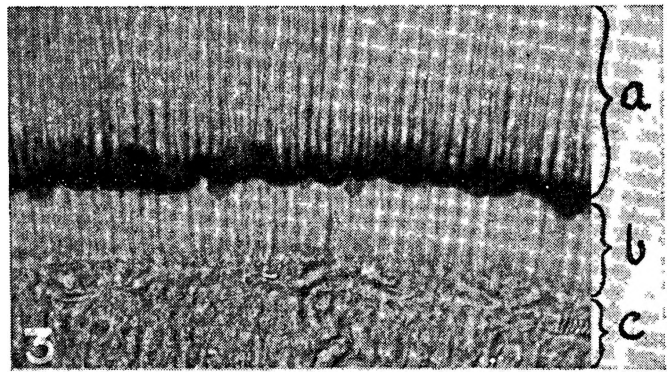

FIG. 3.—Transverse section of labial side of rat incisor tooth, stained with Sudan Black after pyridine treatment. (*a*) dentin, (*b*) predentin, (*c*) pulp. Note darkly stained line at dentin-predentin junction. x 430. (Reproduced with permission from *Nature*).


a
b
c
d
e
4

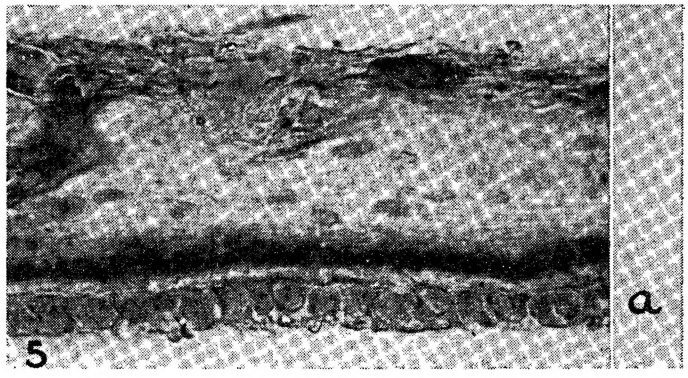
a
5

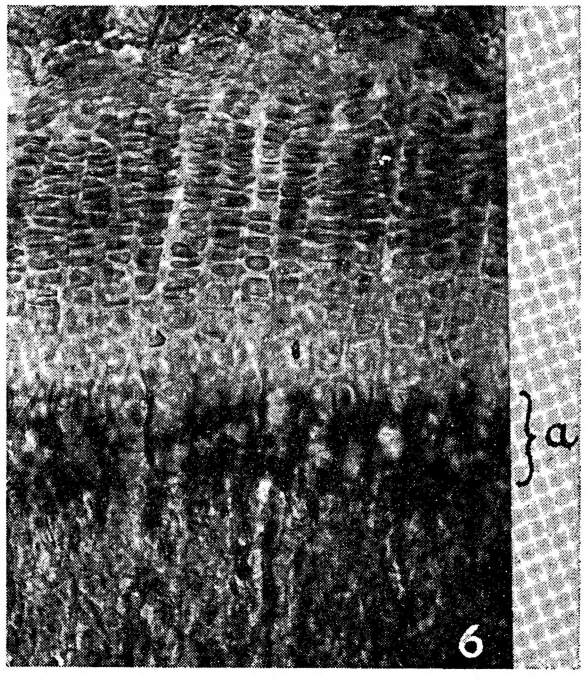
a
6

The only puzzle that has not been explained is why *all* cartilage, which contains chondroitin sulphate, and is very metachromatic, does not necessarily calcify.

In tackling this problem at the Unit, it was noticed that Sudan Black B stains heparin in Mast cells strongly, but no other mucopolysaccharide. Hadadian and Pirrie (1948) found that pyridine precipitated hyaluronic acid, and it was thought that by such means a more specific reaction might be obtained.

When tissues were stained with Sudan Black with no other treatment, they were a uniform pale blue, except for the granules of Mast cells which were a deep blue-black. When, however, the tissues were first treated with pyridine, quite a different picture was found, and all areas where calcification was being initiated stained a deep blue. Thus in dentin, the dentin-predentin junction stained, (Fig. 3) and in enamel, the part which was becoming acid-soluble (Fig. 4). Bone was bounded by a thin preosseous layer which did not stain, but there was an intensely staining



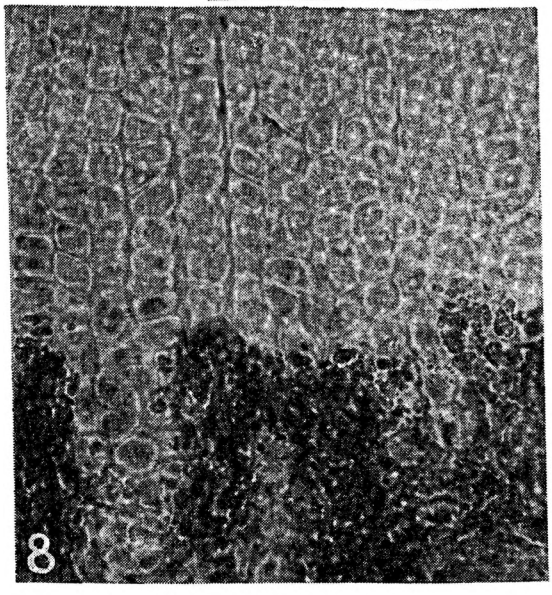

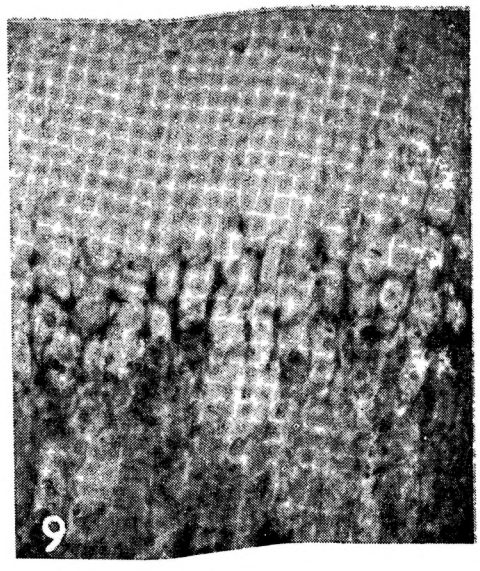

line where the preosseous layer joined the calcified bone (Fig. 5). In epiphyseal cartilage the matrix stained between the hypertrophic cells (Fig. 6) at the level where calcification begins (Irving, 1958).

In undecalcified teeth toluidine blue stained strongly only the dentin-predentin junction (Fig. 7), thus giving a similar picture to Sudan Black, but in epiphyseal cartilage the entire width stained metachromatically, so there was not correlation here between the two stains.

A number of other techniques were employed in an endeavour to identify the sudanophil component. It was not affected by pepsin or by hyaluronidase, but this latter enzyme is known not to be very effective on histological material. Perchloric acid, which removes ribonucleic and deoxyribonucleic acids, likewise failed to abolish the stain. The sudanophil areas were not specifically stained with the periodic acid-Schiff reagents. The methylene blue extinction method indicated that a lightly sulphated mucopolysaccharide was possibly involved.

FIG. 7.—Longitudinal section of labial side of rat incisor stained with toluidine blue. (*a*) enamel, (*b*) dentin, (*c*) predentin, (*d*) odontoblasts. Note the intense staining line at the dentin-predentin junction. x 430.

FIG. 8.—Longitudinal section of tibial epiphyseal cartilage of rachitic rat, stained with Sudan Black after pyridine treatment. No staining at all is seen round the hypertrophic cells. x 220.

FIG. 9.—Section of area similar to that in Fig. 8. Rachitic rat treated with vitamin D 4 days previously. The sudanophil material has reappeared round the hypertrophic cells. x 220.

In order to confirm that the Sudan Black staining was really associated with calcification, a number of rats with pronounced rickets were studied. The epiphyseal cartilage of these rats showed no Sudan Black staining, (Fig. 8), but three days after vitamin D dosage, the stainable material returned at the same time that calcification of the cartilage recommenced, (Figs. 9 and 10). Exactly the same was found in bone. In dentin during rickets, the predentin becomes wide, and dentin calcification is retarded but not stopped, (Fig. 11). When vitamin D was given, the sudanophil material reappeared at the right distance from the pulp, and was also scattered throughout the rachitic predentin as proper calcification was resumed, (Fig. 12).

It thus appears certain that the sudanophil material is associated with the initiation of calcification and is probably a mucopolysaccharide, but not chondroitin sulphate. Its exact nature is as yet unknown — experiments are now under way in an attempt to identify it.

To reconcile these findings with those reported above on collagen, the following tentative theory has been evolved. The sudanophil substance acts as a "primer" for calcification, since in its absence no calcification occurs. The specific type of collagen is needed for the seeding of the crystals and also for the apatite crystals to "stick to", forming a stable calcified structure such as dentin and bone. Once the crystal of apatite is formed, the role of the mucopolysaccharide is over and it is possibly removed. The collagen's function now is the maintenance of the structure of the mineralized material.

SUMMARY

A brief account is given of the composi-

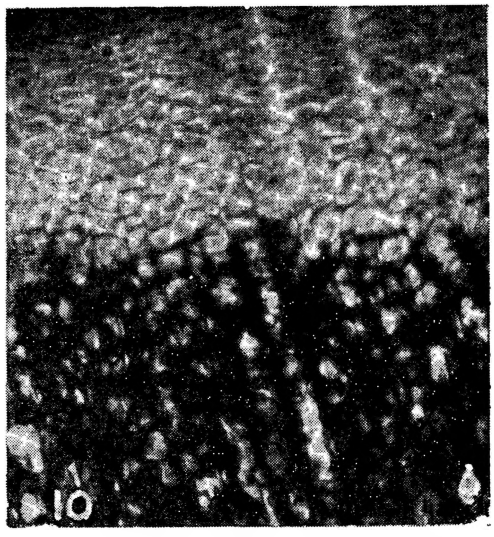

FIG. 10.—Same section as Fig. 9, stained with silver nitrate to show calcification. Note the intense reaction, and also that in Fig. 9 only the area where calcification is being initiated stains with Sudan Black. x 220.

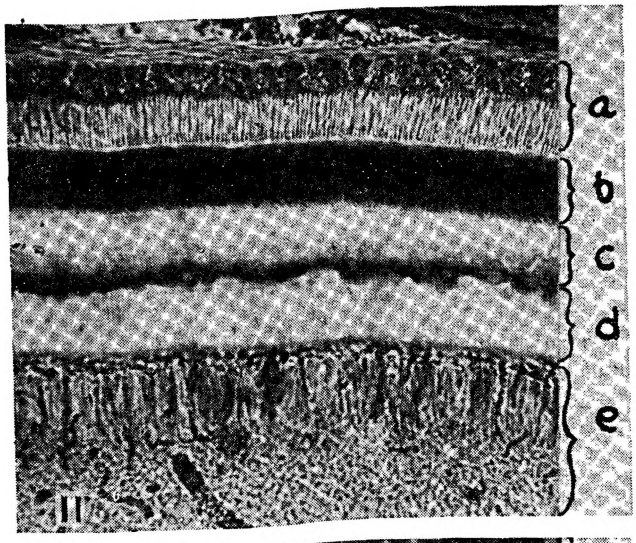

FIG. 11.—Longitudinal section of labial side of incisor of rachitic rat. (*a*) enamel organ, (*b*) enamel, (*c*) dentin, (*d*) predentin, (*e*) odontoblasts and pulp. Note in comparison with Fig. 4 that the predentin is wider, but calcification has not stopped and the sudanophil material is still present. x 140.

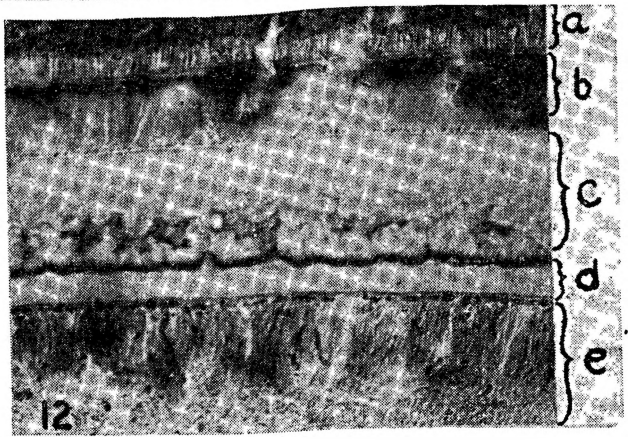

FIG. 12.—Section of area similar to that in Fig. 11. Rachitic rat dosed with vitamin D 4 days previously. Notation same as Fig. 11, save that (*c*) is a mixture of dentin and calcifying predentin. Note the line of new calcification at the dentin-predentin junction and the calcification occurring in the rachitic predentin. x 140.

tion and some of the factors involved in the calcification of dentin, enamel and bone.

From work done at the Dental Research Unit it is concluded that a specific mucopolysaccharide in dentin and bone acts as a primer for mineralization, and that the calcifiability of these tissues resides in a specific type of collagen which differs in several ways from that of the soft tissues.

REFERENCES

BÉLANGER, L. F. (1954). Canad. J. Biochem. Physiol., **32,** 161.

BÉLANGER, L. F. (1955a). Proc. Soc. exp. Biol. Med., **88,** 150.

BÉLANGER, L. F. (1955b). J. dent. Res., **34,** 20.

BOYD, E. S., and NEUMAN, W. F. (1951). J. biol. Chem., **193,** 243.

DEAKINS, M., and BURT, R. L. (1944). J. biol. Chem., **156,** 77.

FREEMAN, D. J. (1956). Arch. Path., **61,** 219.

HADADIAN, Z., and PIRRIE, N. W. (1948). Biochem. J., **42,** 260.

HESS, W. C., LEE, C. Y., and NEIDIG, B. A. (1953). J. dent. Res., **32,** 585.

IRVING, J. T. (1957). Calcium Metabolism. London: Methuen & Co. Ltd.

IRVING, J. T. (1958). Nature, **181,** 704.

LACROIX, P. (1956). Bone structure and metabolism. London: Ciba Foundation Symposium.

MCLEAN, F. C., and URIST, M. R. (1955). Bone. An introduction to the physiology of skeletal tissue. Chicago: Univ. of Chicago Press.

ROBINSON, R. A., and WATSON, M. L. (1955). Ann. N.Y. Acad. Sci., **60,** 596.

SANGER, F. (1945). Biochem. J., **39,** 507.

SOLOMONS, C. C., and IRVING, J. T. (1958). Biochem. J., **68,** 499.

VINCENT, J. (1955). Recherches sur la constitution de l'os adulte. Bruxelles: Editions Arscia.